

An Atlas of
PELVIC OPERATIONS

PARSONS AND ULFELDER

An Atlas of

PELVIC OPERATIONS

By LANGDON PARSONS, M.D.

Professor of Gynecology, Boston University School of Medicine
Chief, Department of Gynecology, Massachusetts Memorial Hospital
Gynecologist, Palmer Memorial Hospital
Gynecologist, Massachusetts Department of Public Health,
Hospital for Cancer at Pondville, Massachusetts

And HOWARD ULFELDER, M.D.

Clinical Professor of Gynecology, Harvard Medical School
Chief of Gynecology, Massachusetts General Hospital
Chief of Staff, Vincent Memorial Hospital
Gynecologist, Massachusetts Department of Public Health
Hospital for Cancer at Pondville, Massachusetts

Illustrated by Mildred B. Coddington, A.B., M.A.

Surgical Artist, Department of Surgery, Harvard Medical School
and Peter Bent Brigham Hospital, Boston, Massachusetts

W. B. SAUNDERS COMPANY

Philadelphia London

akushner-lib.ru

COPYRIGHT, 1953, BY W. B. SAUNDERS COMPANY

Copyright under the International Copyright Union

Reprinted, February, 1954, June, 1956, and November, 1957

ALL RIGHTS RESERVED

*This book is protected by copyright. No part of it may
be duplicated or reproduced in any manner without
written permission from the publisher*

MADE IN U. S. A. Press of W. B. SAUNDERS COMPANY, PHILADELPHIA

LIBRARY OF CONGRESS CATALOG CARD NUMBER 53-5311

DEDICATED TO

JOE VINCENT MEIGS, M.D.

*This Atlas in a very real sense is the product of
the school of gynecological surgery which he has developed
and in which we operate as grateful students*

akusher-lib.ru

Preface and Acknowledgments

The purpose of this Atlas is to teach the technical details of pelvic surgical procedures by means of illustrations.

The format of the book is designed to permit a surgeon to follow a detailed description of the operation by word as well as by drawings or to combine the two if he chooses.

The written material on each page applies only to the plate which accompanies it. This method of necessity restricts the amount of descriptive writing, but we hope that the drawings are in sufficient detail to be almost self-explanatory. General matters are discussed in the introduction to each section.

It is our intention that each step in the operative procedure shall have a definite reason for its description. In this manner the operation proceeds according to a plan of reasonable steps rather than as a memory exercise. Frequently in the past operative descriptions have indicated that certain dangers are inherent in a given operation, but at no point is the surgeon told how the danger may be avoided or what to do about it if it is encountered. The steps of the operative procedures recorded here are designed to keep the operator out of trouble as well as to point out the exact moment in the operation when trouble is most likely to occur.

The operations described in this Atlas do not represent the only procedures for each given situation. Rather than present a description of multiple procedures of comparable usefulness, we have selected the operative technique regarded as standard in the institutions where we work. The methods illustrated have been applied repeatedly by surgeons of varying degrees of proficiency, and have proved to be safe and effective. Complications have usually been avoided, while the morbidity and mortality have been low.

Not all pelvic operations have been described. Many textbooks continue to include surgical procedures now rarely used. Here an attempt has been made to select for the reader the operations in common use.

Indications for or against a given operative procedure may vary from year to year. An operation may be sound but the indication for its use open to question. We have made no attempt to influence the train of thought which leads to a decision as to the choice of operative procedure. However, once the surgeon has elected to perform a specific operation

this book will provide a detailed "road map" which will guide him through to a satisfactory conclusion with the greatest possible ease and safety. Since we are not writing a textbook of surgery, consideration of the physiological aspects of preoperative and postoperative management is not included.

It is our hope that the procedures outlined will be useful to surgeons interested in pelvic operations as well as to those men who limit their practice to this specialty. Inasmuch as the preoperative diagnosis of pelvic conditions may not always be accurate, and unsuspected pathology may be encountered in the pelvis at the time of laparotomy, the Atlas includes many general surgical procedures outside the field of what is usually considered gynecological surgery. It is our feeling that the surgeon operating in the pelvis should be capable of dealing with the unexpected problem. Whether or not the surgeon feels that he is capable of performing any given procedure is a matter of judgment based on conscience and experience. When the operator does not feel qualified to perform the definitive surgery required by the unexpected situation, other less formidable operations are outlined which may serve as stages for subsequent treatment.

A section on radical surgery for malignant disease of the pelvic organs is included because we wish to emphasize that this type of surgery in scope and magnitude differs markedly from the operative procedures employed for benign disease within the same organs. Operations for cancer have as their primary aim complete eradication of the malignancy. This presupposes a thorough understanding on the part of the surgeon of the life history of the particular neoplasm encountered and a working knowledge of the normal pathways of extension. To be successful both the local disease process and the regional areas to which it may spread must be eliminated. The emphasis is on cure. It is not enough to achieve a limited survival or palliation when a more extensive surgical procedure might bring about permanent salvage.

To understand thoroughly the varied ramifications of the malignant process requires years of specialized study. Such training is possible for only a few men in metropolitan treatment centers, and of necessity it cannot be a regular part of the experience of every surgeon and gynecologist. Unfortunately

malignancy does not respect the geographical distribution of these specialized hospitals. The problem involved in the management of neoplasm in the pelvis must often be solved by operators who have little specialized training in this field.

With this in mind the section on malignant disease has been added to this book in the hope that the surgeon who feels himself qualified may find the description of these procedures helpful to him in carrying out what we consider to be adequate surgery for the common pelvic neoplasms.

This book could not have been written without the encouragement and helpful assistance of our colleagues and teachers as well as those directly concerned with the technical details of its production.

We are primarily indebted to the men who instilled in us principles of surgical technique. Dr. George W. Brewster and Dr. Arthur W. Allen were a constant inspiration. To Dr. Joe V. Meigs we owe a never-ending debt of gratitude for teaching us all we know of gynecology. In the preparation of this book his help and encouragement have been unceasing.

Our colleagues and the house staff of the hospitals in which we work have been most cooperative. To the administration and staff of the Massachusetts Memorial Hospital, the Massachusetts General Hospital, the Vincent Memorial Hospital, the Massachusetts Department of Public Health Hospital for Cancer at Pondville, Massachusetts, and to the Palmer Memorial Hospital of the New England Deaconess Hospital we extend our thanks.

We would like to express our appreciation for the helpful spirit which Miss Signe Windhol exhibited in the long and tedious hours of secretarial labor.

Were it not for the unstinting enthusiasm of Miss Mildred Codding the publication of this Atlas would have been impossible. Her friendly cooperation made the sketching in the operating room and revision of drawings a pleasure. Our admiration for her art and her personal qualities is boundless.

Finally we congratulate each other that the Atlas is at last in publication and that we remain firm friends.

LANGDON PARSONS
HOWARD ULFELDER

Table of Contents

SECTION I
ABDOMINAL OPERATIONS

CONSIDERATIONS PRELIMINARY TO ALL ABDOMINAL SURGERY 3
 Position for Curettage—Catheterization—Examination 6
 Curettage. 7
 Positioning at Table—Abdominal Incision 8
 Opening the Abdomen. 10
 Exploration of the Upper Abdomen. 11
 Application of Tenaculum to Fundus Uteri. 12

HELPFUL HINTS FOR HYSTERECTOMY 13
 Technique of Total Hysterectomy—Ovaries not Removed 14
 Closure of Abdominal Wound 22

MODIFICATIONS OF TOTAL HYSTERECTOMY 23
 Removal of Ovary and Tube—Peritonealization 24
 Supracervical Hysterectomy 26
 Marshall-Marchetti Operation for Stress Incontinence 28
 Hysterectomy in Presence of Large Cervical Fibroid. 30
 Mobilization of Adnexa and Uterus 32
 Peritonealization of Defects in Cul-de-Sac 33
 Closure of Vaginal Apex—Splitting Cervical Fascia 34

CONSERVATIVE OPERATIONS. 35
 Excision of Endometrial Implant—Endometriosis. 36
 Olshausen Suspension 38
 Baldy-Webster Suspension. 39
 Shortening Uterosacral Ligaments 40
 Myomectomy. 41
 Presacral Neurectomy 42

OPERATIONS ON TUBE AND OVARY 45
 Salpingo-oophorectomy. 46
 Salpingectomy 47
 Removal of Small Ovarian Cyst 48
 Oophorectomy 49
 Interligamentous Cysts. 50
 Wedge Resection and Exploratory Incision of Ovary. 52
 Sterilization Procedures—Irving and Pomeroy Methods 53
 Falk Tubal Exclusion Procedure 54
 Plastic Operations for Restoration of Tubal Patency 55
 Excision of Fimbriated End of Fallopian Tube. 56
 Cornual Resection of Tube 58

OPERATIONS INVOLVING THE INTESTINE 59
 Repair of Injured Small Bowel 60

Excision of Meckel's Diverticulum 61
 Enteroenterostomy (Side-to-Side) 62
 Resection of Small Bowel and Side-to-Side Anastomosis. 64
 Resection of Small Bowel and End-to-End Anastomosis 66
 Ileocolostomy 68
 Large Bowel Resection and Anastomosis 70
 Colostomy 72
 Closure of Colostomy 73
 Appendectomy 74

OPERATIONS INVOLVING THE URINARY TRACT 75
 Repair of Bladder Damage—Suprapubic Cystotomy 76
 End-to-End Repair of Damaged Ureter 78
 Transplantation of Ureter into Bladder 80
 Uretero-intestinal Anastomosis 83
 Skin Ureterostomy 86

OPERATIONS ON THE ABDOMINAL WALL 89
 Pfannenstiel Incision 90
 Transverse Incision 92
 Incisional Hernia. 95
 Reinforcement of Hernia Repair by Fascia Lata 97
 Inguinal Hernia 98
 Femoral Hernia 99
 Inguinal and Combined Approach 100
 Umbilical Hernia 102
 Diastasis Recti 104

COMPLICATIONS FOLLOWING ABDOMINAL OPERATIONS. 105
 Femoral Vein Ligation 106
 Dehiscence and Resuture 108
 Retroperitoneal Drainage of Pelvic Abscess. 109
 Incision and Drainage of Pelvic Abscess through Vagina 110
 Drainage of Pelvic Abscess through the Rectum 111

SECTION II

VAGINAL AND PERINEAL OPERATIONS

CONSIDERATIONS PRELIMINARY TO ALL VAGINAL AND PERINEAL OPERATIONS 115
 VAGINAL PLASTIC PROCEDURES 117
 Examination under Anesthesia. 120
 Dilatation and Curettage 121
 Advancement of the Bladder 124
 Cystocele Repair 128
 Manchester (Donald or Fothergill) Operation. 130
 Vaginal Hysterectomy 134

Kennedy Repair for Stress Incontinence. 141
 Le Fort Operation 142
 Total Obliteration of the Vagina. 144
 Excision of Cervical Stump 146
 Simple Perineal Repair. 147
 Rectocele Repair 148
 Repair of Third Degree Tear 151
 Vaginal Repair of Enterocele 152
 Hemorrhoidectomy. 154

COMBINED ABDOMINAL AND VAGINAL PROCEDURES. 155
 Combined Vaginal and Abdominal Repair of Enterocele. 156
 Prolapse of the Vagina Following Total Hysterectomy 157
 Sling Operation for Stress Incontinence. 160

OPERATIONS FOR REPAIR OF FISTULAE. 163
 Schuchardt Incision—Closure of Incision 164
 Vesicovaginal Fistula—Vaginal Repair 165
 Transvesical Repair of Vesicovaginal Fistula 166
 Repair of Vesicovaginal Fistula through Abdominal Cavity 168
 Rectovaginal Fistula. 171
 Rectovaginal Fistula near Anal Sphincter 172

MINOR OPERATIONS 173
 Biopsy of the Cervix 174
 Cauterization and Conization of the Cervix 175
 Low Amputation of the Cervix 176
 Trachelorrhaphy. 178
 Excision of Cyst of Bartholin's Gland 179
 Simple Vulvectomy. 180

SECTION III

OPERATIONS FOR MALIGNANT DISEASE

OPERATIONS FOR MALIGNANT DISEASE. 185
 Wertheim Hysterectomy with Pelvic Lymphadenectomy 188
 Combined Abdominal and Perineal Resection of Rectum 196
 Combined Bilateral Superficial Groin Dissection and Radical Vulvectomy 203
 Extraperitoneal Iliac Lymphadenectomy 214
 Vulvectomy 219
 Radical Groin Dissection 222

INDEX 229

SECTION I

Abdominal Operations

akushner-lib.ru

Considerations Preliminary to All Abdominal Surgery

Before discussing the detailed steps involved in pelvic operations, it is appropriate to review some of the general considerations that have a bearing on the ease and success with which this type of surgery may be performed.

PREOPERATIVE PREPARATION

Preoperative and postoperative care are integral components in the success of modern surgery, but the limited scope of this Atlas will not permit a detailed discussion of them. Today chemotherapy, blood and fluid replacement, electrolyte balance and intestinal deflation are all major factors in avoiding many of the unfortunate complications of the surgery of the past. In general, the surgery is in itself superior to that of past decades, but the recent advances in preparation for operation and its after-care have made surgery easier and permitted a more thoroughgoing attack on disease than was hitherto possible. This is as true of operations in the pelvis as it is of those in other areas.

In part the difficulties of pelvic surgery are in inverse ratio to the accuracy of the preoperative diagnosis. With the increasing costs of hospitalization there is a tendency to get on with the presenting pathological signs and symptoms without sufficient preliminary study or even preparation for operation. Too frequently the patient enters the hospital one afternoon, with operation scheduled for the following morning.

If the surgeon is prepared for the unexpected, his ability to cope with the problem is considerably improved. The trouble with encountering unsuspected pathology in the pelvis is the tendency to belittle the problem. If the surgeon is presented with a history of bleeding in a patient with a large abdominal tumor, the surgical procedure seems obvious. Failure to consider the possibility that the small or large bowel may be involved or kidney function impaired through encroachment of the tumor may unduly complicate the actual operation when these findings are discovered for the first time after the abdomen is opened.

Therefore, while we have important additions to our armamentarium of treatment, the increasing economic factor tends to restrict their use to dealing with complications after they have happened rather than in preventing their occurrence.

The preliminary use of a Miller-Abbott tube whenever bowel pathology is known or has a reasonable chance of being present will materially aid the surgeon and patient.

Investigation of the urinary tract for possible involvement of the bladder or ureter may modify the planned surgical attack.

Unexpected pathology or operative difficulty may result in hemorrhage beyond the expectations of the surgeon. Adequate preliminary evaluation of the blood picture is essential.

It is also important to have adequate amounts of blood available to cover unexpected blood loss. A train of unfortunate events not infrequently follows the attempt to replace blood under the stress of operative emergency.

When bowel pathology may be present, it may be well to prepare the bowel with chemotherapeutic agents in anticipation of inadvertent damage. The same factor applies to possible trauma to the urinary tract.

Inasmuch as profound alterations in the electrolyte balance may occur in the postoperative period, it is advisable to have a preliminary evaluation of the nitrogen excretion, chlorides, blood sugar, serum protein, sodium and potassium. Facilities for obtaining these determinations are not always available, but the surgeon should have such determinations if possible. The preliminary values may indicate the need for correction before operation is undertaken.

The basal metabolism in the presence of subjective symptoms may be indicated. Patients with a hypothyroid state, for example, do not tolerate morphine at all well.

The choice of anesthesia may be altered by unexpected findings revealed in a chest roentgenogram.

The electrocardiogram in the presence of minimal symptoms may serve as a base line for comparison in view of possible complications in the postoperative period.

Even in the presence of obvious palpable pathology in the pelvis, other abnormalities, organic or physiological, may be present and bear on the successful outcome of the contemplated operation.

ANESTHESIA

In general, the anesthesia should permit successful and easy access to any pathological state that may be encountered within the abdomen even though preoperative evaluation places the disease in the pelvis. The surgeon, for example, who encounters extensive diverticulitis of the sigmoid colon when the preoperative diagnosis suggested endometriosis should not be handicapped in performing a transverse colostomy because of the inadequacy of anesthesia.

Whenever a prolonged procedure is contemplated, and when there is any question of malignant disease or the diagnosis is in any way obscure, the surgeon would do well to consider gas, oxygen and ether anesthesia with an intratracheal tube as his anesthesia of choice. There may be contraindications to the use of inhalation anesthesia, but by and large the patient will be more relaxed with less risk.

For many of the combined pelvic and abdominal procedures the use of spinal anesthesia with or without supplementary pentothal will give satisfactory relaxation. If the operation is

unexpectedly prolonged through technical surgical difficulties or unsuspected pathology, the spinal anesthesia with pentothal may have to be supplemented by drugs of the curare series in order to get enough relaxation to complete the abdominal surgery and close the peritoneum without tension.

Preoperative evaluation of the patient is important. It is helpful to have the anesthetist consider the needs of the patient in relation to the contemplated operation. The history of old back injury or headache after a previous spinal anesthesia may influence the surgeon or anesthetist in the choice of inhalation anesthesia rather than spinal.

The patient may give some indication in the history of sensitivity to the common preoperative drug medications. Known sensitivity exists to both morphine and barbiturates. As it affects both the immediate operation and the subsequent postoperative course these facts should be known in anticipation. Properly administered preoperative drug therapy will aid materially the smoothest of operative procedures. For success a high degree of cooperation between surgeon and anesthetist is essential.

It seems pertinent at this point to indicate certain preliminary steps which may help to eliminate some of the common errors associated with intra-abdominal surgery for pelvic pathology.

EXAMINATION AND CURETTAGE UNDER ANESTHESIA

It is of utmost importance that all clinic or office observations should be rechecked at the time of operation. The urinary bladder must first be completely emptied by catheter. Complete inspection of the external genitalia, vagina and cervix, as well as a digital examination of the rectum and vagina, is definitely indicated. Too many abdominal explorations are performed on the basis of digital examination alone.

Description of gynecological disease and the specific indications for pelvic surgery are not within the scope of this text. In general, removal of the uterus by the abdominal route is performed for such conditions as fibromyomata, pelvic inflammatory disease, endometriosis, either external or internal, prolapse of the uterus and abnormal uterine bleeding. It is imperative, however, to keep the possibility of both malignancy and pregnancy within the uterus constantly in mind. Most of the tragedies in gynecological surgery involving removal of the uterus arise either because these entities were not suspected or because the preoperative investigation was inadequate. For example, with a history of abnormal intermenstrual spotting the cervix may reveal a focus of carcinoma lurking within the endocervix. Curettage will indicate the size and contour of the uterine cavity and will detect the vast majority of lesions within

the uterus and cervix. Curettage itself is not 100 per cent accurate, and the frozen section interpretations of the curettings may be less so. It is of great importance to send the laboratory every specimen removed at curettage, however small. Should a suspicious specimen be too small to permit frozen section diagnosis, the abdominal exploration should be postponed until permanent sections can be examined. If malignancy is suspected from the history and physical findings, but pathological opinion is doubtful on the basis of frozen section, definitive treatment should await the report of the permanent pathological preparations also.

If the operator will make it an invariable rule to perform an examination under an anesthetic, together with a diagnostic curettage in every instance in which pelvic laparotomy is contemplated, many unfortunate mistakes will be avoided.

EXPLORATION OF THE UPPER ABDOMEN

After entering the peritoneal cavity and before any attack is made on the pelvic viscera, the upper abdomen should be carefully explored with the examining hand to determine co-existent pathology which may have a bearing on the immediate operation or subsequent convalescence. For example, ovarian tumors may represent metastases from the gastro-intestinal tract. Concomitant primary neoplasms can exist in both bowel and genital organs. Pre-existing gallstones may precipitate an attack of acute cholecystitis during the convalescent period from pelvic laparotomy. Knowledge of the accompanying pathology would influence the type of operation in the first instance and a more accurate diagnosis and proper therapy in the second.

MOBILIZATION OF THE UTERUS AND ADNEXA

This phase of intra-abdominal surgery is difficult to illustrate pictorially, but represents an essential preliminary maneuver for any surgical procedure in the female pelvis.

In order to secure an adequate operating field the intestine must be gently packed out of the pelvis with moist gauze. Not infrequently, however, the uterus and adnexa are fixed in the pelvis by previous surgery or inflammatory disease. In such instances the bowel may be densely adherent to the uterus, adnexa or broad ligament. It is imperative that the bowel be freed from the structures and packed out of the field before attempting to remove the uterus. The proper line of cleavage is best established by gentle gloved finger manipulation. Where the bowel loops can be grasped, separation is often possible by gently rolling the tissue between the thumb and forefinger with only occasional help from a sharp instrument such as a knife or scissors. A most useful slogan of "stay on the uterine side" should be closely followed, for it is better to leave benign disease on the attached viscera than to remove a section of small bowel or sigmoid with the specimen.

The adnexa must be freed from the posterior leaf of the broad ligament and sigmoid before any attempt is made to remove either the adnexa or the uterus, or both. Application

of a tenaculum to the fundus or a clamp on the tubal angle and ovarian ligament may be a helpful maneuver.

It is important to recognize that the fixation of tissues resulting from either endometriosis or malignancy differs materially from that encountered in pelvic inflammation from other causes. This observation has practical value. A line of cleavage can always be established between pelvic inflammatory disease involving tube and ovary and the attached viscera. For the most part, mobilization in pelvic inflammation should be begun from below upward. A suction apparatus attached and ready for use should be available in the event an abscess is entered. Whenever firm bands of tissue are encountered, they should be avoided until they can be brought under complete vision before applying clamps. The presence of adhesive bands that will not separate suggests that either vessels are present or a false cleavage plane has been established.

The invasive tendency of endometriosis differs from that of pelvic inflammation. Ovarian endometriosis invades the posterior leaf of the broad ligament and cannot be separated without rupture of the adherent chocolate cysts. Great care must be taken in this type of pathology that endometriosis may not have invaded the small bowel or sigmoid adherent to the pelvic masses.

The approach to this type of pathology is usually made from above downward rather than from below upward as in pelvic inflammation. It is extremely important to stay on the uterine side in the dissection.

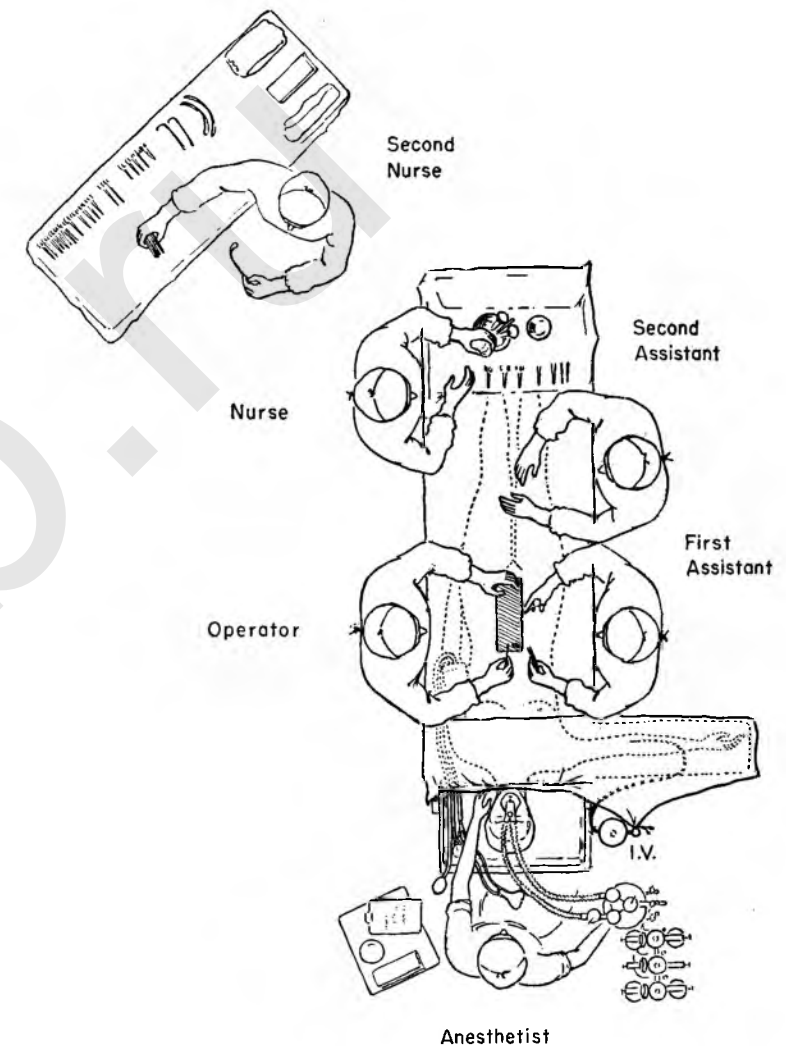
When the surgeon encounters a large malignant ovarian cyst or pathologic state involving the side wall of the pelvis, it is important to ascertain position of the ureter by exposing it at the pelvic brim through the posterior peritoneal covering.

The mobilization of the uterus and adnexa simply constitutes a preparation of an adequate operative field and represents basic preliminary steps in whatever type of pelvic surgery the surgeon elects to perform.

POSITIONING OF THE OPERATING TEAM

The diagram indicates the usual position of the surgeon and his assistants and nurses.

The *surgeon* (operator) stands left of the patient. This is the optimum position for a right-handed surgeon operating in the lower abdomen. By shifting his feet and turning his body toward the head he is in a satisfactory position to do any needful exploration or operation in the upper abdomen as well. By and large this position is maintained throughout the operative maneuvers described. Occasionally the surgeon may shift to the opposite side of the table to have better access to the lateral structures deep in the left pelvis. When this is done, it will be indicated to the reader. Such a move is made usually in cases in which the overhanging edge of the abdominal wound interferes with exposure of the pelvic wall. Moreover, separate bilateral procedures, such as extraperitoneal lymph node resection, will be made easier if the surgeon changes his position to the side on which the operation is to be done.



Diagrammatic Representation of Operating Room for Pelvic Surgery

The *anesthetist* occupies a position at the head of the patient. The anesthesia machine, if inhalation is the chosen method, will be set up to the right of the anesthetist. The worktable with his supplies and charts will be on the left. He is protected from the operating field by linen drapes over a wire hoop which attaches to the table and is adjustable either forward or backward. The wire hoop permits him to have constant direct observation of the patient's face as well as an unobstructed working field. The patient's right arm is extended on a board placed beneath the mattress to permit intravenous infusion. The upright used to support the infusion bottle is placed to the right of the anesthetist behind the board supporting the arm. The entire pathway of the intravenous fluid is under the direct vision of the anesthetist, whose duty it is to regulate the speed and quantity of the flow.

A blood pressure cuff is in place on the patient's left arm, which is tucked beneath her body with the fingers extended. The surgeon's movements are thus unencumbered. The tubes from the sphygmomanometer lead toward the patient's head,

allowing the anesthetist to make the necessary observations from behind the protective drapes.

The *nurse*, operating on the same side as the surgeon, from her position at the patient's feet is able to feed the instruments to him from a Mayo stand placed over the foot of the table. The main instrument table is on her left. A *second nurse*, standing in front of the instrument table, anticipates the nurse's need for supplies not available on the Mayo stand, such as suture material, sponges or infrequently used instruments. If only one nurse is scrubbed, the larger instrument table is so placed that from her position to the left of the surgeon she may supply her own needs from it.

The *first assistant* stands directly opposite the surgeon just below the board carrying the patient's extended arm. He should be cautioned not to hyperextend the patient's shoulder by pushing too firmly against the board in his zeal to provide more effective assistance.

The *second assistant*, if available, usually takes his place to the right of the first assistant opposite the nurse. His job is to aid in exposure by retraction as directed.

Consistently throughout this Atlas the drawings have been made from the position which offers the most unobstructed view of the field, usually just behind or beside the surgeon. Since the operator stands on the left side of the table, in most cases the reader may assume that the patient's feet are toward the top of the page. A real effort has been made in all plates (except for the insets and close-ups) to keep the relationships accurate on a scale approximately two-thirds of normal size.

POSTOPERATIVE MANAGEMENT

This important phase of pelvic surgery strives for anatomic healing and physiological recovery in the shortest possible time and with minimum discomfort. Every decision made and every order written in the postoperative period must take these factors into account, perhaps favoring one at the expense of another in individual cases.

The orders which accompany the patient as she leaves the operating room should be concise and specific, avoiding the routine in favor of the individual need. Recording of the vital signs is essential and must be maintained throughout the recovery period. Periodic registering of pulse, respiration and blood pressure is also important during the period of returning consciousness after anesthesia. The patient should

be constantly observed during this time, preferably in a special room or ward. She should be turned often enough to give each lung a chance to expand. The order sheet must include specific orders for administration of an opiate for relief of pain and discomfort.

Blood and fluid replacement are based on the calculated need. Both the volume and the electrolyte content will vary with circumstances. In general, a total fluid intake of approximately 2000 cc. daily should be maintained. Such quantities often cannot be taken by mouth in the immediate postoperative period, and intravenous supplement will be necessary. The actual amount, rate of administration and the time they are to be given should be clearly stated in the postoperative orders.

After recovery from anesthesia a different set of problems arises. Recordings of the pulse, temperature and respirations are continued, and the patient will need further opiates for pain and discomfort. A change of drug may be indicated if nausea and vomiting persist. The blood pressure readings are recorded as the individual case dictates.

Dysfunction of the urinary bladder after pelvic laparotomy is common but not routine. Although a variety of plans for management are in vogue, the basic precept should be the avoidance of overdistention; even one such episode may stretch the bladder to such an extent that the faculty of complete emptying is not recovered for days. An order for catheterization should be written to cover the immediate postoperative situation. When bladder difficulty can be expected from the kind of operation performed, an indwelling catheter may be inserted at the conclusion of the operation. Orders should then be left to cover the management of the catheter. Small prophylactic doses of nontoxic chemotherapeutic agents may be advisable if repeated catheterizations have been necessary or the nature of the surgery suggests bladder infection.

Ileus may be expected for one or two days after operation, and it will be advisable to restrict the intake by mouth to clear fluids in small amounts until normal peristalsis has been re-established. At times the ileus is severe enough to produce gastric dilatation. Simple gastric lavage may bring much relief. In severe cases a Levin tube in the stomach or a Miller-Abbot tube in the small intestine may be indicated. The large bowel is usually less prompt than the small intestine in its recovery of tone, but this delay is rarely the cause for serious difficulty. Relief by enemas should be given with due regard to the

immediate findings and the type of operation performed. They should not be given purely as a routine.

With a strong wound closure early ambulation is possible and should be encouraged as a means of minimizing postoperative tissue wasting. It may have some bearing on reducing the incidence of postoperative pulmonary emboli. To this end it is better to have the patient walk to the point of tolerance than to sit up in a chair for protracted periods.

Complications are infrequent, but should be anticipated and forestalled as far as possible. In general, they will develop least often when surgery is gentle and hemostasis is complete and when a happy balance between activity and comfort is maintained during the recovery period. Every available adjunct which has demonstrated its usefulness during convalescence should be understood and used for proper indications. This applies particularly to chemotherapeutic agents. The surgeon would do well to question exactly what he hopes to accomplish by any agent he uses. Routine use of any one or combination of drugs on the theory that they probably will not cause any harm and may do some good should be condemned.

Postoperative pain and discomfort vary enormously in different patients. The surgeon should therefore not fall back on standardized orders for opiates. Some patients may require more, some less, medication for discomfort based on similar cause. The wound itself is most painful immediately after the operation and requires an opiate for relief. Within a day, however, physical comfort seems to improve with moderate activity, and it may be wise to change to medications with less depressant effects. As the convalescence progresses a great variety of causes for discomfort may develop, and each should be treated in its own appropriate fashion to try to eliminate the cause as well as to stifle the pain.

Intangible factors play a role in the recovery phase after surgery. Most people abhor illness and disability and are anxious to return to the security of their daily routine. All are apprehensive to a greater or less degree, and attentiveness and sympathy on the part of the physician are very much in order. The same attitude will help sustain the patient through the trials of convalescence. The doctor who is wise and sincere cannot consider his job done until the patient is restored to full activity; he must be ready with explanations and advice at any point along the path to this goal. Each patient must be regarded as an individual problem.

TOTAL ABDOMINAL HYSTERECTOMY

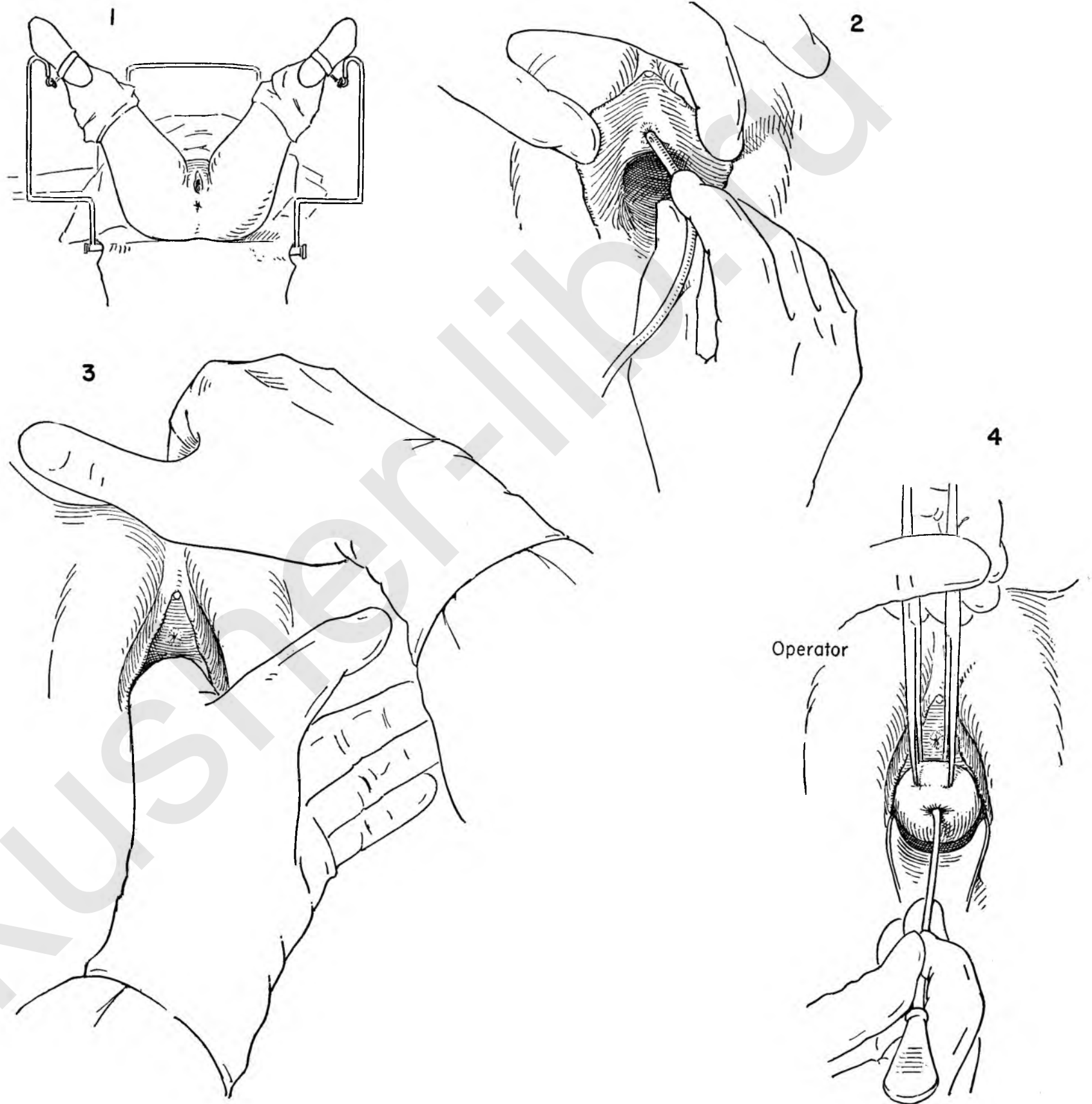
In this first series of sixteen plates the authors have chosen to carry the reader through an entire operation from the preliminary phases to the completed closure. As in every pelvic laparotomy, a preliminary examination and curettage must precede the abdominal surgery. The reasons for this maneuver are many: (1) The previous pelvic findings should be checked. (2) The bladder is emptied. The technical steps of abdominal hysterectomy are simplified if the bladder is collapsed. (3) The cervix is inspected and the uterine cavity and endometrial and cervical canals are evaluated as regards unsuspected pathology. The decision to leave or remove the adnexa may depend on the findings at curettage. Performed as a routine step whenever hysterectomy is contemplated, the maneuver avoids the pitfall of discovering unsuspected pathology after the uterus is removed.

FIGURE 1. The patient is placed in the lithotomy position. Note the wide-angled stirrups which permit the legs to lie easily without pressure on the medial calf. The patient's buttocks present at the table's edge. In this position the perineum is prepared with whatever antiseptic agent the surgeon elects to use.

FIGURE 2. The lips of the labia are separated with the thumb and finger of the left hand, exposing the urethra. A lubricated catheter is inserted into the urethra and the bladder emptied. Complete evacuation is ensured by pressure of the left hand on the abdominal wall above the symphysis.

FIGURE 3. A careful vaginal examination is carried out. The complete relaxation under anesthesia may confirm, enhance or deny the previous observations.

FIGURE 4. The gross appearance of the cervix is evaluated. Any suspicious area should be biopsied. Two tenacula are placed on the anterior lip of the cervix. Traction is applied. Elevation and traction on the tenacula exposes the cervical os. A long probe is gently inserted in the cervical canal. This gives some indication of the depth of the cavity. Undue pressure on the probe may result in perforation of the uterus. This is particularly true of the small atrophic uterus in the older woman. Care must be exercised.



This description of curettage is in abbreviated form. For full details the reader is referred to the section on Vaginal Procedures.

FIGURE 5. The depth of the cavity has been determined by the probe. The graduated type of Hank dilator is now introduced into the cervical canal. The surgeon holds the tenacula himself in his left hand in order to increase his sense of touch. This cannot be done if the assistant holds them. The cervix is placed on traction and elevated, and the cervical os exposed. The dilator, held gently between thumb and forefinger, is then inserted into the cervical canal. The smallest of the series of dilators is followed serially by those of increasing diameter. This maneuver should be a gradual stretching of the cervical musculature. Avoid a too forceful, plunger-like action in order to minimize the danger of pushing endometrial content through the tubes into the peritoneal cavity.

FIGURE 6. Fine-meshed gauze or rubber is inserted into the vagina beneath the cervix to aid in the collection of the uterine contents. The use of fine-meshed gauze or rubber prevents the curettings from becoming enmeshed and lost in the interstices of the usual rough gauze. The endometrium is then thoroughly curetted unless grossly malignant material is obtained. Particular attention should be given to the cornua of the uterus. This area is the "blind spot" in any curettage. The examining finger should palpate the curettings. Curettings that break up under the finger should be regarded as suspicious of malignancy. Save every piece of material for pathological examination, however small.

FIGURE 7. Inasmuch as the curette may fail to dislodge a uterine polyp suspended by a stalk and lying free in the cavity, another instrument is used to explore the cavity.

INSET A. The common duct stone searcher used to explore the endometrial cavity after curettage.

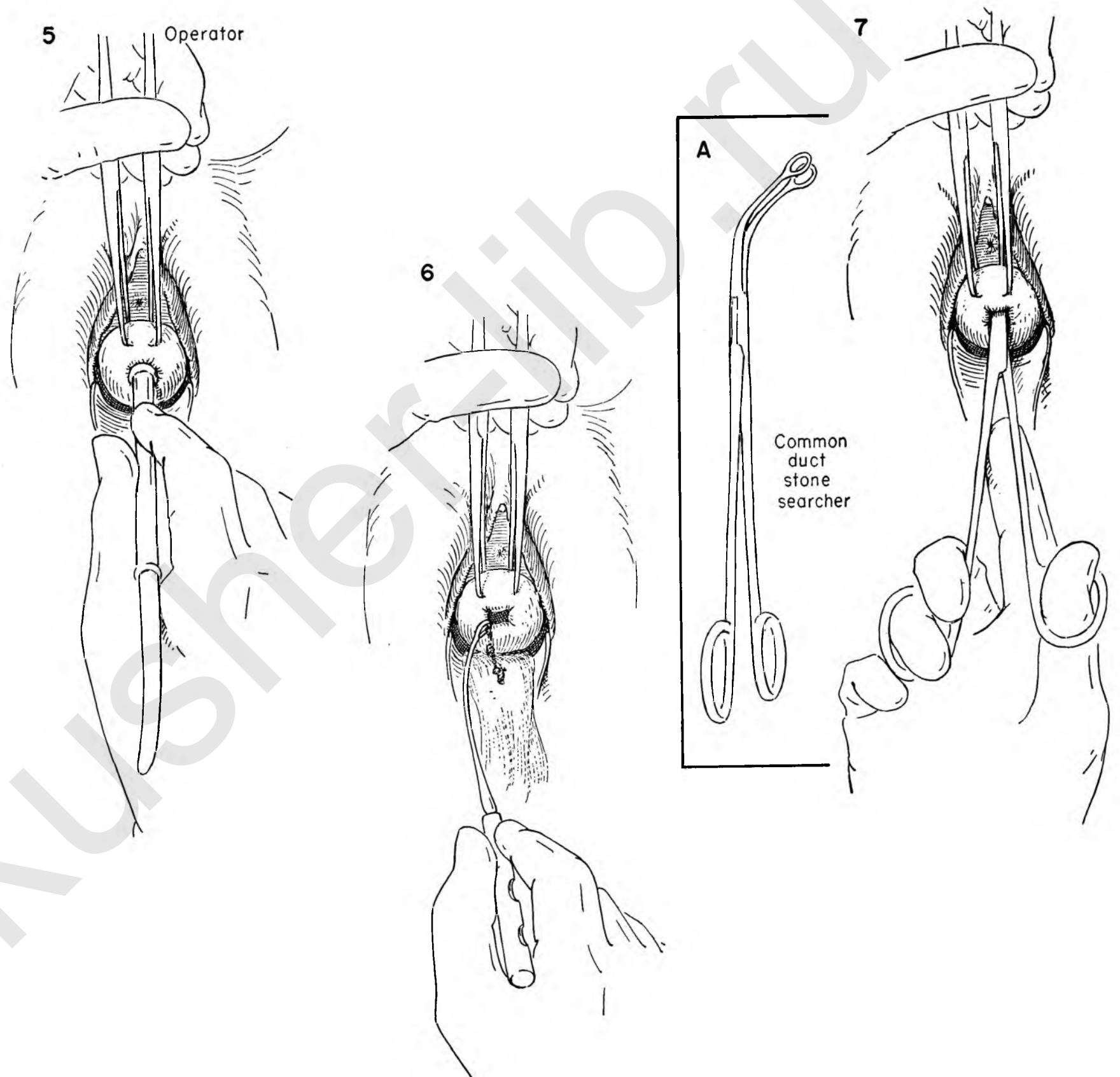


FIGURE 8. Proper positioning of the patient on the table is important to the surgeon and anesthetist during operation and to the patient in her convalescence.

The patient is portrayed in Trendelenburg position. The degree of depression of the head of the table should allow the intestines to fall back out of the pelvis with the minimal amount of packing. Extremes place too much demand on the anesthetist.

The feet are tied by a long, wide-tailed cotton strap which passes around the ankle to fix to the crossbar beneath the foot of the table. This permits less strain on the shoulder brace and minimizes the danger of brachial stretching and subsequent paralysis.

The main trunk of the body is supported by a straight table. Angulation, either in extension or flexion, maintained during a long operation may produce troublesome backache later.

The foot piece is broken at the level of the popliteal space. An improper break may produce abnormal pressure on the calf. The right arm is extended on a flat board passed beneath the mattress to permit intravenous infusion. The surgeon operating from the left side of the table is unencumbered. Care must be taken that the shoulder is not abducted excessively. An adjustable frame protects the anesthetist from the operative field, but gives him ample room at the head of the table.

The surgeon stands to the left of the patient with the first assistant directly opposite.

INSET A. After proper draping, the paramedian incision begins at the symphysis, passing upward to curve slightly to the left if necessary to go above the umbilicus.

FIGURE 9. The incision extends through the skin and fat to the fascial level.

FIGURE 10. Individual bleeding vessels are clamped by the assistant as the incision is made.

FIGURE 11. The clamped vessels are ligated with fine silk or cotton.

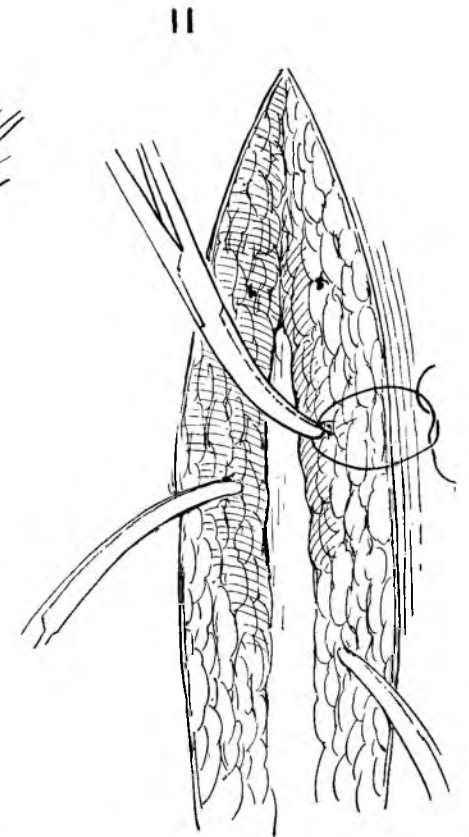
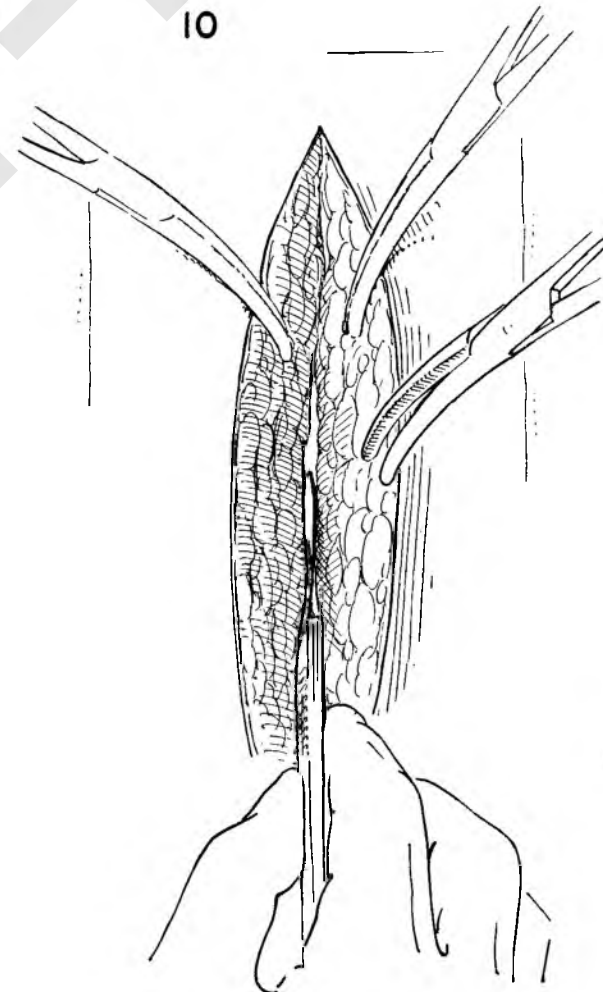
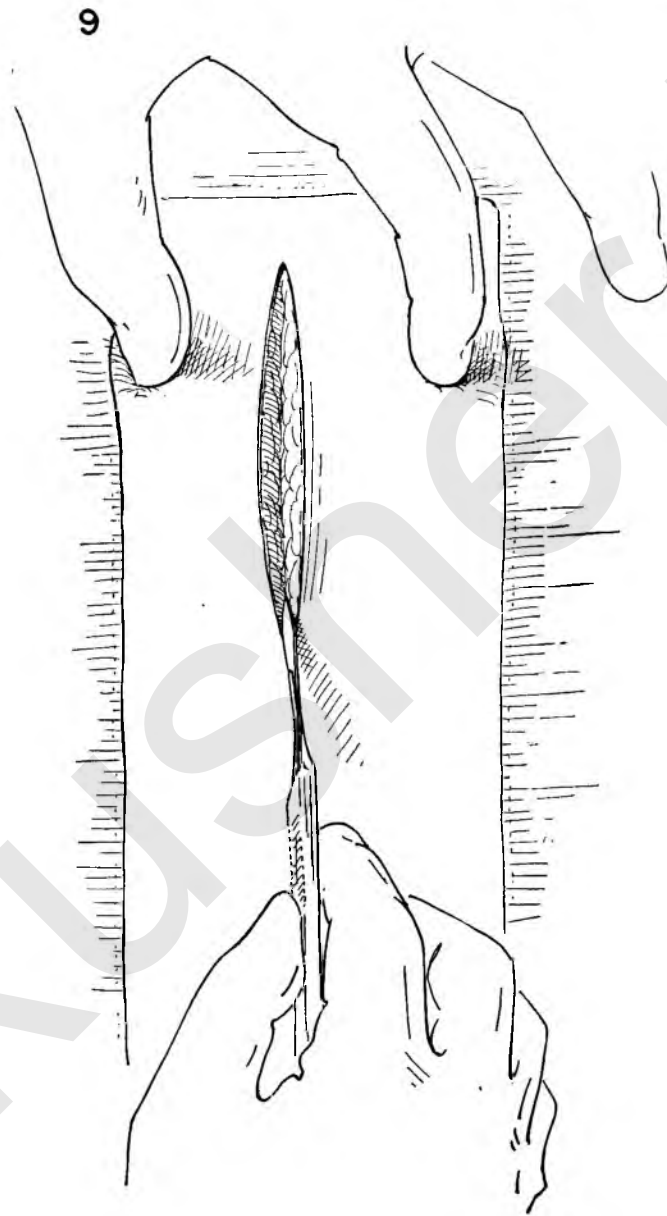
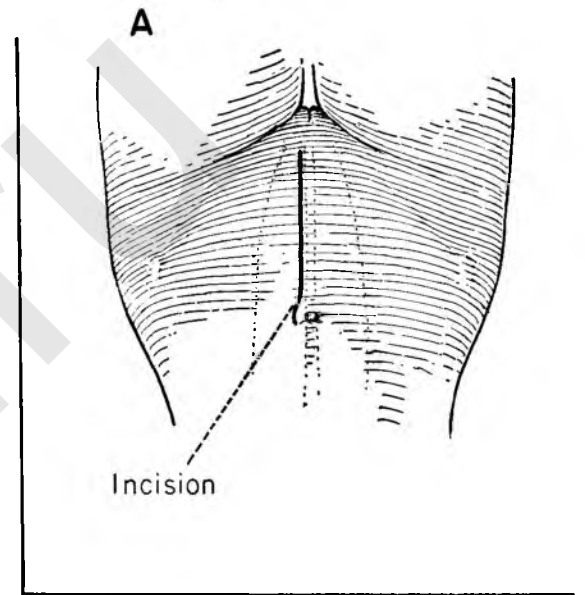
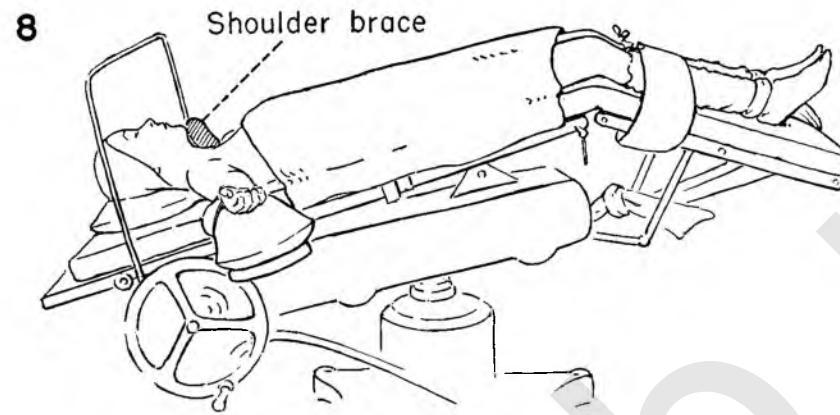


FIGURE 12. Towels have been applied to the incised skin edges and held in place by clips. The operative field is thus protected from the surrounding skin.

The surgeon and assistant apply counter-traction on the incised wound to expose the underlying fascia. An incision is made in the fascia slightly to the left of the midline, beginning at the symphysis and passing upward toward the umbilicus. The underlying rectus muscle is exposed.

FIGURE 13. The assistant applies clamps to the cut edge of fascia on his side. The clamps are placed on traction, and the surgeon retracts the muscle with his left hand to dissect the muscle from its bed and expose the peritoneum lying beneath. Individual vessels are ligated.

FIGURE 14. At the lower end of the wound the pyramidalis crosses the field obliquely. This muscle is freed from its bed without dividing it. During closure the pyramidalis will lie obliquely across the rectus, thereby strengthening the lower abdominal wall.

FIGURE 15. This dissection exposes the vessels at the midportion of the muscle which give troublesome bleeding when divided. These vessels should be identified, clamped and ligated with silk or cotton.

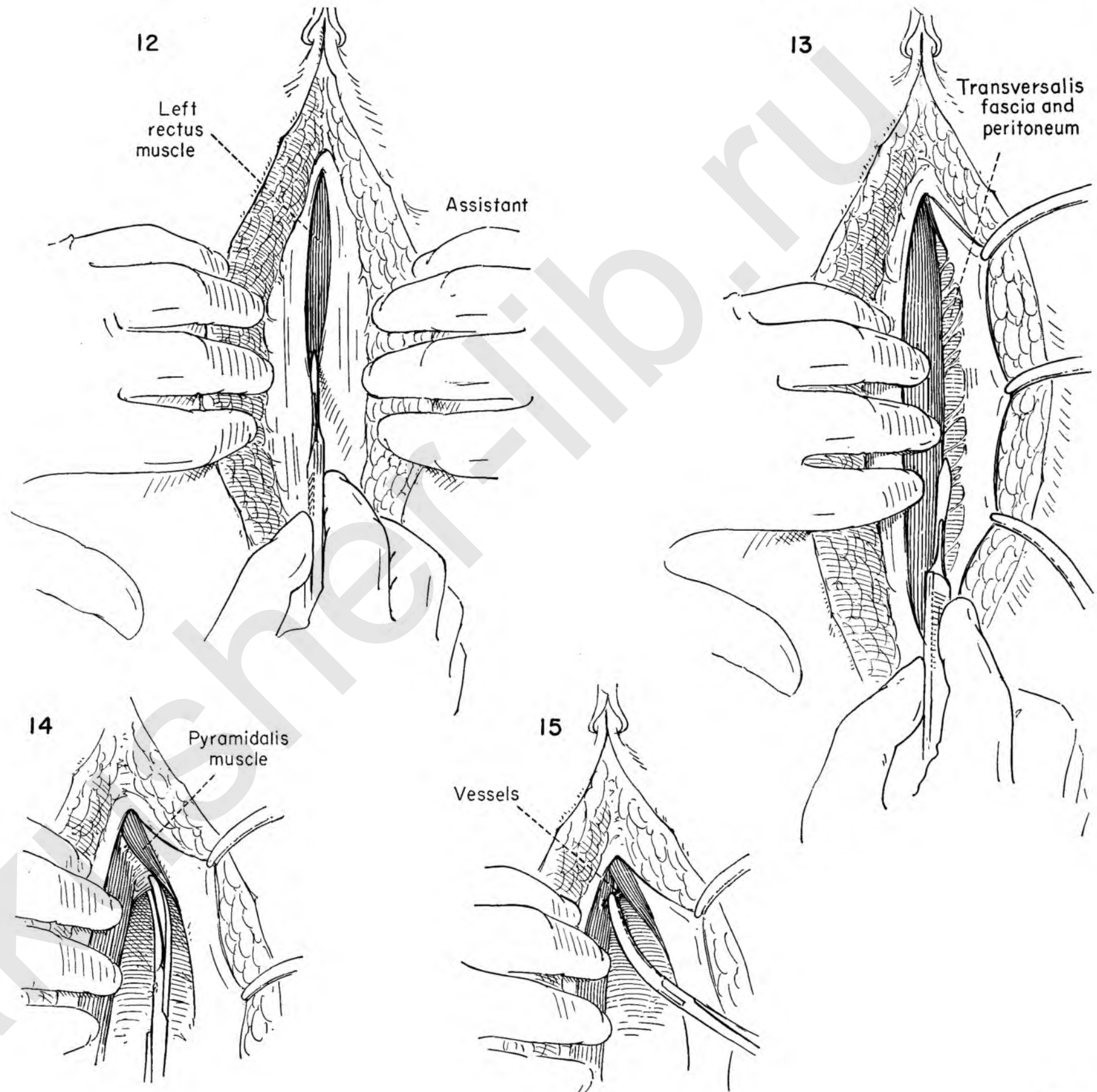


FIGURE 16. The left rectus muscle is retracted laterally. The peritoneum presents through the whole extent of the wound. The surgeon and assistant grasp the peritoneum opposite one another with toothed forceps. The use of Kelly or Kocher clamps for this maneuver is to be condemned. Extreme care must be taken that bowel is not included in the forceps. Bowel may be adherent to the peritoneum. If there is any question, select another spot to enter the abdominal cavity. Should the peritoneum be taut because of incomplete anesthesia, wait until complete relaxation is acquired. The peritoneum is then elevated by forceps and an incision made through its full thickness to enter the abdominal cavity.

FIGURE 17. The opening is widened by lateral traction of the tissue forceps. After assuring himself that there is no bowel adherent to the peritoneum, the surgeon applies a Kelly clamp to the cut edge. The assistant carries out the same maneuver and clamps the opposite side.

FIGURE 18. The scalpel is now abandoned for curved scissors. After proper inspection of the under surface of the peritoneum the incision is enlarged.

FIGURE 19. The surgeon then introduces the second and third fingers of the left hand into the opening of the peritoneum, extending them in the direction of the symphysis. This step protects the bowel from inadvertent damage as the incision is enlarged. The extent of the incision downward is limited by the proximity of the bladder. The first observation of bleeding from the cut edge as the incision approaches the symphysis should give warning of the region of the bladder.

FIGURE 20. The same maneuver is carried out in an upward direction away from the symphysis.

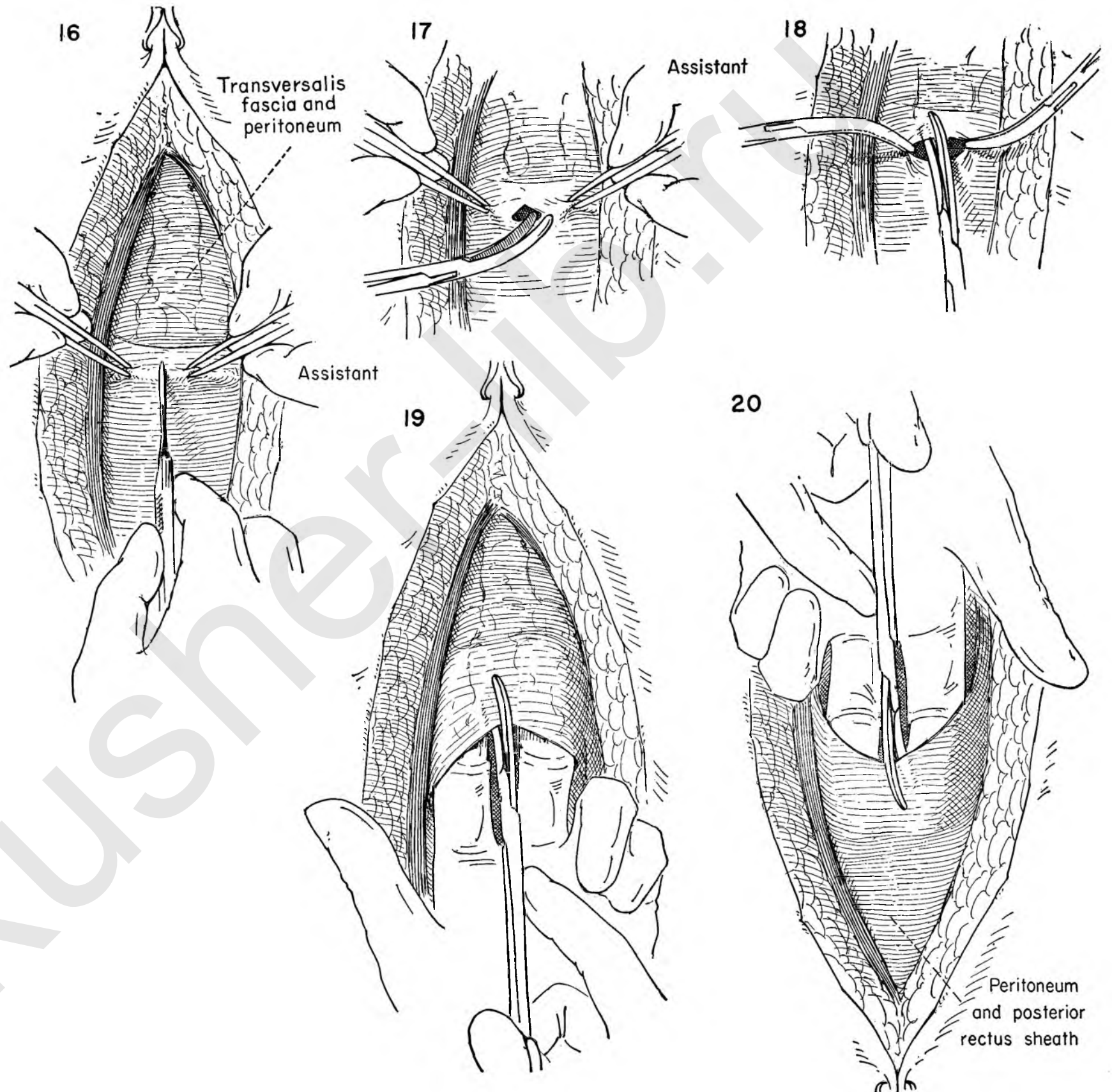


FIGURE 21 AND INSET A. Though the surgeon is operating primarily for pelvic pathology, it is, nevertheless, his obligation to explore the remainder of the abdominal cavity distant to his immediate operative field. Metastases to the liver, unsuspected malignancy of the stomach, small bowel or colon, or extension of malignancy to involve aortic nodes may influence the surgeon in his choice for or against a planned pelvic procedure. The presence of silent gallstones may serve to explain a postoperative attack of right upper quadrant pain or the onset of jaundice in the postoperative period. Not to know of the presence of coexistent pathology may trap the surgeon into performing an inadequate or ill-advised pelvic operation. The time to explore comes with the entrance into the peritoneal cavity. This maneuver is too often neglected by gynecologists concentrating on their chosen field of surgery.

FIGURE 22. Before any attempt is made to operate on the uterus or adnexa the entire operative field must be cleared of adherent bowel or omentum. The adhesion may be the result of previous operative intervention or existing pelvic pathology such as inflammatory disease or endometriosis. Once freed, the intestine is then gently packed out of the pelvis with large, moist sponges or packs.

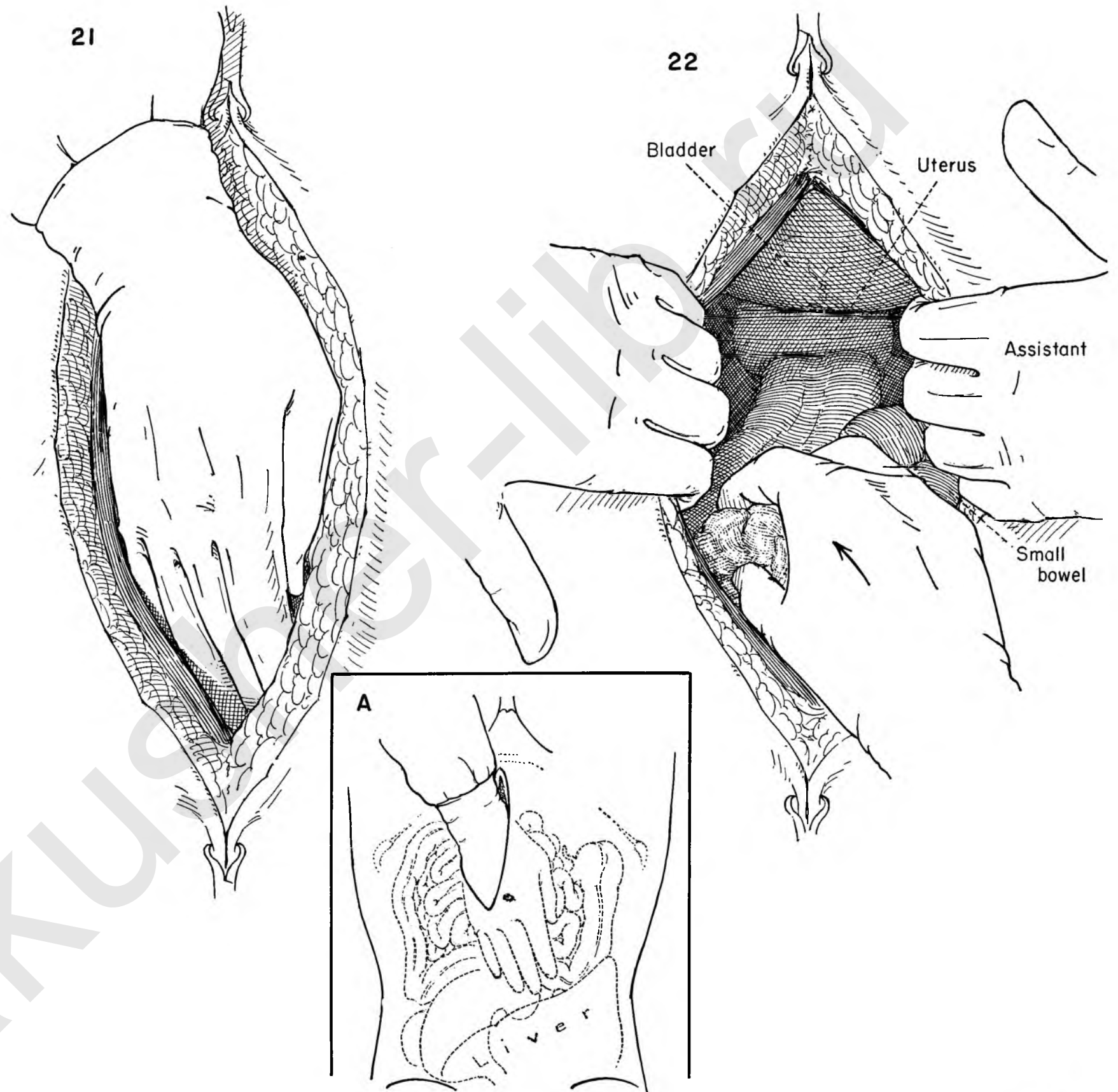


FIGURE 23. With the operative field completely cleared of bowel, the adnexa lying free, and the small bowel packed out of the pelvis, the wound edges are then protected by moist gauze pads. The self-retaining retractor is then introduced. In general, we have elected to avoid use of the fixed lower retracting blade, preferring instead the more mobile type of Deaver retractor. It is our custom, therefore, to insert the Balfour retractor with the crossbar toward the patient's head. In applying the self-retaining retractor, be sure that the blades do not compress the cecum, sigmoid or small bowel.

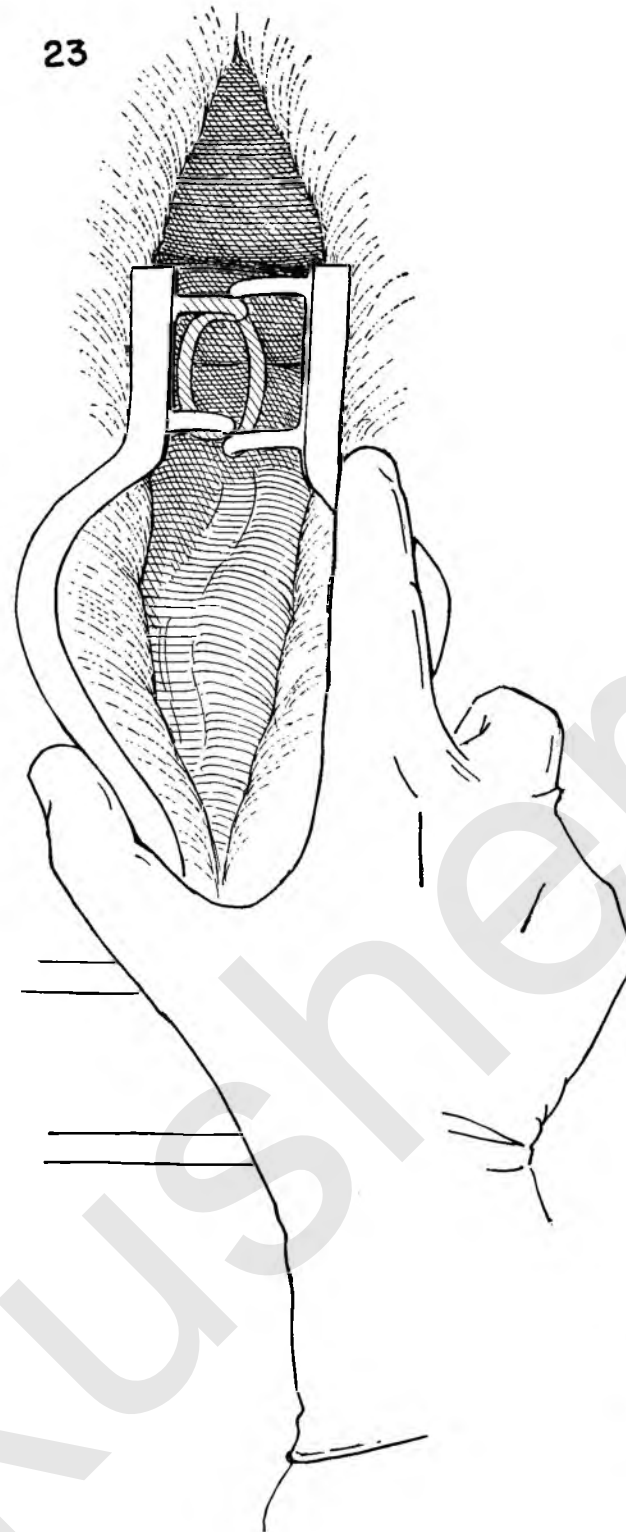
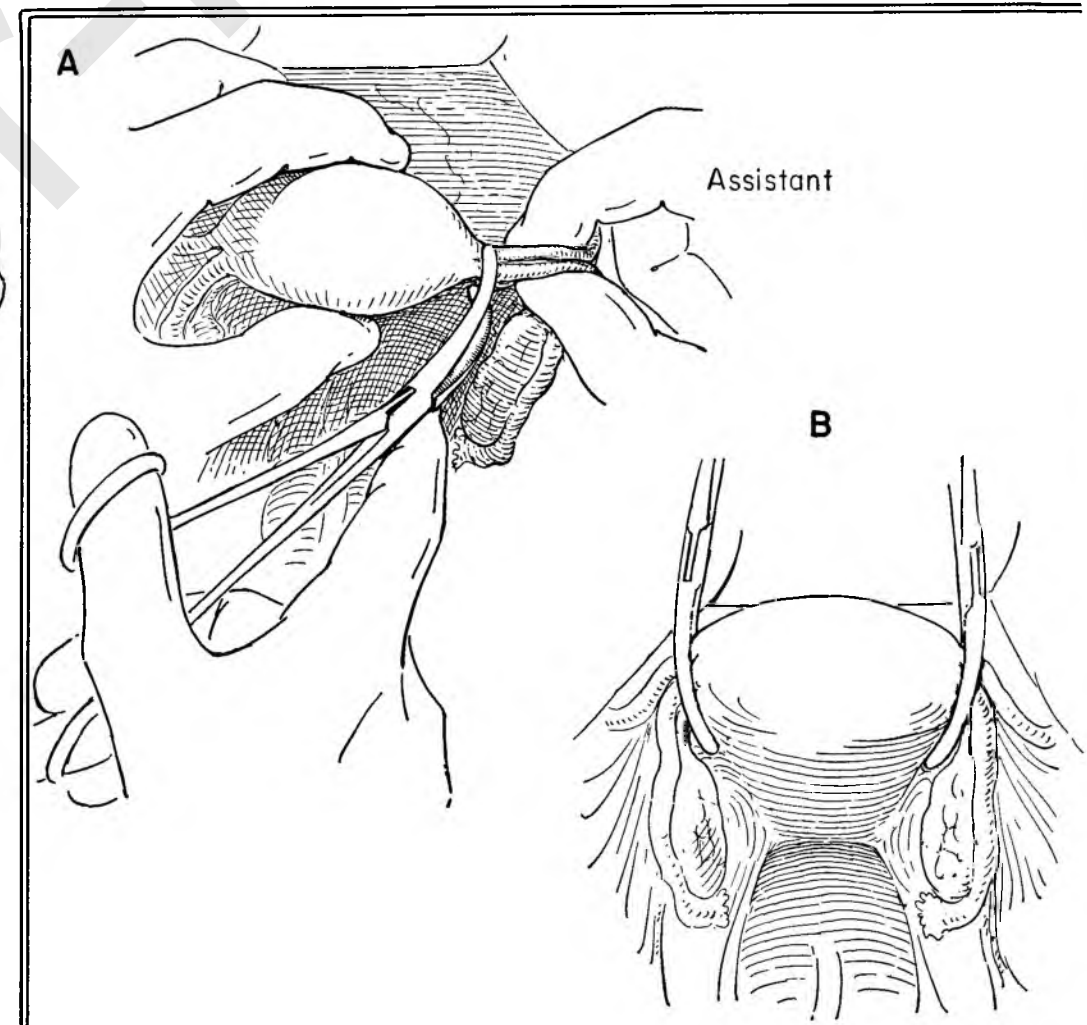
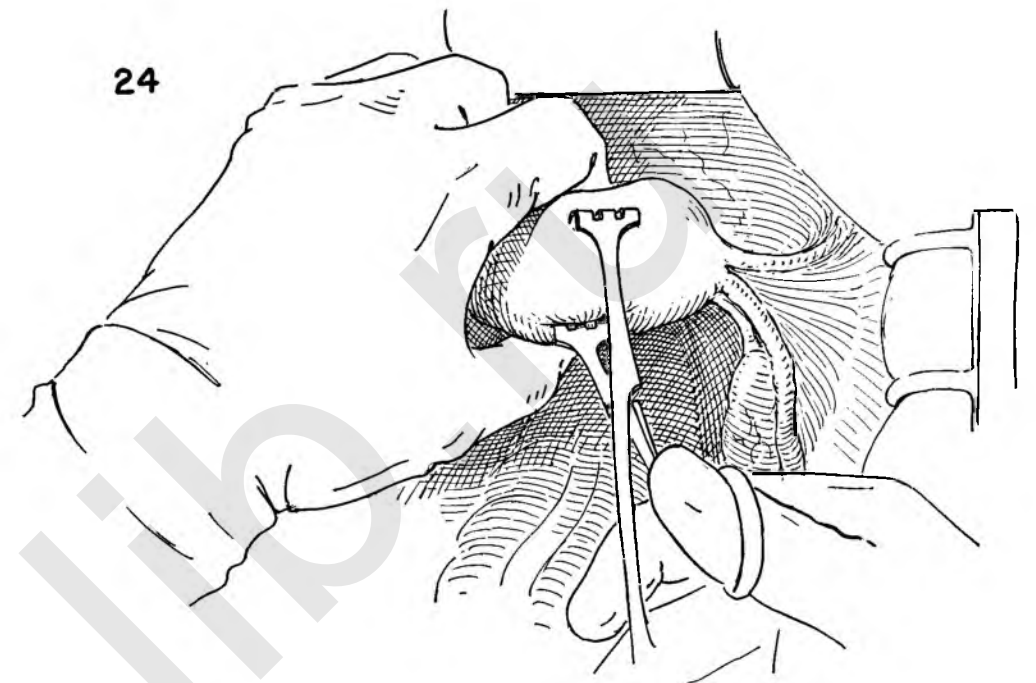


FIGURE 24. The secret of all surgery involving the uterus or adnexa is continued traction maintained throughout the operation. Bleeding is controlled and tissue planes maintain their proper relationships as a result of constant traction on the uterus. Injuries to the bladder and ureter are less likely to occur. The bladder reflexion in relation to the cervix and vagina is made apparent. The course of the ureter is less tortuous when the structures are placed on stretch.

When there is no question of malignancy of the endometrium on history, checked by preliminary curettage, the surgeon applies a tenaculum to the uterine fundus. The bladder is reflected by the Deaver retractor. The uterus is steadied by the thumb and forefinger of the left hand while the tenaculum is applied with the right. Enough tissue is incorporated in the clamp to prevent it from pulling out of the muscle and causing troublesome and unnecessary bleeding.

INSET A. When malignancy of the endometrium is suspected or confirmed, it is unwise to traumatize the fundus with the tenaculum. As a substitute, a Kelly clamp is placed across the broad ligament close to the uterine body. This clamp includes the round and ovarian ligaments as well as the tube. In addition to avoiding trauma to the fundus, any leakage from the endometrium through the tube is prevented. The peritoneal cavity is protected from accidental seeding in this manner.

INSET B. The broad ligament clamps are applied to both sides, and constant traction is maintained in this fashion in lieu of the uterine tenaculum.



Helpful Hints for Hysterectomy

For the sake of emphasis the measures used to avoid pitfalls inherent in the technique of abdominal hysterectomy will be outlined and discussed.

1. A preliminary examination under anesthesia should always be done. In this manner the office examination is checked.
2. The bladder should be emptied by catheter regardless of whether the patient has previously voided. A distended bladder can add enormously to the technical difficulties of hysterectomy.
3. The importance of curettage has already been stressed. This step should never be omitted.
4. With the peritoneum opened, the upper abdomen must be explored. It is well for the surgeon to have an established routine for such an examination. One might begin with palpation of the right kidney, liver, gallbladder, stomach, duodenum and pancreas, the left kidney and spleen. The examining hand then passes rapidly over the colon from the cecum to the sigmoid. The aorta and adjacent nodal areas are then palpated together with the base of the small bowel mesentery. It matters little how this is done as long as it follows a pattern.
5. Mobilization of the uterus and adnexa must precede any attempt to remove the uterus.
6. The intestine must be kept out of the field of operation. Adequate anesthesia and the Trendelenburg position may suffice, but often moist gauze packs will also be necessary. It is important to minimize the pressure of the packs on the viscera, particularly the large vessels crossing the brim of the pelvis.
7. Whenever the history or physical findings suggest the likelihood of carcinoma within the uterus, Kelly clamps should be placed across the tubal isthmus and ovarian ligament on both sides. These clamps take the place of the tenaculum usually inserted on the fundus of the uterus. Adequate traction is thus maintained and spillage of viable cancer cells through the tubes prevented.
8. Development of the bladder flap as the initial step before dividing the ovarian vessels will greatly simplify the technique of hysterectomy. The bladder can be mobilized bloodlessly with the minimum expenditure of time, effort and risk. The anatomical relationship of the ureter to uterine artery and cervix is readily visualized. If the round ligament and ovarian vessels have been divided first, the lower portion of the broad ligament falls into accordian-like folds which make separation of the bladder, cervix and broad ligament much

more difficult and bloody. For this reason the bladder flap should be developed as the initial step.

9. To avoid injury to the dome of the bladder, the incision through the anterior sheath of peritoneum in the midline should be made with care. This thin peritoneal flap is then dissected off the bladder for 2 to 3 cm. At the conclusion of the operation this will serve to cover the raw areas completely without drawing the bladder over the vaginal or cervical stump.

10. When the adnexa are to be left, it is important that the round and ovarian ligaments be divided and ligated separately. This is done in order that there be no tension on the ovarian vessel when the round ligament is resutured to the stump of the cervix or vagina in the reconstructive phase. Eliminating any tension on the ovarian pedicle ensures an adequate blood supply to the retained ovary.

11. When the ovaries are to be removed, it is of utmost importance that the relation of the ovarian vessel to the ureter be checked at the point where they cross the common iliac artery. This is one of the commonest sites of injury to the ureter and occurs largely because the proximity of the ureter is unsuspected. Injury may be avoided by tracing the course of the ureter as seen through the peritoneum and by elevating the vessels away from the ureter before applying the stitch ligature.

12. The second most common and the most unsuspected point where the ureter may be damaged is the area of the uterosacral ligament where it is closer to the dissection than at any other time during the hysterectomy. The position of the ureter, bladder and uterine artery should be checked by palpating the base of the exposed broad ligament with thumb and forefinger. A characteristic snapping sensation is elicited as the ureter slips between the fingers.

The uterosacral ligaments are then clamped, divided and sutured close to the uterus well away from the ureter. By dividing the peritoneum between the sectioned uterosacral ligaments a bloodless plane of cleavage can be established which allows the peritoneum and uterosacral ligaments and ureters to be pushed downward away from the cervix and posterior vagina.

13. The maneuver just described is also useful in protecting the rectum against injury. Endometriosis of the rectovaginal septum frequently fixes the rectum to the posterior wall of the uterus between the uterosacral ligaments. It may be

separated by sharply angulating the uterus toward the symphysis, producing a fracture through the peritoneum at a safe point. If the separation is not evident, it may be created by dividing the peritoneum between the ligaments with a long-handled knife

14. There is another reason for separating the uterosacral ligaments in this manner. As soon as the surgeon has divided and secured the uterine vessels he approaches what is known as the "bloody angle" in total hysterectomy. This is a dangerous area. The operative steps in this region can be made bloodless. By separating the uterosacral ligaments from the uterus, less tissue will be included in the clamp that must be applied to the cervical branches of the uterine vessels. It is also important to leave a cuff of tissue beyond the clamp to prevent retraction. Because of the cuff and primarily because less tissue is included there is less danger of tissue pulling out of the clamp and causing troublesome bleeding. Blind attempts to recapture the bleeding point further increase the likelihood of ureteral damage.

15. The majority of the vesicovaginal fistulae encountered in gynecology today come, not from poor obstetrics, but from injury to the bladder in the course of total hysterectomy. The initial development of the bladder flap is one important step in their prevention. The bladder may be gently stripped down from the cervix by the same pill-rolling motion used to separate the bowel from the uterus. As further protection the bladder should be separated from the uterine vessels. The bladder tends to be pulled up on the uterine vessels in a crescent-shaped fold of tissue. This attachment may be gently freed with scissor dissection by staying in a plane superficial to the vessels. It is of the utmost importance that any tissue to be incised or sutured be under direct vision if injury to the bladder is to be avoided.

16. The mobilization of the bladder from the cervix is essential if the entire cervix is to be removed. Invariably, enough vagina is removed anteriorly and posteriorly, but some portion of the cervix may be left behind on the lateral vaginal fornix if insufficient attention is paid to these corners.

17. Because we recognize that the curettage is not infallible we have made it an invariable rule that every excised uterus and ovary should be opened at the operating table and their interior inspected before closing the abdomen. The surgeon's observations should be checked by the resident pathologist if available.

The figures on this page illustrate the most important steps in the simplification of the technique of total hysterectomy.

FIGURE 25. A tenaculum, held by the assistant, puts the uterus on constant traction. All folds in the anterior peritoneum overlying the bladder are eliminated by this maneuver. The surgeon picks up the anterior peritoneum lateral to the uterus just below the round ligament. Continuing traction on the uterus, the assistant picks up opposite to the surgeon. The surgeon carefully incises the peritoneum, making certain that no bladder wall is included in the bite.

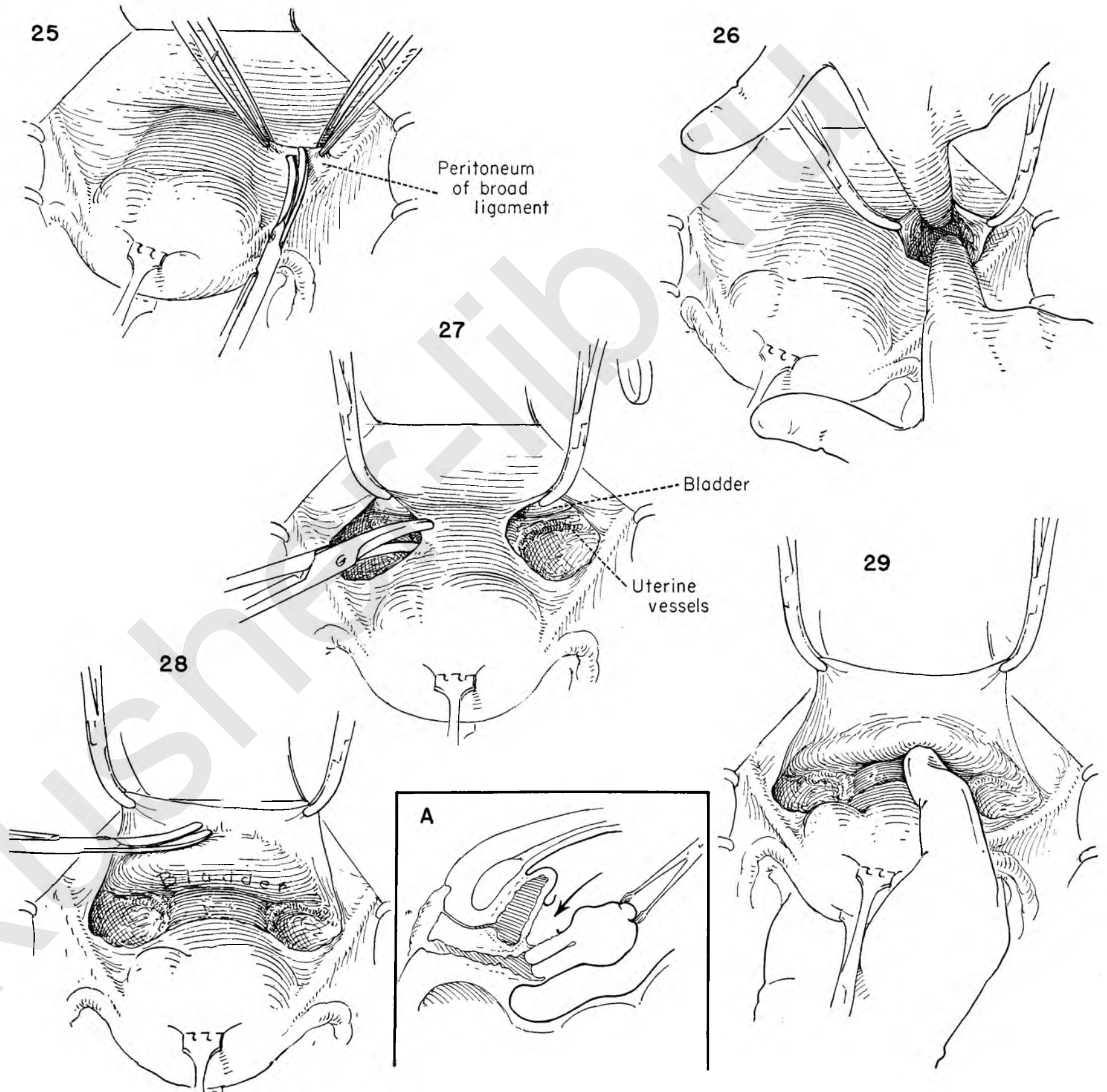
FIGURE 26. Kelly clamps are placed on the distal cut edge of the peritoneum. The areolar tissue within the leaves of the broad ligament is exposed. The bladder, adherent to the anterior peritoneum, lies medially, the external iliac vessels laterally. The surgeon's index fingers are inserted into the space while the assistant and nurse hold the clamps. The areolar tissue is gently separated, pushing the posterior wall of the upper portion of the bladder away from the cervix. The uterine vessels can be seen in the lower reaches of the wound in a bloodless area.

FIGURE 27. This step has been repeated on the other side. Kelly clamps are reapplied to the distal cut edges of peritoneum and traction exerted. The surgeon divides the bridge of peritoneum between the two openings. Great care must be exercised here, for the dome of the bladder is closely adherent and may be accidentally damaged.

FIGURE 28. While the peritoneal sheath is kept on tension, the fine strands which hold the bladder to the peritoneum are divided carefully with scissors. This provides a free peritoneal edge. This is utilized in the final reconstructive steps to cover the raw cut edge of the vagina without disturbing the position of the bladder.

INSET A. The inset shows diagrammatically what has happened up to this point in the procedure.

FIGURE 29. With traction on the uterus maintained, the surgeon grasps the cervix with the right hand. By using a gentle, pill-rolling motion, the lower attachment of the bladder wall to the cervix is pushed down to the level of the vagina.



The figures on this page illustrate the technique of hysterectomy without removal of tubes and ovaries.

FIGURE 30. The surgeon pulls the uterus toward him as he places the stitch ligature in the bloodless area between the ovarian vessels and the round ligament. The stitch includes the tube and ovarian ligament. If placed 1 inch lateral to the uterus, the tube and ovary will lie free without tension when the round ligament is brought over to suspend the vagina in the reconstructive stage.

FIGURE 31. Maintaining traction in the same plane, the operator places a back clamp on the uterine side of the ovarian ligament. The assistant keeps the initial suture on tension and prepares to secure the cut end of the vessel as the surgeon divides it. This step reduces the possibility of the vessel retracting out of the suture and is preferable to placing two stitch ligatures before dividing it.

FIGURES 32 AND 33. The surgeon places a second stitch ligature around the clamp while the assistant cuts the long ends of the first tie. The second stitch is then tied and cut.

FIGURE 34. Pulling the uterus toward him, the operator removes and reapplies a clamp on the uterine side to include all the structures arising at the cornu. This clamp prevents back bleeding.

FIGURE 35. First noting the position of the vessels in the posterior sheath of the broad ligament, the surgeon pushes the index finger of the right hand through the back of the broad ligament beneath the round ligament.

FIGURE 36. A stitch is placed in the round ligament lateral to the clamp. The assistant ties it.

FIGURE 37. The suture is left long and hangs outside the abdominal incision with clamp attached. The assistant keeps the suture on the round ligament on tension. The surgeon pulls the uterus toward him as he divides the round ligament.

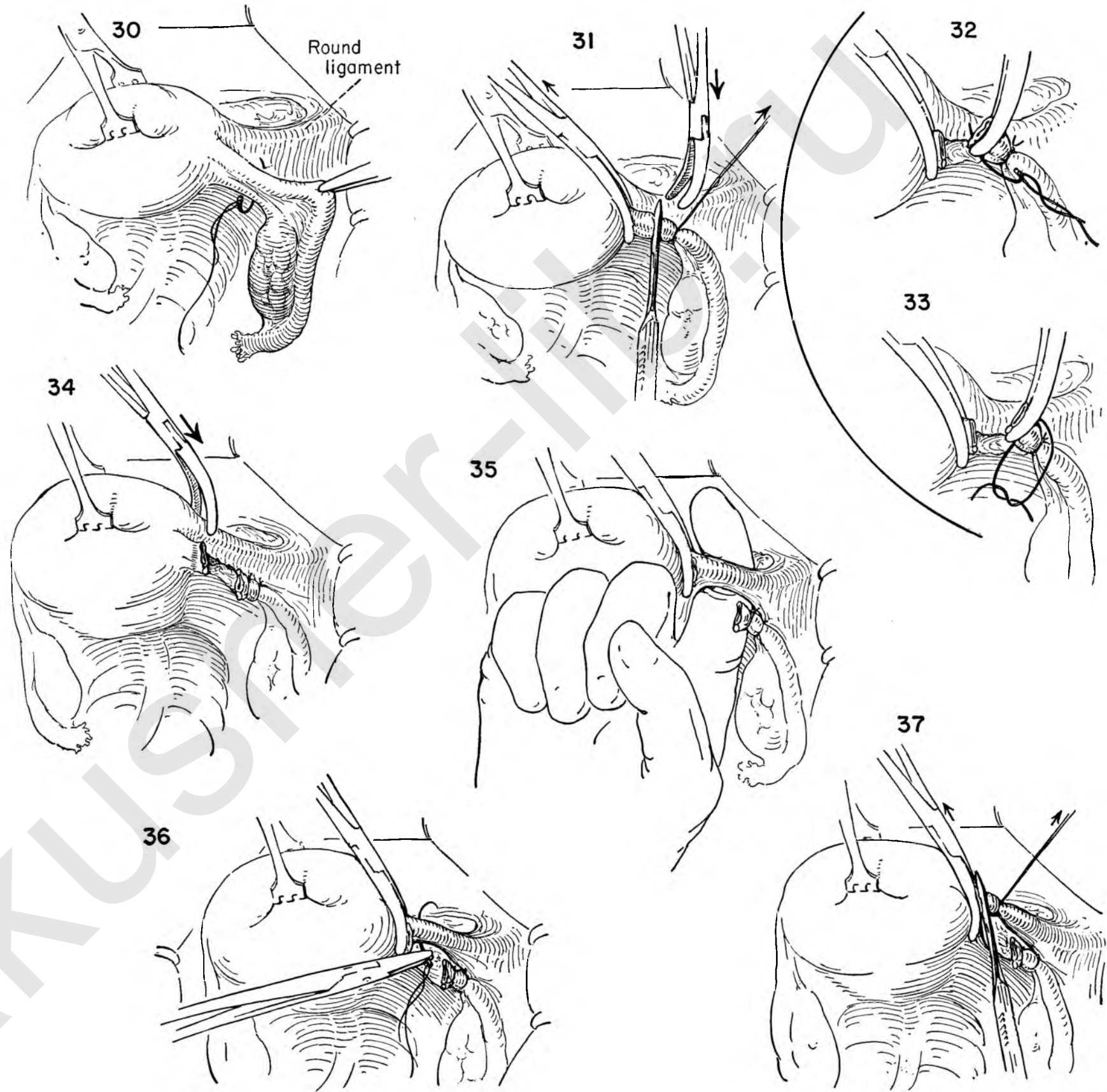


FIGURE 38. The surgeon retracts the uterus to the left while the assistant applies lateral traction on the divided round ligament. This places the broad ligament on tension. The posterior leaf is sectioned with scissors under direct vision down to the level of the uterine vessels seen crossing the ligament at its base.

FIGURE 39. The position of the ureter in relation to the uterine vessels and bladder can be determined by palpation of the base of the broad ligament. The ureter rolls between the thumb and forefinger of the examining hand. The adnexa are freed in similar fashion on the other side.

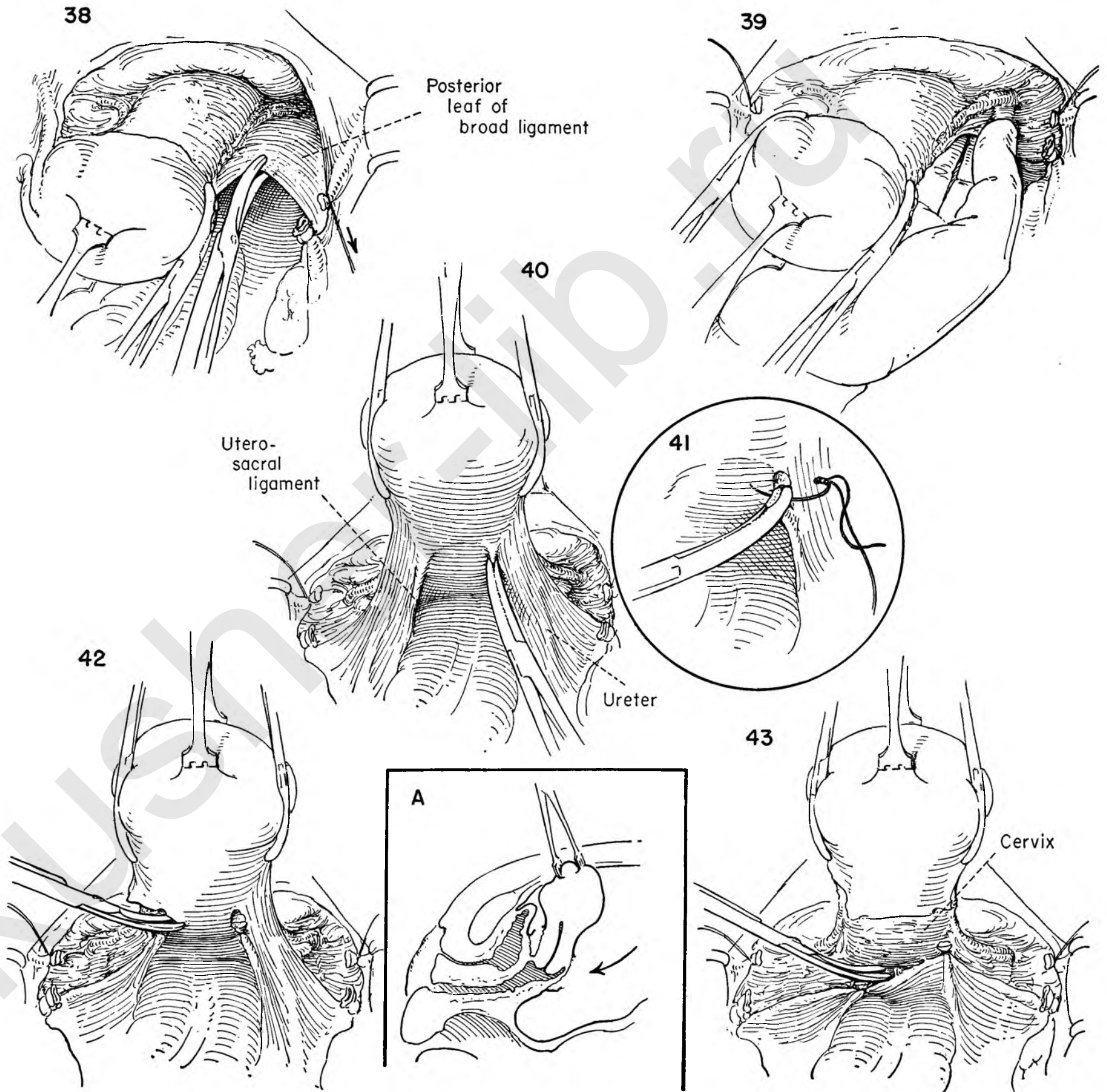
FIGURE 40. To continue mobilization, the uterosacral ligaments are attacked at this stage of the operation. Note the position of the ureter in relation to the uterosacral ligament. It is closer to the dissection at this point than at any other time during the operation. Pulling the uterus upward, the surgeon places a Kelly clamp on the uterosacral ligament close to the uterus and divides it.

FIGURE 41. Because of the proximity of the ureter, the stitch ligature should be applied with care. If there be doubt, the area should be explored. The suture is ligated and divided.

FIGURE 42. The preceding step is repeated on the left side. The operator then divides the posterior peritoneal surface between the sectioned uterosacral ligaments.

INSET A. The schematic sagittal section indicates that the uterus has now been circumcised of all peritoneal attachments.

FIGURE 43. The posterior peritoneal leaf is dissected further downward, exposing the wall of the vagina. The rectum is on occasion pulled up on the back of the uterus between the uterosacral ligaments. By this step the rectum is pushed back away from the posterior uterine and vaginal walls. This step is important. In addition to protecting the rectum and ureter by letting them fall back out of danger, the dissection permits subsequent clamps to be placed on the branches of the uterine vessels without having to include too much tissue. There is thus less danger of the vessel retracting out of the clamp or suture. The possibility of including the ureter in a clamp placed blindly to secure a retracted vessel is eliminated.



The illustrations on this page deal with the management of the uterine vessels. Two main principles that apply to all the steps outlined will greatly facilitate the ease and safety in handling the vessels: (1) The clamps should be placed close to the uterus under direct vision. (2) The exposure will be improved, minimizing the danger of including other structures in the clamp, if the surgeon will keep the uterus under constant traction in a direction away from the side he is working on.

FIGURE 44. Maintaining traction then to the left, the surgeon places a Kelly clamp on the uterine vessels close to the right side of the uterus in order to prevent back bleeding.

FIGURE 45. Under direct vision, another Kelly clamp is placed on the vessels below the previous one, leaving enough tissue to form a $\frac{1}{4}$ inch cuff as the vessels are divided between clamps.

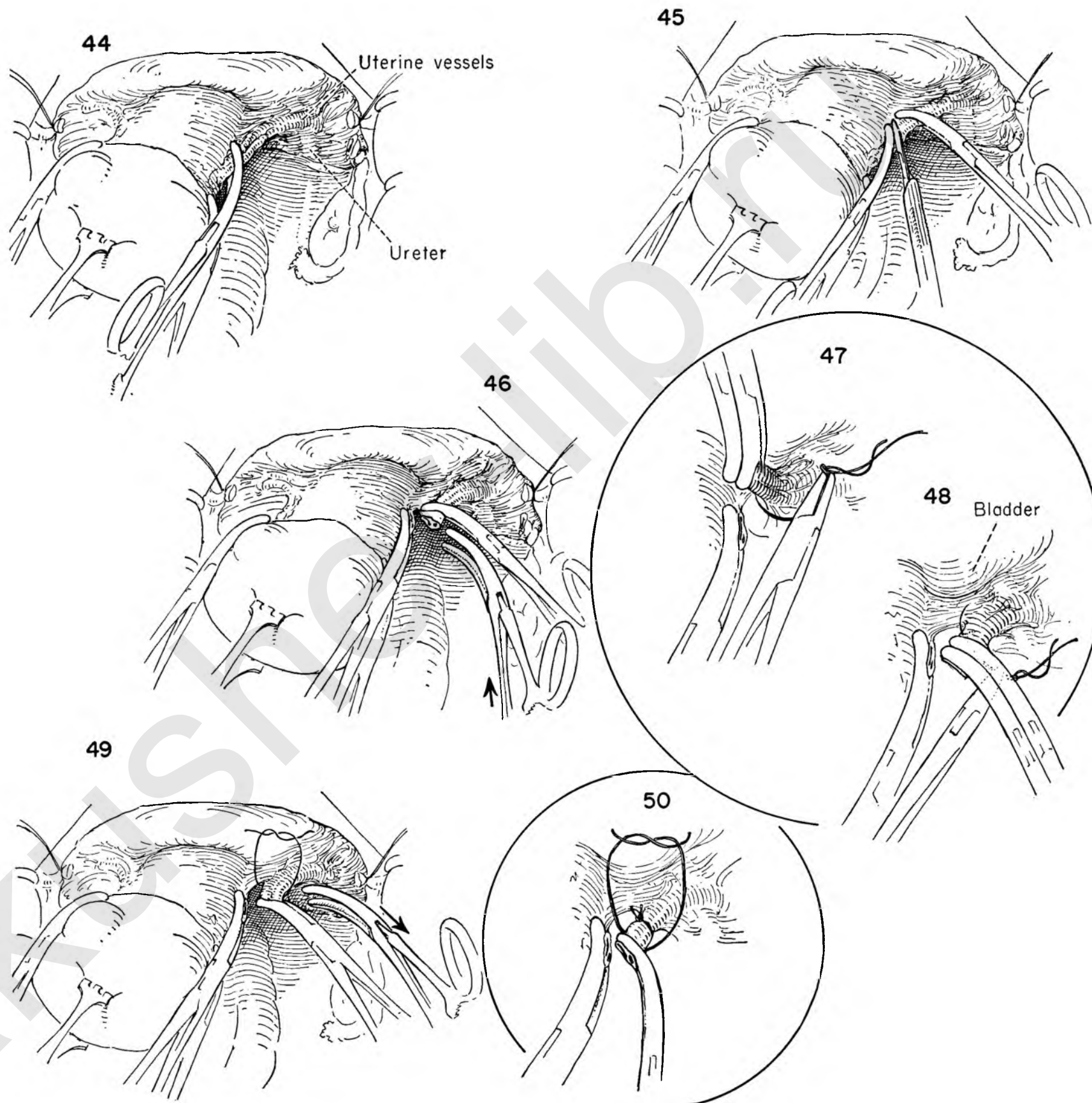
FIGURE 46. To prevent possible retraction of the vessel out of the clamp or loss of control of the vessel through breaking of a single tie, a second clamp is placed on this cuff.

FIGURES 47 AND 48. The proximity of the bladder edge is determined before the operator places a stitch ligature beyond the position of the most distal clamp. Traction on the uterus to the left facilitates this move.

FIGURE 49. The surgeon removes the lateral clamp as the assistant ties the first ligature. The proximal clamp remains to prevent retraction of the vessel should the ligature break in tying.

FIGURE 50. A second stitch ligature is then placed around the uterine vessels and ligated, and the clamp removed.

Because the bladder has been pushed off the cervix (Fig. 29), the broad ligament kept on tension (Fig. 37) and the uterosacral ligaments retracted from the cervix (Fig. 43), the ureter is in a position well lateral to the ligatures around the uterine vessels. The danger here is in the proximity of the bladder. The actual position of the bladder edge must be determined before the stitch is placed around the vessel, to avoid damage and the risk of a vesicovaginal fistula.



If the entire cervix is to be removed without leaving a portion at each lateral angle, it is necessary to mobilize the bladder well off the vagina, not only anteriorly and posteriorly, but laterally as well.

The steps illustrated in this plate indicate the simplest and safest method of separating the cervix from the bladder and interrupting its lateral attachments. The surgeon prepares an operative field where the entire dissection is under direct vision. It is thus easier to control the bleeding vessels. Danger to the ureter comes from attempts to control bleeding with suture and clamp in an area obscured by hemorrhage. Damage to the base of the bladder is avoided by keeping it in sight at all times.

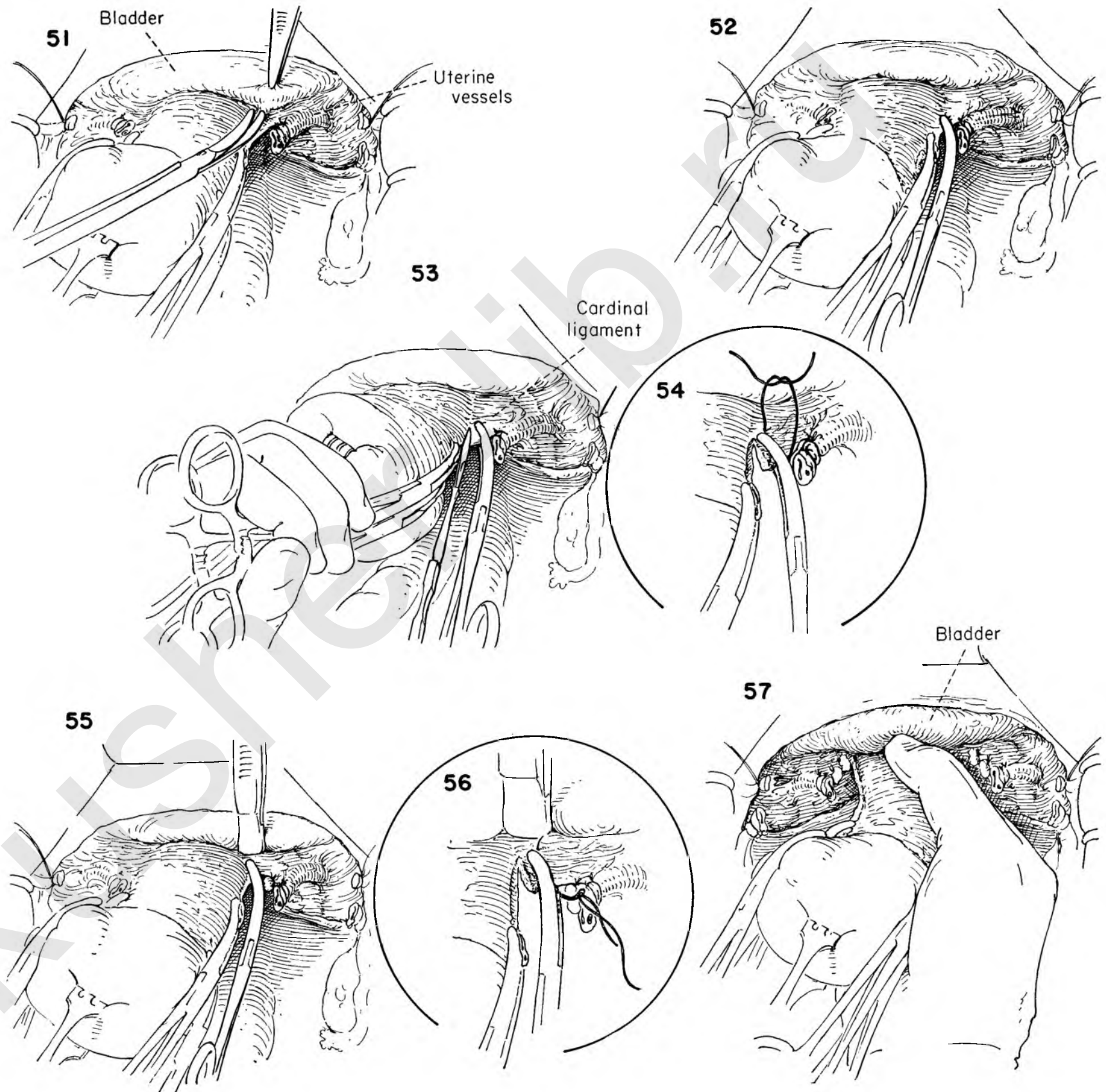
FIGURE 51. Note that the lateral attachments of the bladder hold it up on the uterine vessels in a crescentic fold. The surgeon separates the areolar strands of these attachments by pulling the uterus to one side while the assistant retracts the bladder edge. This tissue cannot be handled roughly without causing free bleeding which obscures the operative field.

FIGURE 52. The bladder is now free from the cervix. The previous dissection of the uterosacral ligaments (Fig. 43) permits the application of a Kelly clamp under direct vision without including a large amount of tissue. This clamp parallels the cervix medial to the sutures on the uterine vessels. A back clamp is unnecessary.

FIGURES 53 AND 54. After retracting the bladder, the surgeon divides the tissue between the cervix and clamp, leaving a cuff to prevent retraction. A stitch ligation is placed and tied.

FIGURES 55 AND 56. It is well to repeat the previous steps and cross the cardinal ligament in a series of small bites, rather than include all the tissue in one large one. The need for this will vary with the individual case. The principle involved is to include only as much tissue as can be safely controlled with the stitch. Note the position of the bladder. No clamp or suture is applied without visualizing the position of the adjacent viscera.

FIGURE 57. By palpating the cervix between the thumb and fingers, the extent of dissection is checked before proceeding further.



The uterus is now completely freed on all sides.

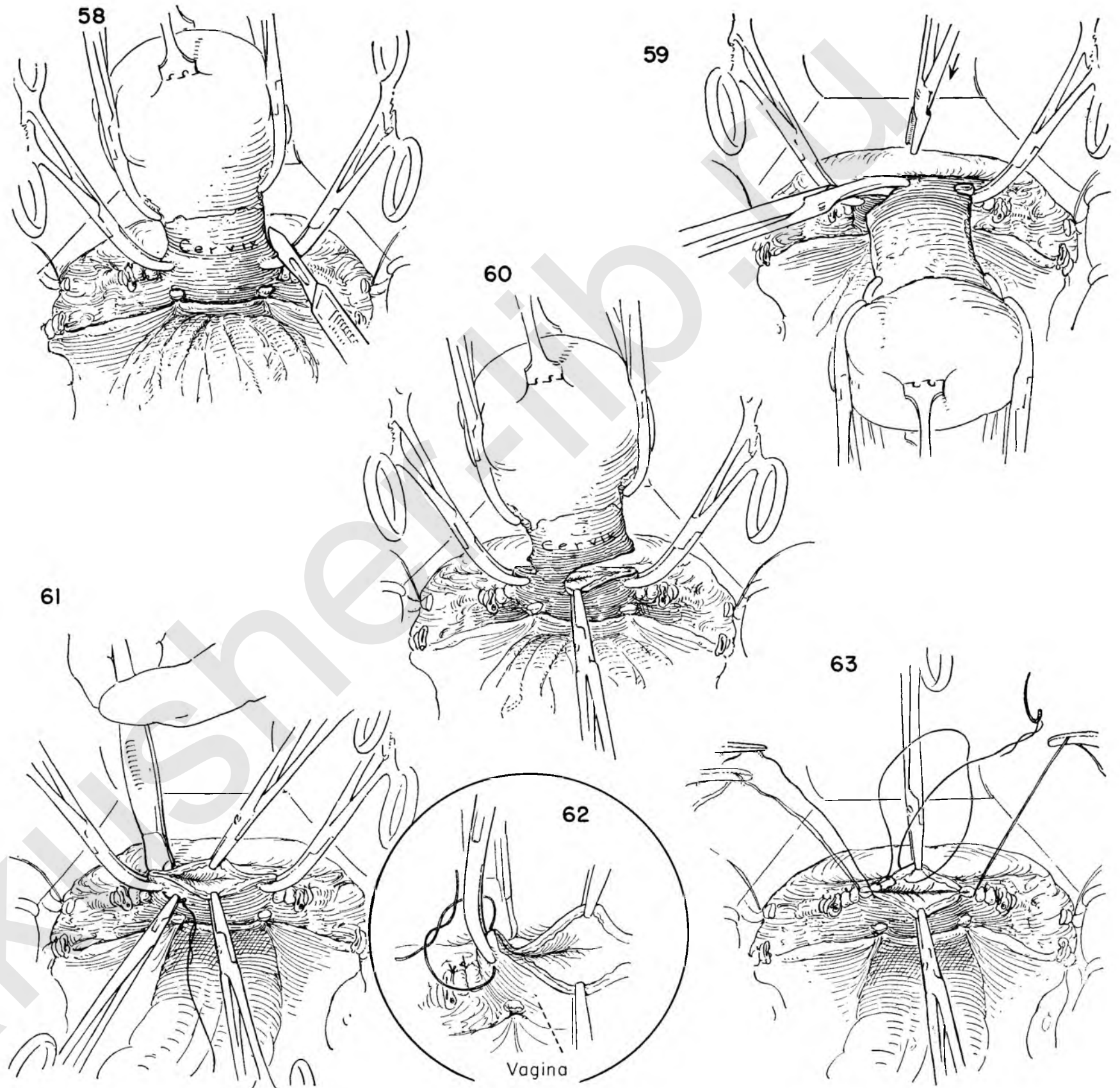
FIGURE 58. The surgeon elevates the uterus and applies a clamp on either side of the vaginal canal approximately $\frac{1}{2}$ inch below the lateral edge of the cervix. The vagina is then entered by incising the tissue above the clamps.

FIGURE 59. The bladder edge is retracted so that it may not be included in the Kocher clamp that the assistant will apply to the anterior edge of the vagina as the surgeon transects it with scissors.

FIGURE 60. A Kocher clamp is placed on the posterior edge of the incised vaginal wall.

FIGURES 61 AND 62. With the bladder again held back, a stitch ligature is placed around the clamp at the lateral angle of the vagina. This stitch is tied by the surgeon on his side and by the assistant on the other. The sutures are clamped and kept long to provide continued traction on the vagina, lost when the uterus was removed.

FIGURE 63. The vaginal canal is to be left open. There is a tendency for the vaginal epithelium to retract from the musculature, carrying thrombosed but unsutured vessels with it. This may result in postoperative bleeding from the vaginal cuff. The cut edge of the vagina is therefore sutured with a running lock stitch around the entire circumference. Leaving the vagina open permits drainage and results in less of a conical-shaped vagina.



The reconstructive steps are now in order.

FIGURE 64. The vagina is maintained on traction with the stay sutures at the angles. The uterosacral ligament on the left is grasped by the surgeon and resutured to the posterior vaginal wall. The step is repeated on the opposite side.

FIGURES 65, 66 AND 67. The round ligament is now brought back into the operative field. The surgeon places a mattress stitch through the substance of the ligament and sutures it to the lateral angle of the open vagina. Note that the ovary and tube hang freely without tension after the round ligament is reapproximated to the vagina. This will avoid interference with the blood supply to these structures.

The remaining figures on the page have to do with peritonealization. The exposed raw areas on the pelvic floor must be covered to prevent bowel from becoming adherent to the operative site.

FIGURES 68, 69 AND 70. The assistant retracts the ovary to expose the raw cut edges of the pelvic peritoneum. The surgeon then uses a running atraumatic suture to close the defect, beginning at the lateral corner and continuing to the opposite side. The value of the initial step in freeing the bladder from the anterior peritoneum now becomes apparent. The bladder flap is brought down to cover the vaginal canal. The bladder remains undisturbed in its normal bed.

FIGURE 71. The finished closure shows the entire pelvic floor covered with peritoneum. The round and uterosacral ligaments suspend the vaginal canal. The tubes and ovaries lie easily in normal position without tension.

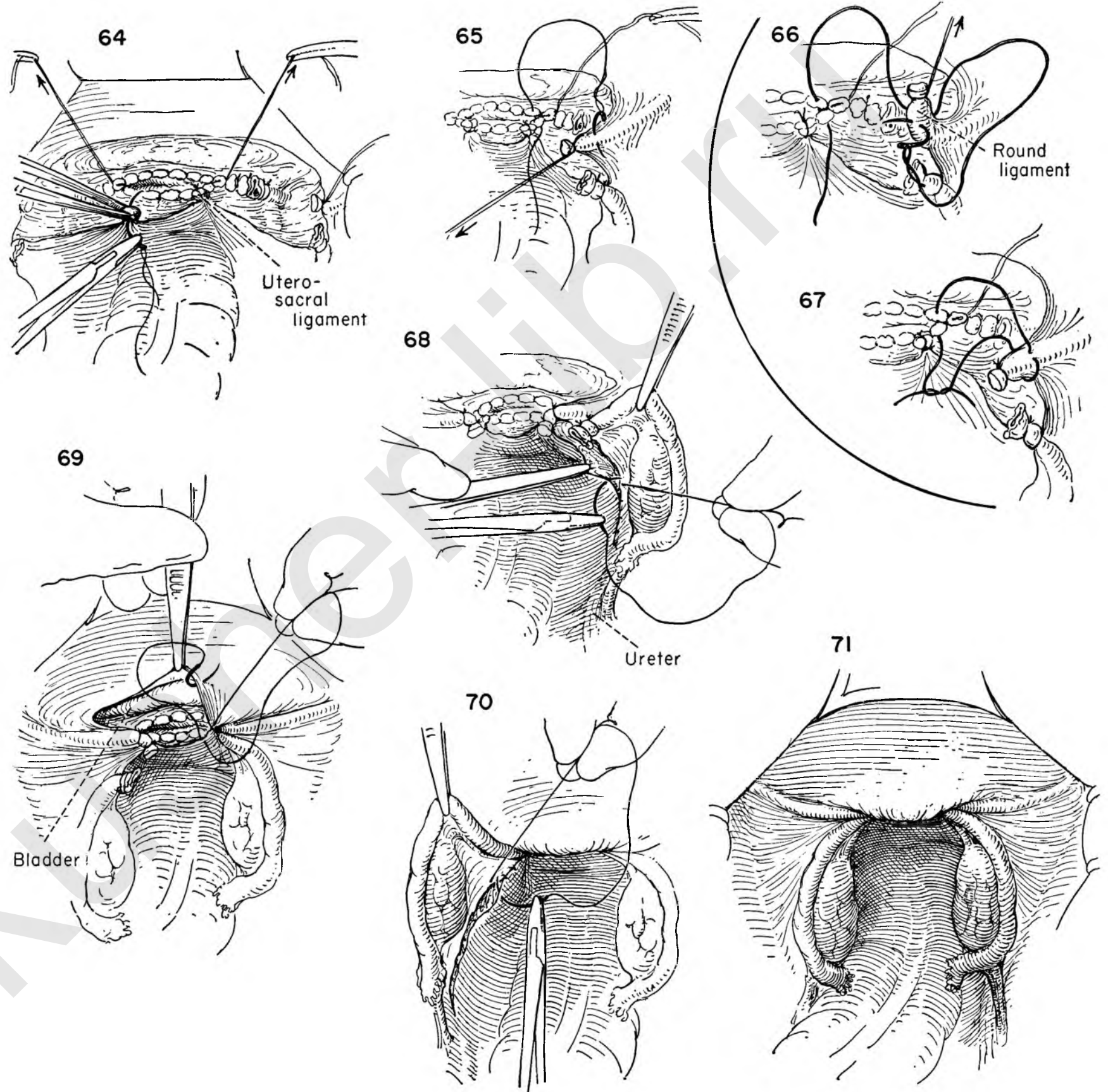
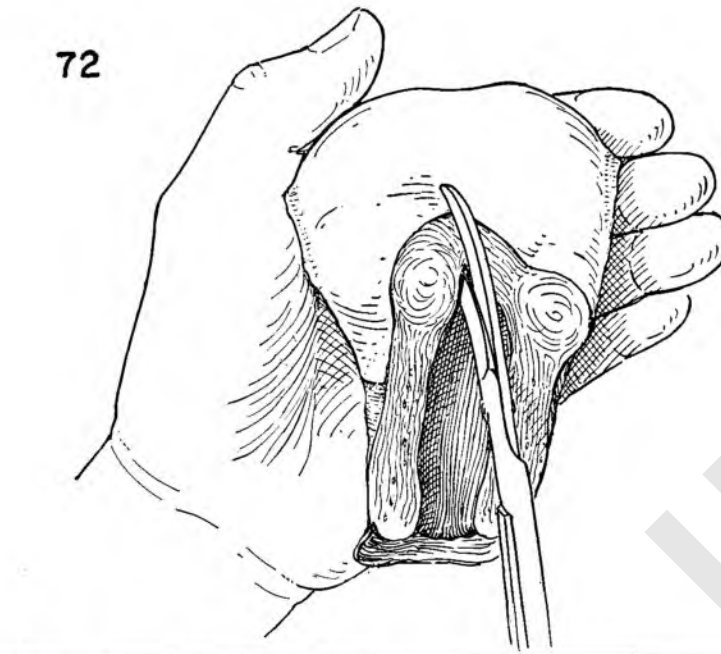


FIGURE 72. Before the abdomen is closed, the uterus should be presented to the pathologist if he is present. If not, the anesthetist should be asked to open the specimen, exposing the endometrial cavity for inspection by the surgeon. Routine insistence on the opening of the uterus at the operating table, before the abdomen is closed and while the patient is still under an anesthetic, will spare the surgeon the unhappiness of being confronted with an unexpected pathological finding later on. This is particularly important when ovarian tissue is left. The curettage is not 100 per cent accurate.

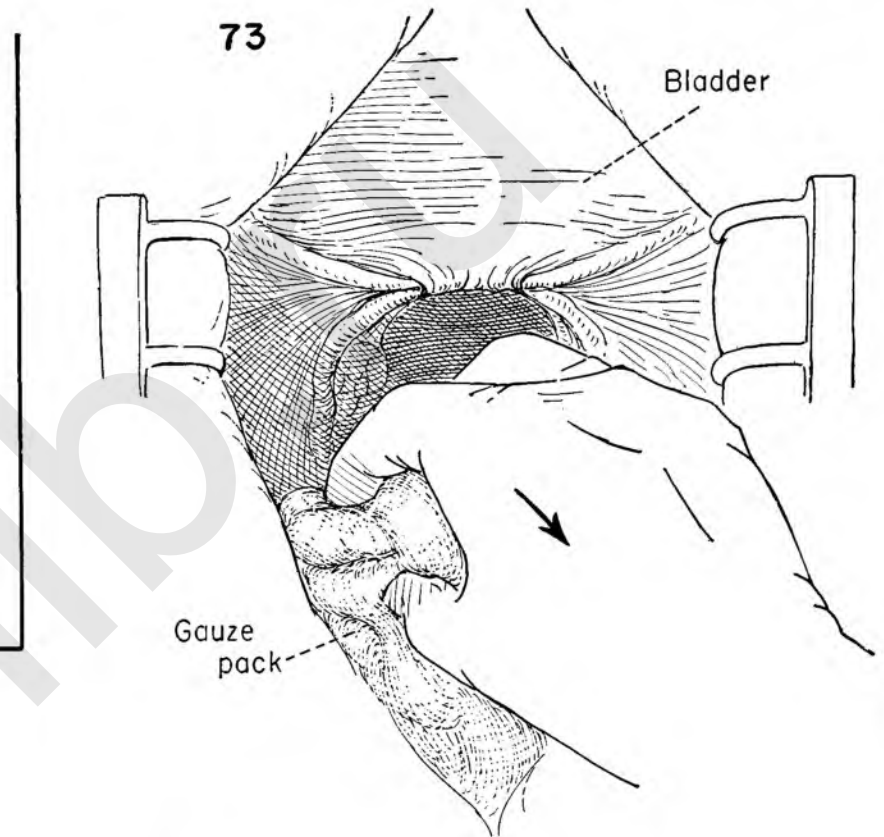
FIGURE 73. With the assurance that all surgery within the abdomen is complete, the surgeon is now ready to close the abdomen. All packs are removed from the upper abdomen and presented to the nurse for counting.

FIGURE 74. To prevent the small bowel from descending into the cul-de-sac and occupying a position adjacent to the recent operative site, the surgeon grasps the redundant sigmoid and carefully places it in the cul-de-sac.

FIGURE 75. The surgeon then reaches into the upper abdomen to retrieve the omentum. The omentum should be inspected for any bleeding points. Any tears or holes should be closed with silk or catgut sutures.



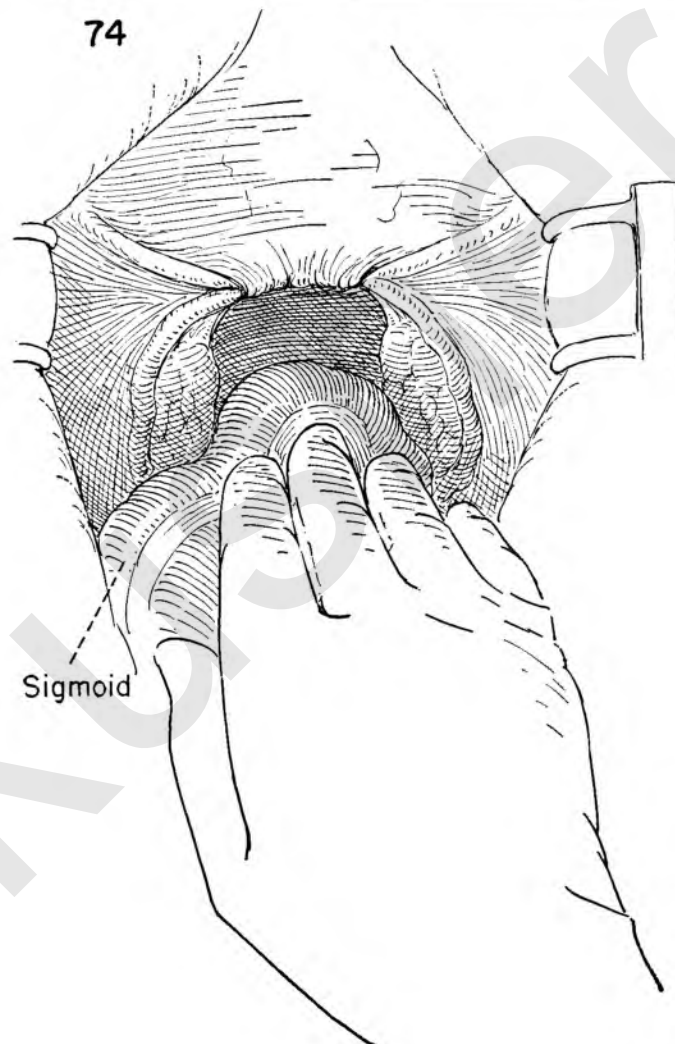
72



73

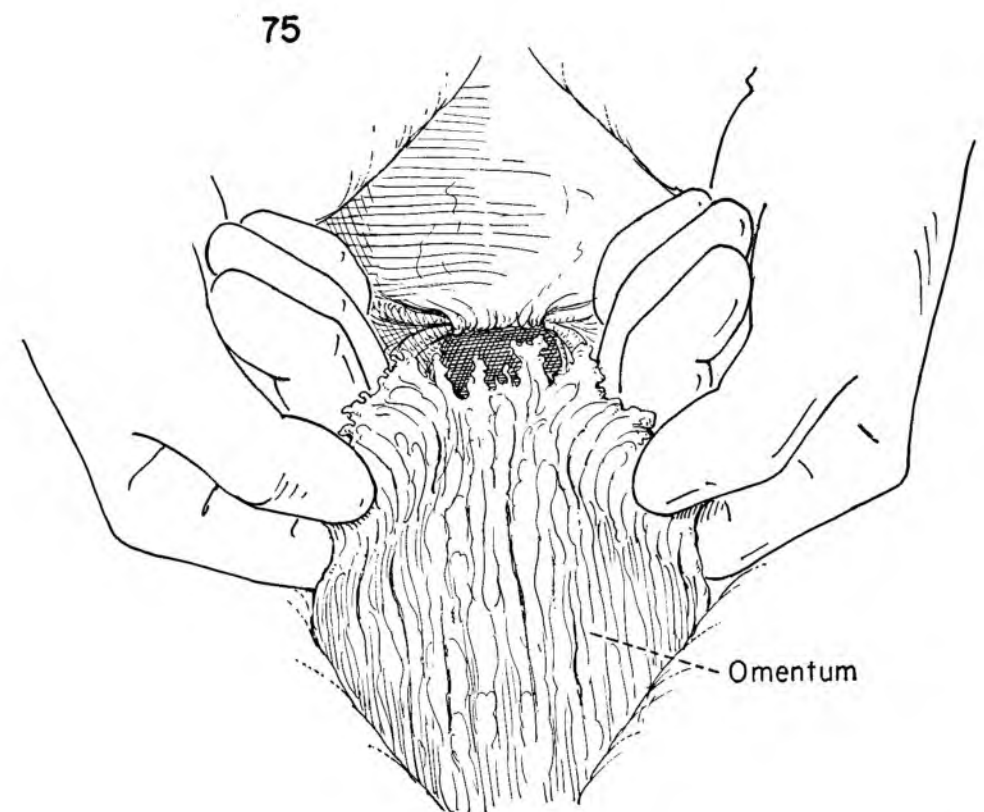
Bladder

Gauze pack



74

Sigmoid



75

Omentum

The operation completed and the sponge count reported correct, the patient is now ready for closure of the abdominal wall.

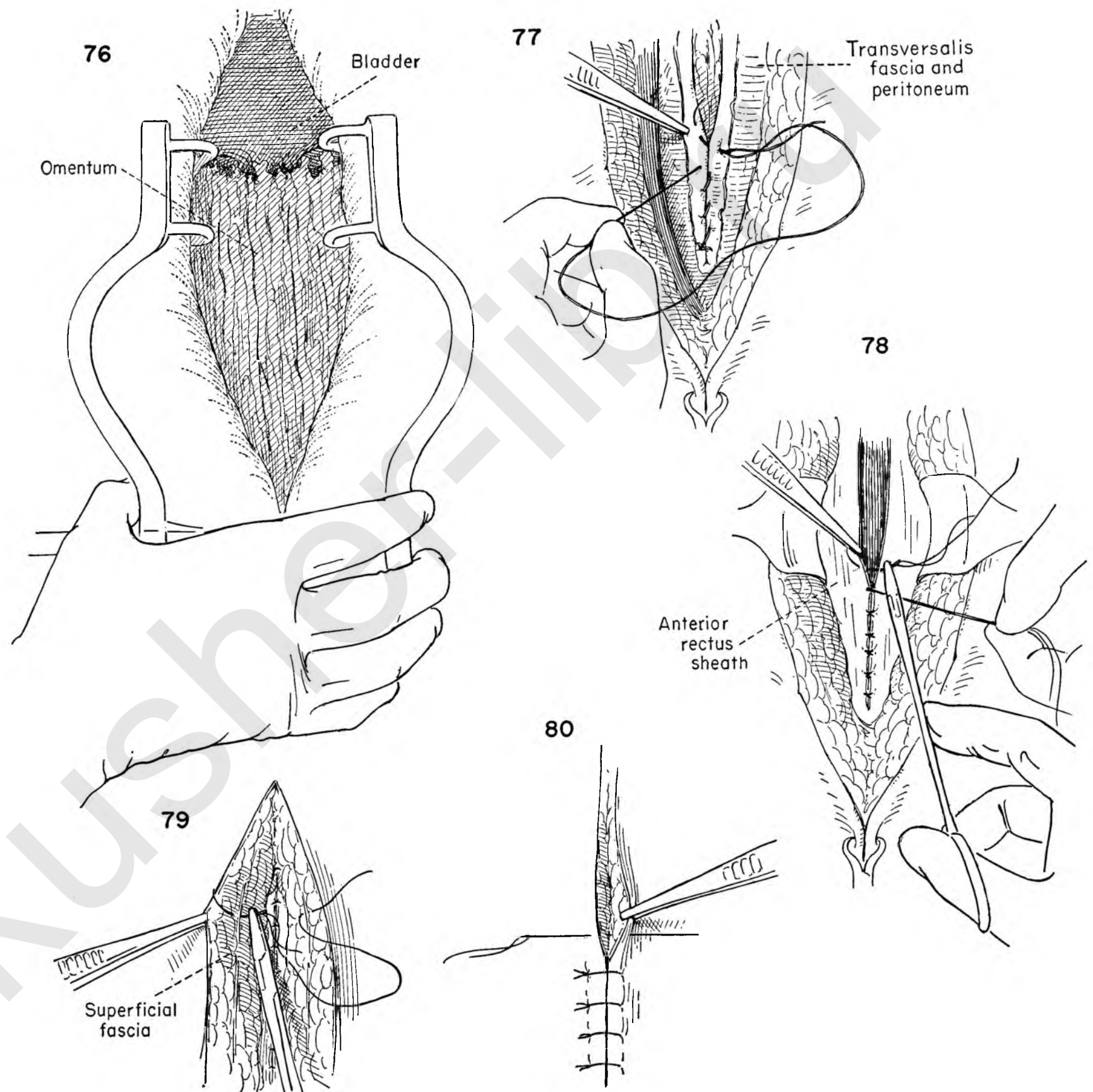
FIGURE 76. The omentum is so placed that the small intestine is completely covered. The self-retaining retractor is then removed.

FIGURE 77. The assistant exposes the upper end of the wound so that the surgeon may place the first suture through the peritoneum and posterior rectus sheath. This suture is continued as a running stitch from above downward. It approximates peritoneum to peritoneum.

FIGURE 78. The operator prepares to close the fascia. The assistant exposes it by retracting the fat of the skin edges. Interrupted silk or cotton sutures are placed and individually tied by the assistant. Exposure is helped by holding each suture on tension as the next one is laid in.

FIGURE 79. The skin towels are now removed. Interrupted sutures are placed at intervals in the subcutaneous fat to close the dead space.

FIGURE 80. The surgeon then closes the skin edges with evenly spaced, interrupted silk or cotton stitches. Care should be taken that each one enters at a right angle to the skin. This insures better approximation. The dressing is then applied.



Modifications of Total Hysterectomy

The operation of total hysterectomy has been described in detail through all the steps to final closure of the wound. Rather than break this continuity, no attempt was made to introduce alternative technical maneuvers that might better serve particular situations. This chapter is introduced to suggest various modifications of the routine total hysterectomy.

REMOVAL OF THE TUBE AND OVARY AS PART OF THE HYSTERECTOMY

There are many occasions when proper therapy demands the removal of one or both ovaries. The ureter may easily be damaged in this operation; in fact, one of the most common points of ureteral injury is the region where both the ureter and ovarian vessels cross the common iliac artery. The two lie in close approximation at this level. Careless handling of tissue in this region may set up troublesome bleeding which may result in the inclusion of the ureter in clamp or stitch as attempts are made to control the bleeding. It is important to visualize the ureter before placing the stitch around the vessels.

SUPRACERVICAL HYSTERECTOMY

It is not our intention to discuss the merits of total versus subtotal hysterectomy. This choice should be made by the surgeon on the basis of the presenting pathological condition rather than technical unfamiliarity with the more extensive procedure. Moreover, it should be kept in mind that when there is any question of malignancy of the uterus, tube or ovary, supracervical hysterectomy is an utterly inadequate operation.

MARSHALL-MARCHETTI OPERATION

Operations advised for the correction of stress incontinence are many and varied and are not always effective. The authors are of the opinion that most instances of stress incontinence will best be attacked by a direct approach on the bladder neck from the vaginal side.

Nevertheless many patients in whom the primary indication for surgery calls for removal of the uterus will have varying degrees of stress incontinence. If no attempt is made to correct the sagging bladder neck, these patients may be made worse after the total removal of the uterus. The procedure described by Marchetti can readily be applied in this situation.

Direct visualization of the bladder neck and urethra is

easily accomplished in a bloodless field after completion of the abdominal surgery.

The technical problems of placing the reparative sutures are minimized by the introduction of a Foley catheter in the bladder and an assistant's hand in the vagina pushing up on the bladder neck. These sutures are placed in the paraurethral tissue close to but not including the wall of the urethra.

HYSTERECTOMY IN THE PRESENCE OF A CERVICAL FIBROID

A fibroid arising from the cervix and expanding between the leaves of the broad ligament may complicate the technical difficulties of a total hysterectomy. The chief problems in surgical management revolve around hemorrhage and possible vesical and ureteral damage due to the proximity of the tumor to the ureter, uterine vessels and plexus of veins around the bladder floor. By observing certain precautions this danger may be minimized.

To avoid damage to the ureter its course in the pelvis should be checked. The ureter can always be seen through the peritoneum as it crosses the common iliac artery. If the peritoneum is incised at this point above the level of the tumor and the operative field kept open by placing stay sutures on the divided edges of the peritoneum, the surgeon will have no difficulty in visualizing the ureter throughout its course.

Damage to the bladder and excessive bleeding may be avoided if the surgeon will take advantage of the pathological fact that the fibroid tumor is normally encapsulated. An incision through the capsule down to the tumor on the superior surface will permit the fibroid to be shelled out of its bed, leaving the vessels, ureter and bladder on the capsule away from harm. With the tumor delivered, the operation proceeds in routine fashion.

MOBILIZATION OF THE UTERUS AND ADNEXA WHEN ADHERENT

It is a common error to attempt to remove the uterus, tube or ovary without first mobilizing the organ to be removed. Small bowel may be found adherent to the fundus, ovary or posterior wall of the broad ligament and must be separated before attempting to remove any of the pelvic organs.

When adhesions bind the intestine to the uterus, it is important to stay on the uterine side in the dissection to

minimize the risk of injury to the bowel. Immediate repair is indicated if damage occurs.

The adnexa must be free from the posterior leaf of the broad ligament before removal. Pelvic inflammation separates readily, but endometriosis, because of its tendency to invade, can be freed only after rupture and spillage of the contents of the chocolate cyst.

Endometriosis of the rectovaginal septum may bind the rectum firmly to the posterior uterine wall. Traction on the uterus with a sudden forward thrust toward the symphysis may produce a crack in the serosal cover of the posterior uterine wall above the adherent bowel. A safe plane of cleavage is thus established.

PERITONEALIZATION OF LARGE RAW SURFACES

The destruction of pelvic peritoneum may be so extensive after excision of widespread endometriosis that not enough normal peritoneum can be mobilized to close the defect. The sigmoid may be used to complete the peritonealization without materially altering the course of the bowel or producing subsequent disturbances in function.

CORRECTION OF SLIGHT CYSTOCELE BY A V EXCISION OF THE ANTERIOR VAGINAL WALL

A small cystocele or tendency of the anterior vaginal wall to sag may be corrected by removal of a V-shaped segment of the anterior wall in its long axis. Closure of the vagina will automatically shorten the anterior wall and take up the slack.

SPLITTING THE ANTERIOR CERVICAL FASCIA

At times the separation of the bladder from the cervix and anterior vaginal wall may be difficult. If there is any possibility of damage to the bladder floor, the surgeon had best split the fascia overlying the cervix. There is always a plane of cleavage beneath it.

If the surgeon will then apply the clamps so that the upper blade is always below the fascia, no possible damage to the bladder can follow, for the bladder floor lies superior to the fascial layer. In fact one may choose to adopt this as a routine procedure in total hysterectomy. The majority of vesicovaginal fistulae seen today follow damage to the bladder during total removal of the uterus.

REMOVAL OF OVARY AND TUBE WITH HYSTERECTOMY

The entire technique of hysterectomy will be markedly simplified if the surgeon will defer sectioning the ovarian vessels until after the bladder flap has been developed.

FIGURE 1. The broad ligament has been entered through the anterior peritoneal leaf on both sides of the cervix. The bladder has been reflected medially by finger dissection in a bloodless area. The peritoneal bridge is now being divided. The surgeon proceeds carefully, for the bladder is closely adherent to the flap.

FIGURE 2. A Kelly clamp is placed on the right tube and ovary. By holding the tenaculum and the Kelly clamp together in the left hand, the uterus and adnexa are pulled toward the operator. This places the right infundibulopelvic ligament with the ovarian vessels on stretch. Before placing the first stitch ligature, determine the position of the ureter in relation to the vessels. This is one of the commonest areas where the ureter may be damaged. The ureter normally crosses the common iliac artery in close proximity to the ovarian vessels. Careless application of the first stitch ligature may include the ureter.

FIGURE 3. The stitch is tied by the assistant and kept on tension as the surgeon applies a Kelly clamp on the uterine side to prevent back bleeding. The surgeon then divides the vessel between clamps and cuts the initial suture as the assistant applies a clamp to the cut end of the ovarian vessels. A second stitch ligature placed around the clamped vessel provides a double ligation of the ovarian vessels.

FIGURE 4. The right adnexa and uterus are again pulled to the left, placing the peritoneum on tension. The attachment is then divided in the bloodless area in the direction of the uterine cornu and up to the point of round ligament attachment.

FIGURE 5. The uterus is now pulled upward and forward toward the symphysis to expose the posterior sheath of the right broad ligament. Noting the position of the uterine vessels, the surgeon gently forces the index finger of the right hand through the broad ligament just below the round ligament. A Kelly clamp has been placed on the uterine end of the round ligament to prevent back bleeding.

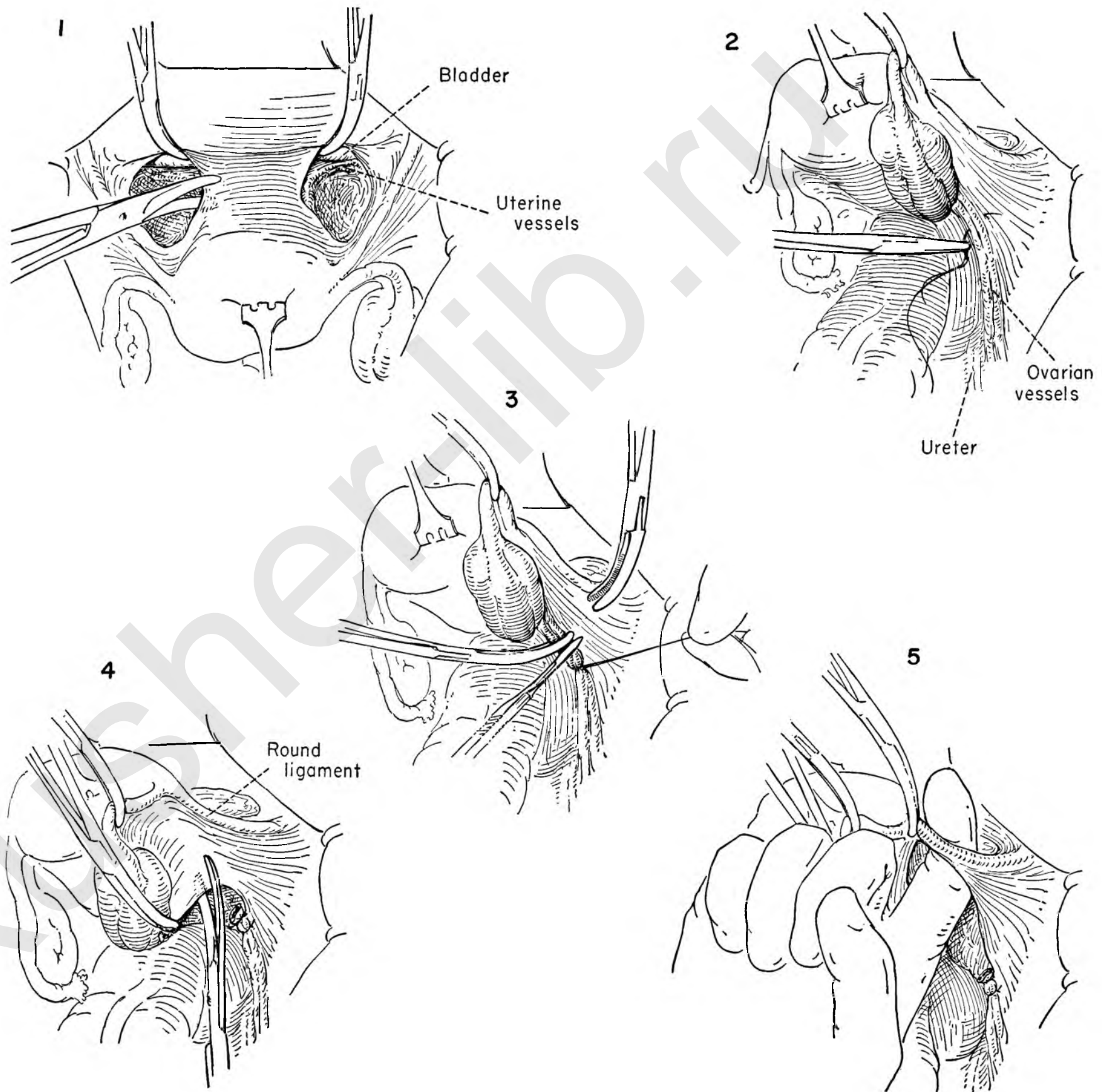


FIGURE 6. The surgeon elevates the uterus by traction on the tenaculum, and a stitch ligation is passed through the substance of the round ligament.

FIGURE 7. The assistant ties the suture and leaves it long, to hang outside the abdominal cavity. The round ligament is divided between clamp and suture.

FIGURE 8. The uterus is kept on tension to the left while the assistant applies traction to the long suture on the round ligament. The posterior leaf of the broad ligament is then divided. The surgeon then proceeds with the regular steps of the total hysterectomy.

PERITONEALIZATION

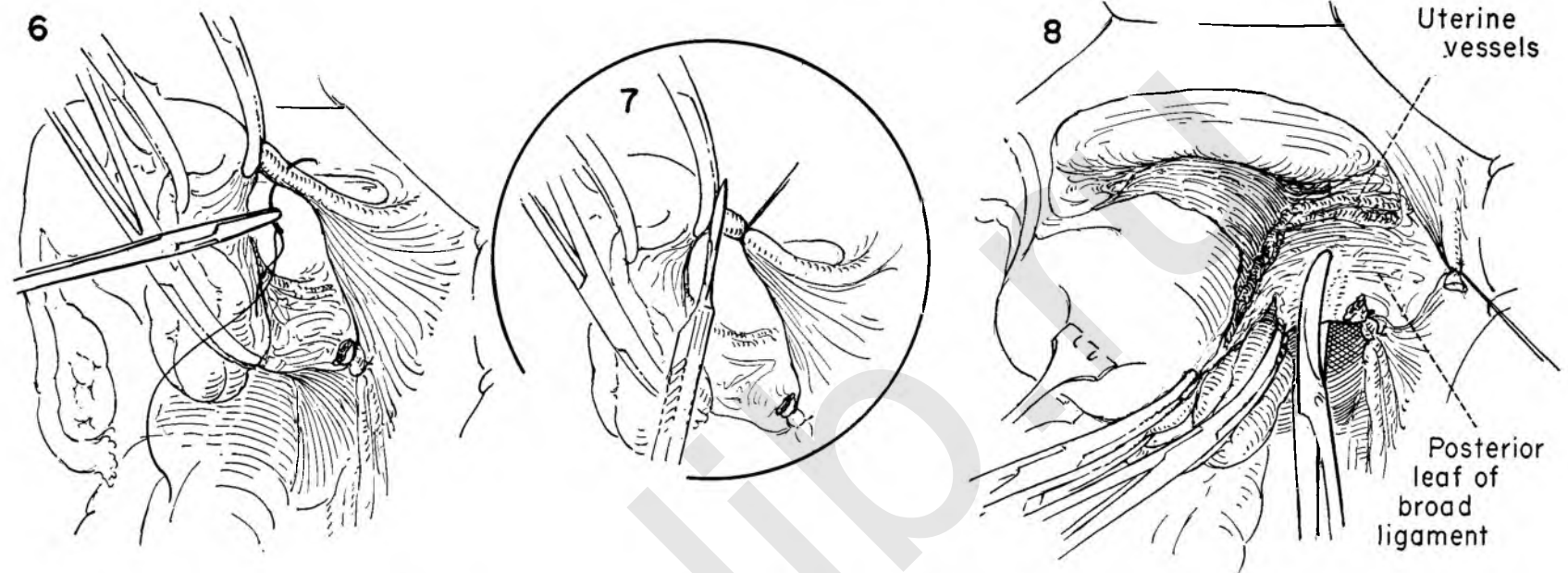
The problem of peritonealization after removal of the adnexa differs from that described when the ovary is left in.

FIGURE 9. The round ligament is resutured to the lateral angle of the open vagina after re-approximating the uterosacral ligaments to the posterior vaginal wall. The raw defect left after removal of the right adnexa is exposed.

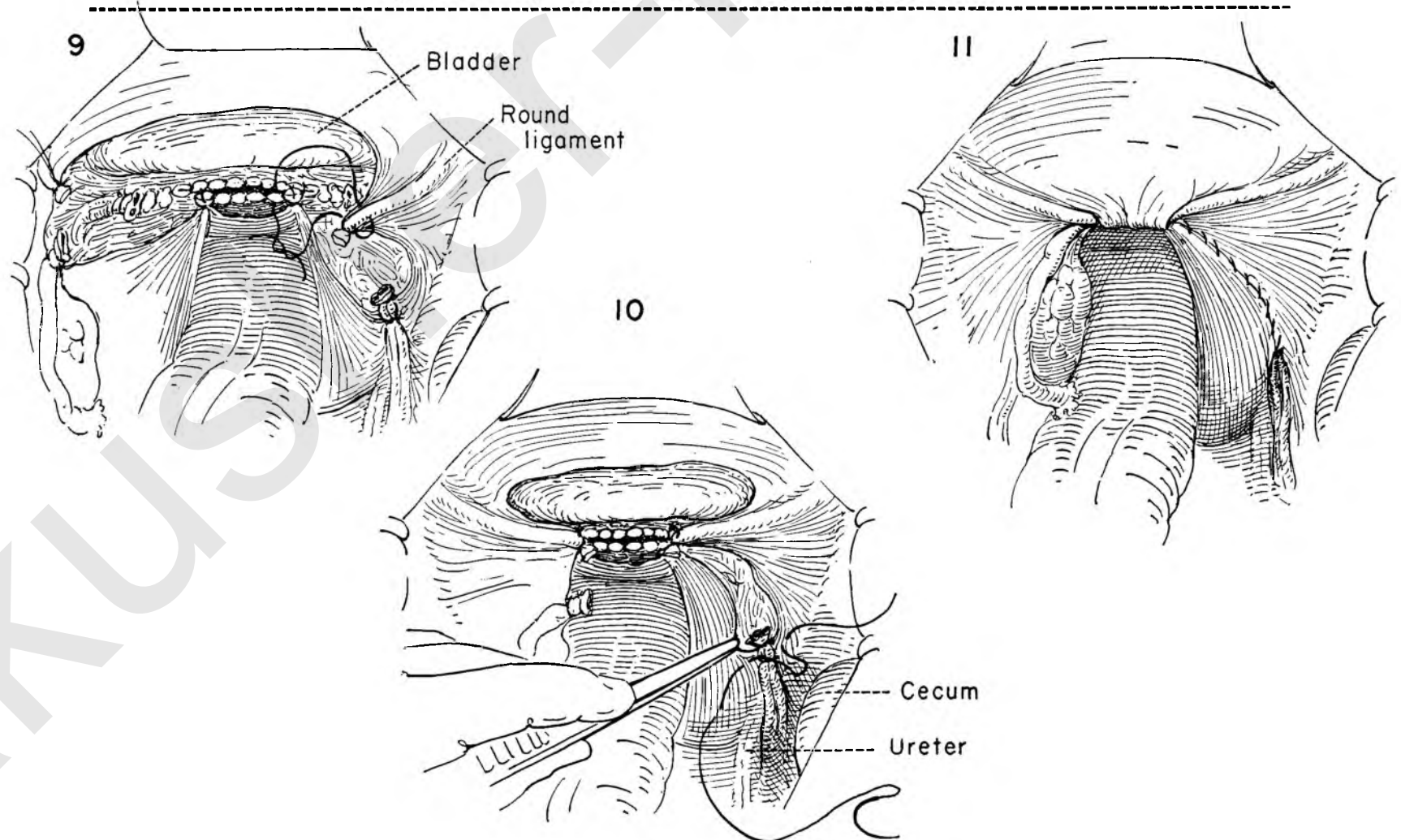
FIGURE 10. An atraumatic suture picks up the peritoneum above and below the stump of ovarian vessels on the right. The suture is so placed that peritoneal surface approximates peritoneal surface. In this manner the cut end of the ovarian vessel is buried beneath the peritoneum. The opposite or left ovary lies freely without tension after suturing the round ligament to the open vagina.

FIGURE 11. A continuous over and over running suture closes the defect in the peritoneum. The free peritoneal edge overlying the bladder is included in the peritoneal covering over the vagina. Note that the free edge pulls down easily without disturbing the position of the bladder.

The peritonealization is now complete. The left ovary and tube remain. The right adnexa have been removed. If there is any doubt about the presence of pathology in the ovary that is to be left, the surgeon should split the ovary in its long axis and inspect the inner surfaces. The ovary is then closed with interrupted sutures.



Hysterectomy then proceeds as in Plates X-XIII



SUPRACERVICAL HYSTERECTOMY

In the past this operation probably represented one of the commonest intra-abdominal pelvic procedures. In recent years the method has largely been superseded by total hysterectomy. However, a surgeon may elect to leave the cervix for adequate cause whenever removing the uterus. Supracervical hysterectomy should never be performed when there is any suspicion of malignancy of the uterus or adnexa.

The preliminary steps are identical with those for total hysterectomy and will not be repeated. The bladder flap has been developed, the adnexa left in situ, the round ligament divided and the broad ligament opened. The uterine vessels have been severed and doubly ligated. The bladder has been mobilized just enough to permit incision through the cervix and subsequent closure without endangering the bladder base.

INSET A. Diagrammatic representation showing the uterus free of peritoneal cover with the line of incision indicated in the lateral view. The relationship of the cervix to the vaginal canal and posterior vaginal wall is outlined.

FIGURE 1. The uterus is placed on tension by grasping all the clamps, including the tenaculum, in the left hand. The surgeon then incises the anterior wall of the cervix above the bladder reflexion and stump of the uterine vessels.

FIGURE 2. The uterus is drawn sharply forward and upward toward the symphysis as the surgeon incises the posterior wall of the cervix above the uterosacral ligaments and the ligated uterine vessels.

FIGURE 3. In order that the traction be continued on the cervical stump after the uterus has been removed, a Kocher clamp is placed on the anterior incised edge. Upward traction is applied by the surgeon on the tenaculum and by the assistant on the Kocher. In order that the endocervical lining be removed from the stump, the surgeon bevels the knife blade to bring about a conical excision of the cervical musculature with included endocervical epithelium.

FIGURE 4. The uterus is again drawn forward against the symphysis to expose the posterior cervical wall. A Kocher clamp is placed on the posterior edge to aid in maintaining traction. The conical removal of the lower cervical segment is completed.

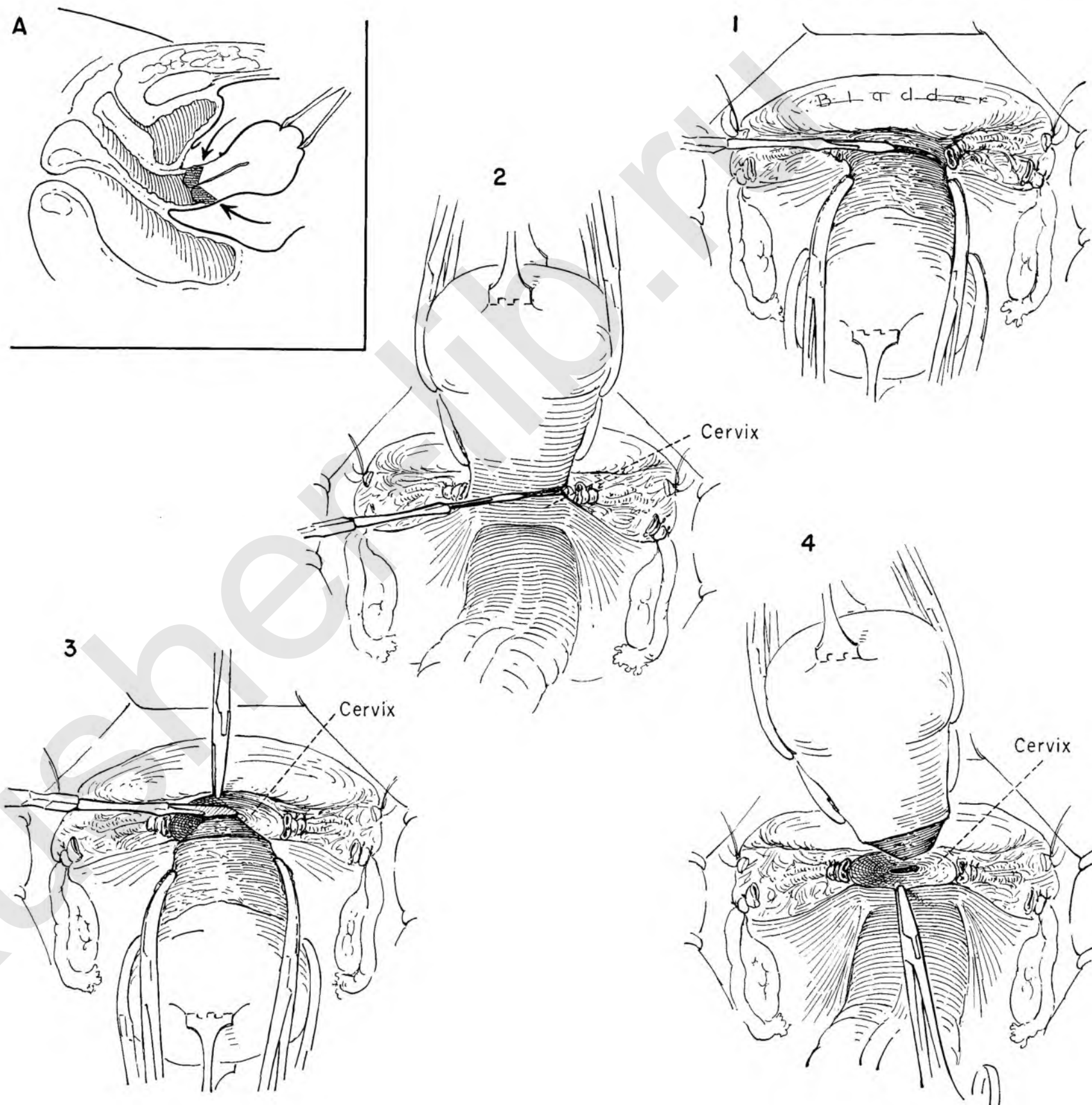


FIGURE 5. Traction on the cervical stump is maintained by the Kocher clamps as the surgeon places the first stitch ligature into the right angle of the cervix just medial to the doubly ligated uterine arteries. A heavy needle with a cutting point is needed to traverse the firm cervical musculature. The sutures are placed deeply into the muscle to include the apex of the cone in order that all bleeding vessels may be controlled.

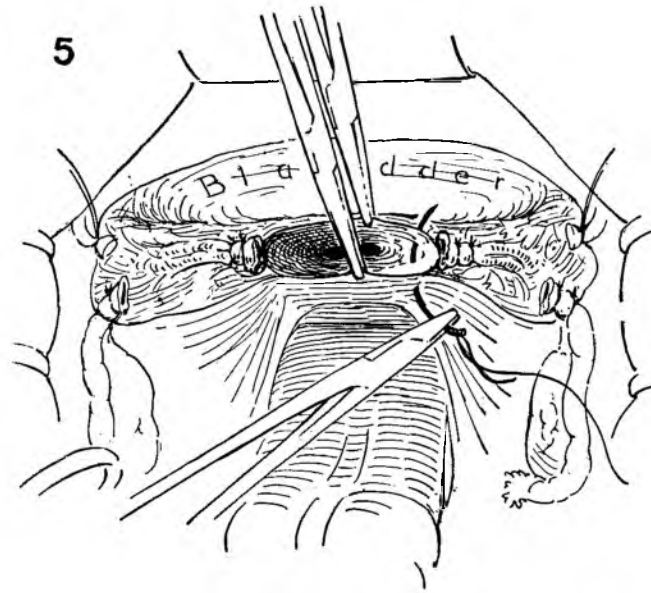


FIGURE 6. A similar stitch is placed in the opposite corner. Both sutures are tied and the ends left long to provide traction. The Kocher clamps may be discarded. The rest of the closure is accomplished by interrupted sutures across the entire body of the cervix. This automatically includes the posterior peritoneum.

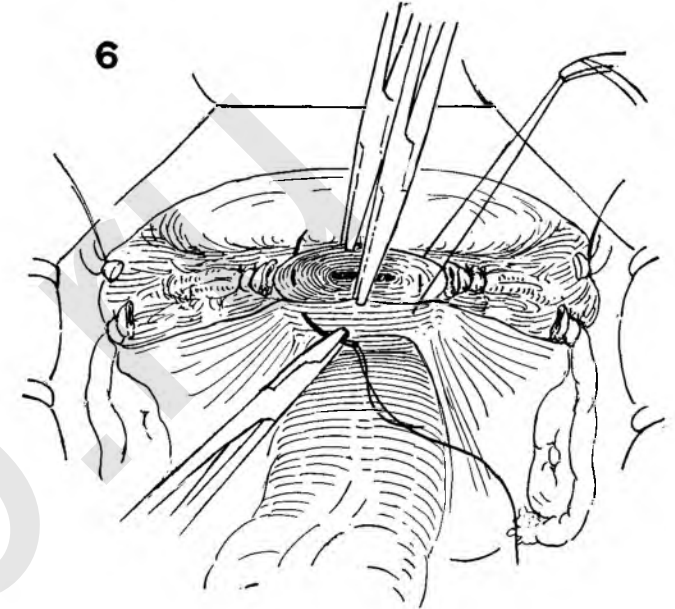


FIGURE 7. The cervix is completely closed and all bleeding controlled. As always, the surgeon must take care that the ovary lies free without tension on the ovarian vessels when the round ligament is brought down to the cervical stump. Note that the round ligament and ovarian vessels have been ligated separately.

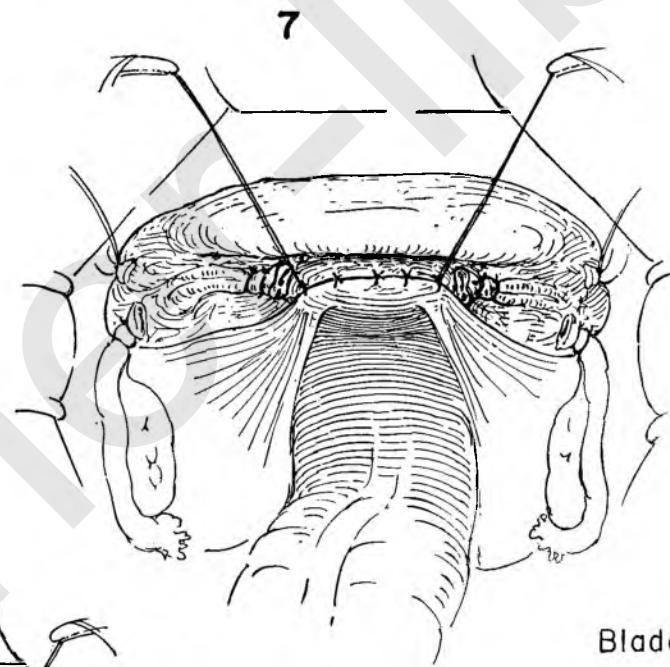


FIGURE 8. The round ligament on the right is then approximated to the closed cervical stump with a mattress suture which passes through the substance of both. The same procedure is carried out on the left side.

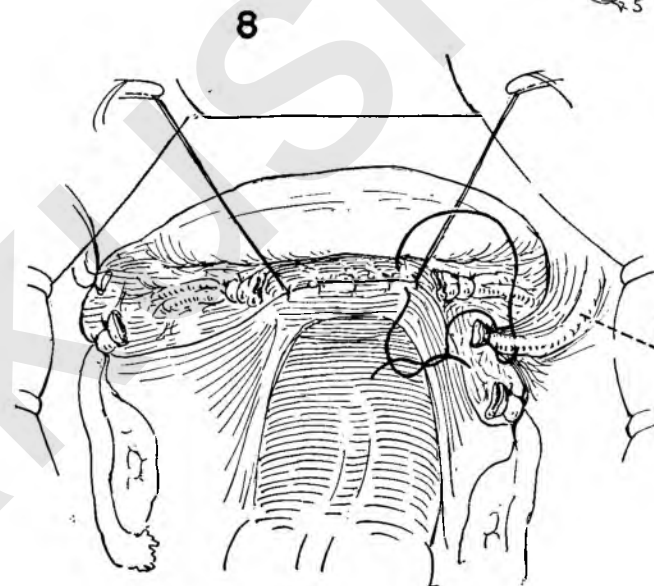
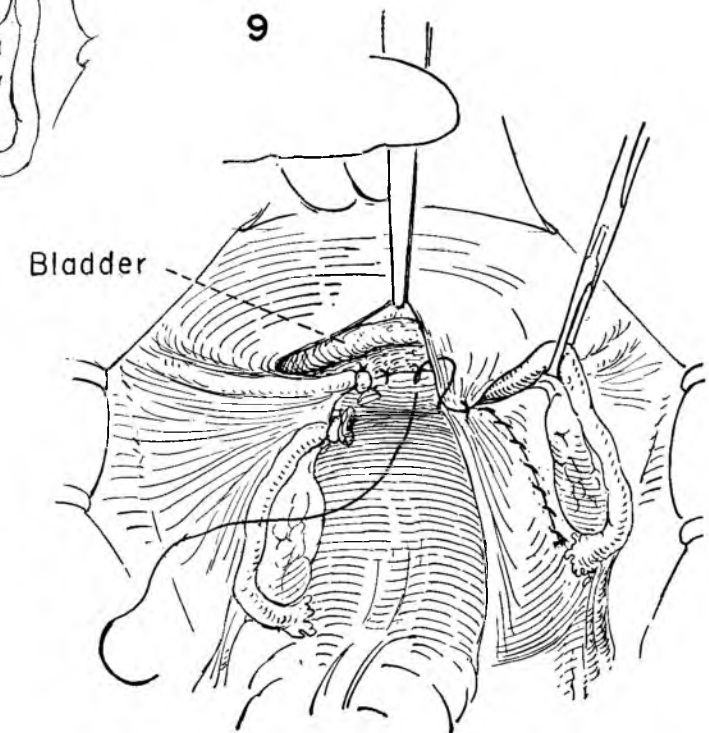


FIGURE 9. Peritonealization is begun in the raw area beneath the right adnexa. Exposure of the incised peritoneal edges is provided by the assistant, who elevates the adnexa with smooth forceps. The anterior peritoneal edge of the bladder flap is best brought into view by a retractor placed in the lower end of the wound. A running suture approximates the cut edges of pelvic peritoneum from right to left.



Round ligament

Bladder

MARSHALL-MARCHETTI OPERATION FOR STRESS INCONTINENCE OF URINE

This operation is usually performed without a concomitant hysterectomy, but it has a logical place among the modifications of total hysterectomy, for not infrequently patients who require removal of the uterus also have symptoms of stress incontinence.

FIGURE 1. After the abdominal operation is finished, the skin incision is extended down to the symphysis. Retractors are placed in the lower end of the wound beneath the rectus muscles. The peritoneum and overlying transversalis fascia are exposed. Kelly clamps are placed on the peritoneum at the lower angles of the abdominal incision. The peritoneum is then freed from the abdominal muscles. Traction on the clamps permits access to the prevesical space between the symphysis and the lower peritoneum.

FIGURE 2. The assistant keeps the peritoneum on tension while the surgeon completes the separation of muscle from peritoneum with the handle of the knife. To gain further exposure, a retractor is placed at the lower angle of the wound.

FIGURES 3 AND 4. The fingers of the surgeon's right hand are gently placed on the flat surface of the exposed peritoneum. By gentle depression of the palm of the hand and flexion of the fingers the entire prevesical space is bloodlessly opened. Dissection is then continued to expose the bladder neck and urethra.

INSET A. Diagrammatic representation showing an inlying Foley catheter in the bladder and assistant's finger in the vaginal canal. By gentle traction on the Foley catheter and upward pressure of the assistant's finger on the bladder base, the neck of the bladder and urethra are exposed further.

FIGURE 5. With the assistant pushing up on the vagina from below, the surgeon is able to identify the urethra in relation to the bladder neck. By pulling up on the bladder with the fingers of the left hand, the surgeon prepares to place the first suture beside the urethra as far down toward the meatus as possible. The urethral wall must not be included.

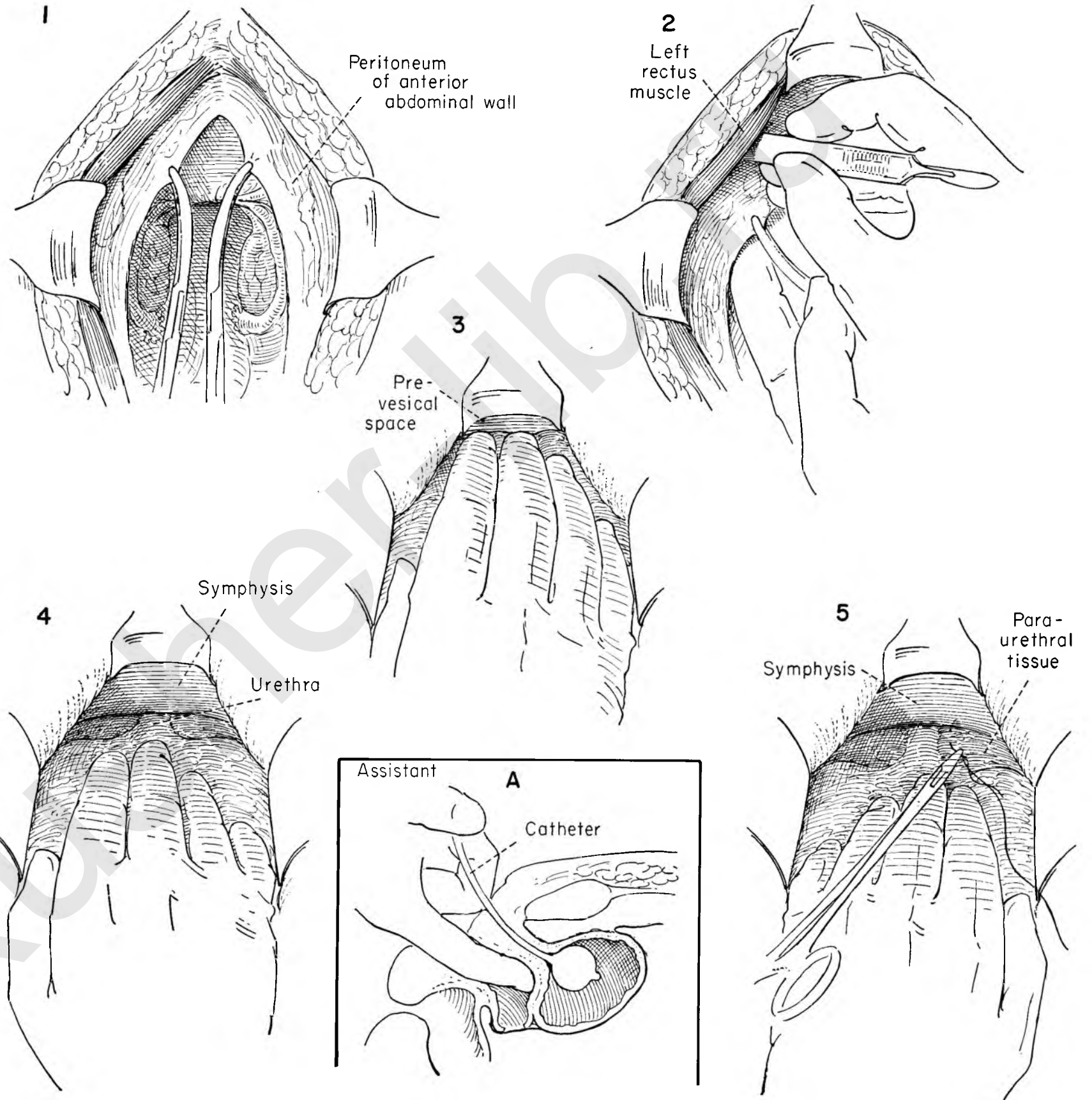


FIGURE 6. This mattress suture approximates the paraurethral tissue to the periosteal layer of the under surface of the symphysis. The first suture on the right has been placed and held. The first suture is being placed on the left side lateral to the urethra. Exposure is obtained by retractors on the muscle edge and over the symphysis.

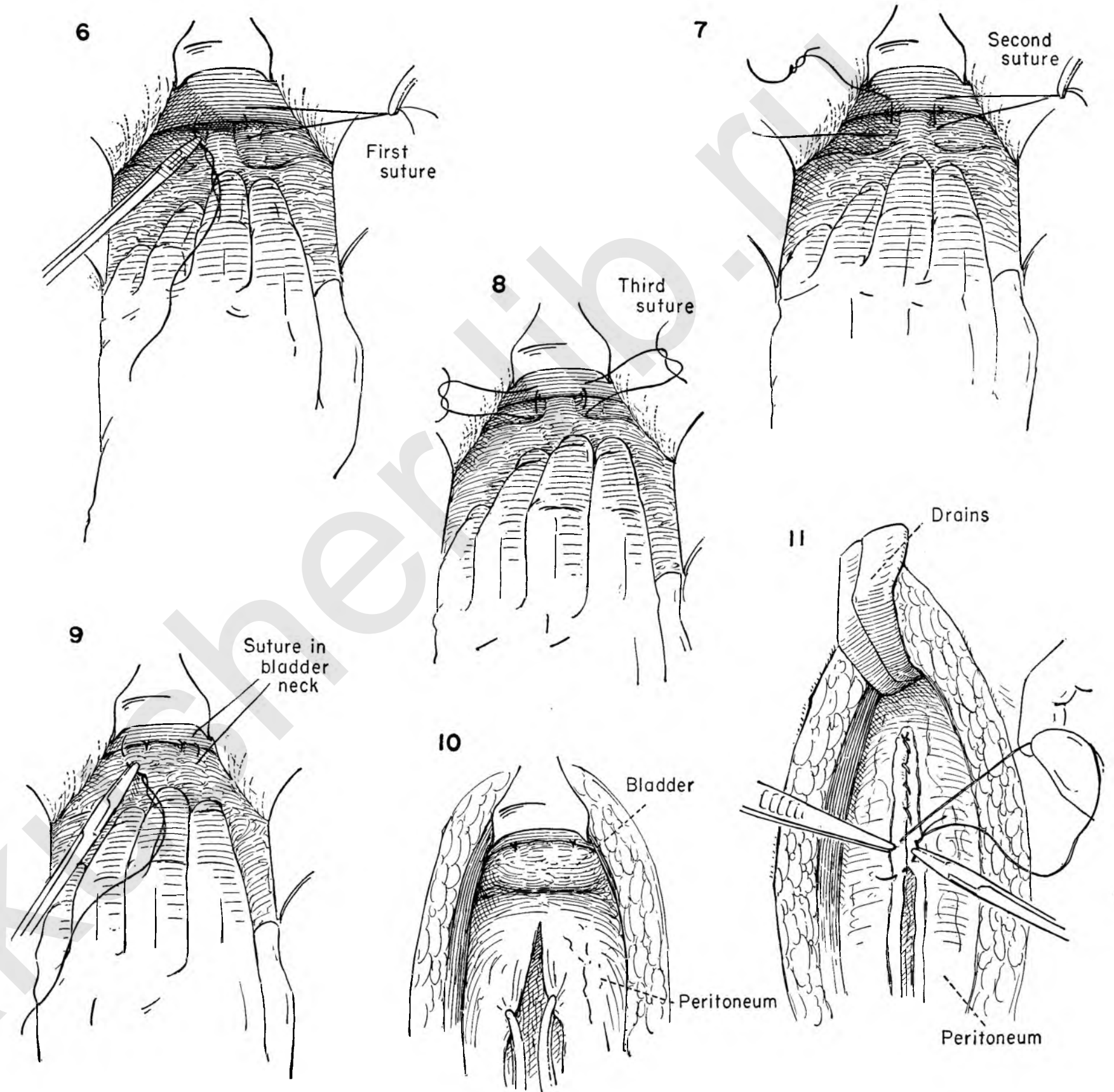
FIGURE 7. The first stitches have been tied, and a second suture is placed in similar fashion through the paraurethral tissue and periosteal covering of the symphysis. The surgeon continues to apply upward traction on the bladder to expose the bladder neck. The area is under direct vision. The Foley balloon within the bladder helps in orientation.

FIGURE 8. Three or four sutures are placed serially along the sides of the urethra and neck of the bladder and tied.

FIGURE 9. Elevation of the bladder floor by upward pressure on the anterior vaginal wall is no longer necessary. The urethra is now out of sight, and a final suture is being placed on either side of the bladder neck.

FIGURE 10. This shows the completion of the bladder suspension. Kelly clamps are placed on the peritoneal edge in preparation for closure of the abdominal incision.

FIGURE 11. The peritoneum is closed, and empty rubber drains are left in the prevesical space.



HYSTERECTOMY IN THE PRESENCE OF A LARGE FIBROID IN THE CERVICAL REGION

A fibroid arising from the cervical portion of the uterus, invading the lower broad ligament and lying below the peritoneal floor may complicate the routine steps of total hysterectomy. There is great danger of damage to the ureter or bladder as well as from hemorrhage.

FIGURE 1. Trauma to the ureter may be minimized by exposing it. The nurse pulls the uterus to the left while the assistant retracts the adnexa. The ureter can be seen beneath the peritoneum at the point where it crosses the common iliac artery. The surgeon and assistant grasp the peritoneum lateral to the ureter. The peritoneum is then incised.

FIGURE 2. Stay sutures of silk are placed on the medial peritoneal leaf and held long. This keeps the operative field open. The ureter can now be followed in its course overlying the fibroid.

FIGURE 3. The bladder flap has been developed, the tube and ovary ligated and sectioned, and the round ligament detached as in the routine steps of total hysterectomy. The ureter is gently retracted by grasping the supporting tissue rather than the ureter itself. The surgeon then dissects the ureter from the surface of the fibroid to the level of the crossing uterine vessels.

FIGURE 4. The routine steps of total hysterectomy are carried out on the left side. The uterus is held on traction, and the posterior peritoneum is divided transversely in such a manner that the right and left sides are connected. Exposure is increased by widening the operative field. The rectum is removed from danger.

FIGURE 5. The uterine vessels as they cross the surface of the fibroid and ureter are then doubly clamped under direct vision, divided and ligated.

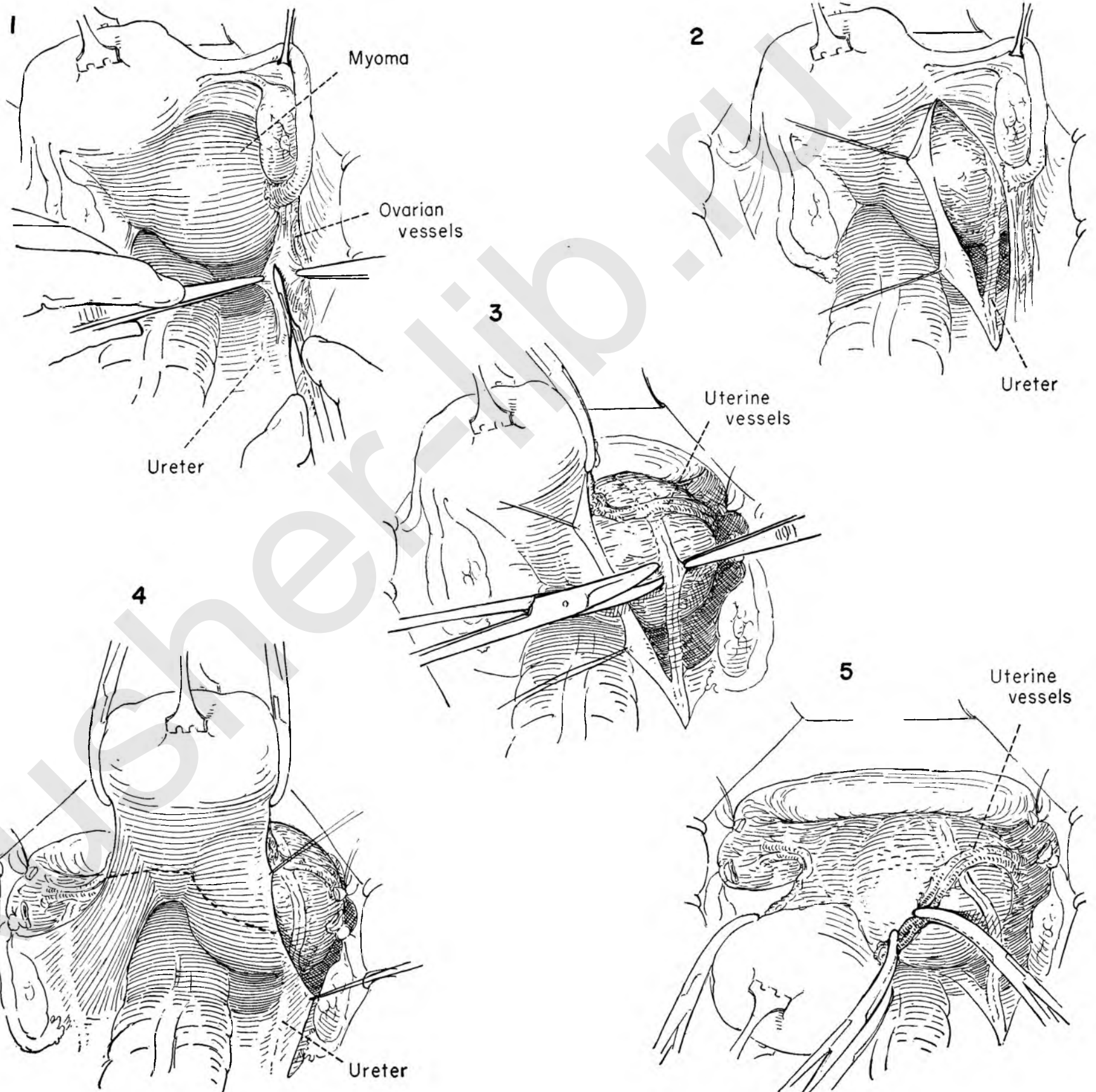


FIGURE 6. The uterus is on tension and drawn to the left. The bladder has been dissected from the cervix on the left side. The adnexa and round ligament have been ligated and sectioned on both sides. The uterine vessels, doubly ligated, can be seen in relation to the ureter lying on the surface of the fibroid. The surgeon incises the capsule overlying the superior surface of the fibroid.

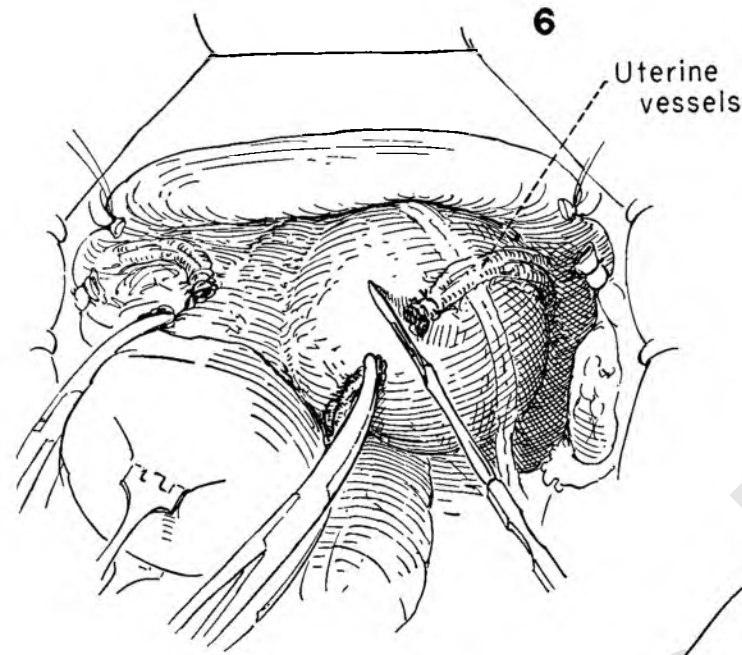


FIGURE 7. The assistant picks up the edge of the capsule with forceps, and the surgeon develops the cleavage plane between capsule and fibroid with the knife handle. The ureter and vessels lie laterally on the surface of the capsule. Any bleeding vessels are apt to be within the wall of the capsule. Obvious bleeding vessels should be clamped and ligated.

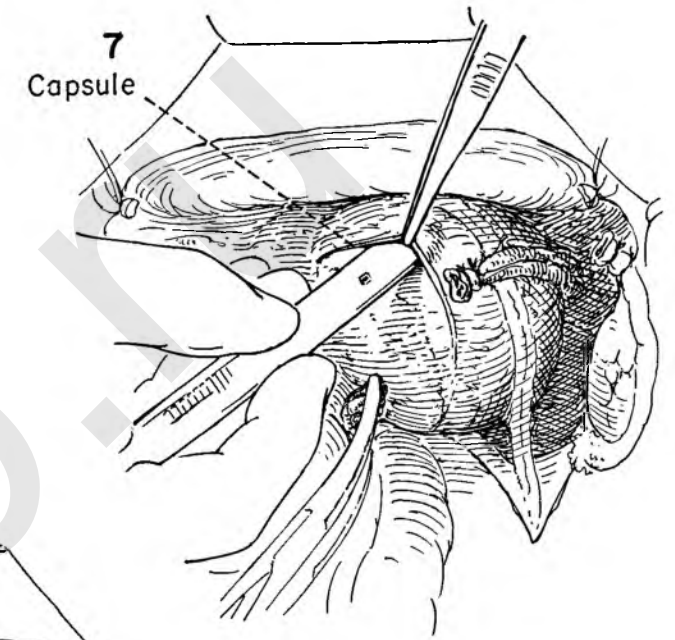


FIGURE 8. With the uterus on tension to the left, the surgeon then inserts his fingers and completes the separation of the fibroid from the capsule. The fibroid is gently elevated out of its bed. Once the proper cleavage plane is obtained, this can be accomplished bloodlessly and with ease.

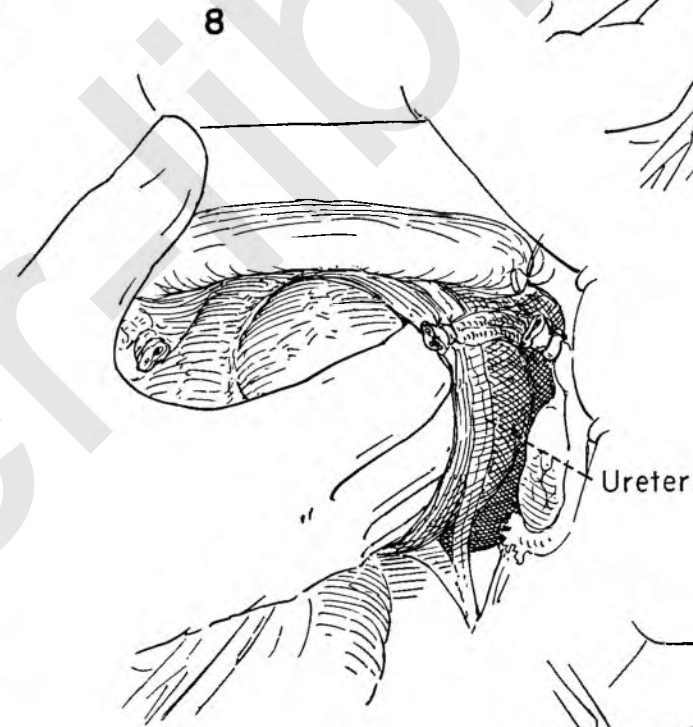


FIGURE 9. Elevation of the fibroid together with traction on the uterus permits the surgeon to visualize the posterior lateral corners of the vagina, which are clamped with Kelly clamps.

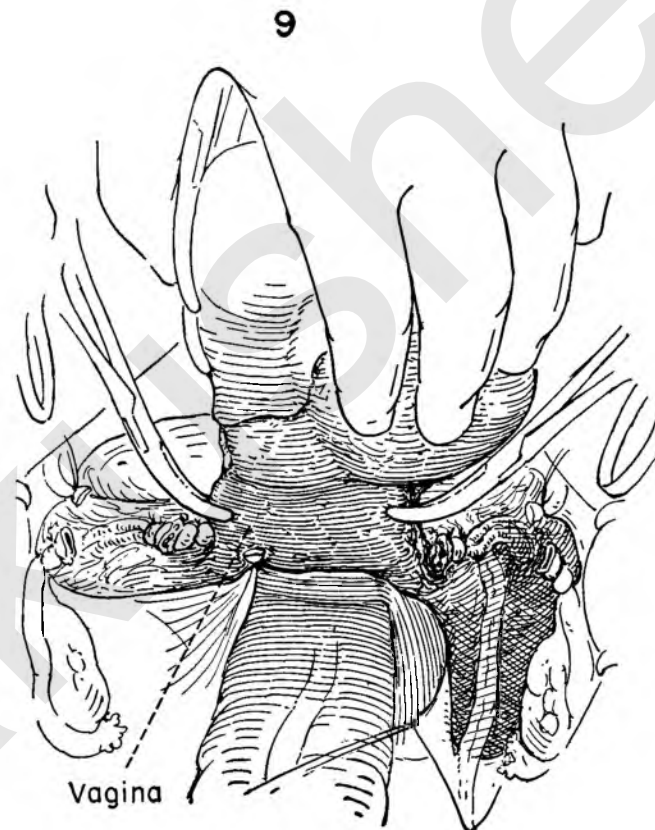
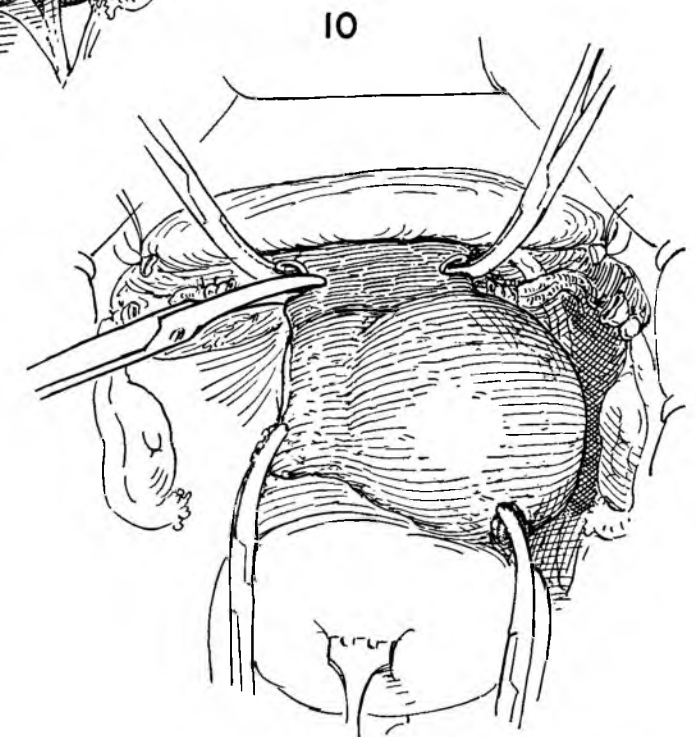


FIGURE 10. Maintaining traction on both uterus and fibroid for purposes of exposure, the surgeon now transects the vaginal wall between the Kelly clamps. The bladder edge is under direct vision. The reconstructive steps of the total hysterectomy then proceed in the usual manner.



MOBILIZATION OF THE ADNEXA AND UTERUS

Before any attempt is made to remove either the uterus or adnexa, the surgeon must prepare an unencumbered operative field. Not infrequently in the presence of pelvic inflammation, endometriosis or previous pelvic surgery, the small or large bowel has become adherent to the uterus or adnexa.

FIGURE 1. The surgeon grasps the tenaculum on the fundus as he holds the small bowel in the fingers of the right hand. A gentle rolling of the bowel between the thumb and forefinger will either establish a plane of cleavage or will expose adhesions that may safely be divided by scissor dissection. If there is any question about the point of division, "stay on the uterine side." Leave a segment of uterus or ovary on the bowel, not bowel on the uterus.

FIGURE 2. The tube and ovary are often found densely adherent to the posterior surface of the broad ligament. With traction maintained on the fundus of the uterus, the palmar surface of the fingers of the right hand is placed against the posterior surface of the broad ligament below the ovary. By elevating the fingers in a "peeling motion," a cleavage plane is established and the tube and ovary dislodged from the adherent bed. Extensive pyosalpinx may be displaced intact. Chocolate cysts will invariably rupture. In either case, a suction tip should be held in readiness to aspirate inadvertent spillage.

FIGURE 3. The cecum becomes attached to the right adnexa after previous pelvic inflammation or surgery. The uterus, the bowel and the tube and ovary are held on tension while the adhesive bands are divided.

FIGURE 4. The rectum is often fixed to the posterior vagina or cervix for one of various reasons. This area is thrown into sharp relief by upward traction on the fundus. The surgeon exerts counterpressure on the sigmoid by the flattened fingers of the left hand. The cleavage plane is exposed and the sigmoid stripped from the back wall of the uterus.

INSETS A AND B. These drawings indicate in a sagittal plane the situation before and after this dissection.

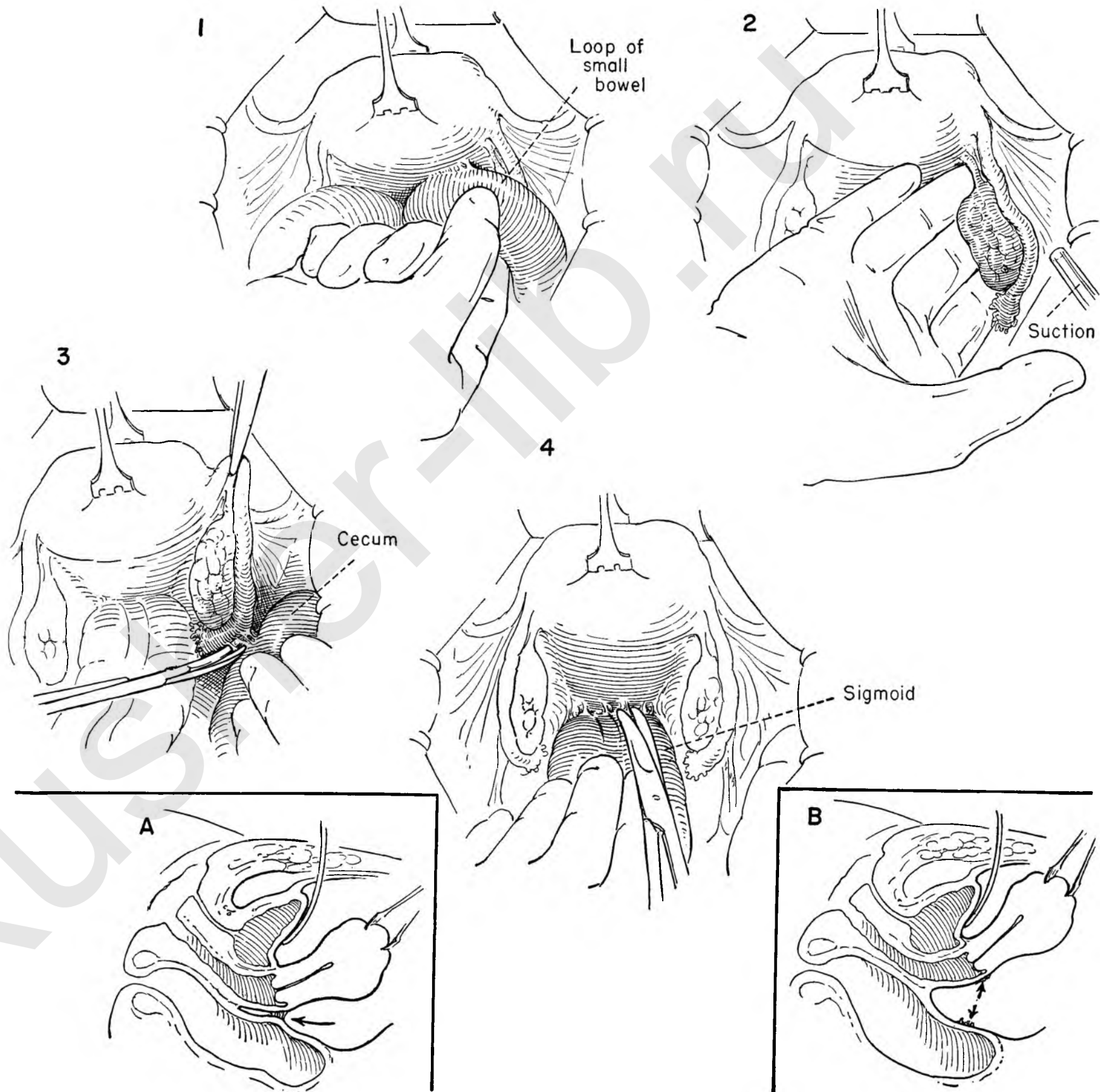
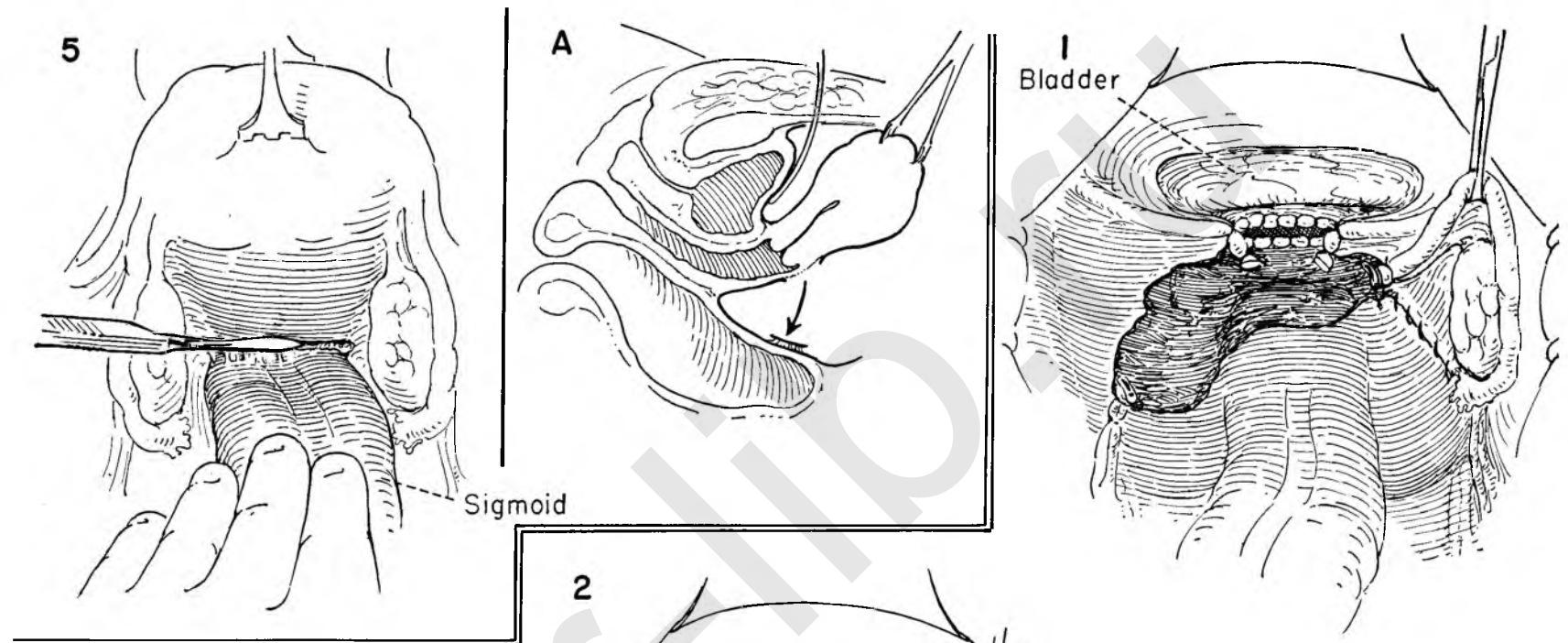


FIGURE 5. The rectum, in endometriosis of the rectovaginal septum, may be adherent to the posterior wall of the uterus between the attachments of the uterosacral ligaments. Separation does not occur in the usual fashion because of the invasive tendency of the disease. Separation is possible by two methods. The surgeon may apply traction to the tenaculum on the fundus. Sudden flexion in the direction of the symphysis cracks the peritoneal surface on the posterior wall of the uterus above the point of bowel attachment. If such separation does not occur, the surgeon lightly divides this peritoneal cover transversely above the area of bowel fixation. A plane of cleavage is created which will permit dissection of the rectum from the uterus without the danger of entering bowel.

INSET A. Diagram showing in sagittal section the result when peritoneum of the posterior cervix or vagina has been left on the bowel in order to achieve satisfactory mobilization.



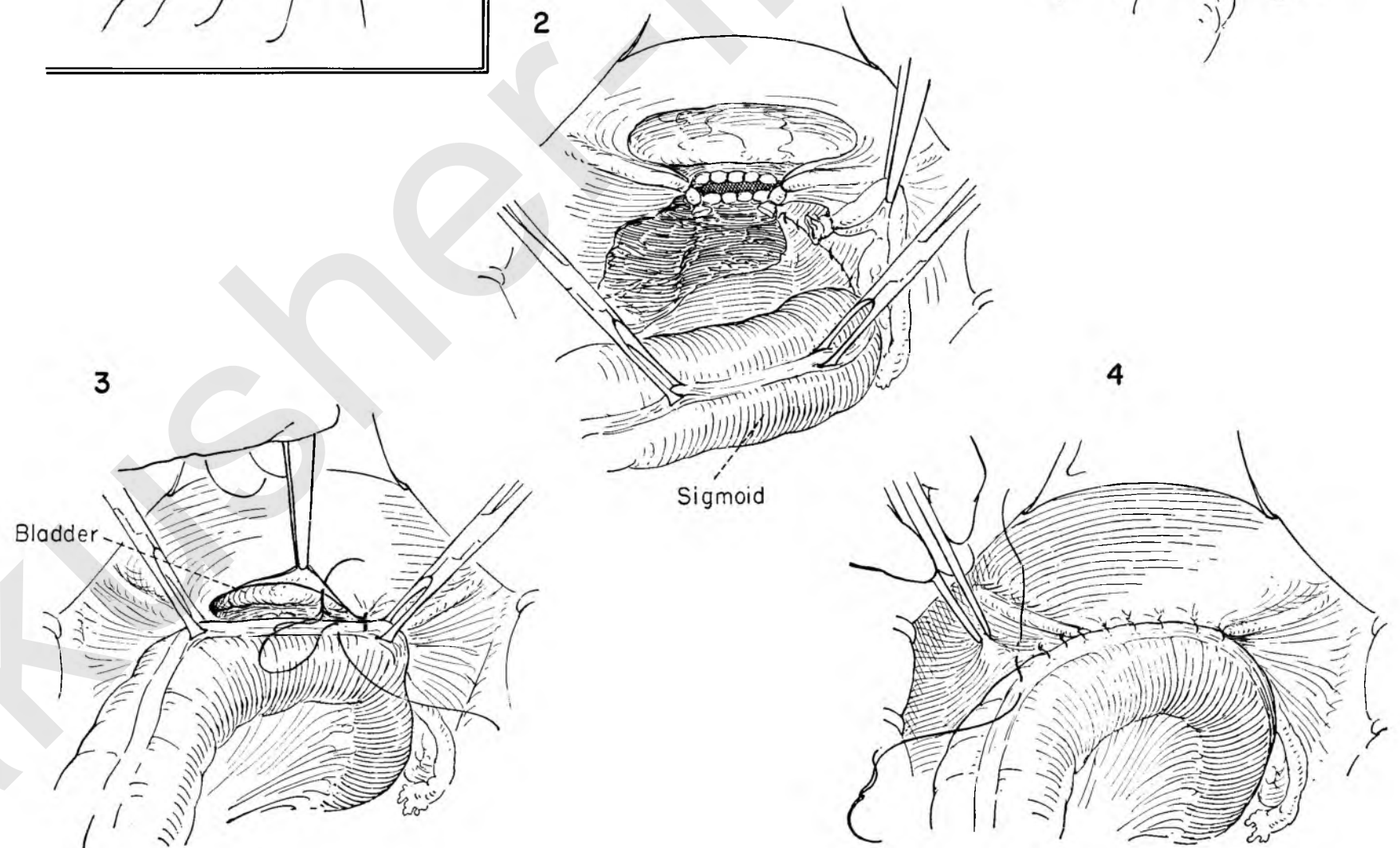
PERITONEALIZATION OF SIZABLE DEFECTS IN THE CUL-DE-SAC

FIGURE 1. When the total hysterectomy has been performed for extensive endometriosis, the peritoneum of the lower pelvis may be widely involved and lost in the act of removing the adherent adnexa. Moreover, large defects may be deliberately created in order to excise endometriosis implanted on parietal peritoneum or uterosacral ligament. The defect is too extensive to permit closure by mobilization of the peritoneum, but can readily be covered by swinging over the adjacent sigmoid colon.

FIGURE 2. The bowel is grasped with Allis forceps at two points and brought over to the vagina in a fashion that permits it to lie comfortably, without distortion or tension.

FIGURE 3. The sigmoid is then rotated to cover the defect. A series of interrupted atraumatic sutures approximates the cut edge of the peritoneum overlying the bladder flap to the longitudinal band of the sigmoid. The assistant aids by keeping the bowel in position with the Allis clamps. Interrupted sutures are used to avoid any puckering effect from a running suture.

FIGURE 4. This line of sutures is continued far enough laterally to obliterate openings or pockets into which small bowel might later descend.



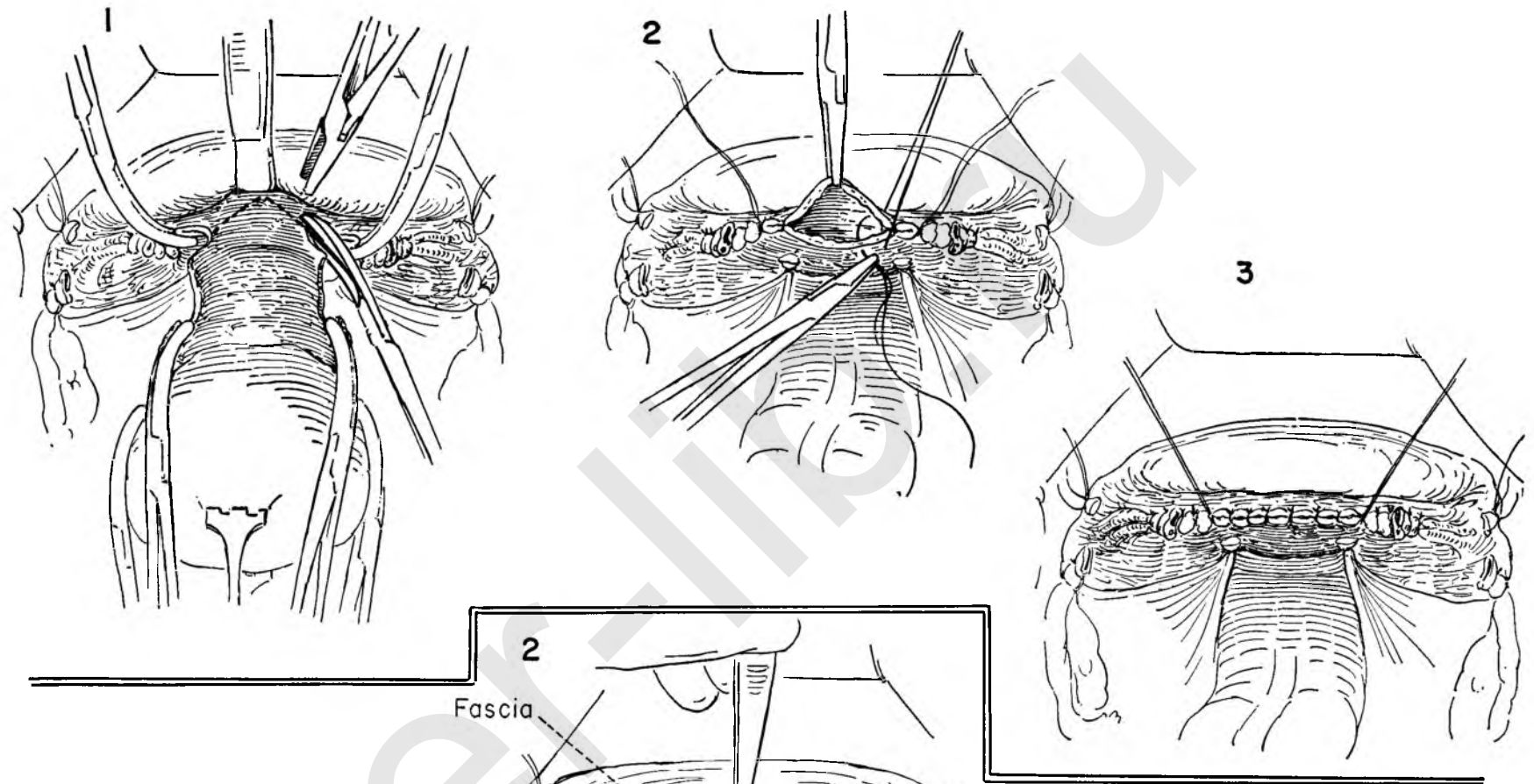
RESECTION OF ANTERIOR VAGINAL WALL: CLOSURE OF VAGINAL APEX

A small amount of prolapse of the anterior vaginal wall, insufficient to require a vaginal plastic procedure from below, is not uncommon. This may be corrected by a minor modification from the abdominal side. A wedge of anterior vaginal wall can be excised with the cervix, and suture of the vaginal cuff in a transverse direction will then shorten the anterior wall and correct the prolapse.

FIGURE 1. The prime requisite for successful performance is adequate retraction of the bladder floor from the vaginal wall. The surgeon applies upward traction on the uterus while the assistant retracts the bladder floor. The vagina is entered laterally on both sides. Kelly clamps grasp the vaginal wall at the angles. The surgeon then removes a V-shaped segment of the anterior vaginal wall. The assistant prepares to grasp the leading cut edge of the vagina with a clamp.

FIGURE 2. The clamps at the angles are individually ligated with stitch ligatures. These are left long for traction. The surgeon then closes the open vagina with interrupted sutures which include the full thickness of both walls.

FIGURE 3. The vagina is now completely closed with interrupted sutures. Reconstruction and peritonealization then follow the procedure outlined in the technique of total hysterectomy.



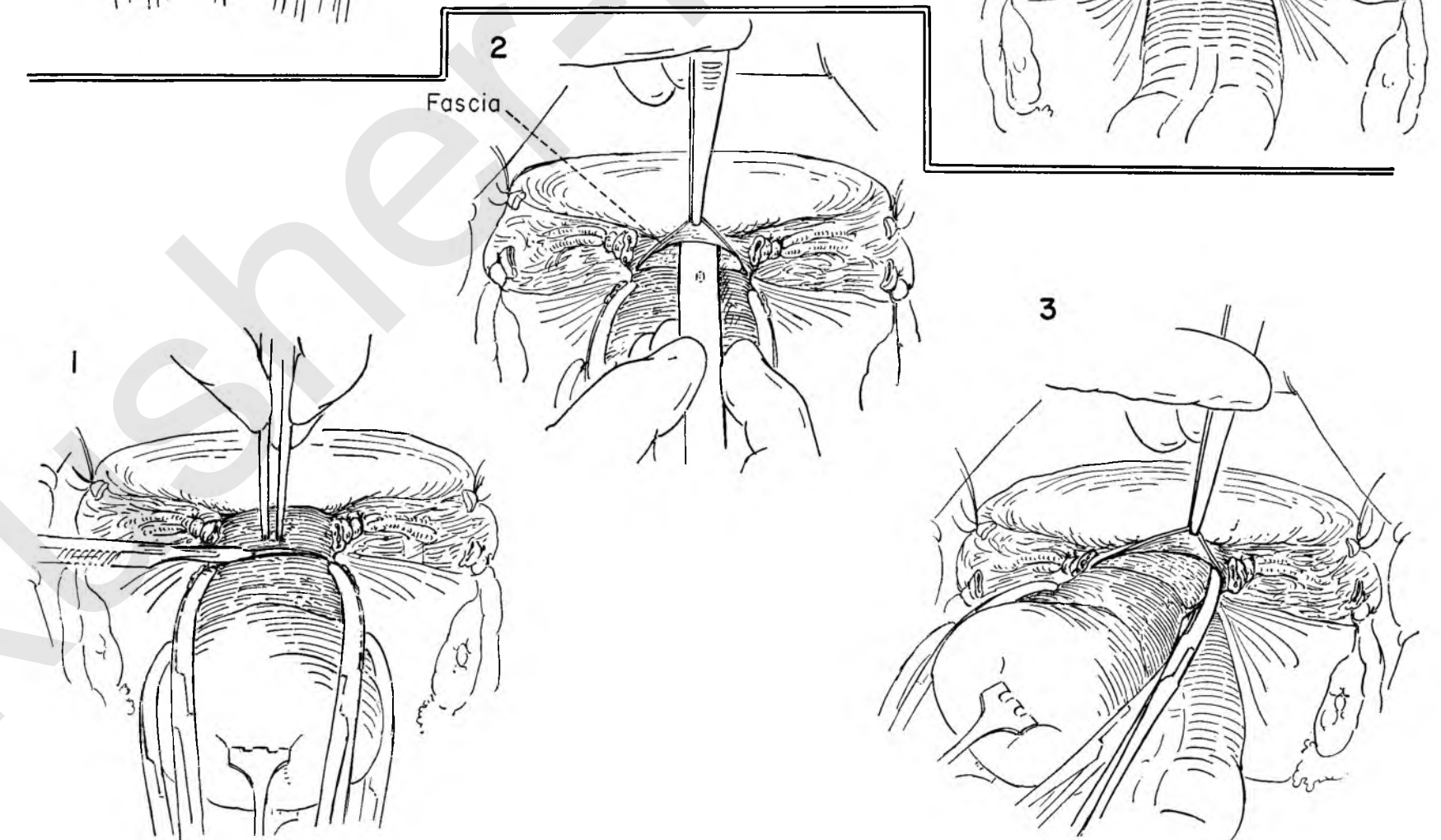
SPLITTING THE ANTERIOR CERVICAL FASCIA

In certain pathological conditions the bladder floor may not strip readily from the anterior vaginal wall. If there is any danger of damaging the bladder, division of the anterior cervical fascia may be a useful step.

FIGURE 1. After doubly ligating the uterine vessels and applying traction to the uterus, the surgeon incises the fascia over the anterior wall of the cervix above the ligated vessels.

FIGURE 2. The fascia can then be gently stripped from the cervix with a minimum of bleeding. The assistant elevates the cut fascial edge as the surgeon dissects the cervix from the fascia with scissors or handle of the knife.

FIGURE 3. After elevation of the fascia, the Kelly clamp on the cervical branches of the uterine artery may be placed beneath the fascial edge without risk of damage to the bladder, which lies superior to the fascial flap.



Conservative Operations

There can be little doubt that the present trend in gynecology in the field of benign disease and anatomical derangement is away from the policy of performing hysterectomy as a routine procedure. Certainly too many hysterectomies have been performed for inadequate cause in women past childbearing.

The older gynecologist performed many operations for the repair of the lacerated cervix, perineum and bladder wall in combination with suspension procedures for the sagging uterus. Great premium was placed on the preservation of uterine function. For cause not entirely clear this plan of attack gave way to reconstruction of the vaginal canal associated with removal of the uterus either entirely or in part.

Unquestionably both plans of attack became less of a thoughtful process than a pattern of procedure based on habit.

It is not our intention to engage in this controversy. Many surgeons feel that the patient's health will be improved by the removal of a uterus overtraumatized by repeated pregnancy or benign pathology. Others feel that the retention of the uterus has a salutary effect on the proper functioning of the ovary, indirectly affecting general health for the better.

It is our purpose to indicate that each has its proper application. There remains a definite place for conservative operations in the field of gynecology short of removal of the uterus.

In line with the trend toward conservatism the thoughtful approach to the problem of endometriosis is an excellent example. While the older school of the gynecologists was perhaps hyperconservative in its attitude toward preservation of the uterus, it was at the same time over-radical in the treatment of this disease entity at whatever age encountered.

In recognition of the fact that persistence of the disease depended on ovarian function, accepted therapy called for total ablation of ovarian activity, either through removal of both ovaries or by radiation therapy. In many instances the mere establishment of the diagnosis, though the manifestations were minimal, was enough to sanction a radical removal of the uterus and ovaries, even in younger women of childbearing age.

Greater familiarity with the disease process gradually modified the direction of therapy toward a more logical conservative approach, particularly in the younger group.

The misconception contributing to the radical concept for therapy of endometriosis springs from the invasive tendency of the disease. Marked scarring follows the insult to the peritoneum from spillage of the contents of the chocolate cysts. As a result of this connective tissue response, adjacent structures like the rectum, sigmoid, round and broad ligaments as well as small bowel become involved in a relatively fixed pelvic mass.

There are several practical points to consider in the effective conservative management of endometriosis.

In the first place, the central endometrial implant is usually relatively small in relation to the extent of the scar tissue response. Secondly, it is probable that many of the scarred areas may represent inactive endometriosis. Finally, endometriosis within the ovary itself has less tendency to invade.

EXCISION OF ENDOMETRIAL IMPLANTS

Because the primary lesion is small and the peritoneal reaction out of proportion to it, multiple implants on the peritoneal floor or uterosacral ligament may be excised with impunity, provided the surgeon exercises reasonable care.

EXCISION OF EXTENSIVE ENDOMETRIOSIS

When it is desirable to preserve the childbearing function, it is often possible to resect widespread endometriosis. The rectosigmoid, for example, may be separated from the back of the uterus between the uterosacral ligaments in the manner previously described (Plate 26). The multiple implants on the pelvic peritoneum and uterosacral ligaments may then be excised en masse by careful dissection of the peritoneum from the underlying structures.

Though the ovary may appear to be hopelessly compromised by endometrial cysts, a plane of cleavage may be invariably established between the cyst and normal ovarian tissue, for the process appears to be less invasive within the ovary. Small but adequate amounts of ovarian tissue may be preserved and a reduced but effectively functioning ovary salvaged. Many subsequent pregnancies have followed this type of procedure.

REPERITONEALIZATION BY OMENTAL GRAFT

In many instances the excision of the peritoneal cover on the posterior wall of the uterus will be so extensive that effective reperitonealization is not possible. If the sigmoid does not lend itself readily as a means of covering the defect, a free omental graft often provides effective protection.

SUSPENSION OPERATIONS ON THE UTERUS

Less commonly used for malpositions of the uterus than was formerly the case, the suspension operation has a definite place in the treatment of gynecological conditions. Inasmuch as most of the indications appear in the reproductive age group, it is important to select the type of suspension that will best stand up under subsequent pregnancy and offer the least interference with successful delivery.

The Olshausen suspension has fulfilled these qualifications over a long period of time. The suture beneath the round ligament should be placed close enough to the uterus to avoid a

narrow lateral gutter through which small bowel may herniate and become fixed, thereby increasing the danger of obstruction.

A *Baldy-Webster suspension* is most effective in combination with other procedures such as excision of endometriosis from the posterior wall of the uterus or broad ligament or posterior wall myomectomy. This suspension provides effective peritonealization and prevents adhesion of either large or small bowel. It is less satisfactory than the Olshausen if pregnancy follows.

Shortening of the uterosacral ligaments may be used in conjunction with other suspension procedures. It is accomplished either by bringing the two uterosacral ligaments together in the midline or by individually foreshortening each ligament with a purse-string suture. A word of caution should be introduced. The ureter lies in close relation to the uterosacral ligament. Care must be taken in placing any sutures in this area.

MYOMECTOMY

When there is a desire to maintain the childbearing function in the face of a uterus which contains either one large or many small fibroids, the operation of myomectomy serves a useful purpose. Inasmuch as the fibroid preserves its own capsule and displaces rather than invades the uterine musculature, it may readily be enucleated without undue trauma, provided the surgeon establishes a proper cleavage plane. The encroachment of the fibroid on the endometrial cavity itself need not be a detriment to enucleation. It is amazing how normal the uterus may appear after large or multiple leiomyomata have been excised. The history of pregnancy after this procedure bears evidence to the soundness of the concept of enucleation.

PRESACRAL NEURECTOMY

For pain localized to the uterus at the time of the period or in conjunction with conservative operations for endometriosis, presacral neurectomy may be performed.

It is the authors' belief that the mere removal of a segment of nerve at the bifurcation of the iliac vessels constitutes an inadequate resection of the many communicating branches that go to make up this nerve plexus. The conception of the presacral nerve as a single trunk we regard as erroneous. To anticipate a satisfactory result, all ramifications of the nerve must be resected, beginning above the bifurcation of the aorta and extending down along the iliac vessels over the promontory of the sacrum. The field must be kept scrupulously dry. The danger lies in possible damage to the midsacral veins which empty into the left common iliac vein.

When the operation is performed to relieve essential dysmenorrhea, the chances of success improve with the proper selection of the cases as well as by adequate surgery.

EXCISION OF ENDOMETRIAL IMPLANT

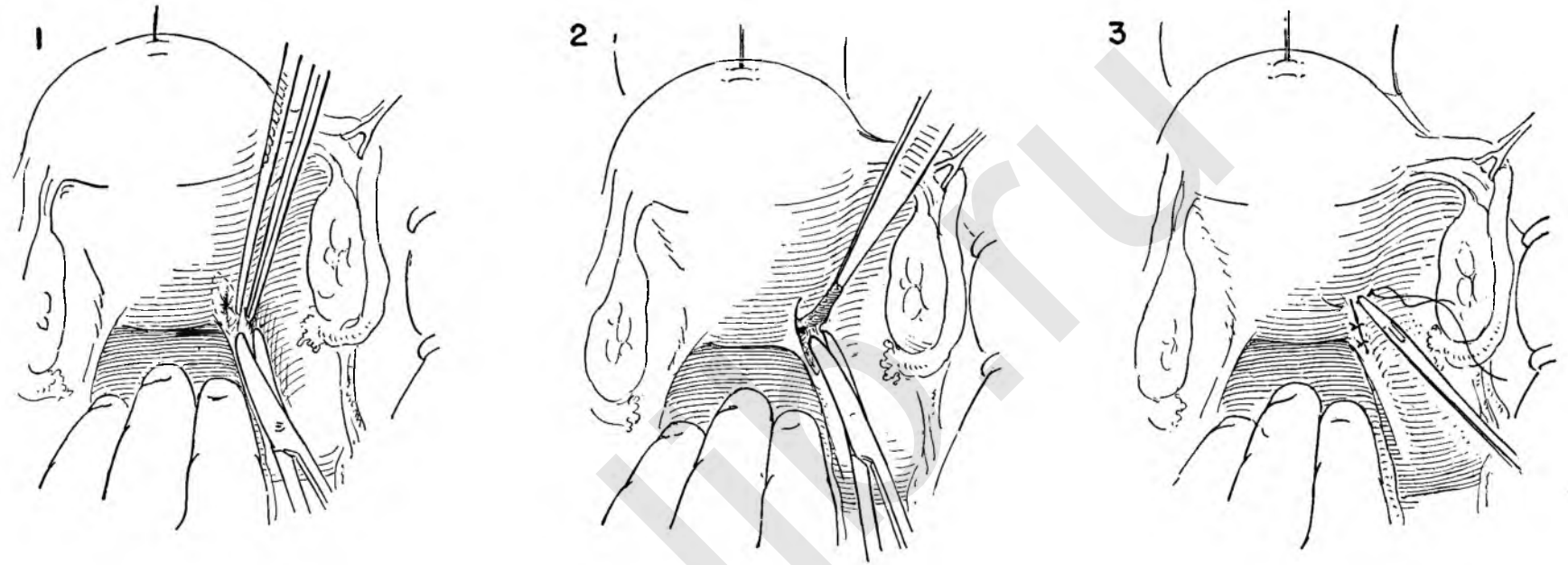
Conservative treatment of endometriosis has had increasing support in the last decade.

The stellate scar surrounding an endometrial implant may draw into it structures lying beneath, but frequently involves only the peritoneum. The individual implants thus lend themselves to excision.

FIGURE 1. Exposure is provided by traction on a figure-of-eight suture placed in the fundus while the assistant retracts the sigmoid and elevates tube and ovary with a Babcock clamp. The Allis clamp often used may cause tissue damage.

FIGURE 2. The surgeon elevates the peritoneal flap and carefully dissects beneath it.

FIGURE 3. The peritoneum is then closed with interrupted atraumatic catgut sutures.



EXTENSIVE ENDOMETRIOSIS

Despite massive invasion of the ovary, uterus and sigmoid, the surgeon may elect to be conservative in order to preserve childbearing function in the young and ovarian function in the older patient.

FIGURE 1. Before undertaking any dissection of the endometriosis, the tube and ovary must be freed from the back of the broad ligament and the sigmoid from the posterior wall of the uterus. The ovary invariably ruptures. This figure shows a chocolate cyst involving the left ovary, the sigmoid adherent to the posterior wall of the uterus, small implants in the right ovary and a stellate scar on the serosal sigmoid surface.

When the sigmoid is fixed to the back of the uterus, two methods are available to establish a proper cleavage plane: (a) If the uterus is drawn sharply toward the symphysis, the serosal surface may crack in the proper plane. (b) If not, a light stroke of the knife above the point of sigmoid attachment will create it.

FIGURE 2. The rupture in the chocolate cyst in the left ovary is evident. The sigmoid has been separated from the posterior wall of the uterus, exposing the uterosacral ligaments. The surgeon elevates the peritoneum beyond the obvious involvement by endometriosis and gently dissects it from any underlying structures.

FIGURE 3. The dissection is carried up on the back of the uterus. Firm traction on the flap with Allis forceps and upward traction on the uterus will facilitate this maneuver. The scar of endometriosis on the sigmoid is left undisturbed.

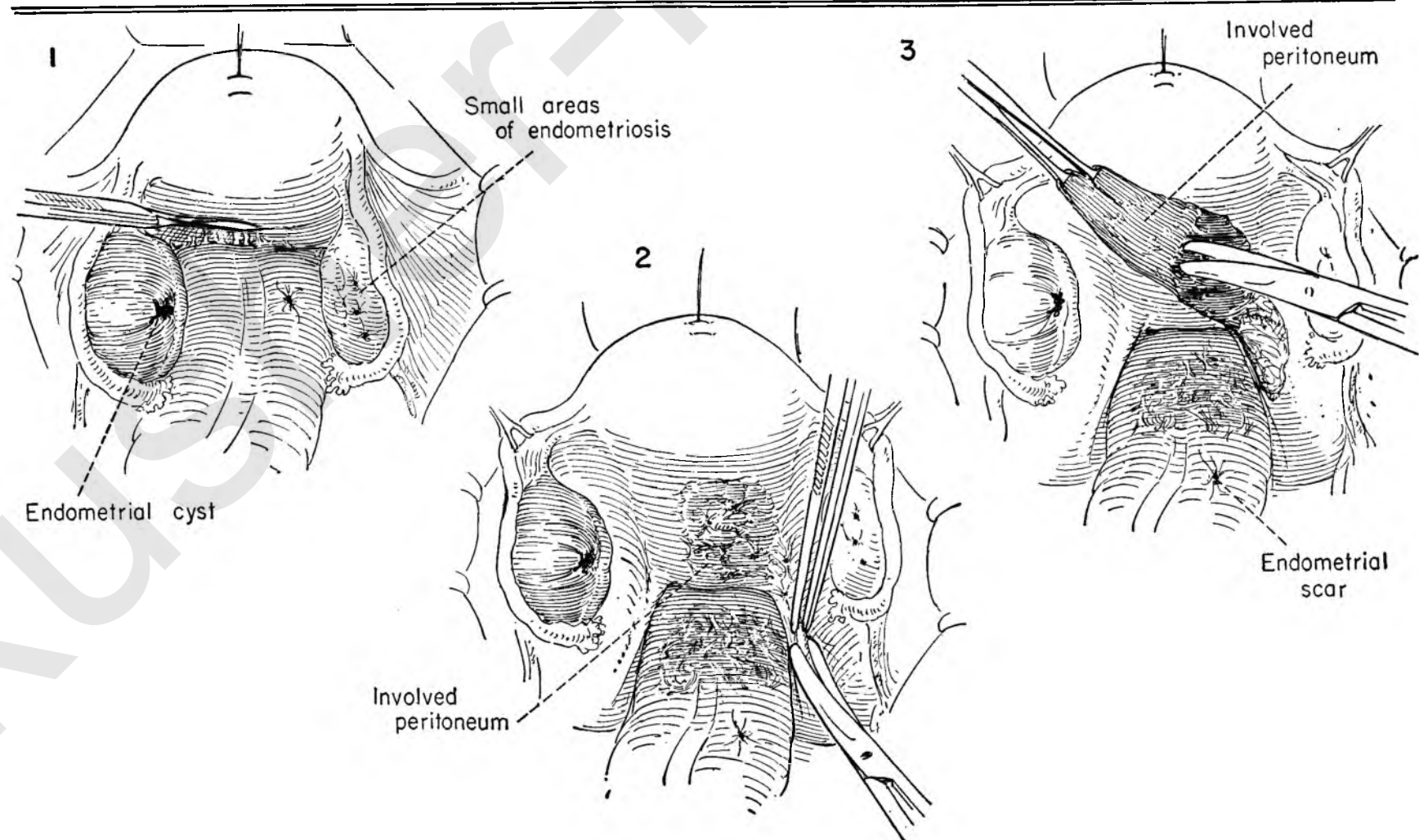


FIGURE 4. The invasive tendency of endometriosis does not apply to the ovary. A definite plane of cleavage is invariably present. The surgeon places a Babcock clamp on the medial end of the ovarian ligament to steady the ovary. The external cover of the ovary on the wall of the chocolate cyst is then incised. An Allis clamp serves to retract the cut edge of the incision and expose the line of cleavage between the cyst and the normal ovarian tissue. The cyst is then shelled out of the ovary, which is then reconstructed with a running catgut suture which begins at the pole, covers the defect and returns to the point of origin.

Such cysts can always be excised, leaving more or less ovarian tissue. It is well to remember that small amounts of ovary may preserve ovarian function and even fertility.

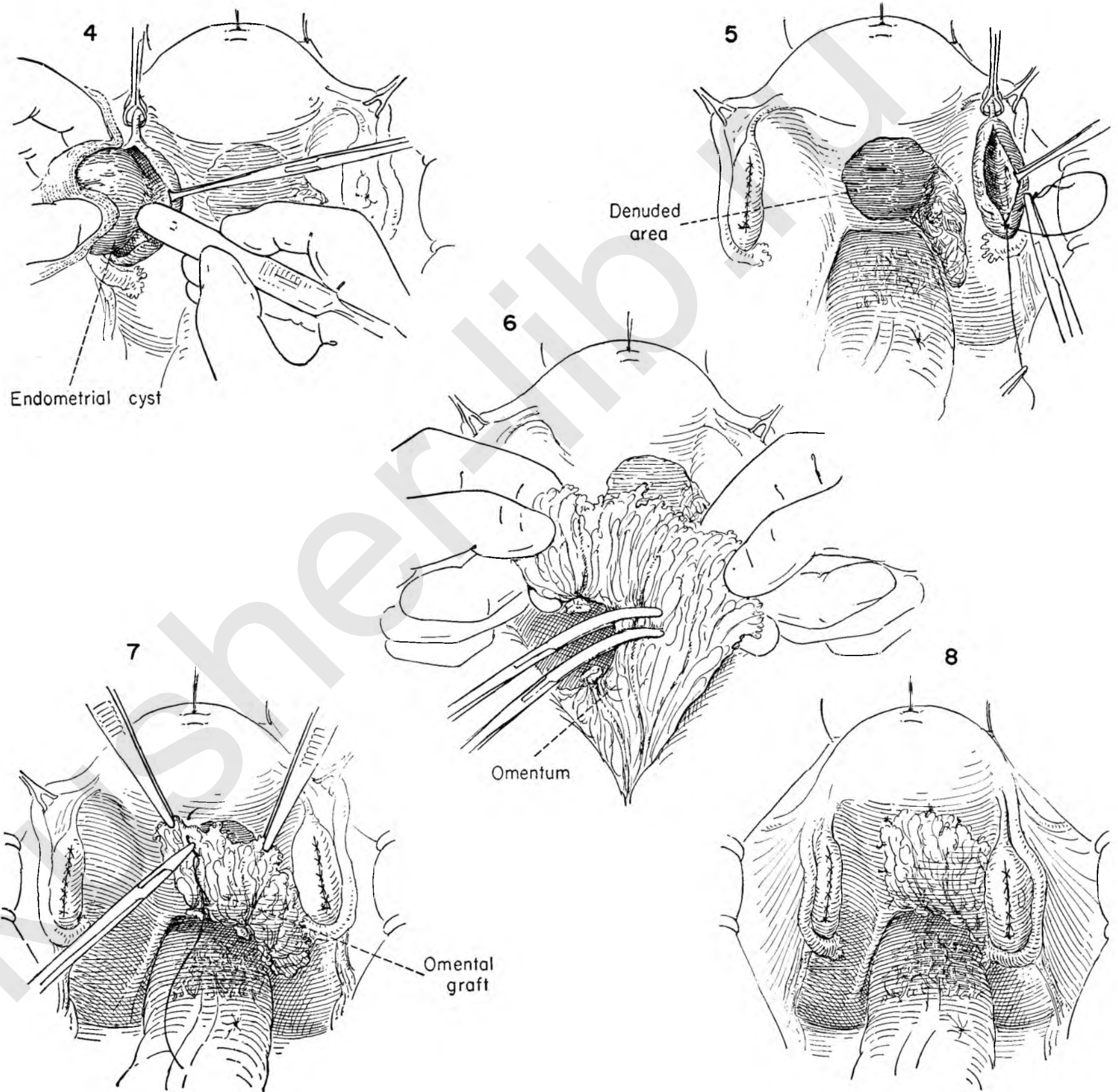
FIGURE 5. The chocolate cyst has been excised from the substance of the left ovary and the defect closed with a continuous catgut suture.

Small individual and coalescent cysts have been excised in a wedge-shaped segment from the right ovary. The ovary is then reconstructed with a running suture. The raw area on the pelvic floor and posterior uterine wall is too extensive to permit peritoneal closing either by approximation of the peritoneal edges or by uterine suspension.

FIGURE 6. To prevent the adhesion of small bowel to the raw defect in the pelvic peritoneum the surgeon may elect to apply a free omental graft. The surgeon and the assistant place the free edge of the omentum on tension. The individual vessels within the omentum are clamped with Kelly clamps, divided and ligated.

FIGURE 7. The free omental graft is then sutured to the peritoneum of the posterior uterine wall and pelvic floor by interrupted catgut sutures.

FIGURE 8. The defect is now covered by the omental graft, thus preventing adhesion of small or large bowel to the area denuded of peritoneum.



OLSHAUSEN SUSPENSION

FIGURE 1. The abdomen has been opened through a paramedian incision in the usual manner. The surgeon grasps the uterus with thumb and forefinger and draws the uterus up out of the pelvis to the position on the anterior abdominal wall where it lies without undue tension. This is important.

The assistant maintains the position of the uterus as the surgeon picks up the round ligament about ½ inch lateral to its point of insertion in the uterine wall. If placed too far out on the round ligament, an opening may be left to the lateral side through which small bowel might herniate.

The surgeon then places a cutting point stitch carrying two strands of heavy braided silk beneath the round ligament at this point.

FIGURE 2. Kelly clamps are placed on the edge of the peritoneum and anterior rectus fascia at the level selected for fixation. The assistant holds back the subcutaneous fat and skin with a retractor. The surgeon exposes the under surface of the peritoneum by elevating the two Kelly clamps in the left hand while he introduces the stitch into the peritoneum, muscle and fascia.

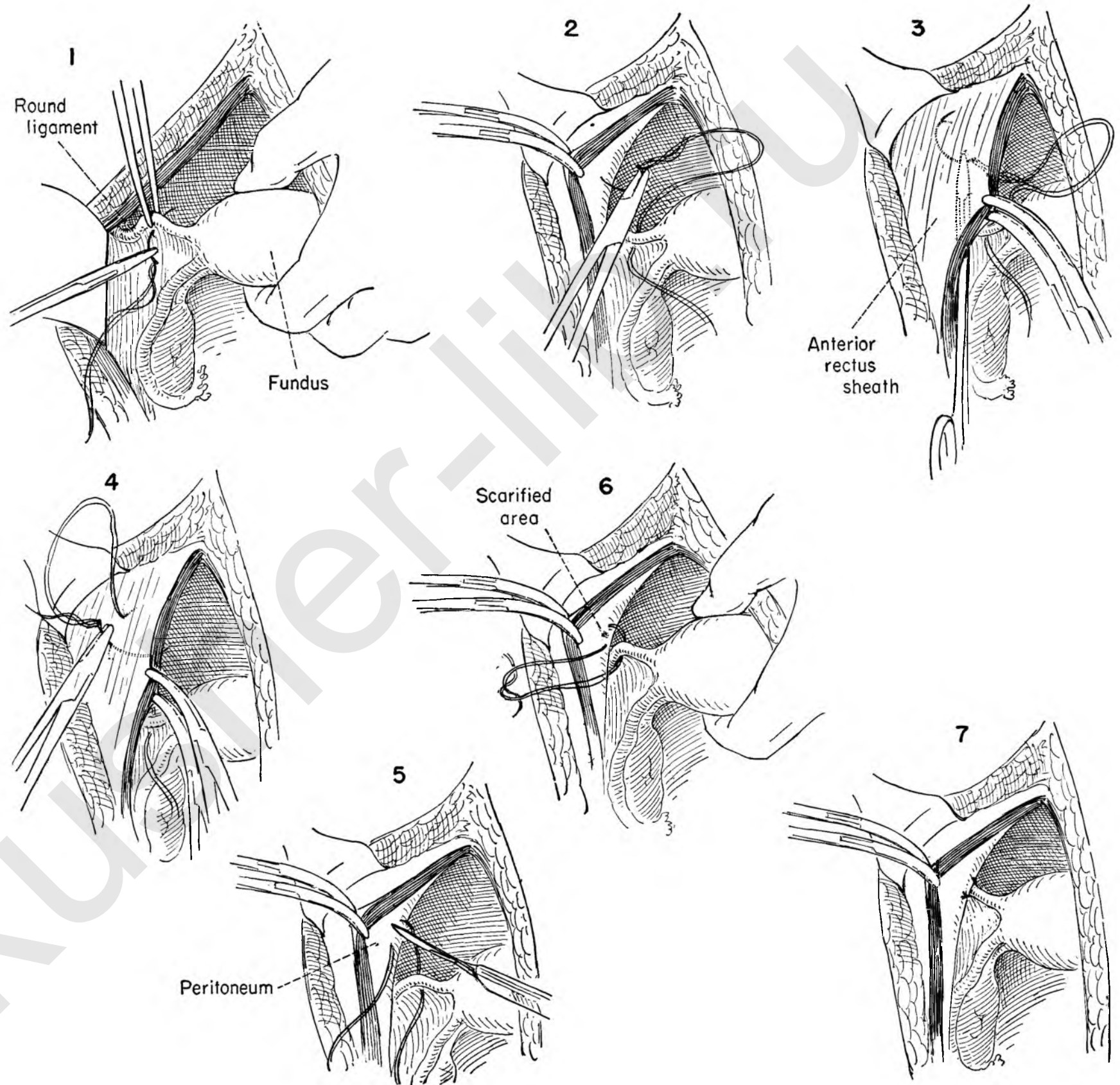
FIGURE 3. The clamps are then drawn firmly to the midline, thus exposing the point of exit of the suture on the anterior rectus sheath.

FIGURE 4. The surgeon maintains traction on the left rectus fascia and peritoneum toward the midline while he returns the suture again through the fascia muscle and peritoneum. The point of exit on the peritoneal side should be approximately ½ inch from the point of the initial introduction. This suture is thus a mattress suture passing through all the structures noted.

FIGURE 5. The peritoneum and fascia are again elevated to the left by the Kelly clamps held in the left hand of the surgeon. The area of peritoneum between the two double strands of silk is then scarified with a knife blade.

FIGURE 6. The double strands of silk are then drawn taut, pulling the round ligament and with it the uterus up to the scarified area on the abdominal wall. The process is repeated on the opposite side.

FIGURE 7. The round ligament in relation to the abdominal wall after the suture has been tied.



BALDY-WEBSTER SUSPENSION

FIGURE 1. The uterus is placed on forward traction to expose the posterior leaf of the broad ligament. A bloodless area beneath the ovarian ligament is thus exposed. The assistant aids in the exposure by retracting the tube and ovary with a Babcock forceps. The surgeon picks up the peritoneum and incises it in the bloodless area with curved scissors.

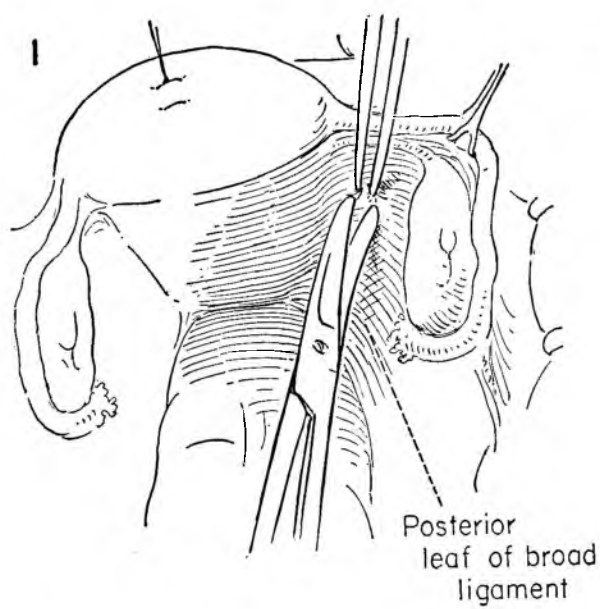


FIGURE 2. The assistant retracts the adnexa while the surgeon inserts a Kelly clamp through the opening in the posterior leaf of the broad ligament and incises the anterior surface of the broad ligament between the open jaws of the clamp.

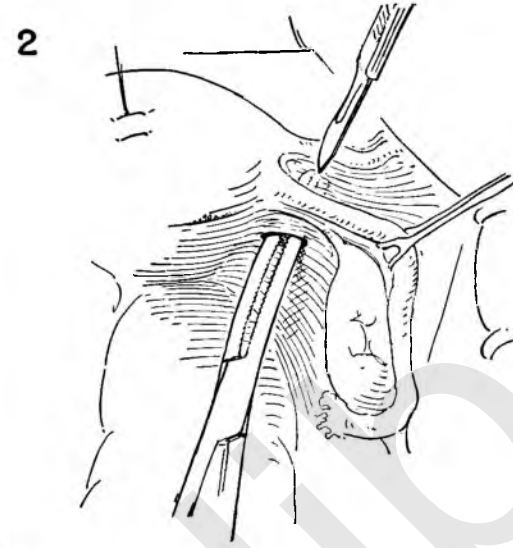


FIGURE 3. The opening in the posterior broad ligament is enlarged with curved scissors.

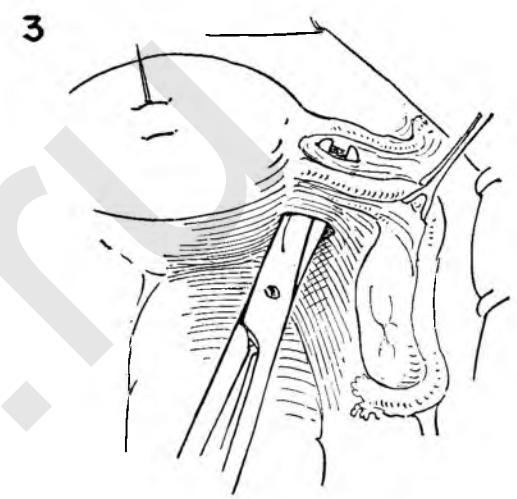


FIGURE 4. The assistant continues to hold back the tube and ovary while the surgeon pulls the uterus to the left. The surgeon inserts an Allis forceps through the opening in the broad ligament and grasps the round ligament at a point well away from the uterus.

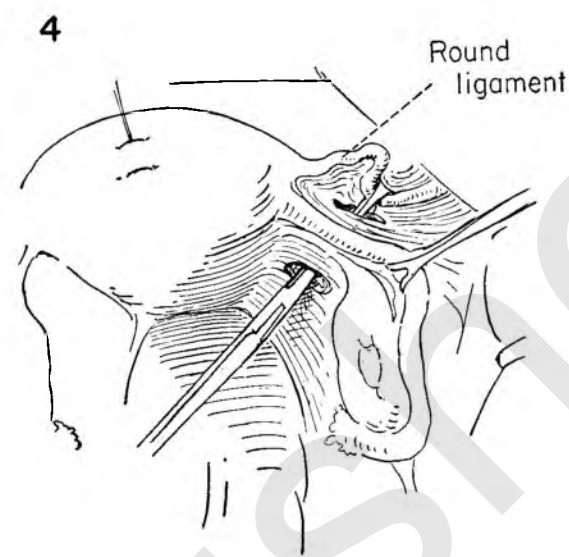


FIGURE 5. A loop of the round ligament is pulled through the opening in the two leaves of the broad ligament onto the posterior wall of the uterus.

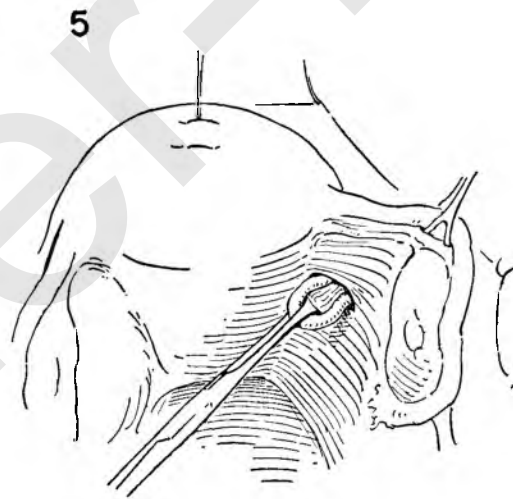


FIGURE 6. The assistant retracts the adnexa and uterus as the round ligament is approximated to the posterior uterine wall with interrupted sutures. A point midway between the fundus and cervix just lateral to the midline is the ideal position.

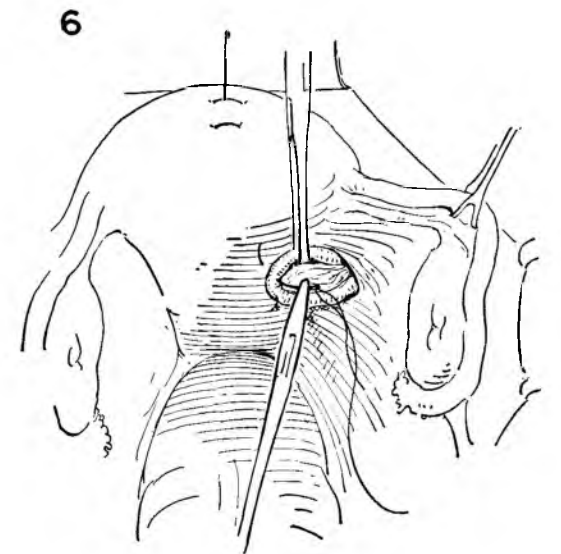


FIGURE 7. The same procedure is carried out on the left side. The defect in the posterior wall of the broad ligament must be closed to prevent herniation of small bowel through the opening. The surgeon places interrupted catgut sutures through the peritoneum lateral to the cut edge and secures it to the peritoneal surface of the uterus.

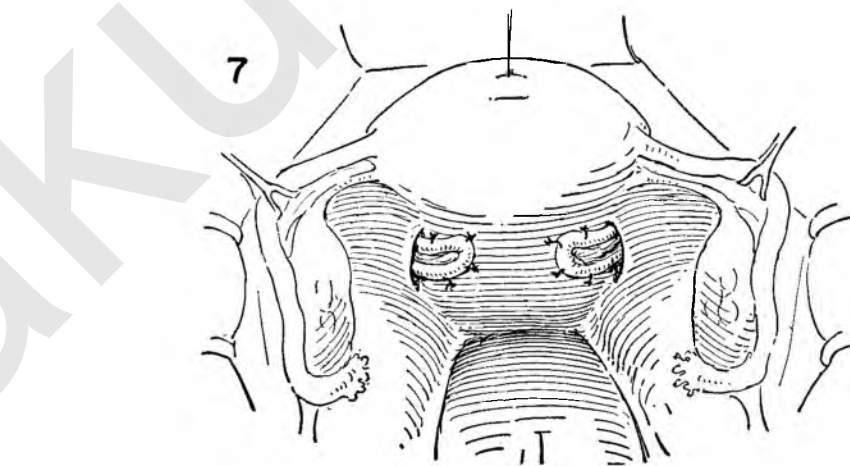
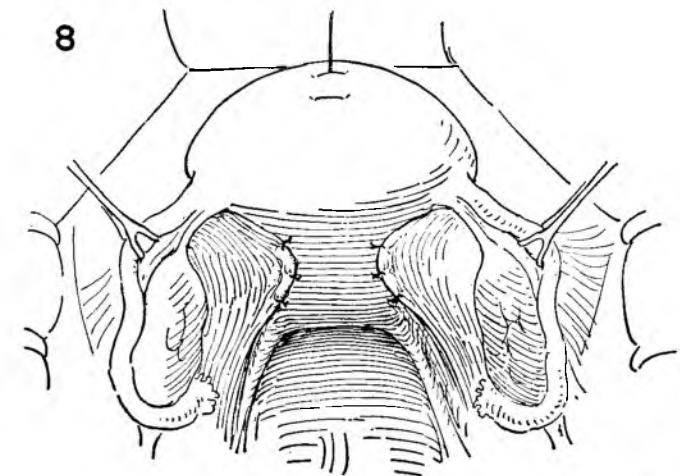


FIGURE 8. The completed suspension and peritonealization. The uterus should lie easily without angulation.



SHORTENING UTEROSACRAL LIGAMENTS

This procedure is sometimes useful in combination with conservative pelvic procedures, but should never be performed as a primary operation. There are two methods by which this may be accomplished.

FIGURE 1. Inasmuch as the ureter is closer to the uterus at the level of the uterosacral attachment than at any other point, the position of the ureter should be determined by either palpation or direct visualization. The uterus is held on traction, and the tube and ovary retracted by the assistant as the surgeon palpates the ureter between the thumb and forefinger. The relation of the ureter to the uterosacral ligament is thus established.

FIGURE 2. The assistant provides exposure by pulling the sigmoid out of the cul-de-sac with his left hand while he elevates the right tube and ovary with forceps. The nurse keeps the uterus on traction. The surgeon, after reassuring himself that the ureter is safely out of the way, picks up the right uterosacral ligament and places the first stitch in its substance.

FIGURE 3. The same exposure is provided by the assistants as the surgeon continues the suture to the left uterosacral ligament. Again the position of the ureter is determined before actually placing the stitch in the ligament.

FIGURE 4. Successive interrupted sutures are placed in like manner to the point where they cease to approximate easily. Each stitch is individually tied and sectioned as it is placed.

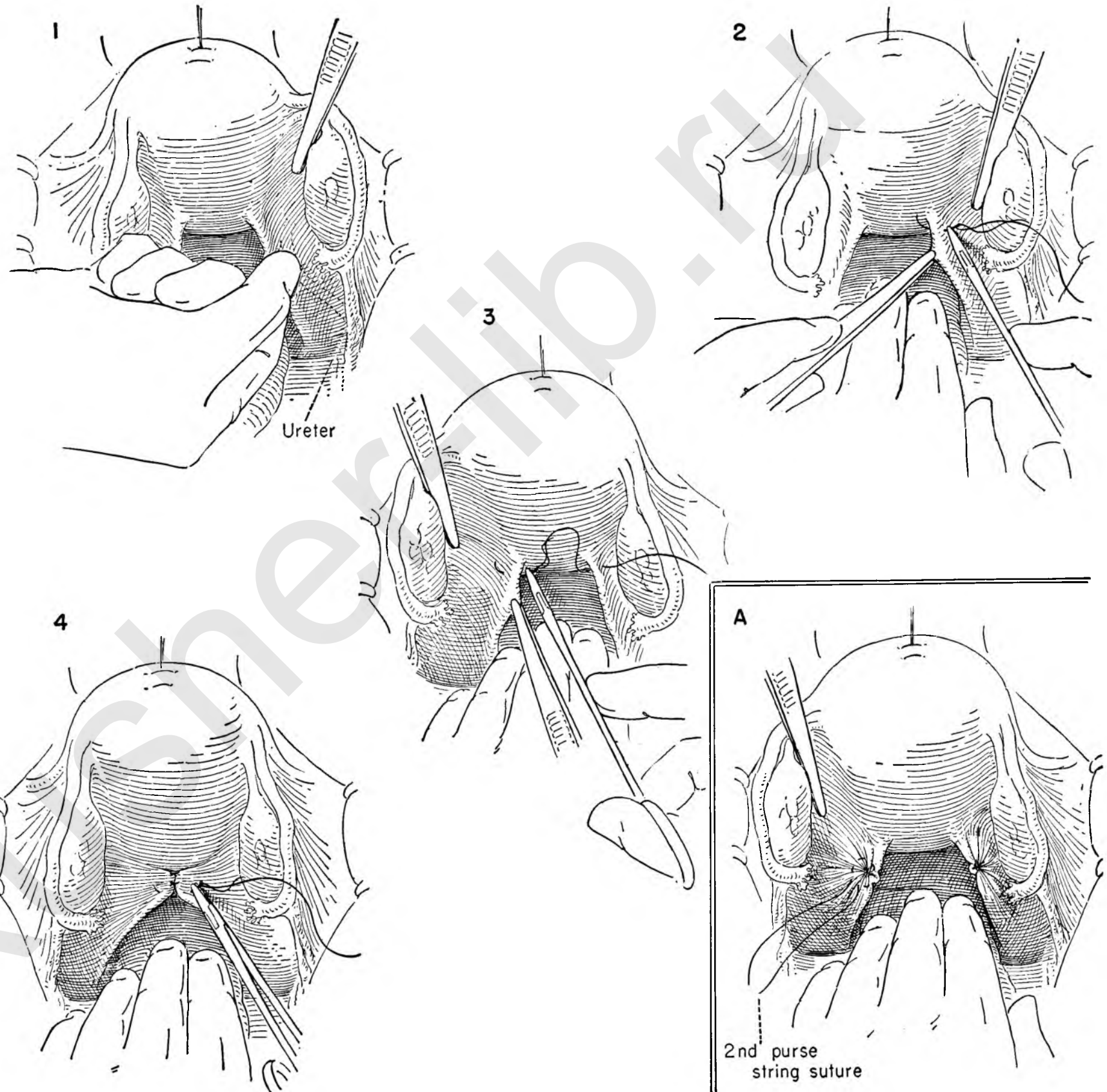
ALTERNATE METHOD

INSET A. Concentrically placed purse-string sutures in each individual uterosacral ligament will likewise produce shortening.

The nurse holds the uterus up by traction on the stitch ligature on the fundus. The assistant retracts both the sigmoid and the left tube and ovary to expose the uterosacral ligament.

The purse-string sutures have been placed and tied on the right uterosacral ligament, which is definitely foreshortened.

The first purse-string suture has been laid in and tied on the left side. The surgeon is completing the second purse-string suture, which, when drawn tight and tied, will include the tissue surrounding the first suture, thereby burying it.



MYOMECTOMY

When it is desirable to preserve the childbearing function, myomectomy is a common gynecological procedure. A simple technique is described readily adaptable to multiple myomectomy.

FIGURE 1. A figure-of-eight suture is placed through the muscle wall of the top of the fundus and held on traction away from the symphysis. A fibroid on the anterior wall of the uterus is thus exposed. The surgeon makes a transverse incision through the serosal surface of the uterus down through the capsule of the fibroid. There is always a plane of cleavage between the fibroid and the surrounding musculature.

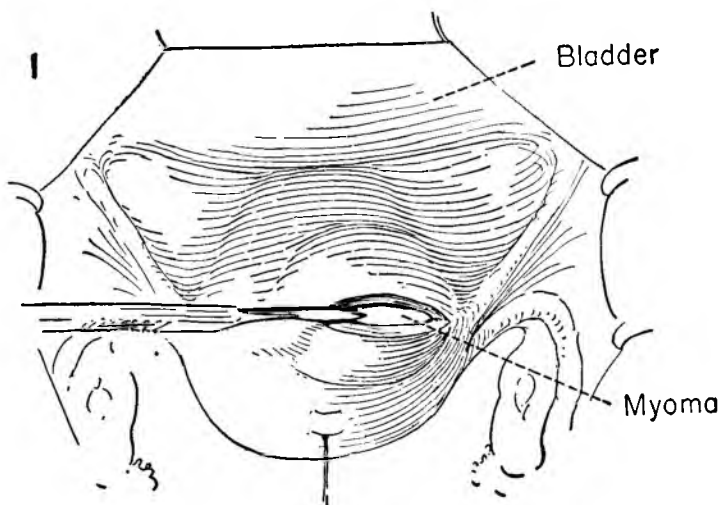


FIGURE 2. The divided edges of the serosa and musculature are held on traction with Allis forceps by the assistant and surgeon as a stitch ligature is laid in the substance of the tumor.

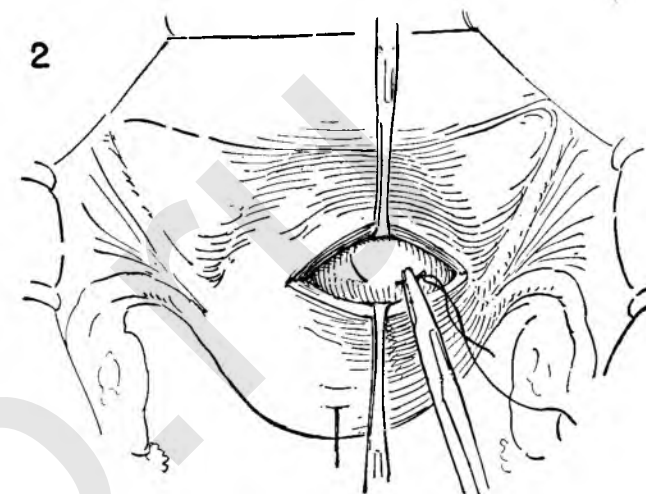


FIGURE 3. The assistant keeps the divided anterior musculoserosal layer on tension with an Allis forceps while the surgeon applies traction to the stitch through the fibroid and begins to separate the tumor from its bed.

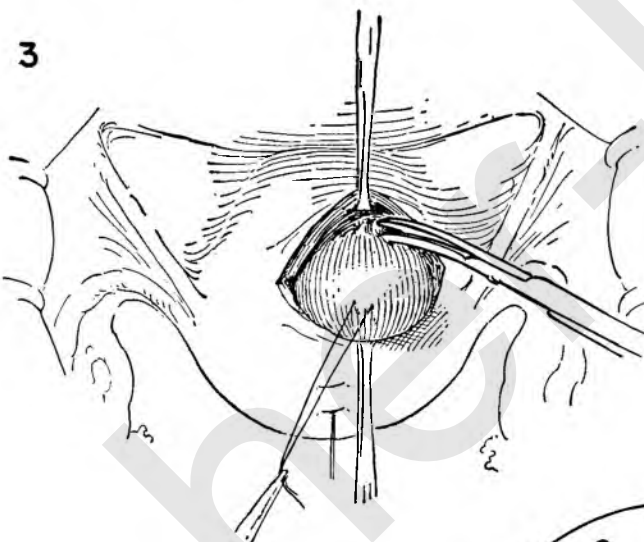


FIGURE 4. The stitch ligature is then held sharply forward to expose the posterior wall of the fibroid. Allis forceps on the seromuscular coat increases the ease of the dissection by providing a wide field. The blood vessels lie in the connective tissue of the capsule. Individual bleeding vessels are clamped.

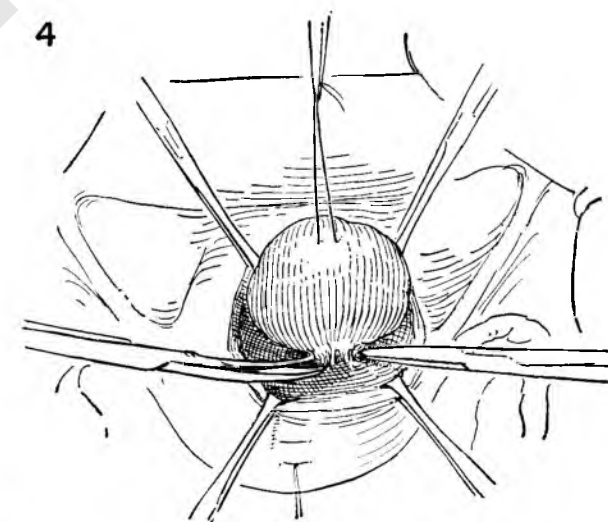


FIGURE 5. The tumor is enucleated, and the assistant ties any clamped vessel.

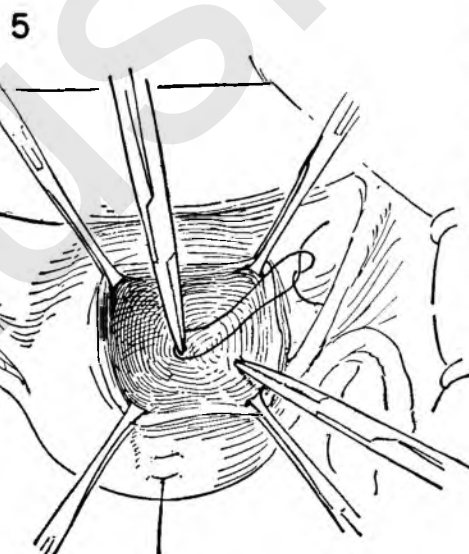


FIGURE 6. Closure is accomplished by placing a cutting point stitch through the serosa and muscle to include the depths of the cavity.

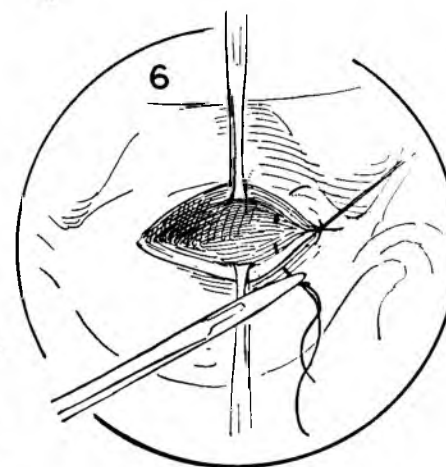
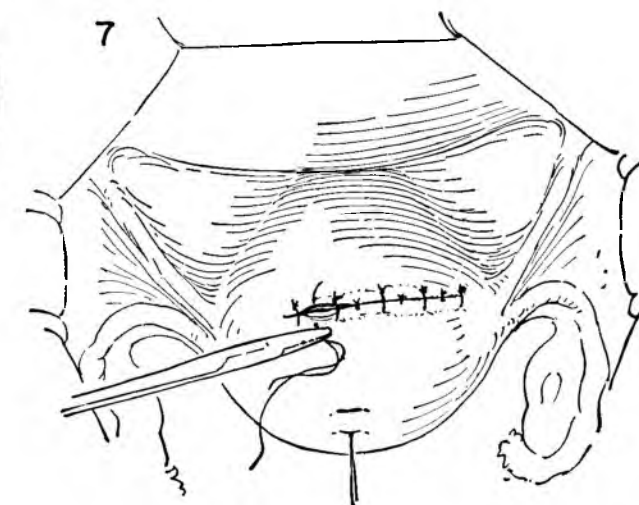


FIGURE 7. Obliteration of the dead space and closure are continued by a series of interrupted sutures similar to that in Figure 6. To complete the serosal approximation, fine interrupted sutures may be placed where needed between the deeper sutures.



PRESACRAL NEURECTOMY

It is the authors' opinion that the operation commonly performed for resection of the presacral nerve has not been extensive enough. The nerve bundle has so many ramifying pathways that complete excision calls for a wide dissection of the nerve trunks along the iliac vessels from above the bifurcation of the aorta distally beyond the promontory of the sacrum.

FIGURE 1. The abdomen is opened through a paramedian incision and the bowel packed out of the pelvis. Patient is in the Trendelenburg position. The sigmoid is retracted to the left. The dotted line indicates direction and extent of proposed incision in the posterior peritoneum.

The surgeon and the assistant elevate the posterior peritoneum from the underlying sacrum as the surgeon divides it with a knife. The incision is then extended down over the promontory and up over the bifurcation of the aorta.

FIGURE 2. Silk stay sutures are placed on the divided edges of the peritoneum and clamped long to hang outside the abdominal cavity. This provides a wide-open operative field. The surgeon then sweeps the areolar attachments toward the midline from the under surface of the right peritoneal flap with curved scissors.

FIGURE 3. The right ureter comes into view, lying adherent to the under surface of the peritoneum. It must be identified and left undisturbed.

FIGURE 4. The dissection should be directed toward the right common iliac artery, incising all the ramifying nerve trunks and leaving the adventitia of the vessel clean and glistening. The tissue is mobilized toward the midline as the dissection continues down along the internal iliac (hypogastric) artery. This vessel forms the lateral limits of the dissection.

FIGURE 5. The common iliac artery has been stripped clean of all nerve branches, and the bare, bony surface of the promontory of the sacrum is seen. The left common iliac vein runs almost transversely across the operative field to disappear beneath the right common iliac, where it joins the right common iliac vein to form the inferior vena cava. The nerve is elevated by forceps and gently dissected free of the superior surface of the vein. Small branching veins must be gently isolated, clamped and tied. The entire nerve bundle has been mobilized toward the midline.

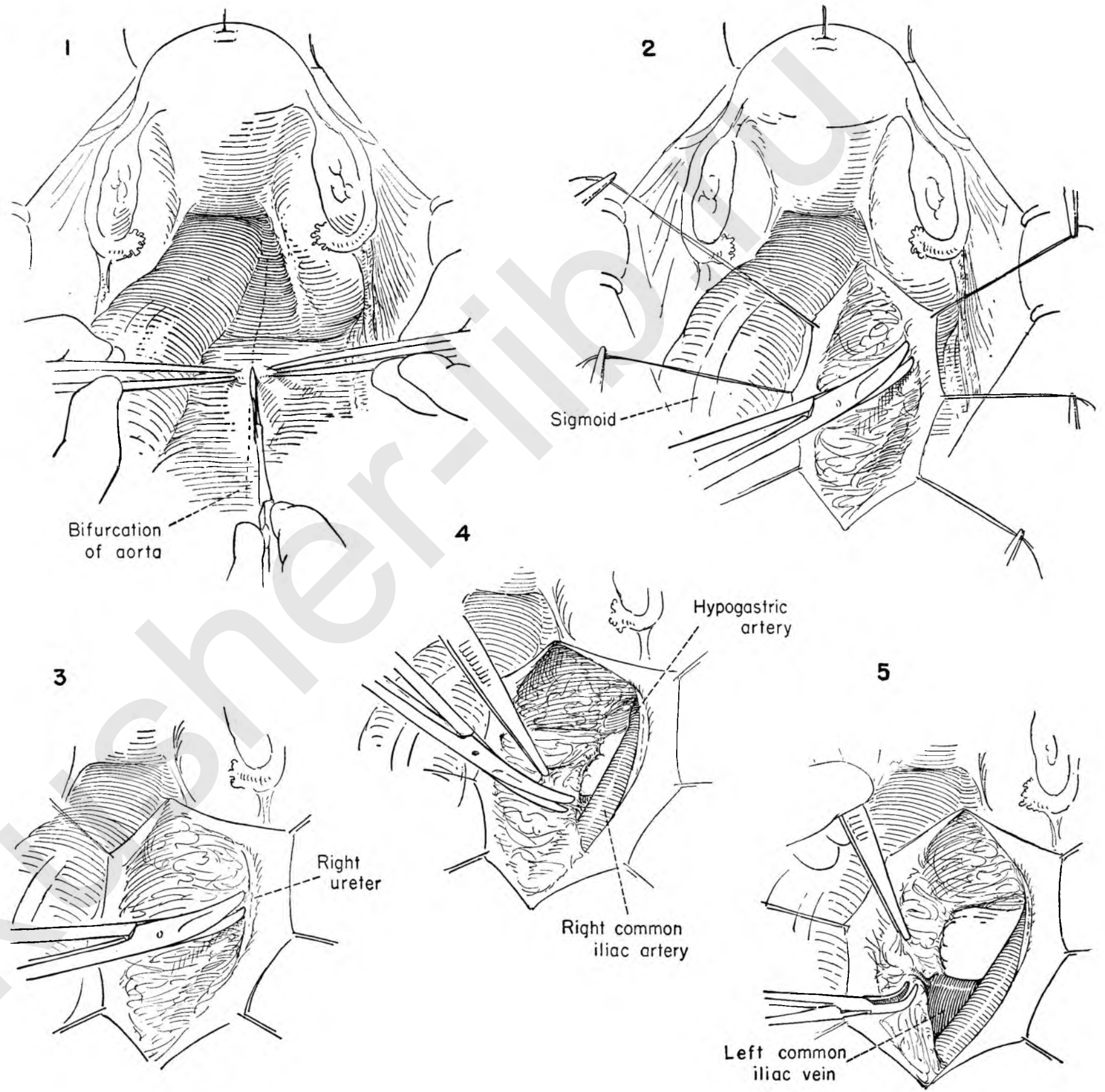


FIGURE 6. The left peritoneal flap is placed on traction, and the nerve bundle pulled toward the midline by the surgeon and assistant as the former dissects the areolar tissue from the under surface of the left peritoneal flap. The dissection soon encounters the sigmoidal vessels, which must be identified and left on the peritoneum as the dissection proceeds beyond them.

FIGURE 7. The ureter then becomes apparent and is handled as on the right side. Medial traction on the nerve is important to facilitate dissection from the vessels.

FIGURE 8. The nerve mass is dissected off the main trunk of the left iliac vessels and continued down along the superior surface of the left internal iliac vein.

FIGURE 9. The nerve is now attached both below and above, but is otherwise dissected free from any underlying attachment to vessel. Kelly clamps are then placed across the main body of the nerve bundle. The nerve mass is then divided between clamps.

FIGURE 10. The surgeon turns the distal end of the nerve bundle toward the symphysis and dissects the under surface of the nerve mass from the anterior surface of the sacrum for a distance of about 1 inch. Care must be taken not to damage the midsacral veins which, although no larger than the lead in a pencil, nevertheless may, when traumatized, cause formidable bleeding difficult to control. The surgeon will be happy to have dura clips available on the operating table in the event of damage. The best advice is to have the vessels in sight and avoid injuring them.

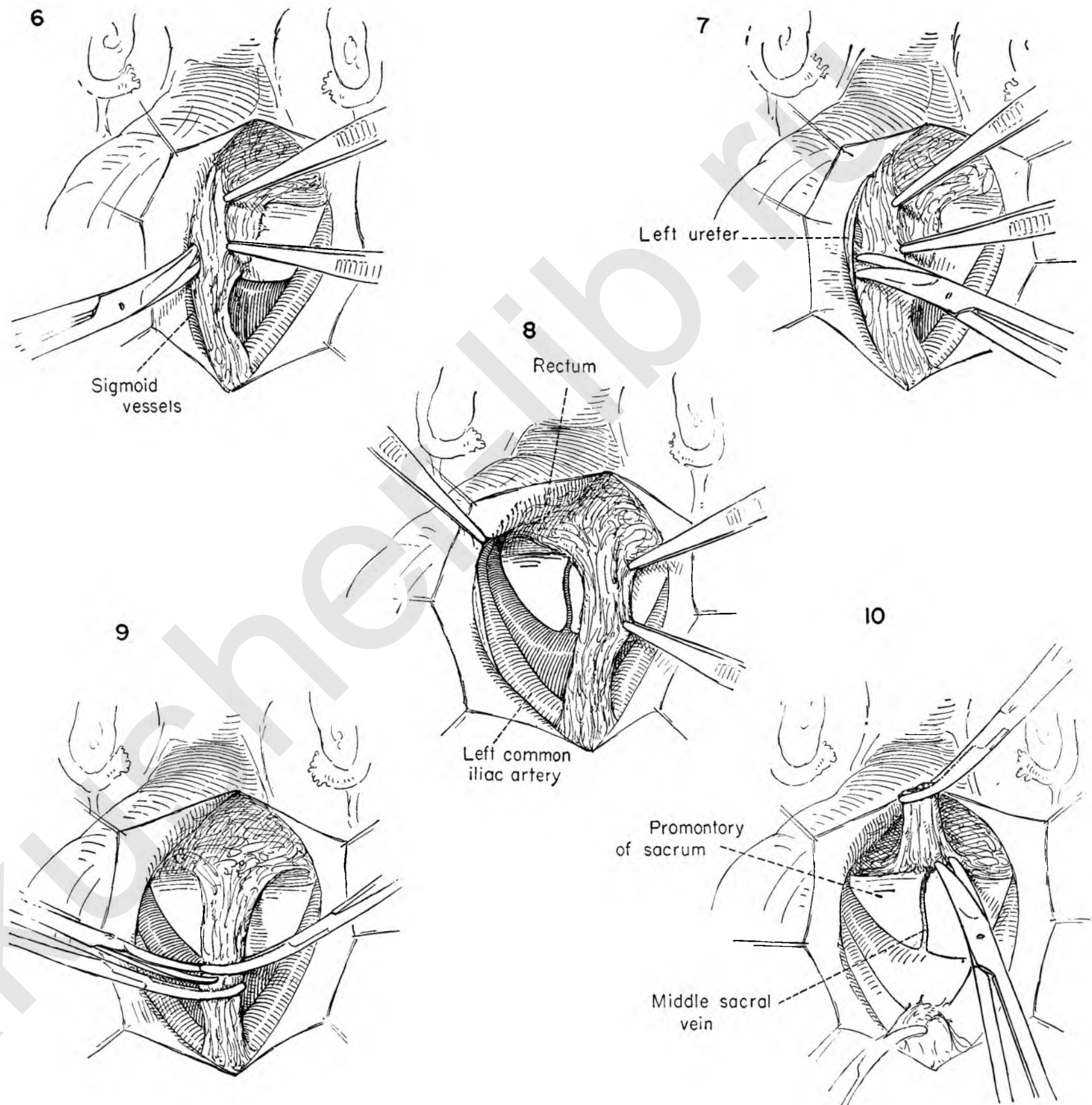


FIGURE 11. The surgeon elevates the distal segment of the nerve bundle and places curved Kelly clamps at the lateral extension beyond the promontory of the sacrum. It is then sectioned above the clamps.

FIGURE 12. Stitch ligatures are then placed to include the tissue in the Kelly clamps. The sutures are tied and divided.

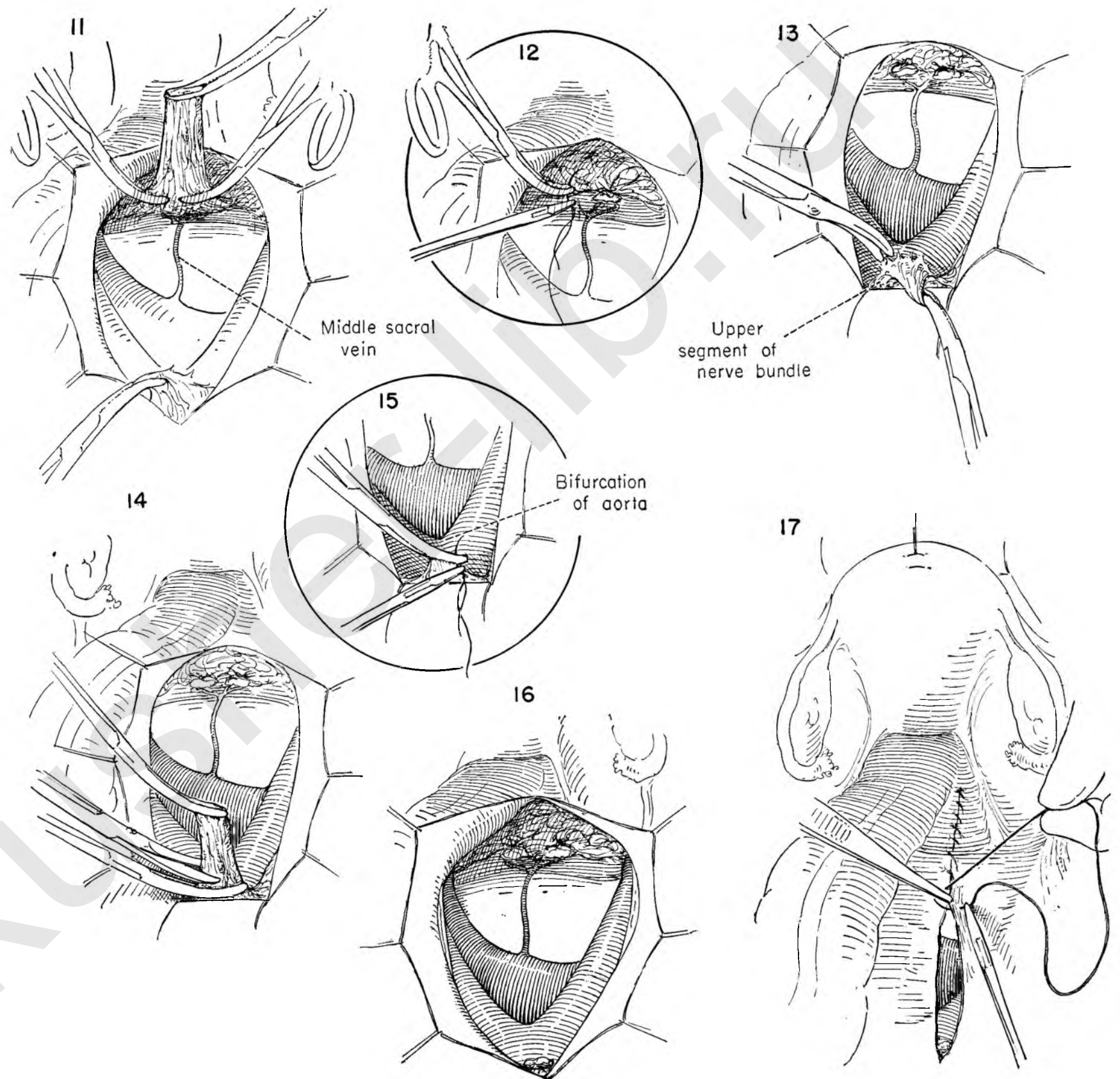
FIGURE 13. The surgeon then directs his attention to the upper nerve segment. Holding the Kelly clamp previously placed on the nerve trunks in the left hand, the operator rotates it upward to expose the under surface in relation to the bifurcation of the aorta. The fine areolar attachments are separated from the adventitia of the main body of the aorta.

FIGURE 14. The nerve mass is held up and a Kelly clamp placed across the main body of the nerve above the bifurcation of the artery. The nerve is then divided.

FIGURE 15. The surgeon then places a stitch ligature around the Kelly clamp and ligates the main nerve trunk.

FIGURE 16. This drawing shows the anatomy in relation to the extent of the dissection. Too frequently all the ramifications of the nerve are not removed. Note that both artery and vein are stripped clean from the aorta above to the promontory of the sacrum and laterally to the internal iliac arteries. The midsacral vein from the hollow of the sacrum can be seen entering the left iliac vein.

FIGURE 17. To have a satisfactory dissection the operative field should be bloodless. Before closing the peritoneal incision all bleeding points must be controlled. A running atraumatic catgut suture closes the posterior peritoneal incision.



Operations on Tube and Ovary

In general, operations on the tube and ovary are performed for unilateral disease in one or the other. If the pathological state indicates the removal of both adnexa, the operation of choice calls for total hysterectomy with bilateral excision of the tubes and ovaries.

It is an unfortunate fact, which may be confirmed in the pathological laboratories of any hospital, that much needless surgery is constantly being performed on the adnexa. A high percentage of the ovaries removed are either normal or contain physiological cysts which would regress if left undisturbed. A curious paradox appears in that the operator seems to adopt a radical attitude toward the excision of the normal ovary, yet becomes solicitous about preservation of the opposite ovary when a malignant process is present. Conservatism in the preservation of ovarian tissue is to be commended, but not when cancer is found in the uterus, ovary or tube.

SALPINGO-OOPHORECTOMY

When the disease is unilateral, involving both tube and ovary, salpingo-oophorectomy is indicated. Occasionally in the attempt to preserve either the tube or ovary the blood supply can be sufficiently jeopardized to warrant their removal.

It is important to remember that the tube and ovary should be completely mobilized before any attempt is made at removal. When the tube is to be sacrificed, the isthmal portion of the tube as it courses through the musculature of the uterine horn should be excised.

SALPINGECTOMY

Practically the only indication for salpingectomy occurs in the presence of ectopic pregnancy. When the underlying pathologic state is extensive, secondary to pelvic inflammation, tuberculosis or endometriosis, the primary disease generally involves the entire uterus or adnexa. In such a case one may remove the uterus with the tubes, but elect to take a calculated risk and leave both ovaries.

EXCISION OF SMALL OVARIAN CYSTS

Too many ovaries are needlessly sacrificed for such benign conditions as simple follicle cysts, corpus luteum cysts or endometriosis. When possible, ovarian tissue should be conserved. Frequent pregnancies have followed the preservation of minimal amounts of ovarian tissue following conservative operations for endometriosis. Simple excision with reconstruction of the ovary is easily accomplished.

OOPHORECTOMY

Many ovarian cysts, including the chocolate cyst, can be shelled out of the ovary; but when all normal ovarian tissue

has been replaced, simple oophorectomy is indicated. All ovarian cysts should be regarded as potentially malignant. Unfortunately, simple serous cysts, serous cystadenomata and pseudomucinous cysts resemble each other grossly and have many characteristics in common. Their true nature is revealed only on inspection of the interior. The serous cystadenoma has a far higher malignant potential. Early carcinoma should be suspected if papillary projections or solid portions are found within the interior of a cyst containing clear serous fluid. Since this tumor tends to be bilateral and occurs commonly in the reproductive age group, the surgeon runs the risk of leaving disease in the opposite ovary in his desire to be conservative.

The best method of avoiding the unhappy experience of having the opposite ovary untouched, only to have the pathological department later report carcinoma, is to insist that every ovarian cyst be opened at the operating table before closing the abdomen. Search for malignancy in the solid portions.

INTERLIGAMENTOUS CYSTS

The ovarian cyst in its growth may retain or lose its normal blood supply, but continue to expand within the leaves of the broad ligament. The problem here is largely a technical one. In order to avoid possible damage to the ureter, the surgeon should make it a point to trace its course as the first step in the removal of the cyst.

WEDGE RESECTION OF THE OVARY

Obscure endocrine disease associated at times with bleeding, at others with amenorrhea, seems to occur in the presence of ovaries that grossly appear to have a heavy, thick fibrous tunica enclosing multiple small follicle cysts within the interior of the ovary. Evidence of corpus luteum formation is either completely absent or extremely rare. Disease entities such as the Stein-Levinthal or the Fröml-Chiari syndrome seem to fall in this group. For reasons as yet not clear, reduction in the size of the ovary may restore the uterus to normal function. This is accomplished by the removal of wedge-shaped sections of the ovary followed by loose closure. The wedge removal is preferred to operations designed to turn the ovary inside out.

STERILIZATION

For adequate medical cause in the interest of the mother's health, the surgeon may elect to perform a sterilization procedure either at the time of caesarian section or in the postpartum convalescence.

The *Irving method* avoids any possible reestablishment of the tubal lumen by sectioning the tube and burying the severed ends in the uterine muscle and leaves of the broad ligament.

The *Pomeroy method* is accomplished rapidly with minimal trauma, but carries with it the danger of recanalization.

FALK PROCEDURE

This procedure introduces an entirely new concept into the treatment of extensive pelvic inflammation of gonorrheal origin. Based on the feeling that recurrent attacks of pelvic inflammation have their source in repeated infection from the uterine side, the operation is designed to disconnect the uterus from the adnexa. The blood supply to the tube and ovary is left undisturbed. Chemotherapy aids in sterilizing the cavity, which collapses as the fluid content absorbs. The postoperative course, both immediate and late, is excellent.

PLASTIC OPERATIONS ON THE TUBE

Though the chance of success is not great, the surgeon occasionally elects to perform a plastic operation designed to restore an obstructed pathway through the tube into the uterus. The chances improve if the basic pathologic condition is secondary to streptococcus infection rather than the gonococcus. The gonococcal infections attack primarily the tubal mucosa, while postpuerperal infections of streptococcal origin produce a perisalpingitis.

The preoperative investigation with air and oil may indicate that the block to the passage of sperm takes place at the cornual end. The remaining portion of the tube may be normal. Resection of the cornual end with transplant of a new lumen into the endometrial cavity is therefore feasible.

When the air or lipiodol investigation of tubal patency seems to indicate a normal patency of the cornual end, but a tube closed at the fimbriated end, the problem is somewhat more complicated. The extent of reasonably normal tube is difficult to determine even with the tube in hand at operation. The use of an insufflation apparatus fixed in place and controlled from outside the operative field will often prove helpful at abdominal exploration. The passage of air into the tube can be heard and seen and the crepitus palpated when air is injected into the uterus by an assistant. The point of maximum distention and crepitus suggests the optimum position for the tubal plastic.

To maintain patency within the reconstructed lumen the surgeon may elect to insert a polyethylene tube into the endometrial cavity and out the cervix or out through the abdominal cavity.

SALPINGO-OOPHORECTOMY

FIGURE 1. The uterus is held to the left and the tube and ovary elevated by a Kelly clamp in the left hand of the operator in order to expose the infundibulopelvic ligament containing the ovarian artery and vein. The position of the ureter is noted in relation to the vessels and a stitch ligature placed around them under direct vision with complete safety.

FIGURE 2. The suture is tied by the assistant and held long as the surgeon places a Kelly clamp on the vessels toward the adnexa designed to prevent back bleeding. As the surgeon cuts the vessels, the assistant stands ready to apply another clamp to the cuff beyond the tie.

FIGURE 3. The first suture is then divided and a second stitch ligature applied. The ovarian vessels are thus doubly ligated. The tube and ovary are pulled toward the midline, and the anterior sheath of the broad ligament below the tube is divided obliquely with scissors up to the point of insertion of the round ligament.

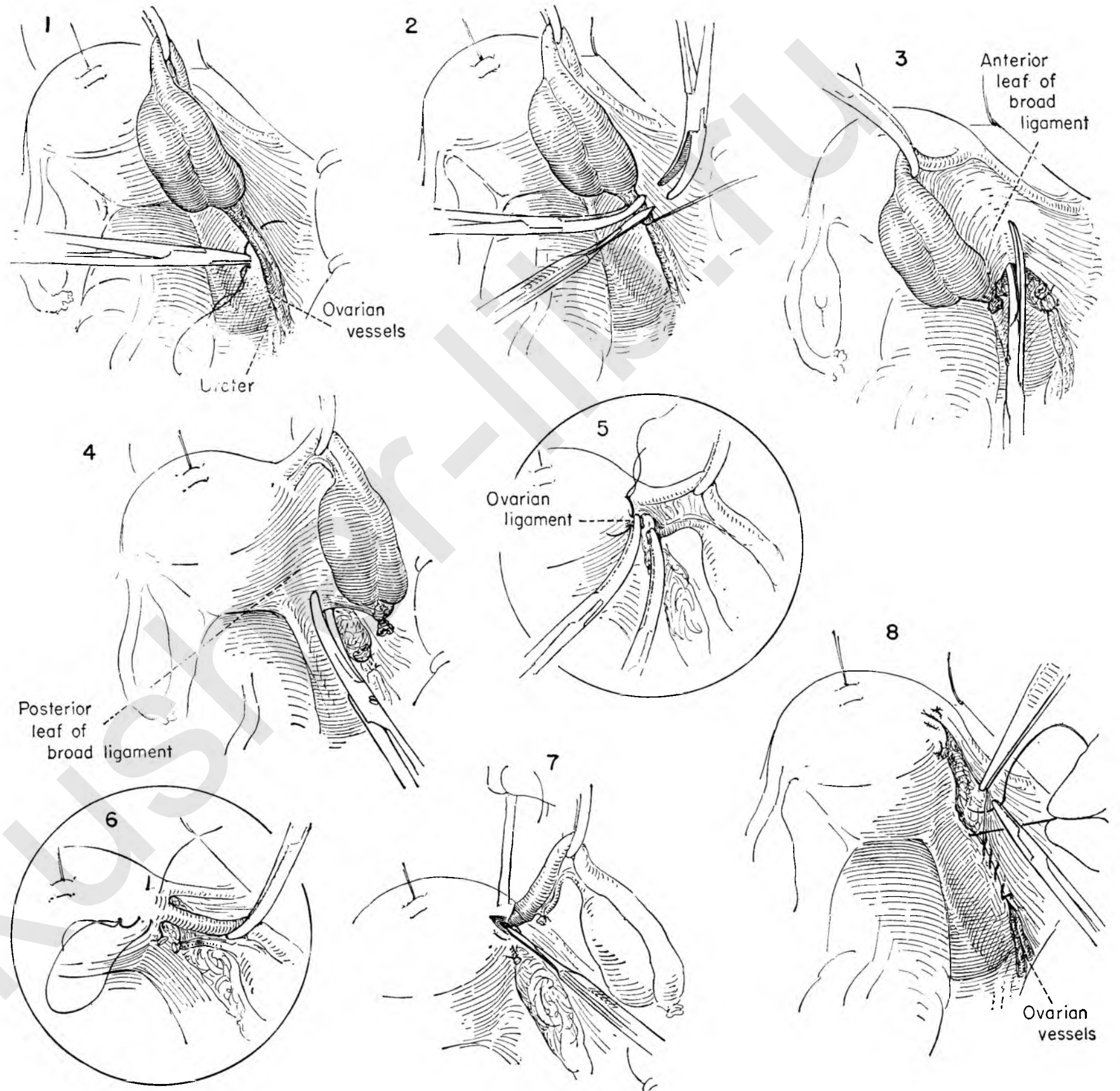
FIGURE 4. The posterior leaf of the broad ligament below the ovary is incised in similar fashion.

FIGURE 5. The ovarian branch of the uterine artery lies within the ovarian ligament close to the uterus. This vessel is secured by Kelly clamps, divided and tied with a stitch ligature on the uterine side.

FIGURE 6. A deep mattress suture is placed in the uterine muscle at the cornu where the tube inserts in the uterus to control a troublesome bleeding vessel which is invariably present at this point.

FIGURE 7. The tube is then removed by a wedge-shaped resection of the uterine wall. The mattress suture is then tied.

FIGURE 8. The peritoneum is closed by a running suture beginning laterally to bury the stump of the infundibulopelvic ligament below the level of the peritoneum.



SALPINGECTOMY

FIGURE 1. The uterus is retracted to the left. The tube is elevated between the thumb and forefinger. This exposes the vessels lying in the mesentery of the tube. Two Kelly clamps are placed on the free end of the mesentery close to the tube to avoid injuring the blood supply of the ovary.

FIGURE 2. The surgeon divides the mesentery between these two clamps. The clamp on the side of the tube simply prevents back bleeding. A stitch ligature is placed around the clamp on the ovarian side and tied.

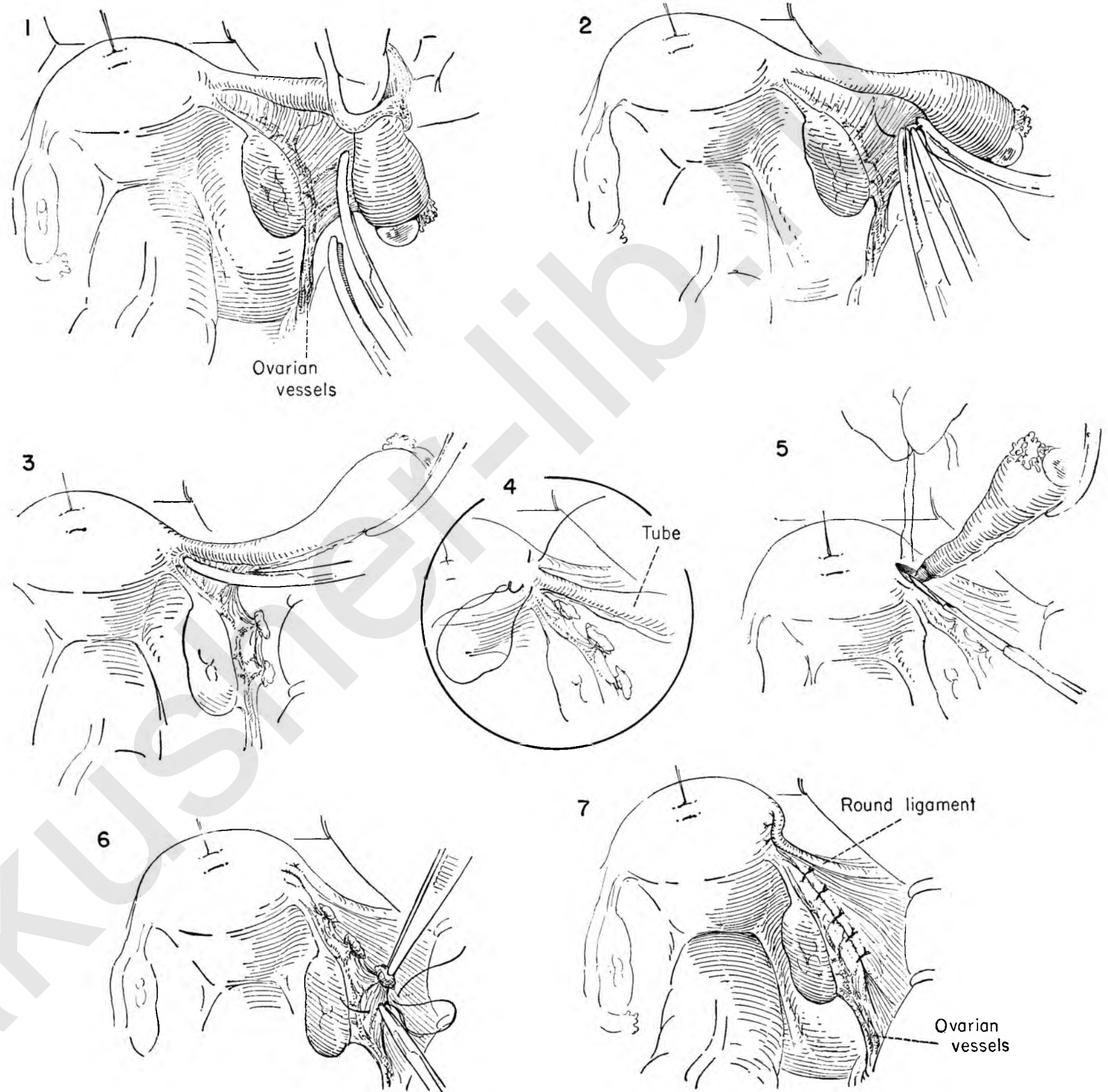
FIGURE 3. The first clamp is left in place to provide elevation of the tube. The surgeon then progresses along the mesentery of the tube, repeating the maneuver of clamping, dividing, and ligating the vessels. The clamps are placed on the tubal rather than the ovarian side of the mesentery in order to disturb the blood supply to the ovary as little as possible.

FIGURE 4. The operator elevates the tube to expose the point of insertion in the cornu of the fundus. A deep mattress suture is laid into the uterine muscle beneath the tube. The suture is left long and untied.

FIGURE 5. The nurse pulls the uterus to the left while the assistant controls the mattress suture in the uterine cornu. The tube is elevated and dissected out of the wall of the uterus in a wedge in the area enclosed by the mattress suture. Tension on this suture controls the bleeding.

FIGURE 6. The assistant ties the mattress suture. The exposed ends of the ligated vessels may be covered by a running suture in the peritoneum. It is a nice refinement in technique to use interrupted sutures rather than a running stitch, which would tend to pucker the area.

FIGURE 7. The round ligament is brought over the cornu and sutured to the posterior uterine wall to add additional coverage to the raw area where the tube was excised.



REMOVAL OF SMALL OVARIAN CYST

The ovary is normally a cystic organ undergoing physiological enlargement and regression throughout the month. The pathologists report too many ovaries sacrificed on the mistaken impression that pathology is present.

For most benign pathology, including endometriosis, the ovary need not be removed. For example, endometriosis invasive in other locations presents a definite plane of cleavage within the ovary. Endometrial cysts then may be shelled out of the ovary. Even a small amount of ovarian tissue may be sufficient to maintain normal menstruation as well as fertility.

FIGURE 1. The uterus is held on traction to the left while the assistant retracts the tube and ovary with Babcock forceps to provide exposure.

FIGURE 2. The cyst is steadied by the operator's left hand while an incision is made through the capsule close to the base of the cyst. Moist gauze beneath the fingers offers additional traction to permit ease in handling.

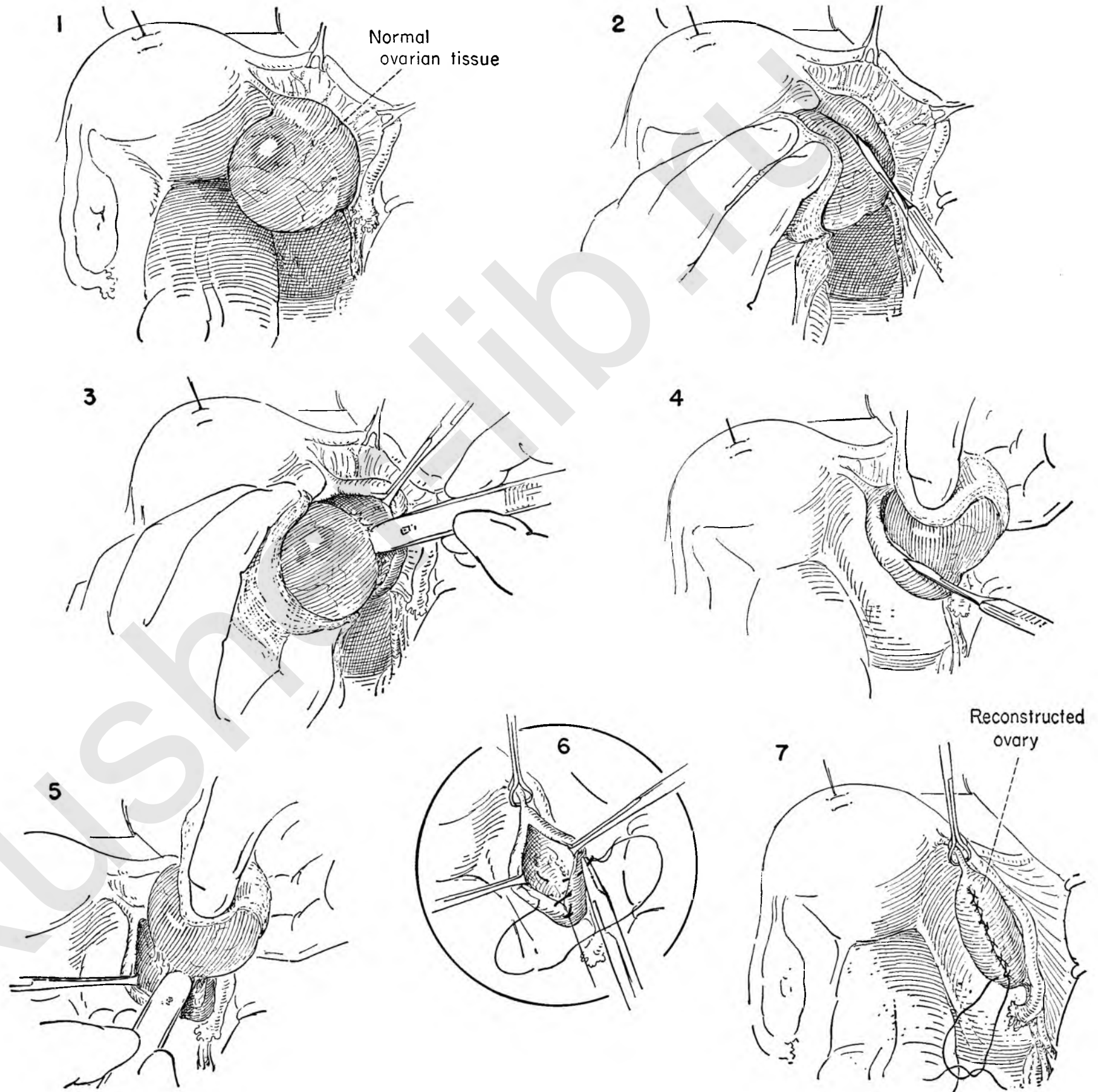
FIGURE 3. A plane of cleavage is readily established which allows the unruptured cyst to be separated from its bed in the main body of the ovary with the knife handle. The assistant applies counterpressure through the Allis forceps placed on the cut edge of the ovary while the surgeon steadies the cyst.

FIGURE 4. The surgeon grasps the cyst with the thumb and forefinger of the left hand and turns it upward to expose the posterior wall. He then incises the posterior capsule at the base of the cyst.

FIGURE 5. Continue to pull the cyst upward to expose the cleavage plane. Traction on the incised edge through the medium of a gently applied Allis forceps will help. The separation is readily made with the knife handle.

FIGURE 6. A Babcock clamp steadies the ovarian ligament while the defect in the ovary is closed with a running atraumatic catgut suture. The stitch passes through the cortex of the ovary to include the depths of the cavity. Exposure is improved by keeping the suture under tension and the edges retracted with Allis forceps.

FIGURE 7. This suture returns to the point of origin and is tied. Hemostasis is complete, and no raw edge is left uncovered.



OOPHORECTOMY

In the patient of childbearing age the surgeon may desire to remove a benign ovarian cyst without disturbing the tube.

FIGURE 1. The uterus is pulled to the left as the assistant retracts the tube with Babcock forceps placed on tension to expose the blood supply of the tube.

The operator displaces the ovary toward him in order to place a clamp as close to it as possible. The tissue included in the clamp is divided with scissors.

FIGURE 2. This bite is secured with a stitch ligature and the clamp removed.

FIGURE 3. This process continues by serial application of clamps close to the ovary until the point of attachment to the uterus is reached. It is wise to avoid the accumulation of multiple clamps by ligating each one as soon as it is free.

FIGURE 4. As the dissection approaches the cornu of the uterus the blood supply from the uterine artery is encountered. A clamp is placed on the ovarian ligament to secure this vessel. The ligament is then divided and the specimen removed.

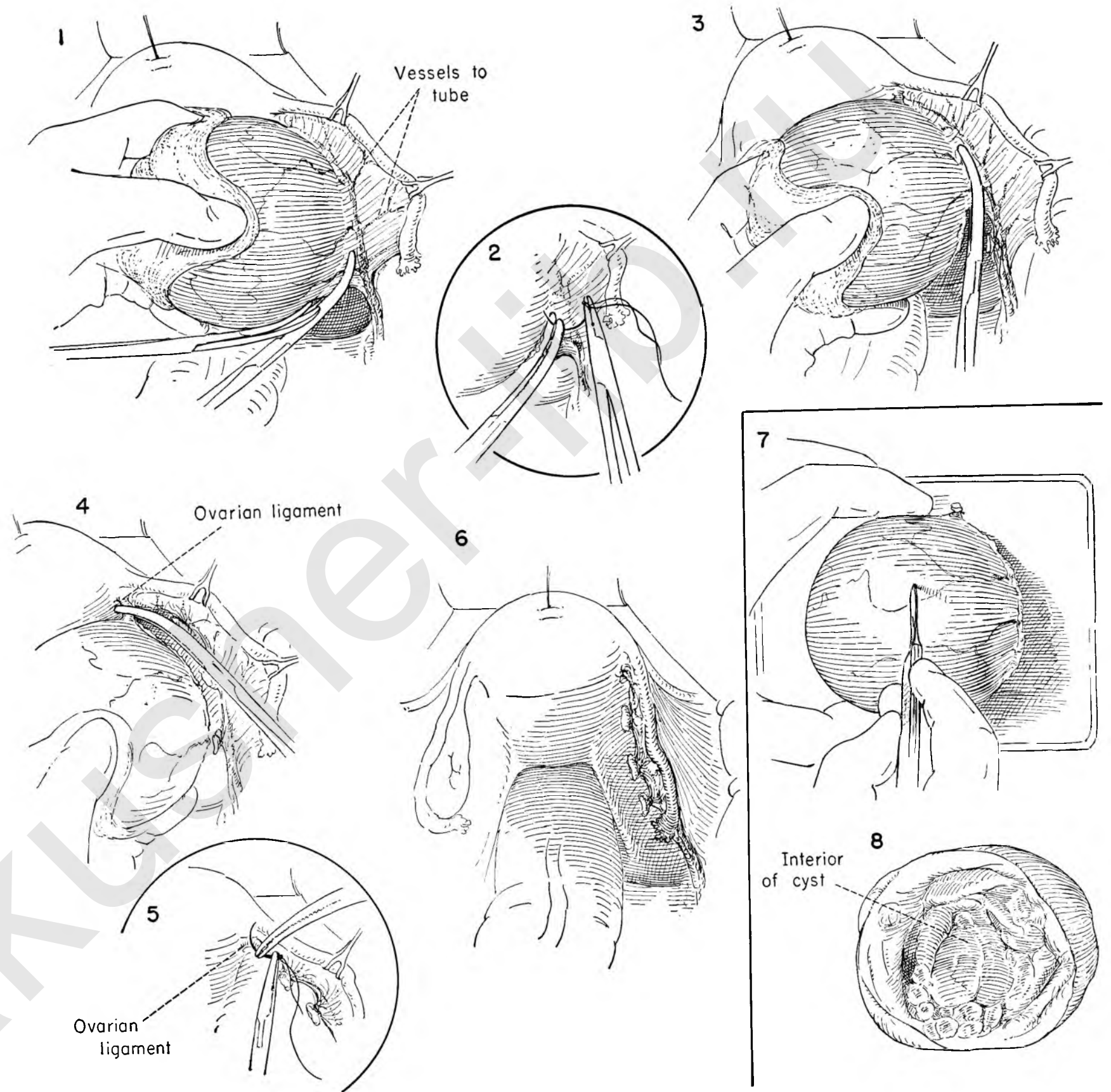
FIGURE 5. A stitch ligature secures the ovarian branch of the uterine artery.

FIGURE 6. The cyst has been removed, leaving a normal tube.

FIGURE 7. Inasmuch as the true nature of an ovarian cyst cannot be determined by inspection of the external surface, it should be an invariable rule that every ovarian cyst should be opened at the operating table before closing the abdomen.

FIGURE 8. The character of the fluid content should be noted, and any papillary projections or solid areas should be regarded with suspicion. Early malignancy appears first in the solid portions of the cyst at the base of the papillary projections. The serous cystadenoma with clear fluid content has an appreciably higher malignant potential than the pseudomucinous cyst.

The disposition of the remaining ovary and uterus is at stake. The optimum treatment of cancer of the ovary demands a bilateral salpingo-oophorectomy and total hysterectomy. If possible, this information should be available before the operation is completed rather than reported later by the pathologist.



INTERLIGAMENTOUS CYSTS

Inasmuch as these cysts arise and expand within the leaves of the broad ligament, the ureter may lie on the lateral surface of the cyst or directly beneath it. To avoid possible damage to the ureter it is important to identify it before beginning the dissection.

FIGURE 1. The uterus is placed on traction to the left, and the ureter is visualized as it crosses the common iliac artery beneath the peritoneum. The peritoneum is incised so as to expose the ureter and the ovarian vessels. The field must be kept dry.

FIGURE 2. Exposure is maintained by stay sutures placed on the edges of the incised peritoneum. The ureter is separated from the ovarian vessels as they cross the iliac artery. They lie in close approximation at this point. Unless separated from the ovarian vessels, the ureter may be inadvertently included in the ligation and division of the vessels. The vessels having been identified, they can easily be freed over a short distance. A clamp is placed beneath them and a strand of catgut drawn back through for the first tie.

FIGURE 3. This maneuver is repeated and the vessels cut and doubly ligated.

FIGURE 4. The assistant retracts the round ligament and applies traction on the uterus toward the operator. The surgeon then divides the peritoneum over both anterior and posterior surfaces of the cyst toward the uterine cornu.

FIGURE 5. The surgeon rotates the cyst toward him. Moist gauze beneath the fingers makes it easier to handle. Simple dissection will free the cyst from the bed under direct vision.

FIGURE 6. A similar plane is easily established beneath the peritoneum on the medial aspect.

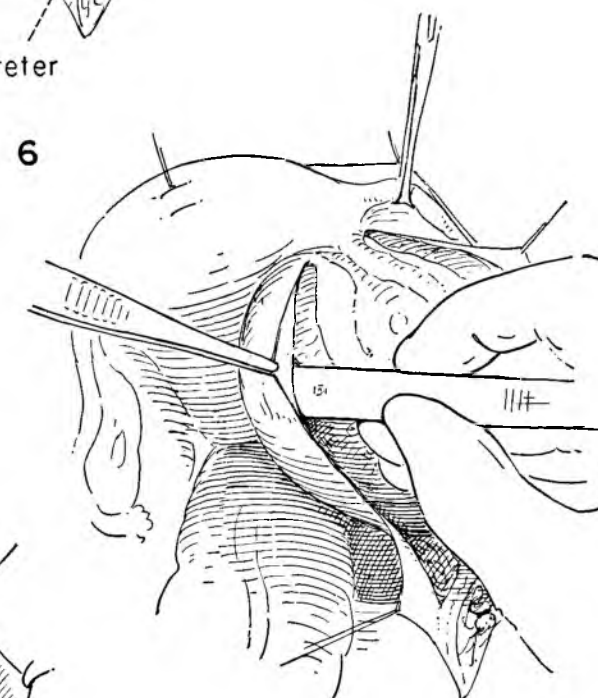
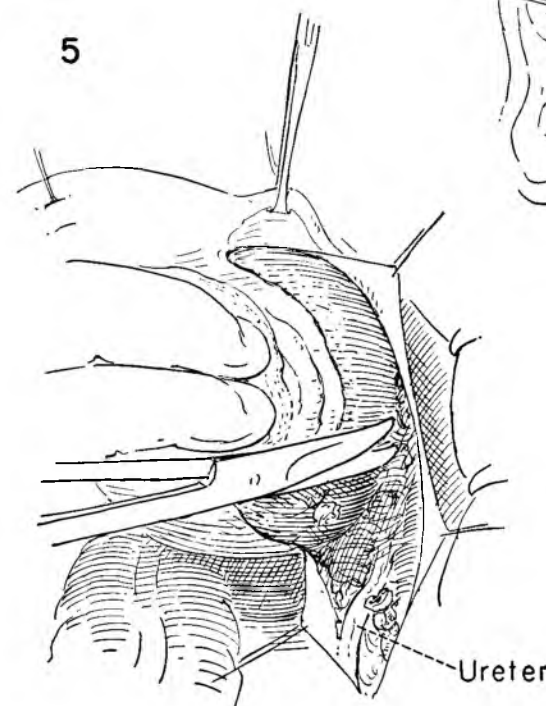
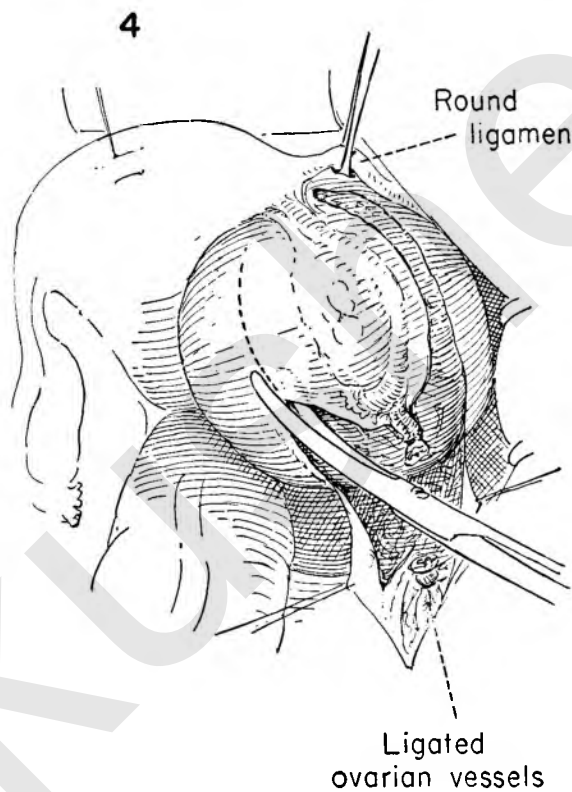
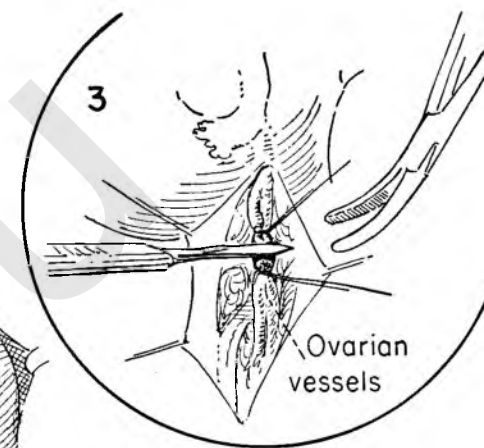
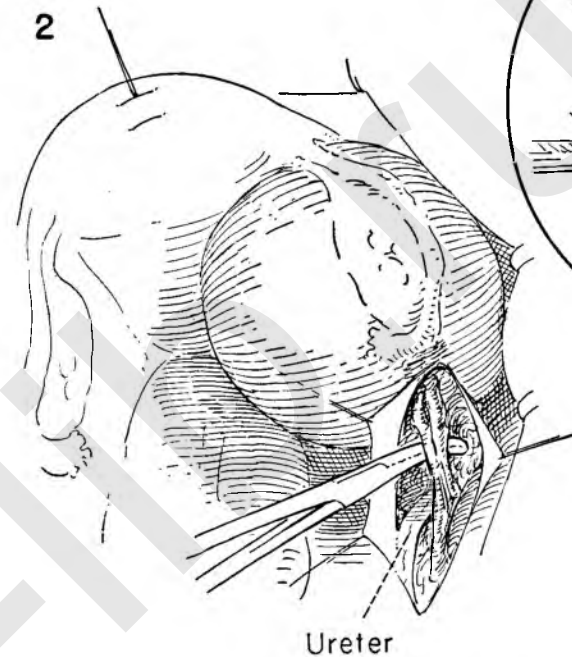
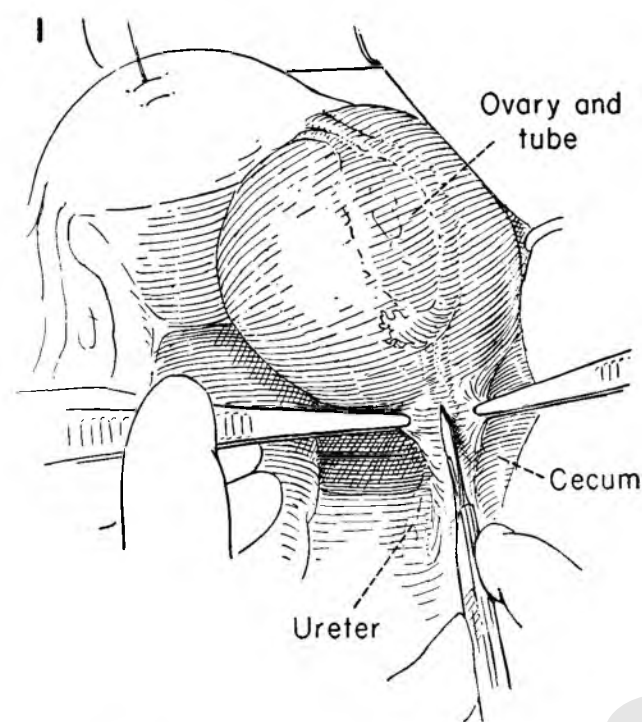


FIGURE 7. The cyst is turned upward toward the symphysis as the areolar adhesions to the under surface of the cyst are exposed and the ureter is visualized. The traction sutures on the peritoneum serve to keep the operative field widely exposed.

FIGURE 8. The uterus is retracted to the side of the operator while the assistant holds up the round ligament with Allis forceps. The ovarian branch of the uterine artery in the ovarian ligament is secured close to the uterus.

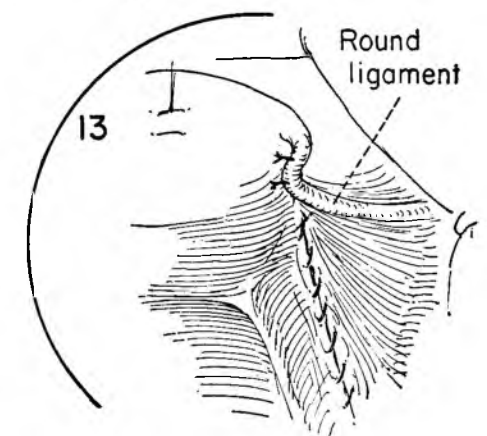
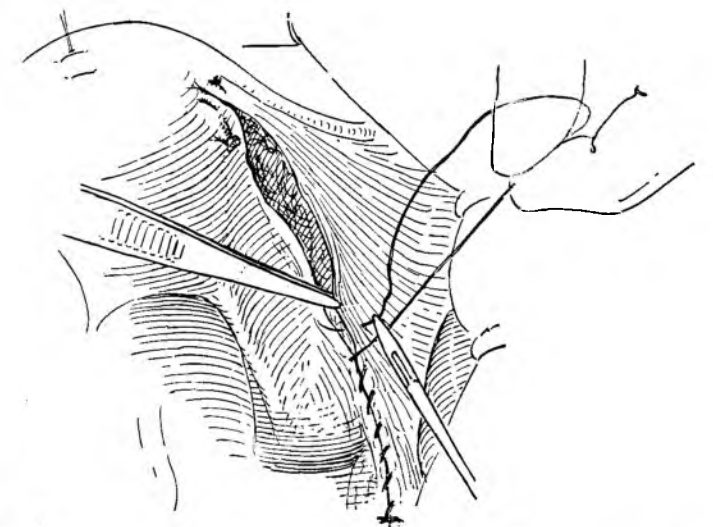
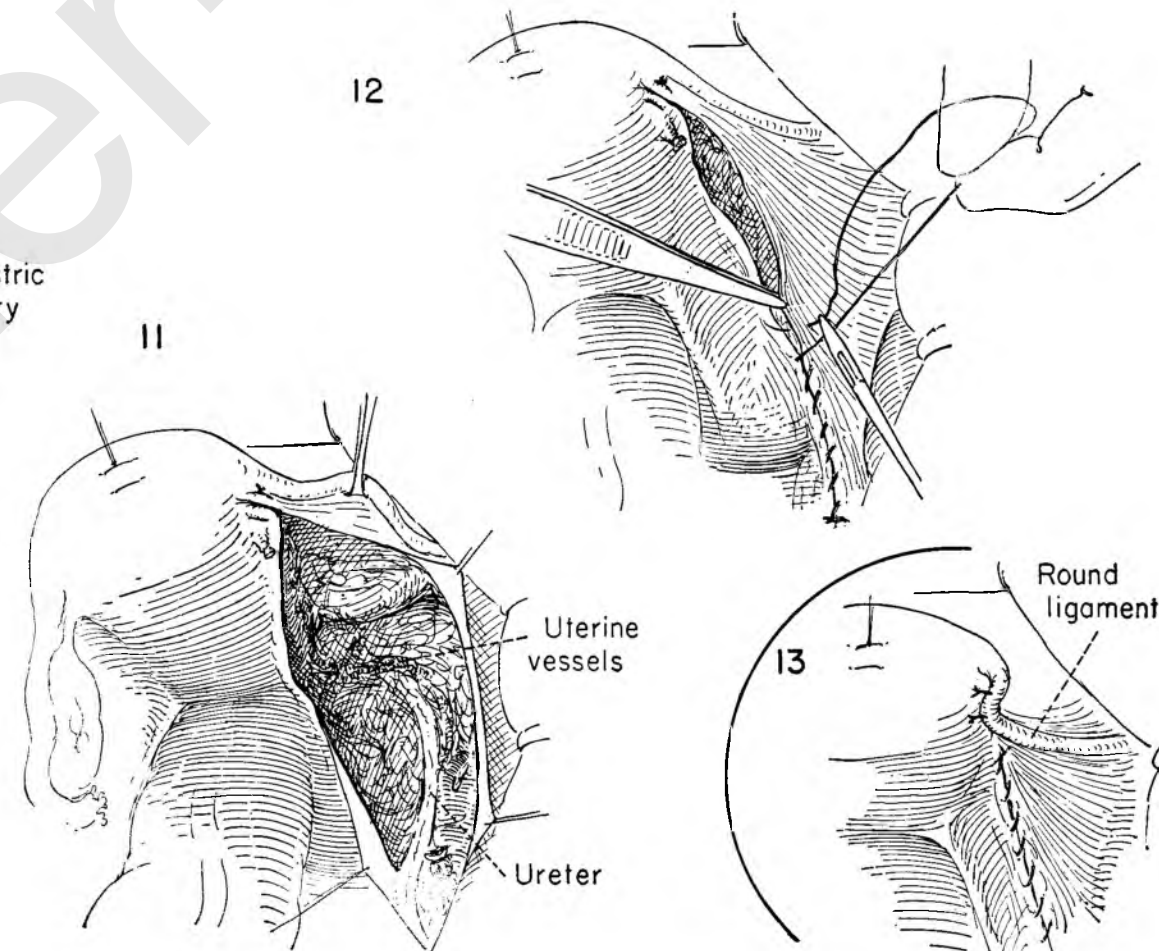
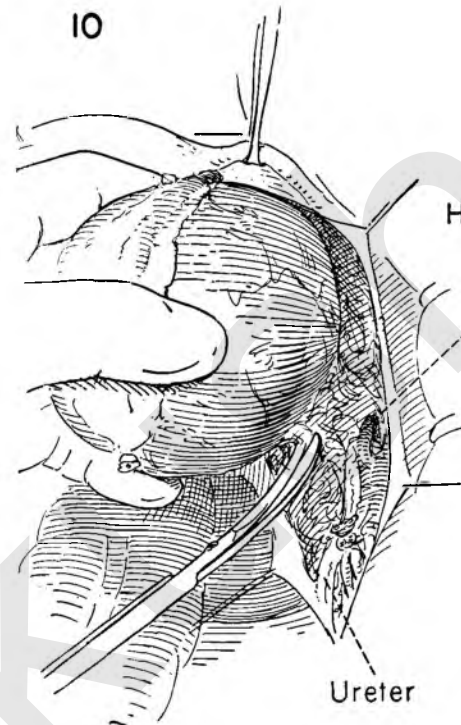
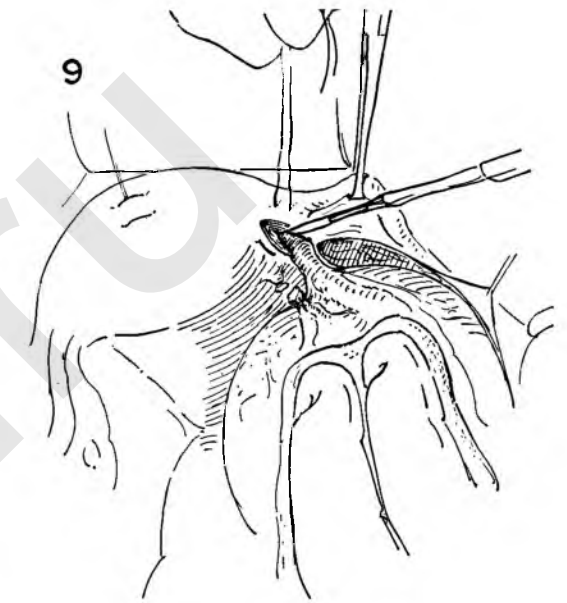
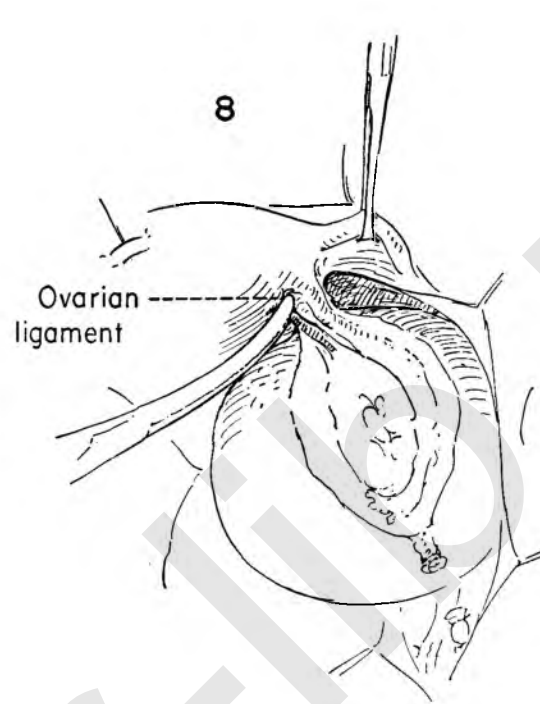
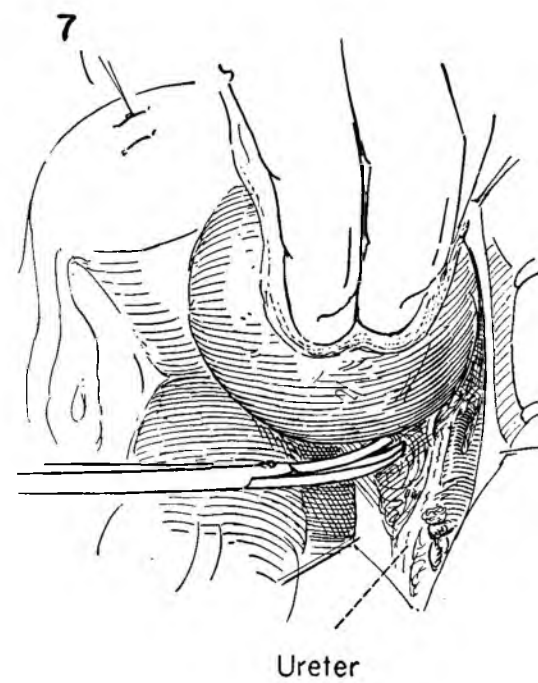
FIGURE 9. A mattress suture is laid in the uterine musculature at the cornu and left untied. The tumor, ovary and tube are drawn away from the uterus, and a wedge is excised at the point of insertion of the tube. The incision is placed within the area inclosed in the mattress suture. The assistant controls the suture while the elliptical incision is carried down to the point of junction of the tube with the endometrial cavity. The suture is then tied to control bleeding from a vessel which is always present at this point.

FIGURE 10. The cyst is dislodged from its bed within the leaves of the broad ligament, and any attachments to the under surface are dissected free. With wide exposure this need never be done blindly.

FIGURE 11. The tumor mass is removed. The anatomy of this region stands out clearly and should be thoroughly checked, particularly the course of the ureter. The iliac vessels and uterine artery are under direct vision.

FIGURE 12. The peritoneal edges are approximated with a running atraumatic chromic catgut suture.

FIGURE 13. The round ligament may be brought down and sutured to the posterior surface of the uterus with a few interrupted sutures to cover the site of the tubal excision.



WEDGE RESECTION OF THE OVARY

In certain physiological disturbances of hormonal nature, such as the Stein-Leventhal syndrome, prolonged amenorrhea and occasionally irregularly profuse bleeding may be secondary to ovarian pathology. The ovary has the characteristic appearance of multiple small follicular cysts within its substance and a heavy thick cortical covering. There is no evidence of corpora lutea either recent or old. Reduction of the bulk of the ovarian substance may correct this condition. This is the so-called wedge resection of the ovary.

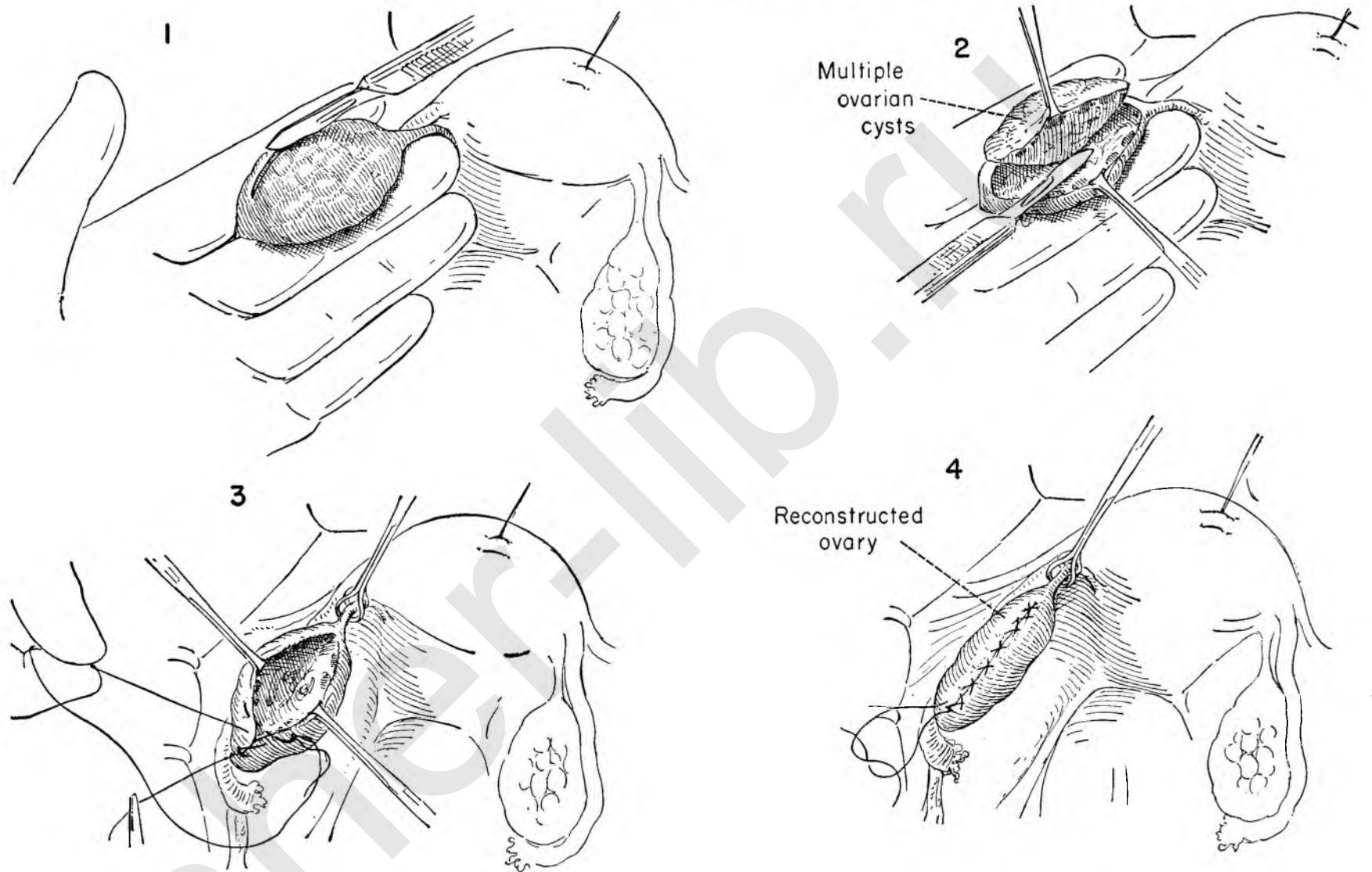
FIGURE 1. The assistant steadies the uterus while the operator grasps the ovarian pedicle and ovary between the index finger and mid-finger of the left hand. A generous segment of ovarian substance is outlined, and the thick, heavy fibrous tunica of the ovary is incised.

FIGURE 2. Allis forceps retract the cut edges, and the dissection is carried well into the substance and the wedge excised.

FIGURE 3. A Babcock clamp steadies the ovarian ligament medially, and the edges of the cavity are held apart with Allis forceps while the raw edges of the ovary are approximated by a suture which includes the base of the cavity.

FIGURE 4. The running suture in the ovary is completed by returning to its point of origin. There it is tied. Note that the bulk of the ovarian tissue has diminished.

Since the pathologic state is always bilateral, the same procedure must be carried out on the opposite side.



EXPLORATORY INCISION OF OVARY

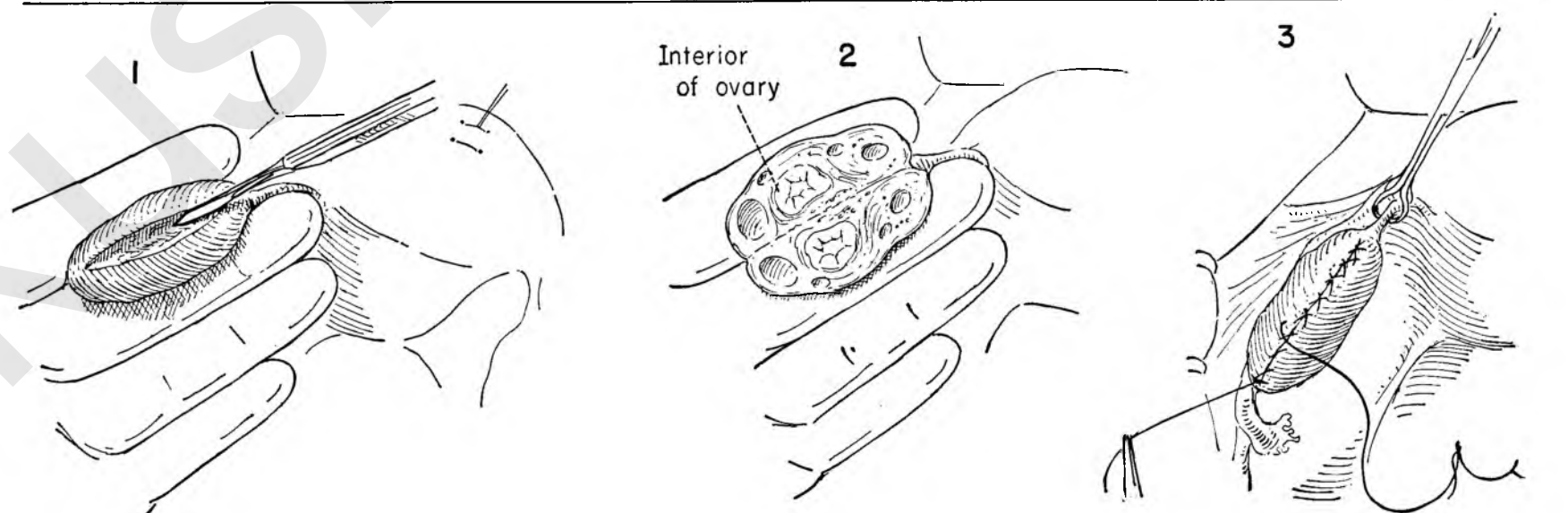
In view of the fact that much pathology occurring in the ovary has a tendency to be bilateral, the surgeon may be concerned as to the proper management of the ovary to be left.

Inasmuch as the ovary may be outwardly normal in appearance, there is often an indication to explore it.

FIGURE 1. The ovary is steadied between the index and middle fingers of the operator's left hand, and a linear incision is made in the long axis and carried directly into the substance of the ovary almost to the hilum.

FIGURE 2. The two cross sections are thus exposed. The interior of the ovary is inspected, and any suspicious area or cyst may be excised for pathological examination.

FIGURE 3. The ovary is reconstructed with a running atraumatic suture up and back.



STERILIZATION PROCEDURES

Simple interruption of tubal continuity has not been completely successful as a means of permanent sterilization. Methods which separate widely and bury the tubal ends decrease risk of failure.

Irving Sterilization

FIGURE 1. The uterus is drawn to the left by a stay suture in the fundus. The surgeon places a stitch ligature around the tube 1 inch from the insertion in the uterus. This suture is held on traction as a similar stitch is passed around the tube ½ inch lateral to it. The tube is divided between ligatures.

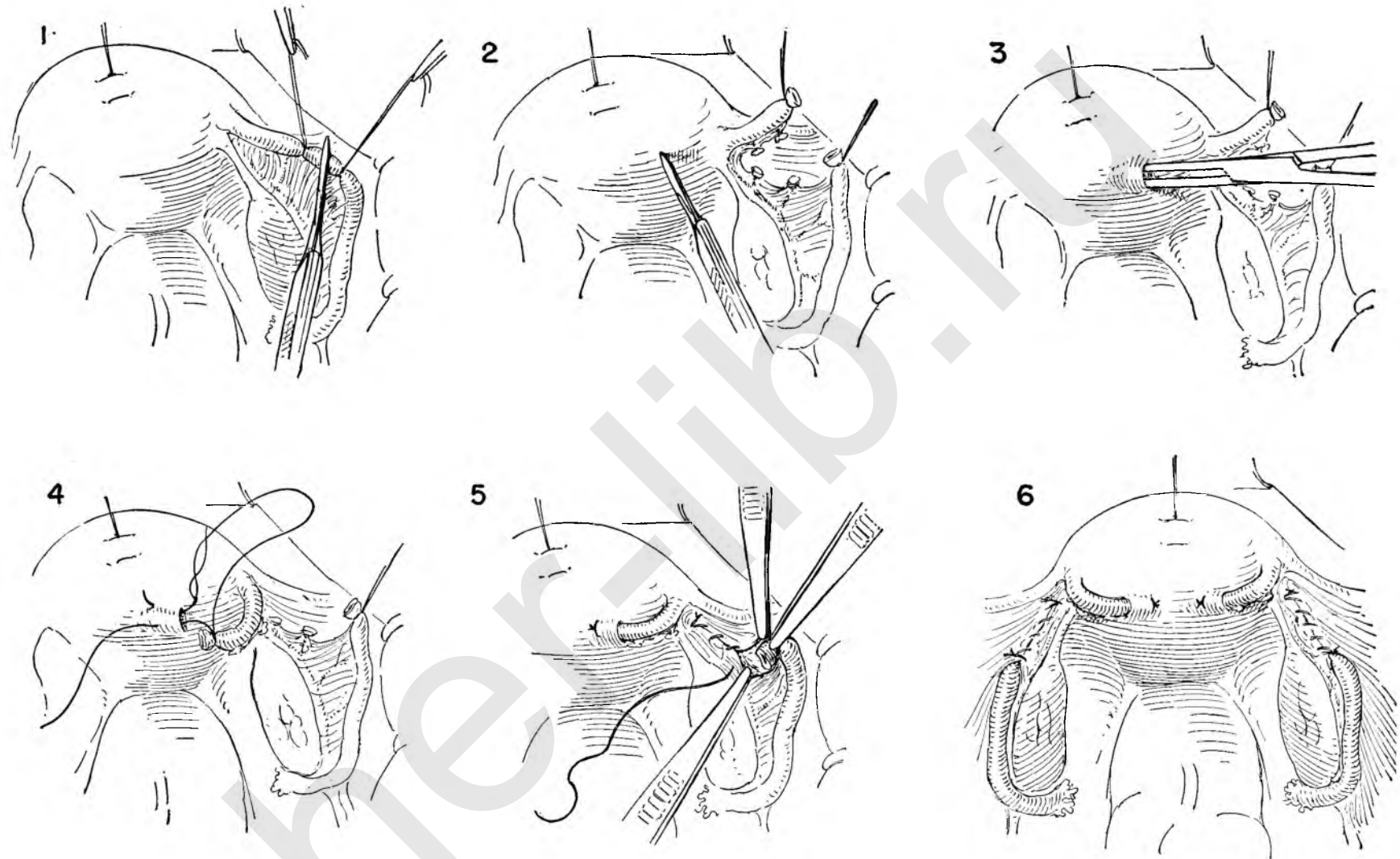
FIGURE 2. The medial segment of the tube is freed from its mesentery and bleeding points ligated. The posterior uterine wall is incised about ¾ inch from insertion of the tube.

FIGURE 3. The incision is enlarged by inserting and spreading the jaws of a small straight hemostat.

FIGURE 4. A needle is threaded on each end of the long suture left on the medial end of the divided tube, carried into the incision and brought out through the peritoneum. Tying draws the cut end below the peritoneal surface.

FIGURE 5. The lateral end of the tube is depressed beneath the peritoneum of the broad ligament and the peritoneal rent closed.

FIGURE 6. The procedure is repeated on the opposite side.



Pomeroy Sterilization

If the surgeon elects to operate a few days after delivery and before involution of the uterus, Pomeroy sterilization is both simple and effective.

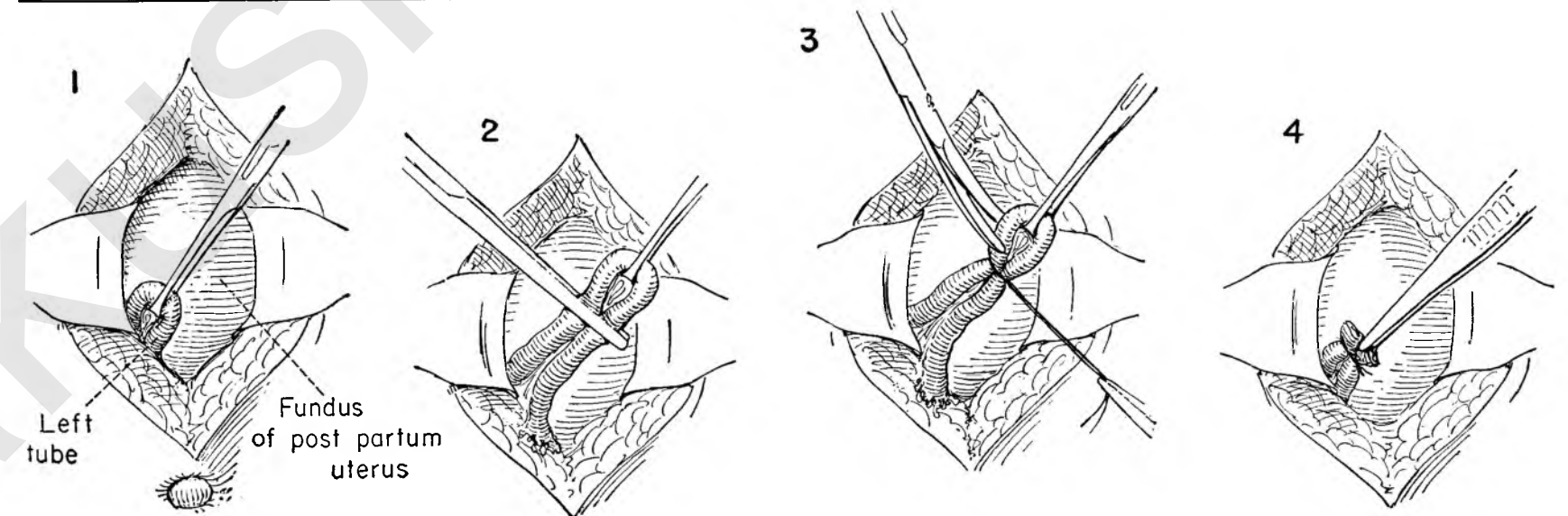
FIGURE 1. The abdomen is opened through a small midline incision about 2 inches below the umbilicus, exposing the fundus of the enlarged uterus. The edges of the wound are retracted to gain exposure. The surgeon grasps the tube at its midportion and delivers it into the incision with an Allis forceps.

FIGURE 2. The assistant holds the Allis forceps on tension while a crushing clamp is applied across both limbs of the loop.

FIGURE 3. The surgeon ligates the tube in the area crushed by the clamp. The loop is then excised just beyond the ligature.

FIGURE 4. The long ends of the ligature are cut and the tube replaced in the abdomen.

A similar procedure is carried out on the opposite side.



FALK TUBAL EXCLUSION PROCEDURE

The rationale of this procedure is based on the premise that the tubal pathology is secondary to recurring infection from disease in the cervix. An operation designed to break the continuity of this pathway should prevent the tube from becoming reinfected. Nothing is removed. The tubes are simply disconnected from the uterus.

FIGURE 1. The uterus is steadied by traction on the mattress suture in the fundus. The tube is grasped with a clamp near the point of origin.

FIGURE 2. A mattress suture is laid into the wall of the uterus around the cornu.

FIGURE 3. The tube is held on tension, and an elliptical incision is carried down to its point of juncture with the endometrium as the assistant holds up the mattress.

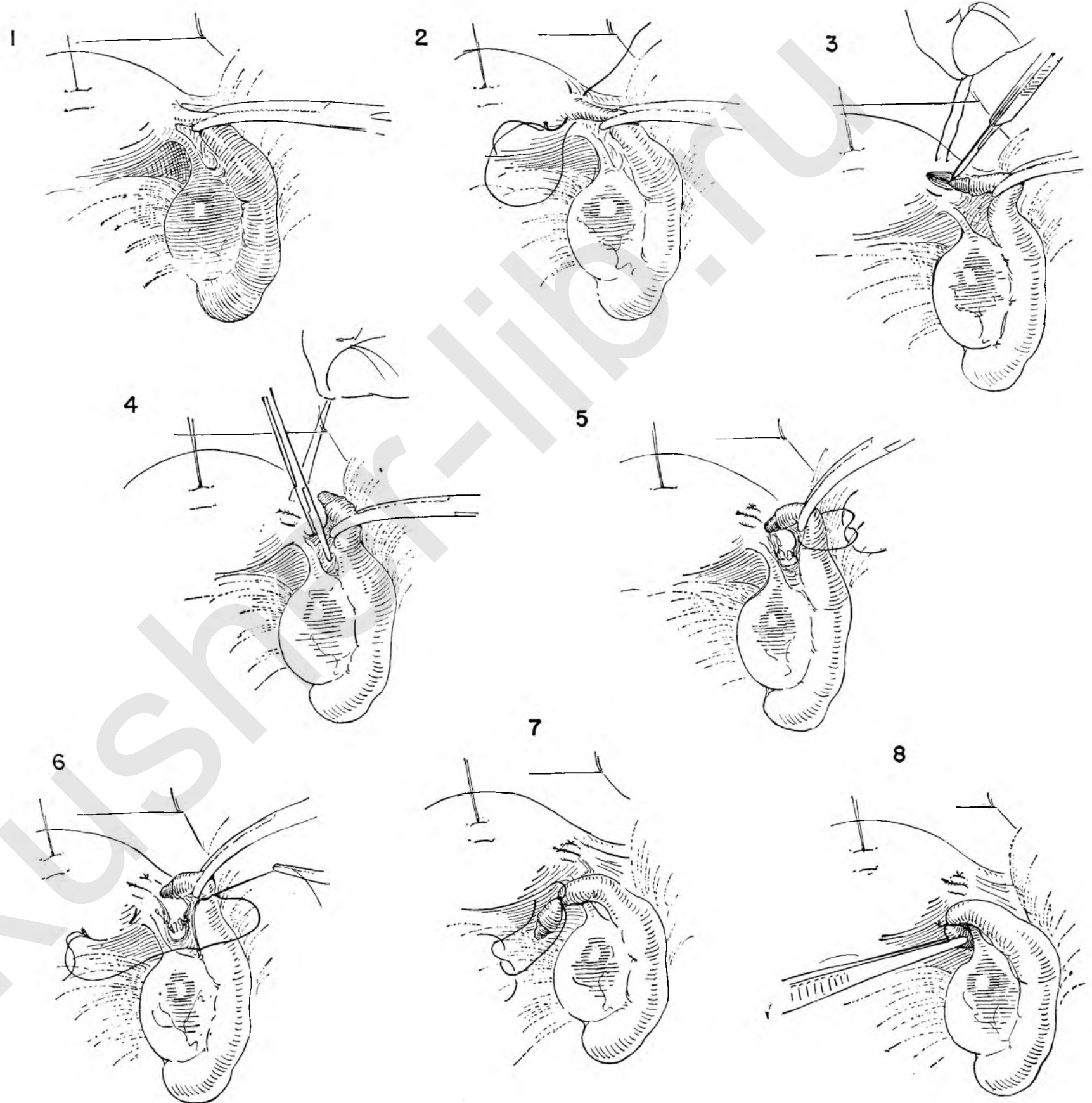
FIGURE 4. The tube is separated from its mesentery for a short distance between clamps as the assistant controls bleeding by tension on the mattress suture.

FIGURE 5. The mattress suture is tied, closing the incision in the uterine wall. A ligature is secured around the tube below the clamp.

FIGURE 6. One end of this tie is threaded on a needle and passed through the peritoneum on the posterior lateral uterine wall.

FIGURE 7. This strand is then tied to the other free end, displacing the tube downward.

FIGURE 8. The cut end of the tube is rotated to lie hidden below the ovarian ligament.



PLASTIC OPERATIONS FOR RESTORATION OF TUBAL PATENCY

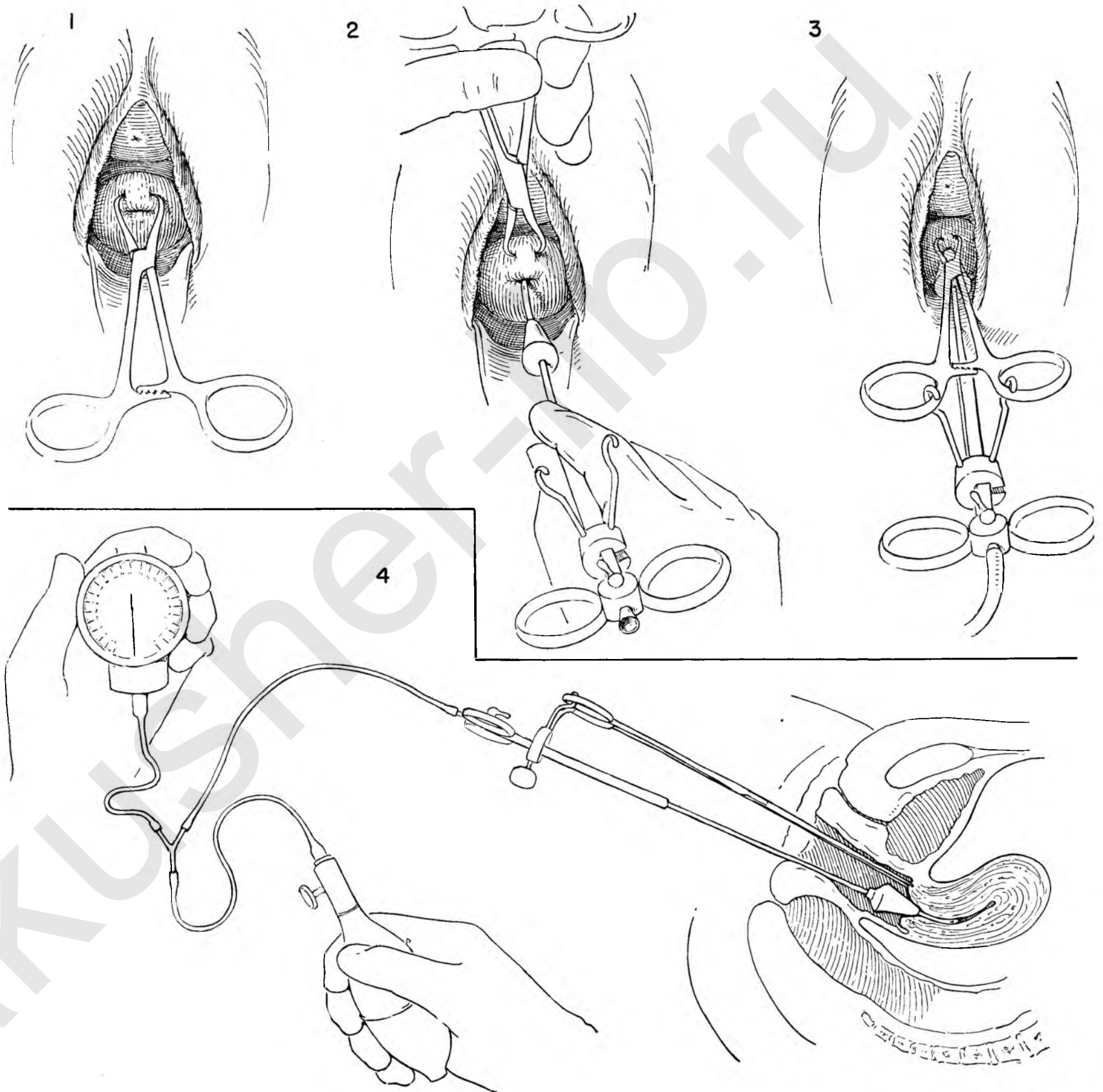
The actual point of obstruction within a fallopian tube damaged by previous pathology may be difficult to determine at abdominal exploration. The fimbriated ends may be closed. This fact may or may not have been determined by a preliminary examination with radiopaque media. Valuable information may be obtained by installing an insufflation apparatus before opening the abdomen. The apparatus is fixed in position so that an assistant can control the injection of air at the direction of the surgeon once the abdomen is opened.

FIGURE 1. The patient is placed in the lithotomy position and the exposed cervix grasped with the tenaculum.

FIGURE 2. The instrument commonly used for tubal insufflation is inserted in the cervical os.

FIGURE 3. The tenaculum is so fixed to a movable carrier on the barrel of the cannula that constant traction on the cervix against a coned rubber plug is maintained, thus preventing the escape of air at this point. The outer end of the cannula is attached to a rubber tube which connects with the insufflating bulb and manometer.

FIGURE 4. The patient is now gently flattened out on the table with the hips abducted. The tubing is left long enough so that an assistant can regulate the flow of air without contaminating the operative field.



EXCISION OF FIMBRIATED END OF FALLOPIAN TUBE

With the insufflation apparatus in place the abdominal cavity is opened.

FIGURE 1. The uterus is placed on traction. The tube is grasped with thumb and forefinger of the left hand over moist gauze. The tube is gently elevated and the clubbed end dissected from the posterior surface of ovary, broad ligament or bowel.

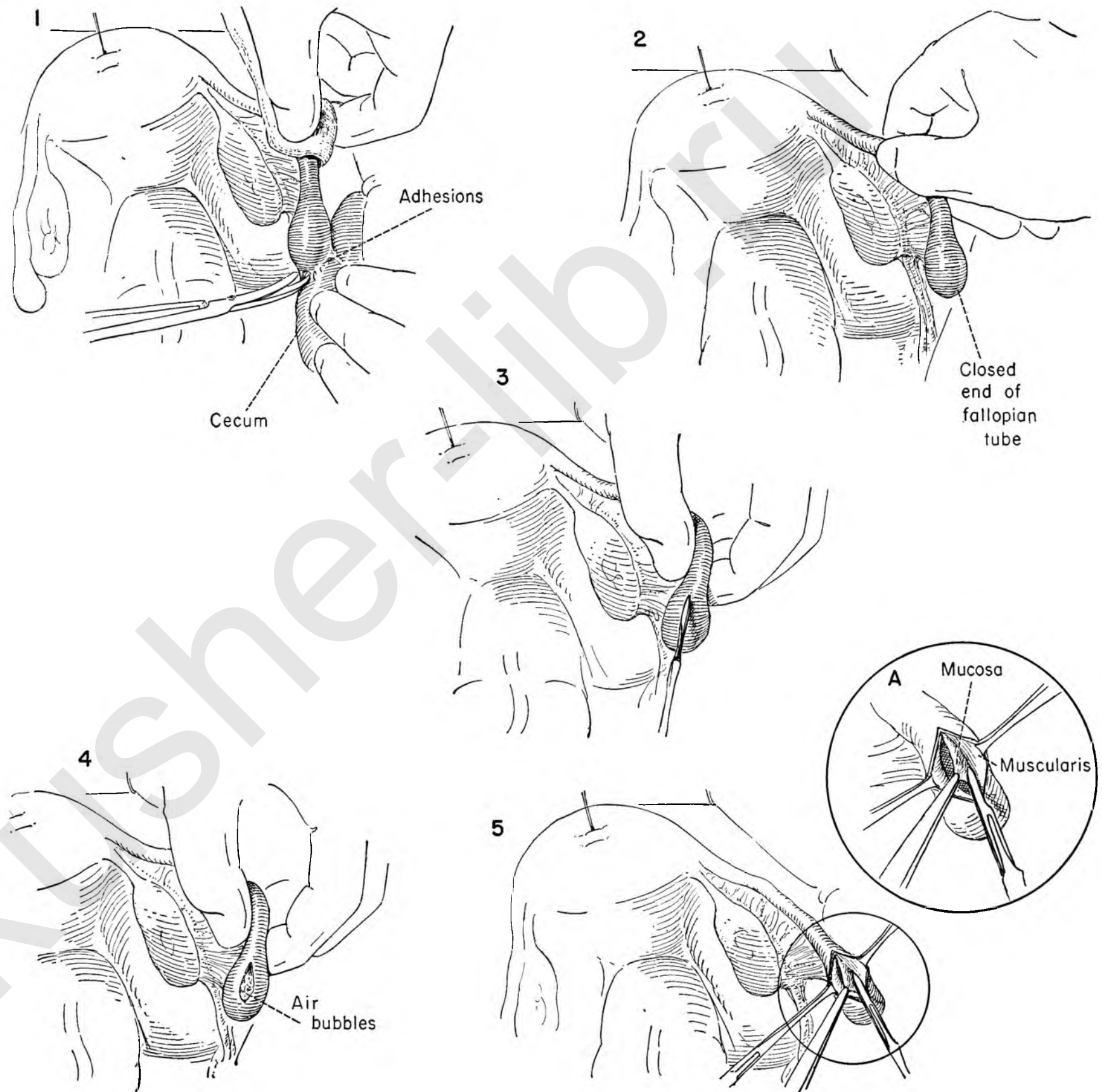
FIGURE 2. At this point the assistant is instructed to gradually inject air into the endometrial cavity. If the cornual end of the tube is open, air will appear in the tube. Its presence can be determined by seeing the tube distend, by hearing the air enter the tube and by feeling crepitus within.

FIGURE 3. With the patency of the main portion of the tube established the surgeon may reasonably attempt a plastic excision on the closed end. The tube is grasped between the thumb and forefinger of the left hand and the superior wall incised at the point of maximum crepitus.

FIGURE 4. The incision is carried into the lumen of the tube for approximately 2 cm. as the air escapes.

FIGURE 5. The serosal edge is gently held back with Allis forceps and the mucosa carefully dissected free from the muscularis of the tube over a distance of about 6 mm.

INSET A. The details of this step. Note the use of the small knife blade.



The following illustrations indicate the method of bringing the tubal mucosa out over the edges of the incision in the tube to create a new orifice and completely bury the cut edge of serosa. This reduces the likelihood of subsequent sealing off of the opening.

FIGURE 6. The upper end of the incised opening in the tube is held by Allis forceps while the assistant applies countertraction to the clubbed end of the tube. The reconstruction is begun by introducing a fine atraumatic catgut suture into the mucosa of the tubal opening at the uterine end.

FIGURE 7. The serosal surface of the tube is picked up just beyond the incised edge with the same stitch. Tying of the suture rolls the mucosa out over the cut edge of the tubal opening.

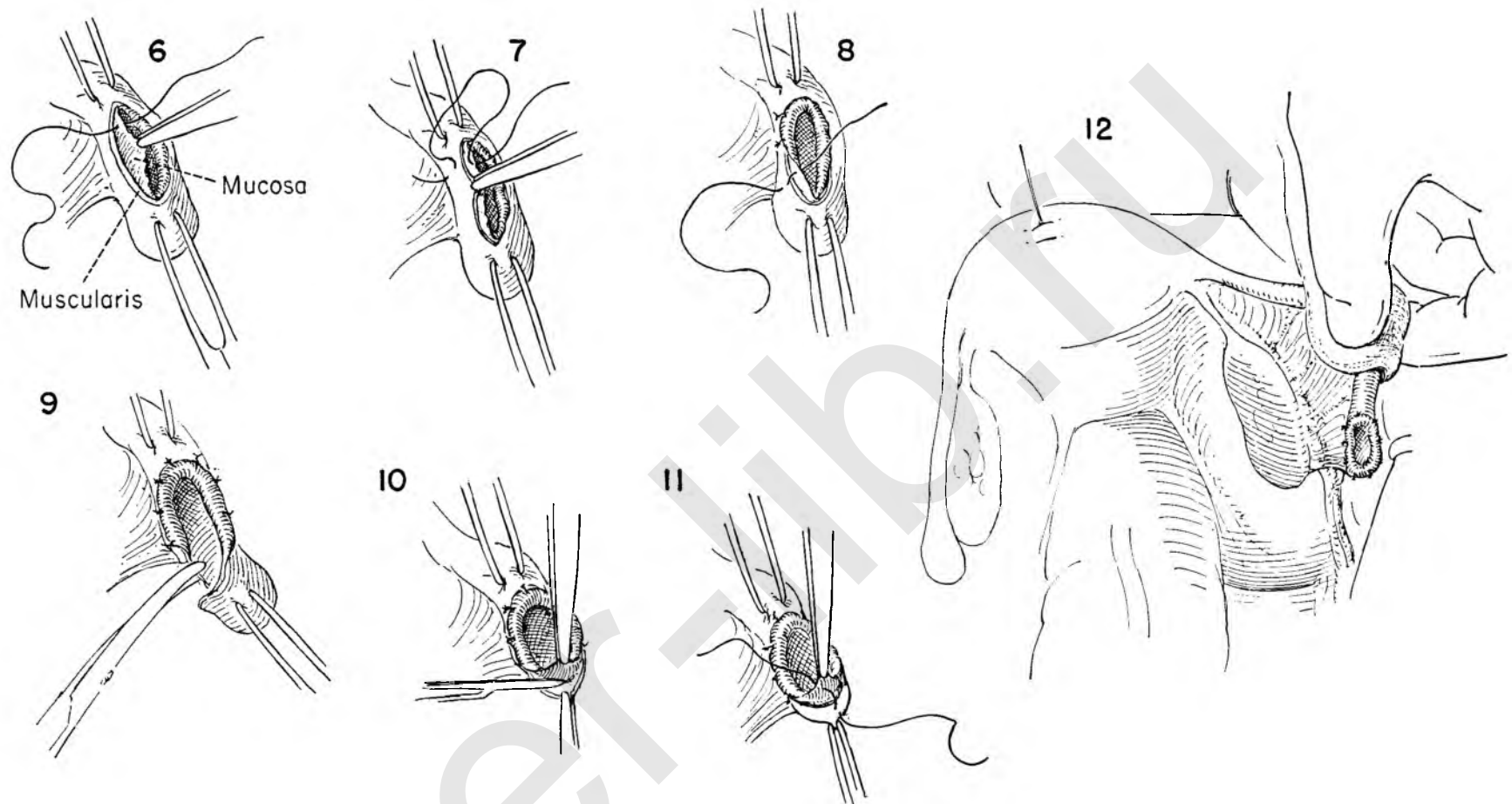
FIGURE 8. This stitch is tied, and further interrupted sutures of similar nature are placed approximately 5 mm. apart, working toward the clubbed end of the tube.

FIGURE 9. The scarred, occluded clubbed end of the tube is then amputated.

FIGURE 10. The mucosa is gently fixed posteriorly.

FIGURE 11. Identical everting sutures are continued around the full circumference.

FIGURE 12. The completed reconstruction.



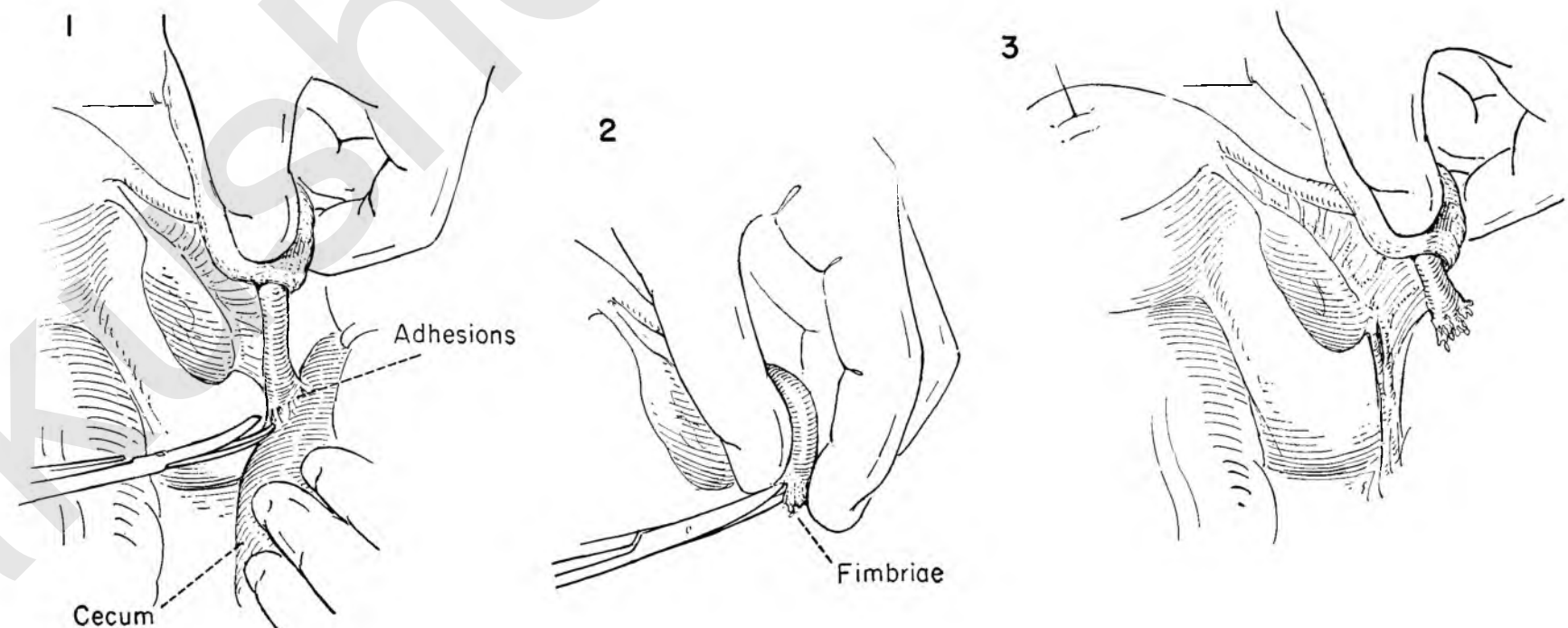
Dissection Plastic

In the initial freeing up of the tube it may be possible to dissect the fimbria free of attachments without doing irreparable damage. The obstruction may be due to the adhesion of the tube to surrounding structures as the result of perisalpingitis, and not to actual destruction of the fimbriated end.

FIGURE 1. Traction is applied to the tube with the thumb and forefinger of the left hand over moist gauze. The adhesions around the tubal end are freed by careful scissor dissection.

FIGURE 2. The fimbriae are gently teased apart. If patency seems established by this procedure, it may be checked by having an assistant introduce air through the cervical cannula.

FIGURE 3. The tube is gently replaced in its normal position. Any raw peritoneal surfaces must be covered to minimize the likelihood of the adhesions re-forming.



CORNUAL RESECTION OF TUBE

The cornual end of the fallopian tube may become obstructed as the result of previous pelvic inflammatory disease and be the sole cause in the problem of sterility. Resection of the obstructed portion of the tube with reimplantation of the normal portion into the endometrial cavity may have a limited place in the correction of this pathological state.

FIGURE 1. The uterus is placed on traction. The fimbriated end of the tube is gently held between thumb and forefinger. The blunt point of a glass Asepto syringe filled with saline solution is inserted into the open end of the tube. The glass tip is held in place with the thumb and forefinger of the left hand. Saline solution is injected into the tube slowly and evenly. The tube can be seen slowly dilating above the point of obstruction at the uterine end. The presence of the obstruction is thus confirmed.

FIGURE 2. The tube is ligated just beyond the point of obstruction. A traction stitch is placed in the wall of the tube to be anastomosed, and the tube is transected cleanly.

FIGURE 3. The obstructed segment is freed from its mesentery between clamps.

FIGURE 4. The isthmus portion of the tube is excised from the uterine wall, and the endometrial cavity entered.

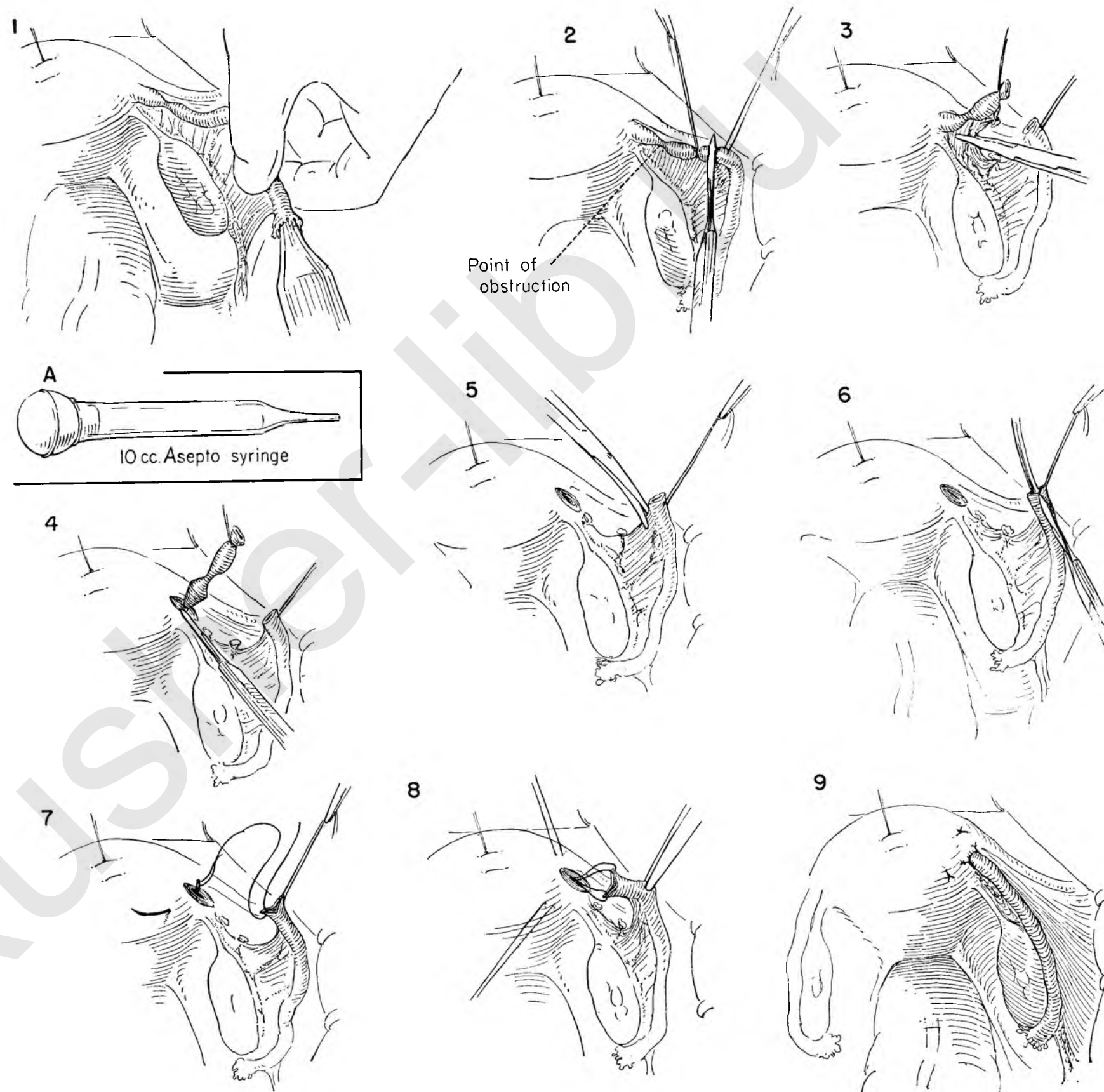
FIGURE 5. The blood supply in the mesentery of the tube is visualized and avoided as the tube is freed for a distance of about $\frac{1}{8}$ inch.

FIGURE 6. A grooved director is placed in the lumen of the tube, and longitudinal incisions are made along the superior and inferior borders in order to fish-mouth the lumen, to provide a larger opening.

FIGURE 7. A double zero chromic catgut suture is passed through each lip and the long ends brought out from the endometrial cavity as mattress sutures, one on either side of the cornual opening and about $\frac{1}{2}$ inch away.

FIGURE 8. Gentle traction is exerted equally on the mattress sutures, and the tube guided with forceps until it passes into the uterine cavity.

FIGURE 9. The sutures are tied and additional fixation provided by a few interrupted sutures between the wall of the tube and the uterine muscle. The patency of the tube should be checked on completion of the plastic procedure by injecting saline solution into the endometrial cavity.



Operations Involving the Intestine

A section on intestinal surgery has been included in this Atlas for two reasons: (1) Inadvertent damage to the bowel may occur during the course of any pelvic operation and must be treated without delay. (2) Coexistent diseases in the pelvis and in the intestine may be discovered without previous warning. They may arise as separate disease entities or as the result of extension of primary disease from one to the other. If they are separate lesions, one may elect to treat only one condition at a time; but if a single disease process involves both systems, individualized treatment may not be possible.

As a general rule, the bowel heals readily. Serosa agglutinates firmly to serosa in a few hours, and one needs only to be certain that peritoneal surfaces of the intestine have been approximated in a way that will permit this process to proceed without the intestine being subjected to distention or distraction. This means that intestinal suture lines cannot be left on tension, that a free passage through the bowel is maintained at all times, and that the technical procedure brings together adequate surfaces of serosa on either side. As in all surgery, the blood supply to the healing area is a vital factor. Any step which may interfere even slightly with the circulation, such as the application of rubber-covered clamps, should be carried out with care and dispatch; the compression should be released at the earliest possible moment.

Close attention to the niceties of technique will always be rewarding, and many surgeons favor the use of light instruments and fine, nonabsorbable suture material because rough handling is almost impossible under these circumstances. There is no conclusive evidence that any one suture is better than the rest, nor is this likely ever to be so. The method presented in this section is that of a two-layer closure with an inner row of running catgut and an outer one of interrupted silk.

No attempt has been made to cover even a small segment of the field of intestinal surgery. The operations described are those which might be indicated for the repair of damage or the removal of disease encountered during the course of pelvic laparotomy. In some cases the procedures offer complete definitive treatment; in others they are first-stage operations designed to relieve symptoms and simplify subsequent surgery. The choice remains as always the responsibility of the surgeon in the operating room. It can be decided only after due consideration of the local findings, the patient's condition and the surgeon's estimate of what is safest in his own hands.

REPAIR OF DAMAGE TO SMALL BOWEL

When a tear or perforation of the small bowel occurs, it is usually wisest to stop and repair the defect in the intestine as soon as the injury is recognized. Shallow breaks in the serosa alone are probably harmless, but if there is doubt, it is

always best to suture them. The smaller tears or perforations may be closed by a simple purse-string suture. A larger rent in the small bowel cannot be closed in this fashion. It is best to convert the longitudinal tear into a transverse defect. Closure will then take place without altering the caliber of the bowel lumen. Whenever the lumen has been entered, a meticulous closure is mandatory.

MECKEL'S DIVERTICULUM

Excision of an asymptomatic diverticulum discovered incidentally during laparotomy borders dangerously close to meddlesome surgery. Occasionally it may suggest the probability of future trouble, and rarely it will prove to be the source of symptoms thought to be pelvic in origin. In this case excision is indicated and should follow the general principle of complete removal with careful closure in a manner that will not constrict the bowel.

ENTEROENTEROSTOMY

This simple method of short-circuiting the intestinal flow offers the easiest solution to the problem of obstruction in the small bowel. It is particularly useful when palliation only is being sought or when resection of the lesion is not essential for cure. Every basic principle of intestinal surgery is brought into play and the method of two-layer closure illustrated.

RESECTION WITH SIDE-TO-SIDE ANASTOMOSIS

If there is much distention or disproportion in size between the two resected loops of small bowel, the surgeon may do well to close the ends of the two sections of bowel and perform an enteroenterostomy. The actual opening in the two loops of bowel should be made close to the closed ends in order not to leave a blind pocket. The resulting stoma is large and unlikely to constrict. This type of anastomosis, though it takes longer to perform because of the added number of suture lines, is perhaps the safest method of reconstituting the intestinal canal after removal of a full segment. It will probably be first choice whenever there is doubt about success with end-to-end suture.

RESECTION AND END-TO-END ANASTOMOSIS

When accidental damage to the small bowel is extensive, it is not advisable to attempt to close the defect by simple suture. Resection is indicated. Likewise bowel which, through disease, cannot be disassociated from attached structures may have to be resected. If the distention is not too great, an end-to-end suture provides an effective and quick anastomosis.

The surgeon must take particular notice of the blood

supply to the cut ends of the bowel before the anastomosis is begun. The method of suture is planned to avoid the risk of decreasing the caliber of the bowel, but this hazard must be kept in mind at all times, and the final check before the intestine is replaced in the abdomen is to determine the size and patency of the stoma.

Properly done, this operation gives a great sense of satisfaction. The normal architecture is so successfully restored that examination of the site in subsequent years may fail to show evidence of any previous surgery at all.

ILEOTRANSVERSE COLOSTOMY

Though it is often possible to resect the ascending colon and perform ileocolostomy at one stage, the two-stage procedure has much to recommend it. If an extensive operation is to be performed in the pelvis, it would certainly be good judgment to complete this, perform an ileocolostomy, and leave the resection of the right colon for a later date.

LARGE BOWEL RESECTION AND END-TO-END ANASTOMOSIS

If the sigmoid has been extensively damaged or implicated in a disease process, the involved segment should be isolated and resected between clamps. Closure is accomplished by end-to-end suture. An open anastomosis is unlikely to stricture or obstruct; with care and appropriate chemotherapy the incidence of septic complications can be kept low. A colostomy proximal to the anastomosis offers the maximum protection to the patient in this situation.

COLOSTOMY AND CLOSURE

This rapid and simple operation affords relief for symptoms due to large bowel obstruction when the obstructing mechanism is not removed. It is also useful as a means of putting the bowel beyond it at rest and providing optimum conditions for the subsidence of inflammation or for surgical healing. Only the anterior circumference of the bowel needs to be opened for adequate function, and this may facilitate subsequent closure. If decompression is desired for a long time, a bridge of skin is fashioned and sutured under the loop and the full thickness of bowel eventually cut across.

Closure of the colostomy should be done according to the general principles applied to other intestinal operations. The most common error in this procedure is failure to develop the loop to the point of free mobility.

APPENDECTOMY

This simple method for the removal of the appendix has stood the test of repeated use. Other methods are undoubtedly equally rapid and effective.

REPAIR OF INJURED SMALL BOWEL

Successful repair of injured small bowel will usually follow if the damage is recognized early and a watertight closure is accomplished without narrowing the intestinal canal.

FIGURE 1. When the rent is small, a purse-string suture is laid in place around it. Care must be used to avoid entering the bowel cavity.

FIGURE 2. The suture is drawn and tied. A second stitch around the first can be depended upon to keep the closure tight until healed.

This method should be abandoned at once if it produces appreciable narrowing of the bowel.

REPAIR OF A LARGER RENT

FIGURE 1. To avoid narrowing of the lumen in closing a larger tear, the suture line should cross the bowel at right angles to the long axis. A longitudinal laceration is converted into a transverse one by traction on Allis clamps placed on the edges of the opening.

FIGURE 2. An atraumatic, fine chromic catgut suture is started at one end, including all layers, and placed and tied just beyond the opening to be closed.

FIGURE 3. A straight snap grasps the short end of the stitch.

FIGURE 4. The suture is continued in simple over-and-over fashion.

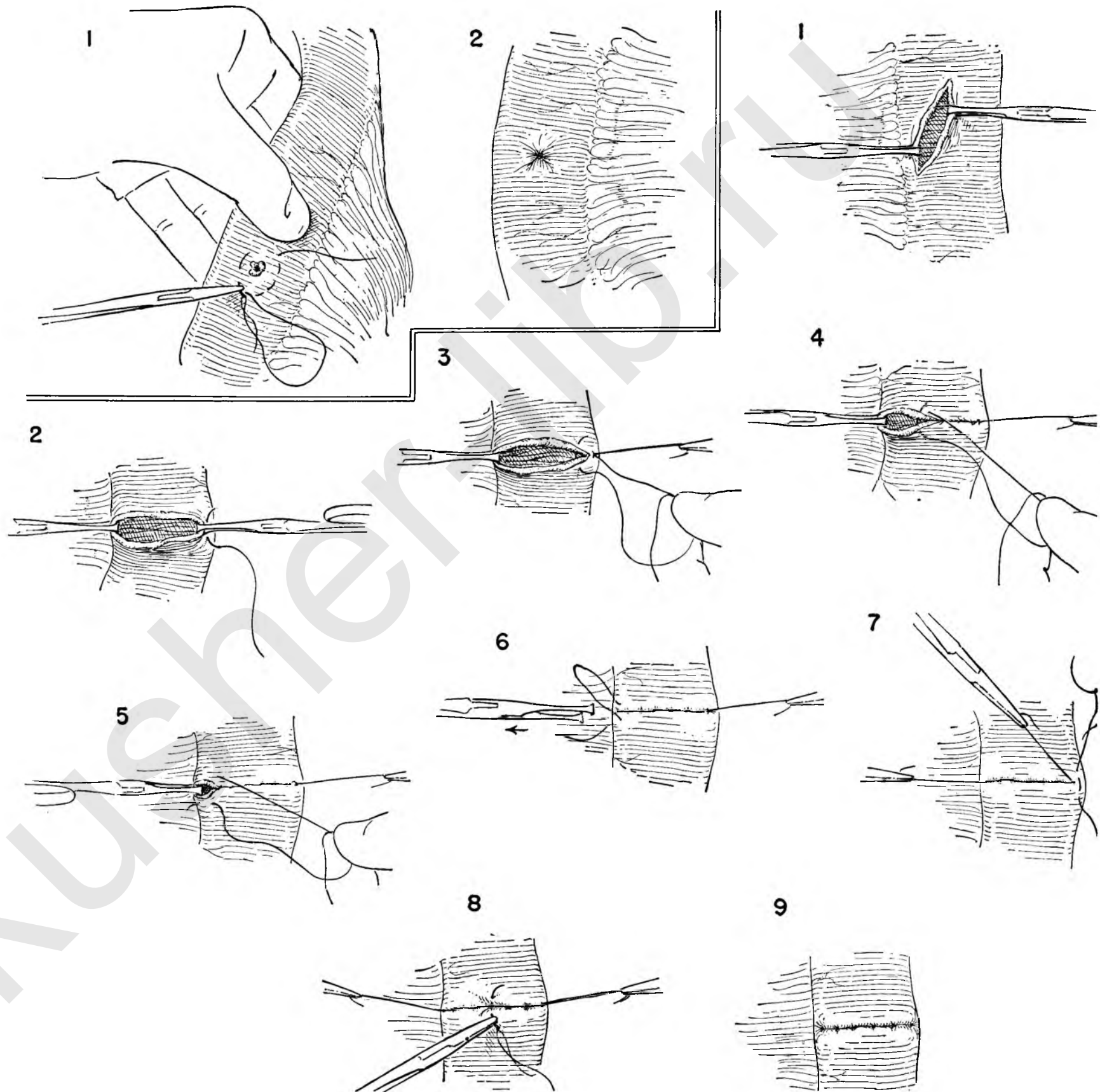
FIGURE 5. At the lower end, one final stitch is placed to lie entirely on one side of the rent and just beyond the opening.

FIGURE 6. The loop and free end of the suture are tied together and the Allis clamp removed as this is done.

FIGURE 7. A straight snap on one end of this suture is kept on tension to steady the bowel, and a series of vertical silk or cotton mattress stitches is started. The first is carefully placed to lie just beyond the end of the inner suture line.

FIGURE 8. The first silk tie is kept long and the end of catgut cut off at the knot. Each subsequent mattress stitch is carefully placed and tied to approximate two narrow serosal surfaces without cutting through.

FIGURE 9. This shows the completed closure.



EXCISION OF MECKEL'S DIVERTICULUM

Occasionally these pouches are lined with gastric epithelium which is sufficiently active to secrete ferments and produce ulceration of the bowel. If it is elected to remove this congenital anomaly, one must be certain that none of its mucosa is left behind.

FIGURE 1. The diverticulum arises in the ileum within 2 feet of the ileocecal valve on the side directly opposite the mesenteric attachment. Vessels in the mesentery of the diverticulum should be freed from the bowel near the base by blunt dissection with the tip of a hemostat, and doubly clamped.

FIGURE 2. The vessels are cut and secured with fine ties.

FIGURE 3. The diverticulum is held on tension by traction on an Allis clamp applied to the blind end and two light Kocher clamps placed across the base, making certain that the lower one is flush with the bowel.

FIGURE 4. Moist gauze is laid across the field beneath the clamps, and the bowel cut across with the cautery.

FIGURE 5. The Kocher clamp is removed, and Allis clamps are applied to the full thickness of the cut edge of bowel on either side.

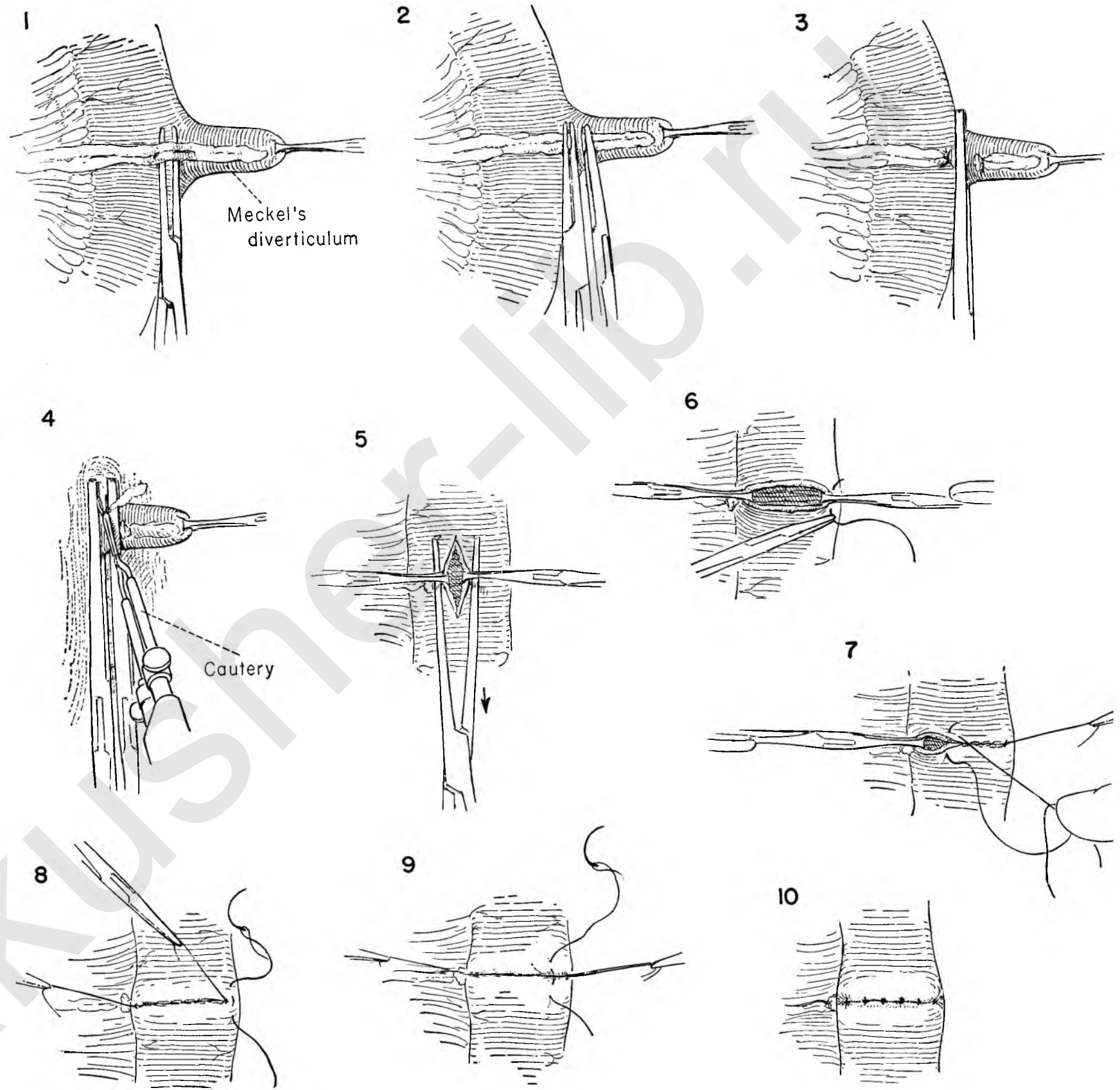
FIGURE 6. By traction, this longitudinal opening is converted into a transverse one, and closure is effected by the method illustrated in detail on Plate 50.

FIGURE 7. An inner row of running catgut is secured at one end and carried to the other, completely closing the opening in the gut.

FIGURE 8. The snap on the long end of this suture is held towards himself by the surgeon, and the first mattress stitch of silk is carefully placed a little beyond it. The catgut is cut and a snap placed on the ends of the silk tie to maintain traction.

FIGURE 9. The outer row of interrupted fine silk stitches is continued to ensure approximation of an adequate serosal surface and bury the first suture line.

FIGURE 10. This shows the completed closure, watertight and with no tendency to narrow the bowel.



ENTEROENTEROSTOMY (SIDE-TO-SIDE)

The simplest procedure available for the relief of symptoms due to a point of obstruction in small bowel is the enteroenterostomy.

FIGURE 1. The loops selected for anastomosis are brought out of the incision. A rubber-shod clamp is applied, the gas and liquid contents expressed from the segment selected for operation, and the clamp closed just tightly enough to prevent reflux.

FIGURE 2. The two selected loops are brought to lie comfortably side by side and the entire field protected with moist gauze, including a strip beneath the loops of bowel themselves.

FIGURE 3. The rubber-covered clamps afford an easy means of holding the bowel in any position desired. Here the first assistant approximates them carefully as the surgeon prepares to join them with the first posterior row of sutures.

FIGURE 4. This is composed of a series of interrupted mattress stitches of fine silk or cotton. Each is tied and cut at once except for the first, which is held long in a hemostat. This suture line is to lie parallel to the long axis of the bowel, but with a calculated drift at either end which will result in a long ellipse, with the stoma in the center of it and just opposite the point of mesenteric attachment. The last stitch is tied and left long like the first.

FIGURE 5. The bowel is opened in two steps: first an incision with the scalpel parallel to the suture line and about 1 cm. from it. The serosa and muscularis cut easily and retract, allowing the mucosa to bulge slightly.

FIGURE 6. As soon as the mucosa is opened, it collapses, and further incision is best made with scissors. An opening 2 inches or more in length is made in each loop.

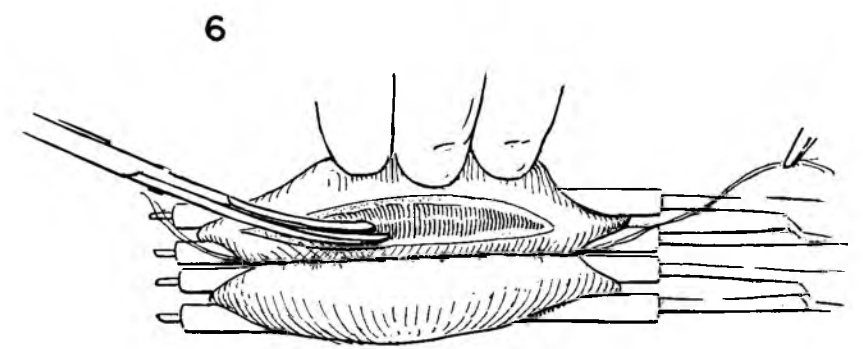
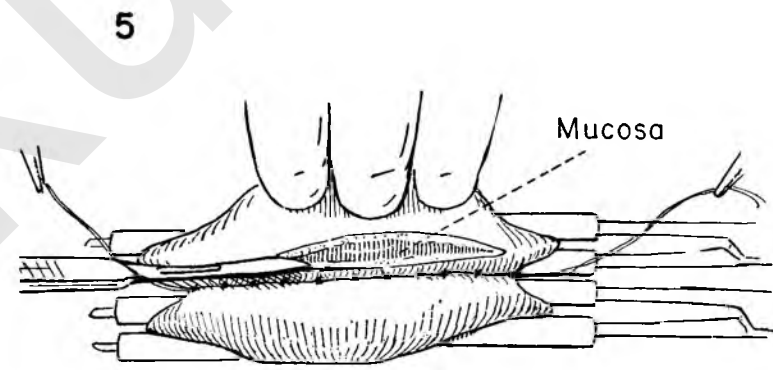
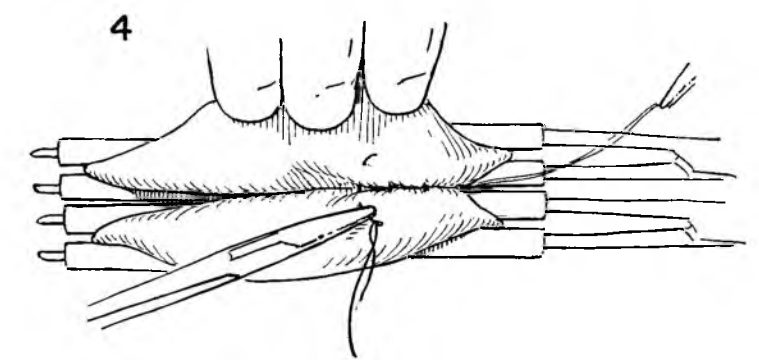
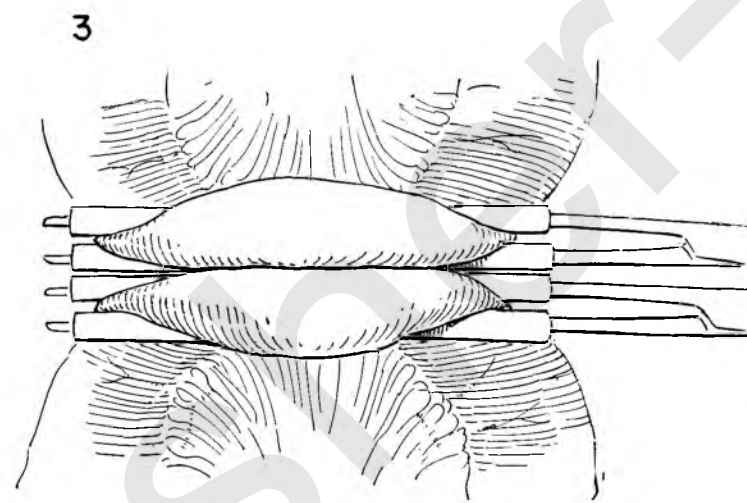
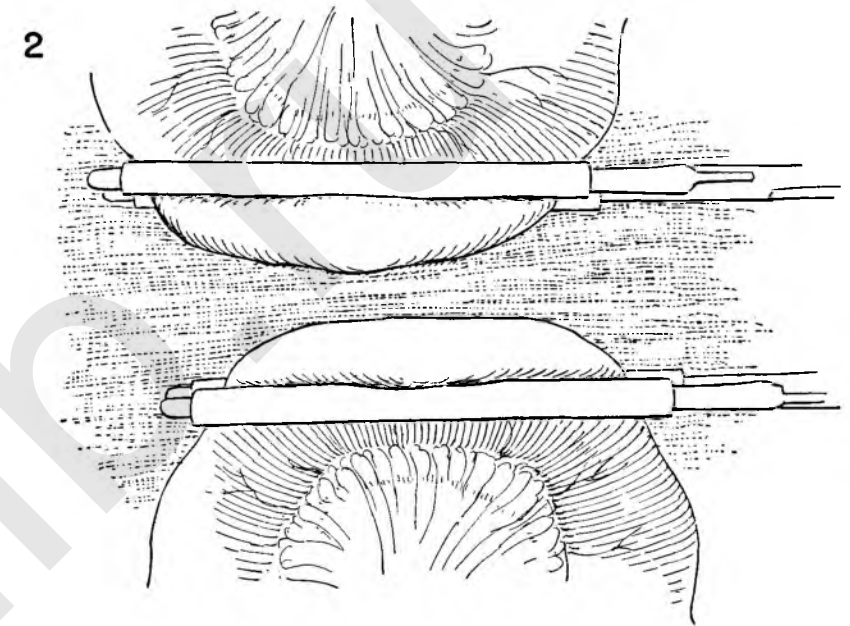
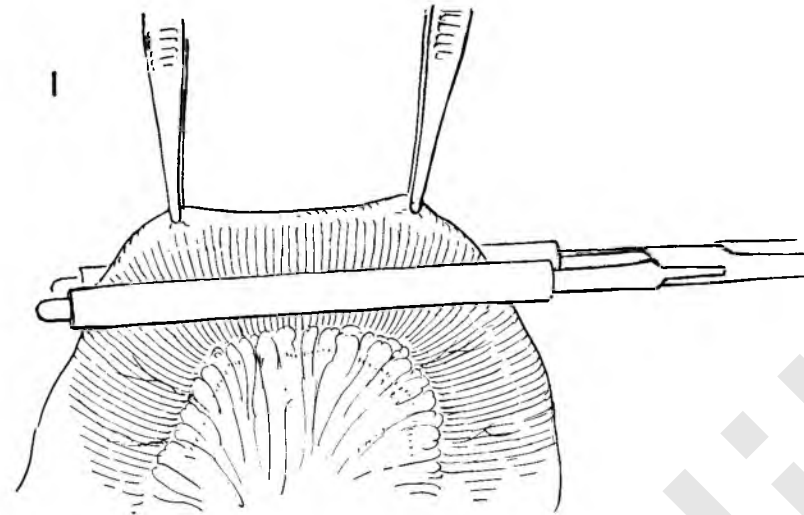


FIGURE 7. The full thickness of bowel wall around these openings is now approximated with a running suture of fine catgut on an atraumatic needle. Turning the corners presents the only technical problem; therefore the suture is started at the center point posteriorly.

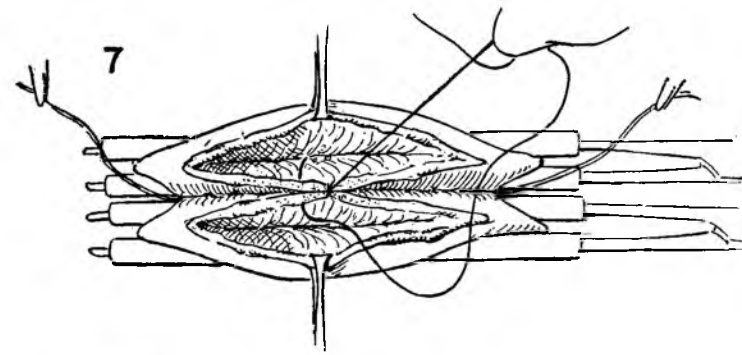


FIGURE 8. As the corner is reached, the stitch is carried out on the serosal surface at a point just beyond the angle and definitely on the anterior surface.

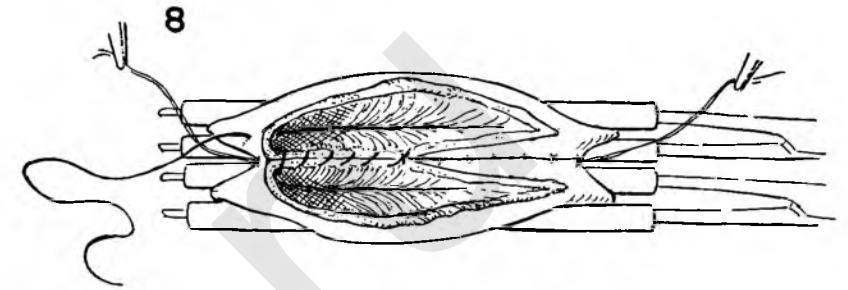


FIGURE 9. The Connell method is used to continue closure along the anterior aspect of the stoma. Each bite of the stitch is taken from the serosal side and includes the full thickness of bowel close to the edge of the opening.

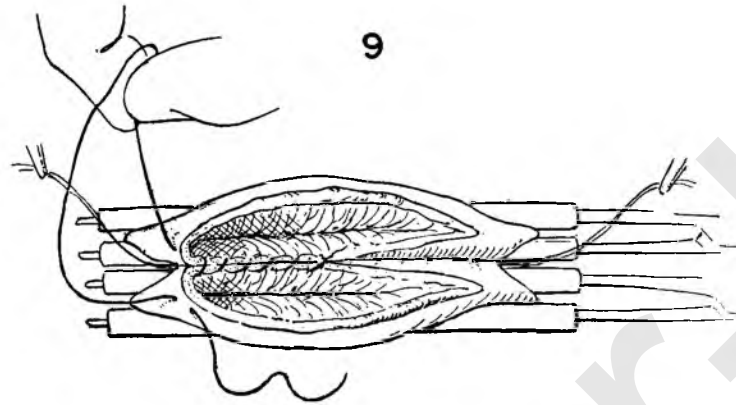


FIGURE 10. By moving alternately from one side to the other, one brings the serosal surfaces of bowel neatly together.

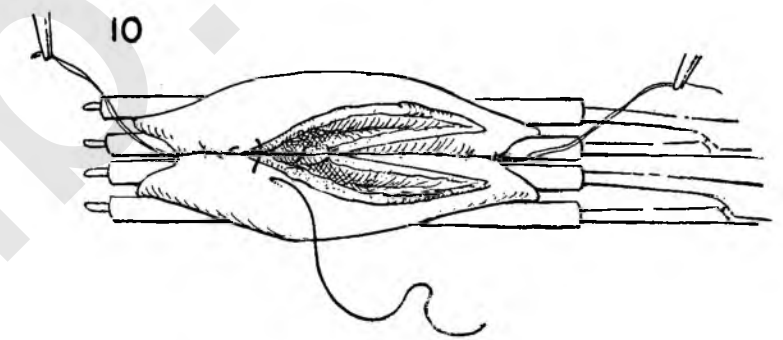


FIGURE 11. This suture is discontinued as the center point is reached and held on tension to maintain approximation of the bowel. A second stitch is begun at the posterior midline and carried around the opposite corner and back along the anterior edge of the stoma exactly as was its predecessor.

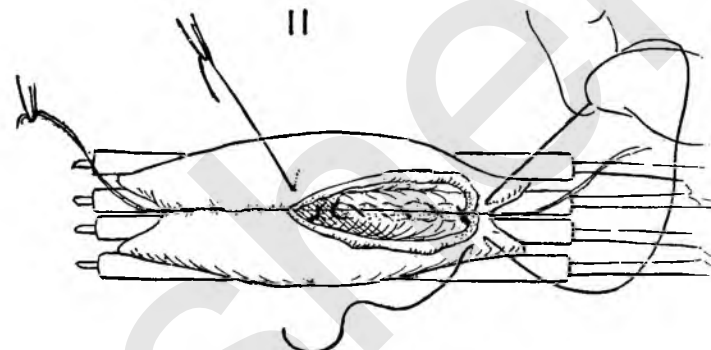


FIGURE 12. This row is calculated to end just opposite the other. The two free ends are tied, completing the inside suture.


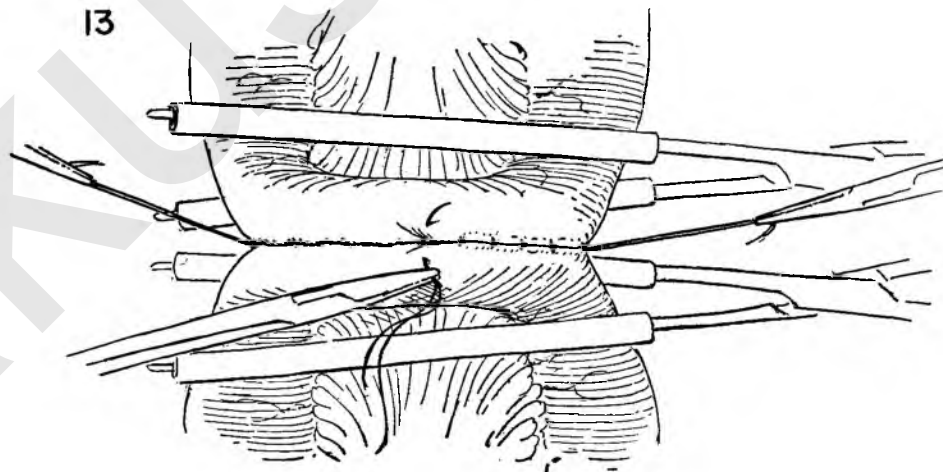
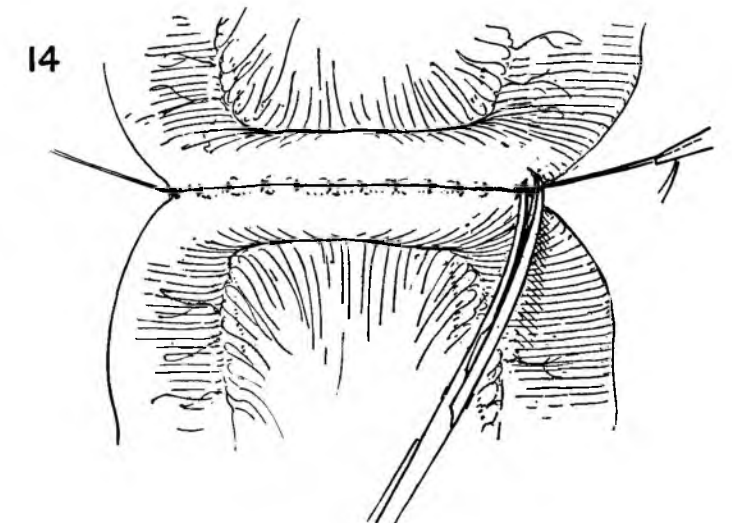


FIGURE 13. The rubber-shod clamps can be released now without fear of spillage. Since they inevitably interfere with the circulation, they should be loosened, and removed at the earliest possible moment.



The outside row of interrupted silk sutures is completed with fine mattress stitches approximately 0.5 cm. apart. The bowel is easily held steady by the assistant if he makes traction on the two end silks which were left long from the first posterior row.

FIGURE 14. This shows the completed anastomosis just before the corner stitches are cut.



RESECTION OF SMALL BOWEL AND SIDE-TO-SIDE ANASTOMOSIS

Actual removal of a segment of small intestine may be elected in a great variety of circumstances. The most common are extensive damage to the gut, devascularization during the course of operation, or as the result of strangulation, and involvement in benign or malignant tumors.

When there is obvious discrepancy in the caliber of the two segments of bowel to be united, the lateral type of anastomosis is eminently suitable. This method permits establishment of a large stoma, and carries the lowest risk of subsequent anastomotic obstruction. It takes longer to perform, for obvious reasons, but is probably the safest procedure available whenever anastomosis of bowel is necessary.

This page illustrates in detail the technique of isolating and resecting a loop of bowel. It is first delivered into the wound, all other structures protected with gauze, and the segment outlined for removal.

FIGURE 1. The surgeon supports bowel and mesentery with the fingers of the left hand and opens the peritoneum with scissors close to the bowel and at a point where no vessels can be seen.

FIGURE 2. This opening is carried to the bowel wall, clamping and cutting mesenteric vessels as they are encountered.

FIGURE 3. These bites are secured with stitch ligatures.

FIGURE 4. The wedge of mesentery to be removed is completely freed between clamps, which are replaced by ligatures before the next maneuver is begun.

FIGURE 5. Kocher clamps are now applied to the bowel in pairs, exactly at the sites where the mesentery has been opened. An effort should be made to distribute bowel evenly across the jaw of the clamp with the teeth at the end well beyond the intestinal wall and exactly in line with the plane of the mesentery.

FIGURE 6. The normal bowel is carefully covered with moist gauze and a cautery used to transect the intestine, flush with the edge of the clamp. A similar procedure at the other site completes the removal of the segment of bowel.

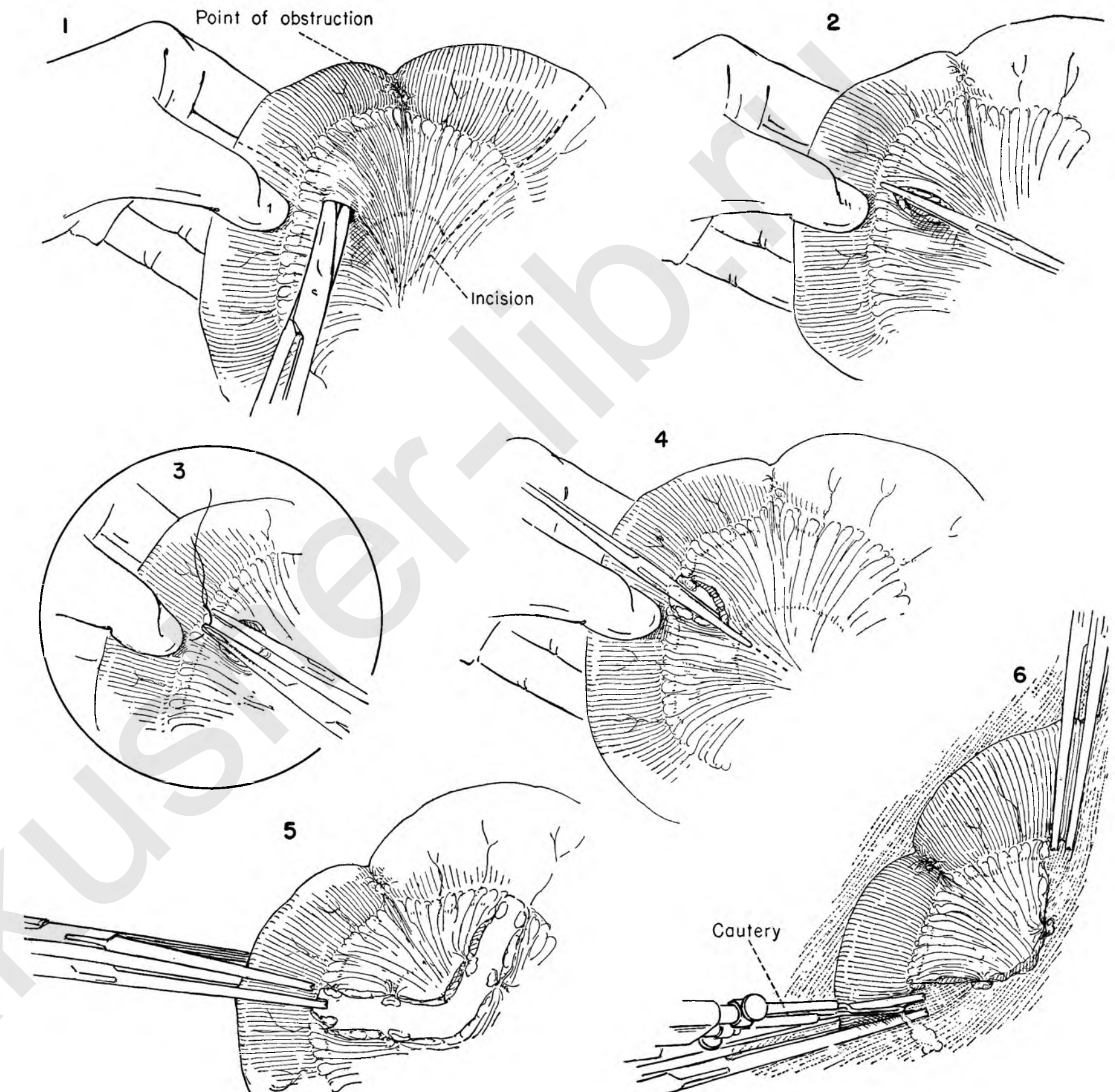


FIGURE 7. Before the anastomosis is begun, the two ends of the bowel are closed. A running catgut suture on an atraumatic needle starts at one end, and bites are placed alternately in the bowel wall on either side of the Kocher clamp.

FIGURE 8. When this row is complete, a gentle pull is applied to the two ends in the same axis as the clamp, and the clamp opened and withdrawn. The tension on the suture should bring the opposing bowel serosal surfaces together.

FIGURE 9. The stitch is carried back as a second running row just outside the first and tied to the free end when it reaches it.

FIGURE 10. An outside row of interrupted silk or cotton mattress sutures is used to reinforce the closure. Both limbs of intestine are handled in identical fashion.

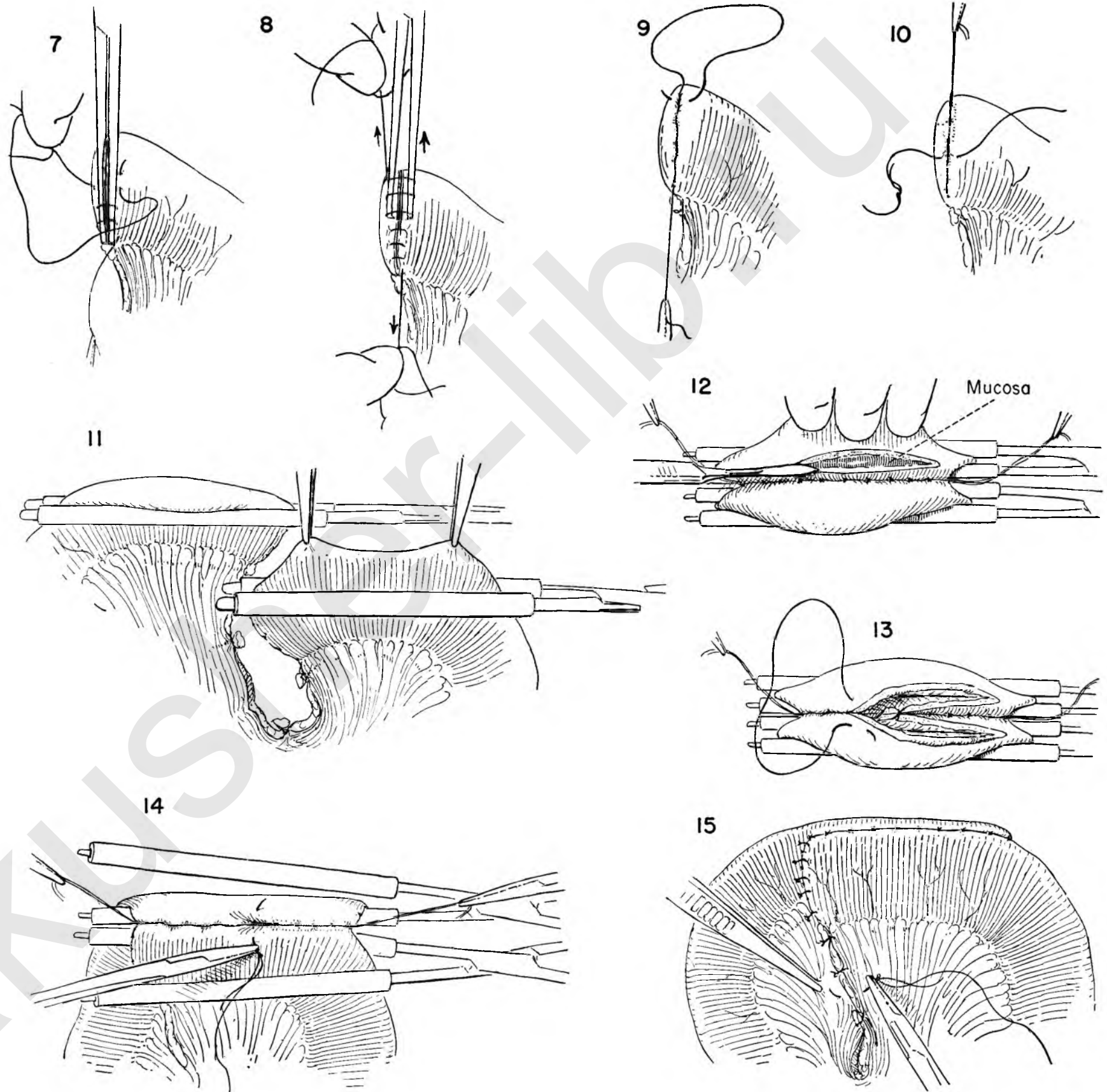
FIGURE 11. The side-to-side anastomosis proceeds as shown in Plates 52 and 53. Rubber-covered clamps prevent spillage of intestinal content while the bowel is open. The stoma is carefully placed close to the turned-in ends of bowel to leave no blind pouches. The two loops are brought together in such fashion that the closed ends are not adjacent, and the cut edges of mesentery overlap slightly.

FIGURE 12. The first posterior row of interrupted silk mattress stitches has been completed, and the bowel is being opened.

FIGURE 13. An inner layer of closure is accomplished with a running over-and-over suture which starts at the posterior midpoint, turns the corner, and continues along the anterior edge of the stoma as a Connell stitch.

FIGURE 14. A similar stitch closes the right half. The rubber-shod clamps are loosened, and the final anterior row completed with interrupted silk. The assistant holds the bowel steady by supporting the end sutures.

FIGURE 15. Additional silk sutures approximate the leaves of the mesentery and close the hiatus where the bowel lies against bowel.



RESECTION OF SMALL BOWEL AND END-TO-END ANASTOMOSIS

The technical steps involved in the resection proceed in a manner identical with that illustrated on Plate 54. They are illustrated in condensed fashion in Figures 1, 2 and 3.

FIGURE 1. The bowel is delivered into the wound and steadied with the left hand, and an avascular spot in the mesentery is selected to begin the dissection.

FIGURE 2. With the mesentery completely freed and the vessels ligated, Kocher clamps are placed on the bowel.

FIGURE 3. All normal tissues are protected by wet gauze and the bowel transected with the cautery.

FIGURE 4. The two segments to be joined are held in close approximation by the assistant. The clamps are rotated slightly to expose the posterior bowel wall.

FIGURE 5. The first posterior row of sutures is in progress. The stitches should be placed as close to the clamp as possible and still permit their being tied without cutting through. Silk or cotton is usually used, and the first and last stitches are tied but not cut.

FIGURE 6. The bowel is steadied by holding up on these two sutures, and the Kocher clamps removed. Usually the crushing has been forceful enough to glue the two sides together, and it will be necessary, as in the illustration, to establish the lumen by applying and pulling on an Allis clamp.

INSET A. If there is dilatation of the intestine with danger of spill when the end is opened, it is advisable to exclude the area temporarily by means of rubber-covered clamps placed lightly across the bowel before the Kocher clamps are removed.

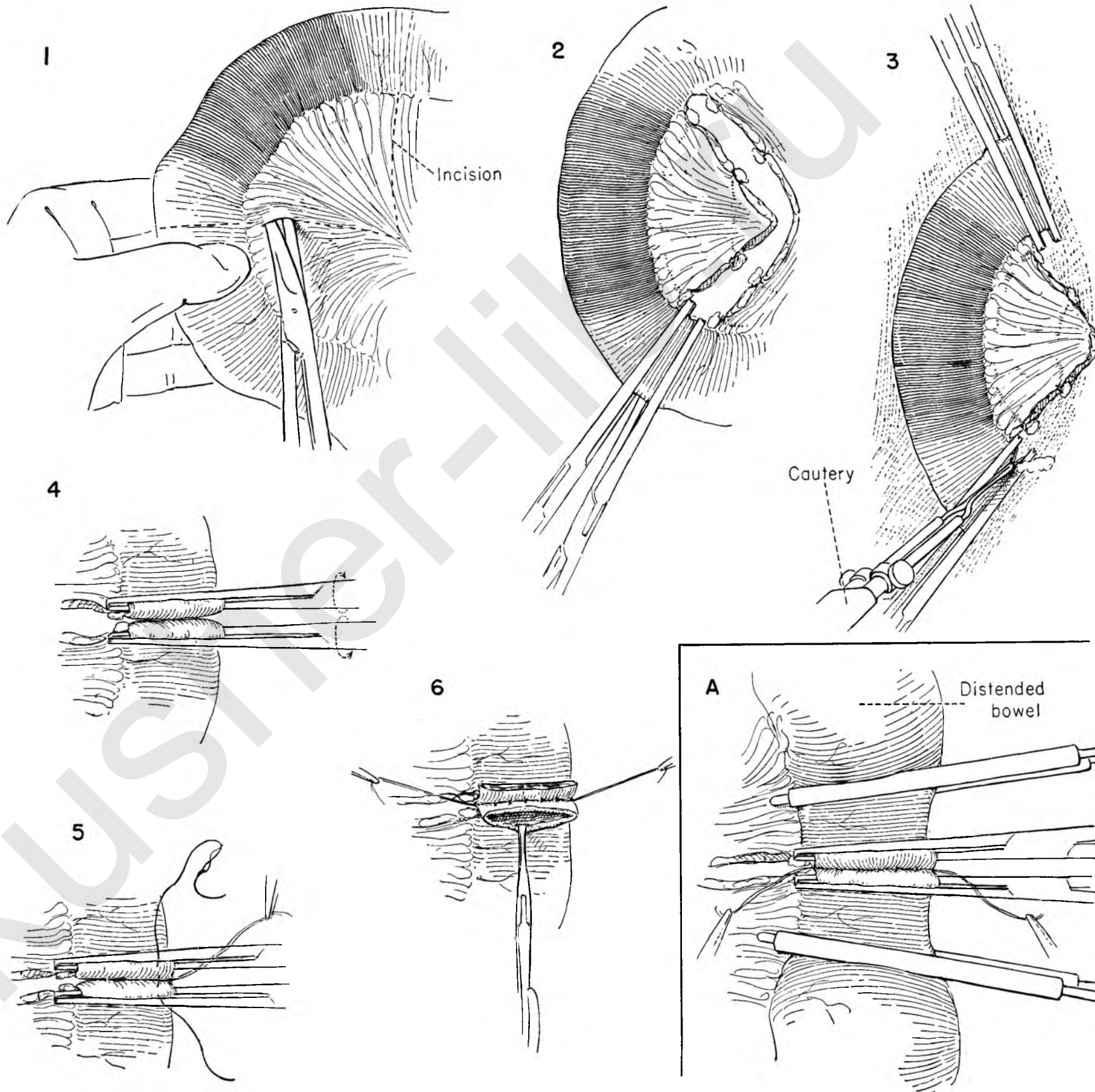


FIGURE 7. An inner row of running catgut is begun at the center of the lumen posteriorly. Double zero chromic catgut on a small atraumatic needle is customary.

FIGURE 8. The suture is carried as a simple over-and-over stitch until it starts around the corner. Here it is brought out through the peritoneal surface on one side or the other. This figure and Figures 9 and 10 have been enlarged to illustrate the details of this technique.

FIGURE 9. It then continues as a Connell suture, approximating the anterior cut edges of bowel, serosa to serosa, until the midpoint is reached. Here it is held on tension.

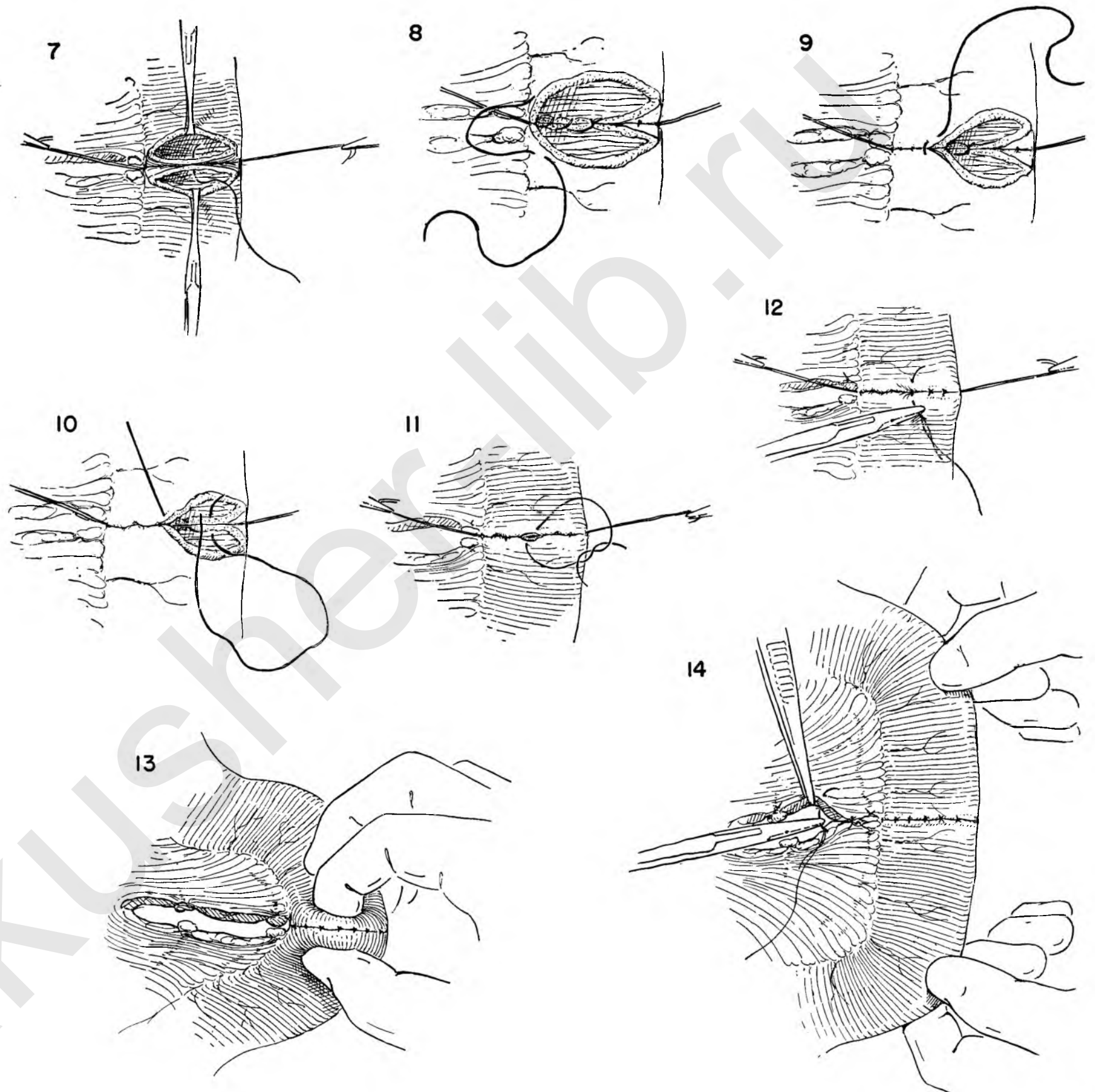
FIGURE 10. A new suture is now started in the center of the posterior edge and run in the opposite direction.

FIGURE 11. The suture is carried around the corner and continued as a Connell stitch anteriorly until it meets the previous suture. The two are tied together.

FIGURE 12. A second anterior row of interrupted silk mattress stitches completes the anastomosis.

FIGURE 13. It is well to check the size and patency of the stoma with the thumb and index finger, as illustrated.

FIGURE 14. As a final step, the opening in the mesentery is closed with interrupted silk sutures.



ILEOCOLOSTOMY

Obstruction in the right colon is best circumvented by anastomosis between the terminal ileum and the transverse colon. The procedure also lends itself readily to use as the first stage when resection of the right colon is contemplated and circumstances do not permit one to do the entire operation at the first sitting.

The short circuit can be accomplished by simple lateral anastomosis between the two segments of gut, but subsequent management of the case is usually made easier if complete defunctioning is secured.

FIGURE 1. The mesentery of the terminal ileum is opened at a selected point, in an area free of vessels.

FIGURE 2. This opening is enlarged by clamping and cutting the mesenteric vessels.

FIGURE 3. It is also further extended toward the root of the mesentery.

FIGURE 4. Kocher clamps are placed across the bowel, the area protected with moist packs, and the intestine cut across with the cautery.

FIGURE 5. The blind stump of ileum adjacent to the cecum is closed. First a continuous catgut suture is laid in place over the clamp.

FIGURE 6. This is drawn together as the clamp is removed and is then brought back as a continuous mattress suture and tied at the point where it started.

FIGURE 7. An outside row of interrupted silk completes the closure.

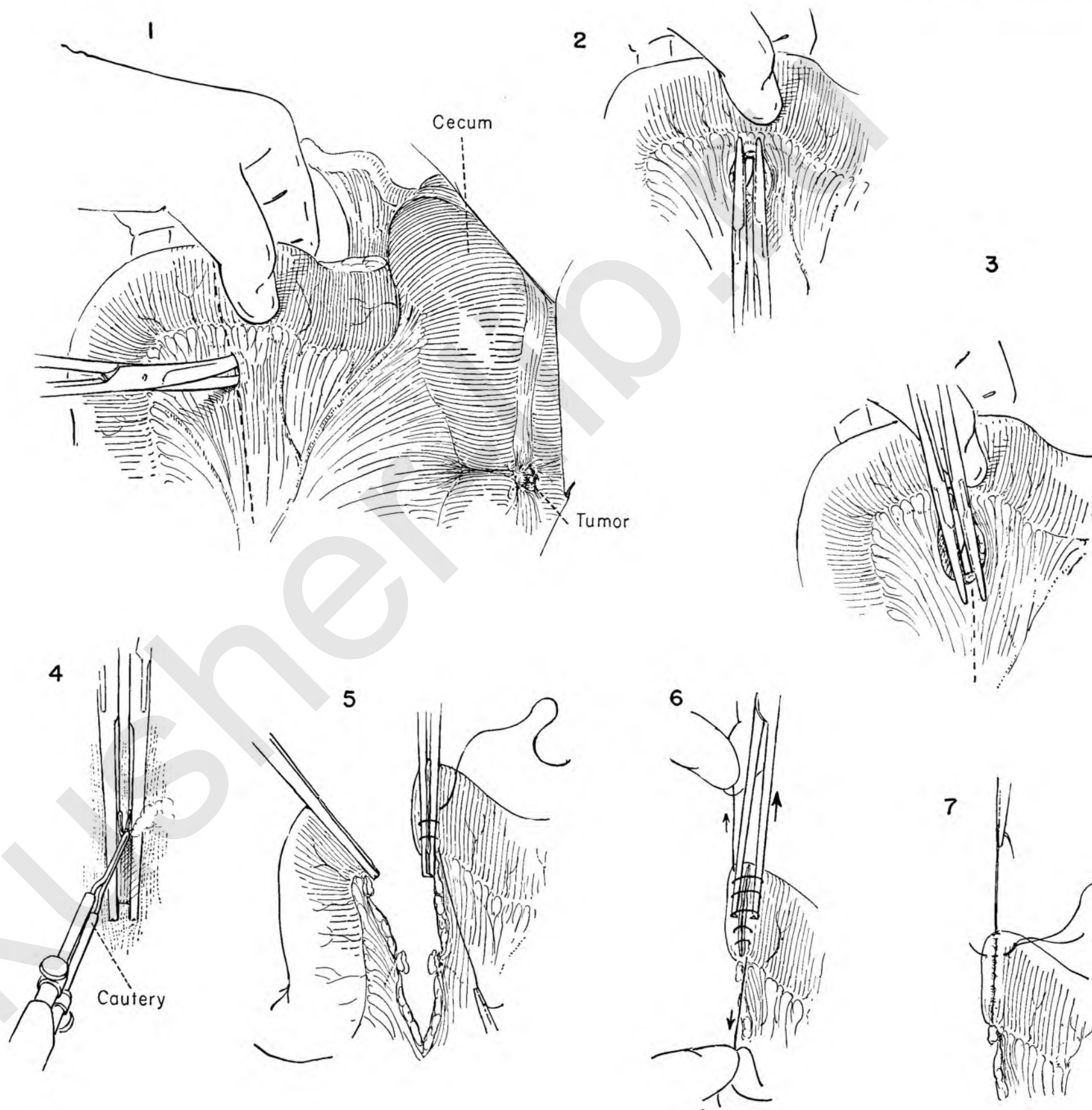


FIGURE 8. A point is selected on the transverse colon comfortably distal to the hepatic flexure, and the full thickness of bowel at a taenia is picked up with the Allis clamp. A Kocher clamp is applied across this fold of colon. The amount of tissue included should be the same size as the cut end of small intestine.

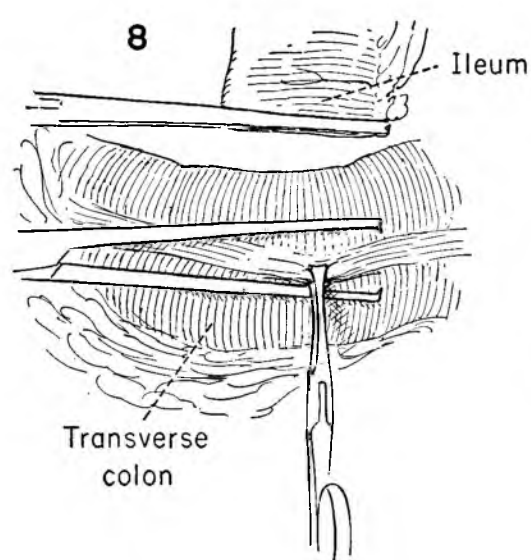


FIGURE 9. This knuckle is removed with the cautery. These precautions are particularly desirable in cases in which the procedure is unanticipated and the bowel not prepared.

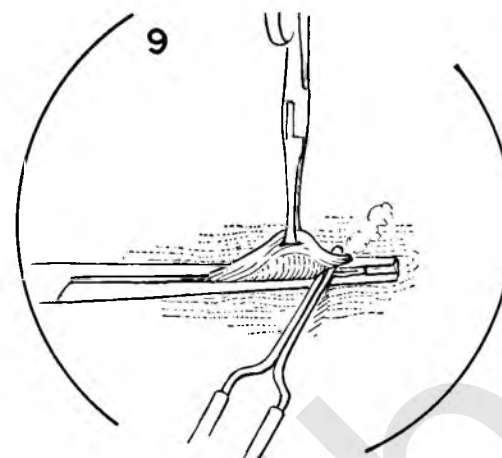


FIGURE 10. Anastomosis then proceeds in standard fashion, with a posterior row of interrupted silk or cotton as the first layer of closure.

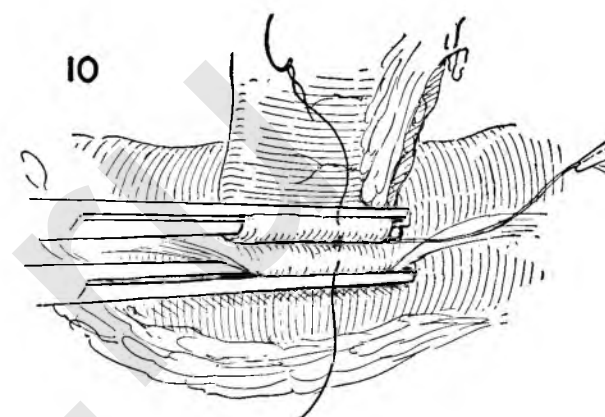


FIGURE 11. Before the Kocher clamps are removed, rubber-covered clamps are applied to prevent spillage of bowel content.

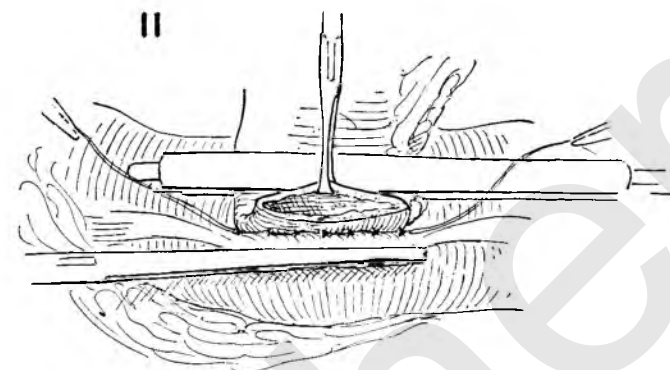


FIGURE 12. The opening in each segment of bowel is carefully demonstrated by holding the walls apart with Allis clamps, and the inner row of running catgut is started.

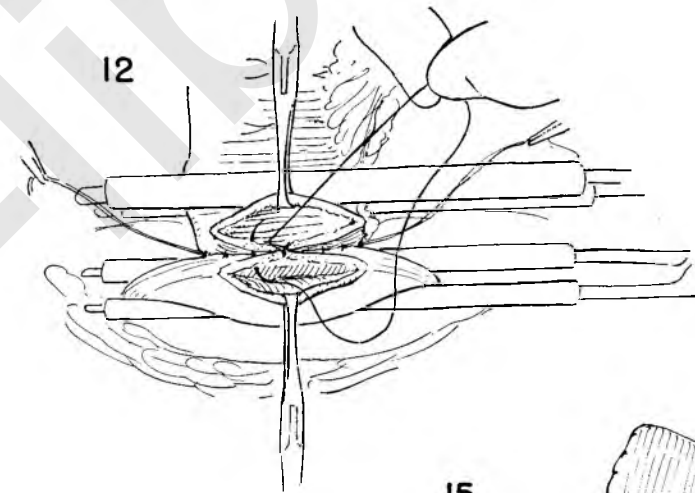


FIGURE 13. The procedure continues exactly as illustrated in detail in Plate 53. The two catgut sutures meet and are tied in the center.

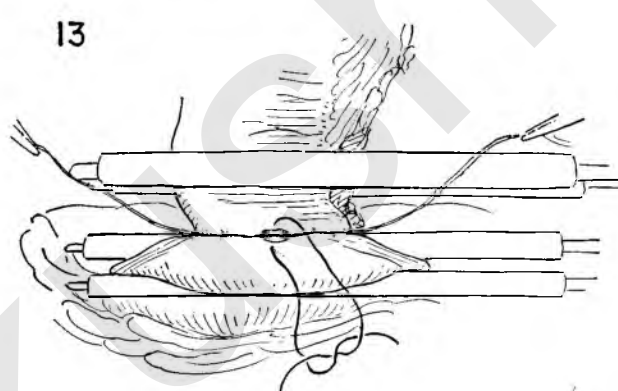


FIGURE 14. Rubber-covered clamps are removed, and the second anterior row of sutures completed.

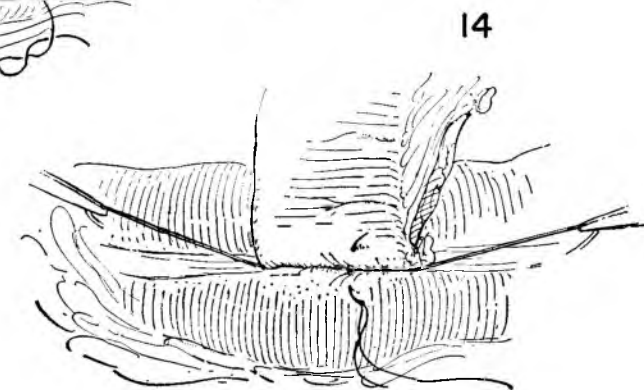
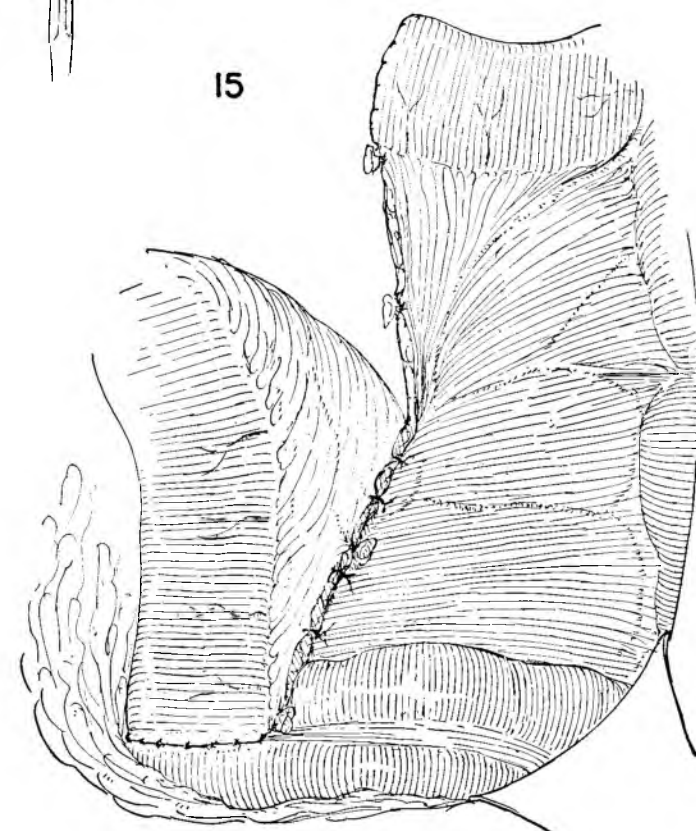


FIGURE 15. This illustrates the finished anastomosis. A real effort should be made to close the opening under the proximal loop where the mesentery was divided. This is best done with interrupted silk sutures between the edge of mesentery and the posterior peritoneum.



LARGE BOWEL RESECTION AND ANASTOMOSIS

The technique is almost identical with that used in small bowel (see Plates 56 and 57). In the colon, however, the suture line must be expected to withstand greater pressures; therefore particular care is warranted to avoid the complication of leakage and extravasation of heavily contaminated large bowel contents.

FIGURE 1. The sigmoid loop has been selected to illustrate this operation. The lateral peritoneal attachments in the left iliac fossa are first cut to permit full mobilization of the bowel. This preliminary dissection to the point of complete mobility is essential whenever the bowel is to be resected, for the two cut ends must come together easily in all cases.

FIGURE 2. The sigmoid has been retracted to the left and the mesentery opened with scissors against the pressure of the supporting fingers.

FIGURE 3. This opening is extended to the bowel by clamping, cutting and tying the vascular arches.

FIGURE 4. A wedge of mesentery has been isolated and thin Kocher clamps placed across the bowel. The field is protected with wet gauze, and the intestine cut across with the cautery.

FIGURE 5. The cut ends are held in approximation by the assistant, and a posterior layer of interrupted silk mattress sutures is accomplished.

FIGURE 6. Rubber-covered clamps are applied to prevent escape of gas and feces before each Kocher clamp is removed.

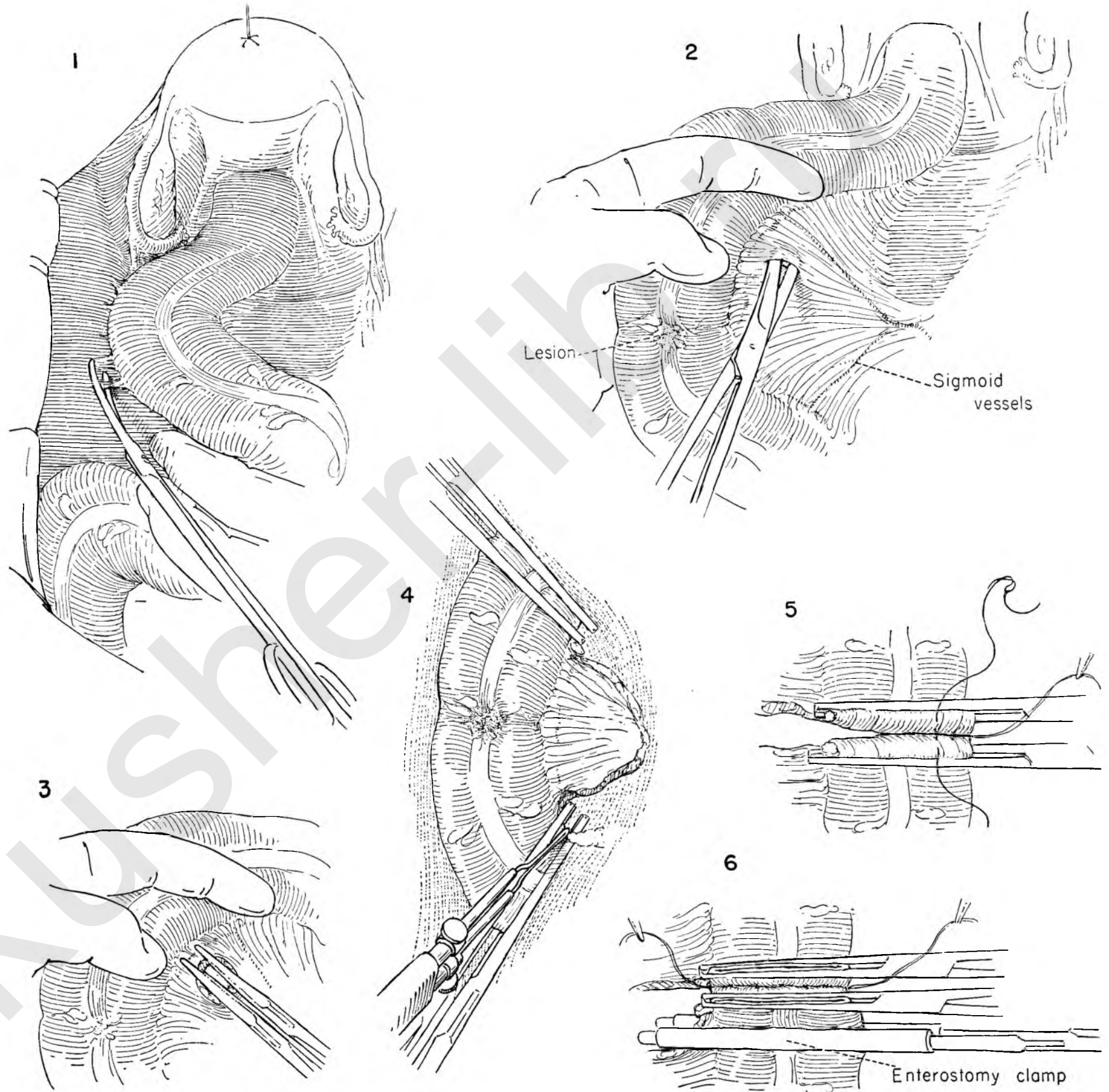


FIGURE 7. The area is steadied by the assistant holding up the handles of the rubber-shod clamps, and the lumen of each segment is exposed. In this illustration, Allis clamps are being used to hold the bowel open.

FIGURE 8. An open anastomosis is performed. Here the inside posterior row is begun with a running, atraumatic, chromic catgut suture at the midpoint.

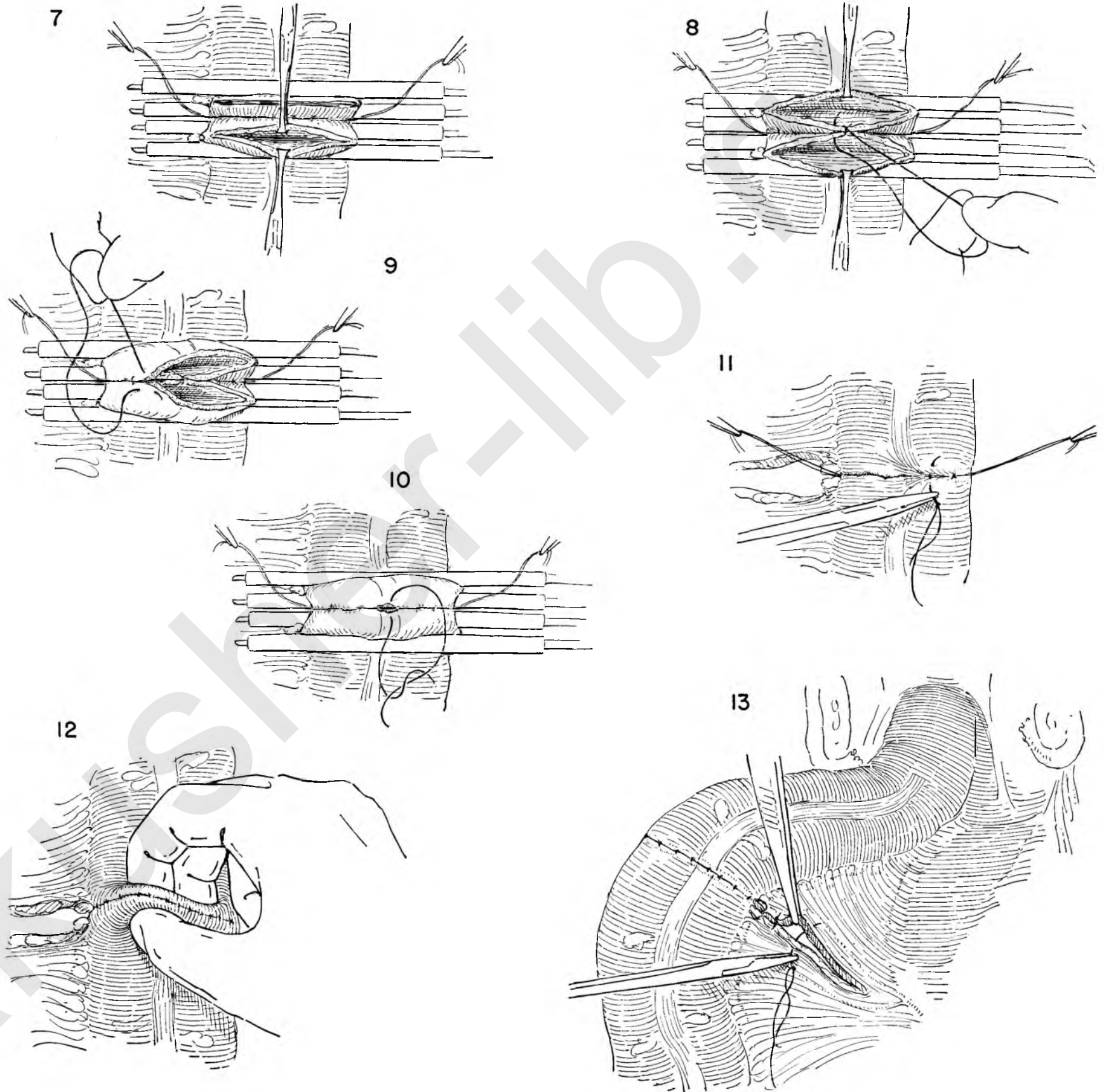
FIGURE 9. This suture is carried around the corner and continues along the anterior edge of bowel as a Connell stitch.

FIGURE 10. A second, similar suture closes the other half of the opening and is tied to the first where it meets it.

FIGURE 11. Rubber-covered clamps have been removed, and the outside row of interrupted silk sutures is being placed.

FIGURE 12. The lumen is tested for size and patency between the thumb and index finger.

FIGURE 13. The opening in the mesentery is closed with more interrupted sutures of silk or cotton.



COLOSTOMY

It is often desirable to decompress the large bowel by means of a colostomy proximal to a point of obstruction. Exteriorization of a loop, in this instance the transverse colon, offers the simplest method and the one least likely to result in complications.

FIGURE 1. One makes a separate, short, transverse skin incision about 2 inches above the umbilicus and just to the right of the mid-line. The transverse colon and its omentum are delivered, and the omentum is turned upwards and dissected free of the colon by cutting filmy, avascular attachments in the line of the taenia.

FIGURE 2. A full 3 inches of bowel and its mesocolon are completely separated from the overlying omentum.

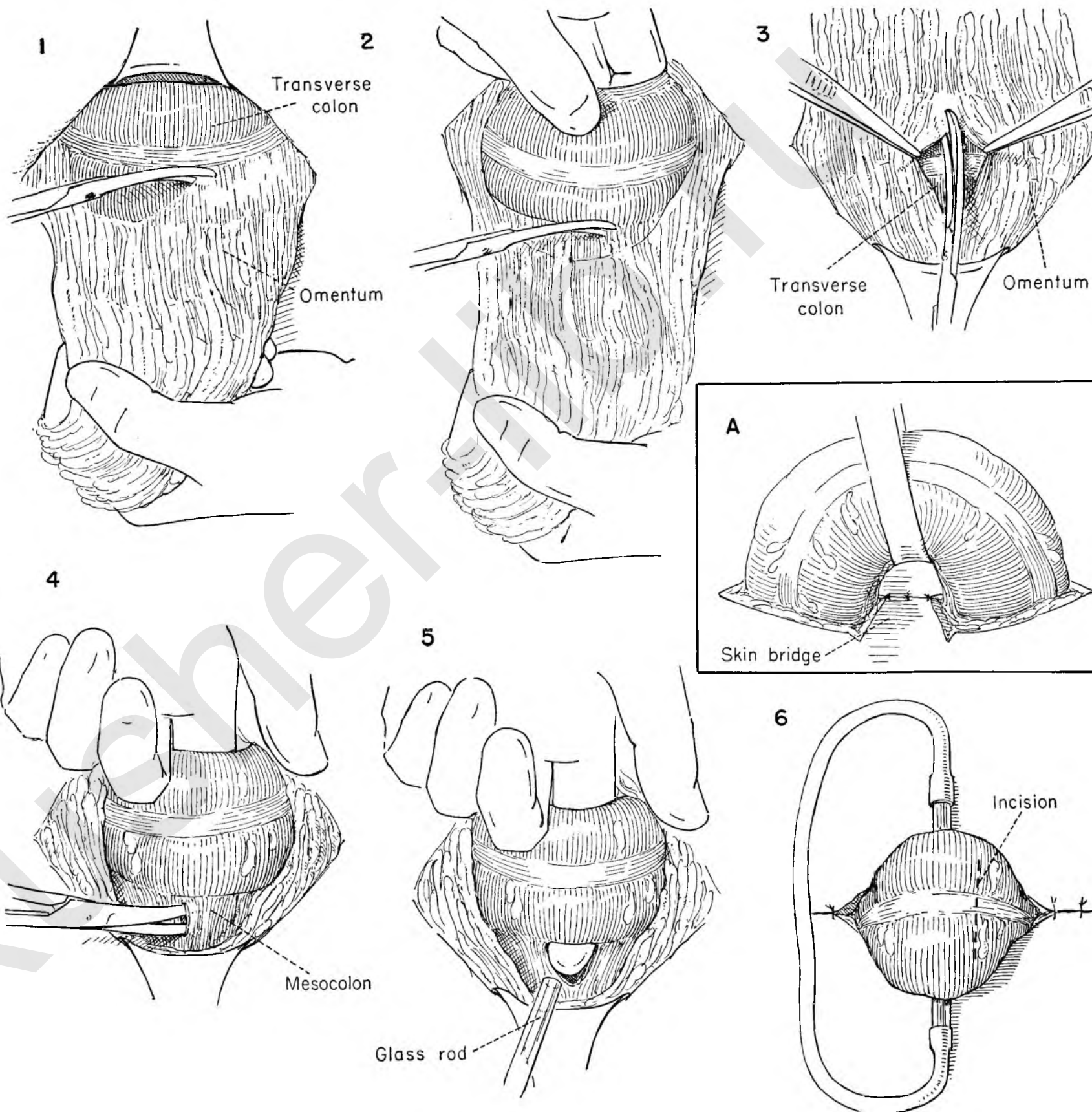
FIGURE 3. The omentum is drawn down over the bowel again and opened vertically where it will expose the area of previous dissection, then replaced within the abdomen.

FIGURE 4. The bowel and its mesentery are elevated with the left index finger, and the mesentery is opened in a bloodless area adjacent to the intestine.

FIGURE 5. A glass rod is passed through under the loop by letting it follow the finger as it is withdrawn.

FIGURE 6. The loop is held up by an assistant, and the wound is closed in layers around it, sufficiently snug to prevent herniation of other bowel loops, yet loose enough to avoid any tendency to obstruct the colostomy itself. One should be able to introduce one finger beside the colon. A length of rubber tubing is now forced over the two ends of the glass rod to prevent accidental dislodgment. The bowel is opened with a cautery in twenty-four hours by a transverse incision on the anterior two-thirds of its circumference at a point slightly nearer the active limb.

INSET A. If a prolonged period of intestinal defunctioning is anticipated, the two stomas produced when the bowel is cut across will separate slightly and lie comfortably if a tongue of skin is fashioned on one side under the loop.



CLOSURE OF COLOSTOMY

Closure of the colostomy is never attempted until one is certain that there is no obstruction in the bowel distal to the colostomy. It must be performed with care to avoid obstruction during the period of healing, which will result in leakage and fecal fistula.

The technique of closure of a simple loop colostomy opened on its anterior aspect is illustrated.

FIGURE 1. A 2-mm. collar of skin is left all around the bowel.

FIGURE 2. Scissor dissection is carried down to the surface of the bowel until the rectus fascia is reached.

FIGURE 3. The fascia is exposed for a centimeter or more on all sides of the bowel. The Allis clamps placed on the skin collar offer an easy means of holding the bowel on tension.

FIGURE 4. The fascia is opened at a point adjacent to the bowel and completely freed from it. This incision is extended at either end in the line of the original wound.

FIGURE 5. The peritoneum is opened and separated in similar fashion. The loop of bowel can now usually be delivered further out of the abdomen.

FIGURE 6. The collar of skin at the stoma and any scar present at the line of juncture between mucosa and serosa are trimmed away.

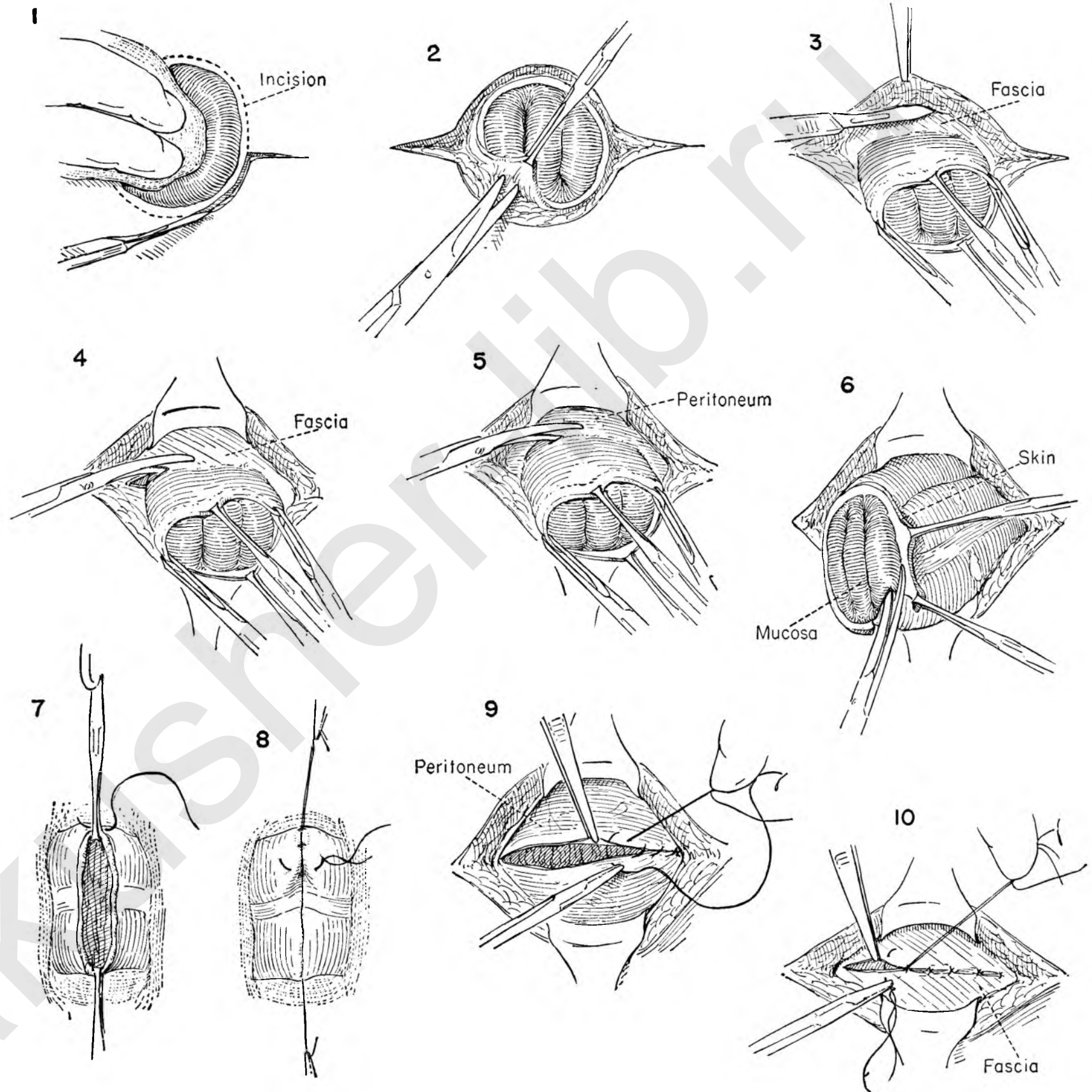
FIGURE 7. Allis clamps on the edges of the stoma keep the bowel up while a closure in two layers and transverse to the axis of the bowel is carried out. First we use an inner layer of running catgut.

FIGURE 8. A second row of interrupted silk is also used, making certain that it extends well beyond the original opening at either end.

FIGURE 9. The bowel has been returned to the free peritoneal cavity and the peritoneum closed.

FIGURE 10. Because the wound is potentially contaminated, interrupted catgut sutures rather than silk or cotton are used to close the fascia.

The superficial fascia and skin are loosely approximated and a dressing applied.



APPENDECTOMY

FIGURE 1. The appendix is easily controlled by a curved hemostat applied to the mesentery near the tip of the organ.

FIGURE 2. A series of bites is taken across the mesoappendix, aiming for the point of juncture with cecum.

FIGURE 3. The tissue is cut as it is clamped. It is usually advantageous to tie these bites before proceeding.

FIGURE 4. The appendix base is crushed with a straight snap.

FIGURE 5. A plain catgut tie is secured at the level of the crush, removing the snap as the tie is made.

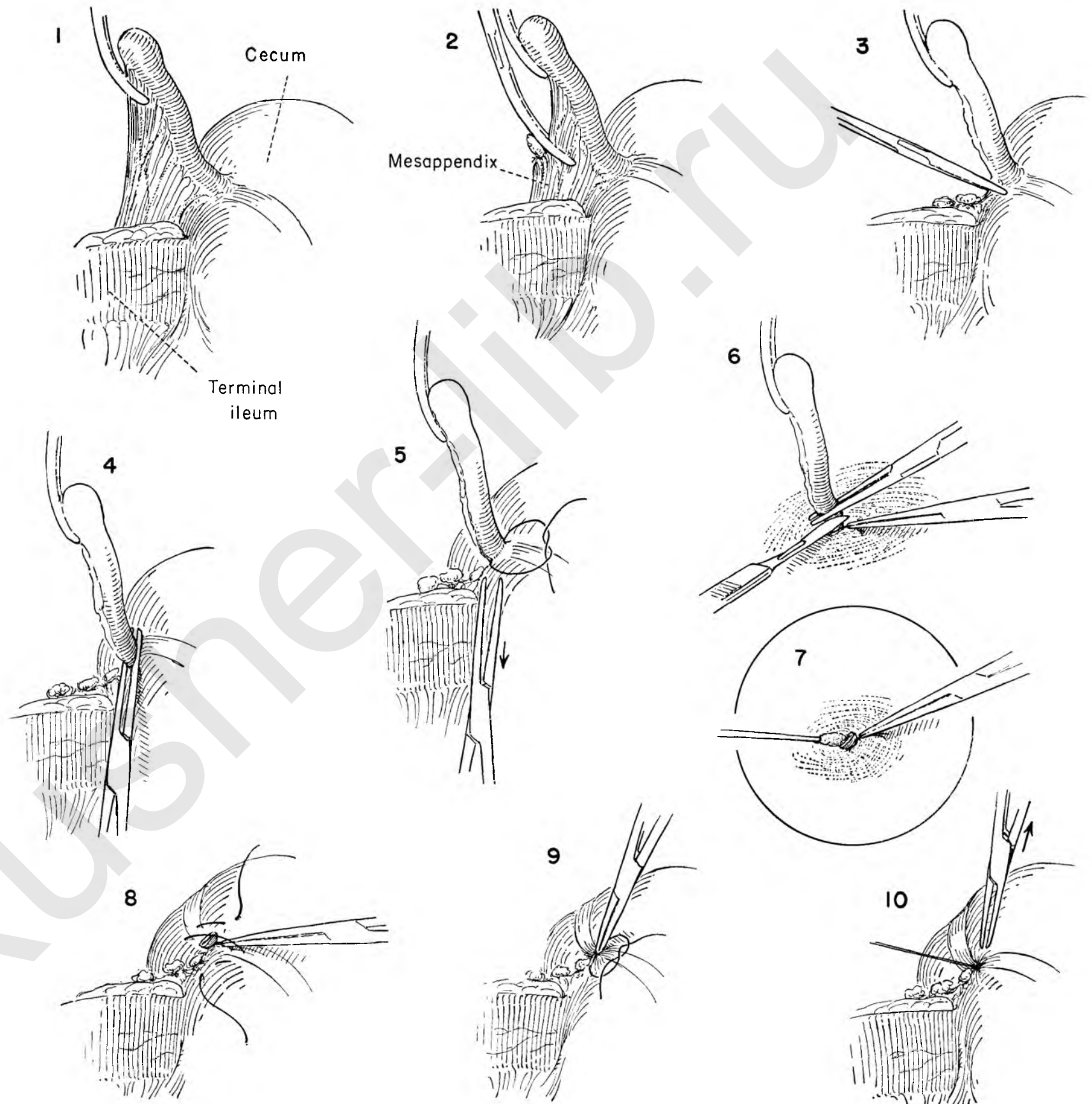
FIGURE 6. The ends of this tie are held close to the knot with a snap. A second crushing clamp is placed about 5 mm. distal, and the appendix is cut across with a knife blade moistened in carbolic acid. A deliberate effort is made to cauterize the cut end of the appendix with this solution; the cecum beneath is carefully protected with dry gauze while this is done.

FIGURE 7. Excess carbolic is neutralized by wiping the stump with a cotton swab dipped in alcohol.

FIGURE 8. Various methods of burying the stump are used. This figure illustrates the placing of a Z stitch of chromic catgut. It is essentially a figure of eight which picks up the bowel at the four corners as a shallow mattress.

FIGURE 9. The stitch is tightened, puckering the appendix site. The stump is simultaneously buried by poking it down in the center of the pucker with the snap which is still on the base tie.

FIGURE 10. The stitch is tied as the snap is released and removed.



Operations Involving the Urinary Tract

The bladder or ureter may be damaged in the course of many gynecological operations. The risk is materially reduced if the surgeon will constantly bear in mind that the ureter is in close proximity to the operative field. Knowledge of the areas where the ureter is most likely to be traumatized will bring additional security. These areas have been stressed in the description of operative details.

IMMEDIATE REPAIR OF DAMAGE TO THE BLADDER

The misadventure of accidentally entering the bladder is in no way serious, provided the operator recognizes that the bladder wall has been perforated and immediate suture is performed.

SIMPLE REPAIR

When the rent is small, simple layer closure will suffice. Interrupted sutures avoid including too much bladder wall and prevent distortion. Small perforations or obvious weakness of the wall near the bladder base may be satisfactorily repaired without danger of obstruction to the ureter, provided the surgeon is cognizant of its proximity. Silk or cotton may serve as a nidus for subsequent stone formation. Catgut should therefore be used for the inner layers.

MORE EXTENSIVE DAMAGE TO THE BLADDER

The surgeon may deliberately remove a segment of bladder to eradicate disease. In this instance, or when the accidental damage to the bladder has been extensive, the operator may feel insecure with a simple layer closure. A suprapubic cystotomy should be added to the bladder repair.

SUPRAPUBIC CYSTOTOMY

This procedure provides adequate urinary drainage until the sutured defect in the bladder heals. Proper placing of the drainage tube in the bladder is important. To avoid a possible osteomyelitis, the tube should not come in contact with the symphysis. Moreover, the tube should be so fixed to the skin that the flared end is held against the roof of the bladder. In this position it cannot ride on the trigone and produce discomfort.

IMMEDIATE REPAIR OF DAMAGE TO THE URETER

However careful the surgeon may be, there is always the

potential risk of severing a ureter or enclosing it in a stitch ligature. Immediate steps must be taken to repair the damaged ureter. This may be done in a number of different ways. In the case in which the damage is unrecognized at the primary operation the same procedures may be used at subsequent exploration.

END-TO-END CLOSURE

When the ureter has been divided with slight loss of tissue length, the two segments may be reapposed with interrupted catgut sutures. Stay sutures placed on the divided ends of the ureter will reduce the use of instruments to a minimum, and also avoid trauma to the ureteral wall and its blood supply. The ureteral anastomosis is usually made around an inlying catheter which acts as an internal splint. The success of the entire procedure depends on the accuracy with which the ends are approximated.

TRANSPLANT INTO THE BLADDER

There may be such loss of ureteral length that a successful end-to-end suture is impossible. Enough ureter cannot be mobilized to bridge the gap.

In this instance the ureter may be transplanted into the dome of the bladder. The point of division of the ureter is determined, the extent of loss of continuity evaluated, and the proximal end of the ureter developed. Additional length may be acquired by dislodging the ureter from its posterior lateral position. The bladder wall is exposed as in suprapubic cystotomy, opened, and the posterior wall incised. The severed end of the ureter is drawn into the bladder and fixed to the bladder wall. The bladder is closed around a suprapubic catheter and the prevesical space drained.

URETERO-INTESTINAL ANASTOMOSIS

Damage to the ureter may not be apparent at the primary operation. The first indication of injury may be the development of signs of ureteral obstruction or ureterovaginal fistula. If anastomosis to the lower segment of ureter is impossible, one may attempt to save the kidney by directing the urinary stream into the bowel.

This operation is hardly feasible for the immediate problem of ureteral drainage, for much of its success depends on proper preliminary sterilization of the bowel with chemotherapeutic agents.

The dissection required to mobilize the severed or damaged end of the ureter may be extremely difficult, for it

lies encased in dense scar tissue. By careful dissection the ureter is mobilized from its bed over a sufficient distance to permit approximation to the sigmoid without tension.

The actual anastomosis is accomplished by fashioning a seromuscular trough on the lateral aspect of the bowel where the ureter will rest easily. An opening is made in the bowel mucosa and the full thickness of ureter anastomosed to the mucosa. A loose closure of the trough is then made over the ureter and reinforced with a peritoneal flap.

It is a cardinal principle in this type of anastomosis that the sigmoid must be brought to the ureter rather than the ureter to the sigmoid. Any tension may cause the ureter to pull out of the bowel, and any malalignment may produce obstruction of the urinary flow. The sigmoid must therefore be fixed. To this end a flap of peritoneum is left on the anterior surface of the ureter. This will serve to cover the ureter in its new position in the sigmoid and at the same time act as an anchor for it.

SKIN URETEROSTOMY

When the extent of ureteral damage is such that end-to-end suture or transplant of the ureter into the bladder is out of the question, the surgeon is faced with a problem. Without preliminary preparation of the bowel, uretero-intestinal anastomosis carries a great risk.

The surgeon may deliberately ligate the divided ureter with impunity, provided the kidney pelvis is not infected. In most cases the kidney will atrophy. Rarely a fistula will develop, and occasionally a nephrectomy may be necessary.

The alternative is to perform a skin ureterostomy. The proximal end of the ureter is mobilized out of its bed as far beneath the peritoneum as the kidney pelvis. The optimum position for the skin incision is on the lateral abdominal wall midway between the rib border and the crest of the ilium, but this may have to be modified, depending on the length of available ureter. A subperitoneal tunnel is then created, and the ureter is led out through the stab wound and fixed to the skin. An excess in length is an asset, for there is a marked tendency of the ureter to retract. An inlying catheter is inserted in the ureter as far as the kidney pelvis and left in place. The position of the catheter is tested by injecting saline solution into the lumen. If there is obstruction to the passage of fluid or if blood appears, the catheter is too far in the kidney pelvis. The catheter must be changed at regular intervals. Obstruction is not uncommon. This usually takes place at the fascia level.

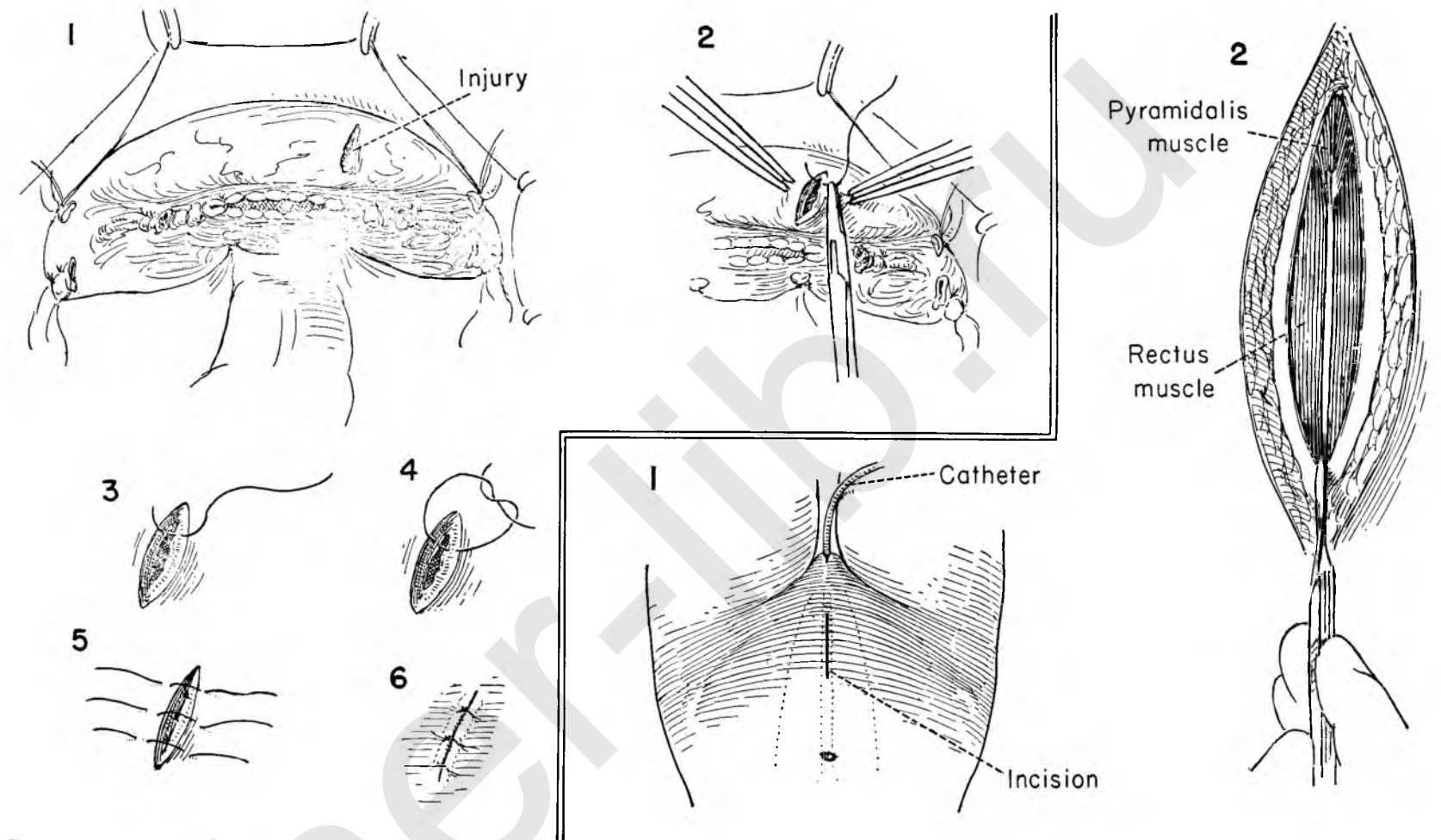
REPAIR OF BLADDER DAMAGE

Damage to the bladder may appear at its base as the surgeon dissects the posterior surface from the underlying cervix or vagina or at the dome in separating the peritoneum from the anterior bladder wall. It is not serious, provided the surgeon recognizes it and takes immediate steps to repair any perforation or reinforce any potential weak spot.

FIGURE 1. The defect is shown on the bladder dome.

FIGURE 2. Catgut rather than linen or silk should be used in the repair to avoid a nidus for subsequent stone formation. The reparative sutures should not enter the mucosa, but include only the serosal and muscle surfaces. The surgeon and assistant prepare to place the first suture.

FIGURES 3, 4, 5, 6. The first layer is reinforced by a second layer of interrupted catgut sutures. The suture enters the outer surface and muscle and emerges at the edge of the defect on either side. Tying of the sutures inverts the tissue, thereby strengthening the closure.



SUPRAPUBIC CYSTOTOMY

Suprapubic cystotomy provides an excellent means of diverting the urinary stream when it is desirable to prevent bladder distention and undue strain on a suture line after repair of extensive damage. It is an essential part of many urological procedures.

FIGURE 1. In most instances the bladder will have been exposed previously. Here the operation begins with a centrally placed lower abdominal skin incision.

FIGURE 2. The skin, muscle and fascia are divided in the midline halfway to the umbilicus.

FIGURE 3. The peritoneum is cleaned from the under surface of the rectus muscle with the knife handle.

FIGURE 4. A retractor is placed in the lower angle of the wound at the symphysis.

FIGURE 5. The surgeon lays the right hand flat on the peritoneofascial surface. By gentle upward pressure flexing the fingers the peritoneal fold is retracted and the prevesical space exposed.

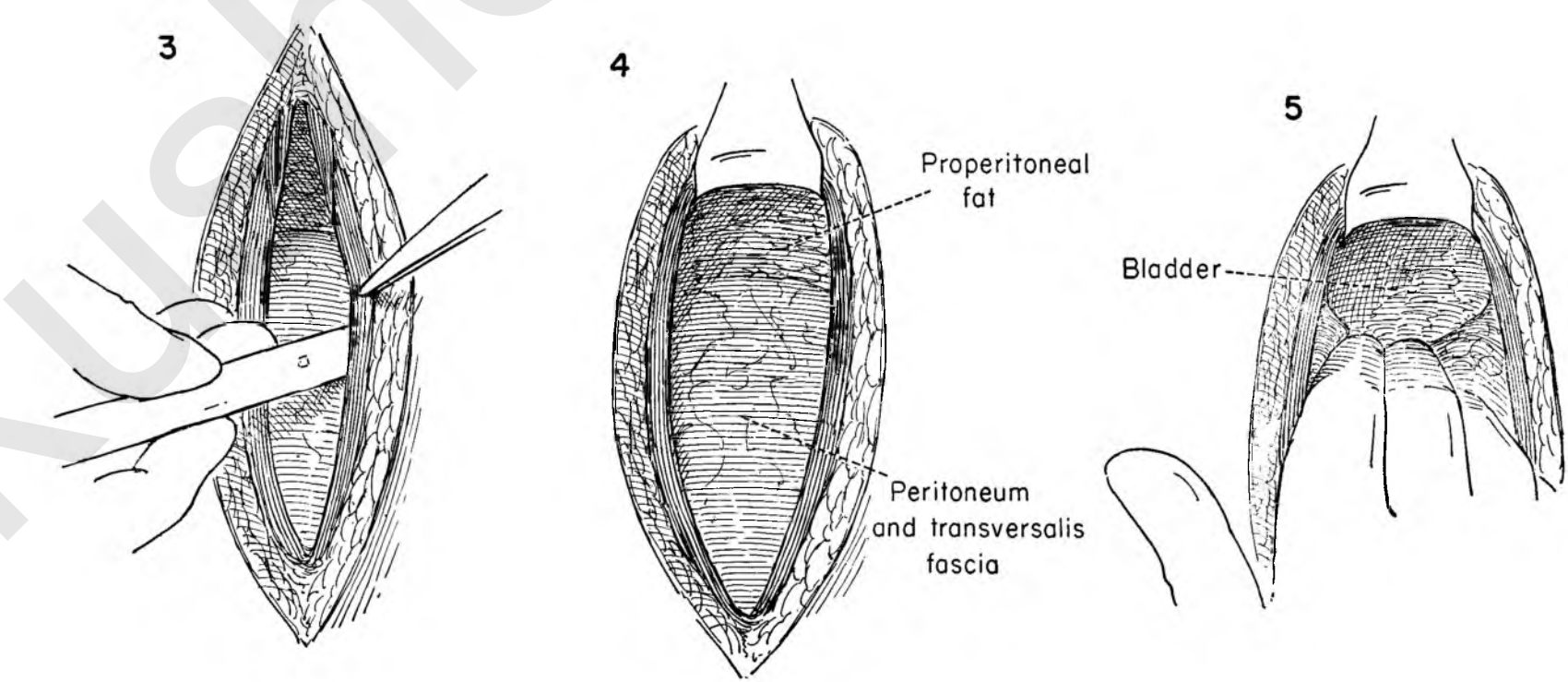


FIGURE 6. The anterior surface of the bladder forms the floor of the prevesical space. Retractors are placed in both ends of the wound to aid in exposure. Allis clamps are placed on the bladder wall at either side of the midline just below the peritoneal reflexion. The surgeon and assistant elevate the clamps as the incision into the bladder is made. If the bladder is empty, the mucosa may have a tendency to recede.

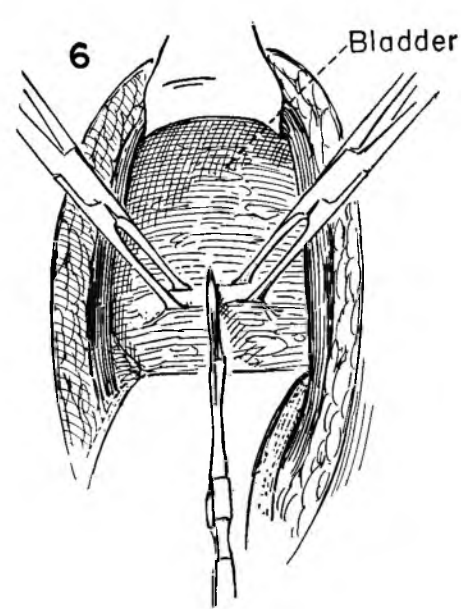


FIGURE 7. To avoid unnecessary spillage of urine the assistant inserts a suction tip into the bladder through the incision. The bladder is sucked dry.

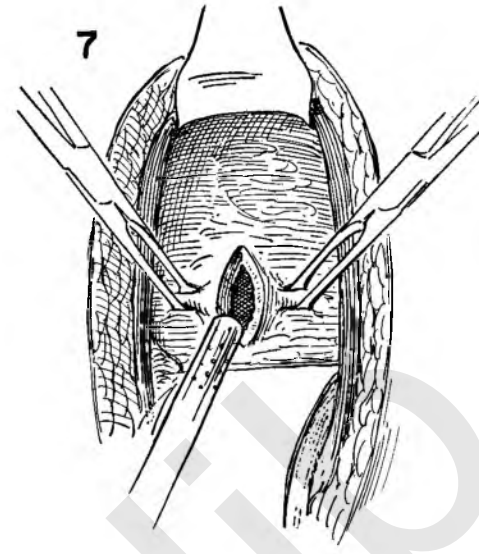


FIGURE 8. The Allis clamps are shifted to include the full thickness of the bladder wall on either side of the incision. Traction is applied to the clamps as the surgeon inserts a Pezzer or large Foley catheter into the bladder interior.

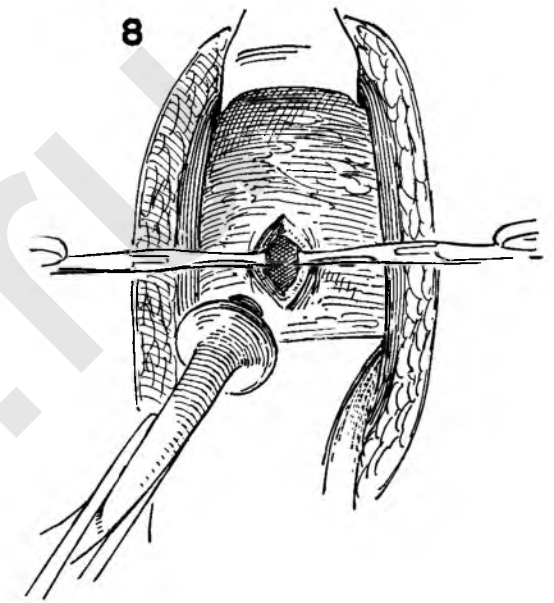


FIGURE 9. The defect in the bladder wall is closed around the catheter with interrupted catgut sutures which pass through the full thickness of the wall of the bladder, but avoid penetrating the mucosa.

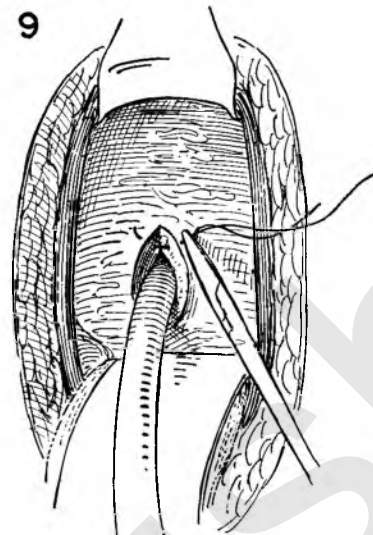


FIGURE 10. The sutures are tied. This illustration shows an empty Penrose drain being placed in the lower end of the wound to minimize the danger of sepsis caused by any urinary leakage.

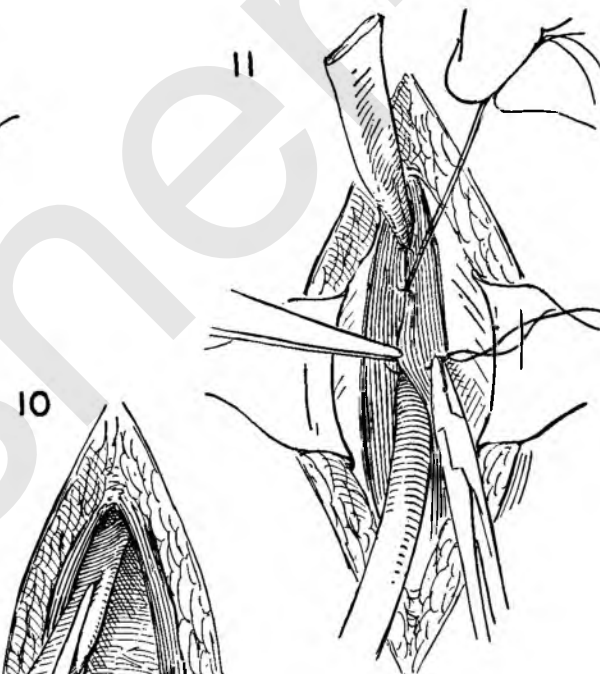


FIGURE 11. The catheter must be brought out well above the symphysis. This materially reduces the possibility of a permanent fistula. The rectus muscles are brought together in the midline with interrupted catgut sutures. The drain in the prevesical space is brought out through the lower end of the abdominal wound.

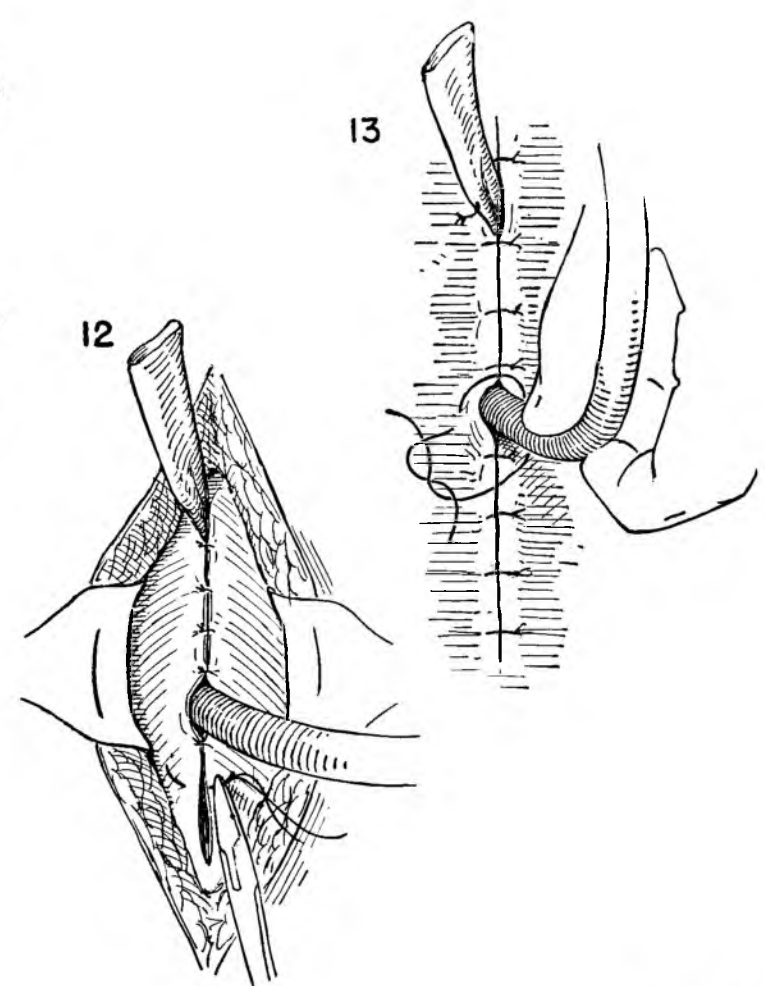


FIGURE 12. Interrupted catgut sutures then complete the closure of the fascia around the catheter and drain.

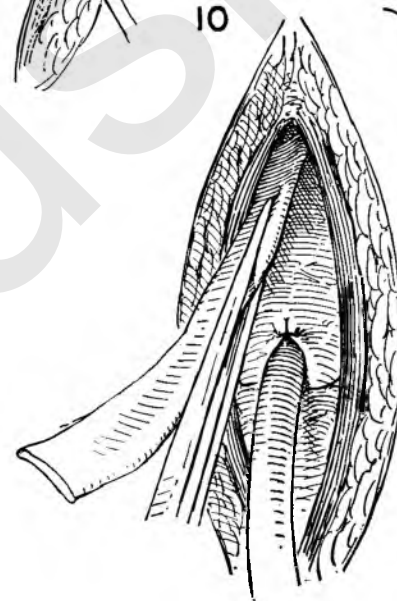


FIGURE 13. Both drain and catheter are fixed to the sutured skin edges. Firm upward traction is applied to the catheter as the fixation stitch is tied, to be certain that it does not rest on the bladder base.

END-TO-END REPAIR OF DAMAGED URETER

The two anatomical areas where damage to the ureter is most likely to occur are at the level of the utero-sacral ligament and the point where the ureter crosses the common iliac artery. Such damage may be recognized at the time of the actual operation or become evident in the convalescent period.

Some difficulty is experienced in mobilizing the ureter from the surrounding scar when the repair is undertaken later, but otherwise the technical steps do not differ basically. When there is no actual loss of substance, end-to-end suture may be feasible.

Immediate repair of damage to the ureter above the level of the ligated uterine vessel is illustrated.

FIGURE 1. An incision in the posterior peritoneum lateral to the ureter exposes the entire length of pelvic ureter lying on the medial flap.

FIGURE 2. Stay sutures are placed on the peritoneal edges to widen the operative field. The periureteral tissue is gently elevated and the ureter dissected free from the underlying attachments.

FIGURE 3. To avoid handling the ureter with instruments, stay sutures are placed in the tissue adjacent to the ureter on either side.

FIGURE 4. If the ureter is deliberately sectioned on the oblique, the largest possible opening will be available for anastomosis. The dotted line indicates the proposed excision. The barest minimum of tissue should be removed.

FIGURE 5. The stay sutures are held on tension, and the lower segment cut with a single decisive incision.

FIGURE 6. The edge of the divided upper ureteral segment is similarly treated.

FIGURE 7. Stay sutures steady the ureter as the surgeon grasps a ureteral catheter in smooth forceps and introduces the tip into the lumen of the upper ureter as far as the kidney pelvis.

FIGURE 8. The assistant steadies the ureter by traction on the stay sutures while the surgeon introduces the catheter into the bladder where the excess curls up in the interior.

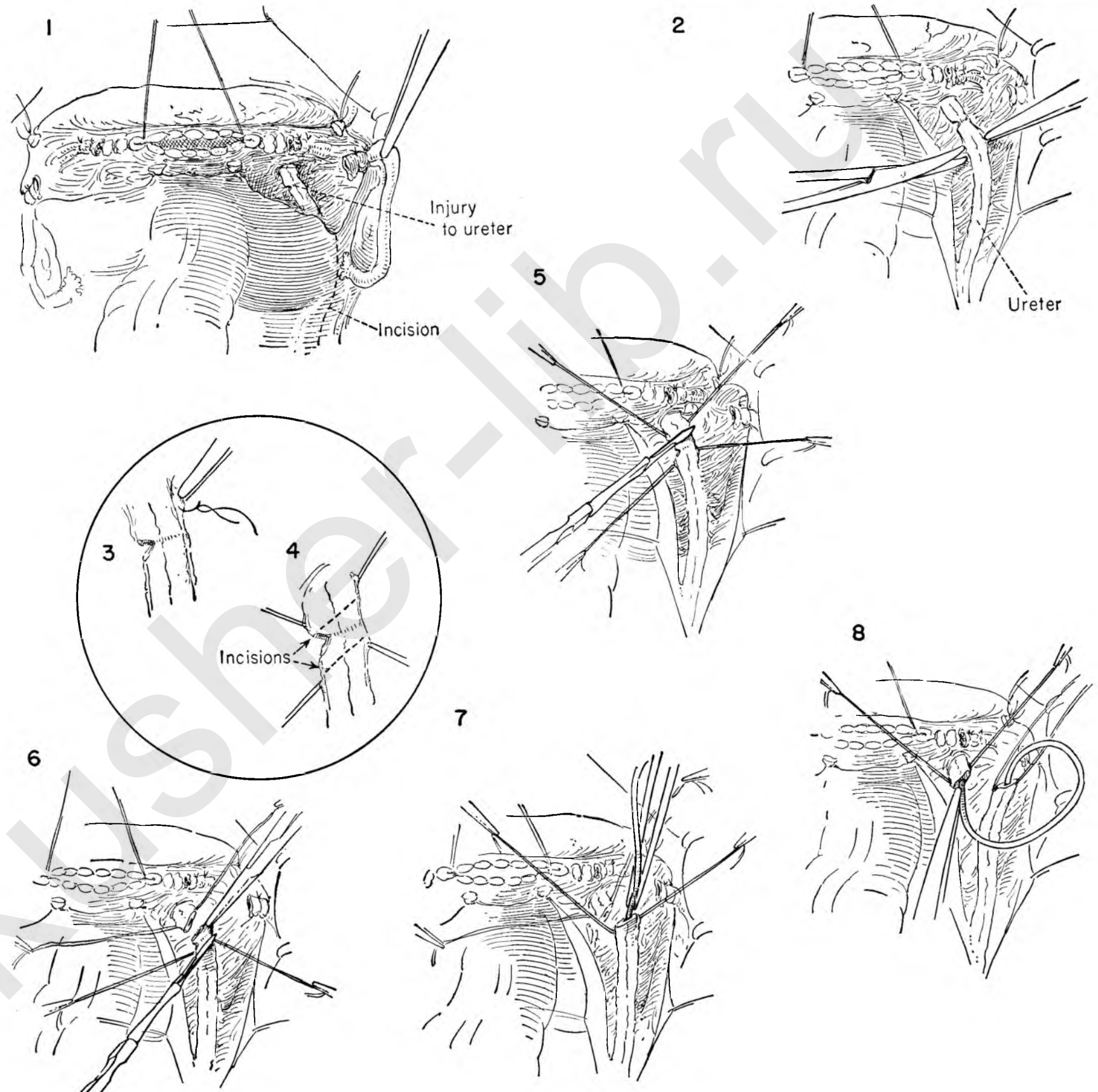


FIGURE 9. The stay sutures placed in the periureteral tissue keep the ureter on tension. The catheter acts as an internal splint.

FIGURE 10. Fine atraumatic catgut sutures are placed in the anterior ureteral wall at both angles. When they are tied and left long, the stay sutures on the ureter can be removed.

FIGURE 11. Additional stitches are placed as the ureter is steadied by traction on the lateral sutures.

FIGURE 12. The posterior wall of the divided ureter is exposed by rotating it with the stay sutures as a similar row of stitches is placed.

FIGURE 13. To reduce tension on the suture line, a permanent traction stitch picks up the periureteral tissue on either side of the incision. Ligation of these lateral sutures steadies the ureter in the manner of tendon repair.

FIGURE 14. The peritoneal floor is reconstructed.

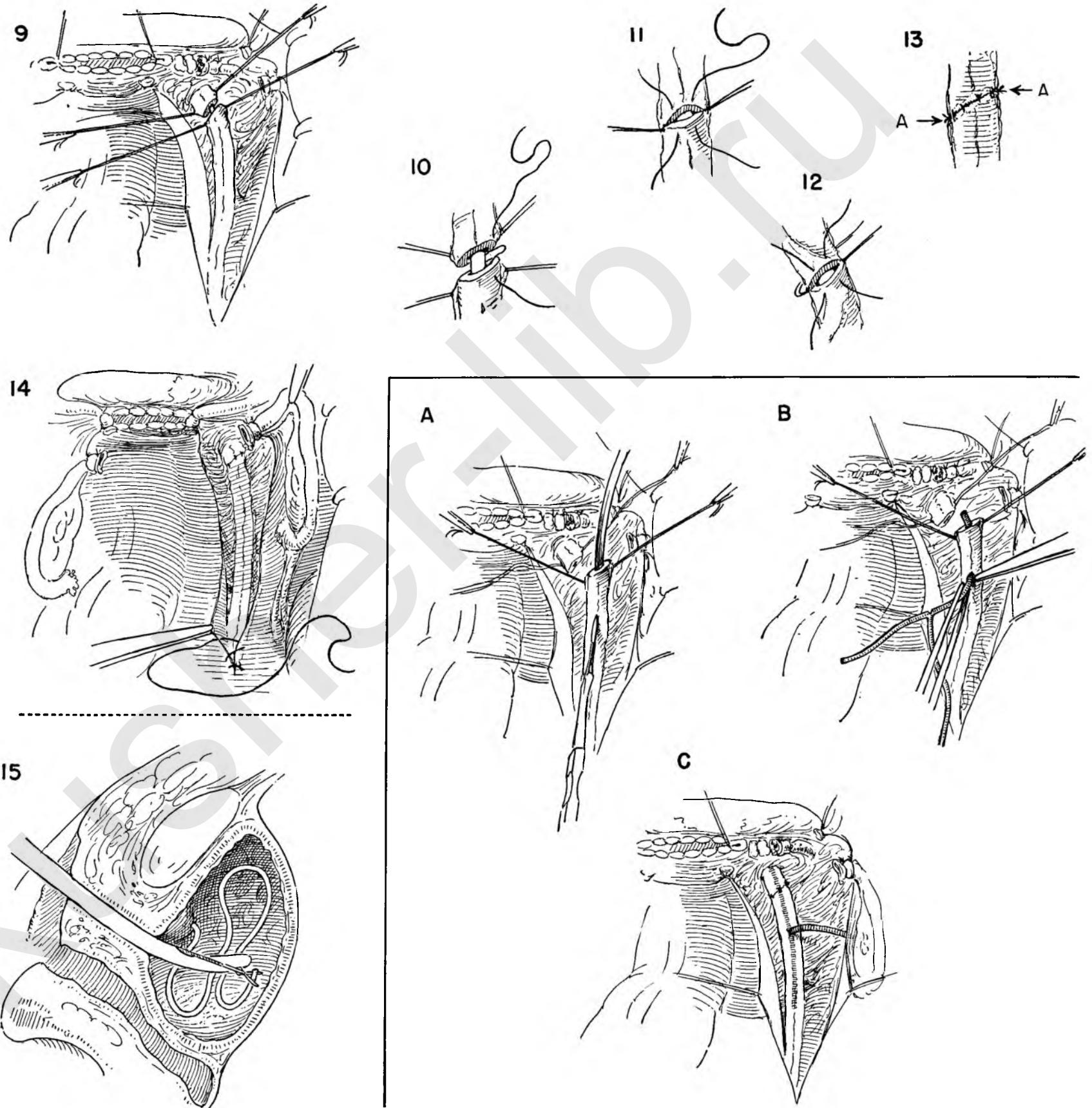
FIGURE 15. The redundant portion of the ureteral catheter lying in the bladder is withdrawn through the urethra by an operating cystoscope.

ALTERNATE METHOD OF SPLINTING THE URETER

INSET A. Stay sutures have been placed on the divided ends of the ureter. A grooved director is inserted into the lumen of the ureter and the anterior ureteral wall incised about 1½ inches from the cut end, avoiding the intrinsic blood vessel.

INSET B. The distal arm of a small T tube is inserted into the stab wound in the ureter and advanced toward the bladder with forceps. The maneuver is repeated on the upper arm. If a V-shaped section is removed opposite the long arm of the tube, the arms will collapse when it is subsequently removed, thus avoiding trauma to the ureteral wall.

INSET C. The distal arm extends through the completed anastomosis as a splint. The main portion of the catheter leads out retroperitoneally through a stab wound in the lower abdominal wall.



TRANSPLANTATION OF THE URETER INTO THE BLADDER

This series is illustrated as though the damage to the ureter had been discovered in the post-operative period. The actual extent of damage to the ureter cannot be revealed until the traumatized ureter is dissected free. The same reconstructive steps would apply had loss of ureteral length been noted at the time of the primary surgical procedure.

The continuity of the operative steps, however, will proceed as though the damage were discovered late.

FIGURE 1. The normal course of the ureter is determined by following it down into the pelvis from the point of identification at the level of the common iliac artery.

The surgeon then divides the posterior parietal peritoneum overlying the ureter as the assistant aids in elevating the peritoneum with forceps.

FIGURE 2. Stay sutures are placed on the severed peritoneal edges to widen the operative field. The assistant picks up the peritoneum overlying the reconstructed bladder flap as the surgeon incises it.

FIGURE 3. The surgeon and assistant elevate the cut peritoneal edge with stay sutures so that the bladder can be mobilized from beneath it.

FIGURE 4. The round ligament previously sutured to the stump of the vaginal canal is isolated and the index finger passed beneath it.

FIGURE 5. Suture ligatures are placed in the round ligament close to the vaginal attachment. These are held on tension while the surgeon divides the ligament between them. The lateral suture on the round ligament is left long and allowed to hang outside the abdominal incision. In this fashion, supplemented by the stay sutures on the lateral edge of the peritoneum, a wide open operative field is created.

FIGURE 6. The surgeon then begins to dissect the damaged ureter from the surrounding fibrosis. Particular care must be taken not to jeopardize the blood supply to the ureter. As far as possible, the dissection should be carried out in the periureteral tissue with the use of instruments reduced to a minimum.

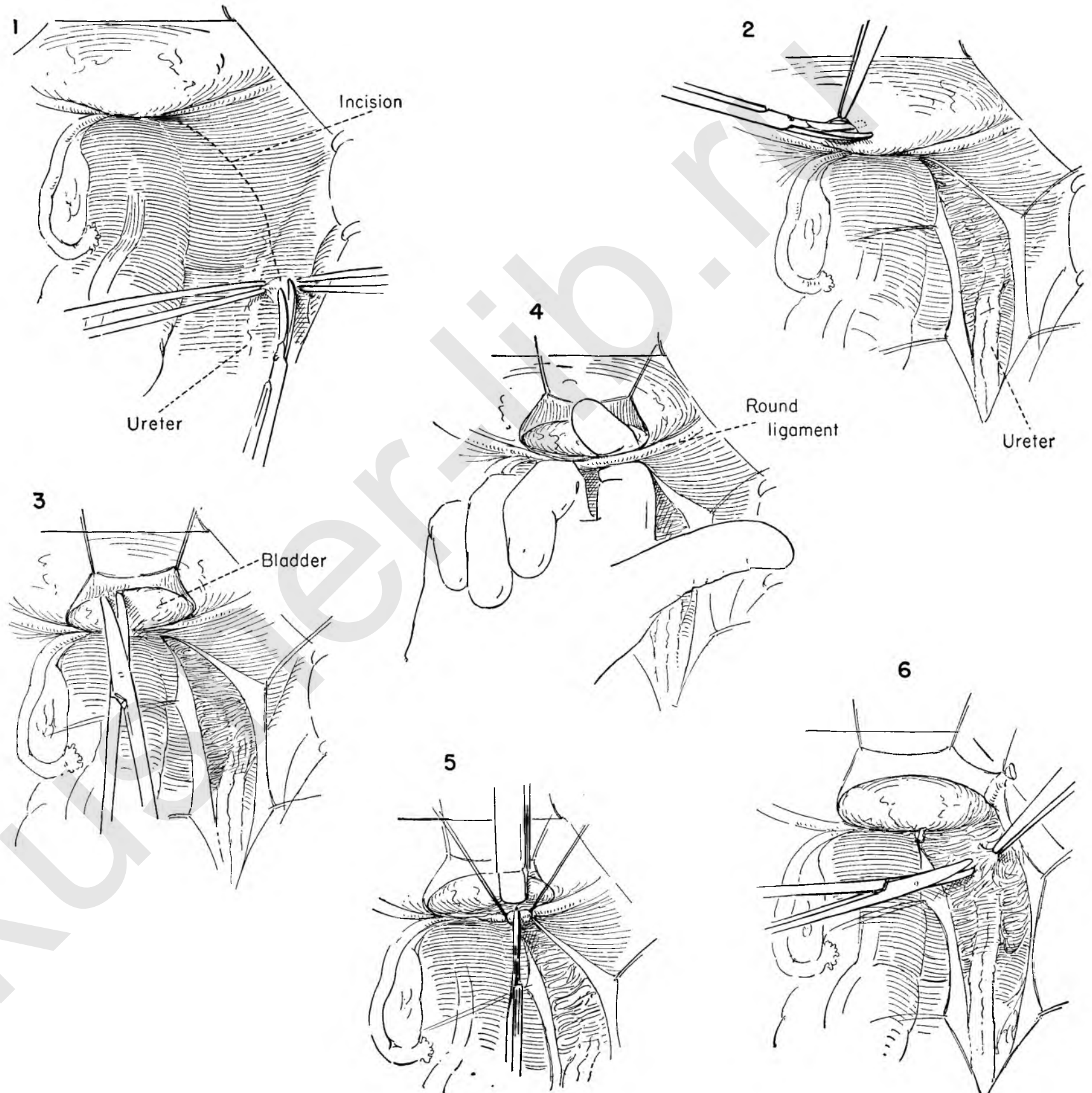


FIGURE 7. The dissection continues in the scar tissue around the damaged ureter. The field must be kept absolutely bloodless. Continuous saline irrigation and suction may ensure this more effectively than routine sponging.

FIGURE 8. The extent of the damage to the ureter is now evident. The lower segment of the ureter is represented by a fibrous cord. The surgeon must now make the decision whether end-to-end suture is possible or whether transplant into the bladder is feasible. The decision has been made to transplant the ureter into the bladder. Stay sutures are passed into the peri-ureteral tissue, the ureter elevated, and a ligature of silk drawn underneath it with a clamp.

FIGURE 9. The ureter is singly tied and transected at the most distal normal portion.

FIGURE 10. As the assistant applies traction to the Kelly clamps placed on the lower peritoneum, the surgeon with the palmar surface of the fingers gently separates the bladder from the symphysis in a bloodless areolar area. A Dever retractor placed in the lower angle of the wound exposes this prevesical space with the bladder presenting on the posterior surface.

FIGURE 11. Allis clamps support the dome of the anterior bladder wall in the midline as the surgeon incises the wall between the forceps.

FIGURE 12. Small curved retractors keep the incision widely open to reveal the trigone with the ureteral orifices as well as the posterior wall of the bladder.

FIGURE 13. Traction on the Kelly clamps is maintained upward. The surgeon then places the left index finger beneath the bladder from the abdominal side. Elevation of the bladder base gives a firm foundation on which to incise the posterior bladder wall at a point where the ureter can be brought to it without tension.

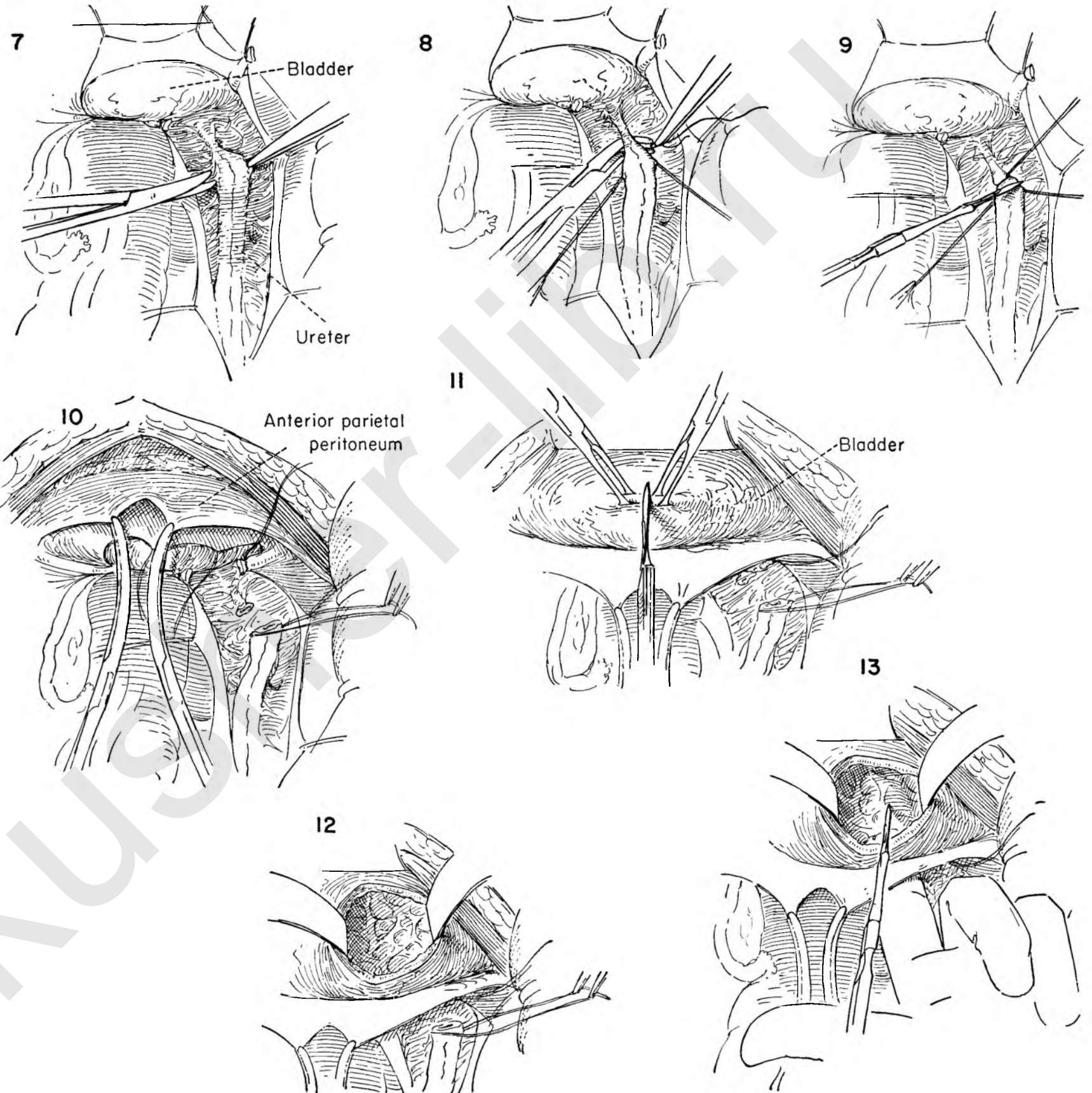


FIGURE 14. The incision in the posterior lateral bladder wall is exposed by applying traction to the stay sutures on the lower peritoneum. The surgeon introduces a Kelly clamp into the interior of the bladder and out through the opening to grasp the stay sutures on the ureter.

FIGURE 15. By traction on the stay sutures the ureter is now led through the opening in the bladder wall. The curved retractors in either angle of the bladder aid in the exposure.

FIGURE 16. Stay sutures held on counter-traction steady the ureter while the surgeon incises the ureteral wall in the longitudinal axis in an area free of blood vessels. This enlarges the ostium. When the ureter lies comfortably without tension or rotation in the long axis, the anastomosis is begun.

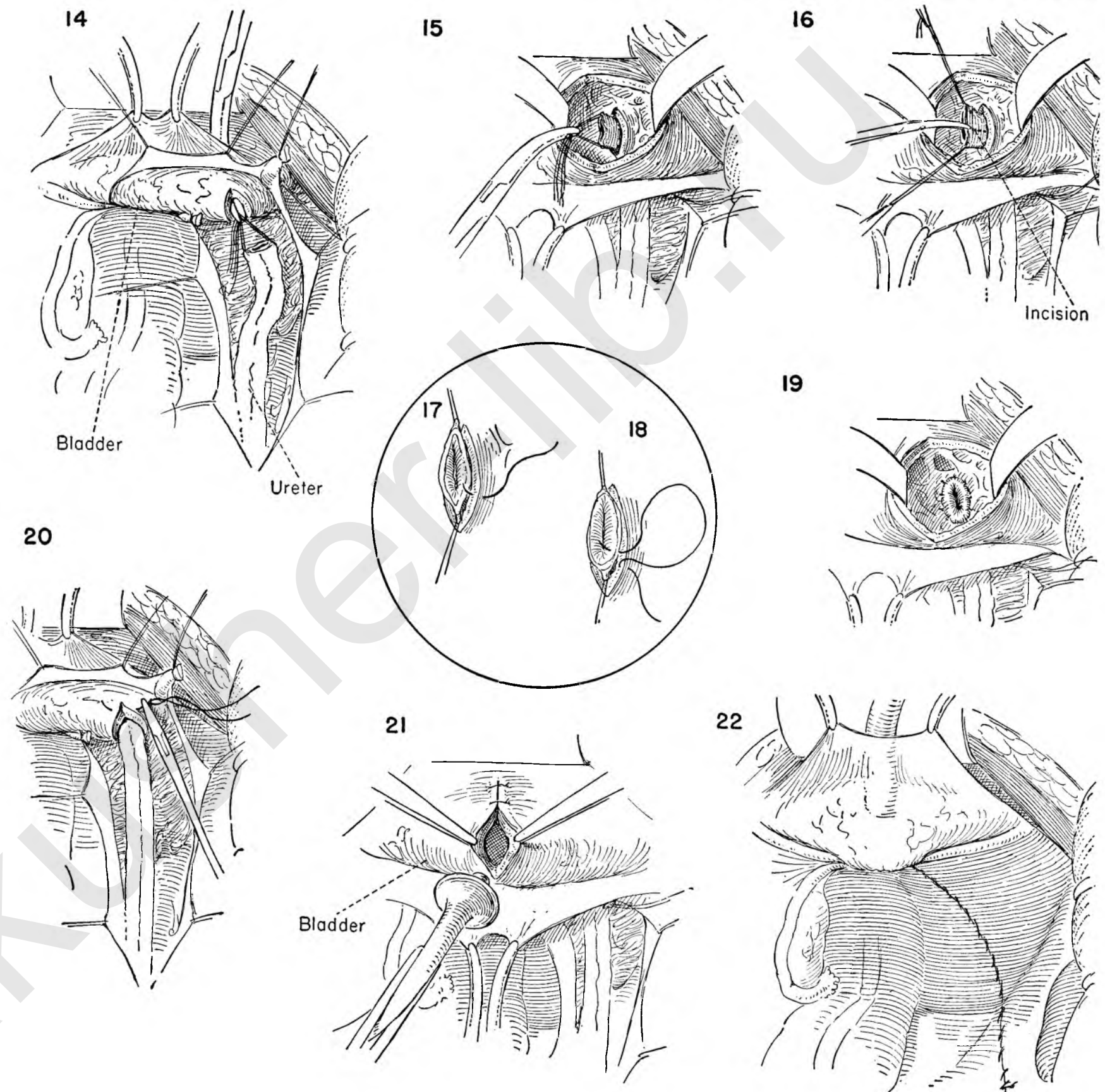
FIGURES 17 AND 18. The surgeon steadies the stay sutures on the ureter and places the first of a series of interrupted catgut sutures which fix the cut end of the ureter to the opening in the bladder wall. The suture includes the bladder muscle and mucosa and the full thickness of the ureter.

FIGURE 19. The complete anastomosis results in an elliptical ostium.

FIGURE 20. The assistant elevates the stay sutures on the peritoneal bladder flap to expose the incision on the posterior bladder wall on the abdominal side. The defect is closed with interrupted catgut sutures the last of which includes the periureteral tissue to help fix the ureter. The closure should be snug without compressing the ureter.

FIGURE 21. The assistant applies traction on the peritoneal clamps to expose the incision in the anterior bladder wall. The incision is then closed with interrupted sutures except for the upper portion. Into this opening a Pezzer catheter is inserted into the bladder to provide drainage while the anastomosis heals. The catheter is fixed in place in the manner of suprapubic cystostomy.

FIGURE 22. The operation is completed by reconstruction of the pelvic floor and peritonealization of the raw areas.



URETERO-INTESTINAL ANASTOMOSIS

When there has been too much loss of ureteral length through operative trauma, either end-to-end suture or transplantation into the bladder may be impossible. Diversion of the urinary stream into the intestine is possible by uretero-intestinal anastomosis. Preliminary preparation of the colon by chemotherapeutic agents is desirable.

This operation may be done for extensive damage to the ureter, irreparable vesicovaginal fistula or as part of extensive surgical procedures for pelvic malignancy.

FIGURE 1. The surgeon identifies the ureter as it crosses the common iliac vessels and divides the peritoneum lateral to it with scissors.

FIGURE 2. The operative field is kept open by placing stay sutures on the incised peritoneal edges. The ureter lies on the medial peritoneal flap. The ureter is carefully dissected out of the dense area of fibrosis. The common and internal iliac arteries lie beneath and are often firmly adherent to the ureter as it courses down toward the bladder. This can be a difficult dissection. To avoid damage to the artery and maintain the blood supply to the ureter, a dry field is a "must."

FIGURE 3. The ureter has now been successfully dissected free of the encasing fibrosis. The extent of damage to the ureter is evaluated.

FIGURE 4. The surgeon then gingerly dissects the proximal ureter free from underlying attachments. This area may be treacherous, for at this point the ureter crosses the common iliac artery, shown beneath the ureter.

FIGURE 5. A stay suture is placed in the periureteral tissue on either side of the ureter. With the separation accomplished, a Moynihan clamp is passed beneath the ureter and a silk tie inserted in the open ends of the clamp as the assistant elevates the stay sutures.

FIGURE 6. The silk is then tied about the distal ureter. The suture is left long for the moment. The assistant elevates this tie while the surgeon applies similar traction to the stay sutures on the proximal ureter and divides it.

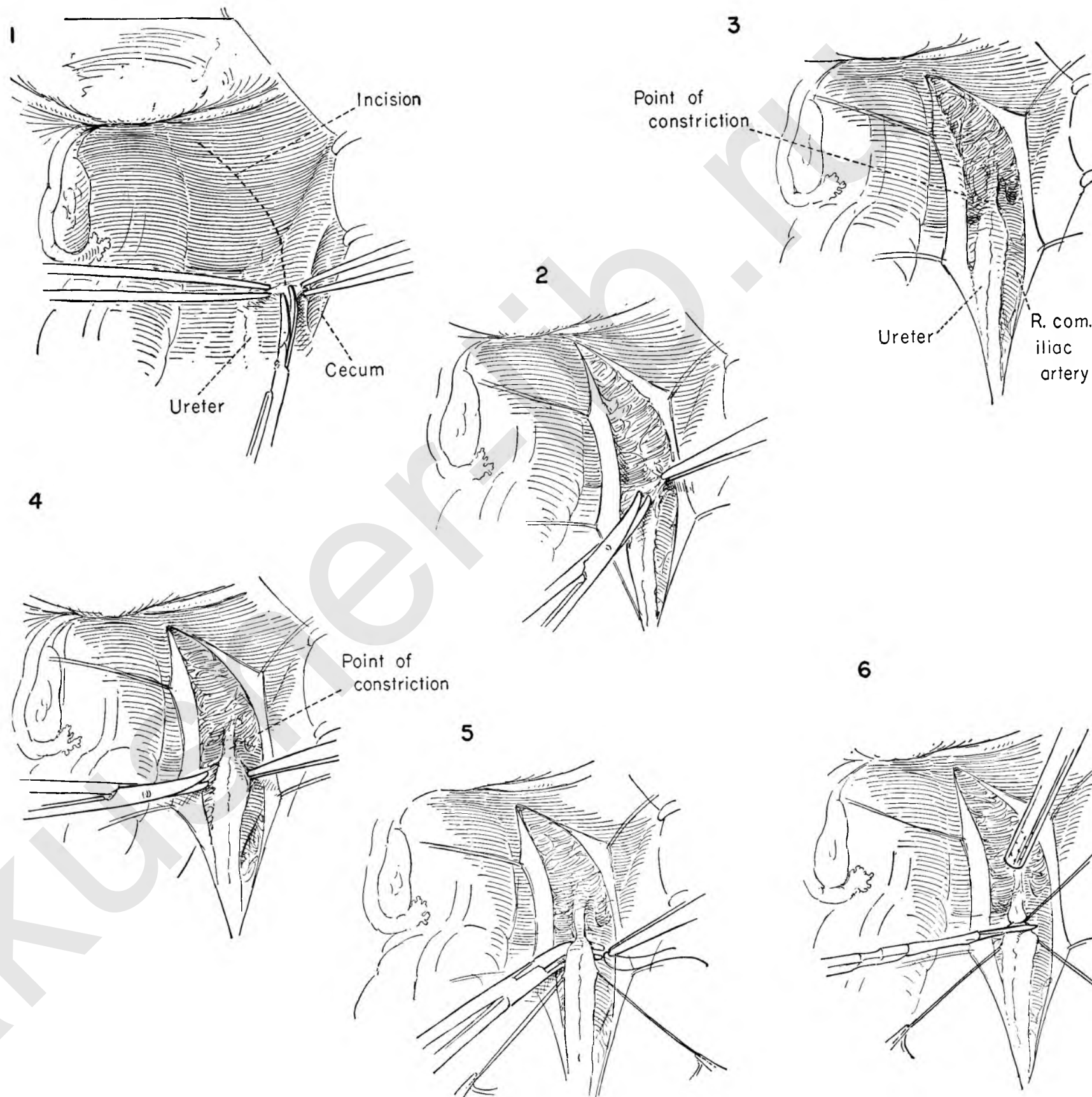


FIGURE 7. The surgeon elevates the stay sutures as he gently dissects the ureter away from the underlying artery under direct vision. The object is to free the ureter on the under side while preserving its attachment to the anterior peritoneum.

FIGURE 8. The ureter has been mobilized posteriorly and freed from the anterior peritoneum for a distance of about 1 inch. The medial leaf of the peritoneal flap is placed on tension as the surgeon sections the peritoneum transversely about $\frac{3}{4}$ inch below the most distal excursion of the ureter.

FIGURE 9. The assistant now pulls the stay sutures toward the symphysis, and the surgeon incises the peritoneum medial to the ureter in an upward direction. The result is a peritoneal flap with ureter adherent to its under surface.

FIGURE 10. The peritoneal flap with attached ureter is evident. The sigmoid is then brought over to meet the severed end of the mobilized ureter. A longitudinal incision is made in the anterolateral surface of the sigmoid in the long axis at a point where the sigmoid lies in proximity to the ureter without tension.

FIGURE 11. The sigmoid is elevated with the left hand and steadied as the surgeon incises the serosal and muscle coats down to but not through the mucosa. The incision extends for a distance of about 1 inch.

FIGURE 12. Fine-tooth forceps and eye scissors are needed for the meticulous dissection necessary to separate the sigmoid mucosa from the overlying muscle. The assistant keeps the seromuscular coat on tension while the surgeon divides the fine tissue bands holding the mucosa to the muscle. A flap approximately $\frac{1}{2}$ inch wide should be developed on each side. Great care must be taken not to perforate the mucosa.

FIGURE 13. With a grooved director as a guide and the ureter on tension the open end of the ureter is enlarged by incising the posterior wall upwards in the long axis for a distance of about $\frac{1}{4}$ inch.

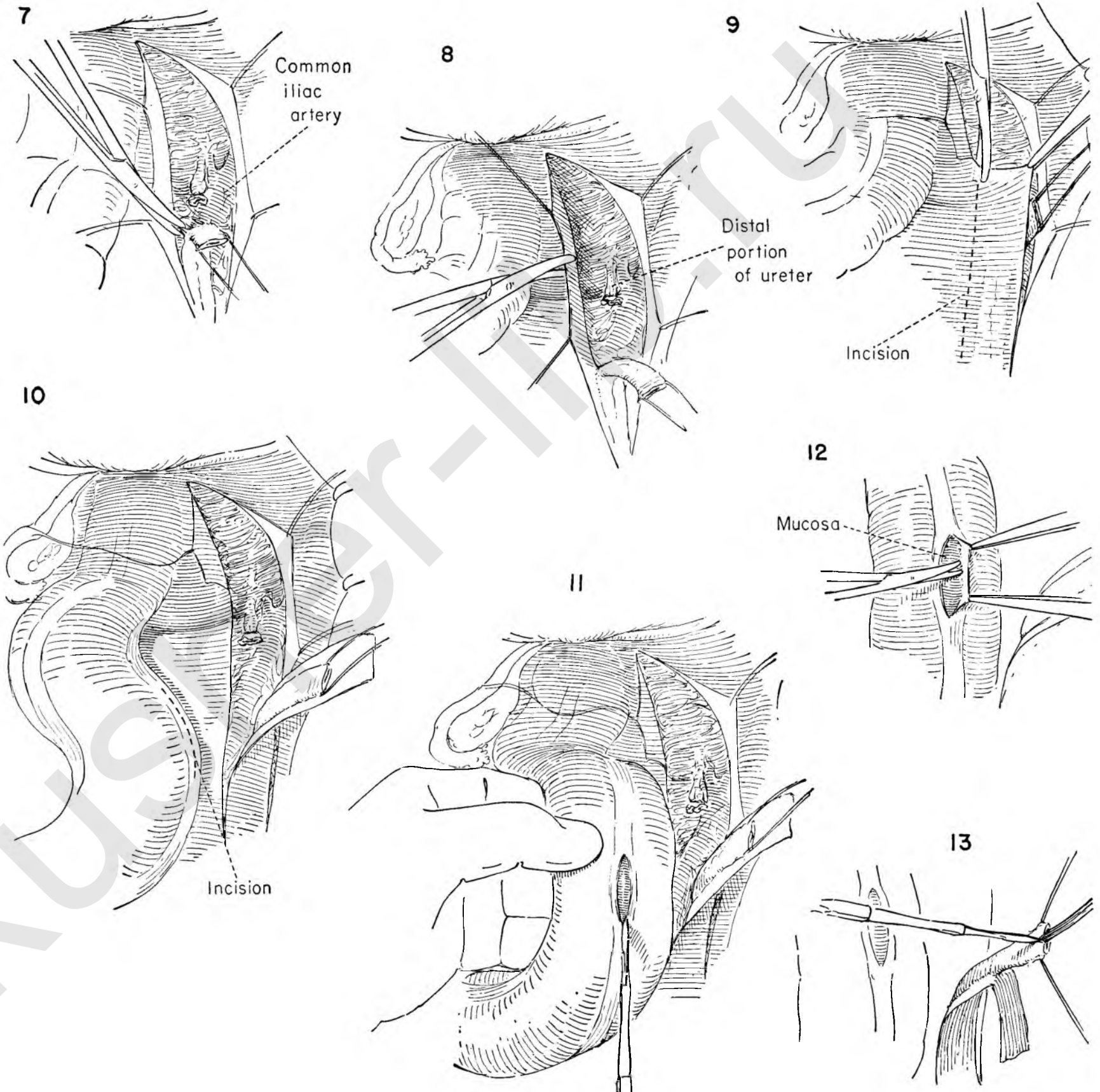


FIGURE 14. The surgeon places a fine atraumatic suture at the upper end of the incision in the ureter, through the entire thickness of the wall, as the assistant holds the ureter on stretch.

FIGURE 15. The bowel lumen is entered by incising the mucosa for about $\frac{1}{4}$ inch at the lower end of the trough previously fashioned in the sigmoid.

FIGURE 16. The fine atraumatic suture which passed from the outside of the ureteral wall into the lumen of the ureter now enters the inside of the bowel to emerge on the outer side of the mucosa. This suture is tied.

FIGURES 17 AND 18. These show the series of interrupted sutures in such a manner that full thickness of ureter is sutured to sigmoid mucosa. This is slow, painstaking work.

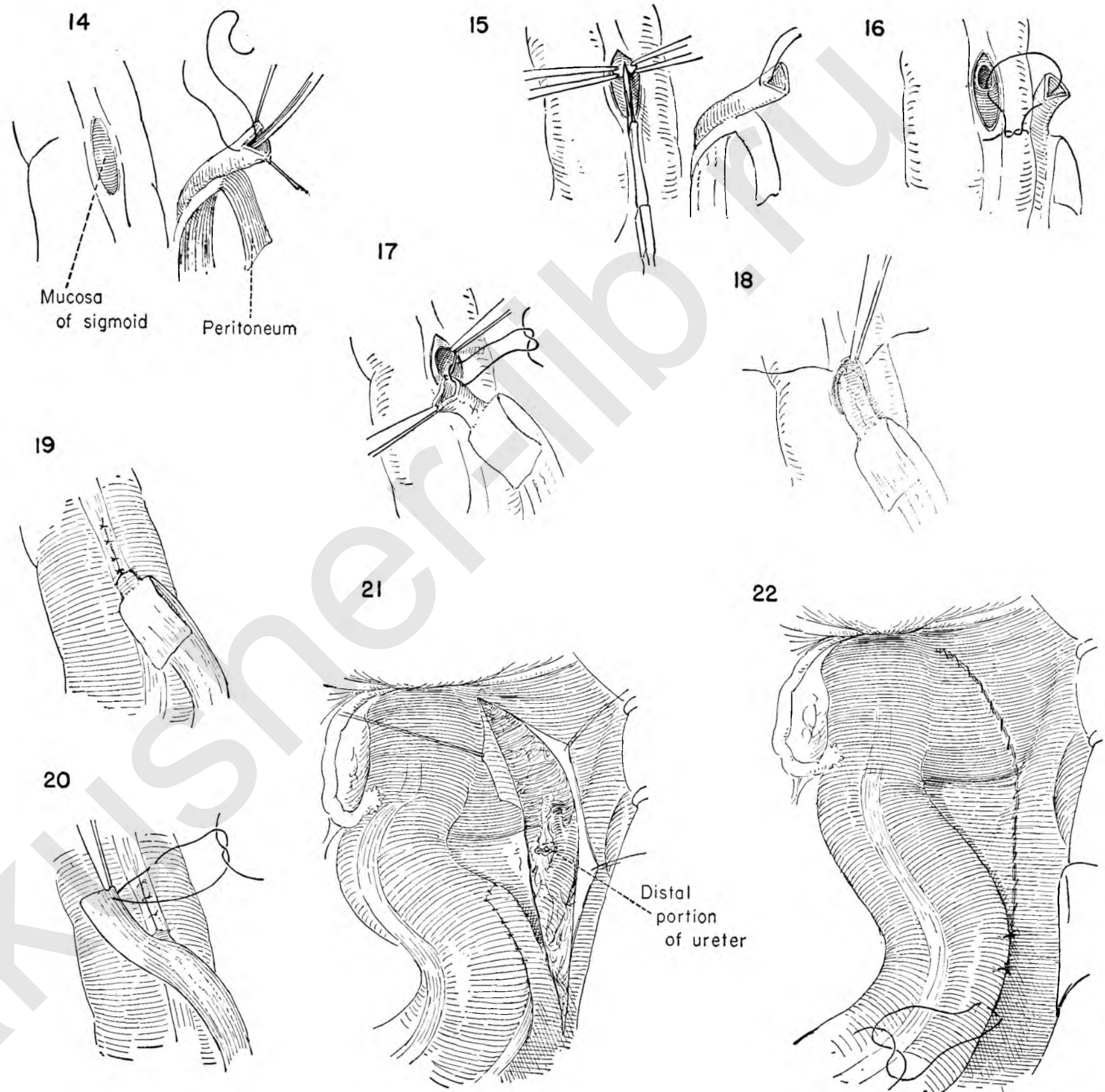
FIGURE 19. The uretero-intestinal anastomosis is now complete. The seromuscular edges of the trough are now loosely closed over the ureter with interrupted sutures. The ureter must lie in the bed without tension or compression and without suggestion of constriction at the point where it enters the serosal tunnel. The peritoneal flap hangs free.

FIGURE 20. The cut edge of the peritoneal flap covering the ureter is then sutured to the sigmoid wall with interrupted silk sutures. The flap must lie easily as a patch over the ureter without kinking. For this reason the distal end of the peritoneal flap is placed first.

FIGURE 21. Interrupted silk sutures are placed at spaced intervals to complete the peritonealization of the ureter. The peritoneal flap not only covers the ureter and seals the anastomosis, but also serves to fill the cardinal principle of all uretero-intestinal anastomoses that the sigmoid must be brought to the ureter and fixed.

FIGURE 22. The fixation of the sigmoid may be further enhanced by interrupted sutures of catgut to the right lateral pelvic peritoneum both below and above the flap.

The operation is completed by closing the defect in the peritoneum with a running atraumatic catgut suture.



SKIN URETEROSTOMY

The loss of continuity of ureter may be so extensive that neither end-to-end suture nor transplant into the bladder is possible. The kidney on the involved side may be infected. It would therefore be unwise to tie off the ureter or to transplant it into the intestine.

The procedure of skin ureterostomy is one method by which this problem may be solved. The same technique may be used for diverting the urinary stream in the radical surgical extirpations for pelvic malignancy.

FIGURE 1. The technical problems are more troublesome on the left side because of the presence of the sigmoid. The sigmoid is retracted toward the midline and steadied by an assistant. The common iliac artery is identified. No ureter can be seen at this point. The assistant steadies the sigmoid while the surgeon picks up and divides the posterior parietal peritoneum above the level of the artery in the course of the normal path of the ureter.

FIGURE 2. Stay sutures are placed on the divided edges of the peritoneum. The dilated proximal end of the ureter is found and traced to the narrow point of obstruction.

FIGURE 3. The periureteral tissue is dissected as the assistant keeps the ureter under tension, using instruments as gently as possible.

FIGURE 4. A cleavage plane between the ureter and surrounding bed is developed and a heavy silk suture passed beneath the ureter. This is tied and held long, stay sutures are placed, and the ureter is divided with a sharp knife. To reduce the amount of spillage, a suction tip should be available.

FIGURE 5. The assistant elevates the ureter gently out of its bed by traction on the stay sutures as the surgeon mobilizes the ureter from the underlying tissue. Here, as in other operations on the ureter, the surgeon should try to establish the cleavage plane in the tissues around the ureter, staying away from the actual ureter itself in order to protect its blood supply. It may, however, be necessary to free up the ureter as far as the kidney pelvis.

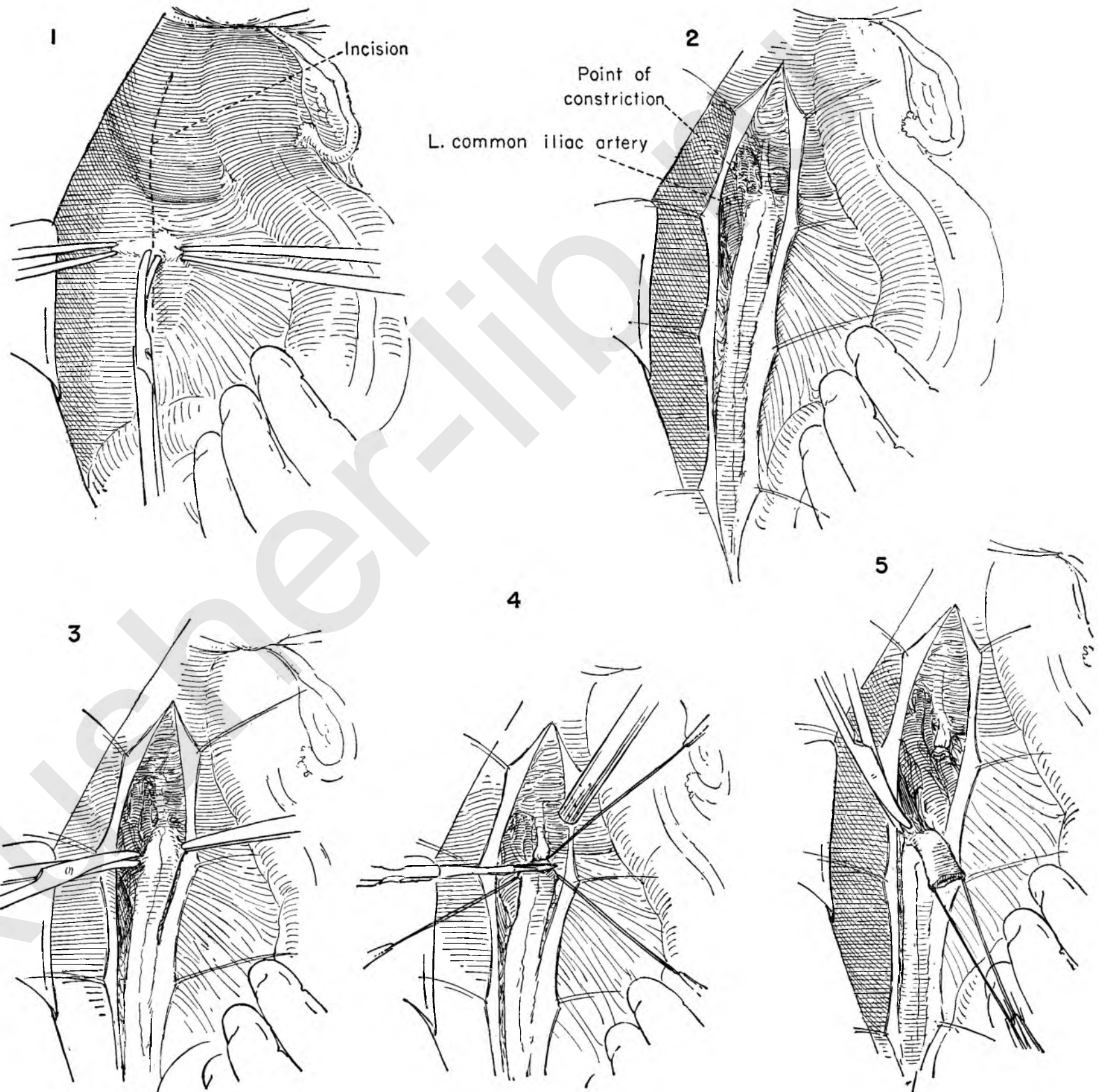


FIGURE 6. With the ureter thoroughly mobilized, the surgeon now directs his attention to the anterior abdominal wall. Kelly clamps at widely separated intervals are placed on the peritoneum. With the handle of the knife the surgeon then peels the peritoneofascial layer away from the abdominal wall musculature.

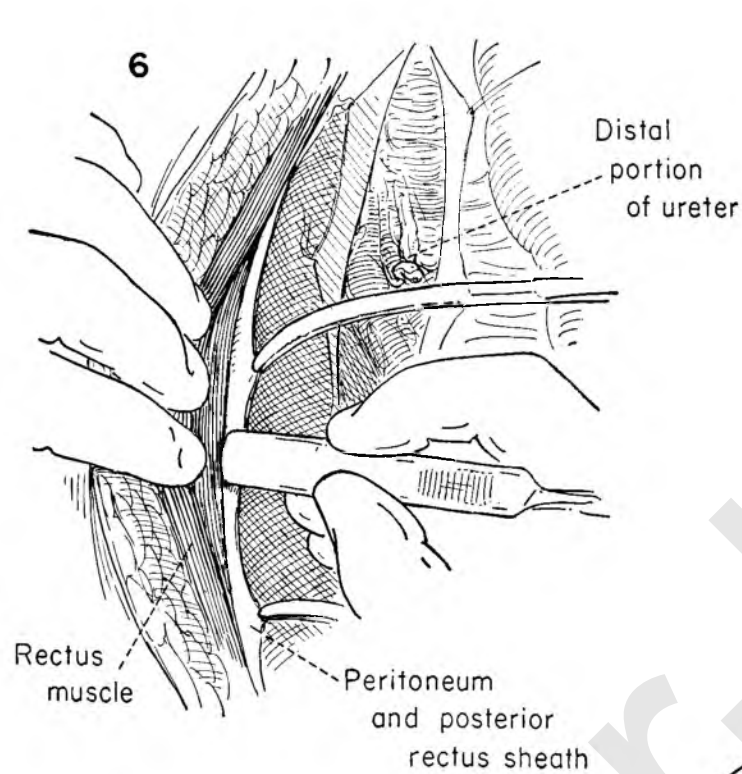


FIGURE 7. The peritoneum has been separated from the muscles for a considerable distance. A Kelly clamp is then inserted in the tissue plane created by the separation of the peritoneum. The tip of the clamp emerges from beneath the peritoneum at the site of the ureteral dissection. The surgeon then grasps the stay sutures on the ureter and pulls it into the retroperitoneal tissue plane.

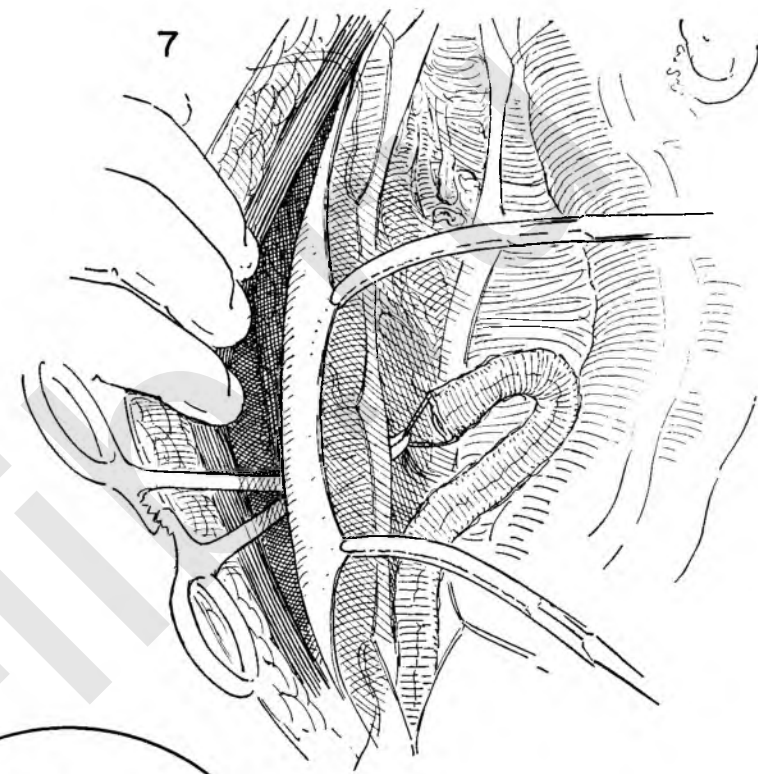
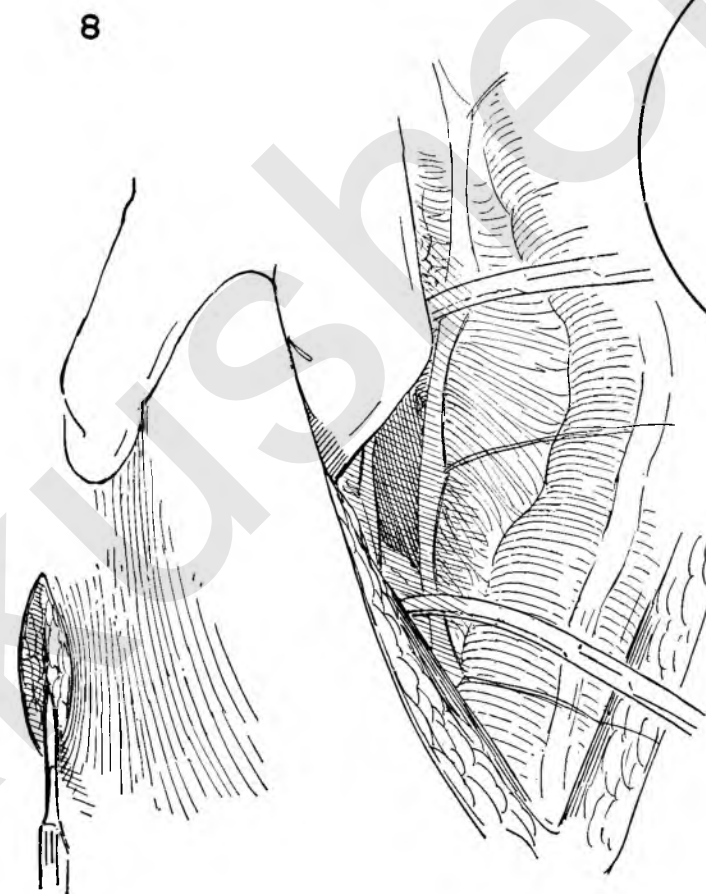
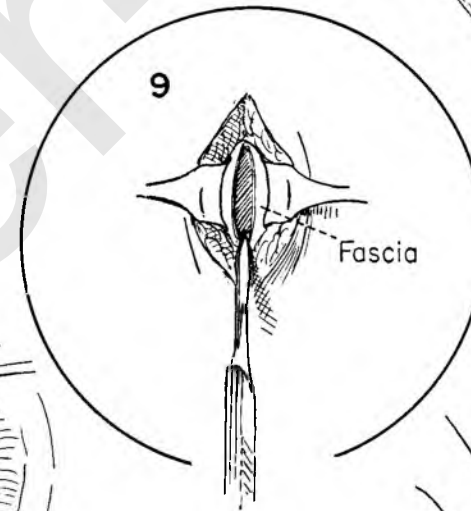


FIGURE 8. The site of the skin incision will be determined by the thickness of the abdominal wall in relation to the length of available ureter. The optimum position is probably at about the level of the anterior superior spine in the nipple line. If the ureter is short, it may of necessity be placed higher and more to the lateral side.



The surgeon introduces the left hand into the peritoneal cavity, steadying the abdominal wall from beneath as he incises the skin at the point of election.

FIGURE 9. Small skin retractors are placed in the wound to expose the underlying fascia. The fascia is incised widely, exposing the oblique fibers of the external oblique muscle. The muscle is divided in line with its fibers.



The opening in the fascia should be a wide one in order to avoid compression of the ureter which will almost invariably result in subsequent stricture at the level of the fascia.

FIGURE 10. A Kelly clamp is introduced through the stab wound and grasps the stay sutures on the ureter. The assistant aids in the exposure by elevating the clamps placed on the peritoneal edge.

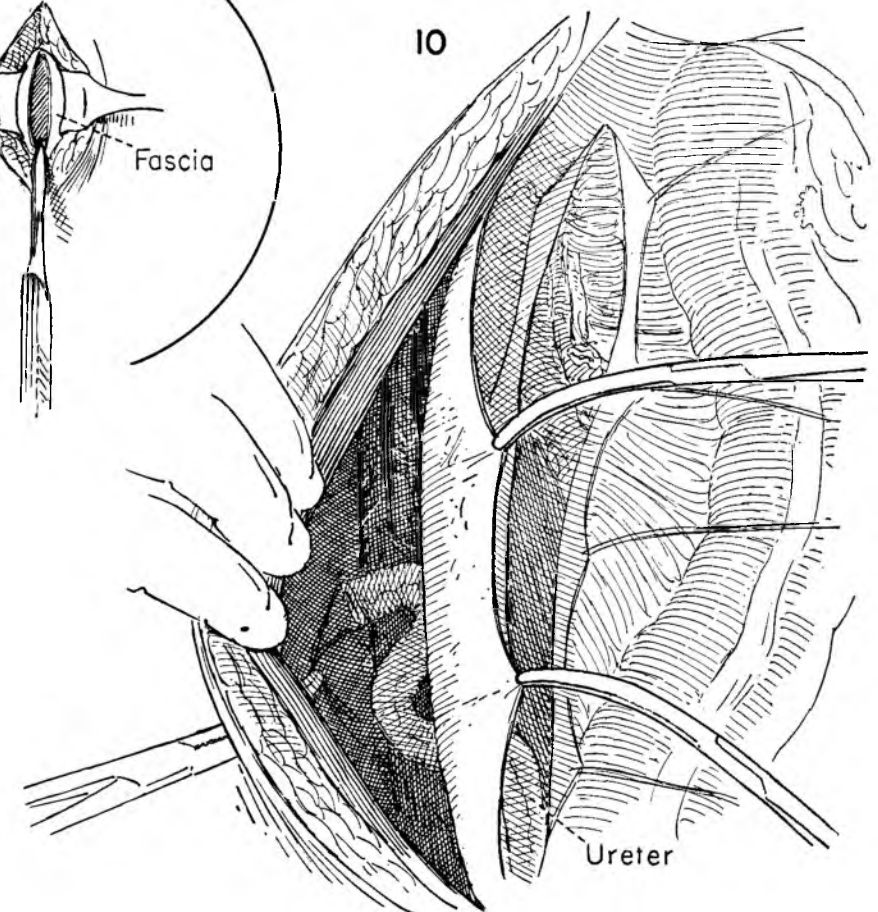


FIGURE 11. The ureter is drawn through the opening in muscle and fascia to lie easily on the skin without tension. Since there is a marked tendency of the ureter to retract, an excess of ureter above the skin level is an asset.

FIGURE 12. The lumen of the normal ureter may require enlarging before suture to the skin. Holding the ureter on tension, the surgeon incises the wall away from the intrinsic vessels for about $\frac{1}{4}$ inch.

FIGURE 13. To avoid a tendency to form a slitlike orifice with resulting constriction as healing takes place, a semicircle of skin is excised on both sides of the ureter.

FIGURE 14. The split end of the ureter is sutured to the skin with carefully placed fine catgut loosely tied.

FIGURE 15. This shows the completed opening with skin closure.

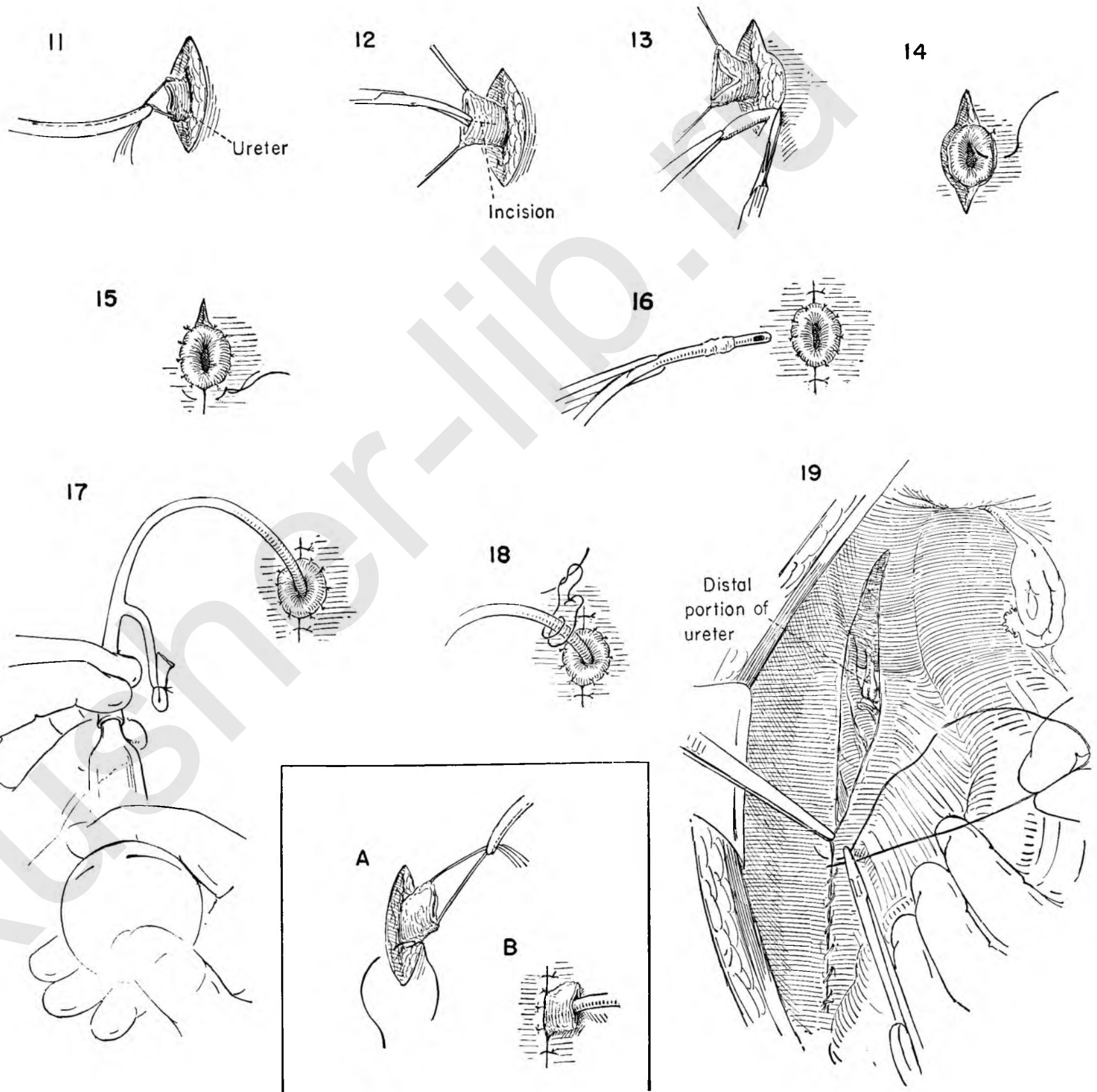
FIGURE 16. The surgeon inserts a Foley catheter into the ureter with smooth forceps. This is an essential step.

FIGURE 17. The catheter is introduced into the kidney pelvis. The Foley bag is inflated with saline solution and its tube tied. The position of the catheter is tested by injecting saline solution with an Asepto syringe. A free passage of fluid in both injection and aspiration should be established. If the aspirate is bloody, the catheter has been inserted too far and must be withdrawn and its position rechecked.

FIGURE 18. Since the catheter is a permanent part of the management of skin ureterostomy, it must be fixed in place with a skin suture placed lateral to it.

INSETS A AND B. As an alternative method the ureter may be fixed to the skin with interrupted sutures placed in the periureteral tissue. The wall of the ureter is not included. The redundant end is allowed to rest on the abdominal wall.

FIGURE 19. The rent in the posterior parietal peritoneum is then sutured with a running atraumatic catgut suture. The abdominal wall is closed.



Operations on the Abdominal Wall

The discussion of abdominal wall procedures revolves around alternate methods of entering the abdominal cavity, together with a description of the operations designed to correct the various types of hernia.

The paramedian incision is the one most generally used to enter the abdominal cavity for pelvic pathology. Inasmuch as the preoperative diagnosis of pelvic disease carries with it a moderate percentage of error, this incision gives the surgeon wider latitude in carrying out procedures over and above those originally planned in the pelvis. It likewise permits a thorough exploration of the rest of the abdominal cavity.

There are, however, definite procedures which can be localized to the pelvis. When the operative indications are confined to the uterus and adnexa without the likelihood of associated pathology, the surgeon may elect to enter the peritoneal cavity through a transverse lower abdominal or Pfannenstiel type of incision.

This method of entering the abdomen has many advantages over and above the esthetic consideration. Excellent exposure is provided the surgeon for any procedure confined to the uterus or adnexa. Myomectomy, salpingectomy, oophorectomy, suspension operations and, when there is no doubt of pathology, hysterectomy may all be satisfactorily managed through either of these incisions.

PFANNENSTIEL INCISION

The Pfannenstiel incision has stood the test of time. The cosmetic effect, of course, is excellent. Though the skin is divided in a transverse direction, the muscles are separated in the midline rather than sectioned. The incision in the peritoneum is made in the long axis. A risk of hematoma formation and subsequent sepsis represents the only disadvantage of this incision.

The advantage of the Pfannenstiel incision over the transverse one lies in the fact that the recti muscles are retracted rather than divided, thus lessening the danger of postoperative hernia.

TRANSVERSE INCISION

The transverse incision is made just above the hairline overlying the mons veneris. The fascia, recti muscles and peritoneum are all divided transversely. Because of the division of the muscles, the incision tends to gape open and a maximum amount of exposure is obtained with a minimum of retraction. With the patient in the Trendelenburg position, the bowel shows little tendency to get in the way. A modicum of gauze is necessary to keep the intestine out of the operative field. The sparse use of gauze reduces the trauma incident to handling the bowel and results in less postoperative discomfort from gas pain. These are the advantages of the transverse incision.

There are definite disadvantages. The operative field is adequate for operations confined to the pelvis, but inaccessibility of the appendix may present a technical problem in removal through this type of incision. There is also the unquestioned disadvantage of dividing rather than separating the muscle bundles. Unless the surgeon is meticulous in the reconstructive phase of the operation, the patient runs the risk of an incisional hernia. With care in reapposing the muscle bundles, this danger is negligible. Because there is some increased tendency to bleed, these wounds may become infected despite attempts to drain the lateral angles of the wound.

When used electively, the advantages tend to outweigh the disadvantages.

REPAIR OF ABDOMINAL WALL DEFECTS

By and large a hernia developing postoperatively in a midline or paramedian incision will appear in the lower end of the wound, though there may be a defect in its entire length. Adequate repair calls for reapposition of the muscles in the midline. Extensive dissection of the hernia sac is necessary with identification and exposure of the normal musculature and fascia.

FASCIAL REPAIR

The use of fascia lata taken from the patient's thigh for reinforcement of the repair of postoperative hernia is advisable if there is any doubt of the ability of the local structures to maintain closure. The fascial strips should not try to bridge a gap, but must be placed without tension.

INGUINAL HERNIA

The repair of inguinal hernia in women is a simpler surgical procedure than in the male. Except for the constant proximity of the external iliac artery, there are no important structures in the operative field such as the spermatic cord in the male. If necessary, the round ligament may be sacrificed in the interest of a stronger repair. If any reinforcement of normal tissue is necessary, the surgeon may construct a flap of external oblique fascia, leaving it attached at the spine of the pubis. The free end of the fascial strip may then be used as suture material to supplement the interrupted silk suture of conjoined tendon, muscle and fascia to Poupart's ligament. This is the so-called MacArthur modification of inguinal hernia repair.

FEMORAL HERNIA

This is a common type of hernia in the female. The repair may be accomplished in two ways. The entire dissection of

the sac may be carried out below the level of the inguinal ligament. An oblique incision is made in the skin overlying the hernial sac. This is then dissected free, the neck of the sac isolated and the opening closed. The defect beneath the inguinal ligament medial to the femoral vessels is then repaired by suturing the ligament to the underlying pectineus fascia.

Recently the exposure of choice has been identical with the incision used for inguinal hernia repair. By dividing the fibers of the transversalis at the base of the inguinal canal the surgeon approaches the sac at the site of its occurrence. By gentle dissection it is then possible to isolate the sac, draw it above Poupart's ligament, tie off the neck of the sac and close the incision in the manner of repair of an inguinal hernia. In essence, a femoral hernia is converted to an inguinal hernia.

It may be necessary to combine the two procedures above and below the ligament when an extensive hernia has become so incarcerated that it cannot be delivered from above. The surgeon should keep constantly in mind that a sliding hernia of the bladder may be present. If the wall of the sac appears to be abnormally thickened, one should be suspicious of the presence of the bladder.

UMBILICAL HERNIA

This defect seems to be more common in the female. Repair is effected by making a transverse elliptical incision to encompass the defect. The sac may ramify out beyond the limits of the skin incision. The dissection must be carried out laterally until normal fascia is encountered and the borders of the defect revealed.

The fascial edges are then separated from the peritoneum of the neck of the sac. When the sac is opened, omentum or bowel may be found densely adherent to it and must be dissected free with considerable care before trimming away the redundant peritoneum. The repair is accomplished by closing the peritoneum, bringing the recti together in the midline and closing the fascia through imbrication in a transverse direction after the method suggested by W. J. Mayo.

DIASTASIS RECTI

As the result of repeated pregnancy the muscles of the abdominal wall become separated widely, leaving a pronounced weakness in the midline which often extends above the level of the umbilicus. Suturing the muscle bundles in the midline combined with imbrication of the fascia repairs the defect. At times it may be advisable to remove the umbilicus in order to get a more satisfactory closure.

PFANNENSTIEL INCISION

The advantages of the Pfannenstiel incision have already been discussed. The transverse incision in the fascia overlying longitudinal separation of the rectus muscles results in a strong closure with minimal postoperative discomfort to the patient.

The exposure beyond the pelvis is definitely limited, however, and the surgeon will be wise if he restricts its use to patients who are not fat and whose pelvic pathology will not require extensive lateral dissection or the removal of large masses.

FIGURE 1. A curved incision is made just above the hairline, extending beyond the border of the rectus muscles on both sides. If it is placed near the symphysis, the subcutaneous fat interferes with clean wound healing. The lateral extension of the incision provides mobility of the skin flap that must be turned up.

FIGURE 2. The bleeding vessels are secured and tied and skin towels applied. The assistant holds up on Kelly clamps placed on the superior edge of the incised fascia on either side of the linea alba as the surgeon completes the section of the fascia in the midline.

FIGURE 3. Another Kelly clamp is placed on the lower fascial edge and elevated to expose the lateral margin of the rectus. The surgeon then extends the fascial incision laterally.

FIGURE 4. Kelly clamps placed on the lower fascial edge are elevated by the assistant as the surgeon separates the sheath from the underlying lower rectus muscles with the knife handle. The pyramidalis muscle remains attached to the fascia.

FIGURE 5. The upper segment of anterior rectus sheath is freed from the underlying muscles in a similar manner.

FIGURE 6. Individual vessels can be seen arising in the muscle and perforating the fascia. These vessels must be clamped, divided and tied as they are encountered.

FIGURE 7. The separation of fascia from muscle proceeds in the direction of the umbilicus, as the assistant continues to elevate the Kelly clamps. The dissection is carried upward far enough to permit an adequate midline longitudinal incision.

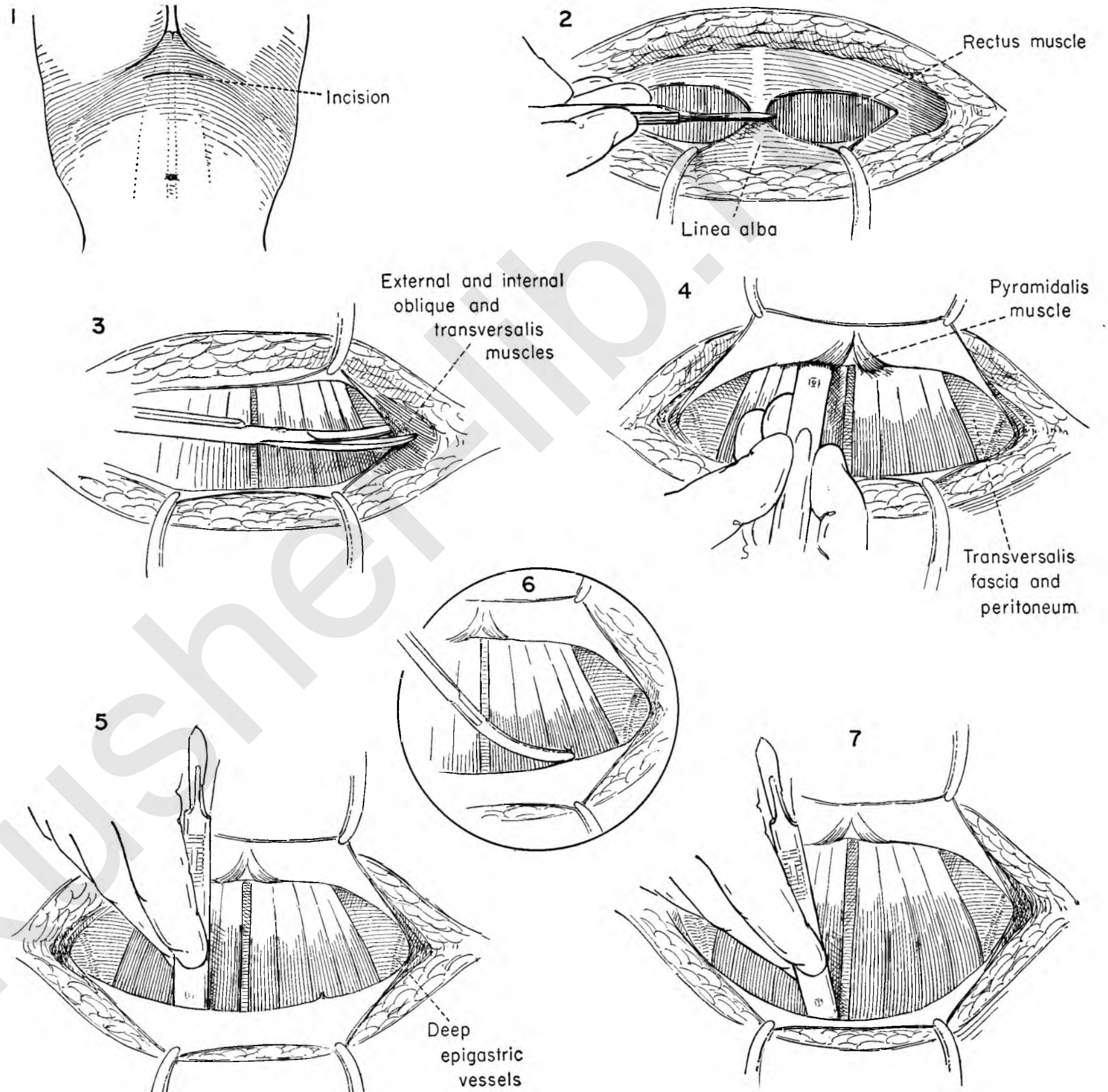


FIGURE 8. The rectus muscles are separated from the transversalis fascia and peritoneum in the midline by elevation of the medial borders with forceps and gentle dissection with the knife handle.

FIGURE 9. The assistant and surgeon pick up the fascia and peritoneum with toothed forceps opposite one another as the surgeon begins the incision into the abdominal cavity. This should be well above the symphysis pubis to avoid the possibility of damage to the bladder.

FIGURE 10. A Deaver retractor is placed in the upper margin of the wound to expose the extent of the separation of anterior sheath from the muscles. Kelly clamps are placed on the peritoneal edges and the peritoneum divided in upward and downward directions as the surgeon provides protection to the small bowel by inserting the index and middle fingers beneath the peritoneum in the line of incision.

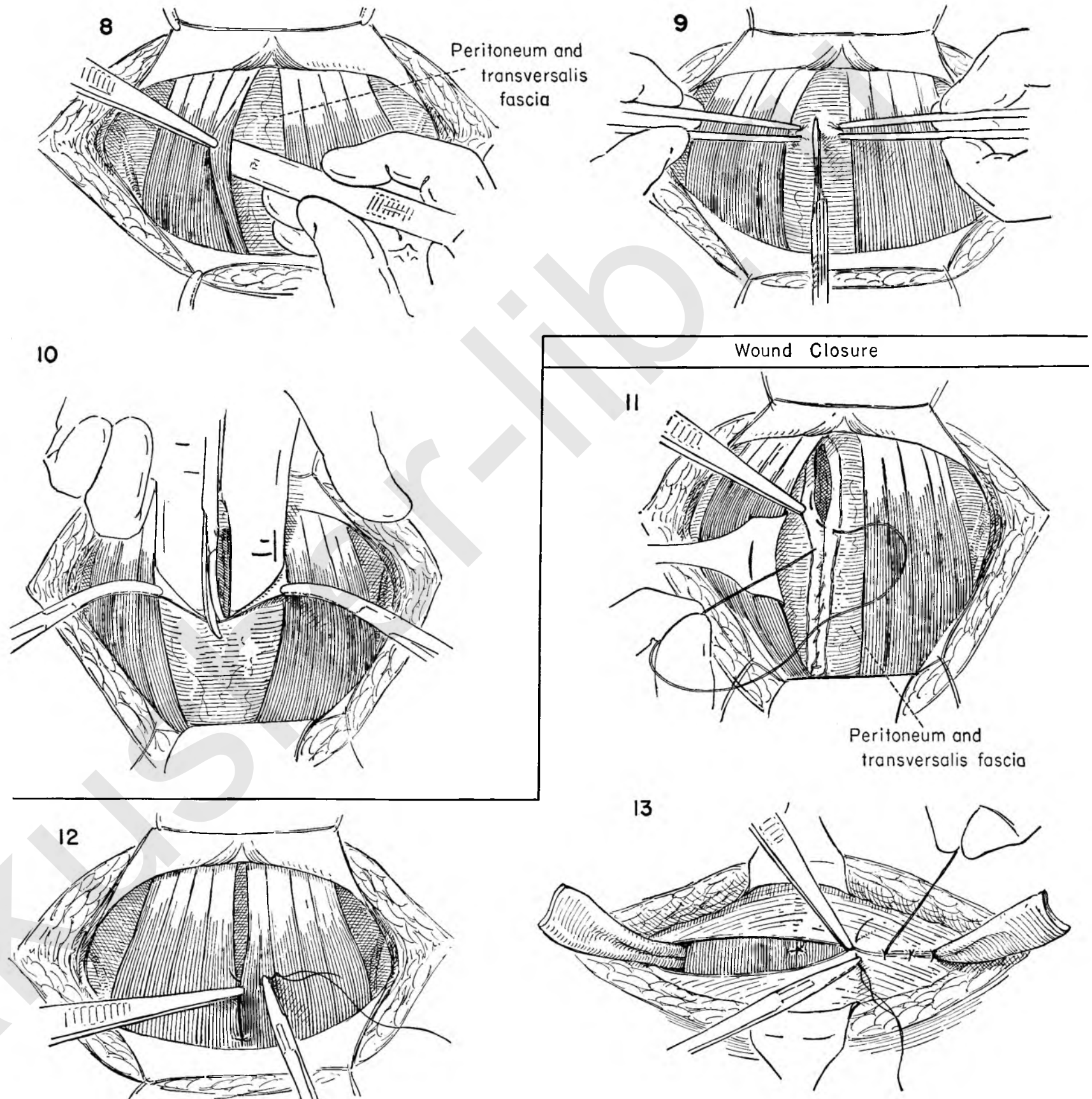
The abdominal operation is then completed, and the surgeon now prepares to close the wound.

CLOSURE OF THE PFANNENSTIEL INCISION

FIGURE 11. Closure of the peritoneum and transversalis fascia begins at the upper end of the wound. A running atraumatic chromic catgut suture approximates serosal surfaces of the peritoneum as the assistant keeps the suture on tension and the surgeon elevates the incised edges of the two layers with toothed forceps.

FIGURE 12. A stronger closure will result if the rectus muscles are approximated in the midline by interrupted plain catgut sutures.

FIGURE 13. Any bleeding points beneath the fascial flap must be secured and the wound completely dry before attempting to close the fascial defect. The fascia is then closed with interrupted silk sutures. The assistant leaves each suture long until the next is tied, and elevates each one in turn to aid the surgeon in placing the next stitch. Drains should be placed in the lateral angles of the wound beneath the fascia level, since these wounds carry the potential danger of hematoma formation.



TRANSVERSE INCISION

When there is no question that the pathology is localized in the lower pelvis, the transverse low abdominal incision dividing the rectus muscles has much to recommend it. The chief advantages are that, after dividing the muscle, little retraction and packing back of the intestine are necessary. This incision gives a much wider exposure to the deep pelvis than can be obtained by the Pfannenstiel approach.

FIGURE 1. The transverse incision is made in the abdominal wall approximately 2 inches above the symphysis pubis and extends to the inguinal ligament on both sides.

FIGURE 2. The skin and subcutaneous fat are divided down to fascia, bleeding vessels are controlled, and protective towels are applied to the wound edges. The assistant and the surgeon retract the skin edges as the surgeon incises the fascia overlying each rectus muscle.

FIGURE 3. The surgeon divides the linea alba while the assistant holds the upper border of the fascial edge on tension with Kelly clamps placed to either side of the midline.

FIGURE 4. To completely expose the lateral border of the rectus muscle, clamps are placed at the angles of the fascial incision, and the incision is carried laterally to the full extent of the fascial envelope which encloses the rectus muscle.

FIGURE 5. The surgeon then separates the transversalis fascia and peritoneum from the under surface of the rectus by gently passing the gloved index finger beneath the muscle. Occasionally the thin, adherent transversalis fascia may interfere with complete exposure of the fingertip. In this case the surgeon then lightly incises the fascia with a knife as he pushes the fascia upward to bulge into the wound.

FIGURE 6. The index finger of the surgeon's left hand is then inserted beneath the right rectus muscle from the lateral side to the midline. The surgeon then elevates the muscle as he begins to divide its fibers transversely.

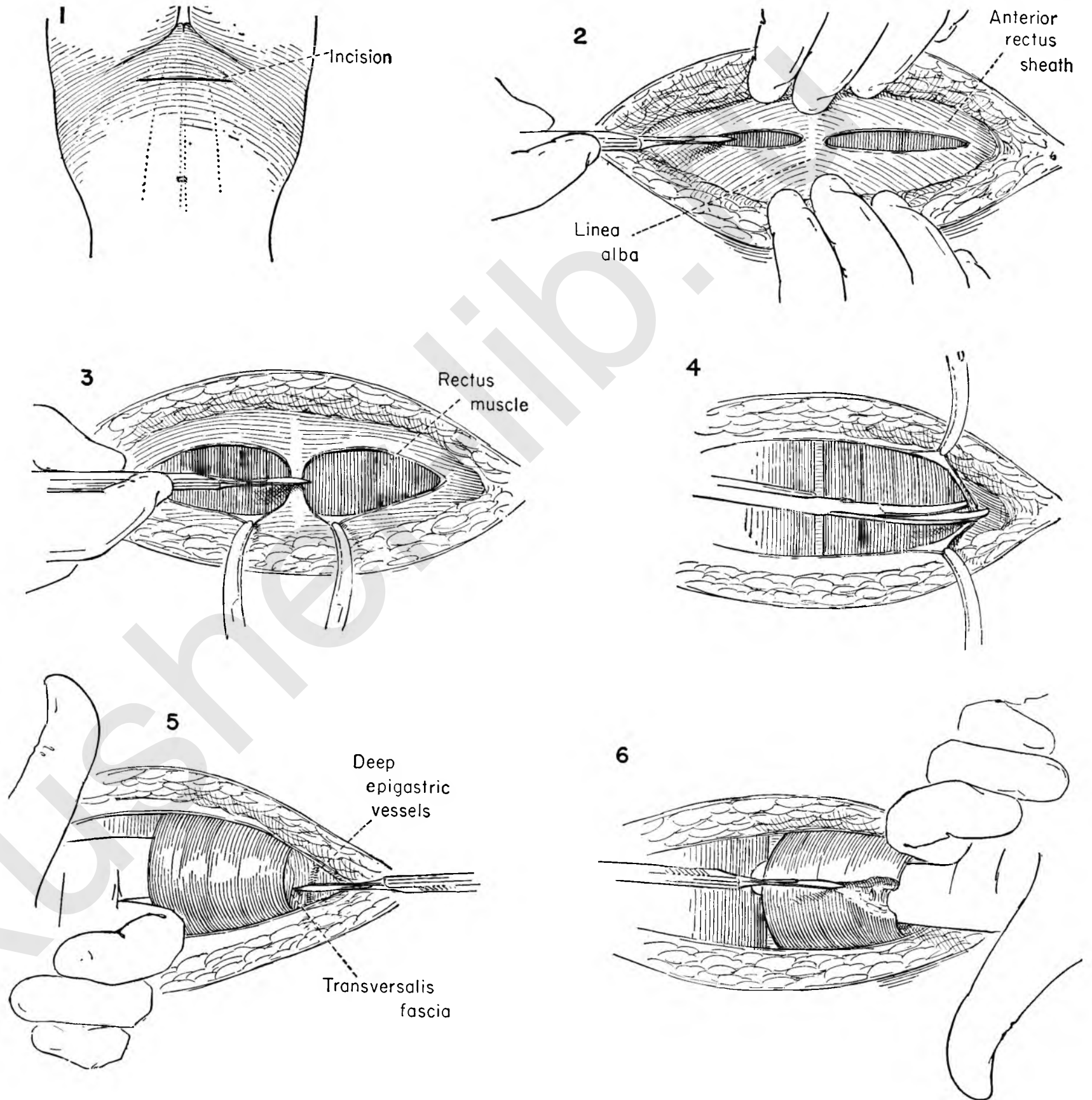


FIGURE 7. The assistant secures any bleeding vessels as they appear in the transection of the muscle and ties them. Because of the absence of any posterior sheath at this level, the upper end of the muscle bundle will retract sharply if it is completely divided at this stage. This will make the reconstructive phase more complicated. The index finger is placed beneath the muscle bundle as the surgeon divides it to the point where only a few muscle fibers remain.

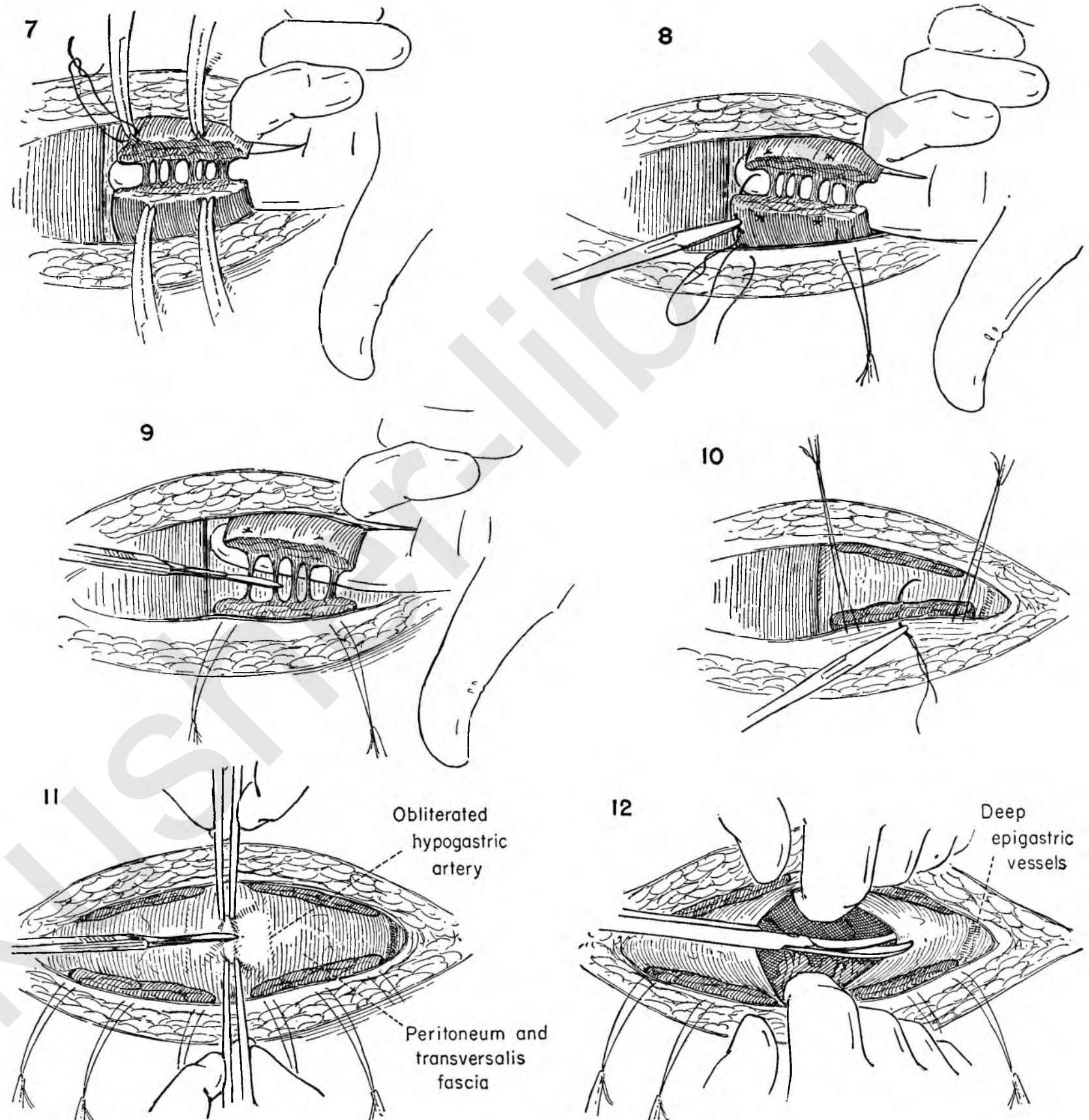
FIGURE 8. To keep the divided muscle and anterior rectus sheath together as one bundle and avoid the retraction, mattress sutures are placed through the overlying fascia and muscle at the medial and lateral angles. The sutures are left long and clamped with hemostats. Only the upper end need be handled in this way.

FIGURE 9. The surgeon elevates the remaining muscle fibers and divides them, completing the incision through the entire bundle.

FIGURE 10. Bleeding points are sought for and controlled. The assistant then elevates the lateral stay sutures while the surgeon places a third mattress suture in the midportion of the divided muscle. The same steps are carried out on the left rectus muscle.

FIGURE 11. The surgeon and the assistant then pick up the peritoneofascial layer with toothed forceps in the center of the exposure. The forceps and incision should be placed in the middle of the exposed layer in order to avoid the dome of the bladder, which lies just beneath. The obliterated hypogastric vessels can be seen lying on the peritoneum on either side of the midline. The surgeon then prepares to divide the peritoneum between the elevated forceps.

FIGURE 12. The abdominal cavity has been entered. The surgeon and the assistant now provide further exposure by inserting gloved fingers into the opening of the peritoneum and elevating it. The peritoneal incision is then continued laterally in both directions. Care must be taken not to damage the deep epigastric vessels which lie on the peritoneum at the lateral margins of the wound.



The abdominal operation has been completed, and the wound is now ready for closure. This must be done with care to prevent subsequent development of a hernia. The risk of a weak wound is somewhat greater in this type of incision, but can be minimized by meticulous closure.

FIGURE 13. The surgeon closes the peritoneum and transversalis fascia with a running chromic catgut suture.

FIGURE 14. The assistant now elevates the stay sutures previously placed through the muscle and fascia of the upper rectus muscle. The surgeon begins to place the first mattress suture through the fascia and muscle of the upper bundle, beginning at the lateral margin.

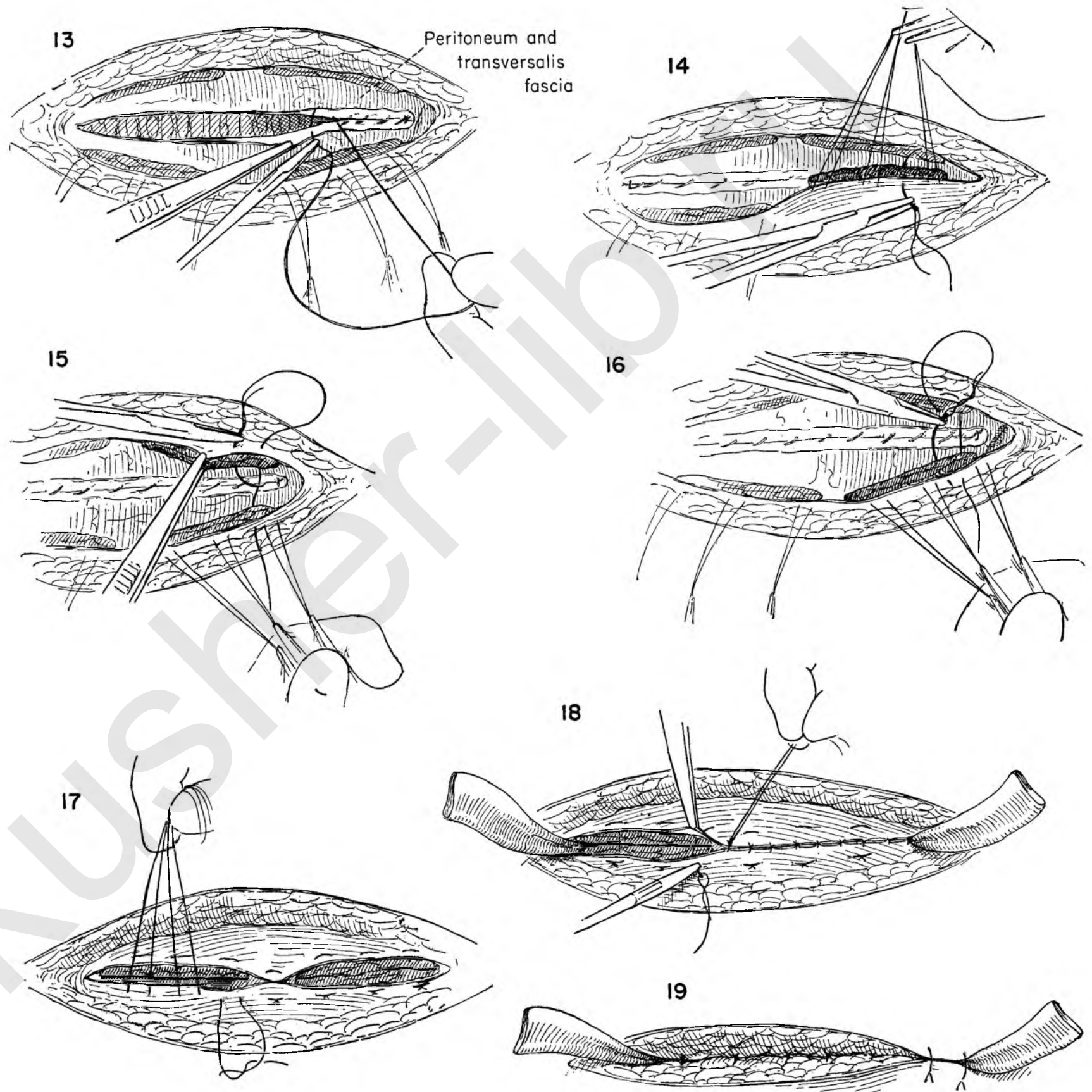
FIGURE 15. The first leg of the mattress suture then continues to the lower muscle bundle, is carried from beneath the muscle to the superior surface of the fascia, and is then returned through the fascia and muscle about 1/4 inch away.

FIGURE 16. The assistant again elevates the upper rectus muscle with the traction sutures as the surgeon begins to return the mattress suture through muscle and fascia from the inferior surface of the muscle. The mattress suture is completed as the needle emerges on the superior surface of the fascia approximately 1/4 inch medial to the point of origin and parallel to it.

FIGURE 17. An entire series of these mattress sutures is placed through the upper and lower muscle bundles on both sides. The initial stay sutures have been removed and the mattress sutures have been tied on the right side.

FIGURE 18. The fascial edges are then brought together over the approximated rectus muscle bundles with interrupted catgut sutures.

FIGURE 19. The fat is approximated with interrupted sutures. Drains are placed in the lateral angles of the wound beyond the rectus muscles.



INCISIONAL HERNIA

After a previous abdominal operation performed through a longitudinal incision, both the fascia and the muscle of the lower abdominal wall may be so weakened that the peritoneum and abdominal contents herniate through the defect. The hernia may include the entire incision, but more commonly is located in the lower portion of the wound.

FIGURE 1. The old scar is to be excised. The redundancy of the skin will determine the amount to be sacrificed.

FIGURE 2. Bleeding vessels are clamped and tied. The old skin incision with attached fat is dissected from the normal fascia in the lower portion of the wound. It is important to identify the normal fascia in relation to the central defect.

FIGURE 3. Inasmuch as the hernia may have lateral extension, the dissection must proceed with care. The assistant draws the hernial defect toward him to permit the surgeon to dissect the lateral prolongation of the hernia from the underlying fascia.

FIGURE 4. The central defect in the fascia has been identified throughout its circumference. The fat of the abdominal wall is being dissected back laterally.

FIGURE 5. The surgeon draws the peritoneum overlying the hernia taut as he outlines the lateral extent of the hernia and divides the fascia, exposing the medial edge of the rectus muscle beneath. The extension of the incision will follow the dotted lines.

FIGURE 6. The surgeon elevates the divided fascial edge and mobilizes the rectus muscle from the fascia above as well as the peritoneum below. The muscle is then freed around its entire circumference.

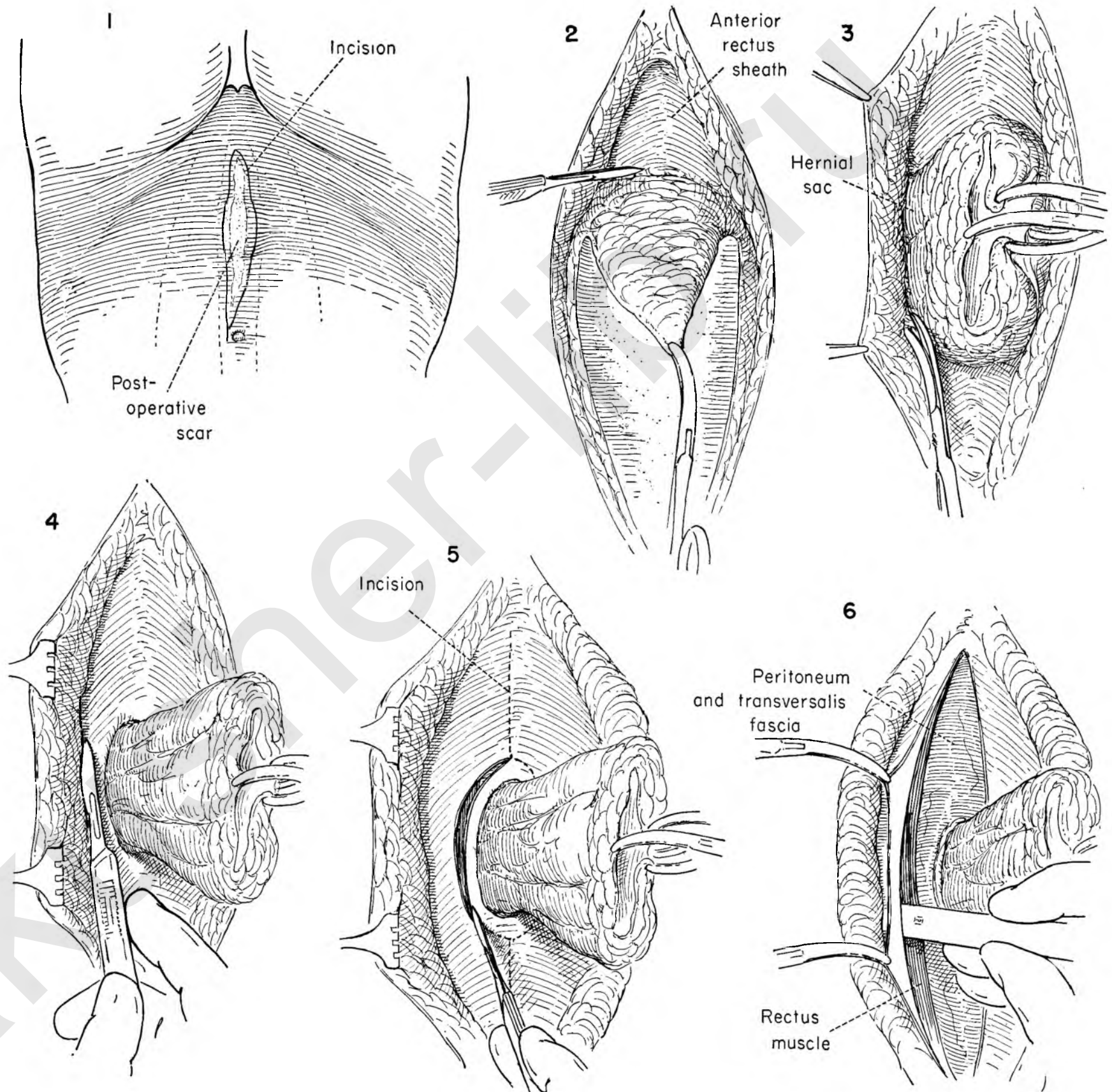


FIGURE 7. The muscle edge is evident around the entire border of the central hernia. The first assistant and surgeon gently pick up the fascioperitoneal covering in the lateral center of the hernial sac. Omentum and small bowel may be adherent to the under surface. The incision is made through the peritoneum with great care.

FIGURE 8. The surgeon's forefinger is gently inserted in the peritoneal opening and any omental attachment teased off. Hemostats are placed on the cut edges to provide traction and increase the exposure. Adherent bowel must be dissected free.

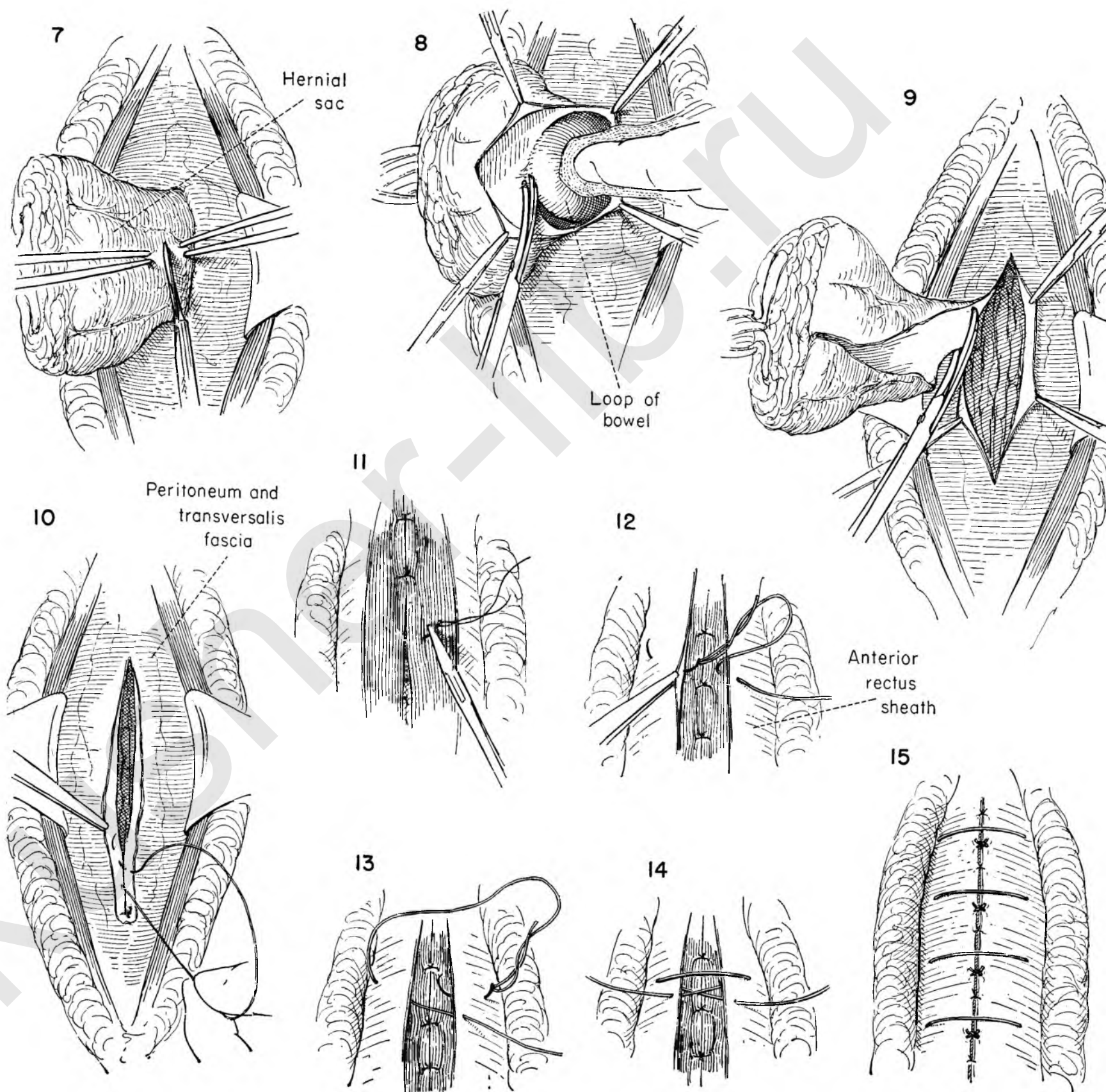
FIGURE 9. The hernial sac, now free of all attachments, is excised and the peritoneum opened for a short distance above and below.

FIGURE 10. The omentum is drawn over the small intestine to prevent adhesion to the new incision. The peritoneum and transversalis fascia are now closed with a running chromic catgut suture.

FIGURE 11. The rectus muscles are approximated in the midline with interrupted sutures of plain catgut.

FIGURES 12, 13 AND 14. To strengthen the wound closure, a pulley type of catgut suture is used. In Figure 12 the suture in the fascia has been started on the right, close to the edge. It then passes beneath the fascia on the opposite side, emerging approximately 3/4 inch from the edge. In Figure 13 the suture returns to the right side and enters the fascia on the superior surface at the same distance from the edge. In Figure 14 the suture emerges close to the left fascial edge. The result is a vertical figure-of-eight suture. Tying of the suture produces a stay suture effect.

FIGURE 15. The sutures are tied and the interstices closed with interrupted sutures.



REINFORCEMENT OF HERNIA REPAIR BY FASCIA LATA

Despite the increasing use of wire as suture material, there remains a definite place for fascial repair to reinforce a weakened abdominal wall.

FIGURE 1. The preliminary steps have repaired the hernia. The fascia is now being closed with interrupted sutures of silk, cotton or wire.

FIGURE 2. Retractors placed in a small transverse skin incision in the upper thigh provide exposure for a 1/2-inch incision in the fascia.

FIGURE 3. Short longitudinal incisions are made in the fascia at either end of the transverse incision.

FIGURE 4. The cut end of fascia is drawn through the end of a fascia stripper and grasped with a clamp.

FIGURE 5. The clamp is steadied as the stripper is thrust down the leg beneath the skin for its entire length. Rotation of a wheel severs the fascial strip at the distal end, and the strip is withdrawn.

FIGURES 6, 7 AND 8. A silk suture designed to prevent fraying is placed through and around the divided end and firmly tied.

FIGURE 9. The prepared end is threaded on a Gallie needle, and the loose end sutured to the long fascial strand to prevent its pulling out of the needle. The fascial strip is used as a running suture beginning in the fascia at the lower end of the wound.

FIGURE 10. The needle passes through the fascial strip below the ligated end to anchor it.

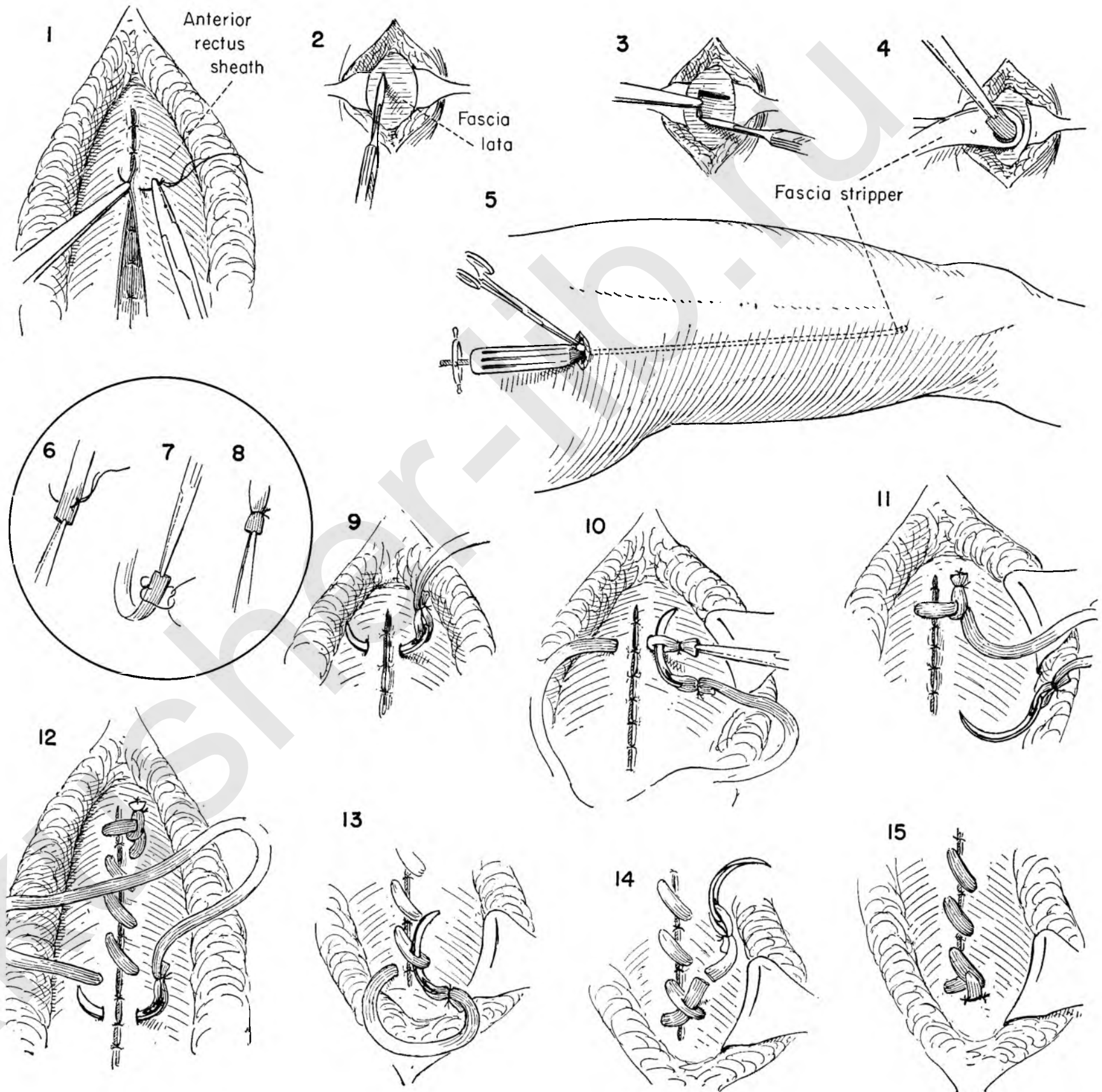
FIGURE 11. The free end is tacked to the rectus fascia with interrupted silk sutures.

FIGURE 12. The continuous running suture of fascia should be applied without tension.

FIGURE 13. The fascial suture passes through the midportion of the strand at the upper end.

FIGURE 14. The fascial strip with needle attached is then divided, leaving a free end which must be anchored.

FIGURE 15. The free end is sutured to the underlying fascia with interrupted silk sutures.



INGUINAL HERNIA

Inguinal hernia in the female is far less common and much easier to repair than the same hernia in the male. A more complete closure of the inguinal canal is possible, for the surgeon is not concerned with preserving the blood supply to the testis.

FIGURE 1. The skin incision parallels Poupart's ligament from the anterior superior spine of the ilium to the pubic spine and about 1 inch above it.

FIGURE 2. The external oblique fascia is cleaned of fat and the external ring identified. The fascia is then divided in line with its fibers, taking care not to injure the ilio-inguinal nerve lying just beneath it.

FIGURE 3. The edge of the internal oblique muscle is held back to permit the surgeon to identify the sac, which is then dissected from its bed. Careful dissection will avoid injury to the deep epigastric vessels, which lie at the medial border of the internal ring. Stay sutures on the edge of the external oblique fascia keep the operative field open.

FIGURE 4. After assuring himself that the sac contains no bowel the surgeon opens it and explores the interior with a finger.

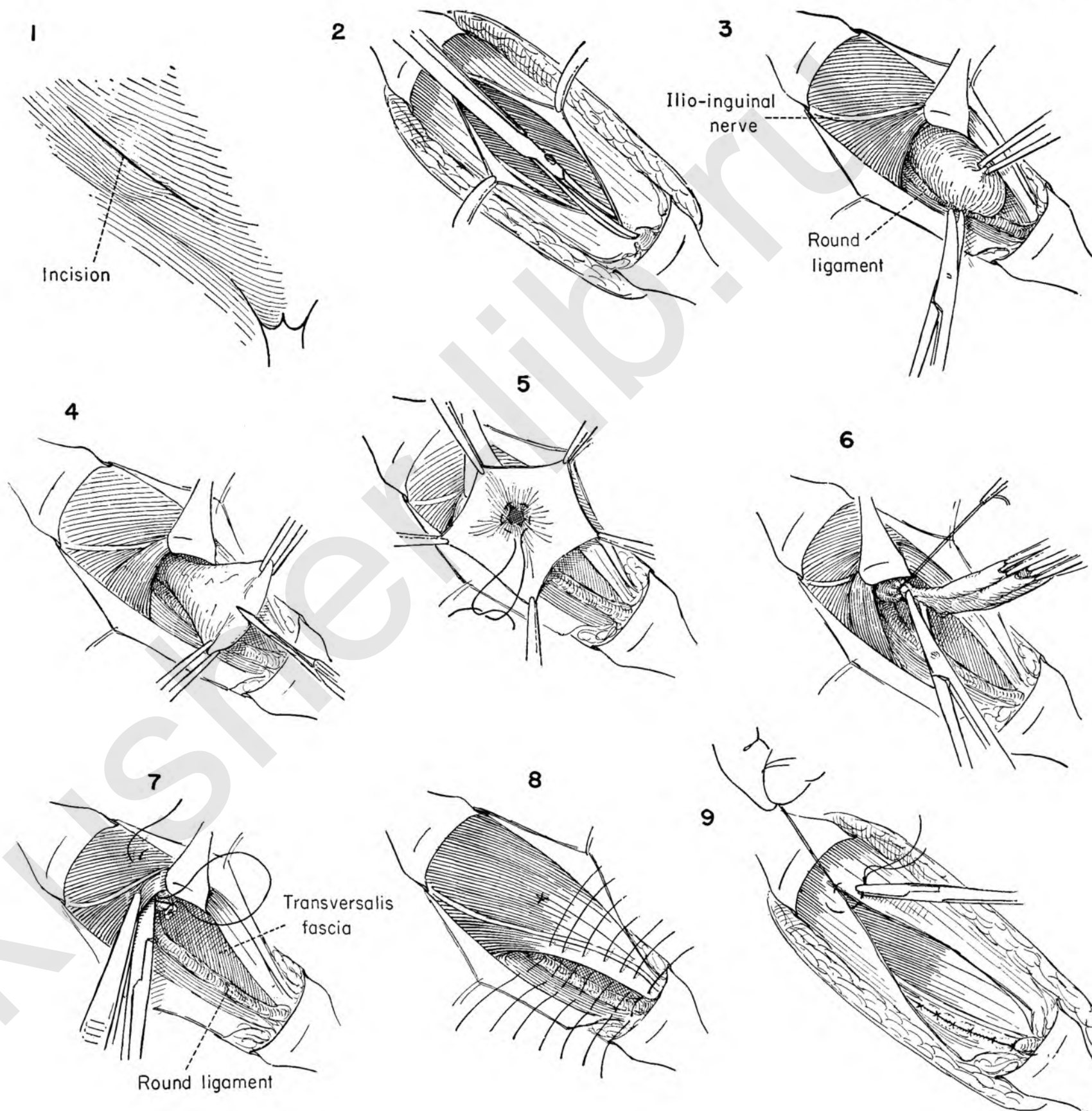
FIGURE 5. A purse-string suture is placed around the inside of the neck of the sac under direct vision and tied.

FIGURE 6. An outside transfixion ligature distal to the purse string ensures complete closure. The ends of this suture are left long after tying, and the sac is amputated.

FIGURE 7. A needle is threaded on each long end of the transfixion ligature and brought out through the internal oblique muscle. When the two ends are tied, the neck of the sac is transplanted upward.

FIGURE 8. Repair is effected by approximating the conjoint tendon to the pubic spine and inner aspect of Poupart's ligament with multiple interrupted silk sutures.

FIGURE 9. The external oblique fascia is closed with sutures of the same material.



FEMORAL HERNIA

The repair of femoral hernia, which is common in the female, may be accomplished either from above Poupart's ligament as in an inguinal hernia or from below it. When strangulation or incarceration is present, a combined approach may be indicated. The simplest approach is from below Poupart's ligament.

FIGURE 1. The incision begins above Poupart's ligament and comes down into the thigh over the center of the presenting bulge. The femoral vessels are in contact with the hernia lateral to the incision.

FIGURE 2. The sac is encountered directly under the skin incision and is retracted with forceps and gently dissected from the medial attachment with scissors.

FIGURE 3. The surgeon draws the sac to the medial side and dissects along the lateral border, taking care not to damage the femoral vessels and saphenous vein.

FIGURE 4. The sac has been dissected free and the neck exposed. The dome is then gently incised.

FIGURE 5. The thin-walled sac may contain small intestine or omentum. Should the sac appear thickened, beware of a possible sliding hernia containing bladder wall or, if the hernia is on the left, large intestine. The index finger in the sac returns the contents to the abdomen. Redundancy of omentum may be sacrificed. If the contents cannot be reduced, the operator should use the combined approach demonstrated in Plates 88 and 89.

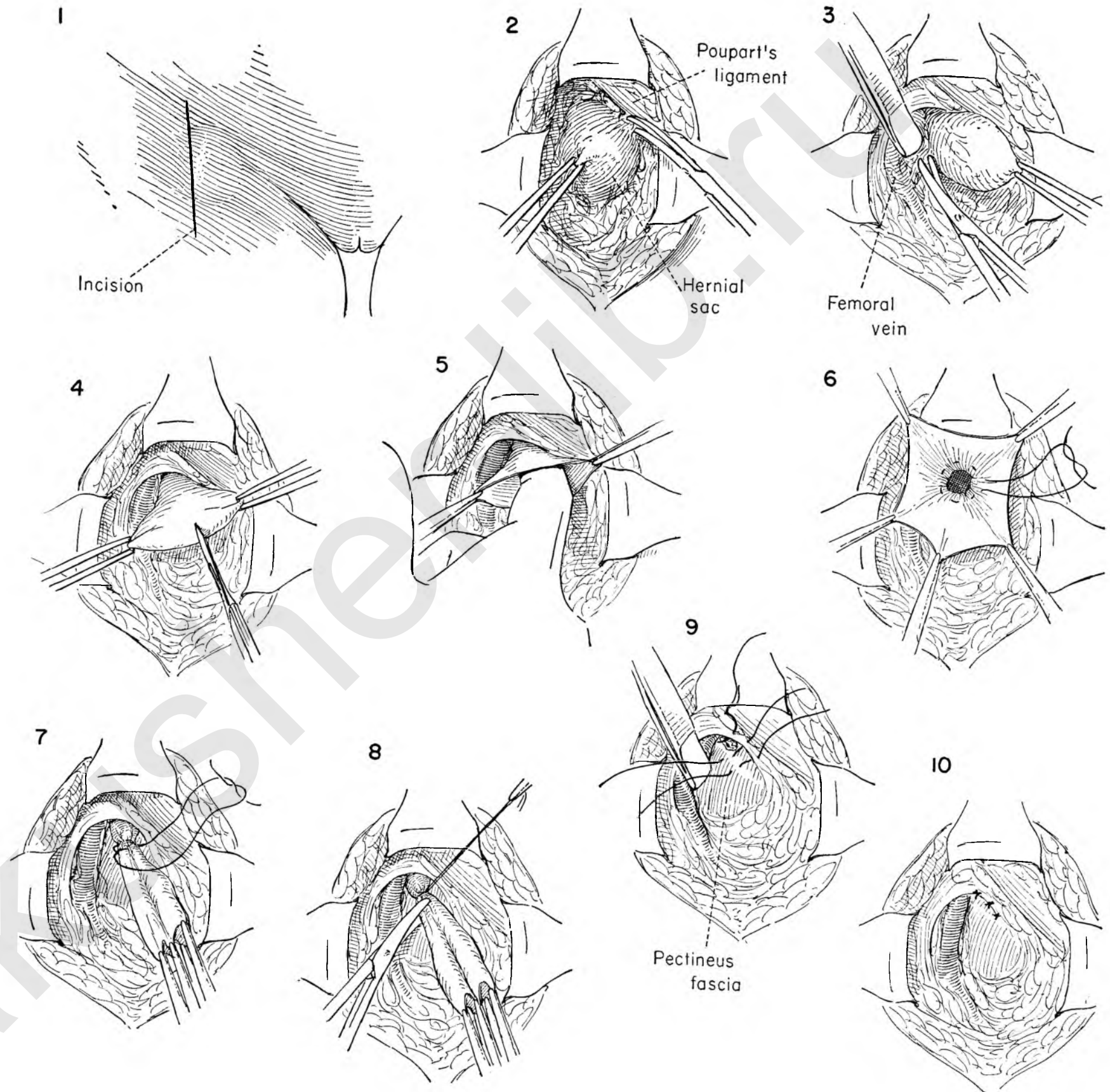
FIGURE 6. After identification of the neck of the sac a purse-string suture is used to close it.

FIGURE 7. The neck of the sac is then further closed with a transfixion suture. The femoral vessels should be retracted to prevent inadvertent damage.

FIGURE 8. The sac is held on traction and excised beyond the transfixing suture.

FIGURE 9. Retracting the femoral vessels, the surgeon now places the first suture of the repair. The interrupted sutures pass from Poupart's ligament above to the pectineus fascia below.

FIGURE 10. The defect in the femoral canal is now closed.



The most satisfactory approach to the reduction and repair of femoral hernia is made through an inguinal incision. The sac below Poupart's ligament can readily be delivered into the incision. If this is not easily accomplished, the lower edge of the skin incision may be retracted and the sac gently freed from below before drawing it above Poupart's ligament. The less restricted operative field makes this the ideal approach when incarceration or strangulation is present. The repair is more effective because the defect in femoral hernia is funnel-shaped with a broad base above. The attack on the base can be made directly upon it.

INGUINAL AND COMBINED APPROACH

FIGURE 1. The incision parallels the inguinal ligament, about 1 inch above it, and running from the spine of the pubis upward for about 3 inches.

FIGURE 2. The incision is carried down through the fat to the external oblique fascia. Bleeding points are controlled.

FIGURE 3. An incision is made through the external oblique fascia in the line of its fibers.

FIGURE 4. The ilio-inguinal nerve and round ligament are identified, and the internal oblique muscle and conjoint tendon exposed. The round ligament is freed from the floor of the inguinal canal.

FIGURE 5. The internal oblique muscle and round ligament are then retracted upward. The transversalis fascia is opened in order to expose the neck of the sac.

FIGURE 6. By gentle traction and blunt dissection the sac may be teased into the inguinal incision.

INSET A. When it is impossible to bring the sac into the operative field because of its size or adherent content, the lower edge of the incision may be retracted downward, exposing the sac below Poupart's ligament. The femoral vessels are identified, and the dissection is carried out as in Plate 87.

If the sac, though freed of attachments, is too large to be reduced, the sac may be opened and the contents returned to the abdomen or redundant omentum excised.

FIGURE 7. The entire hernia has now been reduced and brought into full view above the level of Poupart's ligament. The sac is being opened.

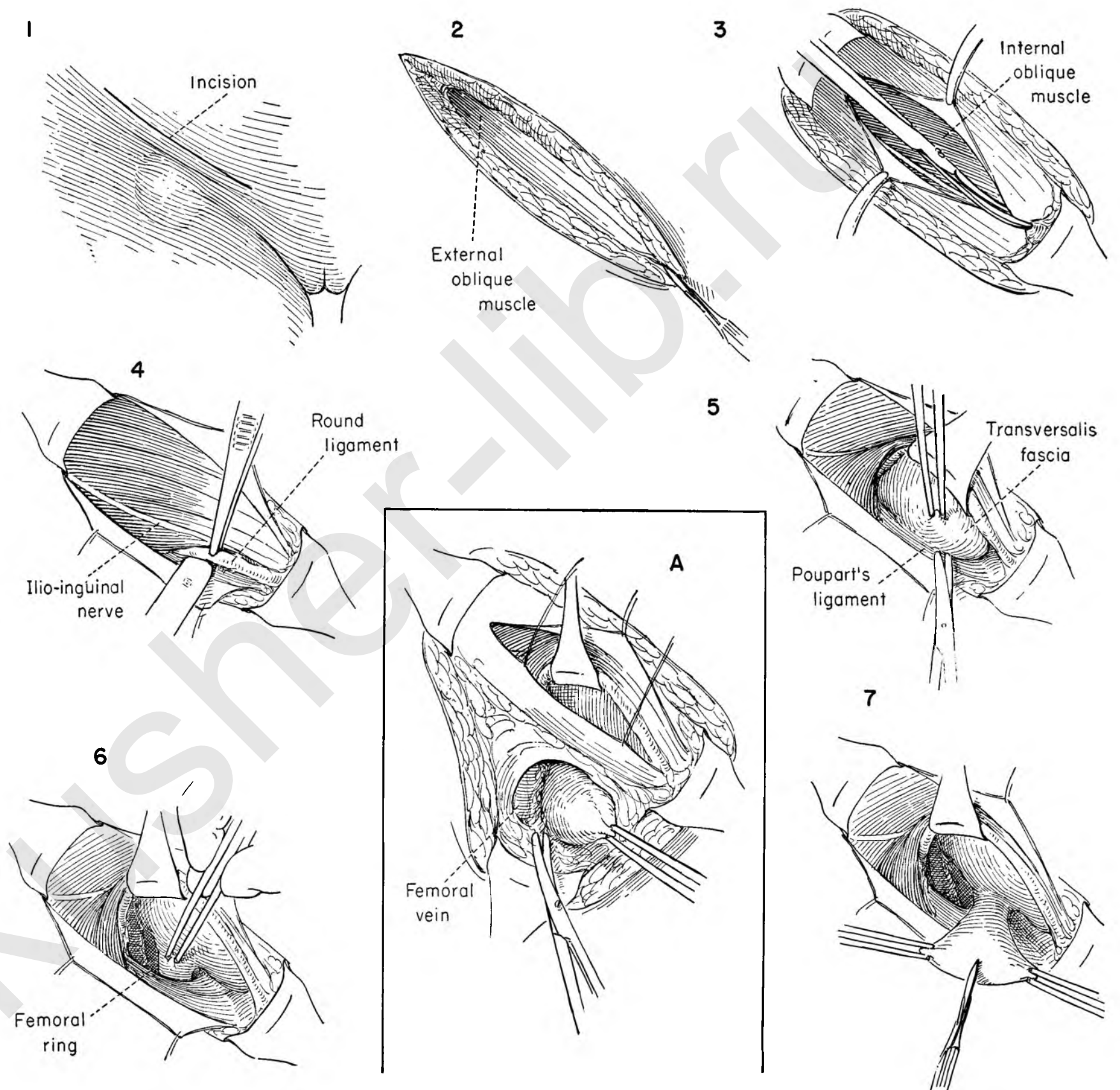


FIGURE 8. The interior of the sac is explored and the contents pushed back through the broad neck into the abdomen before placing a purse-string suture about the base.

FIGURE 9. With the contents out of the way, the purse-string suture has been placed around the inside of the neck of the sac.

FIGURE 10. Because the base is a broad one, a simple purse-string suture will not suffice. A transfixion suture is placed outside and distal to the ligated purse-string suture. This will seal off any interstices that might remain.

FIGURE 11. The transfixion suture and sac are held on tension as the sac is excised.

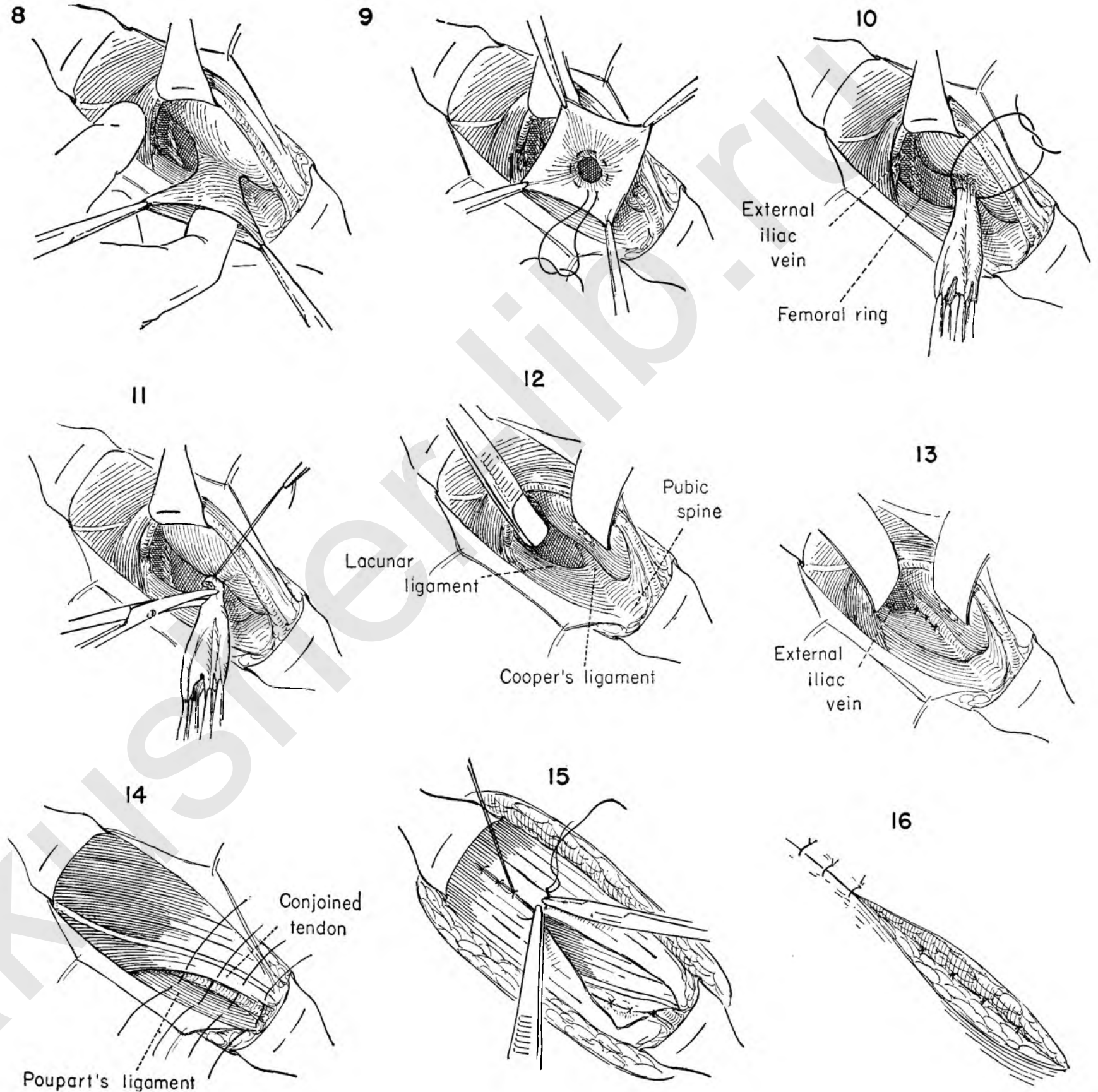
FIGURE 12. The defect in the femoral canal is closed by placing interrupted silk sutures through the lacunar ligament below Poupart's and Cooper's ligaments in the medial portion of the wound. The external iliac vessels are retracted as these sutures are placed to avoid possible damage.

FIGURE 13. The defect in the femoral ring has now been closed with interrupted silk sutures.

FIGURE 14. The balance of the repair now follows the steps outlined for simple inguinal herniorrhaphy. The conjoint tendon is sutured to Poupart's ligament with interrupted sutures. The deep epigastric vessels lie just medial to the point of disappearance of the round ligament and should be avoided.

FIGURE 15. The external oblique fascia is then closed with interrupted silk, cotton or fine wire.

FIGURE 16. Subcutaneous fat and skin are approximated in two layers.



UMBILICAL HERNIA

An umbilical hernia may appear either as a true umbilical hernia characterized by eversion of the umbilicus or more commonly as a para-umbilical hernia. Whatever the cause, the operative steps in eradication and repair are identical.

FIGURE 1. In the adult a transverse incision and repair with removal of the umbilicus is the technique least likely to result in recurrence.

FIGURE 2. An elliptical incision is outlined extensive enough to include the umbilicus, the palpable ramifications of the sac, and the redundant overlying skin.

FIGURE 3. The incision is carried down to the normal fascia as the assistant retracts the skin edge. This is done over the entire area mapped out for excision.

FIGURE 4. With normal fascia as a landmark, the surgeon elevates the block of tissue to be removed and exposes the anterior rectus sheath by dissecting off the overlying fat. The dissection is then carried toward the midline on all sides until the fascial covering of the hernial sac is encountered.

FIGURE 5. The sac and defect are now completely isolated and the extent of normal fascia to be used in the repair process adequately exposed.

The surgeon then sections the anterior rectus fascia transversely on either side of the defect. The dotted line indicates the direction of the incision to be made in the fascia around the neck of the sac in the midline.

FIGURE 6. The incision has been carried through the fascia overlying the hernia in the midline, thus connecting the two lateral incisions. A broad flap of rectus sheath is developed for use later in the repair.

FIGURE 7. The assistant applies traction to the sac as the surgeon incises it at its base. Kelly clamps are applied to the cut edges to provide exposure and avoid any damage to its contents.

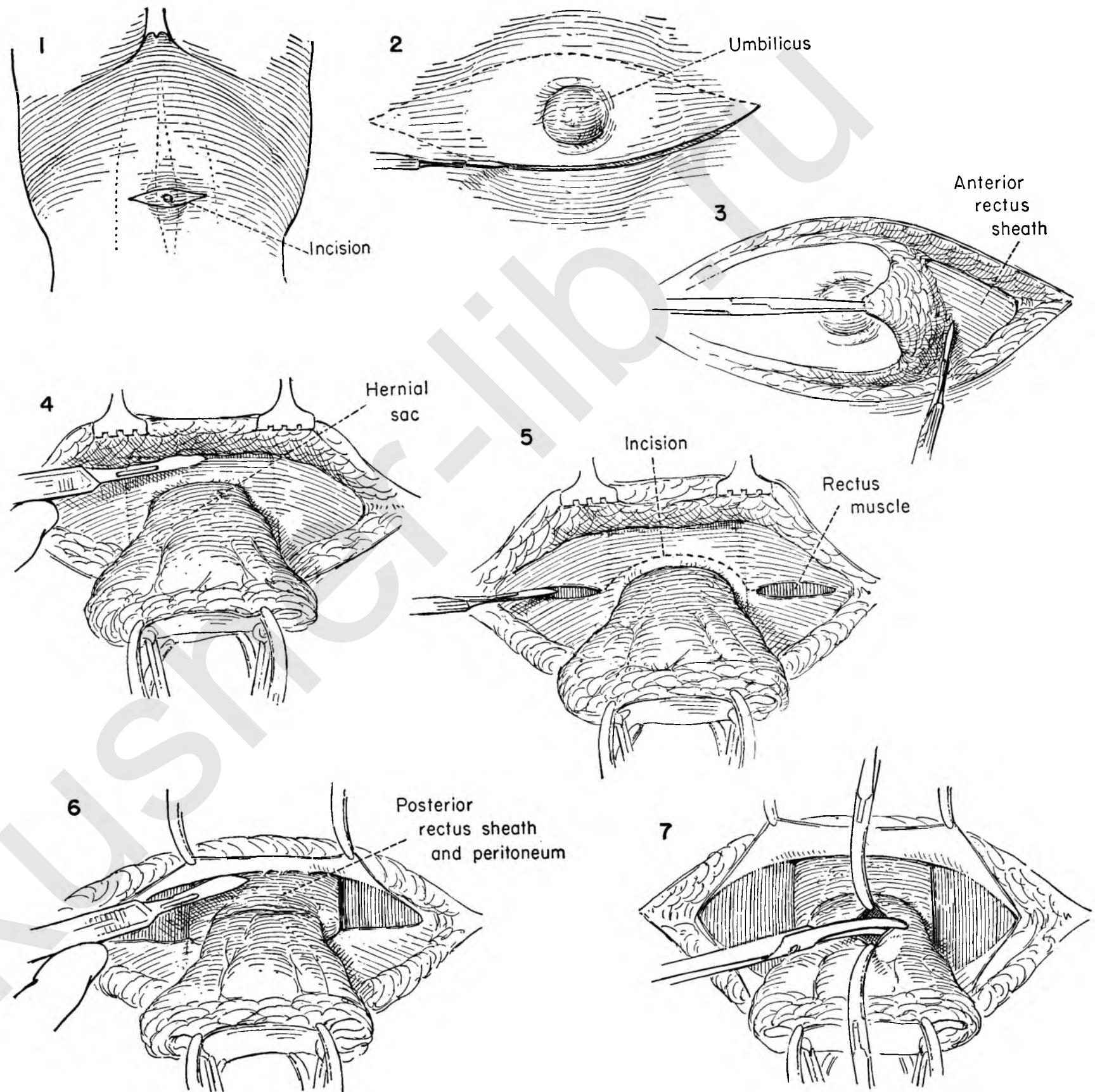


FIGURE 8. Invariably the omentum is adherent to the peritoneum lining the sac. This must be dissected free. Care must be taken in enlarging the opening in the sac because of the adhesions.

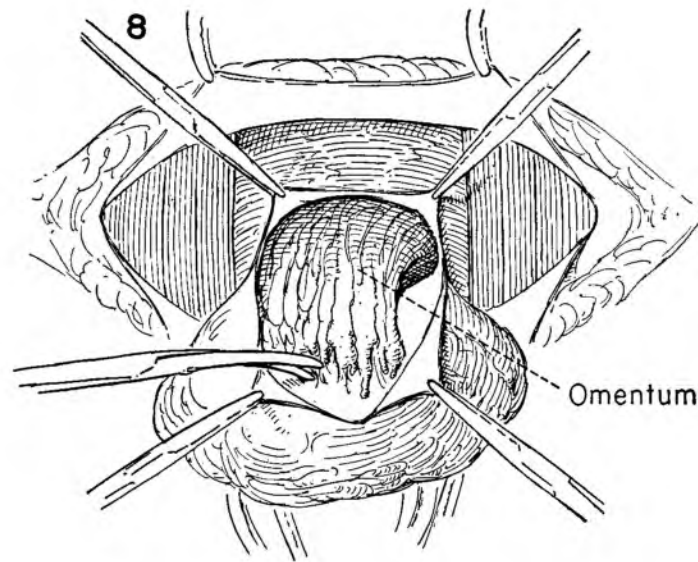


FIGURE 9. With the neck of the sac completely exposed and opened and the edges of the peritoneum held on traction with hemostats, the surgeon excises the redundant peritoneum and fascia.

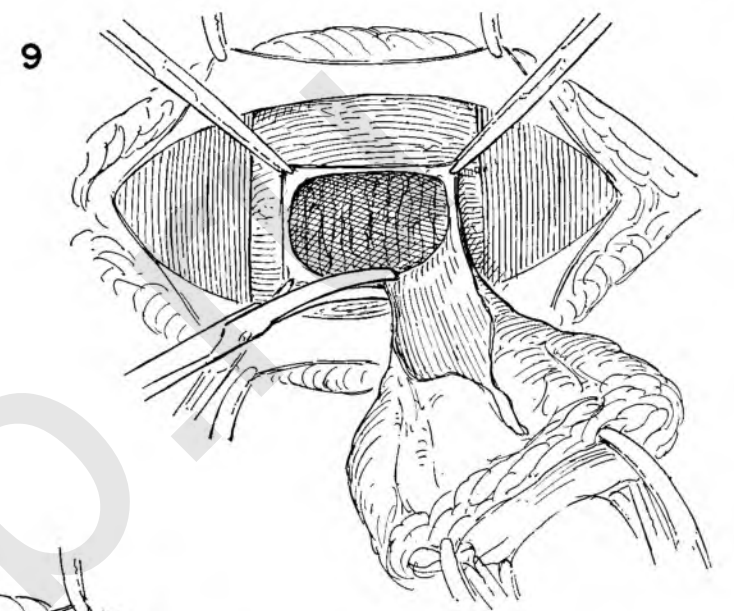


FIGURE 10. The circular defect is converted into an ellipse by lateral traction on Kocher clamps placed on the edges of the hernial opening. The upper and lower clamps simply aid in exposure as the surgeon starts the stitch to close the peritoneum and transversalis fascia.

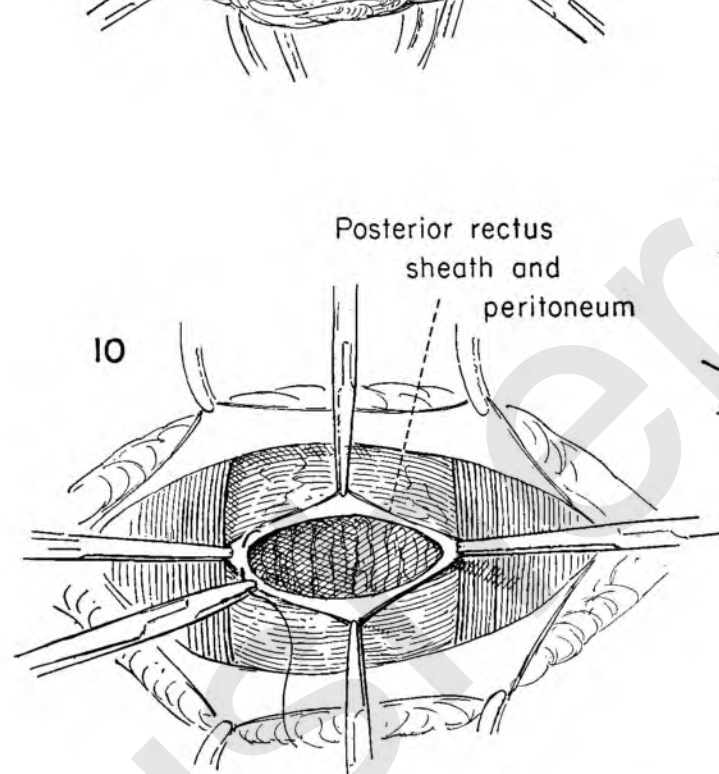


FIGURE 11. The peritoneofascial closure has been completed with a running catgut suture. A wide separation of the rectus muscles is apparent in the midline. The surgeon elevates the medial border of the right rectus and separates the muscle from its posterior sheath. This step is repeated on the opposite side.

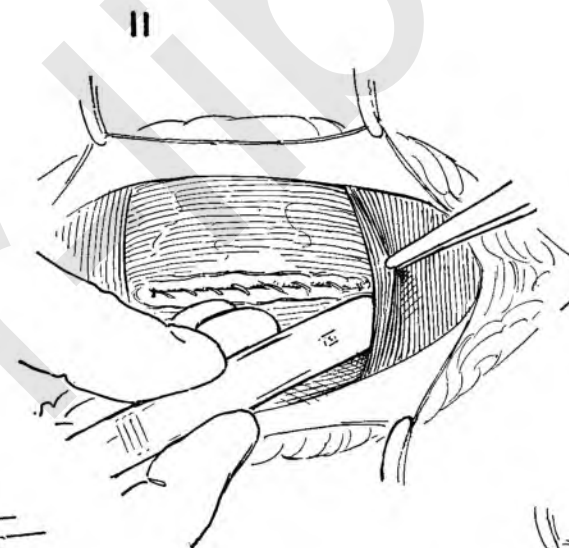


FIGURE 12. After mobilizing the rectus muscles so that the opposing edges lie easily without tension, the surgeon approximates them in the midline with interrupted sutures.

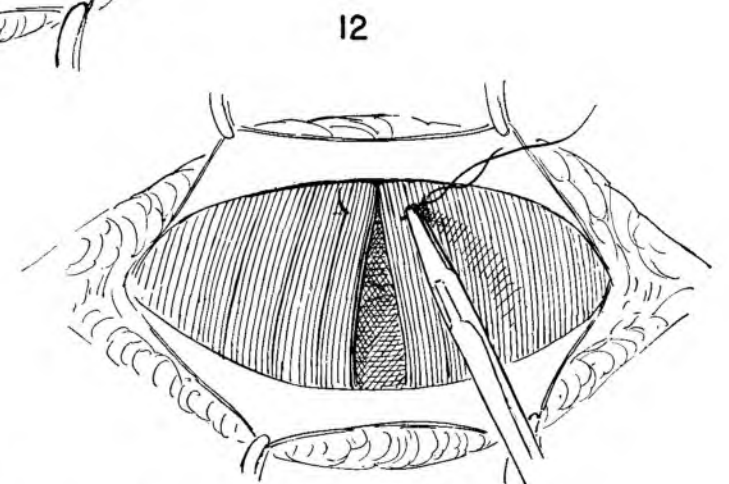
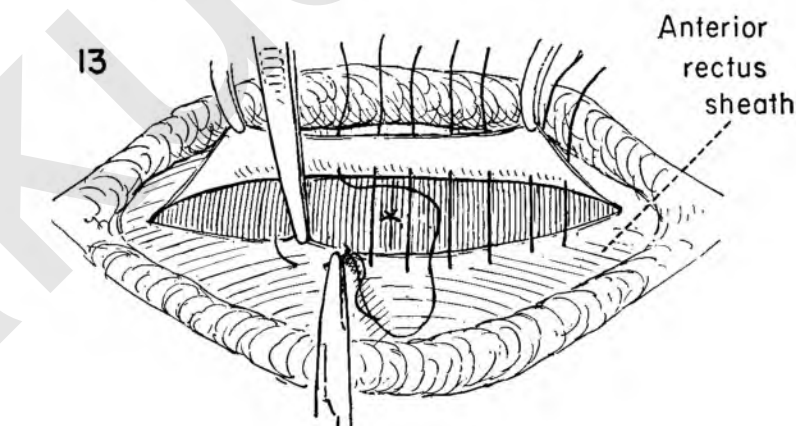


FIGURE 13. The anterior sheath has been separated from the underlying muscle at the lower edge through its entire extent in order to form a flap. This was done deliberately in order to be able to imbricate the aponeurotic sheath and provide a stronger abdominal wall repair.



The lower edge of the sheath is held upward by the assistant as the surgeon begins a series of mattress sutures. The suture enters the lower flap approximately 3/4 inch from the edge, and passes beneath it to pick up the upper edge and return through the fascia to reappear about 1/2 inch from the point of origin. A series of such sutures are placed through the entire transverse extent of the wound.

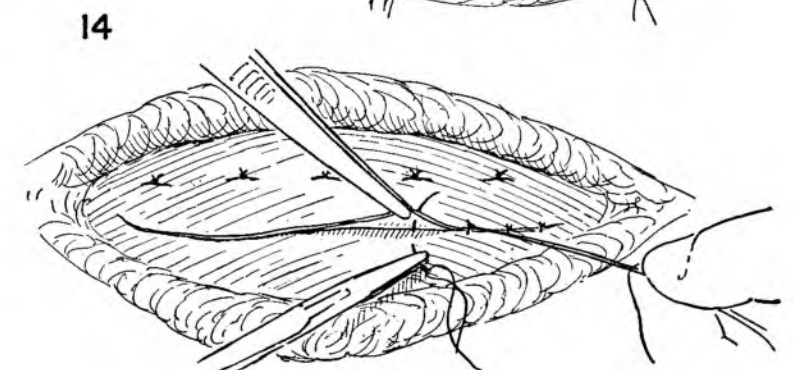


FIGURE 14. These sutures are tied, and the free edge of sheath is then tacked down with another series of interrupted sutures.

DIASTASIS RECTI

As the result of repeated pregnancy or previous operation the rectus muscles become widely separated. Since the separation is not confined to the lower portions of the recti, to perform adequate reapposition of the muscle bundles it is occasionally necessary to excise the umbilicus to avoid tension in the repair.

This operation is rarely done as the sole operation, but may be used in conjunction with other procedures calling for abdominal intervention.

FIGURE 1. The umbilicus has been excised and the outline of the incision indicated. The skin and subcutaneous fascia are dissected from the underlying rectus fascia. The limits of the lateral dissection are determined by the position of the retracted recti muscles. The extent of the separation of the two longitudinal muscles may be formidable. The defect in the peritoneum at the site of the removal of the umbilicus is closed with interrupted silk sutures.

The thinned-out medial borders of the recti are identified and the muscles laid bare in their entire extent by incising the anterior rectus sheath.

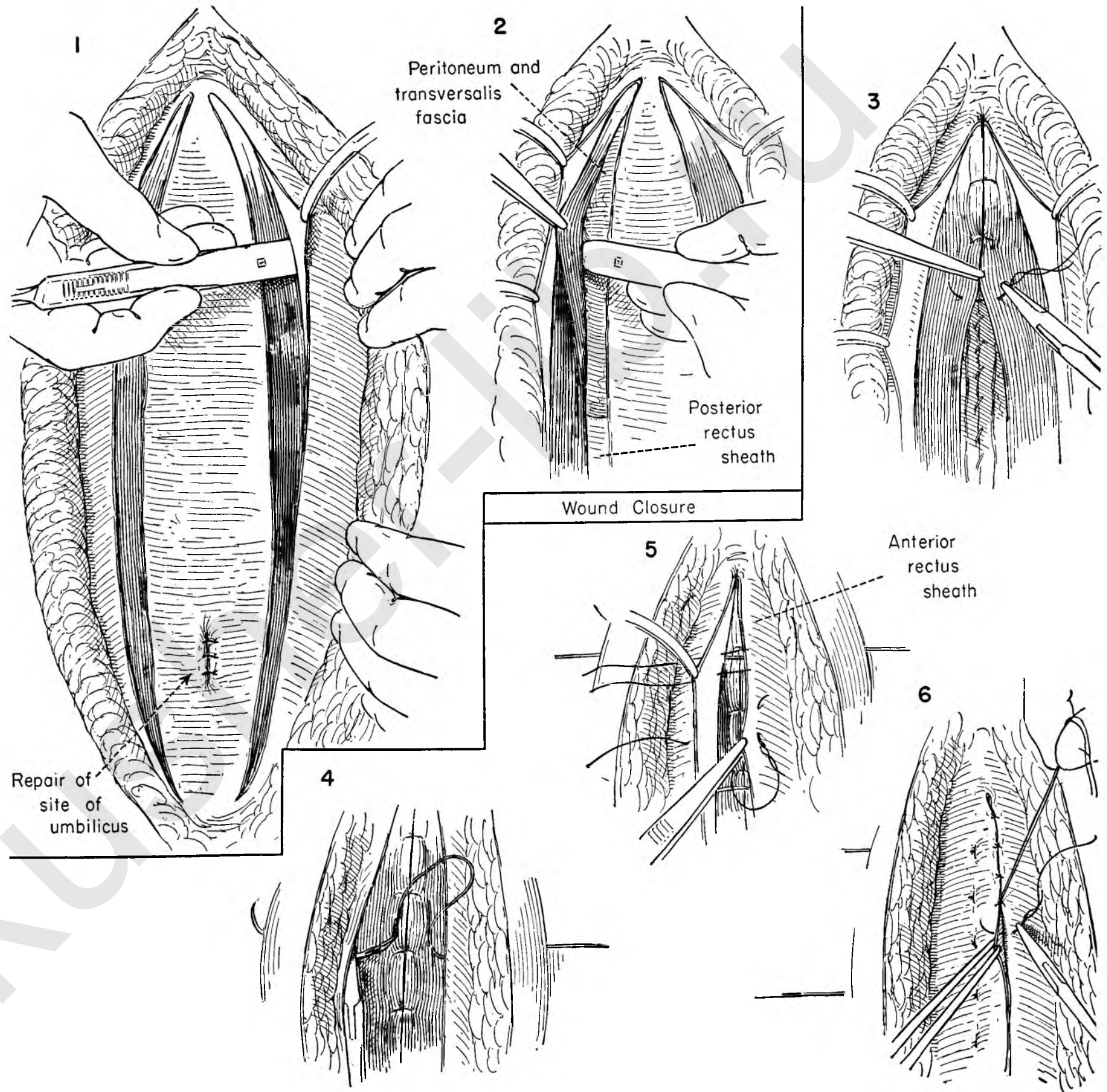
FIGURE 2. The rectus muscle is elevated and the underlying peritoneum dissected free with the handle of the knife. This maneuver is carried out on both sides and over the entire extent of the muscle bundle.

FIGURE 3. The pelvic operation has been concluded and the peritoneum closed. The mobilized rectus muscle is then approximated in the midline with interrupted catgut sutures.

FIGURE 4. Because of the extent of the dead space created in the dissection it is advisable to use deep obliterating wire sutures which pass through the skin, fat and fascia.

FIGURE 5. When possible, the fascia should be imbricated to provide additional strength to the wound.

FIGURE 6. The free edge of fascia is then tacked down with interrupted sutures.



Complications Following Abdominal Operations

By the nature of the pathology commonly encountered in the pelvis many of the complications of abdominal operations are directly referable to the element of sepsis. As a result the abdominal wound may become contaminated and subsequently break down. The source of the contamination may be pelvic inflammation, injury to bowel when adherent, or malignancy. Pelvic abscesses may develop that require drainage, whether through the abdominal wall, extraperitoneally, or by the vaginal or rectal route. Thrombophlebitis is far from rare following intra-abdominal operations for pelvic cause. The relative incidence of pulmonary emboli following pelvic operations is moderately high compared to other areas.

The surgeon must be prepared to deal with these complications as they appear. His greatest care should be exercised to make certain that they do not occur, but however careful he may be, such unfortunate sequelae are bound to appear.

SUPERFICIAL FEMORAL VEIN LIGATION

Inasmuch as pelvic operations are prone to cause pulmonary emboli and thrombophlebitis, every effort should be made to reduce the possibility of their appearance. To this end wide-angled stirrups are used for curettage to prevent pressure on the calves of the legs. Careful packing of the intestine out of the pelvis is encouraged to prevent pressure on the large vessels. Light pressure bandages or elastic stockings on the lower legs in the postoperative period may be helpful. Early ambulation has general acceptance.

Despite the precautions the patient may throw emboli to the lung from a primary thrombus in the popliteal space.

The enthusiasm for widespread use of femoral vein ligation has somewhat abated. The surgeon may prefer to carry out anticoagulant therapy through the use of either heparin or Dicumarol, or a combination of the two. When there is evidence of actual embolus to the lung, the surgeon would do well to consider the procedure of superficial femoral vein ligation as a means of preventing subsequent emboli.

The operation is not without its pitfalls. A complete exposure of the femoral and profunda veins must be obtained. Too many instances of loss of a leg have been reported in which the surgeon has ligated the femoral artery in the mistaken impression that he was dealing with the vein. This can happen only through ignorance or insufficient operative exposure. The artery must be identified before sectioning the vein. When there is evidence of clot above the level of the junction of the profunda and superficial femorals, the main trunk should be opened and the clot sucked out. Stay sutures placed around the vessel will prevent any back bleeding.

The operative procedure must be carried out bilaterally.

Too frequently unilateral ligations have been performed only to have the patient succumb from an embolus from the opposite popliteal.

DEHISCENCE AND RESUTURE

Low grade peritoneal sepsis, frank peritonitis, paralytic ileus or intestinal obstruction may result in abdominal distention in the convalescent period. Every effort should be made to keep ahead of the distention by judicious use of the Levin tube in the stomach, either preoperatively or immediately postoperatively, in any case believed likely to become so embarrassed. Once the distention has become established, it is advisable to use the Miller-Abbot tube in order to get the tube beyond the ligament of Treitz into the small bowel itself, rather than rely on the Levin tube to drain the stomach.

The distention may be so extensive that actual wound separation takes place. The appearance of a serosanguineous discharge from an otherwise clean wound often heralds the hidden presence of dehiscence.

With the diagnosis established, immediate re-exploration of the wound and suture is essential. The patient is given a suitable anesthetic, and the entire wound is laid open to determine the full extent of the separation. Since wound dehiscence is frequently caused by low grade sepsis, the wound should be cultured. In most instances the omentum will have done an excellent job of keeping the intestine out of the wound, but on occasion it may present itself.

These patients are usually poor risk patients, many of them in a precarious state. Time is then of the essence. Rather than attempt suture of the individual layers, the surgeon will do well to use through-and-through wire passing through all layers of the abdominal wall. This type of closure is adequate, yet not so tight that some drainage cannot take place. The end results of this type of wound closure are excellent, showing little tendency to hernia formation in late convalescence.

DRAINAGE OF PELVIC ABSCESS

Despite the efficacy of chemotherapy in the control of pelvic sepsis, abscess formation may occur in the broad ligament or posterior cul-de-sac which may require surgical drainage. The abscess may appear after abdominal or vaginal surgical procedures or be the natural development of pelvic disease in the absence of any operative intervention.

The actual location of the pelvic abscess will depend on the site of the original infection and will tend to follow normal

tissue planes. The point of election for drainage will depend on the localization.

RETROPERITONEAL DRAINAGE OF PELVIC ABSCESS

On occasion the abscess may localize in the broad ligament with no indication that it will ever point in the vagina or rectum. In this instance drainage may be established without contaminating the general peritoneal cavity by an incision in the groin. The retroperitoneal space is entered above Poupart's ligament, the peritoneum retracted upward, and the area of fixation explored with a syringe and needle. Confirmation of the presence of an abscess by the appearance of aspirated pus is ample indication for drainage through this extraperitoneal approach.

DRAINAGE OF PELVIC ABSCESS THROUGH THE VAGINA

The ideal spot to drain a pelvic abscess is through the vagina. This route should be used whenever it is at all feasible. Fortunately the majority of abscesses arising in the female pelvis as a complication of surgery or as a sequela of disease will tend to localize either in the cul-de-sac or at the base of the broad ligament. For safety the surgeon must assure himself that the abscess cavity is fixed to the vaginal wall before attempting to evacuate it. If there is any doubt about it, surgical judgment calls for delay until such time as there is no question about the fixation. It is also important that the induration present actually represents pus and is not simply brawny indurated tissue. If drainage is to be undertaken, pus must be obtained. A soft, tender bulging mass behind the cervix which seems fixed to the vaginal epithelium may be drained without danger.

DRAINAGE THROUGH THE RECTUM

Though the ideal place to drain a deep pelvic abscess is through the vagina, on occasion an abscess developing in the cul-de-sac will present as a bulging mass in the rectal lumen rather than the vagina.

Drainage through the rectum may be readily accomplished, provided the surgeon can be certain that the abscess cavity is firmly fixed to the rectal wall. The incision should be made under direct vision with the anal sphincter sufficiently dilated to permit introduction of retractors to expose the most dependent fixed point.

FEMORAL VEIN LIGATION

The threat of detachment of a clot from the popliteal vein with subsequent pulmonary embolism or infarct may be avoided by ligation of the superficial femoral vein. Whether the operation should be performed prophylactically or only in the presence of symptoms, and whether anticoagulant therapy is superior to surgery must be left to the judgment of the surgeon.

FIGURE 1. The upper portion of the body is elevated to increase venous back pressure. A longitudinal incision under local anesthesia begins at Poupart's ligament and extends down the thigh for 4 or 5 inches just medial to the pulsation of the femoral artery.

FIGURE 2. The skin edges are retracted and the superficial fascial layer incised in a longitudinal direction.

FIGURE 3. The femoral vessels are identified and their sheath exposed in the depths of the incision. The saphenous vein may be encountered and must be retracted medially.

FIGURE 4. The surgeon and assistant have picked up the sheath of the femoral vein to incise it longitudinally.

FIGURE 5. With the sheath on tension the femoral vein is exposed for about 3 inches.

FIGURE 6. The surgeon proceeds carefully to dissect out the femoral vein and its tributaries. It is important that the field be kept dry for the sake of exposure. Any small veins must be clamped and tied. The deep femoral vein must be dissected out at the point of entry into the common femoral.

FIGURE 7. The assistant gently retracts the femoral artery as the surgeon passes a strand of coarse silk beneath the superficial vein just below the bifurcation of the common vessel. This suture is placed as a stay suture and is left untied.

FIGURE 8. A second stay suture is placed around the vein about an inch below the first. This likewise is left untied. The assistant pulls up on the upper stay suture and stands ready with a suction tip as the surgeon keeps the lower stay on traction and prepares to make a transverse incision in the anterior wall of the vein between the two sutures. Another assistant retracts the femoral artery.

FIGURE 9. If no free bleeding follows the introduction of a glass catheter into the lumen, venous thrombosis is present.

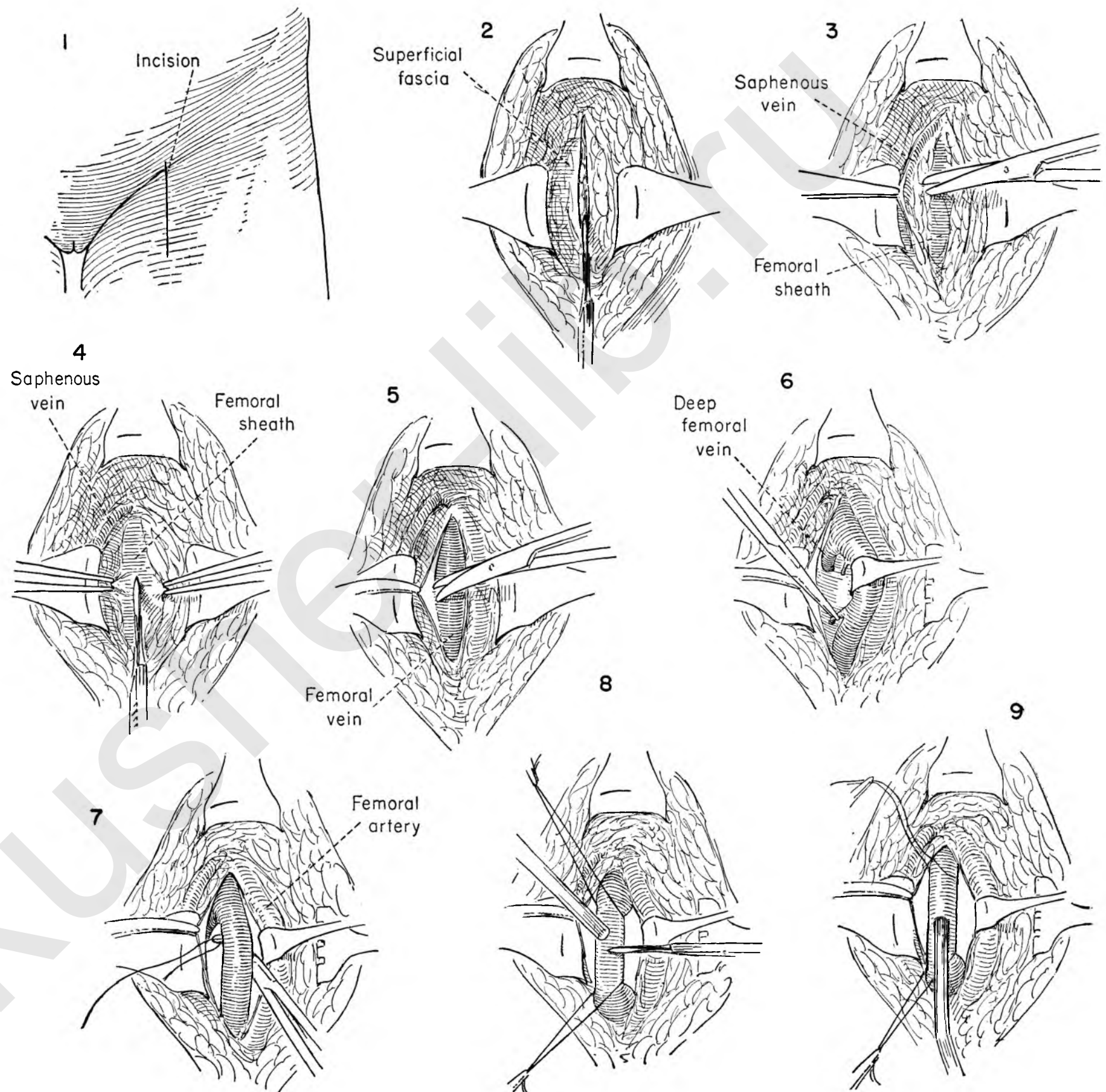


FIGURE 10. The lower stay suture is held on tension to prevent bleeding, and the femoral artery retracted as the surgeon gently aspirates the clot from the upper segment of vein.

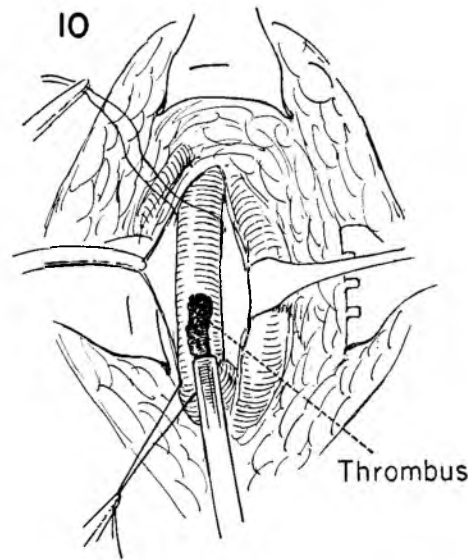


FIGURE 11. The lower segment of the vein must also be aspirated. Free bleeding should follow the removal of the clot. This is controlled by tension on the stay sutures whenever necessary.

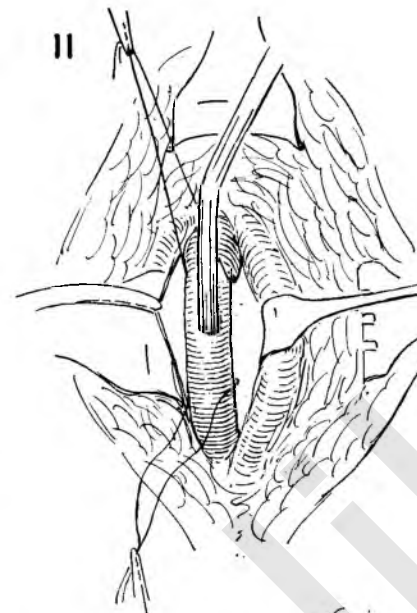


FIGURE 12. Clamps are now placed across the main trunk of the vein below the level of the bifurcation into the deep and superficial femorals. They should be placed about 3/4 inch apart to provide an adequate cuff of vein beyond the clamp on each segment, and above and below the aspiration incision.

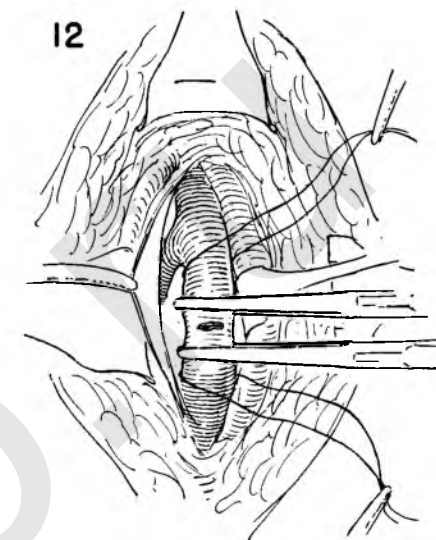


FIGURE 13. The vein is then completely transected. The surgeon is preparing to ligate the upper segment of the vein exactly at the level of the junction of deep and superficial femorals. Ligation at this level is important since it eliminates a blind stump of vein where thrombosis may begin.

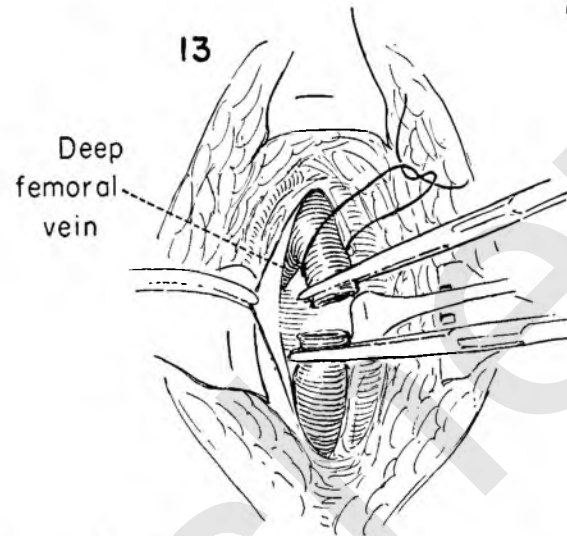
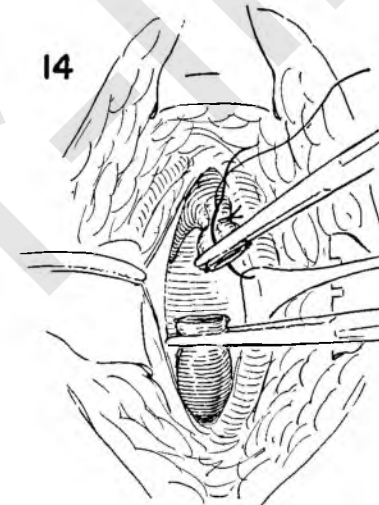


FIGURE 14. The vein has been ligated, and the surgeon now steadies the clamp on the upper divided end as he passes a transfixion suture through the cuff.



FIGURES 15 AND 16. These figures show the ligation of the transfixied vein. The suture first passes through the walls of the vein, is tied, and then carried around the vein to tie again.

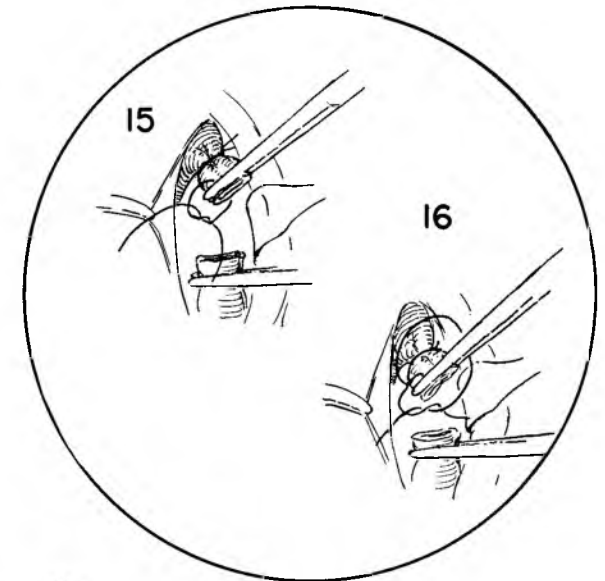


FIGURE 17. The lower segment of vein has been ligated, and a transfixion stitch is being placed through the vein. This likewise will be tied first on one side and then around the entire vein.

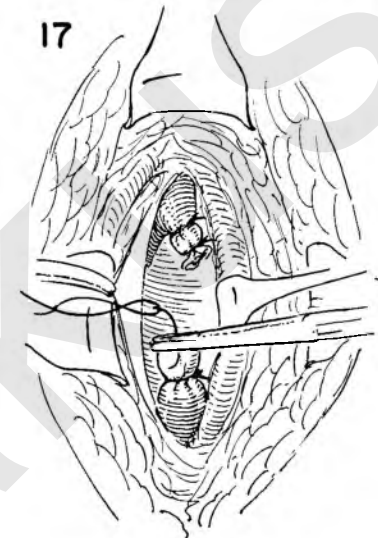
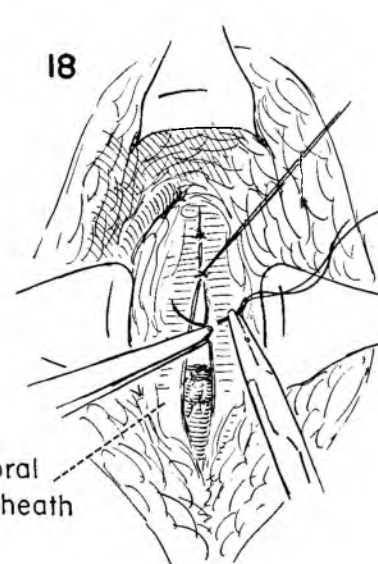
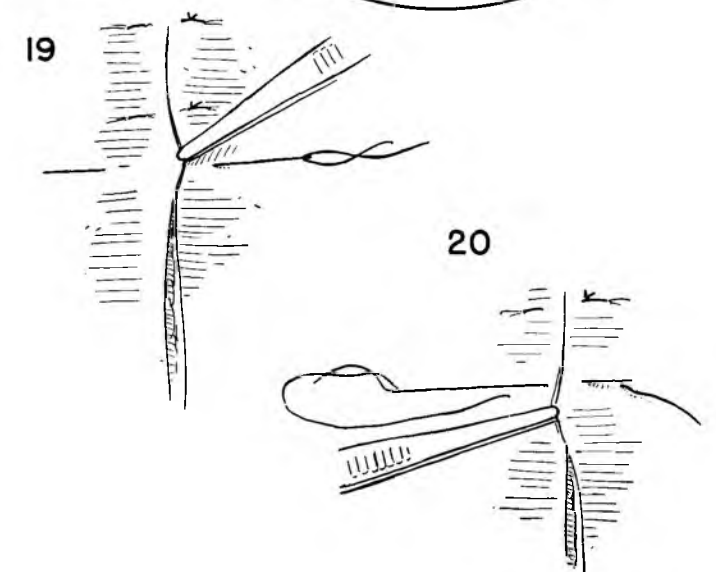


FIGURE 18. The femoral sheath is then closed with interrupted silk or cotton sutures. The assistant holds up on the initial suture as the surgeon introduces the next stitch. A series of such sutures closes the defect.



FIGURES 19 AND 20. The wound is then closed with a series of interrupted vertical mattress sutures of silk. The first stitch passes through the skin of both sides about 1/2 inch from the wound edge. On return the surgeon picks up the skin close to the incision.



DEHISCENCE AND RESUTURE

Wound dehiscence is uncommon, but with pelvic inflammatory disease, malignancy or debility due to age the chances increase. Abdominal distention from whatever cause accompanied by vigorous coughing secondary to atelectasis or pneumonia may produce wound separation. The appearance of a serosanguineous discharge on the abdominal dressing may be the first harbinger of wound disruption. Immediate inspection of the wound in the operating room is indicated. The actual closure should be expedited by using wire sutures through all layers of the abdominal wall rather than employing the customary layer closure.

FIGURE 1. Omentum can be seen protruding through a disrupted wound onto the abdominal wall. Under anesthesia the remaining sutures are removed and the wound inspected.

FIGURE 2. The peritoneum is grasped with numerous Kocher clamps. The omentum and bowel are returned to the abdominal cavity and the omentum drawn over the intestine.

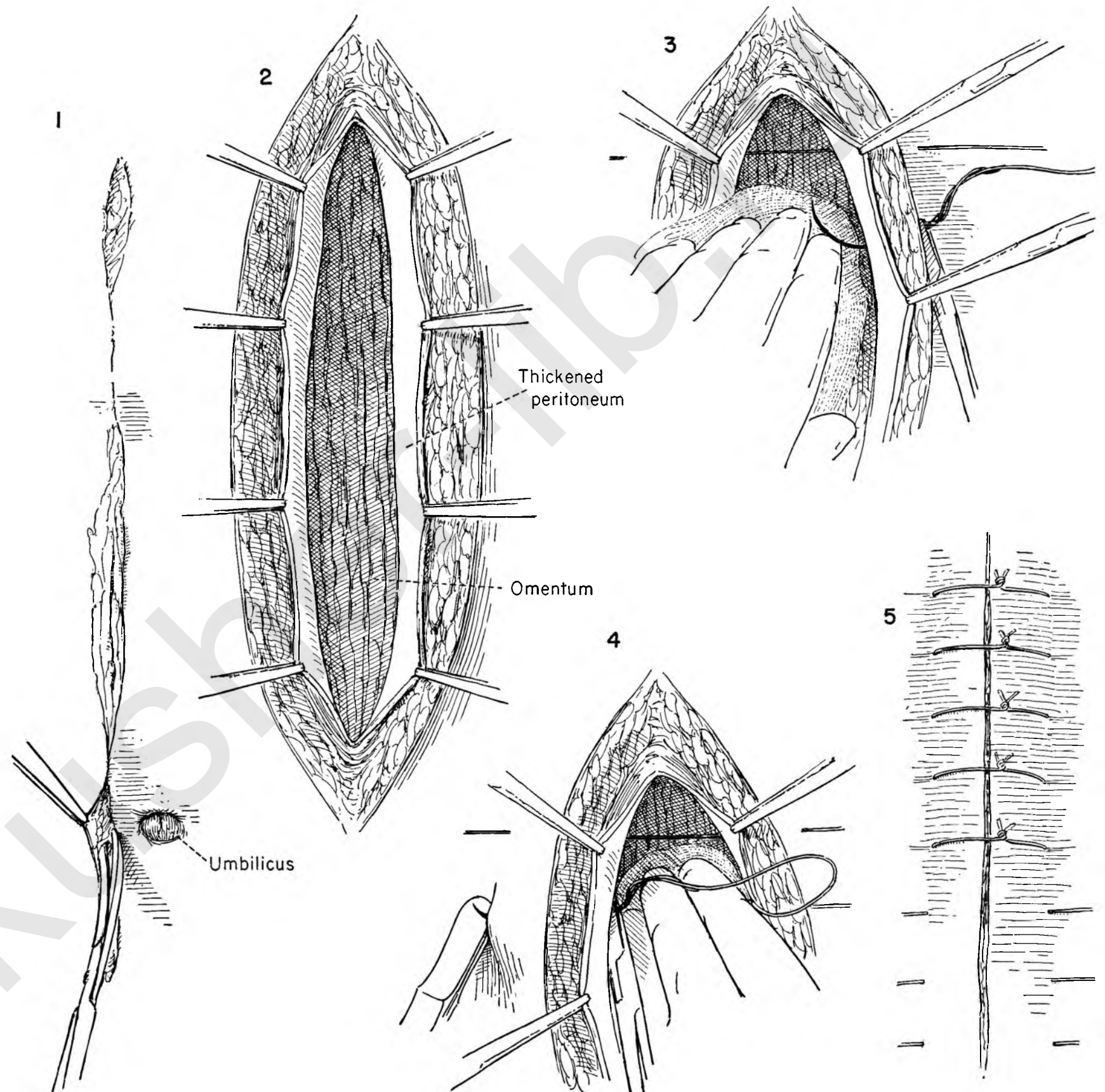
FIGURE 3. Inasmuch as time is of the essence in the depleted, poor risk patient, the quickest and safest method of resuture is to use through-and-through sutures of wire placed as interrupted sutures through all layers.

The assistant elevates the peritoneum as the surgeon places the first stitch through skin, subcutaneous fat, fascia, muscle and peritoneum. The suture is placed about 1 inch lateral to the skin incision.

To protect the underlying abdominal contents, the surgeon depresses the omentum with the left hand as he places the suture.

FIGURE 4. The assistant continues to elevate the peritoneum and the surgeon to depress the abdominal contents as he continues the through-and-through suture on the opposite side to emerge on the skin 1 inch lateral to the incision. A series of such sutures are placed.

FIGURE 5. The wires are drawn taut, but without undue tension, and secured, either by tying them or by twisting the ends. They are left in place at least two weeks.



RETROPERITONEAL DRAINAGE OF PELVIC ABSCESS

An abscess localizing in the upper reaches of the broad ligament may point above Poupart's ligament and be palpated there. Retroperitoneal drainage by the abdominal route is indicated.

FIGURE 1. The localization of the abscess in relation to the skin incision is shown.

FIGURE 2. The skin and fat are incised and retracted. The fibers of the external oblique are split in the long axis.

FIGURE 3. The retractors are introduced below the external oblique muscle on either side of the muscle incision and the wound converted into a transverse field. The internal oblique is then divided in the line of its fibers.

FIGURE 4. Retractors are placed beneath the muscle on the lower edge as the surgeon gently separates the transversalis fascia and retracts the peritoneum with the palm of the hand and extended fingers.

FIGURE 5. The indurated wall of the abscess cavity is palpated in the deep recesses of the wound at its base. The peritoneum is held back by a Deaver retractor. Before attempting to incise the abscess cavity, the surgeon should try to aspirate pus by exploring with a needle and syringe.

FIGURE 6. With presence of pus established and suction tip available to control spillage, the tip of a Kelly clamp is thrust into the abscess and the jaws spread.

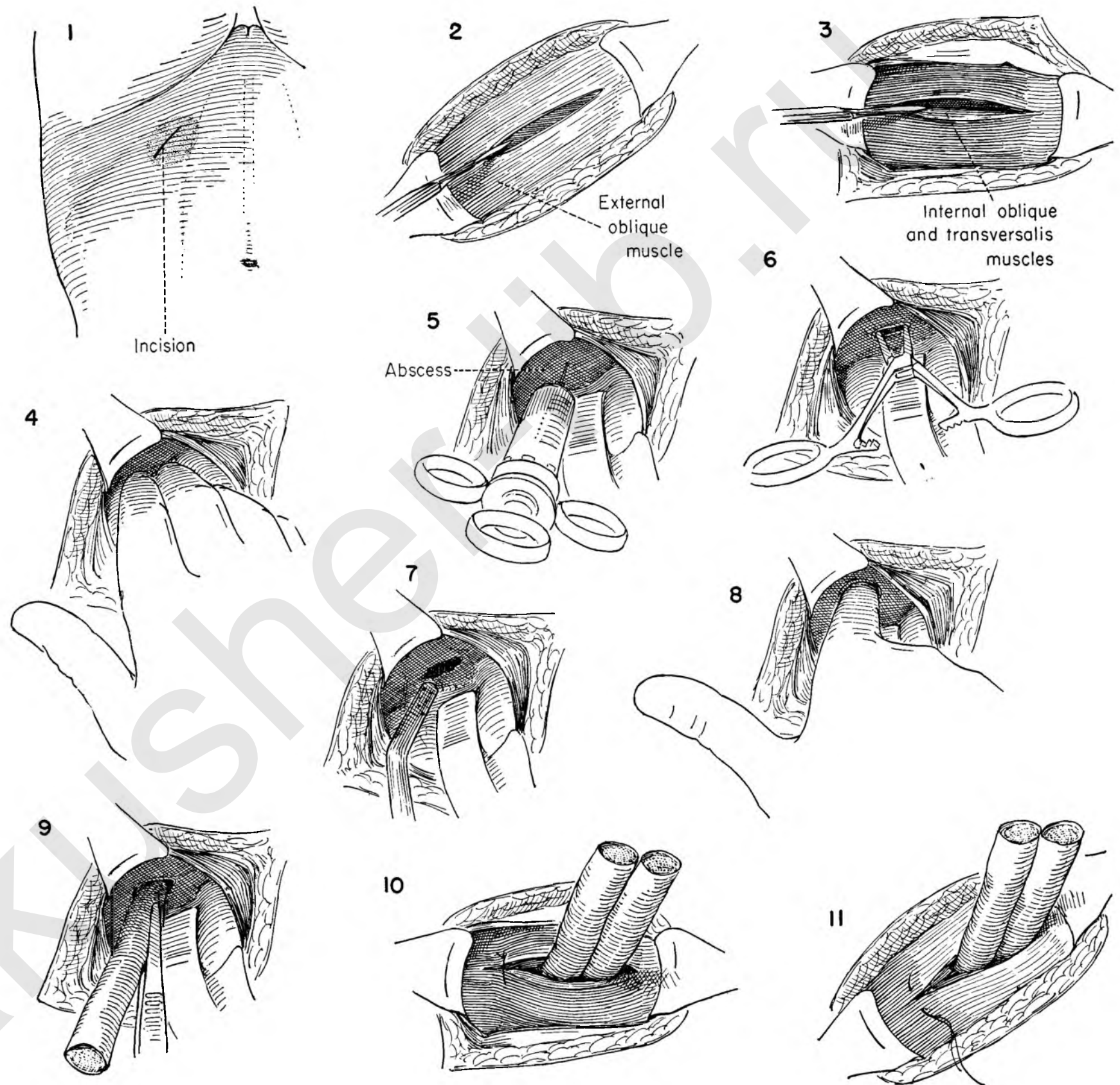
FIGURE 7. The cavity is then aspirated with the suction tip.

FIGURE 8. The finger then explores the cavity to break up any compartments which might contain pus.

FIGURE 9. A gauze-filled drain is introduced into the cavity and another into the retroperitoneal space.

FIGURE 10. The muscle is loosely closed around the drains.

FIGURE 11. The fascia is also loosely approximated with interrupted catgut. A word of caution is introduced. At no point in the drainage tract should the drains be constricted. Looseness of closure is emphasized.



INCISION AND DRAINAGE OF PELVIC ABSCESS THROUGH THE VAGINA

This is the ideal route for drainage of a pelvic abscess and should be used whenever possible.

FIGURE 1. The patient is placed in the lithotomy position, the cervix exposed, and traction applied with a tenaculum. In all probability the uterus will not descend into the vaginal canal to any extent, because of the fixation accompanying the abscess. The abscess cavity is shown in relation to other anatomical landmarks.

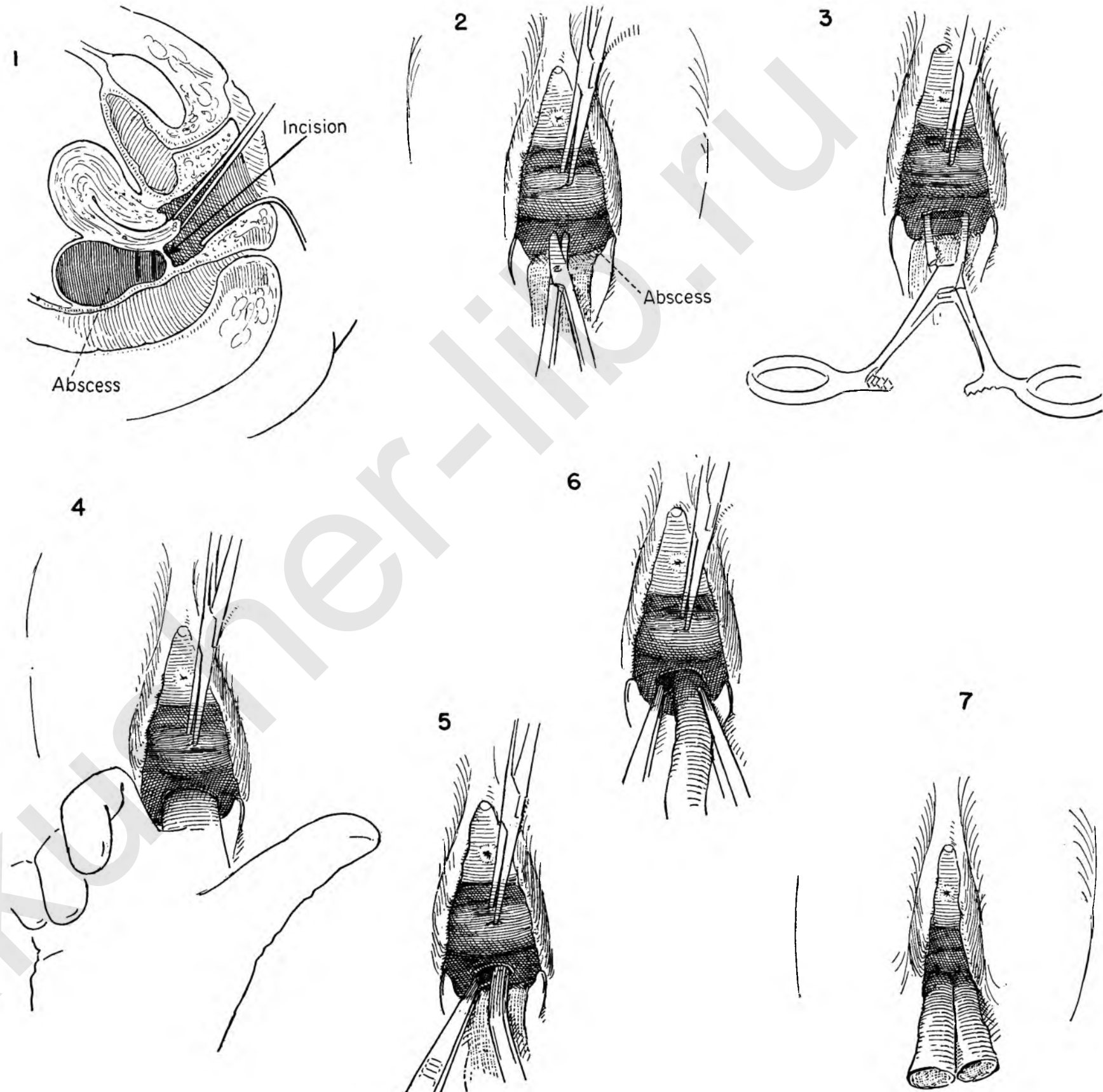
FIGURE 2. The cervix is elevated toward the urethra and the bulge of the abscess is apparent in the posterior fornix. An incision is made in the vaginal epithelium in the midline over the abscess cavity at the point of maximum fluctuation.

FIGURE 3. Maintaining the cervix on upward traction with the tenaculum, the surgeon thrusts a Kelly clamp into the abscess cavity.

FIGURE 4. An exploratory finger is introduced into the opening and the incision widened by blunt dissection.

FIGURE 5. The cervix is maintained on traction while the assistant steadies the lower edge of the incision with forceps. The surgeon then aspirates the cavity with a suction tip.

FIGURES 6 AND 7. Gauze-filled drains are then introduced into the cavity and sutured to the vaginal epithelium.



DRAINAGE OF PELVIC ABSCESS THROUGH THE RECTUM

A pelvic abscess may tend to point in the rectum rather than in the vagina. Drainage through the rectum is a practical approach to such a situation, provided the wall of the rectum itself has become involved and fixed.

FIGURE 1. The uterus has been removed. The abscess is shown dissecting below the pelvic floor to bulge on the rectal side. The arrow points to the optimum drainage site.

FIGURE 2. The patient is placed in the lithotomy position. The anus is dilated under anesthesia. Gradually the two index fingers apply pressure to stretch the anal sphincter. This maneuver should not be hurried or forceful, in order to prevent damage to the sphincter.

FIGURE 3. Narrow blade Richardson retractors should be introduced into the rectum and traction applied to either side.

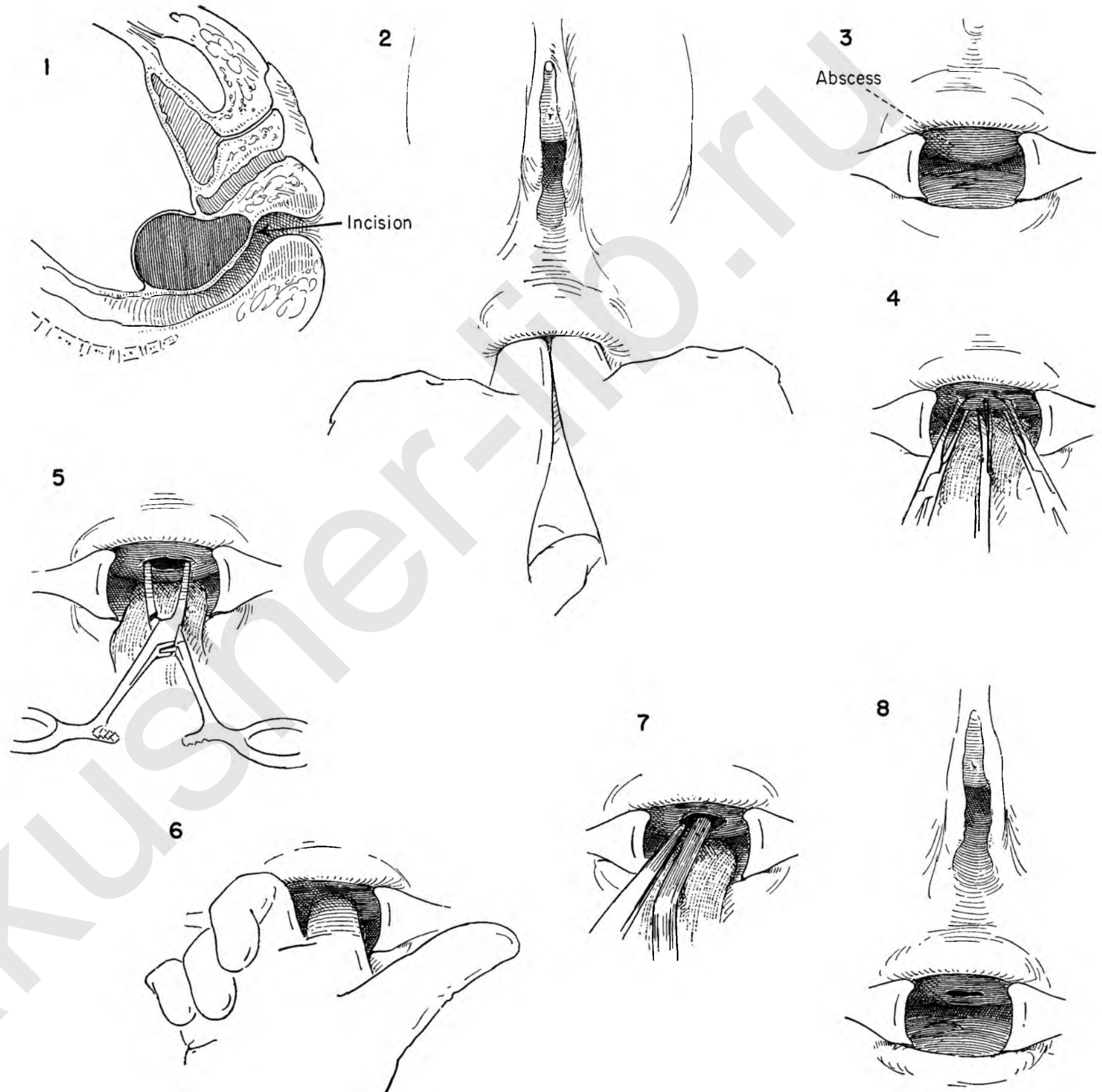
FIGURE 4. Allis clamps grasp the rectal mucosa at the point of greatest fixation to the underlying abscess. The surgeon then divides the mucosa in the long axis.

FIGURE 5. The blunt end of a Kelly clamp is forced into the abscess cavity and the jaws of the clamp spread.

FIGURE 6. An exploratory finger bluntly widens the opening and explores the cavity.

FIGURE 7. The surgeon steadies the lower edge of the incision as he introduces a suction tip to aspirate the cavity. The assistants maintain exposure with the retractors.

FIGURE 8. The interior of the rectum is shown in relation to the opening into the abscess. No drains are necessary.



SECTION II

Vaginal and Perineal Operations

akusher-lib.ru

Considerations Preliminary to All Vaginal and Perineal Operations

Many conditions encountered in the female pelvis do not lend themselves to correction by abdominal surgery. The man who concerns himself with these problems must be equally conversant with operative procedures designed for the vaginal approach. However, the surgeon who feels more at ease in the performance of vaginal procedures should not stretch the indications to conform to his particular facility for this type of surgery. There should be several strings to the bow of the surgeon who operates in the pelvis. It is the operator who should be elastic, not the patient; otherwise, individualization is impossible and the best in surgical treatment is denied the patient.

Most of the operations described in this section are designed to correct anatomical derangements created by age or pregnancy. Some of the operations outlined offer a method for the correction of defects produced by surgical or obstetrical trauma. The surgeon may elect in certain situations to use a combined abdominal and vaginal approach, as in operations for the repair of vesicovaginal fistulae, enterocele or prolapse of the vaginal apex after total hysterectomy. Operations also are described that may be used as prophylaxis against the development of cancer. Finally, the vaginal approach is presented as an alternative method for surgical attack because of special indications in a given set of circumstances.

In dealing with the varying manifestations of prolapse, vaginal repair is the logical method of approach, but the surgeon must be assured that the patient's presenting signs and symptoms are sharply confined to the lower pelvis and capable of correction from below before electing this technique. If benign tumors of the uterus or adnexa can be easily removed through the vagina, it is logical that this should be done, particularly if the patient's general condition is such that the hazards of abdominal surgery are significant. Even under these circumstances, however, if there is any suspicion that additional pelvic pathology contributes to the presenting picture, the surgeon would do well to balance carefully the risk of abdominal operation against the danger and increased difficulty of trying to perform adequate surgery through the vagina in the face of serious unanticipated findings. In the section on malignant disease the authors will try to point out the marked difference in concept between surgery for benign tumors and for their malignant counterparts. If the history or physical examination raised the slightest suspicion that malignant disease is present, surgery had best be performed through the abdomen. Surgery for cancer performed through the vaginal approach requires a highly specialized training and however well done can never be regarded as adequate, for it will not permit the removal of regional nodes, intermediate lymphatics and primary tumor.

Except in cases of malignant disease the final choice of

approach must rest with the surgical judgment of the individual operator based on his own experience, technical facility, extent of pathology and the patient's general condition.

PREOPERATIVE MEASURES

Whether the abdominal or perineal route is chosen, meticulous care must be exercised in the preoperative preparation of the patient if a successful result is to be obtained. Simply because the patient can tolerate vaginal surgery better than the same operation carried out through the abdomen is no excuse for lack of thoroughness in the preoperative workup.

In the elderly patient, anesthesia is always a problem regardless of the method to be used. Two factors tend to decrease the risk of anesthesia in vaginal operations. One is the fact that the Trendelenburg position is unnecessary and excessive pressure against the under surface of the diaphragm is thus avoided; the other is the lack of intraperitoneal packing, which also tends to increase the pressure of intestines against the diaphragm with consequent inhibition of free respiratory exchange and a definite decrease in the likelihood of postoperative ileus, atelectasis and pulmonary complications.

Urological complications may be more troublesome after perineal or vaginal operations. It is doubly important, therefore, to have preliminary investigation of the bladder, ureters and kidneys in these cases, and in many instances it will be advisable to protect the patient against urinary infection by the prophylactic use of chemotherapy.

Routine determination of the blood picture is essential. Although electrolyte imbalance is much less common after this type of surgery, nevertheless it occurs often enough to justify preparedness. Actual blood loss during surgery is often greater with vaginal operations, and preoperative determination of hemoglobin percentage and cell counts is usually indicated. Blood grouping and cross matching with proper provision for the replacement of blood loss should be done.

Thrombophlebitis and pulmonary embolism may occur after vaginal surgery, and every effort should be made to reduce the hazard of this type of complication. The position of the patient on the operating table is undoubtedly of great importance. We have used wide angle stirrups to support the legs without pressure against the calf.

ANATOMICAL CONSIDERATIONS

The authors are convinced that there is much misunderstanding of the various tissue planes encountered during perineal operations. When one consults the textbooks of gynecology,

one becomes confused by the variety of terms used to describe the structures encountered. The term "fascia" is widely used despite the fact that biopsy invariably shows smooth muscle fibers interspersed with the so-called pelvic fascia. Many of the structures described in minute detail do not appear to stand out as clearly during actual surgery as the anatomist would indicate. As a result we are convinced that the surgeon has become disheartened in his attempts to make vaginal surgery follow anatomical lines. The average pelvic repair is accompanied by a degree of blood loss that would not be countenanced elsewhere in the body, but the operation can be made relatively bloodless by paying attention to a few simple details. It is our feeling that there is a layer of smooth muscle and fascia containing vessels which invests the bladder and rectum and is loosely adherent to the under surface of the vaginal tube. If the surgeon will keep in mind that the vessels do not penetrate the vagina, but lie on its under surface, the plane of cleavage can be established without important blood loss. This applies equally well whether the surgeon is on the anterior or posterior vaginal wall.

The proper development of this plane is of the utmost importance, for it forms the basic step in the majority of reparative operations in the vagina. It must be developed if the surgeon is to have bloodless access to the bladder or rectum. It matters not whether the surgeon elects to perform a cystocele repair, Fothergill operation, vaginal hysterectomy or colpoceleisis, the basic maneuver will be the bloodless development of this subvaginal cleavage plane.

It is not easy to point with anatomical accuracy to the structures and maneuvers employed in the repair of pelvic weakness. The major support from below is by the levator ani and pubococcygeus muscles. In the female this muscular hammock is perforated by three tubes of tissue, the urethra, the vagina and the rectum. Each of these holes in the sling is a potential weak spot, but under normal circumstances bulging is prevented by forward tilting of the pelvis with deflection of intra-abdominal pressures against the pubic arch and strong lower abdominal muscles. In particular, the pelvic orifices are protected by the fact that all three tubes pass through the muscular diaphragm obliquely, and increased pressure from above serves but to increase this obliquity. Whenever the oblique pathway is lost and when, in addition, an orifice becomes permanently enlarged, the potential weak spot becomes an actual one and bulging will inevitably appear. Obviously the most permanent repair would be offered if the bulge were reduced and the orifice through the muscles closed entirely, but this is rarely practical. Our surgical effort is directed, therefore, to narrowing the defect and at the same time reconstructing the walls of the canal in the natural oblique direction, using tissues that have a good chance of standing the stresses that will

be brought against them. The best of tissues is skeletal muscle, and in this area the levator ani and pubococcygeus muscles are readily at hand for our purpose.

The decision for a particular operation to correct the prolapse is made on the basis of the type of pathology and the extent of anatomical derangement found. This must be further modified by the age of the patient in relation to the child-bearing function. A similar degree of vaginal or uterine prolapse should influence in favor of a cystocele repair or a Fothergill operation in a young woman who wants more children, whereas vaginal hysterectomy might be the procedure of choice in the woman approaching the menopause.

Whatever operation is chosen, the basic maneuver com-

mon to all is the advancement of the bladder off the cervix. Successful accomplishment of this step depends in turn on the proper development of the vaginal cleavage plane.

POSTOPERATIVE MANAGEMENT

The general principles of patient care discussed under this heading in the introduction to Section I are equally appropriate here. Convalescence from perineal surgery is usually less painful, however, and the need for opiates may be brief. Recovery of normal intestinal action is often rapid.

The complication most frequently seen is dysfunction of the urinary bladder and urinary tract infection. Prophylactic chemotherapy against the latter is indicated in most cases, but

if significant infection develops in spite of this, it is wise to identify the organism and institute appropriate antibiotics in therapeutic dosage. Overdistention of the bladder must constantly be avoided; even when micturition appears normal, catheterization after voiding to check the volume of residual is usually a worthwhile precaution.

Necrosis of tissue in the operative site above the vaginal apex is common. Usually this will liquefy and discharge harmlessly. Occasionally the contaminating organisms are of a more virulent type and significant abscess or cellulitis may develop. The surgeon must be sufficiently alert to recognize this complication early and treat it with antibiotics and the establishment and maintenance of adequate drainage from below.

Vaginal Plastic Procedures

PELVIC EXAMINATION AND CURETTAGE

The importance of pelvic examination under an anesthetic followed by curettage as a preliminary step to any pelvic operation performed through the abdomen has been stressed. The reasons advanced for this maneuver apply equally well when the operation is to be carried out through the vagina.

The surgeon must be absolutely certain that no malignant disease is present, and a thorough curettement of the entire uterine cavity with special attention paid to the cornua is a basic step. This should be followed by a complete exploration of the interior of the uterus by a blunt grasping instrument such as the common duct stone searcher demonstrated here. All tissue should be preserved. Any suspicious material should be given to the pathologist for immediate examination. If there is any question about the benign nature of the curettings, the operation should be deferred to wait the report of the permanent pathological sections.

In addition, the preliminary examination permits a re-evaluation of the pelvis in relation to lesions present in either the uterus or adnexa. When the patient is obese, the use of a dilator in the uterine cavity and held in position firmly with the tenaculum will frequently bring the uterus up into a position so that it can be palpated adequately. The relationship of an adnexal tumor to the uterus can be better brought out as the uterus is moved to one side by the lever-like action of the inlying dilator. When a uterine tumor exists in the presence of a prolapse, the surgeon has a better chance of determining the relative merits of vaginal or abdominal extirpation of the uterus. If adnexal pathology appears to be present or the uterine tumor overlarge, the surgeon may prefer the abdominal approach.

The operations described in this subsection, for the most part, deal with restoration of the relaxed pelvic structures. In many instances the actual extent of the prolapse of the bladder, rectum or uterus cannot be truly evaluated until the patient is completely anesthetized. It is at this point that the surgeon decides for or against any particular operation designed to correct the defect.

ADVANCEMENT OF THE BLADDER

In general there appears to be considerable doubt as to when the surgeon should correct a cystocele, perform a Manchester-Fothergill operation or extirpate the uterus through the vagina. It is the authors' contention that this decision need not be made until after the bladder has been advanced off the cervix. These steps make up the basic moves in all these procedures. The final decision will be made only when the patient's history is considered in relation to the anatomical situation encoun-

tered. Likewise they form the basic maneuvers for most of the operations performed on the anterior vaginal wall whether one wishes to obliterate the vagina when the uterus is absent, expose and repair a vesicovaginal fistula or suspend the neck of the bladder by a fascial strip from the abdominal wall.

For this reason these steps are shown in complete detail. These moves can be carried out in a relatively bloodless field when proper attention is paid to the existing cleavage planes. The basic concept for establishing this plane rests in the fact that the blood vessels do not invade the vaginal wall, but are held against it by fine fibrous bands. Separation of these attachments will free the vessels without damaging them and leave them on the bladder side. Separated in this manner, the "bloody angle" near the urethra can be avoided.

To secure proper infolding of the redundant bladder wall in the repair of a cystocele, it must be separated from the vaginal wall and also from the uterine vessels and their cervical branches. The bladder must be separated and advanced upward until the reparative sutures will correct the defect without being left on undue tension.

REPAIR OF A CYSTOCELE

Pelvic relaxation may be confined to the anterior vaginal wall. Simple repair of a cystocele may be all the surgery the patient requires. The bladder can be completely mobilized as indicated in Plates 103 to 106. A series of interrupted sutures are then placed in the musculofascial layer which completely envelops the bladder. They should not be placed so deeply that they enter the interior of the bladder, nor so widely that they include the intravesical portion of the ureter. Once the initial sutures are placed and tied, it is unwise to place a second series of sutures farther to the lateral side, for there is then real danger of including the ureter. Its position can often be determined by rolling the lateral bladder wall between the thumb and forefinger.

Though redundant anterior vaginal wall may be trimmed away, care must be exercised not to remove so much that a narrow vaginal outlet results.

MANCHESTER-FOTHERGILL OPERATION

A moderate degree of prolapse of both the bladder and uterus can be effectively handled by the Manchester-Fothergill operation. This operation has particular application when the patient is in the reproductive age group with her family as yet incomplete. The uterus is preserved and subsequent pregnancy may follow.

The effectiveness of the operation revolves around the approximation of the cardinal ligament in front of the cervix. The elongated cervix common to uterine prolapse is amputated.

The major support to the uterus rests with the cardinal ligaments. Normally they closely adhere to the side wall of the cervix, but may in the relaxed state drift laterally, forming a V with the cervix. The operation consists in bringing the arms of the V together to form a Y-shaped support by using interrupted sutures on either side of the cervix and tying them in the midline.

Since the cervix is amputated, there is some danger of producing cervical stenosis in the convalescent period. The chance may be materially reduced by a thorough dilation of the cervix as the initial step and by proper coverage of the raw edge of the amputated cervix by the vaginal wall flaps. The Sturmdorf stitch is useful in drawing the mobile vaginal edges across the amputated cervix and into the cervical canal where it rests without tension. During the convalescent phase periodic dilation of the canal should be carried out as an office procedure until complete healing is established.

The operation is completed by reconstructing the anterior vaginal wall defect as in the cystocele repair.

VAGINAL HYSTERECTOMY

Many surgeons prefer to remove the uterus by the vaginal rather than the abdominal approach. The many advocates of this method claim a lower morbidity and mortality as well as a wider operability rate, since the older, poor risk patient may be included. Uterine tumors of appreciable size are removed in this manner. The adnexa are said to be readily available should their resection be indicated.

The authors hesitate to become involved in an argument concerning the relative merits of abdominal versus vaginal hysterectomy. When a uterine or adnexal tumor is present or when there is a suspicion of malignant disease which cannot be dispelled by curettage, we have usually chosen to remove the uterus by the abdominal approach. Vaginal hysterectomy has been reserved for that group of cases which present varying degrees of prolapse up to complete procidentia. Its greatest field of usefulness comes in elderly patients with extreme prolapse. If the patient is a poor surgical or anesthetic risk, the operation can be carried out under local anesthesia.

The decision for or against removal of the uterus is made after the bladder has been advanced off the cervix. The anterior fold of peritoneum can be seen lying on the forward wall of the uterus as the bladder is pushed upward. The peritoneal cavity may be entered by incising this.

In the presence of a procidentia the fundus of the uterus can usually be easily drawn through the opening in the anterior peritoneum. The removal of the uterus can then be accomplished from above downward as in abdominal hysterectomy. The struc-

tures are identified, secured and divided as they are encountered. Depending on the local findings, the surgeon may elect to proceed entirely along one side of the uterus before turning his attention to the opposite side, or he may alternate from side to side as the operation progresses.

In many instances the surgeon may experience some difficulty in bringing the fundus of the uterus out through the opening in the anterior peritoneum. When the uterus appears fixed, greater mobility can be obtained by sectioning the uterosacral and cardinal ligaments. Exposure is obtained by stripping back the posterior vaginal wall off the cervix. The peritoneum of the cul-de-sac is identified lying between the uterosacral ligaments. It is incised and promptly sutured to the cut edge of the vaginal wall to control bleeding here. The uterosacral and lower portions of the cardinal ligament are separately secured, ligated and divided. The sutures on these structures are clamped and held long to be used in the reconstructive phase. This is the approach outlined in this series of drawings. At times the fixation may be such that it will be necessary to remove the uterus entirely from below upward.

The main principles involved are those of continued traction in order that the individual structures may be identified. No tissue is divided without first being secured with a stitch ligature. The emphasis is on a bloodless field. The reconstructive phase is important if prolapse of the vaginal apex is to be avoided. An excellent support to the upper part of the vagina will result if the round and uterosacral ligaments are first sutured together and then attached to the apex of the vaginal wall at either side. As the ligaments retract, the vagina is drawn upward. An adequate vaginal canal results. The cystocele is then corrected. A perineorrhaphy completes the operation, and an inlying catheter is left in the bladder.

KENNEDY REPAIR FOR STRESS INCONTINENCE

The basic defect in this condition is a sagging neck of the bladder, often in the absence of other evidence of prolapse. A wide variety of operations, all of them basically similar, have been devised to correct this defect. It is a general feeling, however, that the majority of patients who present this distressing symptom will be relieved by an adequate reconstruction of the normal vaginal tissue support.

The secret of success lies in wide exposure and adequate mobilization of the bladder neck and particularly the urethra. The site of attack is concentrated on the paraurethral tissues on either side of the freely mobilized urethra. These tissues are approximated in front of the urethra, thereby narrowing the lumen. The important sutures are those placed in the bladder wall on either side of the bladder neck. Ligation of the stitches will elevate the bladder at this point. The bladder must be mobilized so that these sutures are brought together without tension.

Before offering surgery, however, other possible cause for incontinence should be sought. Roentgenograms of the pelvis to

rule out spina bifida occulta, observation cystoscopy to determine obscure bladder pathology and any basis for neurological damage, all should be investigated. A cystometrogram to determine bladder tone may be indicated.

In the absence of cause other than anatomical malposition, the authors feel that the Kennedy type of repair should be undertaken before resorting to such operations as the apposition of the bulbocavernosus muscles beneath the bladder neck or the more complicated Marshall-Marchetti or the fascial sling procedures.

LE FORT METHOD OF OBLITERATING THE VAGINA

Procidentia may occur in older patients who are so debilitated that they are unable to withstand the strain of vaginal hysterectomy. Preservation of a normal vaginal canal is no longer a consideration. The LeForte procedure, which obliterates the vagina without removing the uterus, has a definite place in the correction of procidentia in these patients. Blood loss is minimal and, if need be, the procedure can be done under a local anesthesia.

The operation can be performed only in the presence of a healthy uterus, and malignancy must be ruled out by curettage and biopsy of any suspicious cervical lesion. Likewise it is inadvisable to use this method when symptoms of stress incontinence are present. The repeated infolding of the anterior and posterior vaginal walls, advancing the uterus upward as each successive layer is placed, places a strain on the bladder neck which tends to exaggerate any tendency toward stress incontinence.

The anterior and posterior vaginal walls are denuded as the uterus is held on tension. A cuff of normal epithelium is left around the cervix. A series of sutures brings the anterior and posterior walls together. Successive layers are placed until the denuded areas are completely closed. The perineal body is reconstructed. On completion of the operation the uterus is completely invaginated, and two lateral gutters covered with normal vaginal epithelium remain. An inlying catheter is placed in the bladder.

OBLITERATION OF THE VAGINA IN THE ABSENCE OF THE UTERUS

Rarely after total extirpation of the uterus the apex of the vagina may descend, producing symptoms distressing to the patient. If the patient is in the age group in which marital relations are no longer a consideration, the vagina may be obliterated by bringing the pubococcygeus muscles together in the midline after denuding most of the vaginal wall.

The redundant vaginal wall is placed on tension and the vaginal wall stripped from the vaginal stump on both anterior and posterior walls. The bladder is advanced and the cystocele repaired. The peritoneal reflexion is identified and the abdominal cavity entered. The excess peritoneum is resected and the abdominal cavity closed. The pubococcygeus muscles are identi-

fied on either side of the vaginal canal. They are usually relaxed and can easily be brought together in the midline without tension. What remains of the vaginal wall is approximated and the operation completed by a perineorrhaphy.

CERVICAL STUMP EXCISION

The stump of the cervix left after supravaginal hysterectomy may suffer a variety of vicissitudes which call for its removal. The secret in excision rests in constant traction of the stump. The vaginal epithelium both anteriorly and posteriorly is stripped back from the cervix; the lower end of the cardinal ligaments containing the cervical branches of the uterine artery are identified, ligated and sectioned. The round ligaments appear at the corners of the cervical stump. These are likewise secured and divided. It is possible at times to remove the cervical stump without entering the abdominal cavity. More often the peritoneum is opened and must be closed.

SIMPLE PERINEORRHAPHY AND REPAIR OF RECTOCELE

The difference between the two is largely a question of degree. The repair of the defect is rarely carried out as the only vaginal procedure, for posterior vaginal wall defects give rise to symptoms infrequently. In combination with other procedures, reconstruction of the normal position of the levators and reduction of the rectocele is an important contribution, for it contributes to pelvic support.

In the simple perineorrhaphy the levator ani muscles at the level of the perineal body simply separate and must be reapproximated. In the more extreme degrees of prolapse the upper portion of the rectum bulges out between the separated levator ani. Identification of the rectum follows the same principles previously outlined for separation of the bladder from the anterior vaginal wall. The same relation of blood vessels to the posterior vaginal wall and to rectum applies. This dissection can also be accomplished bloodlessly.

To make certain that the upper portion of the rectum does not roll out over the reconstructed perineum, the fascial envelope which surrounds it must be approximated in front of the bowel.

REPAIR OF THIRD DEGREE TEAR

The third degree tear is simply an exaggeration of the levator ani separation plus an actual division of the anterior rectal wall. The same principles of exposure are involved. The repair involves a reconstruction of the rectal wall together with a reapproximation of the levator ani muscles in front of the rectum.

POSTERIOR VAGINAL WALL HERNIA OR ENTEROCELE

Bulging of the posterior vaginal wall is such a common occurrence that it is lightly regarded. If it is encountered somewhat higher up in the vaginal canal than one is accustomed to finding it, the diagnosis of high rectocele is made and little more

thought given to it. For practical reasons it is important to point out that such a bulging sac is in all probability a true herniation of the peritoneum which includes small intestine and omentum but never rectum. By dissection a definite hernial sac can be isolated, lying on top of the anterior rectal wall and having no connection with it. It commonly occurs with rectocele, but the true hernia or enterocele may appear independently. It is obvious that the customary operation performed for repair of the rectocele will be inadequate to correct this situation. Undoubtedly the unrecognized enterocele serves to explain many of the failures of rectocele repair.

Such a hernia may appear for two reasons. Since a definite peritoneal sac can be isolated when enterocele is present, it must be regarded as a true hernia and therefore may rightfully be thought to have a congenital cause. The opening of the long finger-like projection of the peritoneal-lined sac arises from a point between the uterosacral ligaments. Because of its congenital origin it probably has no relation to childbirth, as evidenced by the fact that it may appear without a rectocele in a nulliparous patient. Commonly, however, it appears in association with pelvic floor relaxation, prolapse and a rectocele. Whether childbirth contributes to the creation of a true enterocele may be questioned.

The second type of acquired posterior vaginal wall herniation does occur with prolapse and is probably directly referable to the rigors of delivery. The cul-de-sac tends to elongate, and through an increase in intra-abdominal tension a plane of cleavage is created between the vagina and the anterior rectal wall in the region of the rectovaginal septum. This sac will also be lined

with peritoneum and may contain small bowel, fluid or omentum. Since it has no connection with the rectum, none will be found when it is opened. That it is possible to acquire such a hernial sac is suggested by the fact that they are not uncommonly found after either total or vaginal hysterectomy. This can only mean that either the true congenital type of hernia was unrecognized at the time of the primary operation or that the prolapse of the cul-de-sac has occurred through a weak spot in the pelvic floor reconstruction.

The mechanism in causation of such a hernia is less important than its existence. Failure to recognize it may lead to an unsatisfactory repair. A long step forward to prevent this will be taken when the possibility of the existence of such a hernia is kept in mind. Its presence preoperatively may be suspected on rectal examination. With one finger in the rectum and a thumb in the vagina a bulging sac can often be felt above but not in contact with the finger in the rectum. Should it contain bowel, it can both be felt and heard as pressure is applied between thumb and forefinger forcing out the gas or fluid. This will become more evident if the patient is asked to strain, thereby forcing small intestine into the sac.

If the presence of an enterocele is not detected in the preoperative examination, it may be discovered during the operative procedure, when the posterior vaginal wall has been dissected free from what was thought to be rectocele. A definite hernial sac is often found lying on top of the rectal bulge with a plane of cleavage appearing between the separate bulges. If a finger in the rectum does not enter this second sac, an enterocele is present and must be dealt with independently.

The repair can often be effected from the vaginal side. Occasionally it may be necessary to use a combined approach isolating the sac from the vaginal side followed by abdominal intervention to obliterate the defect between the uterosacral ligaments. This is the procedure of choice in the younger age group.

In this series of drawings the enterocele is repaired from the vaginal side. The levator ani muscles are developed and the rectal wall dissected free of the hernial sac lying above and on top of it. This sac is then dissected upward toward the cervix as far as possible, and then opened after being assured that intestine does not fill it. The redundant sac is then closed with a purse-string suture. A second layer reinforces the purse string. The neck of the sac is sutured to the posterior wall of the cervix between the uterosacral ligaments. A perineorrhaphy completes the operation.

HEMORRHOIDECTOMY

The most satisfactory surgical management of a hemorrhoid involves excision of the dilated and tortuous veins which produce it. In addition, one must trim away any redundancy of the perianal skin folds, since these loose tags will otherwise often be a source of annoyance to the patient and may raise the suspicion that operation has been unsuccessful. A minimum of mucosa should be removed with the hemorrhoid, however, to leave as little scar within the anus as possible. Precise hemostasis will prevent the complication of postoperative hemorrhage. No attempt is made to close any part of the wound, for an abscess is likely to develop beneath such closures.

EXAMINATION UNDER ANESTHESIA

Except for minor procedures a dilatation and curettage must precede any operation performed in the vagina where there is a uterus present, just as we have insisted that it be done as a preliminary step to all pelvic operations performed from the abdominal side.

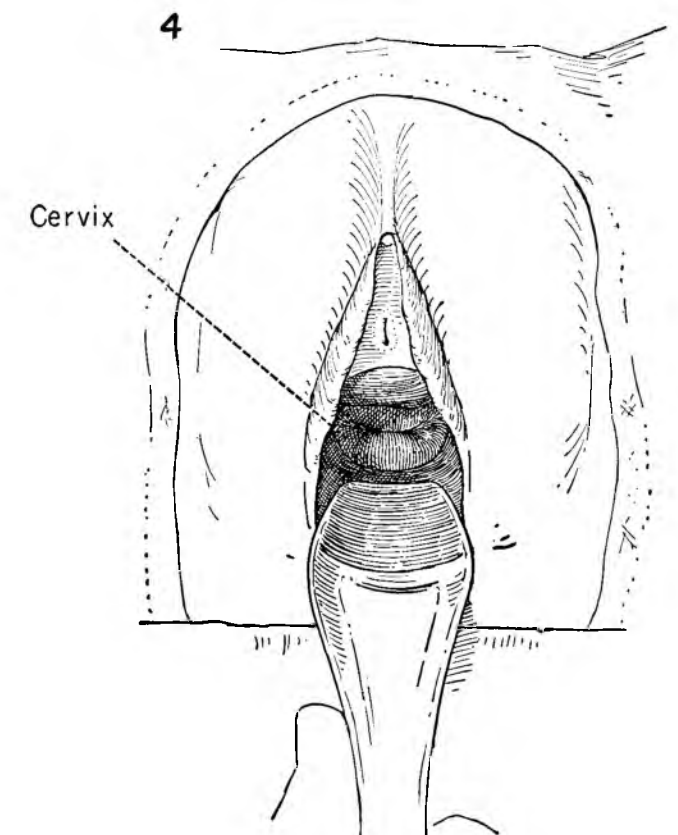
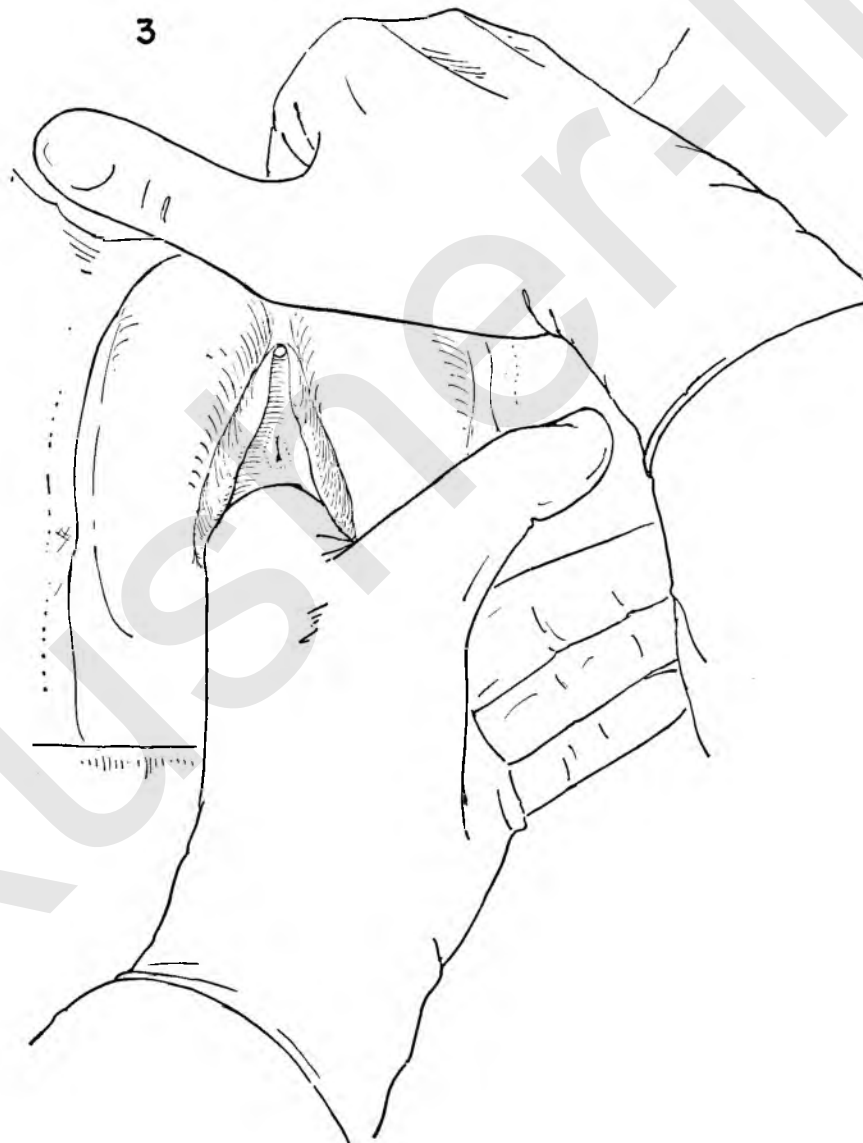
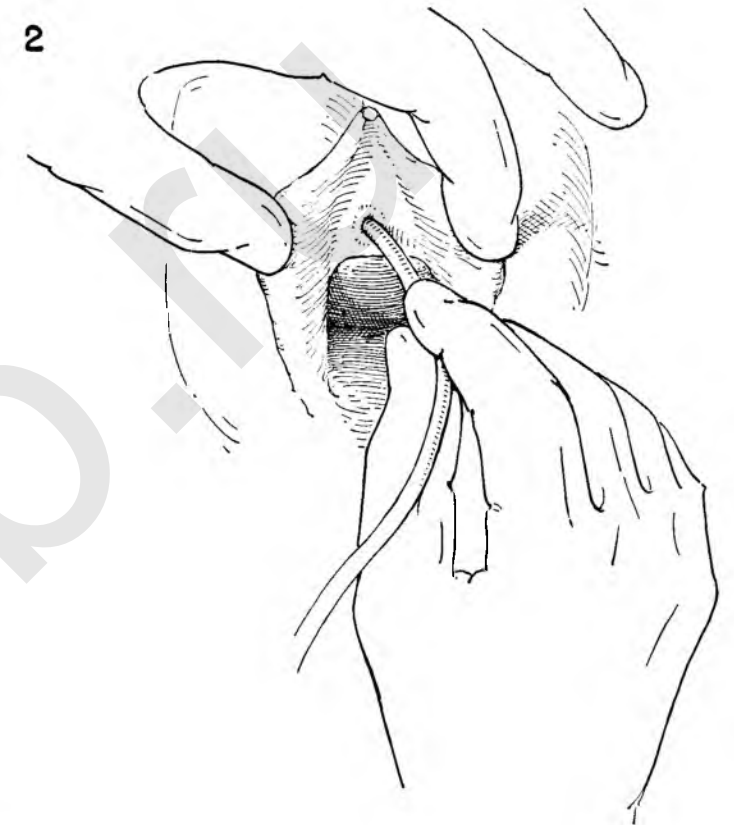
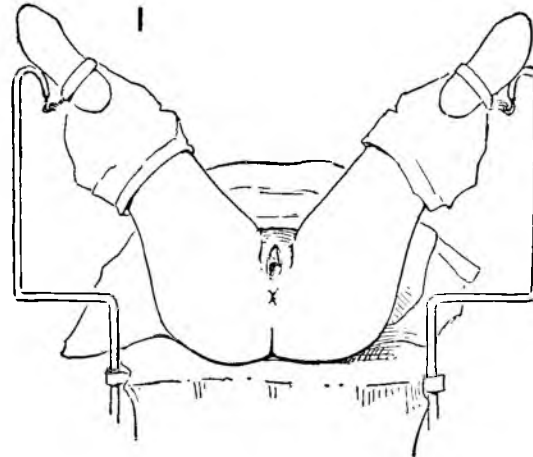
FIGURE 1. The patient is in the lithotomy position with the feet held by ankle straps suspending the legs within the upright bars of the wide-angled stirrups. Note that there is no pressure on the calves of the leg.

FIGURE 2. In this position the vulva and perineum are prepared with soap and water followed by one of the antiseptic solutions. The vaginal canal is similarly prepared.

The bladder should then be completely emptied by catheter. The entire area is now draped with protective linen.

FIGURE 3. As a check on the preoperative office or clinic examination the pelvis should again be palpated. If there has been any question in the surgeon's mind whether the operation should be done from above or below, the examination at this time should enable the surgeon to decide. Unexpected fixation of the uterus due to pathological processes in the adnexa or overenlargement of the uterus may influence the surgeon in performing an abdominal rather than a vaginal operation.

FIGURE 4. A vaginal speculum is then introduced into the canal. The surgeon may elect to use a weighted speculum. Frequently, however, the Sims type of retractor permits greater flexibility of movement. The cervix may or may not be present at the apex of the vagina, depending on the extent of redundancy of the anterior vaginal wall.



DILATATION AND CURETTAGE

FIGURE 5. With the vaginal retractor pressing downward on the posterior wall the cervix is usually exposed at the apex of the vagina. The tenaculum is then applied under direct vision.

If a redundant anterior vaginal wall obscures the cervix, it may be brought into view by applying the thumb of the left hand against the bulging anterior vaginal wall. As upward pressure is exerted the cervix is exposed and the tenaculum may be safely applied to the anterior lip.

FIGURE 6. A single tenaculum may pull through and tear the cervical musculature. More satisfactory control of the uterus is obtained when a second tenaculum is placed to the opposite side of the os, leaving the central portion under direct vision unencumbered by instruments.

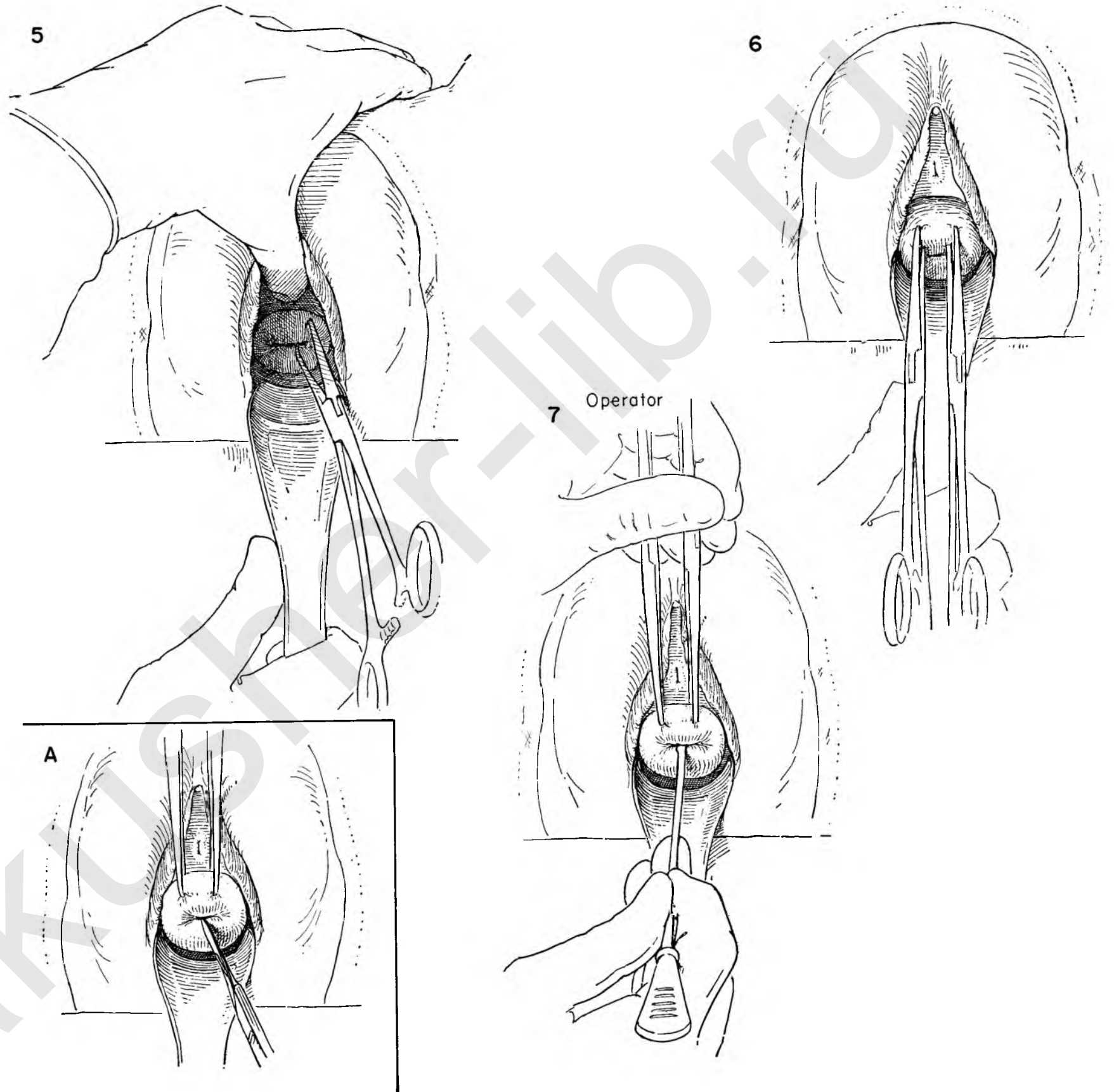
Downward traction is then applied to the tenacula, and the degree of uterine as well as anterior vaginal wall prolapse is determined.

INSET A. The tenacula are first drawn downward and then elevated toward the symphysis to expose the external os. The outer portion of the cervix and endocervical canal, if exposed, should be inspected and any suspicious lesion biopsied. If the gross appearance raises the question of malignant disease, a frozen section diagnosis should be done before proceeding further.

FIGURE 7. A uterine probe is then advanced through the cervical canal into the endometrial cavity. Gentleness is in order, for there is real danger of perforation of the uterus, especially in a uterus recently pregnant or in the atrophic state of the menopause.

If perforation occurs, further exploration of the uterine canal should be discontinued, but it is not imperative that abdominal intervention be done. The indications for abdominal exploration should be strictly limited to signs suggestive of continuing hemorrhage, either locally or intra-abdominally, or if there is reason to believe that the bowel has been damaged.

The depth and irregularity of the uterine canal can be determined with the probe. Free bleeding following withdrawal of the probe should alert the surgeon to the possible presence of cancer.



The figures on this plate illustrate a useful maneuver that may be done when the pelvic examination under an anesthetic has not been completely satisfactory either because of obesity or the extent of the uterine pathology. In many instances the size, contour and position of the uterus or adnexa are inadequately outlined.

FIGURE 8. The actual maneuver suggested is simply an adjunct to the routine dilatation of the cervix customarily performed in any curettage.

The first of a series of dilators graduated in size is then introduced into the uterine canal. This must be done easily in order to avoid a plunger-like action which may force endometrial contents out through the open fallopian tubes into the peritoneal cavity. The possibility of introducing implants of endometriosis or perhaps malignancy onto the pelvic peritoneum is thus avoided.

FIGURE 9. The dilators are serially introduced into the cervical canal and the cavity gradually stretched until the largest of the dilators has been passed.

To better evaluate the position and size of the uterus the largest of the dilators is retained in the uterine cavity. The surgeon pulls down firmly on the tenacula while at the same time thrusting upward on the dilator. All instruments are firmly grasped at the level of the cervix with the left index finger supporting the cervix from behind.

By this maneuver a lever has been provided which will permit the uterus to be moved in any direction desired. A posteriorly placed uterus can be brought into a position in which it can be more readily palpated or directed to one side or the other in order to better evaluate the state of adnexa. This procedure should never be carried out with force.

INSET A. The anatomical figure shows the manner of fixation of the instruments by the left hand, the dilator in the uterine cavity and the palpation of the uterus in its new position by the right hand of the operator.

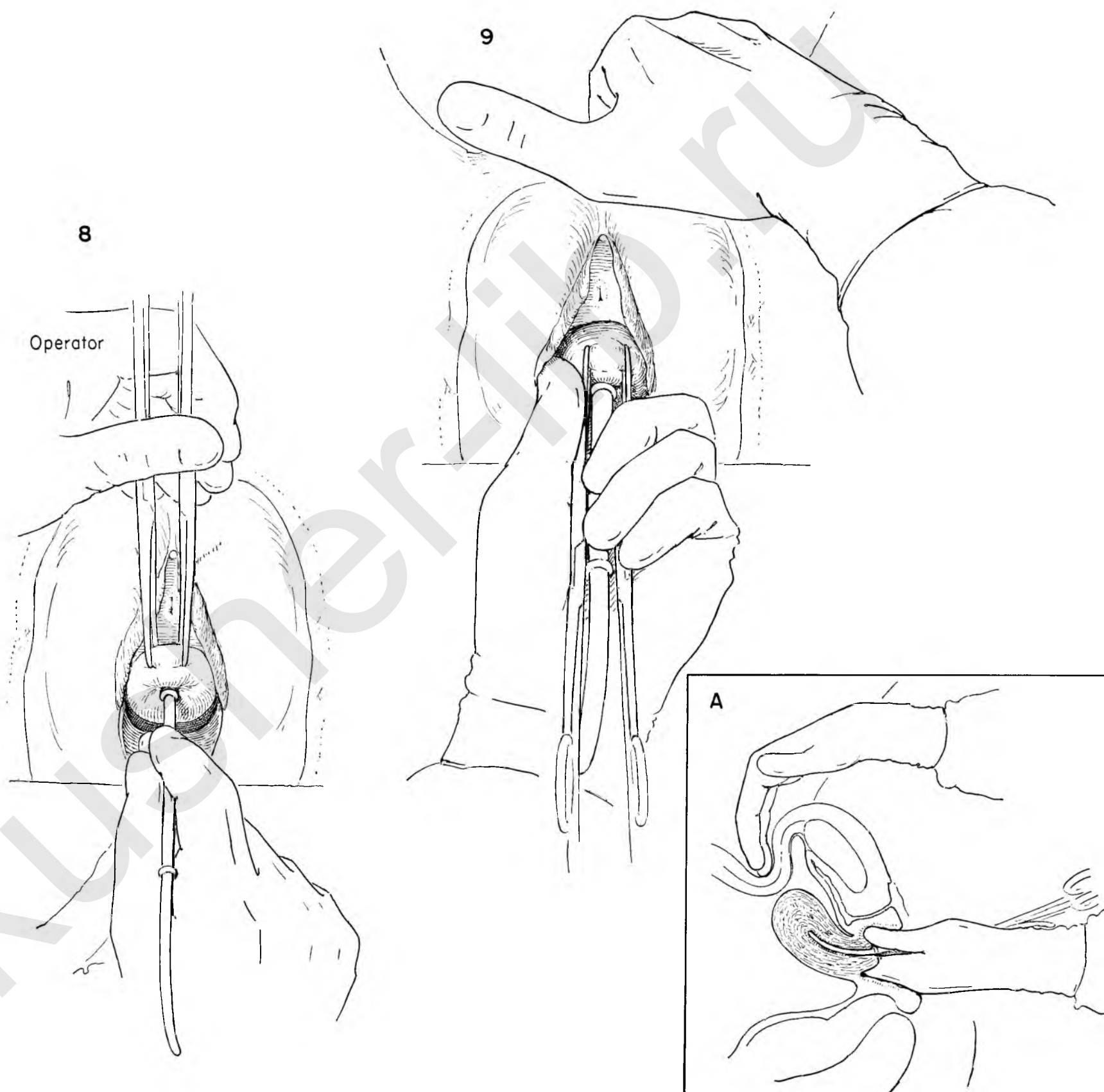


FIGURE 10. After the cervical canal has been stretched and the examination completed by the aid of the dilators, the opening is further enlarged by inserting a Goodell dilator. This instrument has tremendous leverage and must be used with caution to avoid the danger of sudden forceful tearing of the uterine wall. Each instrument has a protective device on a bar between the handles which should be set at the proper distance to protect against overforceful stretching of the canal.

FIGURE 11. The dilatation of the cervical canal is now complete, and the surgeon is ready for curettage.

A sheet of fine-meshed gauze or rubber dam is inserted below and behind the cervix as the assistant pulls down on the perineal retractor and the surgeon elevates the cervix with the tenacula.

Whenever there is the slightest suspicion of malignancy, a so-called fractional curettage should be performed. In this procedure the cervical and endometrial cavities are independently curetted.

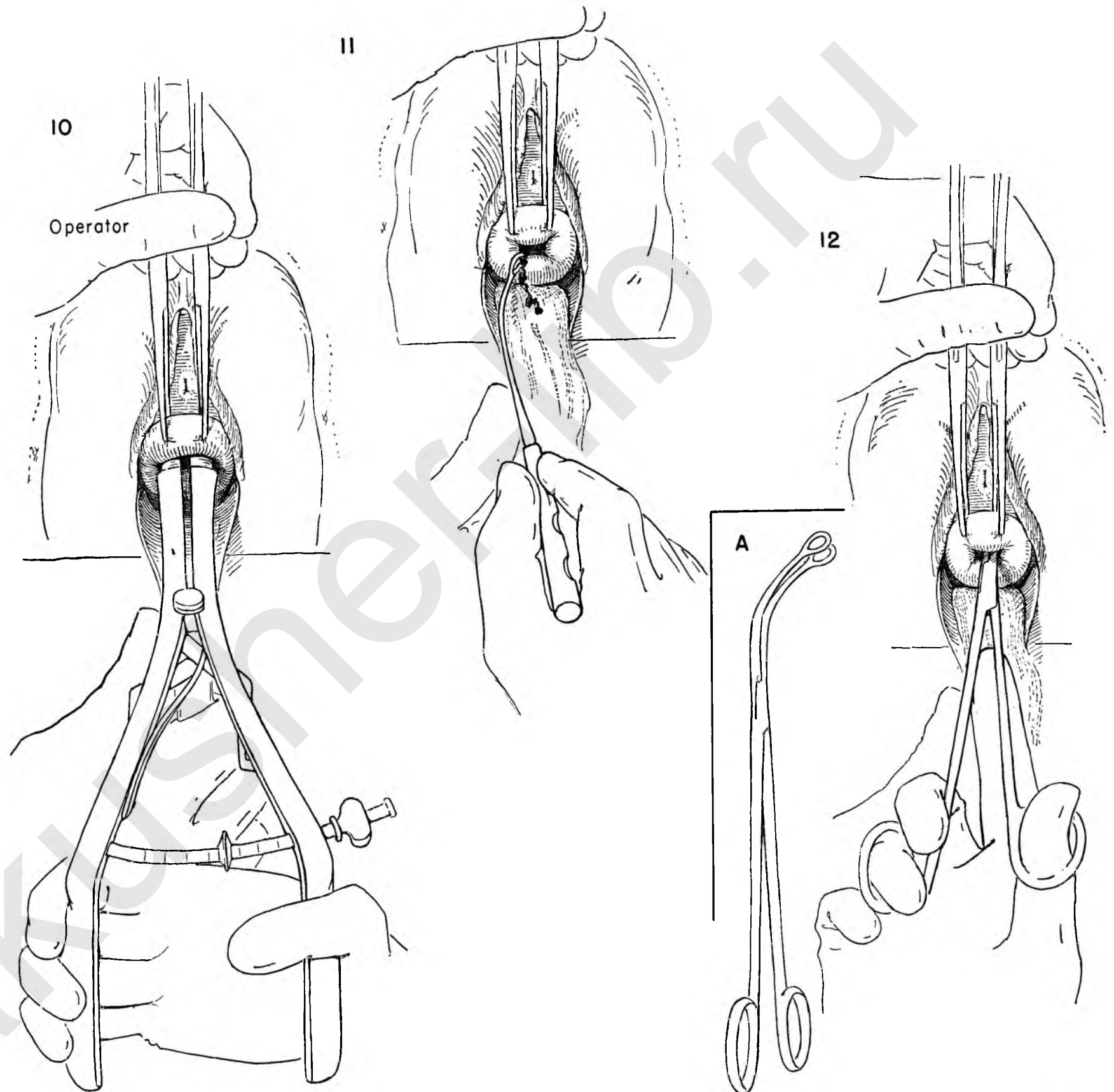
The curette is introduced into the cervix and the cervical canal thoroughly scraped. All material, however small in amount, should be saved and sent to the laboratory.

After the endocervical canal has been completely evacuated another strip of gauze or rubber is placed beneath the cervix and the entire endometrial cavity thoroughly explored. In addition to obtaining all the material within the cavity, the surgeon should be able to evaluate the location and nature of any irregularity.

For diagnostic purposes, curettage is not 100 per cent accurate. Great care should be taken to curette the cornual portions of the uterus.

FIGURE 12. Because endometrial polyps may move freely on a stalk they may be completely missed with the curette. To avoid this and in the interest of complete evacuation of the endometrial contents a common duct forceps or any similar blunt grasping forceps is inserted and the cavity further explored by successive and systematic grasping movements of the forceps.

INSET A. The type of instrument we have used for this maneuver.



ADVANCEMENT OF THE BLADDER

The figures outlined in the next four plates represent the initial steps to be taken in the majority of operations designed to correct anterior vaginal wall defects or prolapse. Though lesser degrees of descensus lend themselves to this procedure, for the sake of clarity in outlining the individual moves the operation will be shown as it is performed in a case of procidentia.

FIGURE 1. To provide better exposure four interrupted catgut sutures through skin and labia place the latter on tension. The cervix is held on traction away from the symphysis.

FIGURE 2. The surgeon notes the last transverse fold of vaginal epithelium and divides it transversely just above this landmark.

FIGURE 3. Kelly clamps grasp the full thickness of the vaginal wall and keep it on tension. The open tips of the scissors keep constant pressure against the under surface of the vaginal wall away from the bladder as they are advanced toward the urethra. The bladder is thus separated from the vaginal wall in a bloodless field.

FIGURE 4. With the uterus and vaginal wall held on tension the surgeon incises it in the mid-line as far as the urethra.

FIGURE 5. The divided edges of the vaginal wall are placed on tension by wide blade Allis-Adair clamps.

FIGURE 6. This is the most important of all the steps. The secret of bloodless separation of the bladder lies in the recognition of the fact that the small vessels and their supporting fibrous strands which bind the bladder to the vaginal wall lie on rather than penetrate the vaginal wall. They are exposed by traction.

The assistant elevates and separates the Allis forceps while the surgeon draws the bladder to the opposite side with the flat portion of the fingers laid over gauze placed on the bladder.

The surgeon then lightly separates with a knife blade the fine fascial attachments above each of the small vessels as they are encountered along the lateral vaginal wall.

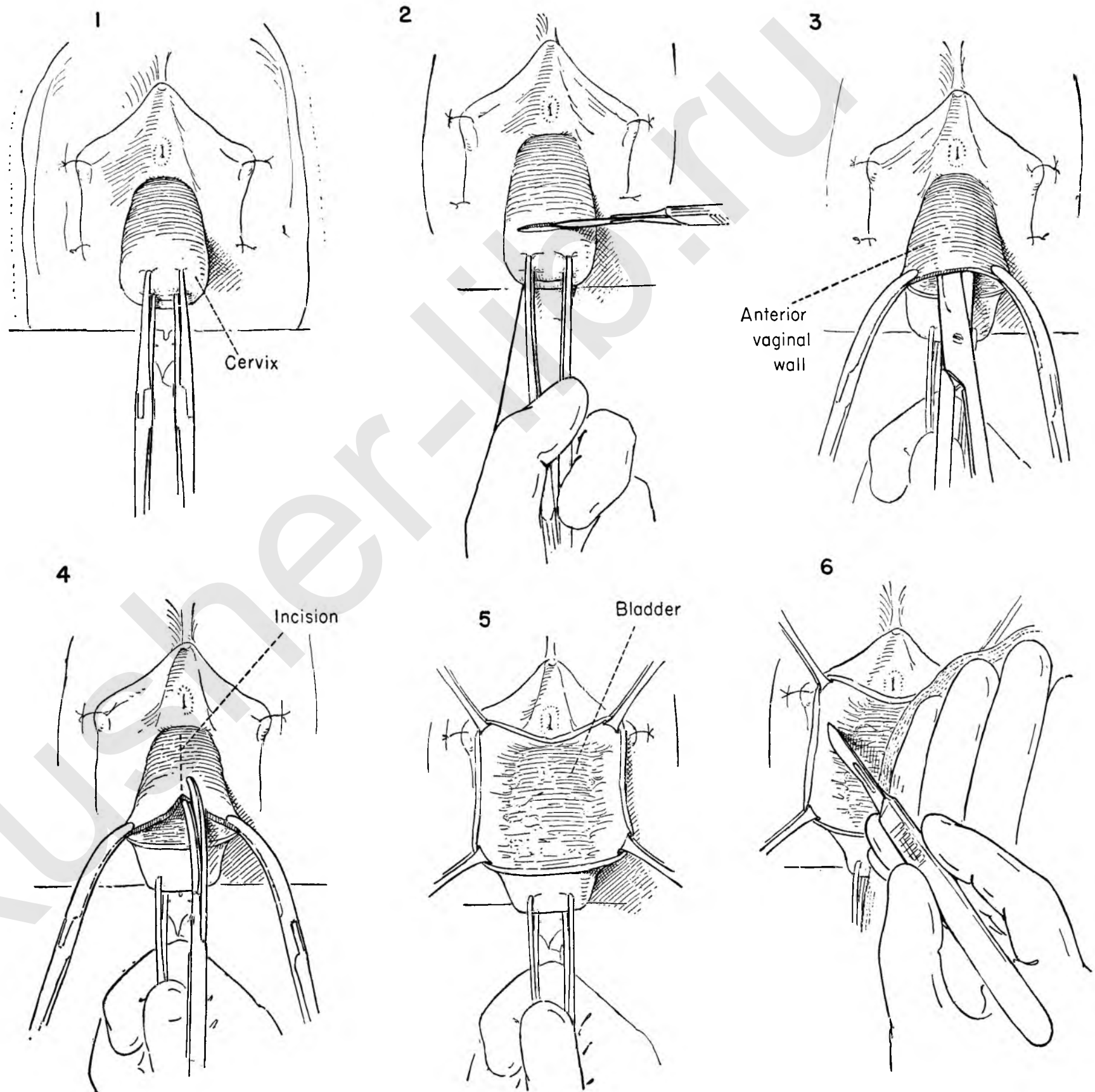


FIGURE 7. Once the fibrous strands holding the vessels have been divided, the bloodless plane of cleavage can be further developed with the handle of the knife, gently pushing the bladder with the vessels lying on it toward the midline. Traction and countertraction make this possible.

FIGURE 8. The dissection is extended in this same avascular plane in order to completely separate the bladder from the vaginal wall. Note the angle of the knife handle. The proper cleavage plane is at a 45 degree angle with the operator's hand retracting the bladder to the midline. The assistant exerts countertraction on the clamps.

FIGURE 9. This is the so-called bloody angle. By using the same principle of traction, countertraction and division of the fibrous strands above the vessels, this portion of the operation may be made bloodless.

FIGURE 10. After dividing the attachments of the vessels the knife handle may again be used to bring the cleavage plane into view. This dissection is then carried up along the under side of the symphysis, freeing the urethra laterally.

FIGURE 11. If the separation is properly developed, the index finger may be inserted into the sulcus formed by the bladder, urethra and lateral vaginal wall without producing any bleeding.

FIGURE 12. The same steps are repeated on the opposite side. The urethra has been freed from the pubic rami in such a manner that the paraurethral tissue at the bladder neck can be approximated in the midline without tension. This is a necessary step when there is any element of stress incontinence.

FIGURE 13. At times the most distal portion of the bladder is not easily identified. To bring this out more clearly and avoid injury to the bladder, the surgeon may elect to introduce a uterine probe into the urethra, advancing it into the bladder until the lower border becomes obvious in its relation to the cervix.

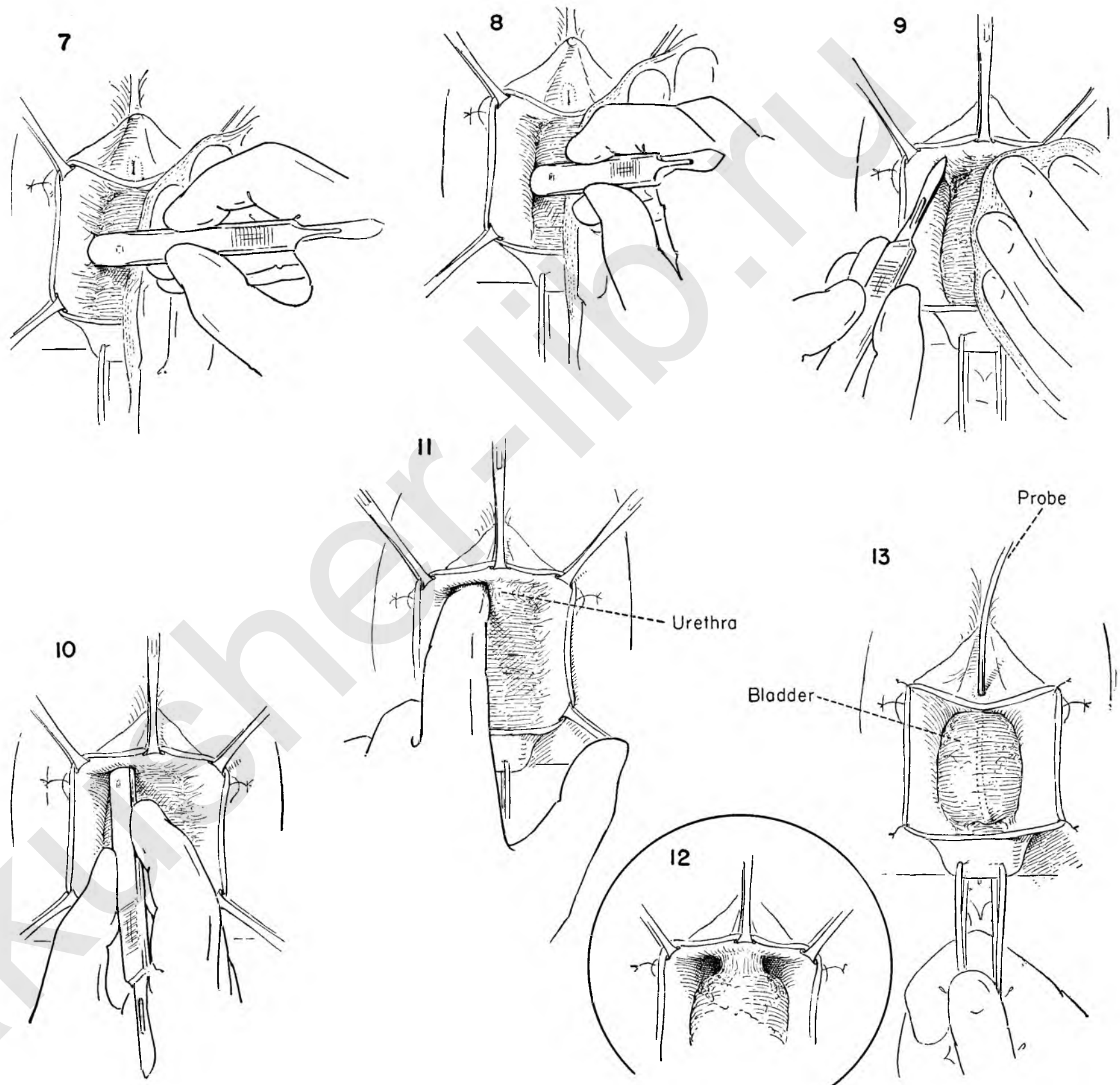


FIGURE 14. Though the bladder and urethra are now free of all lateral attachments to the vaginal wall, the bladder is still attached to the cervix and must be separated.

To increase the exposure the clamps on the vaginal wall are removed and the edges sutured to the skin with four to six interrupted catgut sutures.

The assistant holds the uterus downward on traction as the surgeon picks up the lowermost portion of the bladder in the midline above the cervix.

FIGURE 15. The assistant maintains downward traction on the cervix while the surgeon elevates the bladder in the midline and gently separates the under surface from the cervix for a short distance with the index finger. The attachments at this point are areolar, and a bloodless plane of cleavage should be present. The lateral attachment of the bladder to the cervical vessels is evident on the left side.

FIGURE 16. In order to advance the bladder this attachment must be divided. The plane of cleavage between bladder and cervix is gently developed laterally. This can be done with the blunt end of the Kelly clamps. The cervical branch of the uterine vessels lies lateral to the cervix and on a plane parallel to it and must be avoided. It can easily be seen.

FIGURE 17. Two Kelly clamps are placed across the lateral attachment, avoiding the bladder above and the uterine vessels below. The surgeon then divides the fascia between the clamps. The assistant applies countertraction to the tenacula on the cervix.

FIGURE 18. The bladder with clamps on the lateral attachment is elevated as the surgeon places a stitch ligature around the lower clamp and ties it.

FIGURE 19. The clamp on the bladder side is similarly treated.

FIGURE 20. The same procedures are carried out on the opposite side.

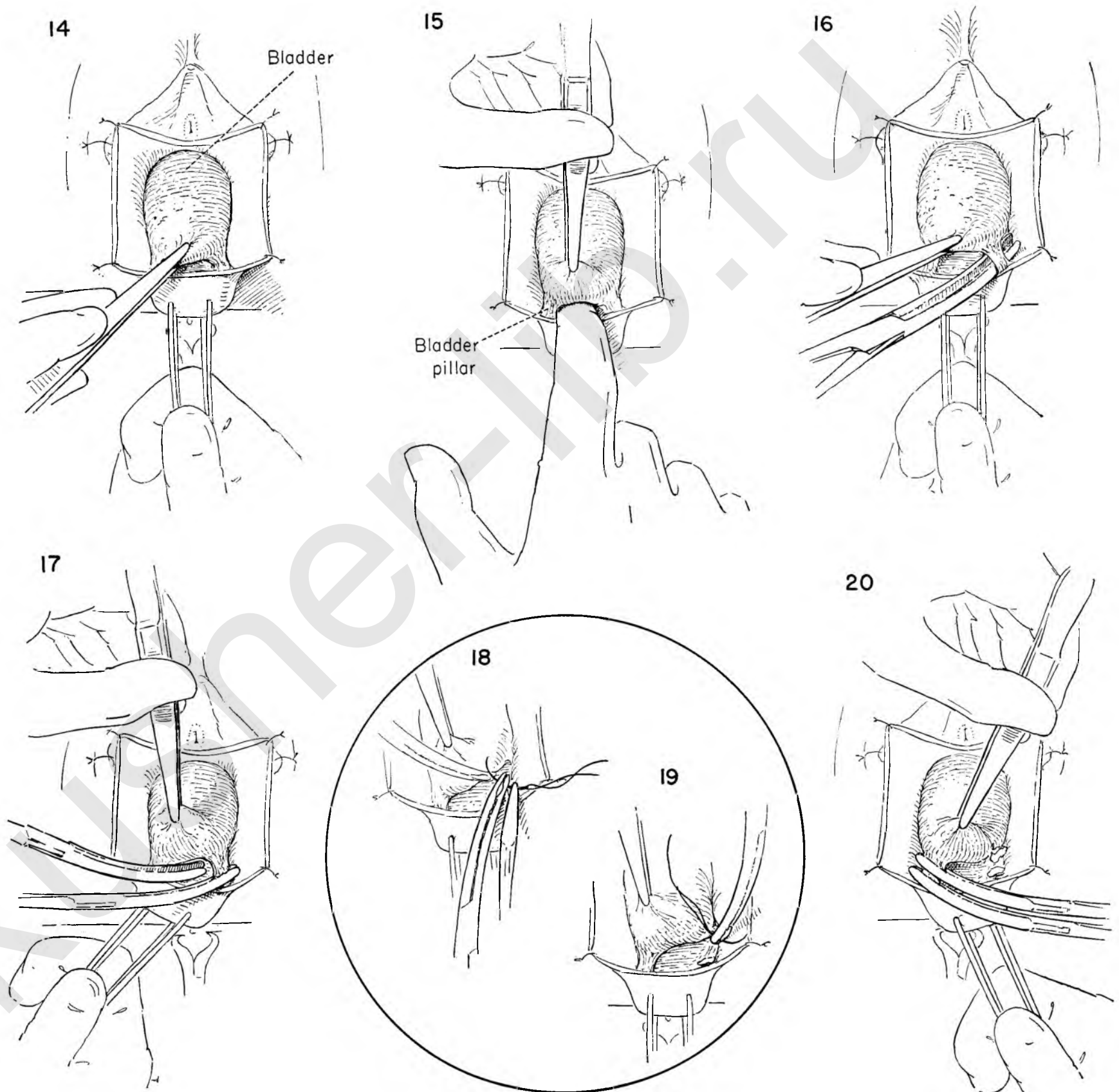


FIGURE 21. The surgeon now elevates the bladder in the midline with smooth thumb forceps and further dissects the areolar attachments of the bladder from the underlying cervix in the midline. The tips of the scissors point toward the cervix away from the bladder. The assistant pulls downward on the tenacula to provide better exposure.

FIGURE 22. The assistant continues the traction on the cervical tenacula as the operator elevates the bladder with smooth forceps and completes its separation from the cervix in the midline with the index finger.

FIGURE 23. The bladder is still attached to the cervix laterally and cannot be sufficiently advanced until the attachments are divided.

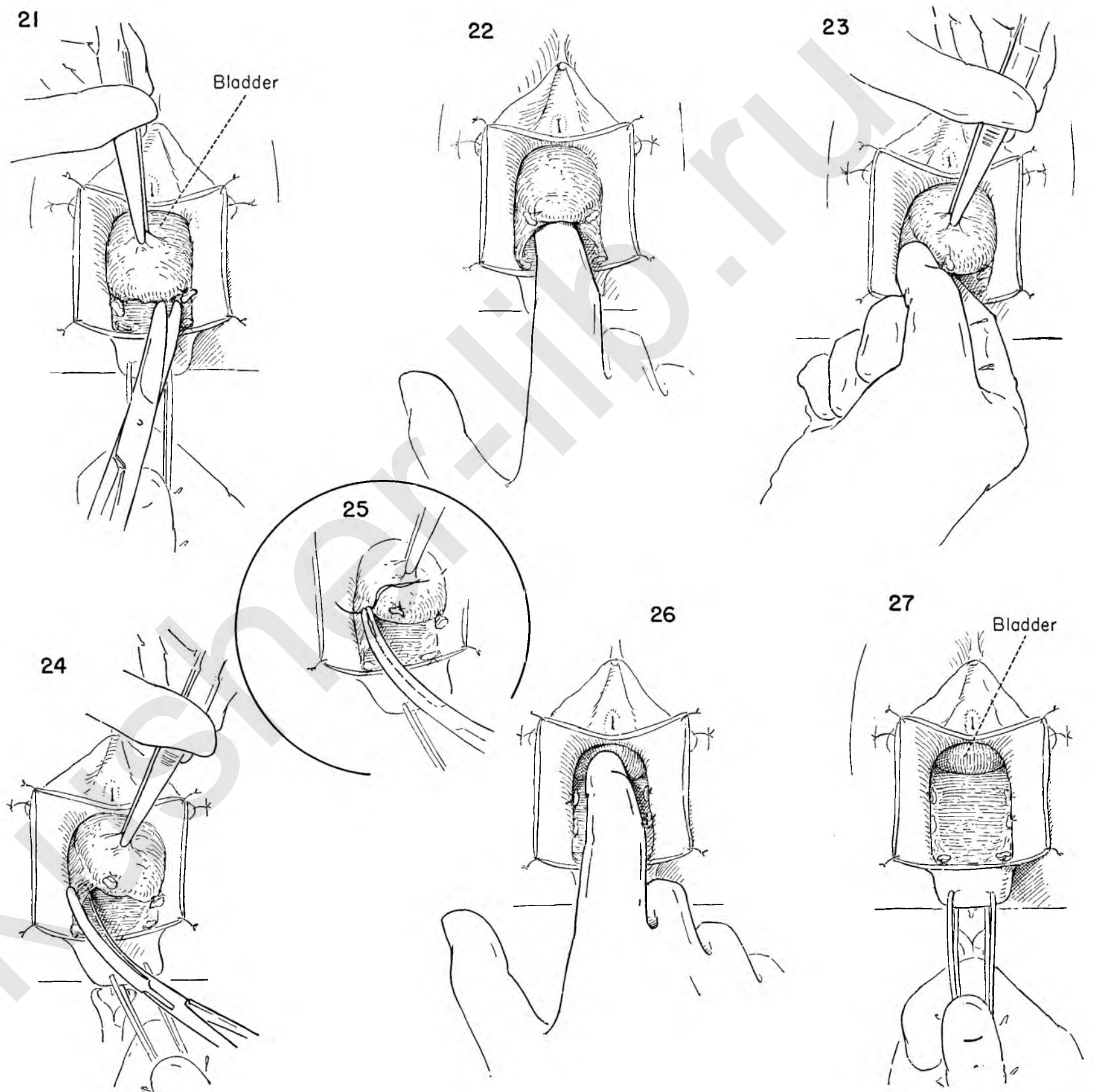
There is real danger of damaging the ureter at this point. Before applying Kelly clamps to this point of fixation the surgeon would do well to palpate the ureter between the thumb and forefinger on both sides. Its presence is detected by a snapping sensation as it is rolled between the fingers.

FIGURE 24. The position of the ureter identified, a Kelly clamp may be safely applied by staying on a plane superior to the underlying uterine vessels. The tissue between the clamp and the bladder is then divided.

FIGURE 25. The bladder is retracted medially and the clamp on the lateral side enclosed in a stitch ligature and tied.

FIGURE 26. With the bladder completely free of attachment to vaginal wall and uterus, it may easily be displaced upward off the cervix and uterus.

FIGURE 27. This figure shows the bladder completely detached. The vesicouterine fold of peritoneum can often be seen beneath the bladder.



CYSTOCELE REPAIR

The bladder has been separated from the vaginal wall and the cervix in the manner illustrated in the preceding four plates. The surgeon must now decide whether the anatomical findings call for a simple cystocele repair or whether a Manchester operation or vaginal hysterectomy is indicated. The technique of cystocele repair will be illustrated first.

FIGURE 1. An Allis-Adair clamp is placed on the incised edge of the vaginal wall in the mid-line. The assistant applies downward countertraction on the tenacula as the surgeon draws the bladder down into the field with smooth forceps.

FIGURE 2. The assistant lifts upward on the Allis forceps while the surgeon retracts the bladder downward with the index finger placed over gauze on the bladder wall. This brings the urethra into view in relation to the bladder. A small curved needle with an atraumatic catgut suture is placed lateral to the urethra, passing into the fascial envelope covering the neck of the bladder.

FIGURE 3. The same stitch continues across the bladder neck and is passed from below upward in the corresponding position on the other side of the urethra.

FIGURE 4. The assistant elevates the clamp on the initial untied suture and pulls down on the cervix with the tenacula. The surgeon then retracts the bladder to the right and places another suture into the bladder wall well out laterally on the left side.

FIGURE 5. The bladder is then drawn to the left, and a parallel suture is placed in the right lateral wall again from below upward. The assistant continues the traction and countertraction.

FIGURE 6. A third suture similar to the previous sutures is placed in the anterior wall of the bladder. All are clamped and left untied. All these sutures must carefully avoid penetrating too deeply in order not to enter the interior of the bladder or catch the transvesical portion of the ureter.

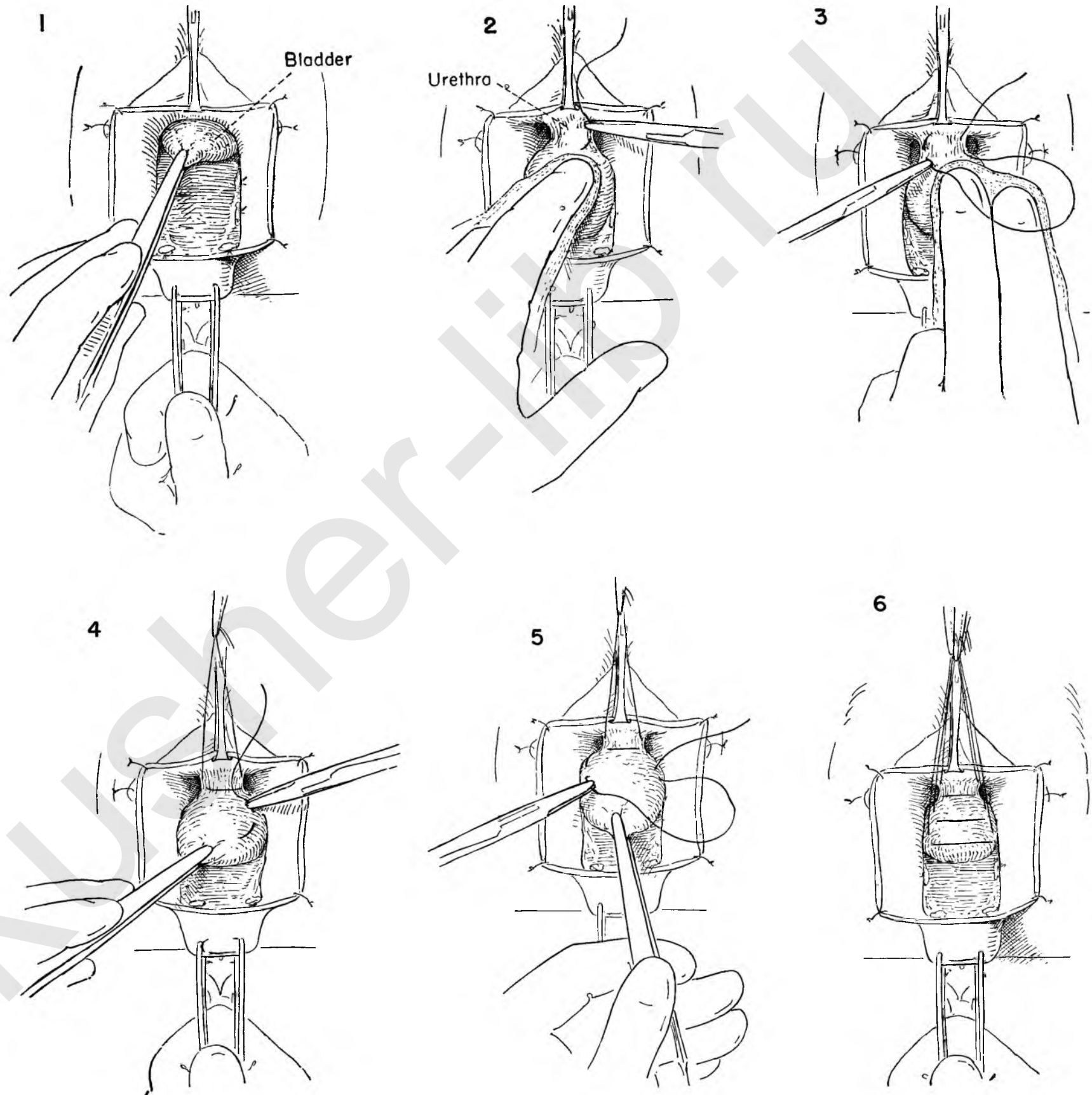


FIGURE 7. The sutures are now tied, beginning at the urethra and descending toward the cervix. The sutures are not divided until the surgeon assures himself that a sufficient number have been placed to satisfactorily infold the redundant bladder. More sutures may be placed. The operator should be cautioned against placing another row of sutures lateral to the initial row. There is great danger of including the ureter in a stitch if this is attempted. In this illustration the last suture is being tied.

FIGURE 8. The midline Allis clamp is removed and the stitches holding the cut edges of vagina to the skin are cut. Kelly clamps are placed on the vaginal wall on both sides opposite one another both above and below. The excess is then cut away. It may be ill advised to sacrifice too much tissue lest narrowing of the vaginal canal result.

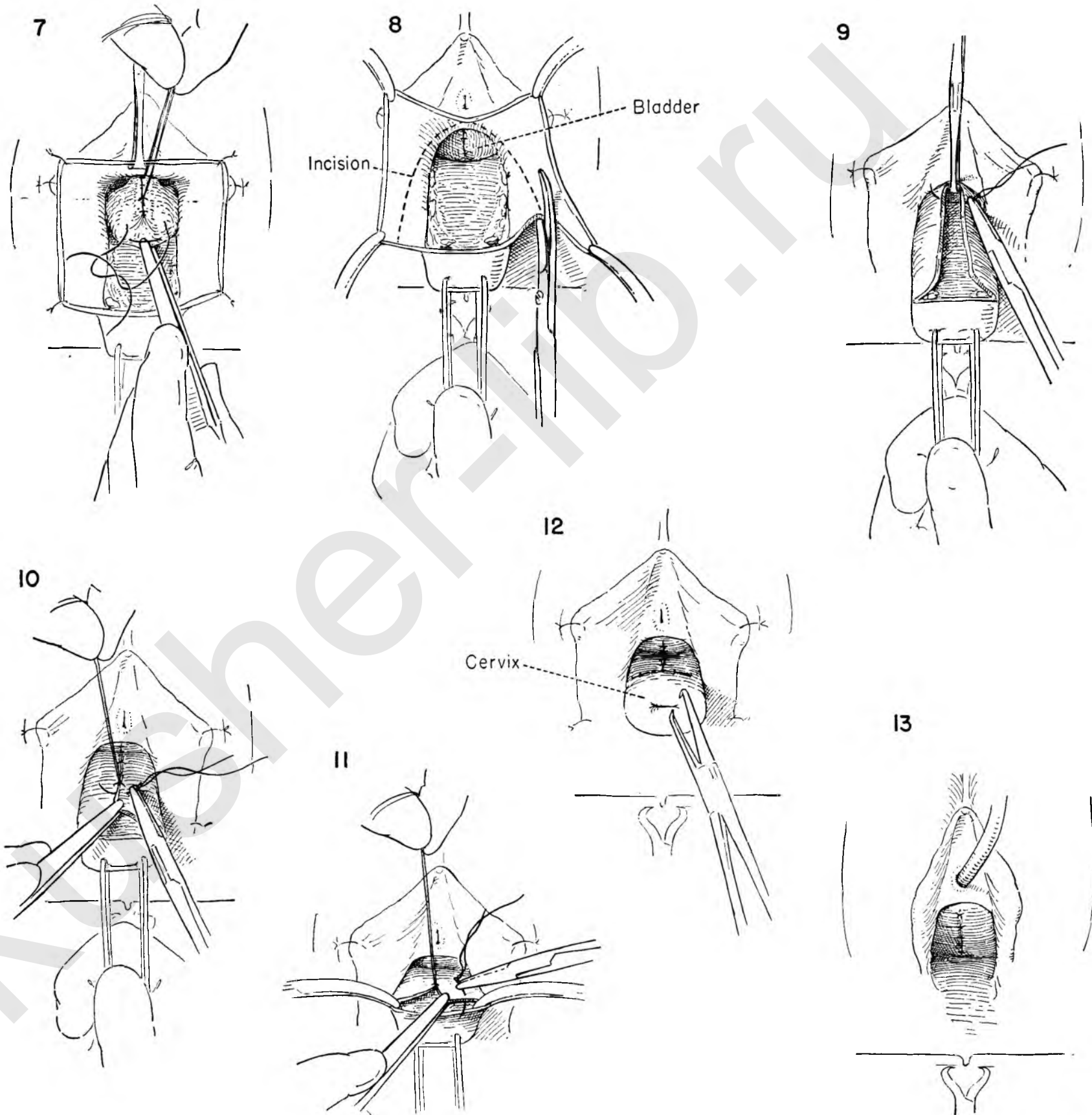
FIGURE 9. The assistant places an Allis clamp at the upper limits of the midline defect. This clamp is held upward while the cervix is held down as the surgeon places the first of the interrupted catgut sutures which will close the vaginal wall.

FIGURE 10. A series of interrupted sutures of catgut reapproximates the edges of the incision in the vaginal wall. Each suture is held up before dividing it to aid the surgeon in the placing of the next stitch.

FIGURE 11. The longitudinal portion of the incision has been finished. Further interrupted sutures close the transverse defect. Clamps on the incised edges of the vaginal wall provide exposure.

FIGURE 12. The closure is now complete and the tenacula are removed.

FIGURE 13. The cervix has returned to its normal position. Only the sutures in the anterior vaginal wall can be seen. An indwelling catheter is left in the bladder for constant drainage.



THE MANCHESTER (DONALD OR FOTHERGILL) OPERATION

When prolapse exists and vaginal hysterectomy seems inadvisable for any reason, the operation popularized by the Manchester, England, school of gynecologists has much to recommend it. It is extremely important that the cervical canal be thoroughly dilated to minimize the risk of cervical stenosis in the convalescent period.

FIGURE 1. After the cervix has been dilated and the bladder advanced, the reparative steps begin. The cardinal ligaments, consisting of the uterine vessels and fascial sheaths, can be seen coming in on either side of the cervix.

FIGURE 2. The bladder is kept out of the field by a small Deaver retractor placed over gauze. The key to the support of the uterus in this operation is the shortening of the cardinal ligaments. This is accomplished by suturing them to the amputated cervix. Strong traction of the uterus to the patient's right exposes the left arm of the cardinal ligament, and the first Fothergill suture is placed through the fascial bundle.

FIGURE 3. The uterus is now pulled to the patient's left as the surgeon continues to stitch across the surface of the cervix into the fascial sheath of the opposite side.

FIGURE 4. Two more such sutures are placed. Traction on the lowermost suture serves to expose the upper and more lateral portion of the ligament. The sutures are held in a clamp untied while the operator proceeds with the amputation of the cervix.

FIGURE 5. The cervix is held upward and the posterior vaginal wall is incised at the level of the original anterior incision.

FIGURE 6. The vaginal wall is stripped from the posterior wall of the cervix for an appreciable distance.

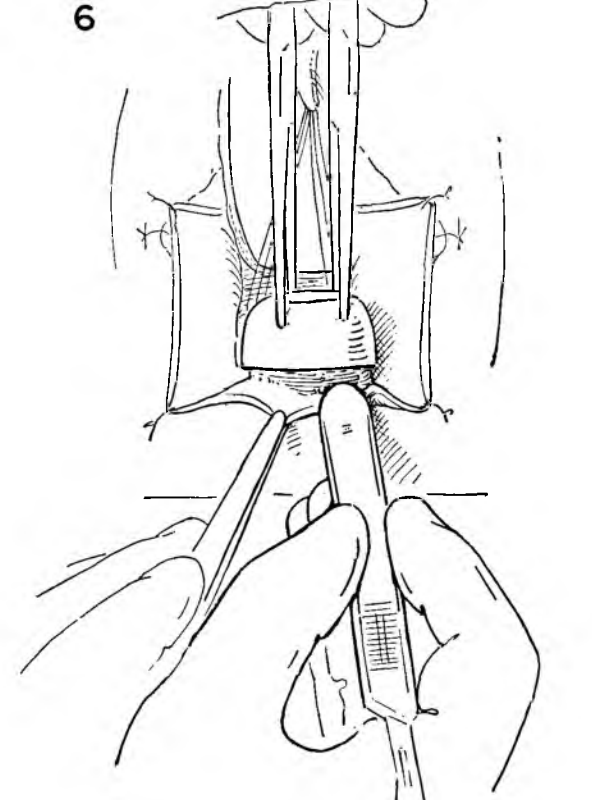
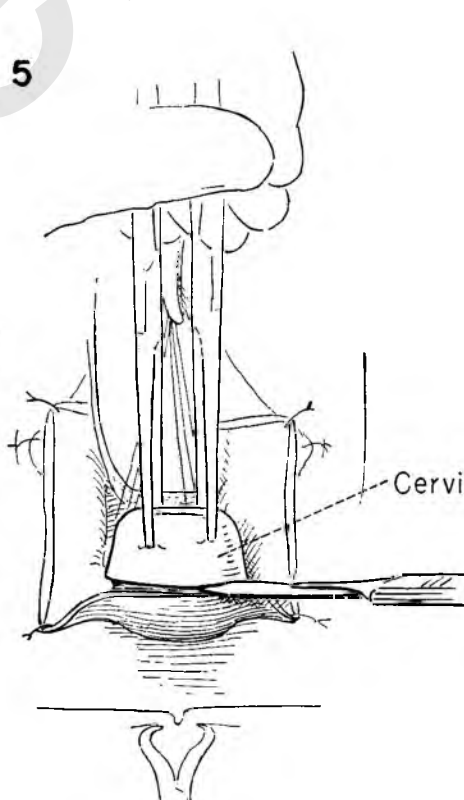
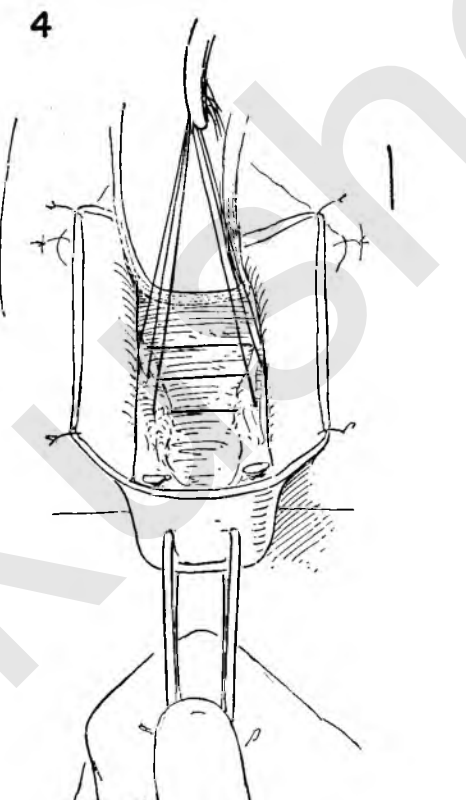
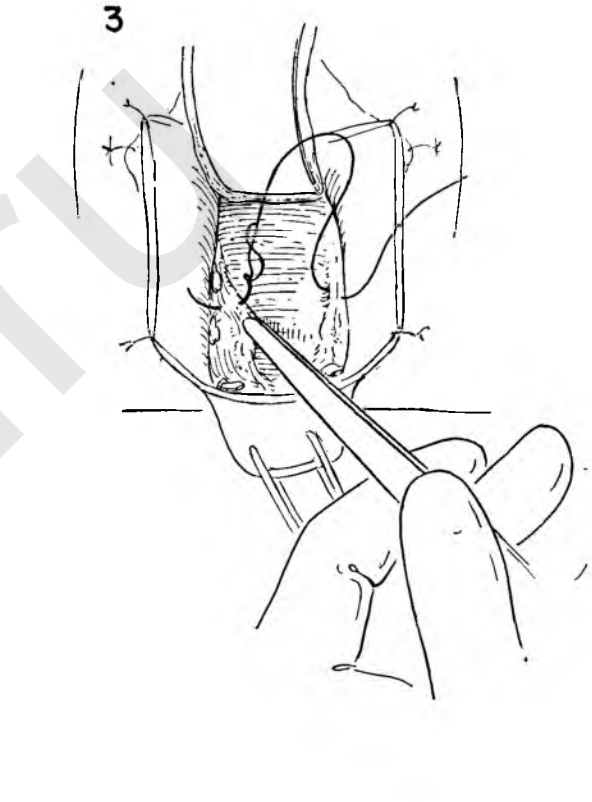
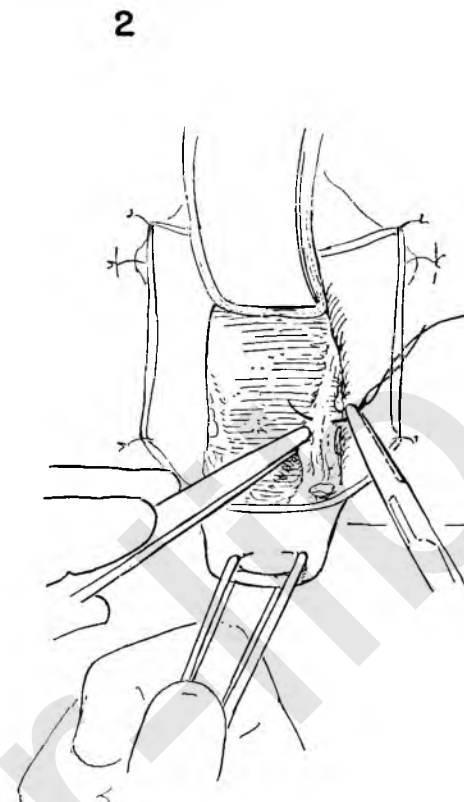
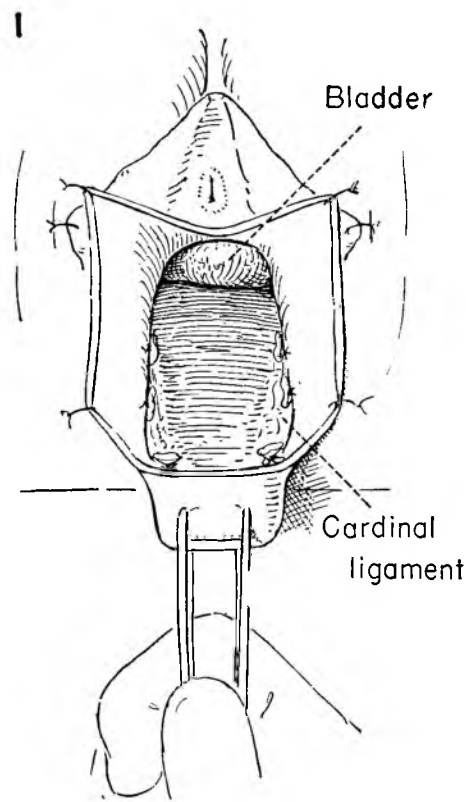


FIGURE 7. A Kelly clamp grasps the cervix at the level where amputation is to be done. It should be allowed to slip off the cervix to ensure that it includes all the tissue lateral to the cervix. The tissue in the clamp is then cut.

FIGURE 8. The tissue in the clamp is secured with a stitch ligature. These steps are repeated on the opposite side.

FIGURE 9. A final Fothergill stitch is placed through the stump of the cardinal ligament, and the ends are added to the group held long in the clamp.

FIGURE 10. The untied sutures are held taut, and countertraction is applied on the tenaculum as the surgeon begins to amputate the cervix just below the position of the last suture.

FIGURE 11. The amputation continues beveling the cervix slightly toward the canal. In order to continue traction after the cervix has been amputated it is necessary to replace the tenacula on the lateral sides of the uterus just below the ties on the cardinal ligament before the final division is made.

FIGURE 12. Both the tenacula and the long ties on the cardinal ligament are held downward as the surgeon removes the retractor and pulls the bladder into view with smooth forceps.

FIGURE 13. The cystocele must now be repaired. The assistant applies traction to the tenaculum as the surgeon places the bladder neck on tension with the index finger laid over gauze on the bladder wall. The first of the reparative sutures is then placed in the paraurethral tissue to the left of the urethra.

FIGURE 14. This suture on a small curved needle is carried across the face of the bladder to enter the paraurethral and bladder tissue directly parallel to the suture on the left.

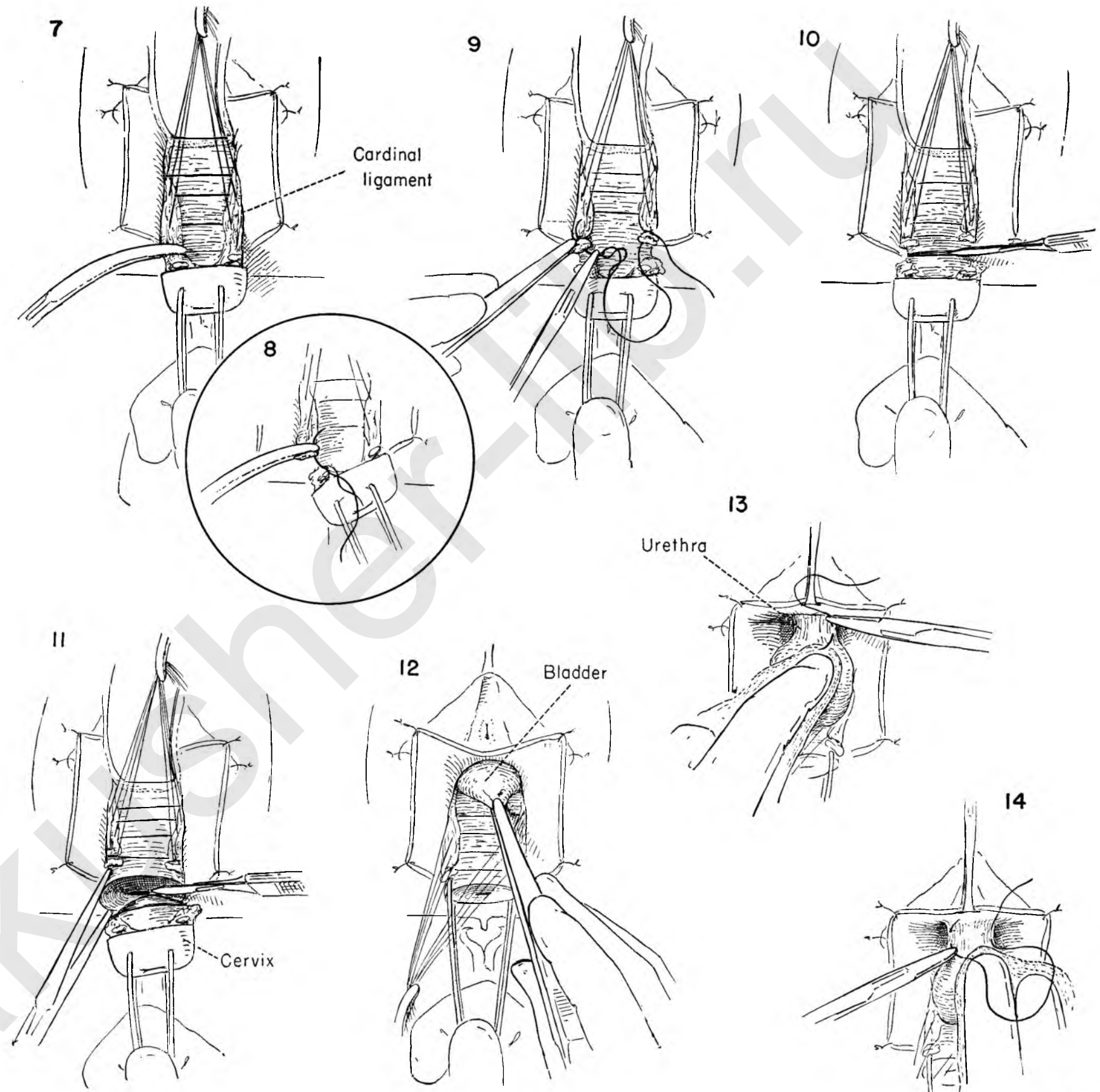


FIGURE 15. A series of interrupted sutures beginning at the urethra and descending toward the cervix has been placed in the anterior bladder wall. Enough sutures are placed to satisfactorily infold the redundant bladder. The assistants hold the bladder sutures upward and the long ties on the cardinal ligaments down.

FIGURE 16. Each of the series of sutures is tied and held long. The assistant dunks the redundant bladder wall as the last suture is tied.

FIGURE 17. After the sutures have been tied and cut the bladder retracts upward in normal position. The retraction sutures holding the cut edges of vagina have been divided and replaced with clamps.

Attention now turns to the amputated cervix, which must be covered by the vaginal wall. A Sturmdorf stitch will be used to draw the wall into its final position where it should lie without tension. A catgut suture on a cutting needle picks up the posterior vaginal wall in the midline about $\frac{1}{8}$ inch from the incised edge.

FIGURE 18. Half of a complete tie is made with this suture. The cervix is then held upward as the surgeon introduces the cutting needle into the cervical canal and brings it out through the cervical muscle and vaginal wall just lateral to the midline.

FIGURE 19. As the assistant holds up the posterior vaginal wall the other end, also on a cutting point needle, is placed in the cervical canal and brought through muscle and vaginal wall to emerge parallel to the first suture approximately $\frac{1}{4}$ inch from it.

FIGURE 20. The suture is pulled taut, drawing the vaginal wall over the raw surface of the cervical stump up into the canal. The tenacula are removed. Control over the position of the cervix can now be maintained by a clamp on the long ends of the Sturmdorf stitch.

FIGURE 21. Each of the sutures in the cardinal ligament beginning from below upward is now serially tied.

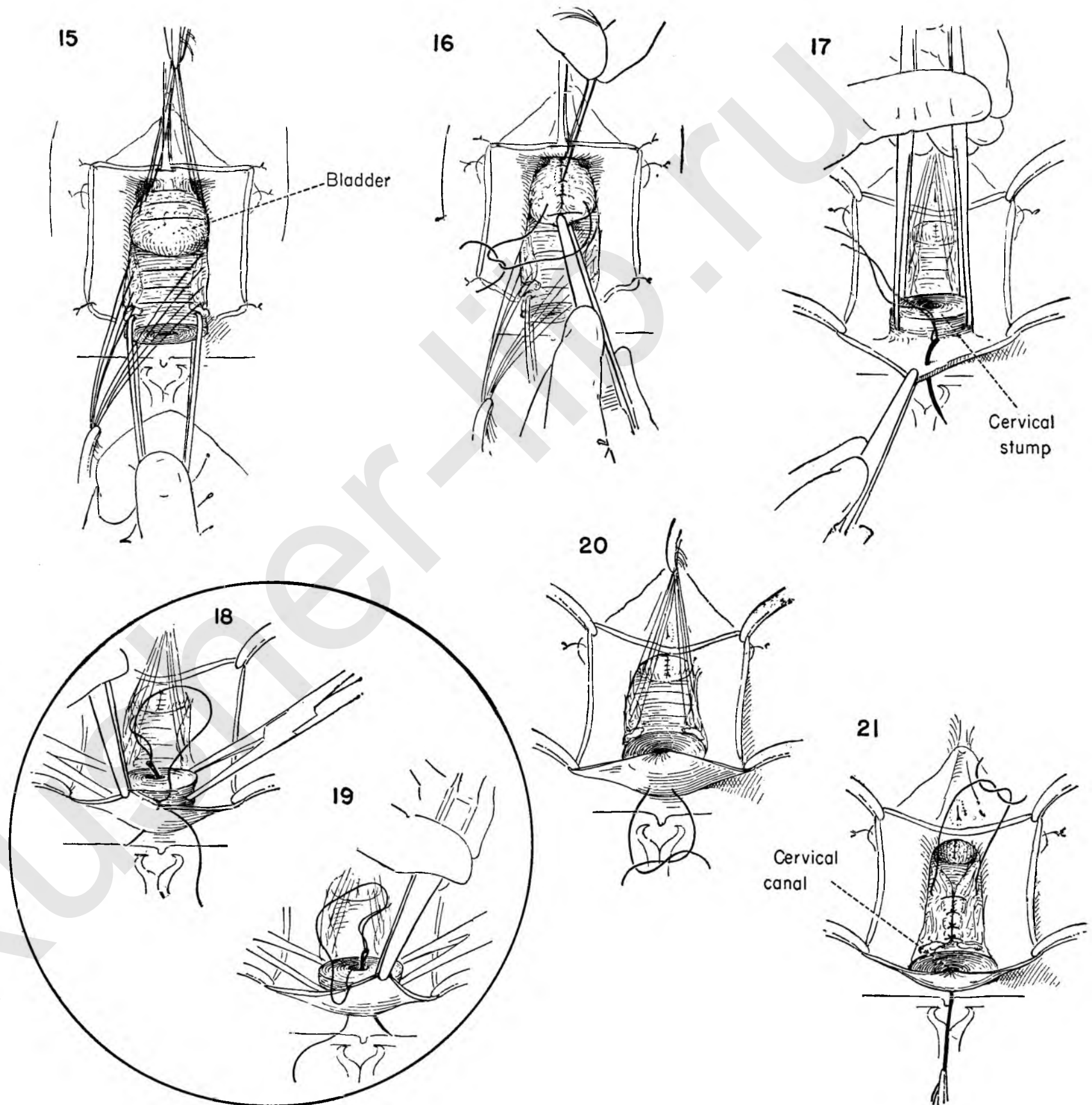


FIGURE 22. The cystocele has been repaired. The cardinal ligaments are now approximated in the midline, in front of the amputated cervix. The vaginal wall has been drawn into the cervical canal covering the raw posterior lip. The excess vaginal wall on the anterior flaps is now excised.

FIGURE 23. The surgeon estimates the amount of vaginal wall necessary to cover the anterior half of the cervix. The assistant places the left anterior flap on tension as the surgeon passes a curved cutting point needle with catgut suture through the vaginal wall at the point selected. This suture passes through the vaginal wall and cervix to emerge in the canal.

FIGURE 24. With the vaginal wall on tension the needle returns through the wall from below upward about 1/8 inch from the corner.

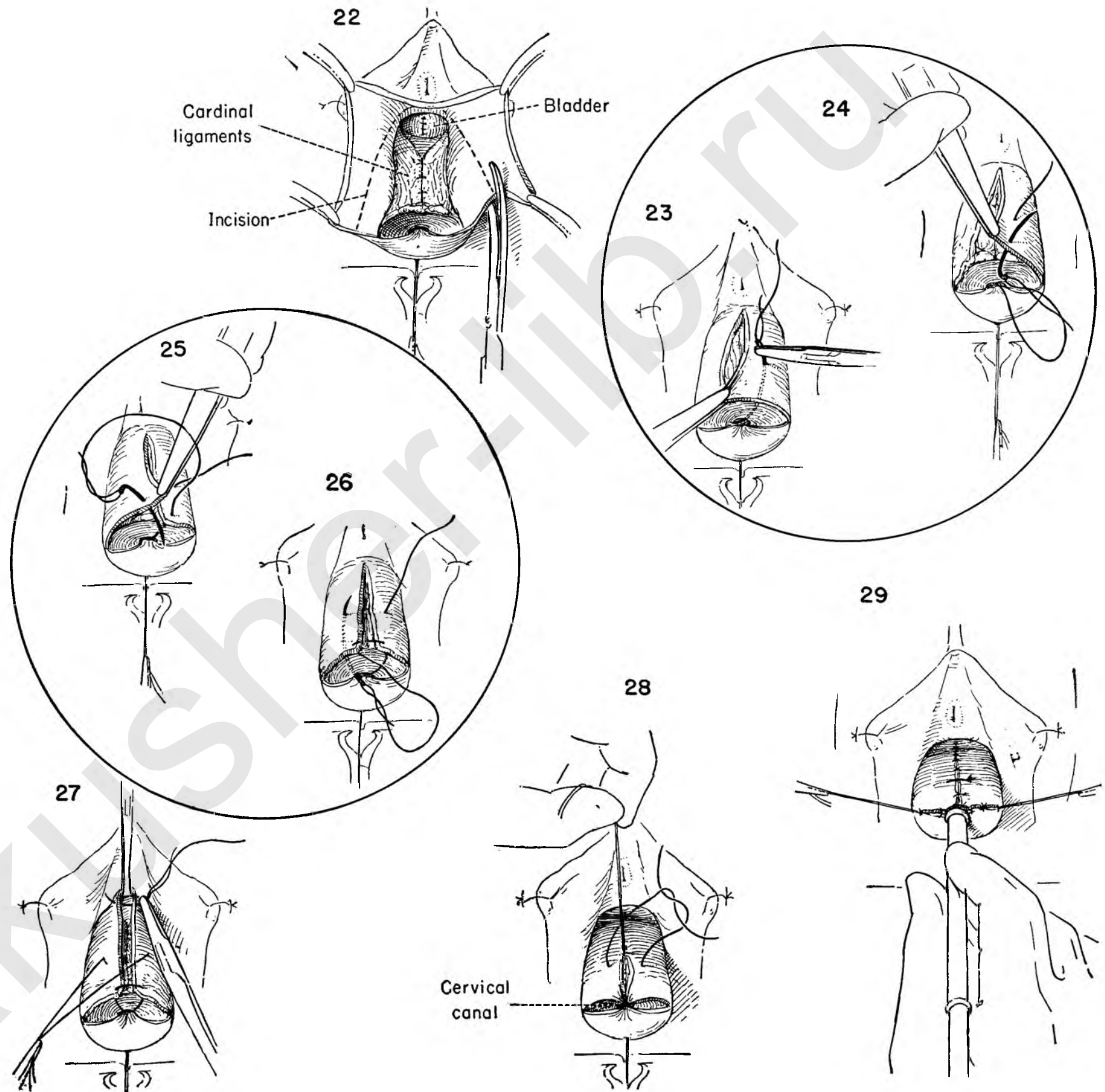
FIGURE 25. The stitch continues through the opposite leaf of vaginal wall at the same relative position, the suture being introduced from above downward.

FIGURE 26. The position of the needle is reversed and enters the cervical canal to emerge through muscle and vaginal wall opposite the point of origin.

FIGURE 27. Downward traction is exerted on the cervix. To exert countertraction an Allis clamp is placed in the midline at the upper limit of the anterior vaginal wall incision as the surgeon places the first of a series of interrupted sutures on the incised vaginal edges. The anterior Sturmdorf stitch is in place, but has not yet been tied. It is clamped and held downward.

FIGURE 28. The Allis clamp is removed as the first of a series of vaginal wall sutures is tied. As each suture is placed and tied the previous suture is cut. The anterior Sturmdorf suture which pulls the vaginal wall over the raw cervix and into the canal is now tied.

FIGURE 29. The anterior vaginal wall defect is now closed. The assistants steady the last sutures on each corner as the surgeon introduces a dilator in the canal to ensure the patency.



VAGINAL HYSTERECTOMY

When procidentia or moderate relaxation of the pelvic floor exists, the surgeon may elect to remove the uterus in the interest of a more satisfactory repair. Moreover, the vaginal approach may be selected deliberately for removal of the uterus in older patients when the risk of abdominal surgery is significant. This risk, however, must be balanced against the technical difficulty of performing this operation in the presence of a fixed uterus or one containing a sizable tumor. Safety and comfort of the patient rather than the operator's technical facility should be the guiding principle in the choice of the vaginal rather than the abdominal approach. Finally, if any suspicion of malignant disease has been raised, vaginal hysterectomy should not be performed. As in abdominal hysterectomy, dilatation and curettage are the first step.

FIGURE 1. The uterus has been curetted and the bladder advanced. The cystocele is not repaired until the reconstructive phase of the operation is begun.

FIGURE 2. The cervix is held upward toward the symphysis, exposing the posterior wall of the cervix and vagina. The surgeon then transects the vaginal wall on the back of the cervix with a knife at the level of the initial anterior incision.

FIGURE 3. With the uterus on tension the vaginal wall is stripped off the cervix. In the proper cleavage plane, bleeding is minimal.

FIGURE 4. The vaginal wall is separated from the posterior cervix until the uterosacral ligaments stand out on either side and the peritoneum of the posterior cul-de-sac appears between them.

FIGURE 5. Upward traction on the uterus continues as the surgeon picks up the posterior peritoneum and incises it, thus entering the peritoneal cavity.

FIGURE 6. If the bleeding from the incised vaginal edge is troublesome, it may be controlled by placing an interrupted suture through the wall and peritoneal edge and tying it. This will be removed later.

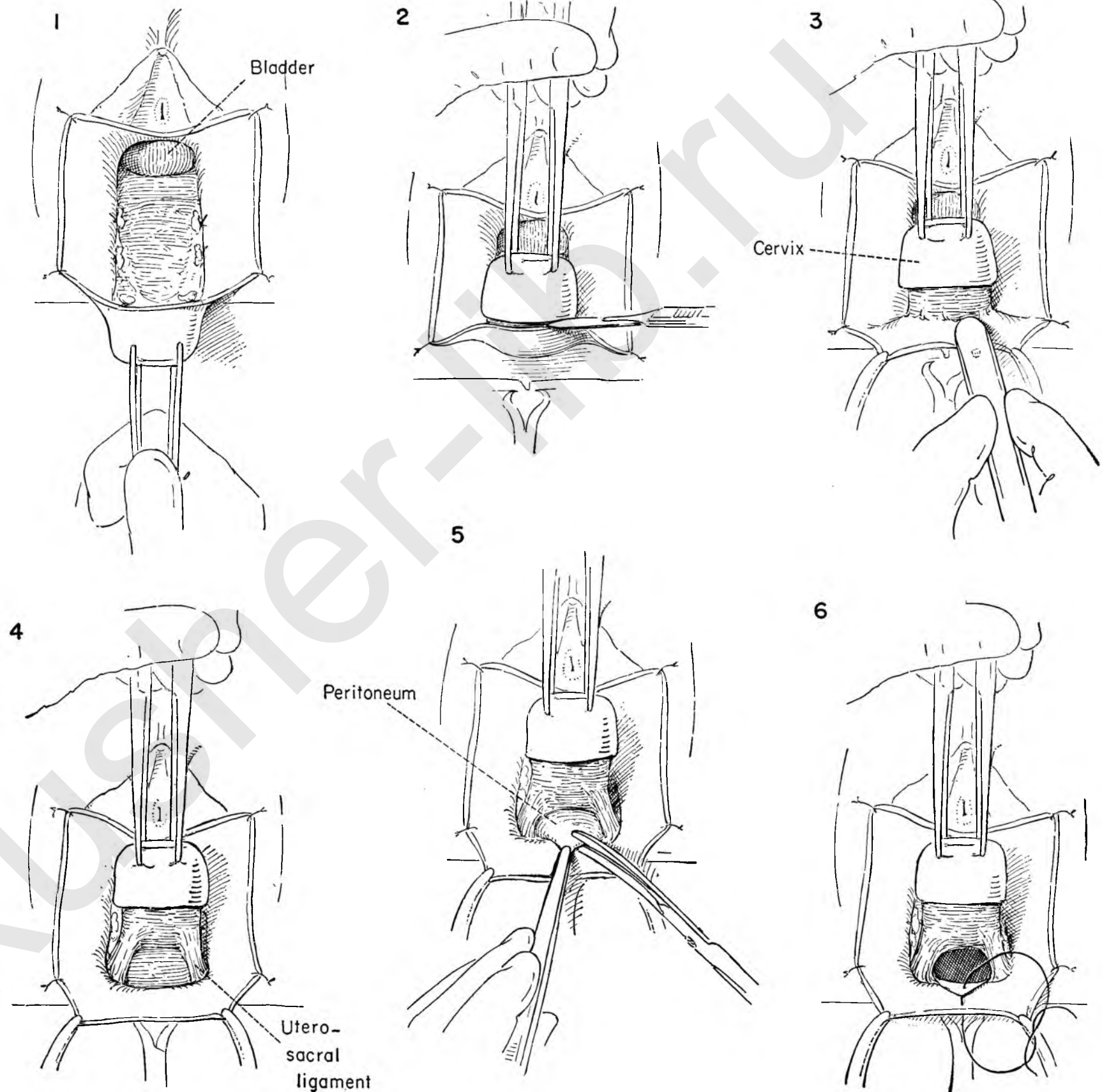


FIGURE 7. The index finger is then inserted into the peritoneal cavity and the cul-de-sac explored to be sure that nothing is adherent to the uterosacral ligament.

FIGURE 8. The cervix is placed on traction in the upward direction while the uterosacral ligament is clamped and the tissue intervening between it and the uterus is sectioned with the knife.

FIGURE 9. The tissue held in the clamp is secured with a stitch ligature and tied, but not cut. The ties are left long and clamped. They will be used later in the subsequent repair. The same steps are repeated on the opposite side.

FIGURE 10. The assistant draws the uterus sharply downward and to the patient's left as the surgeon places a Kelly clamp on the lower end of the cardinal ligament on the right side at the point of its attachment to the cervix. The clamp grasps the cervix and is allowed to slide off it to ensure that all tissue is included. Another clamp is placed below it on the uterine side.

FIGURE 11. The tissue between the clamps is then divided and a stitch ligature placed around the upper clamp and tied.

FIGURE 12. A second stitch ligature secures the pedicle on the uterine side. The cardinal ligament on the other side is similarly treated.

FIGURE 13. The uterus is held on traction and the index finger of the right hand inserted in the peritoneal cavity and around anterior to the uterus to identify the anterior peritoneal fold.

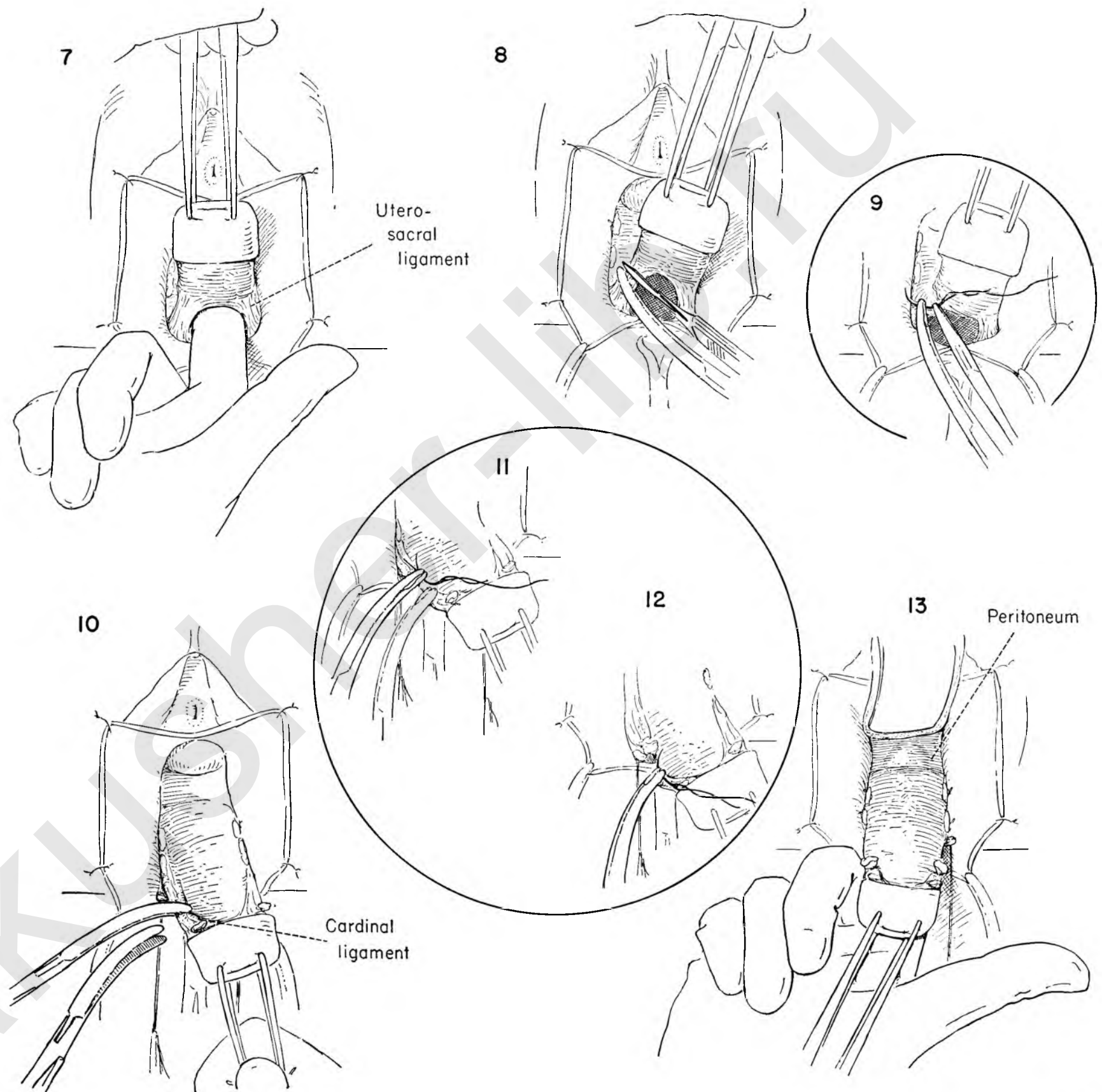


FIGURE 14. A small Deaver retractor is used to retract the bladder while the uterus is placed on downward traction. The operator then picks up the anterior peritoneal fold and divides it with scissors.

FIGURE 15. To identify the anterior leaf of peritoneum subsequently a stitch ligature is placed through it and tied. The ends are left longer than usual after section so that it can easily be found when the time arrives for peritoneal closure.

FIGURE 16. The surgeon then inserts the fingers of the right hand into the peritoneal cavity to palpate the posterior uterine surface and adnexa for possible tubo-ovarian pathology. A retractor now holds back both peritoneum and bladder.

FIGURE 17. As the hand is withdrawn the fundus of the uterus is pulled outward through the opening into the operative field, and a double hook applied to the fundus. A retractor anteriorly protects the bladder and aids in exposure.

FIGURE 18. The fundus is sharply angulated downward in order to expose the adnexa on the left side.

The operator inserts the index finger of the left hand below the adnexa to ward off possible descent of small intestine and places the first stitch around the fallopian tube and ovarian vessels. This stitch is then tied and held long.

FIGURE 19. A Kelly clamp is placed across the ovarian ligament and fallopian tube on the uterine side as the assistant holds the initial suture on tension and prepares to clamp the cut end of the stump.

FIGURE 20. The operator then places another stitch ligature around the clamp and ties it, thus placing two ties on the ovarian vessels. Both ties are then cut.

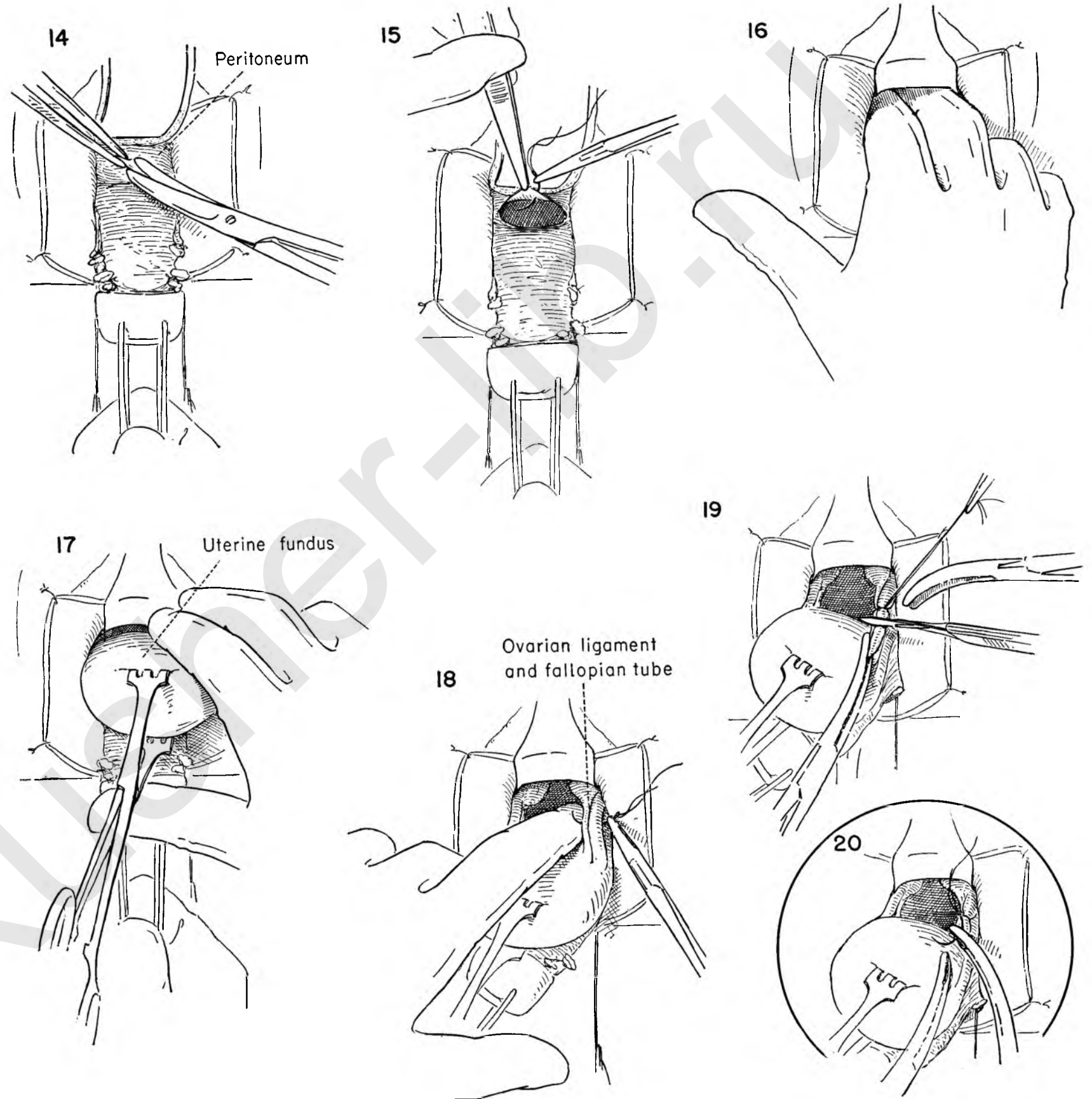


FIGURE 21. The operator pulls the uterus to the patient's right, removes the clamp on the proximal stump of the ovarian ligament and tube, and reapplies it to include the round ligament as well.

FIGURE 22. A stitch ligature is applied around the round ligament and tied. The ends are clamped and left long. The round ligament will be used in subsequent reconstruction of the pelvic floor.

FIGURE 23. The uterus continues to be drawn to the patient's right side as the assistant applies traction on the round ligament to the left. The surgeon then divides the ligament between the clamp on the uterine side and the long tie on the round ligament.

FIGURE 24. Whenever possible, the authors choose to continue to remove the uterus from above downward as in the abdominal hysterectomy. At times because of the fixation produced by associated pathology it may be necessary to approach the uterine vessels from below. The operator may elect to repeat each step on both sides as he goes along or free the uterus entirely on one side, identifying and securing the vessels before turning his attention to the opposite side. These are the steps described here.

Whatever method is chosen, adequate exposure must be obtained. The ureter is in close proximity. By stripping back the vaginal wall the broad ligament is brought into view. This move has the double advantage of producing lateral retraction of the ureter as well as exposing the uterine vessels in their relation to it.

A single clamp has been placed across the broad ligament close to the uterus in order to control the ovarian branch of the uterine artery. The tissue between the uterus and clamp is then divided.

FIGURE 25. A stitch ligature secures and ties the tissue in the clamp.

FIGURE 26. The uterine vessels are now isolated from the surrounding tissue.

FIGURE 27. Two clamps are placed on the uterine vessels, and the operator divides between them, leaving a cuff projecting from the lateral clamp.

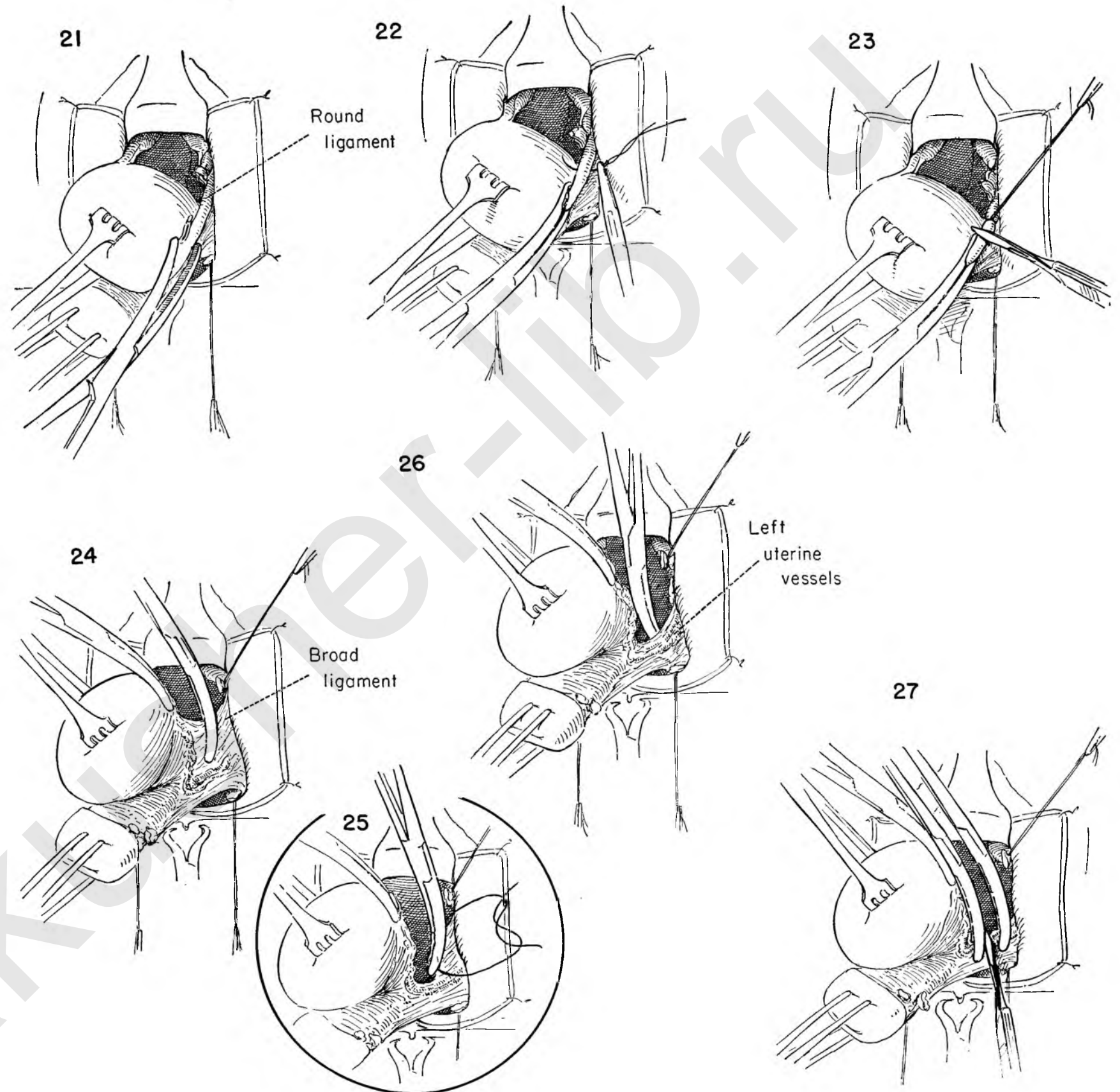


FIGURE 28. The uterus continues to be drawn to the right as a second clamp is placed on the cuff of the sectioned uterine vessels.

FIGURE 29. A stitch ligature is placed around the vessels lateral to the clamps.

FIGURE 30. The operator now prepares to tie this stitch as the first of the clamps is removed, leaving the second clamp to control the vessels if the primary tie should break.

FIGURE 31. The stitch is now tied and a second stitch is placed around the remaining clamp.

FIGURE 32. A final strand of tissue still holds the uterus on the left side. This contains the cervical branch of the uterine artery and must be clamped.

FIGURE 33. The tissue in the clamp is then tied and cut. This is in keeping with the principle that no attachment to the uterus should be cut without previously clamping it, since these supports will always retract, carrying bleeding vessels with them.

FIGURE 34. All steps are repeated on the right side.

FIGURE 35. The uterus has been removed. The tie originally placed on the posterior peritoneal edge, to identify it, is removed, and closure of the peritoneal opening is begun in the center with a fine atraumatic catgut suture.

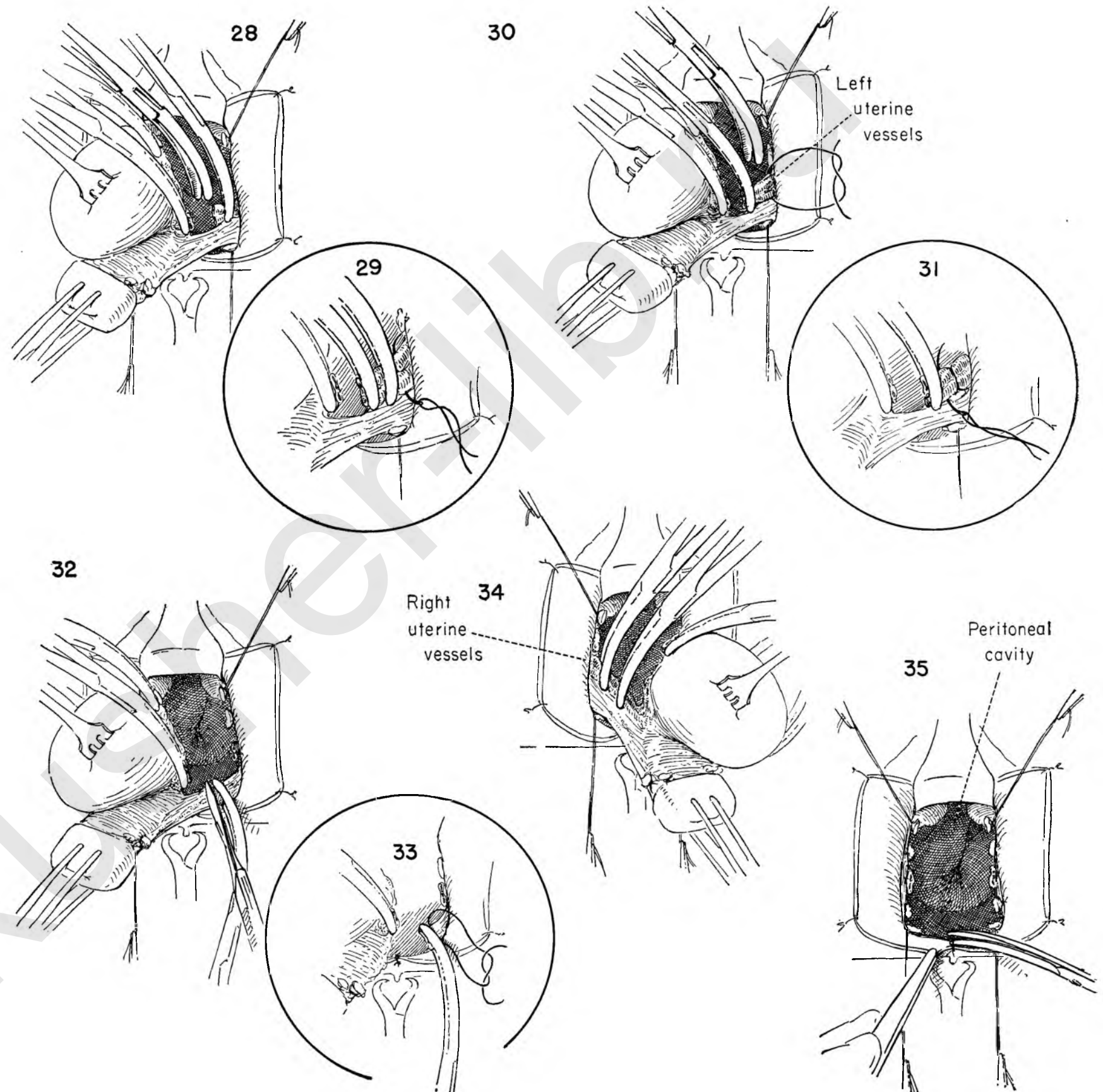


FIGURE 36. A stitch approximating the anterior and posterior peritoneal edges at their mid-points has been tied and drawn to the right to permit the application of the second of a series of interrupted sutures which close the peritoneal cavity on the patient's left. The round and uterosacral ligaments appear outside the peritoneal cavity at the lateral angle of the closed incision.

FIGURE 37. All the ties on the left are divided. The central suture is now drawn to the left to permit placing of the interrupted sutures which will close the right side of the peritoneal defect.

FIGURE 38. The surgeon now picks up the round ligament on the left and passes a stitch ligature through it. The same stitch continues through the uterosacral ligament on the same side.

FIGURE 39. The suture is brought back through the round ligament again, tied, and left long. Similar steps are carried out on the opposite side.

FIGURE 40. The bladder is now brought into view with smooth thumb forceps.

FIGURE 41. An Allis-Adair clamp is placed on the edge of the vaginal wall in the midline and drawn upward. The surgeon pulls down on the bladder and places the stitches to repair the cystocele.

FIGURE 42. The last of the interrupted sutures for the correction of the cystocele is being tied. The transverse closure of the peritoneum and the two long sutures on the round and uterosacral ligaments are evident.

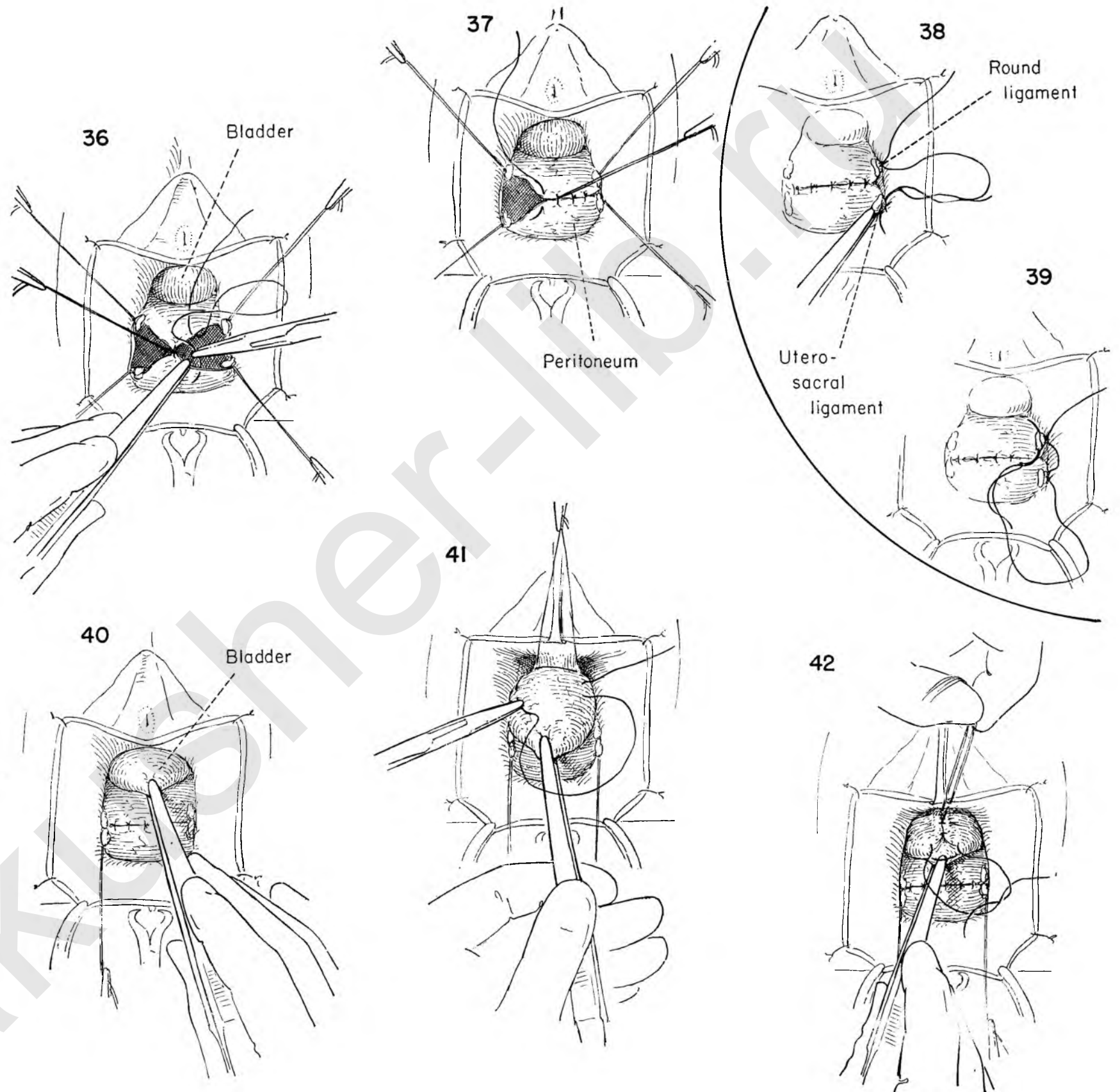


FIGURE 43. The surgeon removes some of the excess anterior vaginal wall.

FIGURE 44. A needle is threaded on one end of the suture which brought the left uterosacral and round ligaments together. This is then carried through the posterior vaginal wall about 1/2 inch from the cut edge. The same maneuver is carried out on the other loose end of the suture. Again these sutures are left untied and clamped. The same thing has been done on the right side.

FIGURE 45. An Allis clamp pulls the upper end of the anterior vaginal wall incision toward the symphysis while Kelly clamps draw down at each angle of the vaginal wall defect as the first interrupted suture closing the defect in the vaginal wall is placed.

FIGURE 46. A series of interrupted sutures approximate the vaginal edges. The untied sutures on the uterosacral and round ligaments are now tied. As the ligaments retract, the apex of the vagina is drawn upward and becomes suspended, thus minimizing the risk of subsequent prolapse.

FIGURE 47. The uterus has been removed, the cystocele repaired, and the apex of the vagina suspended. To complete the operation the surgeon should do a perineorrhaphy.

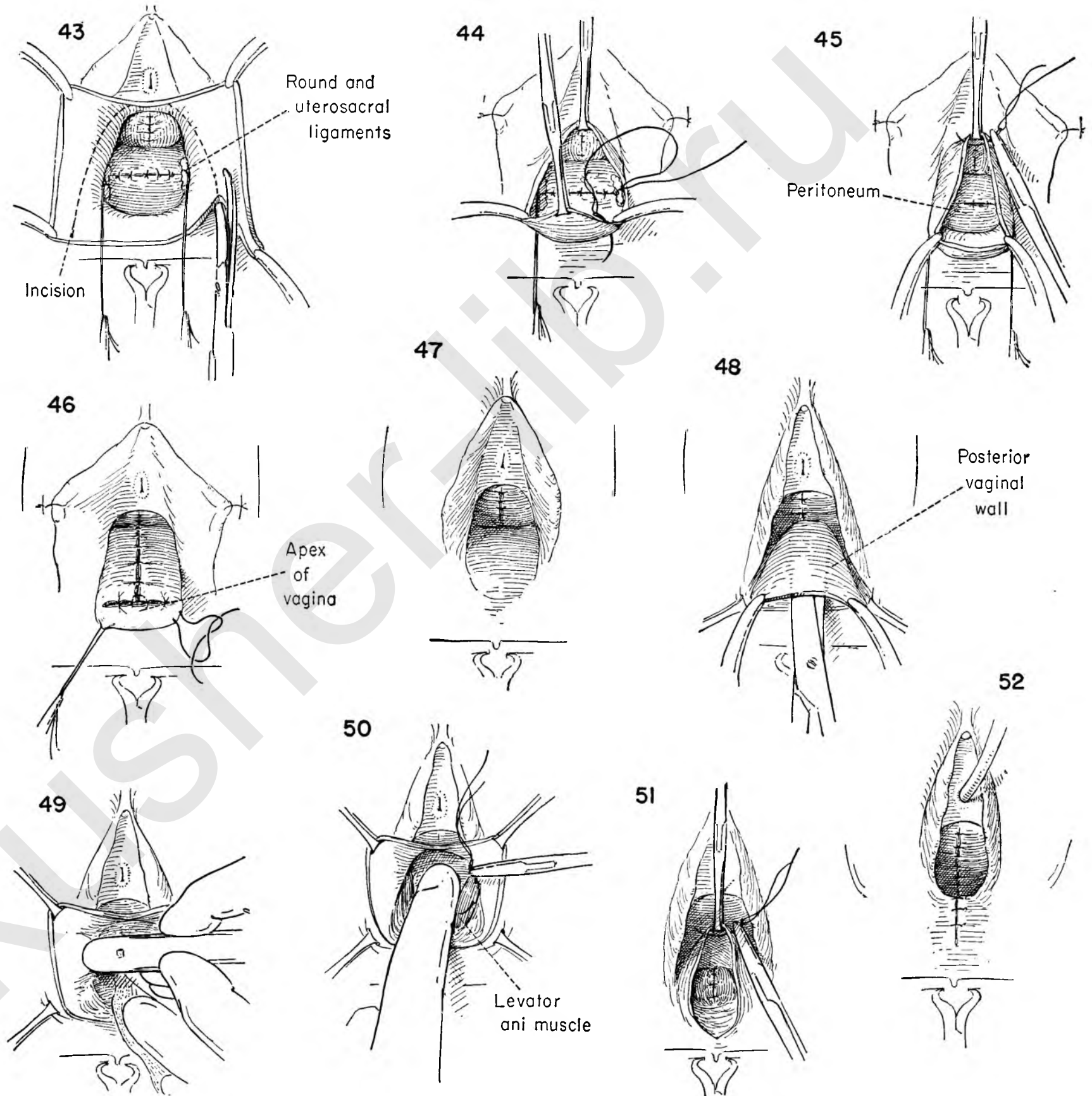
FIGURE 48. After removing the interrupted sutures holding back the labia a transverse incision is made at the junction of skin and vaginal wall at the fourchette. By using Kelly clamps as traction, the tips of the scissors are advanced upward, staying close to the under surface of the posterior vaginal wall.

FIGURE 49. The rectum is separated from the posterior lateral vaginal wall.

FIGURE 50. Separation of the rectum from the vaginal wall exposes the levator muscles. A series of interrupted sutures approximates them in front of the rectum.

FIGURE 51. These sutures are tied. The first interrupted suture to approximate the vaginal edges is being placed at the apex.

FIGURE 52. A few final stitches have been placed in the skin to complete the operation.



KENNEDY REPAIR FOR STRESS INCONTINENCE

A simple procedure for correction of the sagging neck of the bladder, which is the basic cause of stress incontinence, is the Kennedy type of repair.

FIGURE 1. The bladder previously advanced is now brought into the field.

FIGURE 2. The full length of the urethra is exposed, and the first of a series of interrupted atraumatic sutures passes into the paraurethral tissue at the bladder neck on the left, and carries across the face of the urethra to enter a corresponding area on the right. The sutures must not perforate the lumen of either urethra or bladder.

FIGURE 3. Several such sutures are placed along the urethra, tied, and cut.

FIGURE 4. If any redundancy remains in the urethra, a second series of infolding sutures is similarly placed. The caliber of the urethra is deliberately reduced. These are the basic sutures in the Kennedy repair.

FIGURE 5. The cystocele is now corrected by three shallow mattress sutures placed in the bladder wall to either side of the midline.

FIGURE 6. The excess vaginal wall has been trimmed away. To help support the urethra the vaginal wall will now be fixed to the under surface of the pubic rami with fine wire sutures.

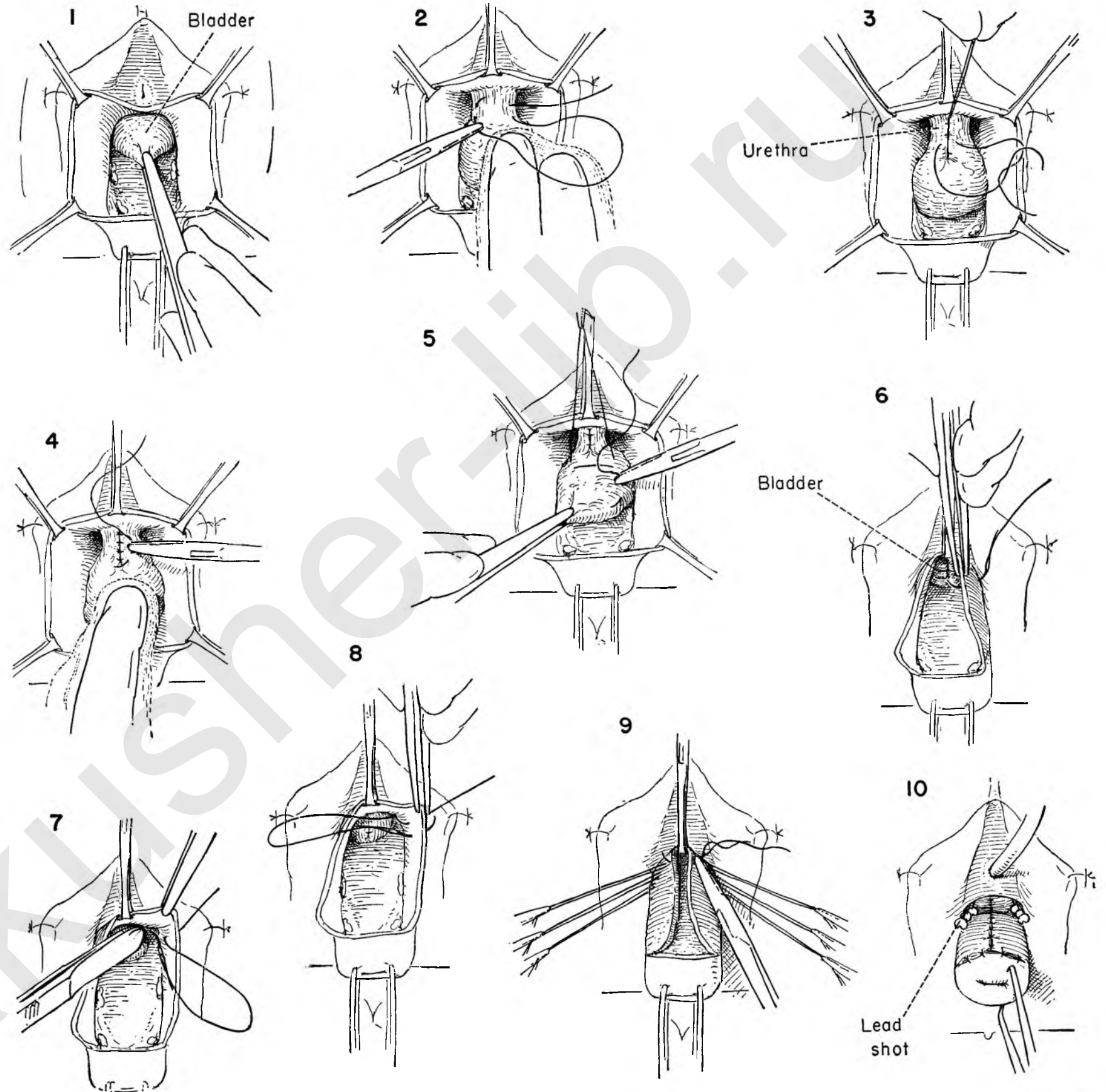
Avoiding the bladder, the suture is first introduced from the vaginal side about 1.5 cm. from the edge of the incision.

FIGURE 7. As the assistant holds up the vaginal flap the surgeon passes the wire through the periosteum of the pubic ramus on its under surface.

FIGURE 8. The same suture is brought out through the vaginal wall 4 to 5 mm. from its point of entrance and the ends held long.

FIGURE 9. Two more wire sutures are placed lateral to this one. The same procedure is carried out on the other side. The vaginal wall is closed in the usual way.

FIGURE 10. The ends of each wire suture are twisted together, snugging the vagina up in place, and small lead shot is squeezed over the ends for protection.



LE FORT OPERATION

Vaginal canal prolapse in an elderly poor risk patient presents a problem. The Le Fort procedure is technically simple and can be performed quickly with a minimal amount of shock to the patient. The net result is an obliteration of the vagina. Because the uterus is not removed, a curettage must be done first.

FIGURE 1. The prolapsed uterus is placed on downward traction and the portion of the anterior vaginal wall to be removed is outlined. A transverse incision is made through the vaginal folds above the cervix, leaving enough vaginal wall to be brought together over the cervix without tension later in the reconstructive phase.

FIGURE 2. The edges of the flap thus started are grasped with Kelly clamps, held upward on tension and stripped away with scissor dissection.

FIGURE 3. The cervix is held upward toward the symphysis. The surgeon outlines the area of posterior vaginal wall to be denuded. Care should be taken that this is not too extensive. Bringing the raw surfaces of anterior and posterior vaginal wall together may produce tension on the bladder neck and create stress incontinence.

The lines of incision flare outward on each side as they approach the fourchette, where they are connected by a transverse cut.

FIGURE 4. The posterior flap is held upward and stripped away over the area outlined.

FIGURE 5. The surgeon picks up the edge of the vaginal wall cuff on the left side of the cervix and passes a curved needle with catgut suture through the lateral corner of the anterior vaginal wall.

FIGURE 6. This suture passes across the face of the upturned cervix and enters the posterior vaginal wall at a point directly opposite the origin of the suture on the anterior wall.

FIGURE 7. This suture is tied. The anterior and posterior edges of the vaginal cuff are thus approximated in front of the cervix.

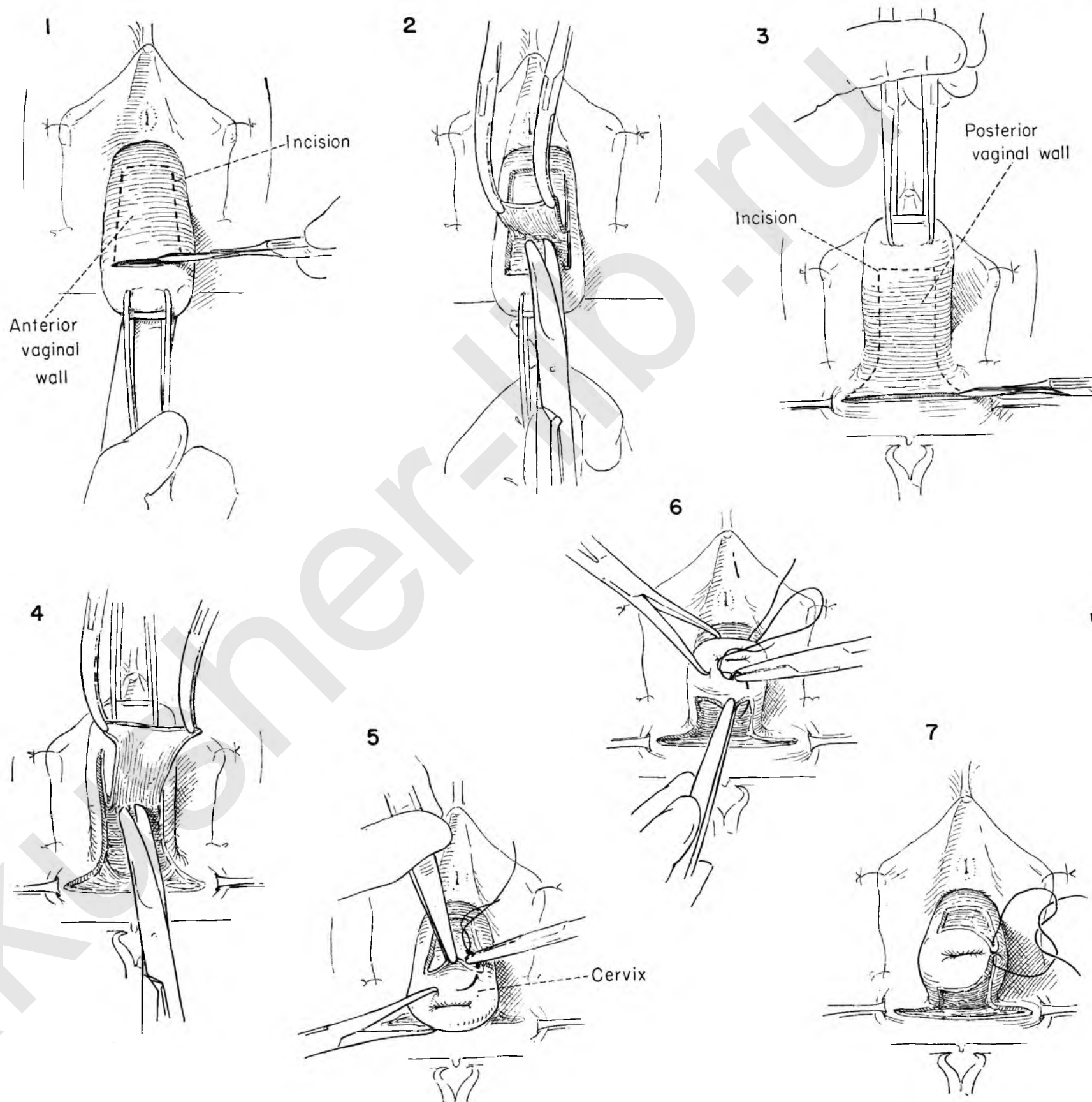


FIGURE 8. A series of interrupted sutures bring the raw edges of the vaginal wall cuff together, front to back. The cervix disappears behind this barrier. The last of the primary row of sutures is being tied.

FIGURE 9. A second row of interrupted sutures buries the first layer. These sutures are begun laterally and are placed progressively across the face of the buried cervix. The first suture in this series is being introduced. This one approximates the cut edge of vagina as a horizontal mattress suture.

FIGURE 10. Additional vertical mattress sutures are laid in across the raw surfaces. These are not tied until all are properly in position.

FIGURE 11. Successive layers are placed, tied and cut in this manner. As each layer is completed the uterus is advanced farther upward.

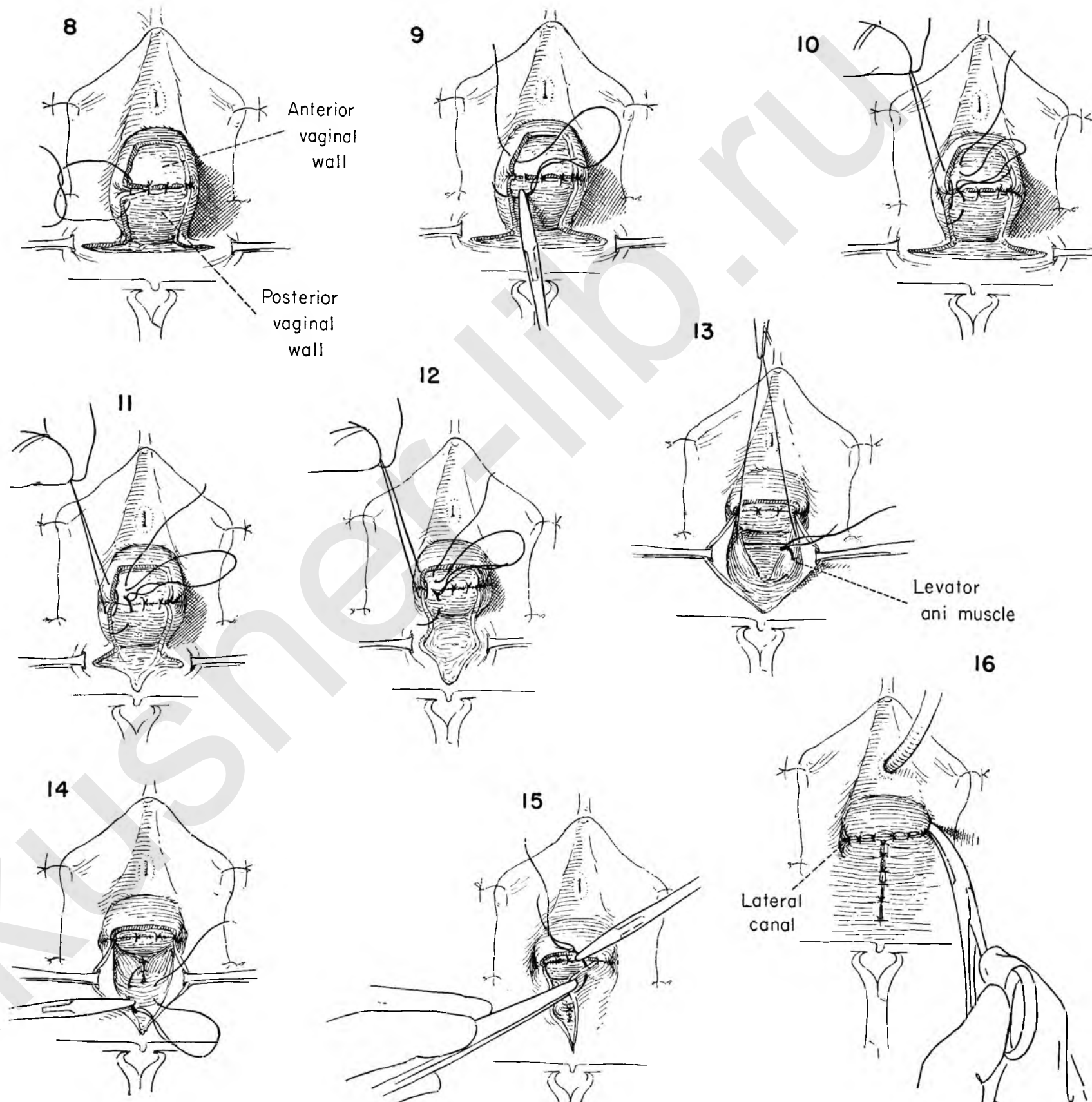
FIGURE 12. Note that the vaginal wall defect gradually closes as each of the inverting layers of sutures is placed. The defect at the fourchette also narrows down toward the midline.

FIGURE 13. The anterior closure is complete and the uterus displaced upward. Interrupted sutures are now placed in the levator ani muscles and held long until all are placed. They are then tied and cut, thereby approximating the levator ani muscles in front of the rectum.

FIGURE 14. Before completion of the closure of the vaginal wall, interrupted catgut sutures are placed in the perineal body. These are then tied and cut.

FIGURE 15. The remaining raw edges of the vaginal wall are approximated in the midline with interrupted sutures.

FIGURE 16. The vaginal wall closure is now complete. The opening of one of the two lateral wall canals left along the side of the closed vagina is indicated by the tip of a Kelly clamp. These canals allow for drainage. An inlying catheter is left in the bladder.



TOTAL OBLITERATION OF THE VAGINA

After total removal of the uterus the support of the apex of the vaginal canal may become so enfeebled that varying degrees of prolapse may result. When the patient is in the younger age group, the surgeon turns to the various types of operation designed to support the vagina while maintaining patency of the canal.

In the older age group the surgeon may elect to obliterate the vagina. One method of accomplishing this is by the Le Fort procedure, particularly applicable when the uterus is present. When it is absent, obliteration of the vagina by denuding it of epithelium and approximating the pubococcygeous muscles in the midline is an acceptable method.

FIGURE 1. The prolapsed apical portion of the vaginal wall is held on tension in exactly the same manner one would grasp the cervix if the uterus were present. A transverse incision is made in the anterior vaginal wall. The lateral corners are placed on traction, and the bladder is separated from the vaginal wall by advancing the tips of the scissors upward toward the urethra as pressure is applied to the under surface.

FIGURE 2. The anterior vaginal wall is divided in the midline.

FIGURE 3. The loose areolar attachments of the bladder wall are gently separated from vaginal wall and peritoneum with the thumb.

FIGURE 4. The posterior vaginal wall is exposed by traction upward on the vaginal apex, and an incision is made at the fourchette.

FIGURE 5. The apex of the vagina is held upward and the lower corners down as the surgeon advances the tips of the scissors along the under surface of the vaginal wall.

FIGURE 6. The vaginal wall is split in the midline.

FIGURE 7. The vaginal wall is then peeled off the rectum.

FIGURE 8. The vaginal apex is turned downward and traction applied as the anterior lateral wall is incised transversely at the apex.

FIGURE 9. The anterolateral walls are then stripped from the underlying peritoneal cover of the vaginal hernia with the handle of the knife.

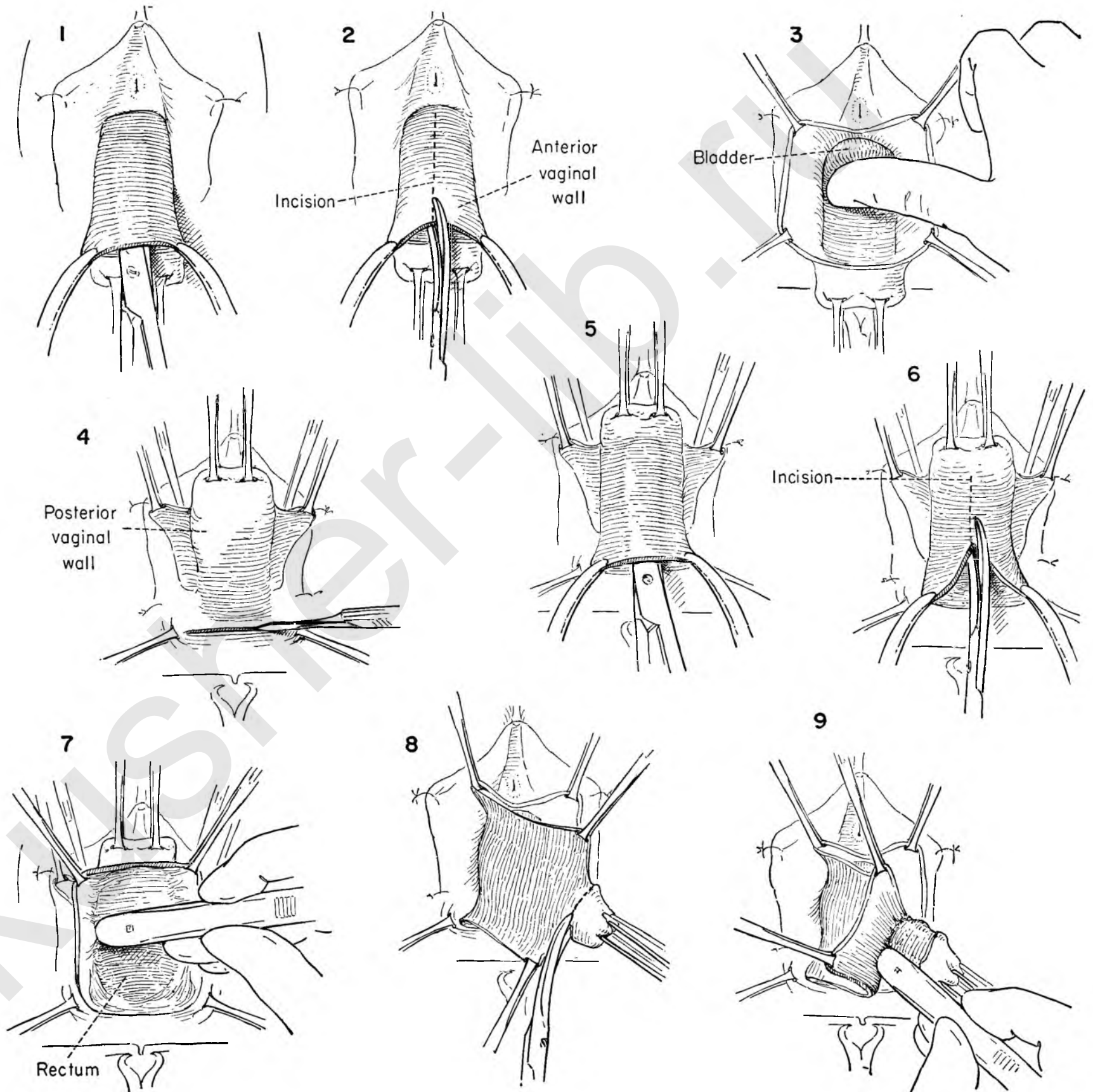


FIGURE 10. The vaginal apex and peritoneal herniation, completely denuded of vaginal wall, are placed on traction as the excess of vaginal wall is excised.

FIGURE 11. The anterior fold of peritoneum is identified, picked up with forceps and incised.

FIGURE 12. Stay sutures are placed on the upper edge of peritoneum and the excess of peritoneum representing the hernial sac excised as it is placed on tension.

FIGURE 13. The peritoneal cavity is then closed with interrupted catgut sutures.

FIGURE 14. The cystocele is then repaired in the usual fashion.

FIGURE 15. The remaining vaginal wall is placed on tension as the surgeon develops the edge of the pubococcygeus muscle with the knife handle, gently separating the muscle so that it can be mobilized medially. This is done on both sides.

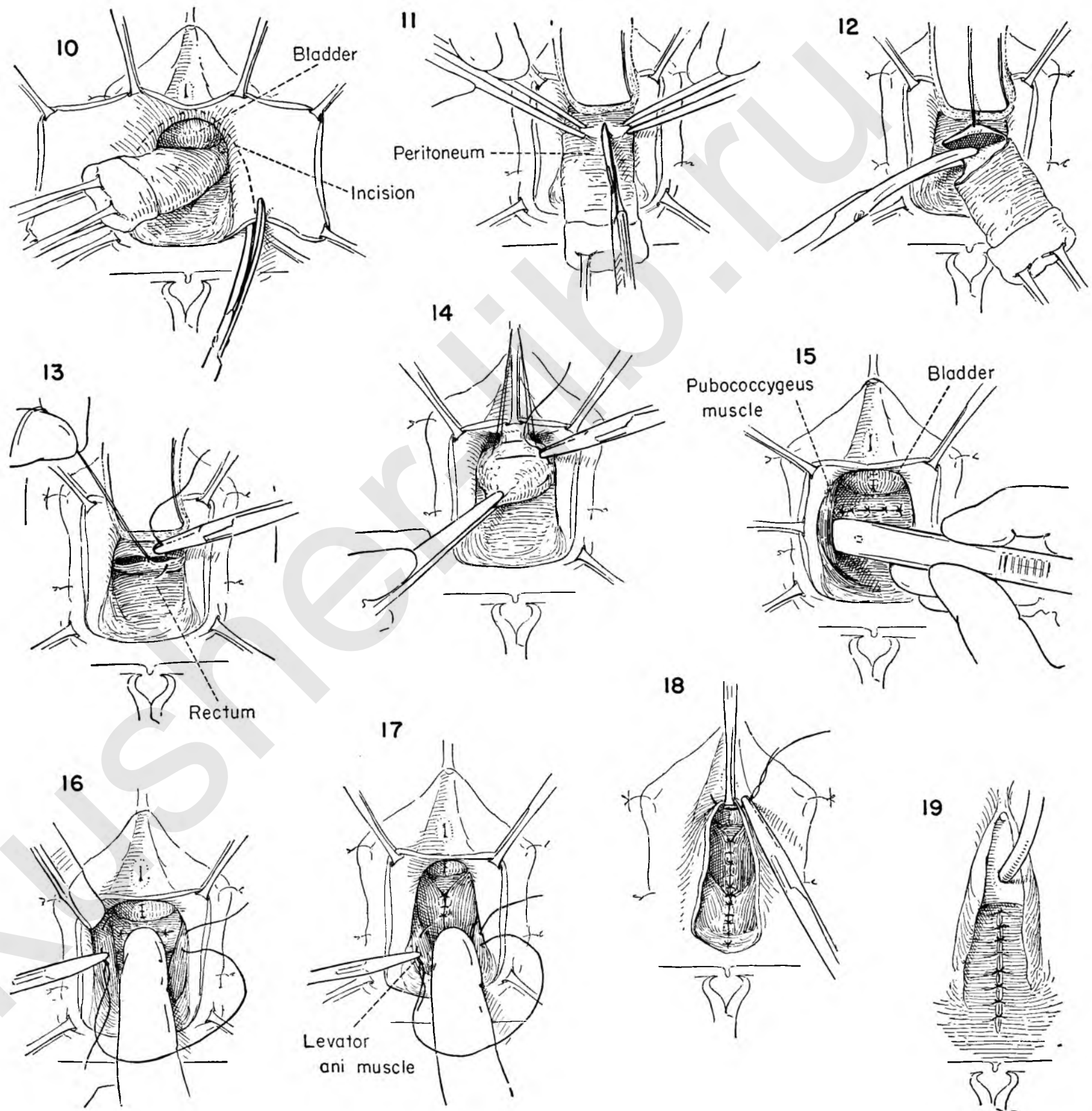
FIGURE 16. The peritoneum is protected with the index finger as the surgeon places a catgut suture on a curved needle into the muscle bundle on the left from above downward. This is carried across the face of the bulging peritoneum and enters the muscle bundle on the opposite side and is passed from below upward.

A series of such sutures are so placed.

FIGURE 17. The pubococcygeus has been approximated in the midline by interrupted sutures which have been tied and cut. The opposing surfaces of the levator muscles will be brought together to strengthen the support. The initial suture enters the muscle from above downward, passes across the rectum, which is protected by the index finger, and enters the right levator in the same corresponding position.

FIGURE 18. A series of such interrupted sutures are placed, tied and cut. The apex of the vaginal wall incision is held upward as the first of a series of interrupted catgut sutures is introduced. Each suture is held until the next one is in position and is then cut.

FIGURE 19. The vaginal wall has been closed and the vagina obliterated. An inlying catheter is placed in the bladder.



EXCISION OF CERVICAL STUMP

After supracervical hysterectomy the remaining cervix may exhibit a variety of lesions of pre-cancerous connotation which indicate the desirability of its excision. It may be the source of chronic infection or descend from its normal position at the apex of the vagina. All conditions would call for its removal.

FIGURE 1. The labia are tacked to the skin with interrupted sutures. Tenacula on the cervical stump are placed on downward tension as the surgeon makes an incision in the vaginal wall below the transverse folds.

FIGURE 2. The tenacula are held upward toward the symphysis and the posterior vaginal wall is incised at the same level, completing the circumcision of the stump.

FIGURE 3. With the vaginal wall and tenacula on tension the surgeon dissects the flap away from the anterior wall of the cervix with the tips of the scissors held downward. The secret of this procedure is to stay on the cervix at all times.

FIGURE 4. The cervix is retracted upward and the posterior surface similarly freed.

FIGURE 5. With the cervix denuded of vaginal wall on all sides, the attachments of the cardinal ligaments containing the cervical branches of the uterine artery come into view on the lateral side. The cervix is drawn to the patient's right and a clamp applied to the ligament before dividing it.

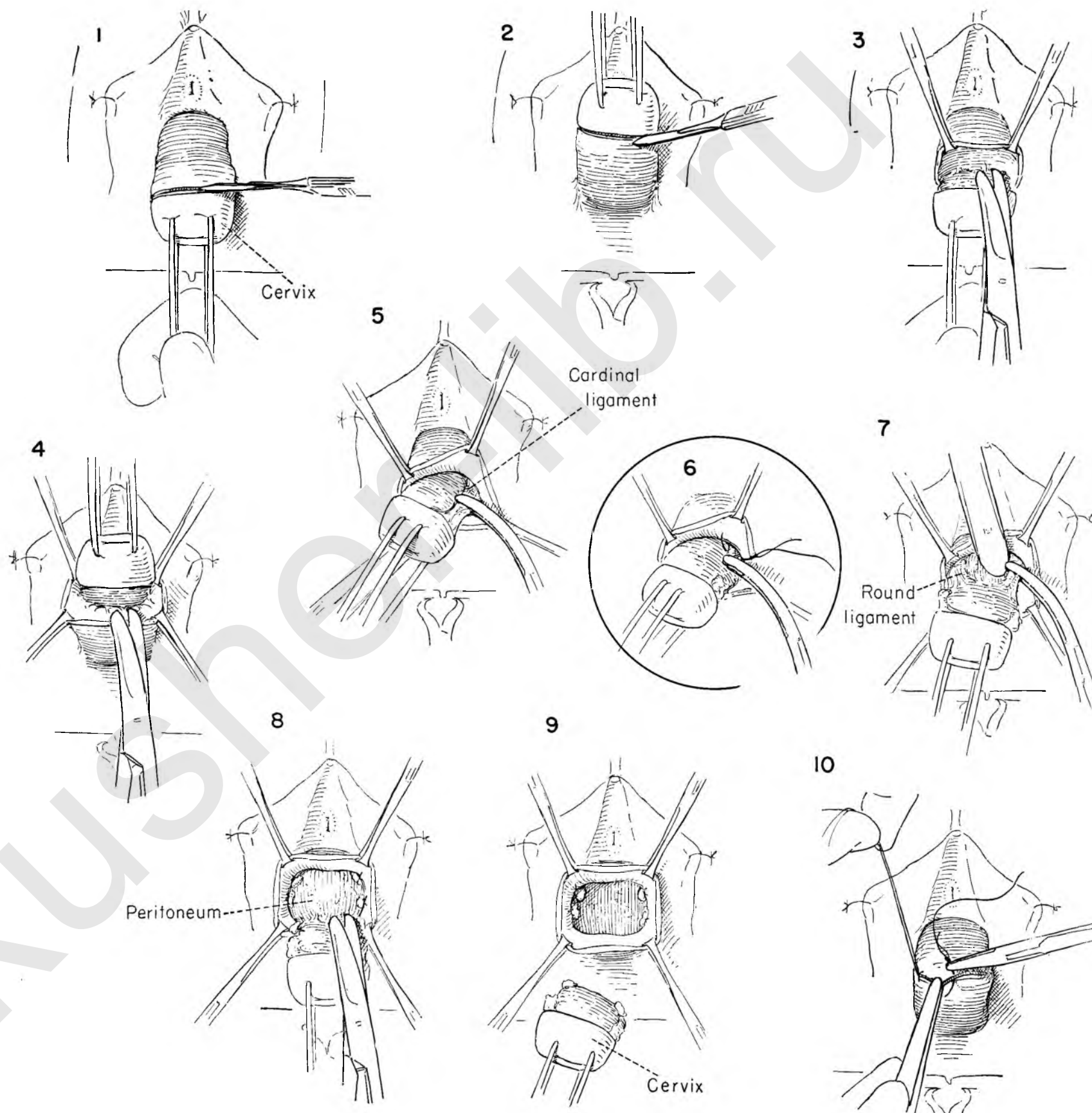
FIGURE 6. The tissue in the clamp is secured with a stitch ligature.

FIGURE 7. The peritoneum is gently pushed back off the cervix with the handle of the knife, the round ligament attachments are clamped and divided, and a stitch ligature is placed around the clamp and tied. The same steps are repeated on the opposite side.

FIGURE 8. The assistant exerts countertraction on the vaginal wall as the surgeon pulls down on the tenacula and teases the peritoneum off the upper end of the cervical stump.

FIGURE 9. The cervix can usually be removed without entering the peritoneal cavity. Any rent in the peritoneum must be closed.

FIGURE 10. The vaginal opening is closed transversely.



SIMPLE PERINEAL REPAIR

In many instances, particularly in association with an abdominal hysterectomy, a simple perineal repair gives added pelvic support and an increased sense of well-being by reconstructing the perineal body.

FIGURE 1. Allis clamps are placed on the lateral sides of the vagina opposite one another at the point indicated by the hymenal remnants. These clamps are placed on tension, and a transverse incision is made across the vaginal wall just above the fourchette.

FIGURE 2. Traction continues as the surgeon elevates the upper edge of the posterior vaginal wall and gently separates it from the underlying muscles of the perineal body.

FIGURE 3. The apex of the triangular flap of vaginal epithelium is then pulled downward and the excess removed with a V incision.

FIGURE 4. The levator muscles come into view on either side. A stitch is placed in the muscle on the left.

FIGURE 5. This is carried across the front of the rectum and inserted in the levator ani muscle on the right in the same relative position.

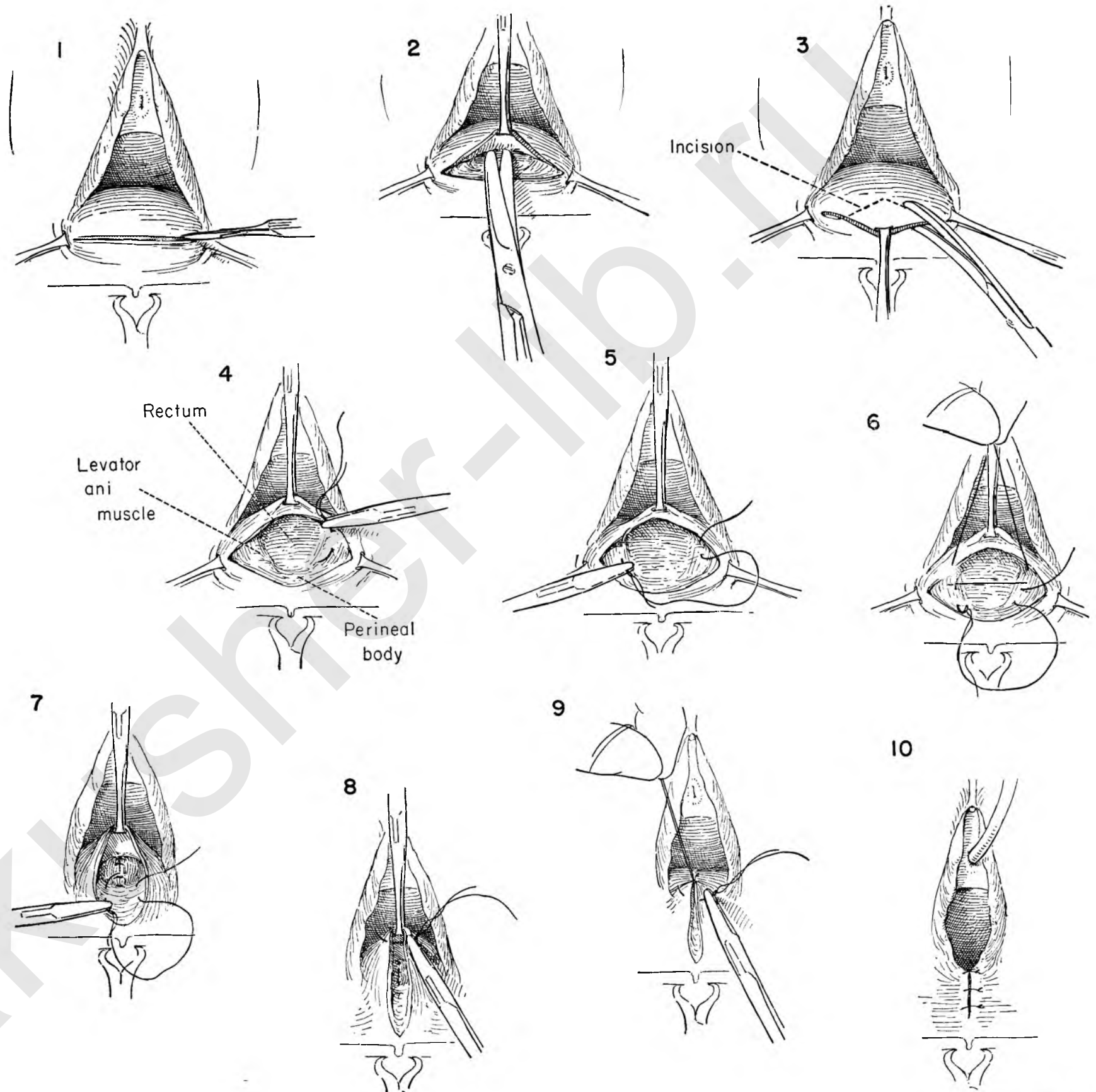
FIGURE 6. The first stitch has been laid in and is being held as the second stitch is placed.

FIGURE 7. The sutures are then tied, bringing the muscle bundles together, and then cut. Additional sutures are used to approximate the structures which form the perineal body, thus raising the fourchette and reestablishing the normal relationship between anus and vagina.

FIGURE 8. The vaginal wall is now closed with interrupted catgut sutures loosely tied.

FIGURE 9. The Allis forceps is removed after the first stitch has been introduced and each stitch held long as the next one is placed.

FIGURE 10. The vaginal wall has been closed. There is still a defect in the skin of the perineum. The skin edges are brought together without tension by interrupted sutures.



RECTOCELE REPAIR

When the separation of the levator ani muscles has been extensive, the upper portion of the vagina bulges out over the relaxed perineal body.

FIGURE 1. Allis clamps are so placed that when they are brought together in the midline a normal vaginal outlet results.

FIGURE 2. These clamps are used to hold the posterior vagina on tension as the surgeon incises the vaginal wall transversely between the clamps.

FIGURE 3. Kelly clamps are placed on the upper edge and pulled downward as the surgeon advances the scissors with the tips upward, staying close to the vaginal wall in the midline.

FIGURE 4. With the edges still on traction the surgeon divides the elevated vaginal wall in the midline.

FIGURE 5. The upper edges of the vaginal flap are grasped with Allis forceps on either side. The traction is maintained on the lower clamps throughout the procedure to the final steps.

FIGURE 6. The edges of the right flap are held on traction to the patient's right as the surgeon pulls the rectum medially with gauze laid over the rectal wall for increased purchase. He then begins to dissect the fibrous strands, holding the small vessels free from the under surface of the vaginal flap.

FIGURE 7. Once the cleavage plane is established the rest of the separation is readily accomplished by using the knife handle.

FIGURE 8. The levator ani muscle on both sides is freed from the bulging rectum to permit careful placing of the sutures.

FIGURE 9. The upper and lower clamps are held on tension as the surgeon places a mattress stitch in either levator ani muscle bundle. As each suture is placed the rectum is pushed back with the left index finger to avoid injury to it.

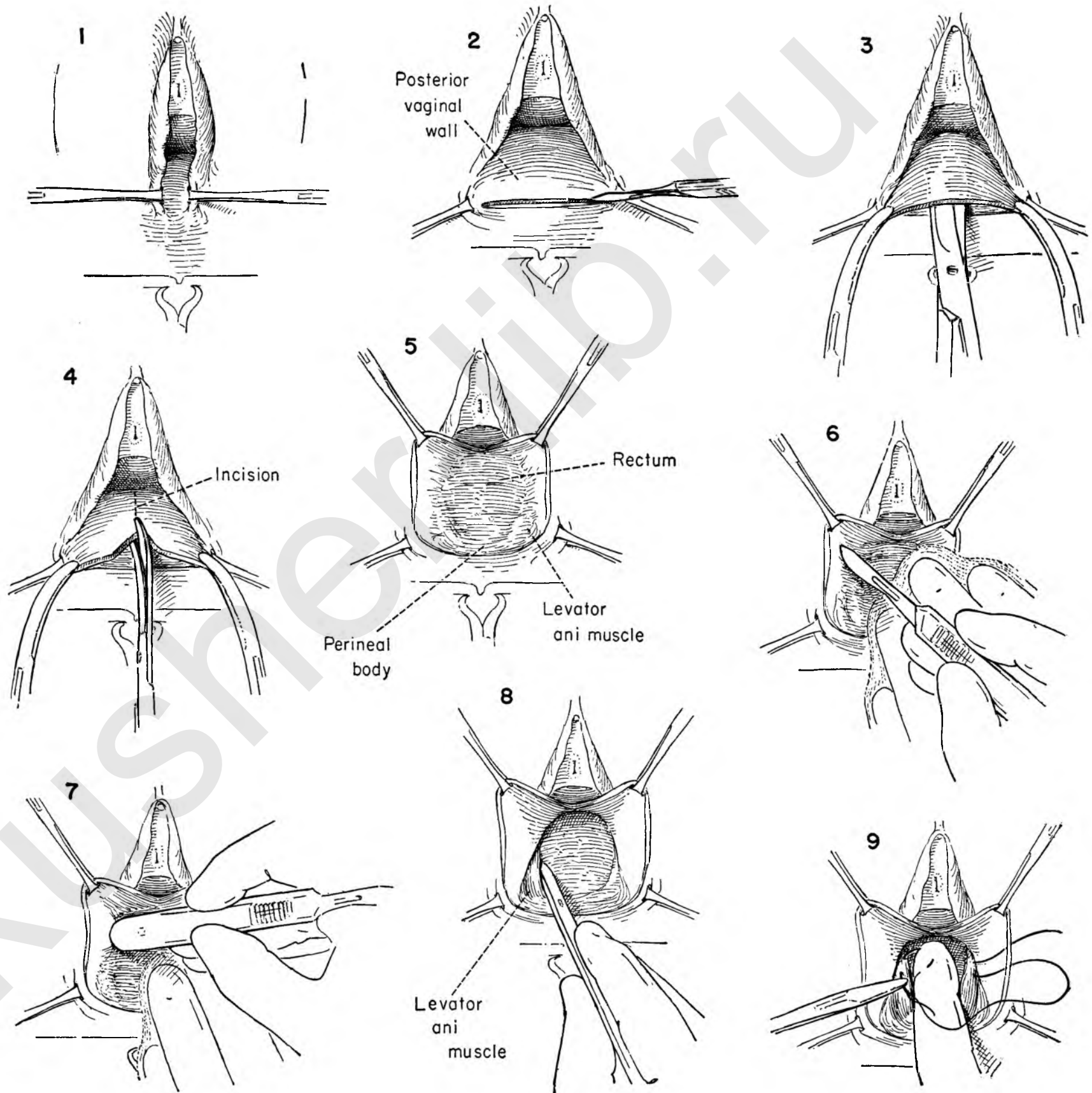


FIGURE 10. Each suture is clamped and held long on tension as the next muscle suture is laid in, clamped and held. Three or four such sutures are used.

FIGURE 11. The clamped sutures are then pulled down to expose the thin edges of the fascia above the point of divergence of the levators. An atraumatic catgut stitch on a small curved needle inserted on either side reduces the bulging rectum in the midline.

FIGURE 12. Several sutures are placed, tied and cut.

FIGURE 13. The sutures in the levators are then elevated and snugly tied from above downward.

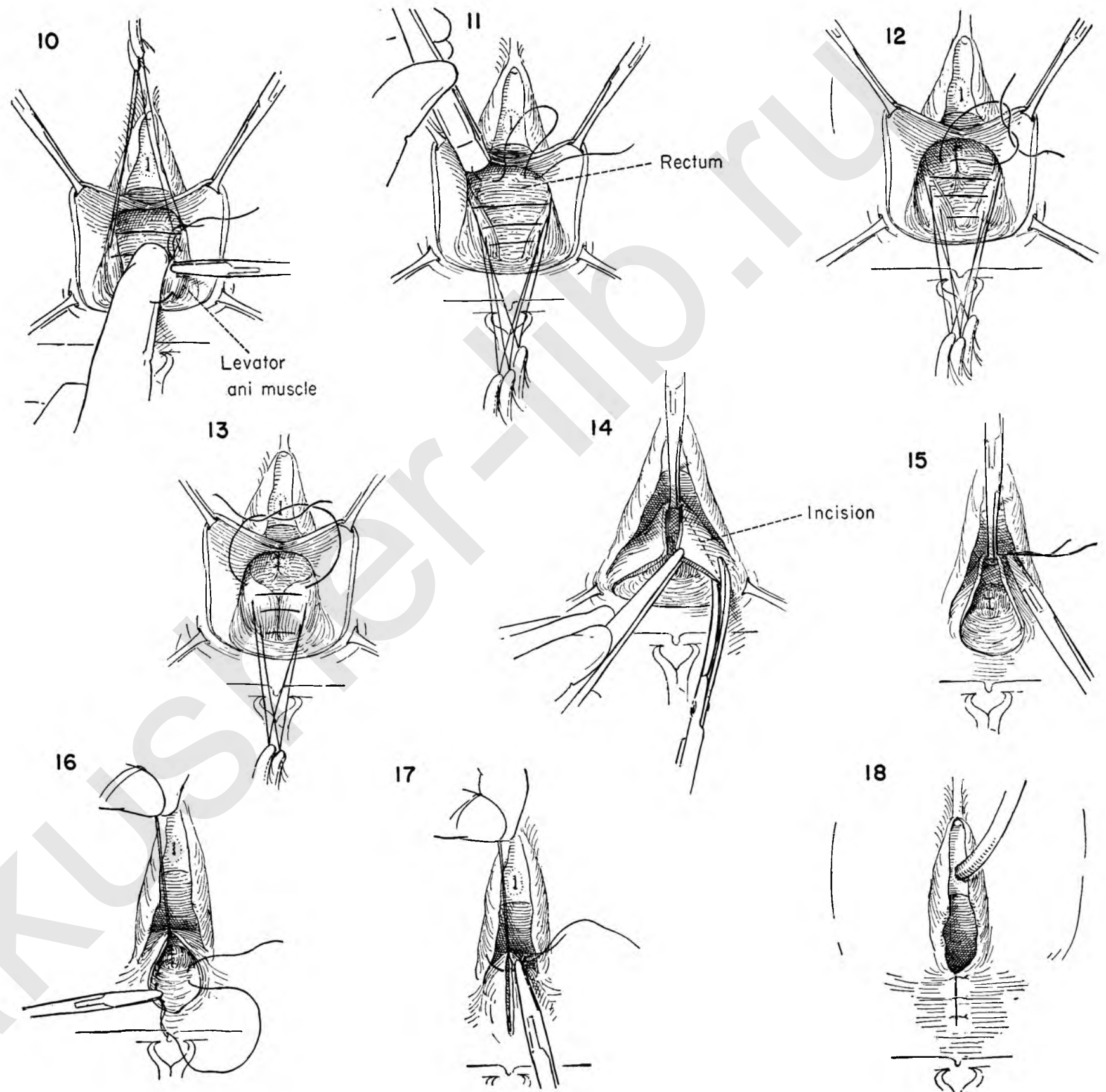
FIGURE 14. Excess vaginal wall is trimmed away on both sides.

FIGURE 15. The closure is begun at the apex with interrupted catgut sutures loosely tied.

FIGURE 16. Several additional sutures are used to reconstruct the perineal body.

FIGURE 17. When the new fourchette is reached, the closure is continued, bringing together the skin edges of the perineum.

FIGURE 18. This figure shows the completed closure. An inlying catheter is placed in the bladder.



REPAIR OF THIRD DEGREE TEAR

The ultimate in posterior lacerations sustained during childbirth is a tear which extends through the anal sphincter into the rectum. This complication is usually successfully repaired when it occurs. Occasionally, however, the injury is not recognized or the immediate repair fails and incontinence of feces results. The problem of late repair involves separate closure of the bowel wall and vagina with careful reconstruction of the perineum and anal sphincter mechanism.

FIGURE 1. This figure shows the everting mucosa of the bowel in the position formerly occupied by the perineal body. An incision is made around the exposed mucous membrane through the full thickness of skin or vaginal wall.

FIGURE 2. Allis clamps are applied, and the vaginal wall is gently separated from the rectum with scissor dissection.

FIGURE 3. With the vaginal wall on tension the dissection is carried laterally, freeing the rectum anteriorly and on both sides.

FIGURE 4. Kelly clamps are applied to the cut vaginal edges and held downward. The surgeon extends the dissection upward in the cleavage plane between rectum and vagina with the tips of the scissors held upward and against the posterior vaginal wall.

FIGURE 5. The vaginal wall is incised in the midline.

FIGURE 6. The operative field has been completely developed.

FIGURE 7. The usual plane of cleavage between the vaginal flap and the rectal wall has been developed on both sides. The rectum is held medially to provide exposure as further separation is accomplished with the knife handle. Complete mobilization of the rectum permits closure of the bowel wall without tension.

FIGURE 8. The surgeon now trims any remaining scar from the edges of the exposed rectal mucosa.

FIGURE 9. The upper edge of the torn rectum is held by an Allis clamp. A row of fine atraumatic catgut sutures in the rectal wall inverts the mucosa and closes the defect. This is continued until the mucocutaneous margin of the anal opening is reached. A normal anal opening is recreated.

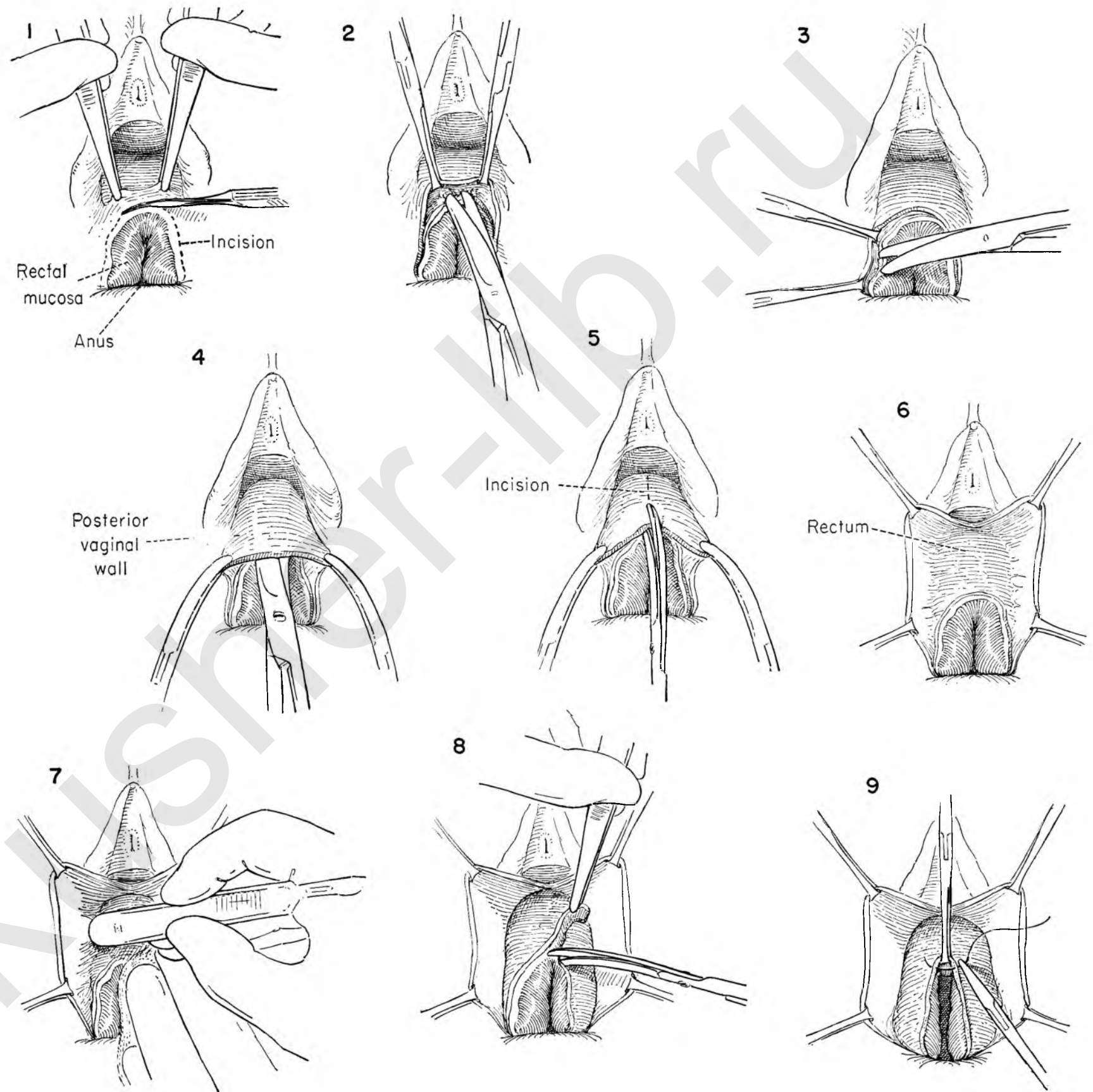


FIGURE 10. A second layer of closure is mandatory. These sutures reinforce, infold and bury the first line of sutures. Although the caliber of the anal opening appears to be reduced, it will prove to be functionally adequate.

FIGURE 11. A deliberate attempt is now made to secure and approximate the retracted ends of the sphincter ani muscles. Their location will be indicated by dimples on either side of the rectum at the point of the old perineal body. A nerve hook is introduced into the tissues at this point on either side.

FIGURE 12. With the two hooks held upward a finger in the anal opening will demonstrate to the surgeon whether the sphincter has been secured. The tissues can then be approximated in the midline with several strong catgut sutures.

FIGURE 13. Several additional sutures are used to strengthen the sphincter repair. If the hooks are crossed and held on tension, the sutures can be tied without difficulty.

FIGURE 14. The steps now proceed as in the repair of a rectocele. A series of interrupted sutures in the levator muscles is being placed in position.

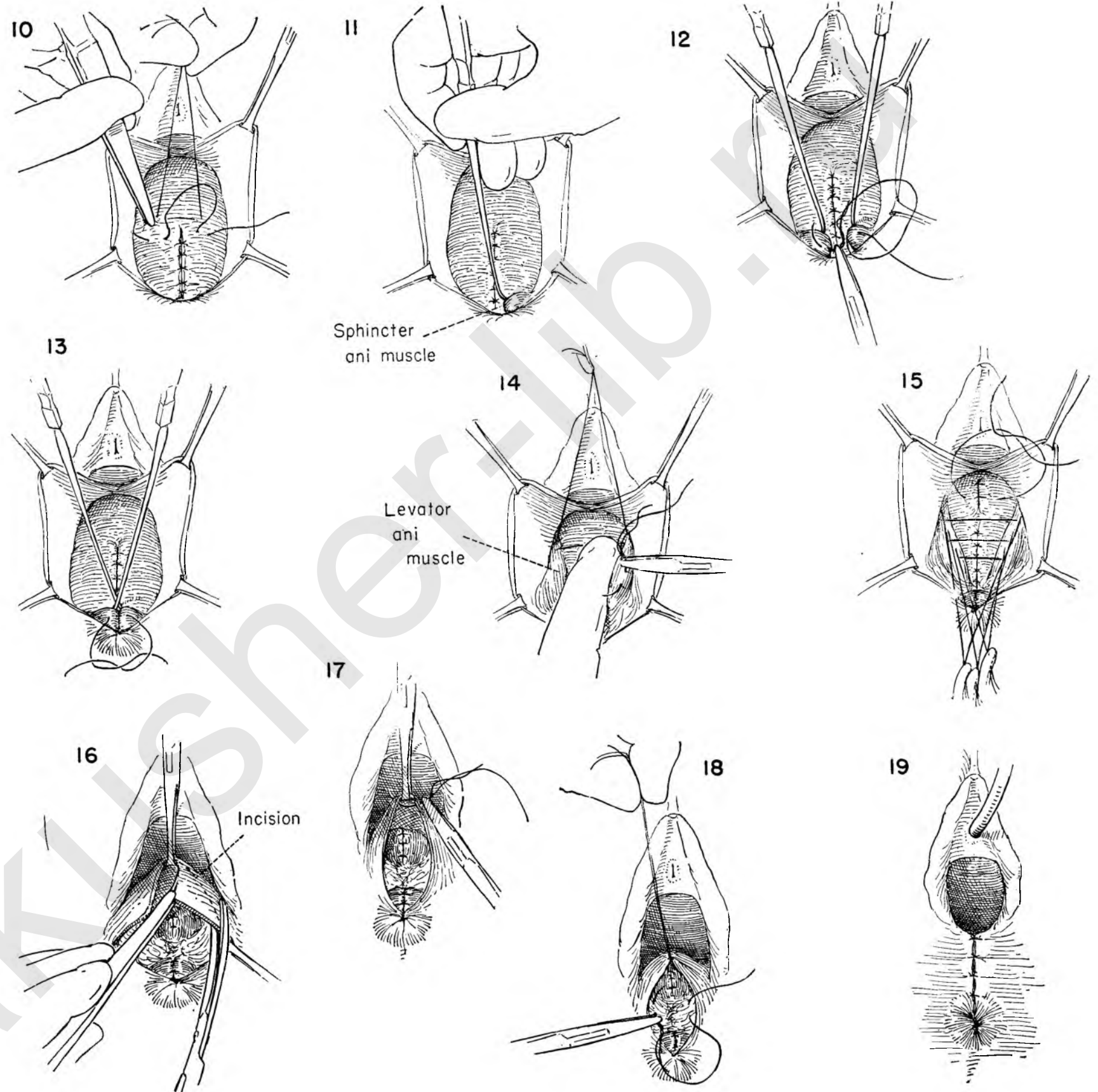
FIGURE 15. All the levator sutures have been introduced and the ends held in clamps downward. Such traction allows the surgeon to place several interrupted sutures in the fascia above the divergence of the levator muscles.

FIGURE 16. All the levator sutures are then tied and cut. Any redundancy of the lateral vaginal flaps is excised.

FIGURE 17. The raw edges of vaginal wall are brought together with interrupted catgut sutures.

FIGURE 18. Each suture is held until the next is in position and then cut. Additional interrupted stitches are used to reconstruct the perineal body.

FIGURE 19. When the vaginal wall is closed, the skin defect below is similarly treated. An inlying catheter is inserted in the bladder.



VAGINAL REPAIR OF ENTEROCELE

An enterocele is a true hernia of the posterior vaginal wall and always contains a complete peritoneal sac which seems to arise from the anterior wall of the pouch of Douglas between the utero-sacral ligaments below the cervix. It may descend to the introitus, lying anterior to the rectal bulge. One should be on the alert when the rectocele seems to include the upper portion of the vaginal wall. The sac of the enterocele must be dissected free of the rectum and the two factors dealt with independently. In most instances the repair is carried out through the vagina. Occasionally it is necessary to enter the abdomen to complete the operation.

The repair illustrated here takes place through the vagina.

FIGURE 1. A transverse incision is made in the vaginal wall as in a rectocele repair.

FIGURE 2. The edges are held down and the scissors separate the vaginal wall from the underlying rectum.

FIGURE 3. The vaginal wall is then divided in the midline.

FIGURE 4. The incision is carried higher than the usual incision for rectocele repair. With the vaginal wall on tension the tips of the scissors are held upward against the posterior vaginal wall as they are advanced.

FIGURE 5. The lateral separation of the rectum from the vaginal wall is made with the knife handle after the proper cleavage plane has been established.

FIGURE 6. The two distinct bulges consisting of the rectum and the peritoneal cover of the enterocele are apparent after dissecting off the vaginal wall.

FIGURE 7. The surgeon picks up the superior surface of the enterocele and elevates it while he gently separates the sac from the rectum lying below it.

FIGURE 8. With the sac completely separated from the rectum, the edges of the enterocele are picked up at two points while the surgeon incises it with a knife.

FIGURE 9. The peritoneal cavity is now open. A purse-string suture of atraumatic catgut has been laid in place around the inside-serous-border of the opening as the open sac is held on tension.

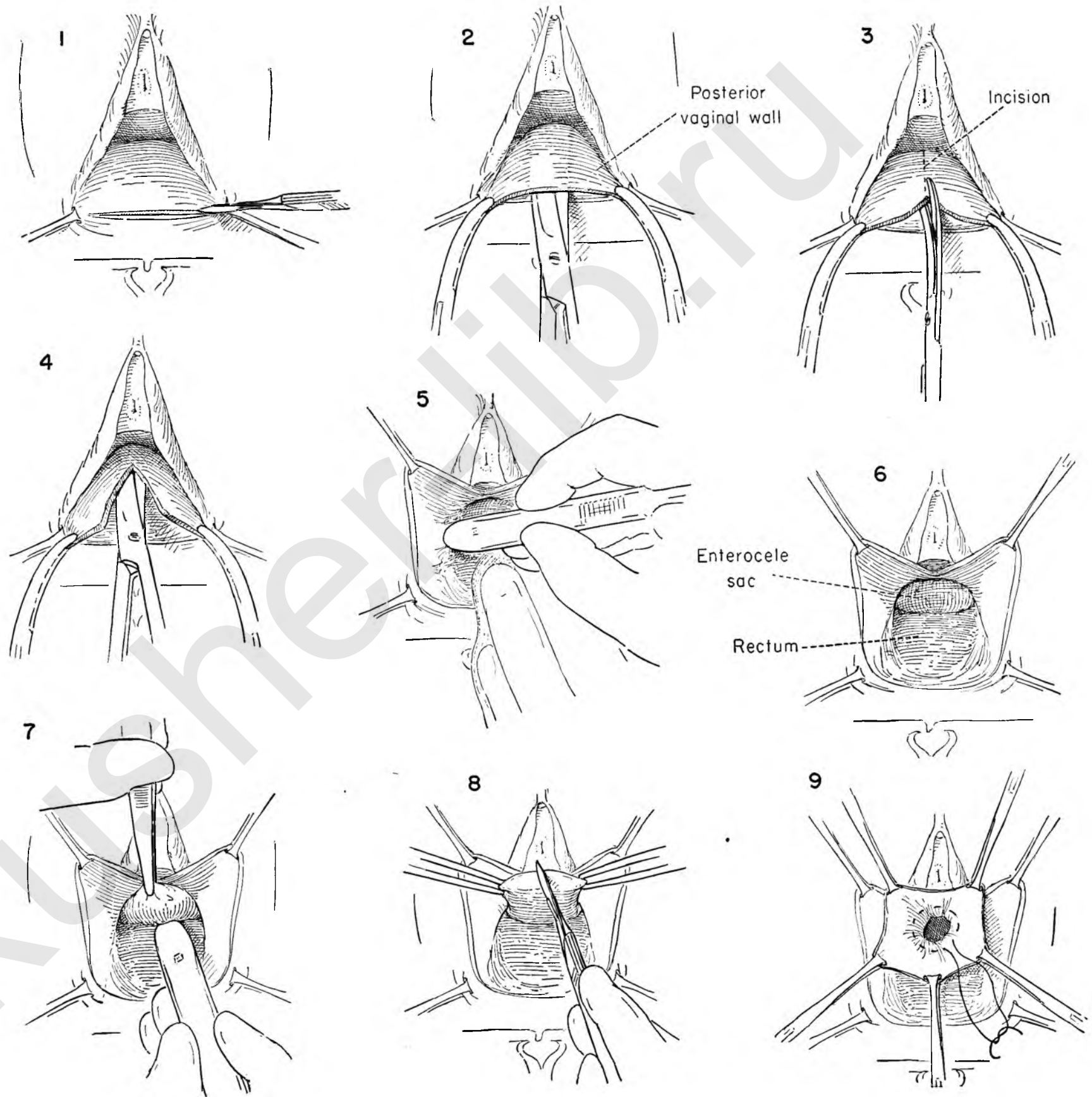


FIGURE 10. The redundant portions of the sac are then excised and discarded.

FIGURE 11. In order to repair the defect through which the hernia developed, the uterosacral ligaments must be approximated. They are best brought into view by upward traction on the cervix, which is now grasped with tenacula.

FIGURE 12. The tenacula are held up toward the symphysis, exposing the uterosacral ligaments. The first of two or three interrupted catgut sutures passes through the left uterosacral ligament, grasps the top of the enterocele sac and continues through the opposite uterosacral ligament.

FIGURE 13. These sutures are then tied and cut, bringing the uterosacral ligaments together behind the cervix.

FIGURE 14. The bulge of the anterior rectal wall alone remains. The tenacula are removed and the cervix allowed to retract.

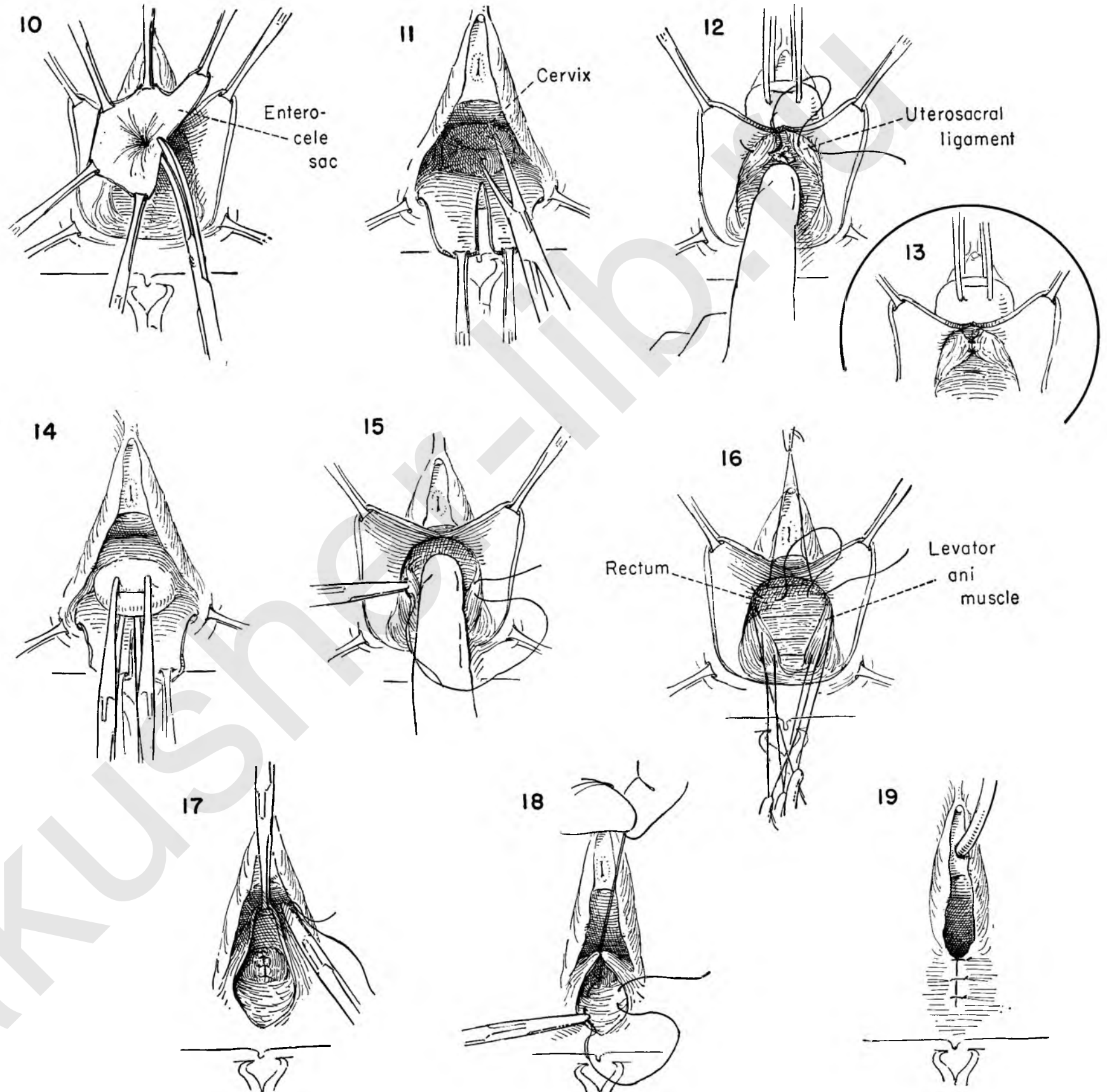
FIGURE 15. The first of the interrupted catgut sutures to bring the levators together is being placed as the rectum is pushed back with the left index finger.

FIGURE 16. Three or four such sutures are placed in the levators and their long ends held in clamps downward toward the fourchette. This will permit the surgeon to place a few interrupted catgut sutures in the fascia above the level of the levators.

FIGURE 17. Any excess vaginal wall may be excised. Closure of the vagina is begun with interrupted sutures tying and holding each one as the next suture is placed.

FIGURE 18. In addition to the support provided by the levators, it is important to reconstruct the perineal body. Interrupted catgut mattress sutures are used.

FIGURE 19. The closure is completed by a series of interrupted sutures in the skin.



HEMORRHOIDECTOMY

FIGURE 1. This shows the area of vulva and anus with the patient in the lithotomy position. All major hemorrhoids will be found in the five, seven or eleven o'clock position. Dilatation of the anal sphincter will simplify exposure. This should be done slowly with graduated dilators, but should be carried to the point where three fingers can be inserted with ease.

FIGURE 2. One usually operates first on the most posterior pile, so that blood oozing from small vessels will not obscure the field at any time. The hemorrhoid is picked up with two grasping forceps, one on the main body of the varix and the other on the corresponding skin tag. A V incision is made through the skin. Excellent exposure is offered if a right-angled retractor with a concave blade is held by an assistant just opposite the hemorrhoid.

FIGURE 3. A small vessel beneath the skin is clamped, the dissection continued further under the varix, and the vessel tied with fine catgut.

FIGURE 4. The incisions are extended up into the mucosa on either side of the hemorrhoid. These are planned deliberately to remove as little mucous membrane as possible, allowing the edges of the wound to fall together easily and heal with minimum scar.

FIGURE 5. The hemorrhoid is elevated forcibly and a Kocher clamp secured along its base, flush with the bowel wall.

FIGURE 6. The hemorrhoid is amputated.

FIGURE 7. A catgut suture is begun about 1/4 inch from the tip of the clamp.

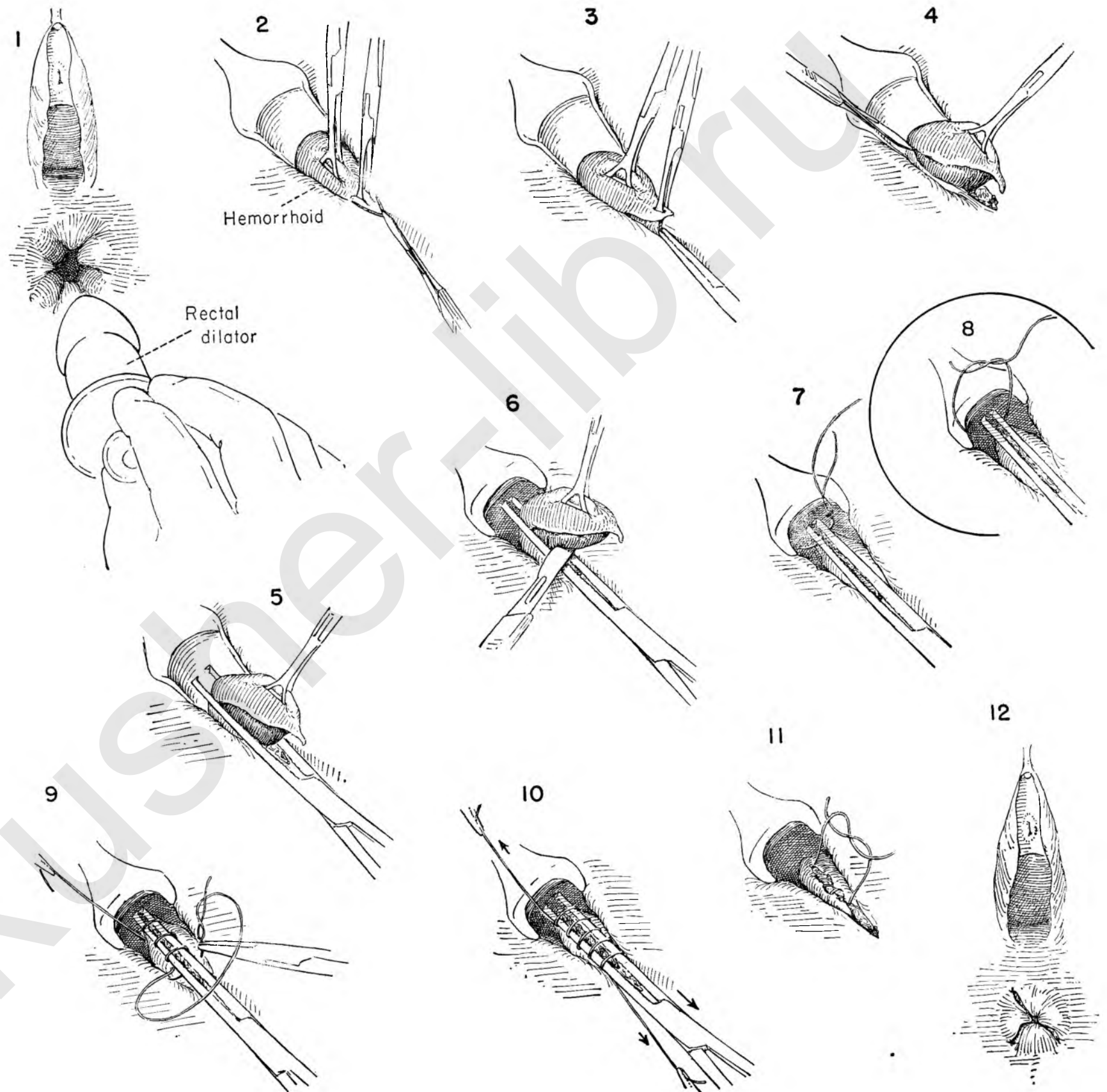
FIGURE 8. This suture is tied once, and is intended to include the major vein at its upper end.

FIGURE 9. The suture is continued over and over the clamp.

FIGURE 10. The ends of the suture are held on light tension in the axis of the clamp, which is now opened, disengaged from the tissue and withdrawn through the loops of the suture.

FIGURE 11. The two ends of catgut are tied securely. This provides excellent hemostasis.

FIGURE 12. This shows the operation completed with three hemorrhoids excised.



Combined Abdominal and Vaginal Procedures

Most gynecological conditions can be satisfactorily handled by operations performed through either the vagina or the abdomen. The occasional situation arises when the success of the procedure will be considerably enhanced by using a combined vaginal and abdominal attack. In most instances the advisability of the combined approach can be foreseen and suitable preparations made for abdominal intervention as an integral part of the operation. Rarely it will become evident to the surgeon in the course of a vaginal operation that he must modify his plan of attack and enter the abdomen. It is far better to have prepared for such a contingency than to be forced to improvise because of the unexpected encounter with a situation which cannot be successfully mastered by the original plan of operation. To this end the authors recommend for any extended vaginal procedure that the abdominal wall be prepared preoperatively.

Posterior vaginal hernia (enterocele), prolapse of the vagina or a sagging bladder neck giving rise to stress incontinence can all be repaired from either the vaginal or the abdominal side, but correction is often better managed by a combined approach.

POSTERIOR VAGINAL HERNIA OR ENTEROCELE

Repair of an enterocele may be accomplished entirely through the vagina. This technique was described in Plates 131-132. Occasionally in abdominal pelvic operation for other cause the surgeon may discover the hernial sac lying between the uterosacral ligaments or an abnormally deep cul-de-sac. He may elect to obliterate these sacs, beginning from the bottom up, as part of the abdominal procedure.

Frequently, however, it is wise to combine the vaginal dissection with abdominal intervention. Recurrence of the enterocele is not unknown. To prevent it the obliteration of the cul-de-sac or suturing the uterosacral ligaments together by an abdominal approach has much to recommend it.

As shown in this dissection the true enterocele sac has been isolated in the vaginal dissection, the interior of the sac explored, the redundancy excised and the neck of the sac sutured. In the abdominal portion of the operation the suture line of the closure is identified. The uterosacral ligaments are then approximated in the midline. These sutures include the anterior rectal wall, which has been pulled up before the sutures are applied. In this manner the defect is closed.

The cul-de-sac may be obliterated by a procedure not described in this Atlas, consisting in the application of a con-

secutive row of purse-string sutures beginning at the lowermost portion of the defect. Tying of these sutures will elevate the peritoneal floor.

PROLAPSE OF THE VAGINA AFTER TOTAL HYSTERECTOMY

This is a distressing complication following total or vaginal hysterectomy. When it occurs in the older patient to whom a patent vaginal canal is of no concern, correction of the herniation may be satisfactorily achieved by any one of the vaginal obliteration operations described. In women of any age to whom intercourse is important such procedures have little to recommend them. The surgeon may elect to try to reconstruct the pelvic support by again repairing the cystocele and rectocele and attempting to bring the supporting structures together. If an adequate operation was performed on the first occasion, this will bring little prospect of success and, when accomplished, will tend to so damage the vaginal canal that dyspareunia will be as distressing as the original complaint.

Various types of abdominal suspension have been suggested. Attempts have been made to suture the prolapsed vagina to the anterior abdominal wall as recommended by Brady. A number of fascial sling operations have been recommended. Ward has suggested ox fascia, while Shaw advocates strips of living fascia taken from the anterior rectus sheath. Since the complication is relatively infrequent and is now rarely seen, no one surgeon will have acquired any large experience with any given technique.

The operation is a combined one as suggested here, for prolapse or inversion of the vaginal apex results from weakened pelvic supporting structures and may be expected to present as a cystocele as well as an inversion. The bladder is therefore developed and cystocele repair performed. The patient is then placed in Trendelenburg position and the abdominal incision made. Two fascial strips attached at the symphysis are developed in the anterior rectus fascia to either side of the midline. The abdomen is then opened and the bladder flap developed to expose the vaginal apex. The attenuated round ligament attachments are divided and the lateral corners of the vaginal stump exposed. A half length is passed behind the peritoneum outside the abdominal cavity along the course of the round ligament. A suture is drawn back and attached to the free end of the fascial strip. This strip is drawn through the peritoneal tunnel and sutured to the wall of the vaginal apex. The procedure is repeated on both sides. The remains of the thinned-out round

ligament are then imbricated over the posterior vaginal wall and the operative field reperitonealized. The abdominal wall is then closed. This procedure accomplishes its purpose in an anatomical fashion and has much to recommend it.

THE FASCIAL SLING OPERATION FOR STRESS INCONTINENCE

It is a general feeling that the majority of cases of stress incontinence can be cured by a variety of vaginal operations designed to correct the sagging of the bladder neck and plicating the internal sphincter.

Before attempting any of the more complicated procedures designed to provide fascial sling support or to build up the prolapsed bladder neck by muscle transplant, the surgeon must assure himself that there is a normal bladder. To this end cystoscopic and cystometric studies are indicated as well as serology to rule out syphilis. Roentgenograms of the pelvis should be taken to exclude spina bifida occulta as well as tumor or other traumatic lesions in the spinal cord.

The authors have chosen, when indication presents, to use a combined vaginal and abdominal approach when fascia is to be used to provide a sling support to the urethra and bladder. The bladder neck is exposed through the vagina, as in Plates 103-104. The sulcus between the urethra and rami of the pubis has been developed and the urethra mobilized from its lateral attachments. Into these openings the ends of a rubber drain are placed and the vaginal wall closed after repairing any cystocele that may be present.

The abdominal wall is then incised, and a single long strip of anterior rectus fascia attached at the symphysis is freed up. The prevesical space is exposed, and the end of the rubber drain placed at the vaginal operation is recovered and sutured to the free fascial edge. Traction is placed on the opposite end of the drain and the fascia drawn up into the prevesical space on the opposite side of the urethra. The fascia is then led out through the lower end of the left rectus muscle and sutured to the anterior fascia. The trick in the operation is a bloodless field and the application of the proper amount of tension to the fascial strip so that the sling supports the urethra without cutting into it. This can be determined only by a sense of touch. Because the operation performed in this manner can be accomplished with most of the structures under direct vision, we recommend the combined vaginal and abdominal approach rather than that from the abdominal side alone.

COMBINED VAGINAL AND ABDOMINAL REPAIR OF AN ENTEROCELE

When the surgeon feels that the repair of an enterocele by the vaginal approach leaves some question as to the permanency of the pelvic floor reconstruction, it may become necessary to add abdominal intervention with obliteration of the posterior cul-de-sac to the repair already accomplished from below. The details of the vaginal portion of the operation have been described in Plates 131 and 132. A brief recapitulation is presented here in Figures 1 to 5.

FIGURE 1. The posterior vaginal wall is placed on stretch by Allis forceps at the lateral angles while the surgeon incises the bridge between them.

FIGURE 2. With the vaginal wall flaps developed as in a rectocele the enterocele sac is separated from the bulging, underlying rectum.

FIGURE 3. The sac is then entered and the peritoneal cavity exposed. A purse-string suture closes the neck of the sac and the redundancy is excised. The surgeon now decides to strengthen the repair from above. The uterosacral ligaments will not be sutured from the vaginal side, but attacked through the abdomen.

FIGURE 4. Interrupted sutures are placed in the levator ani muscles and retracted downward while additional interrupted sutures close the fascia in the midline above the levator repair.

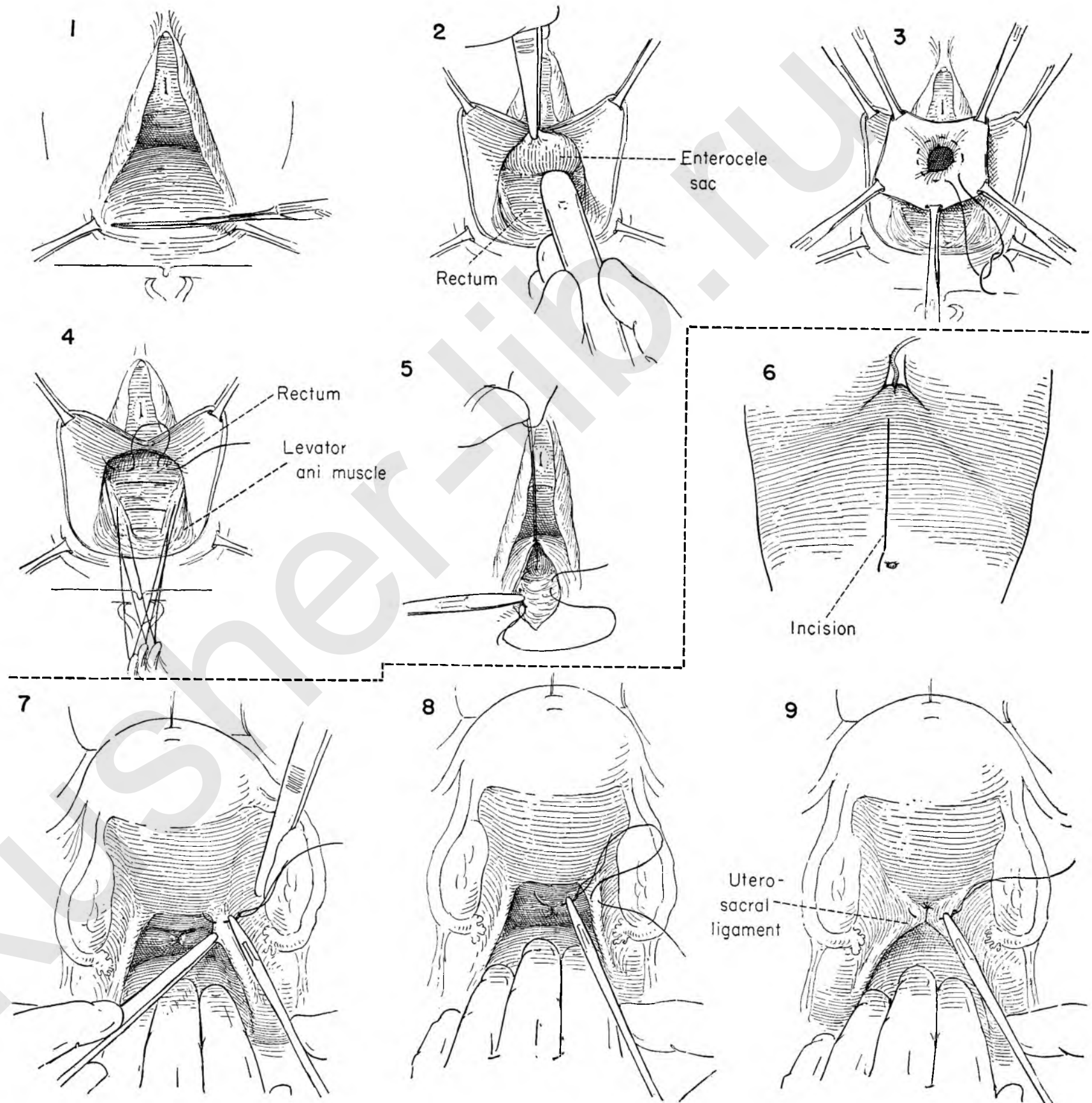
FIGURE 5. All sutures are tied and cut and the edges of the vaginal wall brought together and the perineal body sutured. The skin edges are closed.

FIGURE 6. The abdomen is then opened through a left paramedian incision.

FIGURE 7. The uterus is held upward, exposing the purse-string suture of the vaginal repair lying between the uterosacral ligaments. The ligaments will be brought together in the midline to reinforce the repair. An interrupted silk suture is placed in the right uterosacral ligament just below the cervix.

FIGURE 8. The same suture picks up the region of the neck of the sac and then continues on through the left uterosacral ligament in the same corresponding position on the left side.

FIGURE 9. Several such sutures are placed, tied and cut. The abdomen is then closed in the usual manner.



PROLAPSE OF THE VAGINA FOLLOWING TOTAL HYSTERECTOMY

Occasionally after total hysterectomy the apex of the vagina may prolapse. In extreme cases the entire tube may evert. Repair by obliteration of the vagina is not an acceptable solution. The combined vaginal and abdominal attack restores the canal and provides permanent fixation of the apical portion. It permits in addition a careful reconstruction of the supports under the bladder.

FIGURE 1. The vaginal stump is retracted downward with Allis forceps. The anterior vaginal wall has been separated from the bladder as in the first steps of the advancement of the bladder. The lower edges of the posterior vaginal wall are held downward as the wall is incised in the midline.

FIGURE 2. The fibrous strands holding the vessels to the vaginal wall are carefully divided and then further reflected off the wall with the knife handle on both sides. To facilitate these moves the vaginal wall is held on tension and the bladder pulled toward the midline.

FIGURE 3. The bladder is then gently pushed upward off the anterior peritoneum with the thumb.

FIGURE 4. Interrupted sutures are then placed in the bladder wall to either side of the midline as in cystocele repair.

FIGURE 5. The sutures are tied and cut, infolding the bladder and advancing it upward.

FIGURE 6. Interrupted sutures approximate the raw edges of the anterior vaginal wall incision in the midline.

FIGURE 7. The vaginal stump is replaced in the canal and the posterior wall exposed. Allis forceps on the lateral edges provide exposure as a transverse incision is made on the vaginal wall above the fourchette.

FIGURE 8. An Allis forceps in the midline holds up the posterior vaginal wall as interrupted sutures are laid in the levator muscles.

FIGURE 9. An Allis forceps holds the vaginal wall upwards as the surgeon places the first of the interrupted sutures which will approximate the edges in the midline.

FIGURE 10. The vaginal portion of the operation has been completed as the cystocele and perineum are repaired.

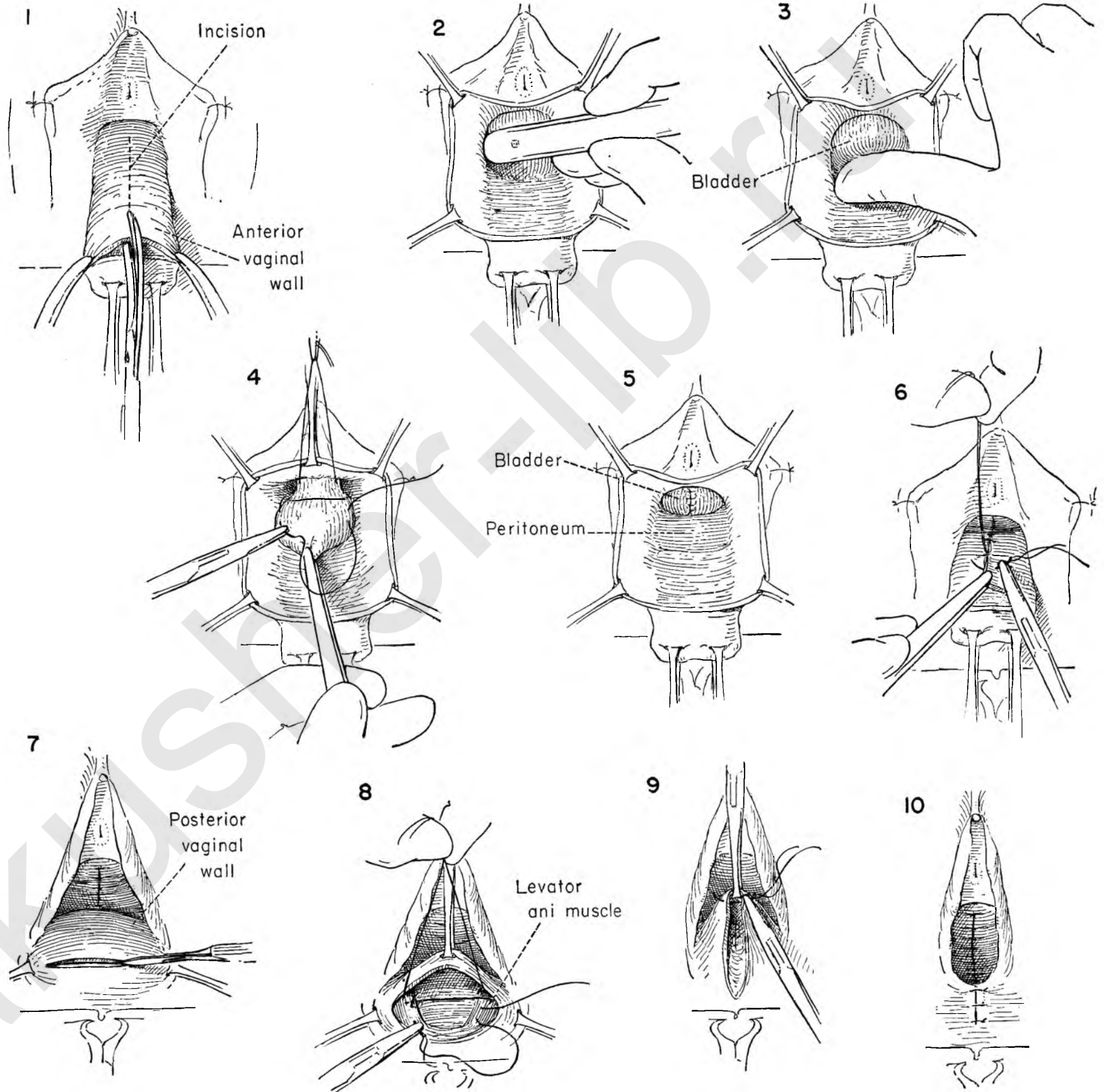


FIGURE 11. The abdomen is now opened through a paramedian incision.

FIGURE 12. The skin and fat of the abdominal wall are dissected laterally to expose a wide segment of the anterior rectus fascia on either side of the midline. The fascia is then incised in the midline from just below the umbilicus to the symphysis in the following manner: Two $\frac{1}{2}$ inch transverse incisions are made to either side at the upper end. Parallel incisions are dropped from the outer end of either transverse incision to the symphysis, developing two fascial strips still securely attached at the lower end. The surgeon separates the strip from the rectus muscle beneath as the assistant holds it on tension with clamps. Both flaps are cleaned to their point of attachment at the symphysis. There they hang free. The rectus muscles are separated and the peritoneum identified.

FIGURE 13. The assistant and the surgeon pick up the peritoneum and open it.

FIGURE 14. Retractors in the wound expose the depths of the pelvis. The intestine is packed back. The peritoneum just posterior to the bladder is incised and a bladder flap developed. The apex of the vaginal stump is identified. A stitch is placed in it and tied. The long ends are held in a clamp.

FIGURE 15. The surgeon then grasps the lower edge of the peritoneum on the left side. It is pulled toward the midline as he bluntly separates the peritoneum from the rectus muscle, gradually forming a retroperitoneal tunnel along the path of the round ligament.

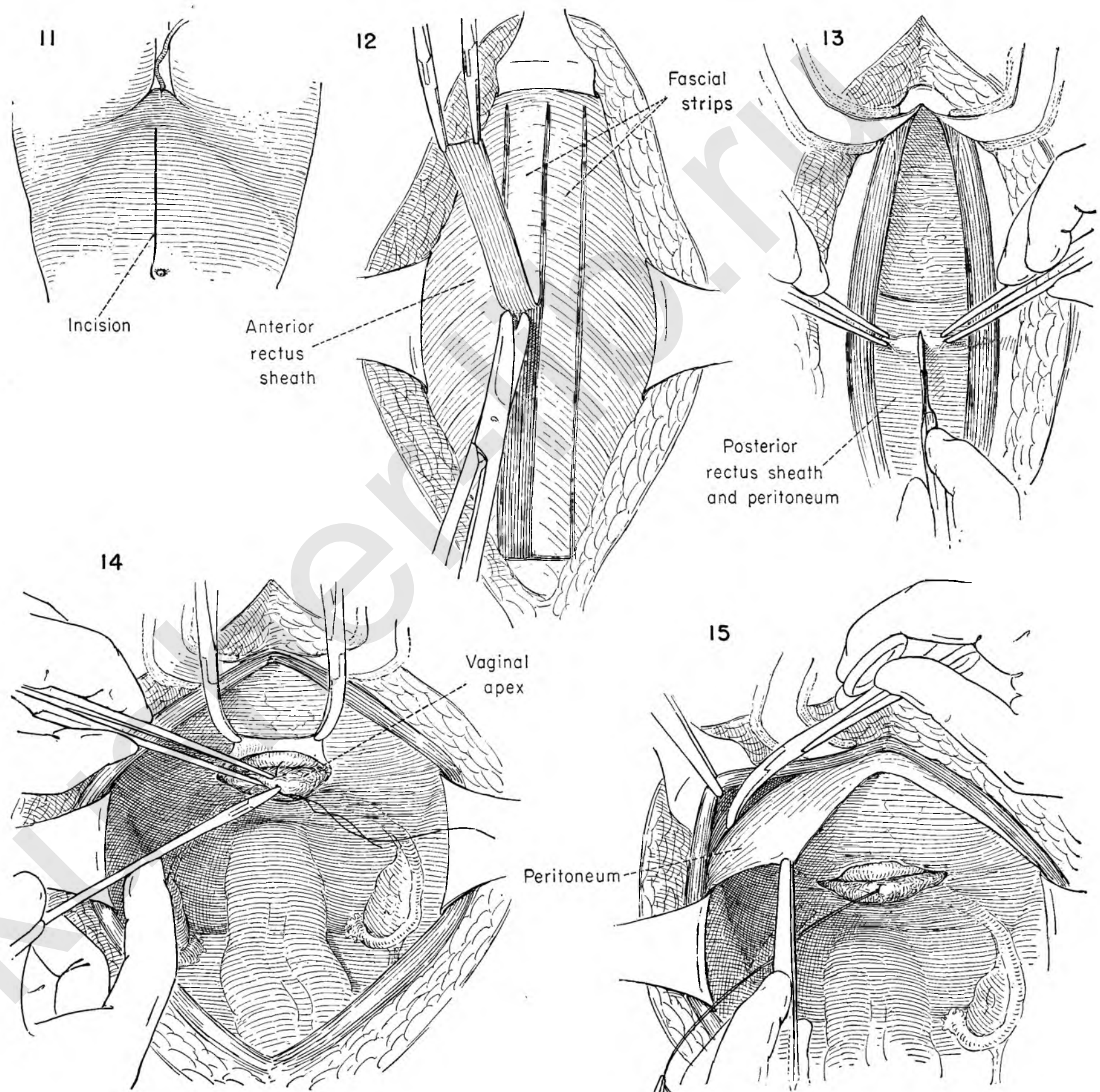


FIGURE 16. The Kelly clamp then grasps one strand of the stay suture previously placed on the vaginal apex. This is drawn through the tunnel to emerge on the abdominal wall.

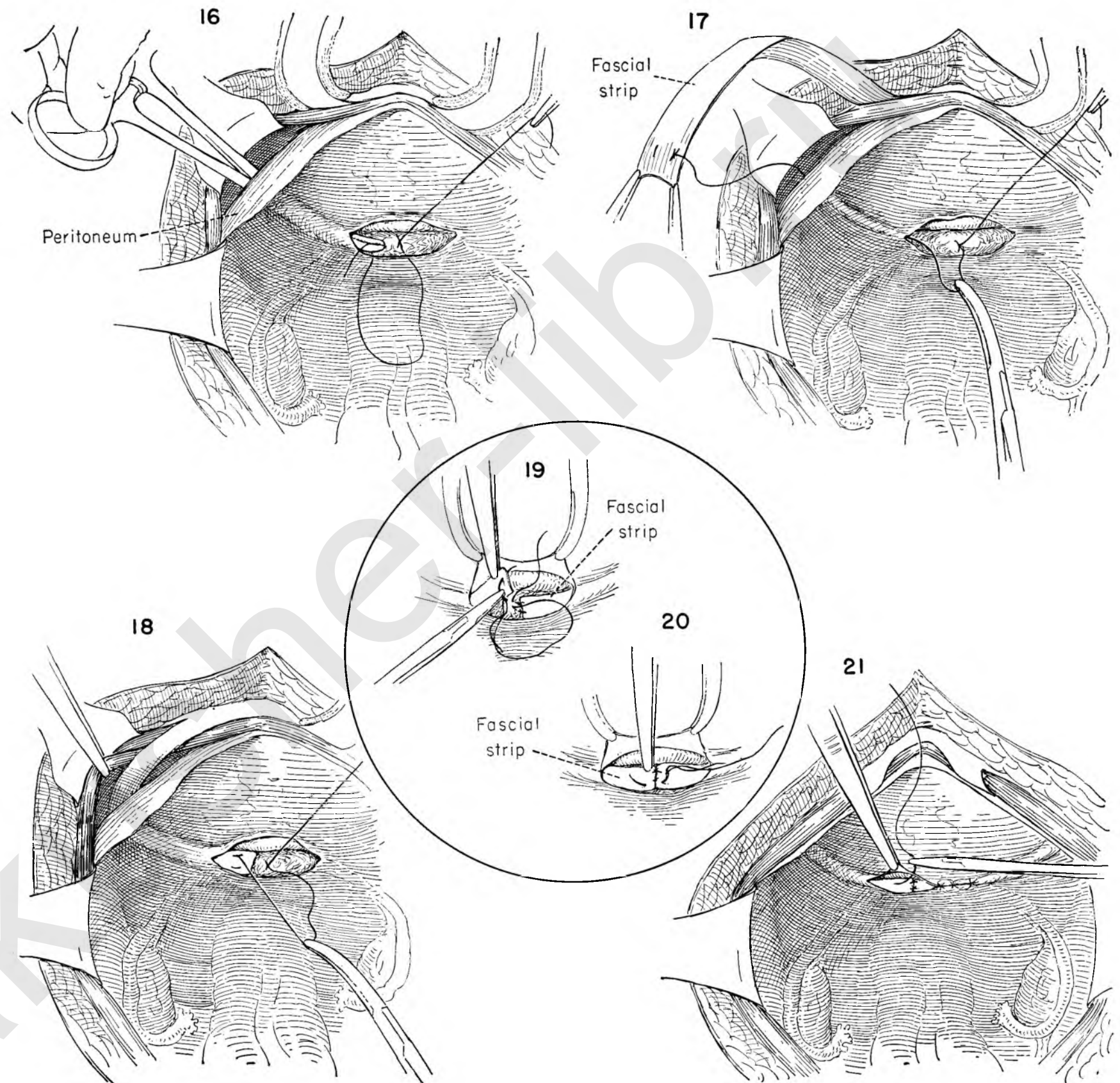
FIGURE 17. A curved needle is then threaded on the single catgut strand and led through the free end of the fascial strip as a mattress suture on the left side and tied and the needle removed.

FIGURE 18. The surgeon then gently pulls on the suture, and in this manner the fascial strip is drawn through the tunnel, its free end appearing within the abdomen while the other end remains attached at the symphysis. The same maneuver is repeated on the right side.

FIGURE 19. Each fascial strip is then sutured to the vaginal apex with interrupted silk sutures while the bladder flap is elevated.

FIGURE 20. Additional stitches secure the fascial strips to each other.

FIGURE 21. The opening in the peritoneum is closed with the bladder under direct vision. The wound is repaired in layers in the usual fashion.



THE SLING OPERATION FOR STRESS INCONTINENCE

After repeated surgical failure to cure urinary stress incontinence the surgeon may elect to try to suspend the bladder neck by passing a strip of fascia beneath it. Rarely is it indicated as the primary procedure.

Though the operation may be performed entirely from the abdominal side, it is much safer when the attack is made from above and below. There is far less chance of damage to the urethra when the combined operation is chosen.

FIGURE 1. The bladder has been advanced off the cervix and the sulcus between lateral vaginal wall, urethra and bladder thoroughly developed. This sulcus may be extended upward beneath the symphysis without bleeding when the steps outlined in Plate 104 are followed closely.

FIGURE 2. One end of a strip of rubber (empty Miller wick) is then placed in the left sulcus lateral to the urethral wall and advanced upward with smooth forceps as the bladder is held down.

FIGURE 3. The same maneuver is repeated on the right with the other end of the same strip of rubber. This illustration shows the sling of rubber beneath the neck of the bladder. Both ends have disappeared behind the symphysis alongside the urethra.

FIGURE 4. An inlying catheter is placed in the bladder and the vaginal wall closed. Note that no attempt is made to repair the neck of the bladder or urethrocele from below.

FIGURE 5. The patient is then placed in Trendelenburg position and a midline incision made.

FIGURE 6. The skin and fat are dissected back, widely exposing the anterior rectus sheath. This is incised in such a way that a strip of fascia is outlined, beginning at the umbilicus and attached to the pubis. The free end is grasped with clamps and the strip freed from the underlying muscle.

FIGURE 7. The rectus muscles are now developed through the length of the incision and the peritoneum freed from the under surface until the prevesical space is entered.

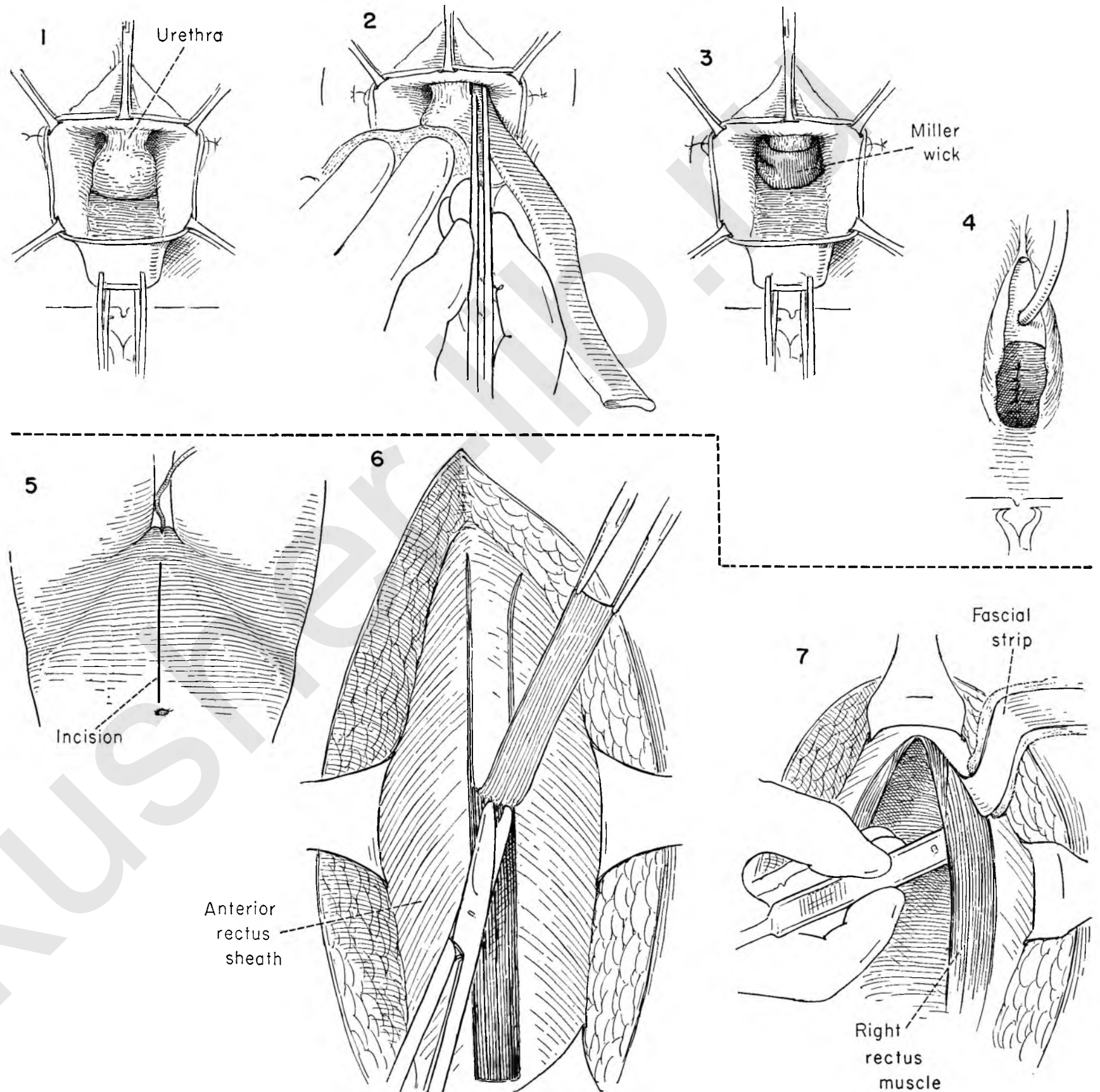


FIGURE 8. Retractors are placed to either side of the wound and in the midline over the symphysis. Laying the flat of the hand on the anterior bladder wall, the surgeon pulls the bladder away from the under surface of the symphysis with a raking motion of the fingers.

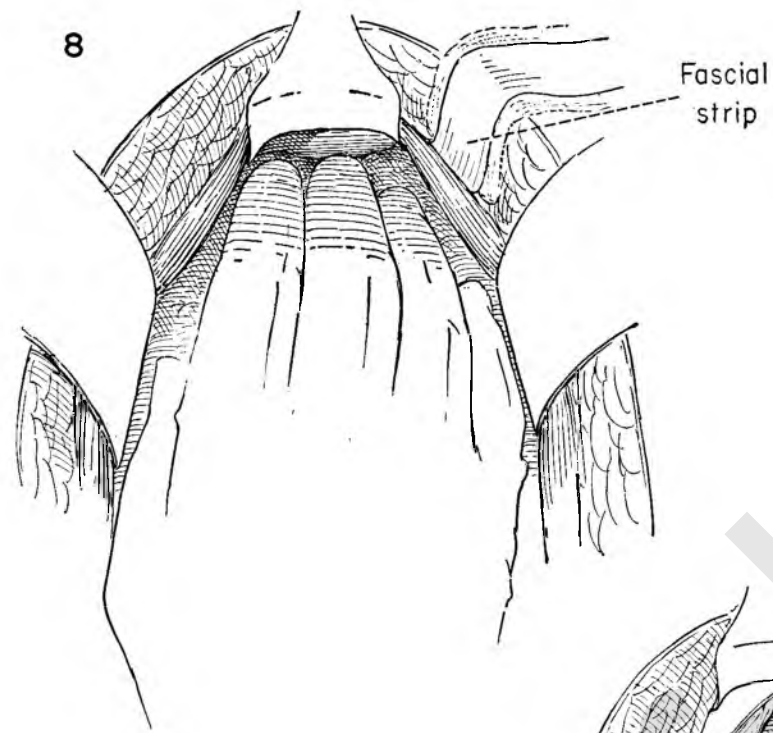


FIGURE 9. The bladder is pulled to the left to expose the right side of the urethra. The free end of the rubber strip presents, and the surgeon grabs it with a clamp and pulls it gently upward. This should not be done too forcefully, for the other end is not attached to anything. The same move is made on the left side and both ends of the rubber strip are pulled upward, thus forming a sling beneath the urethra.

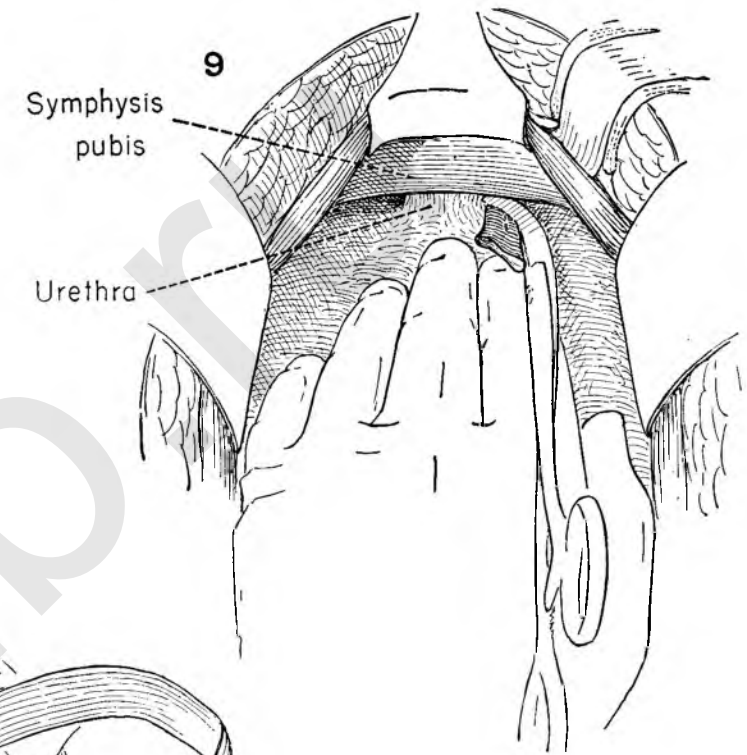


FIGURE 10. The free end of the fascial strip is led through the body of the right rectus muscle about 1 inch from the medial border.

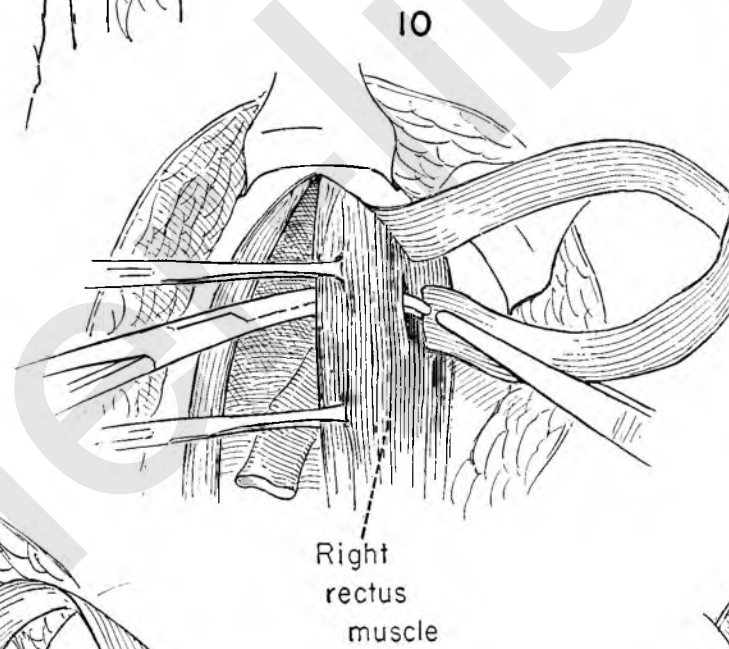


FIGURE 11. The free end of the fascial strip is then sutured to the right arm of the rubber stirrup.

FIGURE 12. The surgeon holds the bladder out of the way as he gently leads the fascial strip through the tunnel underneath the bladder neck by pulling on the left free end of the rubber guide. If it does not slide freely, the fascia should be withdrawn slightly and gentle traction again applied until it appears.

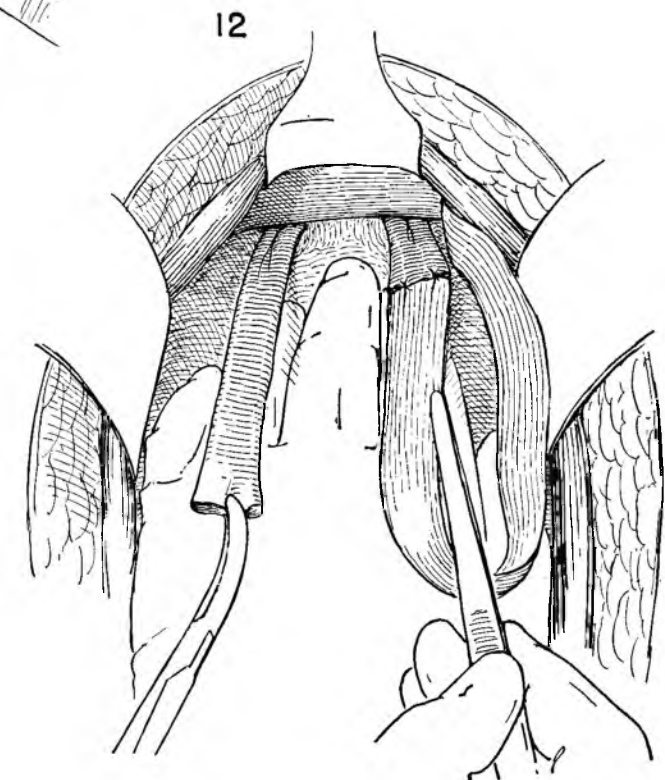
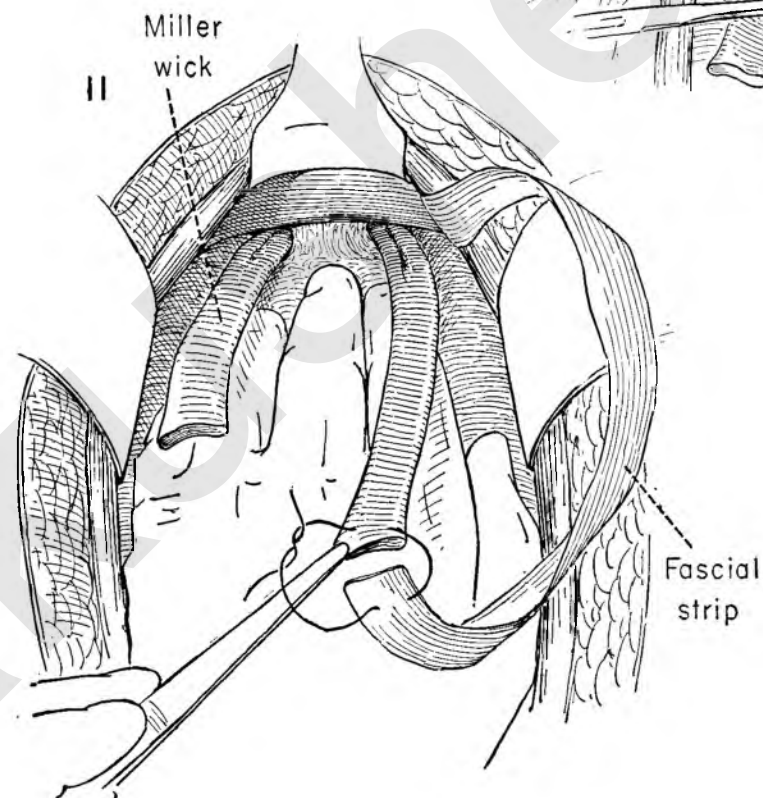


FIGURE 13. The surgeon holds the bladder back and brings the free end of the fascial strip through on the left side. The rubber strip is then detached.

FIGURE 14. The abdominal wall is retracted to the left while the assistant retracts the edge of the left rectus muscle toward the midline. With Allis forceps holding the muscle and Kelly clamps on the fascia, the surgeon then tunnels through the lower end of the rectus muscle 1 inch from the medial border and close to the symphysis.

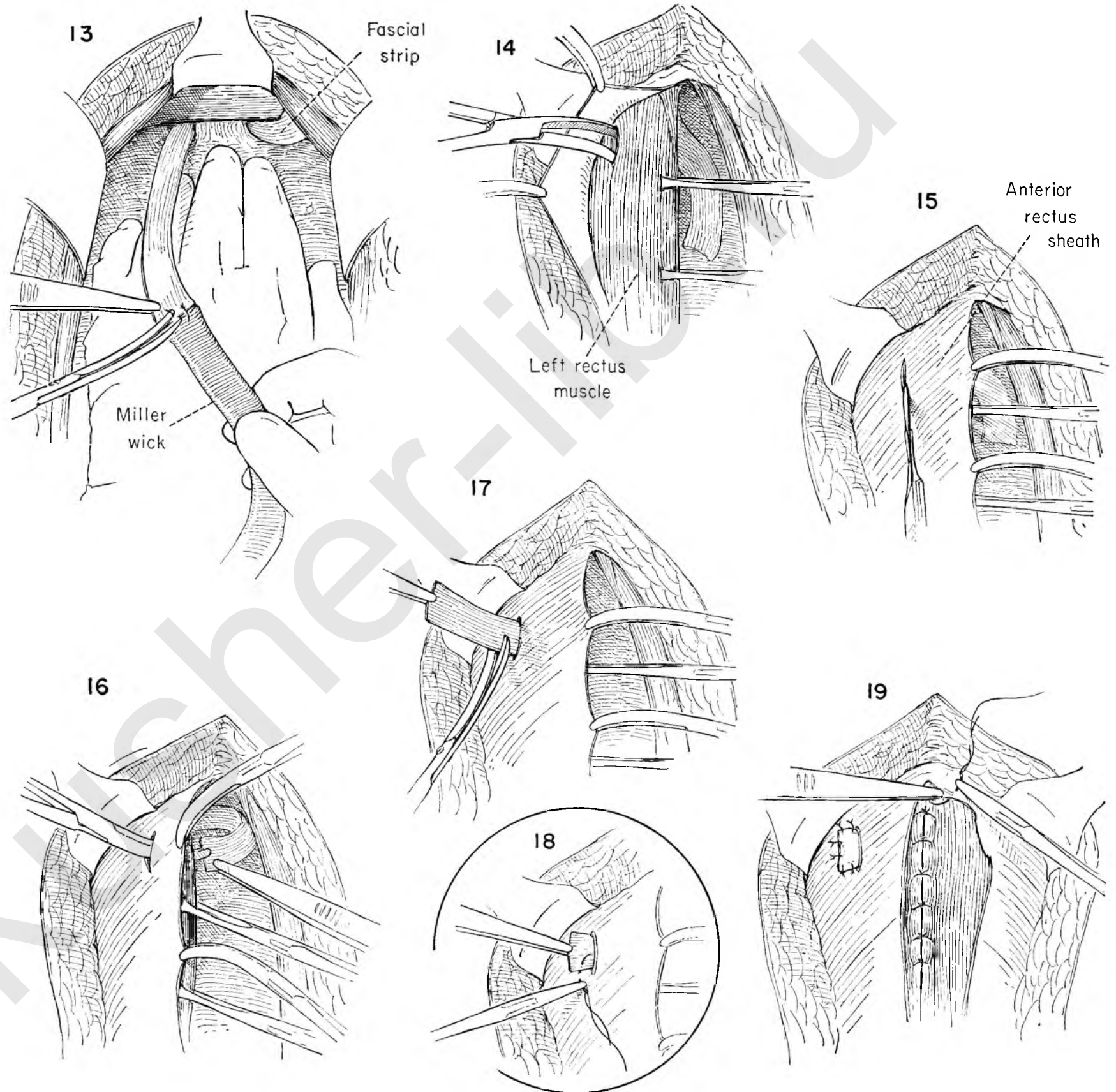
FIGURE 15. The anterior rectus sheath is then held medially and incised just over the opening in the muscle tunnel as the skin is held back with a retractor.

FIGURE 16. With the abdominal wall retracted, the surgeon introduces the tips of a Kelly clamp through the opening in the fascia and muscle and grasps the free end of the fascial strip.

FIGURE 17. As the muscle and fascia are held taut the fascial strip is led through them out onto the superior surface of the left rectus fascia. The amount of tension on the strip is of utmost importance. It should be snug enough to support the neck of the urethra without necrosing it through too much pressure. This is a matter of the surgeon's judgment. The excess is then cut off.

FIGURE 18. The end is sutured to the anterior rectus fascia.

FIGURE 19. To close the defect left in the anterior rectus sheath when the flap was fashioned it will be necessary to mobilize the lateral margin. The wound is closed in layers, first approximating the muscle borders in the midline.



Operations for Repair of Fistulae

Vesicovaginal fistulae with extensive loss of tissue used to be not uncommon after childbirth. Today large fistulae are usually seen only after radiation for carcinoma of the cervix. The majority of fistulae at present occur as the result of trauma during surgery. The fistula is small, but occurs in the vaginal apex on the anterior wall just above the transverse scar left by the previous total hysterectomy. Repair is complicated by the inaccessibility of the fistula. When the fistula follows radical extirpation of the uterus for malignant disease, the location is less constant than for those occurring after simple total hysterectomy, and the differentiation between vesicovaginal and ureterovaginal fistula is not as clear cut.

There are certain principles to be followed which form the basic steps for a successful repair. As a general rule the repair of the fistula should be delayed until adequate blood supply has returned to the tissues in the area of the repair. Too hasty attempts at reconstruction may result in failure because of poor tissue response. Moreover, some small fistulae will close spontaneously during the waiting period.

The problems confronting the surgeon are (1) *Proper exposure*. This is of the utmost importance. An adequate operative field must be created which will permit the surgeon to work easily as he identifies all the structures under direct vision. The field must be strongly illuminated. (2) *Adequate mobilization of bladder wall and fistulous opening*. Unless enough tissue is mobilized so that two rows of reparative sutures can be placed without tension, the reconstruction will tend to break down. The type of suture material is of far less importance than securing enough tissue to ensure easy apposition. Number 00 chromic catgut will prove as effective as silver or fine steel wire. (3) *Postoperative drainage*. To avoid overdilatation of the bladder in the healing phase, a self-retaining catheter of the Foley type should be left in place for ten days to two weeks. This is preferable to repeated catheterizations. If the repair has been extensive, it may be good judgment to do a suprapubic cystotomy. As a further safeguard in such cases the surgeon may elect to have the patient remain in the prone position on a Bradford frame.

Many methods of repair of vesicovaginal fistulae are available. The choice for or against any given approach will depend on the amount of tissue loss and the location of the fistula. The basic principles must be followed whatever the mode of attack.

VAGINAL REPAIR OF VESICOVAGINAL FISTULA

This method of repairing the small inaccessible fistulae that appear high up in the vaginal vault after total hysterectomy has

been described by Latzko. Ready access to the fistulous tract may be acquired by a lateral episiotomy or Schuchardt incision with the patient in the lithotomy position. The Schuchardt incision carries deep into the lateral wall of the vagina, beginning at the level of the fistula and extending down through the vaginal musculature to the levator ani muscles. It then curves outward and downward to pass lateral to the anal opening. The bleeding vessels are ligated as encountered, and the general ooze is controlled with a warm gauze pack. Retractors placed over the pack create adequate exposure for direct attack on the fistula.

The surgeon may elect to have the patient lie prone rather than make the Schuchardt incision with the patient in the lithotomy position. The table is tilted with the head lower than the buttocks. The hips are elevated by a firm pillow. This permits a slight bend to the knees as the legs are abducted widely on padded boards placed under the operative mattress. The surgeon takes a position between the thighs. The advantage of this approach is that upward traction on the posterior vaginal wall brings the fistula into a position where it can readily be seen and approached.

Rarely the fistula cannot be brought down and properly dealt with. In such circumstances the surgeon may insert a small Foley catheter through the fistula into the bladder, inflate the balloon and by traction bring the area into a working position. The repair of the fistula follows the basic steps previously outlined.

TRANSVESICAL REPAIR

After radical surgery for malignant disease the fistula may occupy a position at the trigone in close proximity to one or the other ureteral openings. Successful repair from below is less likely to succeed and carries with it too great a danger of ureteral occlusion. Such a fistula had best be approached by abdominal incision and direct exposure of the fistulous opening through the bladder interior. A sponge placed in the vagina helps to elevate the floor of the bladder, aids in the exposure and permits a more solid surface on which to carry out excision and repair.

Alternatively, traction on stay sutures placed at spaced intervals will elevate the bladder base to permit dissection of the fistulous tract and separation from the underlying vaginal wall. The fistula may be near one of the ureteral openings. Mobilization of sufficient bladder wall to permit closure without tension is apt to encroach on the path of the ureter in the wall of the

bladder. A ureteral catheter may be inserted in the orifice and be passed upward to outline the course of the ureter. The basic principles of repair are followed. The opening into the vagina is closed separately, and two layers of interrupted sutures are placed in the bladder wall. Bladder drainage is accomplished by suprapubic drainage.

REPAIR OF VESICOVAGINAL FISTULA THROUGH THE ABDOMINAL CAVITY

If the fistula is situated at a point distant from the trigone, it may not be readily dealt with from the vaginal side. Because it is remote from the ureteral openings it may be feasible to attempt repair by dissecting the bladder from the vagina without entering the bladder cavity. Since the bladder wall is closely fused to the vaginal wall, the cleavage plane must be developed. Packing the vagina with gauze will provide a firm surface for dissection. With the bladder dissected away from the vagina the fistulous tract is isolated and divided. The vaginal opening is closed independent of that in the bladder. The basic principles of exposure, mobilization and repair apply.

Repair of Rectovaginal Fistula

Basically the same principles apply in the repair of rectovaginal fistula as in the obliteration of the urinary fistula. The rectovaginal fistula, however, is far more accessible. The continual passage of fecal matter over the reconstructed fistulous opening presents more of a problem in successful union than is true of the vesical fistula. The distention element, however, is lacking.

Many of the rectovaginal fistulae are small and can readily be repaired by simple purse-string suture after suitable mobilization.

When there is extensive loss of tissue near the sphincter, it is impossible to mobilize enough rectal wall to use purse-string suture. In this instance it is better to convert the fistula into a third degree tear. The rectal wall must be mobilized widely to permit the apposition of the mucosa without tension. This layer must be placed with care and be reinforced with a second layer. The levator ani muscles are then brought together in the midline over the reinforced suture line in the rectal wall. Since the sphincter ani muscle has been deliberately incised, the divided ends must be recovered and brought together in the midline. The vaginal wall is closed independently.

THE SCHUCHARDT INCISION

Inadequate exposure can hamstring the most skillful operator. It is frequently a problem during fistula repair. Often a simple change in the position of the patient or of the retractors will suffice, but if this is not enough, the outlet of the vagina should be enlarged by incision into the perineum. If still more room is needed, this can be achieved by cutting the levator muscle as described by Schuchardt.

FIGURE 1. An attempt is made to expose the fistula at the vaginal apex with the retractor.

FIGURE 2. The surgeon elects to make a relaxing perineal incision. The left posterior quadrant of the vagina is put on the stretch with narrow bladed retractors, and the incision is carried from a point about an inch within the vagina down and across the perineum in a slight curve.

FIGURE 3. The wall of the vagina and the subcutaneous fat have been cut and retracted to expose the levator ani muscle. This in turn is cut across in the same plane and as deeply as exposure requires. Bleeding points are secured with fine ties.

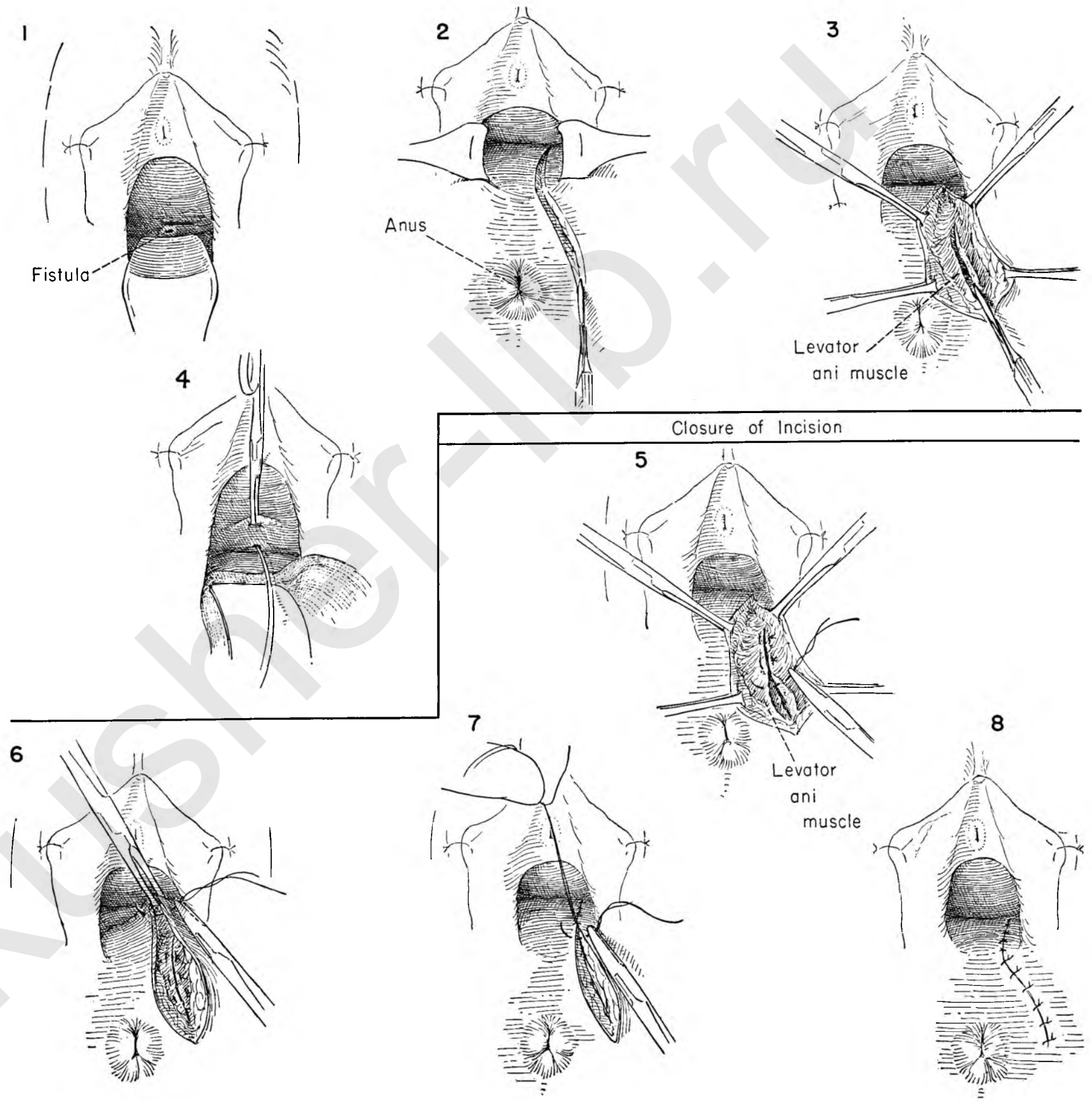
FIGURE 4. With a warm moist pack laid on this wound and a Deaver retractor over this to protect the tissues, an adequate view is now obtained of the fistula. A probe is shown in the tract.

FIGURE 5. When surgery at the vaginal apex is concluded, the perineum is repaired. Here the levator is reapproximated with interrupted mattress sutures.

FIGURE 6. The vaginal portion of the incision is closed in the usual way with interrupted catgut stitches loosely tied.

FIGURE 7. Each suture is held long and on tension to assist in the placing of the next one. Closure is continued down across the perineal skin.

FIGURE 8. This shows the final view after repair has been completed.



VESICOVAGINAL FISTULA

VAGINAL REPAIR

The majority of fistulae can be satisfactorily repaired through the vagina. The secret of successful repair is in adequate mobilization and exposure, not the type of suture material used. When the fistula enters the anterior vaginal wall, operation with the patient in a modified knee-chest position may offer access to it. This plate will demonstrate repair by this approach.

FIGURE 1a. The patient on the table.

FIGURE 1b. As seen from below, one notes the abduction of the thighs which permits ready access to the operative field.

FIGURE 2. With the epithelium on tension and the lateral and posterior walls of the vagina retracted, the surgeon encircles the fistula, incising the full thickness of vaginal wall.

FIGURE 3. The opening is enlarged and the vaginal wall separated from the bladder, leaving the fistula encircled by a rim of epithelium.

FIGURE 4. This separation is carried out on all sides of the fistula, exposing the bladder wall with the fistula in the middle. Stay sutures may be used on the edges of the vaginal incision to minimize the number of instruments in this narrow field. The opening may be extended laterally by incising the vaginal wall.

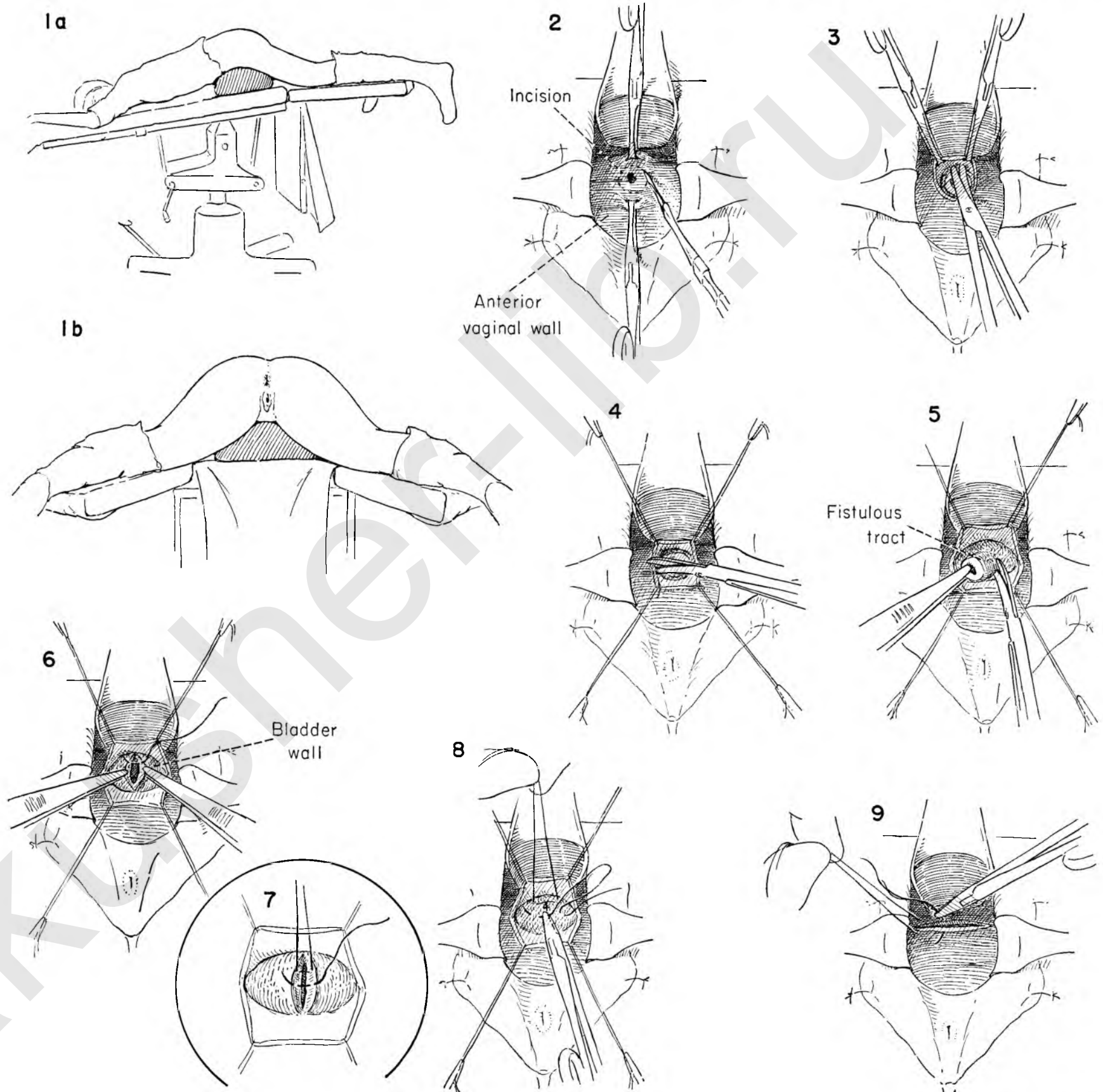
FIGURE 5. With adequate bladder wall exposed the surgeon then places the fistulous opening on traction and excises the entire tract.

FIGURE 6. With a fine atraumatic catgut suture the surgeon picks up the bladder wall on either side and places the first of a series of interrupted sutures. Each suture is held up as the next one is placed.

FIGURE 7. The sutures do not enter the interior of the bladder. They should approximate the edges without tension. When all are placed, they are tied and cut.

FIGURE 8. A second row of sutures approximates the bladder musculature.

FIGURE 9. The defect in the vaginal epithelium is converted into a transverse ellipse and closed with a series of interrupted sutures at right angles to that of the bladder wall.



TRANSVESICAL REPAIR OF VESICOVAGINAL FISTULA

When preoperative cystoscopy and preliminary investigation place the fistula in close proximity to the ureteral outlet in the bladder, vaginal repair may prove to be too blind a procedure. Direct attack on the fistula through the bladder has the advantage that it may be carried out under direct vision.

INSET A. This diagram demonstrates the position of the fistula in relation to the bladder neck and urethra. The vagina is packed with gauze to elevate the floor of the bladder and aid in exposure.

FIGURE 1. A short midline incision is made in the abdominal wall.

FIGURE 2. The peritoneum in the lower wound is separated from the rectus muscle bundles with the knife handle.

FIGURE 3. A retractor provides exposure as the peritoneal reflection is identified in relation to the bladder wall. It is retracted upward with gentle traction of the fingers.

FIGURE 4. With the peritoneum held upward with the Deaver retractor laid over gauze the surgeon and assistant grasp the anterior bladder wall and incise between Allis clamps.

FIGURE 5. A self-retaining retractor is placed in the bladder opening. Further exposure is provided by retractors at opposite ends of the incision. The trigone of the bladder is identified, and a catheter is placed in the ureteral opening close to the fistula to demonstrate the course of the ureter in the bladder wall.

FIGURE 6. An incision is then made in the mucosa circumscribing the fistulous opening. It is here that the gauze pack in the vagina which elevates the bladder floor will be most helpful.

INSET B. If this is not enough elevation, fine stay sutures at spaced intervals around the opening may be placed.

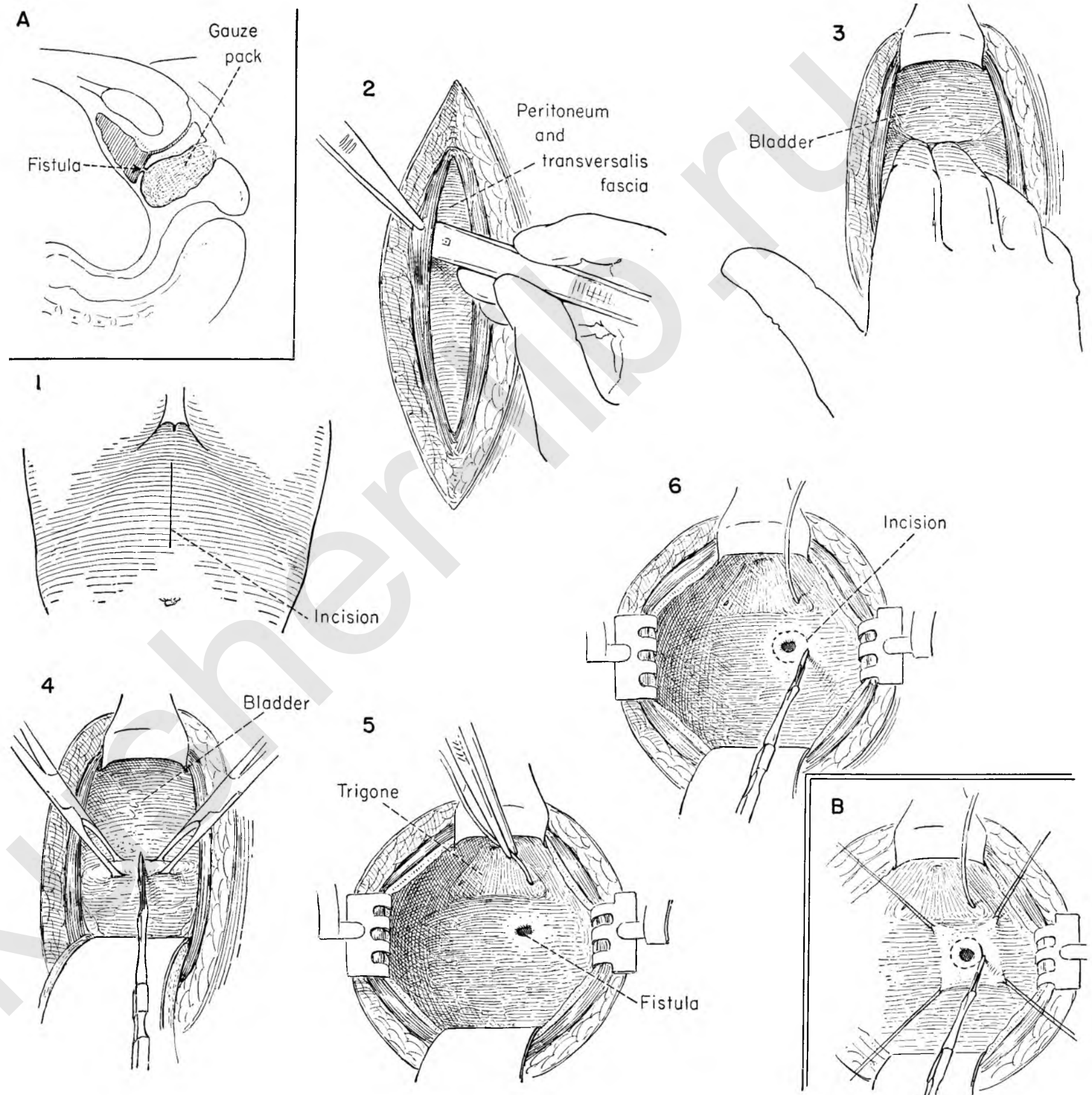


FIGURE 7. Forceps hold the cut edge on tension and provide exposure as the incision is deepened on all sides of the fistulous tract until the vaginal wall is encountered. Further dissection frees the vagina from the bladder for about 1 cm. in all directions.

FIGURE 8. When the vaginal wall is sufficiently exposed in relation to the fistula, the tract is placed on tension and completely excised.

FIGURE 9. The vaginal wall opening is closed vertically with a series of interrupted catgut sutures. When all are placed, they are tied and cut.

FIGURE 10. A second layer of interrupted catgut sutures is placed in the vaginal wall.

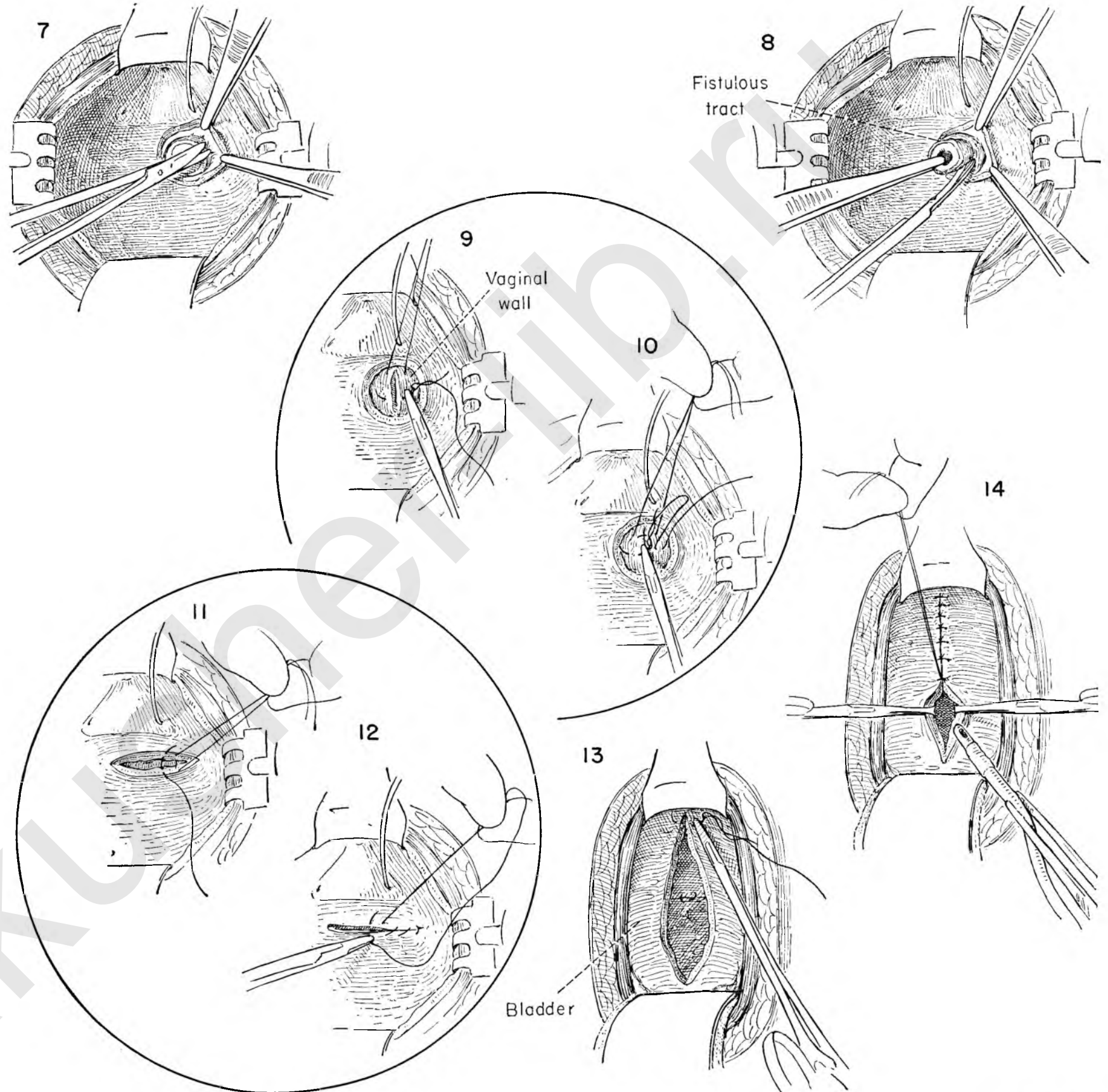
FIGURE 11. The bladder musculature is closed transversely with a series of interrupted catgut sutures.

FIGURE 12. A running row of fine atraumatic catgut approximates the mucosa.

FIGURE 13. The bladder wall incision is then closed with a series of interrupted catgut sutures starting at the lower end. Each is tied and held as the next suture is placed.

FIGURE 14. An opening is left at the dome of the bladder for a Foley catheter, which is held in place with an interrupted catgut suture placed in the bladder wall and through the catheter where it is tied. When the balloon is filled, the catheter should fit snugly against the dome of the bladder.

The wound is then closed and a Penrose drain placed in the prevesical space at the lower end of the wound.



REPAIR OF VESICOVAGINAL FISTULA THROUGH THE ABDOMINAL CAVITY

In certain instances the fistula between bladder and vagina may appear in an area remote from the ureteral opening into the bladder. Inaccessible from below, it is so situated that the approach through the bladder may be less direct than an approach through the abdominal cavity.

INSET A. Showing the anatomical position of the fistula in relation to the vaginal canal, which is packed with gauze to provide a firm surface for dissection.

FIGURE 1. The abdomen may be opened through a paramedian incision. A transverse or Pfannenstiel incision may be used, depending on the preference of the operator.

FIGURE 2. The patient is in the Trendelenburg position. The abdominal wall is held back by the self-retaining retractor after packing the intestine out of the lower pelvis. A Deaver retractor is placed in the midline below to aid in the exposure. The vaginal apex with its peritoneal cover is identified in relation to the bladder wall. The surgeon and assistant pick up the peritoneum with forceps as the former incises it.

FIGURE 3. Kelly clamps are placed on the peritoneal edge as the surgeon separates it from the bladder lying beneath.

FIGURE 4. With the anterior wall of the bladder denuded of peritoneum, the surgeon retracts the posterior wall of the bladder and begins to dissect it free from its attachments to the vaginal stump. Continuation in this plane of dissection will demonstrate the fistulous tract, which is then transected.

FIGURE 5. The assistant continues to elevate the bladder by traction on the anterior peritoneal bladder flap as the surgeon elevates the bladder wall, revealing the fistulous opening into the bladder, as distinct from that entering the vaginal canal.

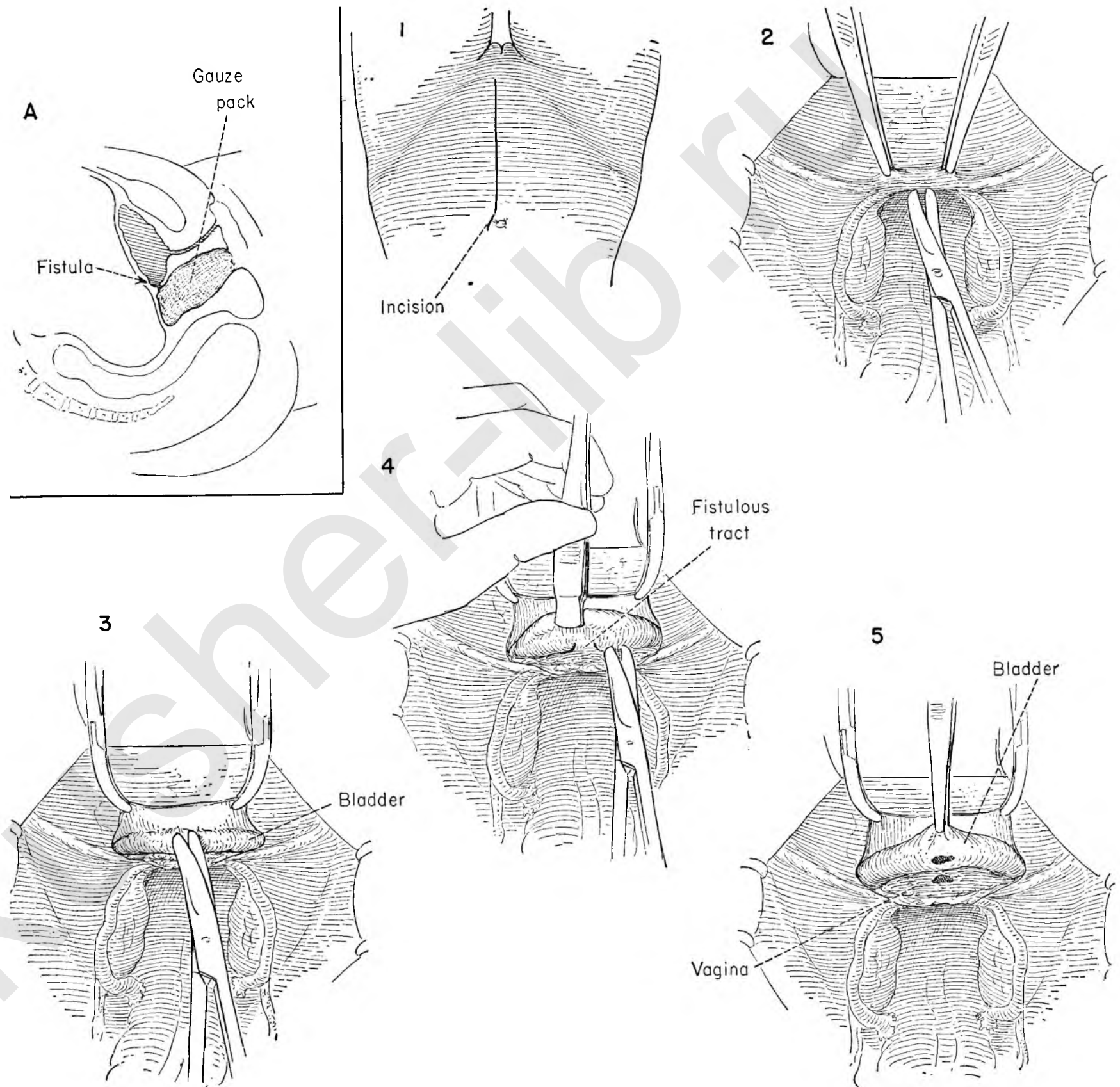


FIGURE 6. With enough bladder wall freed so that the sutures may be approximated without tension, the surgeon picks up the bladder wall on either side of the fistulous opening and introduces an atraumatic catgut suture in the bladder wall, taking care not to enter the bladder mucosa. Each stitch is held as the next one is placed.

FIGURE 7. The initial row of sutures is tied and cut. A second layer is similarly laid into the bladder wall. When all are in place, they are tied and cut, thereby burying the first line of sutures.

FIGURE 8. The bladder closure is now complete. The bladder is then retracted with the forceps handle as the fistula opening in the vagina is exposed. A series of interrupted catgut sutures is then placed in the vaginal wall on one side of the opening into the vagina and then on the other. These sutures are placed transversely or at a right angle to the initial reparative sutures in the bladder wall. When all are in position, they are tied and cut.

FIGURE 9. With the bladder still retracted, a second reinforcing layer of interrupted sutures is laid in place in the vaginal wall, tied and cut, thereby burying the primary vaginal suture line.

FIGURE 10. The opening in the peritoneum at the vaginal apex is now closed with a running stitch to cover all raw surfaces.

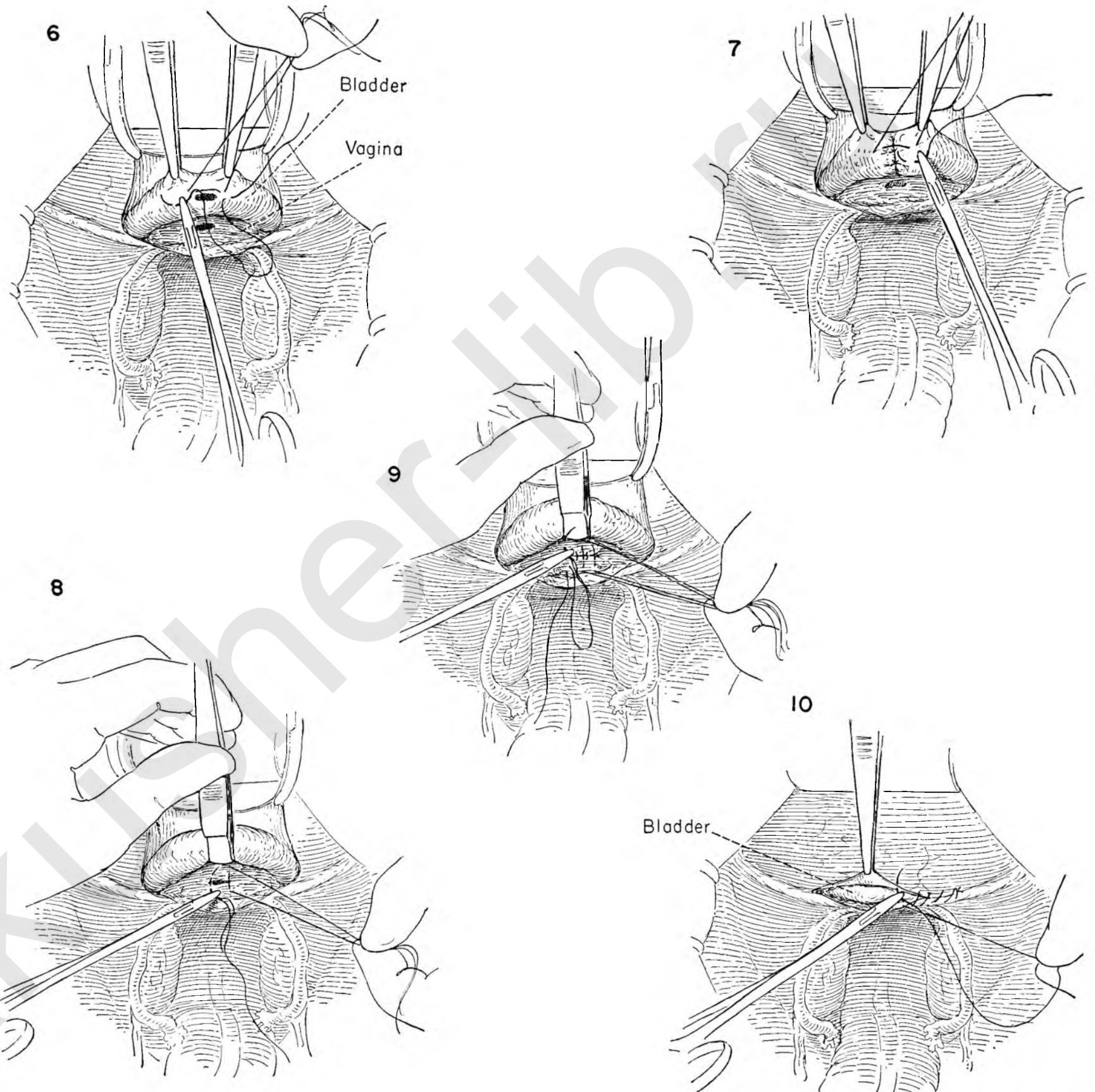


FIGURE 11. To divert the urinary stream during the period of healing, a suprapubic cystostomy should be done. Kelly clamps on the lower edges of parietal peritoneum are placed on tension, and the peritoneum is stripped from the underlying muscles, laterally exposing the bladder.

FIGURE 12. With the palm of the right hand the surgeon strips the peritoneum off the dome of the bladder.

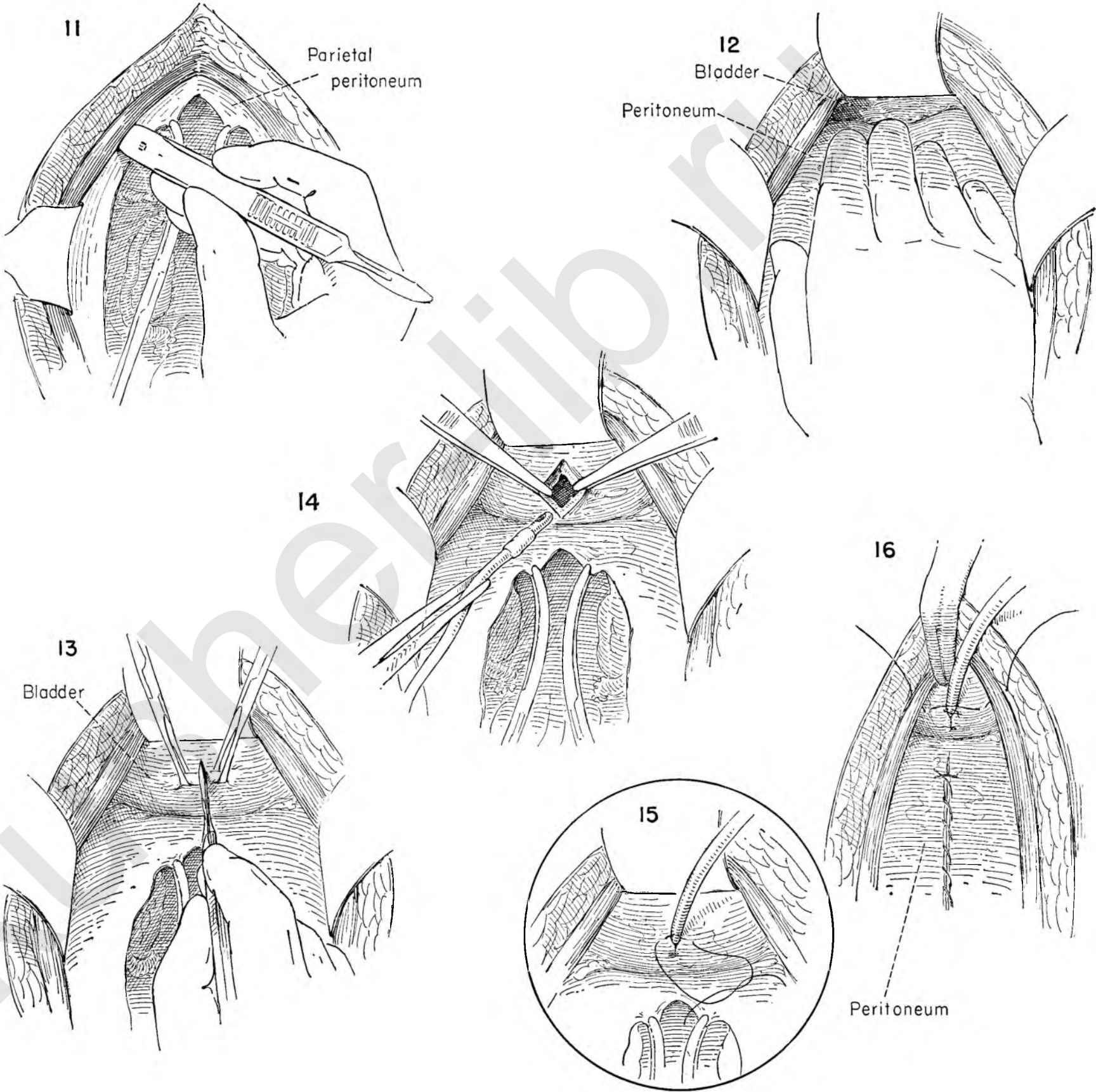
FIGURE 13. The anterior wall of the bladder has now been laid bare. It is grasped near the dome below the level of the peritoneal reflection. The interior of the bladder is entered by incising the wall between Allis forceps.

FIGURE 14. The edges of the bladder opening are steadied with forceps as a Foley catheter is introduced into the bladder.

FIGURE 15. The balloon is filled and the catheter pulled snugly up against the dome of the bladder. The opening in the wall around the catheter is closed with interrupted sutures one of which fixes the catheter in place.

FIGURE 16. A catgut suture is then started through the right rectus fascia and muscle to pick up the bladder on either side of the catheter, and emerges at the same relative position on the left after passing through rectus muscle and fascia.

When the wound is closed, with a drain in the prevesical space, tying of this suture will hold the bladder up to the abdominal wall and at the same time prevent the tube from lying against the symphysis, thus avoiding a possible osteomyelitis.



RECTOVAGINAL FISTULA

Depending on its size and location, a rectovaginal fistula may be repaired in one of two ways. When the fistulous opening is small, it may be readily mobilized and repaired with a simple purse-string type of closure.

FIGURE 1. The posterior vaginal wall is held up by Allis forceps at four equally spaced points to provide a fixed surface for the surgeon to circumscribe the fistulous tract by making an incision through the vaginal epithelium with a knife.

FIGURE 2. The incised vaginal edge is picked up around all sides of the tract and separated from the anterior wall of the rectum for a short distance.

FIGURE 3. The edges of the vaginal wall are pulled downward with clamps as the surgeon advances the tips of the scissors upward in the midline, staying close to the under surface of the posterior vaginal wall.

FIGURE 4. The vaginal wall is then incised in the midline, thus exposing a wide area of anterior rectal wall.

FIGURE 5. The surgeon then picks up the margin of the fistula and excises it with the scissors.

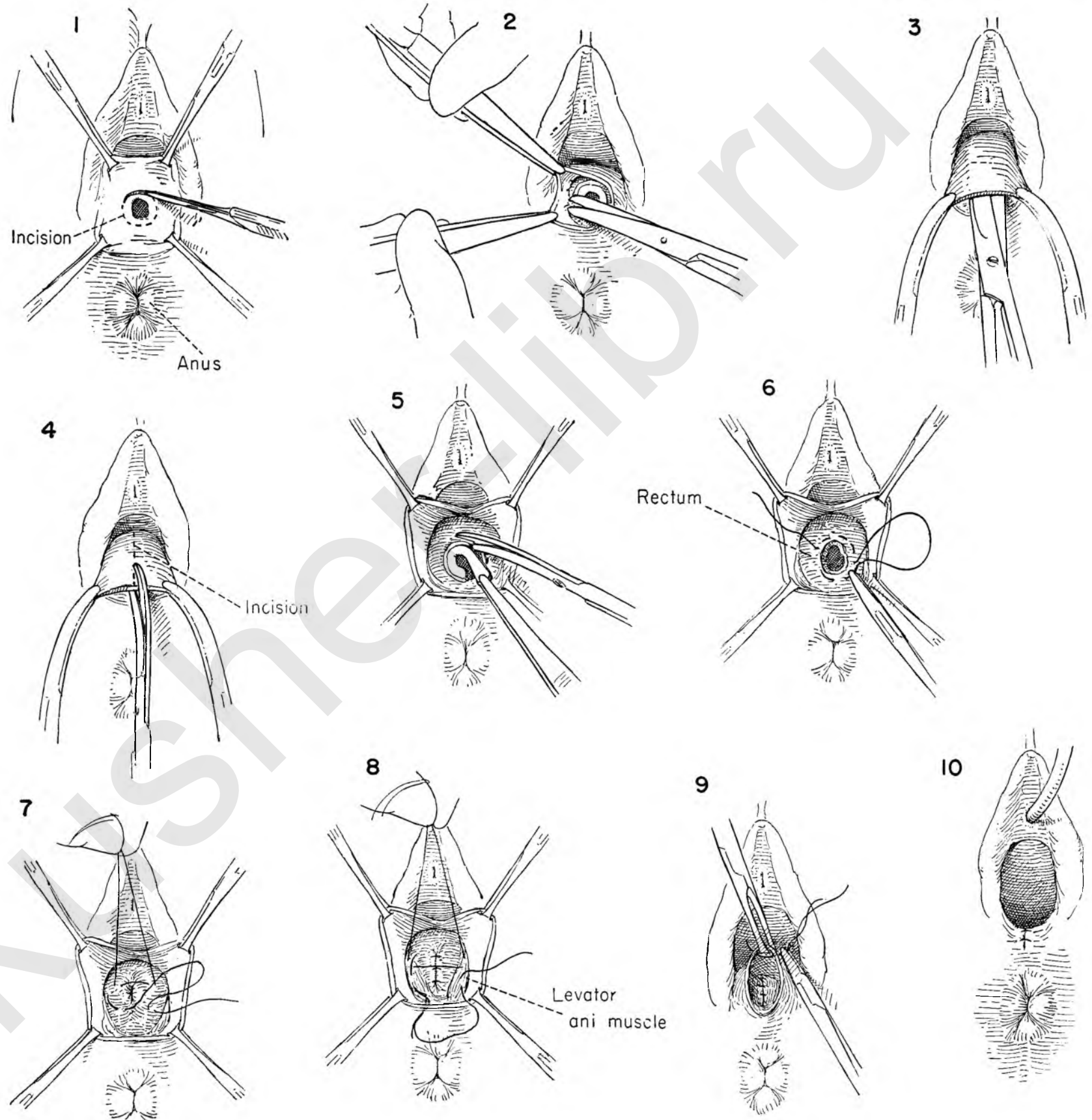
FIGURE 6. A purse-string suture of catgut on an atraumatic needle is then laid in the rectal wall around the fistulous opening. The stitch should be in rectal wall musculature and not penetrate the rectal mucosa.

FIGURE 7. This purse-string suture is then tied and cut. A second layer of interrupted sutures is placed first on one side of the closed fistula and then the other. Several such sutures are placed. When a sufficient number are in place, they are tied and cut, thereby burying the purse-string closure.

FIGURE 8. The levator muscles are brought together in the midline with interrupted catgut sutures, tied and cut.

FIGURE 9. Redundant vaginal wall is trimmed down, and the edges of the vaginal wall are then closed.

FIGURE 10. Showing the completed closure with the fistula repaired.



**RECTOVAGINAL FISTULA
NEAR ANAL SPHINCTER**

When the fistula is large and situated near the fourchette in the midline, the most effective way of repairing it is to convert it into a third degree tear and proceed with the appropriate reconstructive steps.

FIGURE 1. The large midline defect is seen in fairly close proximity to the anal opening. An incision is made through the full thickness of the vaginal wall around the fistula.

FIGURE 2. When it is obvious that insufficient bowel wall can be developed to permit closure without tension, the opening is converted into a third degree tear by cutting through the narrow bridge in the midline.

FIGURE 3. Allis clamps are placed on either side of the vaginal outlet. The plane between vagina and rectum is developed as tension is maintained. This dissection is carried well above the fistula.

FIGURE 4. Kelly clamps will be necessary to maintain adequate traction as the posterior vaginal wall is freed. The flap is then split in the midline.

FIGURE 5. The edges are held up exposing a wide surface of anterior rectal wall and the levator ani muscles on either side. The scarred edges of the fistulous opening are excised.

FIGURE 6. The surgeon picks up the rectal wall and places an interrupted suture first on one side of the rectal wall and then the other, without entering the mucosa. The entire defect is closed in this manner as the sutures are tied and cut.

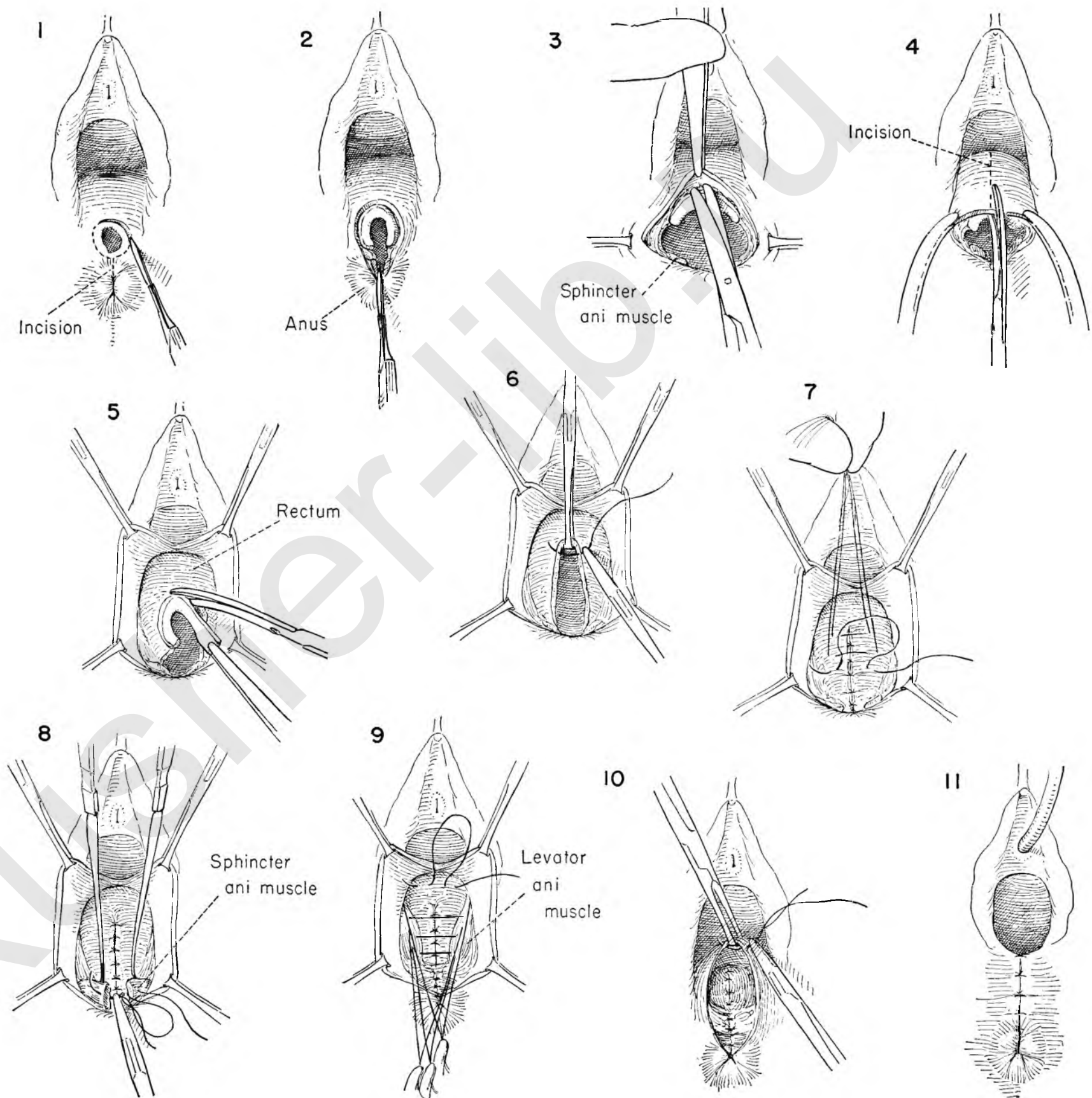
FIGURE 7. A second reinforcing layer is similarly introduced, tied and cut.

FIGURE 8. Nerve hooks pick up the divided ends of the sphincter muscle on either side. These are held on tension as the surgeon approximates the ends with interrupted catgut sutures.

FIGURE 9. The levators are brought together by a series of interrupted catgut sutures. These are held long as the redundant bowel above is reduced with a few shallow stitches in the fascia overlying it.

FIGURE 10. After tying and cutting the sutures, the posterior vaginal wall defect is closed with interrupted catgut sutures.

FIGURE 11. The sutures are tied and cut and the operation is complete.



Minor Operations

There are numerous minor gynecological operations in use today, and situations constantly present themselves in which one or another procedure precisely fits the indications. To select the group for description in this section of the Atlas has been difficult because of this great variety. Of the operations chosen, four deal with the management of the lacerated or eroded cervix. The other two depict the excision of benign lesions of the vulva.

This emphasis on the abnormal cervix is designed to call attention to the fact that cancer of the cervix is so frequently seen that it must be kept always in the foreground of our thoughts. Erosions can never be dismissed as benign on the basis of the way they feel or their gross appearance; biopsy and microscopic examination are essential. It is equally important to remember that the pathologist's report applies only to the samples he has received. A negative biopsy means that no cancer was found in that particular specimen. It is our duty to ensure that all suspicious areas have been included, never forgetting the endocervix as well as the vaginal surfaces.

Once cancer has been excluded as a possibility, treatment of the lacerated or eroded cervix may proceed along one of several lines. The choice in therapy will be made according to the location and extent of the lesion. One usually elects the simplest method that promises to cover the cervix with normal squamous epithelium.

BIOPSY OF THE CERVIX

If there is visible erosion, or if an area of cervical epithelium fails to stain dark brown with aqueous iodine (Schiller test), a fragment is excised from the edge where normal and abnormal tissues meet. Many types of punch biopsy forceps are available, but a small wedge removed with a scalpel has much to recommend it. The full thickness of epithelium must be included.

When biopsy is indicated on the basis of symptoms or cytologic studies and no suspicious area can be seen, it is vital that tissue be removed from all areas that might harbor malignant changes. The first step will be a fractional curettage. This means the removal of tissue for biopsy separately from the endocervical canal, the lower endometrial cavity and the fundus of the uterus. One proceeds deliberately from below upwards; the material from each area is scraped out on a strip of fine-meshed gauze and then transferred to a piece of paper, dropped into a jar of fixative solution, labeled and sent to the pathologist.

The junction of squamous and columnar epithelium near the external cervical os is the area most strongly under suspicion. Biopsies taken from each quadrant will usually detect a lesion if one is present, but even greater accuracy will be possible if the entire squamocolumnar junction is excised in the form of a

cone. This must be done without coagulation or electrodesiccation in order to avoid damage to the tissues of the biopsy specimen. After surgical removal the raw surfaces left behind will usually ooze and should be sutured or cauterized. The pathologist must be encouraged to examine all of the specimen rather than random samples, for one is searching for malignant changes that may affect only a tiny area of the epithelium.

CAUTERIZATION OF THE CERVIX

When an erosion of the cervix is superficial and without extensive deformity or deep scarring, the stimulus to epithelial growth produced by cauterization will usually bring about complete healing. Most often this method is applicable to the cervix with a shallow transverse laceration and exposure of the endocervical canal above and below the os. This is a simple office procedure in the hands of many surgeons; as such it is most successful in the patient who is recently postpartum. Under anesthesia it is possible to do the whole job at one sitting. With the actual cautery a series of deep, radial, linear burns is inflicted on the exposed cervix far enough apart to leave tongues of undamaged epithelium between each pair of lines and extending from the endocervical canal well out into normal epithelium.

The radiant heat given off by the cautery is great, and the surgeon should remember to cover the tissues around the vaginal orifice with moist packs for their protection.

CONIZATION OF THE CERVIX

Hyams has introduced a wire tip for the high frequency electrodissector so shaped that it can be turned on its long axis and a cone of tissue of any size removed. This therapy is suggested for those cases in which infection of endocervical glands or profuse mucopurulent discharge is the chief complaint. The depth of excision should be sufficient only to accomplish destruction of these glands. Circumferential scarring of deeper structures may result in the gradual development of a most troublesome stricture. The patient should return to the office for gentle dilatation to ensure patency of the canal.

LOW AMPUTATION OF THE CERVIX

This operation is offered when scarring and deformity of the cervix are extensive. The vaginal portion of the cervix is transected at the level of the fornices and the stump covered with full thickness flaps of epithelium from the vagina in front and in back. Preliminary dilatation of the canal and curettage are important. The cervix is cut across cleanly. Adequate flaps of vaginal wall are freed up and then brought across the transected cervix and held there with the Sturmdorf stitch. It is essential to check the canal for patency at the conclusion of the operation.

TRACHELORRHAPHY

Plastic reconstruction of the cervix is successful when only one major scar is present. This may be unilateral or extend through the external os to the other side. Each of these situations has been illustrated. The operation is planned to excise the entire laceration and scar, taking care that an adequate central canal is left. The cervix is then reconstructed by suturing together the opposing raw surfaces. These come together with considerable tension. Though chromic catgut is commonly used, it is recommended that one use fine wire for sutures and leave them in place for ten to fourteen days.

EXCISION OF CYST OF BARTHOLIN'S GLAND

This lesion presents in the posterior third of the vulva and distorts both major and minor labia. It is closest to the skin on its medial surface at the point of attachment of the duct of Bartholin's gland. It is preferable to avoid a scar of this aspect of the vulva; excision is deliberately planned through an incision just outside the vaginal canal. There is usually extension much further anterior than one suspects, but all the cyst wall must be removed if recurrence is to be avoided. Profuse bleeding sometimes accompanies these operations. This must be controlled with ties and sutures, and it is wise to obliterate the cavity by suturing the walls to each other. The skin itself heals quickly and easily; loose closure with a few sutures is adequate.

When the cyst is acutely infected, it may be an act of wisdom to drain the abscess and wait for cellulitis to subside before excision is carried out.

SIMPLE VULVECTOMY

This procedure involves the removal of all the vulva, including all labia and the clitoris. The inner border of excision is the junction between keratinized and squamous epithelium surrounding the urogenital vestibule. The operation is designed only to remove diseased or abnormal skin; underlying fat is removed in amounts sufficient only to permit easy closure without tension. It is inadequate for treatment if cancer is present. When the indication is a precancerous change, therefore, invasive carcinoma must be ruled out by biopsy of all suspicious areas prior to the vulvectomy.

Closure of the wound is usually a simple matter. It is advisable in most cases to elevate the posterior vaginal wall and approximate the levator muscles as in perineal repair. To do this will prevent the development of the rectocele which is often noted following vulvectomy.

BIOPSY OF THE CERVIX

There are many instruments designed to permit rapid removal of a bite of tissue when a suspicious area is seen on the cervix. This is usually a simple office procedure.

When the cervix appears harmless, however, and the suspicion of disease has been raised by symptoms or by cytologic studies, the technique of biopsy must ensure an adequate sampling. This is accomplished by following a routine which scans the uterine cavity, the endocervical canal and the entire squamocolumnar junction of the exocervix. In this situation anesthesia is necessary.

FIGURE 1. With the patient in the lithotomy position, the anterior vaginal wall is elevated with the left thumb and the cervix exposed, seized with tenacula and brought to the introitus.

FIGURE 2. The cervical canal is gently dilated.

FIGURE 3. A small curette explores the full circumference of the endocervix. Every fragment of tissue is deposited on a strip of moist, fine-meshed gauze and sent to the pathologist.

The uterine cavity is then similarly explored with the curette and the tissue kept separate from the previous specimen.

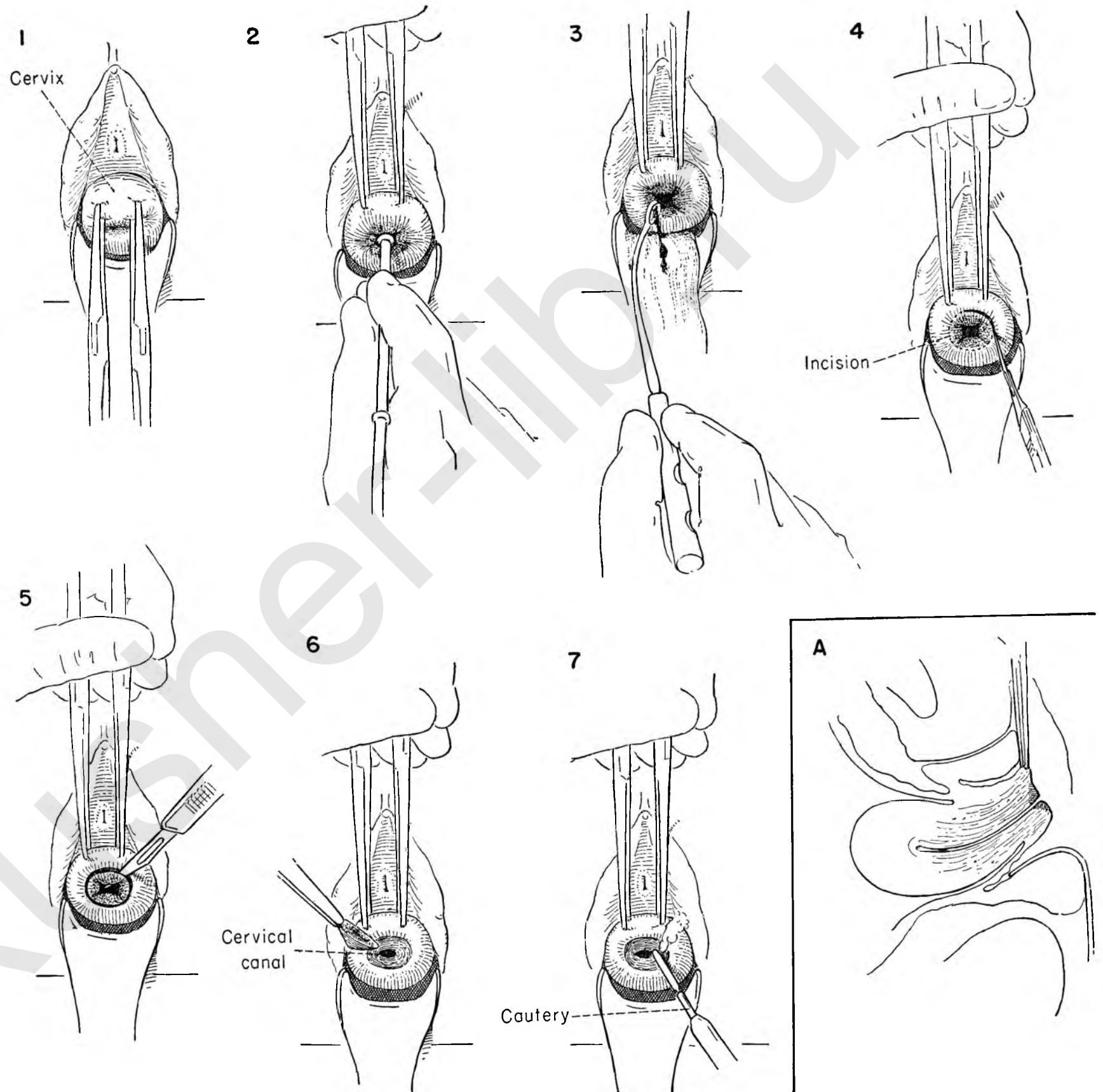
FIGURE 4. The squamocolumnar junction is to be excised in toto. A circular incision is drawn around the external os with a pointed, narrow-bladed knife.

FIGURE 5. The knife is then thrust obliquely through beneath this circle until the tip enters the endocervical canal. With short sawing strokes which follow the circle a cone of tissue is excised completely surrounding the external os.

FIGURE 6. This specimen is carefully lifted out and sent to the pathologist for study. Frequently the irregular contour of the cervix will make it necessary to accomplish this in two or more fragments. All should be examined microscopically.

FIGURE 7. If there is significant oozing from the raw surfaces, light cauterization will control it.

INSET A. Sagittal section showing the cone of tissue excised.



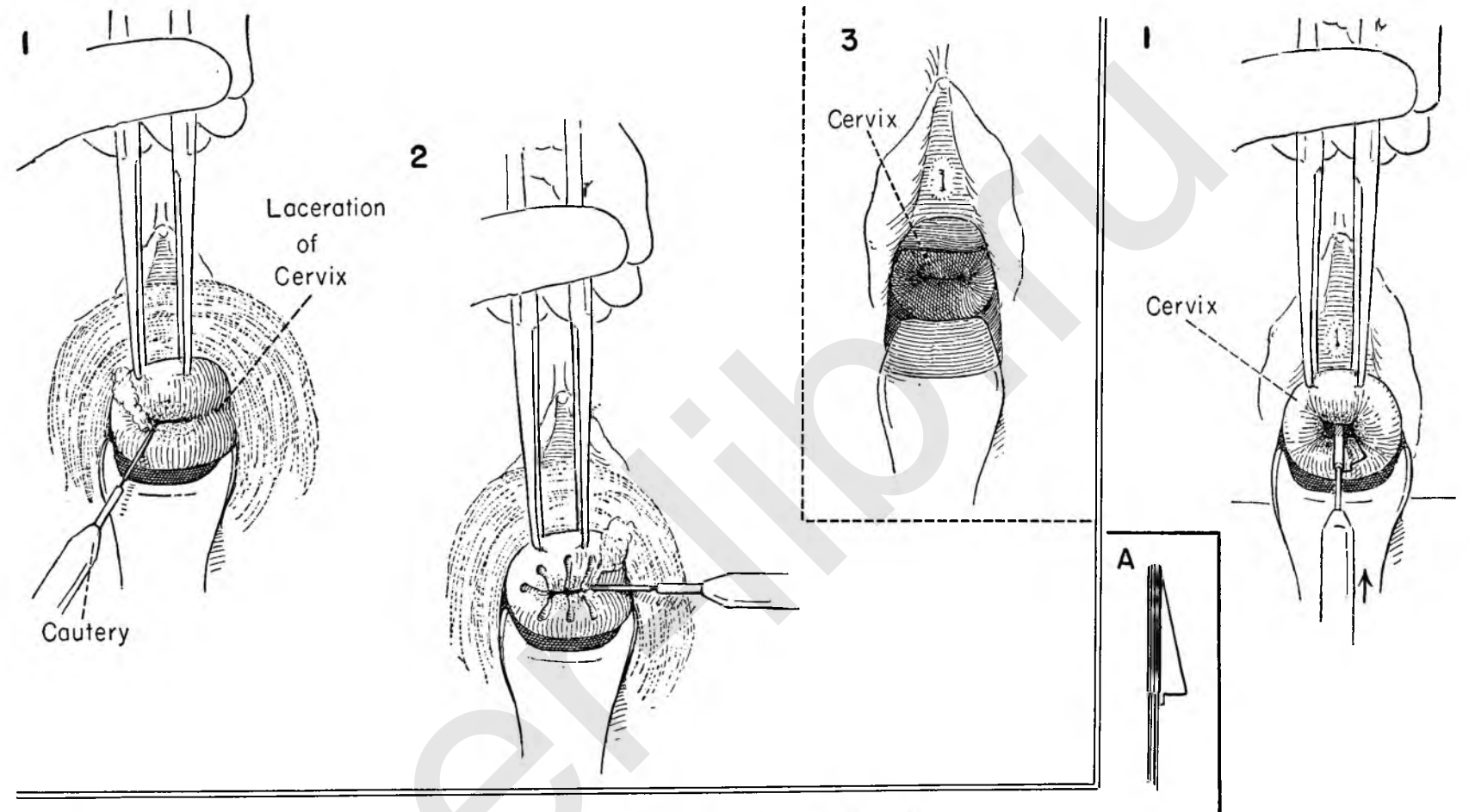
CAUTERIZATION OF THE CERVIX

In the face of marked erosion or ectropion of the endocervical mucosa or deeply seated chronic infection within the tortuous racemose glands of the cervix, all of which give rise to persistent, tenacious and distressing leukorrhoea, radial cauterization of the cervix has much to recommend it. Depending on the depth desired, this procedure may be used in either the office or the operating room. The more superficial lesions can readily be treated as an office maneuver.

FIGURE 1. The cervix is exposed and tenacula applied. Moist gauze protects the vulva. Linear streaks are made with a cauterity radially from the external os as the central point and carried as deeply into the musculature as desired. The tip of the cauterity blade should not carry a white hot heat.

FIGURE 2. Successive linear striations are made from the central focal point, leaving segments of tissue between the cauterized streaks.

FIGURE 3. This shows the healed cervix at three months.



CONIZATION

This procedure is used for the same indications as cervical cauterization.

FIGURE 1. With the cervix on traction the Hyam's conization instrument is inserted into the cervical canal to the full extent of the cutting wire. The width of the erosion or ectropion will determine the size of the conization tip to be used.

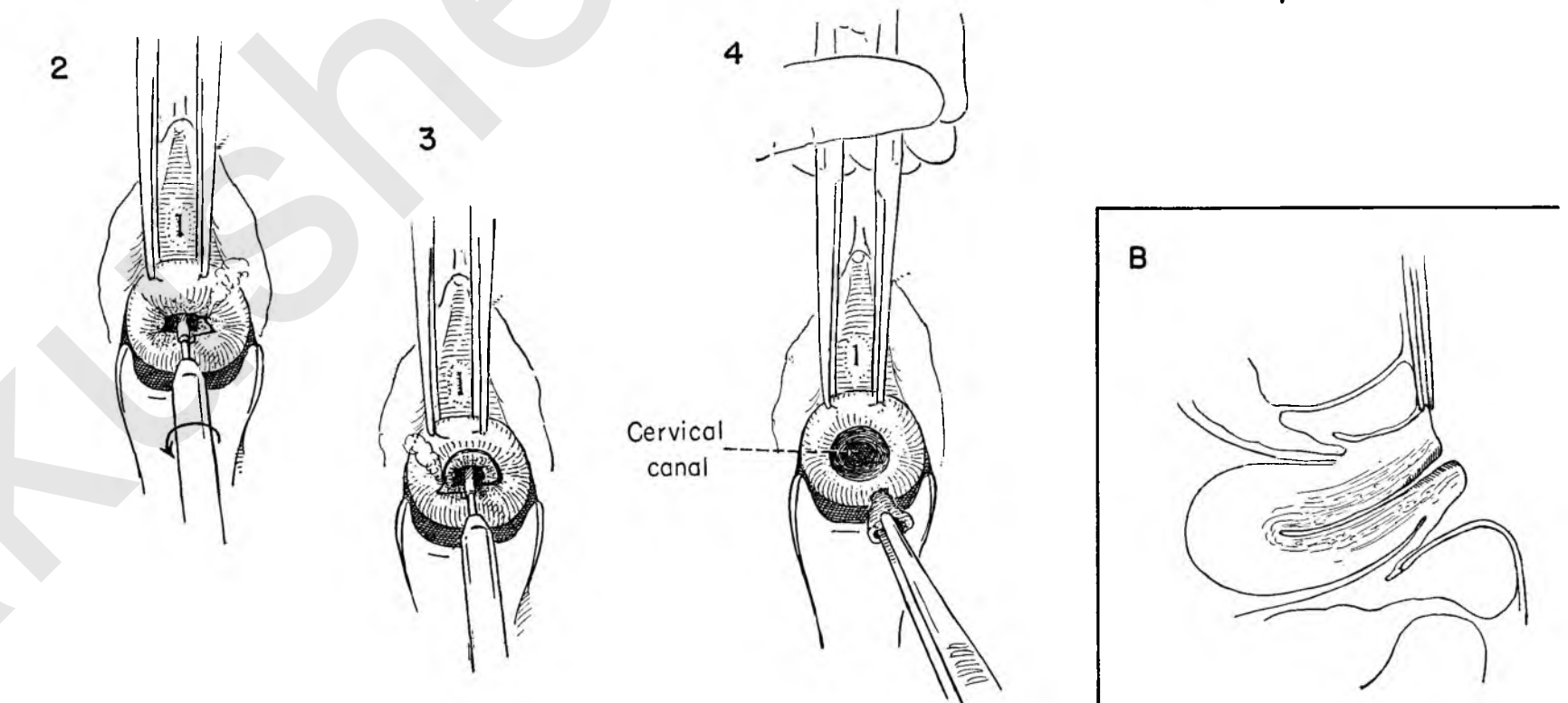
INSET A. Showing the type of coning point.

FIGURE 2. With the wire moderately hot the instrument is gradually turned.

FIGURE 3. The procedure is continued through a full circle.

FIGURE 4. The cone of tissue is removed en bloc. Any bleeding points should be touched with the coagulating current.

INSET B. A sagittal section of the uterus showing the area of excision. Dilatation of the cervical canal at frequent intervals during the period of healing will help to prevent any stenosis.



LOW AMPUTATION OF THE CERVIX

This operation may be done as a definitive procedure for lacerated or infected cervixes with exposure of the endocervix or as part of other procedures such as the Manchester operation. The operation in this instance is being done for a badly lacerated cervix with exposure of the endocervix.

FIGURE 1. Tenacula are applied to the cervix, which is then held upward to permit the introduction of a probe. Thorough dilatation and curettage are performed.

FIGURE 2. The labia are stitched to the surrounding skin with interrupted catgut sutures. The cervix is held down and the vaginal wall incised transversely just above the cervix. The incision carries through the full thickness of the wall.

FIGURE 3. The tenacula turn the cervix upward, and the posterior vaginal wall is similarly incised, thus encircling the cervix.

FIGURE 4. Allis forceps are placed on the edges of the incision on the anterior vaginal wall. Countertraction is applied to the tenacula on the cervix as the vaginal wall is stripped upward.

FIGURE 5. The posterior cervix is freed from the vagina in similar fashion.

FIGURE 6. By elevating the detached vaginal wall on the left side with Allis forceps the lower attachments of the cardinal ligament to the cervix are exposed and clamped just above the site chosen for amputation. The same maneuver is carried out on the right side.

FIGURE 7. The cardinal ligaments are cut and secured with suture ligatures.

FIGURE 8. Amputation of the cervix is carried out at the point of election, using circumferential sweeps of the knife and bevelling slightly towards the fundus. New tenacula are applied to the lateral corners of the cervix to maintain traction as the distal fragment is cut free.

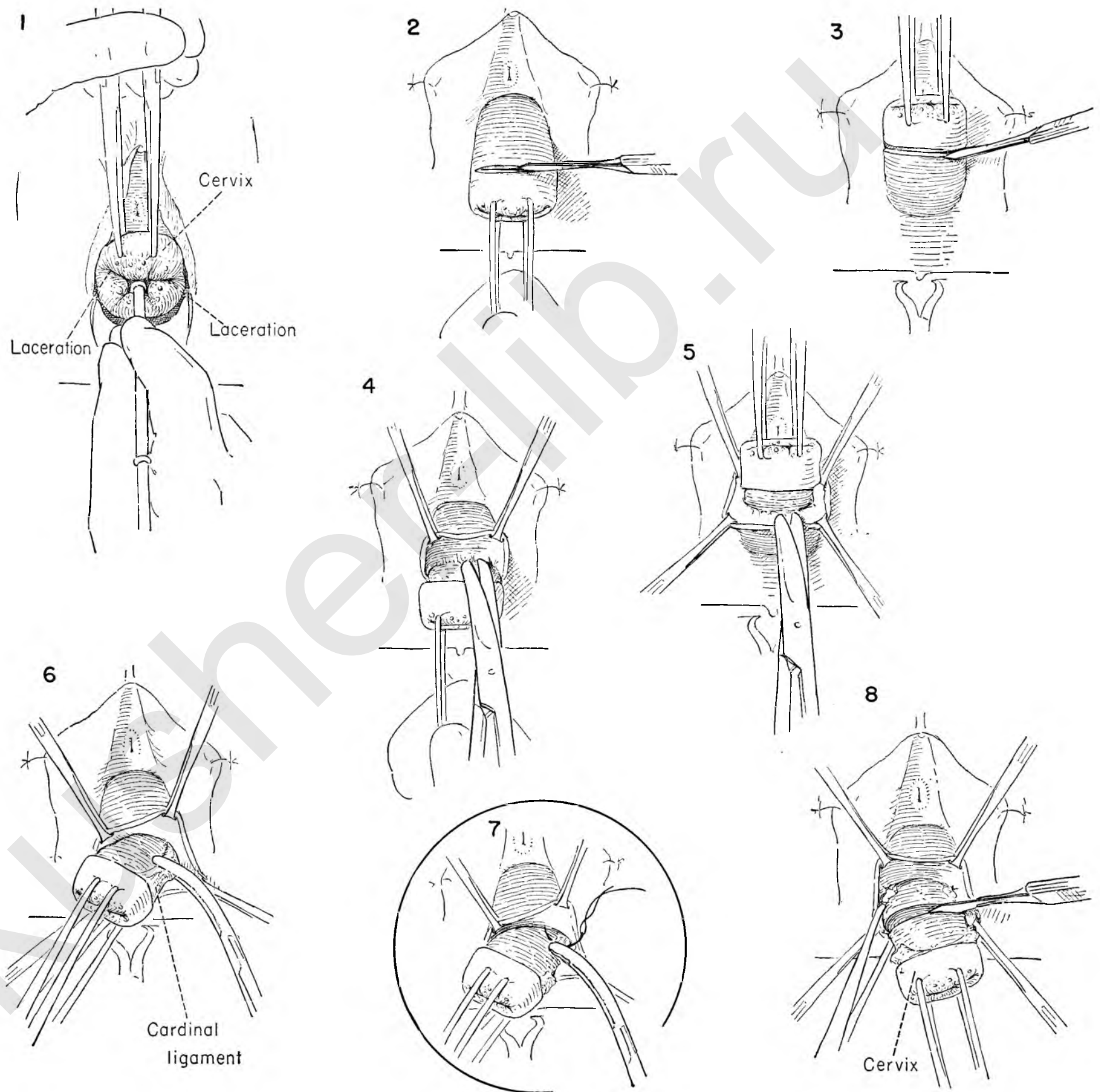


FIGURE 9. Note that the vaginal epithelium has been stripped back from the entire circumference of the cervix for a considerable distance. In this manner a free flap is provided which will be used to cover the raw cervical stump. It should lie easily in this position without tension.

A curved needle with a cutting point is used to pass one end of a catgut suture through the posterior vaginal wall at its midpoint. There it is tied. A second needle is threaded on the other free end of the suture.

FIGURE 10. The surgeon passes one of the cutting point needles through the cervical wall from the canal out through the muscle to emerge on the vaginal side about $\frac{3}{4}$ inch below the original tie.

FIGURE 11. This step is repeated with the cutting needle on the other free end of the suture. This stitch emerges through the vaginal wall about $\frac{1}{4}$ inch lateral to the first one.

FIGURE 12. As this suture is tied the flap of the vaginal wall is drawn up into the cervical canal covering it on the posterior wall.

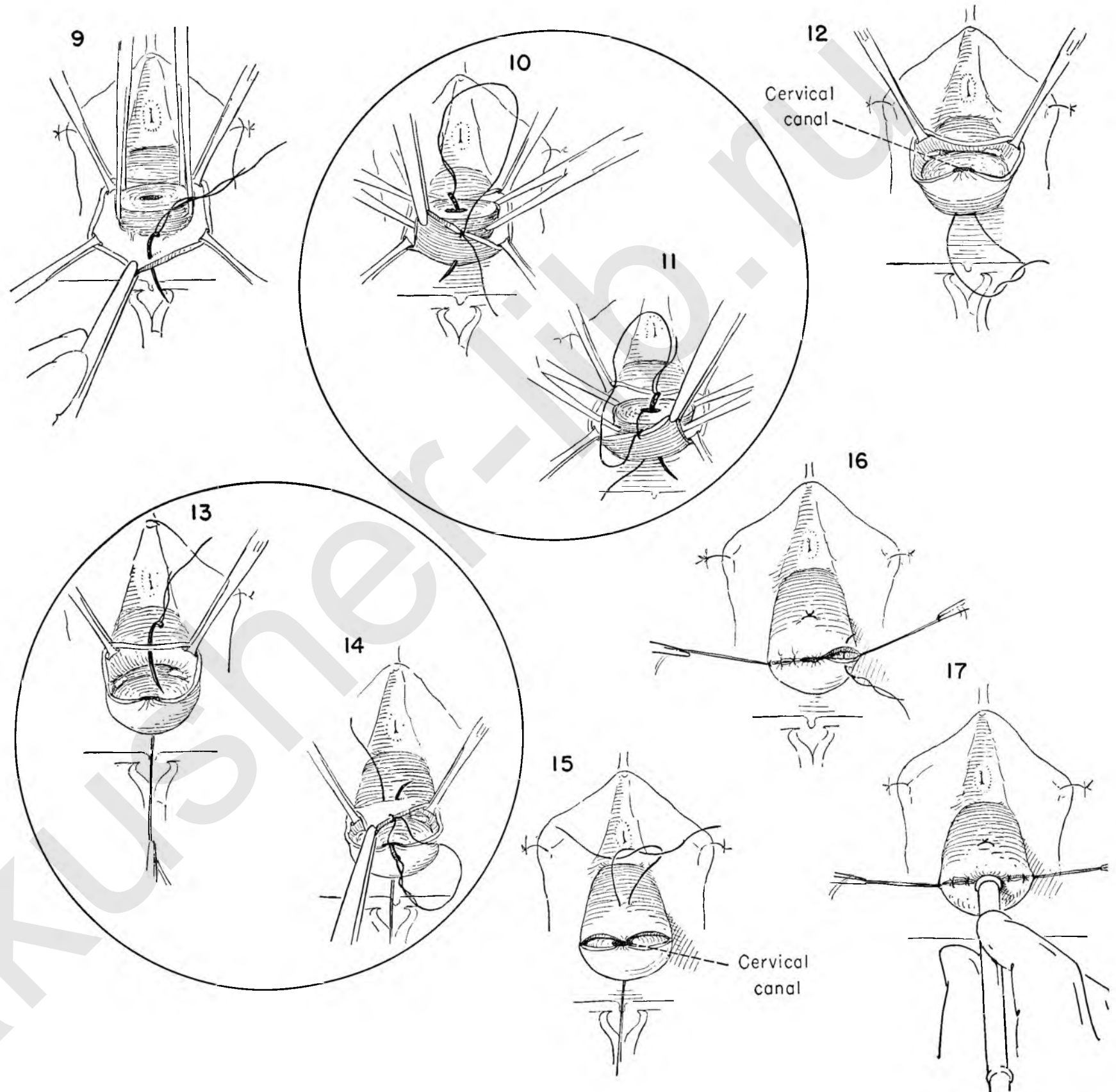
FIGURE 13. The anterior vaginal edge is to be brought over the cervix in identical fashion. Here the stitch is placed in the center of the flap.

FIGURE 14. The second suture is being placed through the substance of the cervix.

FIGURE 15. The epithelium is drawn neatly into place as the stitch is tied.

FIGURE 16. The flap hangs loosely at either lateral corner. The surgeon then begins a stitch at one anterior lateral corner, passing through the vaginal wall and into the substance of the cervix to obliterate dead space and help to control any bleeding from the cervical branch of the uterine artery. A similar suture is placed on the opposite side. These sutures are held long until all raw edges are approximated. They are then tied.

FIGURE 17. The patency of the cervical canal is checked by introducing a medium-sized dilator.



TRACHELORRHAPHY

In the past, trachelorrhaphy was commonly done for repair of the lacerated cervix with exposure of the endocervix as a prophylaxis against subsequent development of carcinoma. Today it is less frequently used than conization, yet it has a definite place in our armamentarium.

FIGURE 1. The anterior lip of the cervix is grasped with a tenaculum on the side away from the laceration. A second tenaculum is placed on the corresponding position on the posterior lip.

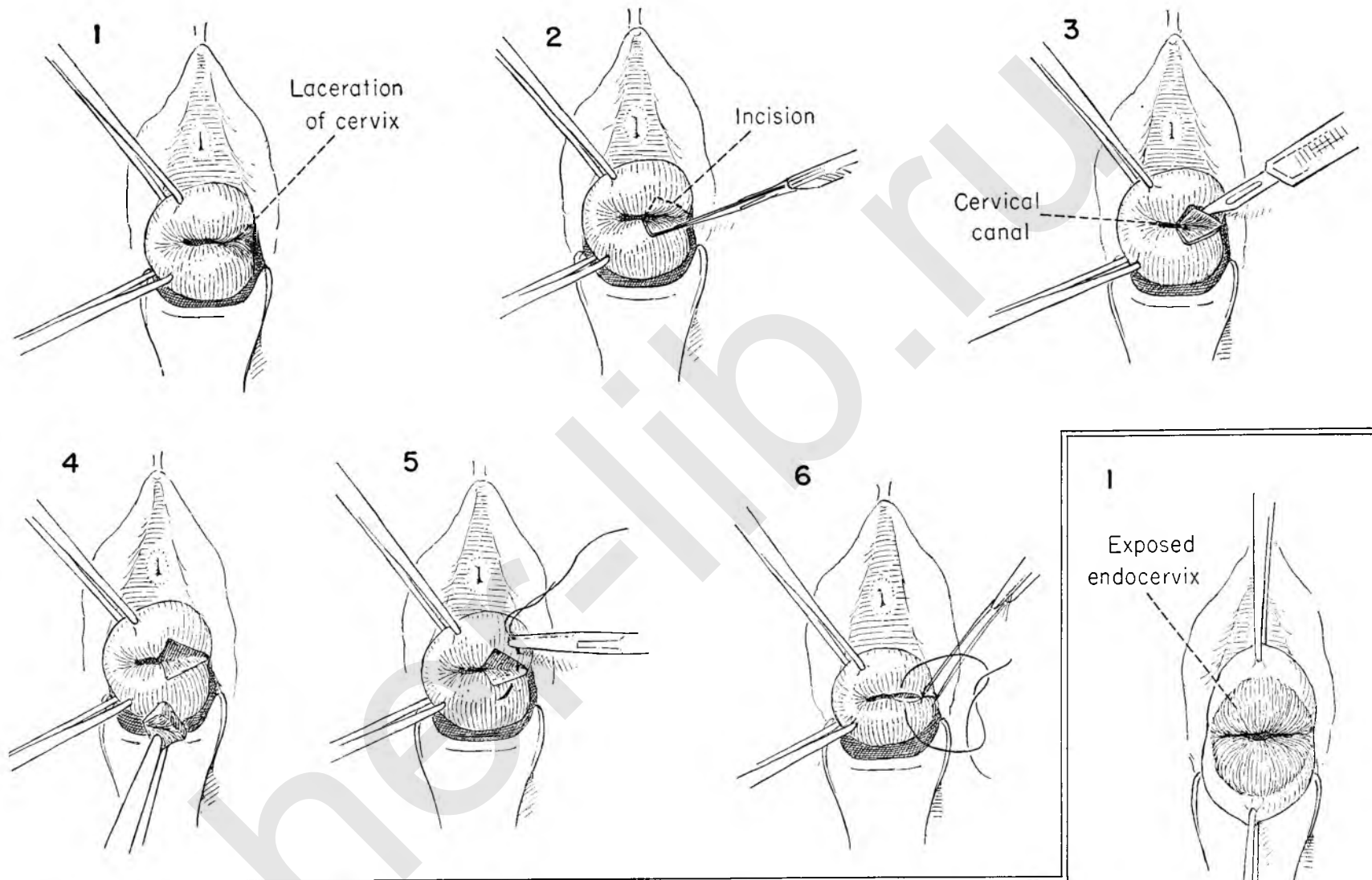
FIGURE 2. Beginning on the lower edge, so that blood running down does not obscure the field, the surgeon outlines the scarred laceration.

FIGURE 3. The incision continues around the area outlined, bevelling medially as one gets deeper.

FIGURE 4. A heart-shaped piece of tissue is removed. Troublesome bleeding from the cervical branch of the uterine artery will be encountered if the excision extends too far laterally on the cervix.

FIGURE 5. The most lateral of the stitches should therefore be placed deep into the muscle, carrying through both edges of the incision. Fine wire sutures can be used.

FIGURE 6. The sutures are drawn to the right and the most lateral suture tied first. Each suture is held long until the next is tied. It is then cut.



BILATERAL TRACHELORRHAPHY

If the laceration is bilateral, both areas are excised before beginning the repair.

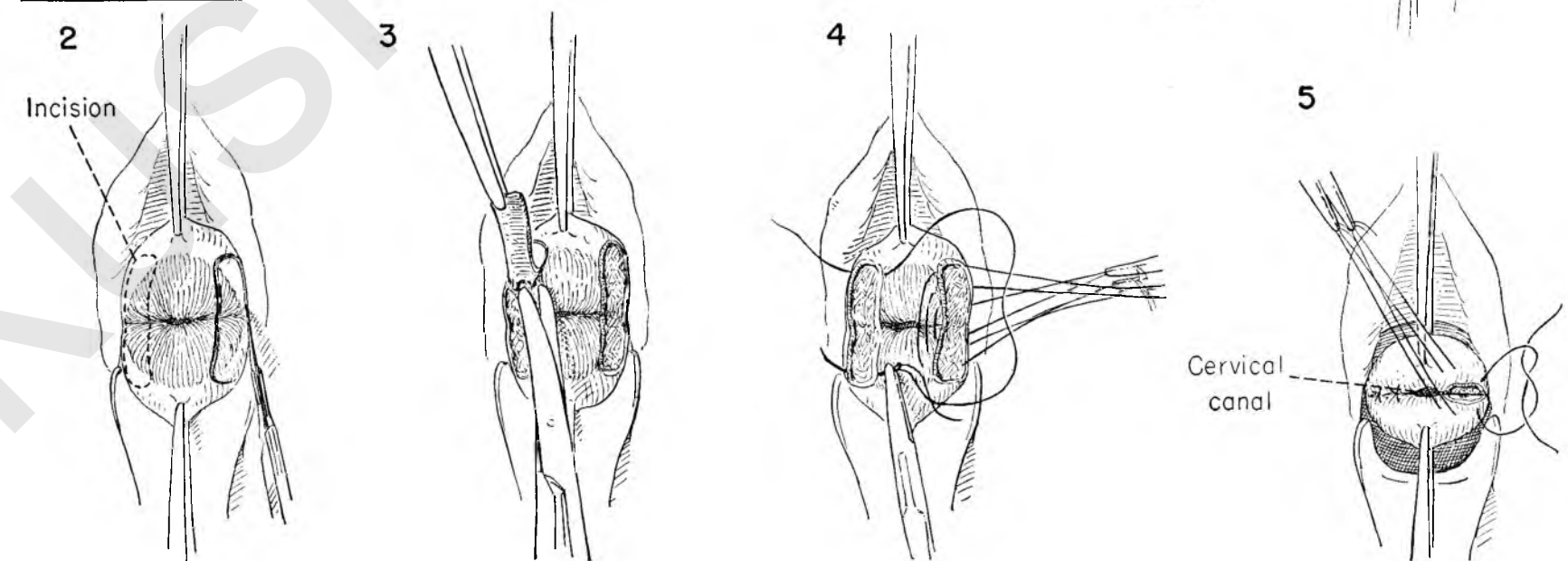
FIGURE 1. A typical bilateral laceration of the cervix with exposed endocervix is shown. Tenacula are applied for traction.

FIGURE 2. The epithelial surfaces on either side are outlined for excision. Since the space between will form one half the circumference of the endocervical canal, care must be taken to leave enough epithelium.

FIGURE 3. The flaps are excised.

FIGURE 4. Fine wire sutures are laid in place, and the ends of each suture are held in a snap.

FIGURE 5. The sutures are drawn together, bringing the raw surfaces of the anterior and posterior cervix in contact. They are tied and cut after testing the canal for patency. Removal in the office will be necessary after two weeks.



EXCISION OF CYST OF BARTHOLIN'S GLAND

Cystic enlargement of Bartholin's gland is a fairly frequent and well recognized gynecological entity. Although the enlargement may regress to the point where only a firm hard kernel can be felt on one side of the vulva or the other, its natural history is that of repeated though intermittent recrudescence. It also has a marked tendency to become infected. A definite effort should be made to remove the gland in its entirety without rupture.

FIGURE 1. The labia are tacked to the skin with interrupted catgut sutures. An incision is made laterally following the natural curve of the introitus through the skin at its junction with the vaginal epithelium.

FIGURE 2. Allis forceps are applied to the edge of this incision. The incised edge on the vaginal side is elevated as the surgeon separates the connective tissue bands holding the vagina to the underlying cyst wall.

FIGURE 3. As the dissection progresses in this plane more clamps are placed on the edge of the vaginal wall to provide countertraction to that offered by the surgeon as he gently retracts the cyst wall with the tips of his fingers laid over gauze. In this manner the dissection proceeds around the circumference of the cyst on its medial side.

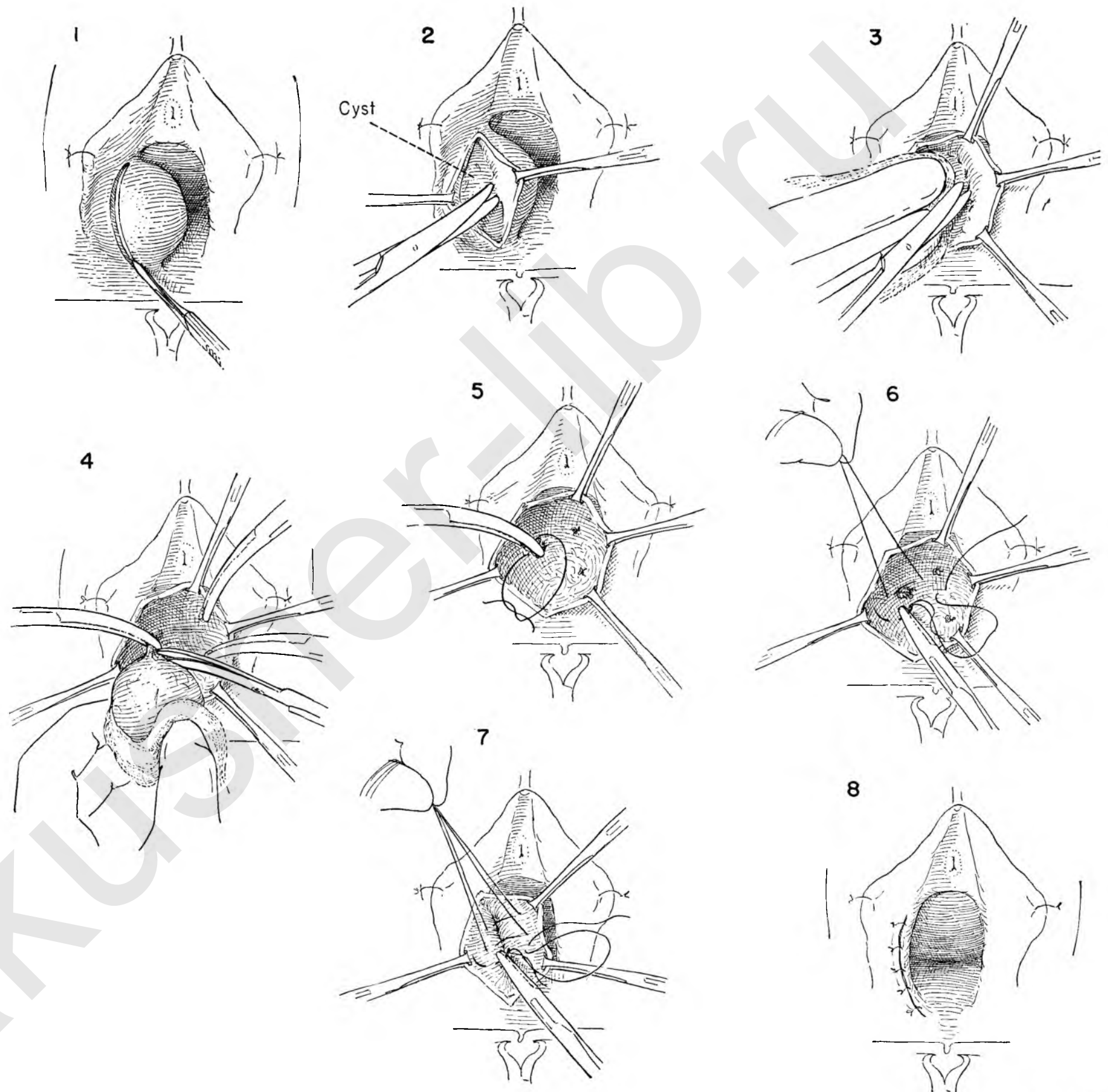
FIGURE 4. This may be a bloody operation. By staying in the plane close to the cyst wall in the dissection and by isolating and clamping each vessel as encountered, the amount of blood loss may be considerably reduced. The cyst is completely enucleated from its bed. A final attachment will always be found at the upper pole. This is clamped and cut.

FIGURE 5. The individual vessels are then tied.

FIGURE 6. To obliterate dead space and to cut down a persistent venous ooze, a series of interrupted catgut sutures is placed in the depths of the cavity. When all are placed, they are tied and cut.

FIGURE 7. A second layer further obliterates the dead space by burying the first line of sutures.

FIGURE 8. The skin edges are loosely closed with interrupted catgut sutures.



SIMPLE VULVECTOMY

In the presence of kraurosis vulvae associated with pruritus the surgeon may elect to perform a simple removal of the skin in and around the vulva. Simple vulvectomy may also be performed as a prophylactic measure in the prevention of subsequent malignant disease. If there is any suspicion of cancer at the time surgery is done, the more radical removal described in the section of the Atlas on Operations for Malignant Disease should be substituted for the simple vulvectomy.

FIGURE 1. Outlines the incisions to be made. The amount of skin to be removed depends on the amount of pathology present. The inner incision encircles the vagina and urethra.

FIGURE 2. The labia are held upward with Allis forceps on either side as the surgeon pulls down on the anterior vaginal wall and incises the epithelium above the urethral opening.

FIGURE 3. The incision continues on both sides and across the midline posteriorly.

FIGURE 4. The surgeon then turns his attention to the outer margin of excision. Beginning in the midline on the mons veneris above the clitoris, the incision extends around the vulva on both sides, removing as much skin as necessary. Individual vessels are clamped, tied and cut as they appear.

FIGURE 5. The incision is deepened around the entire circumference of the vulva as the skin edges are held back with rake retractors. The upper edge of the skin to be removed is pulled downward to expose the suspensory ligament of the clitoris, which is then clamped and divided.

FIGURE 6. The lower edge of the incision is then grasped with Allis clamps and the posterior vaginal wall dissected free of the perineal body and rectum.

FIGURE 7. The lower skin edge is then turned down and held on traction as the surgeon breaks through into the inner incision from below.

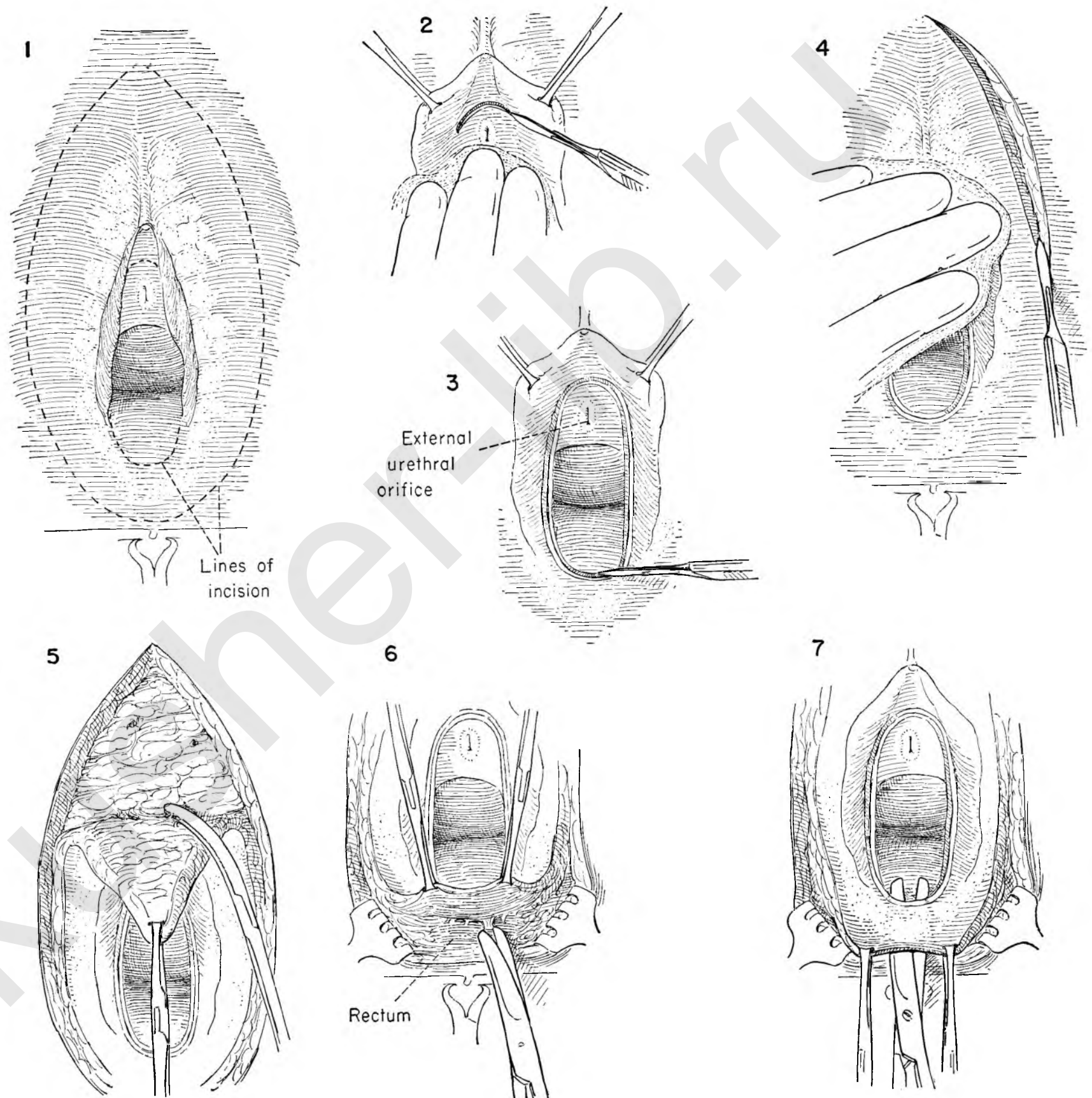


FIGURE 8. Traction is provided on the left lateral margin of skin to be removed, pulling it toward the midline as the surgeon undermines the skin, bevelling the knife toward the vaginal canal. The lateral skin edges are held back with rake retractors.

FIGURE 9. The dissection then continues in this plane until the incision in the vaginal wall is met. In this manner the entire vulva is removed. It is not necessary to remove large amounts of fat or expose the fascia of the deeper muscles.

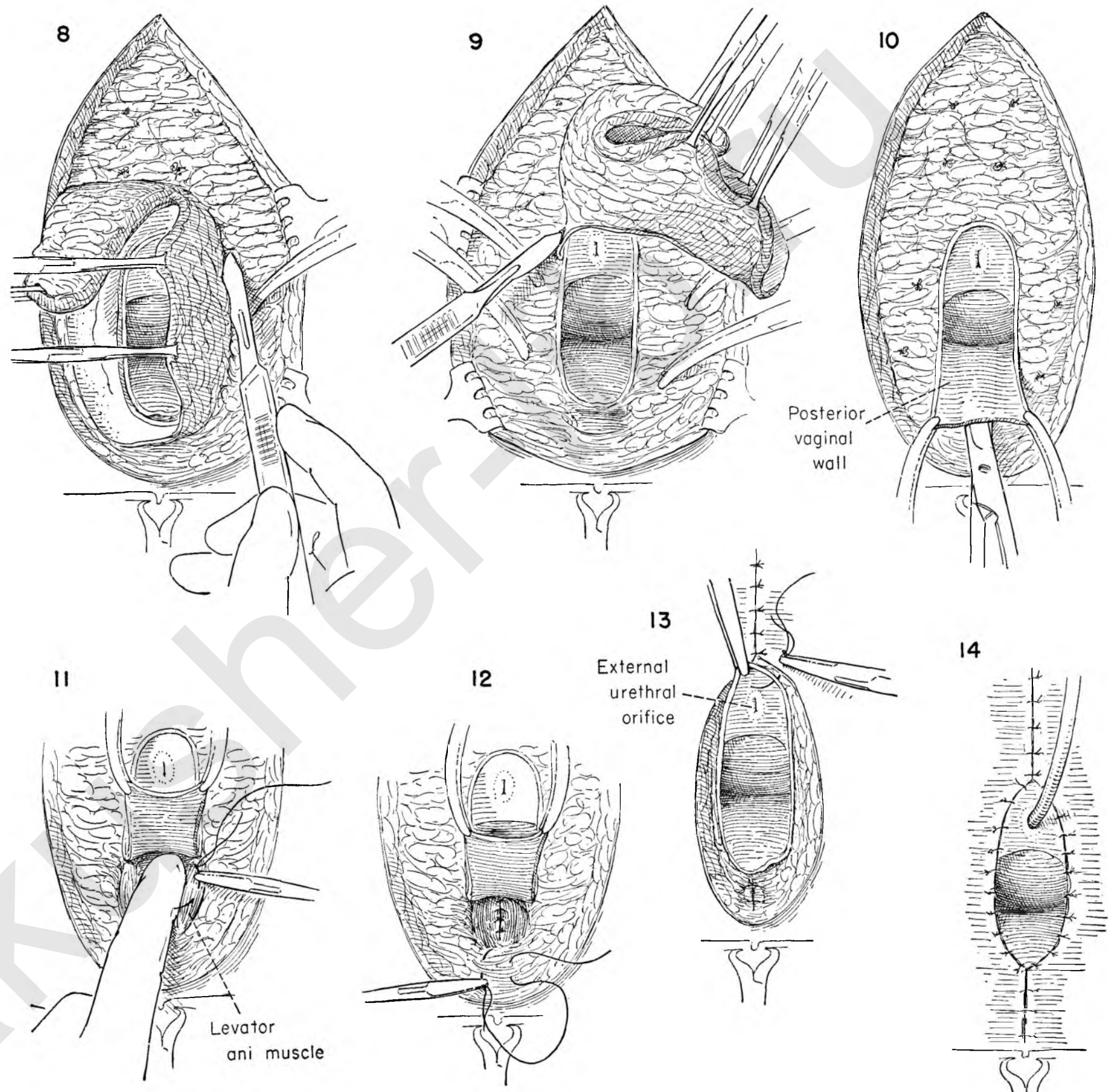
FIGURE 10. The entire specimen has been removed, and any bleeding vessels secured. Traction is applied in a downward direction to the corners of the posterior vaginal wall. The tips of the scissors hug the under surface of the vaginal wall as they are forced upward in the midline. A flap of posterior vaginal wall is created.

FIGURE 11. The posterior vaginal wall flap is then turned upward, exposing the levator muscles. The surgeon places the first of a series of interrupted catgut sutures parallel to each other in each muscle bundle.

FIGURE 12. All these sutures are then tied and cut. Additional stitches reconstruct the perineal body.

FIGURE 13. The skin edges above the vaginal outlet are approximated with interrupted silk. The surgeon then places a series of interrupted silk sutures around the entire circumference of the vagina to bring the skin edges together with the vaginal epithelium.

FIGURE 14. The closure is complete. Drains are unnecessary. The bladder is placed on constant drainage.



SECTION III

*Operations for
Malignant Disease*

akushner-lib

Operations for Malignant Disease

A separate section on the surgery of pelvic cancer has been included in the Atlas because we are convinced that the surgical procedures for cancer differ from those for benign tumors just as the disease cancer differs from its nonmalignant counterpart. The fact that operations for cancer are more extensive and present greater technical difficulty is perhaps less important than the basic difference in concept.

To properly execute the basic principles involved in surgery for malignant disease of the pelvis, the surgeon must have a working knowledge of the life history of the various types of cancer commonly encountered in this area. Each malignant lesion has its own rate of growth, mode of spread and lethal potential. These in turn will be modified by the site of origin. One cannot compare, for example, the lethal possibilities of cancer of the cervix with those of cancer of the endometrium, though both occur in the same organ.

Because malignant disease in the pelvis tends to remain localized to the primary site for a relatively long time, the operation which widely excises the involved organ, its lymphatic drainage channels and the first barrier of lymph nodes in one block of tissue has a greater chance of being successful than is true elsewhere in the body.

Operations for malignant disease in the pelvis begin at the most lateral point of potential spread and move in the direction of the primary cancer in contrast to operations for benign lesions, which are extended laterally only occasionally to permit excision of the local growth. This is the basic concept developed in the wake of better understanding of the malignant process.

Some modification of the basic plan of attack will be necessary under a variety of circumstances. The most common are those cases in which the tumor mass has visibly extended beyond the confines of such a dissection or in which vital structures that cannot be sacrificed pass through the field. The term "radical" has been applied to operations of this magnitude, which is misleading, for it implies that the surgeon exposes the patient to excessive risk. Any operation for cancer must be radical in the sense of being adequate for removal of the malignant process. To do less than adequate surgery under the misguided impression that it is the conservative approach is a tragic error. The use of the term "radical" as distinct from "conservative" dates back to the era when surgeons first timidly extended the limits of simple excision in the hope that some palliation would result. The present day emphasis in surgery for malignant disease is now placed on cure rather than palliation.

Judgment must be exercised in the selection of the proper therapy for the individual patient. Not every patient will survive the magnitude of the operations considered adequate. The preoperative investigation may uncover such serious coexistent

disease that surgery is out of the question. The patient must be evaluated not only in terms of the type, location and probable lymphatic spread of her lesion, but also in her age, general condition and ability to withstand the operation best suited to the extent of her disease. Other adequate forms of cancer therapy are available and must be seriously considered.

PRELIMINARY INVESTIGATION

The preoperative investigations, in addition to evaluating the patient as a surgical risk, attempt to map out the geographical extent of the cancer itself. They aim at the fundamental goal of reducing to a minimum the chance of unexpected features developing during the course of surgery. X-ray examination of the chest and skeleton for metastases is indicated. Cystoscopy, pyelography and barium study of the bowel should be performed whenever clinical evidence suggests possible involvement of these organs. The status of the heart and circulation must be determined. Blood counts and chemistries are of the utmost importance.

Once surgery is selected as the treatment of choice, the patient must be put in the best possible condition to withstand the operation. Transfusions should be given to correct anemia. Preoperative chemotherapy will tend to decrease the dangerous organisms in the area of operation.

There are a multitude of problems over and above the technical details of the actual operation. Of vital importance is the concept of a joint effort, a team act, which calls on the surgeon, nurses, assistants, anesthetists, consultants and the patient herself for sustained and skillful performance at the appropriate time.

A well trained anesthetist is an essential requirement. The ability to provide adequate relaxation is but a small part of the problem. Replacement of blood and fluid at proper intervals during the operation is of vital consequence.

Unless an adequate blood bank is available which is capable of turning out blood in quantity, the operation should be approached with trepidation. Though a number of bloods may be set up and available for use, a sudden demand at operation may exhaust the supply unless the laboratory is equipped to supply the loss at a moment's notice.

It is advisable to have a highly trained complement of resident staff and nurses available. The problems of postoperative care and the maintenance of an adequate electrolyte balance in these patients, many of whom are old and depleted, may tax the best physiological brains.

These problems have been emphasized to indicate that these procedures should not be undertaken without considerable

thought and understanding of the pitfalls such surgery may lead the patient into.

To be consistently successful the surgeon must be thoroughly indoctrinated in the basic principles of surgery for malignant disease and have a certain amount of training and experience. The success must be consistent, not sporadic. The ideal situation for the patient is found when a skilled team provides care in a modern, fully equipped hospital. But cancer neither respects geographical location nor considers the financial condition of the patient. Both may deprive the patient of treatment under ideal conditions. The extensive surgical training programs of the teaching centers today provide surgeons in every community who are potentially qualified to meet the problem.

In this section of the Atlas we have chosen not to discuss disease entities, nor do we wish to select the type of therapy when there is a choice. It is our purpose to provide a detailed road map for reference for the surgeon who has chosen the surgical approach and feels himself competent to operate for pelvic neoplasm.

The four basic operations described in this section serve to demonstrate the essential principle of en bloc removal in continuity of the primary growth together with the intervening lymphatics and regional nodes. Various combinations of the basic operations may be used for a variety of pelvic neoplasms. Alternate methods are outlined which permit staging of the procedures when age or general condition of the patient will not permit the excision in one operation. It should be noted that the sum of a series of staged procedures is always the equivalent of a block resection; each single operation must intentionally overlap the previous field of surgery. There is no place in the treatment of pelvic cancer for simple local excision of the affected organ supplemented by regional node dissection.

WERTHEIM HYSTERECTOMY WITH PELVIC LYMPHADENECTOMY

This operation is performed primarily for cancer of the cervix when the disease appears to be confined to the cervix itself or the immediately adjacent vaginal wall. The same operation has increasing vogue in the treatment of cancer of the endometrium.

The operation removes the contents of the pelvis from one obturator fossa to the other. The lymph nodes in the common iliac, hypogastric, external iliac and obturator areas are removed. The ureters are developed through their entire course from the bifurcation of the aorta to the entrance into the bladder. Complete mobilization of the bladder and ureters from the vagina is essential in order to include the bloc of lymphatic

tissue extending from the side wall of the pelvis to the paracervical and paravaginal area. The entire uterus, adnexa and this wide block of lymphatic tissue are removed in one piece together with a wide segment of vagina. The amount removed varies, but it is never less than 4 cm. and is always sufficient to include a large cuff of normal tissue below the lesion. It is not enough to remove the vaginal epithelium alone. The paravaginal lymphatics form a large part of the excised specimen. This is a most important part of the operation. It cannot be removed by a simple extension of the operation of total hysterectomy. We do not recommend removal of the uterus with subsequent dissection of the nodal areas. Performed as outlined, there is far less chance of leaving behind the important lymphatic pathways in and around the cervix and vagina.

In performing dissection of this magnitude the surgeon runs the risk of damage to the bladder floor and ureters. To remove less tissue in the desire to avoid ureterovaginal or vesicovaginal fistulae is to run the risk of recurrence of cancer. Atony of the bladder in the convalescent period is to be expected. This results from extensive resection of its nerve supply. Not to have some element of this complication suggests that an inadequate resection may have been done.

The best means of preventing urinary fistulae is a thorough knowledge of the anatomy of the area coupled with a dry surgical field. The individual vessels must be clamped and tied and the anatomy clearly displayed at every step. It will do no good to have the ureters catheterized prior to operation, for the problem is not in finding the ureters, but rather in handling them with gentleness in order to preserve the blood supply. The ureter is left in intimate contact with the peritoneum in its upper reaches at the level of the internal iliac artery. The point of greatest danger is where the ureter passes through a compartment just prior to its entry into the bladder. Numerous thin-walled veins lie both above and below the ureter at this point. Much of this bleeding will be reduced by securing the uterine vein at its junction with the internal iliac. Since the vein lies much deeper than the artery and runs a more lateral course, the uterine vein will not be in close apposition to the uterine artery, but comes in at an angle below and about 1 inch away from it.

Even after this compartment has been developed considerable ureter remains to be dissected free from the underlying paravaginal lymphatics. In doing so the ureter must not be stripped too cleanly and its blood supply damaged. The bladder also must be separated from the tissue to be removed, and care must be taken to see that its wall is not so thinned out that necrosis produces a fistula in the convalescent phase.

The dissection is not an easy one, but complications will be minimized by careful attention to all details.

MILES RESECTION FOR CANCER OF THE RECTUM

The one-stage abdominoperineal operation popularized by Miles also adheres to the precept of block resection. Many of

the low rectal lesions involve the posterior wall of the vagina or uterus. Conversely, primary genital neoplasms may invade the rectum. Since all are low-lying lesions, the possibility of spread to the regional nodes and fascia overlying the levators is such that anything short of wide removal would be inadequate. By combining the perineal resection with the abdominal dissection a more complete excision of potential tumor-bearing tissue is possible.

Moreover, the abdominoperineal resection of the rectum may be combined with other procedures to permit adequate excision of lesions even more advanced.

Technically, it is well to remember in the combined operation to do as much as possible through the abdominal incision. The landmarks are more apparent, and the relationship of the rectum to other structures is under direct vision. The ureters, for example, must be identified by exposing them. The patient should come to operation with an indwelling catheter in place. With adequate exposure the surgeon can determine whether the rectal growth has invaded the posterior wall of the vagina or uterus to the point where they must be included with the specimen. The surgeon should be cautioned against traumatizing the sacral veins as he inserts his hand behind the bowel to gently elevate it from the hollow of the sacrum. With minimal trauma these vessels bleed prodigiously and are difficult to control.

The umbilicus is customarily excised in the interests of subsequent cleanliness. The end colostomy is brought out through the midline incision, where it lies most comfortably. If the surgeon elects, he may lead the colostomy out through a stab wound.

At the end of this extensive procedure the patient must be placed in the lithotomy position. In an older patient this may be a shocking experience and is one of the reasons why as much of the dissection as is possible should be carried out from the abdominal side. The perineal stage should be done as expeditiously and bloodlessly as possible, clamping and ligating the vessels encountered and excising the levator and coccygeus muscles.

BILATERAL SUPERFICIAL GROIN DISSECTION AND VULVECTOMY

Ideal surgery calls for resection of the nodes in the superficial inguinal and femoral areas together with vulvectomy. In this operation all the fat and lymph nodes are excised from one anterior-superior spine to the other, leaving the external oblique fascia clear. The dissection then passes down over Poupart's ligament to remove the contents of the femoral triangles as far down the leg as the adductor canal. The saphenous vein is identified and divided on the medial thigh at this level. The dissection passes upward along the femoral vessels to the point of junction of the saphenous with the femoral vein. The mass of tissue is mobilized medially until there remain two large pads of fat still attached to the vulva like the wings of a butterfly. The vulva is then excised with the patient in the lithotomy position. The excision stresses adequate removal of skin rather

than plastic closure. The mons veneris, clitoris, labia majora and minora are all excised with generous margins of skin. In extensive growths it may be necessary to include wider portions of the vagina and urethra.

Many types of incision are in common use for removal of the superficial inguinal and femoral nodes. So much undermining of the wound and excision of fat- and lymph-bearing tissue is required in the dissection that the wounds not only tend to collect serum, but also break down in the healing process. Sepsis and necrosis of skin edges is a common complication. This is true whether the dead space is obliterated by pressure dressings or the groins immobilized by spica bandages or even casts. The ideal incision has not yet been developed.

The curved incision has avoided many of these unpleasant complications. A greater degree of success will follow if the lower portions of the arc of the incision are made to follow the crease of the groin rather than higher up on the abdomen. Where necrosis of the skin edge appears it tends to be in the midline over the symphysis away from the femoral vessels. If necessary, grafts can be applied early on a firm base rather than delayed until a protecting layer of granulations has developed over the region of the vessels. The postoperative edema and accumulation of lymph are minimal.

The operation designed to extirpate the lymph nodes in the external iliac, hypogastric and obturator areas is described immediately following. It can be added to the superficial groin dissection as part of the initial attack, or it can be done at a later date. Adequate therapy will not have been offered the patient until the deep pelvic nodes have been removed bilaterally.

EXTRAPERITONEAL NODE DISSECTION

Dissection of the regional nodes above Poupart's ligament is an essential part of the successful management of many forms of malignant disease in the pelvis. The nodes may be removed either transabdominally as in the pelvic lymphadenectomy for cancer of the cervix or by the extraperitoneal approach. We believe that the latter method is safer and has a wider field of application than the same dissection from within the abdomen. Age and obesity are no contraindication.

The extraperitoneal dissection may be used even when the surgeon has elected to treat the primary lesion by radiation as in carcinoma of the cervix, urethra or vagina. The extraperitoneal dissection allows the surgeon complete freedom to do a clean removal of the nodes and lymphatic pathways while still preserving the inguinal ligament.

The key to the exposure is the location of the deep epigastric vessels lying just medial to the point where the round ligament leaves the groin to enter the peritoneal cavity. After dividing the internal oblique muscle, leaving a cuff of muscle attached to Poupart's ligament for ease in closure, the deep epigastric artery and vein are exposed, divided and ligated at their point of origin from the external iliac artery and vein lying directly beneath. The peritoneum can then be separated from

the underlying space and advanced upward in a completely bloodless field without danger of entering the abdominal cavity. The extent of the retroperitoneal exposure is limited only by the length of the skin incision as it is extended upward. The ureter can be seen lying on the under surface of the peritoneum along the medial border of the exposed field. The area to be dissected lies directly beneath under direct vision, thus making the dissection relatively simple.

To be complete, the nodes must be dissected high up along the lateral border of the common iliac artery and include, not only the primary chain of nodes along the external iliac, but those of the intermediate chain lying between the vein and the artery. Nodes are commonly encountered on the under surface of the external iliac vein and in the obturator fossa lying between the vein and the obturator nerve, which runs diagonally across the area to be dissected. If the nodes appear to involve the external iliac vein or obturator nerve, one or the other, or both, may be resected with the specimen. In most instances involved nodes which appear to be densely adherent to the vessels can be dissected free once the sheath surrounding the vessels has been entered and a plane of cleavage established. It is rarely necessary to carry the dissection deep into the hollow of the pelvis below the level of the obturator nerve. The likelihood of nodal involvement is minimal, and the extensive plexus of veins representing the multiple branches of the internal iliac vein makes this area a troublesome and dangerous one from the

viewpoint of massive hemorrhage. For the same reason the dissection is not carried medially beyond the point of origin of the terminal branches of the hypogastric (internal iliac) artery. It is not necessary in lesions primary in the vulva and perineum, and is within the field of radiation when the operation follows extensive radiation for carcinoma of the cervix.

ALTERNATE METHODS OF MANAGEMENT

Many of the primary lesions are formidable in extent when first seen. In a poor risk patient with an extensive local growth the surgeon may elect to perform a radical vulvectomy and postpone the attack on the nodes for an arbitrary period of time to see whether any recurrence develops at the primary site.

Radical Vulvectomy

The entire vulva must always be removed. There is no place for local excision or hemivulvectomy. The dissection includes both labia, wide margins of normal skin and subcutaneous fat down to the underlying fascia, the entire mons veneris and the clitoris. The amount of skin removed should not be influenced by the possibility of primary closure. An excellent result will follow in time if the wound is left wide open. The dissection should be carried out laterally to remove as much as possible of the lymphatics intervening between the primary growth and the superficial inguinal nodes. The disease rarely extends up the vaginal canal, but in extensive growths that involve the

urethra it is possible to excise all but 1/2 inch of the urethra at the base of the bladder without producing incontinence. Enough of the vaginal canal must then be removed to provide adequate margins to the growth. If the skin can be approximated, it should be done loosely; if not, the wound should be permitted to granulate.

Unilateral Groin Dissection

After healing of the radical vulvectomy the deep and superficial nodes may be removed on the involved side as the second stage in the move toward the complete operation.

The exposure is made through a linear incision following the course of the femoral vessels and extending above Poupart's ligament. The lymphatic pathways intervening between the previous radical vulvectomy and the nodes in the superficial inguinal and femoral areas must be removed, in keeping with the basic concept previously outlined.

The actual dissections follow those previously outlined for the removal of both superficial and deep nodes. Skin necrosis in the midportion of the wound is a common complication and frequently delays the surgical attack on the nodes of the opposite groin.

Since the sum of the staged operations must add up to a complete bilateral removal of the regional nodes and intervening lymphatics as well as the primary growth, the dissection of the groin must be carried out on both sides.

COMBINATIONS OF OPERATIONS FOR CANCER

Throughout this Atlas the emphasis has been concentrated on procedures designed to win specific goals, with little mention of the disease processes encountered. This statement applies equally well to this section on operations for cancer. Each one described is designed to extirpate a sector of the pelvic organs with due consideration given to the behavior of malignant disease as we understand it. Two or more procedures may be combined simultaneously or segments may be extracted, depending on the extent of the disease process or particular situation encountered. For example, the urologic surgeons combine transabdominal pelvic lymphadenectomy with total cystectomy and uretero-intestinal implantation. On the other hand, many surgeons perform abdominal lymphadenectomy as a single procedure in conjunction with radiation therapy for cancer of the cervix. The operation has been described in this Atlas with the radical Wertheim extirpation of the uterus. The actual steps of the operation are the same whether the procedure is carried out singly or in conjunction with removal of other pelvic organs. To describe each operation in full would simply result in repetition of plates already included. The exenteration operations, so-called, represent the ultimate in en bloc excision for cancer of the female pelvic organs.

EXENTERATION PROCEDURES

The removal in one stage of the pelvic lymph nodes, uterus, vagina, bladder and rectum with diversion of the urinary stream by transplant of the ureters either into a colostomy or to the surface of the skin is a formidable surgical procedure. This operation is called total exenteration, to distinguish it from the anterior or posterior exenteration in which the surgeon chooses to spare either rectum or bladder.

No attempt has been made in this Atlas to illustrate the technical steps of these long and complicated combination operations, in part because of the repetition in plates previously described, but chiefly because the indications for such surgery are not clearly defined. These operations must be considered to be still in the experimental stages of development.

The operation should not be offered to all patients with advanced malignant disease in the pelvis, despite the fact that they have exhausted all hope of cure by traditional methods of therapy. The selection must take into account age, general condition, extent of the malignant process and its possible spread, as well as the patient's will to live and ability to adjust to her altered physiological state.

From the initial preoperative preparation to the final discharge from the hospital the successful management of these cases calls for intense concentration and labor on the part of the entire hospital staff. The patient depleted by cancer and sepsis, often with urinary function far below normal, is at best a poor surgical risk. The paragraphs on general considerations and preliminary investigations at the beginning of this section may be repeated with even greater emphasis when the exenteration operations are in prospect. No preparatory move is neglected which offers a real improvement in the patients' chance to survive and escape complications. These heroic procedures are truly elective. The sights should be set on possible cure, not palliation.

The principles of good surgery will apply here as elsewhere. Anatomical dissection under direct vision with blood vessels controlled as they are met will keep technical problems at a minimum. When all pelvic viscera are to be removed, there will be no structures to prevent a true resection en bloc, including the hypogastric artery and vein and the levator ani muscles all in continuity.

The procedure is a formidable one and should not be undertaken lightly.

**WERTHEIM HYSTERECTOMY
WITH BILATERAL
PELVIC LYMPHADENECTOMY**

The dissection required in the Wertheim hysterectomy demands that the surgeon familiarize himself with the detailed anatomy of the area in which he will work. It is a cardinal principle that each step be carried out under direct vision in a field unobscured by blood and unencumbered by clamps. The surgeon should be able to anticipate where each structure will normally lie in order to develop it without injury. This applies to the major vessels and their branches as well as to the ureters, bladder and rectum.

INSET A. This anatomical drawing shows the major blood supply in the area to be dissected in relation to the structures to be preserved—that is, the ureters, bladder and rectum.

FIGURE 1. A long left paramedian incision is used.

FIGURE 2. Since damage to the ureter may occur at the point where the ureter crosses the common iliac artery, it must be identified at this point and the peritoneum incised lateral to its downward course.

FIGURE 3. The ureter lies on the medial peritoneal flap. If stay sutures are placed on the peritoneal edges, and the long ends clamped and permitted to hang outside the abdomen, the operating field can be kept exposed. The ovarian vessels are dissected free of the ureter and underlying common iliac artery. A Moynihan clamp is passed beneath the vessels and a catgut suture pulled through and tied under direct vision.

FIGURE 4. The vascular bundle is divided between this ligature and a Kelly clamp placed distal to it to control bleeding. A suture ligature reinforces the proximal stump, and a tie on the distal cut end of the vessels allows the Kelly clamp to be removed.

FIGURE 5. The uterus is now drawn toward the patient's head, and the bladder flap is developed as in the technique of total hysterectomy. The lateral incisions in the anterior bladder flap have been made. With the edges of the peritoneum held on tension the surgeon now divides the bridge of peritoneum between them.

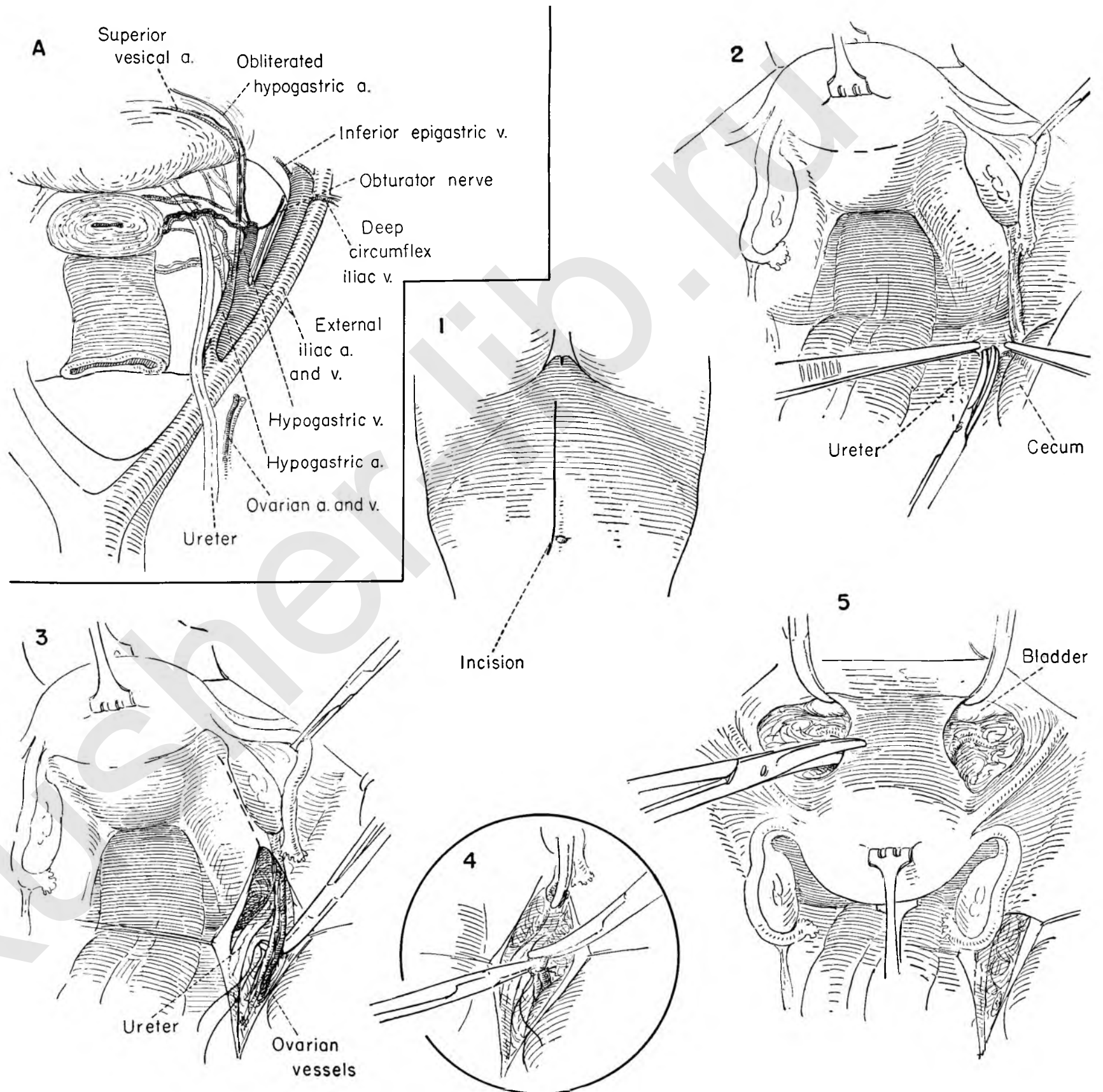


FIGURE 6. The uterus is held on tension and a stitch ligature placed on the round ligament far out laterally near the pelvic wall. The ends of the ligature are clamped and held on tension as the surgeon places another clamp medial to the ligature and divides the round ligament with a knife.

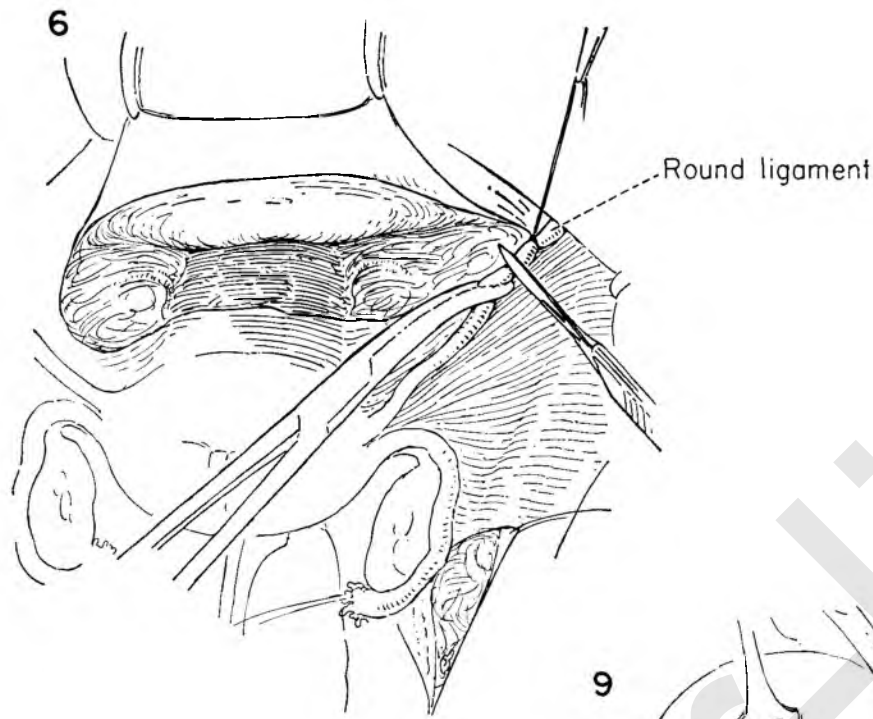


FIGURE 7. The uterus is drawn medially, and the cut ends of the round ligament are held upward. The surgeon then connects the upper and lower portions of the operating fields by incising the peritoneal bridge between them.

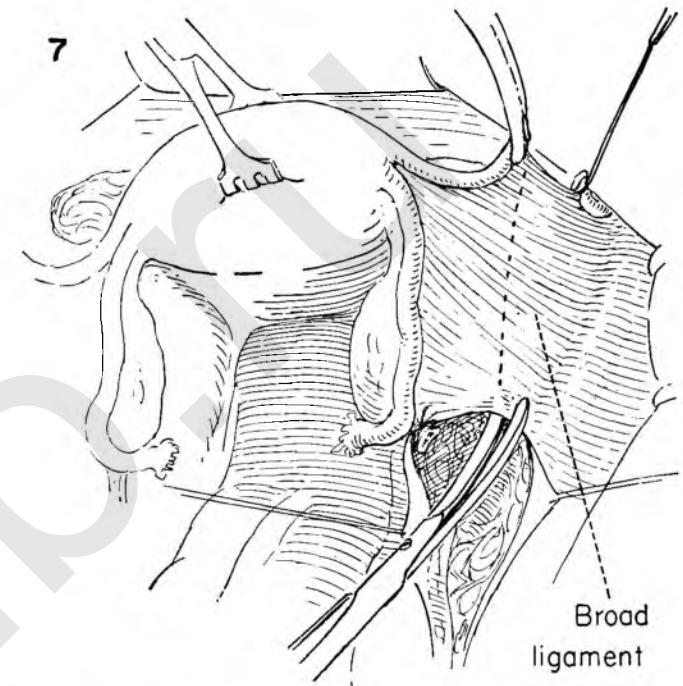


FIGURE 8. Additional stay sutures are placed on the lower edges of the peritoneal flap. The surgeon draws the uterus to the left with the tenaculum and the clamp on the round ligament. The junction of the external and internal iliac arteries can be seen lying in the fatty tissue which surrounds the vessels in this region. Note the proximal stump of the severed ovarian vessels in relation to the ureter as it lies on the medial peritoneal flap.

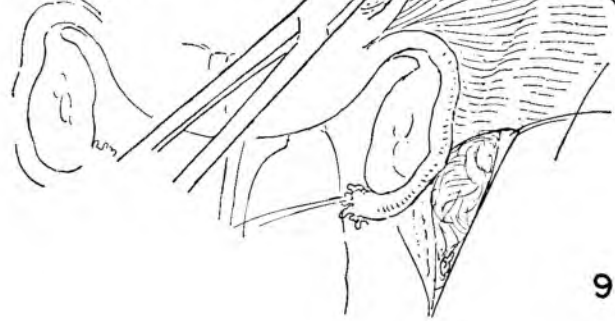


FIGURE 9. The uterus is drawn sharply to the left to provide exposure through tension. The assistant and the surgeon pick up the areolar tissue overlying the vessels. The dissection begins well lateral to the artery on the psoas muscle and, staying on the muscle, continues down along its medial surface to enter the upper portion of the obturator space. The genitofemoral nerve can be seen lying on the muscle. With care this nerve can be preserved. The dissection exposes the lateral and inferior surfaces of the external iliac vein. The aim of this dissection is to clean off the pelvic wall and mobilize all areolar tissue towards the midline.

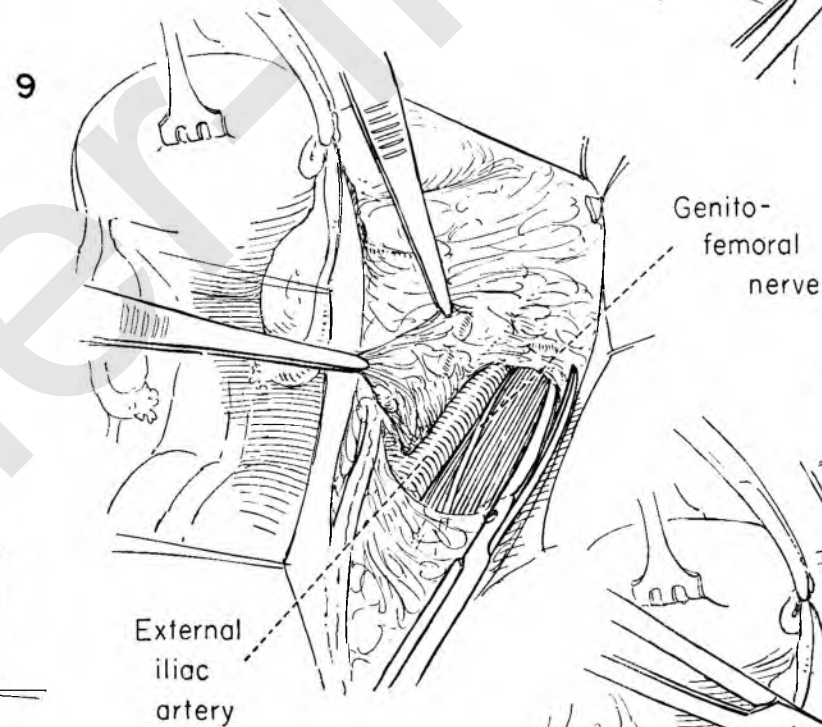


FIGURE 10. The fibrofatty mass is held on tension with forceps as the surgeon cleans it from the full circumference of the artery. The external iliac vein lies medial to and just below the artery. Any tissue lying between the inferior surface of the artery and the superior surface of the vein should be removed and the vein similarly completely exposed and stripped clean.

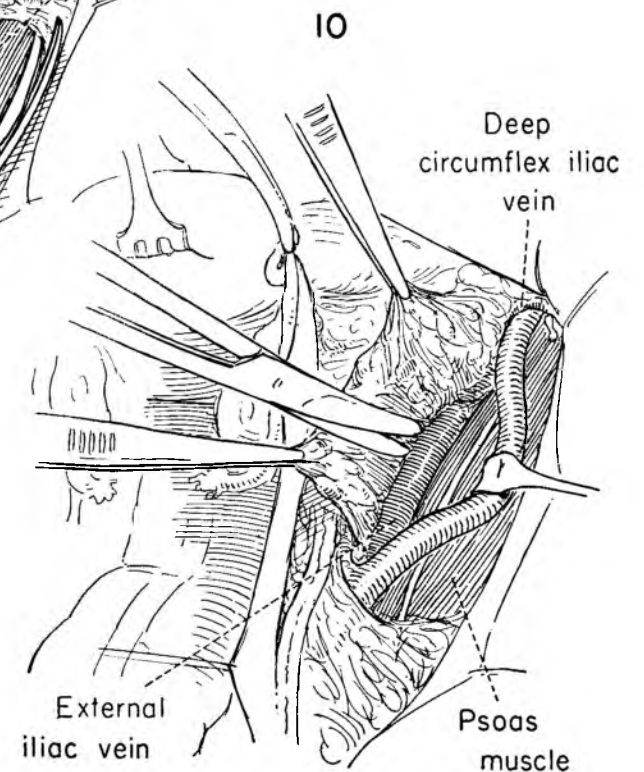
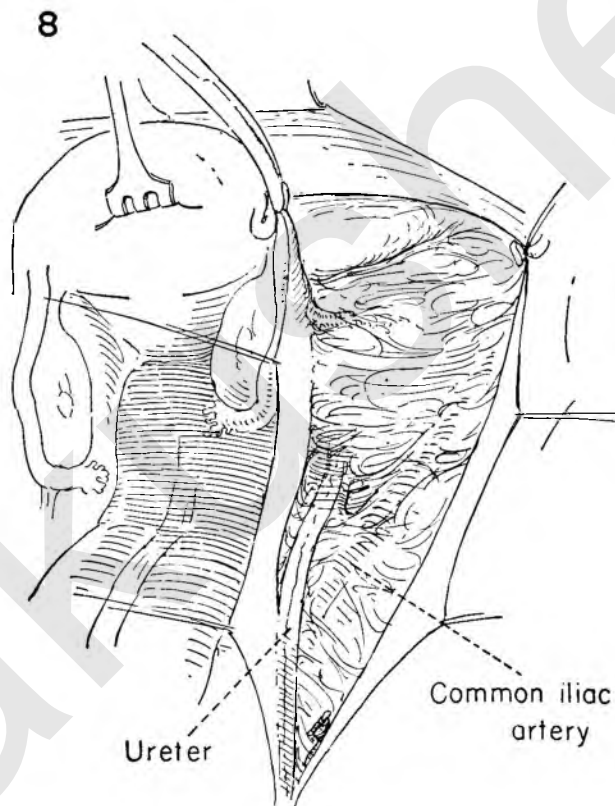


FIGURE 11. The common iliac lymph nodes lie anterior and lateral to the artery. It is expedient to transect the specimen at the iliac bifurcation and remove the node groups separately. This has the additional advantage of permitting separate pathologic study and more accurate localization of metastases if they are present. Dissection starts as it did lower down on the psoas muscle and advances medially. A Deaver retractor in the upper corner of the wound greatly facilitates exposure.

FIGURE 12. By holding the specimen firmly on tension, the vessels are easily stripped and the right common iliac vein exposed in the floor of the dissection. At the level of the vena cava the node mass is clamped and divided. The ureter must be seen and protected, since it will invariably be close by.

FIGURE 13. A small vein often emerges beneath the bifurcation of the iliac artery. This is exposed, clamped and cut.

FIGURE 14. The external iliac nodes can then further be freed from the medial side of the internal iliac vein, carrying the dissection downward deliberately to Poupart's ligament and exposing the inferior epigastric vessels.

FIGURE 15. This corner is now shown completely cleaned, exposing the pubic ramus. The external iliac node mass is removed by cutting along the inferior border of the vein.

FIGURE 16. The medial surface of the obturator and internal iliac node group is developed by dissection along the lateral aspect of the internal iliac artery and its branches.

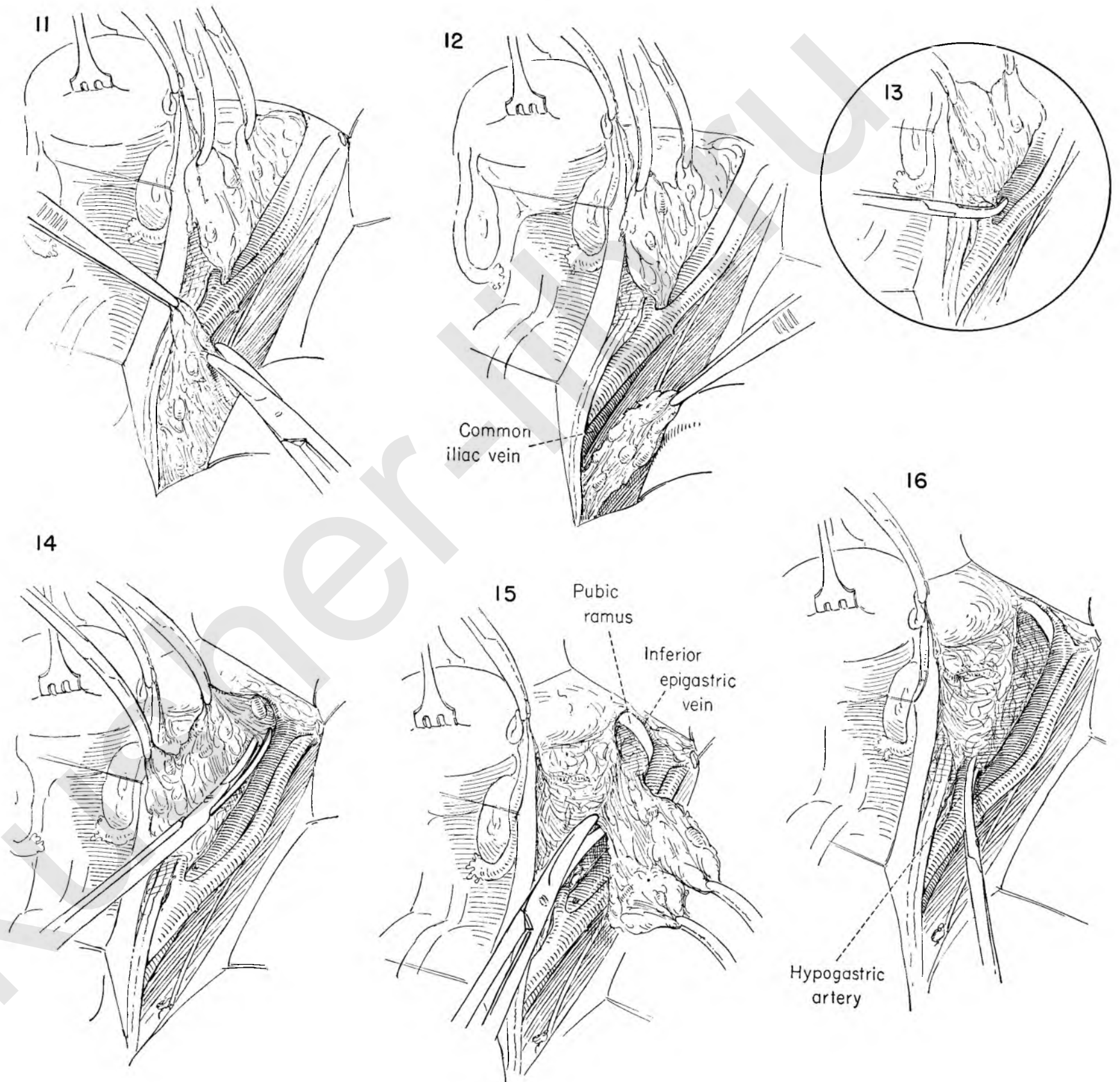


FIGURE 17. A small branch often joins the external iliac vein on its lower border. It should be looked for and clamped, cut and tied at this time.

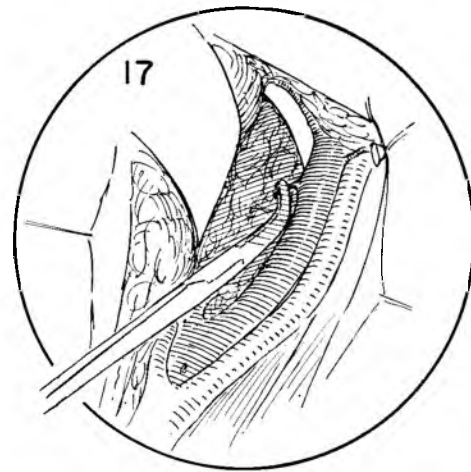


FIGURE 18. Exposure deep in this area is afforded by a retractor holding the bladder and internal iliac vessels medially. The obturator fossa is entered by following the under surface of the external iliac vein to the pelvic wall.

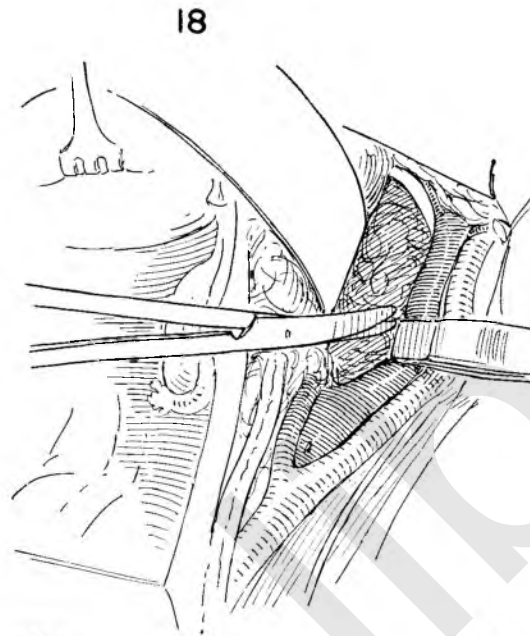


FIGURE 19. The vein and artery are gently held aside with the handle of a forceps and the lateral pelvic wall easily exposed with scissor dissection. Fat and nodes fall medially as one compact mass with the obturator nerve running through it and near the lateral surface. Small vessels are often present deep in this area, and troublesome oozing will result if they are damaged. Firm pressure usually suffices for control, though pumping arteries should be tied. If pressure is applied, the return flow through the external iliac vein must not be interfered with, since this can rapidly trap several liters of blood in the leg.

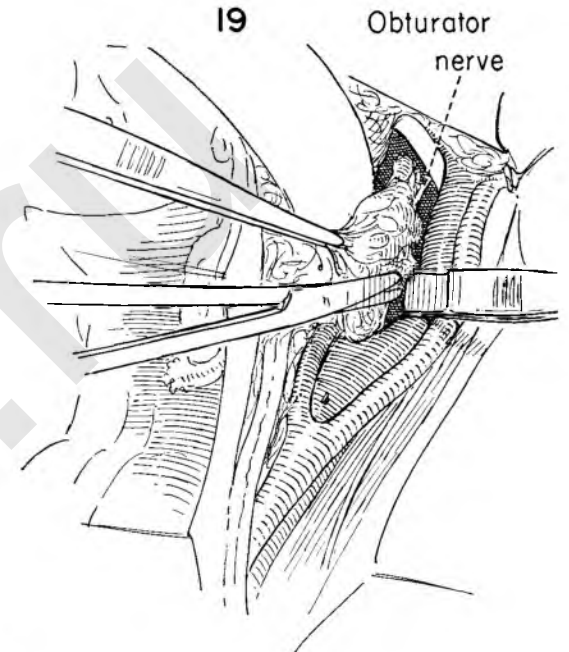


FIGURE 20. The obturator nerve is identified and spared. The obturator-internal iliac node mass is removed.

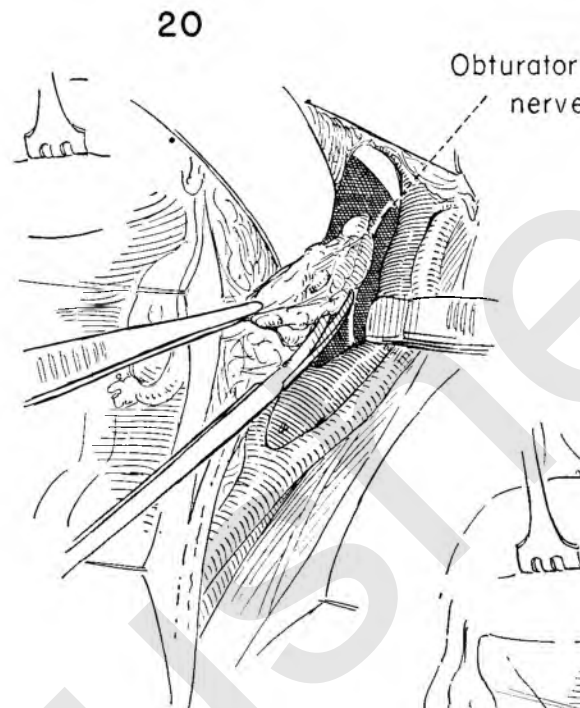


FIGURE 21. Attention returns to the internal iliac artery. It is freed on its medial aspect from the specimen and its branches exposed. Identification of the uterine artery, which usually arises from a common stalk with the superior vesical artery, often from an inferior and medial aspect, is much simplified if the surgeon will develop the pararectal space. This can be done by carrying the dissection downward into the areolar tissue lying between the ureter medially and the internal iliac artery laterally, staying along the side of the rectum. The uterine artery is a small vessel rarely more than 2 mm. in diameter and is strikingly redundant and tortuous. It must be identified with certainty before it is cut. The vesical branches are to be spared.

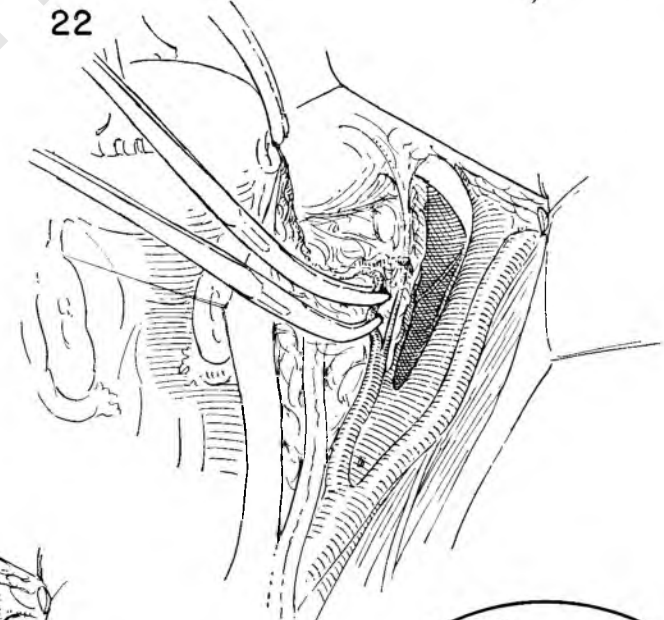


FIGURE 22. The uterine artery is then doubly clamped. The ureter is easily seen lying several centimeters medially.

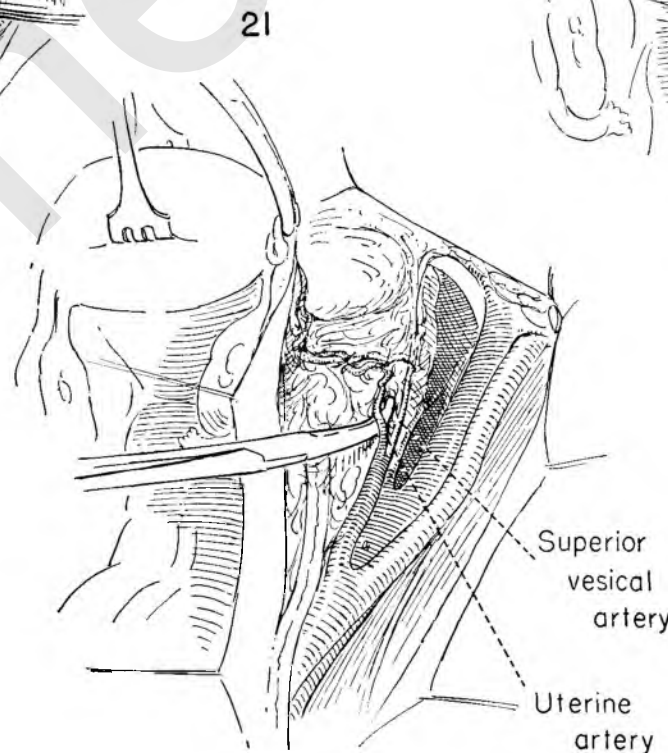


FIGURE 23. The artery has been divided, leaving a proximal cuff long enough to be secured with two ligatures.

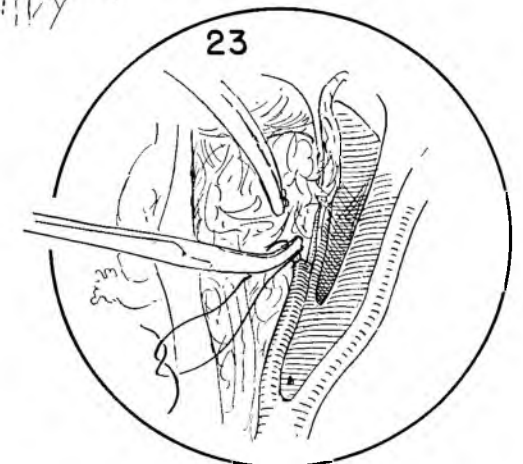


FIGURE 24. The uterine vein is identified at the point where it enters the internal iliac vein and freed upward by blunt dissection with a Moynihan clamp. It approaches the uterus at a sharp angle some distance below the uterine artery.

FIGURE 25. The vein is secured between clamps, cut and ligated.

FIGURE 26. The tissue lateral to the ureter and deep to the superior vesical artery is then separated by dissection as this artery is elevated with a Moynihan clamp. The dissection continues to the point where the vessels fan out on the surface of the bladder.

FIGURE 27. The entire pelvic dissection of the lymph nodes described in Figures 2 through 26 should now be carried out on the left side. To facilitate this the surgeon comes over to the right side of the operating table.

FIGURE 28. The dissection on the left side complete, the surgeon returns to his original position and begins to free the ureter from the peritoneum. A small artery which arises from the internal iliac, below the bifurcation, is identified as it joins the ureter. The ureter is then gently picked up distal to this artery and separated from the peritoneum and underlying tissue down to the point where it passes under the divided uterine vessels. It cannot be stripped too cleanly, for the intrinsic blood supply to the ureter will be jeopardized. The stumps of the uterine vessels are held up and the ureter is dissected free beneath them.

FIGURE 29. The uterus is held on traction towards the patient's head and the bladder elevated by two pairs of forceps as the surgeon dissects it from the anterior vaginal wall. The use of two pairs of forceps will allow the surgeon to stay on one plane in the dissection, thereby minimizing trauma to the bladder. The ureter is shown lying free in its upper portion, but entering a tunnel just before joining the bladder.

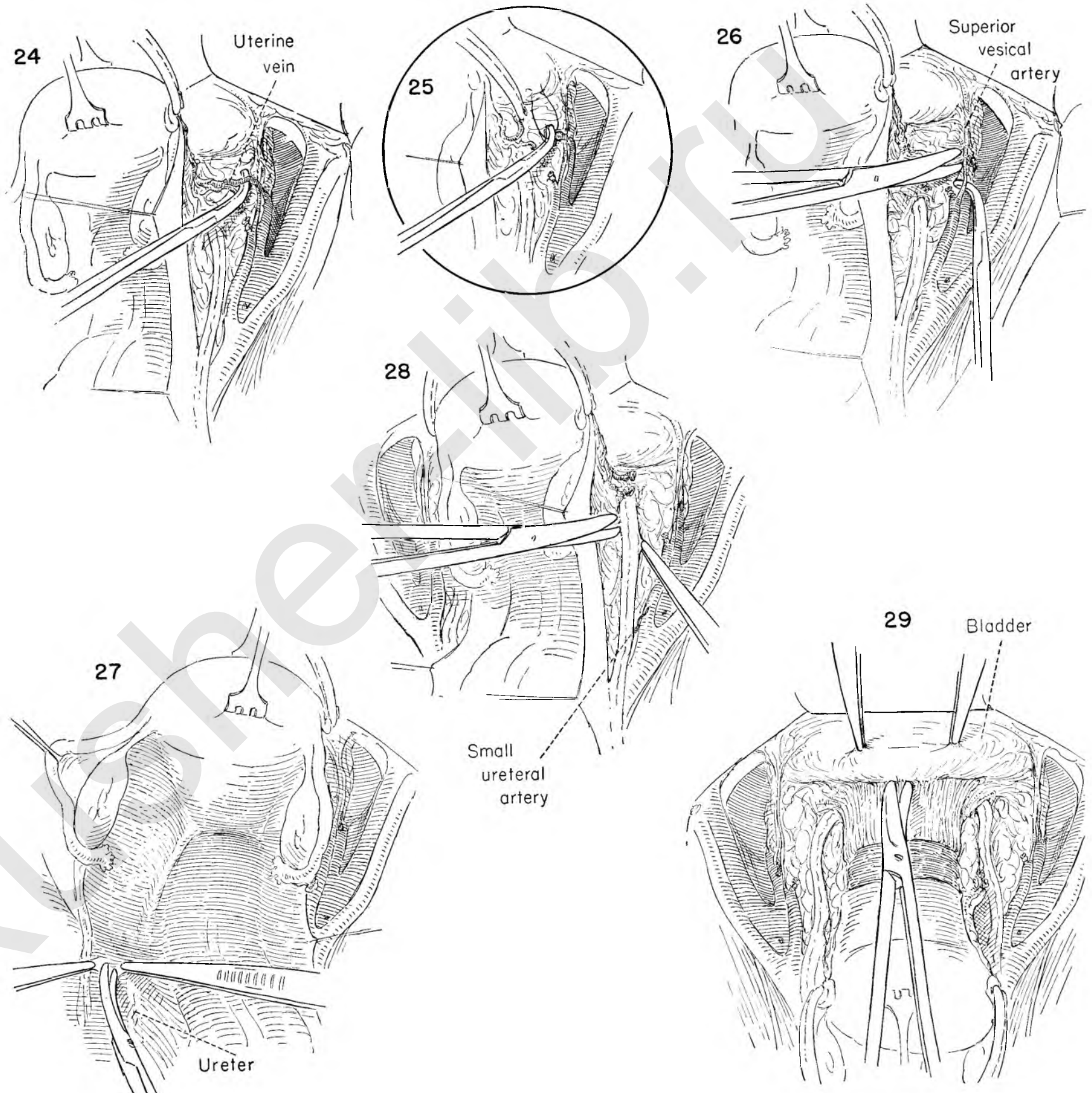


FIGURE 30. The lower end of the ureter lying along the anterior vaginal wall can be seen emerging from the canal. The ureter must be freed from this tunnel in order for the paracervical and paravaginal lymphatics to be removed. A plexus of vaginal veins lies above and below it. A clamp is first introduced under the vessels into the canal, gently freeing it from the ureter. Gentle upward traction on the ureter will keep it safe while the roof of the canal is divided between clamps.

FIGURE 31. The ureter is now completely freed from its bed and its junction with the bladder developed. Dissection continues in this plane until an adequate length of vagina and paravaginal tissue has been exposed.

FIGURE 32. Attention now turns to separating the rectum from the posterior vaginal wall. The uterus is held upward in the direction of the symphysis and the peritoneum placed on tension. As indicated by the dotted line, the peritoneum is excised from a point laterally, just distal to where the ureter has been dissected free from the peritoneal flap, continuing across the midline to the same point on the opposite side. The peritoneum of the entire pouch of Douglas comes with the specimen.

FIGURE 33. With the peritoneum held on tension by Kelly clamps the areolar attachments of the rectum to the posterior vaginal wall are dissected free. By placing the extended fingers of the left hand over a gauze pack on the upper rectum and exerting countertraction on the uterus the line of cleavage becomes obvious and the anterior rectal wall should be in no danger of perforation.

FIGURE 34. The dissection is carried downward until nearly two thirds of the vaginal wall is clear of the rectum. The posterior portion of the lateral web of tissue which contains the paravaginal lymphatics is now exposed at the point of attachment to the lateral pelvic wall. The entire dissection to this point has been designed to expose this block of tissue.

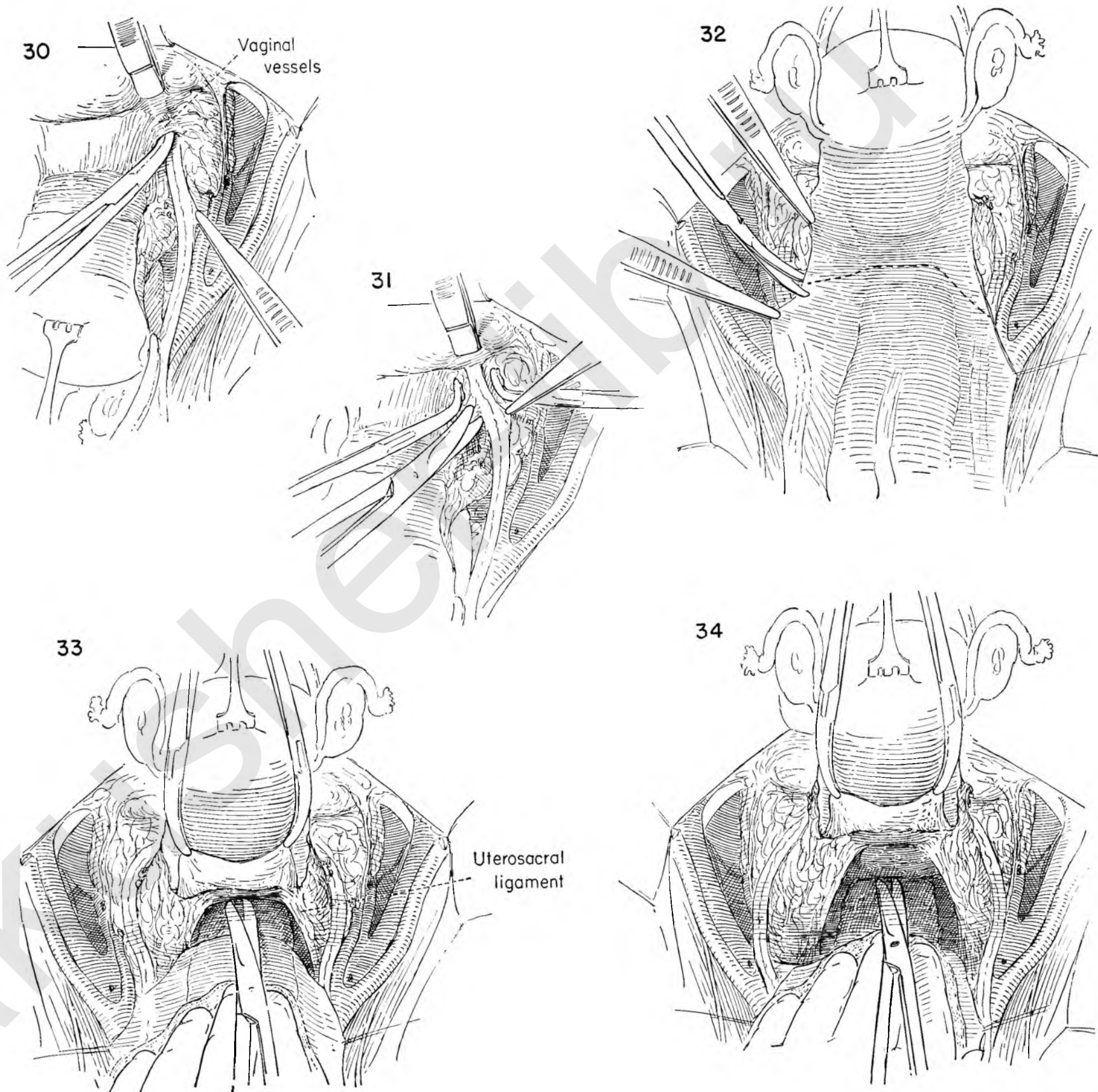


FIGURE 35. A large Moynihan clamp is placed on the most lateral extension of this web of tissue as the internal iliac artery and vein are retracted out of harm's way with the handle of the forceps held by the assistant. The tissue is then divided medial to the clamp.

FIGURE 36. The tissue included in the clamp is then secured by passing a stitch ligature around and beneath the clamp as the assistant protects the internal iliac artery and vein with the forceps handle.

FIGURE 37. The internal iliac artery and vein are again retracted as the second in a series of clamps is placed as far posterior and lateral as possible. This bite in turn is divided and secured with a stitch ligature.

FIGURE 38. The process is repeated on the other side until all posterior attachments to the pelvic wall have been freed. The ties on the divided tissue are seen below the internal iliac artery. The uterus, with the attached wings of paracervical and paravaginal lymphatics, has been drawn upward to show the extent of the dissection. The rectum is shown posteriorly completely free of the vaginal wall. The uterus is now attached only to the vagina and the anterior extensions of the lymphatic-bearing tissue.

FIGURE 39. To expose this anterolateral attachment, the uterus is drawn sharply back toward the promontory of the sacrum. The bladder and ureters are carefully elevated and the dissection begun beneath the bladder, freeing it laterally first on one side and then on the other.

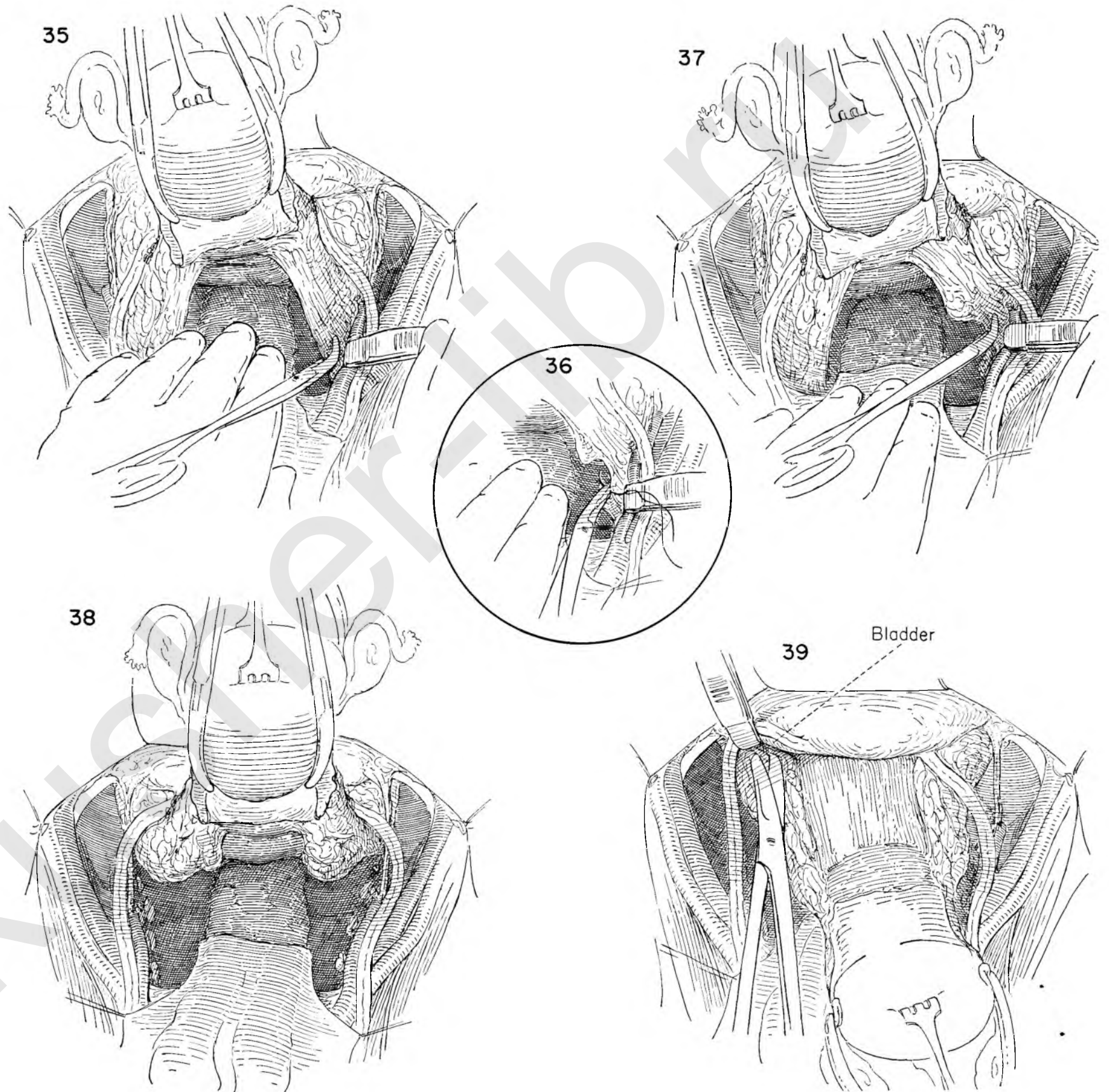


FIGURE 40. This is the most important area of the entire dissection. To avoid the risk of recurrence it is imperative that a wide block of tissue containing the paravaginal lymphatics be removed. An adequate amount cannot be removed unless the bladder and ureters are mobilized from the underlying tissues. This area contains many large veins. Elevation of the bladder and ureters permits the application of a large Moynihan clamp to the most lateral excursion of the paravaginal lymphatics.

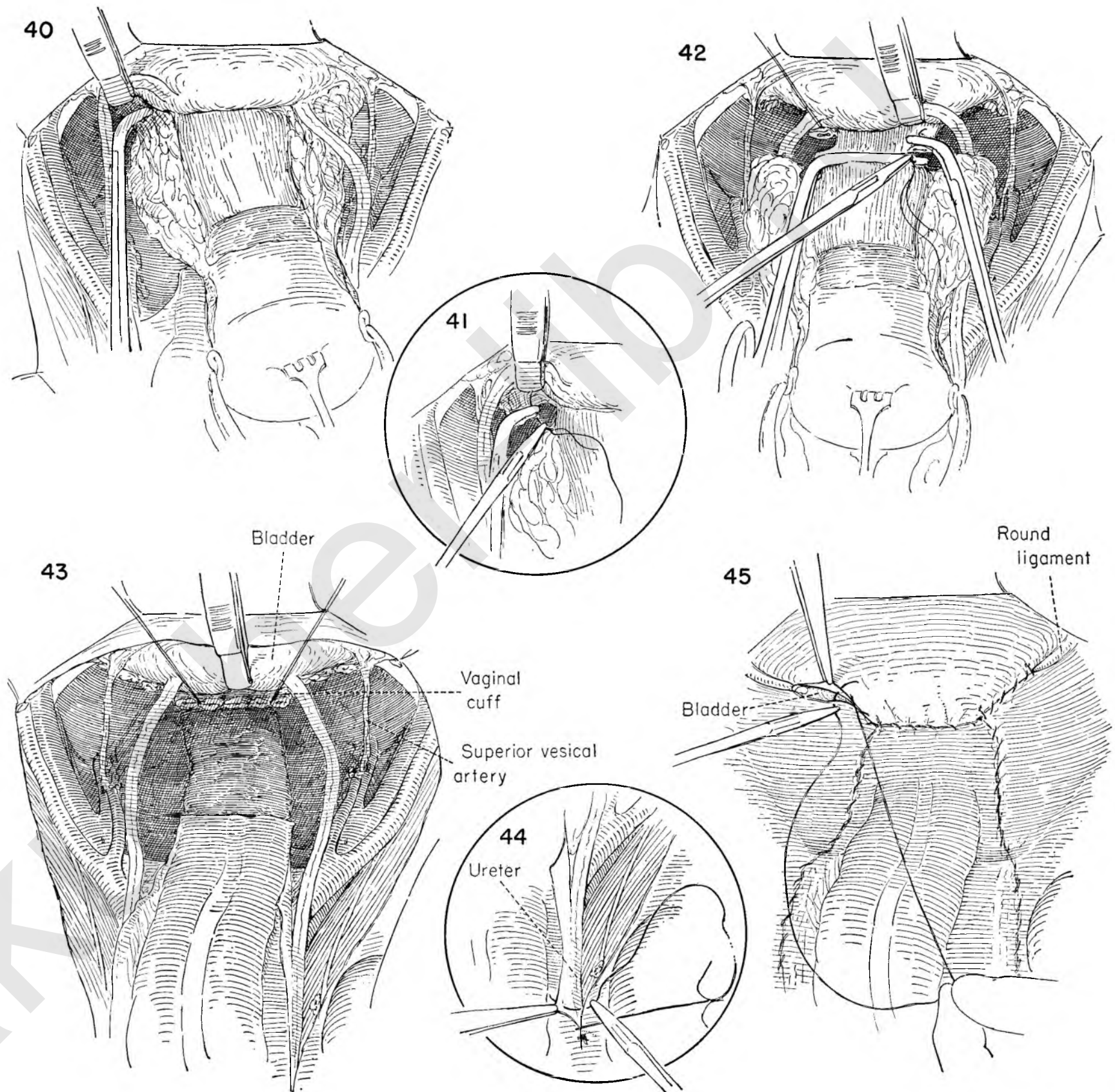
FIGURE 41. The ureterovesical portion of the bladder is elevated as the tissue held in the clamp is divided and a stitch ligature is placed around it.

FIGURE 42. The dissection has now reached the vaginal wall. The amount of vagina to be removed depends on the degree of vaginal extension. Approximately one half of the vagina should be excised in any event. The uterus is held on tension as a large right-angled clamp is placed across the vagina to prevent spillage of malignant cells as the vagina is transected. The bladder is retracted with the forceps handle as a Moynihan clamp is placed below the right-angled clamp at the vaginal corner. Successive applications of the clamp are made, and the tissue included is divided and secured with a stitch ligature after each bite.

FIGURE 43. The dissection is now complete. Note that both iliac areas and the obturator fossae have been stripped clean of all the intervening lymphatic tissue. The bladder and ureters lie mobile above the closed vaginal stump. A dissection less complete will be inadequate in the majority of cases.

FIGURE 44. The reperitonealization is begun at the upper end of the peritoneal incision beneath the cecum and continues as a running suture of catgut. Beware of including the ureter, for it lies attached to the under surface of the peritoneal flap.

FIGURE 45. The reperitonealization is nearly complete. The severed ends of the round ligament lie buried beneath the peritoneum. The closure is tailored to fit the circumstances; usually the angles will have to be closed separately.



COMBINED ABDOMINAL AND PERINEAL RESECTION OF THE RECTUM (MILES OPERATION)

This operation is designed to excise the anus, rectum and rectosigmoid colon together with its vessels and lymphatics and adjacent peritoneum and muscles. It is appropriate in cases in which cancer is primary in the lowest segment of the intestinal tract. The principles of en bloc resection and taking a wide margin of normal tissue everywhere around the growth should govern its performance. The exposure is best from above, and as much dissection as possible should be done through the abdominal incision.

FIGURE 1. A median lower abdominal incision is used. We shall illustrate a terminal sigmoid colostomy brought out through the incision; therefore, the umbilicus is excised to leave as smooth an abdominal surface as possible in the vicinity of the stoma.

FIGURE 2. The uterine fundus is held against the pubic symphysis with a traction suture. If the fallopian tube is in the way, it can be held aside without trauma by means of a Babcock clamp. The bowel is drawn forcibly upward by the assistant's left hand, exposing and putting tension on the peritoneal attachments between the sigmoid and the left iliac fossa. These attachments are cut.

FIGURE 3. This maneuver permits full mobilization of the free sigmoid loop. The point for future transection of the bowel is selected and the mesentery adjacent opened with the scissors. A site free of blood vessels is chosen for this.

FIGURE 4. The opening is carried through the full thickness of mesentery and a length of rubber wick passed through. The two ends of the wick are held in a clamp and provide a handle by which the bowel can be held firmly in any position. The lateral leaf of mesenteric peritoneum is then opened in a line parallel to the major vessels. When the parietal peritoneum is reached, the incision is continued around the inner surface of the pelvic basin an inch or so medial to the ureter and then down into the pouch of Douglas to the bottom.

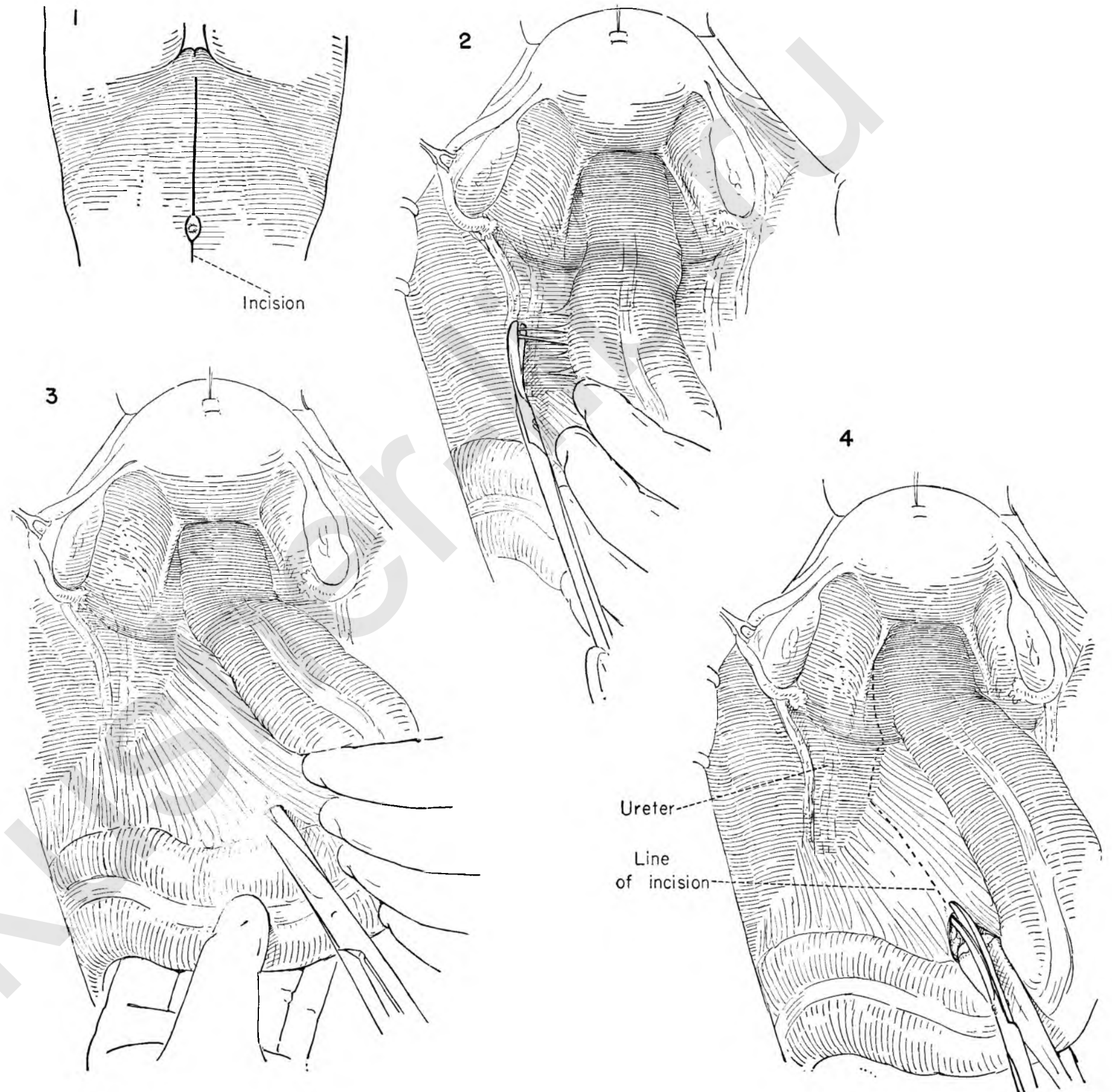


FIGURE 5. A similar incision is made in the peritoneum on the opposite side of the bowel. If the position of the ureter is in doubt, it is mandatory that one stop and identify it by palpation before proceeding.

FIGURE 6. This incision exposes the fat and vessels of the mesentery, which are most easily secured by cutting between parallel curved Kelly hemostats applied by the surgeon as the colon is held towards him. It is usually wise to stop and apply ligatures after each bite. The tissues are friable, and clamps will not hold under traction, particularly in the obese patient. If a clamp pulls away and the vessel retracts, the resultant hematoma in the mesentery may jeopardize the blood supply of the bowel.

FIGURE 7. The vessels and mesentery are separated right up to the bowel wall. A final small bite with straight hemostats is usually necessary to accomplish this.

FIGURE 8. At the base of the mesentery lying on the lumbar spine one finds the major blood supply, the superior hemorrhoidal vessels; usually these can be exposed and clamped by themselves.

FIGURE 9. A strong ligature properly tied secures the pedicle. Some surgeons will elect to use a second one also.

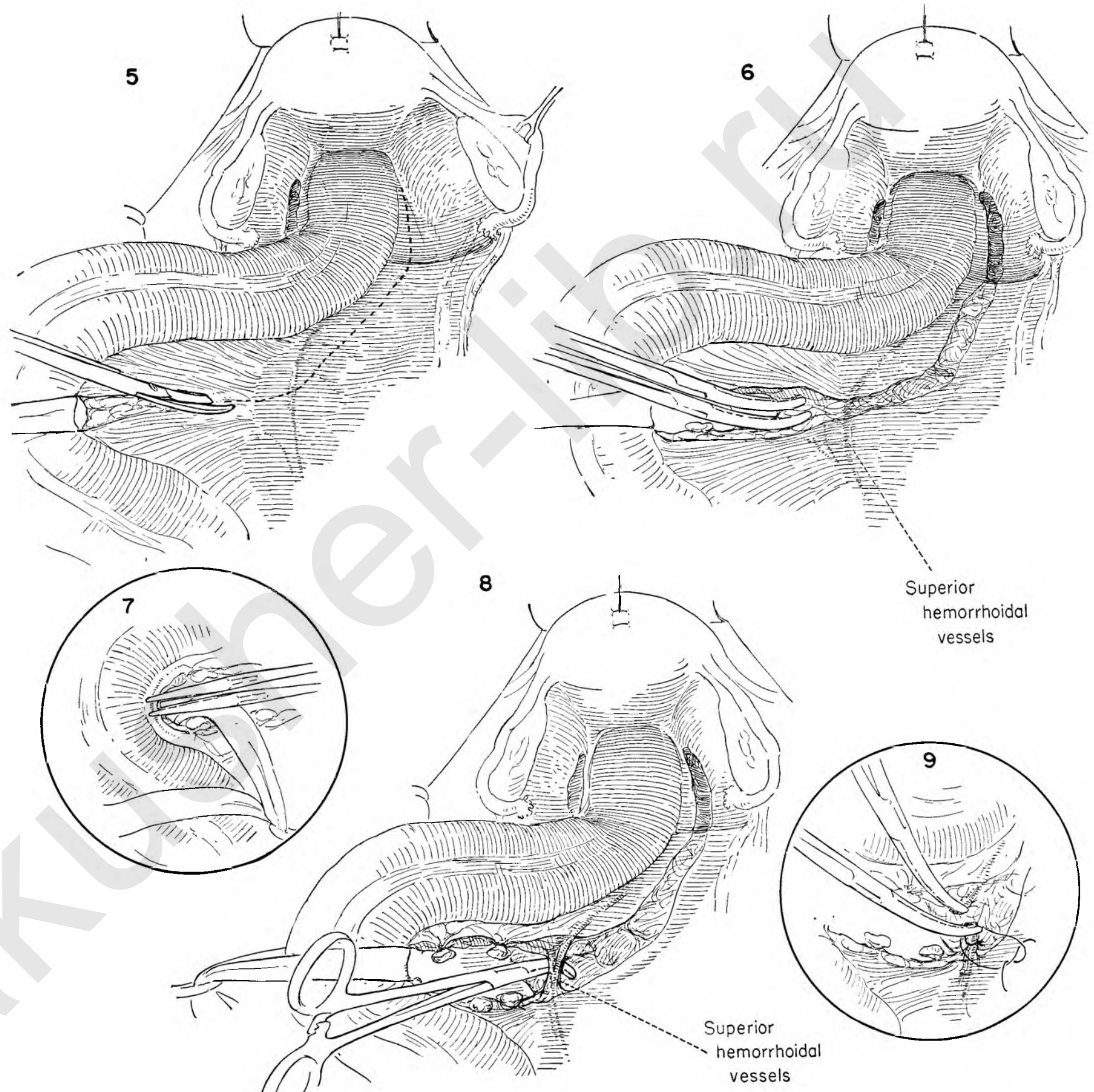


FIGURE 10. The bowel will now be found completely freed of all major posterior attachments. The operator's right hand is introduced into the space behind the rectum and easily advances along the anterior surface of the sacrum, freeing filmy avascular attachments. A ladder of veins lies on the sacrum superficial to the periosteum. These veins are thin walled and should be avoided, for a tear often results in copious bleeding which is difficult to control and obscures the field.

FIGURE 11. This dissection is carried to the tip of the coccyx and the levator muscles, permitting free elevation of the bowel and inspection of the depths of the pelvis. The contour of the sacrum with the patient supine is such that the angle of advance in the lower portion of the field is actually obliquely forward and upward.

FIGURE 12. The bowel is again drawn firmly upward and against the vertebrae, the uterus held toward the symphysis on tension, and the peritoneum incised anterior to the rectum in the fold between bowel and vagina, joining the two lateral peritoneal openings.

FIGURE 13. Dissection with the scissors is continued downward in a bloodless plane between the rectum and the posterior vagina. Here also the advance is noted gradually to angle obliquely forward and upward.

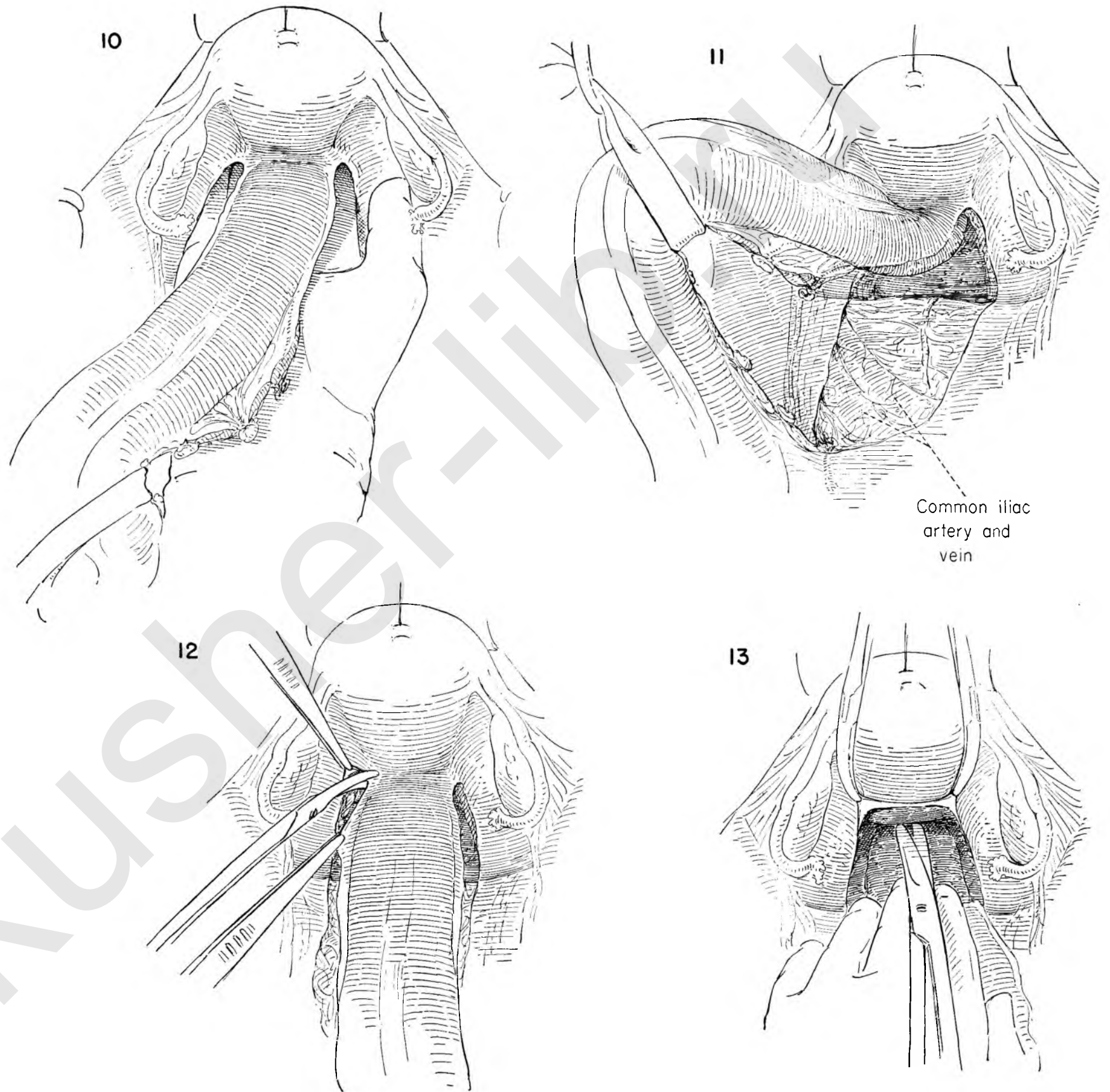


FIGURE 14. With the bowel freed in front and behind, an obvious vascular attachment is demonstrated on either side. In these attachments run the middle hemorrhoidal vessels. The lateral peritoneum and the ureter adherent to its under surface are gently freed and displaced laterally to a position of safety, and the vascular pedicle is secured as close to the pelvic wall as possible between clamps.

FIGURE 15. Suture ligatures replace both clamps. The same procedures are carried out on the left side.

FIGURE 16. With long-handled scissors the sides of the bowel are now easily dissected free of the pelvis. This maneuver is carried down around the full circumference of the rectum to the levator muscles. This completes the dissection from above.

FIGURE 17. Kocher clamps are now applied across the bowel at the point selected for transection.

FIGURE 18. Adjacent tissues are protected with moist gauze and the bowel cut with a cautery.

FIGURE 19. The distal cut end is to be buried beneath the pelvic peritoneum temporarily, and the clamp must therefore be removed. A running suture of catgut on an atraumatic needle is started at one end of the clamp and carried back and forth along the clamp, taking alternate bites on either side of it.

FIGURE 20. The ends of this suture are held on tension in the axis of the clamp as it is withdrawn. It is usually necessary to open the jaws momentarily to free them from the bowel before doing this. The crushed end of the bowel will be inverted beneath opposing serous surfaces as the basting stitch is tightened.

FIGURE 21. The same suture is then used to put in a second running row of stitches which ends at the point of origin, and the two ends of the suture are tied together.

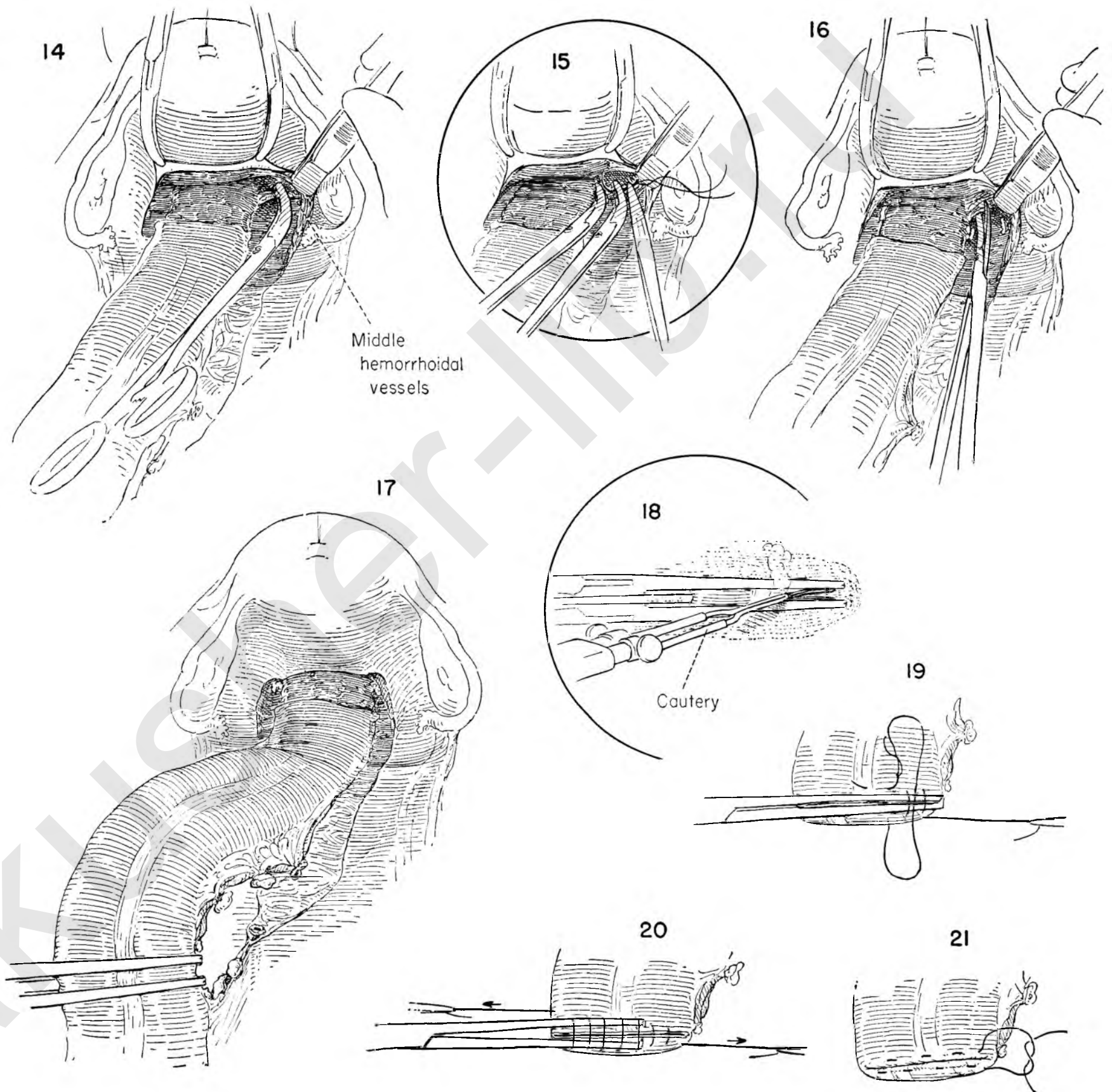


FIGURE 22. The distal segment of bowel is pushed downward into the cavity produced by previous dissection. A new pelvic peritoneal floor is to be made, and the lateral peritoneal edges must be freed sufficiently to come together without tension. This is accomplished with scissor dissection under direct vision, keeping the ureter always in sight and freeing it sufficiently so that it will tend to remain in its natural course.

FIGURE 23. The peritoneum is closed with a running suture, starting at the root of the sigmoid mesentery near the point of ligation of the superior hemorrhoidal vessels. This closure is continued downwards to the point where tension develops. The suture is then tied and the remaining gap closed transversely with a second running catgut stitch.

FIGURE 24. Postoperative prolapse of small bowel down the left gutter is undesirable. The gutter is closed by approximating the edge of the sigmoid mesentery to the parietal peritoneum with multiple interrupted stitches. The point of emergence of the bowel through the incision is first determined. It is that point where the intestine lies most comfortably without tension or angulation. Care is exercised to ensure that the bowel is not rotated as it is fixed in position.

FIGURE 25. One plans the operation to leave about an inch of bowel external to the abdominal wall. The wound is closed in layers around the sigmoid, leaving an opening that admits one finger snugly next to the bowel. The wound above and below is closed separately, starting with running catgut sutures in the peritoneum.

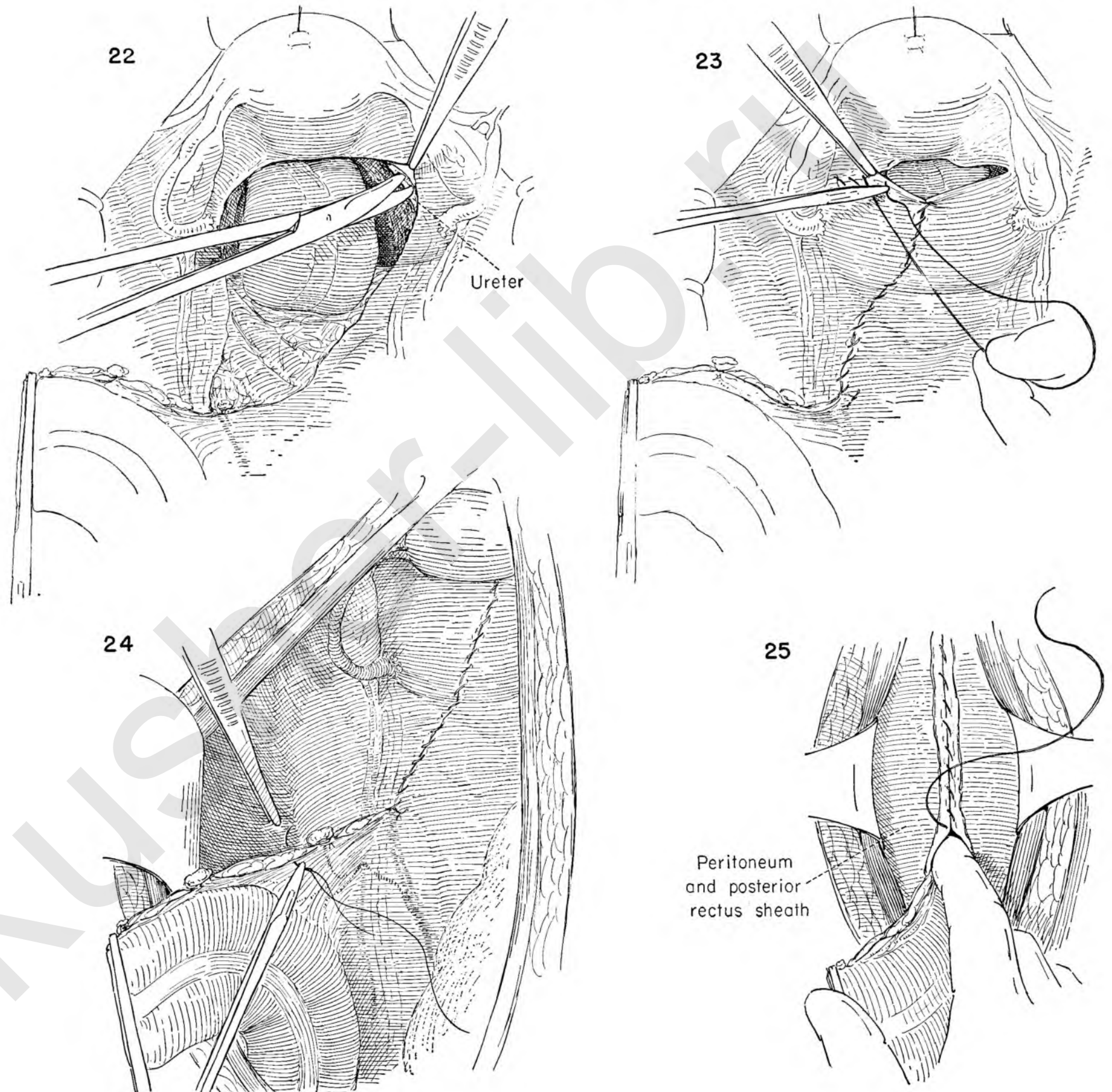


FIGURE 26. The anterior rectus sheath is approximated with interrupted stitches.

FIGURE 27. The superficial fascia and skin layers have been closed. The use of heavy retention sutures is optional. If they are loosely tied, they will not separate and will obliterate dead space in the wound. A gauze sponge is loosely wrapped around the exposed inch of bowel and a dressing applied with the Kocher clamp still in place. It should be supported on gauze and separately fixed to the abdomen with adhesive tape to prevent accidental dislodgment.

Moving the patient into position for the perineal stage may precipitate some degree of vascular collapse in one who is not a good risk or in whom the abdominal procedure has been prolonged or bloody. The lithotomy position entails the least change and is preferred.

FIGURE 28. The perineum is prepared and draped. An elliptical incision is made through the skin around the anus and dissected sufficiently free to permit closure.

FIGURE 29. The skin ellipse is folded on itself and closed over the anus. The ends of this suture may be left long and held in a clamp to provide traction on the bowel.

FIGURE 30. Knife dissection is carried down through the subcutaneous fat, clamping, cutting and tying vessels as they are met.

FIGURE 31. The levator muscle on both sides is exposed.

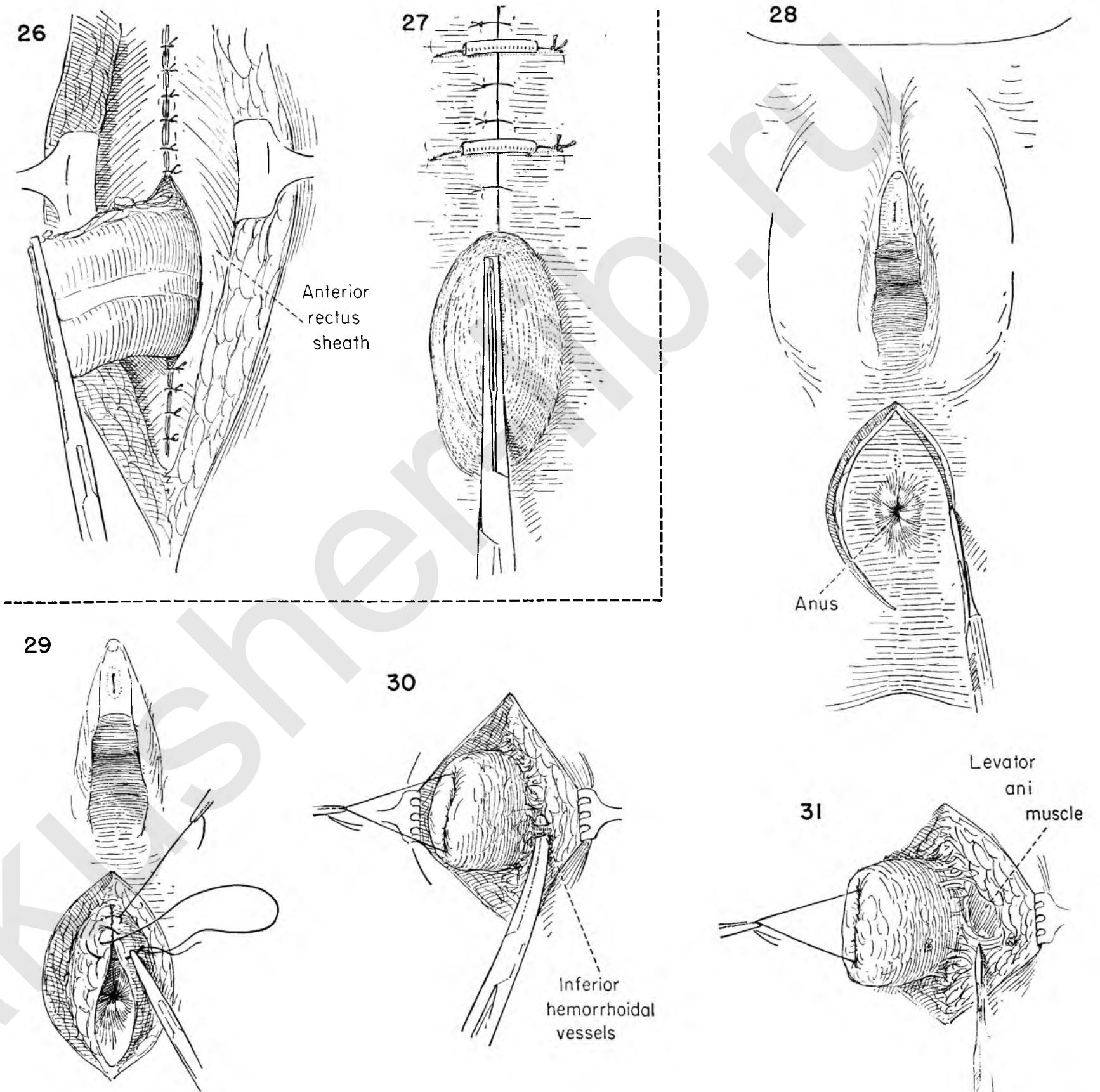


FIGURE 32. The bowel is drawn toward the symphysis and the tip of the coccyx identified. A strong fascial attachment, the anococcygeal body, is cut across at the end of the spine.

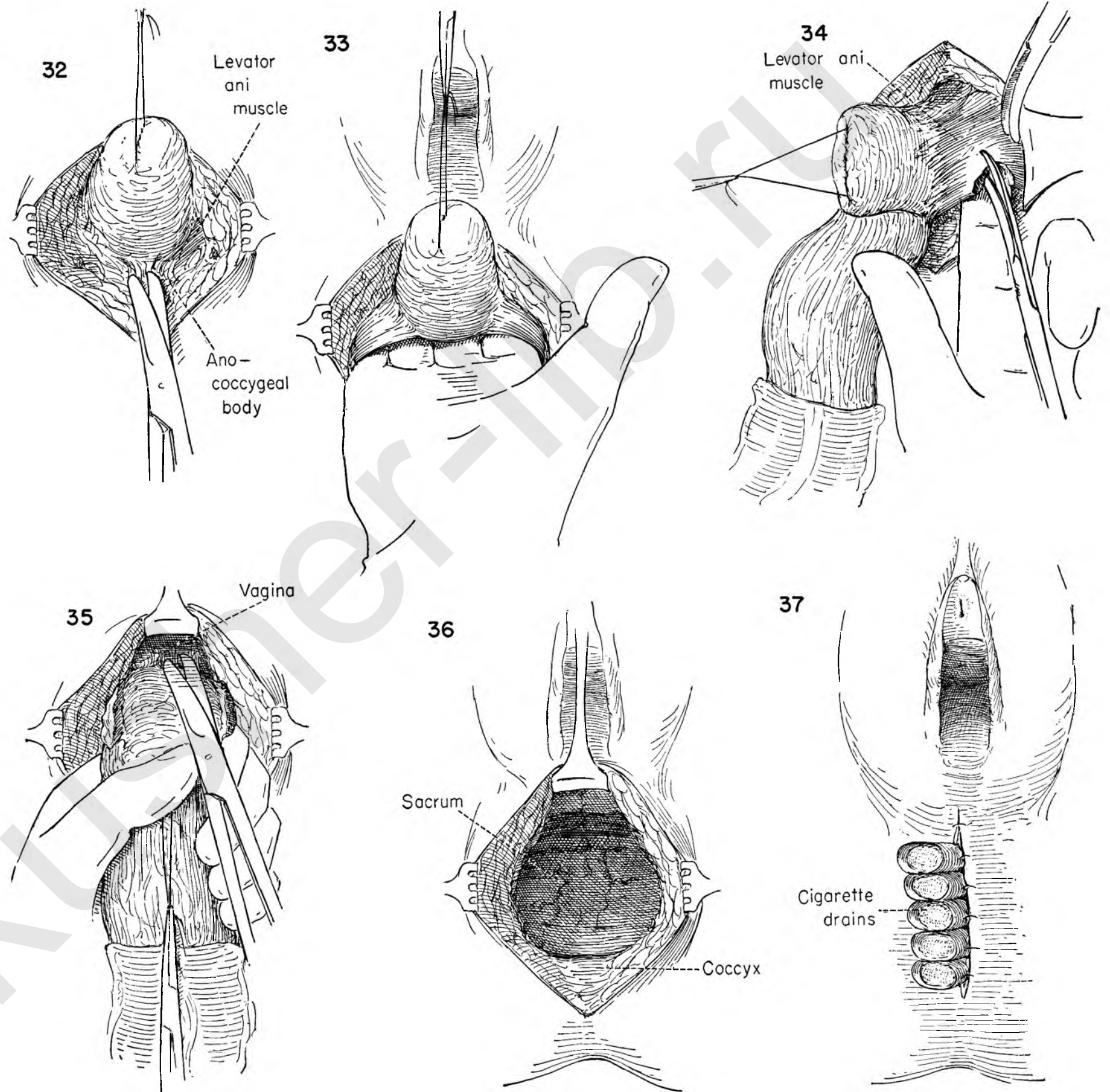
FIGURE 33. This incision enters the space previously dissected from above. The hand is introduced and the bowel delivered below.

FIGURE 34. With the colon held on tension to one side, the levator muscle is brought into sharp relief and cut close to its lateral attachment. Vessels are caught and tied as they are met. The same procedure on the opposite side leaves the bowel free except for the posterior vagina and perineal body.

FIGURE 35. Now with the bowel held on tension towards the coccyx, these final attachments are cut.

FIGURE 36. With the bowel removed, the operator can inspect the cavity for bleeding points. The peritoneum and its suture line are easily seen. The ureters can be visualized. The sacrum and coccyx are readily accessible.

FIGURE 37. No attempt is made to approximate the levators, but the skin and fat are closed loosely in one layer with heavy silk in the area just below the vagina. Five cigarette wicks are then placed in the cavity and secured to the skin edge with separate sutures. The longest drain is the one nearest the vagina. It is planned to start removing these on the third postoperative day, and one every two days thereafter, the longest one first. There is wide variation in the handling of the posterior wound, and many surgeons nowadays close without drainage at all.



COMBINED BILATERAL SUPERFICIAL GROIN DISSECTION AND RADICAL VULVECTOMY

This procedure best serves to illustrate the principle of en bloc removal of the regional lymph nodes together with the intervening lymphatics and primary tumor growth.

FIGURE 1. The authors prefer the crescent incision to the many types of skin incisions advocated to carry out this dissection. The incision begins at the right anterior-superior spine on the abdominal wall, curving down to the crease of the groin as the lowest point of the arc, crossing above the mons veneris, and arching up from the left groin to the anterior-superior spine on the left side.

FIGURE 2. The skin incision is completed, and protective gauze is applied to the edges. The assistant provides traction to the upper skin flap by elevating rake retractors. The surgeon undermines the skin in a plane just above the superficial fascia well up on the abdominal wall. The individual bleeding vessels are clamped as they are encountered.

FIGURE 3. The deep layer of fat is then dissected downward off the underlying aponeurosis of the external oblique muscle.

FIGURE 4. The rake retractors are transferred to the lower skin flap. The assistant elevates the flap while the surgeon undermines the lower skin edge, again in the plane of the superficial fascia.

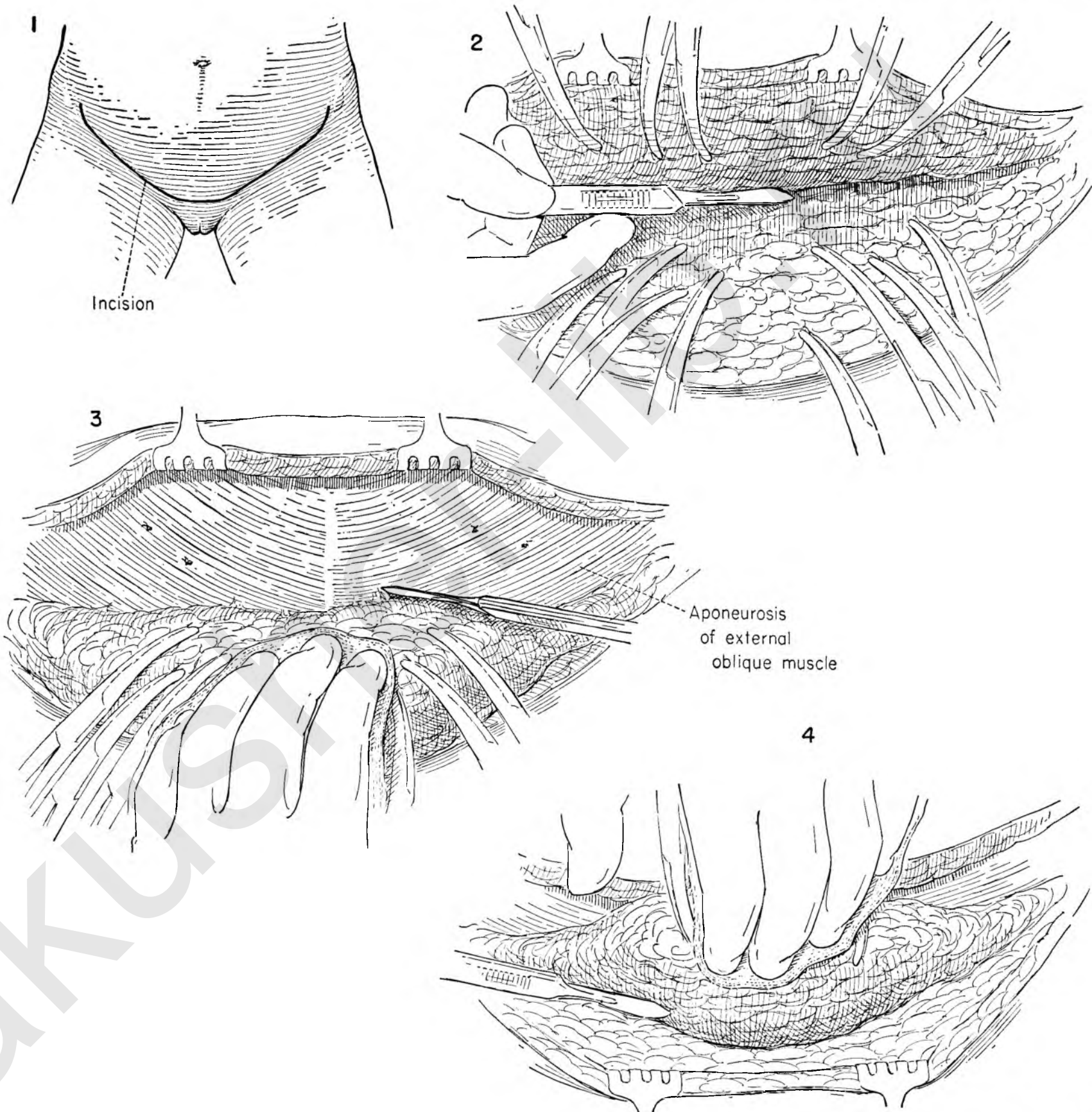


FIGURE 5. By placing the lower skin edge on tension and elevating it, the separation of the deep fatty tissue from the superficial fat and skin can be carried as far down the thigh as the adductor canal.

FIGURE 6. With the lower skin flap elevated, the surgeon begins to dissect the deep fatty tissue containing the nodes and lymphatic channels from the underlying fascia. The dissection is begun laterally with scissors and the mass of tissue mobilized toward the midline. The exposed fascia lata is seen as this is developed. The assistant maintains traction on the mass of fat and nodes as the surgeon continues to mobilize the material toward the midline until the femoral vessels are approached. Only a narrow attachment of tissue to Poupart's ligament remains.

FIGURE 7. With the mass held on traction with Kelly clamps the surgeon completes the removal of fat from Poupart's ligament.

FIGURE 8. To ensure a complete removal of the superficial and femoral nodes, the saphenous vein must be sacrificed. It lies on the deep fascia, running diagonally to enter the femoral vein in the fossa ovalis amid the mass of fat and nodes. The surgeon should identify the vein in the most distal point of the dissection. It will be found on the medial side of the femoral vessels. The vein is isolated and clamps applied.

FIGURE 9. The saphenous vein is then divided. The upper clamp is left on for purposes of traction, but the lower segment of vein is ligated with catgut. The cuff above the primary tie is clamped and a stitch ligature of silk applied for reinforcement.

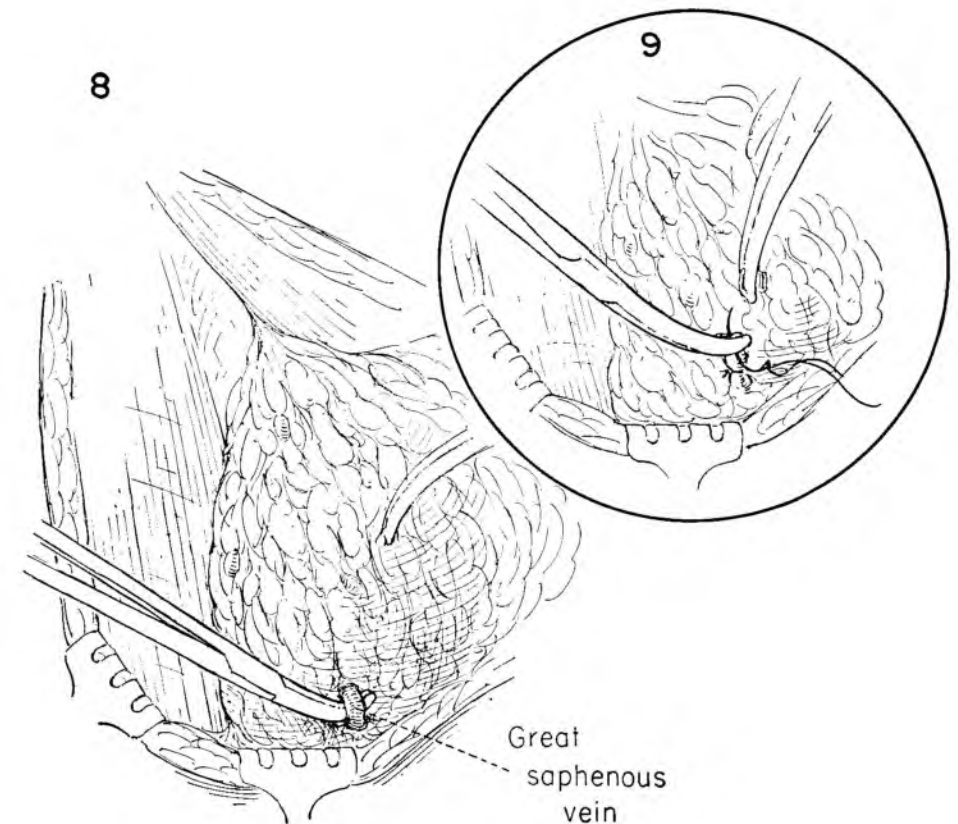
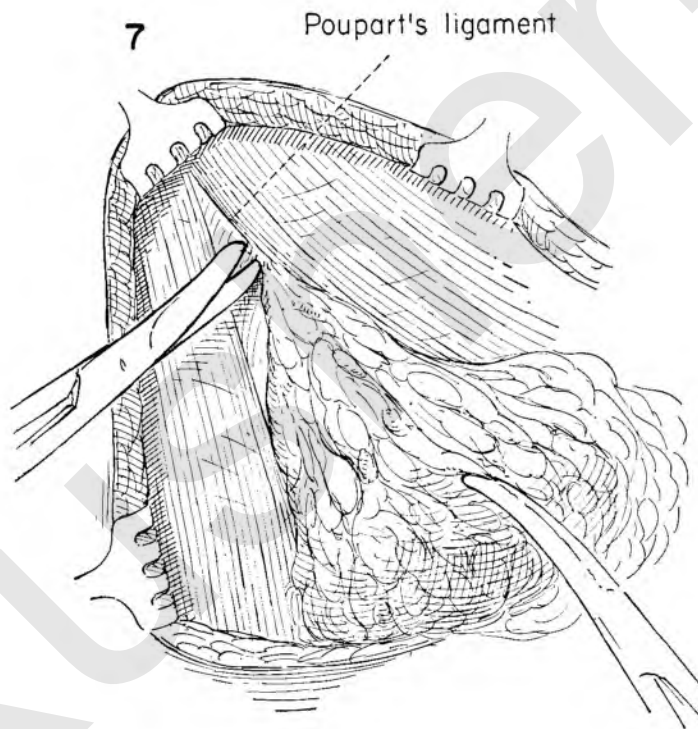
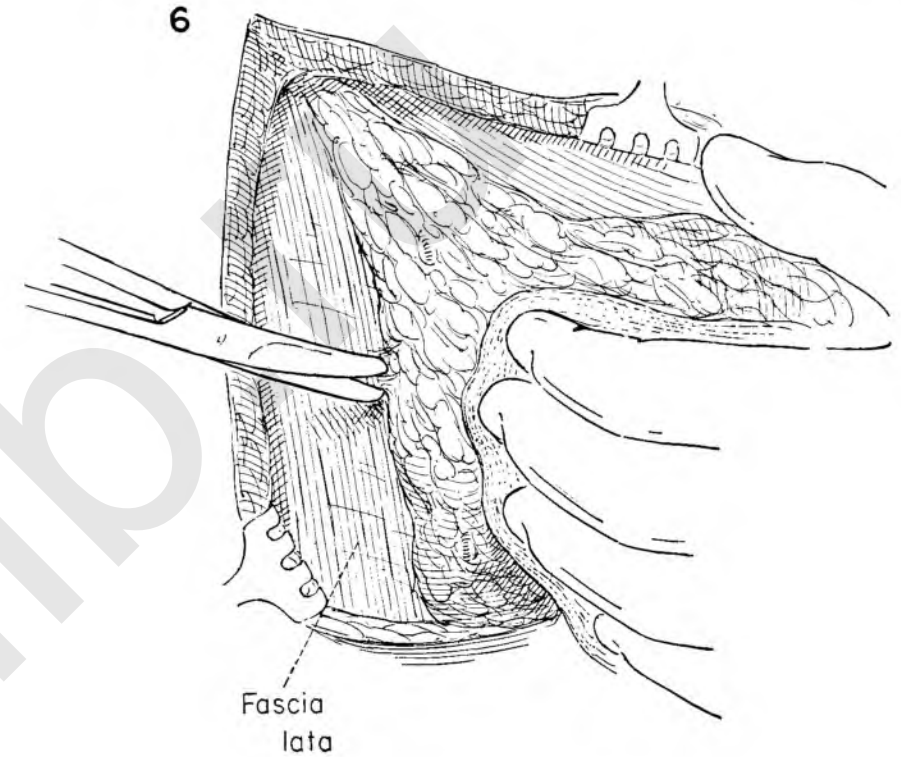
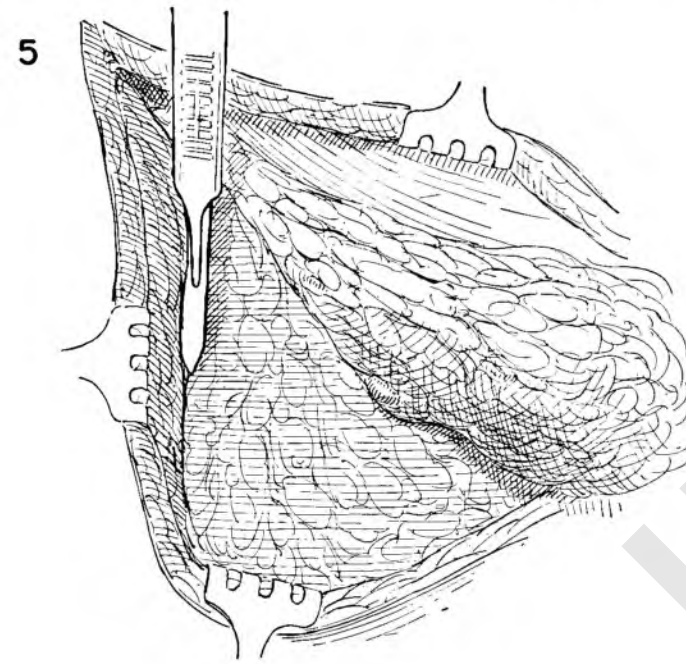


FIGURE 10. The dissection now continues medially and towards the vulva, separating a large triangle of adipose tissue from the muscle aponeurosis and from the lower flap of skin and fat.

FIGURE 11. The area is now exposed sufficiently to permit careful removal of all tissues from the femoral vessels. The contents of this triangle can most surely be removed en bloc if the fascia over the muscles on either side comes with it. The sartorius muscle is identified and a vertical incision is made through the aponeurosis, exposing the muscle along its medial border.

FIGURE 12. The muscle is left clean and the fascia dissected medially until the femoral artery is palpated immediately adjacent to the field.

FIGURE 13. The femoral sheath is incised on its lateral aspect.

FIGURE 14. The femoral artery is dissected free from the under surface of the specimen. This step will proceed easily if the surgeon stays in the plane immediately outside the vessel. When nodes appear to be grossly adherent to the vessel because of involvement by tumor, this plane of cleavage will be found free and easy to dissect in the majority of cases.

FIGURE 15. This dissection carried to Poupart's ligament often encounters small arteries which must be ligated at their points of origin.

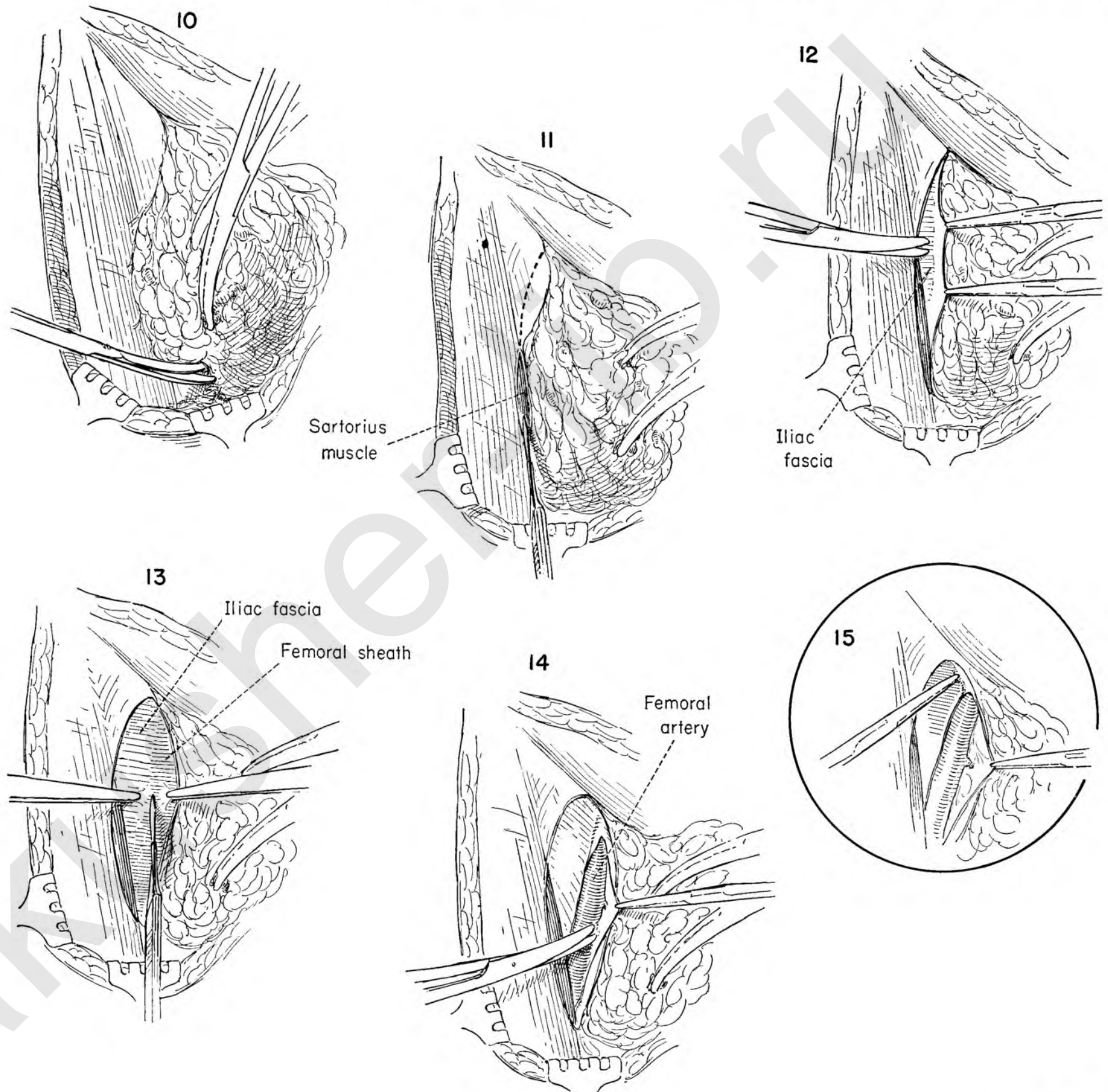


FIGURE 16. The point of entrance of the saphenous vein into the femoral is obscured by a mass of fatty tissue which contains the nodes. A clue to its site of entrance can be obtained by isolating a small arterial branch which crosses the femoral vein just below the point where the junction of the veins takes place. Its position is constant. It is the lower border of the fossa ovalis. The mass of tissue is drawn medially to facilitate the exposure.

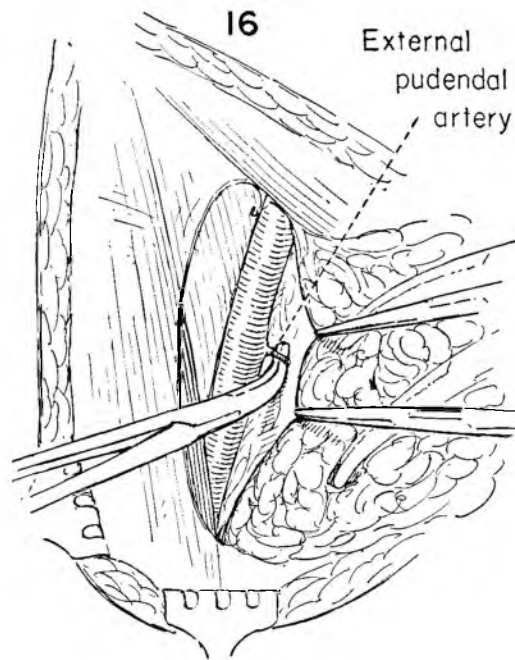


FIGURE 17. The small arterial branch is divided and ligated with silk close to the femoral artery.

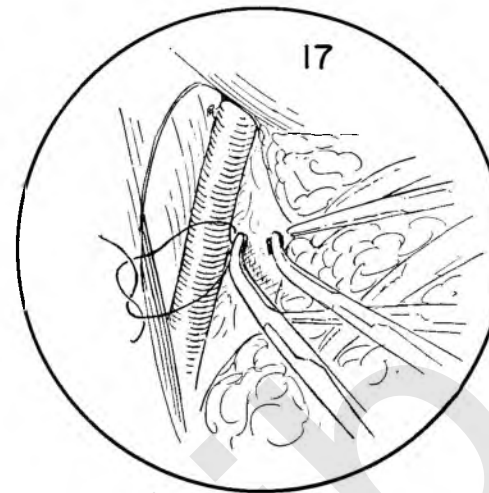


FIGURE 18. The area between the femoral artery and vein is now dissected free of areolar tissue and the femoral sheath opened over the vein.

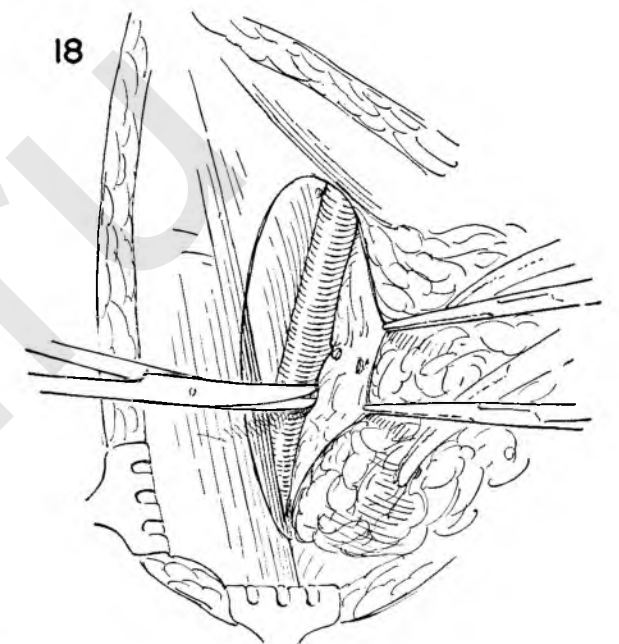


FIGURE 19. As the sheath is separated from the vein, the point of entrance of the saphenous vein is identified.

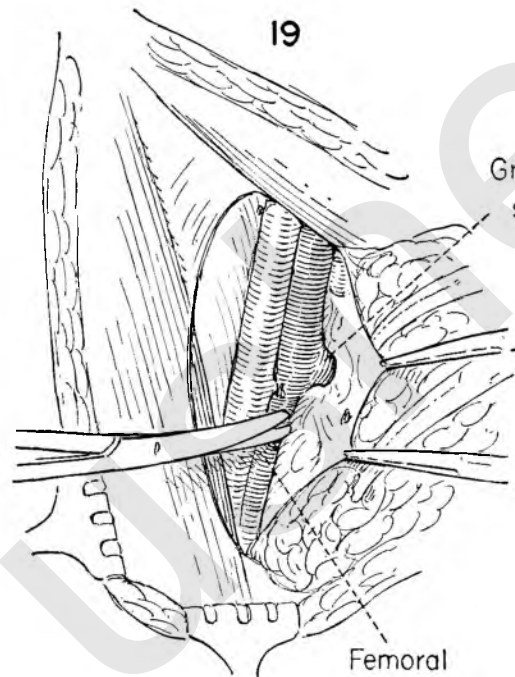


FIGURE 20. The mass of fatty tissue and nodes is drawn medially, and the saphenous vein is further exposed. There are many small tributaries entering the saphenous just before it joins the femoral. These branches should either be avoided or be individually clamped and ligated.

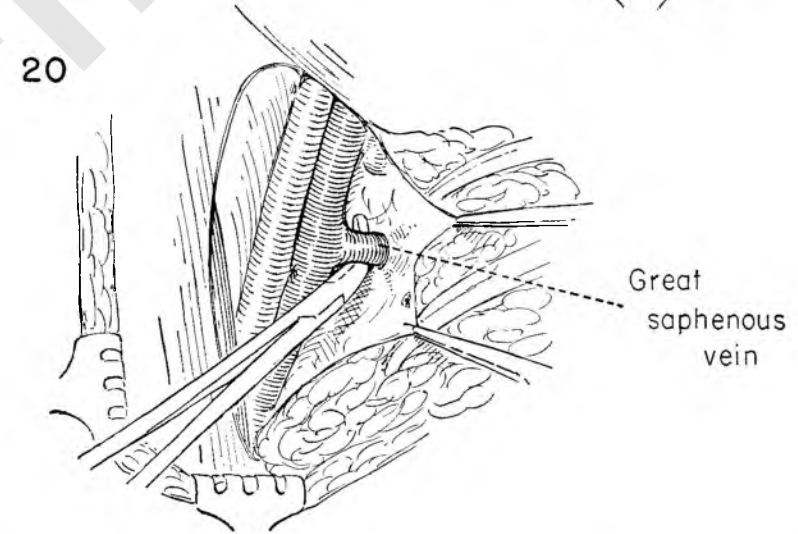


FIGURE 21. With both veins exposed, Kelly clamps are placed across the saphenous vein at the point of junction. As the clamps are applied, tension on the mass of tissue should be relaxed to avoid including the wall of the femoral vein because of tenting.

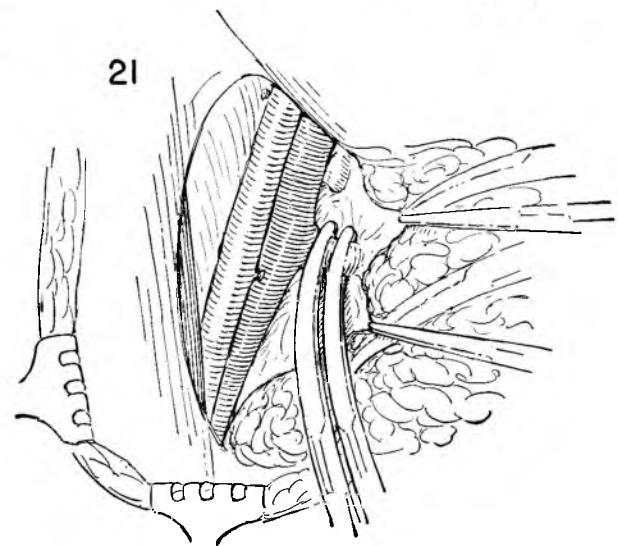


FIGURE 22. The saphenous vein is then cut and ligated with catgut. The clamp is removed and reapplied to the stump and the first tie reinforced with a stitch ligature of silk.

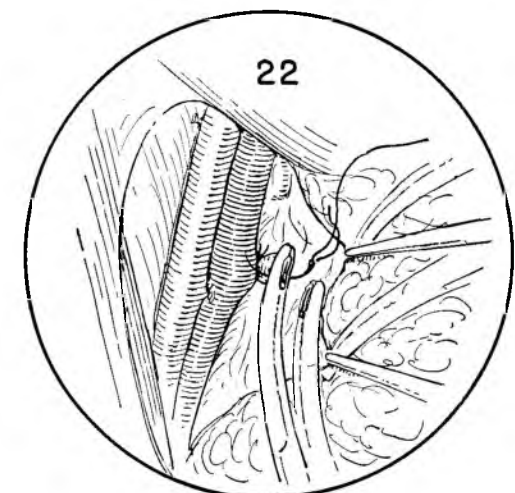


FIGURE 23. The femoral vein is now exposed throughout its length and the sheath divided along its medial surface.

FIGURE 24. The mass of fat, lymphatics and nodes is now completely free of any major attachment to vessels. Traction is applied in a medial direction and the areolar tissue dissected from the region of the femoral canal. It is in this area beneath Poupart's ligament and medial to the vein that the major lymphatic channels run in communicating with the deep nodes of the pelvis. It must be dissected clean.

FIGURE 25. The mass is rotated upwards and held on tension as it is cut free with some of the fascia exposing the glistening aponeurosis overlying the pectineus muscle.

FIGURE 26. Only the attachments over the external inguinal ring now remain. The tissue is further mobilized down and medially until the round ligament is exposed.

FIGURE 27. The external oblique fascia is split upward in the line of its fibers from the external ring for a distance of 1 inch.

FIGURE 28. The round ligament and contents of the inguinal canal are freed and retracted forcibly downwards. Clamps are applied and the ligament cut. A suture ligation replaces the proximal clamp.

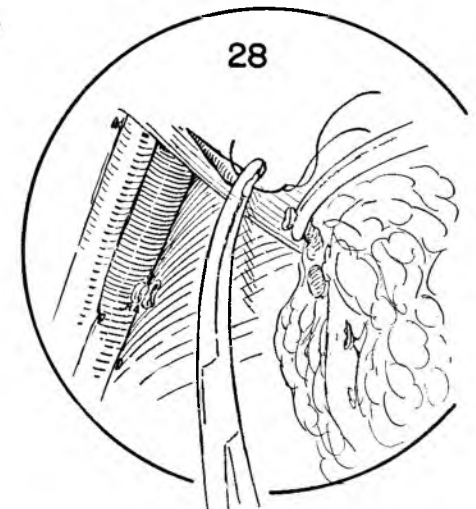
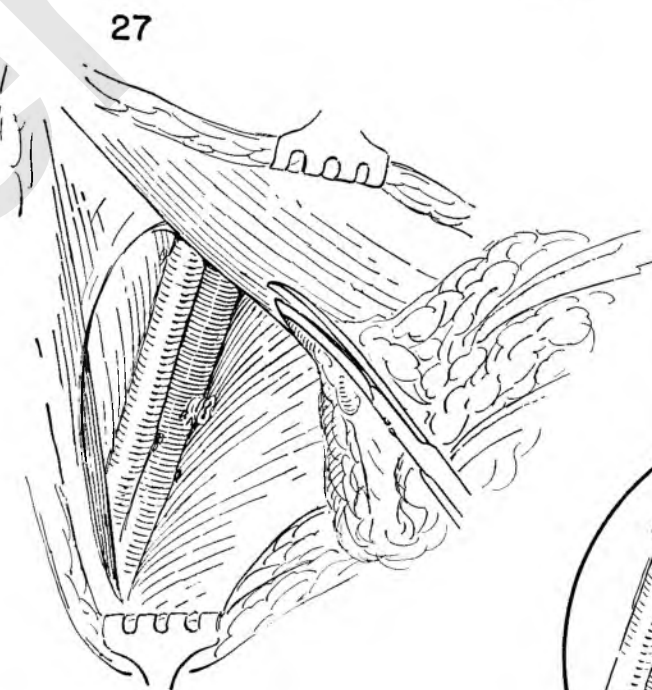
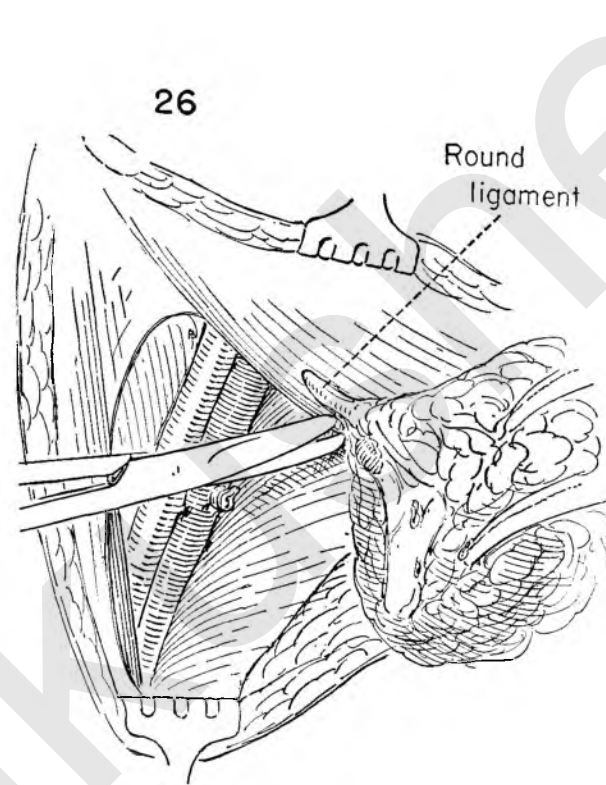
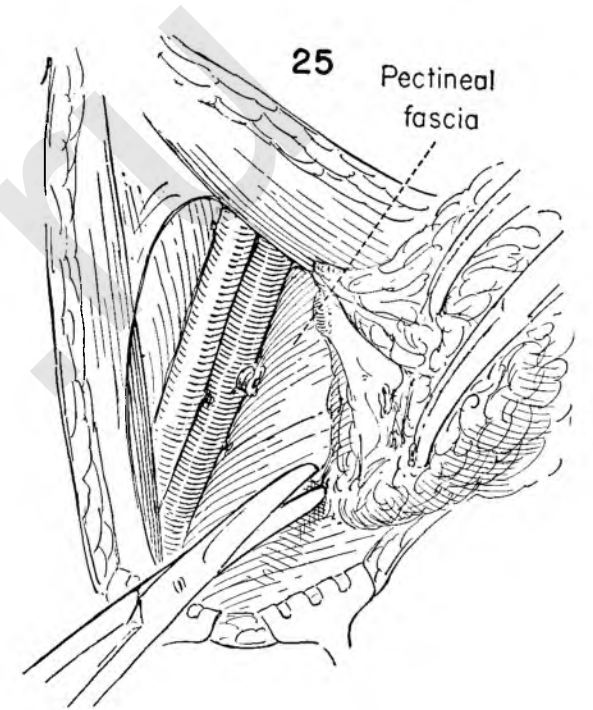
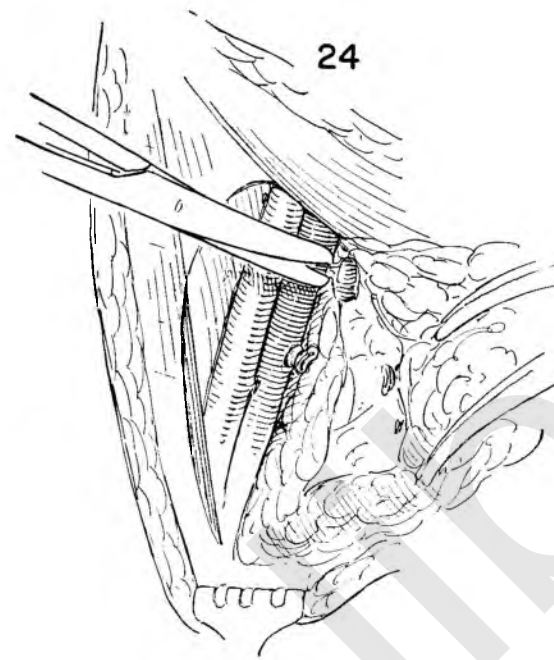
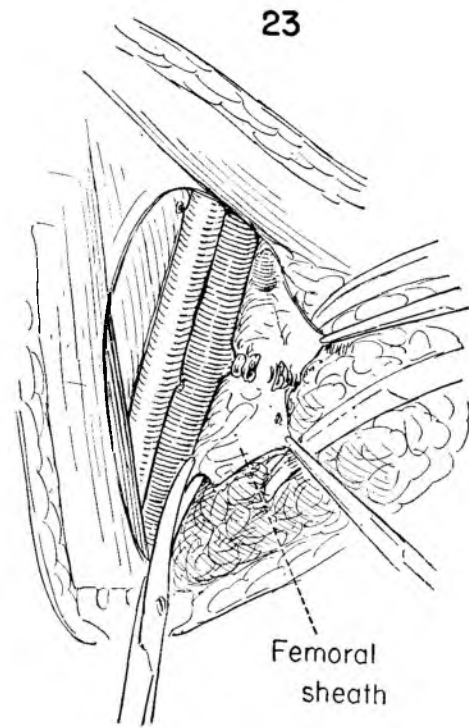
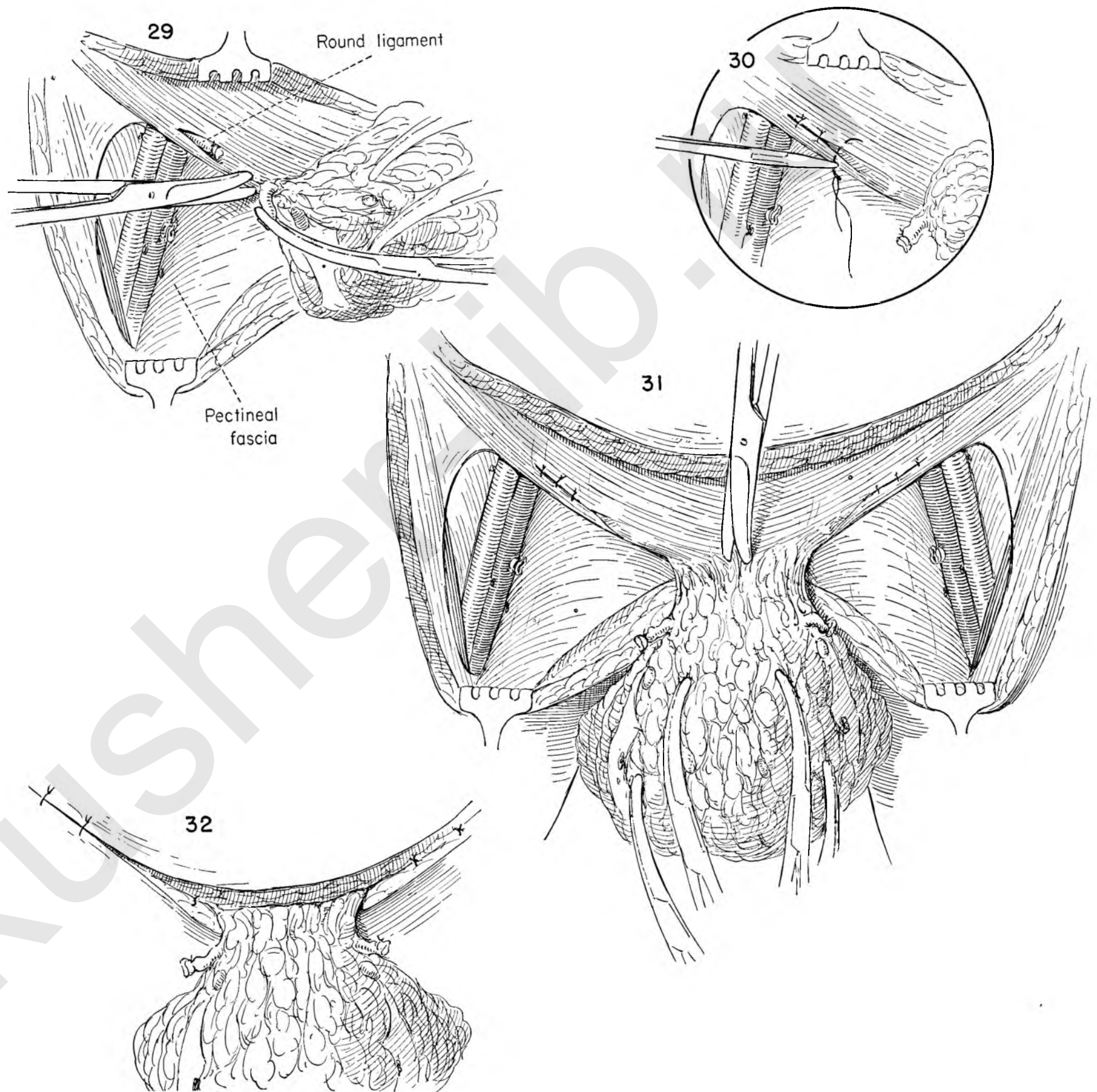


FIGURE 29. The round ligament and surrounding tissue are further freed medially from the fascia and pubic bone.

FIGURE 30. The defect in the fascia overlying the round ligament is closed with interrupted silk sutures.

FIGURE 31. Here the field is shown after dissection has been completed in both groins. The fat of the mons veneris is then freed from the bony surface of the symphysis pubis. The principle of en bloc removal of the regional nodes and intervening lymphatic pathways is emphasized in this dissection. The primary growth is yet to be removed. This marks the extent of the dissection possible with the patient in this position.

FIGURE 32. The upper and lower skin flaps are approximated at the corners with two layers of interrupted sutures. The first brings together the fat and the second the skin edges.



The dissection to this point has removed the entire lymphatic-bearing area in both groins together with the block of lymphatics intervening between the superficial inguinal nodes and the primary tumor. This tissue remains attached to the specimen.

FIGURE 33. The patient is now placed in the lithotomy position to permit the removal of the entire vulva. Clamps are placed on the open edges within the area of the tissue outlined for removal. The assistant applies upward traction on the clamps as the surgeon grasps the skin opposite and starts the incision along the left side. Note that wide margins are given to the growth despite the fact that the primary tumor is small.

FIGURE 34. The labia are placed on counter-traction with Allis forceps to expose the urethral orifice. The surgeon places the anterior vaginal wall on tension with the palmar surface of the fingers placed over a gauze sponge and incises the vaginal epithelium above the urethral orifice.

FIGURE 35. The labium is held on traction to the right and the anterior vaginal wall to the midline as the operator continues the incision along the lateral epithelial wall of the vagina. The same maneuver is repeated on the left side, completely circumscribing the vaginal epithelium except at the fourchette.

FIGURE 36. The incision lateral to the vulva is deepened to expose the fascia of the underlying muscles. The primary tumor mass is pulled to the midline with the operator's left hand. The use of gauze to provide purchase for the fingers will facilitate this maneuver. Deep rake retractors provide exposure on the lateral side. Individual vessels are clamped as they are encountered.

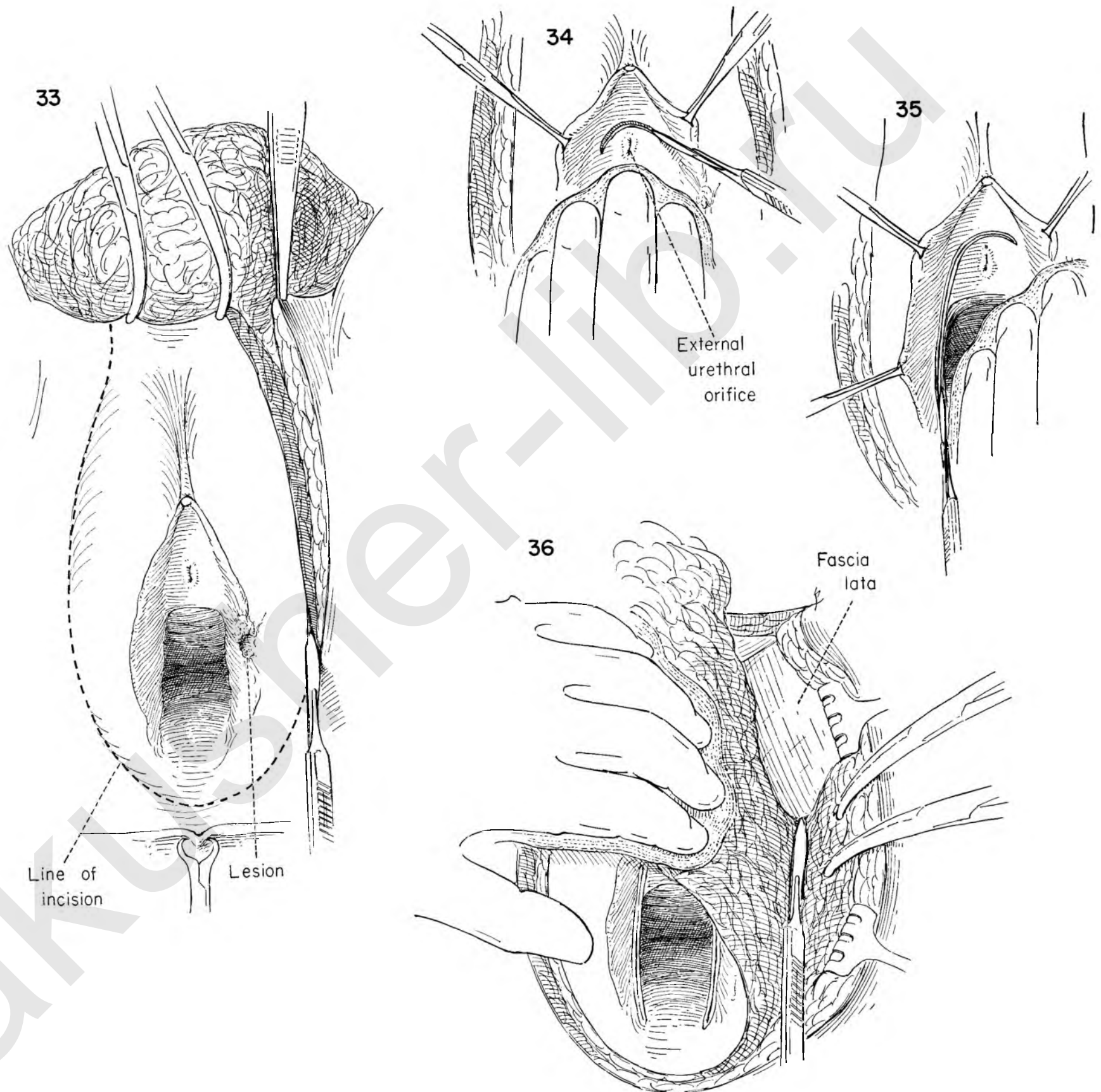


FIGURE 37. The moves are repeated on the opposite side. The entire mass of tissue is drawn downward as it is dissected from the fascia overlying the symphysis and muscles attaching to the anterior pubic rami. The suspensory ligament of the clitoris must be freed. The mass then falls downward.

FIGURE 38. By continuing with the dissection in this plane the mass is completely freed from the symphysis, not only on its anterior surface, but also underneath the pubic arch. Care must be taken to avoid a plexus of veins in this area. The handle of the knife is useful in making this separation.

FIGURE 39. The mass of tissue is again drawn sharply to the midline, exposing the pudendal vessels appearing just below the level of the midpoint of the lateral dissection. The vessels are being dissected free of the surrounding fat by the tips of a Kelly clamp.

FIGURE 40. The vessels are doubly clamped as the assistant holds back the lateral border of the skin incision with the deep rake retractors.

FIGURE 41. The operator then places a ligature around each of the clamps while the assistant maintains the exposure. The same steps are repeated on the opposite side.

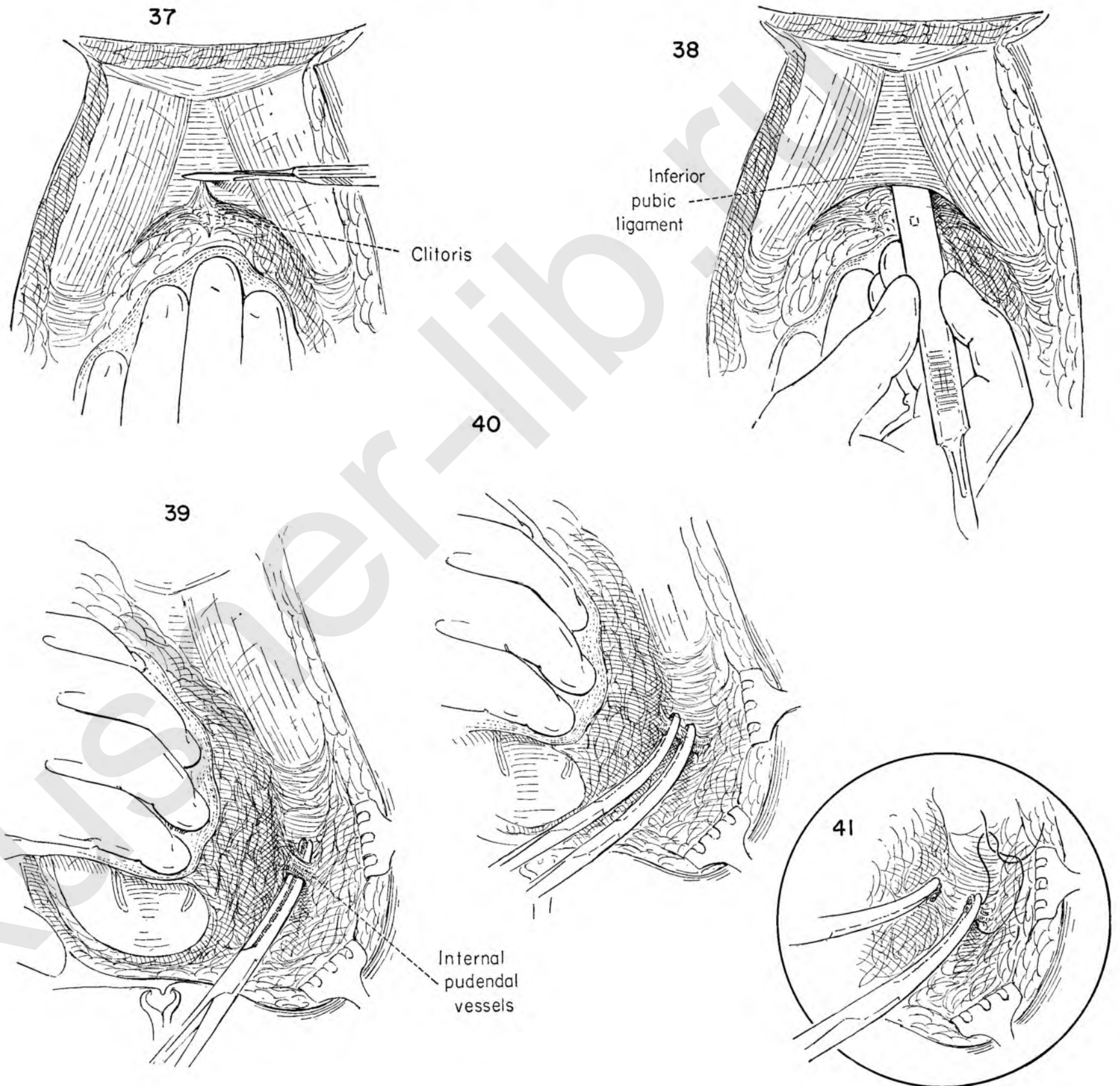


FIGURE 42. The outer aspect of the specimen has now been completely outlined and the vaginal aspect on both sides and above, but remains attached in the midline below the fourchette and above the anal opening, which is covered by linen drapes.

Clamps are applied to the edges of the specimen at spaced intervals in order to hold the entire specimen upward toward the symphysis. An Allis forceps on the upper edge provides traction as the surgeon deepens the posterior incision. Rake retractors provide additional exposure.

FIGURE 43. Upward traction is maintained on the vulva specimen. Two Allis clamps on the edge of the transverse incision below the vagina provide upward traction as the operator separates the vaginal wall from the anterior surface of the underlying rectum. Countertraction with the rake retractors gives additional exposure. This dissection is continued well up between the posterior vagina and the rectal wall to permit approximation of the levators at the time of closure. For this reason the inner incision is not carried across the fourchette.

FIGURE 44. The specimen is still attached by the fibrous fatty tissue between the two areas already dissected. The assistant provides traction to the left as the surgeon divides this fatty connection.

FIGURE 45. Continuing to hold the specimen upward on tension, the operator connects the lateral dissection with the incision previously made to circumscribe the vaginal epithelium by passing the index finger between the mass, breaking through on the vaginal side. The same procedure is carried out on the other side.

FIGURE 46. Before accomplishing a similar separation over the urethral meatus, the canal should be identified by introducing a blunt instrument to demonstrate its course.

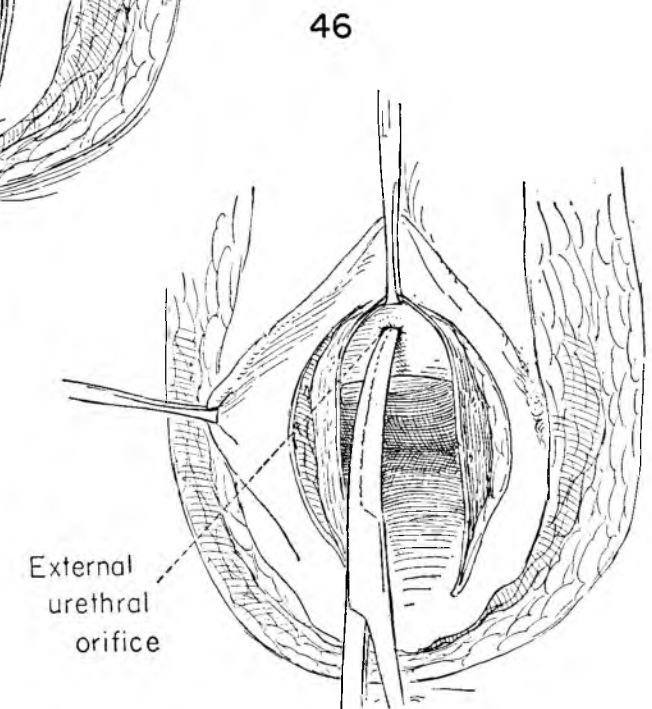
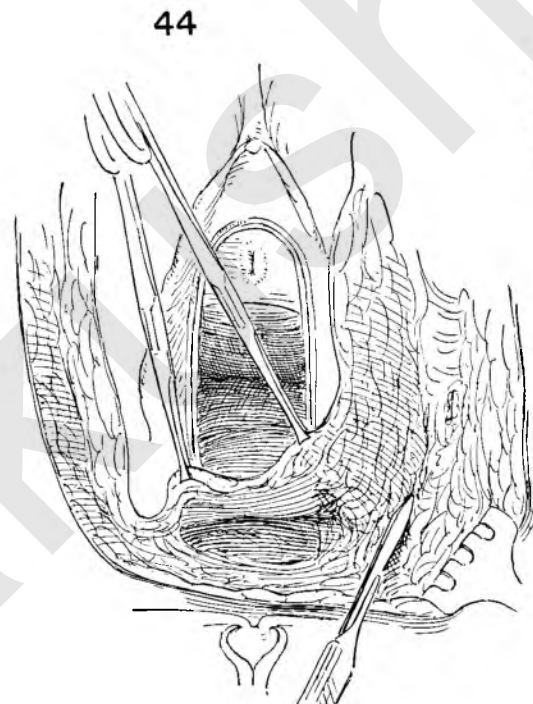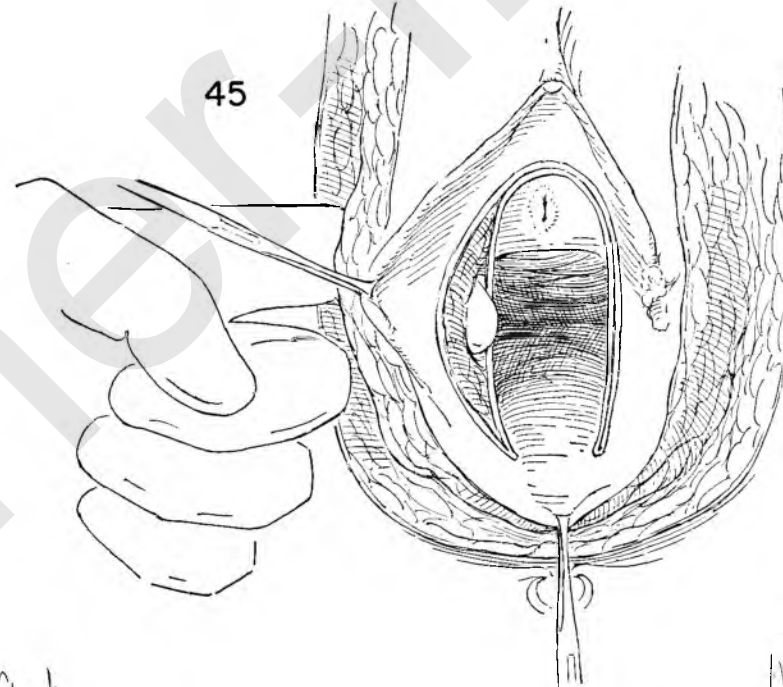
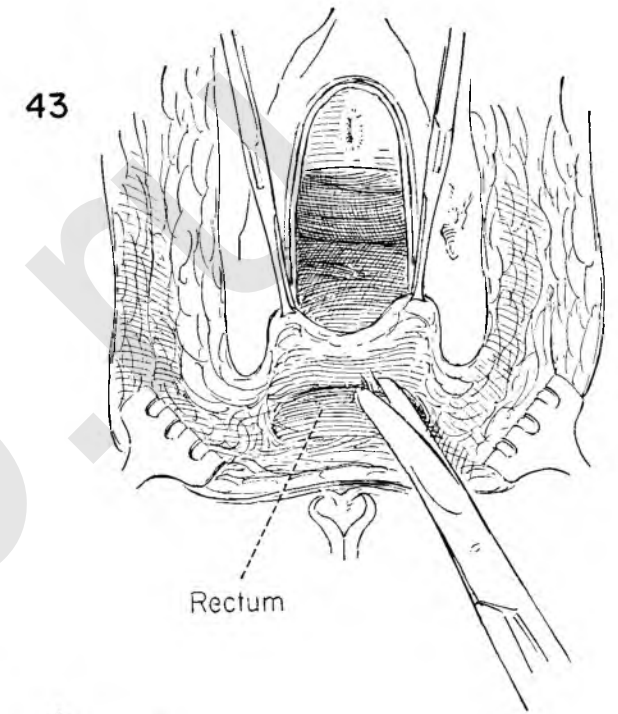
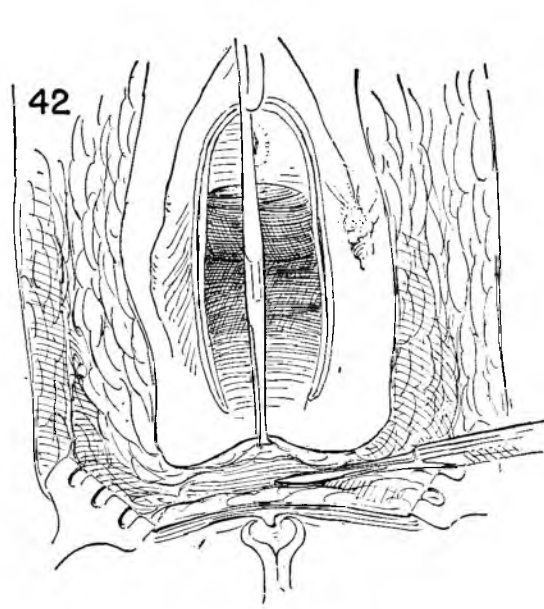


FIGURE 47. For the sake of exposure the specimen is held on tension by lateral clamps. An Allis forceps grasping the upper edge of the incision above the urethra is placed on traction. The surgeon then separates the urethra from the under surface of the specimen with the knife handle.

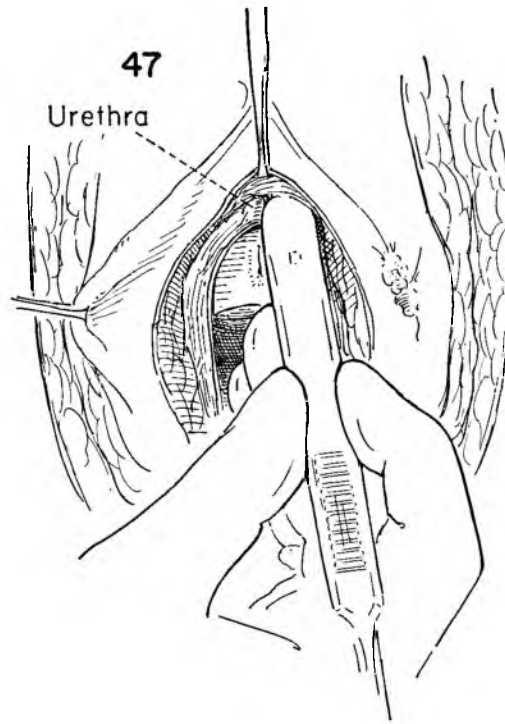


FIGURE 48. This maneuver soon leads one into the area of previous dissection from above. The surgeon's left index finger demonstrates this fact.

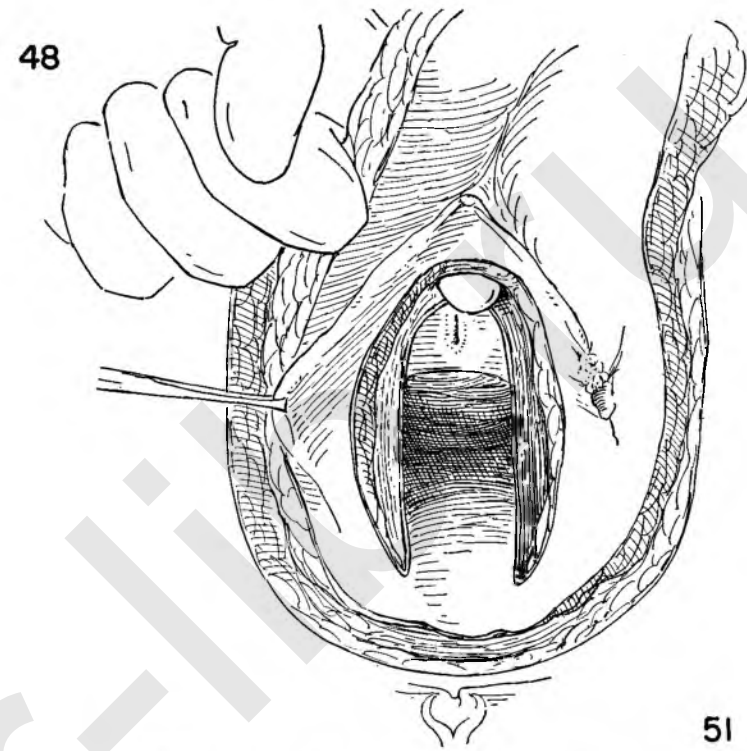
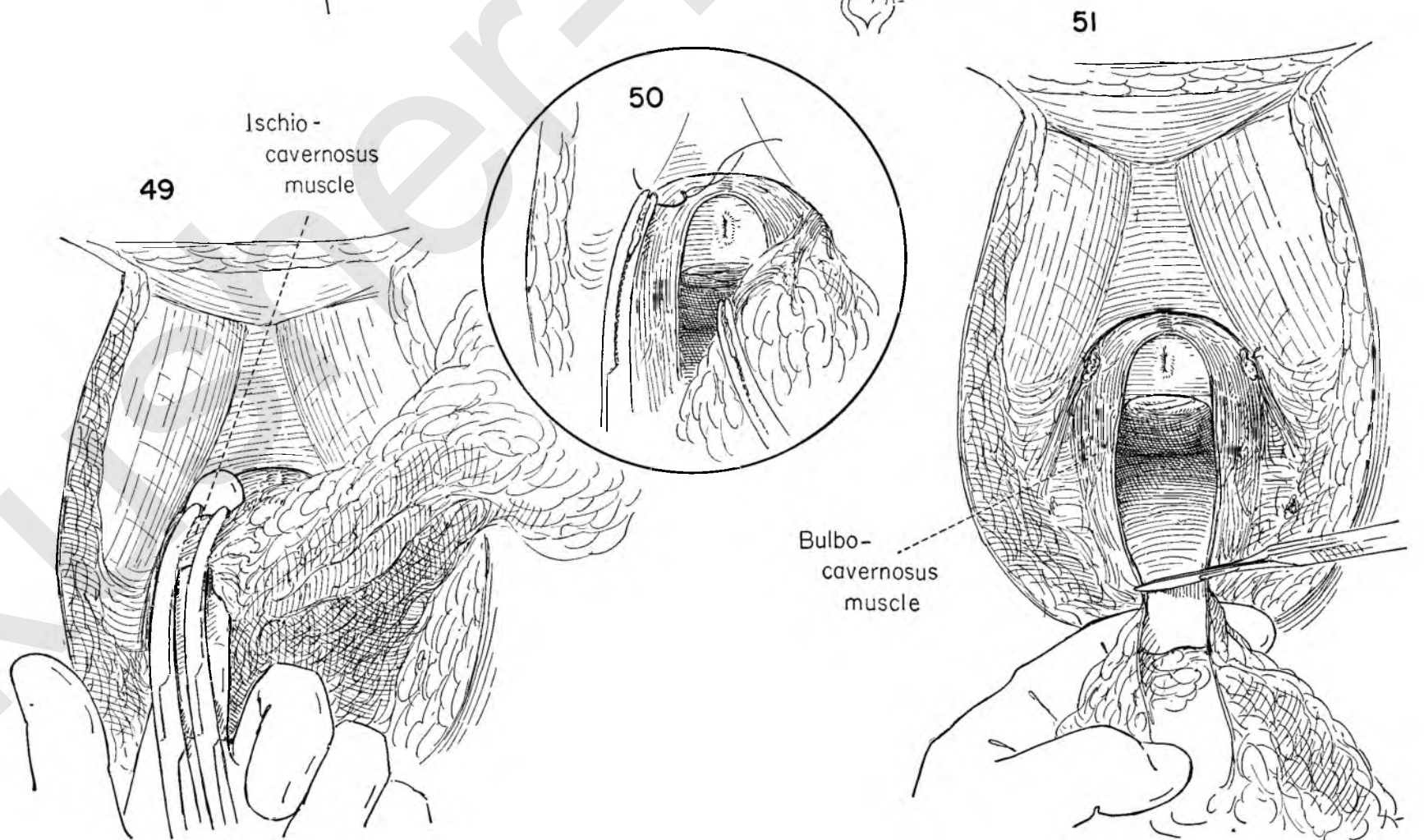


FIGURE 49. The specimen is now detached from the symphysis and pubic rami except for the small muscle bundle of the ischiocavernosus which holds it on either side. This muscle is included between two Kelly clamps and the tissue between then divided. The index finger behind the muscle helps to support the weight of the specimen.

FIGURE 50. The tissue in the lateral clamp is secured with a stitch ligature. The opposite ischiocavernosus muscle is still intact and must be similarly divided, stitched or ligated.

FIGURE 51. The entire specimen is now held only by the bridge of posterior vaginal wall epithelium. This is now divided and the specimen removed.



After radical excision of the vulva there is a tendency later for the rectum to bulge out over the perineal body. At times this becomes a decided nuisance to the patient. In the interest of the patient's subsequent comfort the surgeon is advised to reconstruct the levator muscles in front of the rectum.

FIGURE 52. The lower corners of the vaginal wall are grasped with Kelly clamps and held downward on tension as the operator completes the dissection which separates the vaginal wall from the rectum and exposes the levator muscles on either side.

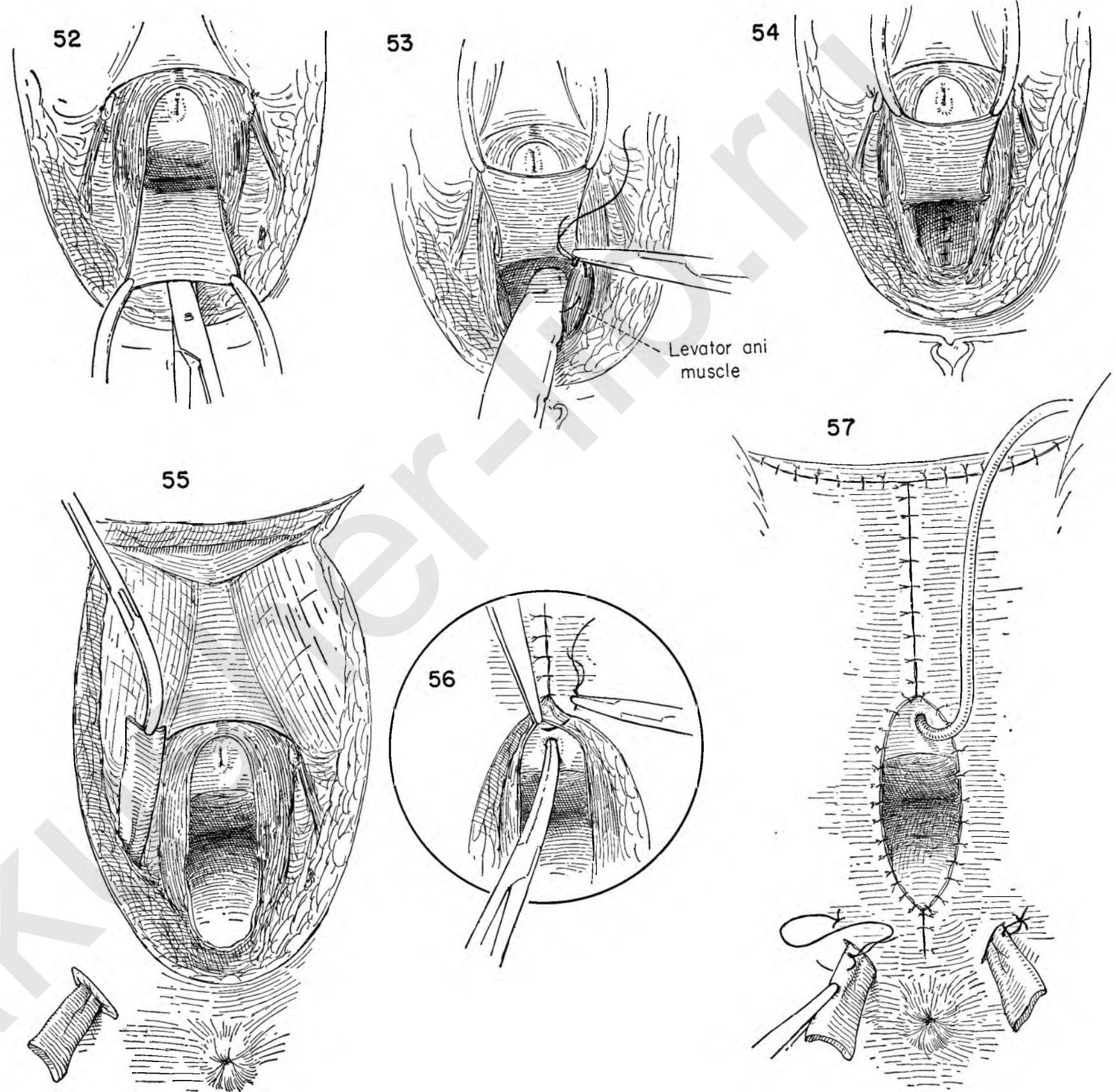
FIGURE 53. The rectum is held back by the left index finger, and a series of interrupted catgut sutures is laid into the levator ani muscles in the manner of a perineal repair.

FIGURE 54. The rectum now lies behind the levator muscles, which are approximated in the midline, and the individual sutures are tied and divided.

FIGURE 55. So much dead space has been created in this extensive dissection that drainage is an essential part of the wound closure. Stab wounds through the skin laterally on either side of the lower border of the defect permit the surgeon to introduce Penrose drains into the operative field.

FIGURE 56. The edges of the skin in the upper portion of the dissection are brought together with interrupted silk sutures. The surgeon now approximates the edge of the skin to that of the vaginal wall with interrupted silk sutures throughout the circumference. Because of the extensive dissection the edges should fall together with only moderate tension. If they do not fall together easily, one should not hesitate to leave portions of the wound open.

FIGURE 57. The vaginal wall has been approximated to the skin, and the new vaginal opening is completed. An inlying Foley catheter has been inserted in the bladder. Each drain should be held in position with a stitch ligature.



EXTRAPERITONEAL ILIAC LYMPHADENECTOMY

The iliac lymph nodes may receive metastases from any pelvic cancer, either directly or after passage through other nodes, as in the groin. The indications for iliac lymphadenectomy will vary somewhat in different cases, but this area is accessible and dissectible, and in most cases this procedure should be included. It may be an integral part of the primary definitive operation as in the Wertheim operation. It can be performed bilaterally in conjunction with the vulvectomy and groin dissection illustrated in Plates 173 through 183. On the other hand, it can be done as one of two subsequent operations whenever it seems safer to accomplish one's purpose in stages.

FIGURE 1. This and the following illustrations demonstrate the operation performed as a separate unilateral procedure on the left side, the surgeon standing on the left. The incision parallels Poupart's ligament about 4 cm. above it and extends from the pubic spine to the anterior-superior spine of the ilium.

FIGURE 2. The incision is carried down to the external oblique fascia, which is opened in the line of its fibers. The external inguinal ring and the round ligament emerging from it serve as the landmark.

FIGURE 3. The internal oblique muscle is exposed over a width of 2 inches by peeling and dissecting off the medial leaf of the fascia. Tension upwards through the medium of hemostats on the fascia makes this a rapid and simple maneuver.

FIGURE 4. With the left index finger the internal oblique muscle is easily separated from the transversalis beneath.

FIGURE 5. Then with two fingers beneath the muscle it is elevated and kept under control as it is cut obliquely along a line 2 cm. from Poupart's ligament. Bleeders are clamped and tied as they are met. It is important to leave a segment of muscle at Poupart's ligament rather than dissect it from the ligament to facilitate closure.

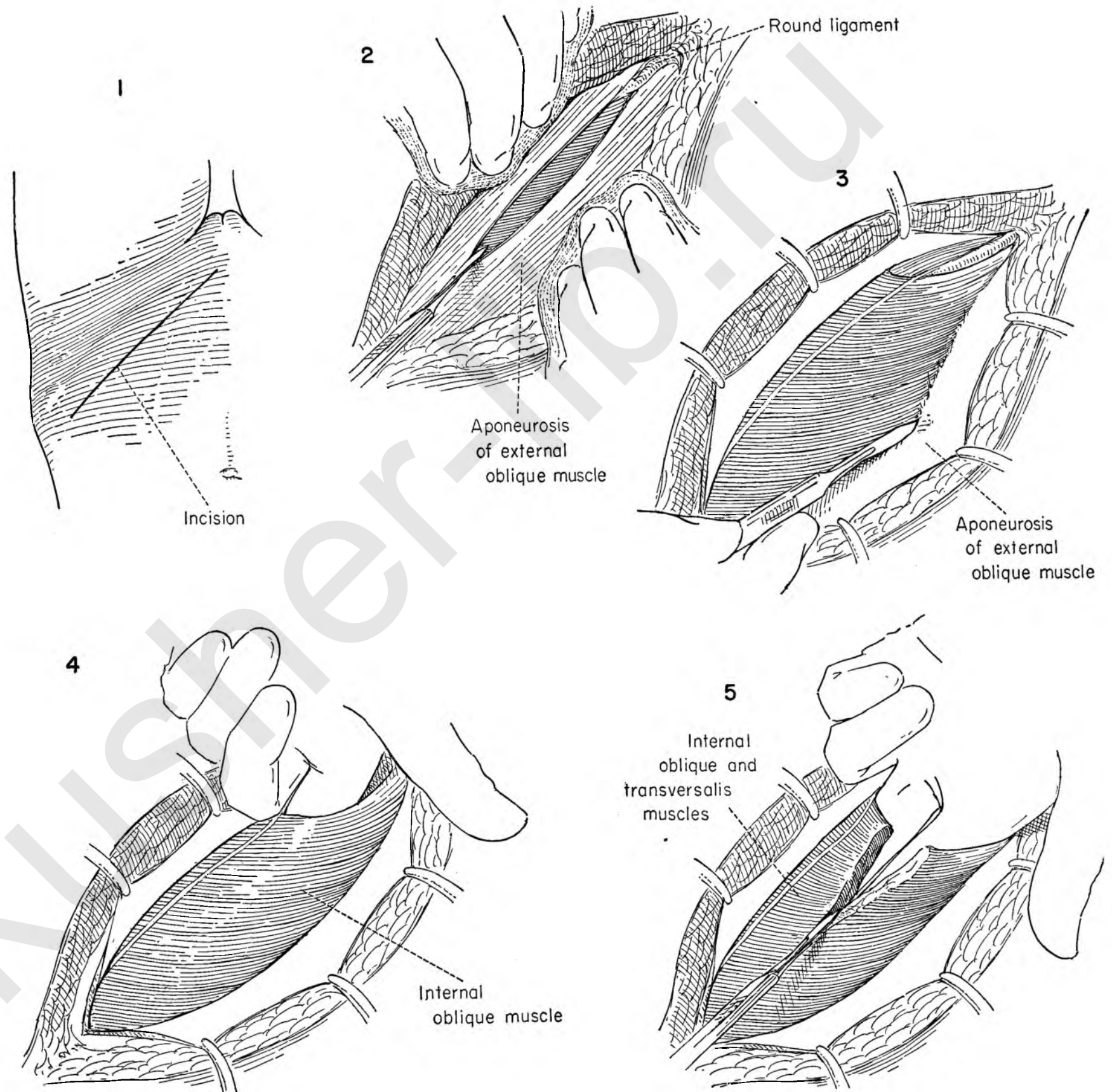


FIGURE 6. The round ligament is exposed at the internal inguinal ring where it passes beneath the peritoneum. A Kelly clamp is inserted below the round ligament, freeing it from its bed.

FIGURE 7. Clamps are placed across the round ligament, which is then divided between these clamps, and both ends are secured with stitch ligatures.

FIGURE 8. The secret of adequate exposure in this operation is the ability to reflect the peritoneum upward without damaging it. To do this satisfactorily the deep inferior epigastric vessels must be divided. They can always be found regardless of the obesity of the patient by searching beneath the round ligament stirrup. They lie on the peritoneum, running upward medially at the edge of the internal ring.

Once isolated, each can be separated individually from the peritoneum with blunt dissection.

FIGURE 9. The artery is identified, clamped and divided. Both ends are secured with stitch ligatures.

FIGURE 10. The vein is similarly disposed of.

FIGURE 11. Poupart's ligament is held on tension by Kelly clamps placed on the distal edge. The transversalis fascia, which is less of a real structure than a filmy layer, attaches the peritoneum to the under surface of Poupart's ligament. It is readily broken through and separated from the ligament below by retracting the peritoneum upward with the palmar surface of the fingers, using a raking motion with their tips.

FIGURE 12. The peritoneum can be elevated as far upward toward the diaphragm as need be for adequate exposure of the common and external iliac vessels, which lie directly beneath. The plane of cleavage is bloodless with only areolar attachments to the psoas muscle and iliac vessels.

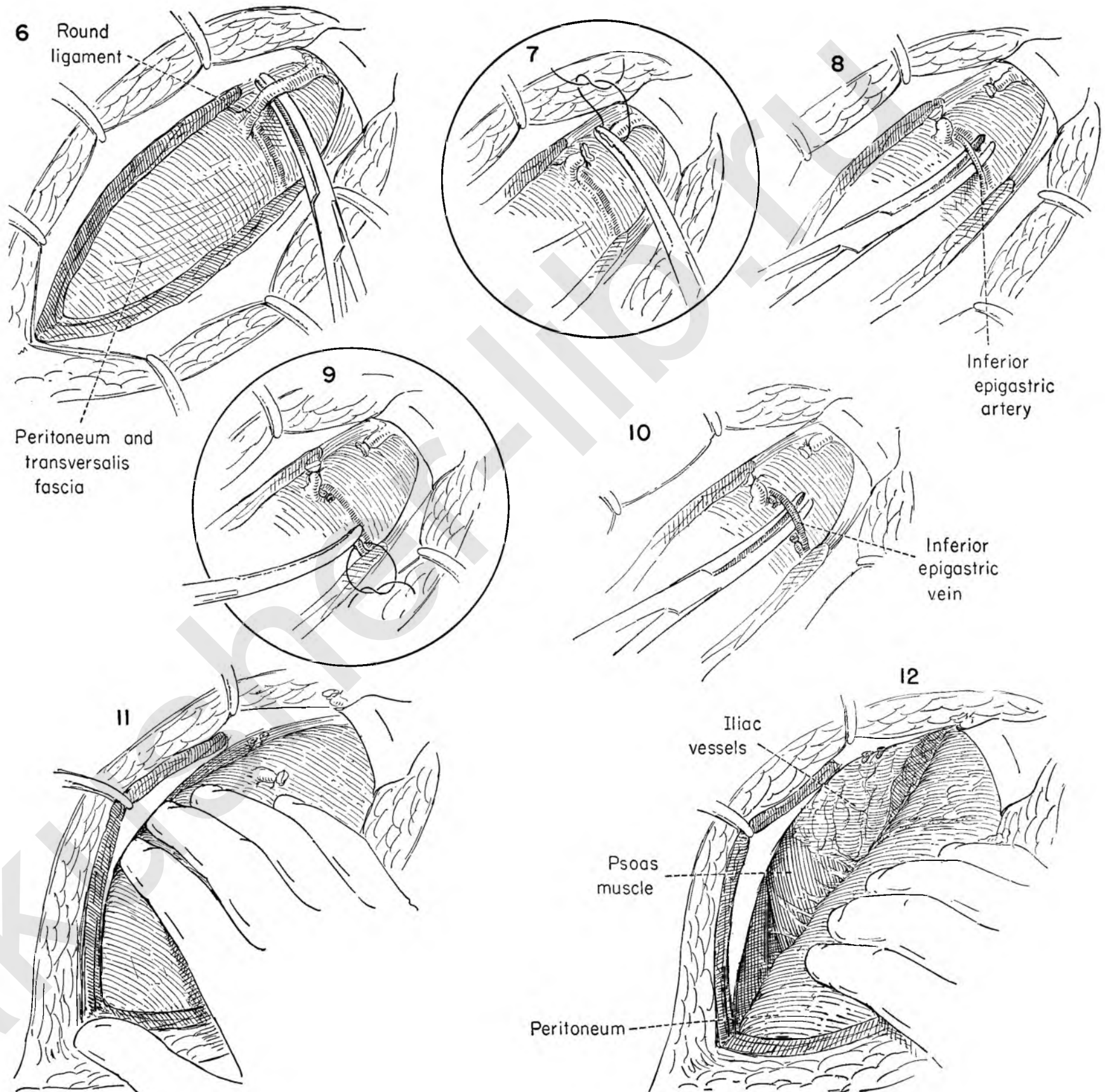


FIGURE 13. The psoas muscle and iliac vessels have been exposed. A Deaver retractor holds the bladder medially while other Deaver retractors keep the peritoneum and its contents in check. The ureter goes with the peritoneum and is easily seen. After operation, sepsis or radiation these structures may become adherent, but otherwise there should be no difficulty in exposing them.

FIGURE 14. The excision begins at Poupart's ligament. Traction is placed on the ligament and on the mass of fat and nodes, which is then gently stroked, beginning laterally over the muscle and extending medially until the superior surfaces of the external iliac artery and vein are clearly seen. Care must be taken not to injure the short stumps of the epigastric vessels and the circumflex iliacs which arise a short distance above.

FIGURE 15. The fatty mass is held on tension medially as the dissection continues along the medial surface of the vessels, leaving them clean and separate. If the nodes appear to be densely adherent, as is sometimes true of the postradiated case, a line of cleavage is always present when the adventitia of the vessel is incised. Note that the mass of fat and nodes has been dissected free of the vessels and Poupart's ligament. This is an important part of the dissection, for at this point the efferent lymphatic channels of the leg pass beneath Poupart's ligament to join the nodal chain above.

FIGURE 16. The dissection is carried along the external iliac vessels to the bifurcation of the common iliac artery. A small vessel at the bifurcation of the iliac artery should be clamped and tied.

FIGURE 17. The peritoneum is retracted upward and the common iliac artery better exposed. The specimen is divided as it crosses the bifurcation of the iliac artery for convenience in removal. The surgeon picks up the node-bearing tissue lateral to the common iliac artery and dissects it away from the vessel, leaving it clean. An arbitrary point of division at the upper end of the dissection is decided upon, and the fat and nodes in this area are removed.

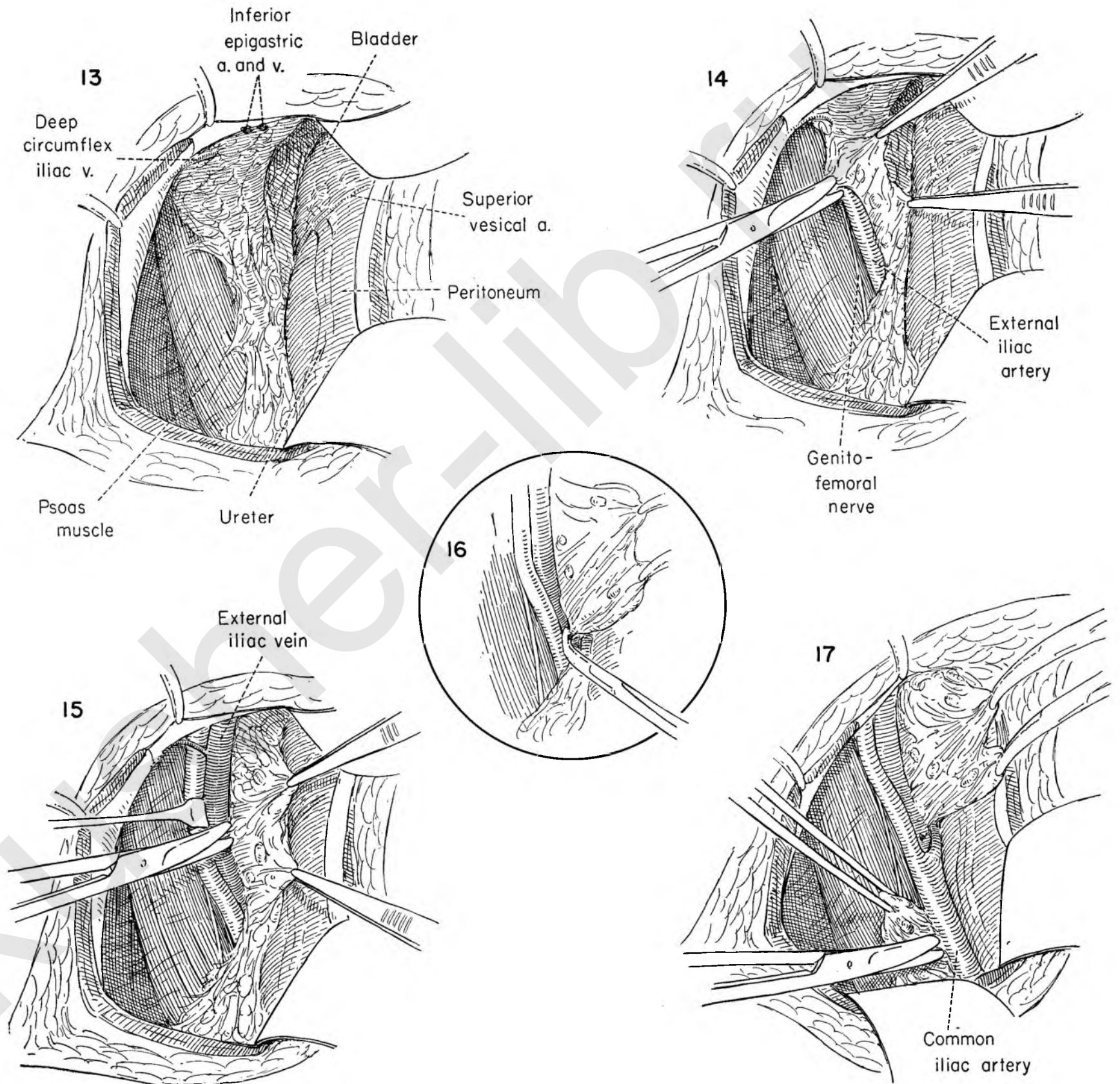


FIGURE 18. The fatty tissue and nodes along the external iliac vessels are now placed on tension toward the midline and dissected free from the medial side of the external iliac vein.

FIGURE 19. The mass of tissue is drawn laterally, exposing the superior lateral surface of the internal iliac (hypogastric) artery. Scissor dissection is then carried down along the surface of the vessel, freeing it from the contents of the obturator fossa. This block of tissue is then removed.

FIGURE 20. The bladder is retracted medially. Scissor dissection progresses slowly and carefully along the lateral surface of the internal iliac artery. The contents of the obturator fossa are freed from the lateral surface of the vessel. Beware of the internal iliac vein, which lies just beneath the artery.

FIGURE 21. The surgeon may find it to his advantage to go to the opposite side of the table before continuing with the dissection of the obturator space, but the drawings here show the operation being done from the left side. By retracting and keeping close to the under surface of the external iliac vein the obturator fossa is entered with ease. A small branch of the external iliac vein may be present and should be carefully secured and tied with silk.

FIGURE 22. After reaching the pelvic wall the mass of fat and nodes is easily displaced medially with the obturator nerve. The vein should be retracted to prevent injury and provide more exposure. The material surrounding the nerve must be dissected on both its superior and inferior surfaces. The surgeon should take care to avoid injury to the small arteries and veins in the floor of the fossa. The pressure of a gauze pack will usually control bleeding that proves troublesome.

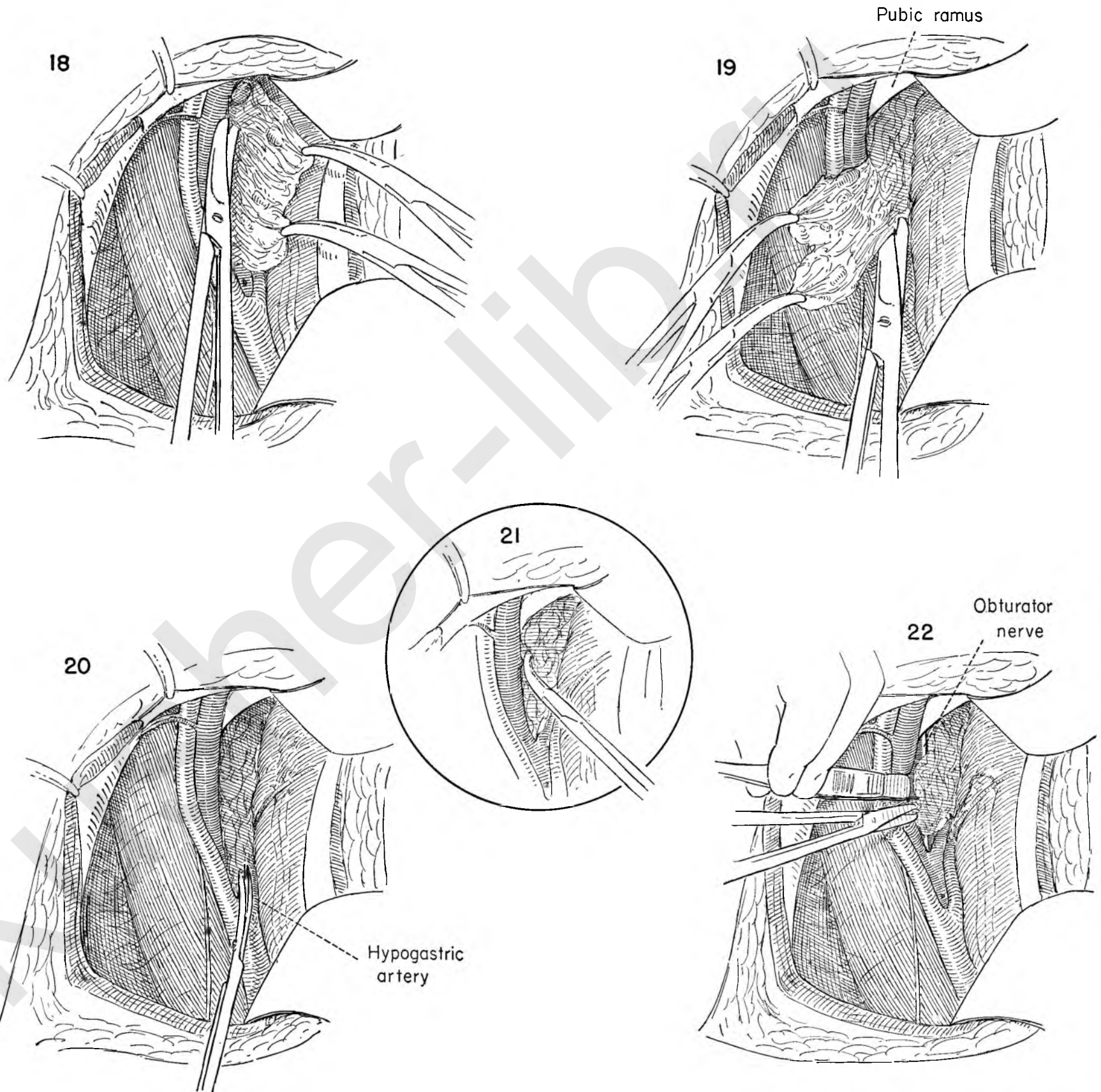


FIGURE 23. The mass of fat and nodes representing the contents of the obturator fossa surrounds the obturator nerve. This figure shows the nodal mass being elevated and dissected free from the nerve.

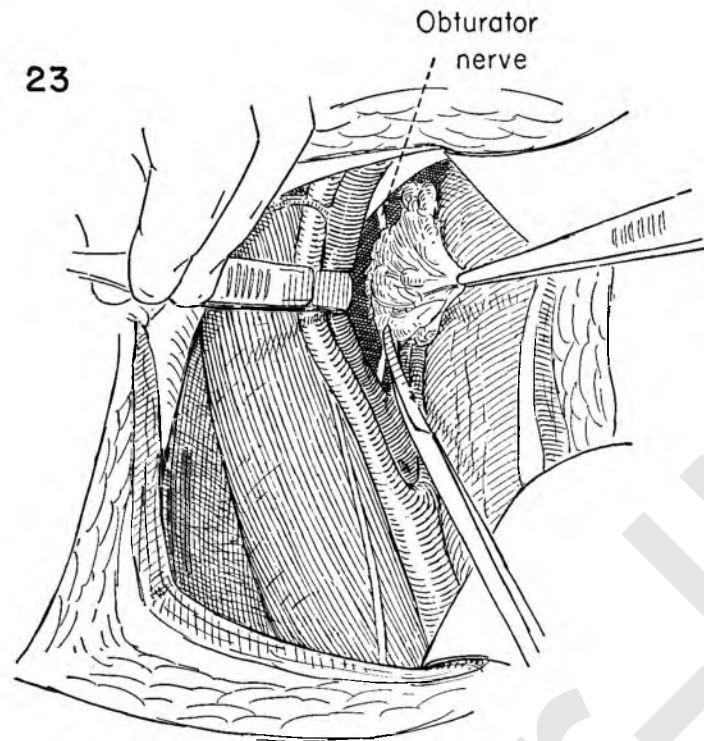
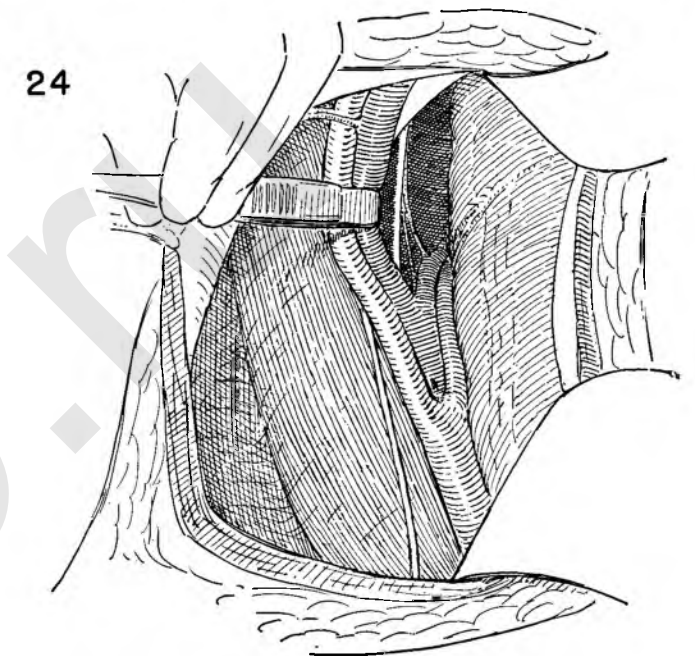


FIGURE 24. This drawing shows the completed dissection. The ureter lies on the peritoneum and is shown being crossed by the superior vesical artery.



The external iliac vessels, the common iliac artery and the obturator fossa have been thoroughly cleaned. Retraction of the vessels with the forceps handle demonstrates the pelvic wall beneath them with the obturator nerve traversing the fossa and the obturator artery and vein visible beneath it. Note how the nerve appears from beneath the bifurcation of the iliac vein.

FIGURE 25. Packs and retractors are removed and the peritoneum allowed to fall back into place. The internal oblique muscle is reconstructed by approximating the cut surfaces with closely placed silk or cotton horizontal mattress sutures. The first suture has been tied, and a second is being placed.

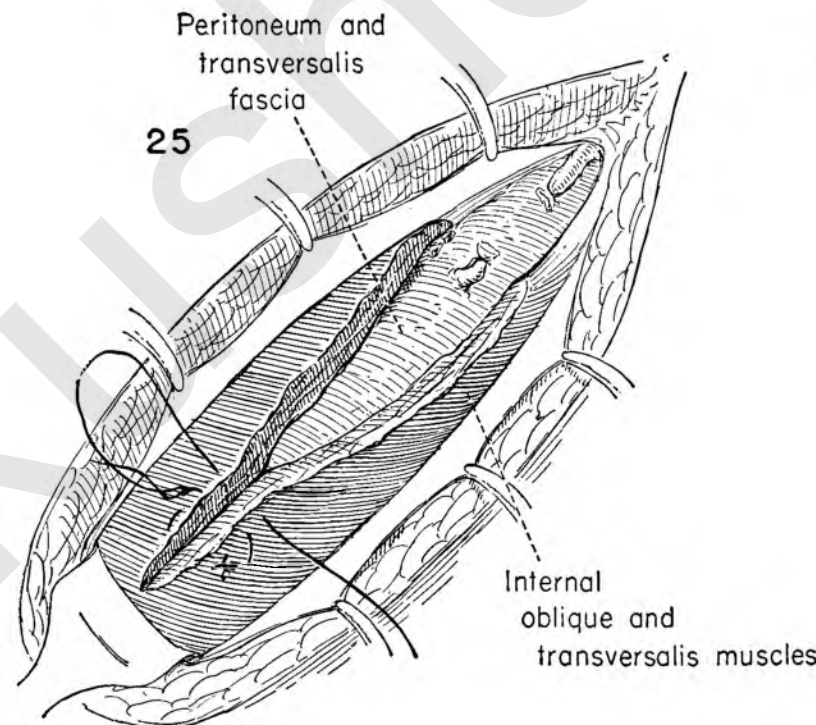


FIGURE 26. The weak spot left in the region of the external ring is given support by bringing the internal oblique muscle and conjoined tendon to the under surface of Poupart's ligament with interrupted sutures as in repair of inguinal hernia. This illustration shows the sutures in place before tying.

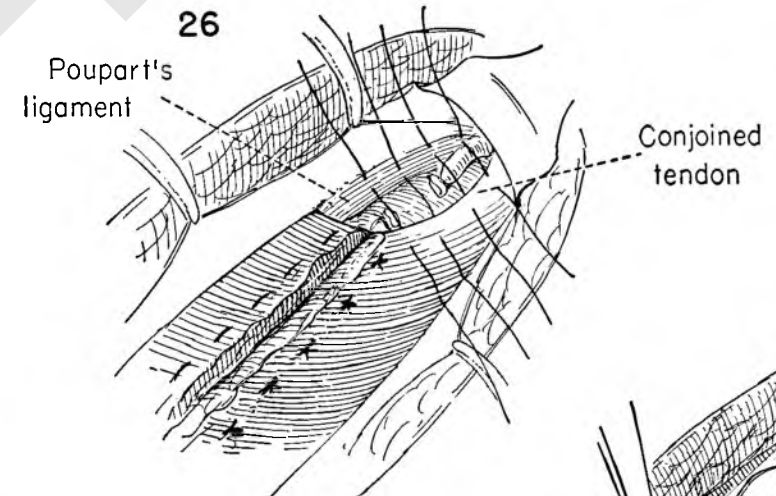
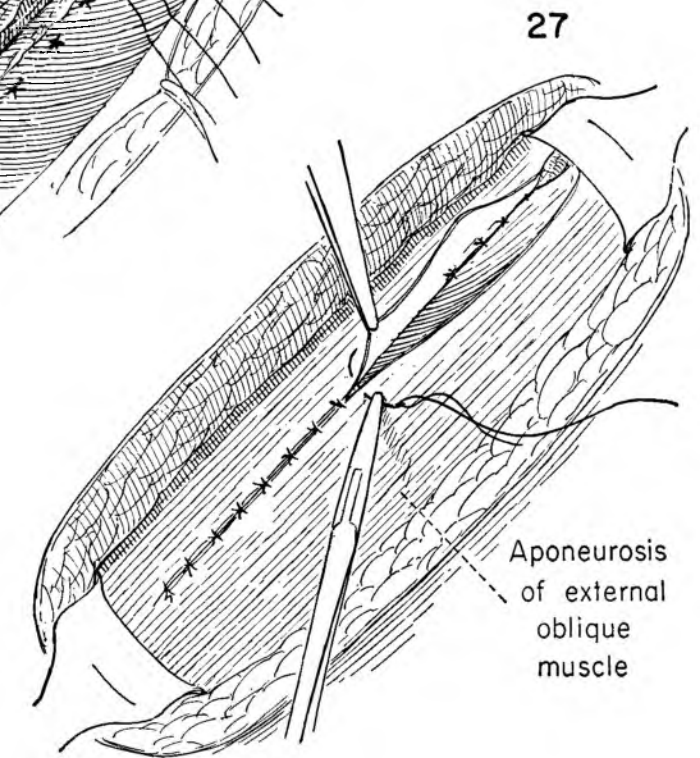


FIGURE 27. The incision in the external oblique fascia is then closed with interrupted sutures of silk or cotton. The fat and skin are separately closed. Exactly the same procedure is done on the right side, now or at a subsequent operation.



VULVECTOMY

Many of the patients on whom a vulvectomy and node dissection must be performed are in the older age group who for one reason or another may not be able to withstand the rigors of the extended dissections performed in one or even two stages.

It is possible to achieve the same ultimate aim of complete removal of the regional lymphatics, intervening channels and primary tumor by further dividing the staging into a primary attack on the vulva (Plates 189 to 191) followed by separate dissections of the regional nodes (Plates 192 to 197).

It is important to remember that the sum total of all stages should be the equivalent of a complete primary operation.

FIGURE 1. The patient is in the lithotomy position. Wide margins are given to the growth. An incision is made beyond the labia extending around the vulva from above the mons to the fourchette on both sides.

FIGURE 2. With the skin incision outlined the vaginal epithelium is exposed by placing the labia on tension and holding the vaginal wall toward the midline. An incision is then made beginning above the urethra and extending down along the inner wall of the vagina on both sides.

FIGURE 3. The skin edges are retracted and the vulva mass reflected toward the midline as the incision is carried downward on either side until the fascia overlying the symphysis and the muscles attaching to the pubic rami are reached.

FIGURE 4. The symphysis has been cleaned, and the suspensory ligament of the clitoris is being divided.

FIGURE 5. Exposure with the rake retractors continues as the surgeon draws the mass down off the symphysis and separates some of the attachments from the under surface of the symphysis with the handle of the knife.

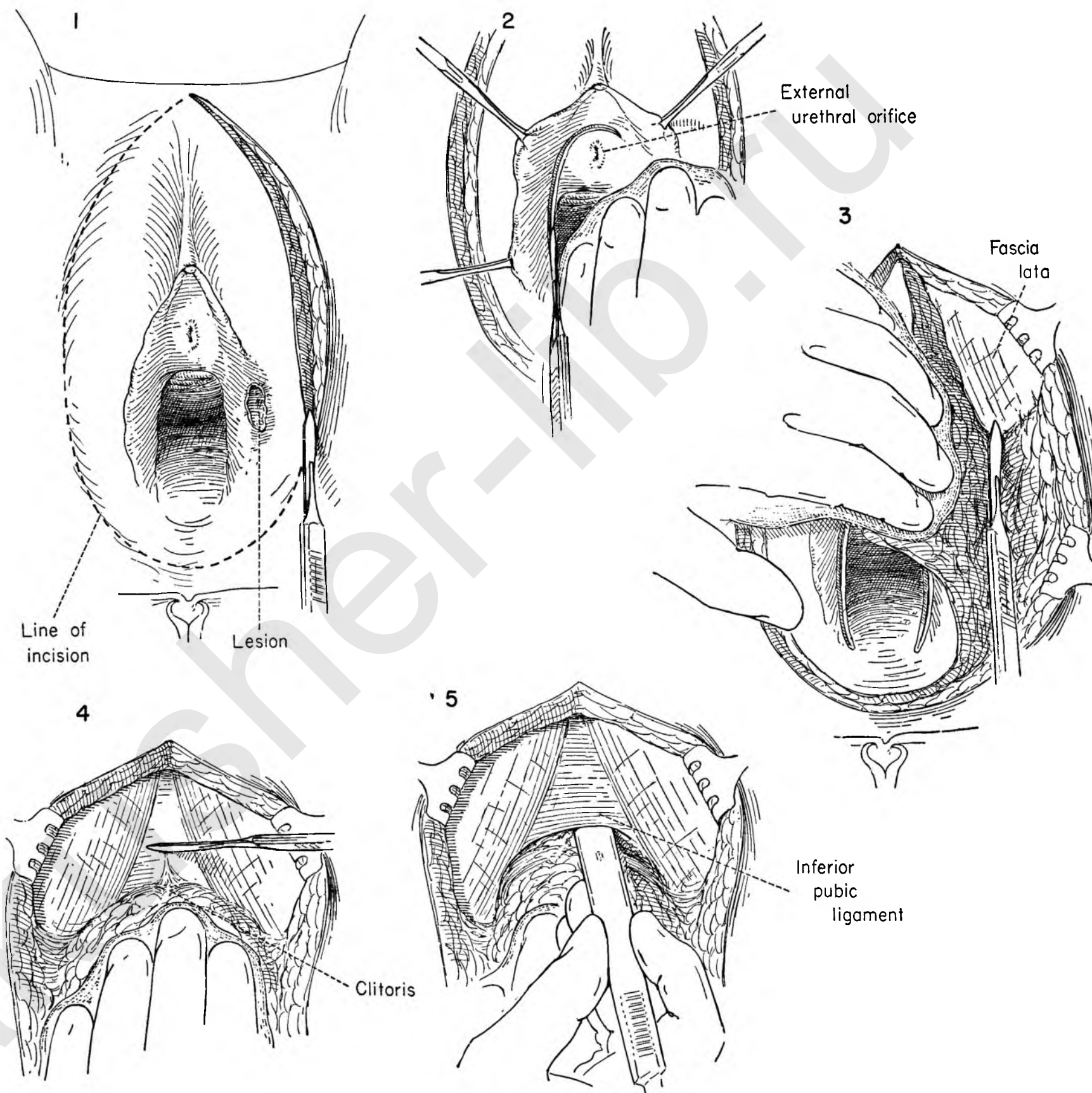


FIGURE 6. The dissection is carried downward on either side into the posterior quadrants where the pudendal vessels are identified, clamped, cut, and ligated.

FIGURE 7. Two Allis clamps held on equal tension now offer exposure under the flap, and the vaginal wall is undermined as for perineal repair, exposing levator muscles and the bulge of the rectum.

FIGURE 8. The lower edge of the specimen over the perineum is now grasped with Allis forceps and held on tension as the lateral attachments are cut.

FIGURE 9. On each side of the vulva the operation now has proceeded to a point where contact is made with the inner incision. The left index finger demonstrates this. It is a simple matter to carry this up and down, leaving the specimen attached only above at the urethra and at the posterior edge of the vagina.

FIGURE 10. An Allis clamp is placed on the tissue above the urethral meatus. The specimen is retracted upward and the urethra itself freed from it with the handle of the knife until one enters the area cleared from above.

FIGURE 11. It is then possible to retract the specimen forcibly to either side with the index finger.

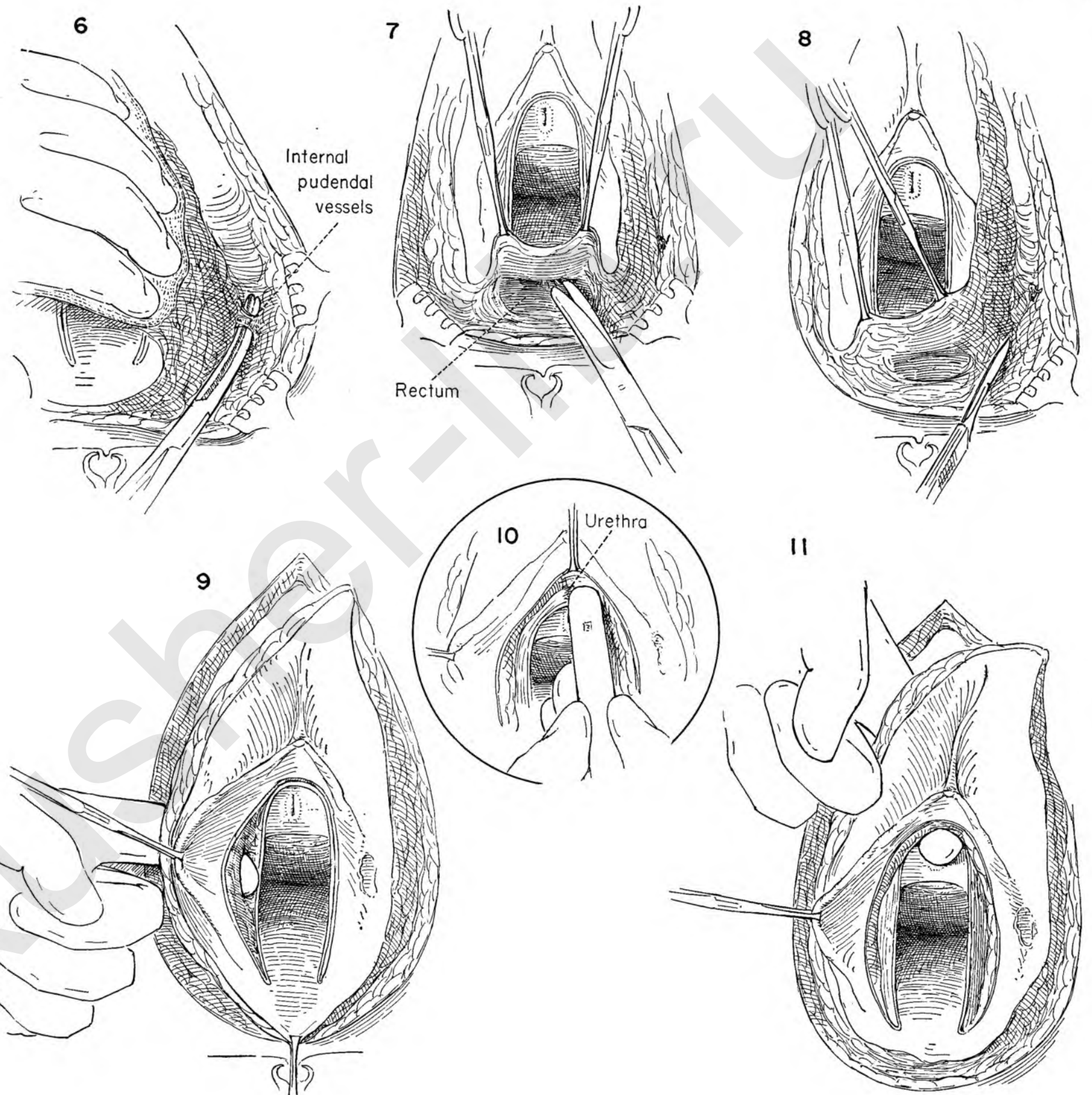


FIGURE 12. Retraction of the specimen exposes the remaining small muscular attachments on either side. Two clamps are applied in preparation for division between them. This is done on either side.

FIGURE 13. The specimen is now separated and falls downward, its only attachment being at the fourchette. This is then divided.

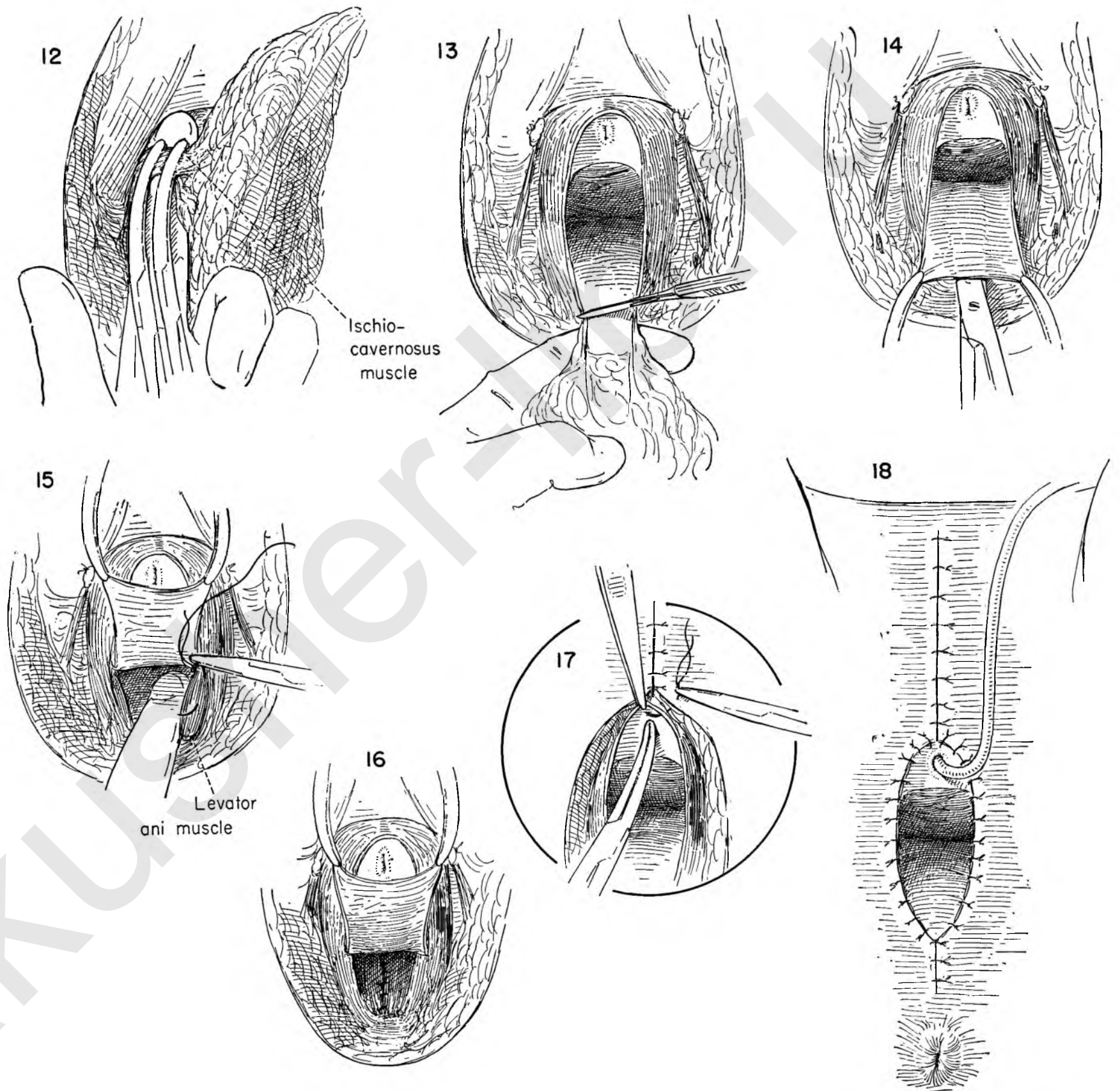
FIGURE 14. The posterior vaginal wall is held on tension with Kelly clamps while the surgeon completes its separation from the underlying rectum with the scissors as in the operation for perineal repair.

FIGURE 15. An assistant then exposes the levator muscles by holding the vaginal wall upward. Deep sutures of 0 chromic catgut are laid in place in the muscle at the point where they will approximate without tension.

FIGURE 16. This drawing shows the newly reconstructed perineal repair with the muscles approximated.

FIGURE 17. Closure can usually be accomplished under some tension, first bringing the skin together over the symphysis with interrupted sutures of braided silk which include both skin and underlying fat. The cut edge of the mucosa over the urethra and vagina is approximated to the skin with many interrupted silk sutures. The urethral opening is identified with a clamp if there is any question about the closure.

FIGURE 18. This illustration shows the completed closure with the patient ready to be returned to her bed, with the catheter on constant drainage.



RADICAL GROIN DISSECTION

This procedure resects the lymph nodes and lymphatics from the femoral, inguinal and deep iliac areas on one side. It completes the operation for cure of the primary lesion in the vulva, anus or vagina. The side on which the lesion arises should be dissected first. A similar procedure in the opposite groin is necessary, however, for the lymphatics are not strictly lateralized and cross metastasis has often been noted.

It should be planned so that no lymphatic pathways can be missed. In cancer of the vulva the radical groin dissection must deliberately enter the field of the prior vulvectomy.

FIGURE 1. Failure to heal per primam is common after this operation, and no incision or technique guarantees success. Here we have indicated an almost vertical skin incision which overlies the femoral artery and extends from the adductor canal to the left lower quadrant of the abdomen.

FIGURE 2. Leaving a thin layer of fat attached beneath the skin, the surgeon bevels steeply outward until the entire area for dissection has been undermined. Rake retractors aid in the exposure. The individual vessels are clamped and ligated.

FIGURE 3. This dissection exposes a mass of fat containing lymphatics and nodes, the removal of which is begun by dissecting it off the aponeurosis of the external oblique muscle down to Poupart's ligament.

FIGURE 4. The skin is retracted with the rakes and further undermined over the lateral aspect of the thigh.

FIGURE 5. The specimen is held with finger and gauze traction toward the midline by an assistant as the dissection is carried medially, exposing the fascia lata.

FIGURE 6. The attachment along the inguinal ligament is then freed, holding the mass on tension to facilitate dissection and keeping a weather eye open for the femoral artery. Small vessels are encountered, clamped and tied.

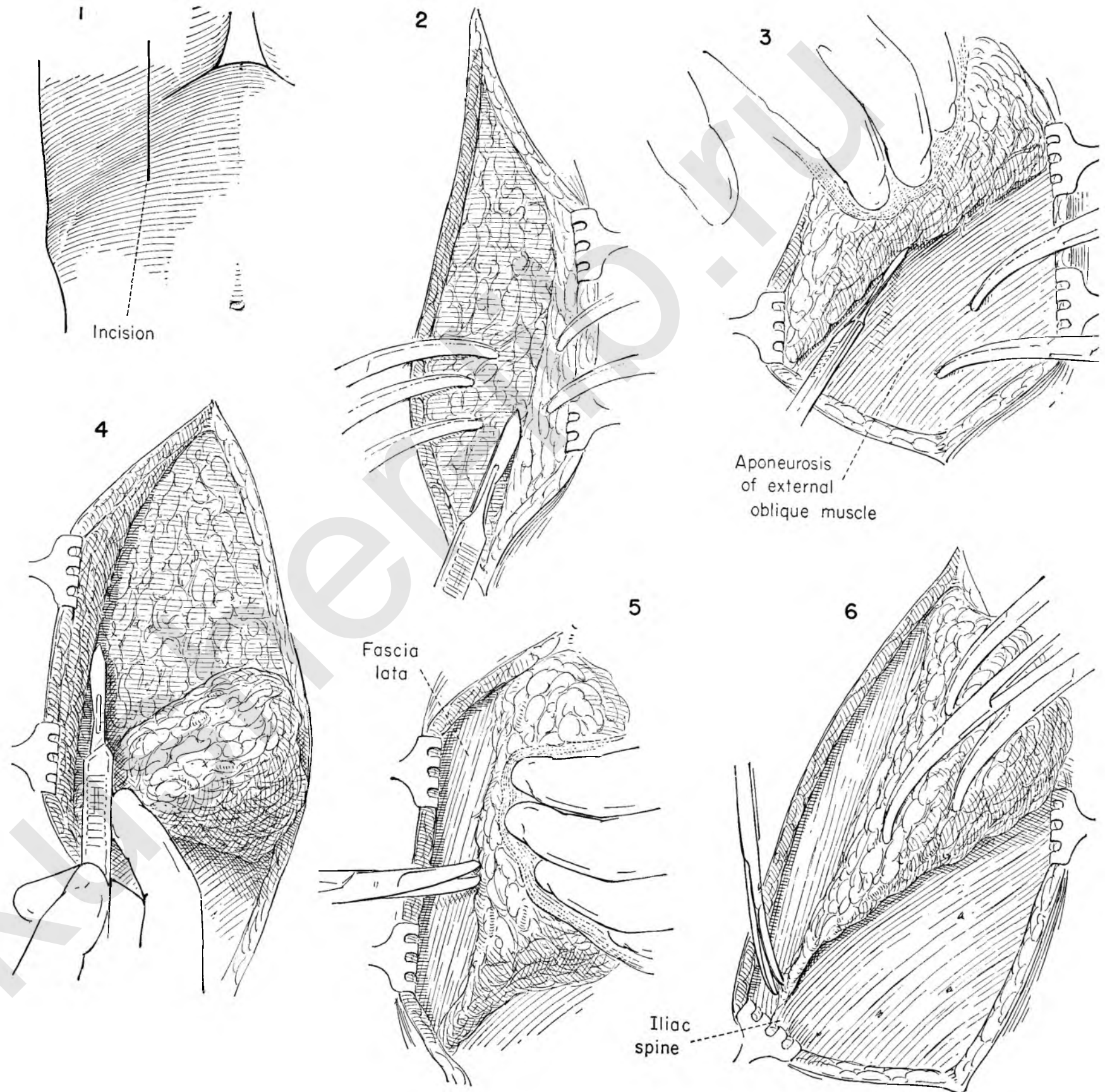


FIGURE 7. The saphenous vein is identified on the anterior medial surface of the deep fascia at the lower margin of resection. It is freed by blunt dissection and cut between clamps, and double ties are applied to the distal stump.

FIGURE 8. The aponeurosis of the sartorius muscle is incised vertically just lateral to the femoral artery. A narrow strip of muscle will be exposed. With the fascia held on tension between clamps the incision can be extended up and down and the dissection continued medialward. Proceeding in this plane, one ensures total removal of the contents of the femoral triangle except for the main artery and vein.

FIGURE 9. When the artery is reached, the femoral sheath is picked up with forceps and opened.

FIGURE 10. Clamps are applied to the edges of this sheath for traction and the artery cleaned as far upward as Poupart's ligament.

One constant branch of the femoral artery will be found entering the specimen. It runs transversely at the lower edge of the fossa ovalis and points the way to the saphenofemoral junction. It should be sought for, freed up and clamped.

FIGURE 11. This vessel is divided between clamps. Double ligatures replace the clamps.

FIGURE 12. The femoral vein is now exposed throughout its course and the saphenous vein easily demonstrated as it enters the mass of fat and nodes. It often breaks up at once into a number of branches which will be torn if care is not used in passing the clamp beneath it to free it up.

FIGURE 13. The saphenous vein is then divided and a catgut suture tied at its base, taking care not to tent the femoral lest its lumen be narrowed. A stitch ligature of silk is placed in the cuff above the level of the initial tie. The second tie is then made. The proximal clamp may be included in a stitch ligature or left on to provide traction on the mass.

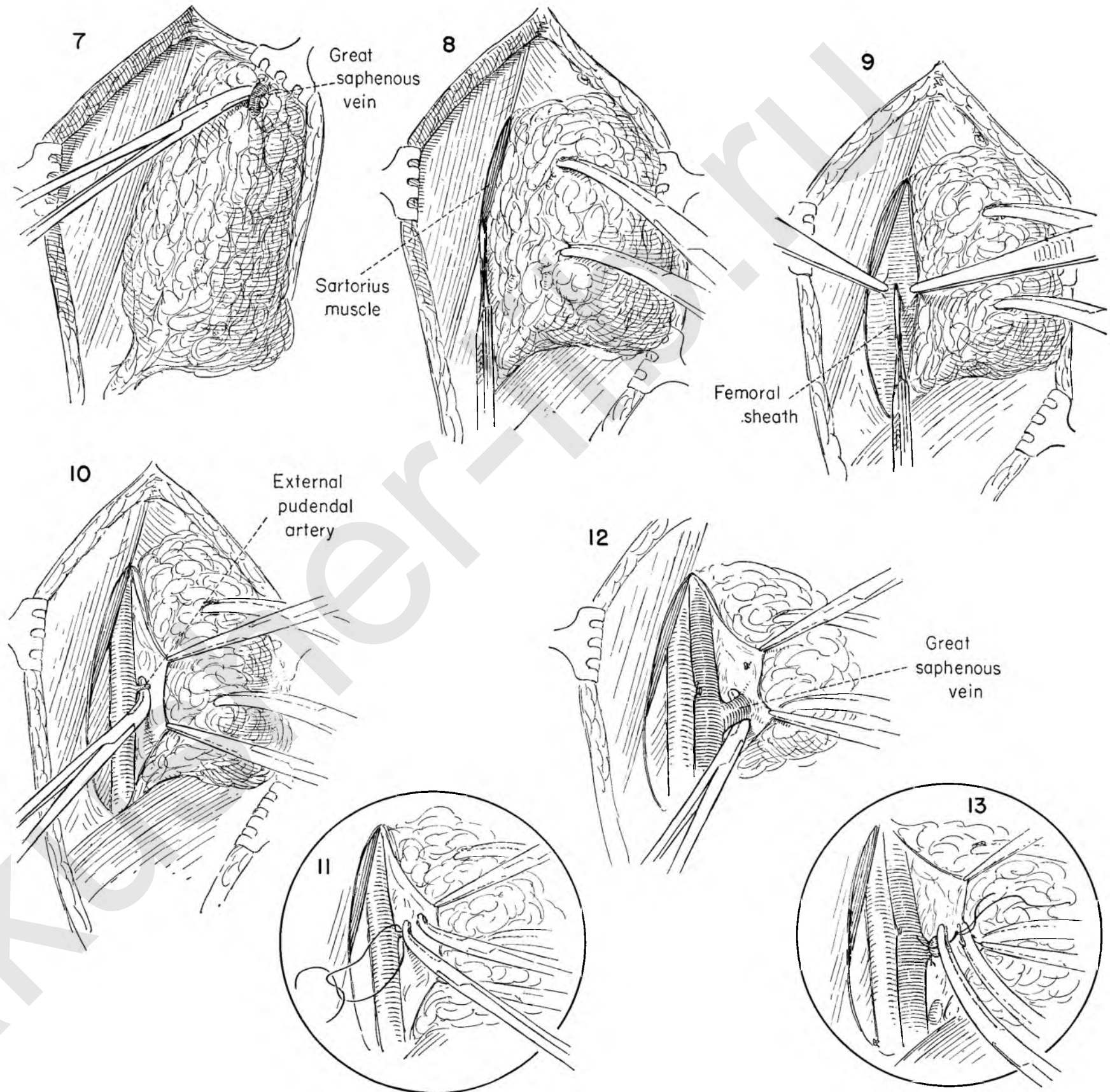


FIGURE 14. The mass has now been freed completely from the femoral vessels except for the femoral sheath which made up the compartments of the femoral canal. This sheath of tissue is held on tension and sectioned from below upward to Poupart's ligament.

FIGURE 15. Particular care is exercised at the upper end to remove the contents of a deep pocket where all lymphatics converge to pass medial to the femoral vein and join the deep chain of glands above Poupart's ligament.

FIGURE 16. The rest of the triangle is now easily cleaned of its contents and the pectineal fascia exposed.

FIGURE 17. The mass of fat and nodes is now held by the round ligament. This is then held on traction and all fatty tissue stripped away before clamps are applied to it.

FIGURE 18. The round ligament is divided and the proximal end secured with a stitch ligature.

FIGURE 19. The specimen narrows down to the point where it approaches the pubic symphysis. The dissection continues until the specimen comes away, free of all attachments, and the surgeon finds that he has entered an area previously dissected at the time of vulvectomy.

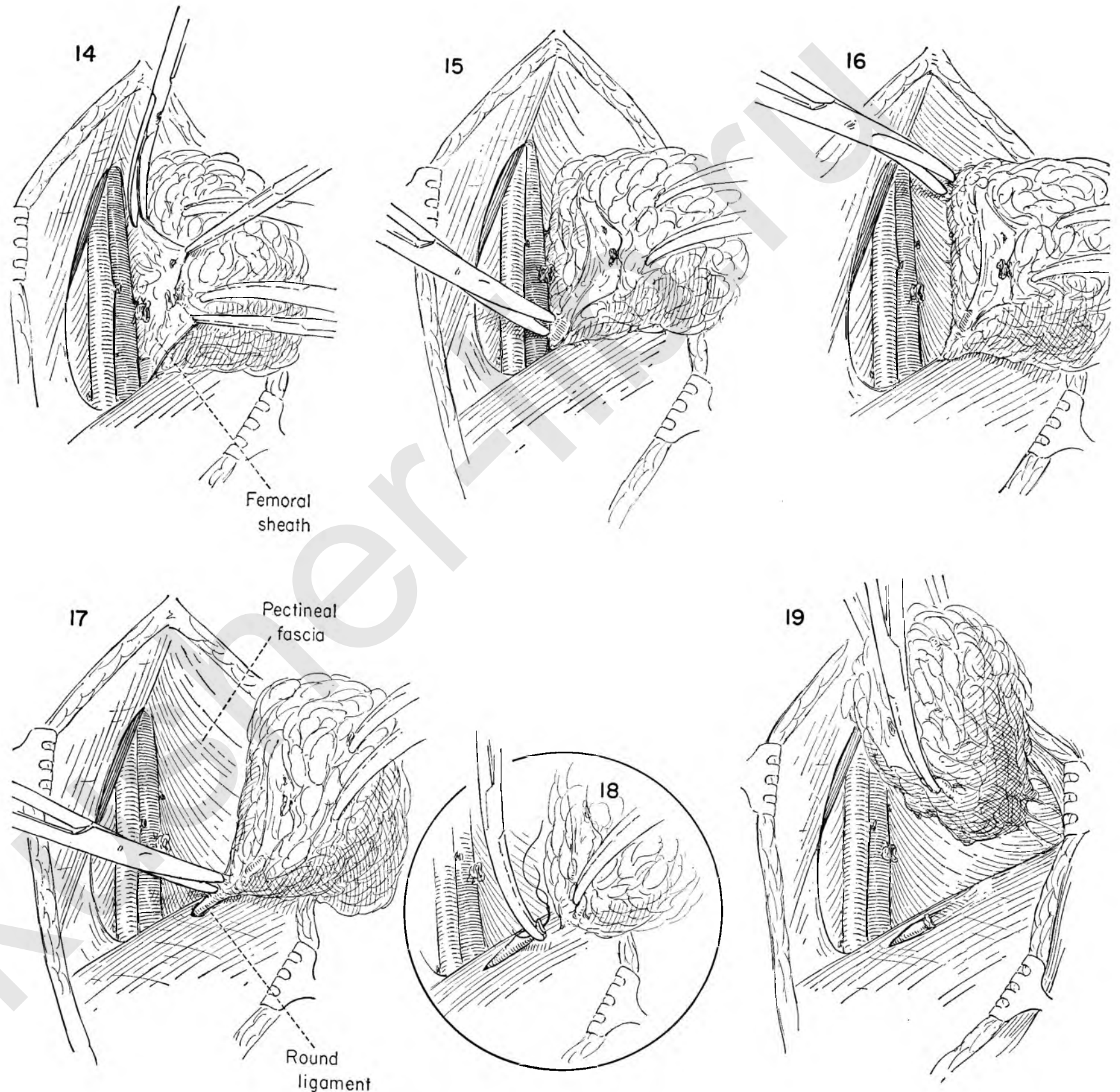


FIGURE 20. The exposed surfaces of the thigh are protected with gauze. The deep iliac dissection is identical with the procedure illustrated in Plates 184 through 188. Incision is made through the aponeurosis of the external oblique muscle from the external inguinal ring to the anterior-superior spine of the ilium.

FIGURE 21. The internal oblique muscle is exposed by freeing it from the aponeurosis of the external oblique muscle. It is freed from the underlying transversalis and cut parallel to the inguinal ligament about 1 inch above it.

FIGURE 22. The deep epigastric vessels are identified running medial to the stump of the round ligament. A clamp is placed beneath the artery, isolating it so that it may be divided and tied.

FIGURE 23. The vein is similarly clamped, cut and tied.

FIGURE 24. The thin transversalis fascia holding the peritoneum to Poupart's ligament is broken through with the tips of the fingers placed flat on the peritoneum and retracted upward with a raking motion. This may be accomplished bloodlessly.

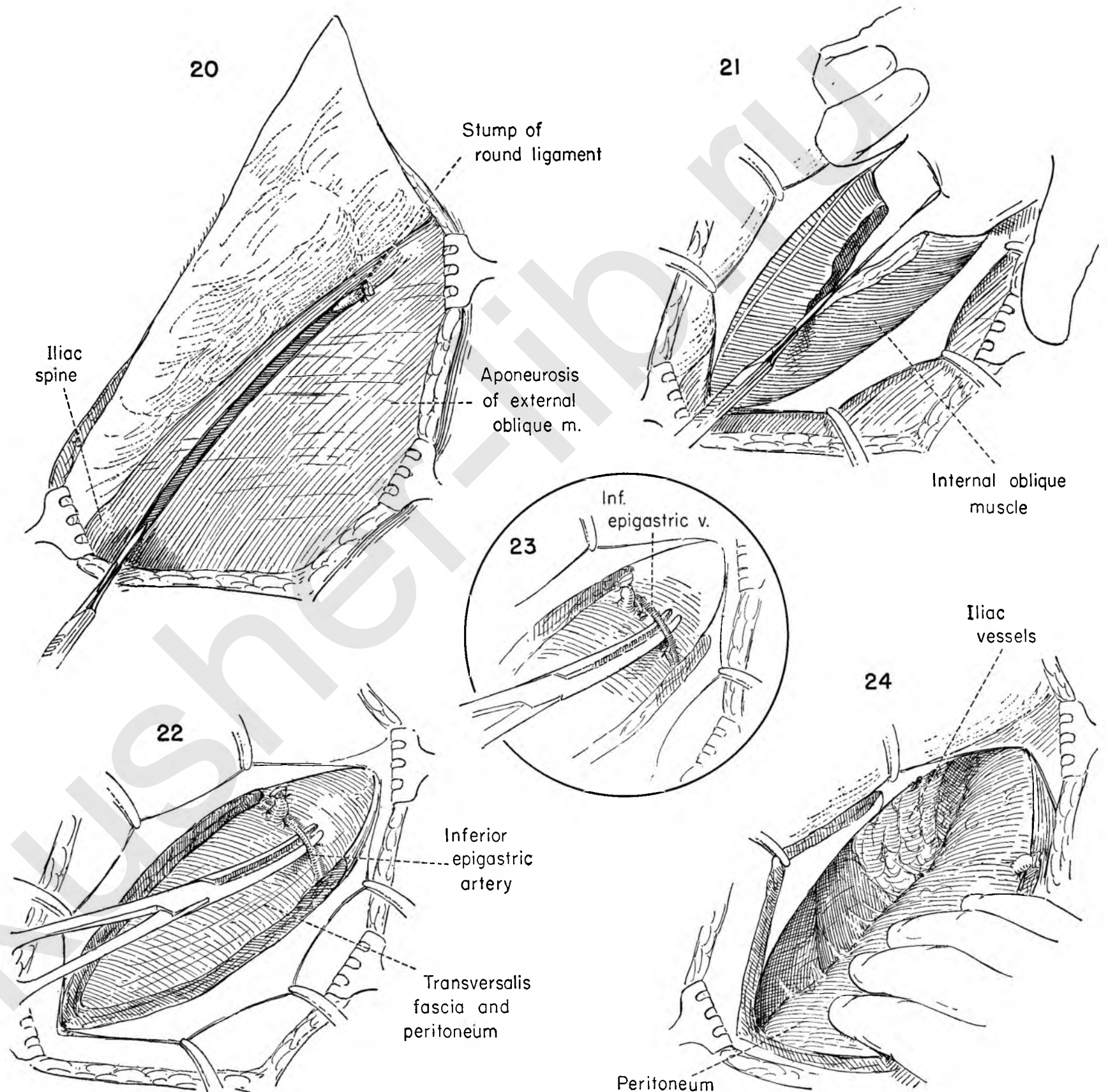


FIGURE 25. The bladder and peritoneum are held back by Deaver retractors to provide satisfactory exposure. The dissection begins well out on the psoas muscle, and the mass of fat and nodes is mobilized medially, exposing the external iliac artery. The dissection continues downward along the lateral side of the artery.

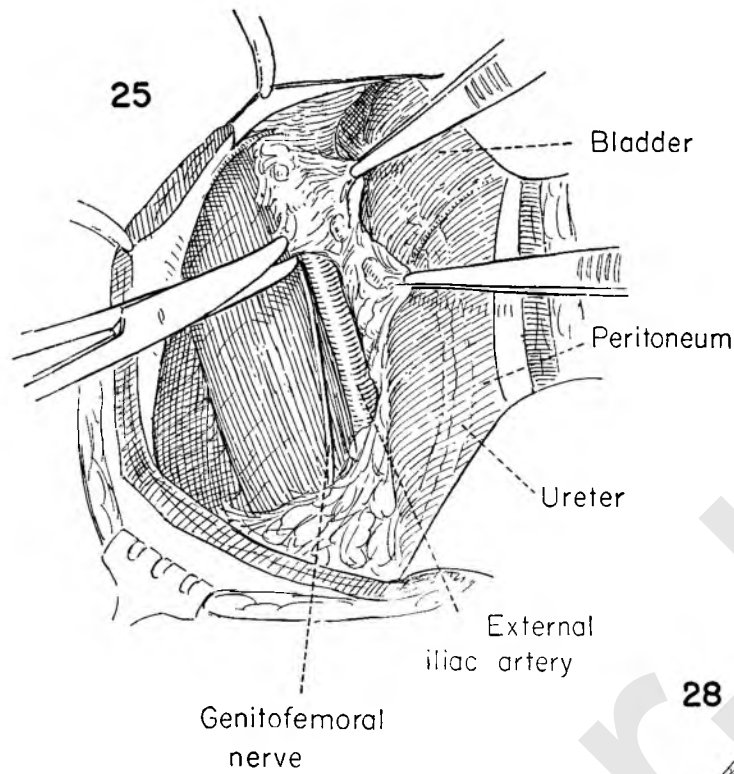


FIGURE 26. The dissection of the external iliac artery has been completed up to the bifurcation. All tissue lying between artery and vein has been removed, and the specimen is now being separated from the medial surface of the vein itself. The circumflex iliac vessels can be seen clean of all tissue at Poupart's level.

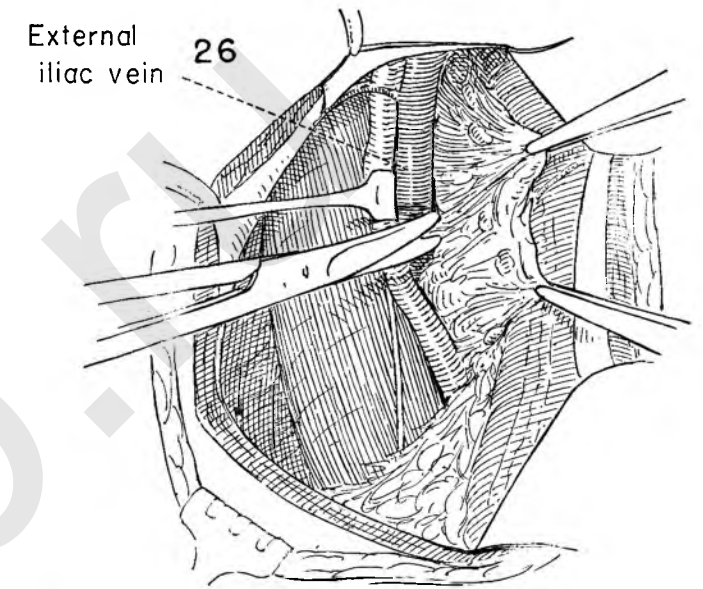


FIGURE 27. The specimen is divided as it crosses the bifurcation of the iliac artery for convenience in removal.

Traction on the upper Deaver retractors provides additional exposure to facilitate the removal of the nodal chain lying lateral to the common iliac artery. An arbitrary division point is made in the upper part of the field and this block of tissue removed.

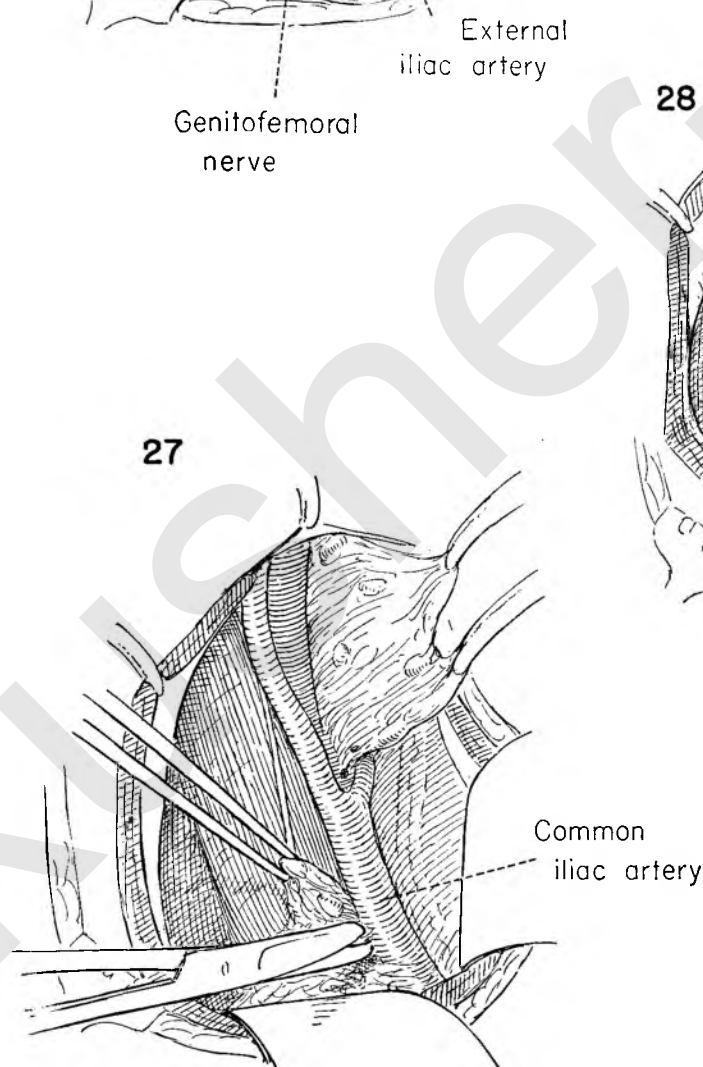


FIGURE 28. The nodal mass already freed from the external iliac vessels is held medially and dissected from the under surface of the vein, thus entering the obturator space.

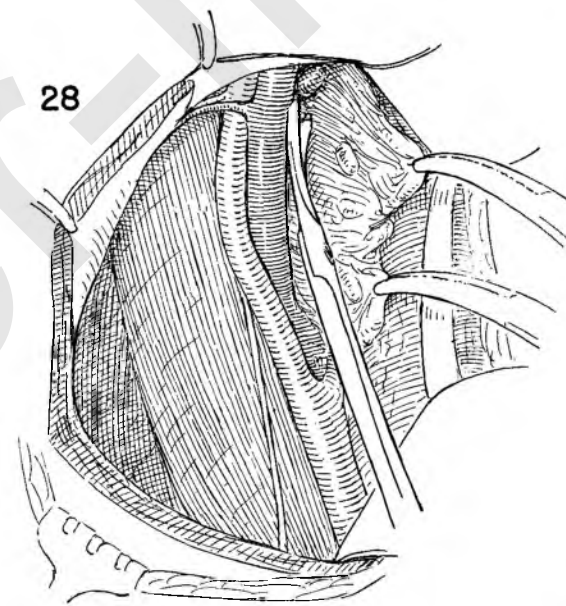


FIGURE 29. Once freed, the mass is held laterally and cut free to permit the dissection along the lower border of the external iliac vein. This accomplishes its removal as distinct from the contents of the obturator fossa.

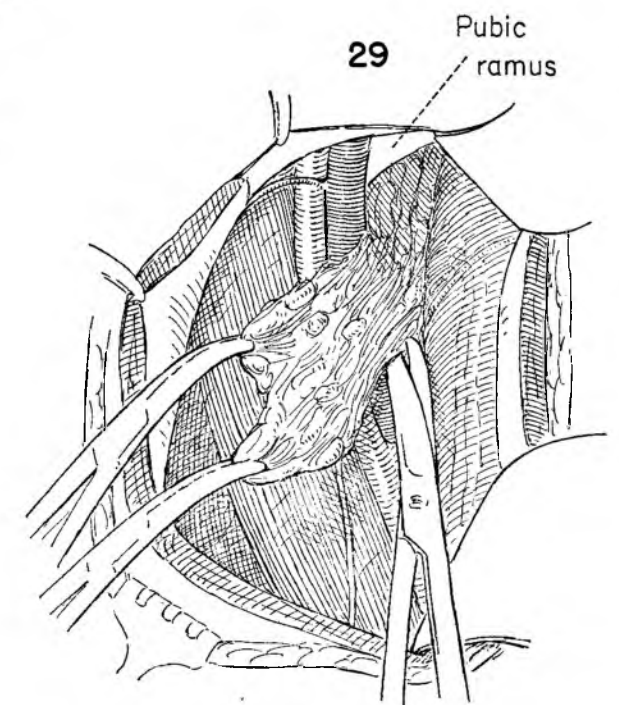


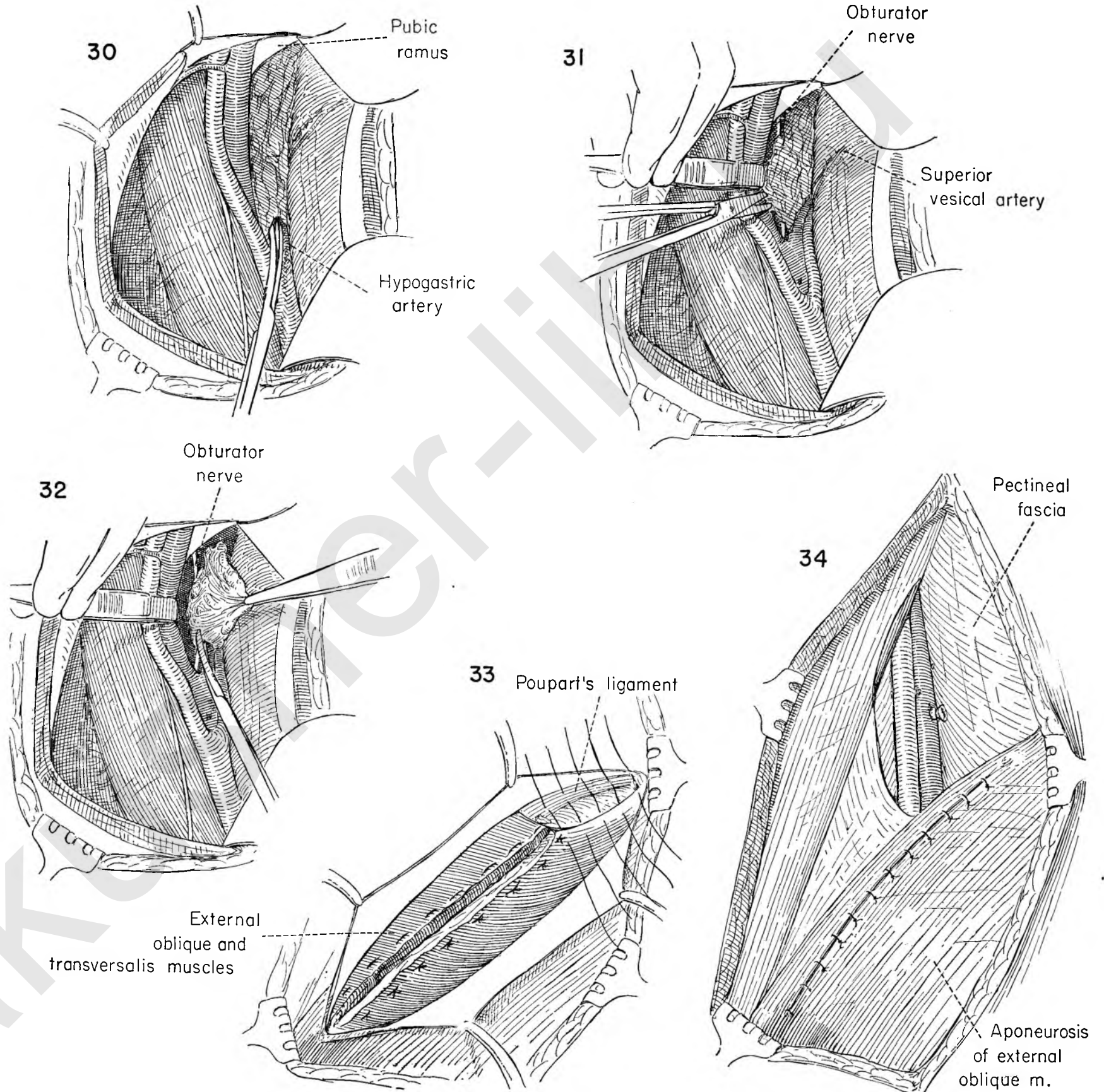
FIGURE 30. The surgeon then carefully dissects downward along the lateral surface of the internal iliac artery to begin the separation of the obturator lymphatics. Beware of the internal iliac vein, which lies just beneath.

FIGURE 31. The external iliac vein is then retracted laterally with the handle of the forceps and the fat and nodes dissected from its under surface. The obturator nerve is now visible, completely surrounded by the mass of obturator nodes and fat.

FIGURE 32. The pelvic wall has been reached and all fat reflected medially with the obturator nerve. The external iliac vein is held back with the handle of the forceps as the surgeon draws the mass medially and separates it from the nerve.

FIGURE 33. All packs and retractors are removed, the peritoneum is allowed to fall back into place, and the internal oblique muscle approximated with deep horizontal mattress sutures of silk or cotton.

FIGURE 34. This illustration shows the closure of the external oblique fascia above and the area of the femoral groin dissection below. The skin is now closed without drainage and a firm pressure spica type dressing applied. This dressing is of utmost importance, for a large subcutaneous space has been left in which fluid will accumulate. Uniformly distributed pressure in the dressing will aid in minimizing this complication. It has not been our practice to drain the wound.



Index of Subjects

ABDOMEN

- cavity, exploration before total hysterectomy, 11
 - closure after total hysterectomy, 22
 - exploration before total hysterectomy, 13
 - operations, 1-111
 - anesthesia for, 3
 - complications following, 105
 - conservative, 35
 - postoperative management, 5
 - preliminary considerations, 3-5
 - preoperative preparation, 3
 - postoperative distention, 105
 - upper, exploration, 4
 - wall, defects of, repair, 89
 - operations on, 89
 - Pfannenstiel incision, 90, 91
 - transverse incision for, 92-94
- Abdominal. See also *Abdomen*.
- and perineal resection of rectum. See *Miles operation*.
 - and vaginal procedures, combined, 155
 - and vaginal repair of enterocele, 156
 - hysterectomy. See under *Hysterectomy*.
- Abscess, pelvic
- drainage, 105
 - retroperitoneal, 105, 109
 - through rectum, 105, 111
 - through vagina, 105, 110
- Adnexa, uterine
- mobilization, 4
 - before abdominal hysterectomy, 13
 - peritonealization after removal of, 25
- Advancement of bladder, 117, 124-127
- Ambulation, early, after abdominal surgery, 5
- Amputation of cervix, low, 173, 176, 177
- Anastomosis
- and resection of large bowel, 70, 71
 - end-to-end, and resection of small bowel, 66, 67
 - in intestinal resection, 59
 - side-to-side, and resection of small bowel, 64, 65
 - in intestinal resection, 59
 - uretero-intestinal, 75, 83-85
- Anesthesia
- curettage under, 3
 - examination under, 3
 - for abdominal hysterectomy, 13
 - for abdominal surgery, 3
 - in perineal operations, 115
 - in vaginal operations, 115
- Anesthetist, position for pelvic operations, 4
- Appendectomy, 59, 74
- Assistants, surgical, position for pelvic operations, 5

- BALDY-WEBSTER suspension operation, 35, 39
- Bartholin's gland, cyst of, excision, 173, 179
- Basal metabolism, preoperative investigation, 3
- Biopsy of cervix, 173, 174
- Bladder
- advancement, 117, 124-127
 - damage to, extensive, 75
 - repair of, 75, 76
 - dysfunction, postoperative, management of, 5
 - flap development for abdominal hysterectomy, 13
 - injury to, avoidance in abdominal hysterectomy, 13
 - mobilization from cervix in abdominal hysterectomy, 13
 - separation from cervix in abdominal hysterectomy, 13, 18
 - transplantation of ureter into, 75, 80-82
- Blood studies before perineal and vaginal operations, 115
- Bowel
- adherent, freeing before total abdominal hysterectomy, 11
 - large, resection and end-to-end anastomosis, 59, 70, 71
 - preoperative chemotherapy, 3
 - small, damage to, repair of, 59, 60
 - isolation and resection of loop of, 65
 - obstruction of, enteroenterostomy for, 62, 63
 - resection, and end-to-end anastomosis, 66, 67
 - and side-to-side anastomosis, 64, 65
- CANCER
- of cervix, Wertheim hysterectomy with pelvic lymphadenectomy, 185
 - of rectum, Miles resection for, 186
 - of vulva, radical groin dissection for, 222-227
 - operations for, combinations of, 187
 - pelvic, surgery of, 183-227
 - basic concepts, 185
- Catheter, Foley, in Marshall-Marchetti operation, 28
- Catheterization
- for abdominal hysterectomy, 13
 - total, 6
 - postoperative, 5
- Cauterization of cervix, 173, 175
- Cervical. See *Cervix*.
- Cervix
- amputation, 173, 176, 177
 - biopsy, 173, 174
 - cancer of, Wertheim hysterectomy with pelvic lymphadenectomy, 185
 - cauterization, 173, 175
 - conization, 173, 175
 - curettage for total abdominal hysterectomy, 7
 - examination for total abdominal hysterectomy, 6

Cervix (Continued)

- fascia, anterior, splitting of, 34
 - in total hysterectomy, 23
 - fibroid, hysterectomy in presence of, 23, 30, 31
 - mobilization from bladder in abdominal hysterectomy, 13
 - separation from bladder in total abdominal hysterectomy, 18
 - stump of, excision, 118, 146
- Chemotherapy, preoperative, of bowel, 3
- Childbearing function, preservation of, myomectomy for, 41
- Clamp, Kelly, for traction in abdominal hysterectomy, 12, 13
- Cleavage plane, subvaginal, 115
- Closure of vaginal apex, 34
- Colostomy, 72
- closure of, 59, 73
 - ileotransverse, 59
 - sigmoid, terminal, emergence through abdominal incision, 196
- Complications
- following abdominal operations, 105
 - of abdominal surgery, management, 5
- Conization of cervix, 173, 175
- Cornual resection of fallopian tube, 58
- Cul-de-sac, peritonealization of defects in, 33
- Curettage
- and examination under anesthesia, 3
 - cervical, for total abdominal hysterectomy, 7
 - for abdominal hysterectomy, 13
 - pelvic, 117
- Cyst
- endometrial, removal from ovary, 48
 - interligamentous, 45
 - excision of, 50, 51
 - of Bartholin's gland, excision, 173, 179
 - ovarian. See under *Ovary*.
- Cystocele
- correction by V incision of anterior vaginal wall, 23
 - repair, 117, 128, 129
- Cystotomy, suprapubic, 75, 76, 77
- DEHISCENCE and resuture after abdominal operations, 105, 108
- Diagnosis, accuracy of, as part of preoperative preparation, 3
- Diastasis recti, 89
- repair of, 104
- Dilatation of vagina, 121-123
- Dissection
- of groin, radical, 222-227

Dissection (Continued)

- plastic of fimbriated end of fallopian tube, 57
- Diverticulum, Meckel's. See *Meckel's diverticulum*.
- Donald operation, 130-133
- ELECTROCARDIOGRAM, preoperative, 3
- Electrolyte
- management, postoperative, 5
 - studies, preoperative, 3
- Endometrial. See *Endometrium*.
- Endometriosis
- extensive, excision of, 35, 36, 37
 - management, conservative, 35
 - ovarian, fixation of tissues in, 4
- Endometrium
- cyst of, removal from ovary, 48
 - implants in, excision of, 35, 36
- Enterocoele, 118
- vaginal and abdominal repair, 156
 - vaginal, posterior, 155
 - vaginal repair, 152, 153
- Enteroenterostomy, 59
- side-to-side, 62, 63
- Examination
- and curettage under anesthesia, 3
 - of cervix for total abdominal hysterectomy, 6
 - of vagina for total abdominal hysterectomy, 6
- Excision
- of cervical stump, 118, 146
 - of cyst of Bartholin's gland, 173, 179
 - of endometrial implants, 35, 36
 - of endometriosis, extensive, 35, 36, 37
 - of Meckel's diverticulum, 61
 - of ovarian cysts, small, 45
 - of vaginal wall, anterior, for correction of cystocele, 23
- Exenteration procedures, 187
- Exploration
- of abdominal cavity before total hysterectomy, 11
 - of upper abdomen, 4
- Extraperitoneal
- iliac lymphadenectomy, 214-218
 - node dissection, 186
- FALK tubal exclusion procedure, 45, 54
- Fallopian tube
- and ovary, removal with hysterectomy, 24, 25
 - cornual resection, 58
 - excision of fimbriated end, 56, 57
 - fimbriated end, dissection, plastic, 57
 - operations on, 45
 - patency, restoration by plastic operation, 55
 - removal as part of hysterectomy, 23

- Fascia**
 cervical, anterior. See under *Cervix*.
 exposure for total abdominal hysterectomy, 9
 lata in reinforcement of hernia repair, 97
 Fascial repair of incisional hernia, 89
- Femoral**
 hernia. See under *Herniorrhaphy*.
 vein ligations, superficial, 105, 106, 107
- Fibroid, cervical, hysterectomy in presence of, 23, 30, 31**
- Fistulae**
 rectovaginal, near anal sphincter, 172
 repair, 163, 171
 repair of, operations for, 163
 urinary, prevention of, 186
 vesicovaginal, drainage, postoperative, 163
 exposure, 163
 mobilization of bladder wall and fistulous opening, 163
 repair, through abdominal cavity, 163, 168-170
 transvesical, 163, 166, 167
 vaginal, 163, 165
 Schuchardt incision for exposure of, 164
 uretero-intestinal anastomosis for, 83-85
- Fixation**
 of tissues, in ovarian endometriosis, 4
 in pelvic inflammation, 4
- Foley catheter in Marshall-Marchetti operation, 28**
- Fothergill operation, 130-133**
- GLAND, Bartholin's, cyst of, excision, 173, 179**
- Graft, omental, reperitonealization by, 35, 37**
- Groin dissection,**
 radical, 222-227
 superficial, bilateral, and radical vulvectomy, 186, 203-213
 unilateral, 187
- HEMATOLOGIC examination, preoperative, 3**
- Hemorrhoidectomy, 119, 154**
- Hernia. See also *Herniorrhaphy*.**
 vaginal, posterior, 155
 vaginal wall, posterior, 118
- Herniorrhaphy**
 femoral, 89, 99, 100
 inguinal and combined approach, 100, 101
 incisional, 89, 95, 96
 inguinal, 89, 98
 reinforcement by fascia lata, 97
 umbilical, 89, 102, 103
- Hysterectomy**
 abdominal, avoidance of injury to bladder or ureter, 13
 bladder flap development, 13
 catheterization for, 13
 division and ligation of ovarian ligament, 13
 examination under anesthesia, 13
 exploration of abdomen before, 13
 helpful hints for, 13
 inspection of uterus and ovary, 13
 mobilization of intestine out of pelvis, 13
- Hysterectomy (Continued)**
 mobilization of uterus and adnexa before, 13
 peritoneal incision for, 13
 protection of rectum against injury, 13
 total, 6-22
 catheterization for, 6
 cervical curettage, 7
 cervical examination, 6
 circumcision of peritoneal attachments of uterus, 16
 closure of abdomen, 22
 exploration of abdominal cavity before, 11
 fascial exposure for, 9
 freeing of adherent bowel and omentum before, 11
 freeing of pyramidalis muscle, 9
 freeing of uterus, 19
 incision for, 8
 inspection of uterus, 21
 Kelly clamp for, 12
 management of uterine vessels, 17
 mobilization of adherent uterus and adnexa, 23
 modifications of, 23
 peritoneal exposure for, 9
 peritoneal incision for, 10
 peritonealization, 20, 23
 positioning of patient, 8
 reconstructive steps, 20
 repair of omentum, 21
 retractor, self-retaining, application, 12
 separation of cervix from bladder, 18
 sigmoid placed in cul-de-sac, 21
 splitting of anterior cervical fascia, 23
 sponge count, 21
 steps in simplification of technique, 14
 tenaculum applied to uterine fundus, 12
 vaginal examination, 6
 vaginal prolapse after, 155, 157-159
 traction for, 13
 without removal of tubes and ovaries, 15
 in presence of cervical fibroid, 23, 30, 31
 removal of ovary and tube with, 23, 24, 25
 supracervical, 23, 26, 27
 vaginal, 117, 134-140
 Wertheim. See *Wertheim hysterectomy*.
- ILEOCOLOSTOMY, 68, 69**
- Ileotransverse colostomy, 59**
- Ileus, postoperative, 5**
- Iliac lymphadenectomy, extraperitoneal, 214-218**
- Implants, endometrial, excision of, 35**
- Incision**
 exploratory, of ovary, 52
 for total abdominal hysterectomy, 8
 of peritoneum for total abdominal hysterectomy, 10
 paramedian, for operations on abdominal wall, 89
 Pfannenstiel, 89
 Schuchardt, for exposure of vesicovaginal fistula, 164
 transverse, closure of, 94
 for operations on abdominal wall, 89, 92-94
- Incisional hernia, fascial repair of, 89, 95, 96**
- Incontinence, stress**
 Kennedy repair for, 118, 141
 Marshall-Marchetti operation for, 23, 28, 29
 sling operation for, 160-162
- Inflammation, pelvic, fixation of tissues in, 4**
- Inguinal hernia, repair of, 89, 98**
- Inhalation anesthesia for abdominal surgery, 3**
- Interligamentous cysts, 45, 50, 51**
- Intestine**
 mobilization before abdominal hysterectomy, 13
 operations involving, 59
 small, damage to, repair of, 59
 resection, and end-to-end anastomosis, 59
 with side-to-side anastomosis, 59
- Irving method of sterilization, 45, 53**
- KELLY clamps for traction in abdominal hysterectomy, 12, 13**
- Kennedy repair for stress incontinence, 118, 141**
- LE FORT method of obliterating vagina, 118, 142, 143**
- Levator muscles, reconstruction after groin dissection and vulvectomy, 213**
- Ligaments**
 round and ovarian, division and ligation in abdominal hysterectomy, 13
 uterosacral, shortening of, 35, 40
- Ligation of superficial femoral vein, 105, 107**
- Lymph node dissection, extraperitoneal, 186**
- Lymphadenectomy**
 iliac, extraperitoneal, 214-218
 pelvic, bilateral, with Wertheim hysterectomy, 185, 188-195
- MACARTHUR modification of inguinal herniorrhaphy, 89**
- Malignancy**
 pelvic, uretero-intestinal anastomosis in, 83-85
- Malignant disease**
 operations for, 183-227
 preliminary investigation, 185
- Malpositions of uterus. See under *Uterus*.**
- Manchester-Fothergill operation, 117, 130-133**
- Marshall-Marchetti operation, 23, 28, 29**
- Meckel's diverticulum, 59**
 excision, 61
- Metabolism, basal, preoperative investigation, 3**
- Miles operation, 186, 196-202**
 bowel dissection, 197
 closure of peritoneum, 200
 incision for terminal sigmoid colostomy, 196
 ligation of blood vessels, 197
 perineal stage, 201
 resection of colon, 202
 transection of bowel, 199
- Miller-Abbott tube in preoperative preparation, 3**
- Minor operations, 173**
- Mobilization of uterus and adnexa in abdominal hysterectomy, 4, 23, 32, 33**
- Muscle, pyramidalis, freeing in total abdominal hysterectomy, 9**
- Myomectomy, 35, 41**
- NEURECTOMY, presacral, 35, 42-44**
- Node dissection, extraperitoneal, 186**
- Nurses, position for pelvic operation, 5**
- OLSHAUSEN suspension operation, 35, 38**
- Omental graft, reperitonealization by, 35, 37**
- Omentum**
 adherent, freeing before total abdominal hysterectomy, 11
 repair after total abdominal hysterectomy, 21
- Oophorectomy, 45, 49**
- Operating team, positioning of, 4**
- Orders, postoperative, for abdominal surgery, 5**
- Ovarian. See also *Ovary*.**
 endometriosis, fixation of tissues in, 4
 ligament, division and ligation for abdominal hysterectomy, 13
- Ovary**
 and tube, removal with hysterectomy, 24, 25
 cyst, removal by oophorectomy, 49
 small, excision of, 45, 48
 incision of, exploratory, 52
 inspection in abdominal hysterectomy, 13
 operations on, 45
 removal of, as part of hysterectomy, 23
 removal of endometrial cyst from, 48
 wedge resection, 45, 52
- PAIN, postoperative, management of, 5**
- Paramedian incision for operations on abdominal wall, 89**
- Pathology, unexpected, and preoperative preparation, 3**
- Patient, positioning**
 for examination before total abdominal hysterectomy, 6
 for total abdominal hysterectomy, 8
- Pelvis**
 curettage, 117
 examination, 117
 inflammation of, fixation of tissues in, 4
- Perineal**
 and vaginal operations, 113-181
 operations, anatomical considerations, 115
 anesthesia in, 115
 blood studies before, 115
 postoperative management, 115
 preliminary considerations, 115
 preoperative measures, 115
- Perineal repair, simple, 147**
- Perineorrhaphy, simple, and repair of cystocele, 118**
- Perineum, tear of, third degree, repair of, 150, 151**
- Peritonealization**
 after removal of adnexa, 25
 in total abdominal hysterectomy, 20
 of defects in cul-de-sac, 33
 of large raw surface in total hysterectomy, 23

- Peritoneum**
 exposure for total abdominal hysterectomy, 9
 incision for abdominal hysterectomy, 10, 13
Pfannenstiel incision, 89
 closure, 91
 for operations on abdominal wall, 90, 91
Plastic operations
 for restoration of tubal patency, 55
 on fallopian tube, 45
Pomeroy method of sterilization, 45, 53
Positioning
 of operating team, 4
 of patient, for examination before total abdominal hysterectomy, 6
 for total abdominal hysterectomy, 8
Postoperative management of abdominal surgery, 5
Preoperative preparation for abdominal surgery, 3
Presacral neurectomy, 35, 42-44
Prolapse of vagina. See under *Vagina*.
Pulmonary embolism or infarct, prophylactic femoral vein ligation, 106, 107
Pyramidalis muscle, freeing for total abdominal hysterectomy, 9
- RECTOCELE repair**, 148, 149
 and simple perineorrhaphy, 118
Rectum
 abdominal and perineal resection. See *Miles operation*.
 cancer of, Miles resection for, 186
 resection for, 196-202. See also *Miles operation*.
 protection against injury in abdominal hysterectomy, 13, 16
Reperitonealization by omental graft, 35, 37
Resection
 abdominal and perineal, of rectum. See *Miles operation*.
 and anastomosis of large bowel, 70, 71
 and end-to-end anastomosis of large bowel, 59
 and end-to-end anastomosis of small intestine, 59, 66, 67
 and side-to-side anastomosis of small intestine, 59, 64, 65
 Miles, for cancer of rectum, 186
 of anterior vaginal wall, 34
 wedge, of ovary, 45
- Retractor, self-retaining, application for total abdominal hysterectomy**, 12
Roentgenogram, chest, preoperative, 3
Round ligament, division and ligation in abdominal hysterectomy, 13
- SALPINGECTOMY**, 45, 47
Salpingo-oophorectomy, 45, 46
Schuchardt incision for exposure of vesicovaginal fistula, 164
Sigmoid placed in cul-de-sac after total abdominal hysterectomy, 21
Skin ureterostomy, 75, 86-88
Sling operation for stress incontinence, 155, 160-162
Spinal anesthesia for abdominal surgery, 3
Splinting of ureter, 79
Splitting of anterior cervical fascia, 34
Sponge count after total abdominal hysterectomy, 21
Sterilization, 45, 53
 Irving method, 45, 53
 Pomeroy method, 45, 53
Stress incontinence. See *Incontinence, stress*.
Stump excision, cervical, 118, 146
Surgeon, position for pelvic operations, 4
Suspension operations, 35
 Baldy-Webster, 39
 Olshausen, 38
- TEAR, third degree, repair of**, 118
Tenaculum, application for total abdominal hysterectomy, 12
Tissue fixation
 in ovarian endometriosis, 4
 in pelvic inflammation, 4
Trachelorrhaphy, 173, 178
Traction for abdominal hysterectomy, 13
Transplantation of ureter into bladder, 80-82
Tubal
 exclusion procedure, Falk, 54
 patency, restoration of, plastic operations for, 55
Tube
 fallopian. See *Fallopian tube*.
 Miller-Abbott, in preoperative preparation, 3
- UMBILICAL herniorrhaphy**, 89, 102, 103
Ureter
 avoidance of injury to, in abdominal hysterectomy, 13
 damage to, repair of, end-to-end, 78, 79
 immediate, 75
 uretero-intestinal anastomosis for, 83-85
 end-to-end closure, 75, 78, 79
 splinting of, 79
 transplantation into bladder, 75, 80-82
Uretero-intestinal anastomosis, 75, 83-85
Ureterostomy, skin, 75, 86-88
Urinary fistulae, prevention of, 186
Urinary tract
 operations involving, 75
 preoperative preparation, 3
Urine, incontinence of. See *Incontinence, stress*.
Uterosacral ligaments, shortening of, 35, 40
Uterus
 and adnexa, mobilization, in total hysterectomy, 4, 23, 32, 33
 before total hysterectomy, 13
 blood vessels, management in total abdominal hysterectomy, 17
 circumcision of peritoneal attachments in abdominal hysterectomy, 16
 disconnection from adnexa by Falk procedure, 45
 freeing of, in total abdominal hysterectomy, 19
 fundus of, tenaculum applied for total abdominal hysterectomy, 12
 inspection, after abdominal hysterectomy, 13
 before total abdominal hysterectomy, 21
 malpositions of, shortening of uterosacral ligaments for, 35, 38
 suspension operations for, 35, 38
- VAGINA**
 apex of, closure, 34
 curettage, 121, 122, 123
 dilatation, 121, 122, 123
 examination, for total abdominal hysterectomy, 6
 under anesthesia, 120
 Le Fort method of obliterating, 118
- Vagina (Continued)**
 obliteration in absence of uterus, 118
 total, 144, 145
 prolapse, after total hysterectomy, 155, 157-159
 operation for, 142, 143
 wall of, anterior, resection of, 34
 V excision for correction of cystocele, 23
 hernia, posterior, 118
Vaginal
 and abdominal procedures, combined, 155
 and abdominal repair, combined, of enterocele, 156
 and perineal operations, 113-181
 hysterectomy, 117, 134-140
 operations, anatomical considerations, 115
 anesthesia in, 115
 blood studies before, 115
 postoperative management, 115
 preliminary considerations, 115
 preoperative measures, 115
 plastic procedures, 117
 repair, of enterocele, 152, 153
 of vesicovaginal fistula, 163
Vein ligation, femoral, superficial, 105, 106, 107
Vesicovaginal fistula. See under *Fistulae*.
Vulva, cancer of, radical groin dissection for, 222-227
Vulvectomy, 219-221
 and bilateral superficial groin dissection, 186
 radical, 187
 and bilateral superficial groin dissection, 203-213
 simple, 173, 180, 181
- WEDGE resection of ovary**, 45, 52
Wertheim hysterectomy
 with bilateral pelvic lymphadenectomy, 185, 188-195
 development of bladder flap, 188
 excision of areolar tissue, 189
 excision of iliac nodes, 190
 excision of paravaginal lymphatics, 198
 excision of vagina, 195
 freeing of ureter from peritoneum, 192
 ligation of iliac and uterine arteries, 191
 reperitonealization, 195
 separation of rectum from posterior vaginal wall, 193, 194