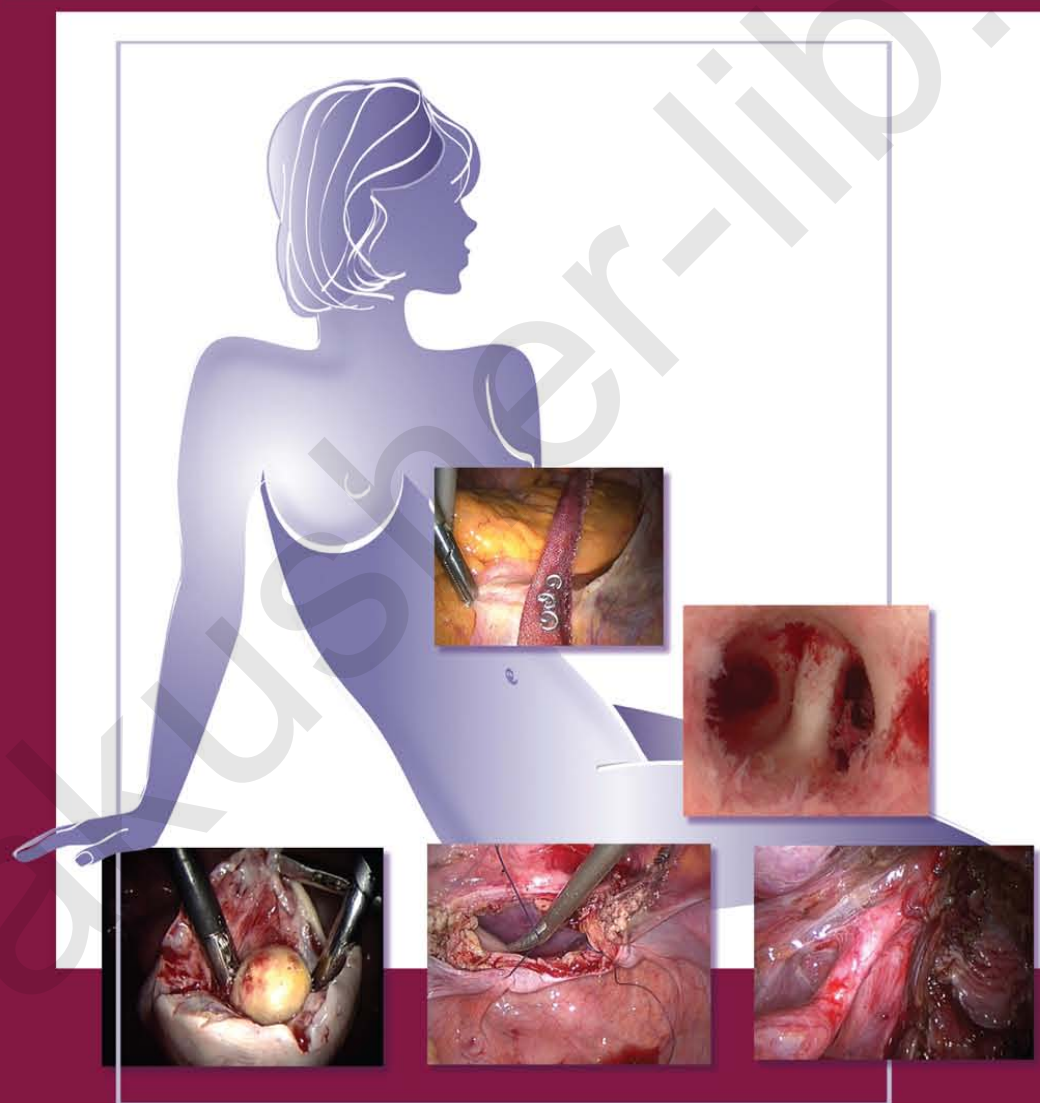


Atlas of
**OPERATIVE
LAPAROSCOPY
AND HYSTEROSCOPY**

Third Edition



informa
healthcare

Edited by Jacques Donnez

DONNEZ

Atlas of OPERATIVE LAPAROSCOPY AND

ma
re

Atlas of
**OPERATIVE
LAPAROSCOPY AND
HYSTEROSCOPY**

akusher-lib.ru

akusher-lib.ru

Atlas of
**OPERATIVE
LAPAROSCOPY AND
HYSTEROSCOPY**

Third Edition

Editor

Jacques Donnez MD PhD

Department of Gynecology
Catholic University of Louvain
Brussels, Belgium

informa
healthcare

© 2007 Informa UK Ltd

First published in the United Kingdom in 1994 by Parthenon Publishing Ltd.

Second Edition published in the United Kingdom in 2001 by Parthenon Publishing Ltd.

Third Edition published in 2007 by Informa Healthcare, 4 Park Square, Milton Park, Abingdon, Oxon OX14 4RN.

Informa Healthcare is a trading division of Informa UK Ltd. Registered Office: 37/41 Mortimer Street, London W1T 3JH. Registered in England and Wales Number 1072954.

Tel.: +44 (0)20 7017 6000

Fax: +44 (0)20 7017 6699

E-mail: info.medicine@tandf.co.uk

Website: www.informahealthcare.com

All rights reserved. No part of this publication may be reproduced, stored in a retrieval system, or transmitted, in any form or by any means, electronic, mechanical, photocopying, recording, or otherwise, without the prior permission of the publisher or in accordance with the provisions of the Copyright, Designs and Patents Act 1988 or under the terms of any licence permitting limited copying issued by the Copyright Licensing Agency, 90 Tottenham Court Road, London W1P 0LP.

Although every effort has been made to ensure that all owners of copyright material have been acknowledged in this publication, we would be glad to acknowledge in subsequent reprints or editions any omissions brought to our attention.

A CIP record for this book is available from the British Library.

Library of Congress Cataloging-in-Publication Data

Data available on application

ISBN10: 0-415-38415-X

ISBN13: 978-0-415-38415-5

Distributed in North and South America by

Taylor & Francis

6000 Broken Sound Parkway, NW, (Suite 300)

Boca Raton, FL 33487, USA

Within Continental USA

Tel.: 1(800)272 7737; Fax: 1(800)374 3401

Outside Continental USA

Tel.: (561)994 0555; Fax: (561)361 6018

E-mail: orders@crcpress.com

Distributed in the rest of the world by

Thomson Publishing Services

Cheriton House

North Way

Andover, Hampshire SP10 5BE, UK

Tel.: +44 (0)1264 332424

E-mail: tps.tandfsalesorder@thomson.com

Composition by Parthenon Publishing

Printed and bound in India by Replika Press Pvt Ltd

Contents

List of contributors	ix
Foreword	xiii
1. Anatomy in relation to gynecological endoscopy <i>S Ploteau, J Donnez</i>	1
2. Instrumentation and operational instructions <i>J Donnez, P Jadoul</i>	17
Section I: Operative laparoscopy	
Part 1: Endometriosis	
3. Laparoscopic management of peritoneal endometriosis <i>P Jadoul, J Donnez</i>	31
4. Laparoscopic management of ovarian endometriosis <i>P Jadoul, C Wyns, J Donnez</i>	43
5. Douglasectomy, torus excision, uterine suspension <i>J Donnez, J Squifflet, P Jadoul</i>	55
6. Laparoscopic excision of rectovaginal and retrocervical endometriotic lesions <i>J Donnez, P Jadoul, O Donnez, J Squifflet</i>	63
7. Ureteral endometriosis: a frequent complication of rectovaginal and retrocervical endometriosis <i>J Donnez, P Jadoul, J Squifflet</i>	77
8. Bladder endometriosis <i>J Donnez, J Squifflet, O Donnez, P Jadoul</i>	85
9. Laparoscopic hysterectomy including for advanced endometriosis with rectosigmoid disease <i>H Reich, T Seckin, JM Reich</i>	93
Part 2: Tubal pathology and ovarian pathology	
10. Fertiloscopy <i>A Watrelot</i>	115
11. Transvaginal laparoscopy <i>S Gordts</i>	133
12. CO ₂ laser laparoscopic surgery: fimbrioplasty, salpingoneostomy and adhesiolysis <i>J Donnez, P Jadoul, M Smets, J Squifflet</i>	141
13. Ectopic pregnancy following assisted conception treatment and specific sites of ectopic pregnancy <i>C Pirard, J Donnez</i>	157
14. Medical treatment: the place of methotrexate <i>J Donnez, C Pirard</i>	171
15. The laparoscopic management of ectopic pregnancy <i>JL Pouly, G Mage, M Canis, B Rabischong, R Botchorishvili, K Jardon</i>	181

16.	Laparoscopic microsurgical tubal anastomosis <i>CH Koh</i>	187
17.	Laparoscopic management of ovarian cysts <i>J Donnez, J Squifflet, P Jadoul</i>	195
18.	Laparoscopic management of adnexal torsion <i>M Canis, H Manhes, B Rabischong, R Botchorishvili, K Jardon, JL Pouly, G Mage</i>	211
Part 3: Uterine and pelvic floor pathology		
19.	Laparoscopic repair of wide and deep uterine scar dehiscence following cesarean section <i>O Donnez, P Jadoul, J Squifflet, J Donnez</i>	219
20.	Laparoscopic myomectomy <i>JB Dubuisson, A Fauconnier</i>	227
21.	Laparoscopic myomectomy and myolysis: to whom should it be proposed? <i>P Jadoul, J Donnez</i>	239
22.	LASH: laparoscopic subtotal hysterectomy – a series of 1400 cases <i>J Donnez, J Squifflet, O Donnez, M Smets, P Jadoul</i>	251
23.	Laparoscopic hysterectomy in benign diseases: a series of 1233 cases <i>J Donnez, M Smets, J Squifflet, P Jadoul</i>	263
24.	Laparoscopic approach for prolapse <i>A Wattiez</i>	277
25.	Laparoscopic sacrocolpexy for severe uterine prolapse and severe vaginal vault prolapse <i>J Donnez, M Smets, J Squifflet, O Donnez, P Jadoul</i>	289
Part 4: Oncology		
26.	Borderline tumors of the ovary or epithelial ovarian tumors of borderline malignancy <i>A Münschke, P Jadoul, J Squifflet, J Donnez</i>	307
27.	Laparoscopic reimplantation of cryopreserved ovarian tissue <i>J Donnez, MM Dolmans, D Demylle, P Jadoul, C Pirard, J Squifflet, B Martinez-Madrid, A Van Langendonck</i>	323
28.	Ovarian tissue cryopreservation and existing alternatives <i>MM Dolmans, B Martinez-Madrid, A Van Langendonck, A Camboni, D Demylle, J Donnez</i>	333
29.	Technical aspects of ovarian tissue cryopreservation <i>MM Dolmans, B Martinez-Madrid, A Van Langendonck, A Camboni, D Demylle, J Donnez</i>	343
30.	Laparoscopic ovarian transposition before radiotherapy <i>P Jadoul, J Squifflet, J Donnez</i>	349
31.	Laparoscopic preservation of female fertility <i>H Baakdah, T Tulandi</i>	355
32.	The place of endoscopy in malignancy <i>J Donnez, M Berlière, J Squifflet, P Jadoul</i>	359
33.	Indications for lymphadenectomy in stage I/IIa endometrial cancer <i>J Squifflet, J Donnez</i>	369
34.	Place of laparoscopic surgery in the management of cervical cancer: the Dargent techniques <i>D Dargent, P Mathevet</i>	375

Part 5: Endoscopy during pregnancy

35. Fetal endoscopy 391
C Hubinont
36. Laparoscopic abdominal cerclage 403
R Al-Fadhli, T Tulandi

Part 6: Robotics: the future

37. Improving ergonomics in laparoscopic gynecological surgery 409
R Polet, J Donnez
38. Robotically assisted gynecological surgery 417
T Falcone, JM Goldberg

Part 7: Complications

39. Complications of laparoscopic surgery in gynecology 425
P Jadoul, J Donnez

Section II: Operative hysteroscopy

40. Instrumentation for hysteroscopy 453
J Donnez
41. Hysterosonography and hysteroscopy in the diagnosis of specific disorders 457
J Squifflet, J Donnez, P Jadoul
42. Office hysteroscopy 471
S Bettocchi, O Ceci, L Nappi, G Pontrelli, L Pinto, A Costantino, L Selvaggi
43. Müllerian duct anomalies 483
P Jadoul, C Pirard, J Donnez
44. Hysteroscopic lysis of intrauterine adhesions 507
J Donnez, P Jadoul, J Squifflet
45. Hysteroscopic myomectomy 515
J Donnez, P Jadoul, M Smets, J Squifflet
46. Endometrial resection 527
BJ van Herendael
47. Global endometrial ablation 533
GA Vilos
48. Tubal sterilization 549
BJ van Herendael
49. Complications of hysteroscopic surgery in gynecology 553
P Jadoul, J Donnez

- Index 561

Members of the Department of Gynecology

St. Luc's University Hospital (Catholic University of Louvain)
Brussels, Belgium



'There is no life without pressure...'

Brussels, July 2006

Contributors

R Al-Fadhli

Department of Obstetrics and Gynecology
McGill University
Montreal
Quebec
Canada

H Baakdah

Department of Obstetrics and Gynecology
McGill University
Montreal
Quebec
Canada

M Berlière

Department of Gynecology
Université Catholique de Louvain
Cliniques Universitaires Saint-Luc
Brussels
Belgium

S Bettocchi

Department of General and Surgical Sciences
Institute of Obstetrics and Gynecology II
University of Bari
Bari
Italy

R Botchorishvili

Department of Obstetrics, Gynaecology and
Reproductive Medicine
Polyclinique de l'Hotel Dieu
Clermont-Ferrand
France

A Camboni

Department of Gynecology
Université Catholique de Louvain
Cliniques Universitaires Saint-Luc
Brussels
Belgium

M Canis

Department of Obstetrics, Gynaecology and
Reproductive Medicine
Polyclinique de l'Hotel Dieu
Clermont-Ferrand
France

O Ceci

Department of General and Surgical Sciences
Institute of Obstetrics and Gynecology II
University of Bari
Bari
Italy

A Costantino

Department of General and Surgical Sciences
Institute of Obstetrics and Gynecology II
University of Bari
Bari
Italy

D Dargent

Deceased

D Demylle

Department of Gynecology
Université Catholique de Louvain
Cliniques Universitaires Saint-Luc
Brussels
Belgium

MM Dolmans

Department of Gynecology
Université Catholique de Louvain
Cliniques Universitaires Saint-Luc
Brussels
Belgium

J Donnez

Department of Gynecology
Université Catholique de Louvain
Cliniques Universitaires Saint-Luc
Brussels
Belgium

O Donnez

Department of Gynecology
Université Catholique de Louvain
Cliniques Universitaires Saint-Luc
Brussels
Belgium

JB Dubuisson

Département de Gynécologie et Obstétrique
Hôpitaux Universitaires de Genève
Genève
Switzerland

T Falcone

Department of Obstetrics and Gynecology-A81
Cleveland Clinic Foundation
Cleveland, OH
USA

A Fauconnier

Département de Gynécologie et Obstétrique
Hôpitaux Universitaires de Genève
Genève
Switzerland

JM Goldberg

Reproductive Endocrinology
Department of Obstetrics and Gynecology-A81
Cleveland Clinic Foundation
Cleveland, OH
USA

S Gordts

Leuven Institute for Fertility and Embryology
Leuven
Belgium

C Hubinont

Department of Obstetrics
Université Catholique de Louvain
Cliniques Universitaires Saint-Luc
Brussels
Belgium

CH Koh

Reproductive Speciality Center
Milwaukee, WI
USA

P Jadoul

Department of Gynecology
Université Catholique de Louvain
Cliniques Universitaires Saint-Luc
Brussels
Belgium

K Jardon

Department of Obstetrics, Gynaecology and
Reproductive Medicine
Polyclinique de l'Hôtel Dieu
Clermont-Ferrand
France

G Mage

Department of Obstetrics, Gynaecology and
Reproductive Medicine
Polyclinique de l'Hôtel Dieu
Clermont-Ferrand
France

H Manhes

Department of Obstetrics, Gynaecology and
Reproductive Medicine
Polyclinique de l'Hôtel Dieu
Clermont-Ferrand
France

B Martinez-Madrid

Department of Gynecology
Université Catholique de Louvain
Cliniques Universitaires Saint-Luc
Brussels
Belgium

P Mathevet

Department of Obstetrics and Gynaecology
Hôpital Edouard Herriot
Lyon
France

A Münschke

Department of Gynecology
Université Catholique de Louvain
Cliniques Universitaires Saint-Luc
Brussels
Belgium

L Nappi

Department of General and Surgical Sciences
Institute of Obstetrics and Gynecology II
University of Bari
Bari
Italy

L Pinto

Department of General and Surgical Sciences
Institute of Obstetrics and Gynecology II
University of Bari
Bari
Italy

C Pirard

Department of Gynecology
Université Catholique de Louvain
Cliniques Universitaires Saint-Luc
Brussels
Belgium

G Pontrelli

Department of General and Surgical Sciences
Institute of Obstetrics and Gynecology II
University of Bari
Bari
Italy

S Ploteau

Department of Gynecology
 Université Catholique de Louvain
 Cliniques Universitaires Saint-Luc
 Brussels
 Belgium

R Polet

Department of Gynecology
 Université Catholique de Louvain
 Cliniques Universitaires Saint-Luc
 Brussels
 Belgium

JL Pouly

Department of Obstetrics, Gynaecology and
 Reproductive Medicine
 Polyclinique de l'Hôtel Dieu
 Clermont-Ferrand
 France

B Rabischong

Department of Obstetrics, Gynaecology and
 Reproductive Medicine
 Polyclinique de l'Hôtel Dieu
 Clermont-Ferrand
 France

H Reich

Shavertown, PA
 and
 Columbia Presbyterian Medical Center
 New York, NY
 USA

JM Reich

Morristown Memorial Hospital
 Morristown, NJ
 USA

T Seckin

Lenox Hill Hospital
 New York, NY
 and
 Kingsbrook Jewish Medical Center
 Brooklyn, NY
 USA

L Selvaggi

Department of General and Surgical Sciences
 Institute of Obstetrics and Gynecology II
 University of Bari
 Bari
 Italy

M Smets

Department of Gynecology
 Université Catholique de Louvain
 Cliniques Universitaires Saint-Luc
 Brussels
 Belgium

J Squifflet

Department of Gynecology
 Université Catholique de Louvain
 Cliniques Universitaires Saint-Luc
 Brussels
 Belgium

T Tulandi

Department of Obstetrics and Gynecology
 McGill University
 Montreal
 Quebec
 Canada

BJ van Herendael

ACZA Campus Stuivenberg
 Endoscopic Training Center Antwerp
 2060 Antwerp
 Belgium

A Van Langendonck

Department of Gynecology
 Université Catholique de Louvain
 Cliniques Universitaires Saint-Luc
 Brussels
 Belgium

GA Vilos

Department of Obstetrics and Gynecology
 Division of Reproductive Endocrinology and Infertility
 The University of Western Ontario
 London, Ontario
 Canada

A Wattiez

Gynécologie Obstétrique Reproduction Humaine
 Polyclinique de l'Hôtel Dieu
 Clermont-Ferrand
 France

A Watrelot

Centre de Recherche et d'Etude de la Stérilité (CRES)
 Lyon
 France

C Wyns

Department of Gynecology
 Université Catholique de Louvain
 Cliniques Universitaires Saint-Luc
 Brussels
 Belgium

akusher-lib.ru

Foreword

The use of laparoscopic and hysteroscopic access for gynecologic surgery is now state of the art. However, acceptance of these surgical access routes and their incorporation into daily gynecologic practice has been slow and took well over two decades. Yet the advantages of laparoscopic access as opposed to conventional laparotomy were already evident more than 30 years ago. These advantages include shortened post-operative hospital stay and recovery period; reduced post-operative discomfort which results in less analgesia requirements; frequently lesser costs; and the ensuing medical and cosmetic gains associated with the avoidance of a laparotomy. Many more complex gynecological procedures can now be successfully performed by laparoscopy. The most telling of these developments has been the use of laparoscopic access for pelvic and para-aortic lymphadenectomy and radical hysterectomy for gynecologic malignancy.

In the 1970s hysteroscopy was described as 'a technique looking for an indication.' The application of the technique, which at the time was purely diagnostic, remained limited. This was largely due to significant improvements in non-invasive imaging techniques, especially ultrasonography, and the use of a vaginal transducer for the assessment of the pelvic organs. Yet the impact of hysteroscopy in our specialty has been radical. This came about with the use of hysteroscopy as a surgical access into the uterus. It greatly simplified many procedures that previously required a laparotomy and a hysterectomy to access the uterine cavity: lysis of severe uterine synechiae, metroplasty for septate uterus, excision of symptomatic intrauterine fibroids. These, after all, are common conditions; hysteroscopy has radically simplified these procedures and reduced their morbidity. It has also permitted the introduction of a simple technique of permanent tubal sterilization.

Direct access to the uterus led to the introduction of interventions such as endometrial excision and endometrial ablation that offer a less invasive, yet effective alternative to hysterectomy in the treatment of abnormal (dysfunctional) uterine bleeding refractory to medical treatment. Hysteroscopic endometrial ablation is already being replaced by simpler ablation techniques called "global ablation" or "non-hysteroscopic ablation" that yields similar outcomes. Schopenhauer said it so well: 'change alone is eternal, perpetual, immortal.'

Progress in medicine frequently follows innovations and improvements in technology. Evolution and acceptance of operative laparoscopy and hysteroscopy and their use in more complex procedures was made possible by

such technical progress. Improvement in lens systems resulted in the production of endoscopes of smaller caliber and better optics and the introduction of lightweight mini video cameras and high-resolution television monitors permitted the surgeon and others assisting at the procedure to view the operative field in one or more television monitors and work in concert as a team.

The production of hysteroscopes of smaller caliber permitted hysteroscopy to be performed without anesthesia; this eventually led to the introduction of the so-called 'office hysteroscopy.' Improved optics, together with the production of new and better equipment and instruments, allowed hysteroscopic intrauterine procedures to be performed more easily, more quickly and with greater safety.

The advantages associated with minimal access must not reduce the surgeon's threshold in recommending a surgical procedure. Both laparoscopic and hysteroscopic surgery is minimal access surgery, but what is minimal is only the access; not the level of skill required, nor the rate or the degree of complications. One must be reminded that more than one half of the major vascular complications and nearly one half of the gastrointestinal complications occur during the establishment of the laparoscopic access route. Proper technique and vigilance are of foremost importance.

Neither the use of minimal access, nor technical feasibility is an indication for surgical intervention. A surgical procedure is undertaken to benefit the patient. Patient safety and successful outcome are dependent upon the presence of good surgical indication; proper selection of patient and procedure, including selection of surgical access; knowledge of the prerequisites, respect of the principles and application of careful techniques by an experienced operator.

The *Atlas of Operative Laparoscopy and Hysteroscopy* is comprehensive; it is well written and superbly illustrated. The book is divided into two sections that are preceded by two pertinent introductory chapters: 'Anatomy in relation to gynecological endoscopy' and 'Instrumentation and operational instructions.' The first section, 'Operative laparoscopy' is composed of seven parts: Endometriosis, Tubal and ovarian pathology, Uterine and pelvic floor pathology, Oncology, Endoscopy during pregnancy, Robotics, and Complications. The second section is on 'Operative hysteroscopy.' The book has been edited by Jacques Donnez. It contains a total of 49 chapters. Twenty-six of these have been contributed by European and North American authors, each one internationally recognized for

their expertise in the specific field. The vast majority, 32 chapters, have been authored by Professor Donnez and his associates at the Université Catholique de Louvain, Cliniques Universitaires Saint Luc. Thus, the book largely carries the imprint of the Donnez school.

I am please and honored to have been asked to contribute a foreword for this superb book. I have followed with interest Jacques Donnez career. He has embraced with enthusiasm successive developments in gynecologic surgery, from microsurgery to the more recent cryopreservation of ovary, with operative laparoscopy, operative

hysteroscopy, endometriosis, lasers, etc. in between; experimenting with each and incorporating them into the practice of his own department. I had the privilege of being invited to the academic and social program presented in Brussels last year, in celebration of Professor Donnez 20 years as a chair of department, and the opportunity and pleasure to observe to what extent his visionary leadership is appreciated and respected by members of his institution. The meticulous attention he gives to the tasks he undertakes is very much evident in this book, which I strongly recommend to anyone interested in gynecologic surgery.

Victor Gomel

*Professor Department of Obstetrics and Gynecology
Faculty of Medicine, University of British Columbia
Vancouver BC, Canada*

Anatomy in relation to gynecological endoscopy

S Ploteau, J Donnez

In gynecology, as in other surgical fields, an excellent knowledge of human anatomy is necessary. Surgical progress makes this even more pertinent; laparoscopy requires, more than ever, a thorough knowledge of all the relationships between anatomic structures. If one injures the ureter, uterine artery or large vessels, or if intra-peritoneal bleeding occurs, it is necessary to be able to react quickly and to convert to open surgery. Experienced surgeons possess the required skills, but younger practitioners with less extensive anatomic knowledge could experience serious difficulties. Laparoscopy reveals the undeniable aspect of anatomy as a tool of work. Without perfect knowledge of the different structures encountered during dissection, and particularly those which one would prefer not to encounter because of the dangers they evoke, laparoscopy can become hazardous due to the surgeon's lack of awareness. We are not about to cover all the anatomic data concerning the pelvis; this information can be found in any anatomic textbook and, in any case, it is well known. What is required is the ability to identify, without hesitation, all the structures grasped or isolated during dissection. We will simply call back to mind some anatomic notions to ensure a safe pelvic approach during laparoscopy, and present some anatomic points which highlight potential dangers and require particular attention during surgery. In this chapter, we describe the different steps of gynecological laparoscopy and some recent surgical techniques such as TOT (transobturator tape) for treatment of stress urinary incontinence and the anatomic basis of pelvic or perineal pain. For each stage of surgery, we explain the dangerous elements which should inspire only one instinct in the surgeon: vigilance. In practice, we describe certain strategic notions which should be perfectly understood before beginning laparoscopy, whatever the pathology: pelvic wall anatomy, pelvic cellular tissue and ureteral and broad ligament relationships.

INSUFFLATION AND PRIMARY TROCAR INSERTION

Pneumoperitoneal needle placement should be performed with rigor because it is responsible for 90% of vascular and visceral injuries. It is advisable to use a blunt needle with a perforated mandrel, mounted on a spring, to avoid any unwelcome surprises. After making the cutaneous incision, the abdominal wall is raised, particularly in thin patients, to distance the large vessels (except in cases of previous

surgery in this area). For the same reason, needle placement should be perpendicular to the stretched abdominal wall, which corresponds to an angle of 45° from the horizontal.

The pneumoperitoneal needle penetrates the abdominal cavity, crossing several successive layers (Figure 1.1). At the umbilicus, the aponeurosis is stuck to the peritoneum and is therefore pierced in one go. Further down, on the subumbilical linea alba, the peritoneum is not stuck to the aponeurosis and one can feel the two successive jolts as the needle pierces the aponeurosis and the peritoneum. Tactile identification of these jolts is essential in order not to place the needle between the peritoneum and the aponeurosis and so induce an awkward extra pneumoperitoneum, and also so as not to advance the needle through the viscera or a vessel, when the peritoneum has already been crossed.

At this stage, there are many potential hazards, and the surgeon must remain extremely vigilant at all times. During their abdominal passage, trocars can injure numerous structures. Concerning the insufflation needle, it is very important to be aware of the position of the umbilicus because of the risk of major visceral and vascular injury. The umbilicus most often projects towards the L4 (in 67% of cases), that is to say, at the level of the most anterior point of the lumbar lordosis. In fact, the umbilicus is situated opposite the aortic bifurcation in 80% of cases, to within 2 cm. The most dangerous situation is observed in thin patients when the umbilicus is perpendicular to the aortic bifurcation or, in 50% of cases, perpendicular to the left common iliac vein which crosses the promontory near the midline.

In dorsal decubitus, with flexed legs, the stretched aorta tends to move away from the abdominal wall because of sagging of the lumbar lordosis. With age, as well as in obese patients, the umbilicus tends to descend and its relation to the aorta is altered.

The insufflation needle may injure the following organs: large vessels that are even more vulnerable as they are against bone structures, the omentum, the small intestine, the transverse colon, the sigmoid and, more rarely, the left side of the liver and the stomach. For this reason, insufflation and needle insertion should be performed only after assurance that the patient's stomach and bladder are empty. In case of doubt concerning the presence of adhesions, especially if there is a median subumbilical scar, it is recommended that insufflation be performed in the left hypochondrium area, two fingers'

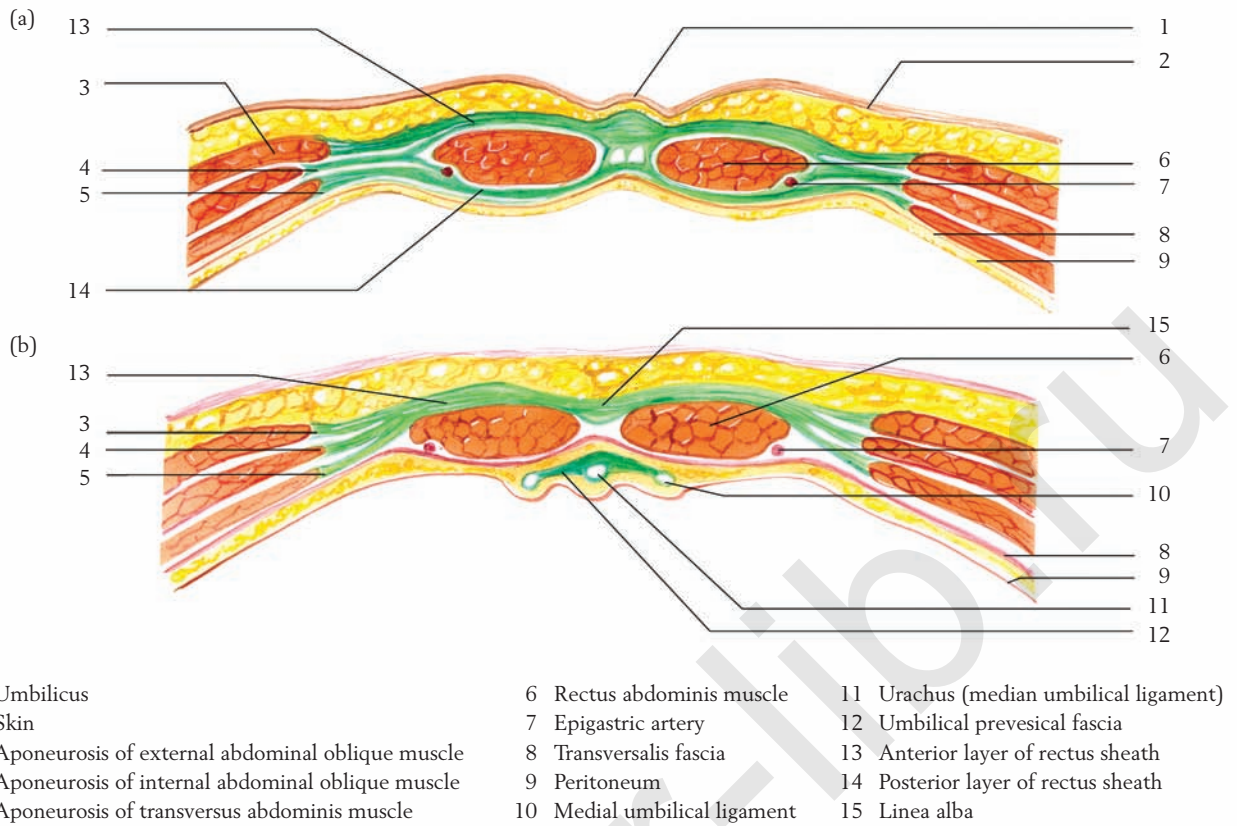


Figure 1.1 Transverse sections of the abdominal wall: (a) at the level of the umbilicus, (b) below the umbilicus

breadth from the costal border, to avoid a large spleen on the lateral side of the rectus abdominis muscle. This is an area of little depression where adhesions are uncommon.

When insufflation has started, one must be vigilant at all times so as to be immediately alerted if a needle is not in the right position. With the pneumoperitoneum established, the subumbilical trocar can be carefully introduced.

ANCILLARY TROCAR PLACEMENT

Ancillary trocar placement requires the Trendelenburg position. This position forces back the bowel, increases pelvic venous circulation, thereby reducing the consequent risk of venous thrombosis, and improves blood flow. We cannot place the patient in this position before insufflation because it may lead to some modifications in the position of the needle, with the consequent risk of vascular injury. During abdominal passage, these trocars may injure two principal structures: the bladder, if it is not empty or if it is attracted to the umbilicus by an anterior scar, and the inferior epigastric vessels. These vessels are situated in the preperitoneal space (between the peritoneum and the transversalis fascia). They originate from the external iliac artery near the deep inguinal ring and go up medially

towards the lateral side of the rectus abdominis muscle; they then rejoin this muscle 5 cm above the pubis. When one of these arteries is injured, it can induce significant bleeding, but the multiplicity of anastomoses in the abdominal wall and the wealth of blood supply mean that it can be sacrificed and ligated, if necessary. On the inside of these epigastric vessels is the median umbilical ligament, a vestige of the urachus, stretched between the umbilicus and the vesical apex, and the medial umbilical ligaments, obliterated umbilical arteries, which extend to the umbilicus. Before ancillary trocar placement, it is important to identify the inferior epigastric vessels along the abdominal wall behind the rectus abdominis muscle. In thin patients, they are usually transparently visible under the peritoneum. However, locating them can be more difficult if there is thick adipose tissue. The distance between the epigastric vessels and the midline is 5–6 cm, located 5 cm above the symphysis pubis; the mean distance between the medial umbilical ligaments and the inferior epigastric vessels is 2 cm. However, humans are not made symmetrically and these distances are significantly greater on the right side than on the left. There is no significant correlation between weight and any measured distance. However, a high body mass index affects the visibility of the inferior epigastric vessels, medial umbilical

ligament and ureter on the left. Once the abdominal wall is pierced, the surgeon must take care not to injure the pelvic structures, particularly vascular and visceral structures.

During laparoscopic surgery, two golden rules that must be applied in order to avoid injury to the intraperitoneal and retroperitoneal structures are knowledge of their normal anatomic localization and their visibility and appearance on the video-monitor. Compared with the laparotomic view, certain anatomic structures in the abdominal and pelvic cavity may look different during laparoscopic procedures because of the effect of pneumoperitoneal pressure, Trendelenburg positioning and the use of an intrauterine manipulator. However, magnification should enhance visualization of these structures, allowing finer dissection.

PELVIC ANATOMY IN LAPAROSCOPY

Broad ligament or operative peritoneum

When one penetrates the peritoneal cavity, one encounters the digestive viscera which are moved upwards. One is then opposite the pelvic viscera, covered with peritoneum, which define, from front to back, the retropubic space (of Retzius) behind the pubis symphysis, in front of the vesical wall, known for the venous plexus which is situated there; the transverse vesical fold on the vesical corpus; and the vesicouterine pouch situated between the bladder and the uterine isthmus, with its opening leading to the vesicouterine septum. This septum is bordered below by an intimate connection between the ureters and the vagina. The rectouterine pouch described by Douglas is bordered by the rectum and its fascia behind, the vagina and the uterus in front and laterally by rectouterine folds which extend backwards towards the pararectal fossae. Its opening leads to the rectovaginal septum, which is limited by the joining of the two uterosacral ligaments behind the cervix. The retrorectal space is situated between the rectal and the retrorectal fascia.

The broad ligament is situated laterally, a double-layer formation extending from the uterus to the lateral walls of the pelvis. Perfect knowledge of its anatomy is essential to performing adnexal and fertility surgery. It extends like a sheet across clothes-lines, which represent the different subperitoneal elements. Each broad ligament consists of three peritoneal mesos, the funicular meso, the mesosalpinx and the meso-ovarium, which extends with the mesometrium, below and medially.

The funicular meso, raised by the round ligament of the uterus, extends from the uterine horn to the deep inguinal ring. Its removal allows one to approach the paravesical fossae the superior opening of which is situated between the umbilical artery on the inside and the iliac vascular pedicle on the outside. It is a wide and deep space;

its floor consists of the levator ani muscle and its caudal part of the iliopubic branch and Cooper's ligament. It is crossed by the obturator pedicle which emerges from the interiliac space. The obturator nerve is the most superficial element of the pedicle and converges towards the obturator foramen. It can be recognized by its pearly white color at the level of the lateral pelvic concavity. One sometimes observes, against the superior branch of the pubis, accessory obturator vessels, branches of the inferior epigastric vessels. This paravesical space contains the obturator lymph nodes and the external iliac nodes and is therefore affected by lymphadenectomy. The potential danger at this level is from the inferior hypogastric vessels and the sometimes present accessory obturator vein, which emerges from the obturator pedicle near the foramen and ends on the inferior side of the external iliac vein, 1 or 2 cm from the femoral foramen.

The mesosalpinx, triangular when spread out, is bordered by the Fallopian tube above and the infundibulopelvic ligament on the outside. It contains vascular archways (infratubal, infraovarian and tubal branches of ovarian vessels) and the infratubal nervous plexus.

The lateral limit of the mesosalpinx is the tubo-ovarian ligament, partially followed by Richard's fimbrial fringe, whose role it is to connect the fimbria loosely with the ovary. It is essential that the mesosalpinx and tubo-ovarian ligament are free for good ovular capture and subsequent fertilization.

The meso-ovarium contains the ovarian vessels and nerves.

The preovarian fossa is bordered in front by the funicular fold and the mesosalpinx behind. It forms a triangle the relief of which is marked by the external iliac vessels laterally and the uterine horns inside. It covers the obturator fossa and faces the appendix on the right side, and the sigmoid on the left.

The tubo-ovarian recessus is between the mesosalpinx and the meso-ovarium. The ovarian fossa is between the meso-ovarium in front, the iliac vessels on the outside and the discrete fold of the ureter behind. Under its peritoneum is the obturator pedicle. Just behind, the uterine vessels are covered by the dorsal side of the broad ligament, advancing into the parametrium with the ureter.

Lateral to the ovary is the infundibulopelvic ligament, which contains the ovarian vessels. It crosses the external iliac vessels 2 cm in front of the ureter. It ends on the tubal extremity of the ovary. On the inside of the ovary is the proper ovarian ligament which emerges from the uterine horn behind and below the uterine tube, and goes to the uterine side of the ovary. The mesometrium extends behind, as far as the uterosacral ligaments.

The two pararectal fossae, the superior opening of which is narrow in the sacroiliac sinus, are not generally affected by gynecological laparoscopy. They are bordered in front by the paracervix, and inside by the rectum and the uterosacral folds, with the piriformis muscle outside, the levator ani muscle below and the lateral rectal ligament

behind. They are covered with peritoneum under which is the ureter. They extend forwards by the paravesical space, passing under the paracervix. Access is difficult because of the presence of internal iliac and rectal vessels.

Laterally, still under the peritoneum, are the iliac vessels. The most accessible structure is the external iliac artery which continues the bifurcation of the common iliac artery (Figure 1.2). If the internal iliac artery is dissected at this level, one inevitably arrives at the anterior branches and some of its visceral branches. Situated more deeply on the inside of the artery is the external iliac vein. More laterally, the pelvic wall consists of the internal obturator muscle and its fascia.

Pelvic cellular tissue

A knowledge of pelvic cellular tissue is essential for the surgeon who operates on the pelvis. This tissue has two forms: slack zones, which can be easily dissected, and dense zones (fascia and visceral ligaments), which must be cut for dissection.

The slack zones are full of areolar tissue, relatively easy to dissect (retropubic space, paravesical fossae, pararectal fossae, retrorectal space, vesicovaginal septum, rectovaginal septum). The pelvic fascia is a dense conjunctive lamina covering the pelvic wall (parietal pelvic fascia), and forms

the adventitia of the viscera (visceral fascia). The pelvic parietal fascia (or urogenital diaphragm) is not greatly affected by laparoscopy. It is, first of all, a conjunctive lamina which constitutes an effective support for the pelvic viscera because of the continuity between the parietal and visceral pelvic fascia.

The visceral pelvic fascia covers the visceral non-peritonealized surface. The thickness of this fascia is variable and it is impaired particularly on the midline in case of prolapse. Only the vaginal fascia is a thick conjunctive layer reinforced by a strong elastic network. All this fascia exchanges fibers which makes anatomic relationships much tighter and dissection more precarious. This generates risks of visceral injury, especially at the level where the connections between the viscera and the urogenital diaphragm are dynamic (at the point where each viscus passes through the pelvic fascia, between the vagina and the vesical cervix, between the vagina and the rectum).

The visceral ligaments are made up of densifications of pelvic cellular tissue whose visceral insertion intermingles with the perivisceral fascia. They are very resistant structures that require ligature and section for visceral mobilization. Pelvic cellular tissue looks like the stitches of a mesh, with traction on a point of this mesh provoking a reduction of the stitches and mesh densification. The

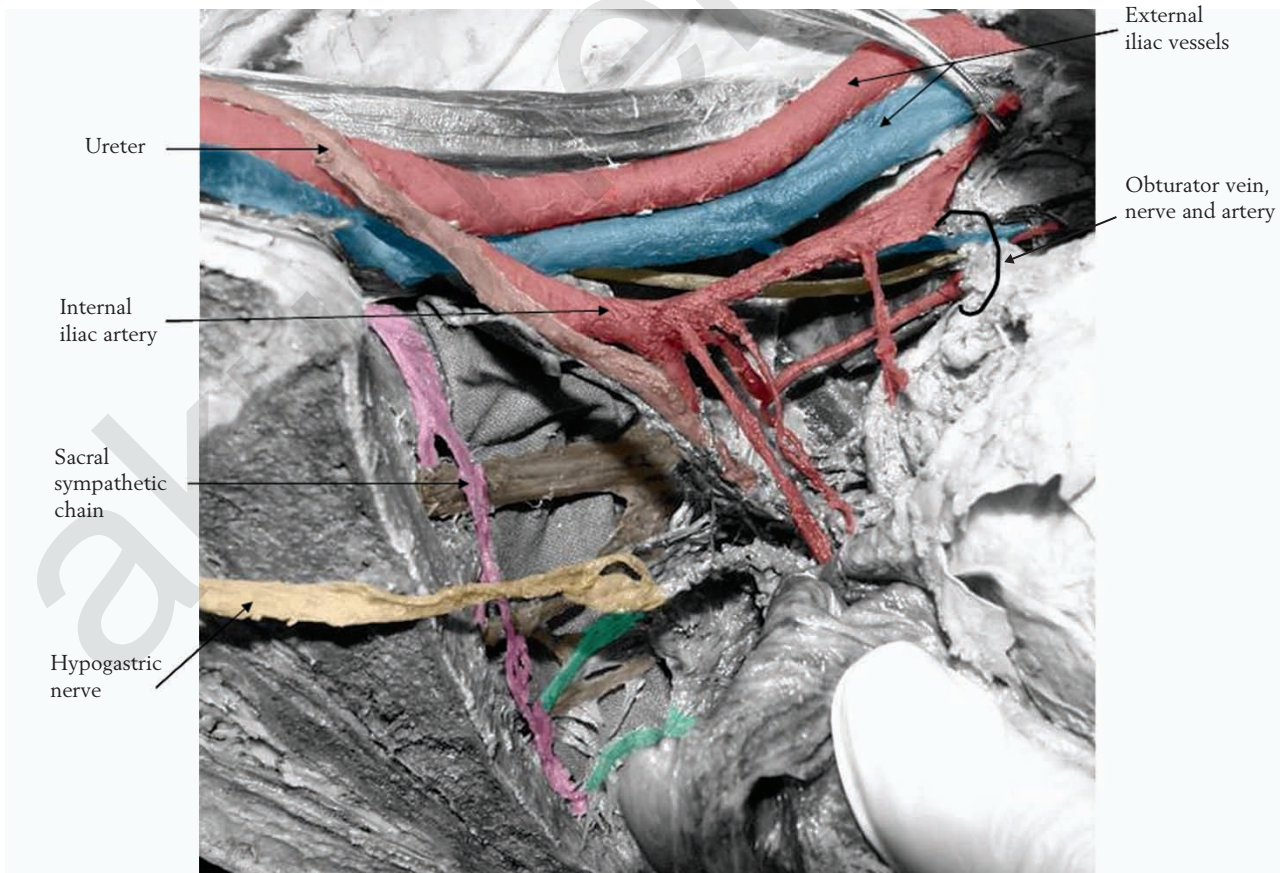


Figure 1.2 Left female hemipelvis

greater the traction, the more pronounced the densification near the point of traction, in other words, near the viscera. These visceral ligaments are divided into two groups: the lateral ligaments go with the internal iliac artery branches and the sagittal ligaments convey the inferior hypogastric plexus branches.

There are three lateral ligaments: rectal, genital and vesical. The genital ligament is the strongest and constitutes the strongest means of suspension of the uterus. It comprises three continuous parts: the parametrium, the paracervix and the paravagina. They present, near their visceral attachments, a densification of conjunctive tissue, very rich in elastic fibers and smooth muscle fibers. The parametrium situated just above the ureter contains the uterine artery, veins and lymphatics. The sometimes present lateroureteral cervicovaginal arteries can give the parametrium an anterior extension which is near the vesicouteral ligament and even merged with it. The paracervix, situated under the ureter, contains the vaginal arteries, the voluminous venous plexus and the uterovaginal lymph nodes. Contrary to the parametrium, the paracervix is frequently affected by cervical cancers. The genital ligament is also called the cardinal ligament.

The vesical ligament is located around the anterior vesical arteries, branches of the umbilical artery, and is attached to the anterior side of the paracervix. The rectal ligament is located around the middle rectal vessels. It is thick and disposed almost transversally on each side of the rectum. It separates the retrorectal area from the pararectal area.

The sagittal ligaments consist of the uterosacral, vesicouterine and tubovesical ligaments. The uterosacral ligaments are attached to the posterolateral side of the cervix and the vaginal fornix, and run alongside the lateral sides of the rectum to be finally lost, like a broad fan, on the inside of the sacral foramen from S2 to S4. They contain few vessels, but notably the inferior hypogastric plexus nerves described by Lee and Frankenhauser. A little transverse relief joins the points of uterine origin: the torus uterinus. On the whole, the content of these ligaments is principally made up of nerves; vessels are few and often their surgical section does not cause bleeding or necessitate hemostasis. Moreover, the wealth of nervous elements in these ligaments is expressed by their sensitivity. Their section can soothe pain provoked by static uterine defects. They are always extremely resistant and are even very elastic. Their resistance is due to both the nervous elements and the framework of pelvic fascia.

The vesicouterine ligaments extend from the isthmus and the cervix to the meatus uretrae area. They are situated around the arterial and venous cervicovaginal branches and extend in front of the parametrium. In front of them, the pubovesical ligaments extend from the posterior side of the pubis symphysis to the vesical cervix. All these structures form the tendinous arch of the pelvic fascia (the genitopelvic–rectosacral arch).

The parametrium and the paracervix have an extremely important functional role in the support of the uterus and vaginal fornix. These ligaments and fascias share numerous fibers which make their individualization very difficult and their borders imprecise. A typical example is the pericervical and perivaginal fascia which turn into the uterosacral ligaments and the two paracervices, and which share fibers with the parietal pelvic fascia. This explains why removal of the cervix does not provoke prolapse, because the vaginal vault is supported by the fascia.

Vascular relationships

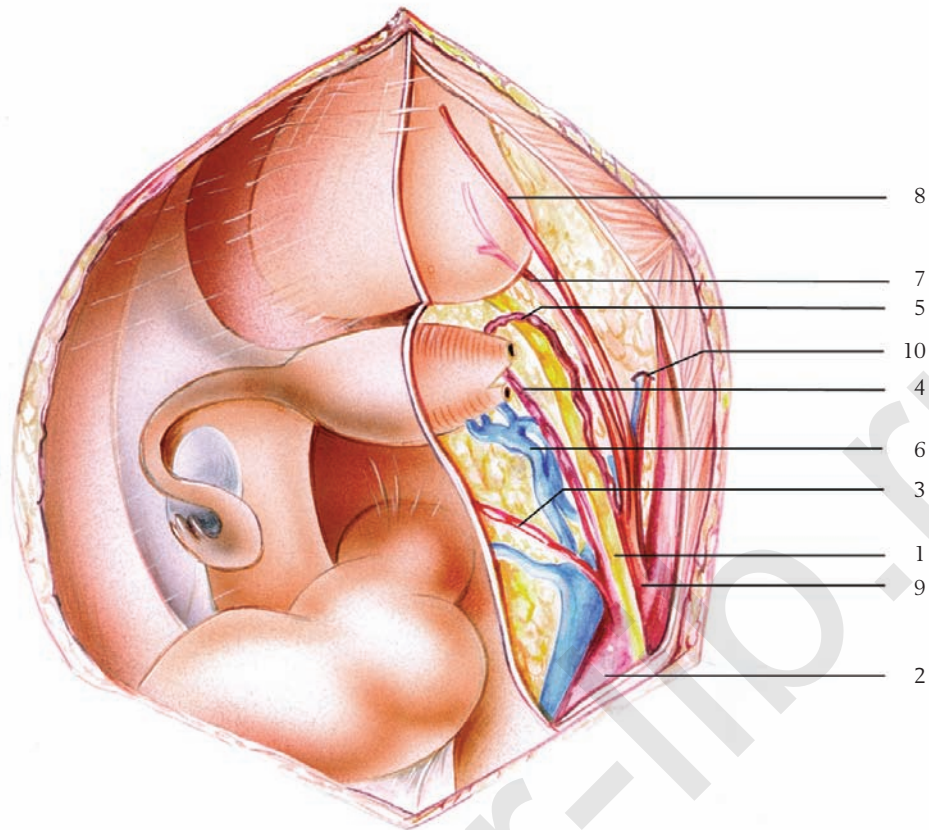
Pelvic visceral vascularization derives from the iliac vessels, but also from the abdominal vessels for the adnexa and the rectum. We only briefly recall these elements and describe in more detail the strategic points which can be risk factors during laparoscopy. It is vital to know the dangerous anatomic areas, and carefully identify the important structures before proceeding with dissection.

Arterial relationships

The principal vascular relationship that is encountered when introducing the optic is represented by the external iliac vessels, which continue outside the viscera against the lateral pelvic wall. Pelvic visceral vascularization is essentially assured by the internal iliac arteries, the ovarian arteries and the superior rectal arteries.

The internal iliac artery divides into the principal visceral pelvic arteries. To see it during laparoscopy, it is necessary to push the infundibulopelvic ligament upwards. It is not necessary to cut it, as it serves as a screen against bowel inrush. It is classically divided into two branches at the level of the greater sciatic foramen. The anterior branch separates into essentially visceral branches. The umbilical artery continues in front along the superior part of the vesical inferolateral side. It constitutes a surgical landmark which leads to the origin of the uterine artery. It then leads to the superior vesical arteries. The uterine artery has three segments (Figure 1.3):

- (1) The parietal segment descends forwards from its origin against the pelvic wall as far as the ischiatic spine. It is accompanied by the umbilical and obturator arteries in front and the ureter inside.
- (2) The parametrial segment: the artery branches transversally inside, under the parametrium, and crosses the ureter in front. Around this point of crossing, there are some important venous plexus and lymph vessels.
- (3) The mesometrial segment is very sinuous, running alongside the lateral side of the uterus in the mesometrium. It is accompanied by the uterine venous plexus, lymphatic vessels and the sometimes present parauterine lymph nodes.



- | | | |
|------------------------|------------------|---------------------------|
| 1 Right ureter | 4 Vaginal artery | 7 Inferior vesical artery |
| 2 Common artery | 5 Uterine artery | 8 Umbilical artery |
| 3 Middle rectal artery | 6 Uterine veins | 9 Internal iliac artery |
| | | 10 Obturator artery |

Figure 1.3 Relationships of the ureter to the blood vessels

The uterine artery leads to several collateral branches, including vesicovaginal branches, the cervicovaginal artery after the ureteral crossing, the sinuous cervical artery, the corporeal artery and the round ligament artery. The vaginal arteries run behind the uterine artery. The obturator artery proceeds forwards, towards the obturator foramen. It is situated against the internal obturator muscle fascia and is bordered by the obturator nerve above and the obturator vein below. Its distal part is opposite the obturator lymph nodes. The middle rectal artery goes down medially towards the lateral side of the rectum, into the lateral rectal ligament. The internal pudendal artery accompanies the pudendal nerve in the perineum. After leaving the pelvis through the greater sciatic foramen, passing around the sciatic spine, penetrating the ischiorectal fossa and traveling along the pudendal canal, it ends in two branches, the deep artery and the dorsal artery of the clitoris. The posterior branch of the internal iliac artery has parietal branches, the iliolumbar artery, the lateral sacral artery and the superior gluteal artery.

The ovarian artery emerges from the abdominal aorta at the L2 level and joins the ovary by means of the infundibulopelvic ligament.

The superior rectal artery emerges from the inferior mesenteric artery and joins the superior rectal ligament.

At the pelvic level, there is an efficient anastomotic arterial system which compensates for all obstruction, even internal iliac.

An important arterial relationship to be aware of is the median sacral artery. It emerges from the posterior side of the aorta just above its bifurcation and descends against the anterior side of L4, L5 and the sacrum. It vascularizes the posterior side of the rectum. During surgical intervention for genital prolapse, we perform vaginal vault sacrofixation. During strip fixation using tackers at the L4–L5 level or promontory, there is always a risk of arterial injury and that is why efficient coagulation of the fixation zone is necessary. One must also take great care not to injure the anterior sacral roots which emerge on each side.

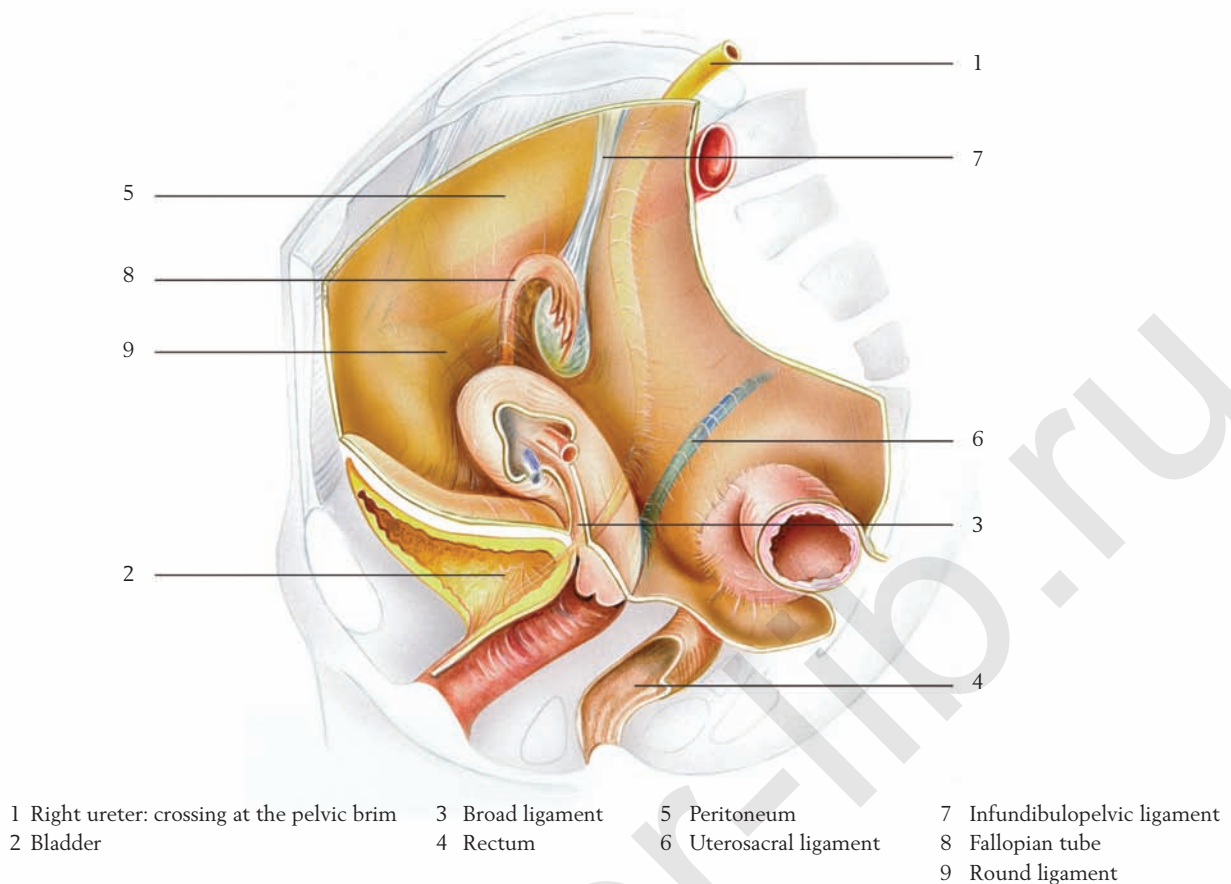


Figure 1.4 Relationships of the ureter to other pelvic organs

Venous relationships

The pelvic veins are essentially drained by the internal iliac veins and secondarily by the external iliac, common iliac, superior rectal and ovarian veins. The internal iliac vein does not contain valves, and emerges from the superior side of the greater sciatic foramen and connects to the external iliac vein at the promontory level, to form the common iliac vein. The tributary veins are satellites of the arteries and drain the pelvic venous plexus.

The ureter and its relationships

The lumbar ureter lies on the psoas muscle on each side of the rachis, and is only seen in gynecology by specialists who perform para-aortic lymphadenectomy. It then passes through the superior pelvic strait and becomes pelvic. The right ureter crosses the right external iliac artery in front, near its origin. The left ureter is situated in front of the end of the common iliac artery. On each side, it maintains a close relationship with the infundibulopelvic ligament which crosses it (Figure 1.4). It is therefore vulnerable when hemostasis of this ligament is carried out and during re-peritonealization, which are pointless anyway. Laterally,

it is situated opposite the internal iliac vein and next to the obturator nerve and obturator, umbilical, uterine and vaginal vessels. In a thin patient, it is easy to identify under the peritoneum by its characteristic peristaltic motion. In an obese patient, it is necessary to search for it and dissect it in order not to injure it.

The retroligamentary ureter runs forwards and medially, along the posteromedian side of the uterine artery, approaching the uterosacral ligament origin. This course may be modified in the case of attraction to endometriosis, sequelae of infection or previous surgery. It can then come into contact with the ovary or the uterosacral ligament, and its identification is indispensable before continuing the dissection further. The distance between the ureter and the uterosacral homolateral ligament and the infundibulopelvic ligament is small, but significantly greater on the left side. The ureter is located about 1–3 cm from the uterosacral ligament and the infundibulopelvic ligament.

The intraligamentary ureter is of even more concern to the surgeon as it is invisible. It crosses the vessels and the lateral ligaments of the uterus from back to front to join the bladder (Figures 1.3 and 1.5). In fact, in crossing under

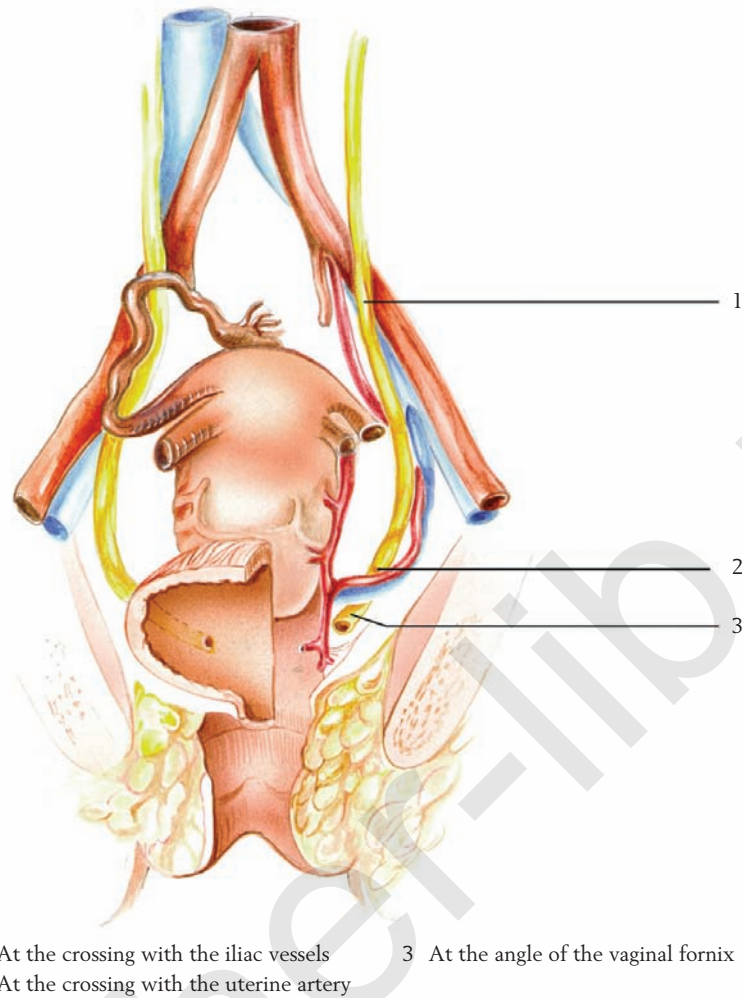


Figure 1.5 Localization of ureteric injuries

the uterine artery loop, it passes between the parametrium and the paracervix.

The ureter, however, remains clearly independent of the uterine artery, since the crossing occurs behind the artery, 15 mm from the isthmus and 10 mm from the lateral vaginal fornix. It then joins the vesical extremity of the vesicouterine ligament which attaches above the ureteral meatus (retrovesical ureter).

Knowing that the ureter is at some distance from the isthmus and the vaginal fornix is not enough to guarantee safe surgery. It is necessary to know exactly how to dissect and shelter it. Mobilizing the uterus, it is possible to display the ascending segment of the uterine artery without modifying the position of the ureter, which remains at some distance from the vascular section. One can also use the uterine artery as a guide, cutting it at the isthmus level, and, by moving aside its parietal stump laterally, the ureter is effectively protected. Another way is to open the vesicouterine space and remove the vesicouterine ligament laterally and with it the retrovesical ureter which runs alongside.

Ureteral vascularization (Figure 1.6) merits a brief reminder. It derives from the renal, ovarian, common iliac and uterine arteries. These ureteral branches divide into a T-shape on ureteral contact to form a rich adventitial network the anastomotic system of which compensates for vascular interruption, thus allowing dissection over a long distance.

Digestive system

After moving the bowels upwards, out of the way, the only other awkward digestive elements in laparoscopy are the sigmoid and the rectum. The rectal peritoneum extends forwards to the vagina to form the rectouterine pouch. The lateral sides of the rectal peritoneum extend, with the pelvic wall peritoneum, to form the pararectal fossae which proceed obliquely towards the rectouterine pouch. Injury is rare in gynecology, but possible in some operations which require a prior intestinal wash-out, such as cases of rectovaginal adenomyosis resection by laparoscopy. It is difficult and perilous surgery, reserved for

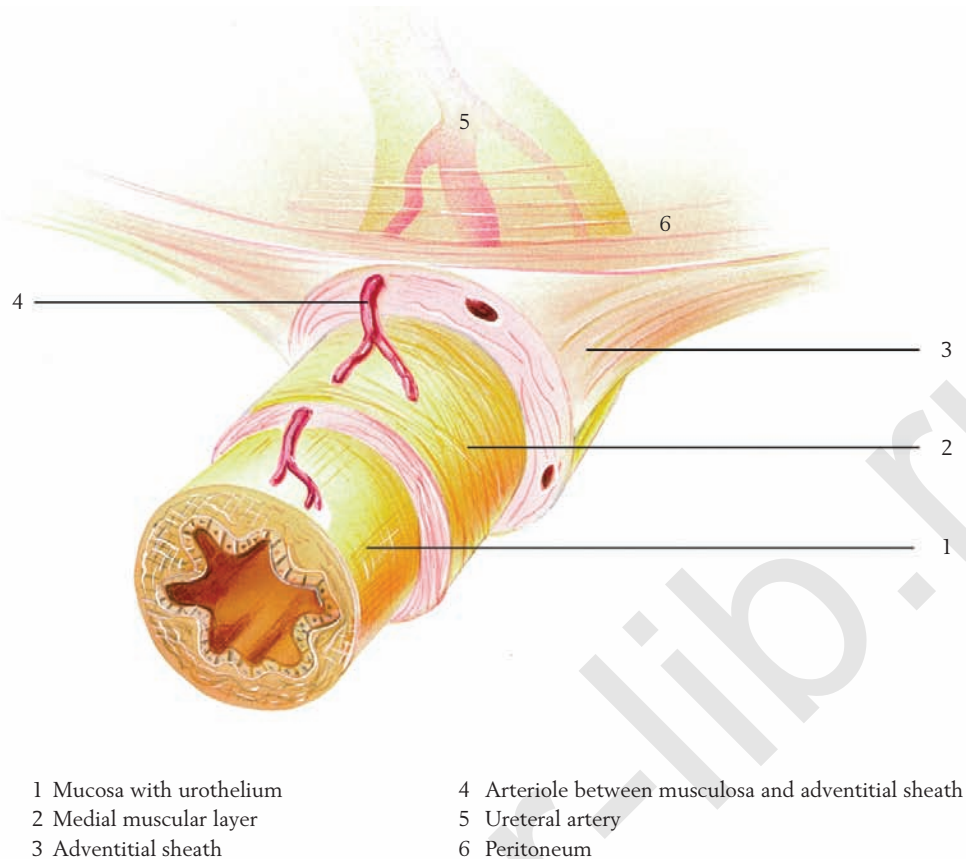


Figure 1.6 Anatomy of the ureter

experienced surgeons, because it requires not only gynecological knowledge but also knowledge of the particular behavior of endometriosis and of digestive surgery. Rectal effraction is a constant risk, and, if any doubt exists, a diagnostic test by air or dye injection in the rectum may be necessary. On the other hand, the spread of these lesions can be considerable, not only on the rectal mucous membrane but also more laterally towards the pelvic wall, sometimes leading to ureteral stenosis and even invasion of the muscle elevator ani.

The rectum can also pose a danger in cancer surgery. Its invasion can make its approach dangerous during dissection. There is another gynecological procedure that is risky for the rectum, namely vaginal vault sacrospinofixation, described by Richter and Dargent in prolapse surgery. It consists of fixing the vagina to the sacrospinal ligament through a vaginal approach. Without a wide opening of the pararectal fossa, the ligatures are placed blindly and a rectal or pudendal nerve injury is possible.

Nervous elements

Pelvipерineal innervation is both somatic and vegetative. The peripheral nervous system of the pelvis includes the sacral and pudendal plexi. The first, which consists of roots

L4, L5, S1, S2 and S3, goes to the inferior limbs and the pelvis. The second, coming from roots S2, S3 and S4, is responsible for the innervation of the perineum and the viscera. These two plexi are closely linked with the vegetative nervous system from the superior and inferior hypogastric plexus. This association between the somatic and vegetative nervous systems exists in all the great visceral functions of the organism, but is more intense at the level of the pelvic viscera.

The laparoscopic surgeon safely avoids, in contrast to the abdominal surgeon, section of the anterior branch of the iliohypogastric and ilioinguinal nerves, which may lead, although reversible, to cutaneous anesthesia of the pubic region, the inside of the thigh and the labium majus, as well as injury to the femoral nerve, which extends along the lateral side of the psoas and may be in danger of compression by the autostatic valves during laparotomy.

The nervous elements that are important to know in laparoscopy include primarily the genitofemoral nerve which emerges from spinal nerves L1 and L2 and crosses the psoas to extend in its sheath behind the ureter and the peritoneum. It then continues along the lateral side of the external iliac artery. Its genital branch provides sensitive innervation to the labia majora and the neighboring areas. Its injury is very rare in laparoscopy.

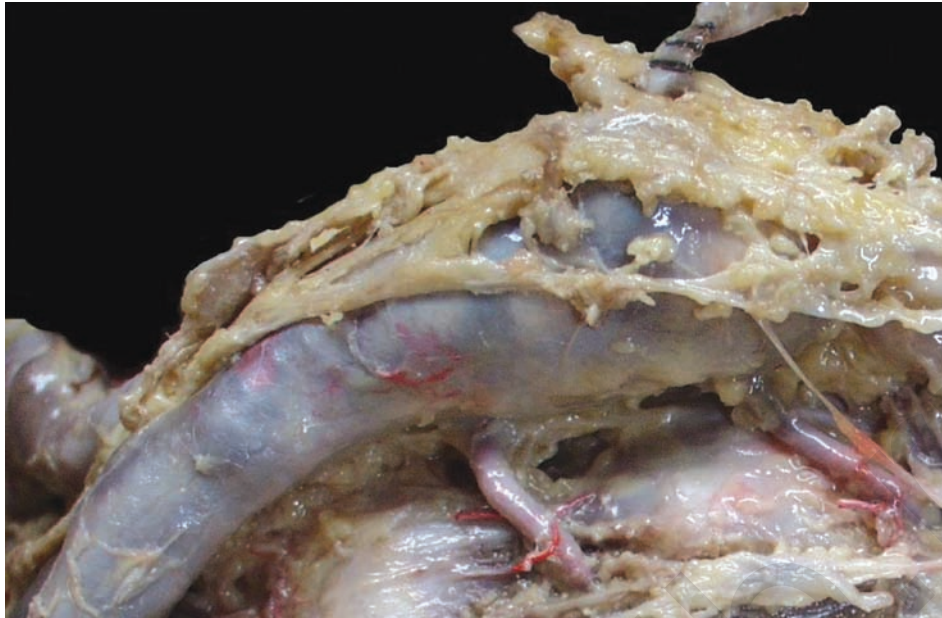


Figure 1.7 Superior hypogastric plexus

The obturator nerve (L2, L3, L4) emerges in the pelvis between the external and internal iliac vessels. It extends against the lateral wall opposite the ovarian fossa, before entering the obturator foramen. It can be affected at this level by endometriosis or adnexal infection, leading to obturator neuralgia on the superomedial side of the thigh and the knee.

Surgical injury to these nerves can be observed during lymphadenectomy, but the functional consequences are minor.

ANATOMIC BASIS OF PELVIC AND PERINEAL PAIN AND THERAPEUTIC APPLICATIONS

Anatomic description

The perineum receives its innervation from the pudendal plexus. This plexus also supplies visceral nerves, which are of variable number. They extend forwards towards the lateral walls of the pelvic viscera to the bladder, the rectum and the internal genital organs, either directly, or by the intermediary of the hypogastric plexus. Through these branches, the nervous impulses controlling micturition, defecation and sensory innervation of the pelvic viscera proceed. Vegetative innervation of the pelvic viscera derives essentially from the inferior hypogastric plexi, but also from the superior hypogastric plexus and the ovarian plexus.

The superior hypogastric plexus is situated facing L5 and the promontory, and is the origin of the left and right hypogastric nerves which connect to the corresponding

inferior hypogastric plexus (Figure 1.7). This plexus used to be resected according to Cotte's procedure, but the mediocre results obtained have now made this method obsolete.

The inferior hypogastric plexus, or Lee and Frankenhauser's ganglion, is a collection of afferent and efferent fibers going towards the pelvip erineal viscera. It is symmetrically paired in the form of a nervous quadrilateral lamina of 4 cm in length and 3 cm in height. It is located in the lateral part of the uterosacral ligament, surrounded by the lateral side of the rectum on the inside and the visceral venous plexus on the outside. Its superior edge is in contact with the ureter, its inferior edge with the pelvic floor, its posterior edge with the sacrum and its anterior edge with the posterior bladder wall. This inferior hypogastric plexus is the central point of a considerable number of nervous branches aimed at all the organs inside the pelvis.

Each inferior hypogastric plexus receives afferent branches: the hypogastric nerve originating from the superior hypogastric plexus, the sacral sympathetic chain (sacral splanchnic nerves), the pelvic splanchnic nerves (*nervi erigentes*) and the inferior mesenteric plexus (some spindle nerves). Efferent branches make up the pelvic visceral plexus: the uterovaginal plexus, the rectal plexus and the vesical plexus (vesical nerves, when cut during extended hysterectomies, can account for bladder hypotonia).

The ovarian plexus supplies innervation to the ovaries and the distal half of the Fallopian tubes. It originates from the aortic plexus. The parasympathetic fibers come from the pneumogastric nerve, which could explain vagal digestive reactions during adnexal torsion. These plexi contain orthosympathetic and parasympathetic fibers. The

pelvic orthosympathetic centers are located inside the intermediolateralis columnae of the medulla, from the tenth thoracic vertebra to the third lumbar vertebra. The efferent branches, the positioning of which is segmental, provide nerve supply to the pelvic viscera. The fibers follow the vessels, leading them to the viscera.

The sacral parasympathetic nucleus is located at the level of the S2–S4 segments, on the basal part of the ventral horn, and takes charge of all pelvic elements except the ovaries. Concerning the orthosympathetic system, the sensitive fibers are individualized and carry influx such as nociception. Thereafter, they join the closest somatic nerve and account for abdominal wall pain originating from visceral discomfort. Concerning the parasympathetic fibers, their sensitive role is still in question, even if their existence itself cannot be disputed. The motor response to nociceptive perceptions correlates with the anatomy: the parietal pain experienced during acute salpingitis is, in fact, pain from a viscus transmitting painful information through the closest somatic nerve into the corresponding iliac fossa. Motor cells under orthosympathetic influence may account for abdominal wall contracture on clinical examination.

Another example of these sensitive functions is the pain experienced by patients who suffer from adenomyotic nodules of the rectovaginal septum. These are caused by stimulation of the orthosympathetic fibers inside the rectovaginal septum; through the inferior hypogastric plexus, they carry their nociceptive information to the superior centers. The sympathetic motor cells then induce a reflex contraction of the pelvic diaphragm, closing the vagina and making intercourse even more painful.

Although such pain is no indication for laparoscopic treatment, it is important to evoke the anatomic basis of chronic perineal neuralgia and the role of the pudendal nerve which leads to pain, the etiologic diagnosis of which is sometimes difficult, and often considered as having a psychiatric origin. These patients suffer pain in the area of the pudendal nerve, either uni- or bilaterally, and this pain is exacerbated, if not provoked, by the sitting position. The positional character of this pain in a given area leads us to investigate a compression syndrome of the nerve stem.

These pains can be urogenital, anal or mixed. They involve women in two-thirds of cases and manifest themselves as burning sensations, torsions, heaviness or even intravaginal or intrarectal foreign bodies. They are not satisfactorily treated by different local therapeutic approaches and can be exacerbated by a proctological, urological or gynecological surgical procedure.

The pudendal nerve generally issues from S3, and can intercept contingents from adjoining roots S2 and S4. Emerging in the ventral sacral area, it rapidly penetrates, together with its vessels, the gluteal area under the piriformis muscle, in ligamentary claws formed from the sacrotuberous and sacrospinous ligaments (Figure 1.8). It passes around the sciatic spine between the superior rectal

nerves on the inside and the pudendal vessels on the outside. In the perineal area, the nerve lies on the medial side of the internal obturator muscle in the pudendal canal (described by Alcock), formed by a split in the aponeurosis. In the posterior part of this canal, it crosses over the falciform process of the sacrotuberous ligament, which is a fibrous lamina with a sharp superior edge, concave above, and parallel to, the medial side of the ischium.

Medially, the abundant fat of the ischioanal fossa occupies all the posterior perineum. Observation of the course of this nerve, as described above, highlights several possible areas of conflict:

- In the ligamentary claws near the sciatic spine, the nerve is pressed between the sacrotuberous and sacrospinous ligaments
- The falciform process of the sacrotuberous ligament can emerge very high and come into contact with the nerve which overlaps it
- The fascia of the internal obturator muscle, when it splits, can be thickened and thus become a potential site of conflict

Several studies have shown that a sitting position provokes an ascent of the ischioanal fat, which presses the sacrotuberous ligament falciform process laterally and brings it closer to the nerve stem.

Therapeutic applications

LUNA (laser uterine nerve ablation)

This is the practical application of the anatomy of the inferior hypogastric plexus. Uterosacral ligament ablation by laser interrupts the vegetative fibers and thus leads to a diminution in dysmenorrhea and dyspareunia. Some authors believe that the beneficial effect of LUNA is due more to the treatment of endometriosis of the uterosacral ligament than to the fiber ablation itself.

Torus uterinus ablation

According to the same principle, surgery consists of ablation of the area which joins the isthmus of the two uterosacral ligaments.

Rectovaginal septum adenomyosis

Apart from ablation of the adenomyotic lesion, surgery also effects suppression of vegetative fibers which provoke pain at the level of the rectovaginal septum.

Chronic perineal pain

Surgical liberation of the pudendal nerve, described by Robert *et al.*, gives excellent results when anesthetic infiltrations fail. Of course, this type of surgery requires

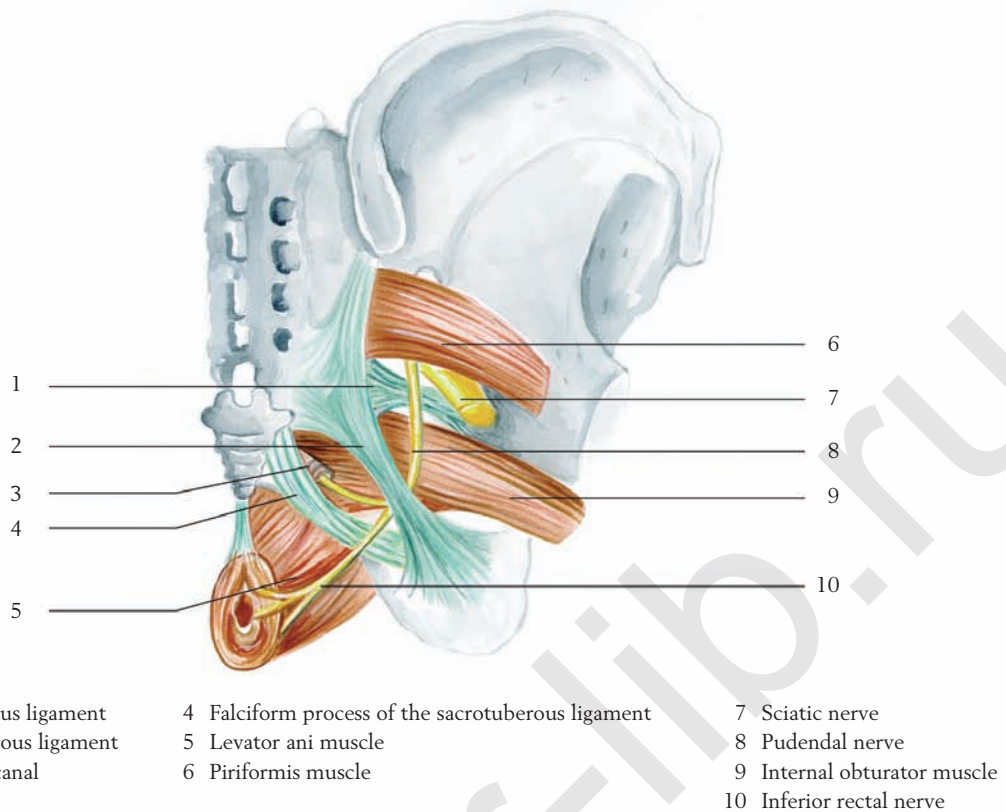


Figure 1.8 Posterior view of the deep gluteal area

perfect knowledge of the regional anatomy. The principle is very simple: by a transgluteal approach, the gluteus maximus muscle is incised in the direction of its fibers, on both sides of a transverse line passing at the level of the coccyx and thus the sciatic spine. The muscular attachments of the posterior side of the sacrotuberous ligament are removed over 2–3 cm. The pudendal pedicle then appears to cross the sacrospinous ligament behind. The latter is sectioned and the nerve can then be transposed forwards to the sciatic spine, gaining precious centimeters. Dissection of the nerve in the pudendal canal is easy, and the internal obturator muscle fascia is incised and the nerve stem and its branches are freed over 3–4 cm. Section of a threatened falciform process is performed if necessary. It is then easy to release the nerve stem in this simple way.

DANGEROUS RELATIONSHIPS DURING ILIAC AND AORTIC LYMPHADENECTOMY BY LAPAROSCOPY

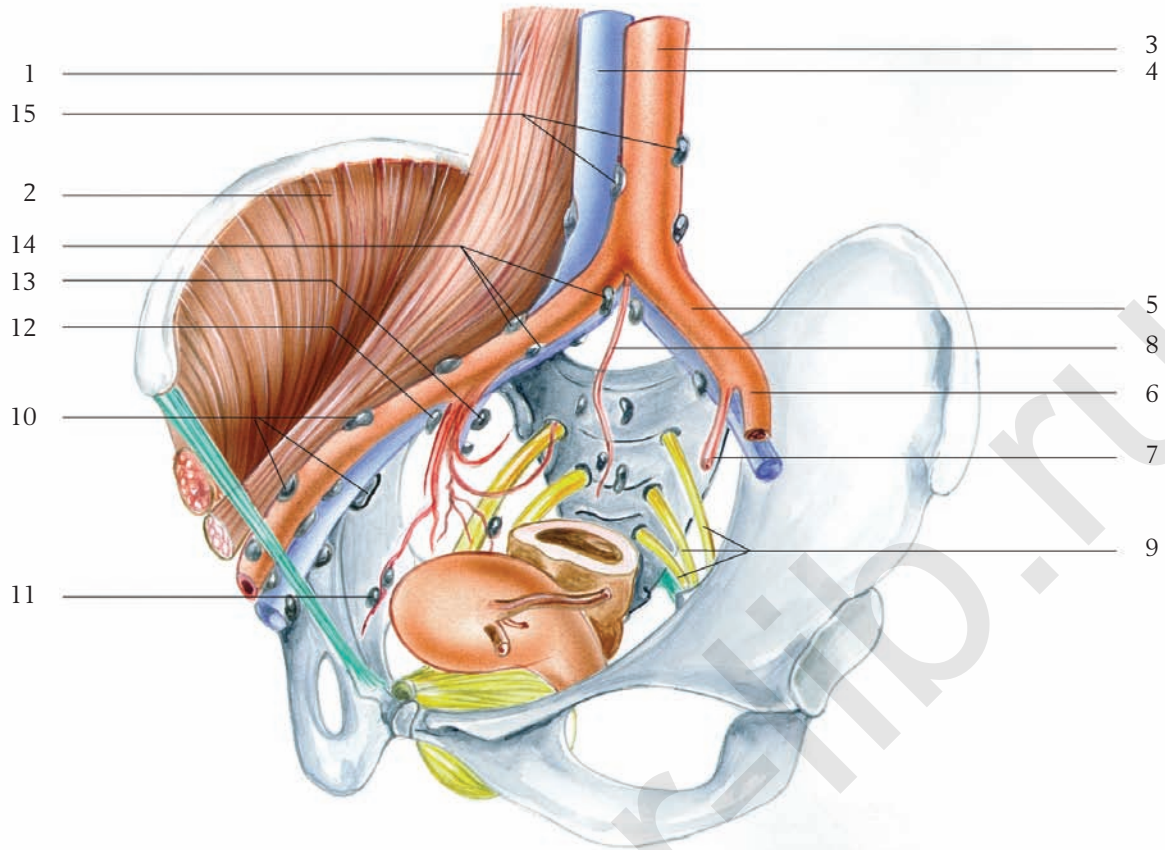
Because of the anatomic complexity and technical difficulty of lymphadenectomy, we devote an entire chapter to this subject. In fact, rare are those gynecologists who perform lymphadenectomy by laparoscopy, because vascular and nervous relationships of pelvic lymph nodes

make dissection extremely delicate. The advantages of the laparoscopic approach are the absence of trauma and a decreased risk of adhesions, for the price of specialized training, but without any diminution in the quality of samples taken.

Cancer work-ups and pelvic or lumbar lymphadenectomy require thorough knowledge of these lymph nodes (Figure 1.9). The indications are essentially diagnostic and prognostic. Lymphadenectomy is the surgical removal of an entire cellulolymp node area.

Occasionally present pelvic lymph nodes are situated near the viscera and are drained by the external iliac, obturator, interiliac, internal iliac, common iliac and lumbar nodes. The paravesical nodes are situated in the lateral ligaments of the bladder. The parauterine nodes are found in the parametrium near the uterine artery loop. The paravaginal nodes are located in the paracervix. The pararectal nodes are situated in the lateral ligaments of the rectum. External iliac nodes are eight to ten in number; they are found along the external iliac vessels, and they include three groups:

- (1) The lateral group are outside the external iliac vessels.
- (2) The intermediate group lie on the external iliac vein or between the artery and the vein. They drain the



- | | | | |
|----------------------|-------------------------|-------------------------|-------------------------|
| 1 Psoas muscle | 5 Common iliac artery | 9 Sacral plexus | 13 Internal iliac nodes |
| 2 Iliacus muscle | 6 External iliac artery | 10 External iliac nodes | 14 Common iliac nodes |
| 3 Abdominal aorta | 7 Internal iliac artery | 11 Obturator nodes | 15 Lumbar nodes |
| 4 Inferior vena cava | 8 Median sacral artery | 12 Interiliac nodes | |

Figure 1.9 Anterior view of the lymph nodes of the pelvis

inguinal nodes and the medial external iliac nodes towards the common iliac nodes.

- (3) The medial group are situated under the vein and against the pelvic wall, so it is necessary to lift the vein to reach them. This group receives the lymph vessels of the bladder, the pelvic ureter, the uterus and the vagina.

The obturator nodes are situated against the obturator pedicle and the internal obturator muscle. They receive the lymph vessels of the bladder, the ureter, the uterus and the vagina. The interiliac nodes are situated at the bifurcation of the internal and external iliac vessels. They drain the obturator and external iliac nodes. They also receive the lymph vessels of the bladder, the uterus and the vagina.

The internal iliac nodes are found between the internal iliac artery branches. One can distinguish the sacral nodes, situated along the lateral sacral artery, which receive the lymph vessels of the rectum and the cervix, and the gluteal nodes, which lie on the piriformis muscle, and drain the lymph vessels of the rectum, the deep area of the

perineum and the gluteal area. The common iliac nodes are situated against the common iliac vessels, and drain the external, internal and intermediate iliac nodes. They include five groups:

- (1) The lateral group: on the lateral sides of the common iliac artery at the level of the iliolumbar fossa;
- (2) The intermediate group: under the common iliac vessels, against the obturator nerve, the ascending lumbar vein and the lumbosacral trunk;
- (3) The medial group: situated against the medial side of the right common iliac artery and the right and left common iliac veins;
- (4) Promontory nodes;
- (5) Subaortic nodes; the lumbar nodes are found around the aorta, the inferior vena cava and between these two vessels.

Lymphadenectomy is performed according to several techniques in laparoscopy: by either a transperitoneal

approach to the paravesical fossa, or an extraperitoneal approach, by careful detachment of the peritoneum, beginning with the retropubic space and then the prevascular and preperitoneal areas. Insufflation through the trocar detaches the preperitoneal area. Lymphadenectomy can be extended to several levels, described below.

Level I describes the angle defined by the common iliac artery bifurcation. It removes the medial and intermediate external iliac nodes, obturator and interiliac. These are the sentinel lymph nodes of the front line of the uterine cervix, which can first be identified by the sentinel lymph node technique during surgery for cervical cancer. This level is sufficient for small cervical tumors and endometrial cancers. The risk during dissection of this area is to the inferior obturator vein, the internal iliac vein branches and the obturator vessels.

Level II is astride the pelvis and the abdomen, limited above by the angle of the aortic bifurcation. It includes the common iliac nodes, the lateral external iliac nodes not affected by the first level, the promontory and the sub-aortic nodes. The risk during lateral external iliac node removal is injury to the genitofemoral nerve which runs alongside the psoas and, particularly, the sometimes present psoic artery, which emerges from the external iliac artery. The epigastric vessels must also be respected near the deep inguinal ring. On the other hand, the retrocruel nodes described by Cloquet are removed. During promontory node dissection, care must be taken with regard to the middle sacral pedicle, the presacral veins and, particularly, the left common iliac vein.

Level III is lower aortic, defined above by the emergence of the inferior mesenteric artery. It is bordered laterally by the lumbar ureters, and behind by the iliac vessels, the sympathetic ganglions and psoas attachment. These elements are generally well visible, and complications are rare if the dissection is carefully performed.

Level IV, infrarenal, does not generally involve laparoscopy and is rarely carried out.

Increasingly, removal of the cellular lymph node tissue of the distal part of the paracervix, known as paracervical lymphadenectomy, is performed. Its purpose is to supplant the removal of the distal part of the paracervix. The affected tissue is removed, preserving the nerves and vessels of the paracervix. It is necessary, at this level, to identify the middle rectal artery at the back and the vegetative nerves in order to protect them.

ANATOMIC BASIS OF URINARY STRESS INCONTINENCE AND THERAPEUTIC APPLICATIONS

Stress incontinence is a frequent and complex symptom in women. It is caused by obstetric trauma to the urogenital perineum, but also dystrophic modifications of the menopause. Finally, it can be the consequence of surgery or radiotherapy to the bladder or urethra. The principal

anatomic structures implicated in stress continence are the retropubic space, the base and cervix of the bladder, the urethra and its sphincter. The retropubic space described by Retzius is situated in the preperitoneal space. It is bordered in front by the pubis symphysis, the pubovesical ligaments, the tendinous arch of the pelvic fascia and the retropubic branches of the obturator and pudendal vessels. Laterally is the superior branch of the pubis and a thickening of the periosteum, the pectineal or Cooper's ligament, implicated in pectineal colposuspension described by Burch. Behind is the inferolateral side of the bladder as well as the urethra and the pelvic vagina. This area is closed below by the pelvic diaphragm. It is full of loose tissue, infiltrated by fat and easily cleavable during laparoscopy. The vesical base includes the trigone of the bladder and the retrotrigonal fossa, the depth of which increases with age, which is a factor in post-micturition dribble.

The vesical cervix is essential for urinary continence. It is situated 25 mm from the pubic symphysis and 10 mm above the horizontal, passing along its inferior side. Its anterior fixity is assured by the pubovesical ligaments. The normal urethrovesical angle is 90–100°.

The urethra includes three segments: supradiaphragmatic, diaphragmatic and infradiaphragmatic. It is situated obliquely below and in front, and at an angle of 30° from the vertical. The supradiaphragmatic urethra is supported by the pubovesical ligament; the infradiaphragmatic urethra is supported by the pubourethral ligament and suspensory ligament of the clitoris.

Micturition requires absolute synergy between the bladder, the urethra and abdominal pressure.

During the repletion phase, abdominopelvic pressure constitutes a passive occlusion force of the urethra. It opposes urogenital diaphragmatic resistance against which the urethra pushes. The resultant force exerted by the abdominopelvic pressure and the resistance of the urogenital diaphragm makes its way forward, perpendicularly, to the perineal membrane, which constitutes the essential static structure of diaphragmatic urethral occlusion. Techniques using a perineal sling in urinary stress incontinence surgery illustrate perfectly the biomechanics of the urogenital diaphragm. The TVT and TOT methods (tension-free vaginal tape and transobturator tape), in particular, are among those which, by their physiological and almost non-invasive approach, currently give very good results. This sling exerts retrourethral resistance the orientation of which adjoins that of the pubis. The resultant abdominopelvic pressure and tape resistance is then perpendicular to the perineal membrane. During any effort, abdominopelvic pressure, oriented towards the posterior perineum, leads to a posterior transfer of the supradiaphragmatic urethra. On the other hand, the diaphragmatic urethra opposes the resistance of the tape and bends.

During the micturition phase, the association of both intravesical pressure and intraparietal tension created by

detrusor contraction is directed to an area of weak resistance, the vesical cervix. The tonus of the urethra yields and the urethra opens.

In urinary stress incontinence, there is ptosis of the urethrovesical region, and shortening and horizontalization of the urethra. The surgeon's objective is to replace the vesical cervix so that it will maintain its anatomic position, while preserving cervical and urethral flexibility.

The wide use of retropubic tension-free suburethral slings (TVT) has been associated with various peri- and postoperative complications. To reduce these complications, TOT using transobturator passage of the tape has been developed. This technique uses specific instruments for the passage of synthetic tape from beneath the urethra towards the thigh fold. With this technique, the risk of injury to the bladder, the epigastric vein and the external iliac vein is non-existent. By contrast, such injuries may occur if the tape is introduced through the retropubic space. Anatomic dissection shows that the transobturator tape does not enter the retropubic space. The tape is inserted according to a fixed path which penetrates from the suburethral space into a strictly perineal region, limited medially and cranially by the levator ani muscle, caudally by the perineal membrane and laterally by the obturator internus muscle. This region corresponds to the most anterior recess of the ischiorectal fossa. The tape then perforates the obturator membrane and muscles, and exits through the skin after crossing the adductor muscles and subcutaneous tissue. It passes through the obturator foramen along the upper third of the ramus inferior of the pubic bone. The tape courses away from the dorsal nerve of the clitoris located more superficially below the perineal membrane, the obturator nerve and vessels, and the saphenous and femoral vessels. The tape is not visible in the Retzius space; it remains covered with the fasciae of the internal obturator muscle, so that it cannot access the lower pelvis at any time. This is a highly accurate, reproducible and safe technique, which does not require perioperative cystoscopy, as does TVT.

BIBLIOGRAPHY

- Bonnet P, Waltregny D, Reul O, de Leval J. Transobturator tape inside out for the surgical treatment of female stress urinary incontinence: anatomical considerations. *J Urol* 2005; 173: 1223–8
- Bradley WE. Neural control of urethrovesical function. *Clin Obstet Gynecol* 1978; 21: 653–67
- Carter JE. Surgical treatment for chronic pelvic pain. *J Soc Laparoendosc Surg* 1988; 2: 129–39
- Dargent D, Salvat J. *L'Envahissement Ganglionnaire Pelvien*. Paris: Medsi, 1989
- Dargent D. Laparoscopic surgery in gynecologic oncology. *J Gynecol Obstet Biol Reprod Paris* 2000; 29: 282–4
- Enhörning G. Simultaneous recording of intravesical and intraurethral pressure. A study on urethral closure pressure in normal and stress incontinent women. *Acta Chir Scand Suppl* 1961; Suppl 276: 1–68
- Faucheron JL. Surgical anatomy of pelvic nerves. *Ann Chir* 1999; 53: 985–9
- Fauconnier A, Delmas V, Lassau JP, et al. Ventral tethering of the vagina and its role in the kinetics of urethra and bladder-neck straining. *Surg Radiol Anat* 1996; 18: 81–7
- Fétiveau G. The inferior hypogastric plexus, Report for MSBM. Anatomy Laboratory, Faculty of Medicine, University of Nantes, France, 2002
- Jacquetin B. Use of TVT in surgery for female urinary incontinence. *J Gynecol Obstet Biol Reprod Paris* 2000; 29: 242–7
- Kamina P. *Petit bassin et périnée. Rectum et Organes Urogénitaux*. Paris: Maloine, 1995; 1, 2
- Lazorthes G. *Le système nerveux périphérique. Description, Systématisation, Exploration Clinique Abord Chirurgical*. Paris: Masson, 1955: Ch XXII
- Nezhat CH, Nezhat F, Brill AI, et al. Normal variations of abdominal and pelvic anatomy evaluated at laparoscopy. *Obstet Gynecol* 1999; 94: 238–42
- Ploteau S, Donnez J. Anatomy in relation with gynecological endoscopy. In Donnez J, Nisolle M, eds. *An Atlas of Operative Laparoscopy and Hysteroscopy*, 2nd edn. Carnforth, UK: Parthenon Publishing, 2001: 33–45
- Querleu D. *Techniques Chirurgicales en Gynécologie*, 2nd edn. Paris: Masson, 1998
- Richter K, Dargent D. La spino-fixation dans le traitement des prolapsus du dôme vaginal après hystérectomie. *J Gynecol Obstet Biol Reprod* 1986; 15: 1081–8
- Robert R, Brunet C, Faure A, et al. Surgery of the pudendal nerve in various types of perineal pain: course and results. *Chirurgie* 1993–94; 119: 535–9
- Robert R, Prat-Pradal D, Labat JJ, et al. Anatomic basis of chronic perineal pain: role of the pudendal nerve. *Surg Radiol Anat* 1998; 20: 93–8
- Roberts WH, Hunt GM, Henken HW. Some anatomic factor having to do with urinary continence. *Anat Rec* 1968; 162: 341–8
- Shafik A. Pudendal canal syndrome as a cause of vulvodynia and its treatment by pudendal nerve decompression. *Eur J Obstet Gynecol Reprod Biol* 1998; 80: 215–20
- Testut L, Latarjet A. *Traité d'Anatomie Humaine*, 9th edn. Paris: G. Doin & Cie, 1949; 3: Book 7; 5: Books 12, 13
- Ulmsten U, Falconer C, Johnson P, et al. A multicenter study of tension-free vaginal tape (TVT) for surgical treatment of stress urinary incontinence. *Int Urogynecol J Pelvic Floor Dysfunc* 1998; 9: 210–13

akusher-lib.ru

Instrumentation and operational instructions

J Donnez, P Jadoul

ENDOSCOPIC INSTRUMENTS

Telescopes

Telescopes used in laparoscopy are available with different viewing directions, either with or without an instrument channel. The various telescopes and their application range are briefly described below (Figure 2.1):

- 0° straightforward telescope: this telescope has the greatest application range, because it facilitates orientation and conveys an impression of the area inspected. The direction of view corresponds to the natural approach and the usual perspective. The 0° telescope is generally preferred in gynecological interventions
- 30° forward-oblique telescope: this can be rotated to enlarge the field of vision. Use of the 30° telescope can be advantageous during dissection in the Douglas pouch
- 45° telescope

Telescopes without instrument channels are used in the majority of cases in gynecology, as they give a better overview and offer better image resolution. However, in some cases, it may be more reasonable to use telescopes with an integrated instrument channel (telescope with parallel eyepiece, see Figure 2.1, top). These telescopes are generally 0° straightforward telescopes. The diameter of the instrument channel is 5–7 mm; thus, a correspondingly large instrument can be inserted.



Figure 2.1 Telescopes used in gynecology. From top to bottom: telescope with instrument channel, 30° and 0° telescopes (Karl Storz)

Additional devices can also be connected to this laparoscope, such as a CO₂ laser. The best example of this is for laparoscopic sterilization; tissue fragments or biopsy specimens can also be extracted through the telescope trocar with the aid of a grasping forceps, which is introduced through the telescope's instrument channel.

A disadvantage of using telescopes with instrument channels is the deterioration in image quality. This is due to the lower light intensity that can be picked up by the video camera, when compared with telescopes that do not have an instrument channel.

A Verres optical needle with insufflation can be used in some difficult cases (Figure 2.2), or in order to perform 'mini-laparoscopy'.

Trocars

Small passageways through incisions in the abdominal wall are created with the aid of trocars. The use of disposable trocars is clearly in decline, in the era of cost reduction.

In general, trocars with various diameters are used in surgical endoscopy. The standard sizes (Figure 2.3) are 5.5, 11, 12, 15 and 22 mm.

Spherical and flap valves make it possible to change operating instruments quickly, as the change can be carried out without activating the valve mechanism. Trumpet valves are mostly found in telescope trocars. The telescope is protected from contamination by tissue and blood particles during insertion by pressing the trumpet valve. Sharp, pyramidal trocar tips, on the other hand, can be positioned

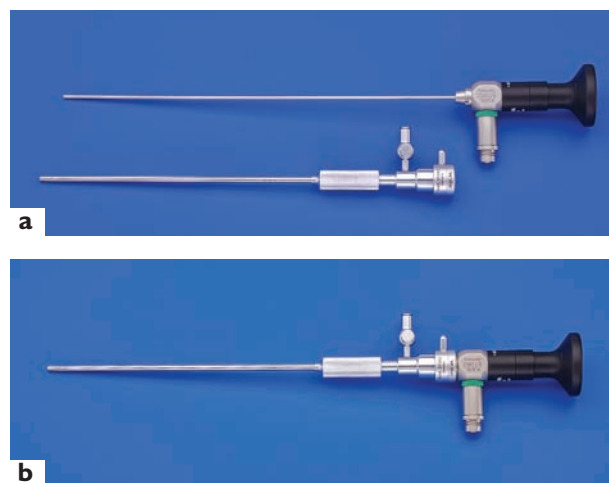


Figure 2.2 (a) and (b) Optical Verres needle



Figure 2.3 Trocars are available in different sizes and with various valve mechanisms (Karl Storz)



Figure 2.4 Various trocar tips (Karl Storz)




Figure 2.5 (a) Threaded trocars offer a better grip in the abdominal wall (Karl Storz); (b) various trocar reducers (Karl Storz)

relatively easily. The sharp edges can sometimes damage smaller blood vessels and other organs.

There are great differences between trocar tips (Figure 2.4). By using spherical, blunt, trocar tips, the blood vessels are pushed aside and protected to a large degree. Sometimes, however, greater pressure has to be exerted during insertion. Since the skin incision for the auxiliary puncture is carried out under transillumination and the puncture itself is in full view, the choice of trocar tip here can be regarded as being of secondary importance. Better protection to prevent the trocar slipping out of the intraperitoneal space is provided by sheaths with screw threading (Figure 2.5a). However, these cause increased trauma to both the abdominal wall and the peritoneum. Trocar reducers facilitate the surgery (Figure 2.5b).

INDIVIDUAL INSTRUMENTS

Grasping forceps

Atraumatic dissecting and grasping forceps (Figures 2.6 and 2.7) are particularly suitable for grasping and the liberation of hollow organs. The claws are fashioned so that trauma to the tissue should not occur. Atraumatic grasping forceps (multiserrated) are designed for atraumatic and precise tissue grasping, such as of ligaments during diagnosis. Grasping forceps (2×4 teeth) are used to grasp and liberate solid organs. Sturdy grasping forceps are indispensable in surgical endoscopy; in the case of endoscopic cyst extirpation, for example, they can help to fix the ovary capsule properly and remove the cystic bag.

Dissecting and grasping forceps (claw forceps) are particularly designed for grasping solid structures (e.g. myomas). These forceps are used where trauma of the tissue does not have to be particularly considered.



Figure 2.6 Grasping forceps. From top to bottom: Kelly grasping forceps (atraumatic), Manhes grasping forceps (atraumatic), Manhes grasping forceps (traumatic), Schneider lymph node grasping forceps (atraumatic)

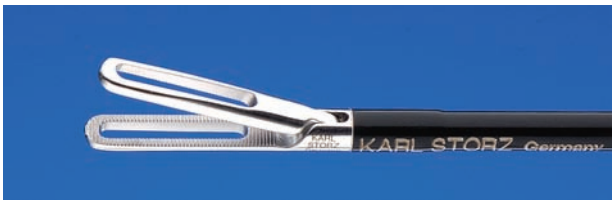

Figure 2.7 Intestinal grasping forceps, diameter 5 mm (Karl Storz)



Figure 2.8 Laparoscopic scissors. From top to bottom: straight scissors, curved scissors (different lengths of blades), hook scissors



Figure 2.9 Monopolar high-frequency needle (Karl Storz): the tip of the needle can be retracted into the sheath

Scissors

Hook scissors (Figure 2.8) are particularly suitable for transecting ligature fibers and for tissue transection. Delicate dissection can be carried out with straight scissors. Curved scissors, in general, have the same features as for straight scissors. In some cases they are easier to dissect with, because the curvature changes the viewing angle.

Coagulation instruments

The tip of a monopolar high-frequency needle (Figure 2.9) can be retracted into the sheath. Various bipolar forceps (Figures 2.10 and 2.11) can be introduced through a 5-mm trocar.

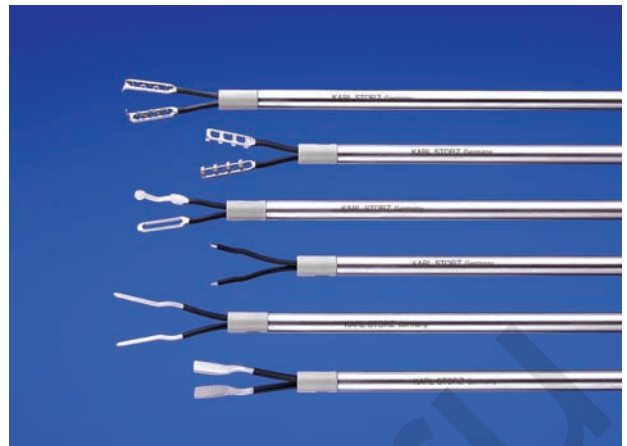

Figure 2.10 Various bipolar forceps (Karl Storz)



a



b



c

Figure 2.11 (a) 1-mm and 3-mm wide bipolar forceps; (b) RoBi™: new generation of rotating bipolar forceps and scissors; (c) bipolar ball electrode

Additional instruments

Other 5-mm instruments are needed for laparoscopic surgery, for example probes (atraumatic), a needle for cyst puncture and an irrigation–suction probe (Figure 2.12).

Biopsy forceps

Biopsy forceps (Figure 2.13) are used during diagnostic laparoscopy in cases of malignant disease (ovarian cancer: before chemotherapy or during second-look laparoscopy) and benign disease such as endometriosis.

Needle holder

Figure 2.14 shows 5-mm and 3-mm needle holders.

Myoma holder

Figure 2.15 shows a myoma fixation instrument.



Figure 2.12 Additional instruments. From top to bottom: palpation probe, irrigation and suction tube, puncture needle



Figure 2.13 Various biopsy forceps

Atraumatic forceps

Atraumatic forceps (Figure 2.16) are used for prehension of the Fallopian tube or the ureter.

Intestinal probe

The intestinal probe (Figure 2.17) is used to push back the intestines in order to achieve a good view.

MORCELLATORS

In the past, laparoscopic surgeons were faced with the difficult problem of extraction of tissue, and were often



Figure 2.14 Tips of various needle holders



Figure 2.15 Myoma fixation instrument

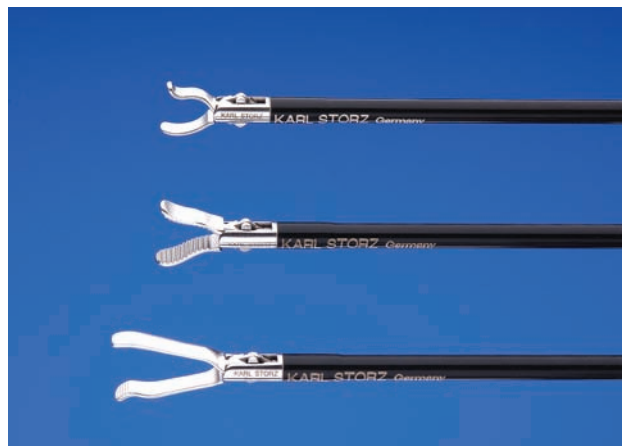

Figure 2.16 Various atraumatic forceps

obliged to perform a suprapubic mini-laparotomy or a transvaginal extraction. The first substantial improvement was the development of the manual morcellator (Semm–Wisap). Much force and time were necessary, depending on the consistency of the tissue.

In collaboration with Storz, Steiner developed the electromechanical morcellator (Figure 2.18), consisting of a motor-driven cutting tube. The speed can be selected in three stages. It is possible, with the aid of this morcellator, to extract even large amounts of tissue from the abdomen, using the size 11 trocar, in a short period of time. With 12-mm and 15-mm trocars (Figure 2.19), large quantities of tissue can be extracted in this way within a few minutes.

Because of the good cutting quality of the rotating morcellator, the tissue structure is minimally damaged. It also enables a reliable histological examination to be carried out.

CO₂ GAS INSUFFLATOR

A pneumoperitoneum must be created so that the organs and tissues are separated from each other and rendered accessible. Conventional gas insufflators are sufficient for a purely diagnostic laparoscopy. However, in surgical laparoscopies performed today, compensation for considerable volume losses must be made in a relatively short period of time, for example due to frequent suction of irrigation solutions using high-performance irrigation–aspiration



Figure 2.17 Intestinal probe



Figure 2.18 Rotocut™ G1 morcellator with Unidrive® Gyn motor system

units. High-flow CO₂ insufflators (Figure 2.20) are a basic prerequisite for surgical laparoscopy, as they offer the only option for reducing operating time to a minimum. Electronically controlled insufflators have become the preferred choice in this respect.

The insufflator's display, which the surgeon should always be able to see, gives continuous information on the following data:

- The patient's intra-abdominal pressure (actual value): the preselected maximum intra-abdominal pressure should never exceed a value of 15 mmHg!
- Flow rate: the required set value for the patient's intra-abdominal pressure must be preselected. The maximum flow rate (set value) must be preset
- Total CO₂ insufflated volume is given
- Gas reserve, is indicated

Some of the state-of-the-art insufflators (Figure 2.20) are equipped with an integrated preheating element which



Figure 2.19 Rotocut G1 morcellator in diameters 12 mm and 15 mm



Figure 2.20 Thermoflator for high-flow insufflation (30l/min) with Optitherm® heating element



Figure 2.21 EndoCart™ set-up, including: flat screen monitor, digital camera, xenon light source, insufflator, suction-irrigation system, Aida DVD recorder (for digital storage of still images, video sequences and audio files) and motor system for morcellator



Figure 2.22 Digital three-chip Image1™ camera with camera control unit

keeps the insufflated gas at body temperature, to prevent the patient from cooling down. In order to avoid the disadvantages of CO₂ insufflation, gasless laparoscopy could be an alternative.

IRRIGATION-SUCTION UNIT

Within the framework of diagnostic and surgical laparoscopy, it is often necessary to drain fluids and irrigate wound surfaces until they are clean and can be viewed adequately. Sometimes, effective irrigation can also be used for adhesiolysis (hydrodissection). Suction is performed either with an additional suction pump or by means of a central vacuum supply system. It is important that these solutions are used at body temperature.

In summary, the equipment in an operating theater for endoscopic surgery (laparoscopy) should comprise (Figure 2.21):

- Gas insufflator
- Light source
- Video camera unit (Figure 2.22)
- Suction irrigation device
- Monitor and documentation system (video recorder, printer or photodigitalizer for digital image storage)

LASER INSTRUMENTATION

Utilization of the laser in advanced modern surgery owes its wide dissemination to the fact that lasers commonly used in industrial, military, commercial or scientific applications interact with biological tissue in such a way that localized and precisely controlled alterations of the cellular structure are effected irreversibly. In the hands of the skilled surgeon, the laser becomes an instrument capable of inducing desired therapeutic effects, far beyond the scope of conventional surgical tools such as cold knives or electrocautery probes. The laser enables the surgeon to utilize a variety of operational modalities for the treatment of diseased tissue. Precise incisions can be performed, lesions extending over large areas can be vaporized and voluminous lesions can be debulked and destroyed by ablation or necrotization. Very often, it is possible to target the therapeutic energy selectively at cells characterized by a well-defined property (e.g. color), implementing the selectivity of the interaction process between laser and tissue.

Laser energy can be delivered to tissue in a variety of ways: by contact or from a distance, in conjunction with an operative microscope, through an endoscope or with the aid of freehand tools.

Finally, laser treatments provide significant advantages, unmatched by competitive techniques; in the majority of cases the operation is largely hemostatic. Thus, the surgeon

enjoys the convenience of a dry and clear field, even when operating in an environment of high vascularity.

Moreover, the contamination of adjacent areas is considerably reduced because of the sealing of blood and lymph vessels. The extent of injury to surrounding tissue is, to a large degree, controllable. Consequently, the risk of postoperative pain, complications or irreversible damage is diminished considerably. In some cases, the recurrence rate of the disease also appears to be reduced. The laser enables the surgeon to reach anatomic structures the size or location of which renders them inaccessible to any other known surgical instrument.

The reasons for this impressive procedural variety and wealth of benefits lie in the particular properties of the laser as a special source of energy

Physical effects of laser on tissue

The laser effect on a tissue sample is one of transmission, reflection, scattering or absorption (Figure 2.23). The effect on tissue achieved by any laser commonly used in therapeutic medicine is a consequence of its absorption therein. In particular, the energy deposited by most of the commonly used lasers is transformed into heat, thereby obtaining a thermal effect on the tissue. The types of lasers used in therapeutic medicine are confined to the visible, ultraviolet and infrared regions of the spectrum. Figure 2.24 presents a list of these lasers with their respective wavelengths.

The infrared lasers constitute the primary subject of this book. They are widely recognized by the medical community as part of the armamentarium of modern surgery. Therefore, we elaborate further on their interaction with biological tissue.

Figure 2.25 illustrates the relative absorption of light in water as a function of wavelength. Because water is a major component of the cellular structure, its interaction with the laser is predominant. The CO₂ laser features a wave-

length of 10.6 μm in the far infrared range. It is strongly absorbed by water, as indicated in Figure 2.25. CO₂ laser radiation is readily absorbed by the first few cellular layers of tissue, constituting the first 100 μm. Consequently, this is a laser used for superficial treatments.

The neodymium : yttrium–aluminum–garnet (Nd : YAG) laser features a wavelength of 1.06 μm (near infrared). Water is completely transparent to this type of radiation. Consequently, the Nd : YAG laser is ideal for the treatment of lesions located in liquid-filled cavities, such as the bladder and the uterus (filled with a distension liquid). The Nd : YAG laser is, however, strongly scattered by the tissue. Penetrating beams are scattered and folded at multiple sites, increasing the effective path length of the beam through the tissue. Nd : YAG laser light, which is absorbed to some degree by the proteins within the tissue bed, deposits energy each time absorption takes place. The end result is the creation of a deep and laterally extended ball of affected tissue, 3–5 mm in diameter.

Contact fibers allow a more controlled incisional effect with Nd : YAG lasers, with only about 1 mm of surrounding thermal necrosis.

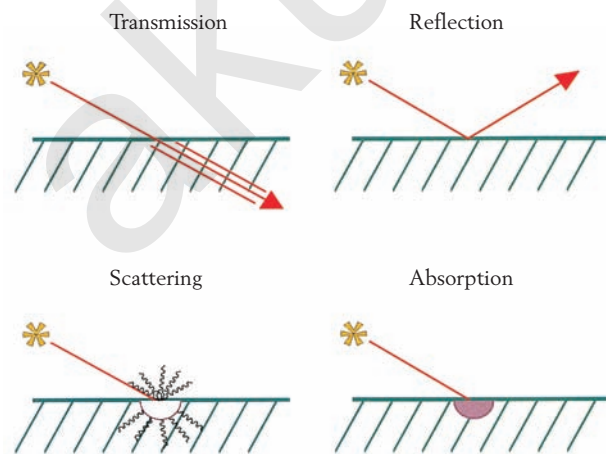


Figure 2.23 Laser–tissue interaction

Name	Color	Wavelength
Excimers	Ultraviolet	200–400 nm
Argon	Blue	400 nm
532 Yag	Green	515 nm
Krypton	Green	531 nm
	Yellow	566 nm
Dye laser	Yellow-green	577 nm
	Red	630 nm
Helium–neon	Red	630 nm
Gold vapor	Red	630 nm
Krypton	Red	647 nm
Ruby	Deep red	694 nm
Diode	Infrared	810–980 nm
Nd : YAG	Infrared	1064 nm
	Infrared	1318 nm
CO ₂	Infrared	10 600 nm

Figure 2.24 Lasers used in therapeutic medicine

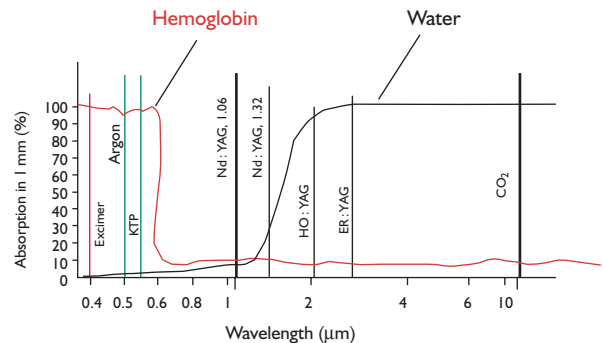


Figure 2.25 Absorption of laser radiation

More recently, high-power diode lasers have become available, emitting wavelengths of either 810 or 980 nm. Tissue interaction at these wavelengths resembles the interaction of the Nd:YAG laser; therefore, these diode lasers are replacing the Nd:YAG lasers in certain medical applications.

Thermal effects on tissue

Heat deposited in tissue elevates its temperature. Figure 2.26 summarizes how the tissue is affected, both visually and biologically, by the increase in its temperature. As long as the temperature does not reach 60°C, there is no visual change in the appearance of the tissue. Up to 45°C, the changes that occur are all reversible. Beyond that temperature, some of the cellular enzymes are destroyed and the functional operation of the cell is impaired. Between 60 and 65°C, capillary blood vessels shrink and the tissue undergoes extensive coagulation, showing distinct blanching.

It is noteworthy that the coagulation process induced by the CO₂ laser is rather different from that effected by the Nd:YAG laser. Shrinkage of the capillary vessel caused by the CO₂ laser is a result of vaporization of the water contained in the walls of the blood vessel. If, however, the CO₂ laser beam hits a vessel, it is readily absorbed by the liquid blood at its exit from the initially desiccated wall. Thus, it will never have the chance to hit the opposite wall, leaving the vessel open and, thereby, causing extensive bleeding. Hence, it is important to remember that the sharply focused beams of CO₂ lasers are inadequate for the treatment of highly vascular tissue.

Conversely, Nd:YAG lasers are unhindered by the presence of the liquid medium; consequently, they can very effectively accomplish complete coagulation of the bulk of the tissue. Nd:YAG lasers are excellent coagulators.

Temperatures between 65 and 90°C completely denature the proteins. The tissue turns a whitish color, indicative of dead cells, which subsequently slough off.

At 100°C, vaporization of the cellular water occurs. The high vapor pressure (generated by rapid expansion of

the cellular content that undergoes transformation from liquid to vapor) pushes against the cell membrane, which eventually ruptures, vigorously expelling the resulting fragments in an outgoing plume. The end effect of the entire process is the local removal of tissue matter.

If temperatures are raised much above boiling point, carbonization ultimately occurs.

Energy, power and power density

The rise in temperature of the tissue matter depends primarily on the amount of energy deposited on the target site, as well as on the capability of the tissue to rid itself of heat by dissipating it to surrounding areas. If a large quantity of energy is deposited in the tissue before it can dissipate the heat, a rise in temperature will occur.

Energy, power and power density are the physical parameters that determine the eventual rise in temperature. Energy is measured in joules. Power is the amount of energy delivered per second and is measured in watts (joules/s). The thermal effect of the laser is local. Thus, the physical quantity which governs the thermal response of the tissue is the amount of power delivered to a unit of area; this quantity is called power density, and is measured in W/cm².

The higher is the power density, the more rapid is the temperature rise on and around the area where the laser beam impinges upon the tissue. In order to obtain the desired surgical effect, both power and power density can be adjusted easily. All commercial laser systems enable the user to vary the power to the tissue in a continuous manner. At constant output powers, the power density can be varied with the aid of optical devices, which either bring the laser beam into focus on the target site, or defocus it intentionally (Figure 2.27).

The shape of the cross-section of the beam in most commercial systems is approximately circular. The diameter of the beam can be decreased or increased by the respective focusing/defocusing method. Reducing the diameter of the beam spot by a factor of two represents a reduction of the spot area by a factor of four and,

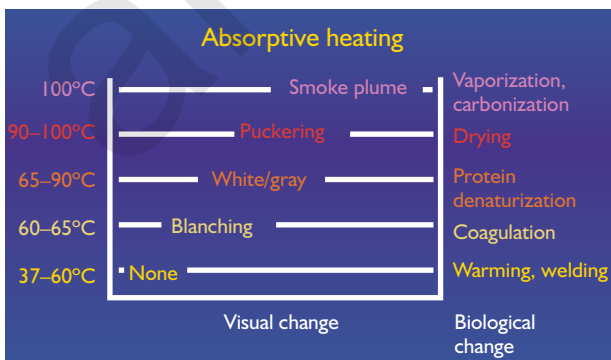


Figure 2.26 Thermal effects on tissue

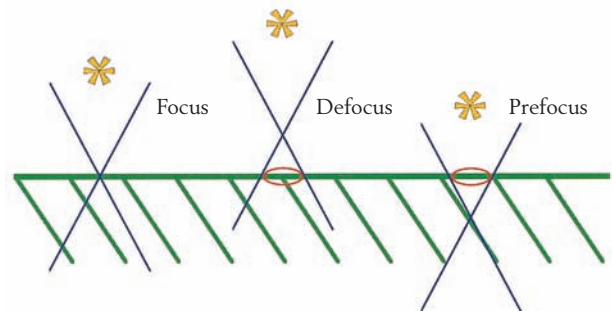


Figure 2.27 Focusing/defocusing the laser beam on tissue

consequently, a four-fold increase in the power density (Figure 2.28).

The optical system through which the CO₂ laser beam is delivered incorporates specially designed lenses. This system is responsible for bringing the beam into focus on the tissue at the operative site. For a given optical system at a given power, the maximum power density is obtained when the beam is completely focused.

If the surgical circumstances require lower power densities, the surgeon can achieve this by defocusing the beam, i.e. by increasing the diameter of the spot size and, consequently, increasing its area. Defocusing is normally effected by manually retracting the optical system from its focused position, or by employing a focusing/defocusing device.

High-power densities are required when fine incisions must be performed. Traction is applied to the tissue on both sides of the desired incision and a focused beam is aimed at the required location. The depth of the incision is a function of the power delivered and of the dwell time of the laser on each and every point of the incision. The longer is the dwell time, the larger is the volume of tissue removed by the laser and, therefore, the deeper is the cut. However, the dwell time is inversely proportional to the speed of movement of the cutting tool. In short, the depth of the incision increases with the power of the beam and decreases with the speed of movement. Vaporization may be performed with a defocused beam and high power. However, in this mode, tissue ablation is not well controlled, and is accompanied by excessive carbonization and deeper thermal necrosis. A significantly more effective CO₂ laser vaporization technique is based on rapid scanning of a focused beam over the area to be vaporized. This Flashscan™ technology allows extremely uniform, char-free, layer-by-layer vaporization with minimal residual thermal necrosis.

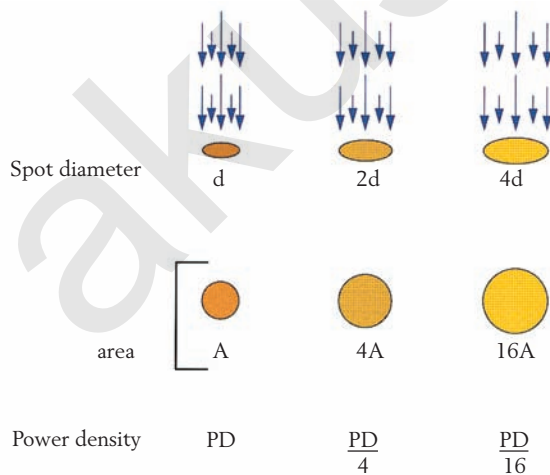


Figure 2.28 Diameter (d) and area (A) of the spot versus power density (PD)

CO₂ laser systems and accessories

The CO₂ laser beam is generated by a sealed gas-filled tube. The lasing gas is CO₂, and it is mixed with other types of gases which are required for different technological reasons. The excitation of the CO₂ molecules is effected by an electrical discharge.

One of the limitations of the CO₂ laser beam is that it cannot propagate very effectively through flexible fibers. Consequently, the delivery system ordinarily used in commercial products consists of a lightweight articulated arm, composed of straight, hollow, segmental tubes with reflective mirrors mounted at the joints. Hence, the CO₂ laser beam propagates in straight lines and bounces off each consecutive joint, eventually reaching the target tissue through an optical device attached to the end joint. As the CO₂ laser is invisible to the human eye, each laser system is equipped with a red helium–neon (He–Ne) laser tube, the direction of propagation of which is coincident with the infrared beam. The red He–Ne beam enables the surgeon to aim at the target area and simulate visually, on the tissue, the position and the extent of the therapeutic beam.

Manufacturers offer CO₂ laser units featuring various maximum powers from 15 to 150 W. CO₂ laser systems are composed of:

- A laser tube
- A power supply which provides the necessary electrical energy to excite the lasing gas
- A closed-circuit water-cooling system which removes excess heat from the tube and its surroundings
- A control system based on a microcomputer
- An articulated-arm delivery system
- A He–Ne laser tube

Figures 2.29 and 2.30 show, respectively, a schematic diagram and a photograph of a state-of-the-art CO₂ laser system.

The latest generation of CO₂ lasers employs SurgiTouch™ Flashscan technology, which significantly improves the laser's tissue vaporization capabilities. This technology, introduced by Lumenis, allows uniform, char-free, layer-by-layer tissue vaporization control with minimal residual thermal necrosis. Tissue layers as thin as 100 μm may be removed with extreme precision and excellent visual control.

The 'Flashscanner' is a miniature optomechanical scanner compatible with any Lumenis microprocessor-controlled laser (Figure 2.31). It consists of two almost, but not exactly, parallel folding mirrors. Optical reflections of the CO₂ laser beam from the mirrors cause the beam to deviate from its original direction by an angle θ (Figure 2.32). The mirrors constantly rotate at slightly different angular velocities, thereby rapidly varying with time

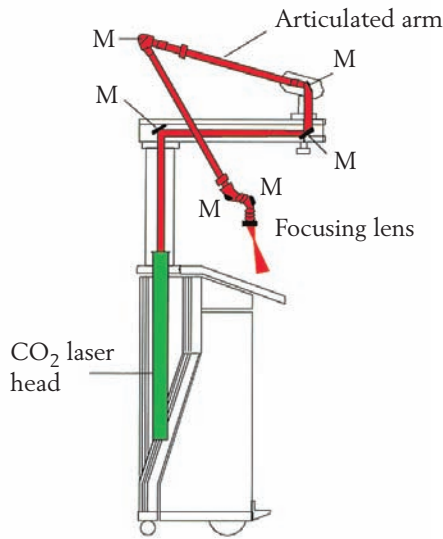


Figure 2.29 Schematic structure of a CO₂ laser. M, mirror

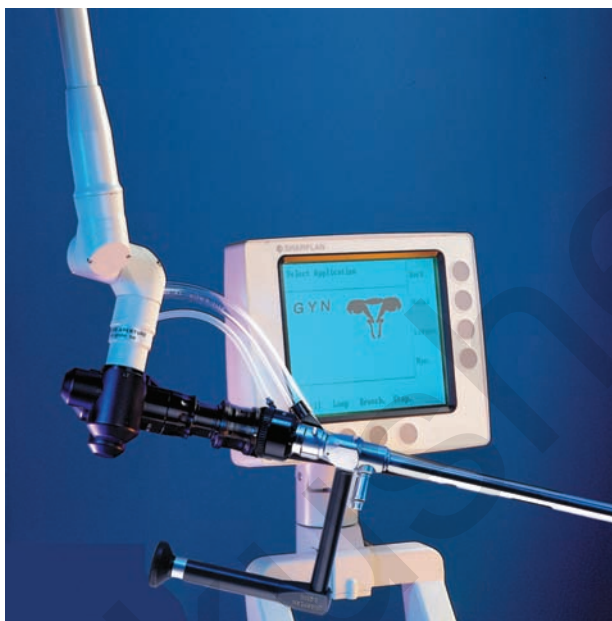

Figure 2.30 SurgiTouch™ CO₂ laser system

between zero and a maximal value, θ_{max} . By attaching the laparoscope-focusing coupler of focal length F to the Flashscan, the CO₂ laser generates a focal spot which rapidly and homogeneously scans and covers a round area of diameter $2F \tan \theta_{max}$ at the distal end of the laparoscope.

For a single-puncture laparoscope ($F = 300$ mm), θ_{max} is selected to provide a round treatment area of 2.5 mm diameter. The rapid movement of the beam over the tissue ensures a short duration of exposure on individual sites within the area, and very shallow ablation.

Since therapeutic CO₂ medical lasers typically generate a focused beam smaller than 0.9 mm in diameter at the laparoscope working distance, use of the SurgiTouch with a laser power level of 30 W will generate an optical power density of greater than 50 W/mm² on tissue. This is considerably higher than the threshold for the vaporization of tissue without residual carbon charring (the threshold for char-free tissue ablation is about 30 W/mm²). The time required for the SurgiTouch to cover homogeneously a 2.5-mm round area is about 100 ms. During this time, the 30-W operating laser will deliver 3000 mJ to the tissue. Since the typical energy required to ablate tissue completely is about 3000 mJ/mm³, keeping the laparoscope precisely on a single site for 0.1 s will generate a clean, char-free crater of 0.2 mm in depth.



a



b

Figure 2.31 (a) SurgiTouch optomechanical scanner consisting of two almost, but not exactly, parallel micro-processor-controlled mirrors; (b) 'Flashscanner', connected to the direct coupler (ESC Lumenis)

Nd:YAG laser and accessories

Manufacturers offer Nd:YAG laser units featuring different maximum powers, from 40 to 100 W. Nd:YAG laser systems are composed of:

- A laser head or resonator
- A power supply, which furnishes the flashlight lamp with the necessary electrical energy
- A closed-circuit water-cooling system, further chilled by a radiator which removes excess heat from the resonator
- A control system, based on a microcomputer
- A He-Ne laser tube
- An output port optical assembly to which the external glass fiber is attached

Several types of fibers are offered with the Nd:YAG laser.

THE OPERATING LAPAROSCOPE

The operating laparoscope for laser laparoscopy is an instrument which is 11 mm in diameter with a 7.3-mm operative channel. To use the CO₂ laser through the laparoscope, the operator simply swings the articulated arm of the laser over the operative field and attaches the BeamAlign™ coupler to the operative channel of the laparoscope (Figure 2.33) or to a special second-puncture laser delivery tube. The laser coupler assembly (Figure 2.34) consists of the following:

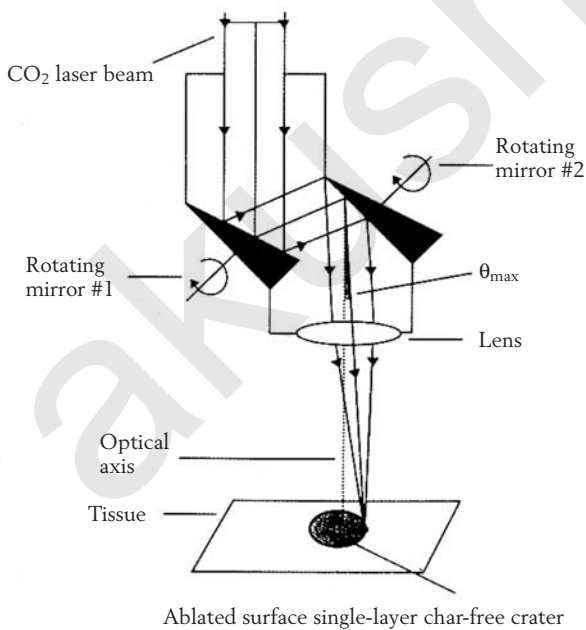


Figure 2.32 Optical reflections of the beam from the two mirrors cause it to be deflected from its original direction by θ°

- Direct coupler housing: this contains a mechanical alignment mechanism which must be preadjusted for the specific operating laparoscope used. Once adjusted, alignment remains for multiple uses with the same laparoscope
- Interchangeable lens housing:
 - 200-mm working distance lens housing to match beam focal length to nominal length of standard second-puncture tube, giving spot size diameter of 0.64 mm; laser beam may also be defocused
 - 300-mm working distance lens housing to match beam length to nominal length of single-puncture tube (and optional 300-mm second-puncture tube), giving spot size diameter of 0.70 mm; laser beam may also be defocused
 - Each lens housing has a groove around it for convenient attachment of the sterile drape
- Laser arm attachment

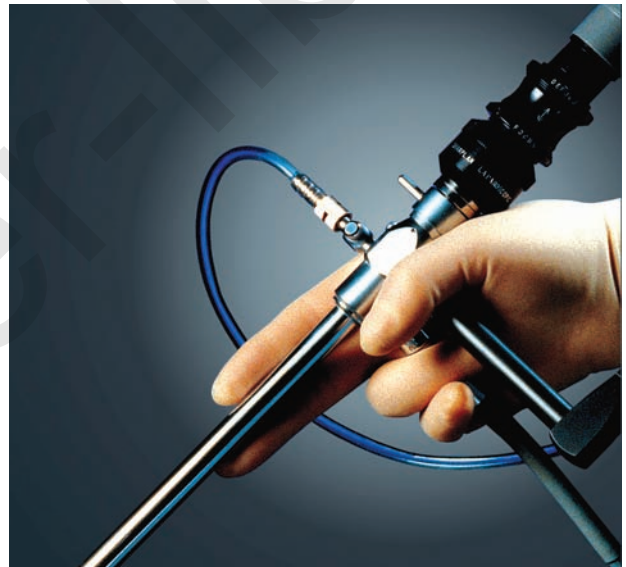

Figure 2.33 The single-puncture operating laparoscope for laser laparoscopy. The direct coupler containing the focusing lens is attached to the operative channel of the laparoscope



Figure 2.34 Laser 'direct' coupler (ESC Lumenis)

SMOKE EVACUATION

To allow a flow of fresh CO₂ down the beam channel, the CO₂ insufflation tubing is attached to this operative channel; the flow of CO₂ from the insufflator displaces smoke, which can reduce the power of the beam from the laser channel, and prevents fogging of the mirror and lens in the black coupler. To evacuate smoke, a Verres needle can be inserted suprapubically under direct vision and transillumination, directing it towards the target site and connecting it to the smoke evacuation system. Auxiliary kits are available for synchronizing smoke evacuation with laser emission, providing automatic smoke evacuation from the target site.

With the automatic smoke evacuation kit installed, smoke evacuation begins with actual laser emission and remains active for 3 s after the laser emission ceases.

If smoke disturbs the viewing field, the smoke evacuation flow can be increased, taking care not to cause a collapse of the pneumoperitoneum. The equilibrium state will be reached when the insufflation system is able to provide the amount of gas that the smoke evacuation port is releasing. If a smoke evacuation kit is installed, the expulsion of gas (smoke) can be regulated using a sterile infusion drip kit.

SECOND-PUNCTURE PROBES

The current second-puncture probe which permits use of the CO₂ laser with the laparoscope is a double-ring probe, 8 mm in external diameter with a 5.6-mm operating channel. The second-puncture laparoscope is based on two tubes. The inner tube contains the operating channel and insufflation port as well as the locking device for securing it to the outer tube. Two distinct outer tubes are provided: open-ended and hook-tipped (Figure 2.35).

The outer tube includes a smoke evacuation port with stopcock. This assembly provides the user with a double-lumen second-puncture laparoscope that is easily disassembled for cleaning purposes. The hook-tipped outer tube is recommended for use in clinical situations that require a backstop to protect healthy tissue beyond the treatment site. The probe attaches to the same laser coupler assembly that is used with the operative laparoscope. A 200-mm working-distance lens is then used.

ACCESSORIES

Third-puncture probes are shown in Figure 2.36. The following operating instruments were developed in our department in collaboration with the Storz company:

- Atraumatic probe
- Hook for fimbrioplasty
- Probe with backstop for use in vaporizing adhesions near the blood vessels
- Smoke suction and rinsing tube
- Double-channel probe for rinsing the pelvis and for suction



Figure 2.35 Second-puncture probes. From top to bottom: hook-tipped, open-ended, trocar




Figure 2.36 Third-puncture probes: left, atraumatic probe; center, hook for fimbrioplasty; right, probe with backstop. An inner channel is used for rinsing the operating field (Karl Storz)

SECTION I
Operative laparoscopy

Part I
Endometriosis

akusherlib.ru

akusher-lib.ru

Laparoscopic management of peritoneal endometriosis

P Jadoul, J Donnez

Endometriosis is the cause of pelvic pain (dysmenorrhea, dyspareunia) and infertility in more than 35% of women of reproductive age.

In 1997, we demonstrated that three entities must be clearly distinguished¹

- Peritoneal endometriosis
- Ovarian endometriomas (chocolate cysts)
- Retroperitoneal endometriosis or adenomyosis

In this chapter, we focus on the diagnosis and management of peritoneal endometriosis.

DIAGNOSIS

The increased diagnosis of endometriosis at laparoscopy can be explained by the increased experience and ability of the surgeon to detect such lesions. The diagnosis of peritoneal endometriosis at the time of laparoscopy is often made by the observation of typically puckered black and bluish lesions, but there are also numerous subtle appearances of peritoneal endometriosis^{2,3}. The greatest change has been seen in the case of these 'subtle' lesions, the diagnosis of which increased from just 15% in 1986 to 65% in 1988²⁻⁹. These lesions, frequently non-pigmented, were first diagnosed as endometriosis following biopsy confirmation by Jansen and Russell in 1986¹⁰. Endometriosis was confirmed in 81% of white opacified lesions, 81% of red flame-like lesions, 67% of glandular lesions, 50% of subovarian adhesions, 47% of yellow-brown patches and 45% of circular peritoneal defects. Later, Stripling *et al.*⁶ confirmed endometriosis in 91% of white lesions, 75% of red lesions, 33% of hemosiderin lesions and 85% of other lesions. In our study, we confirmed the presence of endometriosis in non-pigmented lesions of the peritoneum in more than 50% of cases.

A recent study published in 2005 by Marchino *et al.*¹¹ found histological proof of endometriosis in 64% of classic lesions, 62% of vesicular implants, 54% of black lesions, 25% of hemorrhagic lesions, 0% of peritoneal pockets and 20% of scarred lesions. In this study, the authors cast doubt on the accuracy of diagnosis of endometriosis by simple visual inspection of the abdominal cavity, and emphasized the need for histological proof. The accuracy of their histological evaluation raises questions, however, as they confirmed endometriosis in only 64% of typical lesions. In one of our studies, histology confirmed the presence of endometriosis in 93% of typical lesions⁸.

We classified peritoneal lesions into black, red and white lesions for the first time in 1992 (Table 3.1), recognizing that the concept of non-visible endometriosis should be borne in mind³.

Black or bluish lesions

The typical black peritoneal endometriotic lesion (Figure 3.1a) results from tissue bleeding and retention of blood pigment, producing brown discoloration of tissue. Puckered black lesions are a combination of glands, stroma and intraluminal debris (Figure 3.1b).

Red lesions

Red flame-like lesions, glandular excrescences and subovarian adhesions must be considered as the most active lesions^{1,3}, and are described as follows:

- (1) Red flame-like lesions of the peritoneum (Figure 3.2a) or red vesicular excrescences, more commonly affecting the broad ligament and the uterosacral ligaments: histologically, red flame-like lesions and vesicular excrescences are due to the presence of active endometriosis surrounded by stroma (Figure 3.2b).
- (2) Glandular excrescences on the peritoneal surface, which in color, translucency and consistency closely resemble the mucosal surface of the endometrium seen at hysteroscopy (Figure 3.3a): biopsy reveals the presence of numerous endometrial glands (Figure 3.3b).

Table 3.1 Different appearances of peritoneal endometriosis

Color	Description
Black	Typical puckered black lesions
Red	Red flame-like lesions Glandular excrescences Petechial peritoneum Areas of hypervascularization
White	White opacification Subovarian adhesions Yellow-brown peritoneal patches Circular peritoneal defects

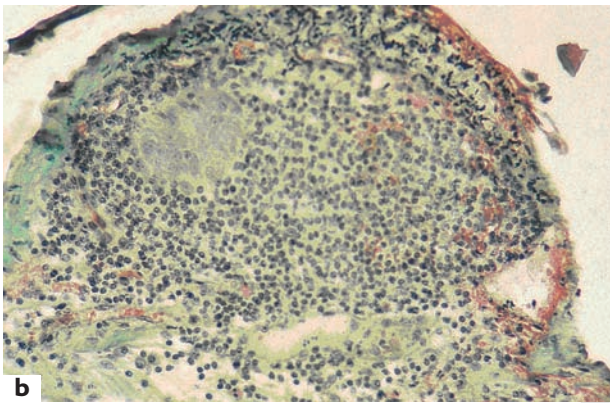
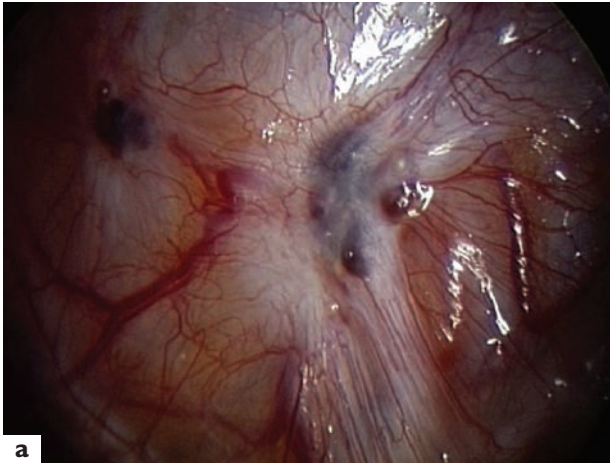


Figure 3.1 Puckered black lesion. (a) Laparoscopic aspect; (b) histology: presence of endometrial glands and typical stroma; note the presence of intraluminal debris (Gomori's trichrome $\times 110$)

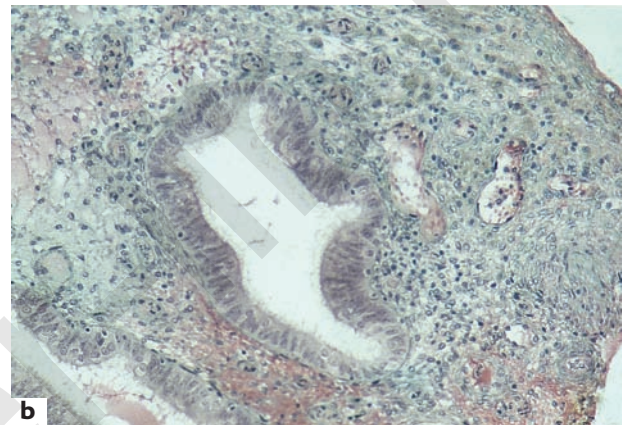
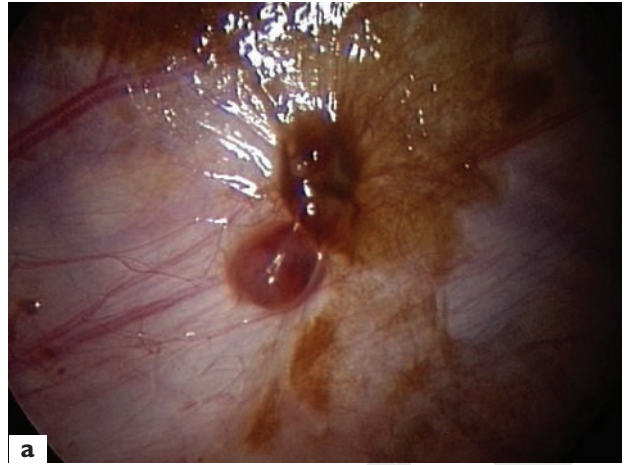


Figure 3.2 Red flame-like lesion of the peritoneum. (a) Laparoscopic aspect; (b) histology: active endometrial glands surrounded by stroma (Gomori's trichrome $\times 110$)

- (3) Subovarian adhesions, or adherence between the ovary and the peritoneum of the ovarian fossa, as distinct from adhesions characteristic of previous salpingitis or peritonitis: they are the consequence of an inflammatory reaction induced by active lesions (Figure 3.4a and b).
- (4) Areas of petechial peritoneum or areas with hypervascularization, diagnosed as endometriosis in one of our previous studies^{1,8,12}: these lesions resemble petechial lesions resulting from manipulation of the peritoneum or from hypervascularization of the peritoneum (Figure 3.5a). They generally affect the bladder and the broad ligament; histologically, red blood cells are numerous and endometrial glands are scarce (Figure 3.5b).

White lesions

Sometimes, subtle endometriotic lesions are the only lesions seen at laparoscopy and appear as:

- (1) White opacification of the peritoneum (Figure 3.6a), which looks like peritoneal scarring or circumscribed patches, often thickened and sometimes raised: histologically, white opacified peritoneum is due to the presence of an occasional retroperitoneal glandular structure and scanty stroma surrounded by fibrotic tissue or connective tissue (Figure 3.6b).
- (2) Yellow-brown peritoneal patches resembling 'café au lait' patches (Figure 3.7a): the histological characteristics are similar to those observed in white opacification but, in yellow-brown patches, the presence of the blood pigment hemosiderin among the stromal cells produces the 'café au lait' color (Figure 3.7b).
- (3) Circular peritoneal defects, as described by Chatman⁴ (Figure 3.8a): serial section demonstrates the presence of endometrial glands in more than 50% of cases (Figure 3.8b).

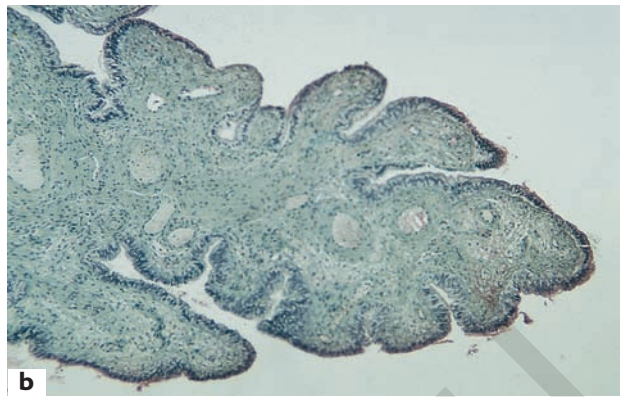
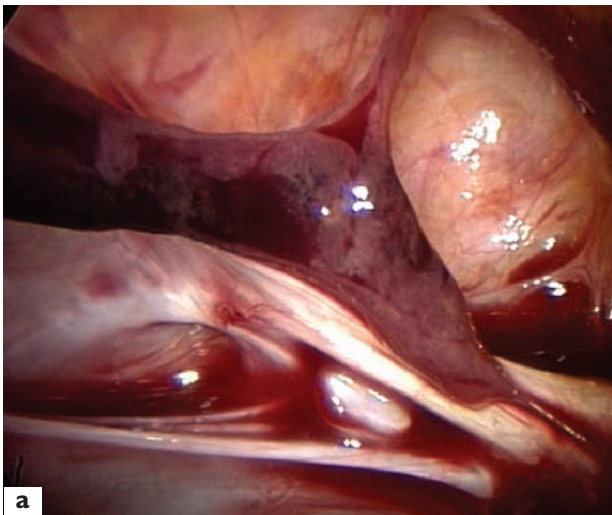


Figure 3.3 Glandular excrescences on the peritoneal surface. (a) Laparoscopic view; (b) histology: presence of numerous endometrial glands (Gomori's trichrome $\times 56$)

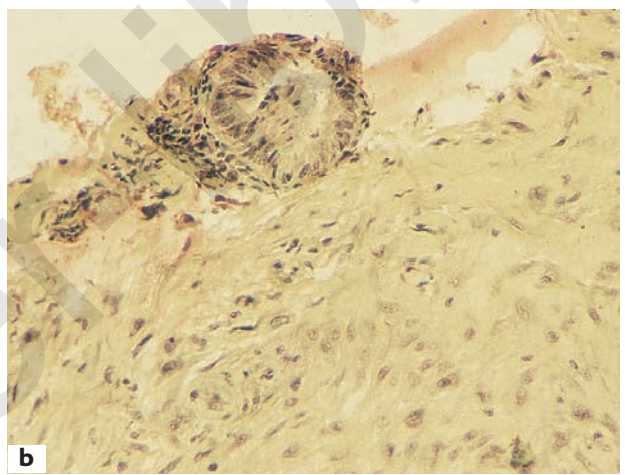
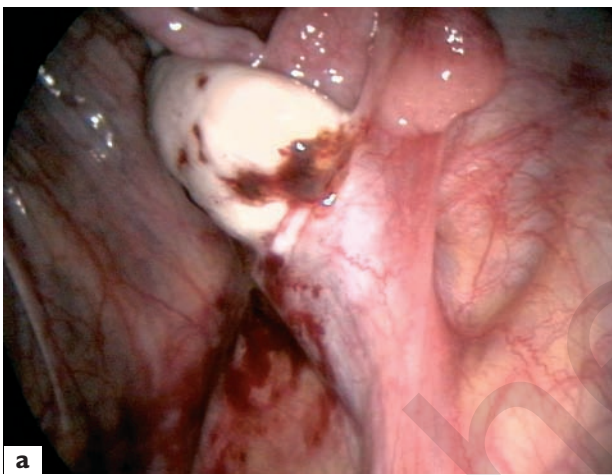


Figure 3.4 Subovarian adhesion. (a) Laparoscopic aspect: adherence between the ovary and peritoneum of the ovarian fossa; (b) connective tissue with sparse endometrial glands (Gomori's trichrome $\times 110$)

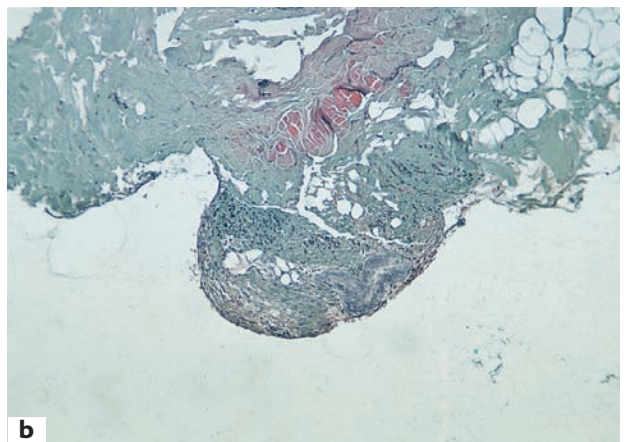
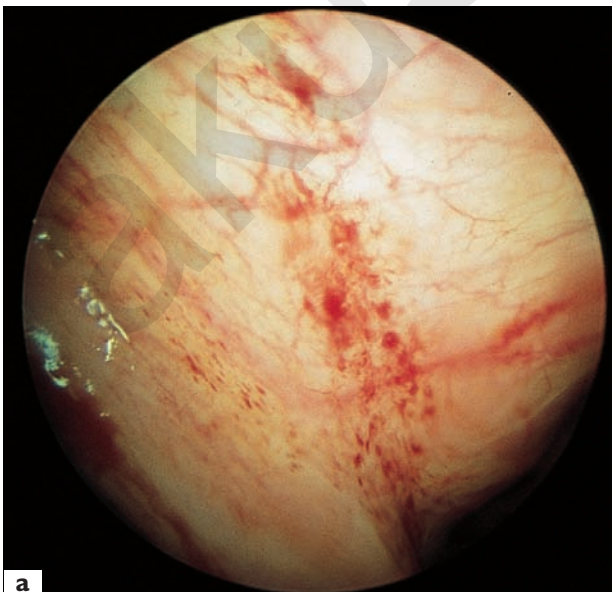


Figure 3.5 Areas of petechial peritoneum. (a) Laparoscopic aspect; (b) histology: note the typical endometrial glands and stroma (Gomori's trichrome $\times 56$)

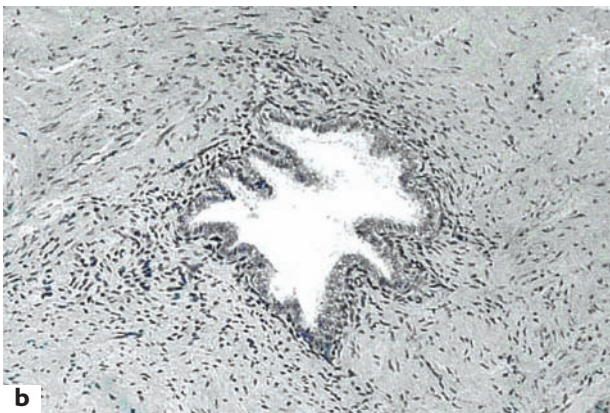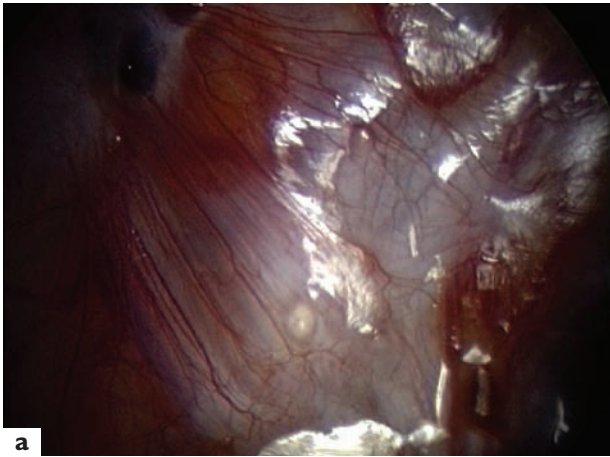


Figure 3.6 White opacification of the peritoneum. (a) Laparoscopic aspect; (b) histology: rare retroperitoneal glandular structure and scanty stroma surrounded by fibrotic tissue (Gomori's trichrome $\times 110$)

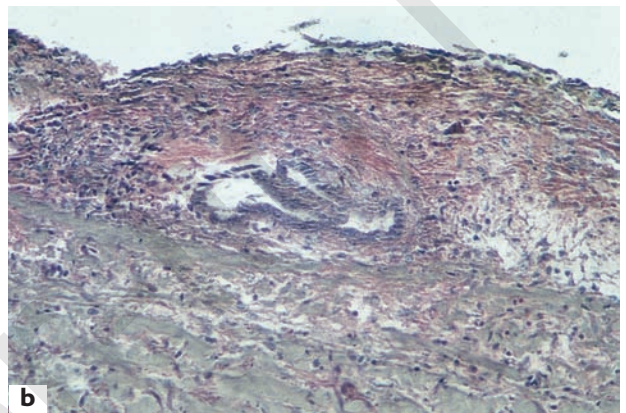
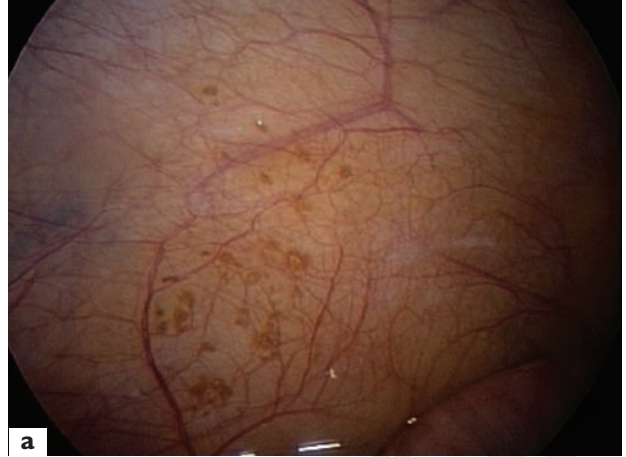

Figure 3.7 Yellow-brown peritoneal patches of the peritoneum. (a) Laparoscopic aspect; (b) histology: the presence of blood pigment (hemosiderin) among the stromal cells produces the 'café au lait' color (Gomori's trichrome $\times 110$)

Non-visible endometriosis

In one of our studies⁸ (Table 3.2), biopsies were taken from visually normal peritoneum of the uterosacral ligaments. Histological study revealed the presence of endometriotic tissue in two out of 32 infertile women without endometriosis. This rate (6%) was less than half the rate (13%) observed in normal peritoneum taken from 52 women with visible endometriosis, but shows that unsuspected peritoneal endometriosis can be found in the visually normal peritoneum of infertile women, with or without known associated endometriosis. The size of endometriotic lesions in visually normal peritoneum, ranging from 88 to 720 μm (mean 313 μm , SEM 185 μm), probably explains why the peritoneum had a normal aspect and why the lesions were not visible, even though a meticulous inspection was carried out to identify small and non-hemorrhagic lesions.

Since our first publication in 1990, the findings of others, such as Nezhat *et al.*¹³, and more recently Walter *et al.*¹⁴, have reinforced the concept of invisible lesions.

The concept of 'non-visible' endometriosis was recently reviewed by Redwine¹⁵. His conclusion was that 'invisible microscopic endometriosis' or IME is a rare and clinically unimportant entity and that allegations of its existence are almost always due to inexperience and lack of magnification at surgery.

According to Redwine, human visual acuity is remarkable, and a human hair (100 μm in diameter) can be seen at arm's length at a distance of 70 cm; he therefore suggests that the non-visible lesions described in our study (ranging from 88 to 720 μm) were actually large enough to be seen.

Redwine forgets to mention, however, that all the non-visible lesions identified in our study were in the retroperitoneal space, beneath the mesothelium, at a distance varying from about 100 to 900 μm . Furthermore, we can safely assume that every gynecologist, every medical doctor and indeed every human-being would agree that it is very difficult to see a human hair under a thin sheet of paper!

In spite of the scant evidence put forward by Redwine, the presence of microscopic endometriosis in visually normal pelvic peritoneum has become a generally accepted concept¹⁶. Evers *et al.*¹⁷ go one step further, suggesting that invisible endometriosis is much more frequent than generally suspected: 'If in every patient in the studies on invisible endometriosis, the researchers had taken 8–16 biopsies instead of a single one, all the women with normal peritoneum would have shown evidence of endometriosis.'

The take-home message is that laparoscopy is fallible. Inspecting the peritoneum through the looking glass of a laparoscope has high false-positive and false-negative rates: not all we see is endometriosis; and if we do not see it, it may still be there. But the presence of non-visible lesions is surely not an argument for prescribing postoperative hormonal treatment, nor does it explain recurrence. Non-visible endometriotic lesions are quiescent lesions. They are non-active and, at this stage, clinically irrelevant. Nevertheless, nobody knows the exact evolution of these lesions.

Vascularization of endometriotic implants is probably one of the most important factors in the growth and invasion of other tissue by endometrial glands. We evaluated histologically the vascularization of typical peritoneal endometriosis and its modifications, according to the macroscopic appearance of peritoneal endometriosis^{18,19}.

Our study demonstrated significant differences between the typical (black or bluish) lesion and the 'subtle' lesion. Subtle lesions were classified as red lesions (vesicular, red flame-like and glandular excrescences) and white lesions (white opacification, yellow-brown patches and circular peritoneal defects). When compared with typical lesion data, vascularization was found to be significantly higher in red lesions and significantly lower in white lesions. This was due to an increase (red) or decrease (white) in the volume occupied by the vessels, as proved by both the mean capillary surface area and the ratio of capillaries/stroma surface area.

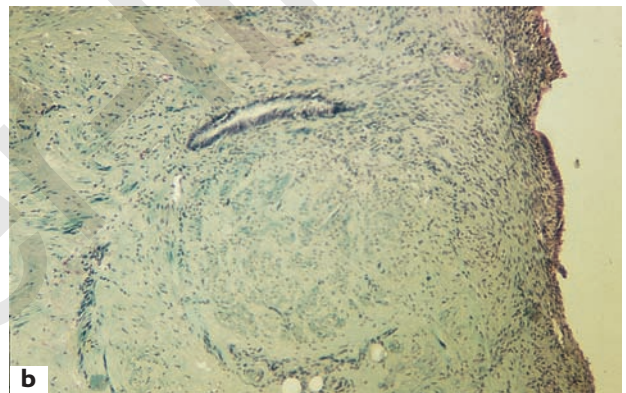
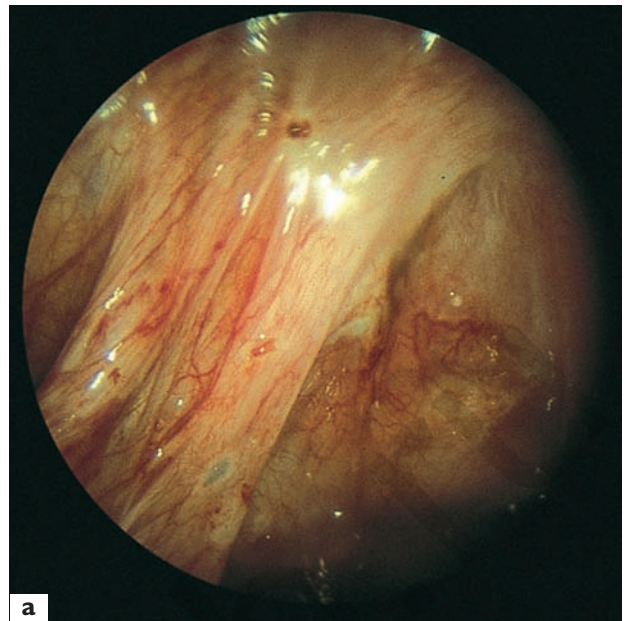


Figure 3.8 Circular peritoneal defects. (a) Laparoscopic aspect; (b) histology: typical endometrial glands are found in more than 50% of cases (Gomori's trichrome $\times 25$)

Table 3.2 Morphological characteristics of peritoneal endometriosis

	Group I (n = 52)	Group II (n = 32)
Number of biopsies		
from visible endometriotic lesions*	86	—
from normal-looking peritoneum*	52	32
Histological proof of endometriosis		
in visible lesions*	80/86 (93%)	—
in normal-looking peritoneum*	7/52 (13%)	2/32 (6%)

*Macroscopic appearance

This difference was more evident in the group of red lesions, where the number of capillaries/mm² was significantly lower than in the other subgroups. Thus, in red lesions, the increased level of vascularization is due to a greater number of larger vessels than in the other groups. In white lesions, there were a greater number of smaller vessels; the number of capillaries was higher than in red lesions.

The mitotic index was also significantly different in the three groups. Mitotic processes permit the maintenance and growth of peritoneal endometriosis. The absence of mitosis in white lesions proves their low 'activity'^{8,18,19}.

According to our data, we can suggest that there are probably different types of peritoneal endometriotic lesions, at different stages of development. Red flame-like lesions and glandular excrescences are probably the first stage of early implantation of endometrial glands and stroma.

The significantly higher stromal vascularization and epithelial mitotic index could be responsible for the invasion of ectopic sites by glands and stroma. Thereafter, menstrual shedding from viable endometrial implants could initiate an inflammatory reaction, provoking a scarification process which encloses the implant. The presence of intraluminal debris is responsible for the typical black coloration of the same lesion. This scarification process is probably responsible for the reduction in vascularization,

as proved by the significant decrease in the capillaries/stroma relative surface area. Thereafter, the inflammatory process devascularizes the endometriotic foci, and white plaques of old collagen are all that remain of the ectopic implant. Concerning white lesions, our study demonstrated an absence of mitosis and poor vascularization, although a similar number of capillaries were found compared with typical lesions. Our hypothesis is that white opacification and yellow-brown lesions are latent stages of endometriosis. They are probably non-active lesions, which could be quiescent for a long time^{18,19}.

Our morphological and morphometric data lead us to suggest that eutopic endometrium and red peritoneal lesions are similar tissues, red lesions being recently implanted and regurgitated endometrial cells^{20,21}. These data constitute an argument in favor of the transplantation theory for peritoneal endometriosis (Figure 3.9). After endometrial tissue transplantation, the factors that regulate the attachment phase and initiate subsequent ectopic growth are not known, but a new hypothesis discussed by Donnez and Van Langendonck²² in a recent paper suggests the involvement of heme and reactive oxygen species in the development of endometriosis.

Erythrocytes²³, apoptotic endometrial tissue and cell debris²⁴ transplanted into the peritoneal cavity by menstrual reflux and macrophages²⁴ have all been implicated as potential inducers of oxidative stress (Figure 3.10).

Erythrocytes are likely to release pro-oxidant and proinflammatory factors, such as hemoglobin and its highly toxic by-products heme and iron, into the peritoneal environment. However, erythrocytes are found in the peritoneal cavity of 90% of menstruating women²⁵. Thus, why do some patients develop macroscopically visible peritoneal endometriotic lesions, while others do not? One hypothesis is that, in some patients, protective peritoneal mechanisms are swamped by menstrual reflux, either because of the abundance of the reflux or because of defective scavenging systems²⁶.

Catabolism of hemoglobin involves its degradation into its protein component and non-protein core, heme. Most cells protect themselves from heme toxicity by rapid expression of scavenger proteins, such as hemopexin, and by induction of heme oxygenase-1, which catalyzes heme degradation²⁷.

All products of heme catabolism are biologically active. These products include iron, carbon monoxide acting as a signal molecule and biliverdin, which is further converted into bilirubin, both biliverdin and bilirubin acting as antioxidants. Van Langendonck *et al.*²⁸ showed that endometrial cells express constitutive heme oxygenase-2 and inducible heme oxygenase-1, and that endometrial lesions, especially red lesions, strongly express inducible heme oxygenase-1²⁹. However, the fact that heme oxygenase-1 was found to be poorly expressed in macrophages and mesothelial cells and that levels of bilirubin, the final by-product of hemoglobin catabolism,

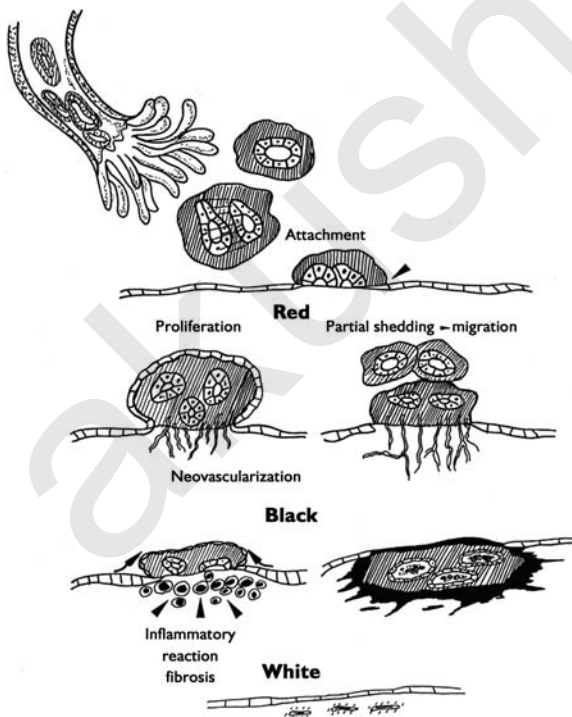


Figure 3.9 Hypothesis of peritoneal endometriotic lesion evolution

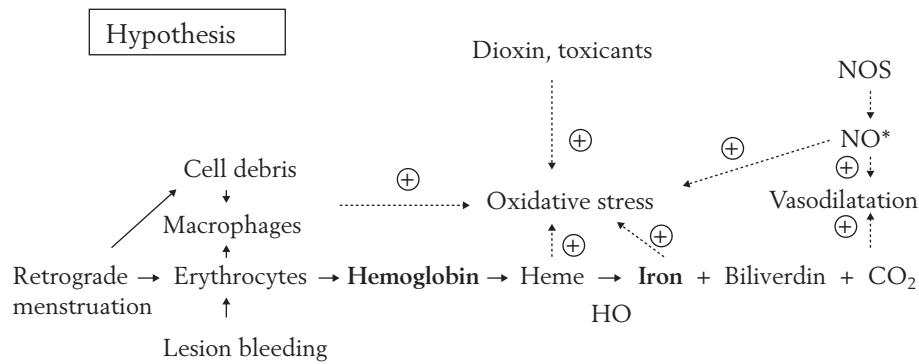


Figure 3.10 Hypothesis explaining oxidative stress in the peritoneal cavity of women with endometriosis. Bold type indicates factors that have been studied specifically in relation to pelvic endometriosis. CO₂, carbon dioxide; HO, heme oxygenase; NO, nitric oxide; NOS, nitric oxide synthase

were not increased in peritoneal fluid may suggest that detoxifying systems are overwhelmed by excess hemoglobin in endometriosis^{29,30}.

The presence of erythrocytes, which release pro-oxidant and proinflammatory factors into the peritoneal environment, could be one of the key factors to explain peritoneal endometriosis.

Red lesions are consistently located on the surface of the peritoneum, which consists histologically of a thin layer of loose connective tissue covered with a layer of mesothelium. There is a rich supply of subperitoneal blood vessels and lymphatics³¹. In our opinion, vascularization of endometriotic implants is probably one of the most important factors of growth and invasion of other tissue by endometrial glands³². Thereafter, detachment of glands from viable red endometrial implants, explained by the presence of matrix metalloproteinases (MMPs), could initiate their implantation in other peritoneal sites, as in a 'metastatic' process³³. Preliminary data from our group revealed the presence of MMPs in the stroma of red lesions throughout the menstrual cycle, although in eutopic endometrium, MMPs are detected only during the marked decline in progesterone. After this partial shedding, the remaining red lesion continues to regrow until the next shedding, but menstrual shedding finally induces an inflammatory reaction, provoking a scarification process that encloses the implant. The enclosed implant becomes a 'black' lesion because of the presence of intraluminal debris. This scarification process is probably responsible for the reduction in vascularization, as proved by the significant decrease in the relative surface areas of the capillaries and stroma. In some cases, the inflammatory process and subsequent fibrosis totally devascularize the endometriotic foci, and white plaques of old collagen are all that remain of the ectopic implant. White opacification and yellow-brown lesions are latent stages of endometriosis. They are probably inactive lesions that could be

quiescent for a long time. In agreement with Brosens³⁴, we regard red lesions as early endometriosis and black lesions as advanced endometriosis. White lesions are believed to be healed endometriosis or quiescent or latent lesions.

TREATMENT

Complete resolution of endometriosis is not yet possible, but therapy has three main objectives: (1) to reduce pain; (2) to increase the possibility of pregnancy; (3) to delay recurrence for as long as possible.

Medical and/or surgical therapy can be proposed for endometriosis. However, the efficacy of medical and surgical treatment of endometriosis-associated infertility and pelvic pain continues to be a source of debate and controversy.

In infertile women presenting with minimal or mild endometriosis (American Fertility Society (AFS) classification), laparoscopic 'destruction' was initially proved to be the first line of therapy³⁵, but a later study³⁶ demonstrated exactly the opposite. It is very curious that two evidence-based medicine (EBM) (degree 1) studies on the same subject reached two completely different conclusions.

In the first study³⁵, 341 infertile women (20–39 years of age) with minimal or mild endometriosis were randomized into two groups: either laparoscopic resection or ablation of the endometriotic lesions ($n=172$), or diagnostic laparoscopy ($n=165$). Cumulative pregnancy rates of 30.7% and 17.7%, respectively, were achieved. The authors concluded that laparoscopic resection or ablation of minimal and mild endometriosis enhances fecundity in infertile women. The most frequently cited bias is that patients were aware of the randomization. Another possible bias could be that mapping of the lesions was not considered in the selection at the time. Moreover, no

distinction was made between red, black and white lesions. Vascularization and mitotic activity, which are criteria suspected of inducing infertility, were not taken into account. This, surely, influenced the peritoneal fluid content and the peritoneal inflammatory reaction, with resulting cytokine production and macrophage induction³⁷.

The results of the later study published by the 'Gruppo Italiano per lo Studio dell'Endometriosis'³⁶ do not support the hypothesis that ablation of endometriotic lesions markedly improves fertility rates. Here, too, bias exists: first, the series is small (54 vs. 47 patients); second, seven centers participated in the study, giving a mean of 14 patients per center; third, histological confirmation of the diagnosis of endometriosis was not requested; and last, the percentage of active red lesions or non-active black or fibrotic lesions is unknown. We also have no idea of the vascularization and mitotic activity of the lesions.

It is easy to criticize, but which study should we believe if we agree that both studies are supposed to be randomized controlled trials? We are therefore faced with the following question: do we really need evidence-based medicine (degree 1) when we know that two prospective, randomized controlled studies have led to two completely opposing conclusions?

As far as endometriosis-related pain is concerned, medical treatment alone is not effective, and the results of therapy with a gonadotropin-releasing hormone analog (GnRH-a) are disappointing. Following the laparoscopic diagnosis of endometriosis in 130 patients, Waller and Shaw³⁸ administered GnRH-a treatment for 6 months. Most of the women underwent second-look laparoscopy. The cumulative recurrence rate 5 years after cessation of treatment was 53.4% (36.9% for minimal disease and 74% for severe disease). The authors concluded that patients treated with GnRH-a alone stand a greater chance of suffering a recurrence, particularly if the disease is more severe. A second trial confirmed the poor results of purely medical therapy. Miller *et al.*³⁹, retrospectively analyzed data from 327 patients treated for 6 months with danazol (128/327) or GnRH-a (199/327). The mean interval before pain recurred was 6.1 months in the danazol group and 5.2 in the GnRH-a group. Recurrence times varied according to the stage of endometriosis. Miller *et al.* found this rapid recurrence of pain disappointing in both treatment groups.

Our group clearly demonstrated that relatively hormone-independent endometriotic lesions persisted after GnRH-a treatment^{40,41}.

We can conclude that, because of the limited information currently available on the activity of lesions described in studies on mild or minimal endometriosis, any absolute statement on endometriosis and infertility and pain is probably inappropriate at this time. Nevertheless, it seems that there are more arguments in favor of treating minimal and mild endometriosis at laparoscopy, if laparoscopy is decided upon. Thus, in the case of pain or infertility,

endovaginal echography must be performed, with CA125 dosage if required (Figure 3.11). If the two examinations prove normal, the question of laparoscopy arises. In some departments, medical therapy will be attempted. In other departments such as ours, laparoscopy will automatically be performed in order to evaluate the presence or absence of endometriosis and establish the exact stage of the disease. It should be emphasized that preventing the progression of endometriosis may be considered an argument in support of laparoscopy.

In the case of pain, dyschezia or deep dyspareunia, a very careful vaginal examination should be carried out to exclude the presence of nodules. If a nodule of the rectovaginal septum is discovered, preoperative examinations must be performed (Figure 3.12; and see Chapter 6).

ENDOSCOPIC TECHNIQUES

For peritoneal endometriotic implants, three different techniques exist: laser vaporization, excision and coagulation.

Laser vaporization

In our department, we use the CO₂ laser to vaporize peritoneal endometriosis.

A power setting of 40–50 W is used. The debulking of endometriotic implants is best performed using a continuous firing mode. If a lesion is overlying a vital structure such as the ureter, urinary bladder, colon or larger blood vessels, a retroperitoneal injection of fluid (hydrodissection and hydroprotection) provides safer vaporization of the lesions. This technique allows a 100–200- μ m depth of vaporization, thus substantially limiting the depth of penetration. Vaporizing an endometriotic implant (Figure 3.13) provokes the bubbling of old blood, followed by a curdy white material, representing vaporization of the stromal layer. After the endometriotic lesion has been vaporized, retroperitoneal fat is encountered, and the appearance of bubbling confirms complete vaporization of the lesion.

Excision

Another technique for removal of peritoneal endometriosis is excision with scissors. The lesion is grasped with forceps and then, using scissors, the peritoneum and endometriotic lesion are excised. Once all the endometriotic tissue has been excised, it is removed.

Care is taken to remove all the lesions and to have sufficient borders between the lesions and healthy peritoneum, which is left in place.

With this technique, excision of the peritoneum seems rather excessive. Moreover, excision of large peritoneal defects may induce adhesions. The risk of adhesions is not zero with laser vaporization, but is much lower than after large excision.

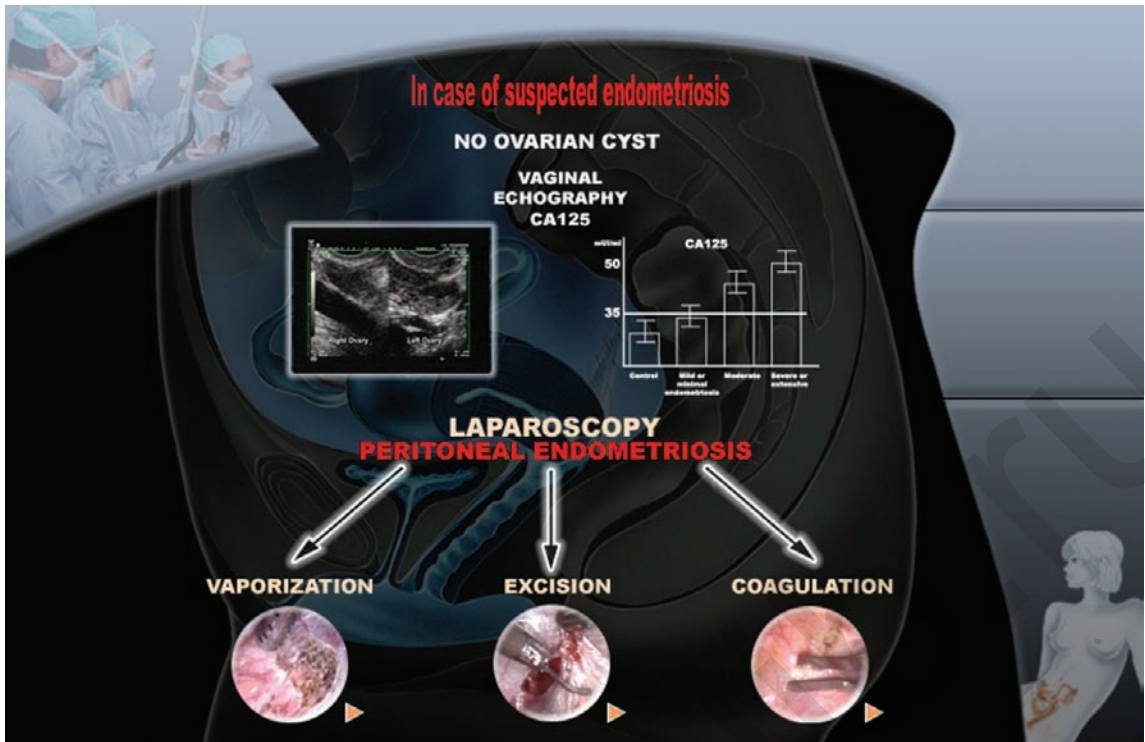


Figure 3.11 Decisional tree in case of suspected endometriosis

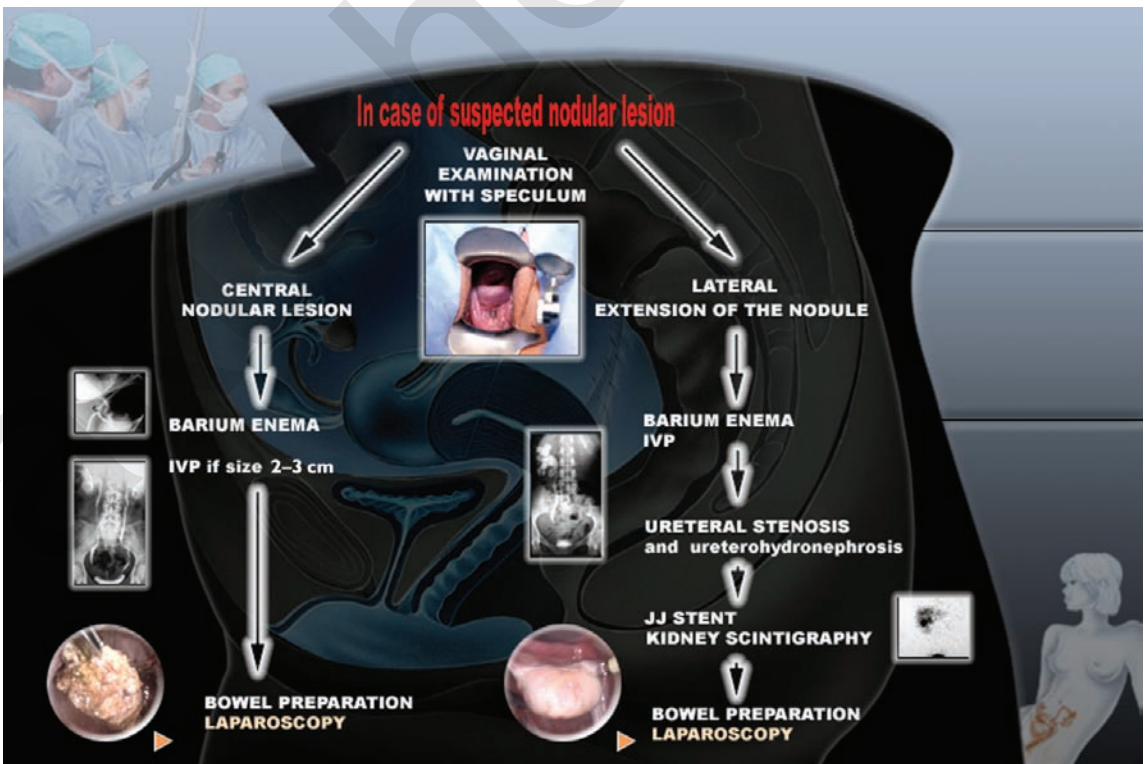


Figure 3.12 Decisional tree in case of suspected rectovaginal nodule. IVP, intravenous pyelography

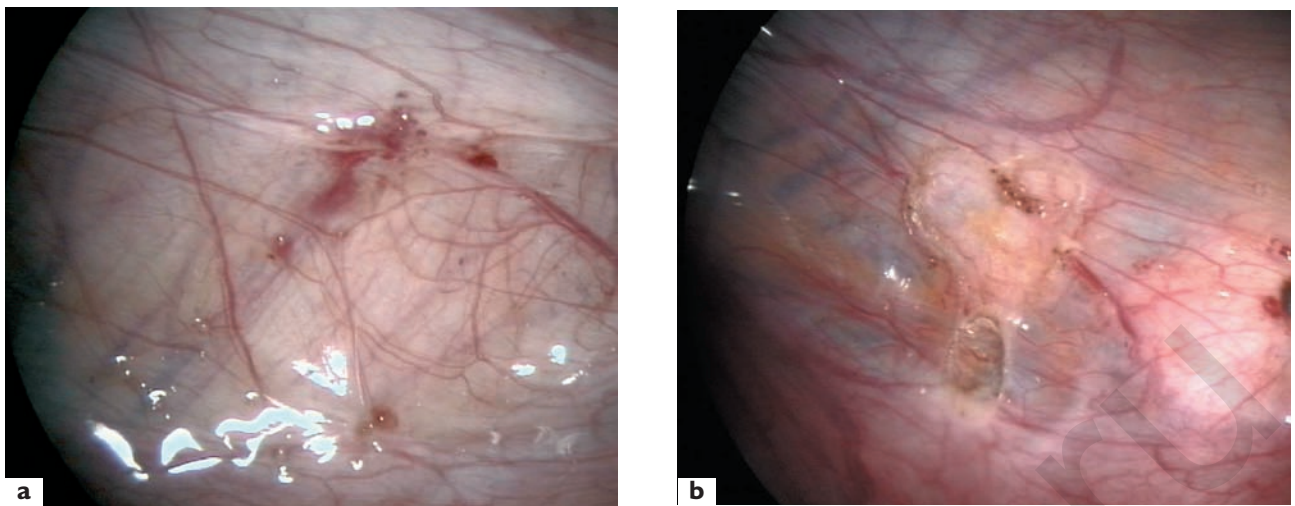


Figure 3.13 (a) Peritoneal endometriotic lesion, typical red lesion; (b) after vaporization with the SurgiTouch™ (CO₂ laser). Note the absence of carbonized areas (char-free ablation)

Those who criticize laser vaporization claim that excision is more thorough, and point to the risk of recurrence after vaporization. Our response is plain and simple: if bubbling appears during vaporization, it means that the retroperitoneal fat has been reached and we can safely say that vaporization is complete.

Coagulation

A third technique of destruction is coagulation with bipolar forceps, but this method has two major shortcomings. First, thermal damage appears to be greater than with the CO₂ laser, despite the use of bipolar forceps. Second, there is coagulation of tissue, but no proof of real destruction of peritoneal lesions.

Recurrence is therefore possible, because endometriotic cells are not destroyed.

REFERENCES

1. Nisolle M, Donnez J. Peritoneal endometriosis, ovarian endometriosis and adenomyotic nodules of the rectovaginal septum are three different entities. *Fertil Steril* 1997; 68: 585–96
2. Jansen RPS, Russell P. Non-pigmented endometriosis: clinical laparoscopic and pathologic definition. *Am J Obstet Gynecol* 1986; 155: 1154
3. Donnez J, Nisolle M, Casanas-Roux F. Peritoneal endometriosis: two-dimensional and three-dimensional evaluation of typical and subtle lesions. *Ann NY Acad Sci* 1994; 734: 324–51
4. Chatman DL. Pelvic peritoneal defects and endometriosis; Allen–Masters syndrome revisited. *Fertil Steril* 1981; 36: 751
5. Redwine DB. The distribution of endometriosis in the pelvis by age groups and fertility. *Fertil Steril* 1987; 47: 173–5
6. Stripling MC, Martin DC, Chatman DL et al. Subtle appearances of pelvic endometriosis. *Fertil Steril* 1988; 49: 427
7. Martin DC, Hubert GD, Van der Zwaag R, et al. Laparoscopic appearances of peritoneal endometriosis. *Fertil Steril* 1989; 51: 63
8. Nisolle M, Paindaveine B, Donnez J. Histologic study of peritoneal endometriosis in infertile women. *Fertil Steril* 1990; 53: 984–8
9. Nisolle L, Casanas-Roux F, Donnez J. Peritoneal endometriosis: evaluation of typical and subtle lesions. In Donnez J, Nisolle M, eds. *An Atlas of Operative Laparoscopy and Hysteroscopy*, 2nd edn. Carnforth, UK: Parthenon Publishing, 2001: 49–62
10. Jansen RPS, Russell P. Non-pigmented endometriosis: clinical laparoscopic and pathologic definition. *Am J Obstet Gynecol* 1986; 155: 1154
11. Marchino GL, Gennarelli G, Enria R, et al. Diagnosis of endometriosis with use of macroscopic versus histologic findings. *Fertil Steril* 2005; 84: 12–15
12. Donnez J, Nisolle M. Appearances of peritoneal endometriosis. Presented at the 3rd International Laser Surgery Symposium, Brussels, 1988
13. Nehzat F, Allan CJ, Nehzat C, Martin DC. Nonvisualized endometriosis at laparoscopy. *Int J Fertil* 1991; 36: 340–3
14. Walter AJ, Hentz JG, Magtibay PM, et al. Endometriosis: correlation between histologic and visual findings at laparoscopy. *Am J Obstet Gynecol* 2001; 184: 1407–13
15. Redwine D. ‘Invisible’ microscopic endometriosis. *Gynecol Obstet Invest* 2003; 55: 63–7
16. D’Hooghe TM. Invisible microscopic endometriosis: how wrong is the Sampson hypothesis of retrograde menstruation to explain the pathogenesis of endometriosis? *Gynecol Obstet Invest* 2003; 55: 61–2
17. Evers J, Dunselman G, Groothuis P. Now you see them, now you don’t. *Fertil Steril* 2005; 84: 31–2

18. Donnez J, Nisolle M, Casanas-Roux F. Three-dimensional architectures of peritoneal endometriosis. *Fertil Steril* 1992; 57: 980
19. Nisolle M, Casanas-Roux F, Anal V, et al. Morphometric study of the stromal vascularization in peritoneal endometriosis. *Fertil Steril* 1993; 59: 681
20. Nisolle M. Peritoneal, ovarian and rectovaginal endometriosis are three distinct entities. Thèse d'Agrégation de l'Enseignement Supérieur. Louvain, Belgium: Université Catholique de Louvain, 1996
21. Nisolle M, Donnez J, eds. *Peritoneal, Ovarian and Rectovaginal Endometriosis: The Identification of Three Separate Diseases*. Carnforth, UK: Parthenon Publishing, 1996
22. Donnez J, Van Langendonck A. Typical and subtle atypical presentations of endometriosis. *Curr Opin Obstet Gynecol* 2004; 16: 431-7
23. Arumugam K, Yip YC. De novo formation of adhesions in endometriosis. The role of iron and free radical reactions. *Fertil Steril* 1995; 64: 62-4
24. Murphy AA, Santanam N, Parthasarathy S. Endometriosis: a disease of oxidative stress? *Semin Reprod Endocrinol* 1998; 16: 263-73
25. Halme J, Hammond MG, Hulka JF, et al. Retrograde menstruation in healthy women and in patients with endometriosis. *Obstet Gynecol* 1984; 64: 151-4
26. Vinatier D, Cosson M, Dufour P. Is endometriosis an endometrial disease? *Eur J Obstet Gynecol Reprod Biol* 2000; 91: 113-25
27. Maines MD. The heme oxygenase system: a regulator of second messenger gases. *Annu Rev Pharmacol Toxicol* 1997; 37: 517-54
28. Van Langendonck A, Casanas-Roux F, Nisolle M, Donnez J. Potential implication of haemoglobin and its derivatives in pelvic adhesion formation. Presented at the 7th Biennial World Congress on Endometriosis, London, May 2000: abstr 18
29. Van Langendonck A, Casanas-Roux F, Dolmans MM, Donnez J. Potential involvement of hemoglobin and heme in the pathogenesis of peritoneal endometriosis. *Fertil Steril* 2002; 77: 561-70
30. Van Langendonck A, Casanas-Roux F, Donnez J. Oxidative stress and peritoneal endometriosis. *Fertil Steril* 2002; 77: 861-70
31. Bloom W, Fawcett DN. *A Textbook of Histology*. Philadelphia: WB Saunders, 1978: 186-7
32. Donnez J, Nisolle M. L'endométriose péritonéale, le kyste endométriotique ovarien et le nodule de la lame rectovaginale sont trois pathologies différentes [Éditorial]. *Réf Gynécol Obstét* 1995; 3: 121-3
33. Kokorine I, Nisolle M, Donnez J, et al. Expression of interstitial collagenase (matrix metalloproteinase-1) is related to the activity of human endometriotic lesions. *Fertil Steril* 1997; 68: 246-51
34. Brosens IA. Is mild endometriosis a disease? Is mild endometriosis a progressive disease? *Hum Reprod* 1994; 9: 2209-11
35. Marcoux S, Maheux R, Berube S. Laparoscopic surgery in infertile women with minimal or mild endometriosis. Canadian collaborative group on endometriosis. *N Engl J Med* 1997; 24: 217-22
36. Gruppo Italiano per lo Studio dell'Endometriosis. Ablation of lesions or no treatment in minimal-mild endometriosis in infertile women: a randomized trial. *Hum Reprod* 1999; 14: 32-4
37. Donnez J, Smoes P, Gillerot S, et al. Vascular endothelial growth factor (VEGF) in endometriosis. *Hum Reprod* 1998; 13: 1686-90
38. Waller KG, Shaw RW. Gonadotropin-releasing hormone analogues for the treatment of endometriosis: long-term follow-up. *Fertil Steril* 1993; 59: 511-15
39. Miller J, Shaw R, Casper R, et al. Historical prospective cohort study of the recurrence of pain after discontinuation of treatment with danazol or a gonadotrophin-releasing hormone agonist. *Fertil Steril* 1998; 70: 293-6
40. Donnez J, Nisolle M, Clerckx F, et al. Administration of nasal buserelin as compared with subcutaneous buserelin implant for endometriosis. *Fertil Steril* 1989; 52: 27-30
41. Nisolle M, Casanas-Roux F, Donnez J. Immunohistochemical analysis of proliferative activity and steroid receptor expression in peritoneal and ovarian endometriosis. *Fertil Steril* 1997; 68: 912-19

akusher-lib.ru

Laparoscopic management of ovarian endometriosis

P Jadoul, C Wyns, J Donnez

There are two different types of ovarian endometriosis that may be classified as:

- Superficial hemorrhagic lesions
- Hemorrhagic cysts (endometriomas)

Superficial lesions Superficial ovarian lesions are small vesicular lesions covering the ovarian cortex, or small implants usually found on the lateral surface of the ovary (Figures 4.1 and 4.2). Adhesions between the ovary and the broad ligament are often observed. From a histopathological point of view, the endometrial lesion may be lined



Figure 4.1 Superficial ovarian endometriosis

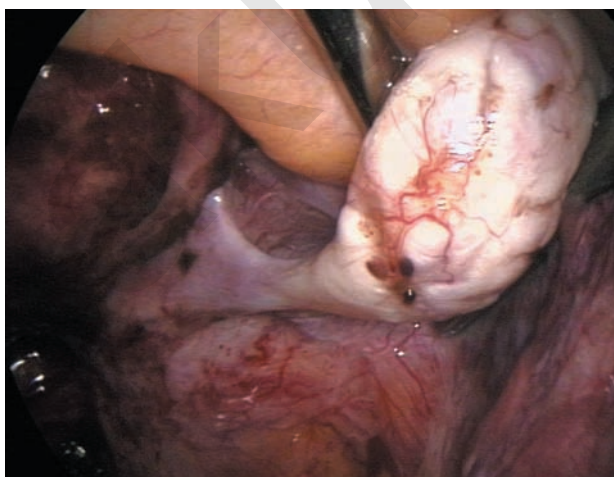


Figure 4.2 Laparoscopic view of superficial ovarian endometriosis

with free endometrial tissue (unpublished observations), which is similar histologically and functionally to eutopic endometrium¹. Active ectopic endometrial tissue can cover the inner surface of a small cavity in the ovary. In some instances, atypical epithelium and ciliated cells are found².

Endometriomas The pathogenesis of typical ovarian endometriosis is a source of controversy. The original paper by Sampson³ on this condition reported that perforation of the so-called chocolate cyst led to spillage of adhesions and the spread of peritoneal endometriosis. Hughesdon⁴ suggested that adhesions are not the consequence but the cause of endometriomas, and thus contradicted Sampson's hypothesis. The site of perforation, as described by Sampson, could represent the stigma of invagination of the cortex following the accumulation of menstrual debris from the bleeding of endometrial implants⁴. This hypothesis corroborates observations based on ovarioscopy and 'in situ' biopsies⁵⁻⁷. Other authors⁸ have claimed that large endometriomas may develop as a result of the secondary involvement of functional ovarian cysts in the process of endometriosis.

We proposed a different hypothesis for the development of ovarian endometriosis based on celomic metaplasia of invaginated epithelial inclusions^{9,10}. This hypothesis, based on the metaplastic potential of the pelvic mesothelium, is a widely accepted theory on the pathogenesis of common epithelial ovarian tumors¹¹.

Our arguments were as follows:

- (1) In our series, we found 12% of endometriomas not fixed to the broad ligament.
- (2) It was not unusual to find multilocular endometriomas that could not be explained by adhesions.
- (3) The epithelium covering the ovary, which is the mesothelium, can invaginate into the ovarian cortex. Invaginations of the mesothelial layer covering the ovarian tissue were described by Motta *et al.*¹². In our serial sections of the ovary, we frequently observed mesothelial inclusions.
- (4) The fact that primordial follicles were found surrounding endometriotic cysts also corroborated our hypothesis.
- (5) Our main argument is based upon the presence of epithelial invaginations in continuum with endometrial tissue, proving the metaplasia theory^{10,13,14}.
- (6) Endometriomas have been described in patients with Rokitansky-Küster-Hauser syndrome who do not

have a uterus and, therefore, do not have retrograde menstruation¹⁵.

- (7) Common epithelial tumors of the ovary are considered to be derived from the surface epithelium covering the ovary and from the underlying stroma¹¹: why not endometriomas?

Our classification published in 1993¹⁶, thus, needs to be revised. There can only be two types of ovarian endometriosis:

- (1) Superficial implants, which must be considered as peritoneal implants, resulting from the implantation of regurgitated endometrial cells;
- (2) Intraovarian endometriosis or endometriomas, which are the consequence of metaplasia of invaginated mesothelial inclusions.

INDICATIONS FOR SURGERY

Ovarian endometriomas are encountered, not infrequently, in infertile patients. The recommended treatment is still a subject of debate. Does the removal of endometriomas increase spontaneous fertility? If there is an indication for *in vitro* fertilization (IVF) other than the endometriosis, do we need to remove the endometrioma before IVF? Does the removal of an endometrioma influence IVF results?

Removal of endometriomas and fertility

In the late 1980s, we initiated a combined treatment regimen with hormonal therapy followed by surgery¹⁷. Pregnancy rates of more than 52% were achieved with moderate endometriosis and more than 45% with severe endometriosis, the difference being due to the severity of periovarian adhesions more frequently observed in 'severe' cases.

In a study published in 1996¹⁰, including 814 women presenting with ovarian endometriomas, we observed a cumulative pregnancy rate of 51% after combined treatment with a gonadotropin-releasing hormone agonist (GnRH-a) and laparoscopic surgery. The majority of pregnancies occurred within 10 months of surgery.

Several studies have confirmed pregnancy rates of approximately 50% after the surgical removal of endometriomas^{18–20}.

Endometriomas and IVF

It is unclear at the present time whether endometriomas have an impact on IVF outcome.

Several authors have claimed that the presence of endometriomas did not affect pregnancy rates during IVF^{21–23}.

A more recent report shows a significantly lower pregnancy rate per fresh embryo transfer among women with stage III/IV endometriosis²⁴. Moreover, in 2005, the

European Society of Human Reproduction and Embryology (ESHRE) guidelines for the treatment of endometriosis²⁵ indicated that IVF pregnancy rates are lower in women with endometriosis than in those with tubal infertility. The main risk of performing IVF in women with endometriomas is that of infection. Several cases of tubo-ovarian abscesses have been published^{26,27}. The treatment of ovarian abscesses can be very difficult, and the risk of recurrence of infection high.

These findings provide arguments in favor of the surgical treatment of endometriomas.

SURGICAL TREATMENT OF ENDOMETRIOMAS

Endometriomas must be treated by laparoscopy. Two techniques are currently proposed: either cystectomy consisting of the removal of the endometrioma wall, or ablative surgery that involves opening the endometrioma and destroying the endometrioma wall by laser vaporization or bipolar coagulation. A third approach combines these two techniques.

Laser surgery

Ovarian endometriosis < 3 cm

Ovarian endometriosis is treated during first-look laparoscopy if penetration of no more than 3 cm into the ovary is observed and if the cyst diameter is no larger than 3 cm. Small (<1 cm in diameter) endometriotic implants of the ovary are vaporized (Figure 4.3) until follicles containing fluid are encountered or no further pigmented tissue is seen (Figure 4.4). Large (<3 cm in diameter) endometriomas are destroyed as follows (Figure 4.5). A 3–4-mm portion of the top of the cyst is excised (Figure 4.6), the chocolate-colored material is aspirated and the cyst is completely opened (Figure 4.7) and washed out with irrigation fluid. After washing, the interior wall of the cyst is carefully examined to confirm the diagnosis of an endometrioma and the absence of any intracystic lesions suspected of being malignant (ovarian cystoscopy, Figure 4.8). At a power setting of 40 W and with continuous mode application, the interior wall of the cyst is then vaporized to destroy the mucosal lining of the cyst (Figures 4.9 and 4.10). Vaporization continues until no further pigment can be seen.

Vaporization with the SurgiTouch™ permits quick and easy vaporization of the internal wall with minimal thermal damage to the normal ovarian cortex. Indeed, experimental histological studies have shown char-free residual damage just 0.1 mm deep¹⁰. Moreover, because the time required for the SurgiTouch to cover a 2.5-mm round area homogeneously is about 100 ms, vaporization of large areas of peritoneal endometriosis, as well as the ovarian endometrial cyst wall, is very fast, significantly

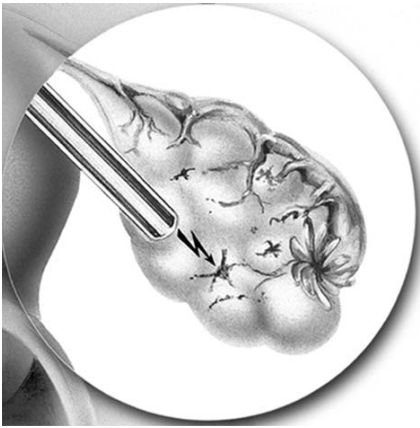

Figure 4.3 Vaporization of superficial ovarian endometriosis

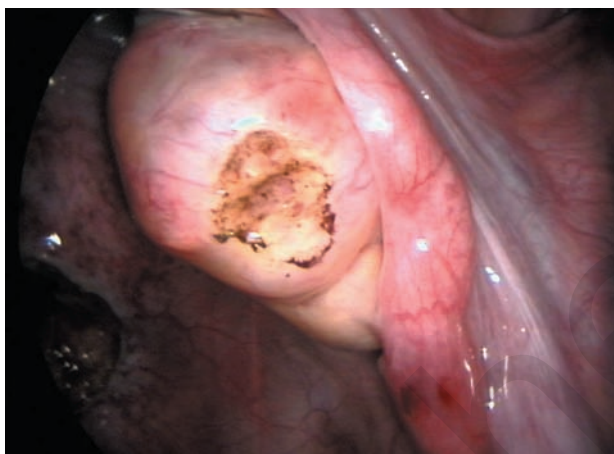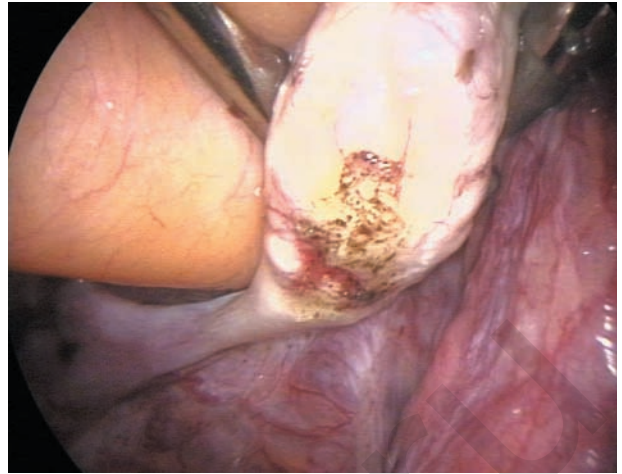


Figure 4.4 At the end of vaporization, no further pigmented tissue is seen

reducing the overall operating time compared with the conventional laser technique. After copious irrigation, the ovaries are left open.

Ovarian endometriosis > 3 cm (Figure 4.11)

During diagnostic laparoscopy, the endometrial cyst is emptied (Figure 4.12), completely opened and washed out with irrigation fluid (saline solution), and a biopsy is taken. Then, GnRH-a (Zoladex®; ICI, UK) therapy is given for 12 weeks to decrease the cyst size. A decrease of 50% in cyst diameter is observed after drainage followed by a 12-week course of GnRH-a (Figure 4.13). Drainage alone (if not associated with GnRH-a) is ineffective; indeed, 12 weeks after drainage, the ovarian cyst diameter is found to be unchanged compared with the diameter observed before drainage.

Thereafter, second-look laparoscopy is carried out. The endometrioma is opened and the interior wall of the cyst is vaporized as previously described. After a 3-month course of GnRH-a therapy, the thickness of the endometrial cyst is dramatically reduced and the epithelial lining is atrophic and white. Vaporization with the SurgiTouch allows very quick and easy vaporization of the internal wall, with minimal thermal damage to the normal ovarian cortex.

Ovarian endometriosis > 10 cm (Figure 4.14)

When the endometrioma is more than 10 cm in size, a first laparoscopy is performed to confirm the diagnosis of an endometrioma and to open it wide and rinse it. Gonadotropin-releasing hormone is then given for 12 weeks to decrease the cyst size. After 6–8 weeks of treatment, ultrasound is performed to assess the residual cyst size. If the endometrioma is still larger than 4 cm, an ultrasound-guided transvaginal puncture of the cyst is performed. Gonadotropin-releasing hormone therapy is pursued for one more month. Second-look laparoscopy is then performed to open and rinse the endometrioma and vaporize its internal wall.

Indeed, in order to be able to completely destroy the endometrioma wall, it is important for the initial or residual endometrioma to be no bigger than 3 cm.

Excisional surgery: ovarian cystectomy (Figure 4.15)

The procedure begins with adhesiolysis. Once the cyst is mobilized, the cortex is grasped with forceps introduced through a second trocar. The cortex is incised using laser or scissors. The incision must be made on the antimesenteric surface, as far as possible from the ovarian hilus. The incision is extended with scissors, and hydrodissection can

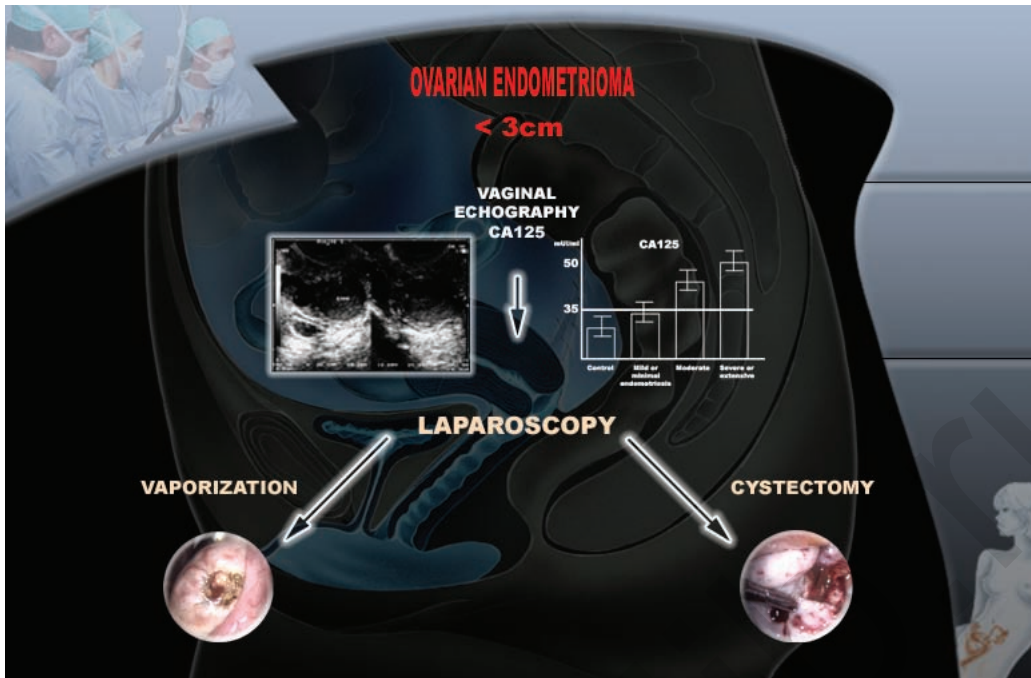


Figure 4.5 Decisional tree for the treatment of endometriomas < 3 cm

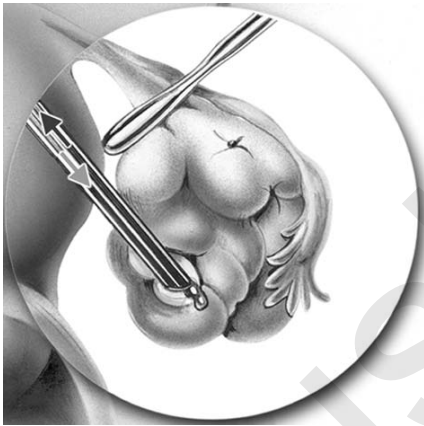


Figure 4.6 Opening and aspiration of the endometrioma

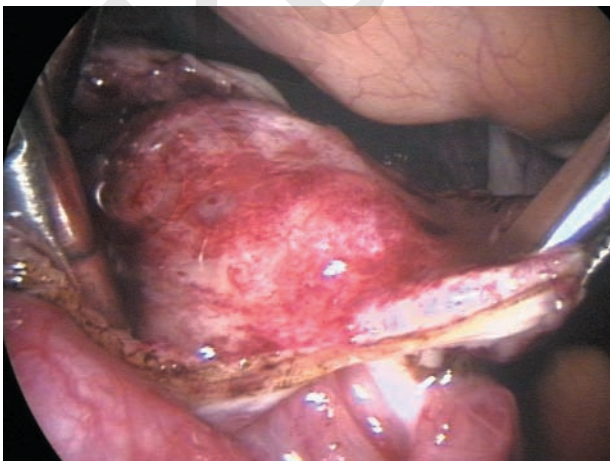
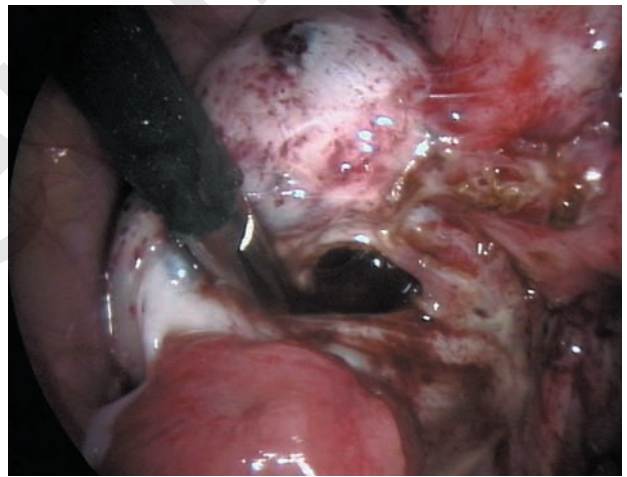


Figure 4.7 The endometrioma is completely opened

be used to separate the cyst wall from the ovarian stroma. If the cyst is opened and spillage occurs, peritoneal irrigation must be performed in order to remove the chocolate-colored fluid. The cyst is decompressed by suction drainage and washed. The cyst wall is then exposed and inspected to confirm the diagnosis of an endometrioma.

After identifying the correct plane of cleavage between the wall of the cyst and the ovarian tissue by applying opposite bimanual traction with two 5-mm grasping forceps, providing strong but non-traumatic traction, the inner lining of the cyst is stripped from the normal ovarian tissue. The bed of the cyst needs to be carefully inspected

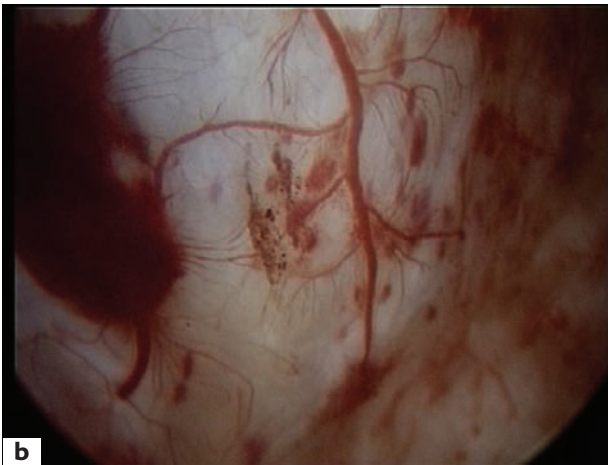
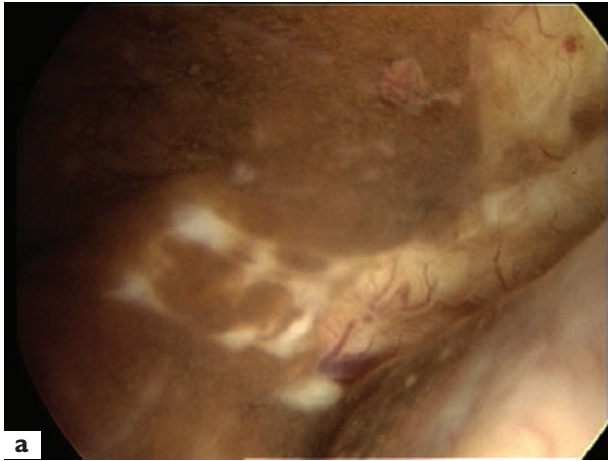


Figure 4.8 (a) Cystoscopy of an endometrioma. (b) After drainage and rinsing, in order to remove the ‘chocolate’ fluid, the internal wall of the cyst can be seen (areas of fibrosis, areas of hypervascularization with mucosal flaps)

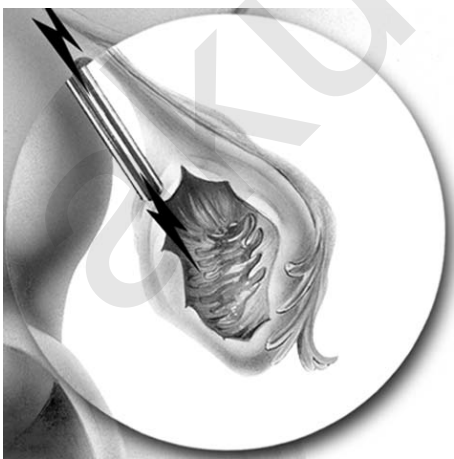

Figure 4.9 Ablation of the endometrioma involves complete vaporization or coagulation of the endometrioma wall

to detect possible bleeding zones that may require coagulation with bipolar forceps.

The endometrioma is removed through the 10-mm trocar. If the volume exceeds the dimensions of the trocar, an endobag can be used.

The ovary does not usually require suturing.

Combined technique: excisional and ablative surgery (Figures 4.16 and 4.17)

Ablative surgery may prove difficult because of the thickness and hypervascularization of the cyst wall. On the other hand, recent data in the literature appear to show that the excisional surgery of endometriomas could be deleterious for ovarian function. Some papers report that ovarian function is compromised by excisional surgery^{28–35}.

According to a report by Muzii *et al.*³⁵, recognizable ovarian tissue was inadvertently excised together with the endometriotic cyst wall in most cases during stripping for endometrioma excision. Close to the ovarian hilus, the ovarian tissue removed along the endometrioma wall consisted mostly of tissue which contained primordial, primary and secondary follicles in 69% of cases. Away from the hilus, no follicles or only primordial follicles were found in 60% of specimens.

In view of these data, we propose a mixed technique of excisional and ablative surgery. A large part of the endometrioma is first excised according to our cystectomy technique. The stripping technique allows the removal of 80–90% of the cyst. If the excision provokes excessive bleeding or if the plane of cleavage is not clear, the cystectomy is stopped because of the risk of removing normal ovarian tissue with primordial, primary and secondary follicles along with the endometrioma.

After this first step, the laser is used to vaporize the remaining 10–20% of the endometrioma close to the hilus. Care must be taken to vaporize all the residual cyst wall in order to avoid recurrence.

Which technique should we choose: laser vaporization or ovarian cystectomy?

There are two main risks associated with the surgical treatment of endometriomas:

- The risk of excessive surgery (removal of normal ovarian cortex together with the endometrioma capsule, due to the absence of a plane of cleavage)
- The risk of incomplete surgery (early recurrence of endometrioma)

In a Cochrane review published in 2005, Hart *et al.*³⁶ concluded the following:

‘There is some evidence that excisional surgery for endometriomata provides for a more favourable outcome than drainage and ablation with regard to the recurrence of the endometrioma, recurrence of

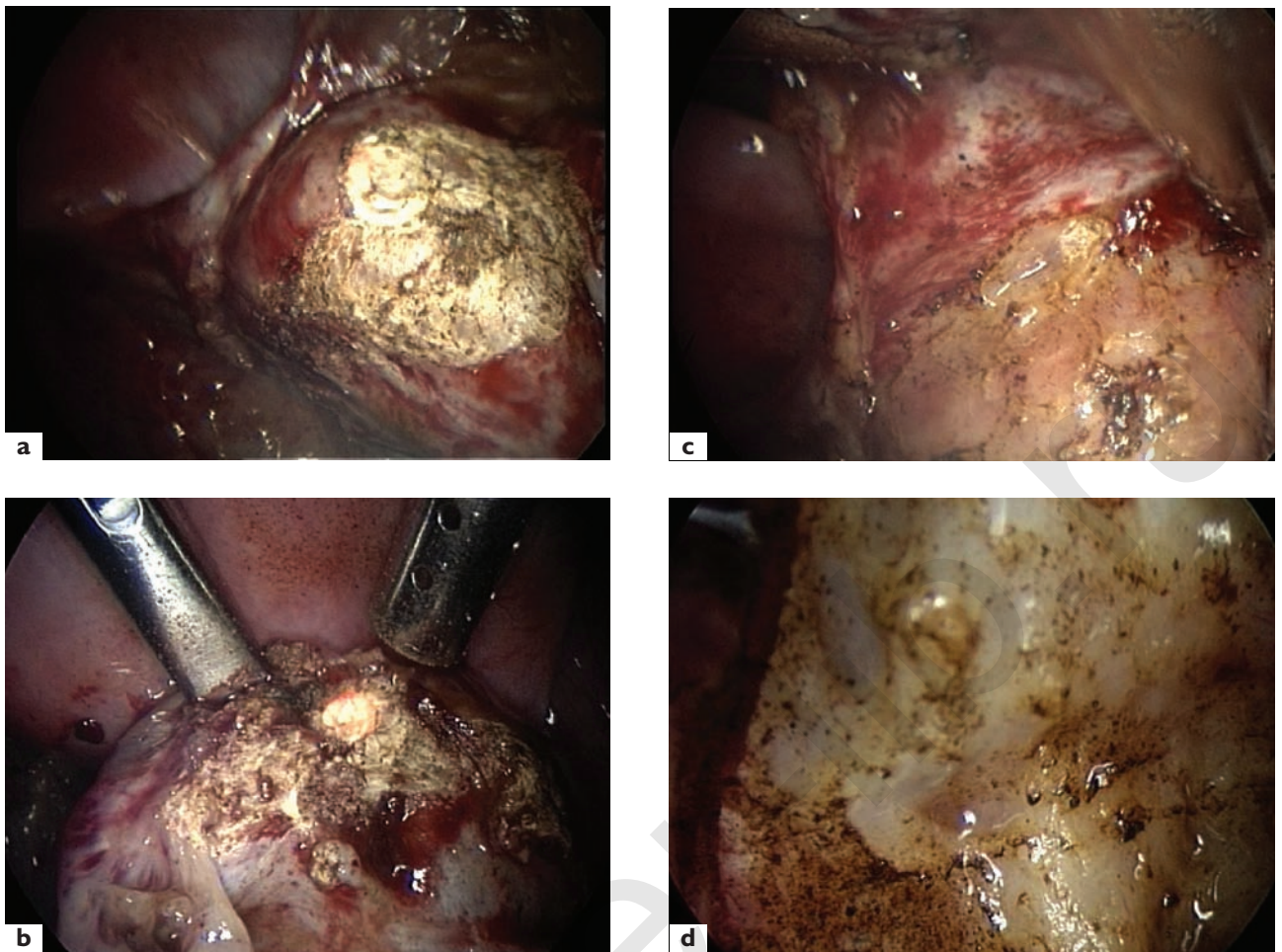


Figure 4.10 Vaporization of the endometrioma wall. (a) Use of the SurgiTouch™ allows quick vaporization of the endometrioma wall. (b) Care must be taken to vaporize the whole endometrioma wall and especially the endometrioma borders. (c) The vaporized areas are easily distinguishable from the remaining endometrioma wall. (d) The endometrioma wall has been completely destroyed

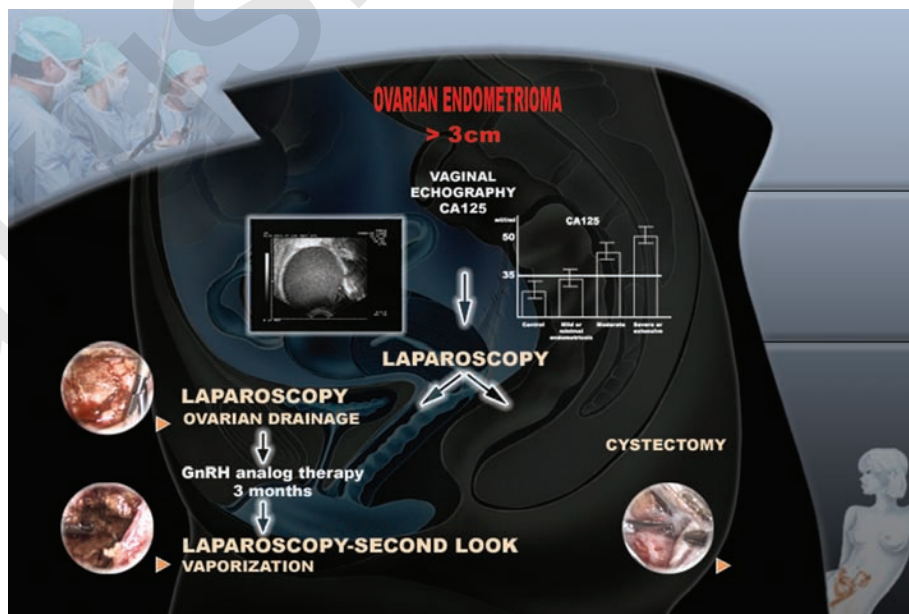


Figure 4.11 Treatment of endometriomas more than 3 cm in size. GnRH, gonadotropin-releasing hormone

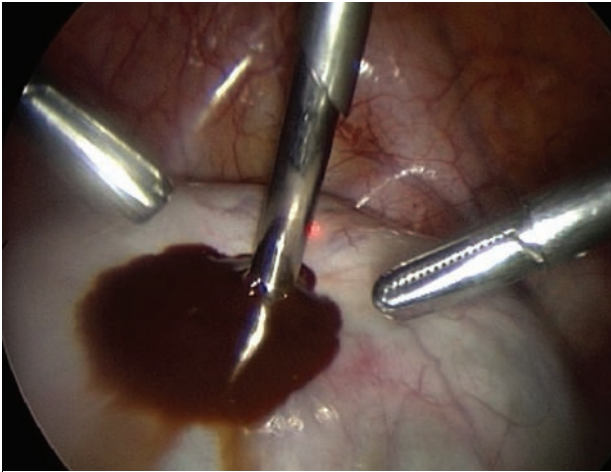


Figure 4.12 Opening and suction of the endometrioma

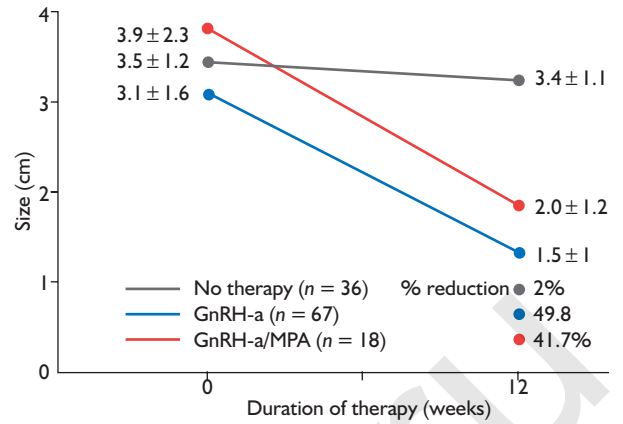


Figure 4.13 Evolution of endometrioma size after opening and drainage. GnRH-a, gonadotropin-releasing hormone agonist; MPA, medroxyprogesterone acetate

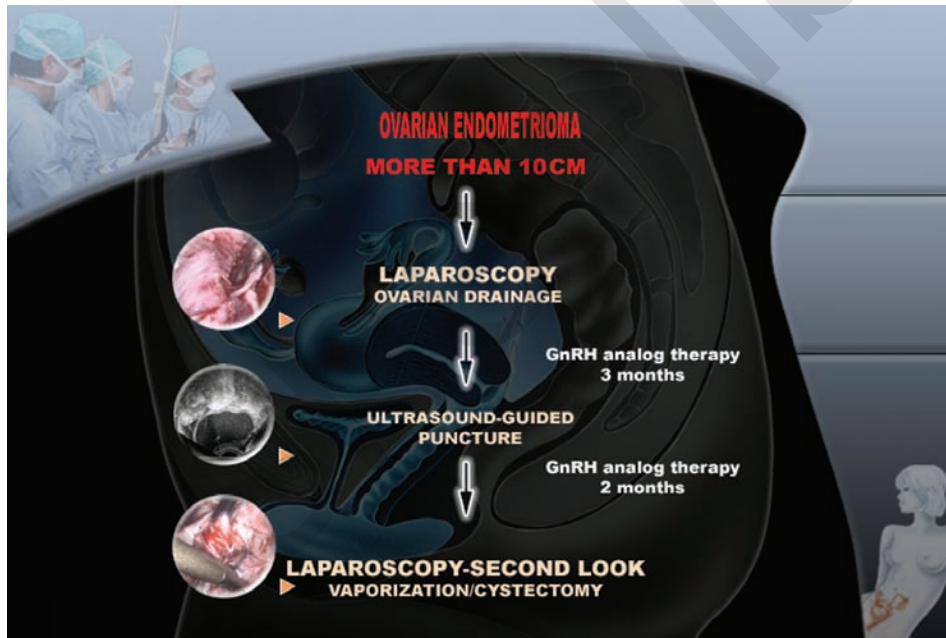


Figure 4.14 Treatment of endometriomas more than 10 cm in size. GnRH, gonadotropin-releasing hormone

symptoms and subsequent spontaneous pregnancy in women who were previously subfertile. Consequently, this approach should be the favoured surgical approach. However, we found no data as to the effect of either approach in women who subsequently undergo assisted reproduction techniques.'

This review was based on two randomized studies comparing the two approaches of cystectomy and ablation by bipolar coagulation^{37,38}. Laparoscopic excision of the cyst wall of the endometrioma was associated with a decreased

rate of recurrence of endometriomas (odds ratio (OR) 0.41, 95% confidence interval (CI) 0.18–0.93), reduced requirement for further surgery (OR 0.21, 95% CI 0.05–0.79) and lower recurrence rates of the symptoms of dysmenorrhea (OR 0.15, 95% CI 0.06–0.38), dyspareunia (OR 0.08, 95% CI 0.01–0.51) and non-menstrual pelvic pain (OR 0.10, 95% CI 0.02–0.56). It was also associated with a subsequently increased rate of spontaneous pregnancy in women who had documented prior subfertility (OR 5.21, 95% CI 2.04–13.29).

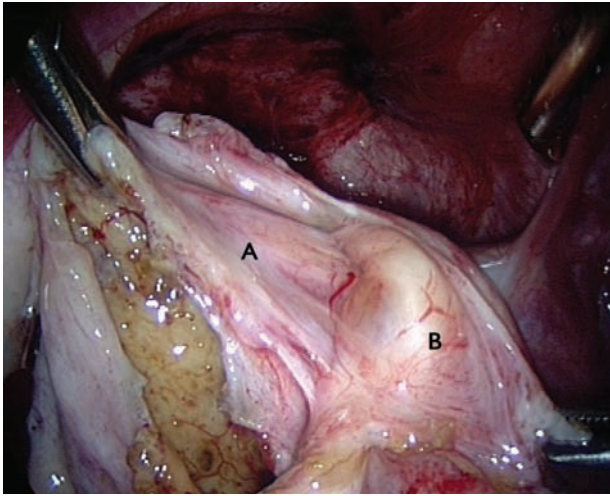


Figure 4.15 Ovarian cystectomy. A, endometrioma capsule. B, ovarian cortex

Although these were randomized controlled studies, we believe it is not possible to draw accurate conclusions from them. First of all, the number of cases was small (164 patients). Second, ablation was performed by bipolar coagulation, not by laser. Third, no preoperative drugs were used to decrease cyst size or reduce the thickness and hypervascularization of the cyst wall. Finally, neither study addressed ovarian function after surgery.

When we attempt to address the question of ovarian function after surgery, data in the literature are contradictory.

Indeed, Canis *et al.*³⁹, Marconi *et al.*⁴⁰, Donnez *et al.*⁴¹ and Wyns and Donnez⁴² found no effect on ovarian response in IVF after cystectomy or vaporization of endometriomas. Canis *et al.*³⁹ showed that the number of oocytes retrieved and the number of embryos obtained did not significantly decrease after ovarian cystectomy. Ovarian response was not affected after cystectomy in Marconi's study either⁴⁰.

In one of our studies⁴¹, endometrioma wall vaporization did not negatively affect IVF outcome. A later study actually suggested that both cystectomy and cyst wall vaporization allow preservation of a good ovarian response to stimulation by gonadotropins⁴².

Our studies led us to conclude that (1) vaporization of the internal cyst wall does not impair ovarian function in terms of IVF parameters and outcome; (2) theoretical risks of loss of viable ovarian tissue during cystectomy exist but may be avoided by a 'microsurgical' laparoscopic technique, taking care to preserve the normal residual ovarian cortex; and (3) after removal or destruction of endometriomas, IVF outcomes are similar in endometriosis patients compared with women with tubal factor or idiopathic infertility.

Other studies in the literature, however, point to the risk of ovarian damage due to ovarian cystectomy for

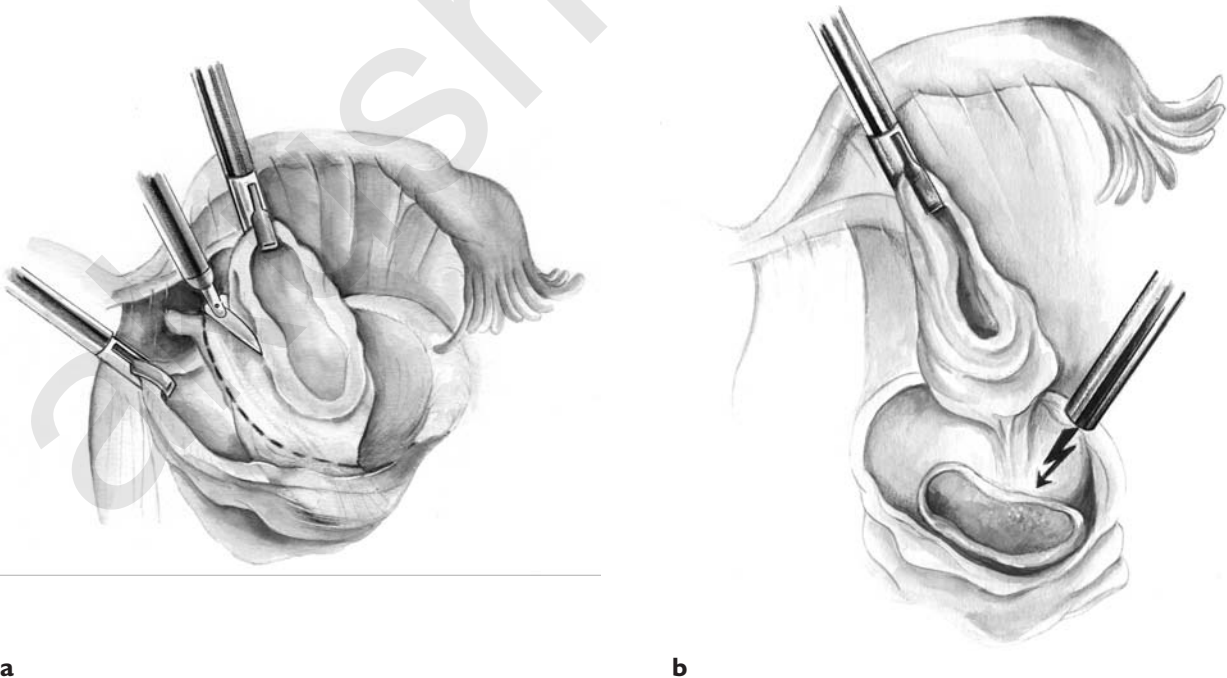


Figure 4.16 Combined technique. (a) A partial cystectomy is carried out. (b) To avoid excessive bleeding close to the hilus, vaporization of the residual cyst is carried out

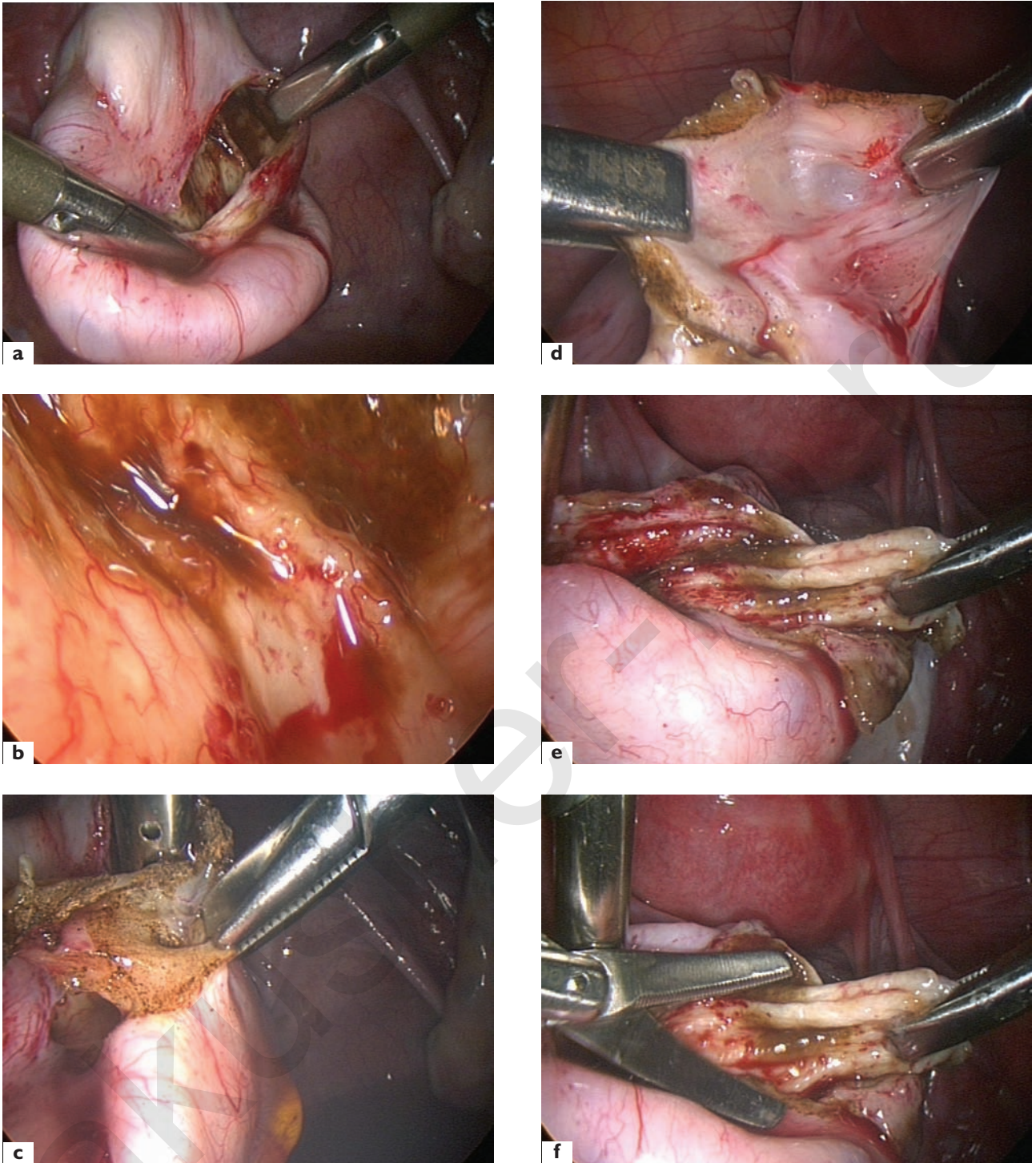


Figure 4.17 Combined technique: laparoscopic view. (a) The endometrioma is opened; (b) endometrioma wall; (c) detection of plane of cleavage between the endometrioma wall and ovarian cortex; (d) cystectomy of the endometrioma; (e)–(g) partial cystectomy: section of the endometrioma wall;

endometriomas. Several studies have shown reduced follicular response after cystectomy. Nargund *et al.*²⁸ showed that in cycles with ovulation induction after cystectomy, the normal ovary yielded a significantly higher number of follicles and oocytes compared with the contralateral ovary which had undergone cystectomy.

Loh *et al.*²⁹ demonstrated that post-cystectomy ovaries showed reduced follicular response in natural and clomiphene citrate-stimulated cycles in women <35 years of age. Ho *et al.*³⁰ concluded that surgery for ovarian endometriomas induces poor ovarian response to controlled ovarian hyperstimulation, compared with the

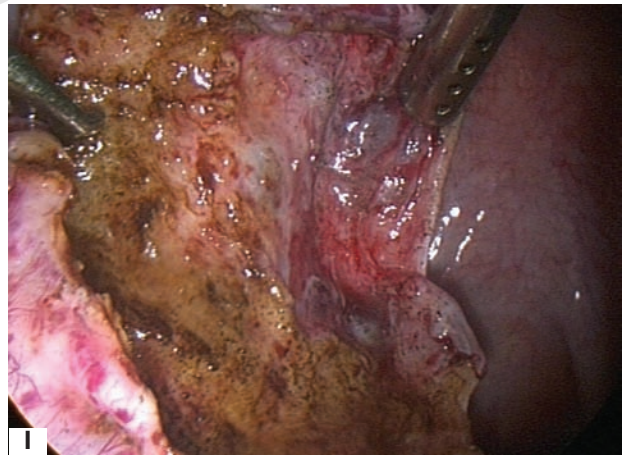
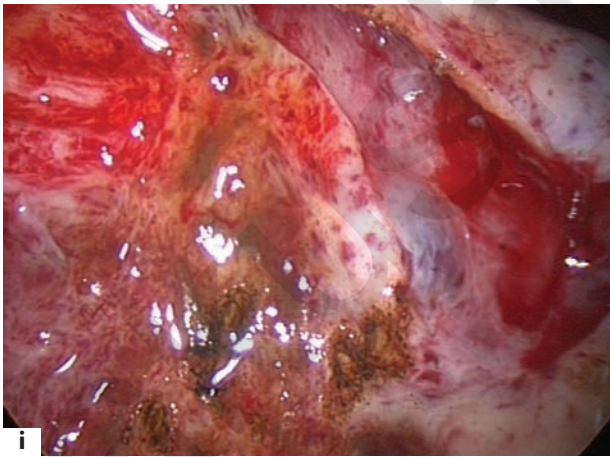
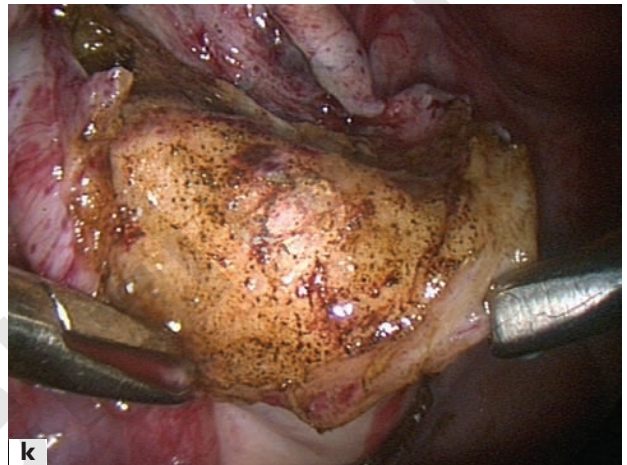
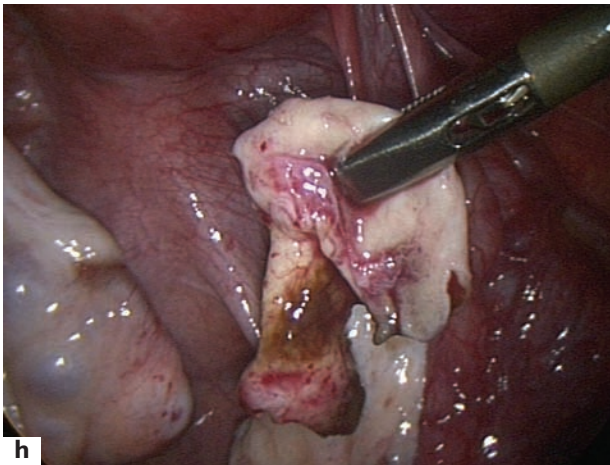
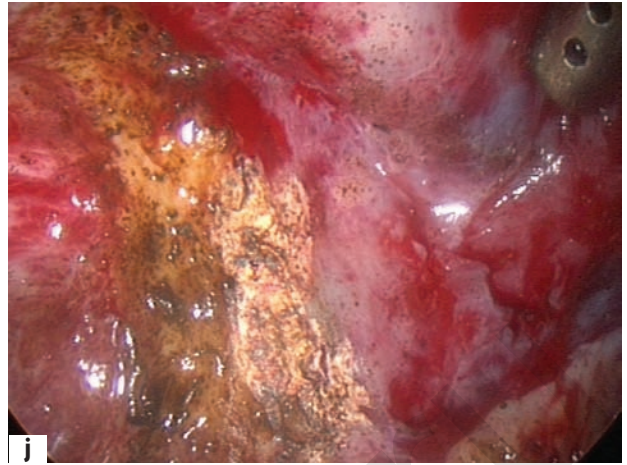
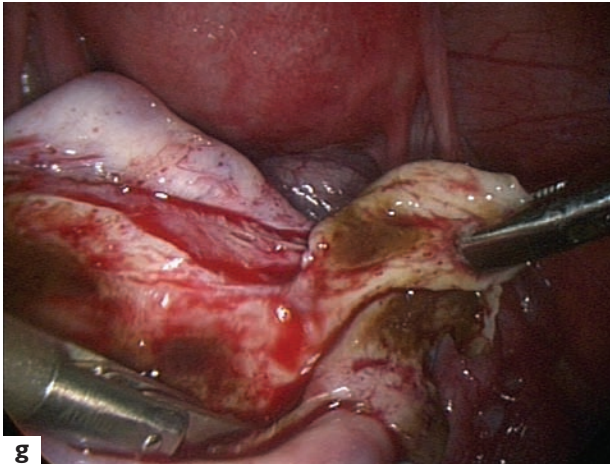


Figure 4.17 continued (h) resected part of the endometrioma; (i) remaining endometrioma wall on the left side, ovarian cortex after cystectomy on the right side; (j) and (k) vaporization of the remaining endometrioma wall; (l) final view: vaporized endometrioma wall on the left, ovarian cortex after cystectomy on the right

response of the contralateral normal ovary in the same individual. In Geber's group, patients <35 years of age with previous ovarian surgery had fewer retrieved oocytes than patients in the control group³¹. Others showed reduced ovarian volume after cystectomy. Exacoustos *et*

*al.*³⁴ showed that ovarian stripping of endometriomas, but not of ovarian dermoids, is associated with a significant decrease in residual ovarian volume, which may result in diminished ovarian reserve and function. Histological studies demonstrated the presence of follicles in the

excised tissue. One or several primordial follicles were found in 68.9% of endometrioma capsules removed by cystectomy in a study by Hachisuga and Kawarabayashi³². Compared with cystectomy for dermoid cysts, cystectomy for endometriomas was associated much more frequently with the ablation of follicles³². Close to the ovarian hilus, the ovarian tissue removed along the endometrioma wall consisted mostly of tissue which contained primordial, primary and secondary follicles in 69% of cases³⁵.

In the light of all this evidence, we can conclude that excisional surgery and ablative surgery are valuable techniques, but that they should be performed by experienced surgeons.

In the hands of inexperienced surgeons, cystectomy can be destructive for the ovary, whereas ablation may be incomplete, with a greater risk of recurrence. The combined technique appears to take the best of both techniques, while avoiding the risks, but requires further evaluation.

REFERENCES

1. Brosens I, Gordon A. Endometriosis: ovarian endometriosis. In Brosens I, Gordon A, eds. *Tubal Infertility*. London: Gower Medical Publishing, 1989: 313–17
2. Nisolle M, Casanas-Roux F, Donnez J. Histologic study of ovarian endometriosis after hormonal therapy. *Fertil Steril* 1988; 49: 423–6
3. Sampson JA. Heterotopic or misplaced endometrial tissue. *Am J Obstet Gynecol* 1925; 10: 649–64
4. Hughesdon PE. The structure of endometrial cysts of the ovary. *J Obstet Gynecol Br Emp* 1957; 44: 69–84
5. Brosens IA. Is mild endometriosis a disease? Is mild endometriosis a progressive disease? *Hum Reprod* 1994; 9: 2209–11
6. Brosens IA. Classification of endometriosis. Endoscopic exploration and classification of the chocolate cysts. *Hum Reprod* 1994; 9: 2213–14
7. Brosens IA. Ovarian endometriosis. In Shaw RW, ed. *Endometriosis – Current Understanding and Management*. London: Blackwell Science, 1995: 97–111
8. Nezhat F, Nezhat C, Allan CJ, et al. A clinical and histological classification of endometriomas: implications for a mechanism of pathogenesis. *J Reprod Med* 1992; 37: 771–6
9. Donnez J, Nisolle M. L'endométriose péritonéale, le kyste endométriotique ovarien et le nodule de la lame rectovaginale sont trois pathologies différentes [Editorial]. *Réf Gynécol Obstét* 1995; 3: 121–3
10. Donnez J, Nisolle M, Gillet N, et al. Large ovarian endometriomas. *Hum Reprod* 1996; 11: 641–6
11. Serov SF, Scully RE, Sobin LH. *Histological Typing of Ovarian Tumors*. International Histological Classification of Tumors, No 9. Geneva: World Health Organization, 1973: 17–21
12. Motta PM, Van Blerkom J, Mekabe S. Changes in the surface morphology of ovarian germinal epithelium during the reproductive life and in some pathological conditions. *Submicrosc Cytol* 1992; 99: 664–7
13. Nisolle M. Peritoneal, ovarian and rectovaginal endometriosis are three distinct entities. Thèse d'Agrégation de l'Enseignement Supérieur. Louvain, Belgium: Université Catholique de Louvain, 1996
14. Nisolle M, Donnez J. *Peritoneal, Ovarian and Rectovaginal Endometriosis: the Identification of Three Separate Diseases*. Carnforth, UK: Parthenon Publishing, 1996
15. Rosenfeld DL, Lecher BD. Endometriosis in a patient with Rokitansky–Kuster–Hauser syndrome. *Am J Obstet Gynecol* 1981; 139: 105–7
16. Donnez J, Nisolle M, Casanas-Roux F, et al. Endometriosis: rationale for surgery. In Brosens I, Donnez J, eds. *Current Status of Endometriosis. Research and Management*. Carnforth, UK: Parthenon Publishing, 1993: 385–95
17. Donnez J, Lemaire-Rubbers M, Karaman Y, et al. Combined (hormonal and microsurgical) therapy in infertile women with endometriosis. *Fertil Steril* 1987; 48: 239–42
18. Sutton CJ, Ewen SP, Jacobs SA, et al. Laser laparoscopic surgery in the treatment of ovarian endometriomas. *J Am Gynecol Laparosc* 1997; 4: 319–23
19. Jones KD, Sutton CJ. Pregnancy rates following ablative laparoscopic surgery for endometriomas. *Hum Reprod* 2002; 17: 782–5
20. Milingos S, Kallipolitis G, Loutradis D, et al. Affecting postoperative pregnancy rate after endoscopic management of large endometriomata. *Int J Gynaecol Obstet* 1998; 63: 129–37
21. Pouly JL. Endometriomas and in vitro fertilization outcomes. *J Gynecol Obstet Biol Reprod (Paris)* 2003; 32: S37–41
22. Calhaz-Jorge C, Chaveiro E, Nunes J, et al. Implications of the diagnosis of endometriosis on the success of infertility treatment. *Clin Exp Obstet Gynecol* 2004; 31: 25–30
23. Garcia-Velasco JA, Mahutte NG, Corona J, et al. Removal of endometriomas before in vitro fertilization does not improve fertility outcomes: a matched, case-control study. *Fertil Steril* 2004; 81: 1194–7
24. Kuivasaari P, Hippelainen M, Anttila M, et al. Effect of endometriosis on IVF/ICSI outcome: stage III/IV endometriosis worsens cumulative pregnancy and live-born rates. *Hum Reprod* 2005; 20: 3130–5
25. Kennedy S, Bergqvist A, Chapron C, et al. ESHRE guideline for the diagnosis and treatment of endometriosis. *Hum Reprod* 2005; 20: 2698–704
26. Younis JS, Ezra Y, Laufer N, et al. Late manifestation of pelvic abscess following oocyte retrieval, for in vitro fertilization, in patients with severe endometriosis and ovarian endometriomata. *J Assist Reprod Genet* 1997; 14: 343–6
27. Wei CF, Chen SC. Pelvic abscess after ultrasound-guided aspiration of endometrioma: a case report. *Zhonghua Yi Xue Za Zhi* 1998; 61: 603–7
28. Nargund G, Cheng WC, Parsons J. The impact of ovarian cystectomy on ovarian response to

- stimulation during in-vitro fertilization cycles. *Hum Reprod* 1996; 11: 81–3
29. Loh FH, Tan AT, Kumar J, Ng SC. Ovarian response after laparoscopic ovarian cystectomy for endometriotic cysts in 132 monitored cycles. *Fertil Steril* 1999; 72: 316–21
 30. Ho HY, Lee RK, Hwu YM, et al. Poor response of ovaries with endometriomata previously treated with cystectomy to controlled ovarian hyperstimulation. *J Assist Reprod Genet* 2002; 19: 507–11
 31. Geber S, Ferreira DP, Spyer Prates LF, et al. Effects of previous ovarian surgery for endometriosis on the outcome of assisted reproduction treatment. *Reprod Biomed Online* 2002; 5: 162–6
 32. Hachisuga T, Kawarabayashi T. Histopathological analysis of laparoscopically treated ovarian endometriotic cysts with special reference to loss of follicles. *Hum Reprod* 2002; 17: 432–5
 33. Somigliana E, Ragni G, Benedetti F, et al. Does laparoscopic excision of endometriotic ovarian cysts significantly affect ovarian reserve? Insights from IVF cycles. *Hum Reprod* 2003; 18: 2450–3
 34. Exacoustos C, Zupi E, Amadio A, et al. Laparoscopic removal of endometriomas: sonographic evaluation of residual functioning ovarian tissue. *Am J Obstet Gynecol* 2004; 191: 68–72
 35. Muzii L, Bellati F, Bianchi A, et al. Laparoscopic stripping of endometriomas: a randomised trial on different surgical techniques. Part II: pathological results. *Hum Reprod* 2005; 20: 1987–92
 36. Hart R, Hickey M, Maouris P, et al. Excisional surgery versus ablative surgery for ovarian endometriomata. *Cochrane Database Syst Rev* 2005; (3): CD004992
 37. Beretta P, Franchi M, Ghezzi F, et al. Randomized clinical trial of two laparoscopic treatments of endometriomas: cystectomy versus drainage and coagulation. *Fertil Steril* 1999; 71: 1176–80
 38. Alborzi S, Momtahan M, Parsanezhad ME, et al. A prospective, randomised study comparing laparoscopic ovarian cystectomy versus fenestration and coagulation in patients with endometriomas. *Fertil Steril* 2004; 82: 1633–7
 39. Canis M, Pouly JL, Tamburro S, et al. Ovarian response during IVF-embryo transfer cycles after laparoscopic ovarian cystectomy for endometriotic cysts > 3 cm in diameter. *Hum Reprod* 2001; 16: 2583–6
 40. Marconi G, Vilela M, Quintana R, et al. Laparoscopic ovarian cystectomy of endometriomas does not affect the ovarian response to gonadotropin stimulation. *Fertil Steril* 2002; 78: 876–8
 41. Donnez J, Wyns C, Nisolle M. Does ovarian surgery for endometriomas impair the ovarian response to gonadotropin? *Fertil Steril* 2001; 76: 662–5
 42. Wyns C, Donnez J. Laser vaporization of ovarian endometriomas: the impact on the response to gonadotrophin stimulation. *Gynecol Obstet Fertil* 2003; 31: 337–42

Douglasectomy, torus excision, uterine suspension

J Donnez, J Squifflet, P Jadoul

INTRODUCTION

The correlation between the severity of pain (dyspareunia and dysmenorrhea) and the extent of disease (stage of endometriosis) has not been proved¹⁻³. It is important to distinguish between psychological pelvic pain and pain due to organic pathology in order to orientate treatment: psychiatric orientation or surgical orientation. In a report from a psychiatric center, only 48% of women with pelvic pain had organic pathology, while 64% reported childhood sexual abuse. Even if the studies did not show any relationship between the extent of the disease and the severity of pain, it is true that there is a relationship between fluid concentrations of CA125, the placental protein, and the peritoneal location of lesions⁴. The American Fertility Society, in their staging of endometriosis, has established an association between pelvic pain, dyspareunia and moderate or severe dysmenorrhea in patients suffering from infertility. Severe dysmenorrhea is highly predictive of endometriosis.

To understand the mechanism of pain in endometriosis, it was suggested by Sturgis and All⁵ that both proliferation of functional glands and fibrotic reactions play a significant role. It is a fact that endometriosis causes pain and tenderness in a significant number of women, but it is more problematic to claim that chronic pelvic pain is just due to endometriosis. Indeed, a psychosomatic approach shows that endometriosis is not commonly a main component of pain.

The treatment of pelvic pain has undergone various changes during the past 30 years, reflecting new developments in medicine and surgery. For many years, presacral neurectomy was performed on patients with untreatable dysmenorrhea but yielded disappointing results, with failure rates of about 11–15% for primary dysmenorrhea and 25–40% for secondary dysmenorrhea. In 1952, White⁶ pointed out that the nerve supply to the cervix is not usually interrupted by the presacral neurectomy procedure. For this reason, and with the development of new drugs to suppress ovulation, the procedure was abandoned by most gynecologists.

ALLEN-MASTERS SYNDROME

Allen–Masters syndrome⁷ was first described in 1955 in 28 patients, all of whom had uterine retroversion. This syndrome also included broad ligament lacerations, hypermobility of the cervix and enlargement and

engorgement of the uterus. Allen and Masters treated their patients with an operation that included repair of the broad ligament defects ('windows') and uterine suspension, which provided good relief from symptoms. However, many gynecologists doubt the existence of the syndrome. In our clinic, no patients have ever been operated upon for a preoperative diagnosis of Allen–Masters syndrome. The 'windows' are simply vaporized with the Swiftlase in 'defocused' mode, in order to shrink the 'pocket' where frequently small lesions of endometriosis are discovered⁸.

DYSMENORRHEA

Primary dysmenorrhea is not related to uterine position. It occurs in the anteverted, as well as the retroverted, uterus. Retroflexion of the uterus interferes with venous drainage from the myometrium and broad ligaments and is a factor in dysmenorrhea. Relative stenosis of the internal cervical os can increase dysmenorrhea. Menstrual discomfort may take the form of cramps or sacral backache.

DYSPAREUNIA

In some patients with deep dyspareunia, uterine retroversion or retroflexion may be the only finding in some indications, either if conservative measures have failed to relieve the pain, or if the dyspareunia disappears with the uterus in an anterior position, for example when a Smith–Hodge pessary has been placed to hold the uterus in antelexion. However, pelvic examination usually reveals significant pelvic pathology, such as endometriosis of the uterosacral ligaments. The uterus may also be retroverted or retroflexed. If an operation is performed to treat the endometriosis, the uterus should be suspended.

INFERTILITY

The finding of a retroposed uterus in a woman complaining of infertility is not an indication that the position of the uterus is directly related to the problem. Although infertility may be more common among women with retrodisplacement of the uterus, the relationship is difficult to prove, except in cases when other associated pathology, such as pelvic endometriosis or chronic salpingitis, exists.

PELVIC CONGESTION SYNDROME

Pelvic congestion syndrome has often been associated with uterine retroversion. In Taylor's original description of the syndrome in 1949, only 35% of patients were found to have uterine retroversion^{9,10}. Taylor believed that vascular congestion of the pelvic organs explained the fact that pelvic veins can easily become dilated because they lack valves, since the surrounding adventitial tissue in the broad ligaments is weak. Taylor did not recommend hysterectomy or uterine suspension for these patients. He recognized the frequency with which his patients also suffered from psychosomatic and psychiatric complaints. It is not known how many patients with vascular congestion of pelvic organs are asymptomatic. Some authors have recommended embolization of the pelvic veins as treatment for pelvic congestion syndrome. Others, such as Manhes (personal communication), have suggested photocoagulating the veins in order to shrink them.

INDICATIONS FOR UTERINE SUSPENSION

Since the 19th century, uterine suspension has been practiced to relieve pelvic pain, dyspareunia and infertility.

Numerous methods and variations have been described in the medical literature, wherein the round ligament is folded, plaited, ligated, transplanted, banded or shirred¹¹. Uterine suspension has been suggested to be very effective in the relief of deep dyspareunia or pelvic pain due to uterine retroversion. Primary suspension of the retroverted uterus is not necessary for adequate gynecological practice. Uterine suspension is most often indicated in connection with conservative operations such as those carried out for endometriosis or tubal pregnancy, or with microsurgical tubal reconstruction procedures for relief of infertility. The goal is to avoid leaving the uterus of an infertile patient in the cul-de-sac, where tubal adhesions may recur, while performing other conservative procedures. The presence of uterine retrodisplacement alone in an asymptomatic patient is not an indication for prophylactic uterine suspension. Symptomatic anatomic vaginal wall relaxation and uterine descensus are rarely associated with uterine retroversion. In such cases, we prefer to perform laparoscopic uterine sacrofixation (see Chapter 25).

Mild pelvic pain with dyspareunia is described as mild abdominal discomfort and fullness on intercourse, while moderate pelvic pain with dyspareunia is described as mild tolerable pain, whereupon the patient still enjoys the sexual act.

Pelvic examinations are systematically performed to evaluate the uterine position, degree of misalignment of the uterus and the severity of adhesions. We also try to reproduce the described pelvic pain and dyspareunia by palpation of the retroverted uterus. Ultrasound is performed to confirm the initial findings and to rule

out myomas, adenomyosis or any uterine or ovarian abnormalities.

CHOICE OF OPERATION

To a great extent, choice of operative technique depends on the patient's desire for future pregnancy. The modified Gillian suspension is a good technique for suspending the uterus while preserving the potential for pregnancy.

The modified Gillian suspension procedure¹² draws each round ligament through an aperture in the peritoneum near the internal inguinal ring, and brings each ligament beneath the anterior rectus sheath. Although some patients experience transient round ligament pain with vigorous physical activity or uterine enlargement, there is no evidence that the suspension is detrimental to subsequent pregnancy.

In the Olshausen operation¹³, on the other hand, the uterus is fixed to the anterior abdominal wall. This procedure precludes the possibility of a future intrauterine pregnancy because the anchored uterus will produce severe abdominal pain as the uterus enlarges with advancing pregnancy. This operation should never be performed.

In the Webster-Baldy procedure¹⁴, the round ligaments are passed through the anterior and posterior leaves of the broad ligament and sutured to the posterior surface of the uterus. The extraperitoneal technique of shortening each round ligament in the inguinal canal described by Alexander¹⁵ and Adams¹⁶ is no longer used in the United States, although it is still in use in some European countries. The operation is blind because the uterus is not visualized unless a laparotomy is performed. The extraperitoneal approach is its only advantage.

Some authors suggest another procedure to provide additional support, whereby the uterosacral ligaments are shortened. This procedure is especially valuable when some descensus is present or when the cervix has been displaced anteriorly. We have never performed this procedure.

Operative technique (Figure 5.1)

After general anesthesia with endotracheal intubation has been established, the patient is placed in the lithotomy position or the Trendelenburg position. The bladder is emptied with a Foley catheter. A laparoscopic trocar is introduced into the peritoneal cavity. The pelvis is then visualized. The right and then left lower quadrants are transilluminated, and an avascular region is selected about 5–6 cm from the midline incision and 2 cm above the inguinal ligament.

Laparoscopic grasping forceps may be inserted through the trocar, or a Kelly clamp may be pushed through the incisions into the peritoneal cavity. The round ligaments are grasped (Figure 5.2) at about the midpoint and gently

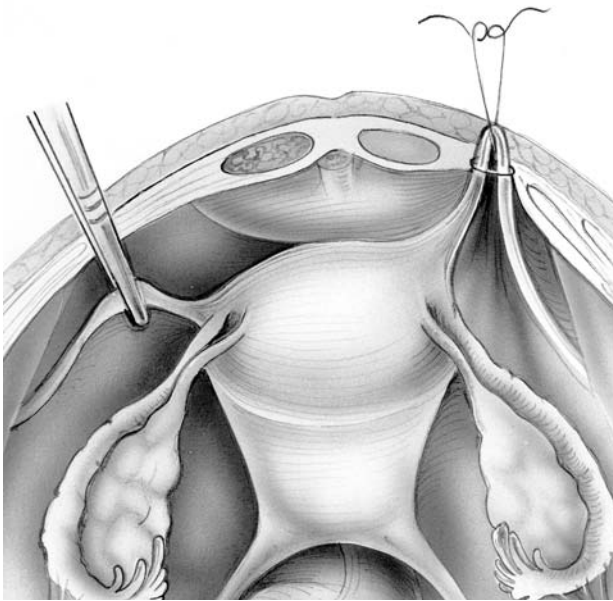


Figure 5.1 Technique of uterine suspension by grasping and fixation of the round ligament

pulled through the fascia as the pneumoperitoneum is allowed to deflate partially (Figure 5.3). The round ligaments are sutured to the aponeurosis with Vicryl® 1-0 suture material (Figure 5.4).

Complications of uterine suspension

Occasionally, evulsion of the round ligament may result when pulling the ligament up to the anterior rectus sheath. The ensuing bleeding must be controlled. If there is undue tension placed on the round ligaments, incisional pain may occur. It is usually mild and temporary and controlled with analgesics, muscle relaxants and heat.

Results (Table 5.1)

The operating time of both procedures is less than an hour.

Mild incisional pain and mild abdominal discomfort are frequently encountered and readily relieved with mild analgesics.

While in the study by Yoon¹⁷, 51.5% and 18.6–45.5% of patients felt better at 6 weeks and 6 months,

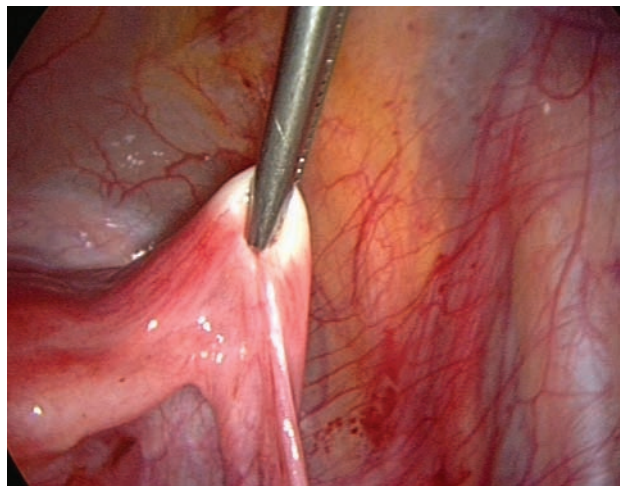
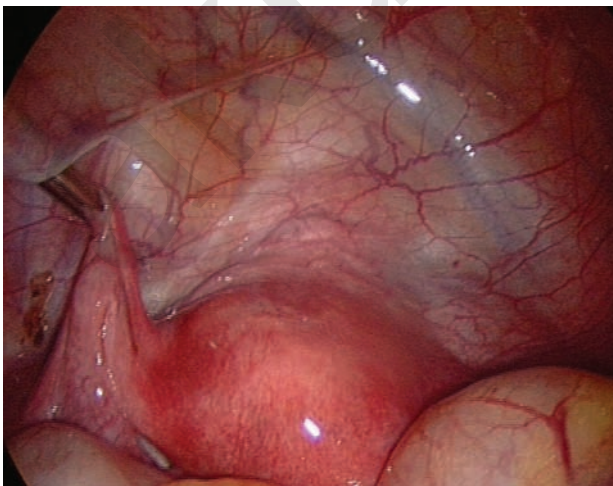
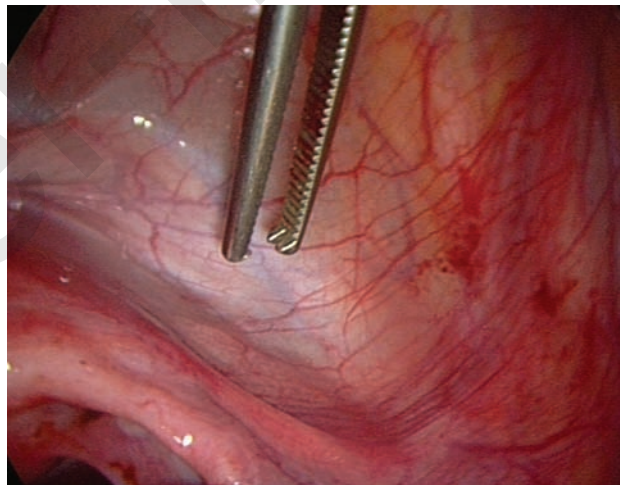
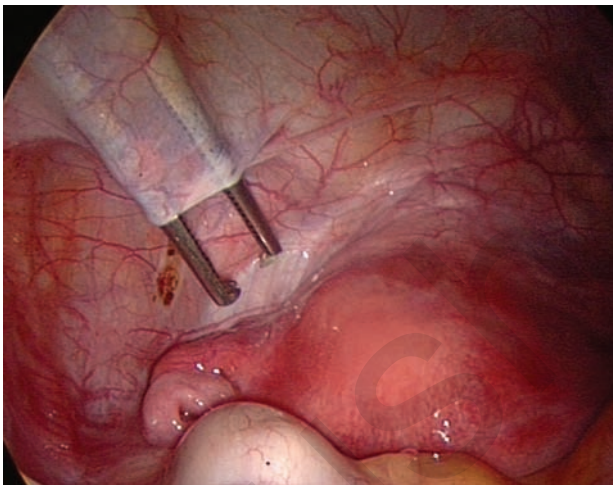


Figure 5.2 The round ligaments are grasped

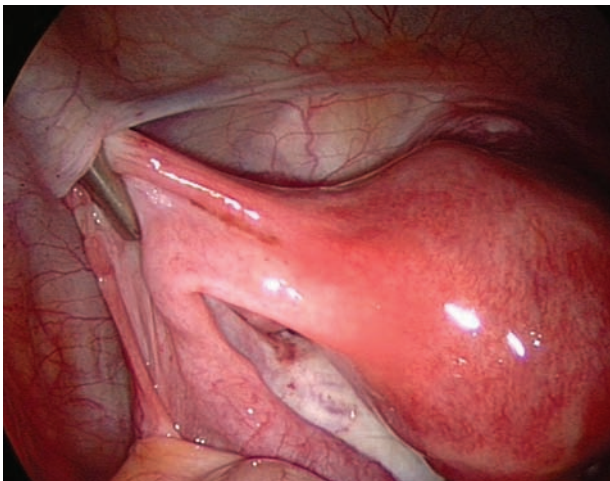

Figure 5.3 The round ligaments are pulled through the fascia

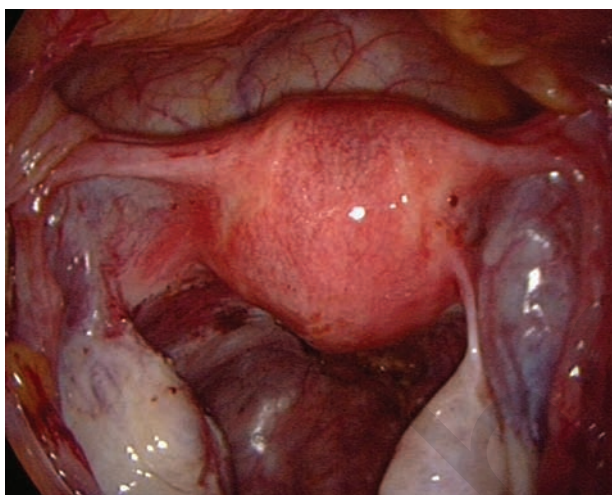
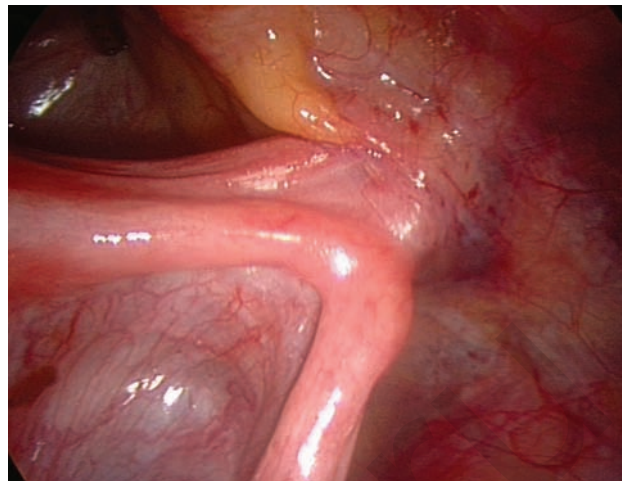


Figure 5.4 The round ligaments have been sutured to the aponeurosis

Table 5.1 Age and parity of 35 patients; indications for pelviscopic uterine suspension, combined with torus excision

Mean age (years)	29.5
Mean parity	1.8
Number of women with deep dyspareunia and chronic pelvic pain	31 (88%)
Improved	32 (91%)
Same	3 (9%)

respectively, following surgery, with no obvious cause for their deep dyspareunia or pelvic pain, all of our patients (100%) experienced a marked improvement at 6 weeks after the operation. Their sex-life improved immensely. After 6 months to 2 years of follow-up in the study by Koh

*et al.*¹⁸, 17 patients with the Webster–Baldy technique and five patients with Franke’s technique (88%) enjoyed an improved sex-life, while three patients were lost to follow-up.

Discussion

Among the many procedures published in the medical literature are Halben’s vesical suspension, the Schmid–Matthiesen suspension, Werth’s interfascial plication, uterine suspension using Fallopian rings, the modified Gillian method, the Mann–Stenger suspension and the Webster–Baldy and Franke techniques.

Laparoscopy is a valuable tool to determine the cause of pelvic pain, and, when dyspareunia and pelvic pain are caused by a retroverted uterus, we believe that uterine suspension using various procedures will certainly relieve the problem.

In one study¹⁸, the Webster–Baldy method was found to be more time-consuming with more bleeding, but causing less kinking to the Fallopian tubes; thus, this method is preferred in patients who still wish to bear children.

Although Franke’s method is simpler, less time-consuming and with less bleeding, since it causes more kinking to the Fallopian tubes, this procedure is more appropriate for patients who no longer wish to become pregnant.

ASSOCIATED SURGERY

Laser uterine nerve ablation (LUNA)

Uterine neurectomy was initially performed by electrocautery, but there was always concern about the spread of electric current in this area due to the close proximity of

the ureter and the uterine artery. Since 1989, we have, by preference, vaporized with CO₂ laser energy transmitted directly through the operating channel^{19,20}. The posterior leaves of the broad ligaments are carefully inspected to identify the course of the ureters, which usually run 1–2 cm laterally. They can usually be ‘palpated’ via a probe, and often the characteristic peristaltic movements can be recognized beneath the peritoneal surface.

The uterosacral ligaments are pulled under tension by manipulating the uterus with an intrauterine manipulator. The laser is set at a relatively high power density of 60 W, and the uterosacral ligaments are vaporized 1 cm from their point of attachment to the posterior aspect of the cervix over a length of 1.5 cm. The idea of the procedure is to destroy the sensory nerve fibers and their secondary ganglia as they leave the uterus. Because of the divergence of these fibers in the uterosacral ligaments, they should be vaporized as close to the cervix as possible. Care must be taken not to vaporize too laterally, to avoid damage to the vessels running alongside the uterosacral ligaments.

Prospective double-blind randomized controlled studies have demonstrated that laparoscopic transection of the uterosacral ligaments close to their point of insertion on the posterior side of the cervix is an effective treatment for dysmenorrhea that has been unresponsive to drug therapy²¹.

Torus excision

Another procedure is to lase deeply the posterior aspects of the cervix between the ligament insertions, to interrupt fibers crossing to the contralateral side. It is relatively easy to vaporize to the correct depth when the uterosacral ligaments are well formed. Sometimes, however, their limits are poorly defined.

Douglasectomy

As previously seen (see Chapter 1), parasympathetic fibers are identified in the anterior two-thirds of the uterosacral

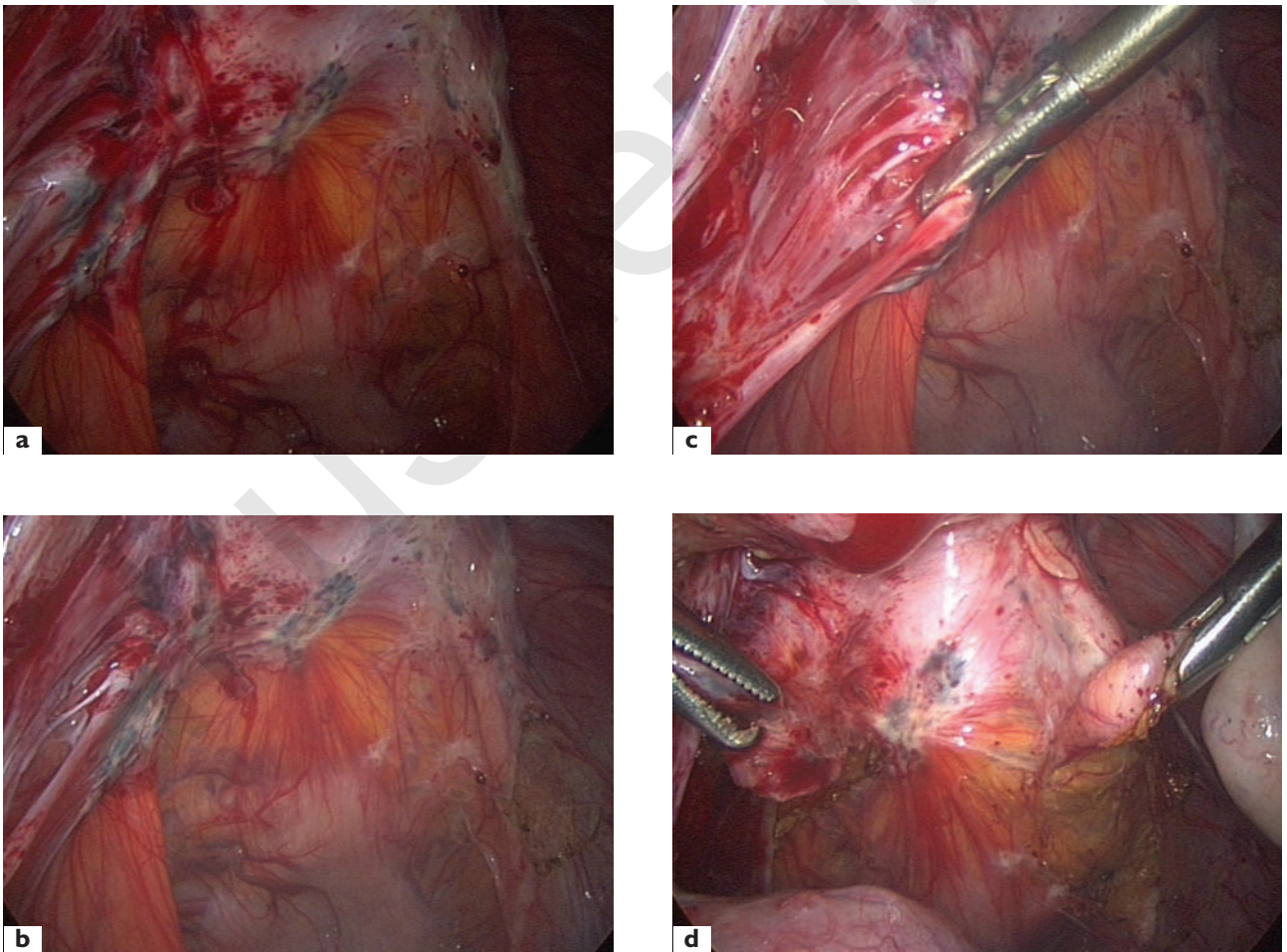


Figure 5.5 Douglasectomy. (a) Endometriosis of uterosacral ligaments and Douglas pouch; (b) vaporization of the right uterosacral ligament; (c) grasping (and vaporization) of the left uterosacral ligament; (d) both uterosacral ligaments have been cut;

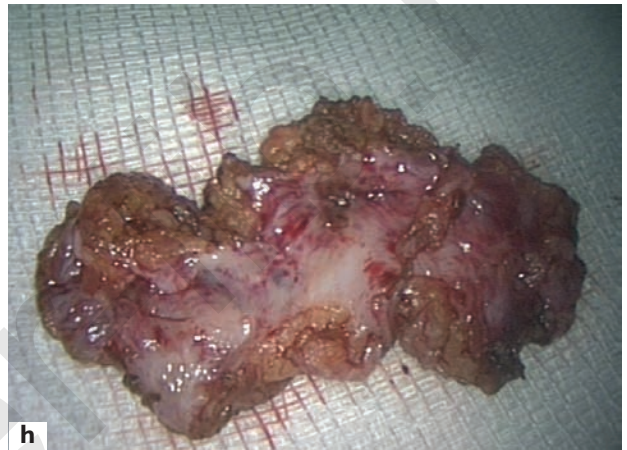
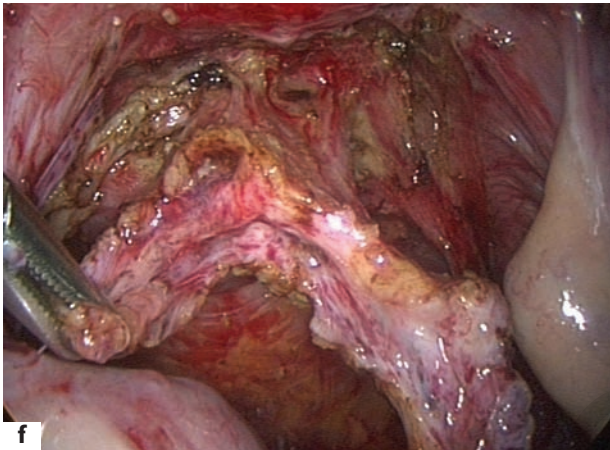
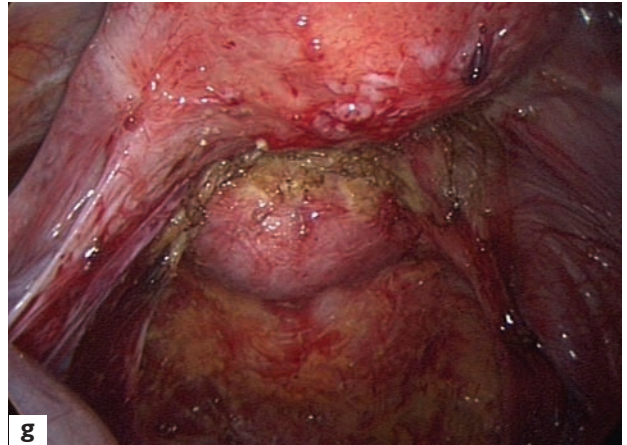
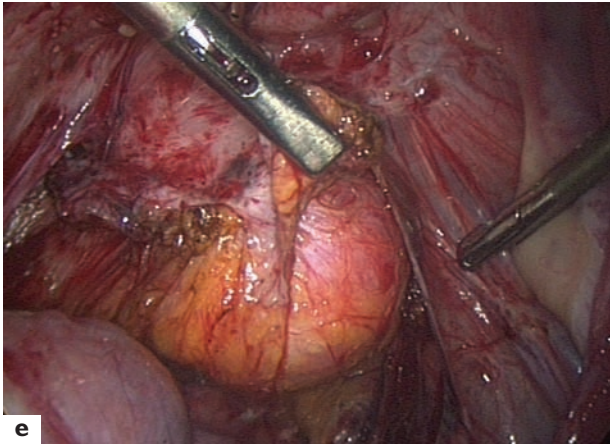


Figure 5.5 continued (e) the Douglas pouch is freed from the vagina (pushed by a vaginal sponge); (f) the Douglas pouch is freed from the cervix; (g) final view after Douglassectomy; (h) the removed uterosacral ligaments and torus uterinus

ligaments. In some patients with deep and severe dyspareunia and secondary dysmenorrhea, or presenting with endometriosis of the uterosacral ligaments at laparoscopy or recurrence of symptoms after LUNA, we propose a Douglassectomy by laparoscopy (Figure 5.5).

The technique starts in the same way as LUNA, vaporizing the uterosacral ligaments as close to the cervix as possible, creating a crater about 2 cm in diameter and 1 cm deep. It is always very important to identify the course of the ureter.

Once this step is completed, the assistant manipulating the uterus places a sponge in the posterior fornix of the vagina in order to individualize the peritoneum of the cul-de-sac of Douglas. In some cases, a 22-mm Hegar dilator is placed in the rectum in order to identify its position. Once the LUNA procedure is completed, we start on one side, pulling the peritoneum of the cul-de-sac of Douglas progressively with the grasping forceps, and separating it from the perirectal fat and the fat below the peritoneum with the CO₂ laser until the peritoneal leaf is completely

removed on the contralateral side. If the cleavage plane between the peritoneum and the fat below has been well defined, there should not be any hemostatic problems. Otherwise, careful bipolar coagulation could be carried out.

Forty-one laparoscopic Douglassectomies with uterosacral ligamentopexy were performed in the Department of Gynecology at the University Hospital of Caen during the period between 1990 and 1995 in patients with painful retroverted uteri²². The surgical endoscopic procedure, identical to the operation first promoted by Jamain and Letessier in 1967²³ using laparotomy, is described. Douglassectomy is the only definitive procedure for restoring normal anatomy of the pelvic floor in the case of painful uterine retroversion in a setting of Allen–Masters syndrome. Furthermore, it allows pathological analysis of the excised peritoneum. The results of this procedure are excellent when the indications are correctly met, particularly with regard to positive pessary testing.

Prevesical neurectomy

Resection of the presacral nerve plexus is associated with significant relief from symptoms. The pain impulses from the uterus, which travel through the inferior hypogastric plexus into the intermediate hypogastric plexus and the superior hypogastric plexus, can be interrupted by performing this procedure laparoscopically. The intermediate hypogastric plexus, composed of two or three trunks lying on the vertebral body of L5, is the most appropriate place for resection. Presacral neurectomy is not appropriate treatment for the relief of lateral or back pain. Patients with midline pain, however, will experience significant relief following this procedure²⁴.

Chen *et al.*²⁵ compared laparoscopic presacral neurectomy (LPSN) and LUNA for primary dysmenorrhea. One group (33 patients) underwent LPSN and the other group (35 patients), LUNA. There were no complications and all the patients left hospital within 24 h of surgery. The efficacy of both surgical methods was almost the same (87.9% vs. 82.9%) at the 9-month postoperative follow-up visit, but LPSN proved to be significantly more effective than LUNA (81.8% vs. 51.4%) at the 12-month visit.

REFERENCES

- Nisolle M, Casanas-Roux F, Anaf V, et al. Morphometric study of the stromal vascularization in peritoneal endometriosis. *Fertil Steril* 1993; 59: 681–4
- Nisolle M, Paindaveine B, Bourdon A, et al. Histologic study of peritoneal endometriosis in infertile women. *Fertil Steril* 1990; 53: 984–8
- Donnez J, Nisolle M, Casanas-Roux F. Three-dimensional architecture of peritoneal endometriosis. *Fertil Steril* 1992; 57: 980–3
- Koninckx PD. Deeply infiltrating endometriosis. In Brosens I, Donnez J, eds. *Current Status of Endometriosis. Research and Management*. Carnforth, UK: Parthenon Publishing, 1993: 437–46
- Sturgis E, All BJ. Endometriosis peritonei – relationship of pain to functional activity. *Am J Obstet Gynecol* 1954; 68: 1421–31
- White JC. Conduction of visceral pain. *N Engl J Med* 1952; 156: 686–90
- Allen WM, Masters WH. Traumatic lacerations of uterine supports: the clinical syndrome and operative treatment. *Am J Obstet Gynecol* 1955; 70: 500
- Donnez J, Nisolle M, Anaf V, et al. Endoscopic management of peritoneal and ovarian endometriosis. In Donnez J, ed. *Atlas of Laser Operative Laparoscopy and Hysteroscopy*. Carnforth, UK: Parthenon Publishing, 1994: 63–74
- Taylor HC Jr. Vascular congestion and hyperemia: their effect on structure and function in the female reproductive system. *Am J Obstet Gynecol* 1949; 57: 211
- Taylor HC Jr. Vascular congestion and hyperemia. II. The clinical aspects of the congestion fibrosis syndrome. *Am J Obstet Gynecol* 1949; 57: 637
- Fluhman CF. The rise and fall of suspension operations for uterine retrodisplacement. *Bull Johns Hopkins Hosp* 1955; 96: 59–70
- Gillian DR. Round-ligament ventrosuspension of the uterus: a new method. *Am J Obstet Gynecol* 1900; 41: 299
- Olshausen R. Uber ventrale operation bei prolapsus und retroversio uteri. *Sbl Gynakol* 1886; 10: 698
- Baldy JM. Treatment of uterine retrodisplacements. *Surg Gynecol Obstet* 1909; 8: 421
- Alexander W. [Cited by] Curtis AH, ed. *Obstetrics and Gynecology*. Philadelphia: WB Saunders, 1937
- Adams JA. [Cited by] Graves WP. *Gynecology*. Philadelphia: WB Saunders, 1916
- Yoon FE. Laparoscopic ventrosuspension. A review of 72 cases. *Am J Obstet Gynecol* 1990; 163: 1151–3
- Koh LM, Tang FC, Huang MH. Preliminary experience in pelviscopic uterine suspension using Webster–Baldy and Franke's method. *Acta Obstet Gynecol Scand* 1996; 75: 575–6
- Donnez J, Nisolle M. Carbon-dioxide laser laparoscopy in pelvic pain and infertility. In Sutton C, ed. *Laparoscopic Surgery. Baillière's Clinical Obstetrics and Gynaecology*. London: Baillière Tindall, 1989: 525–44
- Sutton CJG. Laser uterine nerve ablation. In Donnez J, ed. *Laser Operative Laparoscopy and Hysteroscopy*. Leuven: Nauwelaerts, 1989: 43–52
- Sutton CJ, Pooley AS, Ewen SP, et al. Follow-up report on a randomized controlled trial of laser laparoscopy in the treatment of pelvic pain associated with minimal to moderate endometriosis. *Fertil Steril* 1997; 68: 1070–4
- Von Theobald P, Barjot P, Levy G. Laparoscopic Douglassectomy in the treatment of painful uterine retroversion. *Surg Endosc* 1997; 11: 639–42
- Jamain B, Letessier A. Douglassectomy in gynecology. *Sem Hop* 1967; 43: 157–72
- Carter JE. Laparoscopic presacral neurectomy utilizing contact-tip Nd:YAG laser. *Keio J Med* 1996; 45: 332–5
- Chen FP, Chang SD, Chu KK, et al. Comparison of laparoscopic presacral neurectomy and laparoscopic uterine nerve ablation for primary dysmenorrhea. *J Reprod Med* 1996; 41: 463–6

akusher-lib.ru

Laparoscopic excision of rectovaginal and retrocervical endometriotic lesions

J Donnez, P Jadoul, O Donnez, J Squifflet

INTRODUCTION

In the pelvis, three different forms of endometriosis must be considered¹⁻⁴: (1) peritoneal endometriosis⁵; (2) ovarian endometriosis^{6,7}; and (3) rectovaginal septum endometriosis^{1-4,8-11}.

The third form of the disease has been defined as deep endometriosis, rectovaginal endometriosis or adenomyosis of the rectovaginal septum by Donnez *et al.*⁸⁻¹². Already in 1927, Sampson¹³ suggested a link between the cervix and the rectum. Indeed, he defined cul-de-sac obliteration as: 'extensive adhesions in the cul-de-sac, obliterating its lower portion and uniting the cervix or the lower portion of the uterus to the rectum, with adenoma of the endometrial type invading the cervical and the uterine tissue and probably also (but to a lesser degree) the anterior wall of the rectum.'

As explained further, we are convinced that so-called rectovaginal lesions must be classified into three subtypes. In most cases, the lesion originates from the cervix, and cul-de-sac obliteration implies the presence of deep fibrotic retrocervical adenomyosis beneath the peritoneum (Figures 6.1 and 6.2).

Treatment options for pain or infertility secondary to deep lesions include ovarian suppression therapy with gonadotropin-releasing hormone agonists, or surgery¹⁴.

For existing infertility or the preservation of fertility, reconstructive surgery can be considered via laparoscopy, depending on the skill and experience of the surgeon^{8-12,14-19}.

The aim of this chapter is to describe this entity and its therapeutic approaches.

THE CONCEPT OF RETROCERVICAL AND RETROPERITONEAL DISEASE

Endometriosis, defined as the presence of ectopic endometriotic glands and stroma, may involve all pelvic organs.

Different hypotheses have been proposed for the etiopathogenic aspects of endometriosis. Meyer²⁰ proposed the metaplasia theory, and Sampson¹³ the transplantation theory. The notion that peritoneal endometriosis and rectovaginal endometriosis are two distinct entities was first proposed by Donnez *et al.* in 1996²¹, and the concept of retroperitoneal endometriotic (adenomyotic) disease (RAD) was first published in 2001 by the same team²². Our hypothesis is that these lesions

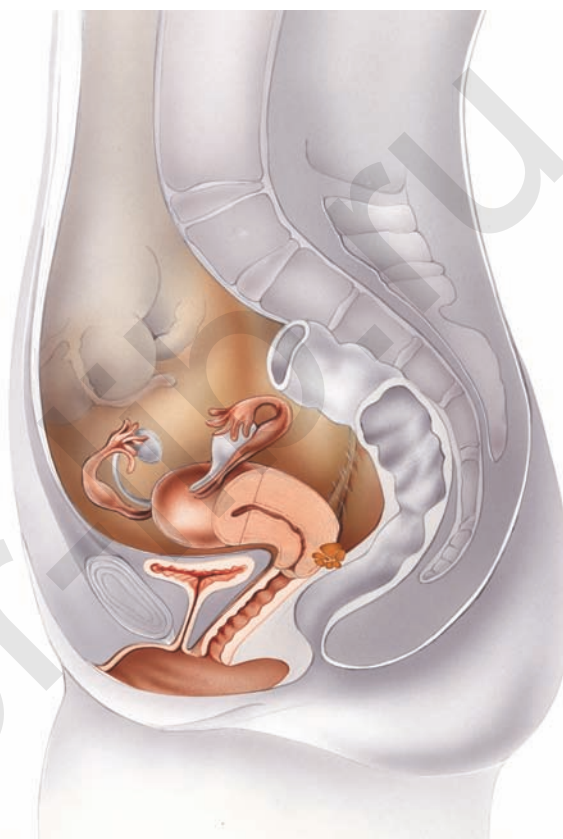


Figure 6.1 Adenomyotic nodule of the rectovaginal septum

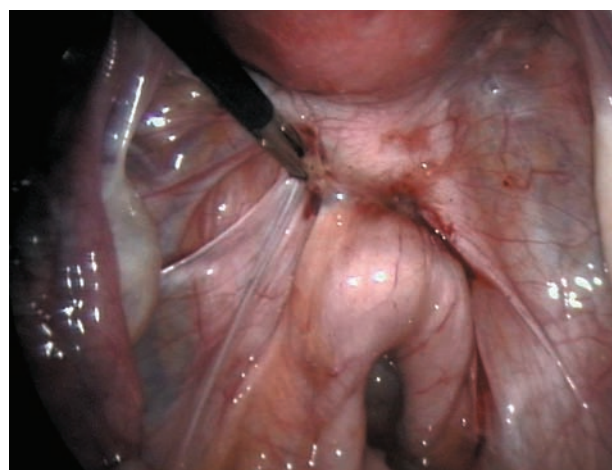


Figure 6.2 The rectosigmoid junction is clearly attached to the posterior part of the cervix

Table 6.1 Increasing prevalence of adenomyotic nodules among the 'endometriosis' population

	1989–1992	1993–1996	1997–2000	2000–2004
Endometriosis (<i>n</i>)	1107	1389	1513	1980
Peritoneal and ovarian endometriosis (<i>n</i> (%))	1058 (95.5%)	1077 (77.5%)	931 (61.6%)	1168 (58.9%)
Adenomyotic nodules (<i>n</i> (%))	49 (4.5%)	312 (22.5%)	582 (38.4%)	812 (41.1%)

are retroperitoneal and may result, in some cases (<10%), from metaplasia of Müllerian rests. In other cases (>90%), the origin of the lesion is the posterior part of the cervix, where the vagina is attached. The retroperitoneal space should thus be considered as the origin of deep endometriotic (adenomyotic) disease, effectively banishing the concept of deep-infiltrating endometriosis^{23–25}. It is indeed highly unlikely that retroperitoneal lesions of a few millimeters in size could induce retroperitoneal lesions of more than 3 cm in size. The nodular aspect of these lesions located in the rectovaginal septum, or behind the cervix, is due to smooth muscle proliferation. These deep lesions are retroperitoneal and may extend laterally or to the anterior rectal wall²⁶.

A new concept? Do we have arguments to support this concept?

Arguments in favor of retrocervical and retroperitoneal disease include the following:

- (1) The marked increase in the prevalence of rectovaginal nodules, compared with peritoneal and ovarian endometriosis, during the past 15 years (Table 6.1) seems to prove that this entity is different.
- (2) Laparoscopic visualization reveals only the tip of the iceberg, with more than 90% of the lesion being retroperitoneal.
- (3) The crucial argument proving that deep retrocervical and rectovaginal lesions do not originate from infiltrating peritoneal endometriosis is the recent discovery, by our team, that these lesions do not express the gene HOX10 (related to endometrium) but rather HOX11 and -12 (related to the cervix and vagina). It was formerly proved that deep rectovaginal and retrocervical lesions are the consequence of a tumoral process, originating from the cervix or the rectovaginal septum²⁷.
- (4) According to Squifflet *et al.* (Figure 6.3), three types of deep endometriotic lesions must be distinguished, and the majority of deep endometriotic lesions (>90%) originate from the retrocervical space, as proved by magnetic resonance imaging (MRI)²⁸.
- (5) Heilier *et al.*²⁹ were recently able to determine that dioxin-like polychlorodibenzodioxin (PCDD) and polychlorinated biphenyls (PCBs) were significantly higher in the serum of women suffering from deep nodular lesions than in women with peritoneal endometriosis or in the control group. These data strongly suggest that environmental toxins could be responsible for this entity.
- (6) This lesion originates from the tissue of the rectovaginal septum or from the posterior part of the cervix. It consists essentially of smooth muscle (90% of the content), with active glandular epithelium and scanty stroma. Smooth-muscle proliferation and fibrosis, consistently observed, are responsible for the nodular aspect of endometriosis. Histologically, it is completely different from peritoneal endometriosis, which can infiltrate the peritoneal surface and beneath the peritoneum. Even if peritoneal lesions may sometimes be found penetrating the subperitoneal layers by more than 5 mm, there is no argument at all to support the claim that these lesions could induce the formation of deep nodular lesions (often more than 2 cm in size).
- (7) In 28% of cases, the rectovaginal adenomyotic nodule is not associated with peritoneal endometriosis^{11,28}. In such cases, the hypothesis of deep invasion by a peritoneal lesion, with the subsequent formation of a retroperitoneal nodular lesion, as suggested by other authors^{25,30}, is obsolete.
- (8) Hyperplasia of the smooth muscle present in the septum often provokes perivisceritis, visible on radiography, because of the inflammatory process and secondary retraction of the rectal serosa. The absence of evolution of the rectal lesion after removal of the nodule supports our hypothesis concerning its purely retrocervical or rectovaginal septal origin^{10,31}. Indeed, lateral and posterior extension occurs retroperitoneally via lymphatics¹¹ or via nerves³². The mode of propagation is very similar to the propagation of cervical cancer.

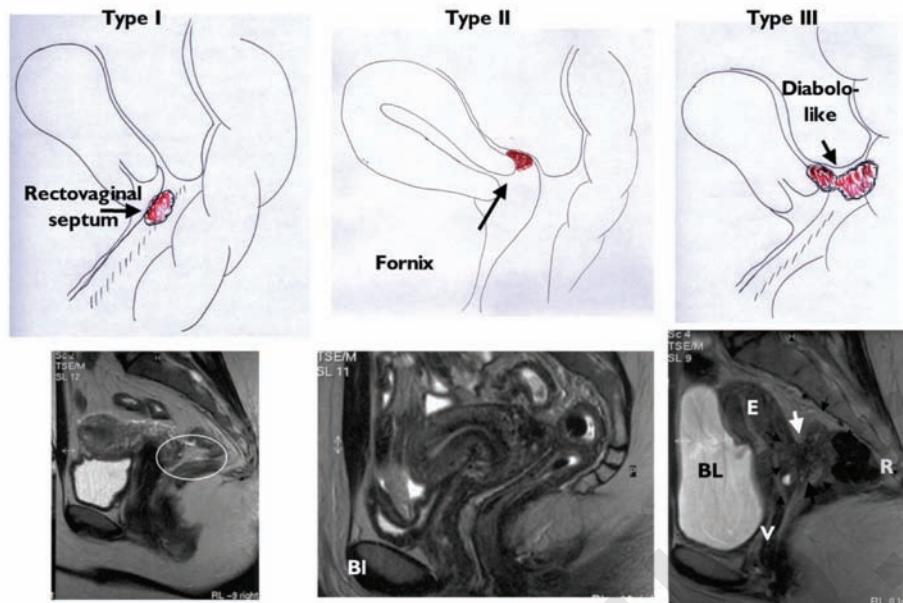


Figure 6.3 Classification of deep endometriotic (adenomyotic) lesions

Hormonal dependence

- (1) Rectovaginal adenomyosis exhibits a varied functional response to ovarian hormones, and does not respond to physiological levels of progesterone (P). Secretory changes are always absent during the second half of the menstrual cycle, indicating that the endometrium present in nodules does not have the same characteristics as eutopic endometrium.
- (2) The adenomyotic rectovaginal nodule is, like an adenomyoma, a circumscribed nodular aggregate of smooth muscle, endometrial glands and, usually, endometrial stroma^{21,33,34}. The similarity in the histological descriptions of uterine adenomyosis and rectovaginal adenomyosis has led us to suggest that the so-called endometriotic nodule of the rectovaginal septum is the same as an adenomyoma or an adenomyotic nodule.
- (3) The steroid receptor content of nodules throughout the cycle suggests that they are probably not regulated by steroids^{21,35,36}. A low estrogen receptor (ER) content could be the key factor in explaining the out-of-phase endometrium, despite normal P levels, but a reduction in progesterone receptor (PR) content could also cause resistance to P action and result in inadequate secretory transformation³⁷. The absence of a response to P levels suggests that the different regulatory mechanisms of endometriotic steroid receptors result in deficient endocrine dependency, or that the receptors are present but

biologically inactive^{38,39}. This explains the poor response of nodules to hormonal therapy.

- (4) The low mitotic activity observed in this pathology could account for the relatively slow evolution of the adenomyotic nodule and the weak response to medical therapy, necessitating surgical excision^{10,11}.

DIAGNOSIS AND CLASSIFICATION

Careful clinical examination⁴⁰, transrectal sonography⁴¹ and rectal endoscopic sonography²⁵ have all been recommended to identify deep endometriotic (adenomyotic) rectovaginal lesions, while transvaginal sonography and MRI are generally used to detect bladder adenomyotic nodules^{26,42–44}.

In our series, the main symptoms were pelvic pain and dysmenorrhea, observed in 95% of cases, and rectal dyschezia, observed in 25% of cases.

About 25% of patients suffered pelvic pain associated with infertility. In all cases of infertility, an evaluation of ovulation, cervical mucus–sperm interaction (postcoital test) and male factor (defined as <15 million sperm/ml using a Makler counting chamber) was undertaken. Preoperative radiography of the colon was carried out in order to assess the involvement of the rectal surface. Profile radiography offers the best evaluation of infiltration of the anterior rectal wall (Figure 6.4).

Examination with a speculum revealed either a normal vaginal mucosa or a protruded bluish nodule in the posterior fornix (Figure 6.5). Using palpation, the diameter

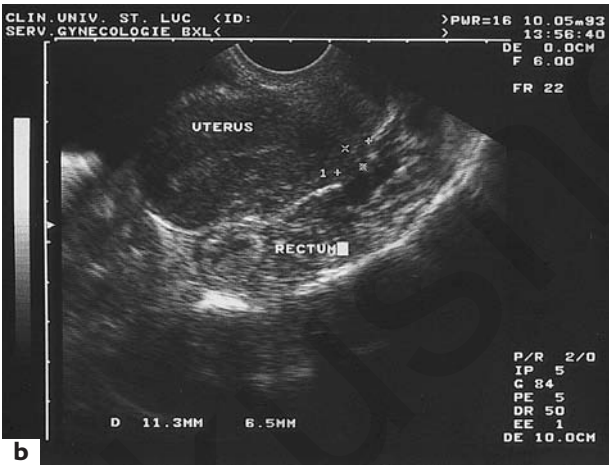
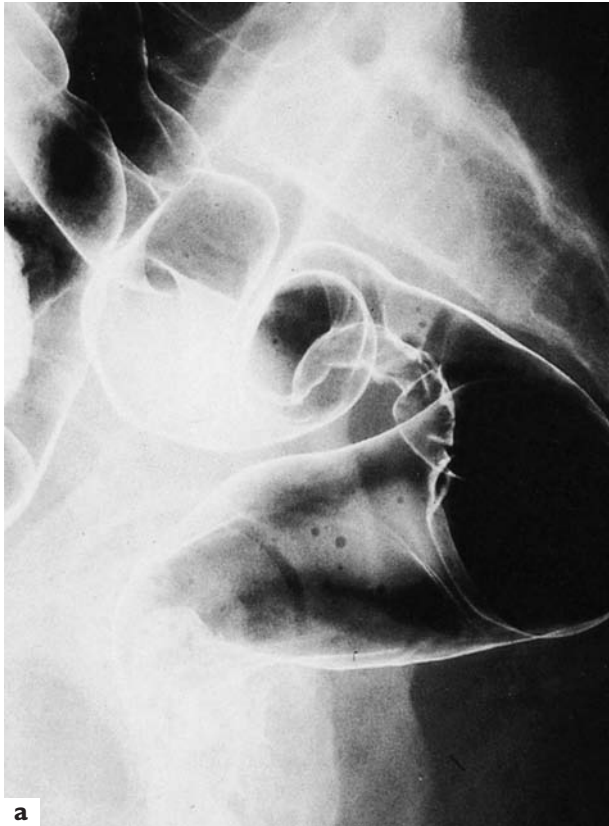


Figure 6.4 Barium enema: profile radiography offers the best evaluation of infiltration of the anterior rectal wall. (a) Typical ‘endometriotic’ infiltration of the anterior rectal wall without stenosis; intact mucosa. (b) The same patient, showing evaluation of rectal infiltration by vaginal echography

of the lesion could be evaluated. Palpation is very often painful, and the presence of a nodule accounts for symptoms such as deep dyspareunia and dysmenorrhea.

A combination of rectal endoscopic sonography (RES) and MRI has also been advocated to evaluate deep endometriotic lesions⁴⁴⁻⁴⁷, but most studies to date have

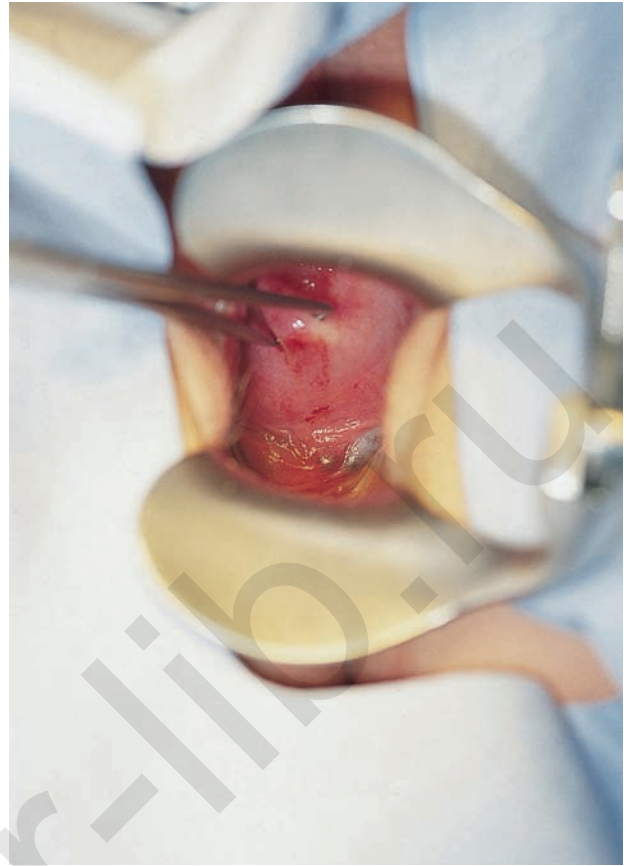


Figure 6.5 Speculum examination: sometimes a bluish lesion is seen protruding into the vaginal fornix

been retrospective and not blind. More recently, Squifflet *et al.*²⁸, Darai *et al.*⁴⁸, Bazot and Darai⁴⁹ and Delpy *et al.*⁵⁰ demonstrated the important role of both RES and MRI in the detection of deep nodular endometriotic lesions. By injecting jelly for ultrasonography into the vagina and rectum, Takeuchi *et al.*⁵¹ were able preoperatively to diagnose high rates of not only deep rectovaginal endometriotic lesions, but also complete cul-de-sac obliteration. Squifflet *et al.* recently proposed a classification of deep lesions into three subtypes, based on transrectal ultrasonography (TRUS) and MRI²⁸.

Classification of deep lesions (Figure 6.3)

Squifflet *et al.*²⁸ distinguished three types of deep retroperitoneal lesions by analyzing their location, as defined precisely by transrectal ultrasonography and MRI³⁴. These three types are: (1) type I: rectovaginal septum lesions, (2) type II: posterior vaginal fornix lesions and (3) type III: hourglass-shaped lesions (Table 6.2).

Rectovaginal septum lesions are situated within the rectovaginal septum between the posterior wall of the vaginal mucosa and the anterior wall of the rectal muscularis. Cranially, the rectovaginal septum is limited by

Table 6.2 Prevalence of the three types of deep lesions

Type I*	10%
Type II	58%
Type III	32%

*Only 10% of deep lesions are clearly separated from the cervix and located in the rectovaginal septum (type I)

the joining of the two uterosacral ligaments behind the cervix. According to our classification³⁴, the lesion is not linked or attached to the cervix. It is situated under the peritoneal fold of the cul-de-sac of Douglas. The caudal portion of the septum is the perineal body. Most cases are located in the cranial part of the septum. This type is observed in only 10% of cases (Table 6.2). Probably only this type is due to metaplasia of Müllerian remnants present in the rectovaginal septum^{2,21}. Rectovaginal septum lesions are usually found to be smaller in size. They are distant from the cervix, and their median size estimated by clinical examination is 2 cm. Most of the lesions are exophytic in the vaginal mucosa, and appear bluish on speculum examination. On clinical examination, a free space is found to exist between the lesion and the cervix.

Posterior vaginal fornix lesions are the most frequent type of deep lesions (58%). They develop from the posterior fornix towards the rectovaginal septum. The posterior fornix is retrocervical and corresponds, in its attachment to the vaginal wall, to the posterior wall of the posterior lip of the cervix. It is bordered by the joining of the two uterosacral ligaments behind the cervix; cranially, it is limited by the peritoneal Douglas pouch, and posteriorly, by the anterior wall of the middle third of the rectum. Crossing of the ureter and the uterine artery occurs 10–15 mm from the lateral vaginal fornix. Posterior vaginal fornix lesions are often small, their average size being assessed by clinical examination. There is no extension to the rectovaginal septum or the rectal wall, and so, most of the time, a barium enema reveals a normal rectosigmoid junction, but large posterior fornix lesions can be associated with extension to the rectovaginal septum.

Hourglass-shaped or diaboloid-like lesions occur when posterior fornix lesions extend cranially to the anterior rectal wall. Their prevalence is 32%. Clinical evaluation usually reveals a larger lesion, more than 3 cm in size, with a greater risk of extension to the rectal wall (barium enema showed perivisceritis in 78% of cases). This continuum between the rectal muscularis and the cervix was found to obliterate the rectovaginal septum cranially. In this type, the part of the adenomyotic lesion situated in the anterior rectal wall is the same size as the part of the lesion situated near the posterior fornix. A small but well-observed continuum exists between these two parts of the lesion.

This is why we termed these lesions diaboloid-like or hourglass-shaped. These lesions always occur under the peritoneal fold of the rectouterine pouch of Douglas. Infiltration of the rectal muscularis is systematically observed in this subtype, as demonstrated by profile radiography or barium enema (Figure 6.4a) and transrectal ultrasonography (TRUS) (Figure 6.4b).

SURGERY

Surgery for deep rectovaginal endometriosis was first described by Reich *et al.*¹⁵ and Donnez⁵² in 1991, and the two first large series including 231 and 500 women, respectively, were published in 1995¹⁰ and 1997¹¹.

Surprisingly, recent studies very often fail to refer to these first papers. Even more surprising, increasingly aggressive surgery, including bowel resection (Figure 6.6a), is systematically proposed in the case of rectovaginal endometriosis and muscularis involvement, even if there is no mucosal involvement^{30,48,53–56}. All of these studies, however, were non-randomized and do not evaluate the long-term results of this surgery compared with debulking or shaving surgery (Figure 6.6b).

Our series of 2147 cases of rectovaginal septum adenomyosis treated by laparoscopy is presented in Table 6.3.

Whenever extensive involvement of the cul-de-sac was suspected preoperatively, either because of the clinical presentation or from another physician's operative record, a mechanical bowel preparation (Fleet® Phospho-soda®) was administered orally before surgery to induce brisk, self-limiting diarrhea that rapidly cleansed the bowel without disrupting the electrolyte balance.

In the case of lesions of the anterior rectal wall (diagnosed by radiography or echography), a bowel preparation was proposed as for conventional bowel resection.

SURGICAL TECHNIQUE: 'SHAVING'

All the laparoscopic procedures were performed under general anesthesia. A 12-mm operative laparoscope was inserted through a vertical intraumbilical incision. Three other puncture sites were made: 2–3 cm above the pubis in the midline, and in the areas adjacent to the deep inferior epigastric vessels, which were visualized directly.

Deep fibrotic nodular adenomyosis involving the cul-de-sac required excision of the nodular tissue from the posterior vagina, rectum, posterior cervix and uterosacral ligaments.

To determine the diagnosis of cul-de-sac obliteration during laparoscopy, a sponge on a ring forceps was inserted into the posterior vaginal fornix (Figures 6.7 and 6.8). A dilator (Hegar 25) or a rectal probe was systematically inserted into the rectum (Figure 6.9). Complete obliteration

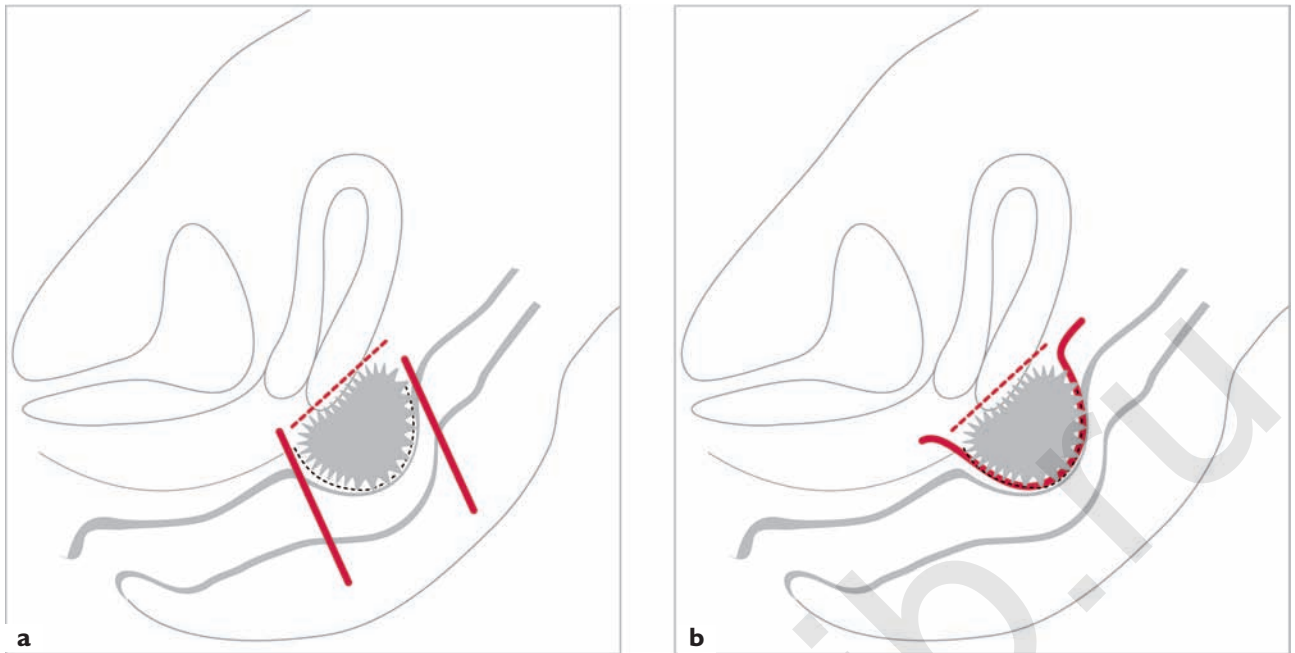


Figure 6.6 (a) Radical surgery: resection of the nodule with a bowel segment. (b) Shaving technique

Table 6.3 A series of 2179 cases: rectovaginal adenomyosis treated by laparoscopic debulking surgery without segmental resection ($n = 2147$) or by segmental bowel resection ($n = 32$). Values are expressed as mean (range) or n (%)

<i>Laparoscopic debulking or 'shaving' surgery*</i> ($n = 2147$)	
Size of lesion (cm)	2.8 (1–6)
Duration of surgery (min)	78 (31–248)
Hospitalization (days)	2.7 (2–7)
Complications	
rectal perforation	12 (0.5%)
fecal peritonitis	1 (0.05%)
delayed hemorrhage (< 24 h postoperative)	3 (0.1%)
ureteral injury	7 (0.3%)
urinary retention	10 (0.5%)
<i>Segmental bowel resection (laparotomy or mini-laparotomy, assisted by laparoscopy)</i> ($n = 32$) [†]	
Size of lesion (cm)	3.2 (2–4.5)
Duration of surgery (min)	152 (138–240)
Hospitalization (days)	8.5 (7–10)
Complications	
'incomplete' surgery (vaginal fornix not resected)	32 (100%)
ureteral injury	1 (3%)
urinary retention	6 (18%)
fistula	0

*Not entering the rectal lumen; [†]in 32 cases, bowel resection was carried out by laparotomy because of bowel stenosis with mucosal involvement (these cases are not included in the series of 2147 patients)

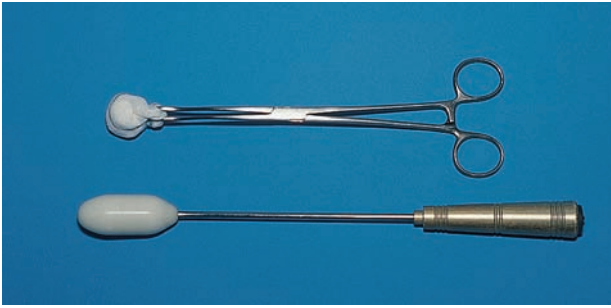


Figure 6.7 Sponge grasped by forceps (top); rectal probe (bottom)

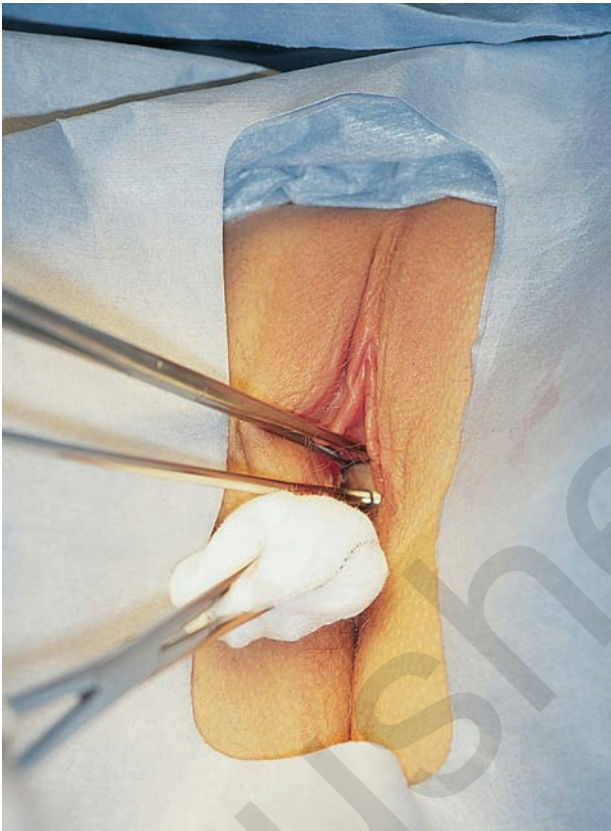


Figure 6.8 Vaginal sponge is inserted into the vagina in order to see the cleavage plane between the rectum, the vagina and the nodule

was diagnosed when the outline of the posterior fornix could not be seen through the laparoscope.

Cul-de-sac obliteration was partial when rectal tenting was visible but a protrusion of the sponge into the posterior vaginal fornix was identified between the rectum and the inverted U of the uterosacral ligaments. Sometimes, however, a deep lesion of the rectovaginal septum is only barely visible by laparoscopy.

Surgical techniques have evolved gradually, but all of them involve separation of the anterior rectum from the posterior vagina and excision or ablation of the

endometriosis in that area. Hydrodissection, scissor dissection and electrosurgery with an unmodulated (cutting) current are used by some authors^{15,18}, while others^{8-12,16,17} prefer the CO₂ laser.

As described by Reich *et al.*¹⁵ and Donnez *et al.*⁸⁻¹², attention was first directed towards complete dissection of the anterior rectum throughout its area of involvement, until the loose tissue of the rectovaginal space was reached. A sponge on a ring forceps was inserted into the posterior vaginal fornix and a rectal probe was placed in the rectum. In addition, a cannula was inserted into the endometrial cavity to antevert the uterus markedly. The peritoneum covering the cul-de-sac of Douglas was opened between the 'adenomyotic' lesion (Figure 6.10) and the rectum.

We used a technique of first freeing the anterior rectum from the loose areolar tissue of the rectovaginal septum, prior to excising visible and palpable deep fibrotic endometriosis, using the so-called 'shaving technique'. This approach was possible even when anterior rectal muscle infiltration was present. Careful dissection was then carried out using the hydrodissector, and the CO₂ laser for sharp dissection, until the rectum was completely freed (Figure 6.11) and identifiable below the lesion (Figure 6.12).

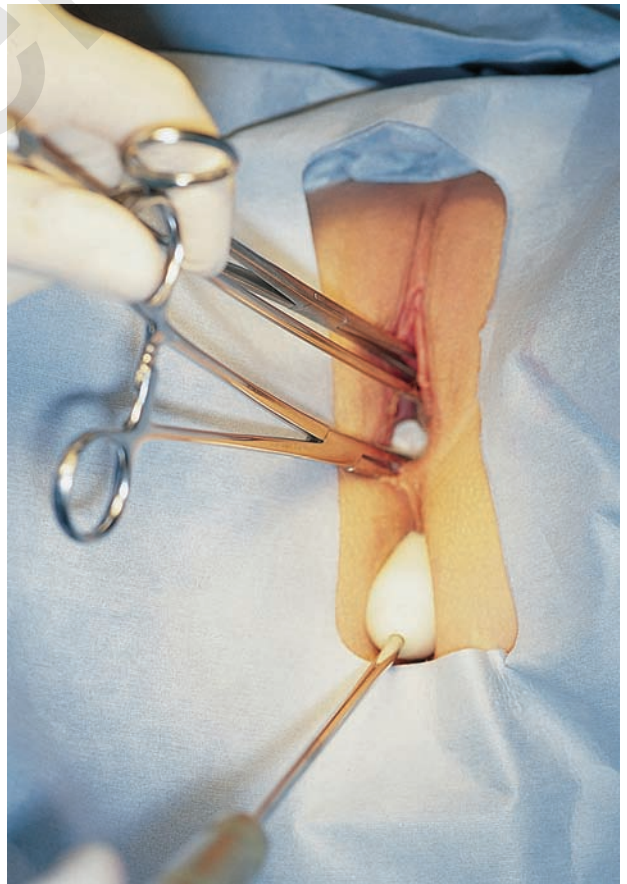


Figure 6.9 The rectal probe is inserted into the rectum

Excision of the fibrotic tissue on the side of the rectum was attempted only after the rectal dissection was complete. In the case of deep lesions, the vaginal wall was more or less penetrated by the adenomyosis and excision of part of the vagina was essential (Figures 6.13 and 6.14).

Dissection was performed accordingly, not only with the removal of all visible adenomyotic lesions (Figure 6.15), but also the vaginal mucosa with at least a 0.5-cm disease-free margin (caudally) (Figure 6.16). Lesions

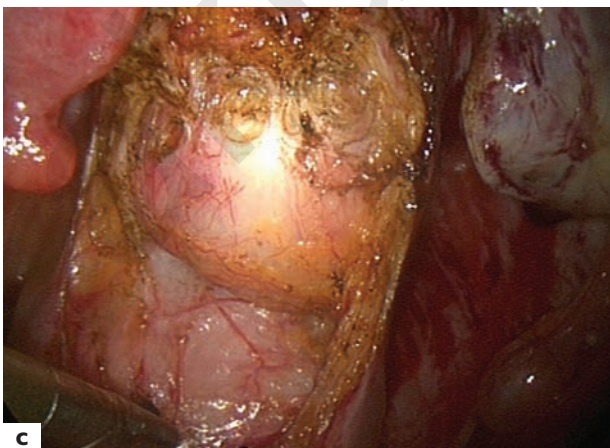
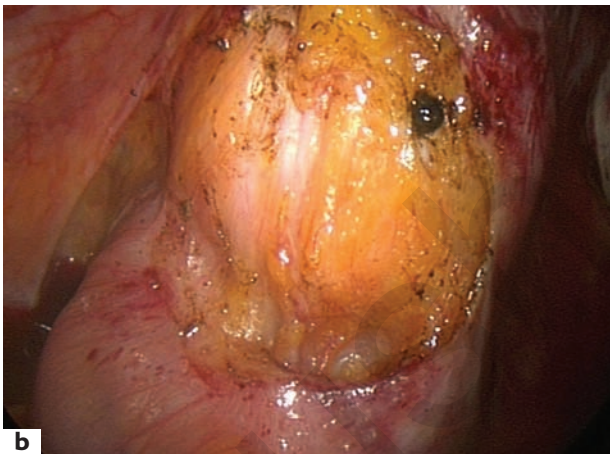
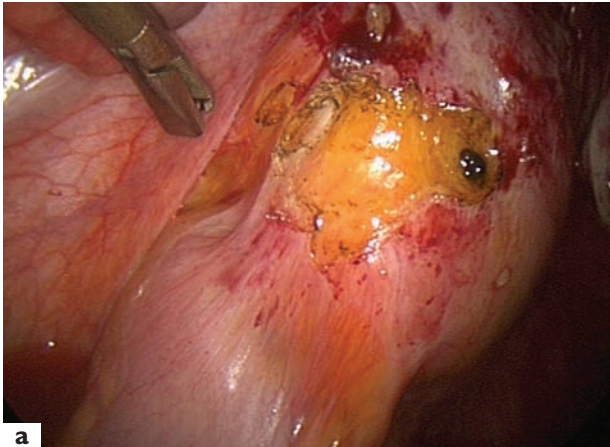
Figure 6.10 (a), (b) and (c) Dissection of the rectum with a CO₂ laser

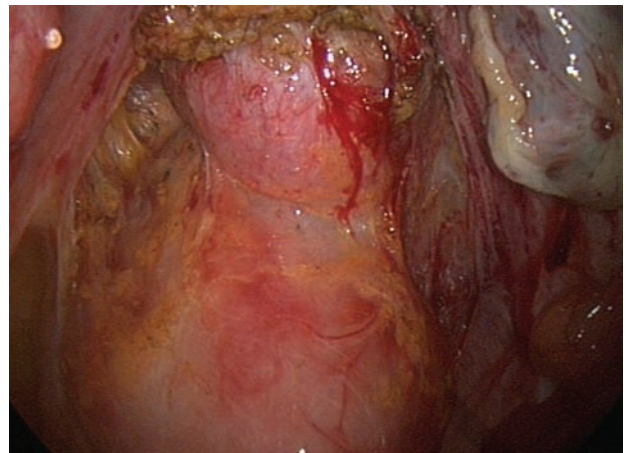


Figure 6.11 The rectum is completely freed

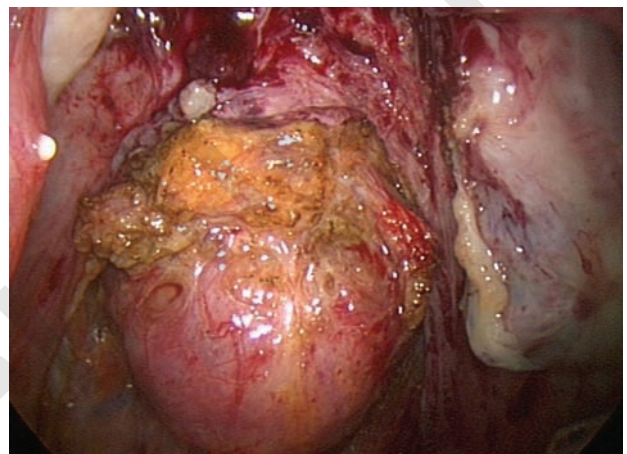


Figure 6.12 Adenomyotic nodule after dissection of the rectum

extending totally through the vagina were treated with *en bloc* laparoscopic resection from the cul-de-sac to the posterior vaginal wall (Figure 6.17); the pneumoperitoneum was maintained and the posterior vaginal wall was closed vaginally (Figure 6.18).

The anterior rectum was not re-peritonealized. Interceed® (Figure 6.19) was used to cover the deperitonealized area⁸⁻¹¹. Deep rectal muscle defects could be closed with suture (Vicryl® 2-0 or 3-0) (Figure 6.20).

Keckstein and Wiesinger⁵⁷ recently reported a series of 202 patients who underwent partial intestinal resection for deep endometriosis. With such surgery, complications are not uncommon and certainly more frequent than with the shaving technique. Much of the recent literature^{30,53-56}, however, seems to encourage very invasive techniques, including bowel resection in the case of rectal muscularis involvement. In our view, removing part of the rectum is simply not justified, since we know that the technique increases the risk of complications. Furthermore, no

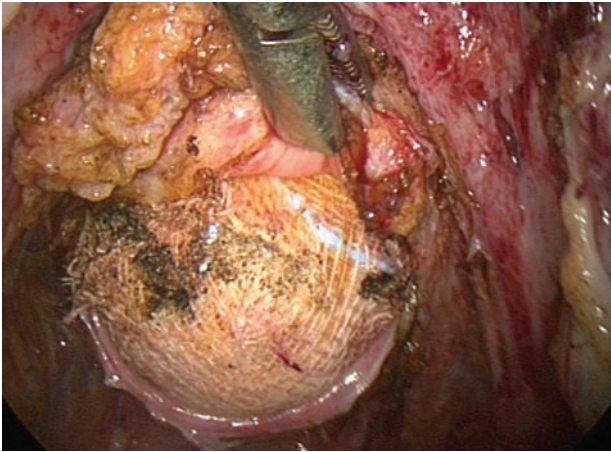


Figure 6.13 Opening of the vagina beneath the nodule on the vaginal sponge

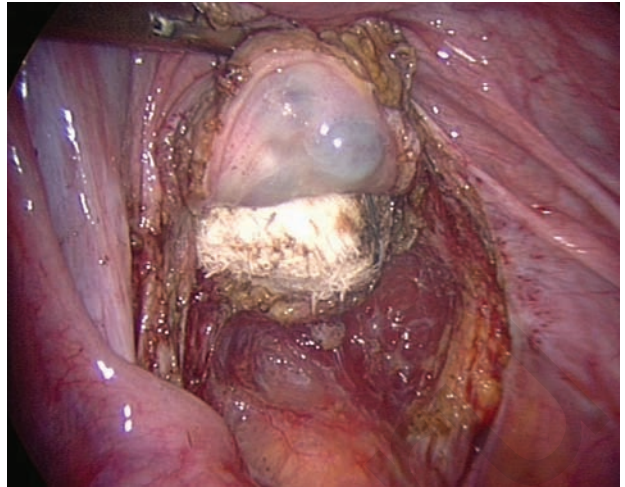
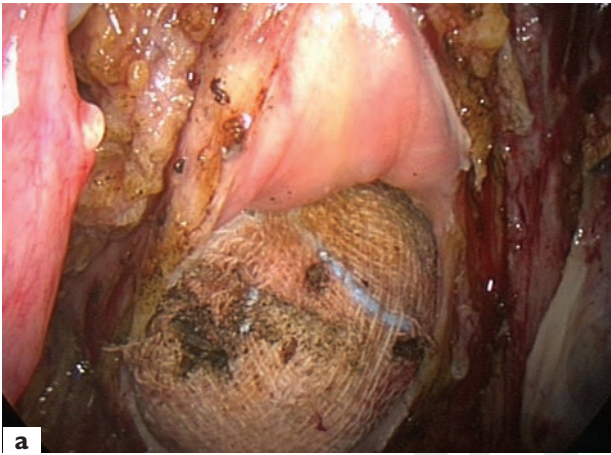
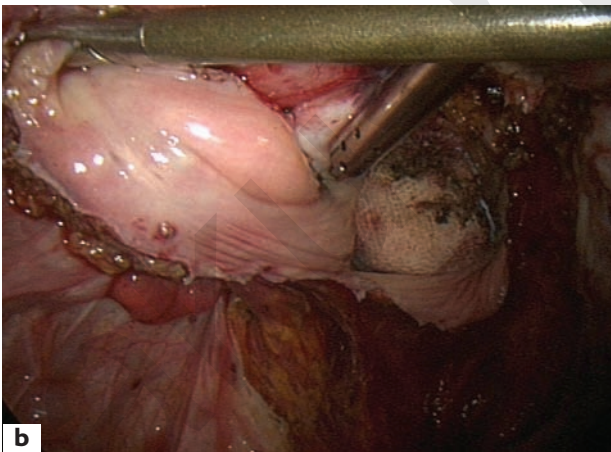


Figure 6.15 Bluish lesion on the vaginal part of the nodule



a



b

Figure 6.14 (a) and (b) Excision of the nodule and a part of the vagina

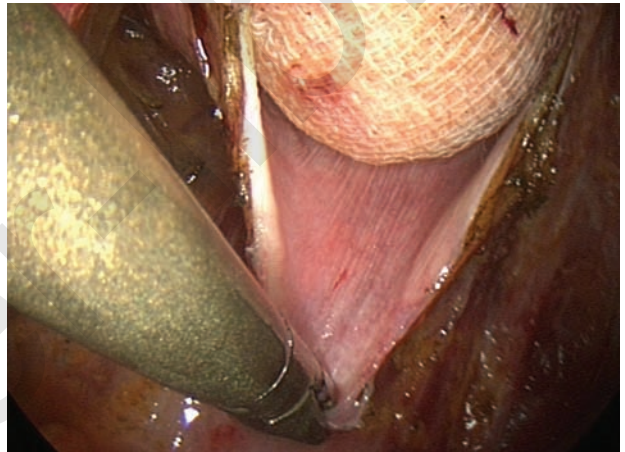


Figure 6.16 Disease-free margin of the vagina (caudally)

randomized studies to date have been able to prove that it is any more effective than the shaving technique.

In our series of 2147 patients (Table 6.3), laparoscopic dissection was performed successfully in all cases, even when radiography of the colon showed bowel involve-

ment. Bowel resection is not usually required, and our 'debulking' or 'shaving' surgical approach is often more than adequate. In most cases, perirectal perivisceritis observed in all cases of type III lesions may be left in place. The residual lesion in the muscularis of the rectum does not evolve, and remains constant for a long time. As patients are usually free of symptoms, we consider systematic bowel resection in the case of perirectal visceritis and rectal muscularis involvement unnecessary. Moreover, such surgery increases morbidity, and is responsible for more adhesions due to extensive lateral dissection.

In the case of bowel occlusion and rectal bleeding with rectal mucosa involvement, resection of the rectosigmoid junction must be carried out. It was performed in 32 cases in our series (Table 6.3). These 32 patients, who had rectal endometriosis with stenosis or substenosis with mucosal involvement and rectal menstrual bleeding, were operated on by laparotomy. Bowel resection with anastomosis was then carried out.

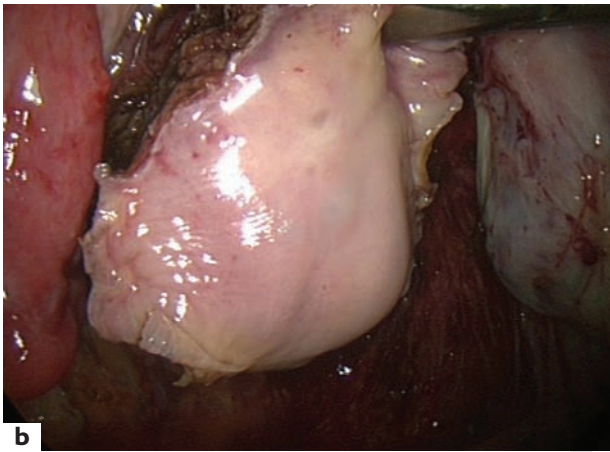
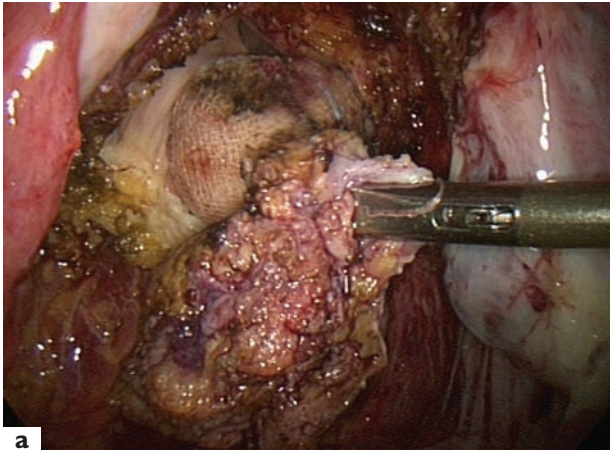


Figure 6.17 Resected nodule: (a) rectal side, (b) vaginal side

COMPLICATIONS

In our series of 2147 cases, laparoscopic rectal perforation occurred in 12 of them. All perforations were diagnosed at the time of laparoscopy. In the first three cases (occurring in the early 1990s), the rectum was repaired by laparotomy, and in the others, by laparoscopy.

One case of fecal peritonitis occurred 7 days after surgery. During surgery, bleeding at the site of lateral dissection of the rectum required extensive bipolar coagulation. At the end of surgery, bowel integrity was checked by CO₂ intrarectal insufflation and the blue test. No rectal defect was diagnosed. Seven days later, a hole of 2.5 cm in size was detected. Extensive coagulation probably provoked thermal rectal injury with subsequent necrosis and a fistula.

Seven cases of ureteral injury were noted in our patients. Two cases of ureteral transection were diagnosed on the first postoperative day by the presence of abundant fluid in the peritoneal cavity. High levels of urea and creatinine in the 'peritoneal' fluid and intravenous pyelog-

raphy (IVP) confirmed the diagnosis. Nephrostomy was carried out. One case resolved spontaneously, with complete healing of the ureter 2 months later. The other case required vesicoureteral reimplantation.

The remaining five cases of ureteral injury were due to thermal damage (bipolar coagulation), and were treated by insertion of a JJ stent.

Urinary retention for a maximum of 2 weeks occurred in ten women. It was probably due to the extensive lateral and prerectal dissection.

RECURRENCE

In one of our previous publications⁵⁸, the recurrence rate of deep endometriosis was 3.7% with excision of the nodule and resection of the posterior vaginal fornix, 16% when the vaginal fornix was not resected and 20% when the bowel, but not the vaginal fornix, was resected. Our study led us to suggest strongly that the shaving technique (for the rectum) and the resection technique (for the

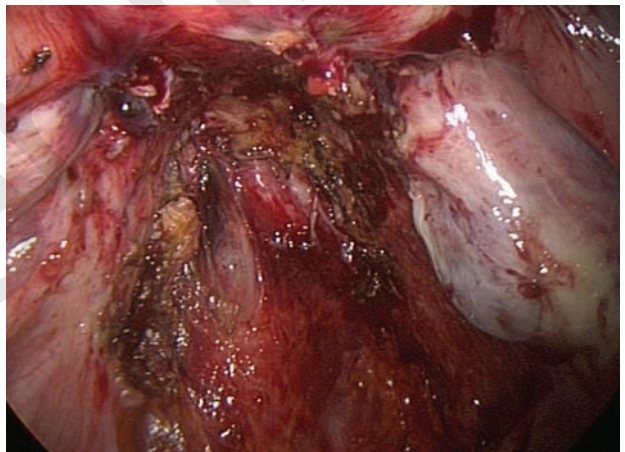


Figure 6.18 Final view after closure of the vagina

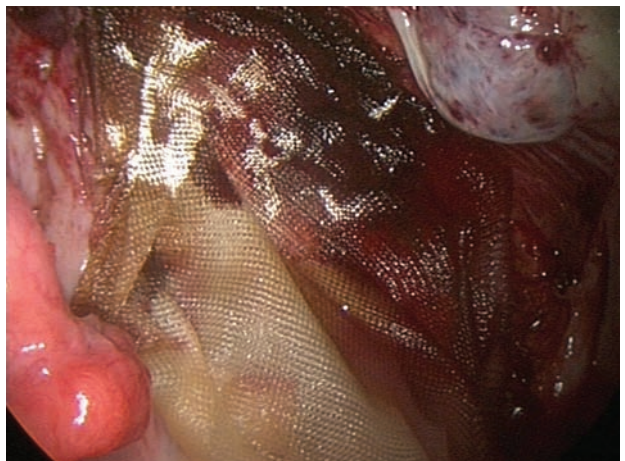


Figure 6.19 Interceed[®] is used to cover the deperitonealized area

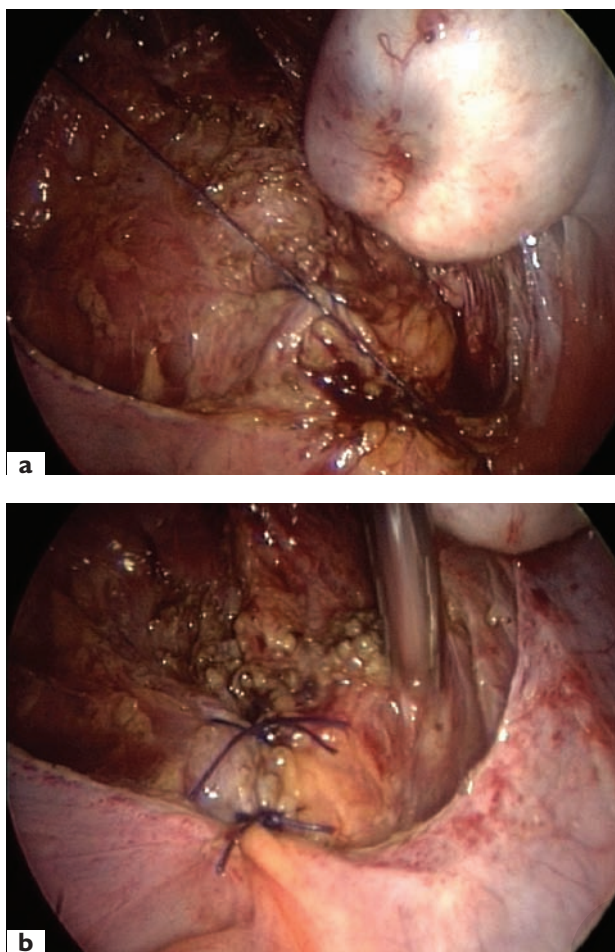


Figure 6.20 (a) and (b) Deep rectal muscle defect should be closed with suture

vagina) must be considered as first-line therapy. Side-wall endometriosis and *ureteral endometriosis* are the consequence of retroperitoneal adenomyotic disease⁵⁹. In the case of rectovaginal adenomyotic nodules or nodules developed more extensively laterally, and in the case of large uterosacral endometriotic nodules (>2.5 cm), patients should systematically undergo preoperative diagnosis of ureteral endometriosis. Lateral extension from the rectovaginal space to the side-wall through the cardinal ligaments also occurs in the retroperitoneal space, sometimes provoking ureteral stenosis, erroneously called ureteral endometriosis. This was observed in nearly 10% of deep lesions of more than 3 cm in size²⁶. In such cases, laparoscopic dissection of the ureter is required (see Chapter 7).

CONCLUSION

Deep endometriosis is essentially characterized by the presence of a rectovaginal or retrocervical nodule, which is

a circumscribed, nodular aggregate of smooth muscle, endometrial glands and, usually, endometrial stroma.

Histologically, scanty endometrial-type stroma and glandular epithelium are disseminated in muscular tissue. The very similar histological descriptions have led us to suggest that the so-called 'endometriotic nodule of the rectovaginal septum' is, in fact, just like an adenomyoma or adenomyotic nodule, originating from the posterior part of the cervix in the majority of cases and invading the retroperitoneal space.

We therefore suggest that the posterior part of the cervix in the retroperitoneal space should definitely be considered as the origin of this disease. We have, in this chapter, reviewed the classification, the diagnosis and the surgical technique of deep endometriosis, which is an adenomyotic disease of the cervix.

A comprehensive laparoscopic procedure, while not eradicating all the endometriosis, may result in considerable pain relief or a desired pregnancy. Although we recognize that bowel resection may be necessary in rare cases (1.8%), it seems prudent to curtail, rather than encourage, the widespread use of an aggressive, potentially morbid procedure.

REFERENCES

1. Donnez J, Nisolle M, Casanas-Roux F. Three-dimensional architecture of peritoneal endometriosis. *Fertil Steril* 1992; 57: 980–3
2. Nisolle M, Donnez J. Peritoneal endometriosis, ovarian endometriosis, and adenomyotic nodules of the rectovaginal septum are three different entities. *Fertil Steril* 1997; 68: 585–96
3. Donnez J, Nisolle M. Appearances of peritoneal endometriosis. Presented at the 3rd International Laser Surgery Symposium, Brussels, 1988
4. Nisolle M, Paindaveine B, Bourdon A, et al. Histologic study of peritoneal endometriosis in infertile women. *Fertil Steril* 1990; 53: 984–8
5. Nisolle M, Casanas-Roux F, Anaf V, et al. Morphometric study of the stromal vascularization in peritoneal endometriosis. *Fertil Steril* 1993; 59: 681–4
6. Hughesdon PE. The structure of endometrial cysts of the ovary. *J Obstet Gynaecol Br Emp* 1957; 64: 481–7
7. Donnez J, Nisolle M, Gillet N, et al. Large ovarian endometriomas. *Hum Reprod* 1996; 11: 641–6
8. Donnez J, Nisolle M, Casanas-Roux F, et al. Laparoscopic treatment of rectovaginal septum endometriosis. In Donnez J, Nisolle M, eds. *An Atlas of Laser Operative Laparoscopy and Hysteroscopy*. Carnforth, UK: Parthenon Publishing, 1994: 75–85
9. Donnez J, Nisolle M. Advanced laparoscopic surgery for the removal of rectovaginal septum endometriotic and adenomyotic nodules. *Baillieres Clin Obstet Gynecol* 1995; 9: 769–74

10. Donnez J, Nisolle M, Casanas-Roux F, et al. Rectovaginal septum endometriosis or adenomyosis: laparoscopic management in a series of 231 patients. *Hum Reprod* 1995; 10: 630–5
11. Donnez J, Nisolle M, Gillerot S, et al. Rectovaginal septum adenomyotic nodules: a series of 500 cases. *Br J Obstet Gynaecol* 1997; 104: 1014–18
12. Donnez J, Squifflet J. Laparoscopic excision of deep endometriosis. *Obstet Gynecol Clin North Am* 2004; 31: 567–80
13. Sampson J. Peritoneal endometriosis due to menstrual dissemination of endometrial tissue into the peritoneal cavity. *Am J Obstet Gynecol* 1927; 14: 422–69
14. Donnez J, Nisolle M, Casanas-Roux F. Endometriosis-associated infertility: evaluation of preoperative use of danazol, gestrinone and buserelin. *Int J Fertil* 1990; 35: 297–301
15. Reich H, McGlynn F, Salvat J. Laparoscopic treatment of cul-de-sac obliteration secondary to retrocervical deep fibrotic endometriosis. *J Reprod Med* 1991; 36: 516–22
16. Koninckx PD. Deeply infiltrating endometriosis. In Brosens I, Donnez J, eds. *Current Status of Endometriosis: Research and Management*. Carnforth, UK: Parthenon Publishing, 1993: 437–46
17. Nezhat C, Nezhat F, Pennington E. Laparoscopic treatment of lower colorectal and infiltrative rectovaginal septum endometriosis by the technique of video laparoscopy. *Br J Obstet Gynaecol* 1992; 99: 664–7
18. Canis M, Wattiez A, Pouly JL, et al. Laparoscopic treatment of endometriosis. In Brosens I, Donnez J, eds. *Current Status of Endometriosis: Research and Management*. Carnforth, UK: Parthenon Publishing, 1993: 407–17
19. Donnez J, Nisolle M, Casanas-Roux F, et al. Endometriosis: rationale for surgery. In Brosens I, Donnez J, eds. *Current Status of Endometriosis: Research and Management*. Carnforth, UK: Parthenon Publishing, 1993: 385–95
20. Meyer R. Über den Stand der Frage der Adenomyositis und Adenome im allgemeinen und insbesondere über Adenomyositis seepithelialis und Adenomyometritis sarcomatosa. *Zentralbl Gynäkol* 1919; 43: 745–50
21. Donnez J, Nisolle M, Smoes P, et al. Peritoneal endometriosis and 'endometriotic' nodules of the rectovaginal septum are two different entities. *Fertil Steril* 1996; 66: 362–8
22. Donnez J, Donnez O, Squifflet J, et al. The concept of 'adenomyotic disease of the retroperitoneal space' is born. *Gynaecol Endocrinol* 2001; 10: 91–4
23. Cornillie FJ, Oosterlynck D, Lauweryns JM, et al. Deeply infiltrating pelvic endometriosis: histology and clinical significance. *Fertil Steril* 1990; 53: 978–83
24. Koninckx PR, Martin D. Deep endometriosis: a consequence of infiltration or retraction or possible adenomyosis externa? *Fertil Steril* 1992; 58: 924–8
25. Chapron C, Dubuisson JB. Management of deep endometriosis. *Ann NY Acad Sci* 2001; 943: 276–80
26. Donnez J, Nisolle M, Squifflet J. Ureteral endometriosis: a complication of rectovaginal endometriotic (adenomyotic) nodules. *Fertil Steril* 2002; 77: 32–7
27. Van Langendonck A, Marques De Saft G, Gonzalez D, et al. HOXA-10 and HOXA-13 gene expression in endometriotic nodules of the vaginal septum. *Eur J Obstet Gynaecol Reprod Biol* 2005 123 (Suppl 1): S35
28. Squifflet J, Feger C, Donnez J. Diagnosis and imaging of adenomyotic disease of the retroperitoneal space. *Gynecol Obstet Invest* 2002; 54: 43–51
29. Heilier JF, Nackers F, Verougstraete V, et al. Increased dioxin-like compounds in the serum of women with peritoneal endometriosis and deep endometriotic (adenomyotic) nodules. *Fertil Steril* 2005; 84: 305–12
30. Vercellini P, Frontino G, Pietropaolo G, et al. Deep endometriosis: definition, pathogenesis, and clinical management. *J Am Assoc Gynecol Laparosc* 2004; 11: 153–61
31. Donnez J, Nisolle M, Casanas-Roux F, et al. Stereometric evaluation of peritoneal endometriosis and endometriotic nodules of the rectovaginal septum. *Hum Reprod* 1995; 11: 224–8
32. Anaf V, Simon P, El Nakadi I, et al. Hyperalgesia, nerve infiltration and nerve growth factor expression in deep adenomyotic nodules, peritoneal and ovarian endometriosis. *Hum Reprod* 2002; 17: 1895–900
33. Nakamura M, Katabuchi H, Toya TR, et al. Scanning electron microscopic and immunohistochemical studies of pelvic endometriosis. *Hum Reprod* 1993; 8: 2218–26
34. Donnez J, Nisolle M. L'endométriose péritonéale, le kyste endométriotique ovarien et le nodule de la lame rectovaginale sont trois pathologies différentes [Éditorial]. *Réf Gynécobstét* 1995; 3: 121–3
35. Nisolle M. Peritoneal, ovarian and rectovaginal endometriosis are three distinct entities. Thèse d'Agrégation de l'Enseignement Supérieur. Louvain, Belgium: Université Catholique de Louvain, 1996
36. Haining RE, Cameron IT, Van Pajendorps C, et al. Epidermal growth factor in human endometrium: proliferative effects in culture and immunocytochemical localization in normal and endometriotic tissues. *Hum Reprod* 1991; 6: 1200–5
37. Hiramata Y, Ochiai K. Estrogen and progesterone receptors of the out-of-phase endometrium in female infertile patients. *Fertil Steril* 1995; 63: 984–8
38. Laatikainen T, Andersson B, Karkkainen J, et al. Progesterone receptor levels in endometriomas with delayed or incomplete changes. *Obstet Gynecol* 1983; 62: 592–5
39. Spirtos NY, Yurewicz EC, Moghissi KS, et al. Pseudocorpus luteum insufficiency: a study of cytosol progesterone receptors in human endometrium. *Obstet Gynecol* 1985; 65: 535–40
40. Koninckx PR, Meuleman C, Oosterlynck D, et al. Diagnosis of deep endometriosis by clinical examination during menstruation and plasma CA-125 concentration. *Fertil Steril* 2001; 75: 1042–4

41. Ohba T, Mizutani H, Matsuura K, et al. Transrectal ultrasonographic detection of uterosacral ligaments – preliminary study for ultrasonographic evaluation of endometriosis. *Nippon Sanka Fujinka Gakkai Zasshi* 1992; 44: 1187–8
42. Fedele L, Bianchi S, Rafaelli R, et al. Pre-operative assessment of bladder endometriosis *Hum Reprod* 1997; 12: 2519–52
43. Donnez J, Spada F, Squifflet J, et al. Bladder endometriosis must be considered as bladder adenomyosis. *Fertil Steril* 2000; 74: 1175–81
44. Balleyguier C, Chapron C, Dubuisson JB, et al. Comparison of magnetic resonance imaging and transvaginal ultrasonography in diagnosing bladder endometriosis. *J Am Assoc Gynecol Laparosc* 2002; 9: 15–23
45. Dumontier I, Roseau G, Vincent B, et al. Comparison of endoscopic ultrasound and magnetic resonance imaging in pelvic endometriosis. *Gastroentérol Clin Biol* 2000; 24: 1197–204
46. Kinkel K, Chapron C, Balleyguier C, et al. Magnetic resonance imaging characteristics of deep endometriosis. *Hum Reprod* 1999; 14: 1080–6
47. Chapron C, Liaras E, Fayet P, et al. Magnetic resonance imaging and endometriosis: deeply infiltrating endometriosis does not originate from the rectovaginal septum. *Gynecol Obstet Invest* 2002; 53: 204–8
48. Darai E, Thomassin I, Barranger E, et al. Feasibility and technical outcome of laparoscopic colorectal resection for endometriosis. *Am J Obstet Gynecol* 2005; 192: 394–400
49. Bazot M, Darai E. Sonography and MR imaging for the assessment of deep pelvic endometriosis. *J Minim Invasive Gynecol* 2005; 12: 178–85
50. Delpy R, Barthet M, Gasmi M, et al. Value of endorectal ultrasonography for diagnosing rectovaginal septal endometriosis infiltrating the rectum. *Endoscopy* 2005; 37: 357–61
51. Takeuchi H, Kuwatsuru R, Kitade M, et al. A novel technique using magnetic resonance imaging jelly for evaluation of rectovaginal endometriosis. *Fertil Steril* 2005; 83: 442–7
52. Donnez J. Excision of deep endometriotic nodules by laparoscopy. In Donnez J, ed. *Laser Surgery*. Leuven: Nauwelaerts Printing, 1991: 148
53. Fleisch MC, Xafis D, Bruyne FD, et al. Radical resection of invasive endometriosis with bowel or bladder involvement – long-term results. *Eur J Obstet Gynecol Reprod Biol* 2005; 123: 224–9
54. Chapron C, Chopin N, Borghese B, et al. Surgical management of deeply infiltrating endometriosis: an update. *Ann NY Acad Sci* 2004; 1034: 326–37
55. Emmanuel KR, Davis C. Outcomes and treatment options in rectovaginal endometriosis. *Curr Opin Obstet Gynecol* 2005; 17: 399–402
56. Ford J, English J, Miles WF, Giannopoulos T. A new technique for laparoscopic anterior resection for rectal endometriosis. *JLS* 2005; 9: 73–7
57. Keckstein J, Wiesinger H. The laparoscopic treatment of intestinal endometriosis. In Sutton C, Jones K, Adamson GD, eds. *Modern Management of Endometriosis*. London: Taylor & Francis, 2006: 177–87
58. Donnez J, Nisolle M, Squifflet J, et al. Endoscopic management of peritoneal and ovarian endometriosis. In Donnez J, Nisolle M, eds. *An Atlas of Operative Laparoscopy and Hysteroscopy*, 2nd edn. Carnforth, UK: Parthenon Publishing, 2001: 69–76
59. Donnez J, Nisolle M. Ureteral endometriosis: a complication of rectovaginal adenomyosis. In Donnez J, Nisolle M, eds. *An Atlas of Operative Laparoscopy and Hysteroscopy*, 2nd edn. Carnforth, UK: Parthenon Publishing, 2001: 93–102

akusher-lib.ru

Ureteral endometriosis: a frequent complication of rectovaginal and retrocervical endometriosis

J Donnez, P Jadoul, J Squifflet

This chapter describes one of the two forms of endometriosis involving the urogenital system: ureteral endometriosis.

It should be pointed out that the prevalence of both ureteral and bladder endometriosis (see Chapter 8) has dramatically and significantly increased in recent years. Indeed, ureteral endometriosis should be considered as a complication of rectovaginal endometriosis, also known as rectovaginal adenomyosis or deep endometriosis, the incidence of which has itself greatly increased. According to the findings of one of our last studies, environmental toxicants could be responsible for this increase^{1,2}.

PREVALENCE OF URETERAL ENDOMETRIOSIS IN WOMEN WITH RECTOVAGINAL NODULES

Despite thousands of scientific reports in the literature on endometriosis, its prevalence in the general population is unknown. In women with pelvic pain and/or infertility, a high prevalence, ranging from 20 to 80–90%, has been reported^{3–6}. Endometriosis usually involves the peritoneum, the ovaries or the rectovaginal septum, and three distinct entities have been described⁶.

Ureteral endometriosis is relatively uncommon, and was previously estimated to occur in just 0.08–1% of patients with endometriosis^{7,8}. The prevalence of 1% observed in the study by Nezhat *et al.*⁸ was actually considered to be somewhat overestimated according to Donnez and Brosens⁹, who observed only six cases in a series of 6285 patients (0.1%).

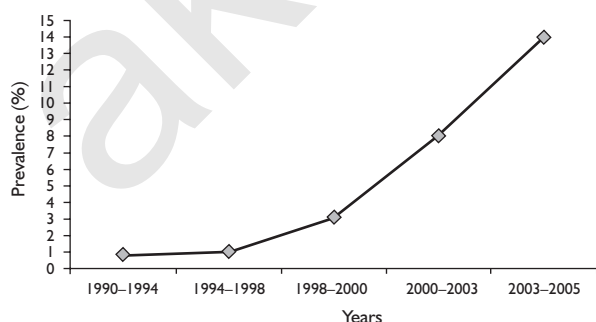


Figure 7.1 Increasing prevalence of ureteral lesions caused by large (>3 cm) deep endometriotic (adenomyotic) nodules

A distinction must be made between extrinsic and intrinsic ureteral endometriosis^{10,11}. Indeed, intrinsic ureteral endometriosis, characterized by the presence of endometriotic glands and stroma in the ureteral wall, is a very rare entity. However, extrinsic ureteral endometriosis, caused by extraureteral disease, is more frequent.

It was suggested in 1997 that uropathy was frequently associated with rectovaginal adenomyosis⁹. Since then, the prevalence of the disease has soared, and an incidence of 10% was reported in nodules of more than 3 cm in size in a previous study¹². It is now evaluated as being as high as 14% (Figure 7.1).

The late consequence of ureteral endometriosis is the silent loss of renal function caused by the progressive ‘enclosure’ of the lower part of the ureter by adenomyosis.

The prevalence of ureteral lesions was prospectively evaluated in a series of 306 patients treated for rectovaginal adenomyotic nodules between March 1998 and July 2000, and published in *Fertility and Sterility*¹². The patients were classified according to the size of the nodule (<2 cm; >2 cm but <3 cm; >3 cm). The size of the nodule was evaluated by palpation of the posterior fornix of the vagina during vaginal examination and vaginal echography. Intravenous pyelography (IVP) was performed in all patients prior to surgery. Care was taken to analyze the lower segment of the ureter. Stenosis was judged to be partial or complete (Figure 7.2). The degree of ureterohydronephrosis was evaluated according to the ureteral diameter.

In this series of 306 cases of rectovaginal adenomyosis, ureteral endometriosis was encountered in 14 of them. The prevalence was thus 4.5% in our prospective study. Classification of patients was carried out according to the size of the rectovaginal adenomyotic nodule (Table 7.1). A significantly ($p < 0.05$) higher prevalence of ureteral endometriosis (11.2%) was observed in patients with rectovaginal adenomyotic nodules of more than 3 cm in size than in patients with smaller nodules (<2 cm, 0%; >2 but <3 cm, 0.8%).

So far, the number of ureteral endometriosis cases treated surgically in our department has reached 78. In this chapter, we describe the technique and report the results.

SYMPTOMS AND DIAGNOSIS

In our series of 78 cases of ureteral endometriosis (Table 7.2), severe dysmenorrhea and/or deep dyspareunia was experienced by all patients, but only two patients, with

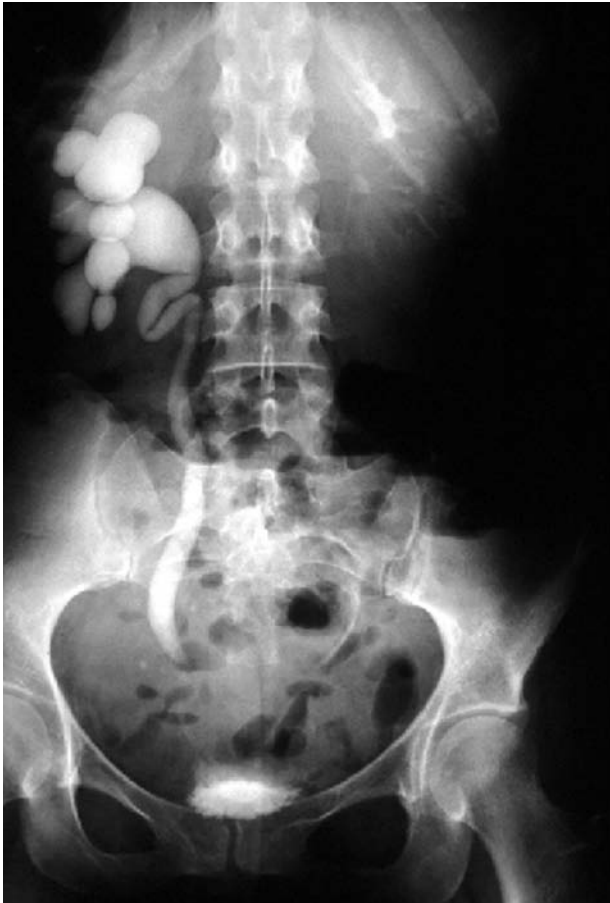

Figure 7.2 Intravenous pyelogram (IVP): complete stenosis with subsequent cortical atrophy

ureterohydronephrosis, complained of typical pain due to obstructive uropathy.

Isolated ureteral endometriosis was never noted; it was always associated with rectovaginal adenomyosis, and ovarian endometriomas were sometimes observed on the ipsilateral side. Ureteral stenosis was not localized where the ovarian endometriomas adhered to the broad ligament,

although in some cases lateral extension of deep lesions can involve the retroperitoneal space up to the ovary and the sigmoid, forming a peritoneal ‘plastron’.

All the women underwent rectovaginal adenomyotic nodule removal during the same procedure, without segmental bowel resection. In six patients, ureteral endometriosis was found to be associated with bladder endometriosis and a rectovaginal adenomyotic nodule.

Kidney scintigraphy (Tc99-DMSA (dimercaptosuccinic acid)) was performed pre- and postoperatively in nine patients with severe pyelic dilatation and cortical atrophy (Figure 7.3). The association of complete ureterolysis and administration of gonadotropin-releasing hormone analog therapy for 3 months led to a significant recovery of ureteral diameter. However, postoperative kidney scintigraphy revealed only a slight improvement in renal function, so laparoscopic nephrectomy was carried out in all nine cases.

OPERATIVE SURGERY

So far, 78 cases of ureteral endometriosis have been operated on in our department. In all cases but three, conservative surgery without ureteral resection was performed by laparoscopy. Three suprapubic trocars (5 mm; Storz, Tuttlingen, Germany) were placed to insert instruments for the laparoscopic procedure. A CO₂ laser or scissors could be used for dissection of the bowel and removal of the adenomyotic lesion and vaginal pouch in the case of rectovaginal adenomyotic nodules, as previously described^{13,14}. In all cases, ureterolysis was performed before adenomyotic nodule resection. The peritoneum covering the ureter was opened where the ureter was free of adhesions and clearly visible (Figure 7.4). The dissection was progressively made in the direction of the uterosacral ligament. The ureter was freed from the surrounding tissue. To facilitate this step of the procedure, a JJ stent was inserted retrogradely by cystoscopy, just before surgery, in 48 cases (62%).

Table 7.1 Incidence of ureteral endometriosis according to the size of the rectovaginal adenomyotic nodule (prospective study of 306 patients). From reference 12, with permission

Rectovaginal adenomyotic nodule size (cm)	Number of patients	Number of patients with ureteral endometriosis	Prevalence of ureteral endometriosis (%)
<2	71	0	0
>2 and <3	119	1	0.8
>3	116	13	11.2*
Total	306	14	4.5

*The prevalence of ureteral endometriosis is significantly higher in this group of patients than in the other groups ($p < 0.05$)

Table 7.2 Cases of ureteral stenosis and substenosis necessitating ureterolysis ($n = 78$)

Symptoms	
associated with deep rectovaginal endometriosis	78 (100%)
associated with bladder endometriosis	6 (7.7%)
only left	38 (48.7%)
only right	16 (20.5%)
bilateral	24 (30.8%)
Conservative surgery	
without ureteral resection	75 (96%)
with ureteral resection	3 (4%)
Non-reversible cortical atrophy* (renal function < 15%, TC99-DMSA)	9 (11%)

*In these nine cases, laparoscopic nephrectomy was performed; DMSA, dimercaptosuccinic acid

In 49 cases (63%), voluntary section of the uterine artery was performed on at least one side, using titanium clips, which were placed on the uterine artery crossing the lowest part of the ureter (Figure 7.5). This procedure allowed the ureter to be freed up to its lowest point. At the end of the procedure, the ureter was free of disease in all cases (Figure 7.6).

After ureterolysis, a fibrotic stenotic ring responsible for the ureteral stricture was sometimes visible (Figure 7.7a). It was removed by careful dissection, without opening the ureteral lumen (Figure 7.7b). The adventitial sheath could be cut, but the medial muscular layer was respected as far as possible (Figure 7.7c).

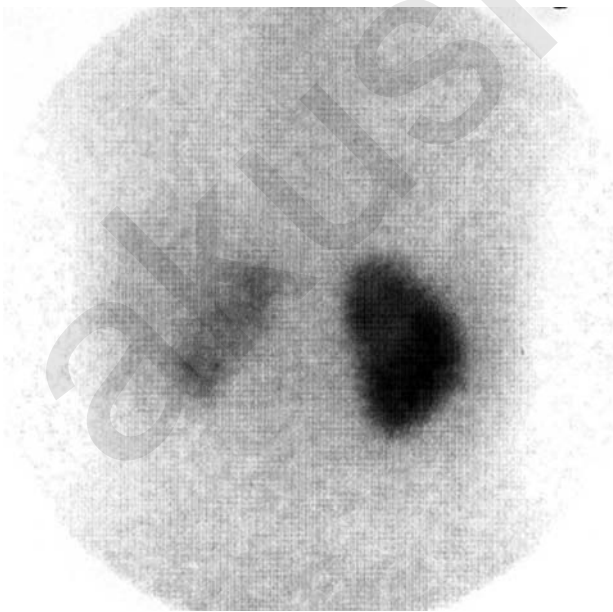


Figure 7.3 Kidney scintigraphy (Tc99-DMSA (dimercaptosuccinic acid)) demonstrates significantly decreased renal function (17% in this case)

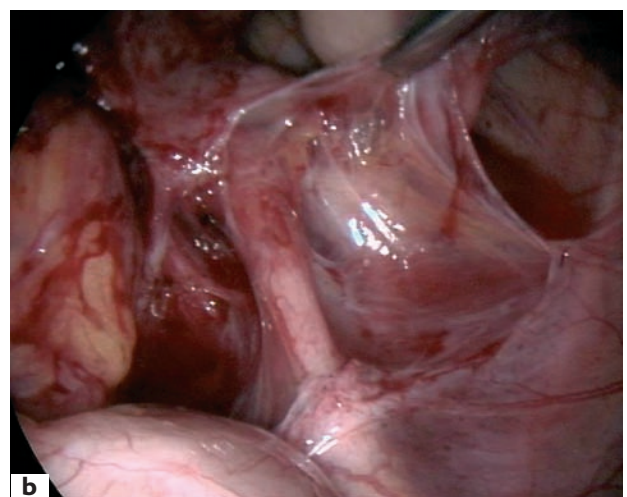
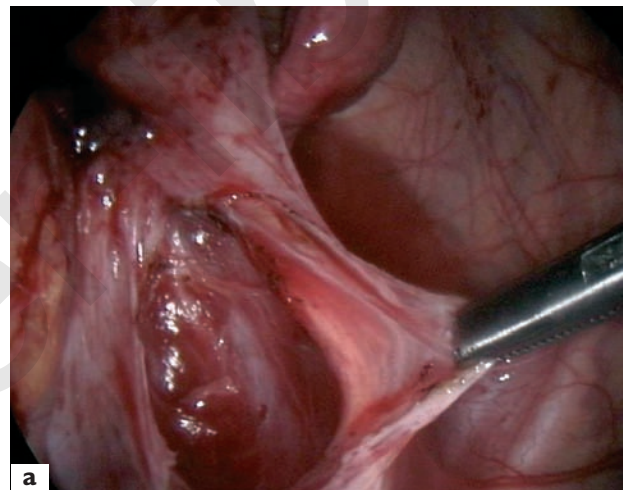


Figure 7.4 (a) and (b) Dissection of the ureter starts by opening the peritoneum covering the ureter, where the ureter is free of adhesions and clearly visible

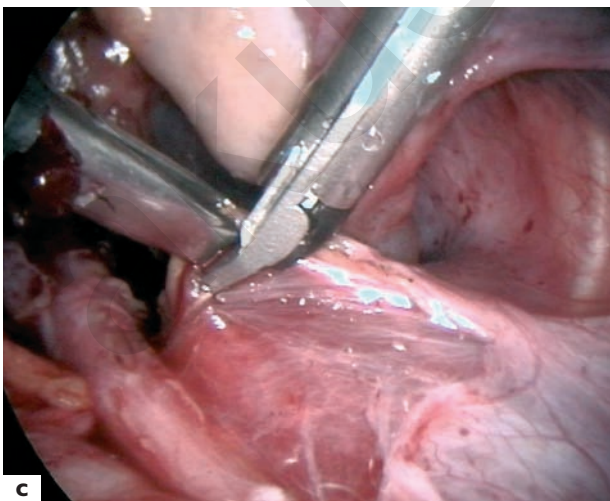
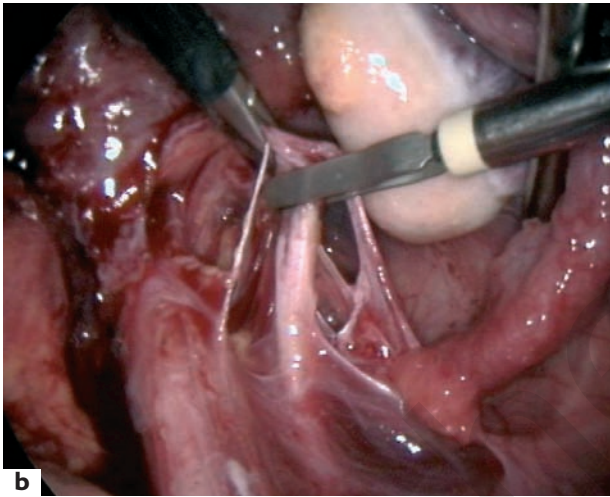
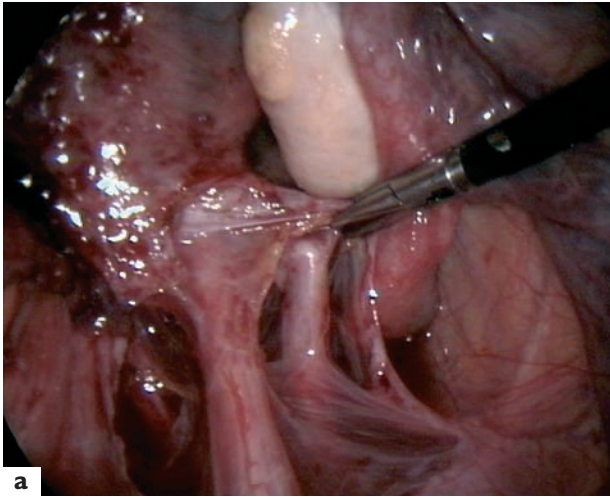


Figure 7.5 (a) Dissection is progressively made in the direction of the uterosacral ligament. Coagulation (b) and ligation (c) of the uterine artery

When partial ureteral resection was required (because of the presence of complete stenosis of more than 3 cm in length), laparotomy with ureteroureterostomy and bladder surgery was carried out. Between 1992 and 2004, this occurred in just three cases, and resection and reimplantation were performed using the psoas hitch technique. This means that, in total, 75 cases (96%) of ureteral endometriosis were conservatively treated by laparoscopy.

In patients who underwent preoperative or intraoperative retrograde stent placement, the catheter was left in place for 1–3 months, depending on the severity of the disease. After that period, the JJ stent was removed, and IVP demonstrated the absence of any ureteral stricture.

DISCUSSION

In the past, ureteral endometriosis was uncommon, accounting for less than 0.3% of all endometriotic lesions.

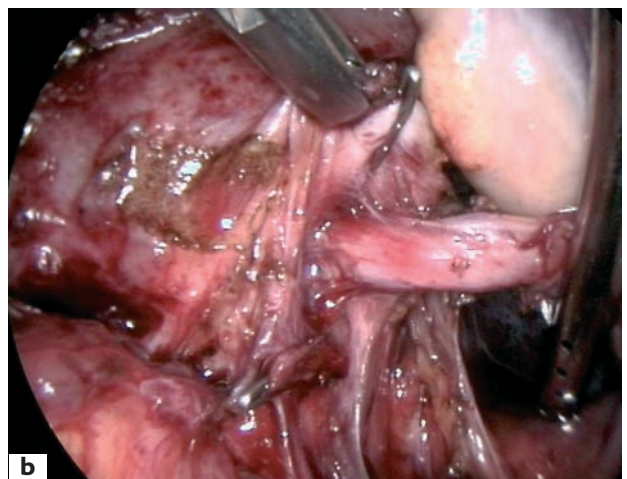
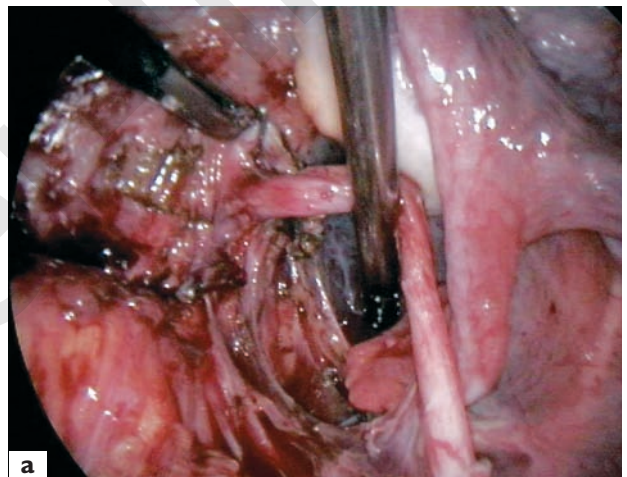


Figure 7.6 (a) and (b) At the end of dissection, the ureter is free of disease

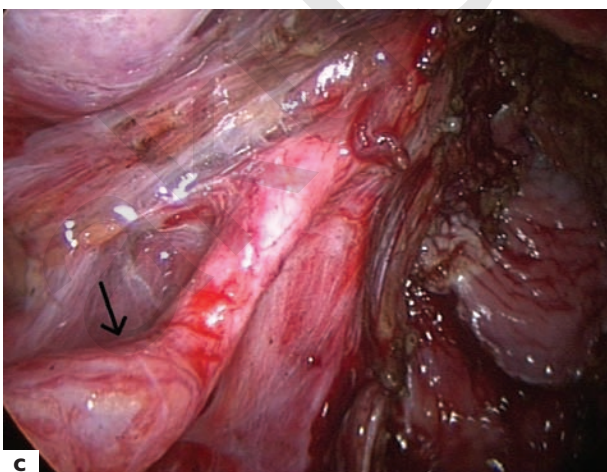
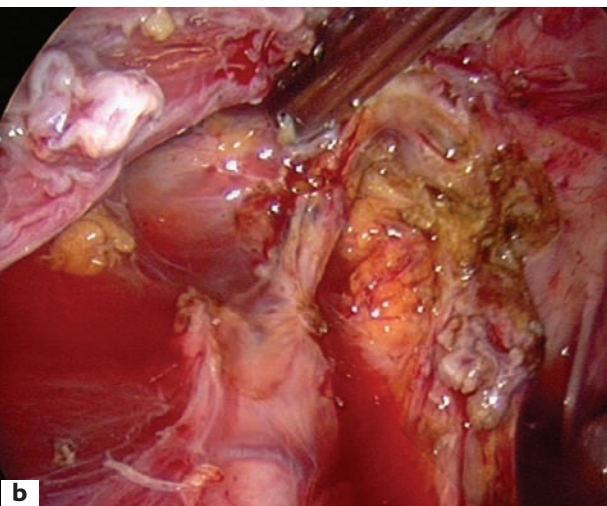
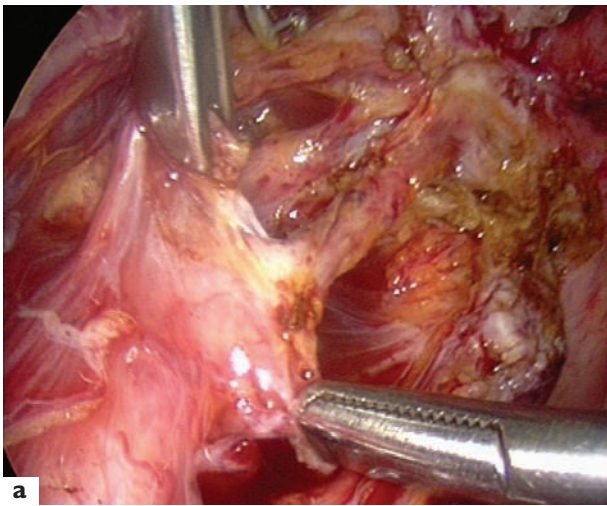


Figure 7.7 (a) The ureteral fibrotic ring, responsible for ureteral stenosis and dilatation, is grasped with forceps; (b) ureteral ring dissection; (c) after dissection, the ureter is free. The ureteral dilatation (arrow) is still visible

Now, its prevalence has reached almost 14% in the case of large (≥ 3 cm), deep, rectovaginal nodules. Ureteral lesions have thus become much more frequent in recent times, and they are a very serious condition because they may cause silent loss of renal function.

There are two types of ureteral endometriosis, extrinsic and intrinsic⁹⁻¹¹. Intrinsic ureteral obstruction is characterized by the presence of endometriotic glands and stroma in the ureteral wall, due to primary endometriotic involvement of the ureteral wall. This type of ureteral endometriosis is less common, however, than ureteral obstruction, caused by external compression by surrounding endometriosis, which is known as extrinsic ureteral endometriosis. According to Donnez *et al.*¹², endometriosis of the ureter usually arises by extension from deep endometriotic (adenomyotic) nodules, or, more rarely, from adhesions with ovarian endometriosis.

Prevalence

Indeed, in a retrospective study from 1988 to 1997, the prevalence of ureteral endometriosis was estimated to be less than 0.1% in cases of endometriosis⁹. In women suffering from rectovaginal adenomyosis, it was found to be 0.9% (6/711). In a prospective study from 1998 to 2000, however, the prevalence was 4.5% in a series of 306 cases of rectovaginal endometriosis or adenomyosis. The latest findings (2005) point to an incidence as high as 14%. The dramatically increasing prevalence of ureteral endometriosis is directly related to the increasing prevalence of severe deep endometriosis, and this must be emphasized.

Surrounding endometriotic lesions responsible for external ureteral compression, without histological evidence of endometriotic glands and stroma in the ureteral wall, are thus mostly the consequence of lateral extension of rectovaginal adenomyotic nodules. These patients also showed other localizations of endometriosis, but ovarian endometriomas were rarely considered solely responsible for ureteral endometriosis, as they were always associated with rectovaginal adenomyosis.

The concept of adenomyosis of the retroperitoneal space should therefore cover not only the rectovaginal space and the vesicovaginal space, but also the area extending laterally in the direction of the cardinal ligaments¹¹⁻¹⁶. Deep endometriotic (adenomyotic) nodules should be considered as a benign cancer originating from the posterior part of the cervix, which spreads laterally like cervical cancer.

Left or right?

In a large review of the literature on retrospective series of ureteral endometriosis, the proportion of lesions located on the left was found to be significantly higher than on the right¹⁷. In one of our previous studies, a higher proportion was also found on the left, but the difference was not

significant, the prevalence being 3% and 2%, respectively. In the series of Nezhat *et al.*, a non-significant difference in the prevalence of ureteral endometriosis was also observed between the left and right sides⁸. In our present study, bilateral ureteral anomalies (medialization, lumen irregularities, substenosis or stenosis) were observed in 24 cases. In this large series, a significantly higher proportion of ureteral lesions were found on the left (48.7%) than on the right side (20.5%). The difference was significant ($p < 0.05$) in this series.

In a publication by Vercellini *et al.*¹⁷, six cases of ureteral endometriosis were described as being associated with ovarian endometriomas. In the opinion of the authors, however, neither the celomic metaplasia theory, nor the embryonic cell rest theory, could explain such a clear-cut difference in the frequency of the distribution of ovarian and ureteral lesions between the two pelvic sites. On the contrary, in our study, adenomyotic disease of the retroperitoneal space, originating from metaplasia of the cervix, was obviously the cause of extrinsic ureteral endometriosis, proved by clinical examination and histological serial sections.

Techniques

In 1996, Nezhat *et al.* described a series of 17 cases of partial ureteral obstruction⁸. Laparoscopic ureterolysis was performed in ten women, but seven of the 17 women (41%) required partial wall resection. They also reported use of the laparoscopic psoas hitch procedure for infiltrative ureteral endometriosis, to obtain tension-free anastomosis of the bladder^{18,19}. A report described one case of recurrent ureteral endometriosis after partial laparoscopic ureteral resection and ureteroneocystostomy. This approach should be considered only in a case of intrinsic ureteral endometriosis involving a long segment of the ureter, to avoid laparotomy.

According to our results, conservative surgery should be proposed in the majority of patients. We do not agree with Yohannes²⁰, who recommend first hormonal treatment and surgery only in the case of the failure of hormonal treatment or severe stenosis. Indeed, even severe ureteral stenosis usually remains asymptomatic²¹, and a delay in efficient therapy may result in the loss of a kidney. Therefore, we recommend performing laparoscopic ureterolysis and removal of the adenomyotic lesions responsible for the ureteral stenosis, even in the case of moderate or severe pyelic dilatation. In the majority of cases, ureteral dissection, with or without uterine artery ligation, is sufficient to free the ureter. In all cases, ureterohydronephrosis was found to be decreased after this procedure. Resection of part of the ureter should only be performed in exceptional cases (4% in our series) or in the case of recurrence. Partial ureteral resection and ureteroneocystostomy can be performed by laparoscopy^{19,22}.

In conclusion, obstructive uropathy is more frequently provoked by 'extrinsic' rather than 'intrinsic' endometriosis.

The approximate ratio of four cases of extrinsic to one case of intrinsic disease, as previously described, has to be re-evaluated according to our study⁸. Obstructive uropathy should be suspected in patients with a rectovaginal adenomyotic nodule of more than 3 cm, because of its high prevalence in such cases. In this group of patients, there is a need to perform non-invasive urinary tract exploration to detect obstructive uropathy and prevent silent loss of renal function, which necessitated nephrectomy in 11% of cases in our series.

Conservative surgery with relief of the ureteral obstruction and the removal of adenomyosis or endometriosis should be the management of choice.

REFERENCES

1. Heilier JF, Ha A-T, Lison D, et al. Increased serum PCB levels in Belgian women with adenomyotic nodules of rectovaginal septum. *Fertil Steril* 2004; 81: 456–8
2. Heilier JF, Nackers F, Verougstraete V, et al. Increased dioxin-like compounds in the serum of women with peritoneal endometriosis and deep endometriotic (adenomyotic) nodules. *Fertil Steril* 2005; 84: 305–12
3. Donnez J, Thomas K. Incidence of the luteinized unruptured follicle syndrome in fertile women and in women with endometriosis. *Eur J Obstet Gynecol Reprod Biol* 1982; 14: 187–90
4. Strathy JH, Molgaard GA, Coulam CB, et al. Endometriosis and infertility: a laparoscopic study of endometriosis among fertile and infertile women. *Fertil Steril* 1982; 38: 667–72
5. Haney AF. Endometriosis: pathogenesis and pathophysiology. In Wilson EA, ed. *Endometriosis*. New York: Alan R Liss, 1987: 23–51
6. Nisolle M, Donnez J. Peritoneal endometriosis, ovarian endometriosis and adenomyotic nodules of the rectovaginal septum are three different entities. *Fertil Steril* 1997; 68: 585–96
7. Stillwell TJ, Kramer SAZ, Lee RA. Endometriosis of the ureter. *Urology* 1986; 26: 81–5
8. Nezhat C, Nezhat F, Nezhat C, et al. Urinary tract endometriosis treated by laparoscopy. *Fertil Steril* 1996; 66: 920–4
9. Donnez J, Brosens I. Definition of ureteral endometriosis? *Fertil Steril* 1997; 68: 178–9
10. Donnez J, Nisolle M, Casanas-Roux F. Endometriosis: rationale for surgery. In Donnez J, Nisolle M, eds. *An Atlas of Laser Operative Laparoscopy and Hysteroscopy*. Carnforth, UK: Parthenon Publishing, 1994: 53–62
11. Clement PB. Disease of the peritoneum. In Kurman RJ, ed. *Blaustein's Pathology of the Female Genital Tract*. New York: Springer-Verlag, 1994: 647–703
12. Donnez J, Nisolle M, Squifflet J. Ureteral endometriosis: a complication of rectovaginal endometriotic (adenomyotic) nodules. *Fertil Steril* 2002; 77: 32–7

13. Donnez J, Nisolle M, Casanas-Roux F, et al. Rectovaginal septum endometriosis or adenomyosis: laparoscopic management in a series of 231 patients. *Hum Reprod* 1995; 10: 630–5
14. Donnez J, Nisolle M, Gillerot S, et al. Rectovaginal septum adenomyotic nodules: a series of 500 cases. *Br J Obstet Gynaecol* 1997; 104: 1014–18
15. Donnez J, Spada F, Squifflet J, et al. Bladder endometriosis must be considered as bladder adenomyosis. *Fertil Steril* 2000; 74: 1175–81
16. Donnez J, Nisolle M, Casanas-Roux F, et al. Endometriosis: rationale for surgery. In Brosens I, Donnez J, eds. *Current Status of Endometriosis. Research and Management*. Carnforth, UK: Parthenon Publishing, 1993: 385–95
17. Vercellini P, Pisacreta A, Pesole A, et al. Is ureteral endometriosis an asymmetric disease? *Br J Obstet Gynaecol* 2000; 107: 559–61
18. Nezhat C, Nezhat F, Freiha F, et al. Laparoscopic vesicopsoas hitch for infiltrative ureteral endometriosis. *Fertil Steril* 1999; 71: 376–9
19. Nezhat CH, Malik S, Nezhat F, et al. Laparoscopic ureteroneocystostomy and vesicopsoas hitch for infiltrative endometriosis. *JSLs* 2004; 8: 3–7
20. Yohannes P. Ureteral endometriosis. *J Urol* 2003; 170: 20–5
21. Antonelli A, Simeone C, Frego E, et al. Surgical treatment of ureteral obstruction from endometriosis: our experience with thirteen cases. *Int Urogynecol J Pelvic Floor Dysfunct* 2004; 15: 407–12
22. Ou CS, Huang IA, Rowbotham R. Laparoscopic ureteroureteral anastomosis for repair of ureteral injury involving stricture. *Int Urogynecol J Pelvic Floor Dysfunct* 2005; 16: 155–7

akusher-lib.ru

Bladder endometriosis

J Donnez, J Squifflet, O Donnez, P Jadoul

Although endometriosis is frequently encountered in females of reproductive age¹, bladder endometriosis is relatively rare, representing less than 1% of all endometriosis cases. One must take particular care, however, to define bladder endometriosis clearly as full-thickness detrusor lesions. Indeed, small implants and small nodules of the vesicouterine fornix cannot be considered as bladder endometriosis.

The condition was first described by Judd² in 1921, and a review of 200 cases was published in 1980³. In the literature, two distinct forms appear to exist: one is found in women without any medical history of uterine surgery (primary), while the other develops after cesarean section (iatrogenic or secondary)⁴.

We published the largest series in 2000⁵, and suggested strongly that bladder endometriosis should be considered as the consequence of metaplasia of the cervix and not the result of infiltration by peritoneal endometriosis, as previously proposed. In this chapter, a series of 51 cases of bladder endometriosis is presented.

PREVALENCE

The prevalence of this type of lesion has increased dramatically in recent years. Indeed, between January 1995 and August 2005, 51 women aged 21–28 years underwent laparoscopy for bladder endometriosis in our department. In this series, about 6% of women with bladder endometriosis had undergone cesarean section, a much lower rate than the previously published 25%⁵. The explanation for this is probably the significant increase in vesical adenomyotic nodules due to environmental toxicants, as has been observed for rectovaginal nodules⁶.

It is important to underline the fact that only full-thickness detrusor lesions (Figures 8.1 and 8.2) were taken into consideration, and small subperitoneal nodules or implants of the anterior cul-de-sac were excluded.

SYMPTOMS

Women suffering from bladder endometriosis (adenomyotic nodules) present with a variety of symptoms, most frequently menstrual mictalgia, recurrent cystitis or pollakiuria, usually limited to the menstrual period. In our series, no germs could be isolated from urine culture, even after several days. Dysmenorrhea and dyspareunia were also experienced by 88% of women (Table 8.1). This was

due to the fact that bladder endometriotic nodules are frequently associated with rectovaginal nodules. Indeed, concomitant bladder and rectovaginal adenomyotic nodules were found in 33 of the 51 cases in our series (65%). Only 6% reported gross hematuria during menstruation, which was confirmed by microscopic analysis that failed to determine hematuria in all other cases.

DIAGNOSIS

The diagnosis of bladder endometriosis can often be made by vaginal examination. In fact, in our series, a tender

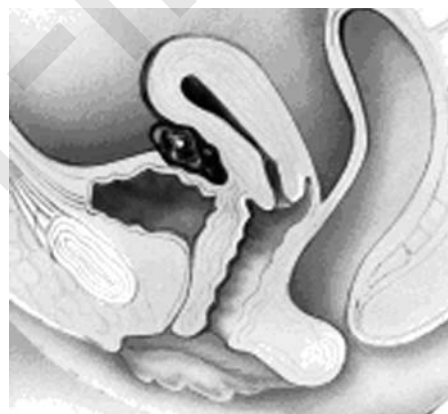

Figure 8.1 Bladder endometriotic nodule: the nodule in the anterior fornix strictly adheres to the bladder and uterus

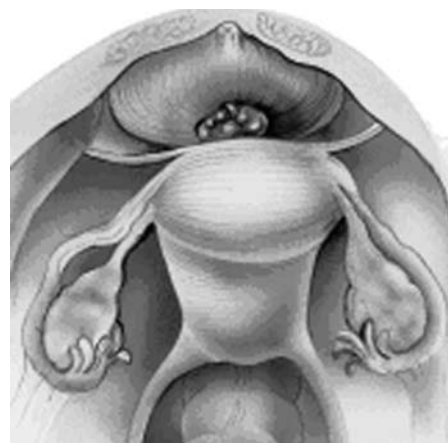


Figure 8.2 Diagram of laparoscopic view: note the attraction of the round ligaments to the bladder nodule

Table 8.1 Symptoms related to bladder endometriosis in our series of 51 patients

Menstrual mictalgia (or recurrent cystitis in the premenstrual period)	49 (96%)
Dyspareunia, dysmenorrhea	45 (88%)
Menstrual hematuria	3 (6%)
Pelvic examination (palpation of a tender nodule in the uterovesical pouch)	49 (96%)
Size of nodule	
< 2 cm	1(0.2%)
2–3 cm	17(33.3%)
3–4 cm	25(49%)
> 4 cm	8(15.7%)

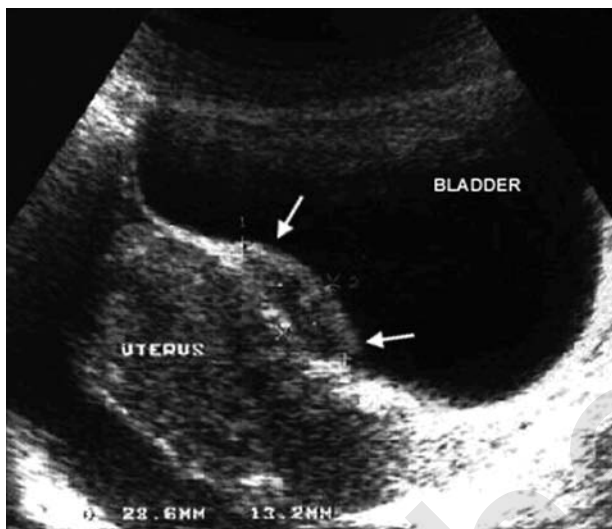


Figure 8.3 Abdominal echography: regular heterogeneous, hypoechoic nodule is clearly visible in the vesicular muscularis protruding into the bladder cavity. In the majority of cases, there is no mucosal involvement

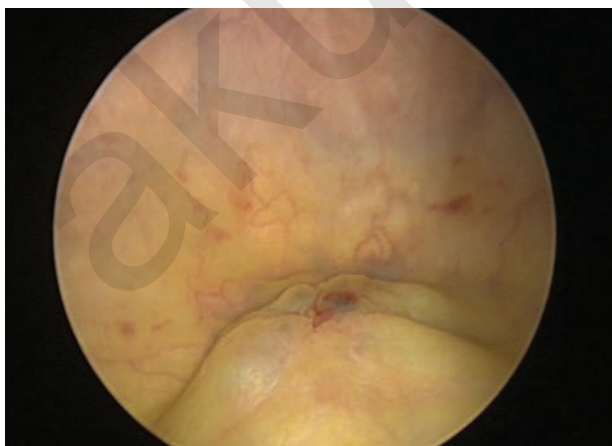

Figure 8.4 Cystoscopy: protruding bluish nodule is clearly visible in the posterior bladder wall with an intact vesical mucosa

nodule could be palpated in the anterior fornix of the vagina in all cases, and abdominal ultrasonography confirmed the presence of a regular heterogeneous hypoechoic nodule of the uterovesical septum (Figure 8.3), showing an association between the endometriotic nodule and the anterior uterine wall.

Cystoscopy was always performed as part of the preoperative assessment. In all patients but two, a protruded mass of the posterior bladder wall was visible at the level of the fundus or trigone. It showed a typical bluish or brownish nodule, sometimes with papular lesions (Figure 8.4). In two patients, the mucosa was intact and the nodule was located entirely in the muscularis.

Intravenous pyelography (IVP) demonstrated the typical aspect of an extravescical nodule in all cases, revealed by a filling defect in the upper part of the bladder (even in the two cases where the mucosa was intact). The vesical filling defect was more obvious on the profile image (Figure 8.5).

Magnetic resonance imaging (MRI) should be performed in all patients. In our series, MRI excluded the presence of associated uterine adenomyosis and clearly revealed the presence of a nodular mass in the anterior fornix adjacent to the uterine wall, provoking extensive compression of the posterior bladder wall (Figure 8.6). Characteristics of adenomyotic tissue were clearly observed in T2 images. MRI also has the added advantage, over ultrasonography, of being able to diagnose small lesions of associated posterior deep endometriotic lesions⁷.

SURGICAL TECHNIQUE

After classic transumbilical insufflation with a Verres needle, the peritoneal cavity was entered by means of a 12-mm umbilical trocar connected to a 12-mm laser laparoscope (Storz, Tuttlingen, Germany)⁸. Three other suprapubic trocars of 5 mm were also introduced. The first step was to check the uterus, the pouch of Douglas and the peritoneum for other endometriotic lesions. If minimal peritoneal or ovarian endometriosis was found, it was

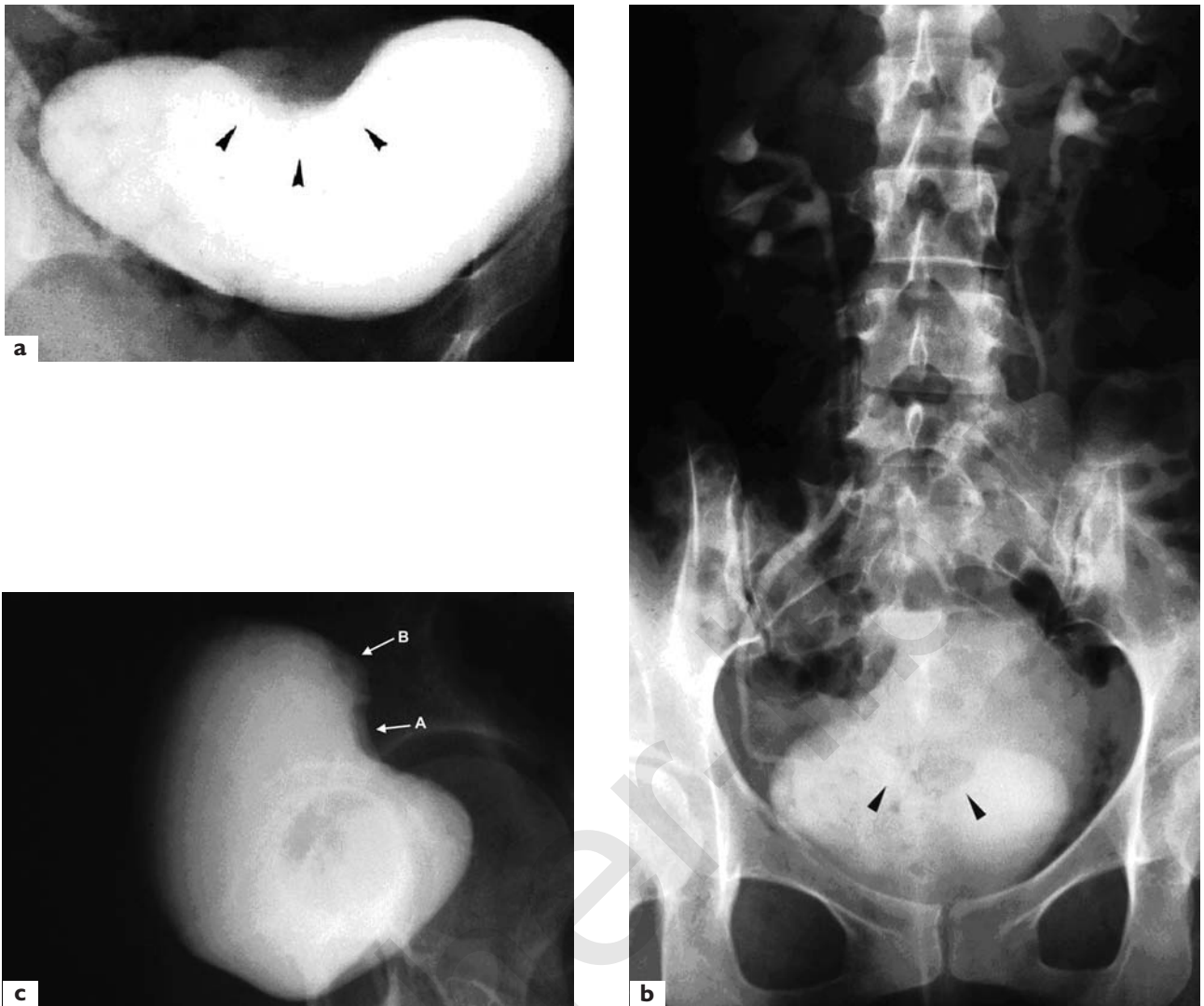

Figure 8.5 (a) Intravenous pyelography demonstrates the typical aspect of an 'extravesical nodule' (arrowheads), revealed by a filling defect. (b) Note the absence of ureterohydronephrosis. (c) Profile image: the bladder filling defect due to the nodule (A) must be distinguished from the normal filling defect due to an anteverted uterus (B)

immediately vaporized. In 65% of cases, a rectovaginal adenomyotic nodule was found to be associated. In these cases, the rectovaginal adenomyotic nodule was removed and the associated peritoneal and/or ovarian lesions were vaporized.

The second step was to check the vesicouterine fornix to confirm the presence of a bladder adenomyotic nodule by retroflexing the uterus with a uterine cannula. Grasping forceps were then introduced through the suprapubic trocars to expose the lesion correctly for dissection. Both round ligaments were systematically medially attached (Figure 8.7). This represents an important laparoscopic sign; in the technique we describe, they are coagulated and sectioned. Deep nodular lesions involving the vesical muscularis required excision of the nodular tissue from the anterior uterine wall. Attention was first directed towards

achieving complete dissection of the uterine wall throughout its area of attachment or involvement until the loose tissue of the vesical space was reached.

This could be done by cutting this area of attachment with a CO₂ laser or using coagulation and scissors, while the uterus was retroflexed and the bladder pulled up by grasping forceps. The peritoneum covering the bladder was opened. By gentle traction, the plane of dissection between the fibrotic nodular tissue and the normal vesical muscularis was exposed, and resection of the nodule was easily carried out, staying as far away as possible from the ureteral insertions (Figure 8.8).

At the end of surgery, the vesical muscularis was closed with stitches (Vicryl® 2-0), the technique depending on the size of the muscularis defect. Either separate stitches or a running suture was performed (Figure 8.9). Finally, a

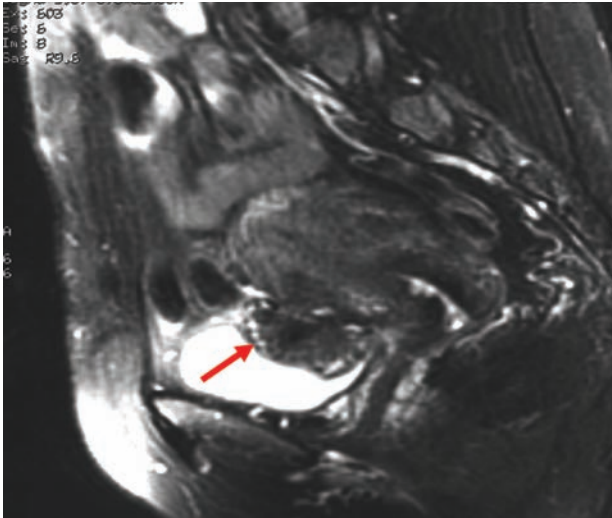


Figure 8.6 Magnetic resonance imaging shows a nodular mass in the anterior fornix adjacent to the uterine wall (arrow), causing extensive compression of the posterior bladder wall (note the absence of concomitant uterine adenomyosis): sagittal image

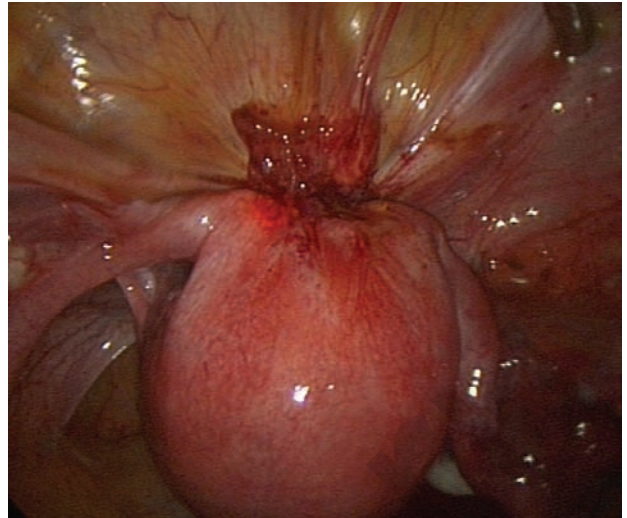
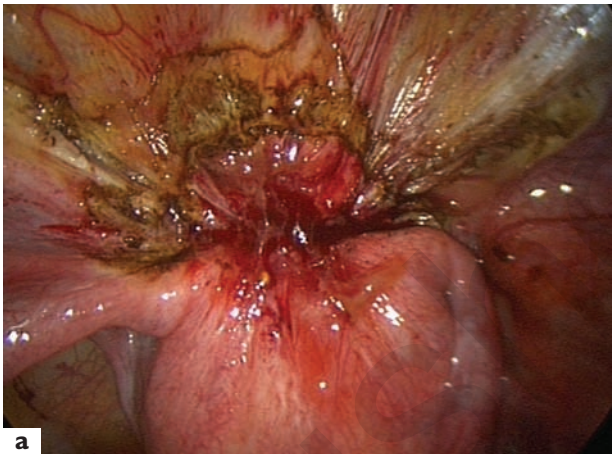
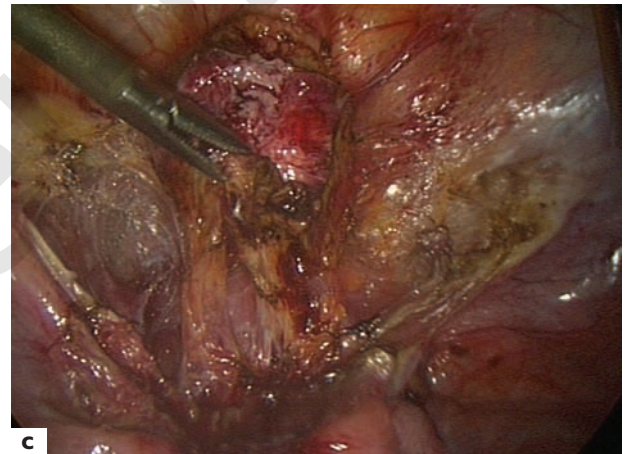
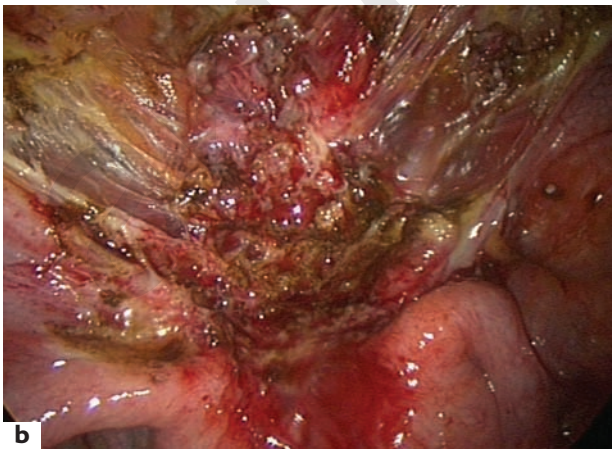Figure 8.7 First laparoscopic view of the bladder adenomyotic nodule. Both round ligaments are systematically medially attached



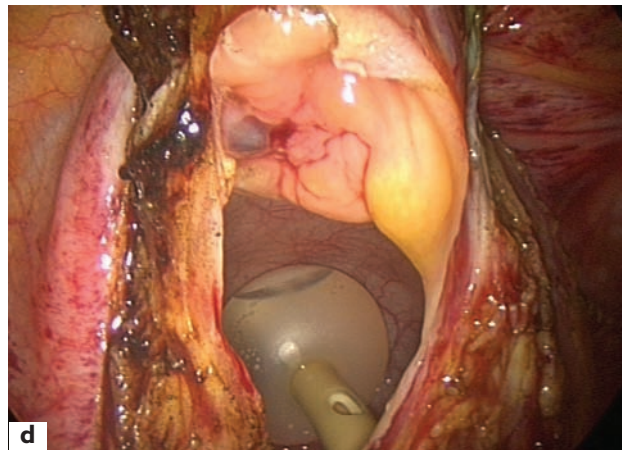
a



c



b



d

Figure 8.8 Laparoscopic excision of the nodule. (a) Incision of the peritoneum; (b) dissection of the nodule from the anterior wall of the uterus; (c) the nodule is grasped by forceps; (d) the bladder is opened and the submucosal bluish nodule is visualized in the bladder;

diluted methylene blue solution was injected, to ensure watertightness of the sutures.

In some cases, a control cystoscopy was carried out to check the bladder defect closure. In all cases, retrograde cystography was performed 10 days postoperatively to confirm complete recovery of the bladder wall and to exclude any liquid leakage.

The bladder catheter was left in place for 10 days.

In our series, no long-term complications, such as vesical fistulas, were encountered.

HISTOLOGY

Serial sections were obtained and colored with hematoxylin–eosin, or analyzed to evaluate steroid receptor (estrogen and progesterone) content according to a previously described method⁹. On microscopic examination (Figure 8.10), the lesion was characterized by the presence of scarce glands, with active endometrial-type epithelium and scanty stroma. No secretory changes were observed, even when the patient was undergoing

progesterone therapy or during the luteal phase. More than 90% of the lesion consisted of smooth-muscle hyperplasia. The bladder nodule was localized throughout the whole thickness of the bladder wall. By serial section, we were able to demonstrate that endometrial glands were not connected to the peritoneal serosa but were almost in the subperitoneal space, again proving that a bladder endometriotic nodule is not the consequence of deep-infiltrating endometriosis.

RESULTS AND DISCUSSION

Several authors have described two types of bladder endometriosis, the first occurring in women who have not previously undergone any uterine surgery (primary) and the second following cesarean section (iatrogenic or secondary)^{10,11}.

Koninckx and Martin¹² suggested that extraperitoneal endometriosis derives from endoperitoneal disease. In the opinion of Vercellini *et al.*^{10,13,14}, peritoneal lesions are able to penetrate under the peritoneum and develop into deep-

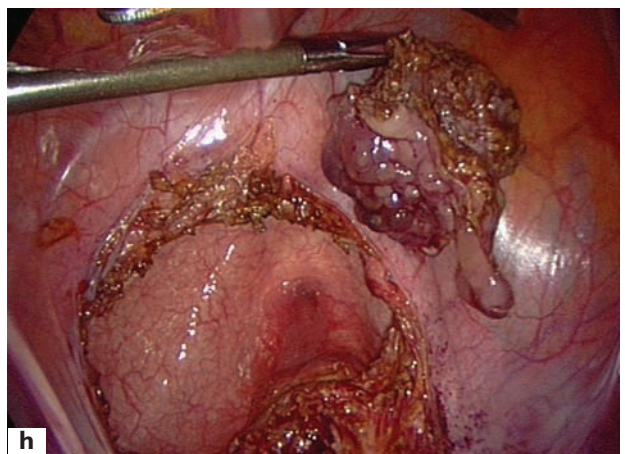
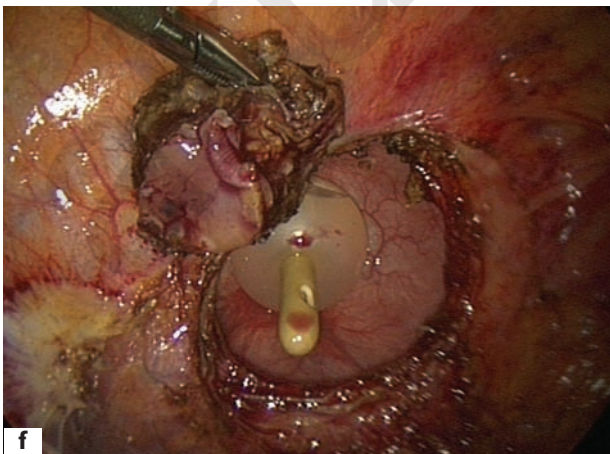
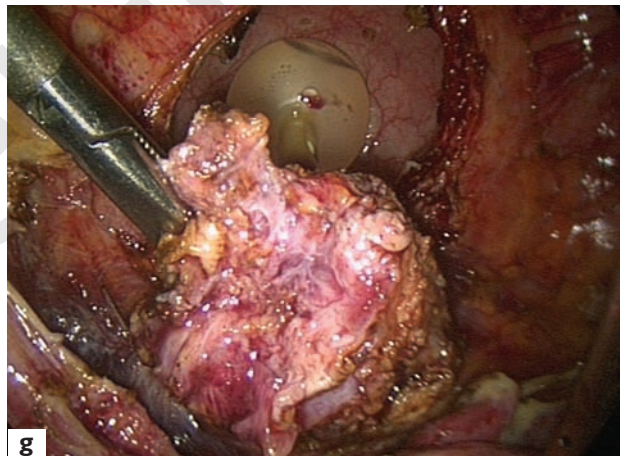
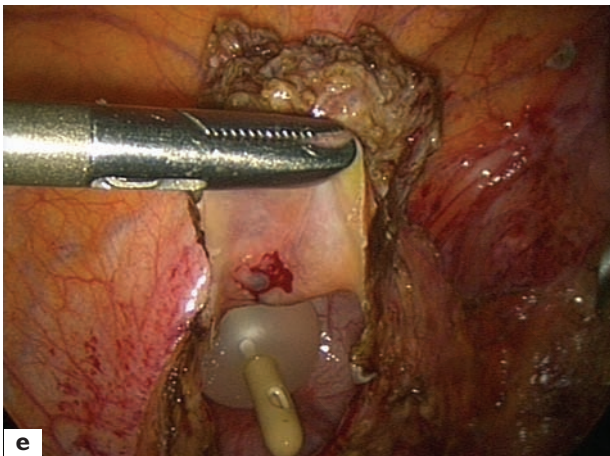


Figure 8.8 continued (e) note the thickness of the nodule caused by hyperplasia of the bladder muscularis; (f) resected nodule (bladder mucosa side); (g) resected nodule (uterine side); (h) bladder defect after nodule resection can reach 5–6 cm

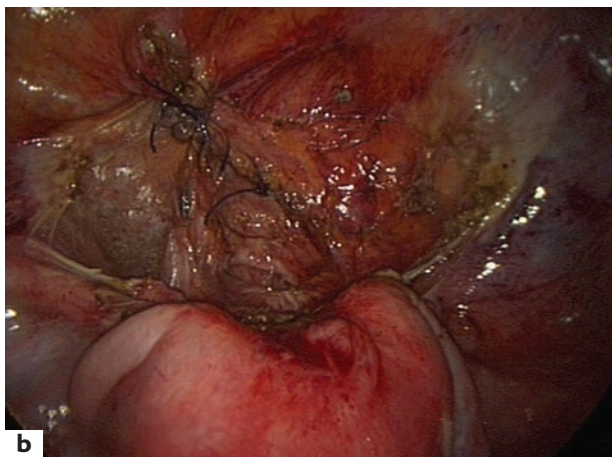
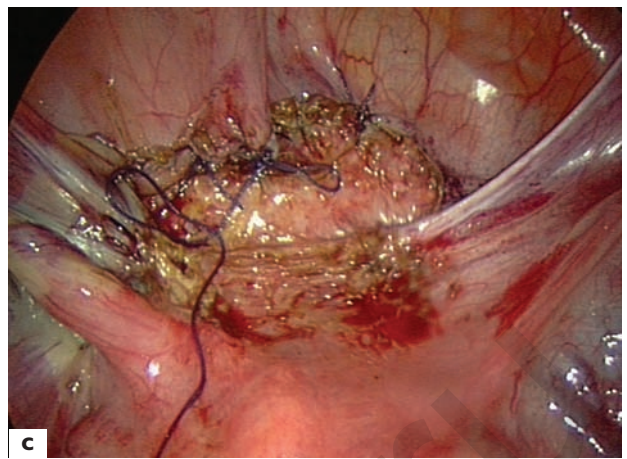
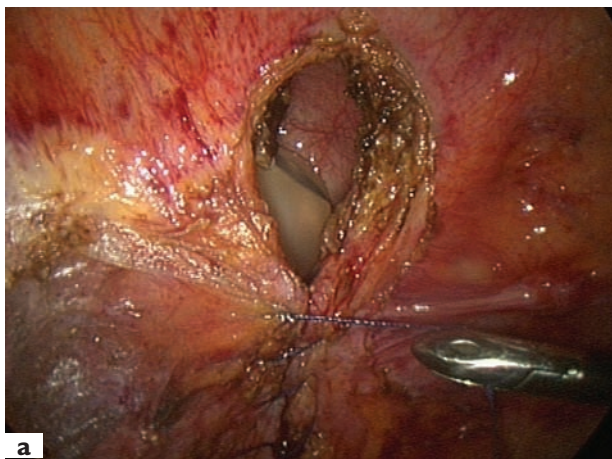


Figure 8.9 (a)–(c) Extramucosal vesical suture by separate or continuous Vicryl® 2-0 stitches

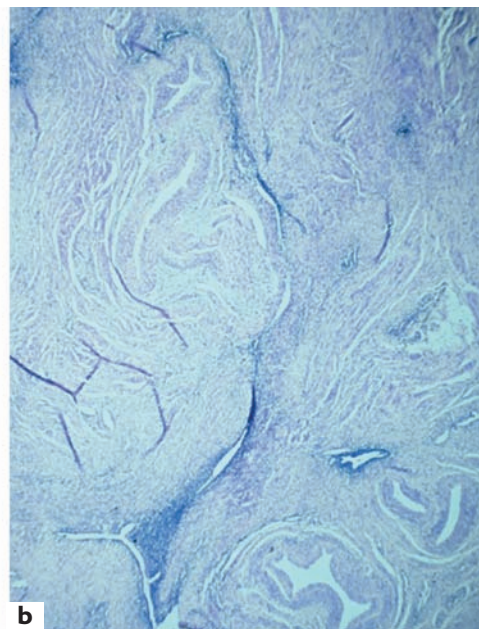
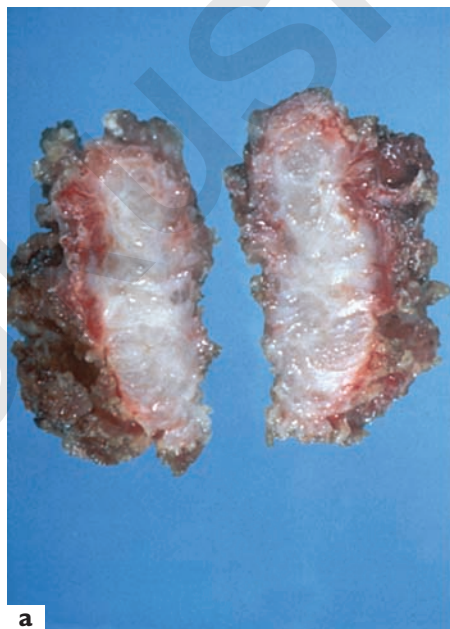


Figure 8.10 Vesical adenomyosis: (a) 90% of the lesion consists of smooth-muscle hyperplasia. (b) Scarce glands with active endometrial-type epithelium and scanty stroma are visible

infiltrating endometriosis. If this were the case, we would have found peritoneal endometriosis in all cases. In our series, 35% of patients had no associated endometriotic lesions, while 65% of women had associated rectovaginal adenomyotic nodules, which we clearly described as a distinct retroperitoneal entity^{1,15}. Indeed, the rectovaginal septum nodule was described, like the adenomyoma, as a circumscribed nodular aggregate of smooth muscle and endometrial glands, surrounded by scanty stroma. We have previously suggested that a rectovaginal nodule may be the consequence of metaplasia of Müllerian remnants. Not surprisingly, a bladder nodule appeared exactly the same as a rectovaginal nodule when viewed microscopically.

This frequent association, as well as the similar histological findings observed in our study, lead us to suggest strongly that bladder endometriosis is actually bladder adenomyosis, and also the consequence of metaplasia of Müllerian remnants that can be found in both the rectovaginal septum and vesicovaginal septum, or the result of metaplasia of the retroperitoneal space, again originating from the cervix. Indeed, we systematically found a clear attachment between the cervix and the nodule, and the absence of any real plane of cleavage.

One of the hypotheses advanced by Fedele *et al.*⁴, claiming that detrusor endometriosis could result from the extension of adenomyotic lesions from the anterior uterine wall to the bladder, is not supported by our study. Indeed, although the adenomyotic vesical nodule was systematically found to be adherent to the uterine wall or to the cervix, no adenomyotic nodules of the anterior uterine wall were found. These data, observed at surgery, were corroborated by the absence of uterine adenomyosis on echography and MRI, when available.

With regard to treatment, although medical therapy has proven effective in relieving symptoms, the quick recurrence of irritative urinary symptoms after cessation of therapy indicates that surgery is required. In the literature so far, partial cystectomy (or segmental bladder resection) has been considered the treatment of choice^{11,16,17}. Successful treatment depends, however, on achieving radical, deep surgical exeresis of the nodule^{18,19}.

In conclusion, so-called primary bladder endometriosis must be considered as retroperitoneal adenomyotic disease, which is the consequence of metaplasia of the bladder muscularis and can be resected using a laparoscopic approach⁵.

REFERENCES

- Nisolle M, Donnez J. Peritoneal endometriosis, ovarian endometriosis and adenomyotic nodules of the rectovaginal septum are three different entities. *Fertil Steril* 1997; 68: 585–96
- Judd ES. Adenomyomata presenting as a tumor of the bladder. *Surg Clin North Am* 1921; 1: 1271–8
- Fianu S, Ingelman-Sundberg A, Nasiell K, et al. Surgical treatment of post abortum endometriosis of the bladder and postoperative bladder function. *Scand J Urol Nephrol* 1980; 14: 151–5
- Fedele L, Piazzola E, Raffaelli R, et al. Bladder endometriosis: deep infiltrating endometriosis or adenomyosis? *Fertil Steril* 1998; 69: 972–5
- Donnez J, Spada F, Squifflet J, et al. Bladder endometriosis must be considered as bladder adenomyosis. *Fertil Steril* 2000; 74: 1175–81
- Heilier JF, Ha A-T, Lison D, et al. Increased serum PCB levels in Belgian women with adenomyotic nodules of rectovaginal septum. *Fertil Steril* 2004; 81: 456–8
- Balleyguier C, Chapron C, Dubuisson JB, et al. Comparison of magnetic resonance imaging and transvaginal ultrasonography in diagnosing bladder endometriosis. *J Am Assoc Gynecol Laparosc* 2002; 9: 15–23
- Donnez J, Nisolle M, Anaf V, et al. Endoscopic management of peritoneal and ovarian endometriosis. In Donnez J, Nisolle M, eds. *An Atlas of Laser Operative Laparoscopy and Hysteroscopy*. Carnforth, UK: Parthenon Publishing, 1994: 63–74
- Nisolle M, Casanas-Roux F, Wyns C, et al. Immunohistochemical analysis of estrogen and progesterone receptors in endometrium and peritoneal endometriosis: a new quantitative method. *Fertil Steril* 1994; 62: 751–9
- Vercellini P, Meschia M, De Giorgi O, et al. Bladder detrusor endometriosis: clinical and pathogenetic implication. *J Urol* 1996; 155: 84–6
- Brosens IA, Puttemans P, Deprest J, et al. The endometriosis cycle and its derailments. *Hum Reprod* 1994; 9: 770–1
- Koninckx PR, Martin D. Deep endometriosis: a consequence of infiltration or retraction or possible adenomyosis externa. *Fertil Steril* 1992; 85: 924–8
- Vercellini P, Frontino G, Pisacreta A, et al. The pathogenesis of bladder detrusor endometriosis. *Am J Obstet Gynecol* 2002; 187: 538–42
- Vercellini P, Frontino G, Pietropaolo G, et al. Deep endometriosis: definition, pathogenesis, and clinical management. *J Am Assoc Gynecol Laparosc* 2004; 11: 153–61
- Donnez J, Nisolle M, Smoes P, et al. Peritoneal endometriosis and 'endometriotic' nodules of the rectovaginal septum are two different entities. *Fertil Steril* 1996; 66: 362–8
- Zaloudek C, Norris HJ. Mesenchymal tumors of the uterus. In Kurman R, ed. *Blaustein's Pathology of the Female Genital Tract*. New York: Springer-Verlag, 1987: 373–408
- Nezhat C, Nezhat F. Laparoscopic segmental bladder resection for endometriosis: a report of two cases. *Obstet Gynecol* 1993; 81: 882–4
- Chapron C, Chopin N, Borghese B, et al. Surgical management of deeply infiltrating endometriosis: an update. *Ann NY Acad Sci* 2004; 1034: 326–37
- Fedele L, Bianchi S, Zanconato G, et al. Long-term follow-up after conservative surgery for bladder endometriosis. *Fertil Steril* 2005; 83: 1729–33

akusher-lib.ru

Laparoscopic hysterectomy including for advanced endometriosis with rectosigmoid disease

H Reich, T Seckin, J M Reich

INTRODUCTION

The laparoscopic approach to hysterectomy is an attractive option for many women for a multitude of pelvic complaints, and as with any surgical procedure, complications can occur. Despite the argument that laparoscopy adds further risk to the procedure, with appropriate surgical technique the complication rate should be less with this approach. There are many surgical advantages to laparoscopy, particularly magnification of anatomy and pathology, access to the uterine vessels, vagina and rectum, and the ability to achieve complete hemostasis and clot evacuation. Patient advantages are multiple, and are related to avoidance of a painful abdominal incision. They include reduced duration of hospitalization and recuperation and an extremely low rate of infection and ileus.

Laparoscopic hysterectomy (LH), defined as the laparoscopic dissection, ligation and division of the uterine blood supply, is an alternative to abdominal hysterectomy with more attention to ureteral identification¹⁻³. First done in January 1988⁴, LH stimulated a general interest in the laparoscopic approach to hysterectomy, as gynecologists not trained in vaginal or laparoscopic techniques struggled to maintain their share of the large, lucrative hysterectomy market. A watered-down version of LH called LAVH (laparoscopy-assisted vaginal hysterectomy) was taught by industry, and became known as an expensive and over used procedure with indications for which skilled vaginal surgeons rarely found the laparoscope necessary. Currently, abdominal hysterectomy, like laparotomy cholecystectomy, should rarely be done if gynecologists have received appropriate surgical training in both vaginal and laparoscopic techniques.

LH remains a reasonable substitute for abdominal hysterectomy. Laparoscopy-assisted hysterectomy (LAH) is a cost-effective procedure when performed with reusable instruments. The procedure is safe, even when performed by a variety of gynecologists with different skill levels. The adoption of this technique can decrease abdominal-incision hysterectomies⁵.

Many academics state that a laparoscopic hysterectomy is rarely indicated when vaginal hysterectomy is possible, i.e. when the uterine vessels are readily accessible vaginally. It must be realized that what is accessible vaginally by one surgeon may be impossible for another. The goal of vaginal hysterectomy, LAVH or LH is to avoid safely an abdominal-wall incision with its known high rate of postoperative adhesions⁶.

The operative environment must be prepared for laparoscopic hysterectomy. Equipment must be available and functional, and a back-up plan must be in place to address any unanticipated malfunction. In addition, the competence level of the operative team is of equal importance. Anesthesia and nursing staff and the surgeon must share the same operative goals, and actively cooperate to achieve them. Frequently neglected is the need for education of the postoperative support staff.

Since hysterectomy is usually an elective procedure, the patient is counseled extensively regarding the range of currently available options appropriate to her individual clinical situation. In 2006, it is clearly not acceptable to advocate hysterectomy without detailing the risks and benefits of other intermediary procedures, such as myomectomy and/or excision of endometriosis with uterine preservation.

Whereas conversion to laparotomy when the surgeon becomes uncomfortable with the laparoscopic approach has never been considered a complication, conversion rates should be monitored to safeguard the consumer's right to have this procedure performed by a competent laparoscopic surgeon. Surgeons who do more than 25% of their hysterectomies with an abdominal incision should not promote their ability and degree of expertise with a laparoscopic approach to their patients. Perhaps, conversion to laparotomy should be considered a complication!

Although hysterectomy remains one of the most commonly performed procedures in the United States, with approximately 600 000 annual cases, most are performed by the abdominal approach⁷. More recently, oncologists have been using the laparoscopic approach for gynecological malignancies, especially endometrial cancer. Despite the surprising increase in total laparoscopic or laparoscopic-assisted hysterectomies performed, from 0.3% in 1990 to 9.9% in 1997⁷, the deficiencies in resident and fellow training programs remain a formidable obstacle to the promotion of this technique.

Two distinct groups performing laparoscopic hysterectomy exist: a very large cluster doing LAVH instead of vaginal hysterectomy, and a much smaller, elitist segment doing total laparoscopic hysterectomy (TLH) when vaginal hysterectomy is not possible. LAVH practitioners add the potential complications of laparoscopic surgery to those of vaginal surgery, and hence it appears that more complications occur. Ureteral and bladder injuries occur often during the vaginal part of the LAVH. Peripheral nerve injuries may be secondary to stirrup changes going

Table 9.1 Laparoscopy-assisted hysterectomy classification

-
- Diagnostic laparoscopy with vaginal hysterectomy
 - Laparoscopy-assisted vaginal hysterectomy (LAVH)
 - Laparoscopic hysterectomy (LH)
 - Total laparoscopic hysterectomy (TLH)
 - Laparoscopic supracervical hysterectomy (LSH) including classical interstitial Semm hysterectomy (CISH)
 - Vaginal hysterectomy with laparoscopic vault suspension (LVS) or laparoscopic pelvic reconstruction (LPR)
 - Laparoscopic hysterectomy with lymphadenectomy
 - Laparoscopic hysterectomy with lymphadenectomy and omentectomy
 - Laparoscopic radical hysterectomy with lymphadenectomy
-

from above to below. We believe it is time to get rid of the LAVH! Learn to do the entire operation under laparoscopic visualization or do a vaginal hysterectomy. Most gynecologists perform laparoscopy and abdominal hysterectomy. As total laparoscopic hysterectomy mimics abdominal hysterectomy in almost all respects, it should be easy to assimilate it into practice for the majority of patients.

LAPAROSCOPY-ASSISTED HYSTERECTOMY DEFINITIONS (Table 9.1)

A variety of operations are done in which the laparoscope is used as an aid to hysterectomy, each with their particular set of problems. Of importance is that these different procedures are delineated clearly.

Diagnostic laparoscopy with vaginal hysterectomy indicates that the laparoscope is used for diagnostic purposes to determine whether vaginal hysterectomy is possible when indications for a vaginal approach are equivocal. It should also ensure that vaginal cuff and pedicle hemostasis is complete, and allow clot evacuation.

Laparoscopy-assisted vaginal hysterectomy (LAVH) is a vaginal hysterectomy after laparoscopic adhesiolysis, endometriosis excision or oophorectomy. This term is also used when the upper uterine ligaments (e.g. round, infundibulopelvic or utero-ovarian ligaments) of a relatively normal uterus are ligated with staples or bipolar desiccation. It must be emphasized that in most cases the easy part of both abdominal and vaginal hysterectomy is upper pedicle ligation.

Laparoscopic hysterectomy (LH) denotes laparoscopic ligation of the uterine arteries by electrosurgery desiccation, suture ligation or staples⁴. All surgical steps after the uterine vessels have been ligated can be carried out either vaginally or laparoscopically, including anterior and posterior vaginal entry, cardinal and uterosacral

ligament division, uterine removal (intact or by morcellation) and vaginal closure (vertically or transversely). Laparoscopic ligation of the uterine vessels is the *sine qua non* for LH. Ureteral identification often by isolation has always been advised.

Total laparoscopic hysterectomy (TLH) denotes that after all vascular pedicles are ligated, the laparoscopic dissection continues until the uterus lies free from all attachments in the peritoneal cavity. The uterus is then removed through the vagina, often with laparoscopic and/or vaginal morcellation. The vagina is closed with laparoscopically placed sutures. No vaginal surgery except for morcellation is done⁸.

Laparoscopic supracervical hysterectomy (LSH) has recently regained some support after suggestions that total hysterectomy results in a decrease in libido in some women⁹. Others claim that it offers physicians an easier, less risky procedure than LH, with a decreased risk of dissection of the ureter and uterine artery and fewer problems with future vaginal prolapse¹⁰. Morcellation from above or below removes the uterus.

Unfortunately, cul-de-sac endometriosis and uterine adenomyosis that cause pain frequently involve the cervix. Leaving the cervix in these women often results in minimal pain relief. Only total laparoscopic hysterectomy should be used for extensive endometriosis.

INDICATIONS AND CONTRAINDICATIONS

Many gynecologists consider the following as indications for an abdominal approach to hysterectomy:

- Uterine size greater than 12 weeks
- Nulliparity with lack of uterine descent
- Previous pelvic surgery

- Extrauterine pelvic pathology (endometriosis, adhesive disease)
- Narrow vagina
- Poor uterine mobility without access to the uterine vasculature
- Obesity
- Need for oophorectomy
- Cancer

These are relative contraindications for laparoscopic surgery in gynecology, where most surgeons would be better served by doing a laparotomy. With the assistance of expert laparoscopic training, the majority of these patients can be spared a laparotomy. In most cases where vaginal access and/or access to the uterine vessels is limited and little or no uterine mobility exists, a laparoscopic hysterectomy can be considered.

LH is not advised for the diagnosis and treatment of a potentially malignant pelvic mass of ovarian origin that cannot be removed intact through a culdotomy incision, or that is too large to fit intact into an impermeable sac, particularly in postmenopausal patients. The medical status of the patient may prohibit surgery. Age alone should rarely be a deterrent. Obesity presents special problems for pelvic surgery, as the use of the Trendelenburg position may be limited because of anesthesia ventilation difficulties. Finally, inexperience or inadequate training of the surgeon is an obvious contraindication to the laparoscopic approach.

A critical factor in considering the degree of difficulty of a laparoscopic operation is the number of previous surgeries the patient has had. Previous surgeries cause adhesions, and adhesions can make the next operation much more difficult⁶. For example, if the patient has endometriosis deep in the rectovaginal septum and has had five previous operations, it could take hours of small-bowel enterolysis to get down to the deep rectal endometriosis, because of all the adhesions that have formed from the previous surgeries and persistent endometriosis. Severe-adhesion cases can be so long and time-consuming that the surgeon feels no progress is being made. Then, it is best to convert a laparoscopy to a laparotomy.

The most common indication for laparoscopic hysterectomy is a symptomatic fibroid uterus. Symptoms include hypermenorrhea leading to anemia, pelvic pressure and, rarely, pain. Most of these cases can be done laparoscopically, with vaginal morcellation, as an overnight hospital stay.

The other common indication for LH is endometriosis causing pelvic pain^{11,12}. The index of suspicion for cul-de-sac or bowel endometriosis should be high when the patient reports deep dyspareunia, pain radiating into the back or leg, pain with bowel movements, tenesmus or rectal bleeding with menses. Less frequently encountered symptoms include the symptomatic and the asymptomatic

pelvic mass and hypermenorrhea. The diagnosis may be known from another surgeon's operative report, pathology report, images or video, or is confirmed, when suspected, at a primary laparoscopic procedure by a capable surgeon.

Most extensive-endometriosis hysterectomies are currently done by an abdominal approach, with bilateral salpingo-oophorectomy, using an intrafascial technique that leaves the endometriosis behind on the rectum and vagina. Even worse, when confronted by extensive disease with the rectum fused to the cervix, many gynecologists perform a supracervical hysterectomy and bilateral oophorectomy in the belief that castration will resolve the endometriosis left behind. These cases would be better served with laparoscopic excision of the endometriosis followed by total laparoscopic hysterectomy (TLH).

Endometriosis involves a chronic inflammatory response with accumulative fibrosis. Partial excision by cautery thermablation may produce an acute phase in which more adhesions form postoperatively. Most extensive-endometriosis hysterectomies can be done laparoscopically when symptoms warrant, and should include resection of the endometriosis. In these cases, the endometriosis, usually surrounded by fibromuscular tissue, should be removed. In women who have endometriosis and wish to have children, the endometriosis can be removed and the uterus and one or both ovaries preserved. When child-bearing is not an issue, the endometriosis is probably best treated in one operation by, first, excision of the endometriosis and, then, a hysterectomy to remove possible deep intrauterine endometriosis (adenomyosis). In our experience, at least one ovary can be preserved in most of these patients. Endometriosis can remain symptomatic after the removal of both ovaries as estrogen is also made by skin, adipose tissue and the endometriosis itself. Even with extensive endometriosis, the diseased areas should be removed, and not normal ovaries. Supracervical hysterectomy should not be carried out, as endometriosis is present commonly in the posterior cervix, and leaving it behind will not result in symptom relief.

Rectovaginal endometriosis requires a radical resection of the endometriotic tissue, which may require a bowel resection if the endometriosis has invaded the bowel wall¹³⁻¹⁵. There, it may cause a stricture which results in dyschezia and difficult evacuation. In most of these cases, bowel resection, if not done during the primary surgery, will have to be done in the future. The best surgeon to perform this surgery should be a gynecologist, because a gynecologist understands the disease of endometriosis better than does a general surgeon or colorectal surgeon. A general surgeon should be available to provide technical advice or work together with the gynecologist. We hope that in the future, we will see more teams of gynecologists with general surgeons operating together on extensive rectal endometriosis.

Hypermenorrhea (heavy bleeding) is a very common reason for hysterectomy. Most of these cases involve a

small uterus and can be done vaginally. Our profession should discourage abdominal hysterectomy for this indication. If the vaginal approach is not available, laparoscopic total or supracervical hysterectomy can be done.

Of course, there are now many different techniques to reduce bleeding by destroying uterine endometrium. This has resulted in a new indication for hysterectomy: endometrial ablation failure. Many women who have ablations continue to have a bleeding problem, resolved by hysterectomy. Most women seeking an ablation should also be given the alternative of a vaginal or a laparoscopic hysterectomy.

In the UK, national figures show an increase in the total numbers of operations for dysfunctional uterine bleeding (DUB) from 1989 to 1996. Hysterectomy rates have remained steady. Ablation has not been a replacement technique for hysterectomy, but an alternative technique. Endometrial ablation rates have fallen since 1993¹⁶.

Laparoscopic treatment is best carried out in women with endometrial cancer. In most cases of endometrial cancer, the uterus is relatively small, and thus the laparoscopic surgeon can take out the uterus and then examine the inside of it. If the depth of myometrial penetration is less than one-half, the patient is probably cured just by the simple hysterectomy. If there is invasion of the muscle greater than one-half through the myometrium, the surgeon should perform a pelvic lymphadenectomy.

Few relative contraindications to laparoscopic surgery, for which most surgeons would be better served by doing a laparotomy, exist in gynecology. With the assistance of expert laparoscopic training, the majority of these patients can be spared a laparotomy. In most cases in which vaginal access or access to the uterine vessels is limited, and little or no uterine mobility exists, a laparoscopic hysterectomy can be considered.

One should remember that concerning the operative indication, laparoscopic hysterectomy is a substitute for abdominal hysterectomy, including difficult abdominal hysterectomy. Hysterectomy by laparotomy is not preferable in most cases with distorted anatomy or a large uterus.

TOTAL LAPAROSCOPIC HYSTERECTOMY TECHNIQUE

Our technique for a TLH is described, since other types of laparoscopic hysterectomy (e.g. LAVH or LH) are simply modifications of this more extensive procedure. These steps are designed to prevent complications.

Preoperative preparation

The patient is optimized medically for coexistent problems. Preoperative ovarian suppression is sometimes used. Patients are encouraged to hydrate with clear liquids

the day before surgery. Fleet® Phospho-soda® 90 ml, divided into two doses, is given at 15.30 and 19.30 to evacuate the lower bowel. If the patient is prone to nausea, Phenergan® 25 mg is taken orally 25 minutes before the bowel prep. Lower-abdominal, pubic and perineal hair is not shaved.

All laparoscopic procedures are done using general endotracheal anesthesia, with orogastric tube suction to minimize bowel distension. The patient's arms are placed at her side (no armboards), and shoulder braces are positioned at the acromioclavicular joint. Nitrous oxide anesthesia gas is avoided because it may cause small-bowel distension. The bladder is emptied when filled. The Trendelenburg position up to 40° is available. We use one dose of a prophylactic antibiotic after induction of anesthesia in all patients.

Incisions

Three laparoscopic puncture sites including the umbilicus are used: 10 mm umbilical, 5 mm right and 5 mm left lower quadrant. Pneumoperitoneum to 25–30 mmHg is obtained before primary umbilical trocar insertion, and reduced to 15 mm afterwards. The lower quadrant trocar sleeves are placed under direct laparoscopic vision above the pubic hairline and lateral to the rectus abdominis muscles (and thus, the deep epigastric vessels). These are placed just beside the anterior superior iliac spines in patients with large fibroids. The left lower quadrant puncture is the major portal for operative manipulation as the surgeon stands on the patient's left side. The right trocar sleeve is used for retraction with atraumatic grasping forceps.

Reduction in wound morbidity and scar integrity as well as cosmesis is enhanced using 5-mm sites. The use of 12-mm incisions when a 5-mm one will suffice is not an advance in minimally invasive surgery.

Vaginal preparation

There will always be room for new innovations in uterine and vaginal manipulation to help the surgeon visualize pelvic anatomy. In the USA, many centers have only old, basic devices available such as the Cohen cannula and HUMI (Harris-Kronner uterine manipulator/injector). The Valtchev uterine manipulator (Conkin Surgical Instruments, Toronto, Canada) has been around for more than 15 years, and is a huge advance. It allows anterior, posterior and lateral manipulation of the uterus, and permits the surgeon to visualize the posterior cervix and vagina. Newer devices are currently available developed by Pelosi, Wattiez, Hourcabie, Koninckx, Koh, McCartney, Donnez and Reich. We still use the Valtchev and the Wolf tube. When using the Valtchev uterine mobilizer in the anteverted position, the cervix sits on a wide pedestal, making the vagina readily visible between the uterosacral ligaments when the cul-de-sac is viewed laparoscopically.

Exploration

The upper abdomen is inspected, and the appendix is identified. Clear vision is maintained throughout the operation using the IC Medical smoke evacuator (Phoenix, AZ). If appendiceal pathology is present, i.e. dilatation, adhesions or endometriosis, appendectomy is done. The appendix is mobilized, its blood supply isolated by making a window in the mesoappendix near the cecum with reusable Metzenbaum-type scissors, and ligated by passing a Vicryl® 2-0 free ligature through this window and securing it extracorporeally with the Clarke–Reich knot pusher. Three endoloops (chromic gut ligature; Ethicon, Somerville, NJ) are then placed at the appendiceal–cecal junction after desiccating the appendix just above this juncture. The appendix is left attached to the cecum. Its stump is divided later in the procedure, after opening the cul-de-sac, so that vaginal removal from the peritoneal cavity can be accomplished.

Retroperitoneal dissection

The peritoneum is opened.

The uterus is pushed cephalad and to one side from below using the uterine manipulator, and the anterior broad ligament is put into tension by pulling the Fallopian tube medially. Scissors are used to make an incision in the peritoneum in front of the round ligament. CO₂ from the pneumoperitoneum rushes into the retroperitoneum and distends it. The tip of the laparoscope is then used to perform ‘optical dissection’ of the retroperitoneal space by pushing it into the loosely distended areolar tissue parallel to the uterus. This blunt dissection technique is usually successful in identifying the uterine vessels, ureter or both. The uterine artery is often ligated at this time, especially in large-uterus patients.

Ureteral dissection (optional)

Three approaches have been used for laparoscopic ureteric identification, which may be called medial, superior and lateral. Stents are not used, as they cause hematuria and ureteric spasm in some patients. The laparoscopic surgeon should dissect (skeletonize) either the ureter or the uterine vessels during the performance of a laparoscopic hysterectomy.

The medial approach

Immediately after exploration of the upper abdomen and pelvis, each ureter is isolated deep in the pelvis, when possible. Ureteral dissection is performed early on in the operation before the pelvic side-wall peritoneum becomes edematous and opaque from irritation by the CO₂ pneumoperitoneum or hydrodissection, and before ureteral peristalsis is inhibited by surgical stress, pressure or the Trendelenburg position¹.

If the uterus is anteverted using a uterine manipulator, the ureter can usually be easily visualized in its natural position on the pelvic side wall (posterior leaf of the broad ligament), provided that no significant cul-de-sac or adnexal abnormality is present. This maneuver allows the peritoneum immediately above the ureter to be incised to create a peritoneal ‘window’ in order to make division of the infundibulopelvic ligament or adnexal pedicle safer. The ureter and its overlying peritoneum are grasped deep in the pelvis below and caudad to the ovary, lateral to the uterosacral ligament. An atraumatic grasping forceps is used from the opposite-sided cannula. Scissors are used to divide the peritoneum overlying the ureter, and are inserted into the incision created and spread. Thereafter, one blade of the scissors is placed on top of the ureter, its blade visualized through the peritoneum, and the peritoneum divided. In this manner, the ureter and its surrounding longitudinal endopelvic fascia sheath are dissected together away from the peritoneum without compromising its blood supply. This dissection is continued into the deep pelvis where the uterine vessels cross the ureter, lateral to the cardinal ligament insertion into the cervix. Connective tissue between the ureter and the vessels is separated with scissors. Bleeding is controlled with microbipolar forceps. Often, the uterine artery is ligated at this time to diminish back-bleeding from the upper pedicles.

The superior approach

The superior approach entails dissecting the colon (rectosigmoid on the left, cecum on the right) from the pelvic brim and freeing the infundibulopelvic ligament vessels from the roof of the broad ligament to allow the ureter that lies below it to be identified. The ureter is found as it crosses the iliac vessels (or below them between the hypogastric and superior rectal vessels on the left). The ureter is then reflected off the broad ligament and traced into the pelvis.

The lateral approach

The lateral approach makes use of the pararectal space to identify the ureter, and the ureter does not have to be peeled off the broad ligament for its entire pelvic course to be visible. The tip of the laparoscope is often the best blunt dissector in this area, and may be inserted alongside and just lateral to the pelvic side-wall peritoneum into the loose areolar tissue already distended by retroperitoneal CO₂ (see above) until the ureter and uterine vessels are identified.

After displacing the uterus to the contralateral side, a pelvic side-wall triangle is identified formed by the round ligament, lateral border by the external iliac artery and medial border by the infundibulopelvic ligament. The peritoneum in the middle of the triangle is incised with scissors and the broad ligament opened by bluntly

separating the extraperitoneal areolar tissues. The infundibulopelvic ligament is pulled medially with grasping forceps to expose the ureter at the pelvic brim where it crosses the common or external iliac artery. The operator then searches for the ureter distal to the pelvic brim and lateral to the infundibulopelvic ligament. The dissection is carried bluntly underneath and caudad to the round ligament, until the obliterated hypogastric artery is identified extraperitoneally. If difficulty is encountered, the artery is first identified intraperitoneally where it hangs from the anterior abdominal wall, and traced proximally to where it passes behind the round ligament. Then, with both its intraperitoneal portion and the dissected space under the round ligament in view, the intraperitoneal part of the ligament is moved back and forth. After the obliterated hypogastric artery has been identified extraperitoneally, it is an easy matter to develop the paravesical space by bluntly separating the areolar tissue on either side of the artery. The obliterated hypogastric artery is next traced proximally to where it is joined by the uterine artery, and the pararectal space opened by blunt dissection proximal and medial to the uterine vessels, which lie on top of the cardinal ligament. After the pararectal space has been opened, the ureter is identified easily on the medial leaf of the broad ligament (really posterior leaf), which forms the medial border of the pararectal space. The uterine artery and cardinal ligament at the distal (caudal) border of the space, and the internal iliac artery on its lateral border, also become clearly visible.

Bladder mobilization

The round ligaments are divided at their mid-portion using a well-insulated spoon electrode set at 150W cutting current or with scissors after bipolar desiccation. Persistent bleeding is controlled with bipolar desiccation at 30W cutting current. Thereafter, scissors or the same electrode are used to divide the vesicouterine peritoneal fold, starting at the left side and continuing across the midline to the right round ligament. The upper junction of the vesicouterine fold is identified as a white line firmly attached to the uterus, with 2–3 cm between it and the bladder dome. The initial incision is made below the white line while lifting the peritoneum covering the bladder. The bladder is mobilized off the uterus and upper vagina using scissors, or bluntly with the same spoon electrode or a suction-irrigator, until the anterior vagina is identified by elevating it from below with ring forceps. The tendinous attachments of the bladder in this area may be desiccated or dissected.

In most cases, incising the peritoneum in front of the round ligaments results in the development of a retroperitoneal pneumoperitoneum. It is very easy to isolate the uterine arteries adjacent to the uterus in this loose, gas-filled areolar tissue.

Upper uterine blood supply (Figures 9.1–9.5)

When ovarian preservation is desired, the utero-ovarian ligament and Fallopian tube are coagulated until desiccated with bipolar forceps, at 25–35W cutting current, and then divided. Alternatively, the utero-ovarian ligament and Fallopian tube pedicles are suture-ligated adjacent to the uterus with Vicryl 2-0, using a free ligature passed through a window created around the ligament. To create the window, the peritoneum is opened just lateral to the tubal cornua, and the Metzenbaum-type scissors slid down lateral to the utero-ovarian vessels until its tip can be seen through the posterior broad ligament peritoneum.

When oophorectomy is indicated or ovarian preservation not desired, the anterior and posterior leaves of the broad ligament are opened lateral and below the infundibulopelvic ligament with a laparoscopic Metzenbaum-type scissors, and a Vicryl 2-0 free ligature passed through the window thus created and tied

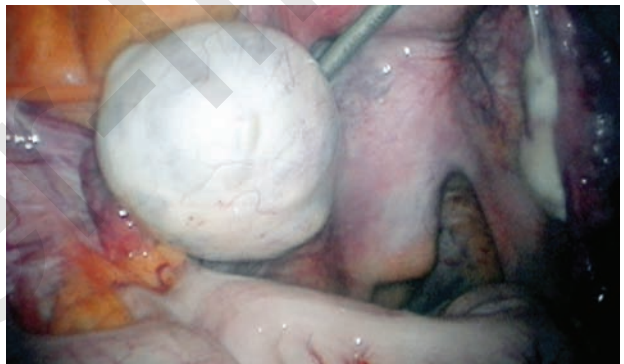

Figure 9.1 A cystic left ovary is seen at the start of total laparoscopic hysterectomy. Left salpingo-oophorectomy will be done. Note the uterus, cervix and upper vagina held anteriorly by the Valtchev uterine manipulator

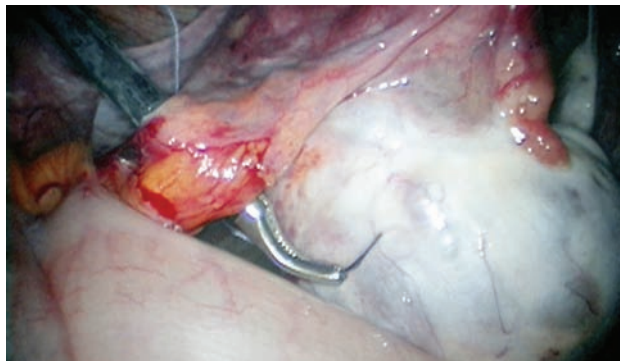


Figure 9.2 A window is made by incising the peritoneum medial and lateral to the infundibulopelvic ligament. A Vicryl® 2-0 suture ligature is placed around the left infundibulopelvic ligament in preparation for its ligation

extracorporeally using the Clarke–Reich knot pusher¹⁷. This maneuver is repeated twice around the ovarian vessels so that two proximal ties and one distal tie are placed, and the ligament then divided. While applying traction to the cut distal pedicle, the broad ligament is

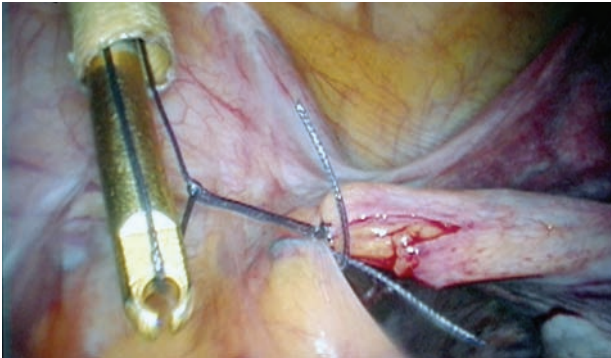


Figure 9.3 An extracorporeal knot is passed down to secure the infundibulopelvic ligament using a Clarke–Reich knot pusher

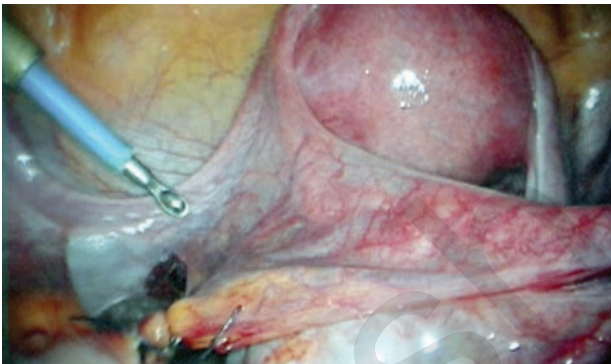


Figure 9.4 After ligation of the infundibulopelvic ligament, a spoon electrode at 100 W cutting current is used to divide it

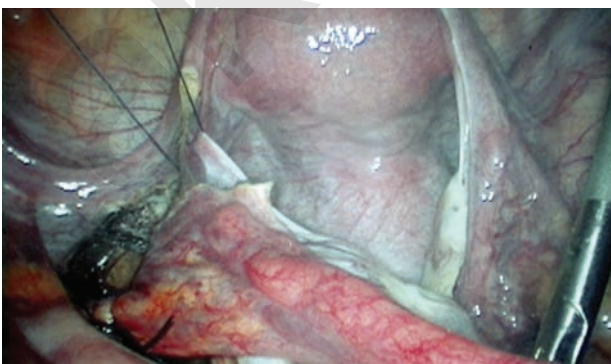


Figure 9.5 Alternatively, the suture ligation can be placed around the utero-ovarian ligament and the ovary preserved

divided to the round ligament just lateral to the utero-ovarian artery anastomosis using scissors or cutting current through a spoon electrode. We rarely desiccate the infundibulopelvic ligament, as it results in too much smoke early on in the operation. If suturing skills are not developed and the tube and ovary are to be removed, the infundibulopelvic ligament is mobilized, and bipolar forceps are used to compress and desiccate its vessels. Stapling devices are rarely used.

If the ovary is to be preserved and the uterus is large, the utero-ovarian ligament/round ligament/Fallopian tube junction may be divided with a 30- or 45-mm GIA™-type stapler. This may be time-saving for this portion of the procedure, thus justifying its increased cost.

Many complications are related to use of the Endo GIA or similar-type staplers. Whereas it decreases operation time, it also increases the risk for hemorrhage and injury to the ureter. At many institutions, complications are associated with the Endo GIA stapler, including postoperative hemorrhage, with resultant re-exploration and transfusion. Ligation or coagulation of the vascular pedicles is safer.

Uterine vessel ligation (Figures 9.6–9.11)

The uterine vessels may be ligated at their origin, at the site where they cross the ureter, where they join the uterus or on the side of the uterus. Most surgeons use bipolar desiccation to ligate these vessels, but these authors prefer suture.

In most cases, the uterine vessels are suture-ligated as they ascend the sides of the uterus. The broad ligament on each side is skeletonized down to the uterine vessels. Each uterine vessel pedicle is suture-ligated with Vicryl 0 on a CTB-1 blunt needle (Ethicon JB260; 27 in, ~68 cm). Use of a blunt needle markedly reduces uterine venous bleeding. The needles are introduced into the peritoneal cavity

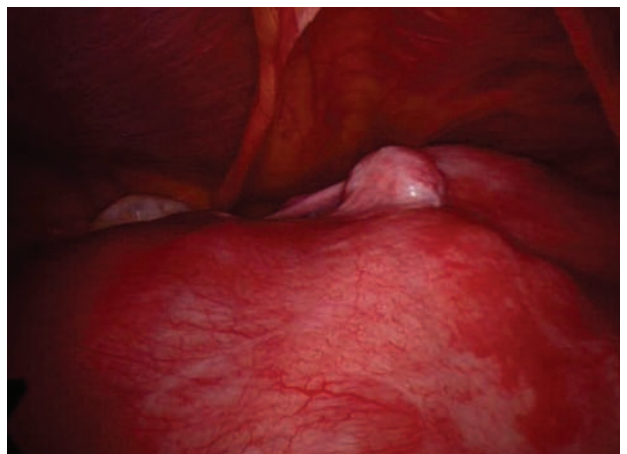


Figure 9.6 A large multiple fibroid uterus fills the peritoneal cavity to well above the umbilicus

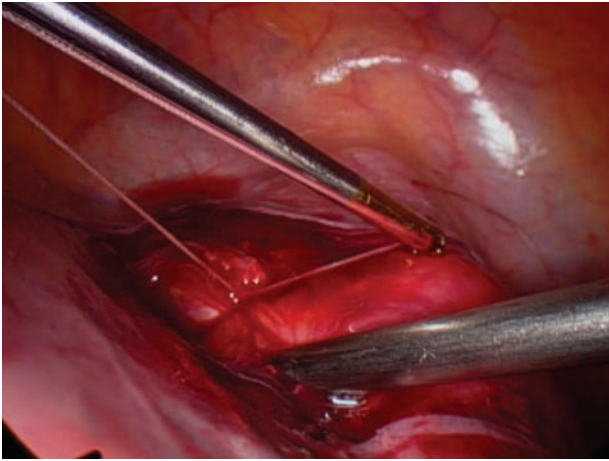


Figure 9.7 The anterior broad ligament is opened as is the vesicouterine peritoneal fold. An extracorporeal knot is passed to secure the left uterine artery with a Clarke–Reich knot pusher

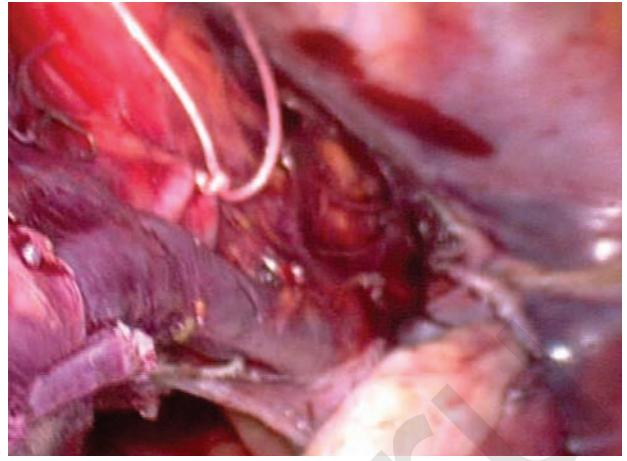


Figure 9.10 The ligated right uterine artery and draining vein are shown

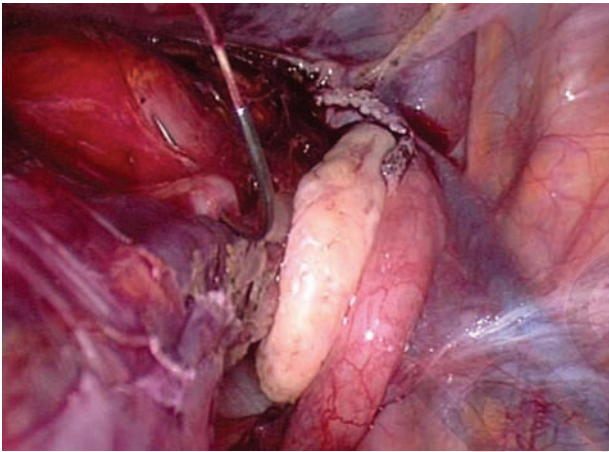


Figure 9.8 A Vicryl 0 suture on a CTB-1 needle is placed around the right uterine artery in preparation for its ligation. The vein is left to drain

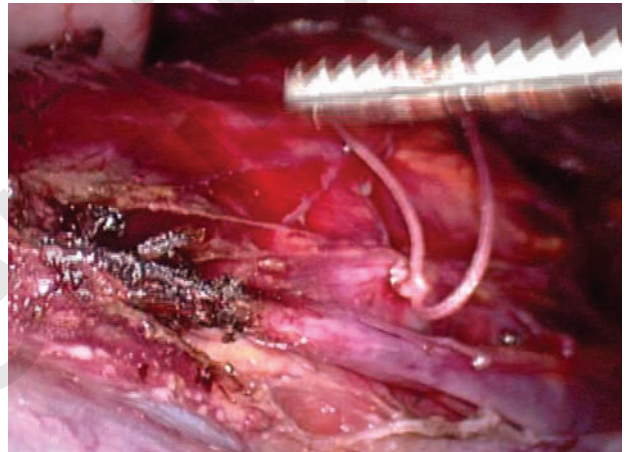


Figure 9.11 After the blood drains out of the uterus, it goes pale and the vein collapses. The vein is then desiccated with bipolar forceps and divided

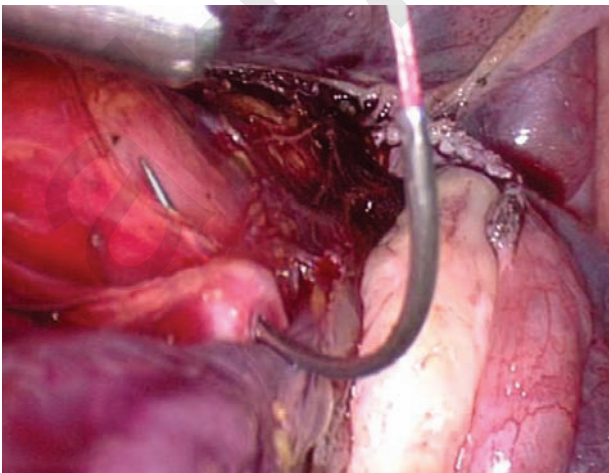


Figure 9.9 Close-up showing same procedure as described in Figure 9.8

by pulling them through a 5-mm incision¹⁸. The curved needle is placed around the uterine vessel pedicle at the side of the uterus. A short, rotary movement of the needle holder brings the needle around the uterine vessel pedicle. This motion is backhand if done with the left hand from the patient's left side and forward motion if using the right hand from the right side. The uterine artery is a sturdy structure, and can be grasped and elevated carefully to avoid the uterine veins underneath. In some cases, the vessels can be skeletonized completely, and a Vicryl 2-0 free suture ligature passed around them. Sutures are tied extracorporeally using a Clarke–Reich knot pusher.

In large-uterus patients, selective ligation of the uterine artery without its adjacent vein is done to give the uterus a chance to return its blood supply to the general circulation. It also results in a less voluminous uterus for morcellation.

In some cases, the curved needle is inserted on top of the unroofed ureter, where it turns medially toward the previously mobilized bladder. A single suture placed in this manner on each side serves as a 'sentinel stitch', identifying the ureter for the remainder of the procedure.

Division of cervicovaginal attachments and circumferential culdotomy (Figure 9.12)

The cardinal ligaments on each side are divided with the CO₂ laser at high power (80 W), or with an electrode using cutting current. Bipolar forceps are used to coagulate the uterosacral ligaments and are invaluable to control bleeding from vaginal branches. The vagina is entered posteriorly over the uterovaginal manipulator near the cervicovaginal junction. A 4-cm diameter vaginal delineator (Wolf) is placed in the vagina to outline circumferentially the cervicovaginal junction, serve as a backstop for laser work and prevent loss of pneumoperitoneum. First, it identifies the anterior cervicovaginal junction and then the lateral fornices. They are incised using the laser, with the delineator as a backstop to complete the circumferential culdotomy. The uterus is morcellated, if necessary, and pulled out of the vagina.

When the vaginal delineator is not available, a ring forceps is inserted into the anterior vagina above the tenaculum on the anterior cervical lip to identify the anterior cervicovaginal junction. The left anterior vaginal fornix is entered using the laser, so that the aquapurator can be inserted into the anterior vagina above the anterior cervical lip. Following the aquapurator tip or ring forceps, and using this as a backstop, the anterior and lateral vaginal fornices are divided. The aquapurator is inserted from posterior to anterior to delineate the right vaginal fornix, which is divided. The uterus can then be pulled out of the vagina.

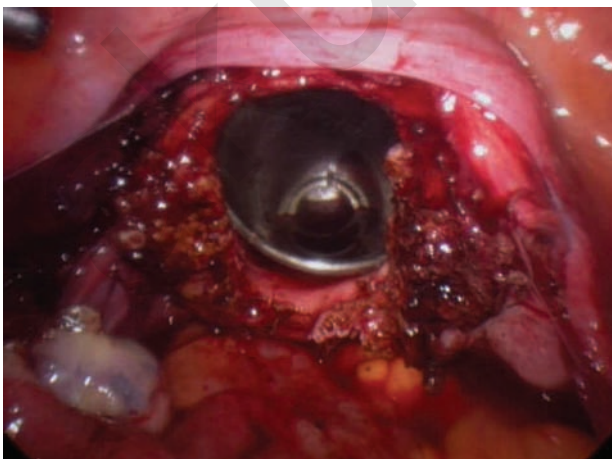


Figure 9.12 The vaginal delineator maintains the pneumoperitoneum, facilitating the vaginal cuff closure

Morcellation (laparoscopic and vaginal) (Figures 9.13–9.16)

Morcellation can be done laparoscopically or vaginally. For the laparoscopic technique, a #10 blade on a long handle is introduced gently through the left 5-mm trocar incision after removing the trocar. With care, the uterus and its enclosed large myoma can be bivalved with the blade. The surgeon's fingers in contact with the skin prevent the loss of pneumoperitoneum.

Vaginal morcellation is done in most cases on a uterus free in the peritoneal cavity, but may be considered after securing the ovarian arteries from above and the uterine arteries from above or below. A #10 blade on a long knife handle is used to make a circumferential incision into the fundus of the uterus, while pulling outwards on the cervix

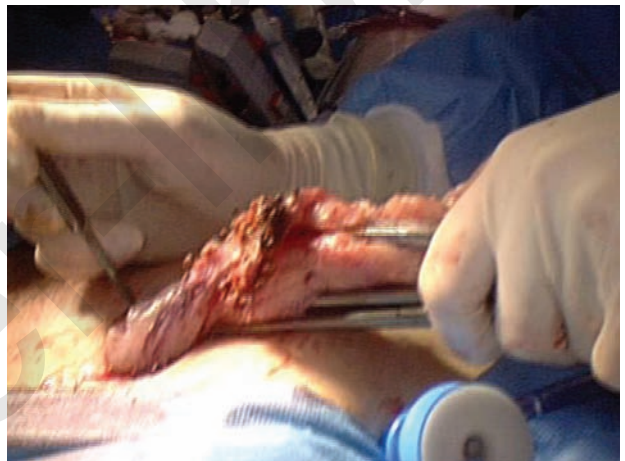

Figure 9.13 A #10 blade is used to morcellate the large fibroid uterus using a coring technique for removal through the left lateral incision

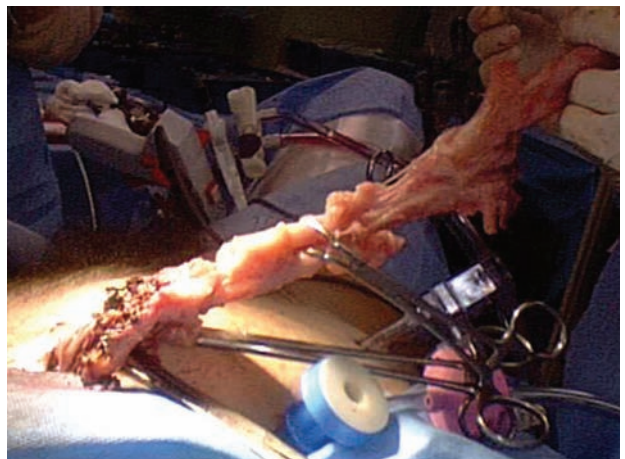


Figure 9.14 Further coring to morcellate the fibroid uterus

and using the cervix as a fulcrum. The myometrium is incised circumferentially parallel to the axis of the uterine cavity with the scalpel's tip always inside the myomatous tissue and pointed centrally, away from the surrounding vagina. The knife is not extended through the serosa of the uterus. The incision is continued around the full circumference of the myometrium in a symmetrical fashion beneath the uterine serosa. Traction is maintained on the cervix, and the avascular myometrium is cut so that the endometrial cavity with a surrounding thick layer of myometrium is delivered with the cervix, bringing the outside of the uterus closer to the operator for further excision by wedge morcellation.

Wedge morcellation is carried out by removing wedges of myoma and myometrium from the anterior and posterior uterine wall, usually in the midline, to reduce the bulk of the uterus. After excision of a large core, the fundus

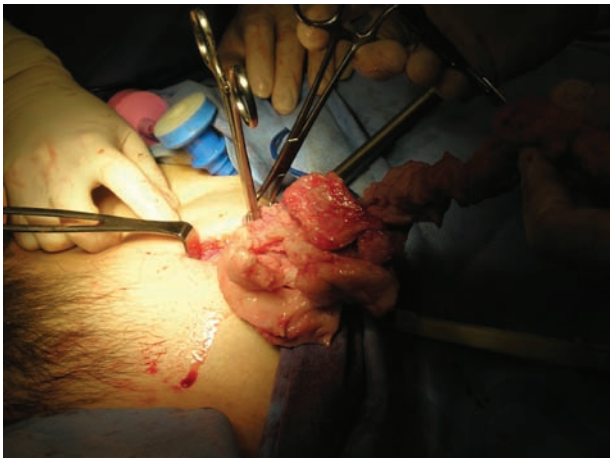


Figure 9.15 Note the blue trocar in the umbilicus. Towel clips and single-tooth tenacula are used to grasp and deliver the fibroid uterus from the 5-mm incision lateral to the left rectus muscle after extending this incision to 12 mm

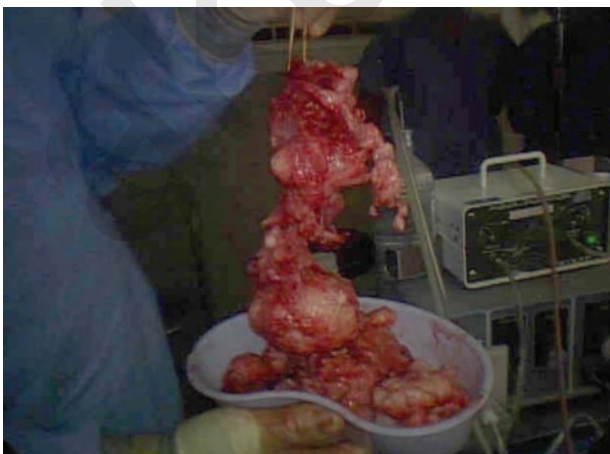

Figure 9.16 Morcellated fibroid uterus specimen

is morcellated with multiple wedge resections, around either a tenaculum or an 11-mm corkscrew device. The remaining fundus, if still too large for removal, can be bivalved so that one half can be pulled out of the peritoneal cavity, followed by the other half.

Morcellation of fibroids through anterior abdominal-wall puncture sites is now practical when vaginal access is limited. The Steiner™ electromechanical morcellator (Storz, Tuttlingen, Germany) is a 10-mm diameter motorized circular saw that uses claw forceps or a tenaculum to grasp the fibroid and pull it into contact with the fibroid. Large pieces of myomatous tissue are removed piecemeal until the myoma can be pulled out through the trocar incision. With practice this instrument can often be inserted through a stretched 5-mm incision without an accompanying trocar. The newer Sawalhe™ morcellator from Karl Storz comes with 12-mm, 15-mm and 20-mm diameter circular saws.

Laparoscopic vaginal vault closure and suspension with McCall culdoplasty (Figures 9.17–9.24)

The vaginal delineator, or a sponge in a glove pack, is placed back into the vagina for closure of the vaginal cuff, occluding it to maintain the pneumoperitoneum. The uterosacral ligaments are identified by bipolar desiccation markings or with the aid of a rectal probe. The first suture is complicated, as it brings the uterosacral and cardinal ligaments as well as the rectovaginal fascia together. The left uterosacral ligament is elevated and a Vicryl 0 suture on a CT-1 needle is placed through it, then through the left cardinal ligament with a few cells of posterolateral vagina

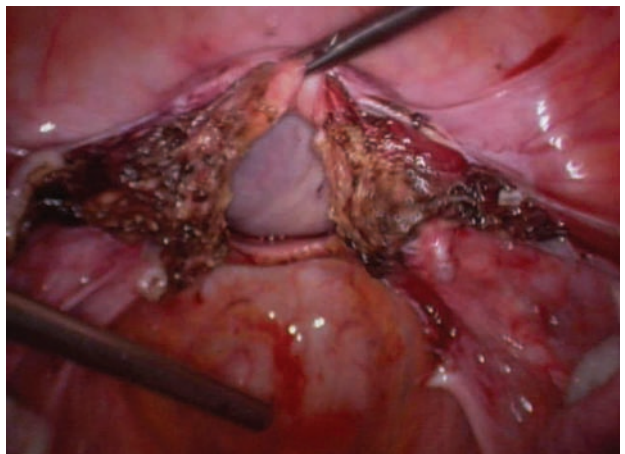

Figure 9.17 Following hemostasis, the vaginal cuff is ready for closure. Each uterosacral ligament has been marked 'white' from bipolar desiccation. Closure is done usually with two sutures to close the vagina and its fascia across the midline. The first suture incorporates both uterosacral ligaments and cardinal ligaments and rectovaginal fascia

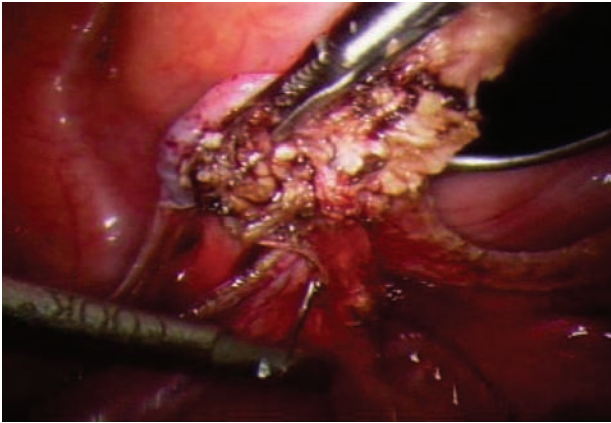


Figure 9.18 Vicryl 0 on a CT-1 needle is placed through the left uterosacral ligament and then the left cardinal ligament just below the uterine vessel pedicle

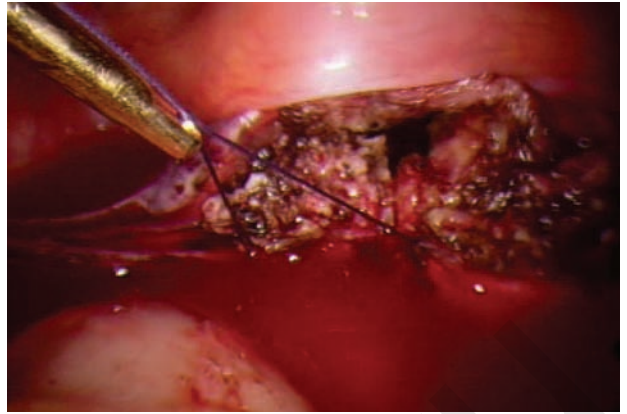


Figure 9.21 The suture is tied extracorporeally and passed down with a Clarke-Reich knot pusher, plicating the uterosacral ligaments, cardinal ligaments and rectovaginal fascia across the midline

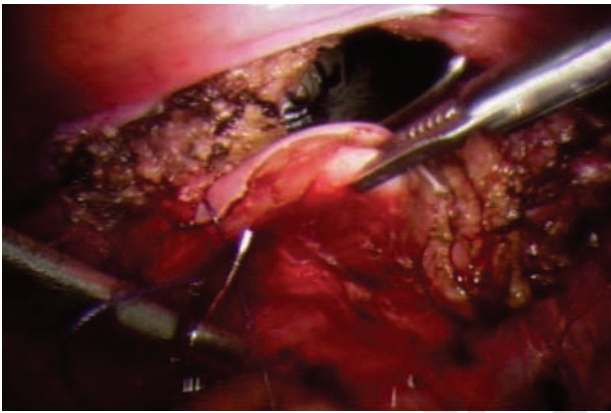


Figure 9.19 The suture continues across the posterior vaginal wall, grasping the rectovaginal fascia

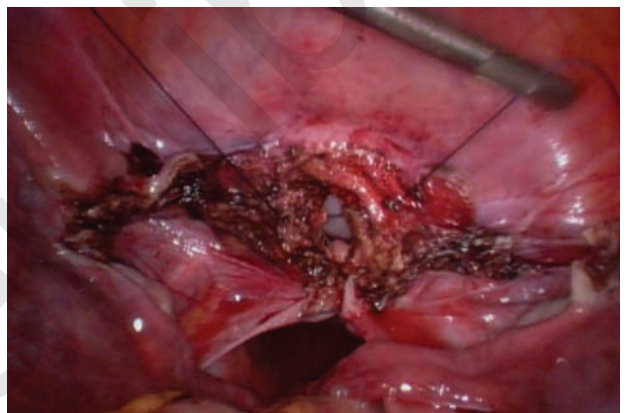


Figure 9.22 The uterosacral ligaments, cardinal ligaments and rectovaginal fascia are together. A second suture is used to close the pubocervicovesicular fascia. This suture is placed just above the uterine vessel pedicles

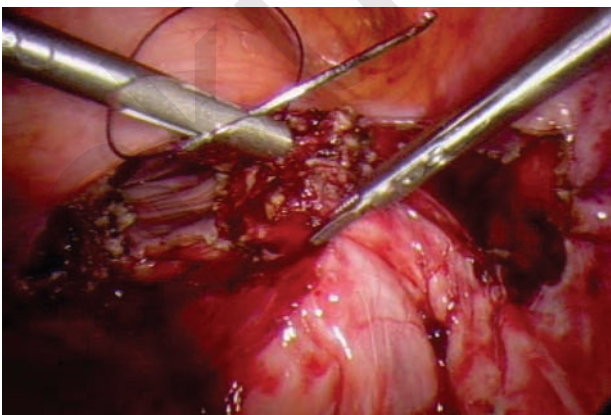


Figure 9.20 The suture finishes with separate bites into first the right cardinal ligament and finally the right uterosacral ligament. A rectal probe is used to help identify the right uterosacral ligament

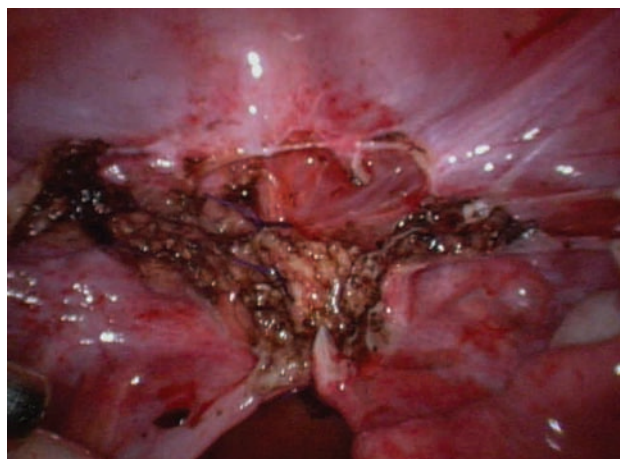


Figure 9.23 The vaginal cuff is closed and hemostatic

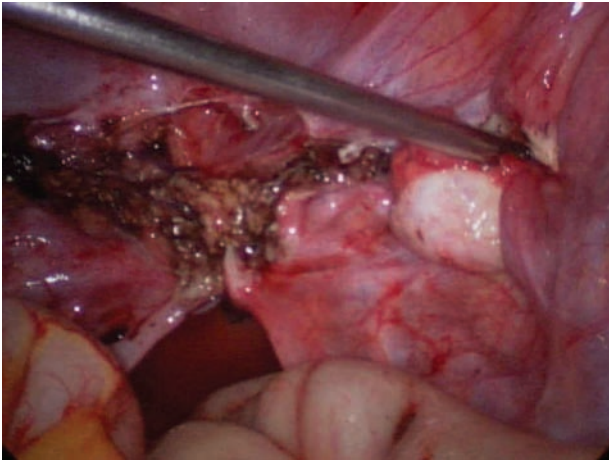


Figure 9.24 The side wall is inspected to follow the course of the ureter and check for hemostasis

just below the uterine vessels, and along the posterior vaginal wall with a few bites over to the right side. Finally, the same suture with needle is put through the right posterolateral vagina and cardinal ligament to the right uterosacral ligament.

This single suture is tied extracorporeally, bringing the uterosacral ligaments cardinal ligaments and posterior vaginal fascia together across the midline. It provides excellent support to the vaginal cuff apex, elevating it superiorly and posteriorly toward the hollow of the sacrum. It also serves to prevent a future enterocele by bringing together the endopelvic fascia from the uterosacral ligaments and rectovaginal fascia.

The rest of the vagina and overlying pubocervicovesicular fascia are closed vertically with one or two Vicryl 0 interrupted sutures. The peritoneum is not closed after TLH, but is closed following supracervical hysterectomy, to cover the cervical stump.

Cystoscopy

Cystoscopy is done after vaginal closure to check for ureteral patency, 10 minutes after intravenous administration of one ampule of indigo carmine dye. This is necessary when the ureter is identified but not dissected, and especially necessary when the ureter has not been identified. Blue dye should be visualized through both ureteral orifices. The bladder wall should also be inspected for suture and thermal defects.

Underwater examination

At the close of each operation, an underwater examination is used to detect bleeding from vessels and viscera tamponaded during the procedure by the increased intraperitoneal pressure of the CO₂ pneumoperitoneum. The CO₂ pneumoperitoneum is displaced with 2–4 l of Ringer's

lactate solution, and the peritoneal cavity is vigorously irrigated and suctioned until the effluent is clear of blood products. Any further bleeding is controlled underwater using microbipolar forceps to coagulate through the electrolyte solution, and at least 2 l of lactated Ringer's solution are left in the peritoneal cavity.

Skin closure

The umbilical incision is closed with a single Vicryl 4-0 suture opposing deep fascia and skin dermis, with the knot buried beneath the fascia. This will prevent the suture from acting as a wick, transmitting bacteria into the soft tissue or peritoneal cavity. The lower quadrant 5-mm incisions are loosely approximated with a Javid vascular clamp (Mueller, McGaw Park, IL) and covered with colloidion (AMEND, Irvington, NJ) to allow drainage of excess Ringer's lactate solution.

ENDOMETRIOSIS

Although excision of endometriosis with uterine preservation is almost always possible, hysterectomy should be reserved for women with severe pelvic pain that affects their quality of life, who do not desire fertility preservation. They require extensive counseling regarding alternatives, and may select hysterectomy as their primary procedure if they have persistent or recurrent symptoms after other surgeries, especially when uterine adenomyosis is suspected. Concomitant oophorectomy is elective.

The goal at laparoscopic hysterectomy for endometriosis is the same as for any endometriosis surgery, i.e. to excise all visible and palpable endometriosis implants⁸. The rectovaginal area can be particularly symptomatic, and requires careful evaluation and meticulous, systematic excision. The surgeon must first free the ovaries, then the ureters and finally the rectum from the posterior cervix and vagina to the rectovaginal septum. Deep fibrotic nodular endometriosis involving the cul-de-sac requires excision of the fibrotic tissue from the uterosacral ligaments, posterior cervix, posterior vagina and rectum. Hysterectomy with excision of all visible endometriosis usually results in relief of the patient's pain. Oophorectomy is not usually necessary at hysterectomy for advanced endometriosis if the endometriosis is removed carefully. The most severely affected ovary may be removed, especially if it is on the left, because this ovary frequently becomes adherent to the bowel. Reoperation for recurrent symptoms is necessary in fewer than 5% of the authors' patients in whom one or both ovaries have been preserved. Bilateral oophorectomy is rarely indicated in women younger than 40 years who undergo hysterectomy for endometriosis.

Hysterectomy should not be carried out for extensive endometriosis with extensive cul-de-sac involvement, unless the surgeon has the skill and time to resect all deep

fibrotic endometriosis from the posterior vagina, uterosacral ligaments and anterior rectum. In these patients, excision of the uterus using an intrafascial technique leaves the deep fibrotic endometriosis behind to cause future problems. Furthermore, removing deep fibrotic endometriosis may be more difficult when there is no uterus between the anterior rectum and bladder. After hysterectomy, the endometriosis left in the anterior rectum and vaginal cuff frequently becomes densely adherent to, or invades into, the bladder and one or both ureters. In many patients with extensive endometriosis and extensive cul-de-sac obliteration, it is preferable to preserve the uterus to prevent future vaginal cuff, bladder and ureteral problems. Obviously, this approach will not be effective when uterine adenomyosis is present. In these cases, after excision of cul-de-sac endometriosis, persistent pain ultimately requires a hysterectomy.

Endometriosis nodules in the muscularis of the anterior rectum can usually be excised laparoscopically without entering the rectum. Full-thickness penetration of the rectum can occur during hysterectomy surgery, especially when excising rectal endometriosis nodules. Following identification of the nodule or rent in the rectum, a closed circular stapler (Proximate™ ILS curved intraluminal stapler; Ethicon, Stealth) is inserted into the lumen just past the lesion or hole, opened 1–2 cm and held high to avoid the posterior rectal wall. The proximal anvil is positioned just beyond the lesion or hole, which is invaginated into the opening, and the device closed. Circumferential inspection is made to ensure the absence of encroachment of nearby organs and posterior rectum in the staple line and lack of tension in the anastomosis. The instrument is fired, then removed through the anus. The surgeon must inspect and ensure that the fibrotic lesion or a 'donut' of tissue representing the excised hole is contained in the circular stapler. When verified, anastomotic inspection is done laparoscopically under water after filling the rectum with indigo carmine solution or air^{13–15}.

Surgical technique to excise endometriosis (Figures 9.25–9.33)

Initially, adhesions from previous surgery are divided until the surgeon can visualize the pelvis. These adhesions frequently involve the omentum and small bowel. When these are all freed from the anterior abdominal wall and pelvis, the pelvic pathological findings are evaluated. Often the rectosigmoid is stuck to the left adnexa and uterus. Each ovary may be stuck to its adjacent pelvic side-wall and uterosacral ligament, often with enclosed endometriomas.

Thus, the steps in endometriosis hysterectomy are to free all pelvic organs, then excise the endometriosis and, finally, remove the uterus. Deep fibrotic nodular endometriosis that involves the cul-de-sac requires cul-de-sac dissection down to the loose areolar tissue of the recto-

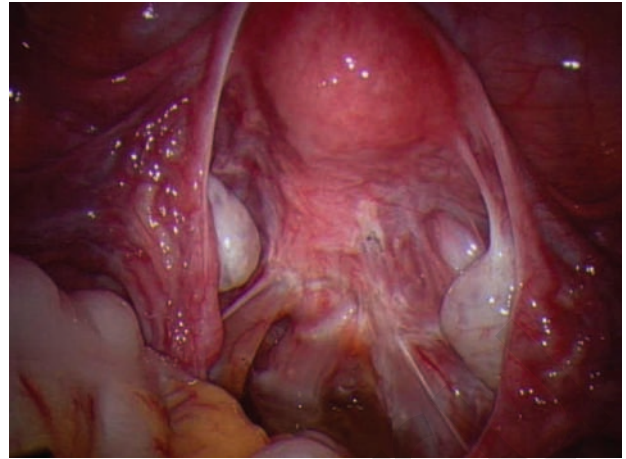


Figure 9.25 A Valtchev uterine manipulator (Conkin Surgical) elevates the uterus anteriorly, stretching out the cul-de-sac. Deep white fibrotic endometriosis is seen, with rectum stuck to posterior vagina and cervix

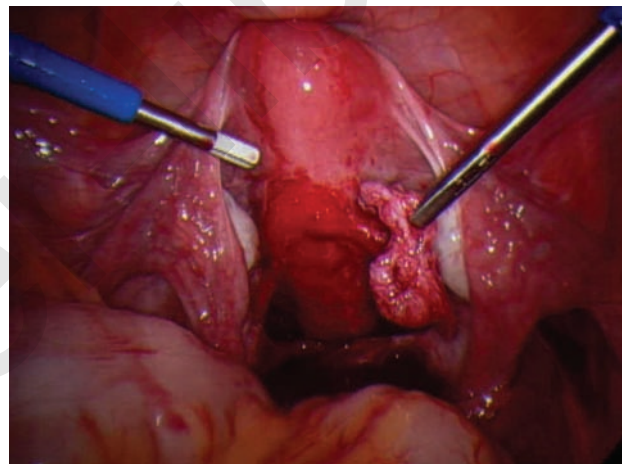


Figure 9.26 *En bloc* excision of the rectovaginal-cervical nodule is done using scissors

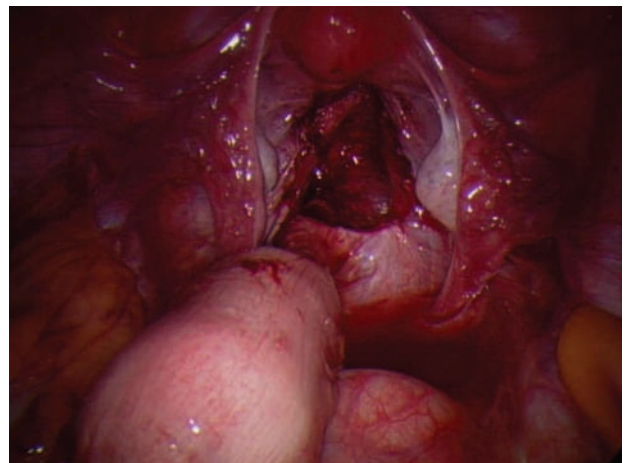


Figure 9.27 The rectal probe is advanced. Hemostasis is seen at the excision site

vaginal septum followed by excision of white fibronodular tissue from the uterosacral ligaments, posterior cervix, posterior vagina and anterior rectum. Less commonly, the sigmoid colon, its mesocolon and lateral rectum are involved⁸.

First, rectosigmoid dissection is done starting at the pelvic brim and working downwards. Attention is then directed toward dissection of the anterior rectum from the posterior vagina and cervix throughout its area of attachment until loose areolar tissue in the rectovaginal space is reached. This technique leaves the bulk of the lesion to be excised on the posterior vagina, including some that was more closely associated with the rectum. Using the rectal probe as a guide to rectal location, the rectal serosa is opened at its junction with the cul-de-sac lesion with scissors or the CO₂ laser. Careful sharp and blunt dissection ensues until the rectum, normal or with contained fibrotic endometriosis, is separated from the posterior uterus, cervix and upper vagina. After anterior rectal mobilization is complete, excision of the fibrotic endometriosis from the posterior vagina (the location of which is continually confirmed by a sponge in the posterior fornix), posterior cervix, including its uterosacral ligament insertions, and rectum is done. This procedure is often accomplished *en bloc* as one large specimen, including the insertions of both uterosacral specimens laterally, the anterior rectal component inferiorly and the posterior cervix–vagina superiorly. The blunt scissors is the main instrument used for this excisional dissection, with the tissue to be removed kept on traction using toothed biopsy forceps.

The ureter lies lateral to most cul-de-sac lesions. When the uterosacral ligament is pulled medially, very little risk of ureteral damage exists. When a ureter is close to the lesion, its course is traced starting at the pelvic brim, and when necessary, the peritoneum overlying the ureter is opened to confirm the ureteral position deep in the pelvis.

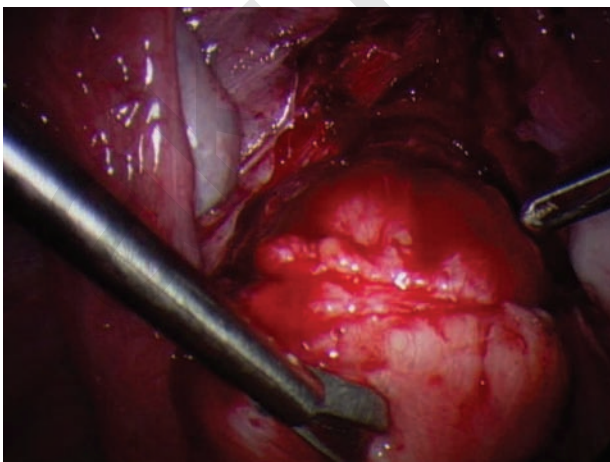


Figure 9.28 A fibrotic band of endometriosis remains across the rectum with resultant early stricture. This will be excised using cold scissors

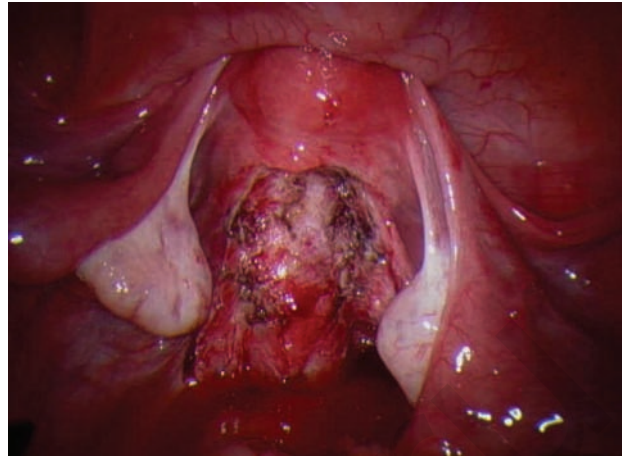


Figure 9.29 After excision of all endometriosis implants, hemostasis is achieved

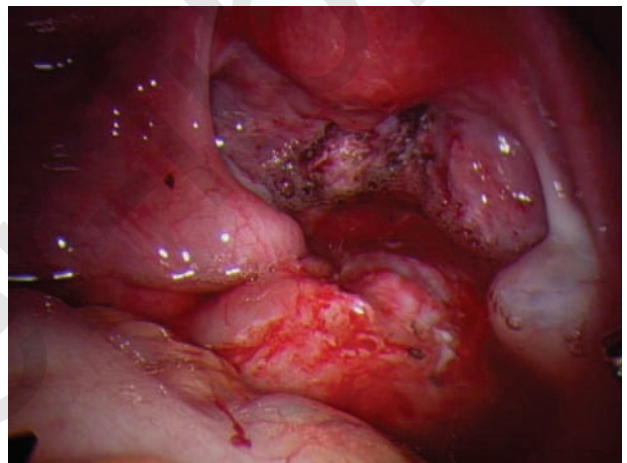


Figure 9.30 Following removal of the rectal stricture, air and dye are instilled via a Foley catheter into the rectum to check for occult perforation and devascularized areas

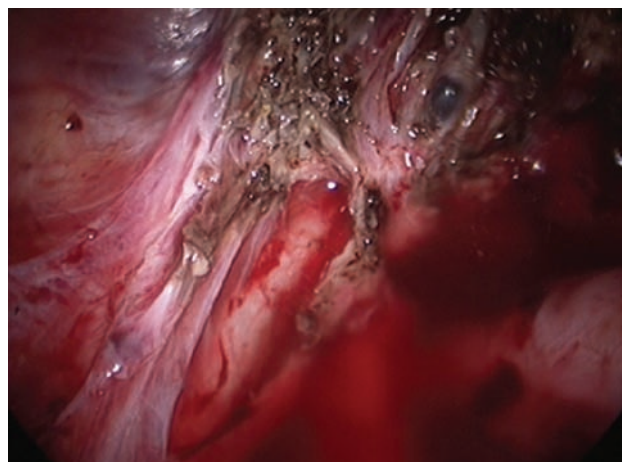

Figure 9.31 The left ureter is inspected and seen traversing the pelvic side wall

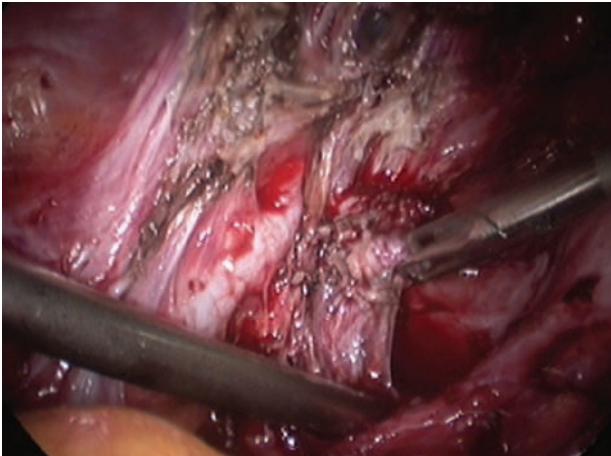


Figure 9.32 An endometriosis nodule just beneath the left ureter is excised

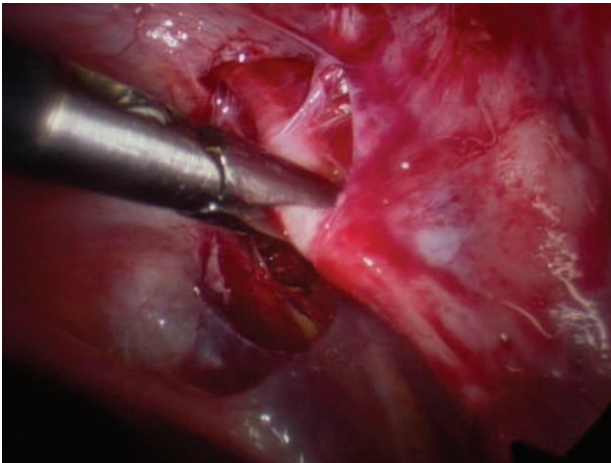


Figure 9.33 The right ureter is grasped and dissected with an atraumatic forceps and endometriosis overlying it excised

Uterosacral fibrotic endometriosis may envelop the ureter, necessitating deep ureteral dissection and excision of the surrounding endometriosis. Microbipolar forceps with irrigation between the tips are used to control arterial and venous bleeding around the ureter.

Uterosacral ligaments infiltrated with endometriosis are removed early in the operation, sometimes before rectal mobilization. They frequently make up a large portion of a rectal nodule. The uterosacral ligament is divided lateral to the rectum where the normal-caliber ligament meets the distended fibrotic ligament and is put on traction. The peritoneum is incised on both sides of the ligament, and the thickened portion of the ligament is excised to, and including, its insertion into the cervix. Soft, loose areolar tissue, adipose tissue, uterine vessels and the ureter are present beneath the ligament. Fibrotic tissue left at the periphery of the excision is coagulated with an

irrigating microelectrode, especially at the junction of the cervix with the uterine fundus. Rarely, the ligament will be involved all the way to the sacrum. In these cases, it may be best to divide the middle of the ligament and, with traction on the sacral side of the ligament, pull it away from the rectum, ureter and hypogastric vessels.

Dissection of the fibrotic endometriosis from the thickened vaginal wall proceeds using traction with a biopsy forceps to pull the lesion from one side to the other. Laser, hydrodissection, electrosurgery or scissors are used as needed. Often, with traction and the help of vaginal distension from below using a vaginal sponge pushed forward by a ring forceps, a distinct dissection plane becomes evident above or beneath the rectovaginal fascia, and the lesion can be pulled free from the vaginal wall. Sometimes, an endopelvic rectovaginal fascial layer, infiltrated with endometriosis, is identified, and after this layer is excised, soft, pliable upper posterior vaginal wall is uncovered. Hypertrophied tissue without endometriosis is often present at the cervicovaginal junction between the insertion of the uterosacral ligaments into the cervix, making it difficult to distinguish accurately fibrotic endometriosis from fibromuscular tissue. This inverted 'u' configuration should be excised or at least biopsied.

Bowel surgery (Figures 9.34–9.39)

Endometriosis of the rectum and rectosigmoid may be superficial (serosal or adventitial), in the muscle (muscularis) or full thickness involving both the muscularis and lamina propria of the mucosa; the mucosal surface is rarely broken. The lesions are anterior or lateral. Posterior wall endometriosis is a rarity, but can form a 'napkin ring' deformity. Fibrotic endometriosis nodules infiltrating the anterior rectal wall are most common and may be focal (cicatrical) or linear (a transverse bar often with associated stricture where the rectum is fused to the posterior vagina). Under the microscope, all these lesions, and those of the uterosacral ligaments, posterior vagina and cervix,

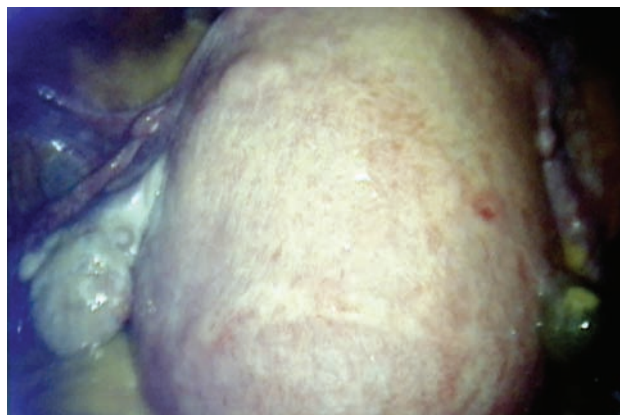


Figure 9.34 A large fibroid uterus fills the pelvis

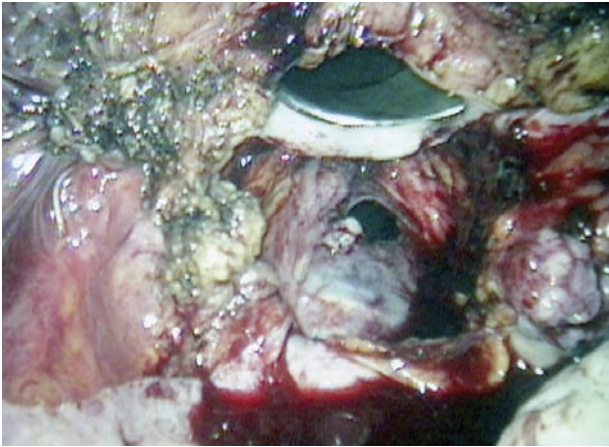


Figure 9.35 Following total laparoscopic hysterectomy and vaginal morcellation of the fibroid uterus, a rectal perforation is discovered. Note the posterior rim of the vaginal delineator in the open vagina above the enterotomy

are made up of fibromuscular tissue surrounding endometriosis glands and characteristic stroma.

Women with suspected or documented extensive endometriosis are counseled preoperatively regarding the risk of bowel injury, methods of possible treatment and the impact of bowel perforation and resection on their hospital stay and postoperative recuperation. The risk of unplanned rectal perforation is appreciated with any kind of intervention near the bowel, but is particularly threatening with excision of rectosigmoid endometriosis due to the fibrotic nature of the disease and related anatomic distortion. Traditionally, laparoscopic rectal injury has been treated with laparotomy closure, sometimes with colostomy. This approach, while necessary in rare cases, is more stressful for the patient, both physically and emotionally, as she must then endure the incisional surgery she had elected to avoid. Laparoscopic repair of the bowel with suture or staples is used for most bowel injuries both planned and unplanned.

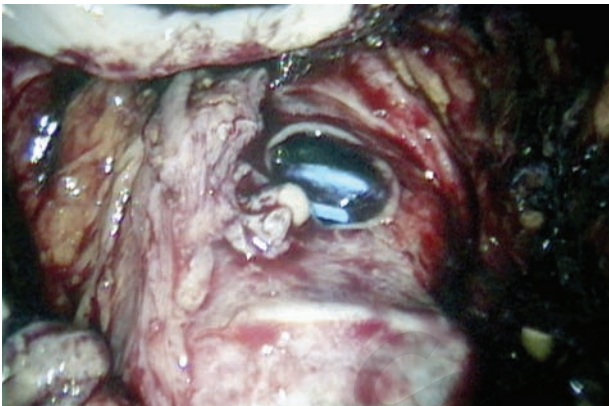


Figure 9.36 A circular stapler is positioned beneath the enterotomy, which is invaginated into the stapler device

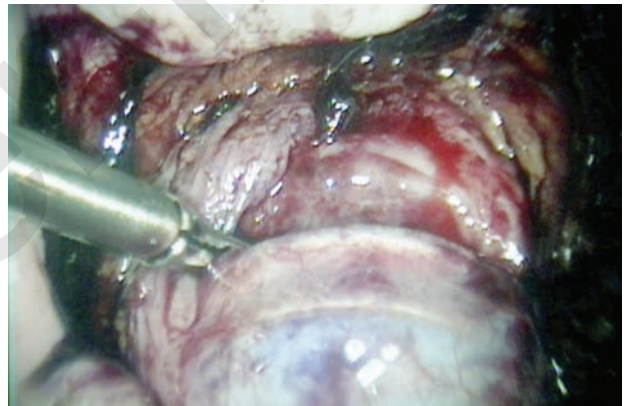


Figure 9.38 The stapler is closed, incorporating the hole

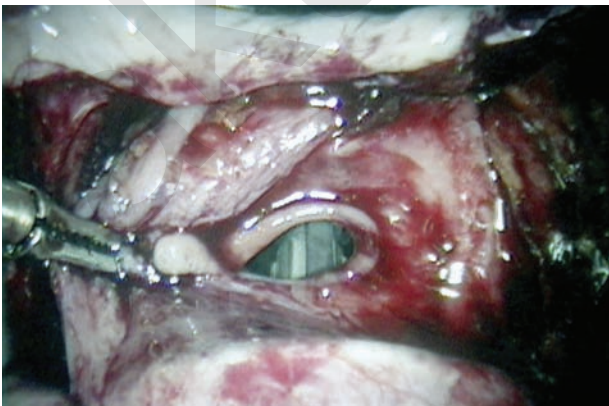


Figure 9.37 The hole is invaginated into the stapler device

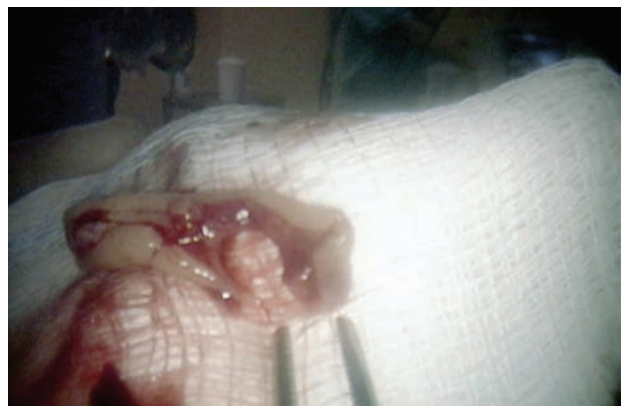

Figure 9.39 The excised area is examined on a sponge. The hole has been completely excised

Knowledge that the bowel can be successfully repaired laparoscopically should increase the confidence of the surgeon operating in the deep pelvis. Suturing experience is suggested for laparoscopists who perform extensive endometriosis surgery.

When separated from the vagina, the rectum and rectosigmoid are examined carefully with the aid of a long blunt probe. Lesions are assessed to determine whether they are superficial, deep or nodular. Superficial lesions that involve the serosa or adventitia are excised by making an elliptical incision around the white fibrotic lesion with a scissors or a CO₂ laser at low power, elevating the lesion with a micro-toothed forceps, and undermining it at its junction with soft, normal-appearing circular muscularis.

Endometriotic nodules infiltrating the anterior rectal wall are excised, partially or totally, usually with a probe or the surgeon's finger in the rectum beneath the lesion. Working with scissors or the CO₂ laser at the junction of nodular white fibrosis with yellow and pink soft normal tissue, the lesion is excised. Deep rectal muscularis defects are closed with suture. The 3-0 suture is applied using curved needles, and the knot tied outside the peritoneal cavity and pushed downward with the Clarke-Reich knot pusher. Enterotomies and full muscularis excisions are closed with suture or the circular stapler.

Nodules in the muscularis of the anterior or lateral rectum can usually be excised laparoscopically⁹. Full-thickness penetration of the rectum may occur during this surgery. Following identification of the rent in the rectum, usually surrounded by fibrotic endometriosis, a 29- or 33F closed circular stapler (Proximate ILS curved intraluminal stapler) is inserted into the lumen just past the hole, opened 1–2 cm and held high to avoid the posterior rectal wall. The proximal anvil is positioned just beyond the hole invaginated into the opening, and the device closed. Circumferential inspection is made to ensure the absence of encroachment of nearby organs and posterior rectum in the staple line and lack of tension in the anastomosis. The instrument is fired, then removed through the anus. Often, a single suture is placed across the hole and used to guide the hole into the stapler. Anastomotic inspection is done laparoscopically under water after filling the rectum with indigo carmine solution.

Full-thickness or muscularis endometriotic nodules of the anterior or lateral rectum also can be resected laparoscopically without opening the rectum, especially if limited to a small circumscribed area. Following delineation of the nodule, the 29- or 33F circular stapler (Proximate) is used as described above, and the lesion invaginated into its opening. This process results in an anterior discoid resection of a wedge of anterior rectum with contained nodule and an anterior staple line. Strictures are often made up of appendices epiploica fused to fibrotic endometriosis implants on the sigmoid colon. Careful methodical dissection using a laser to separate

these fatty appendages and microbipolar forceps for hemostasis may alleviate the stricture.

POSTOPERATIVE CONSIDERATIONS

Most patients are hospitalized overnight after laparoscopic hysterectomy surgery. Patients usually experience some fatigue and discomfort for approximately 1–2 weeks after the operation, but may perform gentle exercise, such as walking, and return to routine activities within 1 week. Sexual activity may be resumed usually after 4 weeks. Examinations within 1 week are indicated for pain, pressure or pyrexia. Routine checks at 1–6 weeks are usually not indicated, as a pelvic examination could impede healing.

After bowel surgery, bowel function returns after an average of 24–30 hours; less inflammation and edema occur after staple than suture bowel closure. Upon passage of flatus or a bowel movement, the patient is started on a diet as tolerated. Usually the patient starts liquids in the morning of the first postoperative day and advances to solids in the afternoon if the morning diet was well tolerated.

COMPLICATIONS

Laparoscopic hysterectomy has clear benefits such as less analgesic requirements, and shorter hospital stay and convalescence. Most series document longer procedure times when compared with abdominal or vaginal hysterectomy, and use this as an argument against laparoscopic hysterectomy. With experience, the length of the procedure and rate of both major and minor complications should decrease. In a review of 1647 cases performed between 1989 and 1999, Wattiez *et al.* determined a significant reduction in major complications, hemorrhage and transfusion, urinary tract injuries and laparoconversions when the group of patients was separated into an early group of 695 patients and a later group of 952¹⁹. During the 10-year period, total complications were reduced from 10.4 to 2.6%, major complications from 5.6 to 1.3% and mean length of surgery from 115 to 90 minutes. Urinary tract injuries, including bladder lacerations and ureteral injuries, decreased from 2.2 to 0.9%.

A recent Finnish publication evaluated the surgical morbidities associated with more than 10 000 hysterectomies (2434 performed laparoscopically), and determined that a significant reduction existed in the number of ureteral injuries (2.2% vs. 0.5%) and bladder injuries (2.0% vs. 0.8%) after the operator had performed at least 30 such procedures²⁰. These two studies suggest that the infrequent and surgically correctable complications that occur with the laparoscopic approach diminish significantly with experience.

Complications of laparoscopic hysterectomy are those of hysterectomy and laparoscopy combined: anesthetic accidents, respiratory compromise, thromboembolic phenomena, urinary retention and injury to vessels, ureters, bladder and bowel, as well as infections, especially of the vaginal cuff²¹. Ureteral injury is more common when staplers or bipolar desiccation are used without ureteral identification. Complications unique to laparoscopy include large vessel injury, epigastric vessel laceration, subcutaneous emphysema and trocar site incisional hernias²². Port site herniations are a rare event, typically occurring less than 1% of the time, with most occurring at extraumbilical sites following the use of 12-mm trocar sleeves for Endo GIA application.

Some of the above-listed complications that are related more to laparoscopic hysterectomy are discussed separately.

Infection

Febrile morbidity associated with a vaginal hysterectomy is about half that associated with the abdominal procedure. Laparoscopic evacuation of all blood clots and the sealing of all blood vessels after the uterus has been removed should further reduce the infection rate. Morcellation during laparoscopic or vaginal hysterectomy results in a slightly increased risk of fever, especially if prophylactic antibiotics are not used. Experience with serious wound infection after laparoscopic hysterectomy is rare.

Since the introduction of prophylactic antibiotics, vaginal cuff infection is rare. This infection can result in pelvic cellulitis, septicemia, vaginal cuff abscess, adnexal abscesses and pelvic thrombophlebitis. Abdominal trocar wound infection is also rare.

These authors' patients have experience with two cases of pelvic cellulitis and three pelvic abscesses in over 500 laparoscopic hysterectomies.

We now use one dose of a prophylactic antibiotic after induction of anesthesia in all cases. Interestingly, no antibiotic was administered in four of the five cases of infection. All of these cases involved a return to hospital and much patient dissatisfaction.

To decrease postoperative infection, the surgeon should evacuate all large clots, obtain absolute hemostasis and then carry out copious irrigation to dilute fibrin and prostaglandins arising from operated surfaces and bacteria. We believe that leaving 1–2 l of lactated Ringer's solution in the peritoneal cavity dilutes the peritoneal cavity bacterial and blood product counts, and prevents fibrin adherences from forming by separating raw, compromised surfaces during the initial stages of reperitonealization, especially after hysterectomy or bowel resection. No other antiadhesive agents are employed. No drains, antibiotic solutions or heparin are used.

Urinary tract infection, unexplained fever and pneumonia also are rare after LAH. Early cessation of both the Foley catheter and the intravenous line within 2 hours

of the end of the operation, followed by early ambulation, may reduce postoperative atelectasis and urinary tract infections.

Hemorrhage

Intraoperative hemorrhage occurs when a previously non-anemic patient loses greater than 1000 ml of blood or requires a blood transfusion. By doing careful laparoscopic dissection, most profuse hemorrhage situations are avoided, or controlled as they occur.

Postoperative hemorrhage is any bleeding event that requires therapy, either conservative or operative. Postoperative hematomas were frequent with the early use of the Multifire Endo GIA 30 (US Surgical, Norwalk, CT) for the upper uterine pedicle during hysterectomy and oophorectomy.

Transfusion rates are often misleading, as they usually include autologous blood, which may be given back to the patient on a routine basis. Currently autologous blood is obtained rarely, because of the reluctance of most anesthesiologists to transfuse it.

Urinary tract complications: prevention and detection

Ureteral and bladder injuries may be expected with complicated cases, but are less suspected in routine operations, and failure to recognize them during these cases or suspect them early postoperatively results in much patient dissatisfaction. These injuries most commonly are associated with laparoscopic ligation of the uterine artery, but surgeons must be aware that both bladder and ureteral injury may occur during the 'easy' vaginal part of a LAVH.

While ureteral protection is advocated by all, how best to achieve it is hotly disputed. These authors remain committed to the prevention of ureteral injury intraoperatively by ureteral identification, often with dissection and by cystoscopy, at the conclusion of the procedure. Isolation by ureteral dissection has been criticized for unnecessarily adding time to the procedure, but this is time well spent if ureteral risk is diminished.

Ureteral stents are not used routinely, although both lighted and infrared catheters are available. Most patients who have stent placement experience postoperative hematuria; anuria from ureteral spasm following surgery with a stent in place has been reported. Ureteral catheters are necessary when ureteral injury occurs during surgical dissection or the release of a ureteral stricture; in these cases the stent is left in place for 6 weeks. Ureteral stricture can be treated by dividing the stricture longitudinally and closing it transversely, or by leaving the resultant ureterotomy open over a JJ stent connecting the kidney to the bladder.

Cystoscopy is done in all hysterectomy cases after the vaginal cuff is closed, to check for ureteral patency and bladder injury. Failure to see dye through a ureter can

result from ureteral ligation (placement of a suture into or around the ureter), kinking from pulling endopelvic ureteral fascia towards the midline during the high McCall culdoplasty or ureteral spasm if a ureteral stent was used. Cystoscopy also confirms bladder wall continuity, and detects intravesicular suture placement and thermal injury that will be seen as a patchy white area. Suture is used instead of staples or bipolar desiccation for uterine artery ligation, as suture can be removed if a ureteral obstruction or a bladder suture is noted on cystoscopy. This has been necessary on more than one occasion^{23,24}.

The ureters are commonly injured at the level of the infundibulopelvic ligament, uterosacral ligament or pelvic side-wall due to adhesions resulting from endometriosis, pelvic inflammatory disease or previous abdominal surgery. During laparoscopic hysterectomy, ureteral injury may occur while cutting dense adhesions and fibrotic scar tissue, while trying to stop bleeding close to the ureter with bipolar cautery or in the process of ligating the uterine vessels with bipolar electrosurgery, staples or suture. Most ureteral injuries are not identified or even suspected without cystoscopy. Without cystoscopic availability, one can expect problems. This is particularly true during TLH, even if the surgeon is visually able to identify the ureters. Normal peristalsis may occur in the damaged ureter.

In our experience, all but the grossest of ureteral injuries are discovered during the cystoscopic examination near the end of the operation. These injuries cannot usually be identified laparoscopically. If no dye is seen flowing from the ureter, the surgeon should first try to pass a ureteral catheter. If it passes without resistance the ureter is fine. If it does not pass, the surgeon should systematically trace the ureter down into the deep pelvis. Previously ligated vessels must be isolated, skeletonized and released from all ureteral attachments. Sometimes this entails release of the suture followed by religation. Continued attempts to pass the stent should be made while the laparoscopic dissection ensues. The dissection stops when the stent passes.

Careful techniques of bladder dissection are important. In difficult cases, the bladder may invaginate into a cesarean section scar and be surrounded by uterine myometrium. When the bladder location is obscured, the surgeon should fill it intermittently during the procedure to check its position and keep the dissection at its junction with uterine muscle.

Urinary retention is a common undetected complication. Most people who undergo general anesthesia experience some degree of temporary inability to contract their bladder musculature voluntarily. It can take weeks for the bladder to regain normal tone if retention occurs. Postoperative urinary retention is more likely with the use of large amounts of irrigant and hydroflotation, as urine can accumulate rapidly in the bladder of a drowsy patient recovering from anesthesia. The Foley catheter should not be removed at the end of

operative procedures lasting longer than 2 hours until the patient is awake and aware that the catheter is in place, usually 1 hour postoperatively. In centers where intravenous fluids are not discontinued soon after the operation, the Foley catheter should be kept in longer. A useful protocol if spontaneous voiding does not occur within 3–4 hours after the catheter is removed is to carry out straight catheterization every 4 hours until spontaneous voiding occurs.

Some endoscopically related injuries to the urinary tract may not become apparent for a few days following surgery. Although the incidence of these complications is low, the surgeon should nevertheless be aware of the risks, and look for signs of such injuries that might have occurred. Unexplained fever, abdominal pain, back pain or abdominal distension may be signs of some injury and should be investigated.

Postoperative recognition of an insult to ureteral integrity is made early by obtaining a single-shot intravenous pyelogram (IVP) in anyone reporting lateralized pain of any kind – abdominal, flank or back. Uncontrollable loss of urine 1–2 weeks postoperatively requires an aggressive work-up to determine whether a ureterovaginal or vesicovaginal fistula is present. Treatment is with a Latzko operation for vesicovaginal fistula, and long-term catheter placement or surgical reimplantation for ureterovaginal fistula.

The bottom line is that an aggressive approach to ureteral protection can reduce but not eliminate ureteral injury. However, prompt recognition and management can prevent multiple surgical procedures and significant patient morbidity, including organ loss.

Bladder injury

Bladder injury can occur during dissection of the bladder off the uterus and cervix or from an inflamed adnexa. In these cases the bladder is repaired using Vicryl 3-0 usually in two layers.

Intravesicular thermal injury can be suspected by cystoscopic visualization of a white patch above the bladder trigone. The area should be reinforced with a laparoscopically placed suture into the bladder musculature surrounding the potential defect.

Bowel injury

Small-bowel injury during laparoscopic hysterectomy is uncommon, and is usually associated with extensive intraperitoneal adhesions. Small-bowel injuries can be suture-repaired. Small-bowel enterotomy may require mobilization from above, delivery through the umbilicus by extending the incision 1 cm and repair or resection. If the hole is confined to the antimesenteric portion, the bowel can be closed with interrupted 3-0 silk or Vicryl. All enterotomies are suture-repaired transversely to reduce the risk of stricture. If the hole involves greater than 50%

of the bowel circumference, resection is done. An extracorporeal segmental enterectomy with side-to-side stapled anastomosis is preferred.

Rectal injury may occur during rectal endometriosis excision or during vaginal morcellation of a large fibroid uterus. Repair is the same as described above in the 'Endometriosis' hysterectomy section¹⁴.

CONCLUSION

Laparoscopic hysterectomy is clearly beneficial for patients in whom vaginal surgery is contraindicated or cannot be done. When indications for the vaginal approach are equivocal, laparoscopy can be used to determine whether vaginal hysterectomy is possible. With this philosophy, patients avoid an abdominal incision with a resultant decrease in length of hospital stay and recuperation time. The complication of abdominal wound dehiscence can be eliminated and cuff infection reduced. Although laparoscopic hysterectomy is not without complications, the incidence is low, and many intra- and postoperative complications can be managed laparoscopically.

The laparoscopic surgeon should be aware of the risks and how to minimize them, and, when they occur, how to repair them laparoscopically. The participating surgeon's skill and experience with innovative techniques and instruments requires continuous training. All the anticipated advantages of laparoscopic hysterectomy can be lost if the surgeon ventures beyond his level of comfort.

REFERENCES

1. Reich H. Laparoscopic hysterectomy. *Surg Laparosc & Endosc* 1992; 2: 85–8
2. Liu CY. Laparoscopic hysterectomy: a review of 72 cases. *J Reprod Med* 1992; 37: 351–4
3. Liu CY. Laparoscopic hysterectomy. Report of 215 cases. *Gynaecol Endosc* 1992; 1: 73–7
4. Reich H, DeCaprio J, McGlynn F. Laparoscopic hysterectomy. *J Gynecol Surg* 1989; 5: 213–16
5. Johns DA, Carrera B, Jones J, et al. The medical and economic impact of laparoscopically assisted vaginal hysterectomy in a large, metropolitan, not-for-profit hospital. *Am J Obstet Gynecol* 1995; 172: 1709–19
6. Lower AM, Hawthorn RJS, Ellis H, et al. The impact of adhesions on hospital readmissions over ten years after 8849 open gynaecological operations. *Br J Obstet Gynaecol* 2000; 107: 855–62
7. Farquhar CM, Steiner CA. Hysterectomy rates in the United States 1990–1997. *Obstet Gynecol* 2002; 99: 229–34
8. Reich H, McGlynn F, Sekel L. Total laparoscopic hysterectomy. *Gynaecol Endosc* 1993; 2: 59–63
9. Kilkku P, Gronroos M, Hirvonen T, Rauramo L. Supravaginal uterine amputation vs. hysterectomy. Effects on libido and orgasm. *Acta Obstet Gynecol Scand* 1983; 62: 147–52
10. Lyons TL. Laparoscopic supracervical hysterectomy. A comparison of morbidity and mortality results with laparoscopically assisted vaginal hysterectomy. *J Reprod Med* 1993; 38: 763–7
11. Reich H, McGlynn F, Salvat J. Laparoscopic treatment of cul-de-sac obliteration secondary to retrocervical deep fibrotic endometriosis. *J Reprod Med* 1991; 36: 516–22
12. Redwine DB, Wright JT. Laparoscopic treatment of complete obliteration of the cul-de-sac associated with endometriosis: long-term follow-up of en bloc resection. *Fertil Steril* 2001; 76: 358–65
13. Cul-de-sac endometriosis. In Hulka J, Reich H, eds. *Textbook of Laparoscopy*, 3rd edn. Philadelphia: WB Saunders Company, 1998: 518–19, 405–6
14. Reich H, McGlynn F, Budin R. Laparoscopic repair of full-thickness bowel injury. *J Laparoendosc Surg* 1991; 1: 119–22
15. Reich H, Wood C, Whittaker M. Laparoscopic anterior resection of the rectum and hysterectomy in a patient with extensive pelvic endometriosis. *Gynecol Endosc* 1998; 7: 79–83
16. Bridgman SA, Dunn KM. Has endometrial ablation replaced hysterectomy for the treatment of dysfunctional uterine bleeding? National figures. *Br J Obstet Gynaecol* 2000; 107: 531–4
17. Clarke HC. Laparoscopy – new instruments for suturing and ligation. *Fertil Steril* 1972; 23: 274–7
18. Reich H, Clarke HC, Sekel L. A simple method for ligating in operative laparoscopy with straight and curved needles. *Obstet Gynecol* 1992; 79: 143–7
19. Wattiez A, Soriano D, Cohen SB, et al. The learning curve of total laparoscopic hysterectomy: comparative analysis of 1647 cases. *J Am Assoc Gynecol Laparosc* 2002; 9: 339–45
20. Makinen J, Johansson J, Tomas C, et al. Morbidity of 10,110 hysterectomies by type of approach. *Hum Reprod* 2001; 13: 431–6
21. Liu CY, Reich H. Complications of total laparoscopic hysterectomy in 518 cases. *Gynaecol Endosc* 1994; 3: 203–8
22. Kadar N, Reich H, Liu CY, et al. Incisional hernias after major laparoscopic gynecologic procedures. *Am J Obstet Gynecol* 1993; 168: 1493–5
23. Ribeiro S, Reich H, Rosenberg J. The value of intraoperative cystoscopy at the time of laparoscopic hysterectomy. *Hum Reprod* 1999; 14: 1727–9
24. Chapron C, Dubisson JB. Ureteral injuries after laparoscopic hysterectomy [Letter]. *Hum Reprod* 2000; 15: 733–4

Part 2
Tubal pathology and ovarian pathology

akusherlib.ru

akusher-lib.ru

Fertiloscopy

A Watrelot

INTRODUCTION

The diagnosis of the cause of infertility is not always easy, especially when it is necessary to establish the status of the Fallopian tubes and the relationship between the tubes and the ovaries. Hysterosalpingography (HSG) is very often applied for this purpose, but this examination is of value only when it shows complete tubal blockage. In other cases, the rate of false negatives and even false positives is very high, as shown by laparoscopy. In a meta-analysis, Swart *et al.*¹ found a point estimate of 0.65 for HSG sensitivity and 0.83 for HSG specificity, and underlined the fact that HSG is not suitable for the evaluation of periadnexal adhesions.

By contrast, laparoscopy is considered the gold standard to explore tuboperitoneal infertility. Nevertheless, laparoscopy is very often performed without discovering any significant pathology.

Unfortunately, laparoscopy presents some risks that can be very serious, as recently shown in the French register of laparoscopic accidents, where six major injuries occurred in diagnostic laparoscopies². The result is either a delay in laparoscopy, which can be detrimental to the patient, for instance if an *in vitro* fertilization (IVF) procedure is decided on the basis of a wrong diagnosis, or having to conduct a great number of normal laparoscopies, with the potential risks that accompany such procedures.

Other diagnostic procedures, such as hysterosonography or falloscopy, are not sufficiently accurate to warrant a therapeutic strategy. Culdoscopy could have been an alternative method, but was abandoned in the 1970s in its classic version, in favor of laparoscopy.

More recent improvements have been suggested, such as the use of dorsal decubitus³, hydroflotation⁴ and

transvaginal hydrolaparoscopy, which provides very good imaging of the pelvis⁵.

Following this initial work, we defined the concept of fertiloscopy⁶⁻⁸ as the combination of transvaginal hydropelviscopy, a dye test, salpingoscopy, microsalspingoscopy and, finally, hysteroscopy performed under strict local anesthesia (Figure 10.1).

TECHNIQUE

Instrumentation

Single-use introducers

Fertiloscopy uses specific instrumentation of the single-use type. The rest of the equipment is the same as that used for gynecological laparoscopy, even if a special scope is required to exploit all the possibilities afforded by fertiloscopy.

Specially designed disposable introducers are the key to performing fertiloscopy. They come in a kit containing two introducers, one for the uterine cavity and the other for the pouch of Douglas (Figure 10.2).

The uterine introducer (FH 1.29; www.fertiloscopy.com) is fitted with a balloon in order to ensure a good seal during the dye test. It also has a smooth mandrel to allow easy insertion into the uterine cavity. Once in place, the mandrel is removed, and, due to the flexible nature of the introducer, it can be fixed to the patient's thigh with the Velcro[®] provided.

The Douglas introducer (FTO 1.40; www.fertiloscopy.com) has three channels. The central one is equipped

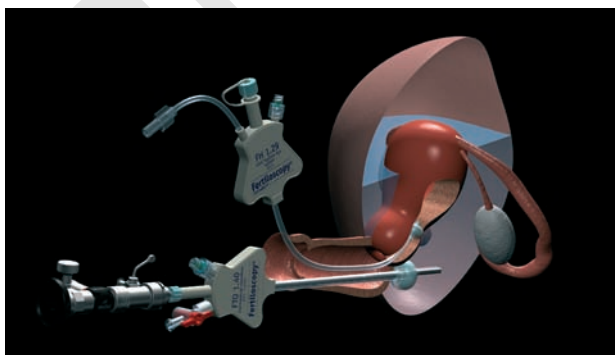


Figure 10.1 Principle of fertiloscopy




Figure 10.2 Fertiloscopy[®] introducers

with a sharp mandrel to enable insertion into the pouch of Douglas. It is then replaced by the telescope. The second channel allows inflation of the balloon located at the tip of the introducer. The balloon is of paramount importance: first, it prevents the introducer from slipping involuntarily out of the abdominal cavity; second, by pulling on the introducer, the pouch of Douglas can be stretched, providing a better view; third, the balloon acts as a ball-joint from which the telescope can be angled in every direction. The last lumen is an operative channel allowing the use of 5F instrumentation as an outflow channel (Figure 10.3).

Veress needle

A Verres needle is necessary, and it is possible to use either a disposable or a reusable one. The important point is to ensure that the safety mechanism works normally.

Fertiloscope

To perform fertuloscopy, it is necessary for the telescope to have a diameter not greater than 4 mm and a 30° lens. In practice, the use of the Hamou II telescope (Storz, Germany) is strongly recommended for several reasons: its 2.9-mm diameter, 30° foroblique vision and ×120 magnification make it the only telescope capable of performing microsalspingoscopy (Figure 10.4).

Additional instrumentation

The Douglas introducer has an operative channel allowing the use of 5F instrumentation. Biopsy forceps, grasping forceps and scissors are used (Figures 10.5 and 10.6).

Bipolar coagulation (which is the only electrical option with a saline medium) is also useful, by means of electrode or bipolar forceps.

Room set-up

The patient needs to be in the gynecological position. The Trendelenburg position is not required, and slight procubitus is even recommended. Monitors and cold light are installed on a mobile videocart located to the left of the patient. Saline solution is administered from the right by means of a standard infusion set-up.

Technique

The technique of fertuloscopy is rather simple. Nevertheless, it has to be very precise if one is to avoid problems.

Preparation of the patient

Preparation of the colon is useful in order to deflate it and, thus, to increase the safety space in the pouch of Douglas.

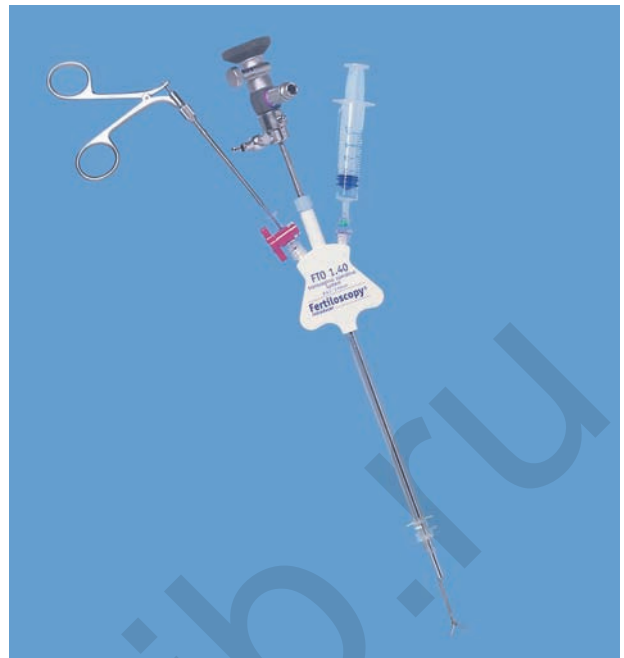


Figure 10.3 FTO 1.40 device with Hamou II telescope, syringe and grasping forceps




Figure 10.4 Hamou II telescope with its sheath

In practice, a mini-enema such as Normacol® is commonly used.

Careful vaginal examination has to be performed prior to fertuloscopy in order to detect any obstructive Douglas pathology, such as a pelvic mass prolapsed in the cul-de-



Figure 10.5 Special atraumatic grasping forceps



Figure 10.6 5F instrumentation. From left to right: scissors, biopsy forceps, grasping forceps

sac, or endometriosis of the rectovaginal septum, which are contraindications to the technique (Figures 10.7–10.15).

Anesthesia

Fertiloscopy can be performed either under general anesthesia, or under strict local anesthesia without any general sedation. Here, we describe the technique of local anesthesia. We start by inserting an anesthetic gel into the

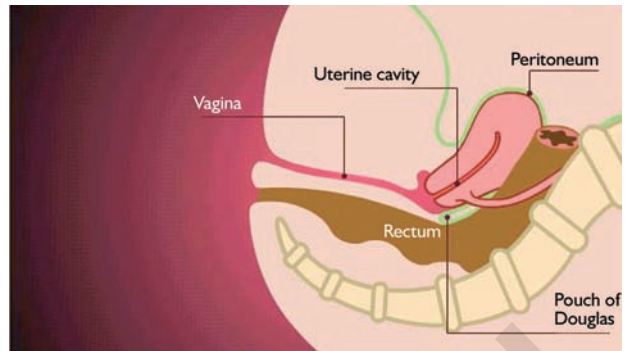


Figure 10.7 Sagittal section of the pelvis

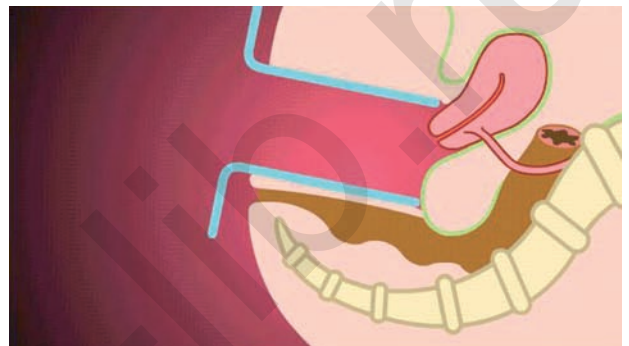


Figure 10.8 The cervix is exposed

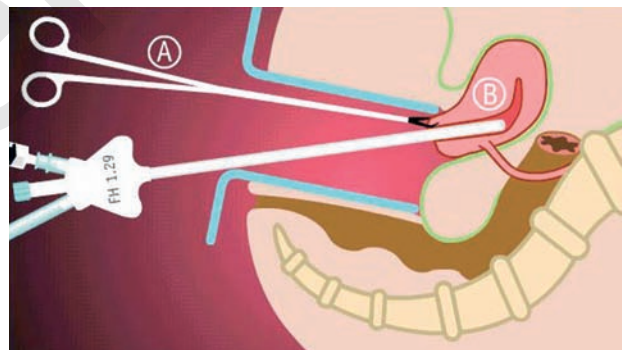


Figure 10.9 (A) Pozzi forceps are attached at 8 o'clock. (B) The uterine introducer is inserted (FH 1.29)

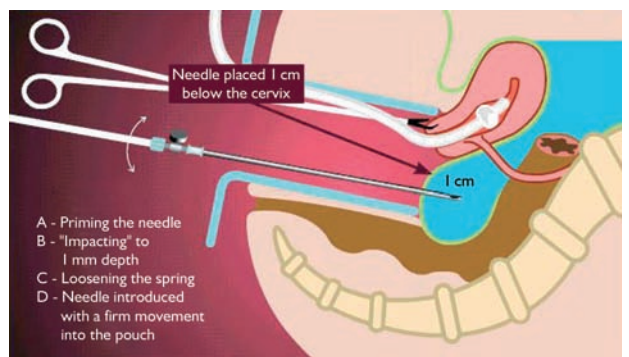


Figure 10.10 Insertion of the Veress needle and creation of a hydroperitoneum with saline solution

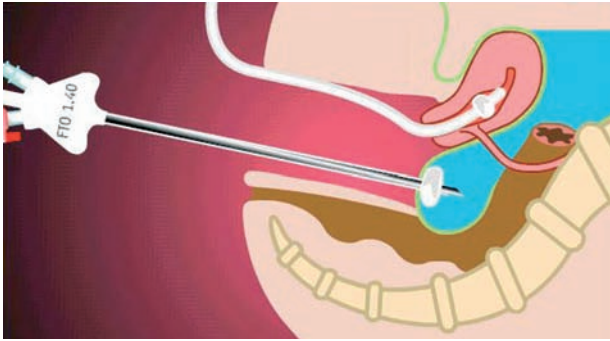


Figure 10.11 Insertion of the Douglas introducer (FTO 1.40)

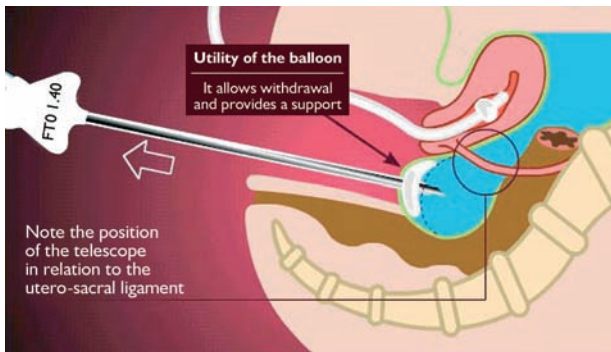


Figure 10.12 The fertiloscope is introduced

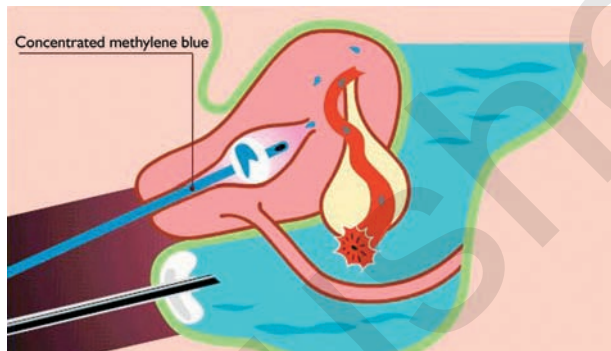


Figure 10.13 Dye test

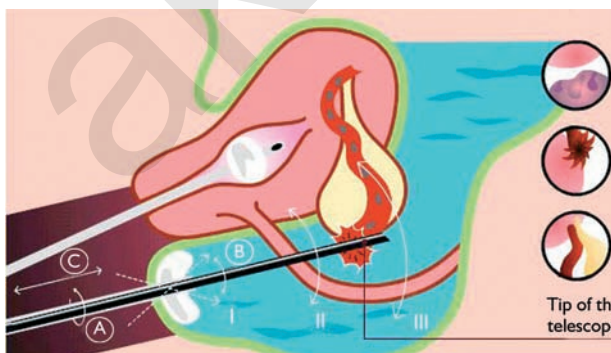


Figure 10.14 The three necessary movements for a complete view

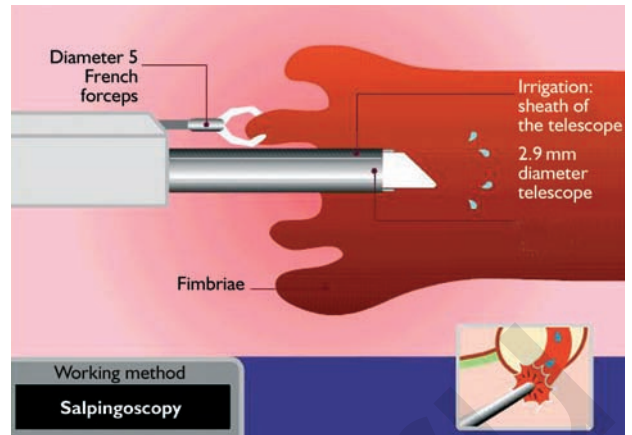


Figure 10.15 Salpingoscopy

fornix (Emla®; Asta Medica). Ten minutes later, the administration of local anesthesia using Xylocaine® 1% without epinephrine can be performed quite painlessly for the patient. Four to five milliliters of Xylocaine are then injected into the vaginal vault close to the uterosacral ligaments.

Introduction of the 'uterine Fertiloscope'

The cervix is first exposed by means of a Colin speculum, inserted deep in the vagina, in order to expose the posterior cul-de-sac. It is important to use a Colin speculum, because it is the only one that can be removed while the instruments are still in the vagina.

A Pozzi tenaculum is fixed at 8 o'clock on the cervix.

The intrauterine balloon Fertiloscope® (FH 1.29; www.fertiloscopy.com) is then inserted into the cervix. If needed, gentle dilatation of the cervix is performed with Hegar dilators.

Once the Fertiloscope is in the uterine cavity, the mandrel is removed and the balloon is inflated with 2–3 cm³ of air.

It is important not to inflate the balloon too much in the case of procedures performed under local anesthesia, because dilatation of the uterine cavity may be rather painful for the patient. The introducer is finally attached to the patient's thigh, with the adhesive provided.

Hydroperitoneum

In order to create a safety space for the introduction of the Douglas Fertiloscope®, a Verres needle is first used.

The point of entry is located 5–10 mm below the cervix. To avoid the possibility of the Verres needle slipping on the vaginal mucosa, it is necessary, at the start, to retract the safety obturation while impacting the tip of the needle in the very first millimeter of mucosa. Then, the safety mechanism is released, and the Verres is inserted with a firm movement. The axis of penetration has to take

into account the position of the uterus. In the case of a retroverted uterus, the axis has to be parallel with the inferior blade of the speculum. In the case of an anteverted uterus, the axis must be horizontal. As during laparoscopy, the tactile sensation of transfixing the vaginal wall and the peritoneum is easily acquired with some practice. Once in the right space, the Verres tap is opened and, thus, the preheated (35–36°C) isotonic saline solution can freely penetrate in the pouch of Douglas. About 200 ml of saline solution is injected before the next step, insertion of the Douglas introducer.

Introduction of the 'Douglas Fertiloscope'

The Douglas Fertiloscope® (FTO 1.40; www.fertiloscopy.com) is then inserted in the same place, using the same axis as that used for the Verres needle, now removed.

If the introducer is in the correct position, after removing the mandrel some saline will usually flow out, and therefore the balloon can be inflated. If no liquid appears, it is better to check the position of the introducer through the scope. Visualization of the intraperitoneal structure allows inflation of the balloon at that time. The balloon is inflated with 4–5 cm³ of air.

The telescope is introduced by unscrewing the valve located at the proximal end of the main channel, and irrigation is continued through the sheath of the scope.

Observation can now start.

Use of the operative channel

A red tap on the introducer closes the operative channel. When opened, it allows passage of additional 5F instrumentation. It is necessary to rotate the introducer until the red tap is located on the left side. In doing so, the operative channel will be above the main scope channel, and the instrument can therefore be seen through the 30° lens of the telescope.

The operative channel is also useful as a saline outflow channel. It is important, when blood is present in the pouch of Douglas, to be able to rinse the cavity in order to increase the quality of vision.

Operative procedure

The view obtained is inverted, compared with that provided by laparoscopy. Therefore, some time is necessary to familiarize oneself with the fertiloscopic view. However, the learning curve is rather short for any laparoscopic surgeon.

Exploration of the pelvis (Figures 10.16–10.25)

As in many procedures, it is important to have a systematic method. The first element to find is the posterior part of the uterus. It is the roof of the explored space. Then, going alternately from one side to the other, it is possible to

locate the origins of the adnexa: the utero-ovarian ligaments and the tubal isthmus. By following the course of the utero-ovarian ligament, the ovary can be reached, and every part of the ovary must be examined. The upper part of the ovary can be visualized, owing to the 30° lens of the

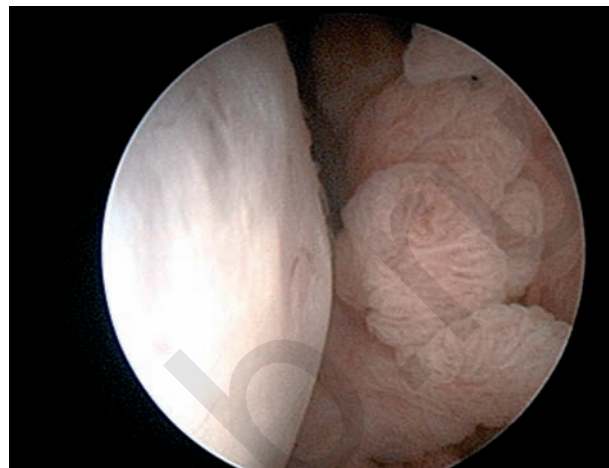


Figure 10.16 Fimbria and normal ovary

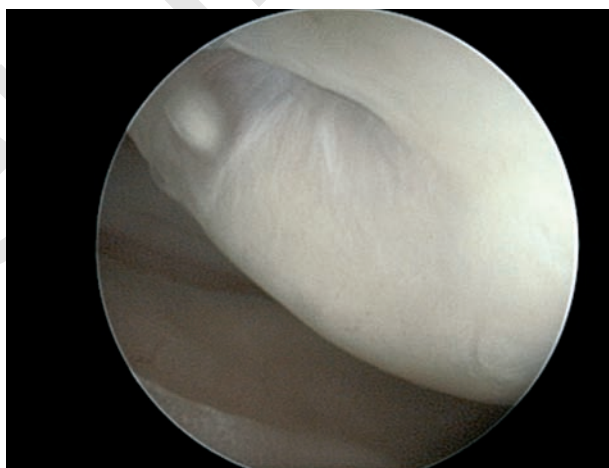


Figure 10.17 Zoom on ovary

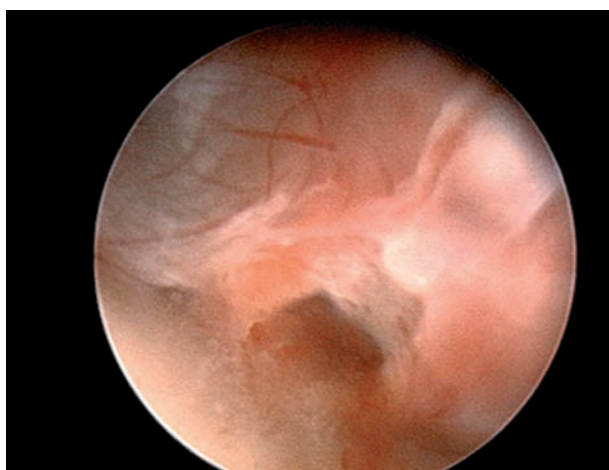

Figure 10.18 Ovulation in progress

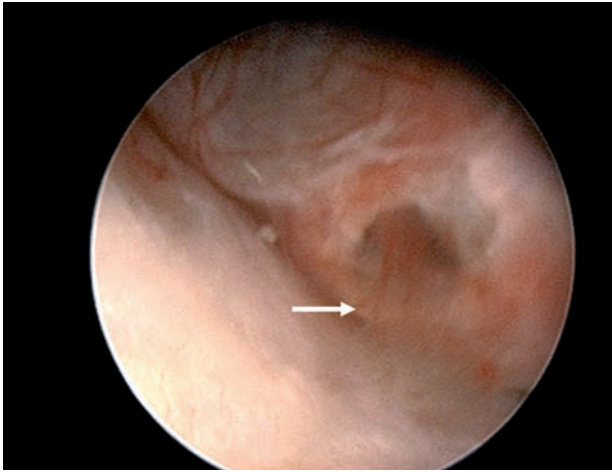


Figure 10.19 Ovulation: note the follicular fluid, indicated by an arrow

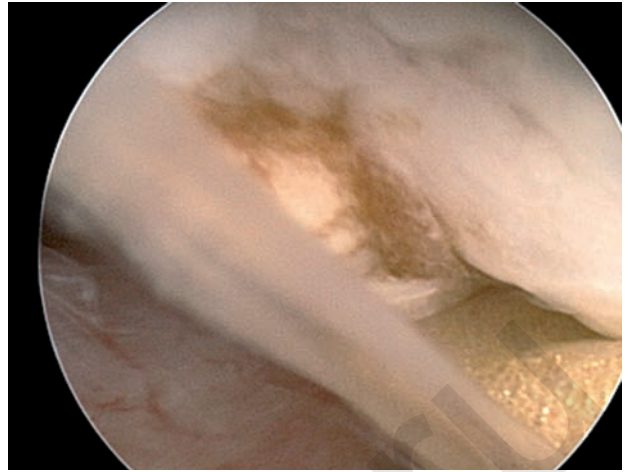


Figure 10.22 Corpus luteum

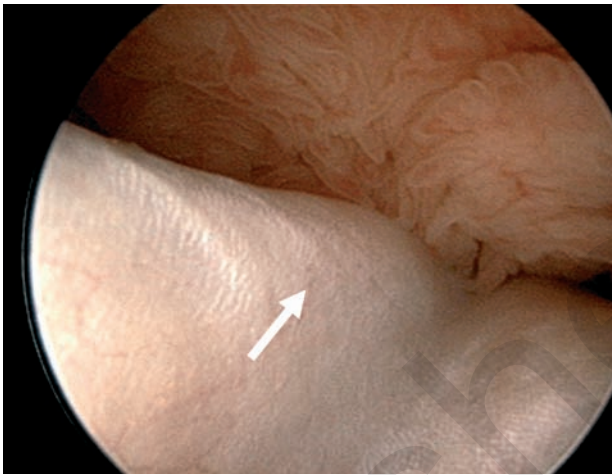


Figure 10.20 Right uterosacral ligament (arrow) and fimbria

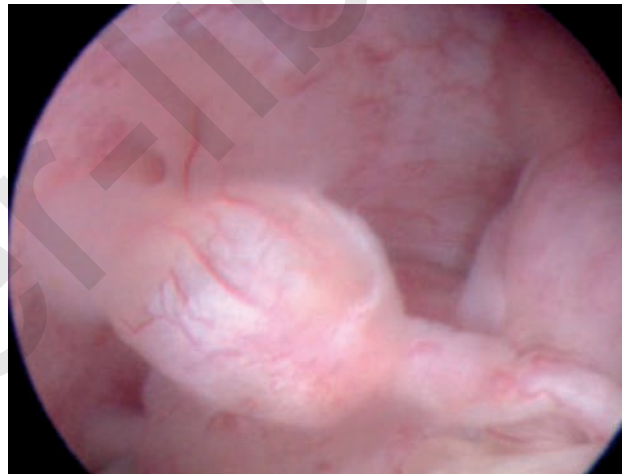


Figure 10.23 Accessory tube

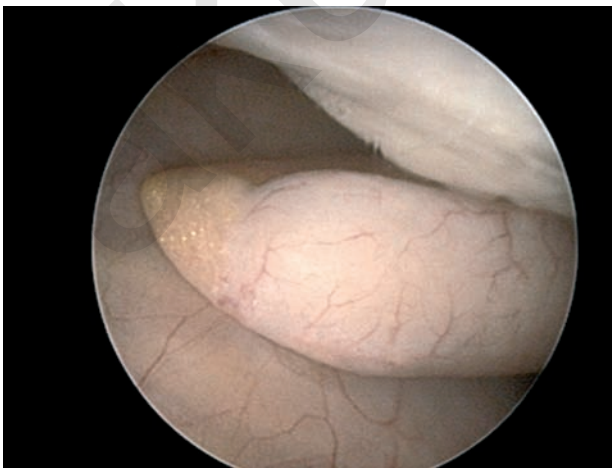

Figure 10.21 Appendix

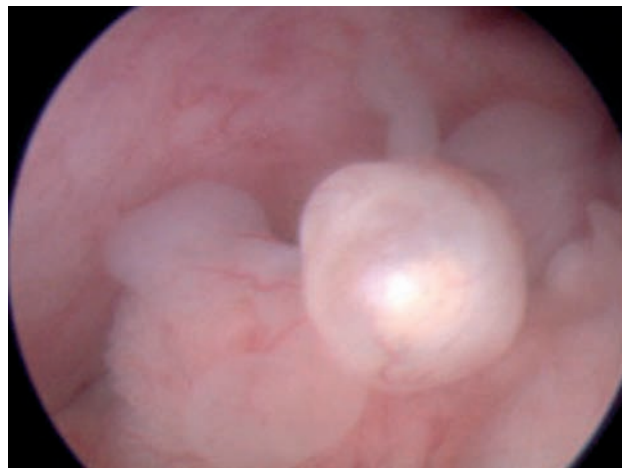

Figure 10.24 Paratubal cyst

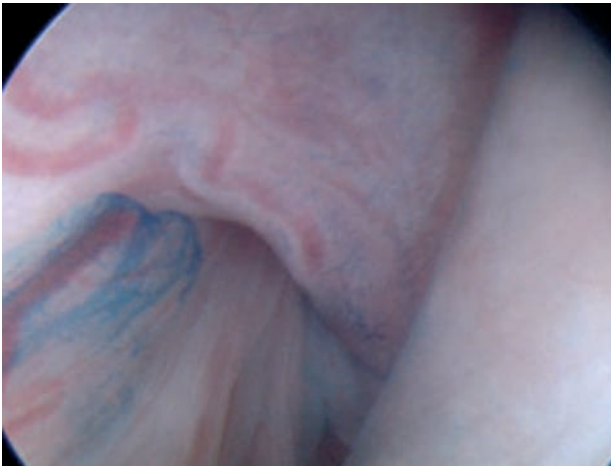

Figure 10.25 Phimosia (under magnification)

telescope, by entering the space between the ovary and the fossa ovarica and rotating the scope on its axis.

The tube can be followed from the isthmus to the ampulla and the fimbria. Due to the inverted view, the tube appears to be located internally to the ovary, which initially can be disorientating.

If visualization of any structure is difficult, it is necessary to wait until more liquid has been instilled, which will improve the view. It is also necessary to move the telescope in all directions, not forgetting forward and backward movements.

The dye test (Figure 10.26)

When all the genital structures have been recognized, the dye test can be performed. Dye is instilled through the appropriate channel of the uterine introducer. A 20-ml syringe is connected, and the dye should be administered gently in order to avoid tubal spasms. The dye is visualized at the fimbria, and it is necessary to move from one side to the other to be sure of bilateral patency.

Salpingoscopy (Figures 10.27–10.36)

Salpingoscopy is known to be a very useful means of investigating the tube⁹. Brosens *et al.*¹⁰, for instance, clearly demonstrated its value in intratubal adhesion pathology. Brosens *et al.*¹¹ described a salpingoscopic score, which is useful for classifying the findings. Nevertheless, routine salpingoscopy is rarely performed during laparoscopy

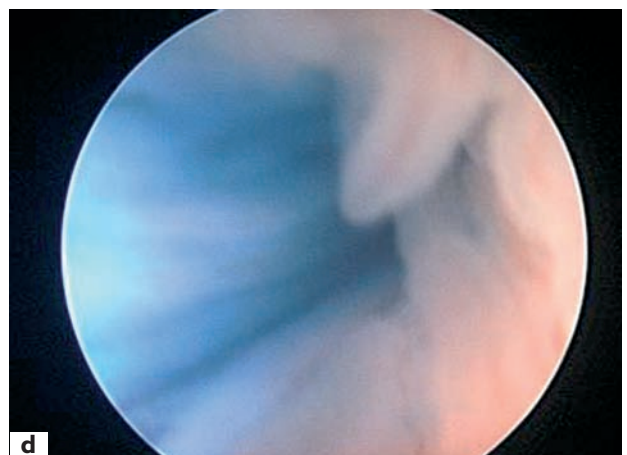
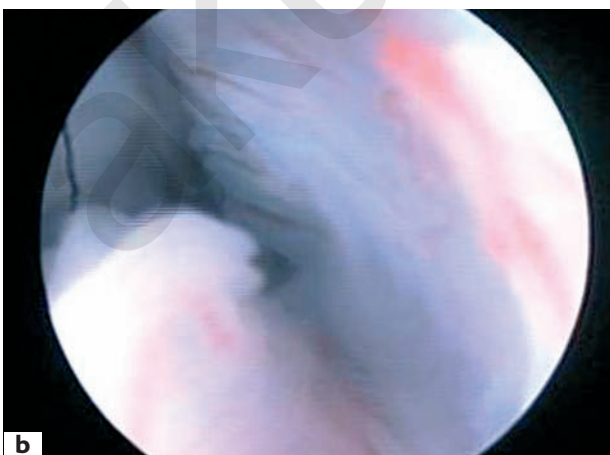
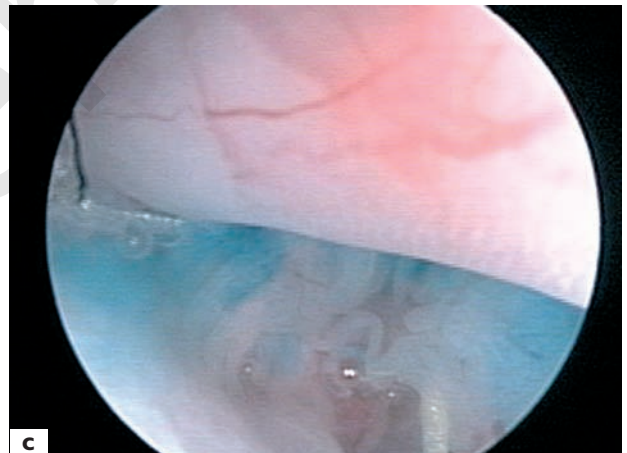
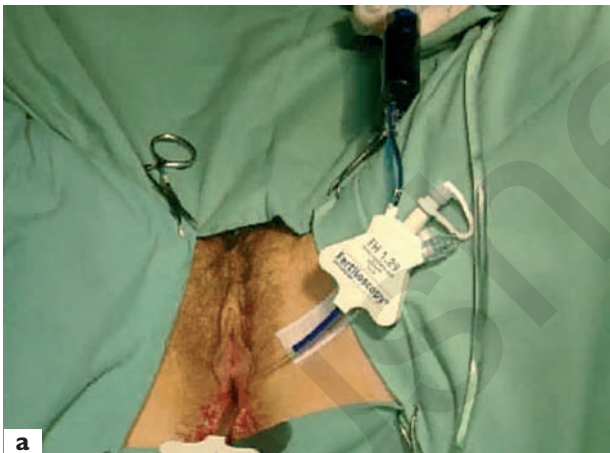

Figure 10.26 (a)–(d) Dye test




Figure 10.27 Salpingoscopy: panoramic view

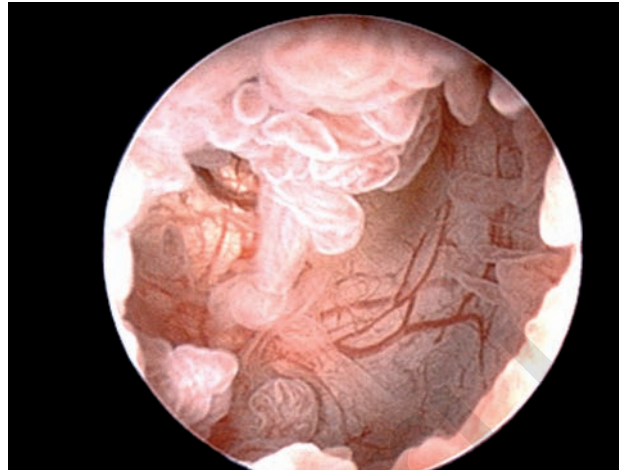


Figure 10.30 Salpingoscopy: flattened folds

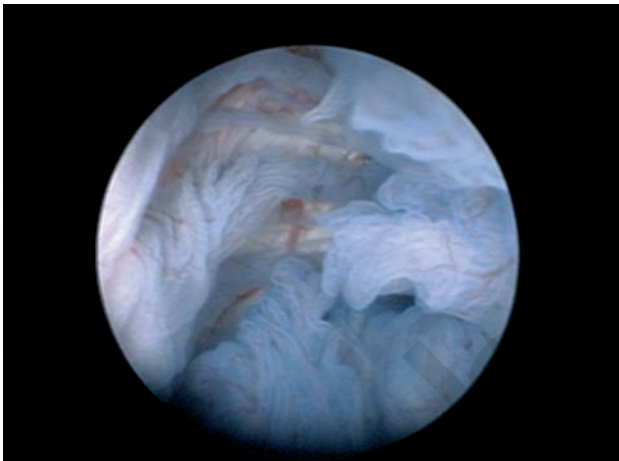


Figure 10.28 Salpingoscopy

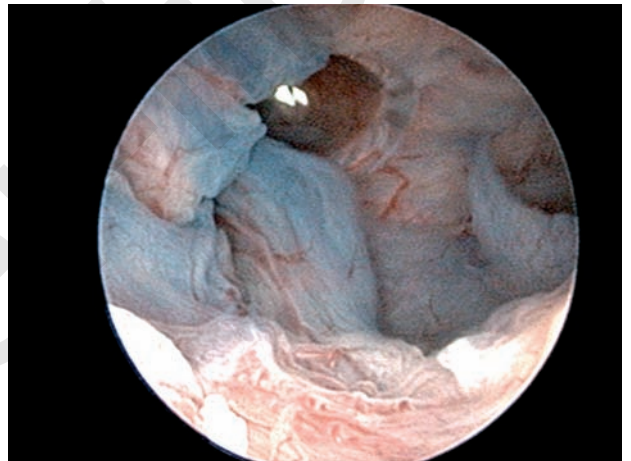


Figure 10.31 Ampulla

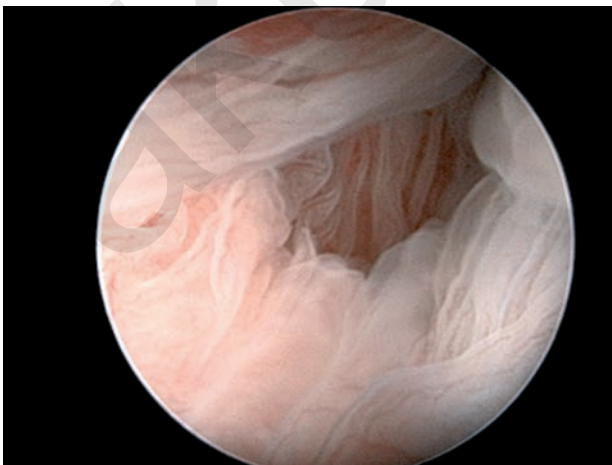


Figure 10.29 Salpingoscopy

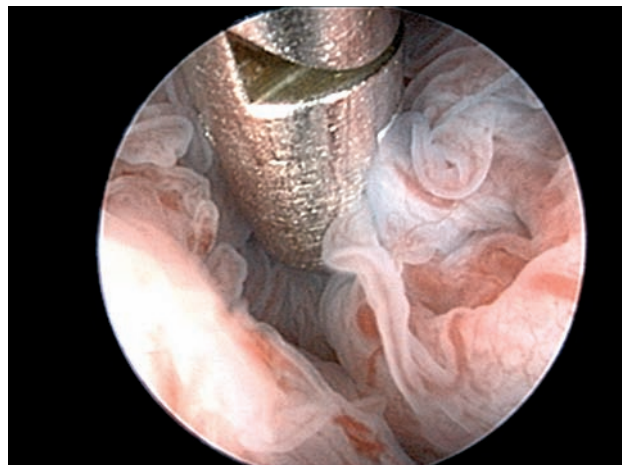


Figure 10.32 Grasping the fimbria

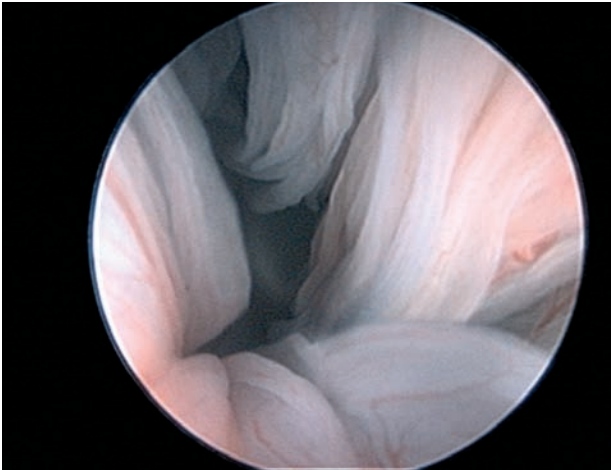

Figure 10.33 Major folds

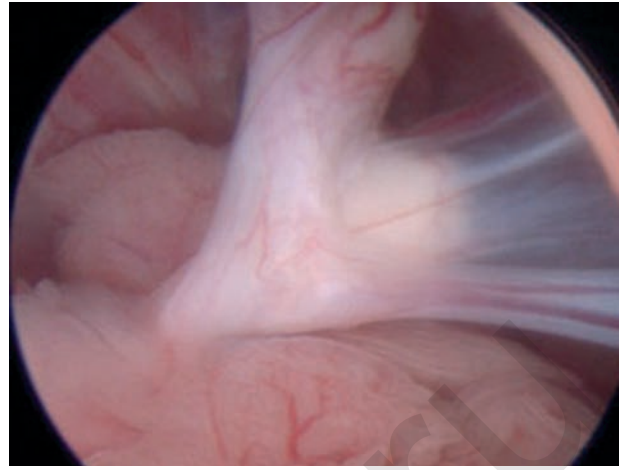


Figure 10.36 Intrafimbrial adhesion

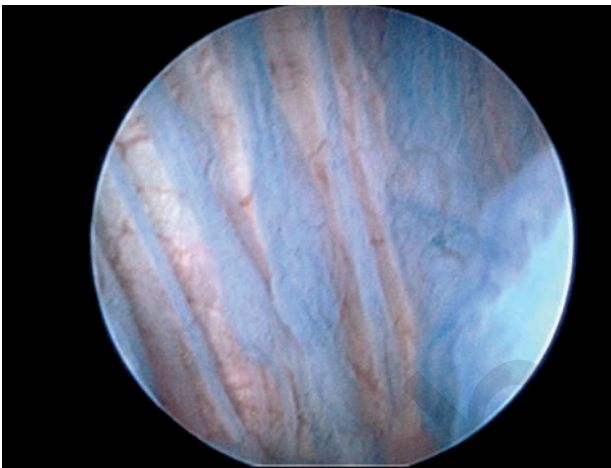


Figure 10.34 Minor folds

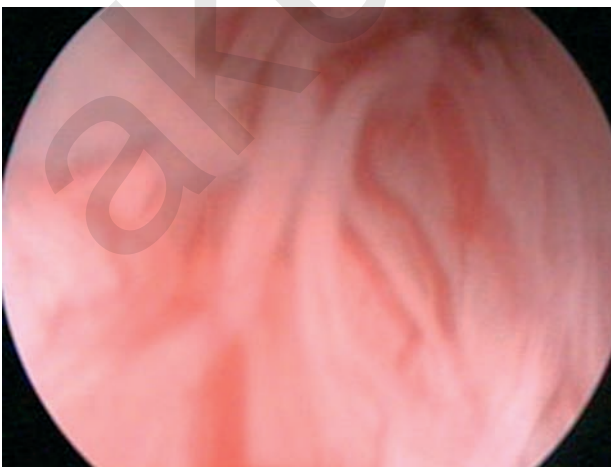


Figure 10.35 Intra-ampullary adhesions

because it is necessary to use a second telescope and an additional cold light source, video camera, monitor and irrigation. In contrast, salpingoscopy is very easily performed during fertiloscopy with the same telescope, due to the position of the fimbria and use of a small telescope. The technique is simple, and involves stabilizing the fimbria by means of grasping forceps introduced into the operative channel. Then, by gently pushing the telescope into the fimbria, it is possible to enter the ampulla and reach the isthmoampullary junction. During the whole procedure, it is necessary to irrigate the tube, through the sheath of the telescope. A tap located on the sheath allows for in-flow adjustment, to avoid too much pressure on the ampulla. By rotating the telescope on its axis, and thanks to the 30° lens, each portion of the ampulla can be examined. All pathological findings can be identified, such as intra-ampullary adhesions or flattened folds. These findings are of great importance when deciding whether surgical repair of a damaged tube is warranted, or whether IVF is a better option.

Microsalpingoscopy (Figures 10.37–10.46)

As we have seen, salpingoscopy is of great value when a tube is blocked, to investigate whether it can be repaired. More often, patent tubes are discovered at the time of fertiloscopy. In these cases, and according to the work of Marconi and Quintana¹², it is interesting to have a more precise evaluation of the tubal epithelium. This can be obtained by performing microsalpingoscopy.

Microsalpingoscopy is possible, owing to the Hamou II telescope (Storz, Germany), which allows a magnification up to $\times 180$ by rotating the wheel near the eyepiece.

Microsalpingoscopy is performed after the dye test, making it possible to examine the number of dye-stained nuclei on the tubal epithelium, which are either intermediary cells on the epithelium or inflammatory cells

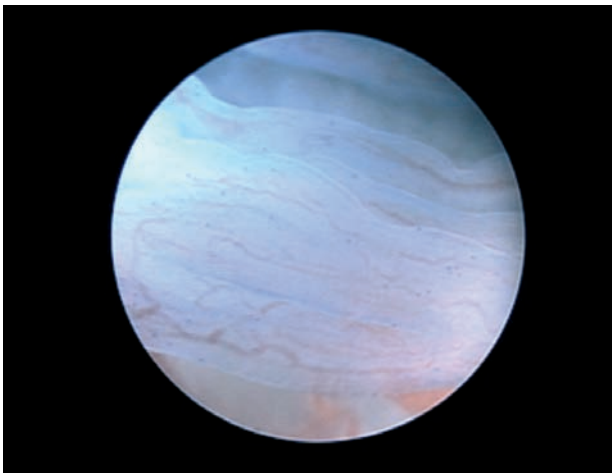


Figure 10.37 Microsalpingoscopy: stage 1




Figure 10.40 Microsalpingoscopy: stage 2

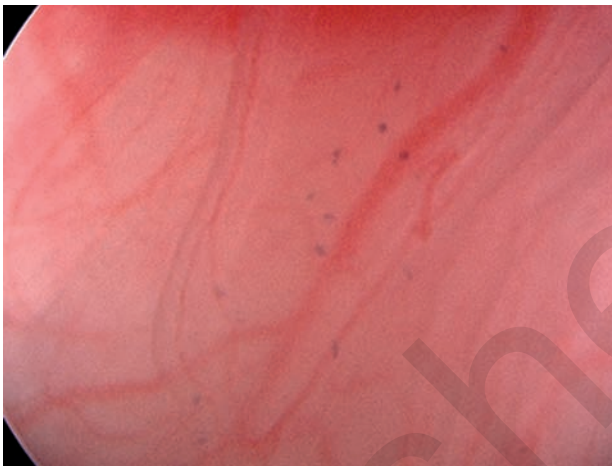


Figure 10.38 Stage 1: some nuclei are dye-stained




Figure 10.41 Stage 2

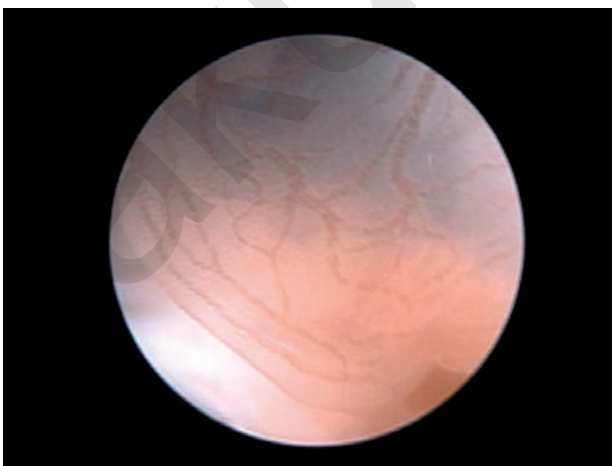


Figure 10.39 Stage 1

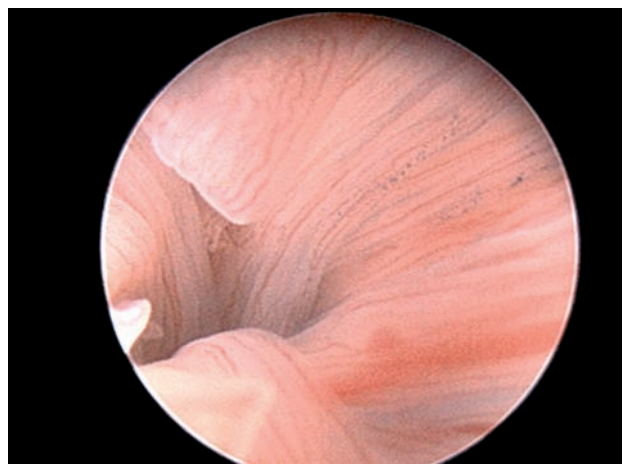


Figure 10.42 Stage 2: dye-stained nuclei are sometimes visible by simple salpingoscopy (without magnification)




Figure 10.43 Microsalpingoscopy: stage 3

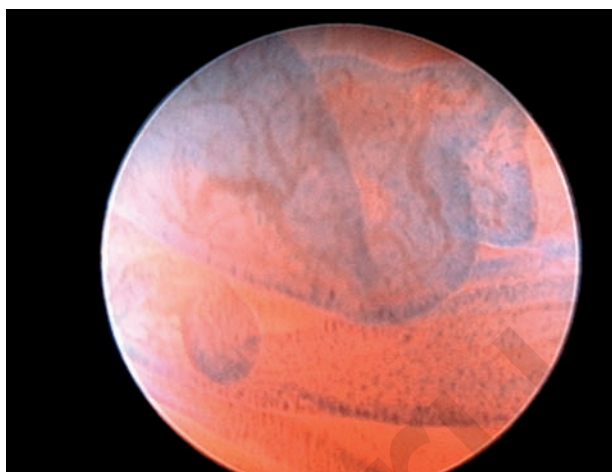


Figure 10.45 Microsalpingoscopy: stage 4: all edges of the folds show many dye-stained nuclei

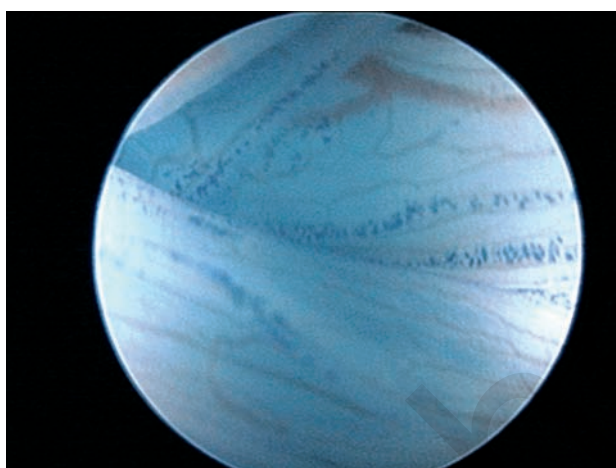


Figure 10.44 Stage 3

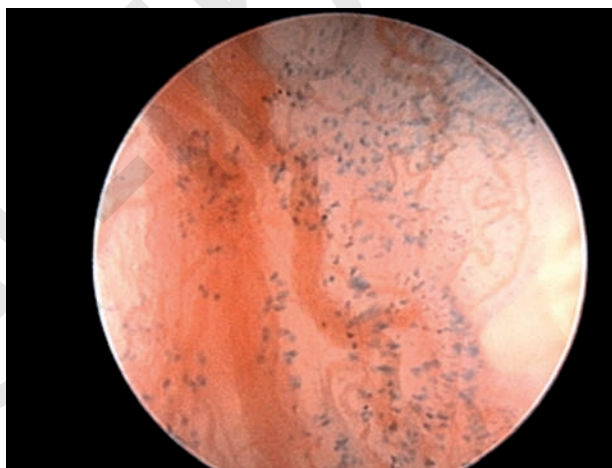


Figure 10.46 Stage 4: mastocytes (between the mucosal folds) and epithelial cells (on edges of the folds) are dye-stained

(mastocytes) in the middle of the tubal folds. According to Marconi and Quintana¹², the number of dye-stained nuclei allows classification of the tubes into four stages, from normal (stage 1) where no nuclei are dye-stained, to pathological (stage 4) where a great number of cells appear to be dye-stained. Such aspects can be confirmed by taking a microbiopsy with 5F biopsy forceps.

Hysteroscopy (Figures 10.47–10.49)

Hysteroscopy is the last step of the procedure. It is carried out using the same scope. Endometrial biopsy is performed at this time if any pathology is suspected.

Operative fertiloscopy

Even if the main aim of fertiloscopy is diagnostic, operative fertiloscopy is a new challenge.

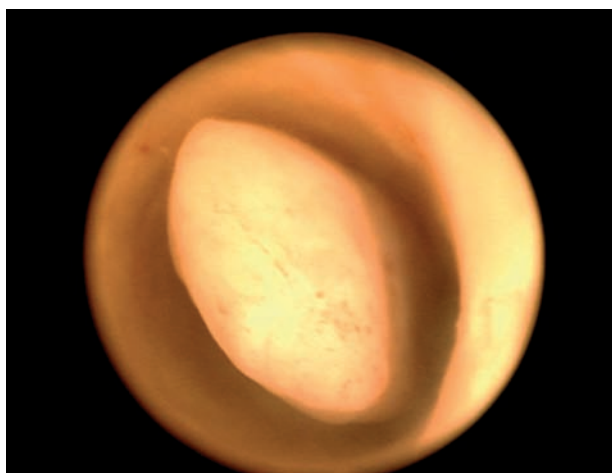


Figure 10.47 Uterine polyp

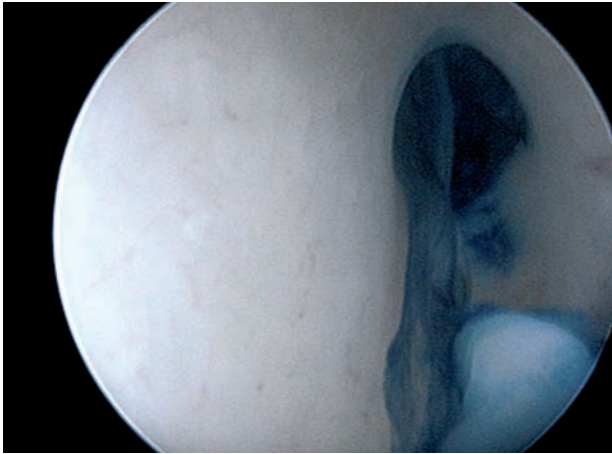


Figure 10.48 Hysteroscopy: mucus plug in the tubal ostium

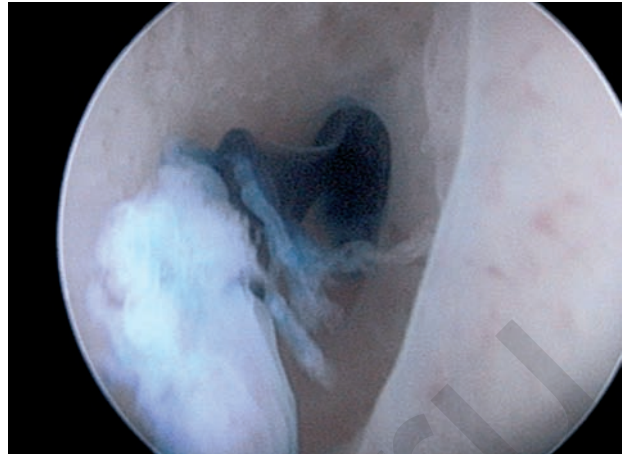


Figure 10.49 Hysteroscopy: the dye previously injected is not an obstacle to a clear hysteroscopic view

At present, certain procedures are possible, such as ovarian drilling (Figure 10.50), limited adhesiolysis (Figures 10.51–10.53) and biopsy. All of these procedures are performed using the 5F operative channel. They are therefore rather limited due to the small diameter of the instrumentation (5F = 1.5 mm), and also because of the

coaxial approach, without the triangulation obtained in laparoscopy.

Nevertheless, in the near future, better adapted instrumentation will allow more operative procedures to be performed. Ovarian drilling is very easily carried out during fertiloscopy. Proposed by Fernandez and Alby¹³ for

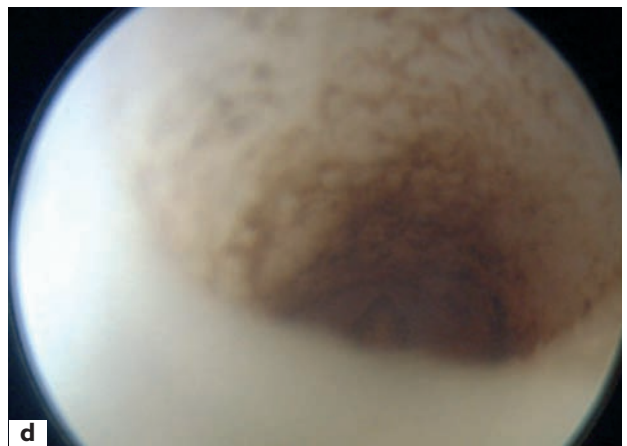
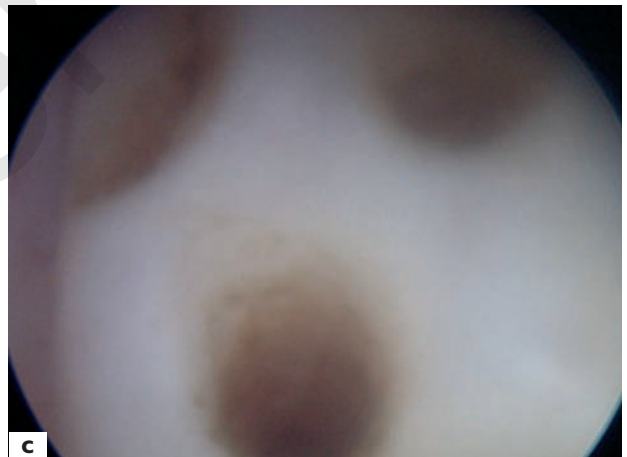
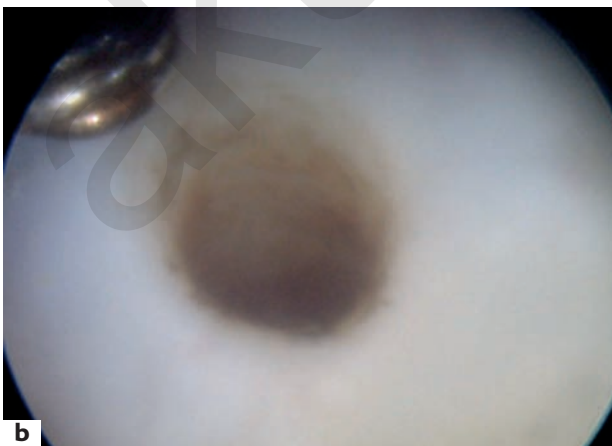

Figure 10.50 (a)–(d) Ovarian drilling

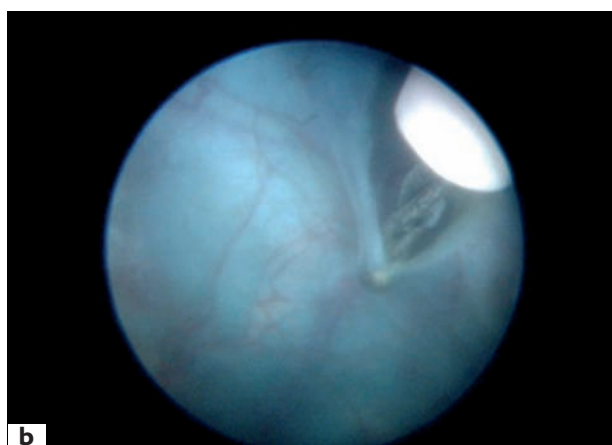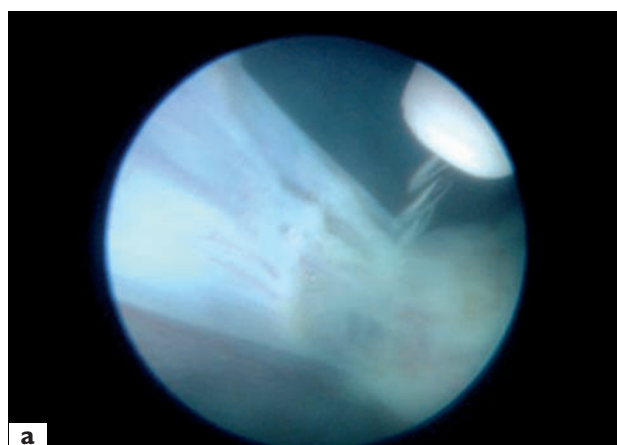


Figure 10.51 (a) and (b) Adhesiolysis

the treatment of women with polycystic ovarian syndrome (PCOS) after the failure of clomiphene citrate, fertiloscopic drilling has proved to be as effective as laparoscopic drilling, and in a very minimally invasive way. A 5F bipolar probe is used, either disposable (Versapoint®; Gynecare, USA) or reusable (Ovadrill®; Erbé-Soprane,

Germany–France), and 10–15 holes are made in each ovary after visualization of the ovarian ligament, which is the landmark for ovarian drilling. The operative procedure is very fast (less than 15 minutes), and is carried out as an outpatient procedure.

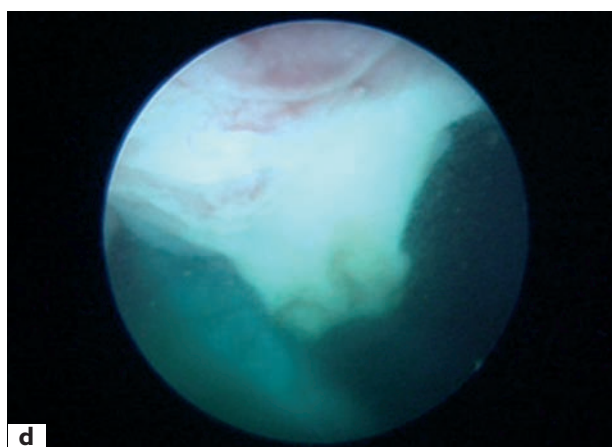
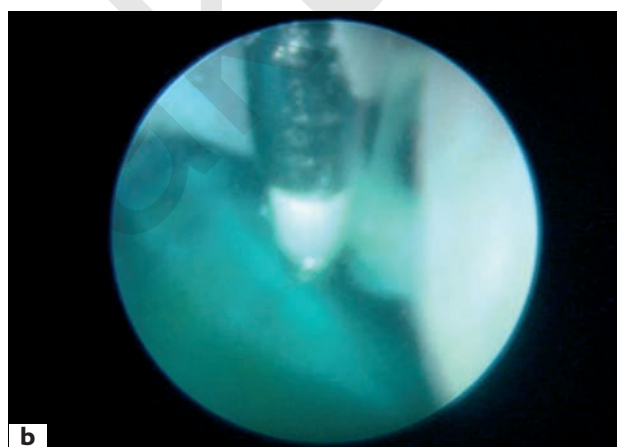
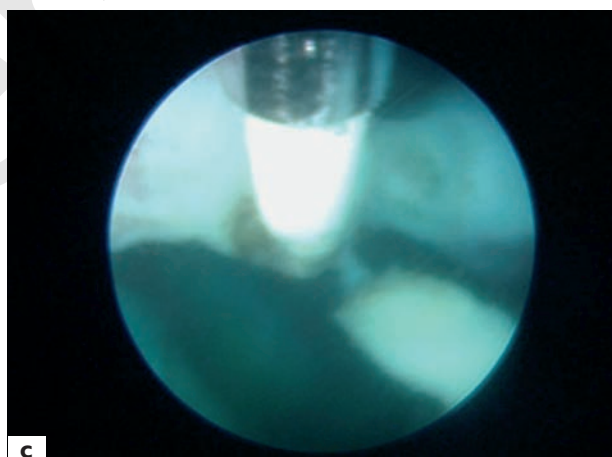
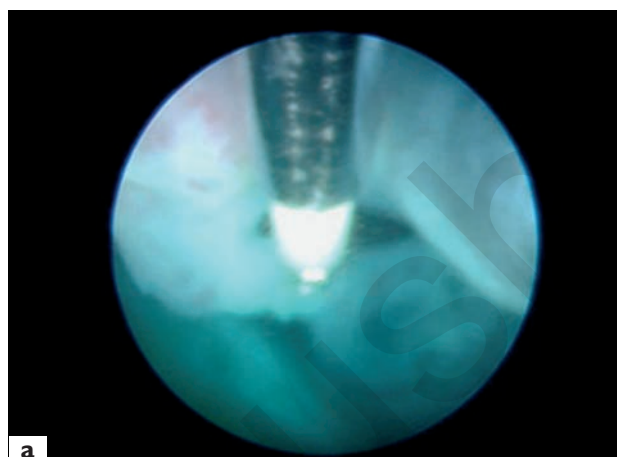


Figure 10.52 (a)–(d) Adhesiolysis

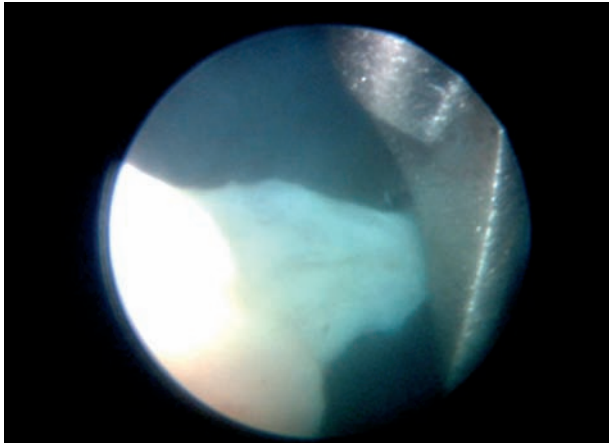


Figure 10.53 Adhesiolysis using microscissors



Biopsies are also performed, as in the tubes, to correlate the microsalpingoscopic findings with the histological aspects.

Adhesiolysis can be achieved using a combination of bipolar probe and scissors. Of course, it is only possible when the adhesions are limited (i.e. when adhesions affect the tubo-ovarian relationship).

It is also possible to open closed tubes such as hydrosalpinx, not in order to treat the obturation, but to be able to perform salpingoscopy to select the best therapeutic option (salpingoplasty or salpingectomy and IVF).

Finally, treatment of minimal or mild endometriosis may be feasible, but the number of procedures carried out at present is too limited to be sure of their effectiveness.

End of the procedure

At the end of the procedure, the telescope is removed, and the liquid can flow out freely. It is not necessary to remove all the saline instilled, because it is well known that the remaining saline will be subsequently reabsorbed.

No stitches are required to close the vaginal scar.

The patient can be discharged immediately if fertiloscopy was performed under local anesthesia, and within several hours if general anesthesia was used. The only recommendation for the patient is to avoid the use of tampons or sexual intercourse for a period of 4 days.

Contraindications

There is only one real contraindication: obstruction of the pouch of Douglas by a fixed retroverted uterus, a myoma or endometriosis of the rectovaginal septum. It is easy to detect obstructive pathology of the pouch of Douglas by ultrasonography or careful vaginal examination.

In case of any doubt, fertiloscopy must not be performed.

RESULTS

Between July 1997 and July 2005, we performed 1500 fertiloscopies and 82 ovarian drillings using fertiloscopy.

We divided our results into four periods. The first period was between July 1997 and October 1997; this was a preliminary study of the first 21 cases, to assess the value of fertiloscopy. For this purpose, fertiloscopy was coupled with laparoscopy. The results showed a very good correlation, and fertiloscopy was therefore introduced on a routine basis into our practice. It was then that we devised the term fertiloscopy.

The second period was between November 1997 and December 1998; during this time, we performed 268 fertiloscopies. The third period was between January 1999 and July 2000; microsalpingoscopy was systematically associated, and 211 fertiloscopies were carried out. The last period was from September 2000 to July 2005; operative salpingoscopy was added to the procedure, and 1011 fertiloscopies were performed.

Overall, we experienced 11 false routes, where the scope was inserted under the peritoneum. These cases occurred mostly in the first two periods, and we did not observe any further false routes after we began administering local anesthetic not on the central line but laterally in the sacral ligaments. Incorrect routing was probably due to the dissection created by injection between the peritoneum and the vaginal vault. Another means of preventing false routes was to insert firmly the Verres needle and ensure that the flow of saline was spontaneous and uninterrupted.

The only complications observed were three cases of rectal injury (3/1500 = 0.2%), easily identified with the scope. In these three cases, due to a lack of experience, the contraindications had not been respected, and insertion was attempted in a pathological cul-de-sac. It is important to note, however, that the perforations occurred in a site located under the peritoneum. Therefore, the treatment of

such injuries was conservative, using only antibiotics for several days. Of course, everything should be done to avoid this type of complication, and strict respect of the contraindications is the best means of prevention.

The patient characteristics are summarized in Table 10.1; this table also shows that fertilioscopy appeared to be normal in 62% of cases. In 8.2% of cases (Table 10.2), salpingoscopy was abnormal, and the patients were referred for IVF for this reason. When microsalingoscopy was performed (Table 10.3), it was considered as stage 3 or 4 of Marconi's classification in 37% of cases. These patients were therefore directly referred for IVF. When microsalingoscopy was normal, intrauterine insemination (IUI) was the chosen option.

Endometriosis was discovered in 13.9% of cases, and post-pelvic inflammatory disease (PID) lesions in 16%. Further laparoscopy was carried out in the case of abnormality, except in six cases, where microsurgical anastomosis was performed for proximal tubal obstruction. It is interesting to note that, in every case where pathology was detected at the time of fertilioscopy, it was confirmed by laparoscopy. Only a few lesions located above the uterus were not correctly identified.

Eighty-two ovarian drillings were also carried out by fertilioscopy in cases of PCOS. Results are summarized in Table 10.4, and appear comparable to those obtained by laparoscopy.

DISCUSSION

We devised the term 'fertilioscopy' to encompass the global nature of this examination, which allows access to the uterine cavity (owing to the last step of the procedure, i.e. hysteroscopy), the outside of the tubes and the tuboperitoneal environment and the inside of the tubes (by way of salpingoscopy and microsalingoscopy), all in the same procedure¹⁴.

The introduction of fertilioscopy to the arsenal of useful tools in the infertility work-up raises some important questions. Is it safe? Is it reproducible? Is it as efficient as the 'gold standard' of laparoscopy? Is it a purely diagnostic tool? With the success of IVF, is it still useful to conduct such a thorough evaluation of the peritoneal cavity and its contents?

Many of these important questions have already been effectively addressed.

Is it as efficient as diagnostic laparoscopy?

It was critical to answer this question, since standard laparoscopy was considered the gold standard for tuboperitoneal evaluation. For this purpose, we designed the FLY study (fertilioscopy vs. laparoscopy)¹⁵. It was a prospective, multicentric, randomized study in which fertilioscopy, then laparoscopy, were performed on the same infertile patient by two surgeons (A and B),

Table 10.1 Global results of 1500 fertilioscopies

	<i>n</i>	%
Age (years) (range)	33.3 (22–42)	
Duration of infertility (years)	4.1	
Primary infertility	1228	81.9
Failure	11	0.7
Complications	3	0.2
Normal fertilioscopy	930	62.0
Endometriosis	209	13.9
Post-PID lesions	241	16
Subtle lesions	106	7

Table 10.2 Results of salpingoscopy (*n* = 500)

	<i>n</i> (%)	Normal <i>n</i>	Abnormal <i>n</i> (%)
Phimosi	25 (5)	8	17 (68)
Hydropsalpinx	6 (1.2)	1	5 (83)
Adhesions	48 (9.6)	15	33 (68)
Endometriosis	95 (19)	79	16 (16)
No pathology	326 (65.2)	299	27 (8.2)
Total	500 (100)		98 (19.6)

Table 10.3 Results of microsalingoscopy (*n* = 500)

	<i>n</i>	Stage 1–2 (<i>n</i>)	Stage 3–4 (<i>n</i>)
Phimosi	12	2	10
Hydropsalpinx	1	0	1
Adhesions	108	56	52
Endometriosis	68	61	7
No pathology	311	196	115 (37%)
Total	500	315	185

Table 10.4 Results of 82 fertilioscopic ovarian drillings

	<i>n</i>	%
Operation time (minutes) (range)	13 (9–23)	
Spontaneous ovulation	49	59.7
Ovulation with stimulation	26	31.7
Total ovulation	75	91.4
Pregnancy (> 1 year)	44	53.6

randomized for the procedure they were to carry out. The procedures were video-recorded and reviewed by two independent investigators. This protocol was submitted for approval by the ethics committee, according to the French Huriet law.

Eighty-two cases were recorded, and the main statistical analysis was a concordance study using the κ score for six sites (both tubes, both ovaries, peritoneum and uterus), leading to a comparison of 492 different sites. The κ score for each site was between 0.75 and 0.91, allowing us to conclude that the concordance between fertiloscopy and laparoscopy was excellent. Thus, the main conclusion of the study was that: 'fertiloscopy should replace diagnostic laparoscopy in infertile patients with no obvious pathology'.

Although it was, to the best of our knowledge, the first time that two endoscopic methods had been evaluated in such a prospective manner, we must underline the fact that salpingoscopy and microsalingoscopy were not taken into account, due to the difficulties involved in performing salpingoscopy routinely during laparoscopy.

Is fertiloscopy safe and reproducible?

Its reproducibility has already been demonstrated in numerous studies, including our own 1500 consecutive cases.

Safety is a concern, since the risk of bowel injury exists. Insertion of the Verres needle, then the fertiloscope, should be performed between the cervix and the rectum. Safety is, thus, mainly prevention.

In the case of nodules, mucosal attraction or fixed uterine retroversion, fertiloscopy may need to be canceled. The detection of such conditions is essentially clinical; careful vaginal examination before fertiloscopy is critical. Ultrasound scanning may help in some cases, but does not replace clinical evaluation.

If a rectal injury should occur, and if it is of small diameter (less than 5 mm) and located beneath the peritoneum, the treatment is always conservative, using antibiotics for a few days. Indeed, there is absolutely no need to perform a further laparoscopy or a laparotomy, as demonstrated by the study of Gordts *et al.*¹⁶.

Is fertiloscopy only diagnostic?

It was at the beginning. Today, thanks to the operative channel (see above), we are able to perform proper adhesiolysis, and treatment of minimal endometriosis, which consequently decreases the number of laparoscopic conversions. This is why we increasingly propose performing fertiloscopy under general sedation (similar to oocyte pick-up in IVF) in order to carry out surgery at the same time.

In fact, depending on the health system, fertiloscopy is performed either as a strict office procedure (with local anesthesia), in which case a further operation will be

required if pathology is detected, or in an outpatient unit where operative fertiloscopy is possible.

Another possibility is performing ovarian drilling in PCOS patients. Many therapeutic options are already available for PCOS patients, with drugs such as metformin. Nevertheless, the attraction of surgical ovarian drilling is immediate efficacy, lack of ovarian hyperstimulation syndrome (OHSS) and a decrease in miscarriages.

Performed through fertiloscopy, ovarian drilling is very fast and safe, and also allows a thorough evaluation of the pelvic tract at the same time.

Due to the success of IVF, is there still interest in endoscopic evaluation of infertile patients?

Indeed, there is no use in certain circumstances, for instance when infertility is due only to severe sperm deficiency.

In other cases, many IVF doctors claim that HSG is sufficient because, in the end, IVF will be the only option for these couples.

We strongly disagree with this opinion, however. First, HSG is well known for its limitations (around 15% of false positives and 35–40% of false negatives). It is therefore of great interest to detect pelvic abnormalities such as endometriosis or adhesions, as the treatment of these lesions leads to a good pregnancy rate. Furthermore, increasing numbers of young couples are keen to obtain pregnancy in a physiological way.

We believe that, after an era of mainly IVF-focused solutions, it is now time to re-evaluate our practice thanks to new minimally invasive options such as fertiloscopy.

REFERENCES

1. Swart P, Mol BW, Van Beurden M, et al. The accuracy of hysterosalpingography in the diagnosis of tubal pathology: a meta-analysis. *Fertil Steril* 1995; 64: 486–91
2. Chapron C, Querleu D, Bruhat MA, et al. Surgical complications of diagnostic and operative gynaecologic laparoscopy: a series of 29966 cases. *Hum Reprod* 1998; 13: 867–72
3. Mintz M. Actualisation de la culdoscopie transvaginale en décubitus dorsal. Un nouvel endoscope à vision directe muni d'une aiguille à ponction incorporée dans l'axe. *Contr Fertil Sex* 1987; 15: 401–4
4. Odent M. Hydrocolpotomie et hydroculdoscopie. *Nouv Press Med* 1973; 2: 187
5. Gordts S, Campo R, Rombauts L, Brosens I. Transvaginal hydrolaparoscopy as an outpatient procedure for infertility investigation. *Hum Reprod* 1998; 13: 99–103
6. Watrelot A, Gordts S, Andine JP, Brosens I. Une nouvelle approche diagnostique: la fertiloscopie. *Endomag* 1997; 21: 7–8

7. Watrelot A, Dreyfus JM, Andine JP. Fertiloscopy; first results (120 case report). *Fertil Steril* 1998; 70 (Suppl): S-42
8. Watrelot A, Dreyfus JM, Andine JP. Evaluation of the performance of fertiloscopy in 160 consecutive infertile patients with no obvious pathology. *Hum Reprod* 1999; 14: 707–11
9. Surrey E. Microendoscopy of the human fallopian tube. *J Am Assoc Gynecol Laparosc* 1999; 6: 383–90
10. Brosens I, Campo R, Gordts S. Office hydro-laparoscopy for the diagnosis of endometriosis and tubal infertility. *Curr Opin Obstet Gynecol* 1999; 11: 371–7
11. Brosens I, Boeckx W, Delattin P, et al. Salpingoscopy: a new preoperative diagnosis in tubal infertility. *Br J Obstet Gynaecol* 1987; 94: 768–73
12. Marconi G, Quintana R. Methylene blue dyeing of cellular nuclei during salpingoscopy, a new in vivo method to evaluate vitality of tubal epithelium. *Hum Reprod* 1998; 13: 3414–17
13. Fernandez H, Alby JD. De la culdoscopie à la fertiloscopie opératoire. *Endomag* 1999; 21: 5–6
14. Watrelot A, Dreyfus JM. Explorations intra-tubaires au cours de la fertiloscopie. *Reprod Hum Horm* 2000; 12: 39–44
15. Watrelot A, Nisolle M, Hocke C, et al. Is laparoscopy still the gold standard in infertility assessment? A comparison of fertiloscopy versus laparoscopy in infertility. *Hum Reprod* 2003; 18: 834–9
16. Gordts S, Watrelot A, Campo R, Brosens I. Risks and outcome of bowel injury during transvaginal pelvic endoscopy. *Fertil Steril* 2001; 76: 1238–41

akusher-lib.ru

Transvaginal laparoscopy

S Gordts

INTRODUCTION

The technique of culdoscopy was introduced in the early 1940s by Decker¹. It allowed the endoscopic visualization of the pelvic organs through a transvaginal puncture into the cul-de-sac, with the patient in the knee–chest, or genupectoral, position. However, when laparoscopy was introduced at the beginning of the 1960s, with the advantage of a panoramic view and the possibility of performing tubal ligation, the technique of culdoscopy was abandoned. Raoul Palmer in Europe² and Eduard Diamond³ in the USA, however, appreciated culdoscopy as the method of choice for the diagnosis of infertility. Although still considered the gold standard, trans-abdominal laparoscopy is too invasive for diagnostic purposes only, and therefore frequently postponed in the exploration of the female pelvis in patients with infertility. The postponement of endoscopic exploration delays the accurate diagnosis and treatment of some uterine lesions, tubo-ovarian adhesions and active peritoneal and ovarian endometriotic lesions. These lesions are assumed to affect 20–30% of subfertile patients. A modern exploration of infertility could start under appropriate circumstances after 6 months without conception, and should be of short duration, with minimal disruption to professional activities, be minimally invasive with high accuracy and provide all the necessary information regarding the reproductive future of the patient.

TECHNIQUE AND INSTRUMENTS

The technique of transvaginal laparoscopy has been previously described^{4,5}. With the patient in a dorsal decubitus position, access to the pouch of Douglas is obtained through a needle puncture technique of the posterior fornix. For this purpose, a special access trocar was developed, enabling entry of the pouch of Douglas with a simple needle and consecutively dilating the site of entrance up to the diameter of the outer trocar (4 mm). The access needle is equipped with a spring-loaded system ensuring painless and quick access to the pouch of Douglas (Figure 11.1). The length of the loaded needle entering the pouch of Douglas can be preset at between 1 and 2.5 cm. With the exception of an obese patient, a preset depth of 1.5 cm is normally used.

The endoscope used is a 2.9-mm endoscope with a 30° angular optical lens, the same as for hysteroscopy. Fixed in

the single-flow outer trocar, the total diameter is 3.4 mm (Storz, Tuttlingen, Germany).

During the entire procedure, a continuous flow of prewarmed Ringer's lactate is used, normally not exceeding 500 ml for a diagnostic procedure. The use of this aqueous distension medium keeps the organs afloat (Figure 11.2a and b), and enables accurate visualization of subtle lesions on the surfaces of the tubes and ovaries (Figure 11.2c and d and Figure 11.3). The transvaginal route offers direct and easy access, and visualization of the tubo-ovarian structures without supplementary manipulation. With the endoscope in the same axis as the tubo-ovarian structures, the total ovarian surface and the fossa ovarica can easily be explored. The umbilical angle at standard laparoscopy is not suitable for visualization of the tubes and ovaries, and supplementary manipulation such as grasping and rotating of the ovaries is necessary to visualize the anterolateral side of the ovaries and the fossa ovarica. In the absence of any manipulation, transvaginal laparoscopy allows inspection of the different structures in their normal position, and their normal relationship to each other. This technique allowed direct observation of the normal physiological events at ovulation and ovum pick-up⁶. Without supplementary manipulation and using the same optics, salpingoscopy through cannulation of the distal tubal ostium was feasible in about 50% of attempted tubes⁷.




Figure 11.1 A specially developed needle–trocar system consists of three parts: a spring-loaded needle (a), a dilating trocar (b) and an outer trocar (c). The spring-loaded system allows quick access to the pouch of Douglas (Storz, Tuttlingen, Germany)

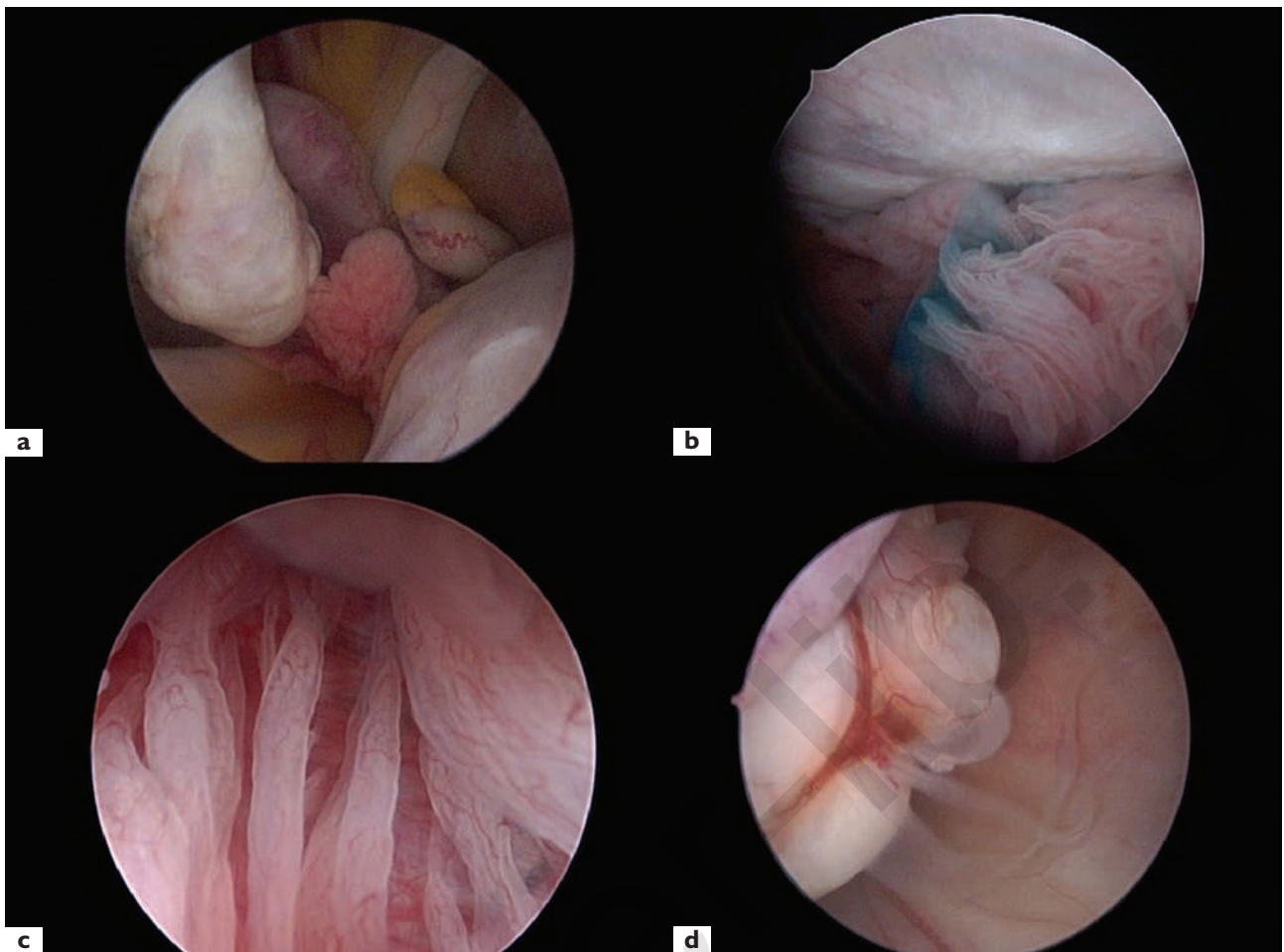


Figure 11.2 The use of Ringer's lactate as distension medium keeps the organs afloat. Without supplementary manipulation, tubo-ovarian structures can be inspected accurately (a) in their normal position. When indicated, a patency test and salpingoscopy can be done (b) and (c). In the absence of high intra-abdominal pressure, subtle lesions on peritoneal and ovarian surfaces can be visualized (d)

FEASIBILITY, ACCURACY AND ACCEPTABILITY

We reported⁸, in a consecutive series of 663 patients, no pathology, or pathology of minor clinical significance, in 66.6% of them. In the case of pathology this was mainly endometriosis (33.4%), tubo-ovarian adhesions (28%), hydrosalpinges, benign ovarian cysts, (evaluation of tubal status after) sterilization and subserous myoma.

Some minor complications occurred in this series: inadvertent puncture of the posterior side of the uterus in five patients and bleeding of the vaginal insertion site in one patient. Needle perforation of the rectum occurred in five patients (0.7%) without consequences.

Rectal perforation could be a potentially serious complication of transvaginal access. In a survey of 3667 procedures⁹ the incidence of bowel perforation was 0.65%, which decreased after initial experience to 0.25%. However, no delayed diagnosis and sepsis occurred, and all cases except for one were managed conservatively with

antibiotics. Analysis of the occurrence of complications as a function of experience confirmed the importance of the learning curve, with a clear decline of complications and failed access after 50 procedures. Routine vaginal examination and vaginal ultrasound to exclude pathology of the pouch of Douglas are strongly recommended to avoid complications.

Our access failure rate was 3.4% ($n=23$), including also our failures in the initial learning period. These findings correspond with the reported experience of others (Table 11.1)⁹⁻¹⁵.

In a recently published study of 1000 procedures, Verhoeven *et al.*¹⁶ reported 32 failures (3.2%), with failed access in 11 patients (1.1%) and absent or poor visualization in 21 patients (2.1%). Bowel perforation occurred in five patients (0.5%).

Acute clinical conditions (bleeding, infection), an obliterated cul-de-sac or a large ovarian cyst are also strict contraindications to the transvaginal approach (Table 11.2).

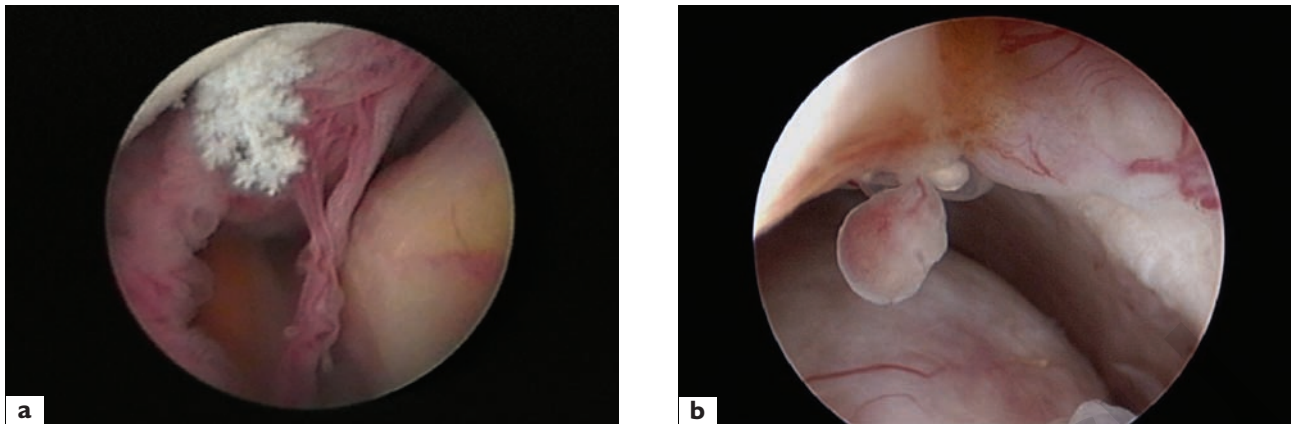


Figure 11.3 In the absence of high intra-abdominal pressure, using prewarmed Ringer's lactate as distension medium enables the visualization of subtle lesions upon the ovarian surface: (a) crystalloid-appearing lesion, diagnosed at histology as a papilloma; (b) small polypoid endometriotic lesion

Table 11.1 Failure of access and complication rates at transvaginal laparoscopy

<i>Authors</i>	<i>n</i>	<i>Access failure (%)</i>	<i>Complications (%)</i>
Gordts <i>et al.</i> , 2005 ⁹	663	3.5	0.9
Watrelet <i>et al.</i> , 1999 ¹⁰	160	3.8	0.6
Darai <i>et al.</i> , 2000 ¹¹	60	10	1.9
Moore <i>et al.</i> , 2002 ¹²	40	0	0
Shibahara <i>et al.</i> , 2001 ¹³	41	7.3	0
Dechaud <i>et al.</i> , 2001 ¹⁴	23	4.3	0
Moore <i>et al.</i> , 2003 ¹⁵	109	0.9	0.9
Verhoeven <i>et al.</i> , 2004 ¹⁶	1000	3.2	0.5

Evaluating the acceptability of the procedure, it has been documented that the procedure was well tolerated by patients¹⁷. On an analog pain rating scale from 0 to 10 for transvaginal laparoscopy performed in an office setting under local anesthesia, the mean pain score was 2.7 (standard deviation \pm 1.5) on a 10-cm visual pain scale. Only five (8%) of the patients marked a score above 5, and 96% of the patients regarded a repeat procedure under the same circumstances as acceptable. Moore and Cohen¹⁸ found, in 17 patients who received conscious sedation, a pain score for cannula insertion, mid-procedure and end of procedure of 2.1, 1.4 and 0.5, respectively.

'One-stop fertility clinic'

With the availability of small, high-quality endoscopes, a complete exploration can now be performed in 1 day. The 'one-stop fertility clinic' is based on transvaginal endoscopy (TVE), and includes a mini-hysteroscopy, transvaginal laparoscopy, chromoperturbation test, fimbrioscapy and, when indicated, salpingoscopy¹⁹. All procedures can

Table 11.2 Contraindications to transvaginal laparoscopy

Narrow vagina
Fixed retroverted uterus
Obliterated pouch of Douglas
Induration of posterior fornix
Acute situation (bleeding, infection)

be performed in the same session under local anesthesia or sedation, in an outpatient setting, using the 2.9-mm endoscope. Prior to attendance, all referred patients receive an information pack, and are asked to complete a detailed medical questionnaire. Non-referred patients are obviously first seen and examined at the routine clinic, and also receive full information and are requested to complete the questionnaire.

On the same day, a sperm examination and the necessary blood analyses can be performed. With the

results ready within a few hours, the complete investigation can be discussed with the couple and appropriate treatment can be proposed.

OPERATIVE PROCEDURES AT TRANSVAGINAL LAPAROSCOPY

The transvaginal approach has the advantage of providing direct access to the tubo-ovarian structures without supplementary manipulation, and particularly to the fossa ovarica, a preferential place for endometriotic implants and adhesions. The use of an aqueous distension medium enables the accurate detection of subtle lesions on the peritoneal and ovarian surfaces. Working in an aqueous distension medium, however, requires meticulous hemostasis to avoid insufficient or disturbed visualization, and only a bipolar current can be used.

In the absence of a panoramic view, surgery will be limited to minimal procedures not requiring an overview of the total pelvis, and there is no place for use of the transvaginal route in acute situations such as bleeding or infection. All operative interventions are performed under general anesthesia or sedation in a 1-day care center. The transvaginal operative route is of particular interest in the treatment of ovarian endometriosis, and in cases of clomiphene-resistant polycystic ovarian syndrome (PCOS), for drilling of the ovarian capsule.

Instruments

For operative procedures, the same 2.9-mm endoscope is used, with an outer operative sheath of 5 mm for the one-working-channel instrument and 6.5 mm for the two-working-channel instrument. As instrumentation, all 5F instruments including scissors, grasping forceps and biopsy forceps can be used. Cutting and coagulation are performed using a bipolar needle and bipolar probe.

Endometriosis

Formation of the endometrioma by superficial implants was suggested by Sampson in 1921²⁰, but it was many decades later that Hughesdon²¹, on serial sections of ovaries with *in situ* endometriomas, demonstrated that the wall of the typical endometrioma is formed by invaginated ovarian cortex. Also, Brosens *et al.*²², using ovarioscopy and selective biopsies, and Donnez *et al.*²³ described the presence of primordial follicles at the base of the invaginated cyst.

The endometrioma is most frequently adherent to the posterior leaf of the broad ligament, the posterior side of the uterus and the uterosacral ligament. All these structures are directly accessible by the transvaginal route. The most appropriate route of access to the endometriotic cyst is not through an antimesenterial fenestration, but by opening the site of invagination²⁴.

As at standard laparoscopy, the operative treatment in the case of an ovarian endometrioma is performed in three steps: first, complete adhesiolysis of the ovary; second, creating a wide opening of the site of inversion; and third, superficial coagulation of the endometriotic implants (Figure 11.4).

Opening of the pseudocyst is performed by adhesiolysis and resection of fibrosis at the site of inversion, and by fenestration. In contrast with the treatment of other benign ovarian cysts, in the case of endometriomas there is no collapse of the wall. After rinsing and aspiration of the chocolate content of the cyst, underwater inspection allows identification of the several endometriotic implants and neovascularization. After a biopsy has been taken, the implants can be selectively cauterized.

The advantage of the transvaginal approach and the use of an aqueous distension medium is that, by means of detailed and accurate viewing, the inversion origin of small endometriomas or early implants in ovaries with *in situ* endometriomas is clearly demonstrated²⁵. What initially appear as small brown or black vesicles upon the ovarian surface are, upon closer inspection, small invaginated areas of the ovarian cortex covered by adhesions, and containing the typical endometriotic content. At the base of these invaginations, endometriotic implants and their neovascularization can be clearly identified (Figure 11.4).

No complications occurred in our series of 100 patients, and no conversion to standard laparoscopy was indicated. Compared with standard laparoscopy, most of the patients had no sensation of pain afterwards or, at most, complained of a light tenderness in the lower abdomen.

Ovarian capsule drilling

For the purpose of drilling of the ovarian capsule, a 5F bipolar needle (Storz, Tuttlingen) is used. After instillation of enough warm Ringer's lactate (~300 ml), the total ovarian surface can easily be identified and inspected. Because of the distension, and the floating of the organs, intestines are kept at a distance. The 5F bipolar needle is gently pushed against the ovarian surface, and current is activated with an energy output of 70 W. To obtain a maximal effect of energy delivery, the inflow of Ringer's lactate is stopped during activation of the current. This enables easy insertion of the needle in the ovarian tissue to a depth of 0.8 cm. The small needle diameter minimizes superficial damage and reduces the risk of postoperative adhesion formation. In total, between 10 and 15 small holes of ~1.5 mm are made, preferentially at the anterolateral side of each ovary (Figure 11.5).

Our own experience confirms the results of Fernandez *et al.*²⁶ and Casa *et al.*²⁷, showing the feasibility of the transvaginal approach, with results comparable to those obtained after standard laparoscopic procedures.

The procedure is easy to perform, with a low morbidity, and allowing at the same time a complete

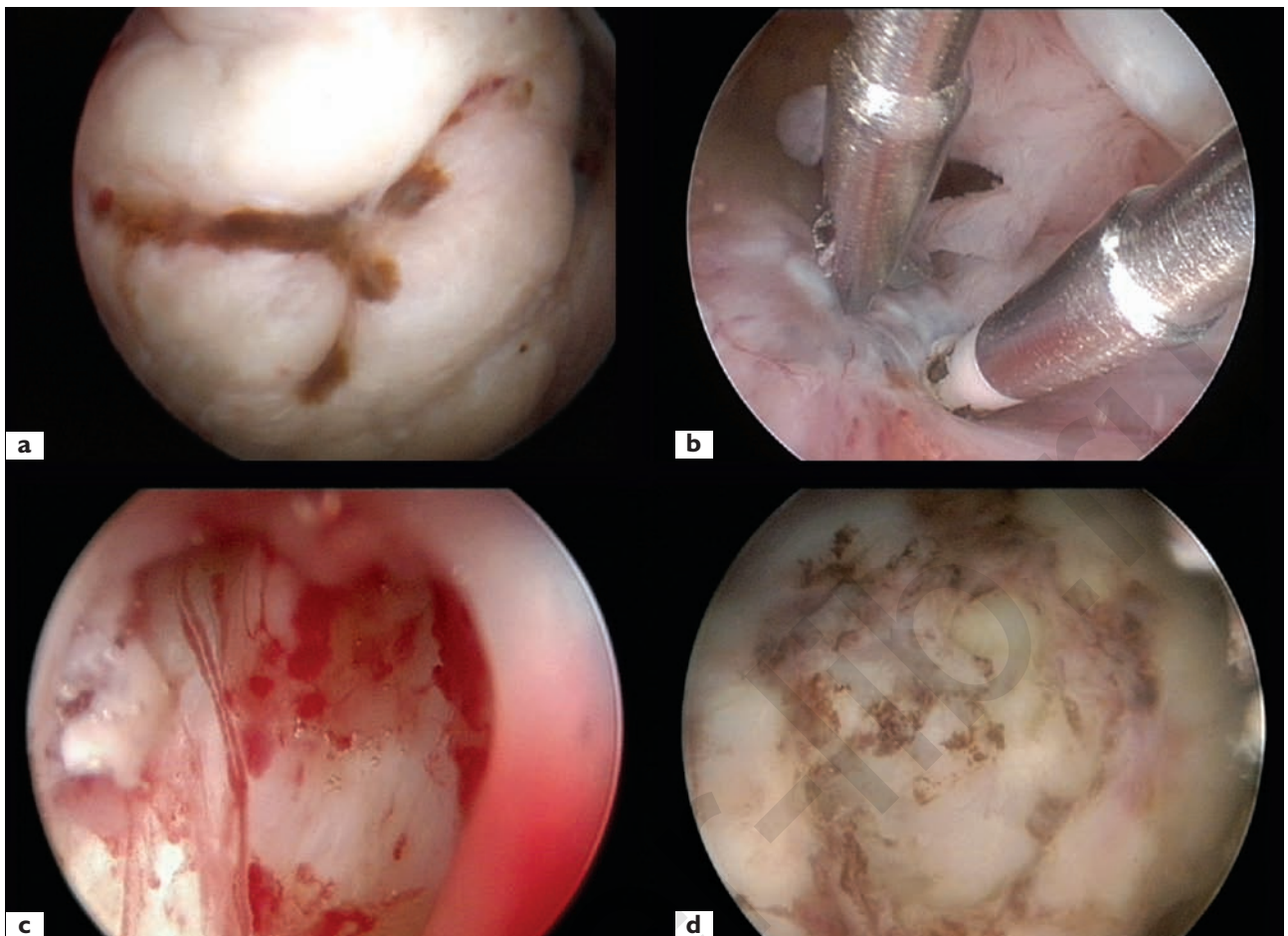


Figure 11.4 Ovarian endometriosis. (a) Endometriotic lesion with invaginating ovarian cortex; (b) use of 5F scissors and bipolar probe for adhesiolysis and opening of the endometrioma at site of invagination; (c) after rinsing, endometriotic lesions and neovascularization are clearly visualized at the base of the endometrioma; (d) view after coagulation of the inner lining of the endometriotic cyst with a bipolar coagulation probe. In contrast with other benign ovarian cysts, there is no collapse of the rigid cystic wall

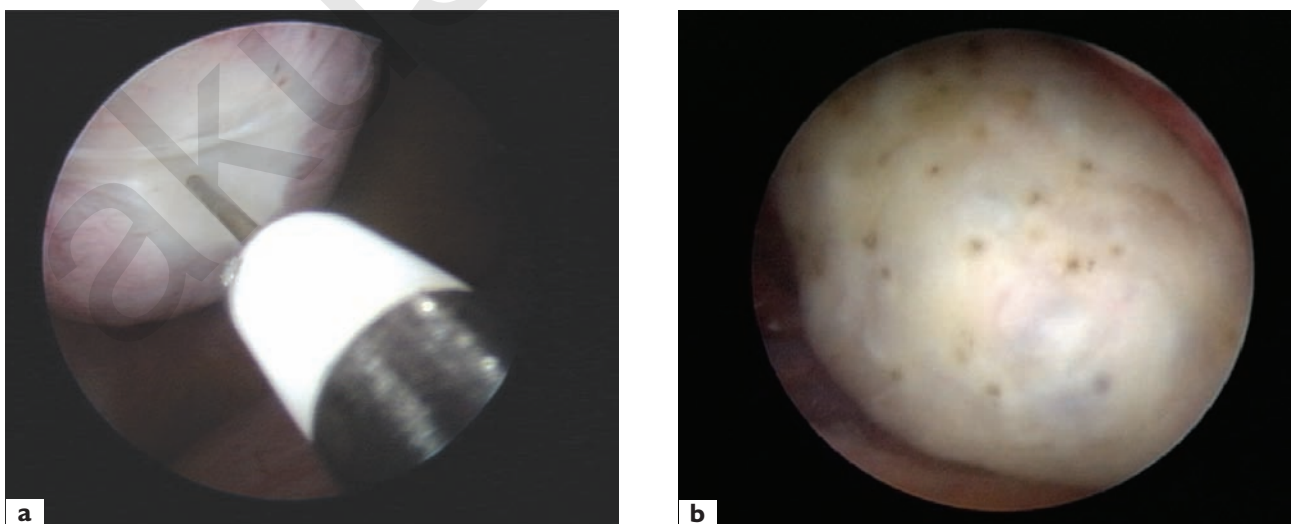


Figure 11.5 Drilling of ovarian capsule. (a) Bipolar needle placed perpendicular to the ovarian surface; (b) presence of small holes on the ovarian surface after drilling

exploration of the female pelvis. Therefore, this approach may be preferable to medical treatment with a prolonged low-dose step-up protocol using gonadotropins and the potential risk of ovarian hyperstimulation, and is certainly recommended before referring patients to an *in vitro* fertilization program. Recently, two complications have been reported after transvaginal drilling, wrongly interpreting the intestinal surface as the ovarian surface²⁸. They occurred during the initial experience of the author with the transvaginal technique, and underline the necessity of a training and learning period before attempting surgery at transvaginal laparoscopy. Filling up the abdomen with enough Ringer's lactate (at least 300 ml) will keep the intestines away, and, as for every operative procedure, anatomic identification of the different structures is mandatory.

SUMMARY

The technique of transvaginal laparoscopy offers, in subfertile patients without obvious pelvic pathology, the possibility via needle puncture of the cul-de-sac to explore in a minimally invasive way the tubo-ovarian structures in their normal position, using Ringer's lactate as distension medium. As the procedure can easily be combined with hysteroscopy and, when indicated, patency testing and salpingoscopy, a complete fertility check-up can be organized in a 'one-stop clinic' setting. Accurate diagnosis early on in the fertility work-up contributes to prompt and appropriate treatment for each individual couple.

In the absence of a panoramic view, there will be no place for major operative procedures. However, because of direct access to the tubes and ovaries and the use of an aqueous distension medium, minor interventions such as drilling of the ovarian capsule and treatment of minimal and mild endometriotic lesions can easily be performed. Before attempting surgery at transvaginal laparoscopy, a training and learning period is necessary.

REFERENCES

1. Decker A. Culdoscopy a method for visual diagnosis of gynecologic disease. *Clin Symp* 1952; 6: 201–10
2. Palmer R. *Les Explorations Fonctionnelles Gynécologiques*, 2nd edn. Paris: Masson, 1974: 226–8
3. Diamond E. Diagnostic culdoscopy in infertility: a study of 4,000 outpatient procedures. *J Reprod Med* 1978; 21: 23–30
4. Gordts S, Campo R, Rombauts L, Brosens I. Transvaginal hydrolaparoscopy as an outpatient procedure for infertility investigation. *Hum Reprod* 1998; 13: 99–103
5. Campo R, Gordts S, Brosens I. Minimally invasive exploration of the female reproductive tract in infertility. *Reprod Biomed Online* 2002; 4 (Suppl 3): 40–5
6. Gordts S, Campo R, Rombauts L, Brosens I. Endoscopic visualization of the process of fimbrial ovum retrieval in the human. *Hum Reprod* 1998; 13: 1425–8
7. Gordts S, Campo R, Rombauts L, Brosens I. Transvaginal salpingoscopy: an office procedure for infertility investigation. *Fertil Steril* 1998; 70: 523–6
8. Gordts S, Puttemans P, Gordts S, et al. Transvaginal hydrolaparoscopy. *Best Pract Res Clin Obstet Gynaecol* 2005; 19: 757–67
9. Gordts S, Waterlot A, Campo R, Brosens I. Risk and outcome of bowel injury during transvaginal pelvic endoscopy. *Fertil Steril* 2001; 76: 1238–41
10. Watrelot A, Dreyfus JM, Andine JP. Evaluation of the performance of fertiloscopy in 160 consecutive infertile patients with no obvious pathology. *Hum Reprod* 1999; 14: 707–11
11. Darai E, Dessolle L, Lecuru F, Soriano D. Transvaginal hydrolaparoscopy compared with laparoscopy for the evaluation of infertile women: a prospective comparative blind study. *Hum Reprod* 2000; 15: 2379–82
12. Moore ML, Liu GY, Cohen M, Waliser TJ. Transvaginal hydrolaparoscopy. *J Am Assoc Gynecol Laparosc* 2002; 9: 389–93
13. Shibahara H, Fujiwara H, Hirano Y, et al. Usefulness of transvaginal hydrolaparoscopy in investigating infertile women with Chlamydia trachomatis infection. *Hum Reprod* 2001; 16: 1690–3
14. Dechaud H, Ali Ahmed SA, Aligier N, et al. Does transvaginal hydrolaparoscopy render standard diagnostic laparoscopy obsolete for unexplained infertility investigation? *Eur J Obstet Gynecol Reprod Biol* 2001; 94: 97–102
15. Moore ML, Cohen M, Liu GY. Experience with 109 cases of transvaginal hydrolaparoscopy. *J Am Assoc Gynecol Laparosc* 2003; 10: 282–5
16. Verhoeven H, Gordts S, Campo R, et al. Role of transvaginal laparoscopy in the investigation of female infertility: a review of 1000 procedures. *Gynecol Surg* 2004; 1: 191–3
17. Gordts S, Campo R, Brosens I. Office transvaginal hydrolaparoscopy for early diagnosis of pelvic endometriosis and adhesions. *J Am Assoc Gynecol Laparosc* 2000; 7: 45–9
18. Moore ML, Cohen M. Diagnostic and operative transvaginal hydrolaparoscopy for infertility and pelvic pain. *J Am Assoc Gynecol Laparosc* 2001; 8: 393–7
19. Brosens I, Campo R, Puttemans P, Gordts S. One-stop endoscopy-based infertility clinic. *Curr Opin Obstet Gynecol* 2002; 14: 397–400
20. Sampson JA. Perforating hemorrhagic (chocolate) cysts of the ovary. *Arch Surg* 1921; 3: 245–323
21. Hughesdon PE. The structure of the endometrial cysts of the ovary. *J Obstet Gynaecol Br Emp* 1957; 44: 481–7
22. Brosens IA, Puttemans PJ, Deprest J. The endoscopic localization of endometrial implants in the ovarian chocolate cyst. *Fertil Steril* 1994; 61: 1034–8

23. Donnez J, Wijns C, Nisolle M. Does ovarian surgery for endometriomas impair the ovum response to gonadotrophins? *Fertil Steril* 2001; 76: 662-5
24. Gordts S, Campo R, Brosens I. Experience with transvaginal hydrolaparoscopy for reconstructive tubo-ovarian surgery. *Reprod Biomed Online* 2002; 4 (Suppl 3): 72-5
25. Brosens I, Van Ballaer P, Puttemans P, Deprest J. Reconstruction of the ovary containing large endometriomas by an extraovarian endosurgical technique. *Fertil Steril* 1996; 66: 517-21
26. Fernandez H, Alby JD, Gervaise A, et al. Operative transvaginal hydrolaparoscopy for treatment of polycystic ovary syndrome: a new minimally invasive surgery. *Fertil Steril* 2001; 75: 607-11
27. Casa A, Sesti F, Marziali M, et al. Transvaginal hydrolaparoscopic ovarian drilling using bipolar electrosurgery to treat anovulatory women with polycystic ovary syndrome. *J Am Assoc Gynecol Laparosc* 2003; 10: 219-22
28. Chiesa-Montadou S, Rongieres C, Garbin O, Nisand I. About two complications of ovarian drilling by fertiloscopy. *Gynecol Obstet Fertil* 2003; 31: 844-6

akusher-lib.ru

akusher-lib.ru

CO₂ laser laparoscopic surgery: fimbrioplasty, salpingoneostomy and adhesiolysis

J Donnez, P Jadoul, M Smets and J Squifflet

New perspectives have emerged in the management of distal tubal occlusion from the tremendous advances gained in the field of assisted reproduction technology and in operative endoscopy techniques. With regard to surgery, it has been demonstrated, on numerous occasions, that classic microsurgery¹⁻³ and laparoscopic surgery⁴⁻⁹ show comparable results in terms of pregnancy rates. There is no doubt that the crucial issue in the surgical management of distal tubal occlusion is the proper selection of patients according to a set of strict criteria, which have prognostic value in determining the chances of postoperative conception.

PHYSIOPATHOLOGY OF HYDROSALPINX

To understand the physiopathological events associated with the development of distal tubal occlusion, an experimental model was created in the rabbit by ligating the uterotubal junction and the ampullofimbrial junction¹⁰.

This model closely reproduces natural clinical hydrosalpinx, observed in 10–15% of all infertile patients. The size of the experimental hydrosalpinx can reach up to 2 cm, 6 months after ligation. Morphologically, only the epithelium of the ampulla is affected by a significant deciliation process, which appears in the 2 months after induction of the experimental hydrosalpinx; epithelial height is seen to be decreased, and the stroma thickens because of submucosal edema and fibrosis. After 6 months, primary mucosal folds become scarce and atrophic, whereas secondary folds in the ampulla disappear completely (Figure 12.1).

Ampullary muscularis is typically invaded by fibrosis, and the size of the capillaries in the tubal wall is significantly decreased; this decrease in the ampullary vascularization probably explains the deciliation process. It should be pointed out that the muscularis layer also shares a role in transportation of the fertilized egg, since intrauterine pregnancies have been described in Kartagener's syndrome¹¹.

In addition, there is generalized adrenergic denervation of the tubal wall, this feature being more prominent on the isthmus portion than at the level of the ampulla, where the innervation is minimal in the healthy tube¹².

All of these lesions induced by hydrosalpinx in the muscularis layer are permanent, and explain the high failure rate associated with the surgical restoration of tubal patency. The increase in fluid volume in hydrosalpinx is probably the result of depolymerization of the fluid

components and subsequent transudation from the underlying chorion. It could also result from a slowing down in secretion of fluid by the epithelial cells, combined with the complete absence of drainage¹⁰⁻¹².

The experimental hydrosalpinx induced in rabbits and hydrosalpinx observed in infertile women have similar patterns: distension associated with unfolding of the mucosal folds and degeneration of the epithelial cells.

The deciliation index investigated on fimbrial biopsies and the degree of dilatation are correlated, and both serve as physiopathological prognostic factors for the success of salpingoneostomy. Indeed, from hydrosalpinx specimens obtained at hysterectomy, it seems that the occurrence of dilatation of the tube results in adrenergic denervation and fibrosis of the muscular layer, completely in accordance with the observations made in the experimental model^{10,11}.

DIAGNOSIS OF HYDROSALPINX

The presence of hydrosalpinx can be diagnosed by a hysterosalpingogram (Figure 12.2) or by laparoscopy with or without chromopertubation. A meta-analysis of all the studies comparing hysterosalpingography with the gold standard of laparoscopy with chromopertubation showed the hysterosalpingogram to have a sensitivity of 65% and a specificity of 83% in the diagnosis of tubal obstruction^{13,14}.

Transvaginal ultrasonography has also been used to evaluate pelvic structures. Normal Fallopian tubes can only be recognized in the presence of pelvic fluid. Transvaginal ultrasonography is very specific in the diagnosis of hydrosalpinx, but its sensitivity is poor¹⁵. Occasional longitudinal folds in the ampullary portion of the Fallopian tube can be seen¹⁶ by transvaginal ultrasonography. A study by Atri *et al.*¹⁵ evaluated the accuracy of endovaginal sonography in the detection of Fallopian tube blockage, and found the specificity of transvaginal ultrasonography to be 100%, with a sensitivity of only 34%. Methods using the passage of air or fluid to visualize the tubes sonographically have also been described. The same principle makes sonohysterosalpingography a useful tool in the diagnosis of hydrosalpinx¹⁷⁻¹⁹. Color Doppler ultrasonography has also been used in evaluating tubal patency and diagnosing hydrosalpinx^{20,21}. Other diagnostic methods include salpingoscopy or falloscopy²²⁻²⁴.

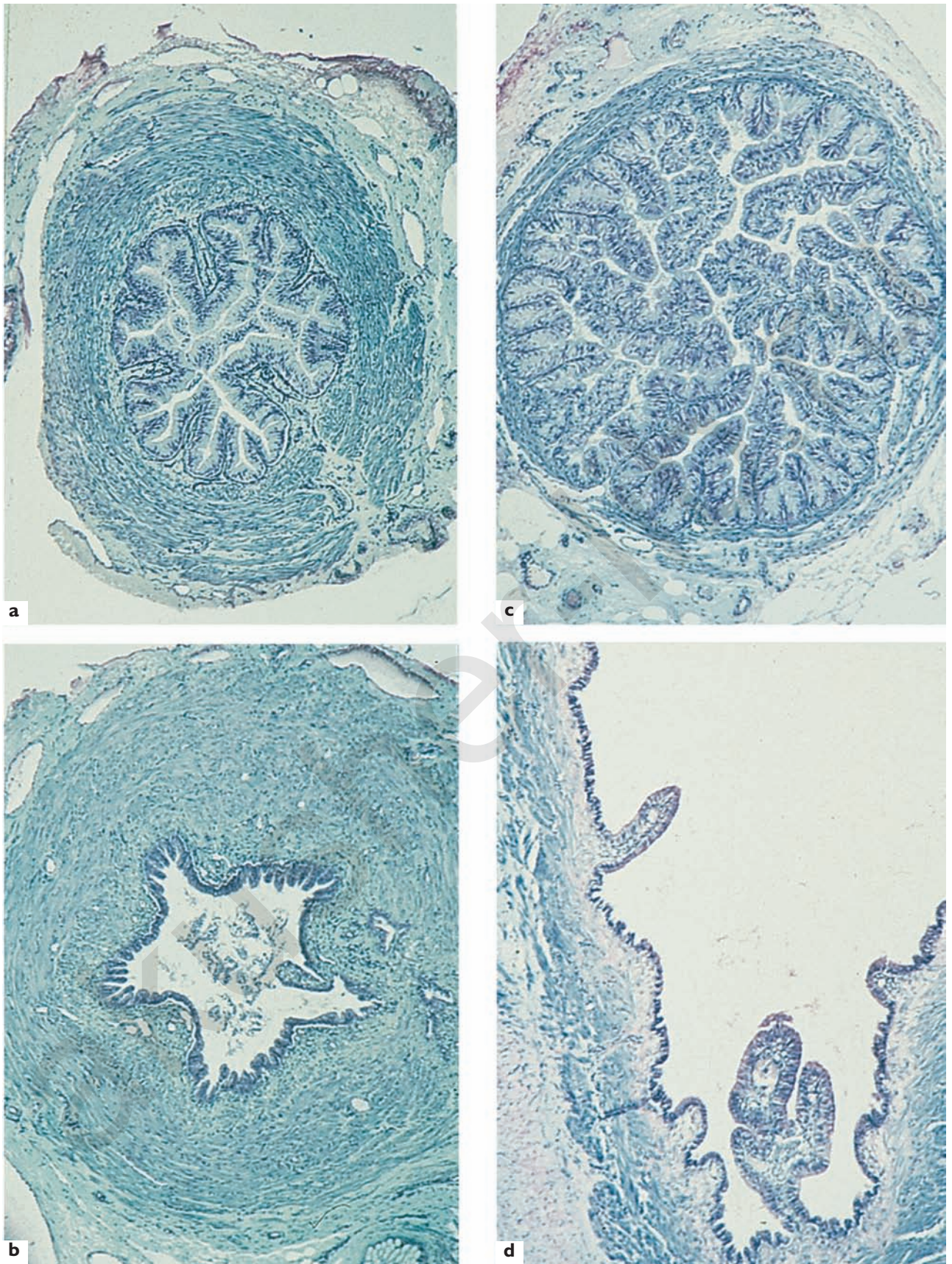


Figure 12.1 Experimental hydrosalpinx. (a) Normal isthmus; (b) dilated isthmus after induction of experimental hydrosalpinx; (c) normal ampulla; (d) dilated ampulla after induction of experimental hydrosalpinx. Note the reduction in number and size of ampullary folds and flattened epithelium between the ampullary folds

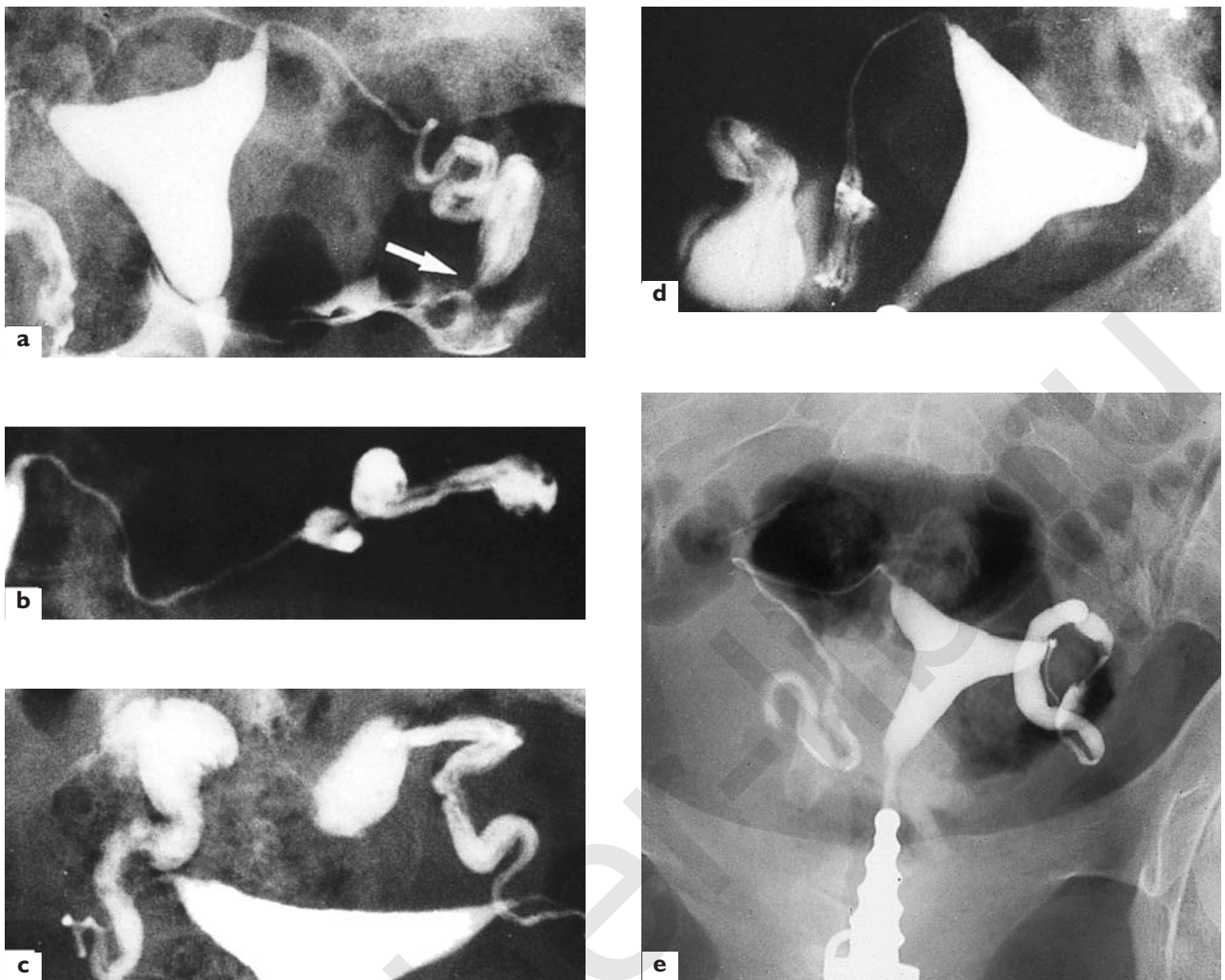


Figure 12.2 Tubal occlusion according to our classification. (a) Degree I: phymotic ostium with preserved tubal patency; (b) degree II: total distal occlusion without ampullary dilatation; (c) degree III: ampullary dilatation <2.5 cm, ampullary folds well-preserved; (d) degree IV: hydrosalpinx simplex, dilatation >2.5 cm, well-preserved ampullary folds; (e) degree V: thick-walled hydrosalpinx, absence of ampullary folds

DEFINING THE PROGNOSTIC FACTORS FOR SUCCESSFUL TUBAL SURGERY

In the management of distal tubal infertility, *in vitro* fertilization (IVF) and tubal surgery should not be considered as competitive, but rather as complementary, modalities²⁵.

When feasible, and with a good chance of success, surgery should always be attempted; IVF should only be considered when the fertility prognosis associated with conservative surgery is too poor. The conditions for surgical feasibility are based on thorough evaluation of the prognostic factors, usually obtained preoperatively and at the time of laparoscopy; this will orientate the patient towards the best therapeutic alternative. Factors contributing to the establishment of a prognosis for surgery can be subdivided into two groups: tubal and extratubal

factors. The information collected during the evaluation phase is usually included in various scoring systems, with the aim of better defining the chances of conception if a surgical approach is selected.

Tubal factors

Inflammation following pelvic infection during surgery leads to tubal damage which is observed, described and eventually scored through different investigational procedures.

Tubal factors to be considered are:

- Ampullary dilatation
- Preservation of the ampullary folds
- Detection of intratubal adhesions
- Macroscopic and microscopic mucosal tubal status

Table 12.1 Classification of distal tubal occlusion by Donnez and Casanas-Roux²⁷

Degree I	Phymotic ostium with preserved tubal patency
Degree II	Total distal tubal occlusion without ampullary dilatation
Degree III	Ampullary dilatation inferior to 2.5 cm; ampullary folds well-preserved
Degree IV	Hydrosalpinx simplex; dilatation more than 2.5 cm; well-preserved ampullary folds
Degree V	Thick-walled hydrosalpinx; absence of ampullary folds

Table 12.2 Distal tubal scoring system of Mage and colleagues³¹

<i>Tubal patency</i>	<i>Ampullary tubal mucosa (hysterosalpingography)</i>	<i>Ampullary tubal wall (laparoscopy)</i>
Phimosis = 2	Normal folds = 0 Decreased folds = 5	Normal = 10 Thin = 5
Hydrosalpinx = 5	No fold, honeycomb = 10	Thick or rigid = 10

Ampullary dilatation

Ampullary dilatation is best assessed and measured at the time of the hysterosalpingogram. Indeed, we, like others²⁶, are convinced that a well-performed hysterosalpingography (Figure 12.2) remains one of the best investigational examinations of the infertile patient.

Hysterosalpingography provides clear information on the normality of the uterine cavity and the endocervical canal, the patency and status of the intramural/interstitial portion of the tube, the patency, possible dilatation, rigidity and anatomy of the ampullar segment and, finally, the suspicion of peritubal adhesions, although the predictive value of the latter remains poor, compared with direct visualization by laparoscopy.

We have proposed a hysterosalpingographic classification of distal tubal occlusion²⁷, based on the extent of occlusion combined with the preservation of the ampullary folds (Table 12.1 and Figure 12.2).

From a series of 215 infertile women with bilateral distal tubal disease operated on using microsurgery²⁷, it was concluded that ampullary dilatation, as determined by laparoscopy and hysterosalpingography, influences the postoperative pregnancy rate.

After fimbrioplasty for degree I occlusion and salpingostomy for degree II occlusion, the term pregnancy rate averaged 50%, whereas salpingoneostomies performed for degree III and IV occlusions resulted in term pregnancy rates of 25% and 22%, respectively. Singhal *et al.*²⁸ found that microsurgical salpingostomy success rates drop if the dilatation is either less or more than 2 cm. The prognostic grading system elaborated by the American Fertility Society (AFS)²⁹ clearly follows the same lines, stating that

an ampullary diameter over 3 cm gives a poor pregnancy outcome.

A prospective study by Vasquez *et al.*³⁰, investigating tubal mucosal lesions and fertility in hydrosalpinges, concluded that there was a significantly better outcome following surgery of thin-walled hydrosalpinges of less than 1 cm in size, compared with moderate (1–2 cm) and large hydrosalpinges (> 2 cm). However, size should not be considered without close examination of the thickness of the ampullary wall, as thick-walled hydrosalpinges, usually with moderate dilatation, have the worst prognosis²⁷.

Preservation of the ampullary folds

The presence of ampullary folds can be observed by hysterosalpingography, endovaginal echography, hysterosalpingosonography and falloscopy. Hysterosalpingography is still considered as a reference for the description of the inner architecture of the ampulla, and is included in several tubal scoring systems (Table 12.2)³¹.

A number of other examinations have recently been proposed as alternative investigational procedures.

Endovaginal echography has the resolution power to reveal the presence of rugae in dilated tubes (Figure 12.3).

Compared with hysterosalpingography, endovaginal echography offers poor sensitivity in the detection of hydrosalpinges (obviously less so in description of the tubal wall); it is, however, thought to be potentially useful in detecting a combination of proximal and distal tubal blockages when hysterosalpingography shows a proximal block¹⁵.

Hysterosalpingosonography³² was developed mainly to document tubal patency, sometimes using a color Doppler

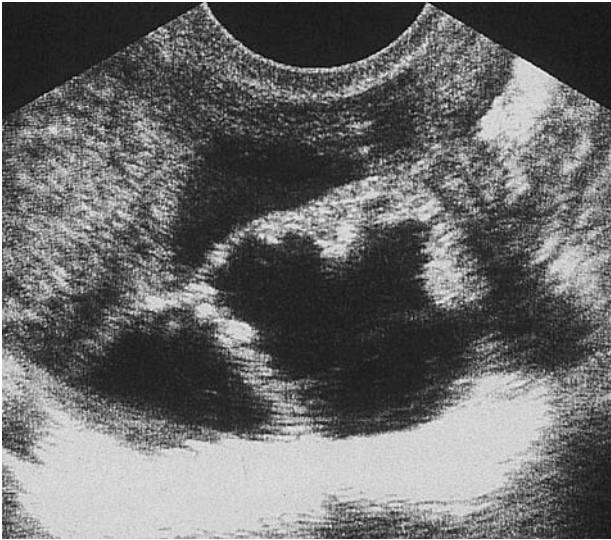

Figure 12.3 Vaginal echography reveals the presence of well-preserved ampullary folds

imaging system^{33,34}, and offers the following advantages over classic hysterosalpingography: absence of radiation, avoidance of potential allergic reactions to iodinated contrast medium and the possibility of office use. While the results correlate well with those of hysterosalpingography and laparoscopic findings as far as tubal patency^{33,34} is concerned, the technique cannot correctly delineate the inner architecture of the Fallopian tube and is therefore of little prognostic interest²⁶.

Falloscopy is the endoscopic (transhysteroscopic) exploration of the tube²⁴, an office procedure³⁵ that can reveal tubal status. There is, at this stage, a definite lack of studies correlating this procedure with hysterosalpingographic and/or laparoscopic features, and with fertility outcome. A classification of luminal disease exists³⁶, but it does not explicitly consider ampullary-fold preservation as a significant parameter. The obscure and narrow view

Table 12.3 Hydrosalpinx classification by Boer-Meisel *et al.*³⁹

1	Normal mucosa; regular patterns of lush mucosal folds, richly vascularized
2	Hydrosalpinx with moderate attenuation of mucosal folds; patches of normal mucosa
3	Absence of ampullary folds; honeycomb aspect

provided by these endoscopes limits the quality and reliability of the observations, thereby somewhat restricting the importance of this examination in the evaluation of ampullary-fold preservation. If not using hysterosalpingography, mucosal folds are probably best visualized at the time of laparoscopy, combined or not with salpingoscopy^{22,37}, or under the magnifying microscope at microsurgery. A scarcity of endotubal folds is unanimously recognized as unfavorable^{10,27,29,31,38,39}.

Boer-Meisel *et al.*³⁹ proposed an endosalpingeal score as part of an overall score for distal tubal occlusions (Table 12.3). This endosalpingeal score was recently demonstrated by Dubuisson *et al.*⁴⁰ to correlate closely with more complex classification systems and to predict fertility outcome satisfactorily.

In our series, in the complete absence of mucosal folds, often associated with thick and fibrotic tubal walls, no intrauterine pregnancies were obtained after microscopic repair.

A complete absence of mucosal folds can also be linked to genital tuberculosis. In this disease, opening the hydrosalpinx reveals the presence of caseum and an absence of ampullary folds (Figure 12.4).

Tuboscopy has the potential to provide an excellent close-up image of the tubal architecture. Abnormal findings can be revealed by tuboscopy in 20–30% of cases with an otherwise normal hysterosalpingography and/or laparoscopy⁴¹.

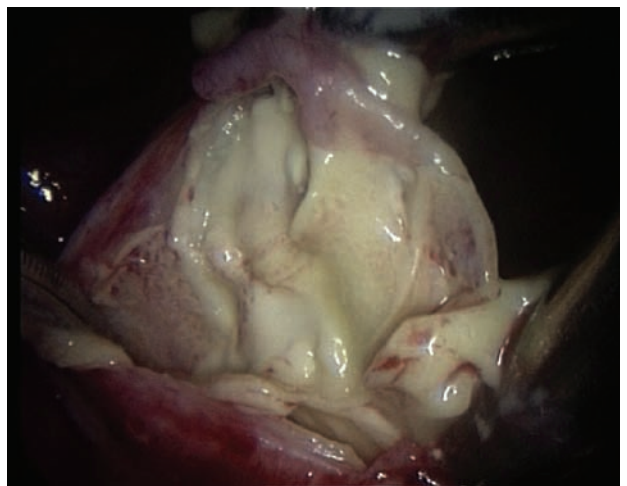
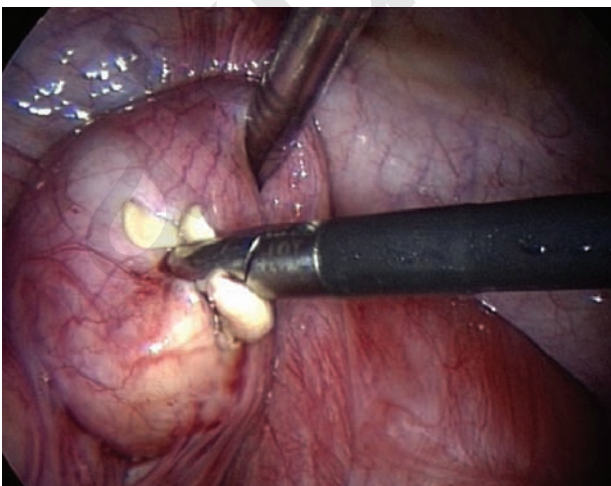


Figure 12.4 Genital tuberculosis: salpingotomy reveals the presence of caseum and an absence of ampullary folds

Herschlag *et al.*⁴², attempting to correlate salpingoscopic findings (including evaluation of the mucosal-fold architecture) with histology, demonstrated a good correlation, but only in cases of mild and severe disease. Our surgical stance depends on a combination of these first two prognostic factors, i.e. the degree of distal occlusion and the preservation of ampullary folds, as assessed by hysterosalpingography^{27,43}.

Detection of intratubal adhesions

Intratubal adhesions are detected only at falloscopy and/or tuboscopy. The formation of intratubal adhesions is one consequence, among others, of an underlying inflammatory process. It is not recognized specifically as a major prognostic factor, probably because the use of tuboscopy is not generalized. Herschlag *et al.*⁴², however, include this parameter in their tuboscopic score. No intrauterine pregnancy was reported in the presence of intratubal adhesions by De Bruyne *et al.*²³ in the presence of intratubal adhesions in a series of 17 patients, despite an overall intrauterine pregnancy rate of 59% in their study. Vasquez *et al.*³⁰ also clearly addressed this issue; in a multicenter study of 50 patients, it was concluded that mucosal adhesions in thin-walled hydrosalpinges are the most important factor in determining fertility outcome. Indeed, the presence and absence of intratubal adhesions were associated with intrauterine pregnancy rates following surgery of 22% and 58%, respectively, thus differing significantly. The rate of ectopic pregnancy was 11% if adhesions had previously been discovered; this condition is seriously affected by a significant risk of ectopic gestation, as was also stressed by Marana *et al.*⁴⁴.

Evaluation of the tubal mucosa

The tubal mucosa can be assessed endoscopically, and the observations are often included in various scoring classifications^{6,27,29,31,39}. Apart from the various features already reviewed above, macroscopic evaluation of the tubal mucosa attempts to determine the tubal wall thickness³¹, and also to distinguish areas of normal-appearing mucosa on the tubal wall, the inflammatory aspect of the epithelium and the underlying vascularization. We pointed out^{6,10} that the smaller is the area of normal mucosal surface observed under the operative microscope, the lower is the incidence of intrauterine pregnancy. The difference was clearly significant when the cut-off level was determined at 50% of normal-appearing mucosal surface.

Histological data in tubal infertility are available from some authors^{10,45}, who have studied the histophysiological factors of distal tubal occlusions and correlated their findings with pregnancy outcome.

The ciliation index

The ciliation index has proved to be valuable in the prognosis of tubal surgery^{3,10,45}. In our original study in which we investigated the prognostic factors of fimbrial microsurgery in 215 patients²⁷, the ciliated cell percentage, as evaluated on fimbrial microbiopsy, and the pregnancy outcome were significantly decreased in the case of degree III and IV distal occlusion, compared with degree I and II. In our study, the ciliation index was related to the pregnancy rate after microsurgical correction of the distal occlusion.

Fibrosis and the thickness of the tubal wall

Long-standing evolution of hydrosalpinges sometimes leads to invasion of the muscularis by fibrosis, which is responsible for a significant thickening of the tubal wall and ultimately results in so-called thick-walled hydrosalpinx. Vasquez *et al.*³⁰ have correlated the incidence of thick-walled hydrosalpinx with histological parameters: in thick-walled hydrosalpinges, the thickness of the tubal wall measures 2–10 mm at the thinnest part and 4–10 mm at the thickest part. Thick-walled hydrosalpinx is usually associated with other unfavorable macro- and microscopic features, explaining the very poor results of fertility-promoting surgery. In our series²⁷, the intrauterine pregnancy rate for this type of tubal pathology was 0%, as also obtained by some other authors^{1–3,30,40}. The recommended approach in this case is to perform a salpingectomy at the time of laparoscopy, in an attempt to enhance the results of IVF⁴⁶ and to limit the incidence of tubal gestation, reported to be as high as 11% in tubal infertility patients undergoing IVF⁴⁷.

Extratubal factors

Adnexal adhesions and endometriosis are sometimes included in the list of prognostic factors affecting pregnancy rates.

Periadnexal adhesions

The significance of pelvic adhesions is controversial in the prognosis of patients with tubal factors. Studies by several authors^{2,28,38,39} suggest that the fertility prognosis correlates with the presence of tubal adhesions and degree of severity. Some investigators^{48,49} restrict the negative influence of adhesions to severe cases only; frozen pelvis is still considered as a contraindication to conservative surgery. Nevertheless, it should be noted that microsurgical or laparoscopic adhesiolysis alone has been shown to promote fertility^{28,43,50}, implicating adhesions in mechanical infertility.

The most recent series, however, appear to challenge the role of adhesions in impairing fertility following surgery. Dubuisson *et al.*⁴⁰, in a series of 90 patients undergoing laparoscopic salpingostomy, failed to show any relationship between adhesion score and pregnancy

outcome. Canis *et al.*⁹ did not note any significant difference in their group of 87 laparoscopic tuboplasties as far as gross pregnancy and monthly fecundity rates were concerned. The implication of periadnexal adhesions has also recently been questioned by Vasquez *et al.*³⁰ in a prospectively designed study.

After tubal infections, periadnexal adhesions can be associated with perihepatic adhesions (Fitz-Hugh-Curtis Syndrome; Figure 12.5).

Endometriosis

Endometriosis has rarely been taken into account in the evaluation of the success of tubal surgery. The most recent study in this respect is by Dlugi *et al.*⁴⁹, who, on treating 113 patients with tubal factors and comparing pregnancy curves, concluded that endometriosis-related tubal occlusion was less detrimental than post-pelvic inflammatory disease or post-surgical tubal distal occlusion. Obviously, treating any concomitant endometriosis at the time of tubal surgery already improves fertility outcome, and can therefore modulate the actual implication of endometriosis as a prognostic factor for successful tuboplasty.

This finding is corroborated by Nezhat *et al.*⁵¹, who found no significantly abnormal results using tuboscopy in a population of 100 patients with endometriosis. This might suggest a better inner tubal condition in distal tubal occlusion of endometriotic origin, compared with distal tubal occlusion of inflammatory etiology, where mucosal impairment is probably more pronounced.

TECHNIQUES AND RESULTS

Tubal occlusion: degree I

Fimbrioplasty is also carried out during laparoscopy. When fimbrial adhesions are found as the blue dye begins to spill

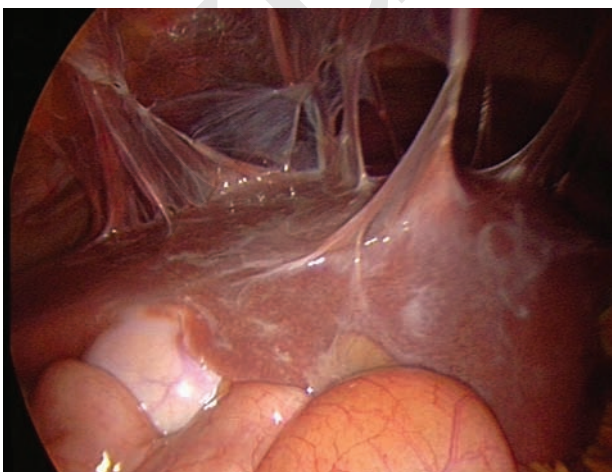


Figure 12.5 Perihepatic adhesions

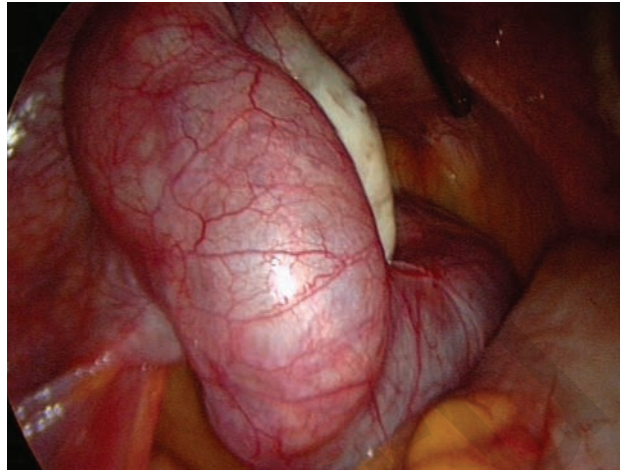


Figure 12.6 Hydroosalpinx: tubal occlusion of degree III; laparoscopic view

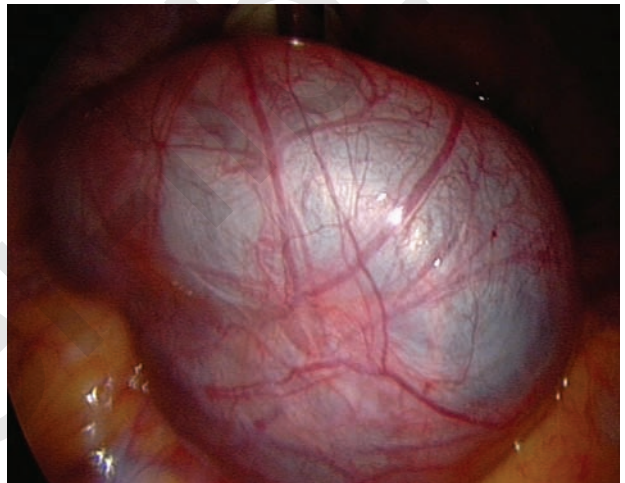


Figure 12.7 Exposure of the distal part of the hydroosalpinx

out through the open tube, these adhesions between the fimbrial folds are carefully grasped by means of a probe with a hook passed through a third-puncture trocar, and cut in a bloodless fashion with the finely focused CO₂ beam set at 40 W. Thereafter, a defocused beam (10 W) is used to cause blanching of the serosa.

The SurgiTouch™ is useful for this purpose. It allows adequate eversion of the mucosa and prevents any recurrence of adhesions.

Tubal occlusion: degrees II, III and IV

Salpingostomy can be performed with the CO₂ laser, and is indicated in cases of thin-walled hydroosalpinx where both proximal tubal patency and the presence of ampullary folds have been confirmed by a hysterosalpingogram (Figure 12.6).

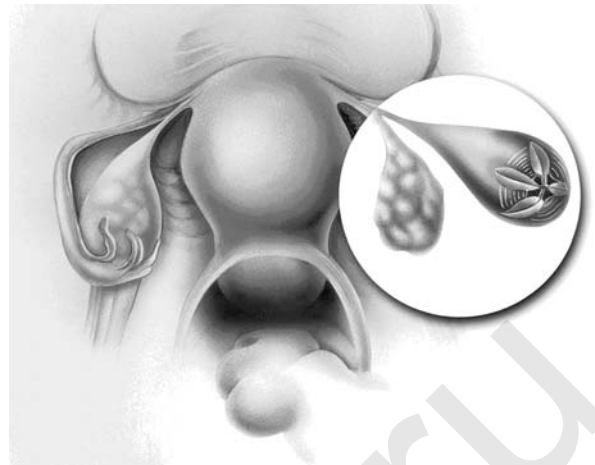
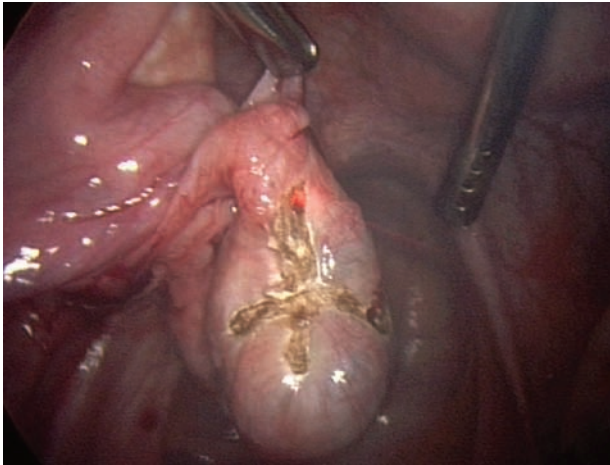


Figure 12.8 Two linear incisions are made with the focused beam

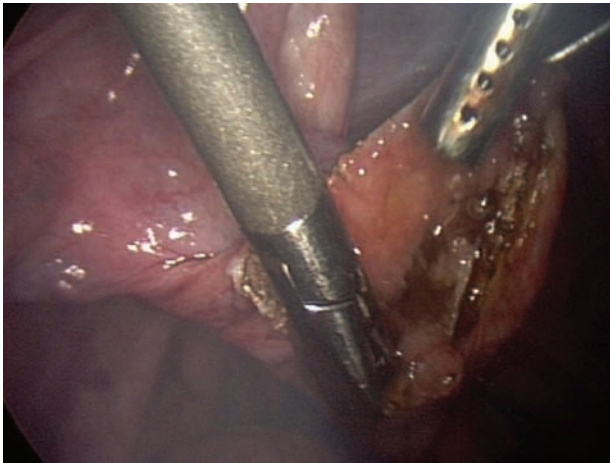


Figure 12.9 The opened tube is gently grasped

Two grasping forceps are introduced for traction and manipulation of the ampullary–fimbrial segment. The blocked tube is held so that the focused laser beam can be aligned at a 90° angle to the dimple (Figure 12.7).

The laser is set to continuous mode (40 W) and two linear incisions are made (Figure 12.8), cutting from the anterior to the posterior part along blood vessels.

As soon as the lumen is entered, the tube collapses; continuous dye injection keeps it distended. Only then is the incision enlarged. At this point, the probes and grasping forceps gently hold the incision edges (Figure 12.9) and a reduced-power (10–15 W), defocused beam (SurgiTouch) is used to evert the serosal aspect of the incised edge (Figure 12.10).

The final aspect of the tube reveals a well-everted fimbria, and, if performed, ampulloscopy reveals the presence of well-vascularized ampullary folds (Figure 12.11). At the end of the procedure, the peritoneal cavity is irrigated with Ringer’s solution to remove carbonized particles.

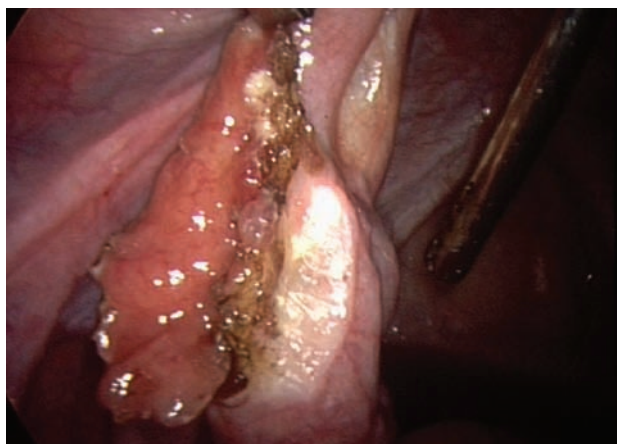
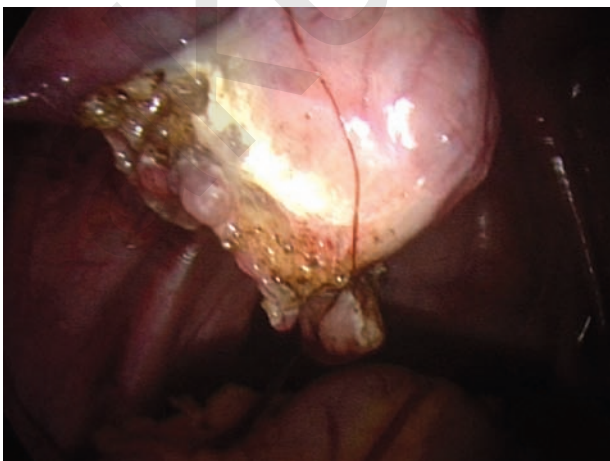
Figure 12.10 The defocused SurgiTouch™ beam is used to evert the serosal aspect of the incised edge

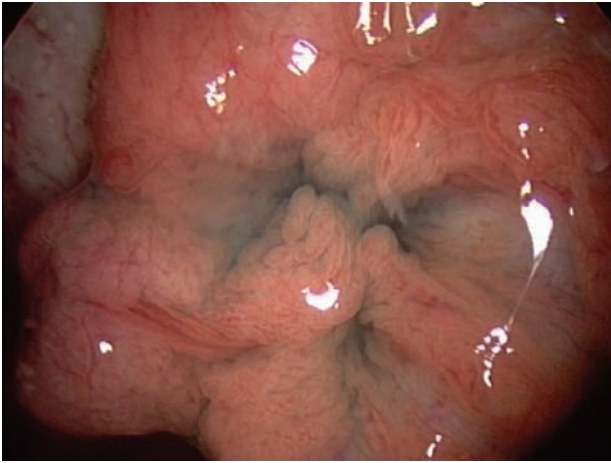


Figure 12.11 Final aspect: well-vascularized ampullary folds

Tubal occlusion: degree V

In the case of thick-walled hydrosalpinx, the ampullary folds are absent. The pregnancy rate after microsurgery¹⁰ is 0%; for this reason, there is no indication for salpingostomy.

We propose laparoscopic salpingectomy to patients before an IVF procedure, in order to avoid the risk of tubal pregnancy after embryo transfer. Table 12.4 reports the results we obtained in a series of 1184 laparoscopic tubal surgery cases⁴³.

As has been repeatedly reported in the literature, these figures are comparable to results obtained with microsurgery and in other laparoscopic series. Indeed, the pregnancy rates are significantly different after fimbrioplasty for degree I occlusions (60%), and after salpingoneostomy for degree III and IV occlusions. In the case of adhesiolysis, the pregnancy rates are 62% and 51%, according to the type of adhesions (degree I and II, respectively).

Table 12.4 Laser laparoscopic management of distal occlusion: 18-month cumulative viable pregnancy rate⁴³

Procedure	n	Pregnancies	
		n	%
Fimbrioplasty	380	228	60
Salpingostomy	85	22	27
Adhesiolysis			
degree I	412	255	62
degree II	307	157	51

Table 12.5 summarizes the results obtained in major series of laparoscopic salpingoneostomies; the intrauterine pregnancy rates range from 19% to 48%, according to the inclusion criteria reported by the authors. These rates remain low and underline the fact that the tubes have probably undergone irreversible damage. The degree of the lesion influences the success of fertility-promoting surgery, so it is essential to rely on prognostic factors, the evaluation of which will help in predicting the success of a surgical approach. We have opted for the technique summarized in Figure 12.12 for the management of distal tubal occlusion.

In degree II–IV distal tubal occlusion, hysterosalpingography is systematically performed 3 months after surgery under antibiotic prophylaxis, in the absence of pregnancy. Reocclusion is, in our opinion, an indication to remove laparoscopically the diseased tube and direct the patient towards IVF, as the presence of hydrosalpinx is thought to impair the success rate of IVF and expose the patient to an increased risk of ectopic gestation^{46,47}. In the case of thick-walled hydrosalpinx (degree V, according to Donnez and Casanas-Roux²⁷), the ampullary folds are absent. The pregnancy rate after microsurgery is 0%; for this reason, there is no indication for salpingostomy. Since 1991, we have proposed laparoscopic salpingectomy to patients before an IVF procedure, in order to avoid the risk of tubal pregnancy after embryo transfer (ET) and the possibility of embryotoxicity, with subsequently low pregnancy rates.

Table 12.5 Intrauterine pregnancy rate obtained from laparoscopic salpingoneostomies

Authors	n	Intrauterine pregnancy rate (%)
Daniell and Herbert ⁵ (1984)	21	19
Nezhat* (1984)	33	36
Bouquet ⁵² (1987)	20	25
Reich ⁵³ (1987)	7	19
Manhes* (1987)	19	48
Donnez <i>et al.</i> ⁶ (1989)	25	20
Dubuisson <i>et al.</i> ⁷ (1990)	31	26
Larue ⁵⁴ (1990)	15	20
Henry-Suchet ⁵⁵ (1991)	28	32
McComb ⁵⁶ (1991)	22	22.7
Matvienko* (1991)	50	48
Canis <i>et al.</i> ⁹ (1991)	87	33.3
Audebert* (1992)	142	20.4
Donnez <i>et al.</i> ⁴³ (1994)	85	27
Total	585	29.03

*Personal communication

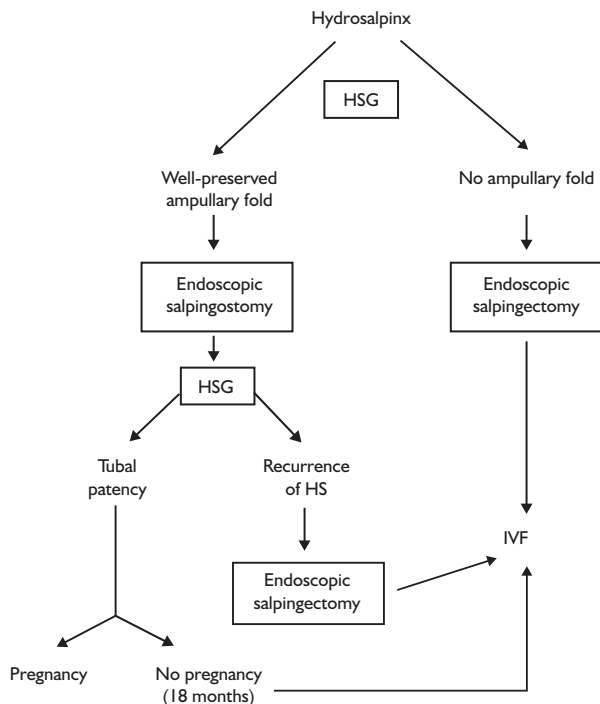


Figure 12.12 Proposed management of hydrosalpinx (HS) in infertility. HSG, hysterosalpingography; IVF, *in vitro* fertilization

HYDROSALPINX AND IN VITRO FERTILIZATION-EMBRYO TRANSFER

In a review, Nackley and Muasher⁵⁷ analyzed the effects of hydrosalpinx in IVF-ET.

Sims *et al.*⁵⁸ were the first to study the effect of hydrosalpinx on IVF outcome. A retrospective case-controlled study was conducted involving 118 patients with hydrosalpinx undergoing 283 stimulations, and 823 patients with tubal factor infertility without hydrosalpinx undergoing 1431 stimulations. A lower clinical pregnancy rate of 18%, and a higher miscarriage rate of 42% resulting in a lower ongoing pregnancy rate of 10%, were found, compared with the control group. They suggested treatment of hydrosalpinx before IVF by laparoscopic removal or peritransfer antibiotic coverage.

In a retrospective study, Strandell *et al.*⁴⁶ concluded that persistent hydrosalpinx was associated with a reduced implantation rate and an increased risk of early pregnancy loss. It was hypothesized that removal of the hydrosalpinx by salpingectomy or salpingostomy would normalize the IVF-ET rates in this group.

Andersen *et al.*⁵⁹ reported a marked reduction in implantation rates when hydrosalpinx was visible on ultrasonography. They found the rates of implantation, pregnancy, early pregnancy loss and delivery per aspiration

to be significantly reduced, despite a comparable number of aspirated oocytes and embryos transferred.

Vandromme⁶⁰ and Vejtorp⁶¹ and their groups also demonstrated a decreased pregnancy rate after IVF in women with hydrosalpinx. The significant reductions in implantation rate and pregnancy rate per transfer in the hydrosalpinx group suggest an unfavorable uterine environment.

We have suggested⁶² that this unfavorable environment could possibly be attributable to hydrosalpingeal fluid drainage into the endometrial cavity. It is conceivable that a connection exists between the hydrosalpinx and the uterine cavity, allowing direct flow of hydrosalpingeal fluid into the uterus, thus exposing the endometrium and the embryo to potentially toxic fluid. It is postulated that the fluid in damaged tubes contains micro-organisms, debris, lymphocytes, macrophages and other toxic agents that flow into the uterus and exert a detrimental effect on the endometrium and developing embryo. There may also be substances, such as cytokines and prostaglandins, interfering with normal endometrial function^{46,59}.

Freeman *et al.*⁶³ suggested that not only does hydrosalpinx negatively affect endometrial receptivity during implantation, but it also exerts a negative influence over oocytes early in follicular recruitment. The presence of hydrosalpinx has moreover been shown to affect implantation rates in unstimulated cycles⁶⁴.

Hydrosalpinx also predisposes patients to increased ectopic pregnancies after IVF-ET⁶⁴⁻⁶⁶. The first human pregnancy after IVF was, indeed, a tubal pregnancy⁶⁷.

Zouvres *et al.*⁶⁸ suggested prophylactic proximal tubal occlusion to prevent tubal pregnancy after IVF. This recommendation had previously been suggested by Steptoe⁶⁹ and Tucker⁷⁰ and Herman⁷¹ and their groups. However, we do not recommend proximal tubal occlusion in a case of distal occlusion because of the risk of subsequent pelvic pain and inflammation due to increased intratubal pressure⁶². We advocate prophylactic salpingectomy instead of prophylactic proximal occlusion.

A study by Schenk *et al.*⁷² and one by Mukherjee *et al.*⁷³ examined the effect of hydrosalpingeal fluid on embryogenesis. All samples demonstrated significant embryotoxic effects.

Although the exact mechanism by which hydrosalpinx alters intrauterine receptivity remains unclear, a marker of uterine receptivity has been established. Integrins are adhesion molecules that participate in cell-cell interactions and are present on all human cells. Lessey *et al.*⁷⁴ conducted an interesting study that examined endometrial integrin expression to evaluate the effects of hydrosalpinges on uterine receptivity. The expression of β -integrin, measured by immunohistochemical assays of endometrial biopsies, was assessed. Women with hydrosalpinges expressed significantly lower levels than those without hydrosalpinges⁷⁴.

REMOVAL OF HYDROSALPINX BEFORE IN VITRO FERTILIZATION-EMBRYO TRANSFER

The benefits of salpingectomy before IVF-ET in patients with hydrosalpinx have been debated by Puttemans and Brosens⁷⁵. They believe that preventive salpingectomy should not be performed without demonstration by salpingoscopy of severe pathology, specifically chronic inflammation.

On the other hand, the study by Vandromme *et al.*⁶⁴ sought to determine whether surgical treatment would benefit patients with hydrosalpinx attempting IVF-ET. The ongoing pregnancy rate before surgery was 10.1%, whereas the postoperative group had an ongoing pregnancy rate of 31%. In the control group, the rate was 21.3%. The results revealed that surgical correction by ablation of the diseased tubes restored normal chances of success for patients with hydrosalpinges. Shelton *et al.*⁷⁶ were the first to conduct a prospective study that demonstrated the positive impact on pregnancy rates of removing hydrosalpinges in patients with repeated IVF failures. Fifteen patients with unilateral or bilateral hydrosalpinges with a history of repeated IVF failures underwent laparoscopic excision of the affected tubes. Because the patients undergoing surgical excision served as their own controls, the ongoing pregnancy rate per transfer was 0% pre-salpingectomy. After salpingectomy, the ongoing pregnancy rate per transfer was 25%. Improved pregnancy rates were noted for both fresh and frozen embryo transfers after surgery.

Lessey *et al.*⁷⁴ were also successful in demonstrating an improvement in integrin status, and consequently uterine receptivity, after correction of hydrosalpinx.

It is unclear whether salpingectomy has a detrimental effect on ovarian blood supply and neural linkage, thus affecting folliculogenesis and hormone production.

Studies by Vandromme⁶⁰, Shelton⁷⁶ and Kassabji⁷⁷ and their groups showed no difference in ovarian response, oocyte retrieval or fertilization rates after salpingectomy.

Nevertheless, other authors⁷⁸⁻⁸⁰ have addressed the importance of maintaining the integrity of the anastomotic vessels between the ovary and the tube. McComb and Delbelke⁸⁰ evaluated the relationship between the ovary and oviduct using microsurgery to alter the structure of the Fallopian tube. The number of ovulations was reduced by ablating the vasculature conveyed through the mesosalpinx. Preservation of the anastomotic ovarian blood supply at the time of salpingectomy must be emphasized, to decrease the possible effects of radical surgery on ovarian function⁷⁹. The risk of interstitial pregnancy is not eliminated, and the remote chance of uterine rupture at the site of salpingectomy exists^{47,81}. Pavic *et al.*⁸² were the first to report an interstitial pregnancy after bilateral salpingectomy for hydrosalpinx and IVF. Cornual resection at the time of salpingectomy does not prevent interstitial pregnancies.

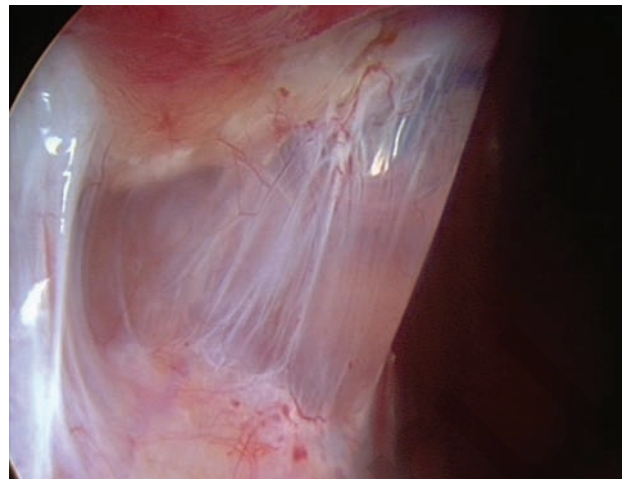


Figure 12.13 Filmy, avascular adhesion

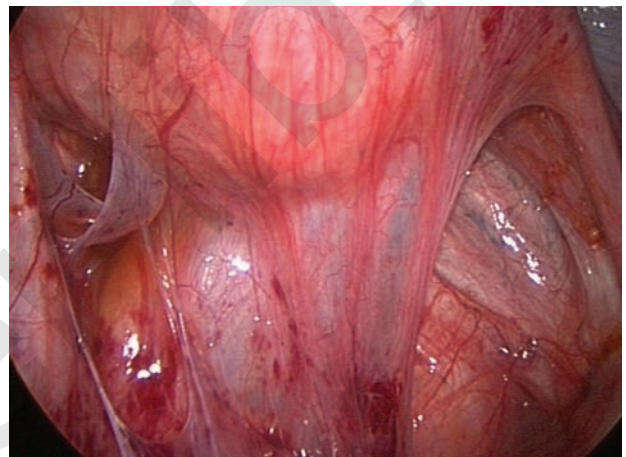


Figure 12.14 Filmy, vascular adhesion

ADHESIONS

Three types of adhesions must be defined:

- Type I (Figure 12.13): filmy, avascular adhesions
- Type II (Figure 12.14): filmy, vascular adhesions
- Type III (Figure 12.15): dense, fibrous, vascular adhesions

Adhesiolysis

In many patients, postoperative or postinfectious adhesions are amenable to vaporization by laser laparoscopy^{6,10,27}. When compared with the standard technique using cautery and laparoscopic scissors (Figure 12.16) or blunt dissection, there is probably no difference in the outcome when the adhesions are small and avascular. With more vascular adhesions or particularly thick tubo-ovarian adhesions, however, the CO₂ laser

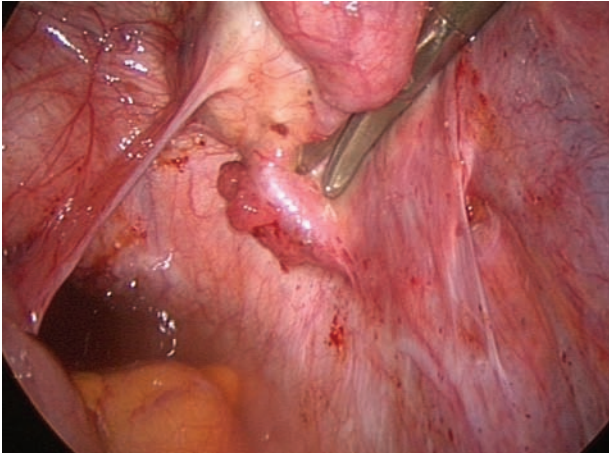


Figure 12.15 Dense, fibrous, vascular adhesion

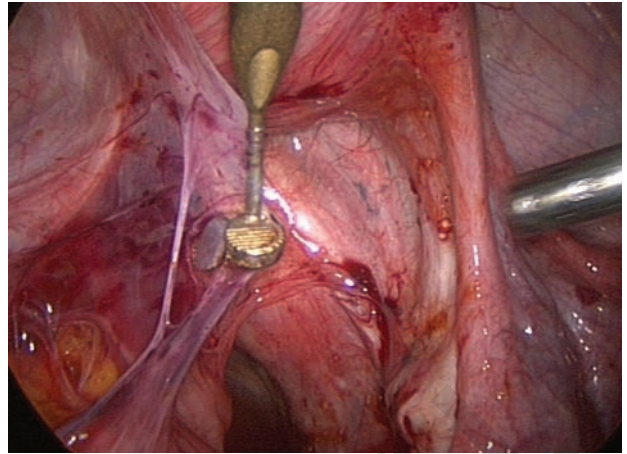


Figure 12.17 The adhesiolysis probe with its backstop should be used to make the procedure safer

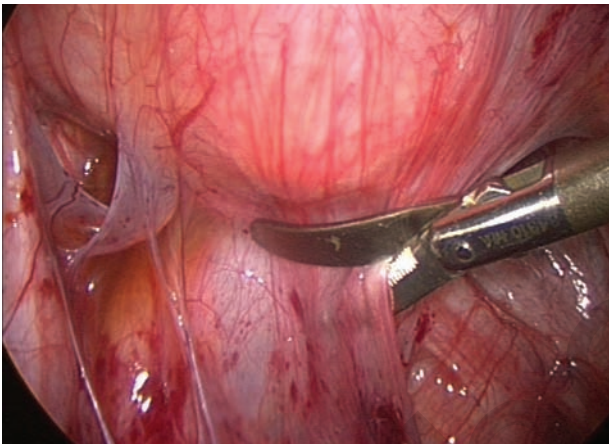


Figure 12.16 Adhesiolysis using scissors

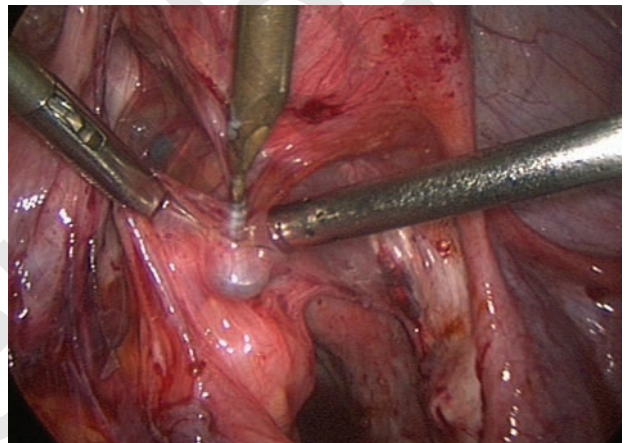


Figure 12.18 Salpingolysis is performed by applying traction to the adhesions with suprapubic atraumatic grasping forceps and another probe

allows more precise destruction of the adhesions with minimal injury to adjacent normal tissue. Filmy peritubal and periovarian adhesions are easily vaporized with the operative laser laparoscope. The adhesiolysis probe with its backstop should be used to make the procedure safer (Figure 12.17).

Traction to adhesions must be applied by two atraumatic forceps. The adhesion is positioned across the 'firing' platform when the laser is activated, to prevent damage to any tissue distal to the adhesion. Using a power output of 40 W, adhesions can be both coagulated and incised. For beginners, single or repeat pulse modes should be used for laser vaporization of the adhesions until confidence in the technique is gained. Great care should be taken when dividing adhesions between the tube and the ovary, because this area is very vascular. Adhesions of types I (filmy and avascular) and II (filmy and vascular, but not very thick) are easily vaporized with the operative laser laparoscope.

Salpingolysis is performed by applying traction to the adhesions with suprapubic atraumatic grasping forceps and another probe (smooth manipulating probe, hook or probe with its backstop) (Figure 12.18).

The probe with a backstop can be used to facilitate the procedure. When this probe is used, the adhesion is placed across the 'firing' platform and the laser is fired to vaporize the band. The use of a probe with a backstop eliminates the risk of inadvertent injury to intraperitoneal structures. Using a power output of 40 W, the adhesions are coagulated and incised. Short exposure times are adequate to vaporize adhesions around the Fallopian tubes and ovaries, and will prevent the laser beam from penetrating more than 100–200 μm . In the hands of more experienced laparoscopists, the continuous mode is easily used.

Ovariolysis is performed by applying torsion to the utero-ovarian ligaments with atraumatic tubal forceps. Elevation and rotation of the ovary are performed while continuing traction and torsion. Adhesions can easily be

dissected from the ovarian surface by superficial vaporization. Care must be taken not to apply too much traction for fear of tearing the ovarian ligament from its attachment, which can result in copious bleeding that can only be stopped by hemostatic clips or coagulation. During adhesiolysis, use of the probe with a backstop eliminates the risk of inadvertent injury to other intraperitoneal structures, particularly the bowel.

Irrigation fluid can be introduced into the pelvis as an aqueous backstop to protect the bowel from any damage from diffusion of the laser beam.

CONCLUSION

In conclusion, the list of prognostic factors for tubal infertility is long⁸³. It underlines the major role of the investigational examinations performed preoperatively on infertile patients, particularly the hysterosalpingogram and laparoscopy, when exploration of the tubal mucosa must be meticulous. Direct visual investigation of the tube, whether preoperative (falloscopy) or intraoperative (tuboscopy), enables clear documentation of all the endosalpingeal features. Failure to recognize these prognostic factors, and subsequent poor selection of patients for conservative surgery, could lead to an unacceptable loss of time and disillusionment for our patients.

REFERENCES

- Swolin K. Electromicrosurgery and salpingostomy: long-term results. *Am J Obstet Gynecol* 1975; 121: 418–19
- Gomel V. Salpingostomy by microsurgery. *Fertil Steril* 1978; 34: 380–5
- Winston RML. Microsurgery of the fallopian tube: from fantasy to reality. *Fertil Steril* 1980; 46: 521–30
- Gomel V. Salpingostomy by laparoscopy. *J Reprod Med* 1977; 18: 265–7
- Daniell JF, Herbert CM. Laparoscopic salpingostomy utilizing the CO₂ laser. *Fertil Steril* 1984; 41: 558–63
- Donnez J, Nisolle M, Casanas-Roux F. CO₂ laser laparoscopy in infertile women with adnexal adhesions and women with tubal occlusion. *J Gynecol Surg* 1989; 5: 47–53
- Dubuisson JB, de Jolinière JB, Aubriot FX, et al. Terminal tuboplasties by laparoscopy: 65 consecutive cases. *Fertil Steril* 1990; 54: 401–3
- Mettler LR, Irani S, Kapamadzija A, et al. Pelviscopic tubal surgery: the acceptable vogue. *Hum Reprod* 1990; 5: 971–4
- Canis M, Mage G, Pouly JL, et al. Laparoscopic distal tuboplasties: reports of 87 cases and a 4-year experience. *Fertil Steril* 1991; 56: 616–21
- Donnez J. La Trompe de Fallope: Hystopathologie Normale et Pathologique. Leuven, Belgium: Nauwelaerts Printing, 1984
- Afzelius BA, Camner P, Mossberg B. On the function of the cilia in the female reproductive tract. *Fertil Steril* 1978; 29: 72
- Donnez J, Caprasse J, Casanas-Roux F, et al. Loss of adrenergic innervation in rabbit-induced hydrosalpinx. *Gynecol Obstet Invest* 1986; 21: 213–16
- Mol BWJ, Swart P, Bossuyt PMM, et al. Reproducibility of the interpretation of hysterosalpingography in the diagnosis of tubal pathology. *Hum Reprod* 1996; 11: 1204–8
- Swart P, Mol BWJ, van der Veen F, et al. The accuracy of hysterosalpingography in the diagnosis of tubal pathology: a meta-analysis. *Fertil Steril* 1995; 64: 486–91
- Atri M, Tran CN, Bret PT, et al. Accuracy of endovaginal sonography for the detection of fallopian tube blockage. *Ultrasound Med* 1994; 13: 429–34
- Schiller VL, Tsuchiyama K. Development of hydrosalpinx during ovulation induction. *J Ultrasound Med* 1995; 14: 799–803
- Friberg B, Joergensen C. Tubal patency studied by ultrasonography. A pilot study. *Acta Obstet Gynecol Scand* 1994; 73: 53–5
- Heikkinen H, Tekay A, Volpi E, et al. Transvaginal salpingosonography for the assessment of tubal patency in infertile women: methodological and clinical experiences. *Fertil Steril* 1995; 64: 293–8
- Volpi E, Piermatteo M, Zuccaro G, et al. The role of transvaginal sonosalpingography in the evaluation of tubal patency. *Minvera Ginecol* 1996; 48: 1–3
- Allahbadia GN. Fallopian tubal patency using color Doppler. *Int J Gynaecol Obstet* 1996; 40: 241–4
- Yarali H, Gurgan T, Erden A, et al. Colour Doppler hysterosalpingo-sonography: a simple and potentially useful method to evaluate fallopian tube patency. *Hum Reprod* 1994; 9: 64–6
- Brosens I, Boeckx W, Delattin P, et al. Salpingoscopy: a new pre-operative diagnostic tool in tubal infertility. *Br J Obstet Gynaecol* 1987; 94: 768–73
- De Bruyne F, Puttemans P, Boeckx W, et al. The clinical value of salpingoscopy in tubal infertility. *Fertil Steril* 1989; 51: 339–40
- Kerin J, Daykhovsky L, Grundfest W, et al. Falloscopy. A microendoscopic transvaginal technique for diagnosing and treating endotubal disease incorporating guide wire cannulation and direct balloon tuboplasty. *J Reprod Med* 1990; 35: 606–12
- Gomel V, Taylor PJ. In vitro fertilization versus reconstructive tubal surgery. *J Assist Reprod Genet* 1992; 9: 306–9
- Gomel V, Yarali H. Infertility surgery: microsurgery. *Curr Opin Obstet Gynecol* 1992; 4: 390–9
- Donnez J, Casanas-Roux F. Prognostic factors of fimbrial microsurgery. *Fertil Steril* 1986; 46: 200–4
- Singhal V, Li TC, Cooke ID. An analysis of factors influencing the outcome of 232 consecutive tubal microsurgery cases. *Br J Obstet Gynaecol* 1991; 98: 628–36
- American Fertility Society. The American Fertility Society: classifications of adnexal adhesions, distal tubal occlusion, tubal occlusion secondary to tubal ligation, tubal pregnancies, Müllerian abnormalities

- and intrauterine adhesions. *Fertil Steril* 1988; 49: 944–55
30. Vasquez G, Boeckx W, Brosens I. Prospective study of tubal mucosal lesions and fertility in hydrosalpinges. *Hum Reprod* 1995; 10: 1075–8
 31. Mage G, Pouly JL, Bouquet de Jolinière J, et al. A preoperative classification to predict the intrauterine and ectopic pregnancy rates after distal microsurgery. *Fertil Steril* 1986; 46: 807–10
 32. Schlieff R, Deichert U. Hysterosalpingo-contrast sonography of the uterus and fallopian tube: results of a clinical trial of a new contrast medium in 120 patients. *Radiology* 1991; 178: 213–15
 33. Peters AJ, Coulam CB. Hysterosalpingography with color Doppler ultrasonography. *Am J Obstet Gynecol* 1991; 164: 1530–4
 34. Stern J, Peters AJ, Coulam CB. Color Doppler ultrasonography assessment of tubal patency: a comparison study with traditional techniques. *Fertil Steril* 1992; 58: 897–900
 35. Dunphy BC. Office falloscopic assessment in proximal tubal occlusive disease. *Fertil Steril* 1994; 61: 168–70
 36. Kerin JF, Williams DB, San Roman GA, et al. Falloscopic classification and treatment of Fallopian tube lumen disease. *Fertil Steril* 1992; 57: 731–41
 37. Cornier E, Feintuch MJ, Bouccara L. Ampullafibrotuboscopy. *J Gynecol Obstet Biol Reprod* 1985; 14: 459–66
 38. Schlaff WD, Hassiakos DK, Damewood MD, et al. Neosalpingostomy for distal tubal obstruction: prognostic factors and impact of surgical technique. *Fertil Steril* 1990; 54: 984–90
 39. Boer-Meisel ME, Te Velde ER, Habbema JDF, et al. Predicting the pregnancy outcome in patients treated for hydrosalpinx: a prospective study. *Fertil Steril* 1986; 45: 23–9
 40. Dubuisson JB, Chapron C, Morice P, et al. Laparoscopic salpingostomy: fertility results according to the tubal mucosal appearance. *Hum Reprod* 1994; 9: 334–9
 41. Marana R, Muscatello P, Muzii L, et al. Perlaparoscopic salpingoscopy in the evaluation of the tubal factor in infertile women. *Int J Fertil* 1990; 35: 211–14
 42. Herschlag A, Seifer DB, Carcangiu ML, et al. Salpingoscopy: light microscopic and electron microscopic correlations. *Obstet Gynecol* 1991; 7: 399–405
 43. Donnez J, Nisolle M, Casanas-Roux F, et al. CO₂ laser laparoscopic surgery: adhesiolysis, salpingostomy and fimbrioplasty. In Donnez J, Nisolle M, eds. *Atlas of Laser Operative Laparoscopy and Hysteroscopy*. Carnforth, UK: Parthenon Publishing, 1994: 97–112
 44. Marana R, Muzii L, Rizzi M, et al. Salpingoscopy in patients with contralateral ectopic pregnancy. *Fertil Steril* 1991; 55: 838–40
 45. Brosens I, Vasquez G. Fimbrial microbiopsy. *J Reprod Med* 1976; 16: 171
 46. Strandell A, Waldenstrom U, Nilsson L, et al. Hydrosalpinx reduces in vitro fertilization/embryo transfer pregnancy rates. *Hum Reprod* 1994; 9: 861–3
 47. Dubuisson JB, Aubriot FX, Mathieu L, et al. Risk factors for ectopic pregnancy in 556 pregnancies after in vitro fertilization: implications for preventive management. *Fertil Steril* 1991; 56: 686–90
 48. Laatikainen TJ, Tenhunen AK, Venesmaa PK, et al. Factors influencing the success of microsurgery for distal tubal occlusion. *Arch Gynecol Obstet* 1988; 243: 101–6
 49. Dlugi AM, Reddy S, Saleh WA, et al. Pregnancy rates after operative endoscopic treatment of total (neosalpingostomy) or near total (salpingostomy) distal tubal occlusion. *Fertil Steril* 1994; 62: 913–20
 50. Donnez J. CO₂ laser laparoscopy in infertile women with endometriosis and women with adnexal adhesions. *Fertil Steril* 1987; 48: 390
 51. Nezhat F, Winer WK, Nehzat C. Fimbriostomy and salpingoscopy in patients with minimal to moderate pelvic endometriosis. *Obstet Gynecol* 1990; 75: 15–17
 52. Bouquet de Jolinière J, Madelenat P, Seneze J. Plasties tubaires distales: traitement coelioscopique. Apport du laser CO₂: techniques, indications, premiers résultats. *Gynécologie* 1987; 38: 3330–9
 53. Reich H. Laparoscopic treatment of extensive pelvic adhesions, including hydrosalpinx. *J Reprod Med* 1987; 32: 736–42
 54. Larue L, Sedbon E, Crequat J, Madelenat P. Percelioscopic surgery of the distal fallopian tube in infertility. *J Gynecol Obstet Biol Reprod (Paris)* 1990; 19: 34–7
 55. Henry-Suchet J, Tesquier L, Boujenah A, et al. [Pregnancy rate after tuboplasty. Comparison between laparoscopic surgery and transparietal surgery]. *Presse Med* 1991; 20: 1570–1
 56. McComb PF, Paleologou A. The intussusception salpingostomy technique for the therapy of distal oviductal occlusion at laparoscopy. *Obstet Gynecol* 1991; 78: 443–7
 57. Nackley AC, Muasher SJ. The significance of hydrosalpinx in in vitro fertilization. *Fertil Steril* 1998; 69: 373–4
 58. Sims JA, Jones D, Butler L, et al. Effect of hydrosalpinx on outcome in in vitro fertilization (IVF). Presented at the 49th Annual Meeting of the American Fertility Society, 1993, Chicago. Program Supplement, American Fertility Society, 1993: S95
 59. Andersen A, Yue Z, Meng F, et al. Low implantation rate after in vitro fertilization in patients with hydrosalpinges diagnosed by ultrasonography. *Hum Reprod* 1994; 9: 1935–8
 60. Vandromme J, Chasse E, Lejeune B, et al. Hydrosalpinges in in vitro fertilization: an unfavourable prognostic feature. *Hum Reprod* 1995; 10: 576–9
 61. Vejtorp M, Petersen K, Andersen AN, et al. Fertilization in vitro in the presence of hydrosalpinx and in advanced age. *Ugeskr Laeger* 1995; 157: 4131–4
 62. Donnez J, Polet R, Nisolle M. Prognostic factors of distal tubal occlusion. *Ref Gynecol Obstet* 1993; 1: 94–102

63. Freeman MR, Whitworth CM, Hill GA. Hydrosalpinx reduces in vitro fertilization-embryo transfer rates and in vitro blastocyst development. Presented at the 52nd Annual Meeting of the American Society, 1996, Washington. Program Supplement, American Fertility Society, 1996: S211
64. Akman MA, Garcia JE, Damewood MD, et al. Hydrosalpinx affects the implantation of previously cryopreserved embryos. *Hum Reprod* 1996; 11: 1013-14
65. Herman A, Ron-El R, Golan A, et al. The role of tubal pathology and other parameters in ectopic pregnancies occurring in in vitro fertilization and embryo transfer. *Fertil Steril* 1990; 54: 79-87
66. Martinez F, Trounson A. An analysis of risk factors associated with ectopic pregnancy in a human in vitro fertilization program. *Fertil Steril* 1986; 45: 79-87
67. Steptoe P, Edwards R. Reimplantation of a human embryo with subsequent tubal pregnancy. *Lancet* 1976; 1: 880
68. Zouvres C, Erenus M, Gomel V. Tubal ectopic pregnancy after in vitro fertilization and embryo transfer: a role for proximal occlusion or salpingectomy after failed distal tubal surgery. *Fertil Steril* 1991; 56: 691-5
69. Steptoe PC. Pregnancies following implantation of human embryos grown in culture. Presented at the 45th Annual Meeting of the American Fertility Society, 1989, San Francisco. Program Supplement, American Fertility Society, 1989: S152
70. Tucker M, Smith D, Pike I, et al. Ectopic pregnancy following in vitro fertilization and embryo transfer. *Lancet* 1981; 2: 1278
71. Herman A, Ron-El R, Golan A, et al. The dilemma of optimal surgical procedure in ectopic pregnancies occurring in in vitro fertilization. *Hum Reprod* 1991; 6: 1167-79
72. Schenck LM, Ramey JW, Taylor SL, et al. Embryotoxicity of hydrosalpinx fluid. Presented at the 43rd Annual Meeting of the Society of Gynecologic Investigation 1996. *J Soc Gynecol Invest* 1996; 3 (Suppl): 88A
73. Mukherjee T, Copperman AB, McCaffrey C, et al. Hydrosalpinx fluid has embryotoxic effects on murine embryogenesis: a case for prophylactic salpingectomy. *Fertil Steril* 1996; 66: 851-3
74. Lessey BA, Castelbaum AJ, Riben M, et al. Effect of hydrosalpinges on markers of uterine receptivity and success in IVF. Presented at the 50th Annual Meeting of the American Fertility Society, 1994, New York. Program Supplement, American Fertility Society, 1994: S45
75. Puttemans PJ, Brosens IA. Preventive salpingectomy of hydrosalpinx prior to IVF. Salpingectomy improves in vitro fertilization outcome in patients with a hydrosalpinx: blind victimization of the Fallopian tube? *Hum Reprod* 1996; 11: 2079-84
76. Shelton KE, Butler L, Toner JP, et al. Salpingectomy improves the pregnancy rate in in vitro fertilization with hydrosalpinx. *Hum Reprod* 1996; 11: 523-5
77. Kassabji M, Sims J, Butler L, et al. Reduced pregnancy rates with unilateral or bilateral hydrosalpinx after in vitro fertilization. *Eur J Obstet Gynecol Reprod Biol* 1994; 56: 129-32
78. Levy MJ, Murray D, Sagoskin A. The adverse effect of hydrosalpinges on IVF success rates are reversed equally well by salpingectomy, proximal tubal occlusion and neosalpingostomy. Presented at the Meeting of the American Society for Reproductive Medicine, 1996. Program Supplement, American Society for Reproductive Medicine, 1996: S64
79. Donnez J, Wauters M, Thomas K. Luteal function after tubal sterilization. *Obstet Gynecol* 1982; 37: 38
80. McComb P, Delbelke L. Decreasing the number of ovulations in the rabbit with surgical division of the blood vessels between the fallopian tube and ovary. *J Reprod Med* 1984; 29: 827-9
81. Sharif K, Kaufmann S, Sharma V. Heterotopic pregnancy obtained after in vitro fertilization and embryo transfer following bilateral total salpingectomy: case report. *Hum Reprod* 1994; 9: 1966-7
82. Pavic N, Neuenschwander E, Gschwind C, et al. Interstitial pregnancy following bilateral salpingectomy and in vitro fertilization-embryo transfer. *Fertil Steril* 1986; 46: 701-2
83. Donnez J, Nisolle M. Prognostic factors of distal tubal occlusion. In di Zerega GS, ed. *Peritoneal Surgery*. New York: Springer-Verlag, 2000: 265-74

akusher-lib.ru

Ectopic pregnancy following assisted conception treatment and specific sites of ectopic pregnancy

C Pirard, J Donnez

ECTOPIC PREGNANCY AFTER ASSISTED REPRODUCTION AND HETEROTOPIC PREGNANCY

The first pregnancy ever conceived after *in vitro* fertilization–embryo transfer (IVF–ET) was an ectopic pregnancy¹. Ectopic pregnancy occurs in 2–11% of all pregnancies resulting from IVF treatment, and, for unknown reasons, this incidence is much higher than that in the normal fertile population. This could either be the result of the fertility treatment or the consequence of infertility itself.

RISK FACTORS

Some risk factors for ectopic pregnancy are common to both spontaneous pregnancy and IVF:

- Pelvic inflammatory disease (PID)
- Pre-existing tubal pathology or tubal surgery²
- Smoking exposure
- Exposure to diethylstilbestrol (DES) *in utero*
- Age of the patient (risk increases with age)
- Previous ectopic pregnancy

The risk of ectopic pregnancy is 2–15 times higher in women with a previous ectopic pregnancy, compared with women without such a history.

Some risk factors are specifically linked to the assisted conception treatment³. The use of clomiphene citrate for stimulation could induce a different hormonal milieu, which may interfere with tubal function, but this remains controversial. The number of patent Fallopian tubes at the time of embryo transfer, the embryos being replaced higher than mid-cavity and the technique of embryo transfer used could also play a role⁴.

The technique of embryo transfer

The technique of embryo transfer may be implicated in the increased incidence of ectopic pregnancy after IVF. Lesny *et al.*⁴ observed (in a group of oocyte donors) that a difficult embryo transfer, due to manipulation of the external rigid part of the catheter, multiple transfer attempts, change of catheter, application of a tenaculum to the cervix and use of a uterine sound (or Hegar dilators), stimulates junctional zone contractions and that strong endometrial waves in the fundal area of the uterus can

move mock embryos into the Fallopian tubes. According to their findings, difficult transcervical embryo transfer should be perceived as a significant risk factor for ectopic pregnancy. Indeed, the overall risk of ectopic pregnancy is 1.5–10 times higher when the embryo transfer is difficult than when it is easy.

Position of the catheter

The position of the catheter inside the uterus is also important. If the uterine fundus is reached during the transfer, fundocervical waves occur, which could relocate the embryos toward the cervix or into the Fallopian tubes. It is recommended that the uterine fundus should not be stimulated, and that a mid-cavitary delivery of the embryos (or keeping a minimal distance of 0.5–1 cm between the end of the catheter and the fundus) should be performed. Ultrasound measurement of uterine length is useful in patients with surgically shortened cervixes.

Volume of transfer medium

Hydrostatic pressure due to a large volume of transfer medium or excessive force during embryo transfer may force the migration of embryos into the tube. The catheter may also be placed into the tube itself.

HOW TO DIAGNOSE ECTOPIC PREGNANCY

The symptoms of ectopic pregnancy may be masked by symptoms frequently found after IVF (for example, ovarian hyperstimulation syndrome (OHSS) induces pain, pelvic liquid and heterogeneous adnexa at echography).

Some tests are helpful in the diagnosis of ectopic pregnancy, for example human chorionic gonadotropin (hCG) measurement and transvaginal ultrasound. Early normal intrauterine pregnancies are associated with a doubling of serum hCG concentrations every 1.4–2.1 days.

The diagnosis of pregnancy is made very early in assisted reproductive treatment cycles. At that time, no current biochemical methods are able to distinguish spontaneous abortion from ectopic pregnancy or from ongoing pregnancy. Later in the pregnancy, an hCG titer of 1000–15 000 IU/l is associated with the presence of an intrauterine sac on transvaginal ultrasound.

In IVF patients, more than one embryo is generally transferred, so more trophoblastic tissue may be present to

produce hCG. Thus, an extra 2–3 days are required for a sac to become visible. An intrauterine pregnancy, diagnosed by ultrasound, can be associated with an extrauterine one^{5,6} (see section on ‘Heterotopic pregnancy’, below), or multiple extrauterine pregnancies can coexist. Because of the danger of ectopic (and heterotopic) pregnancy, experts recommend early (6–8 weeks) systematic ultrasound examination by specialists, to inspect the uterine cavity and the adnexa (even if an intrauterine pregnancy has been established)⁷.

IS THERE A RISK AFTER BILATERAL SALPINGECTOMY?

Some patients have indications for salpingectomy before starting an IVF program, because of severely damaged bilateral tubes, hydrosalpinges, salpingitis isthmica nodosa and/or recurrent ectopic pregnancy. However, even after bilateral salpingectomy, the risk of ectopic pregnancy still remains, even if it is somewhat reduced. Indeed, patients who undergo IVF–ET are at risk of cornual implantation.

Salpingectomy with cornual resection, performed in order to reduce the possibility of interstitial pregnancy, is not a good option, because this resection may attenuate the musculature in the cornual region, which can lead to rupture even early in the course of a subsequent pregnancy.

HETEROTOPIC PREGNANCY

Incidence and predisposing factors

Natural heterotopic pregnancy (or simultaneous intra- and extrauterine gestations) is a very rare condition. The first case was described by Duverney in 1708 at autopsy⁸. As a result of the development of stimulated ovulation techniques and IVF, the incidence of heterotopic pregnancy initially increased dramatically, then stabilized at approximately 1/100 pregnancies obtained by assisted reproductive technologies (ART)⁴.

Fifty years ago, the incidence of spontaneous heterotopic pregnancies was estimated to be 1/30 000 pregnancies, with an ectopic pregnancy rate of 0.37%. In the 1980s, the incidence of spontaneous heterotopic pregnancies reached a rate of 1/3000–1/10 000 because of the increased prevalence of PID and the frequent use of intrauterine devices. In patients treated with clomiphene citrate, the heterotopic pregnancy rate was calculated to be 1/1250–1/3000.

Multiple ovulation or multiple embryo/gamete transfers, with the associated hormonal changes, have a major impact on the incidence of heterotopic pregnancies, and the underlying tubopelvic pathology is contributory, mainly in ART patients⁴. Nevertheless, some authors have

not found any correlation between the number of embryos transferred and the rate of ectopic pregnancy after ART treatment⁹. The most important factor, however, that served to increase the incidence dramatically, was the induction of multiple ovulation and the exposure to multiple embryo/gamete transfers in patients consulting for infertility (some of whom had tubal damage).

Symptoms and diagnosis

The diagnosis of heterotopic pregnancy is very important, because an early diagnosis allows prompt treatment, which will avoid maternal morbidity and mortality, and will also increase the chances of salvaging the associated intrauterine pregnancy.

Generally, the symptoms are abdominal pain or tenderness. Sometimes, there is also an acute abdomen and hypovolemic shock. Vaginal bleeding occurs only in 50% of patients, probably because of the coexisting intrauterine pregnancy. Vaginal bleeding (associated with abdominal pain) can lead to an incorrect diagnosis of miscarriage, and be erroneously treated by dilatation and curettage (D&C). Echographic control, which will reveal the intrauterine pregnancy, is preferable before performing a D&C, especially in patients who have been treated for ovulation induction or by ART.

When the diagnosis is late, the clinical examination reveals abdominal pain, an adnexal mass, signs of peritoneal irritation and an enlarged uterus.

Symptomless heterotopic pregnancies are sometimes detected due to early monitoring of pregnancy by transvaginal ultrasonography.

In a review of heterotopic pregnancies from 1971 to 1993 by Tal *et al.*⁵, 59% of cases were discovered by laparotomy or laparoscopy. Sonographic detection was only possible in 41% of cases, and was not always performed on first examination. Echographic diagnosis is easier when a fetal pole, with or without cardiac activity, is detected outside the uterine cavity. However, even in such cases, the localization may be misconstrued if the echographer does not have enough experience (a cornual or cervical pregnancy can be misinterpreted as a second twin in an intrauterine pregnancy). The frequency of ultrasonic detection has undoubtedly increased since 1993, with the generalized use of vaginal ultrasonography. Sometimes, the diagnosis is only suspected at echography, and then confirmed by surgery.

Localization

An ectopic pregnancy can be localized in the tube (in the ampullary part, the isthmic portion, the fimbria or cornua), on the ovary, in the cervix, in a cesarean scar or in the abdomen. Heterotopic pregnancies with cornual or abdominal implantation can provoke diametric obstetric phenomena. The incidence of hemorrhagic shock is 2.5–5

times greater when a cornual pregnancy is detected than in other varieties of ectopic pregnancy¹⁰.

Bassil *et al.*⁶ reported an abdominal pregnancy, detected by echography at only 19 weeks of gestation, with both fetuses of corresponding size. The patient was hospitalized, tocolytics were administered until the 34th week and two viable newborns were delivered by laparotomy.

Treatment

Surgical treatment

Surgical treatment consists of laparotomy or laparoscopy. In most cases, salpingectomy is preferable to salpingotomy because conservative treatment requires control of the hCG decrease, which is impossible if the intrauterine pregnancy survives.

Total or partial ovariectomy is the surgical procedure performed to remove the ectopic gestation when it involves the ovary. The differential diagnosis from a ruptured and bleeding corpus luteum is not always easy.

Cervical pregnancy can be treated by curettage or suturing of the profusely bleeding cervix, but the chances of a surviving intrauterine pregnancy are very low⁵. In 2000, Carreno *et al.*¹¹ reported a case of heterotopic cervical and intrauterine pregnancy, which was successfully managed by transcervical puncture of the cervical embryo, and ended in a healthy newborn.

According to Habana *et al.*¹², cornually implanted ectopic pregnancy can be evacuated by uterine section and suture. Because of the expected continuation of the intrauterine pregnancy, this operation must be performed by laparotomy, which allows better suture of a uterus that is supposed to continue its growth and preserve further fertility. This type of surgery is nevertheless questionable. The possibility of KCl injection, at least as first-line therapy, must also be discussed. In this case, laparotomy should be reserved for cases of failed KCl injection.

The removal of an abdominal pregnancy by laparotomy is possible during pregnancy or, exceptionally, at the time of cesarean section, when both fetuses continue to develop normally. Bassil *et al.* reported a case of delivery by laparotomy at 34 weeks of gestation⁶. If uncontrollable bleeding occurs, or if uterine tissue damage is extensive, hysterectomy remains the only option to save the mother's life.

During the operation, careful surgical handling is mandatory to avoid endangering the intrauterine pregnancy. However, a complete check of the whole pelvis must be carried out, because multiple ectopic pregnancies, even in both tubes, have been described⁵.

Non-surgical management

Non-surgical management of early ectopic pregnancy has been described. Salpingocentesis with a long needle allows the injection of KCl with or without methotrexate. The safety of this technique for the intrauterine pregnancy has not been proved. Active substances may enter the uterine circulation and damage the intrauterine pregnancy. Experience in transvaginal ultrasound-guided puncture is also needed, to reduce the risk of miscarriage. In 1996, Fernandez and Benifla¹³ reported their experience of the management of cornual pregnancy with methotrexate. In their series of 15 cases, three were heterotopic pregnancies. Complete resolution was obtained in 13 cases (86.6%), with local injection of methotrexate (1 mg/kg) or KCl under transvaginal ultrasound guidance ($n=7$), or a laparoscopic procedure ($n=6$).

In some cases, salpingectomy is necessary after failed non-surgical management. Hsieh *et al.*¹⁴ have reported a case of heterotopic cesarean scar pregnancy combined with intrauterine pregnancy successfully treated by embryo aspiration for selective embryo reduction.

Spontaneous resolution of ectopic pregnancy under expectant management has also been encountered, but only three cases were described in the review by Tal *et al.*⁵.

Recently, Gyamfi *et al.*¹⁵ reported a case of hysterectomy, secondary to profuse bleeding from retained cervical trophoblast tissue after successful KCl fetal reduction, in a case of cervical heterotopic pregnancy.

Conclusion

There is a very important question of ethics associated with the treatment of heterotopic pregnancy. The mother's life is at stake, but also the future of two or more babies, whose chances of being delivered alive are not equal. Approximately two-thirds of intrauterine pregnancies end in live deliveries after treatment⁵.

SPECIFIC SITES OF ECTOPIC PREGNANCY

Cornual pregnancy

Introduction

Cornual ectopic pregnancy is a rare entity, found in 2–4% of all ectopic pregnancies, with an estimated incidence of one in every 2500–5000 deliveries¹⁶. The correct diagnosis of cornual pregnancy in early gestation is difficult. Usually, uterine bleeding, pelvic pain and rupture occur later in pregnancy, compared with ectopic pregnancies located more distally in the Fallopian tube. Transvaginal echography can reveal the gestational sac in a very lateral position in the uterine cavity. Figure 13.1 demonstrates a case of pseudocornual pregnancy. Indeed, the gestational

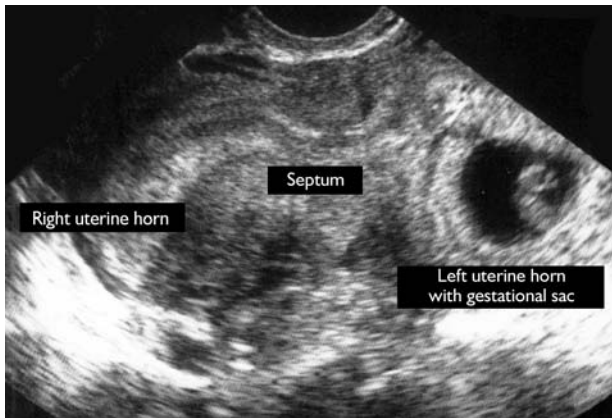


Figure 13.1 Gestational sac in the left uterine horn of an as-yet undiagnosed bicornual uterus

sac was found in the left uterine horn of an as-yet undiagnosed bicornual uterus. In some instances¹⁷ (see later), magnetic resonance imaging (MRI) can confirm a suspected cornual pregnancy.

However, rupture of cornual pregnancies may cause severe bleeding because they are located so close to the uterine blood supply, and, in the literature, some cases of

hysterectomy have been described, because uterine disruption was extensive.

Treatment by surgical management

Laparotomy Cornual ectopic pregnancy is the least common of the four tubal sites for ectopic gestations to be located. These ectopic gestations are most often treated by surgical excision, which at times necessitates the removal of a portion of the myometrium as well. This raises concerns for possible uterine rupture if a subsequent pregnancy is achieved; thus, the mass of tissue excised must be kept to a minimum.

Laparoscopy The possibility of laparoscopic management of cornual gestations has been demonstrated in several case reports (Table 13.1). The initial procedures that were described, however, did not preserve tubal continuity. For example, Hill *et al.*¹⁸ described a patient who presented at 10 weeks' gestation with a large unruptured cornual pregnancy. The authors, after placing an endoloop (Ethicon) around the cornua, were able to evacuate the pregnancy using a unipolar current and blunt removal. In contrast, both Tulandi¹⁹ and Reich²⁰ and their groups used laparoscopic cornual excision to manage interstitial

Table 13.1 Summary of the reported cases of laparoscopic management of cornual pregnancy

Reference	Operation	β -hCG (mIU/ml)	Diameter (cm)	Rupture	Estimated gestational age (weeks)	Vasopressin
Reich <i>et al.</i> (1988) ²⁰	CE	NA	NA	No	14 (calcified)	Yes
	CE	NA	NA	No	NA	Yes
	CE	NA	NA	No	NA	Yes
Hill <i>et al.</i> (1989) ¹⁸	S	NA	NA	No	10	Yes
Reich <i>et al.</i> (1990) ²¹	CE	16 300	NA	Yes	NA	No
Tulandi <i>et al.</i> (1995) ¹⁹	CE	6000	3	No	6	Yes
	CE	14 500	4	No	NA	Yes
	CE	12 000	5	No	10	Yes
	CE	4700	5	No	6	Yes
Pasic and Wolfe (1990) ²²	S	8000	4	No	6	Yes
	S	4400	2	No	6	Yes
Gleicher <i>et al.</i> (1994) ²⁴	S	7704	0	No	NA	Yes
Pansky <i>et al.</i> (1995) ²³	S	3000	NA	No	7	Yes
	S	2600	NA	No	9	Yes
Grobman and Milad (2002) ²⁶	S	32 827	4.5	No	7	Yes
Donnez and Nisolle (1994) ²⁵	S	6200		No		Yes + MTX
	S	7000		No		Yes + MTX
	S	11 200		No		Yes + MTX
	S + CE	18 250		Yes		Yes + MTX

CE, corneal excision; S, salpingotomy; β -hCG, β -human chorionic gonadotropin; NA, not available; MTX, methotrexate

pregnancy. Cornual excision has also been useful for the treatment of ruptured interstitial pregnancy²¹.

A less extensive laparoscopic procedure was performed by Pasic and Wolfe²². They visualized a small cornual pregnancy which was evacuated through a 1-cm salpingostomy. Subsequent hemostasis was maintained with electrocoagulation. A similar procedure was successfully used by Pansky *et al.*²³. Conservative laparoscopic management was also advocated by Gleicher *et al.*²⁴. In their report, a twin gestation visualized on ultrasound, but small enough not to be seen at laparoscopy, was removed from the cornua by salpingostomy. It has been confirmed that conservative laparoscopic surgery can also be used successfully for larger cornual pregnancies¹⁹.

A linear incision is made with monopolar electro-surgery parallel to the axis of the Fallopian tube, in order to minimize bleeding, or perpendicular, in order to minimize extension into the tube. After copious irrigation and suction, removal of the product of conception can be performed by laparoscopy. Cornual injection of diluted

vasopressin (5 IU/20 ml saline solution) and coagulation of the implantation site are often necessary to stop the bleeding in this highly vascular region of the uterus. An injection of methotrexate (20 mg) in the implantation site can be administered only in cases of cornual pregnancy where the site of implantation is the distal portion of the intramural tube²⁵. The question of sutured closure of the cornual defect is still unresolved. Some authors use electrocoagulation with closure by secondary intention, and others make a sutured closure of the cornual defect.

In our series of ectopic pregnancies, we treated four cases of cornual pregnancy by laparoscopy according to the following technique:

- Injection of diluted vasopressin (2–5 IU/20 ml saline)
- Linear incision (Figure 13.2)
- Removal of trophoblast
- Reduce coagulation to a minimum
- Injection of 20 mg methotrexate in the implantation site

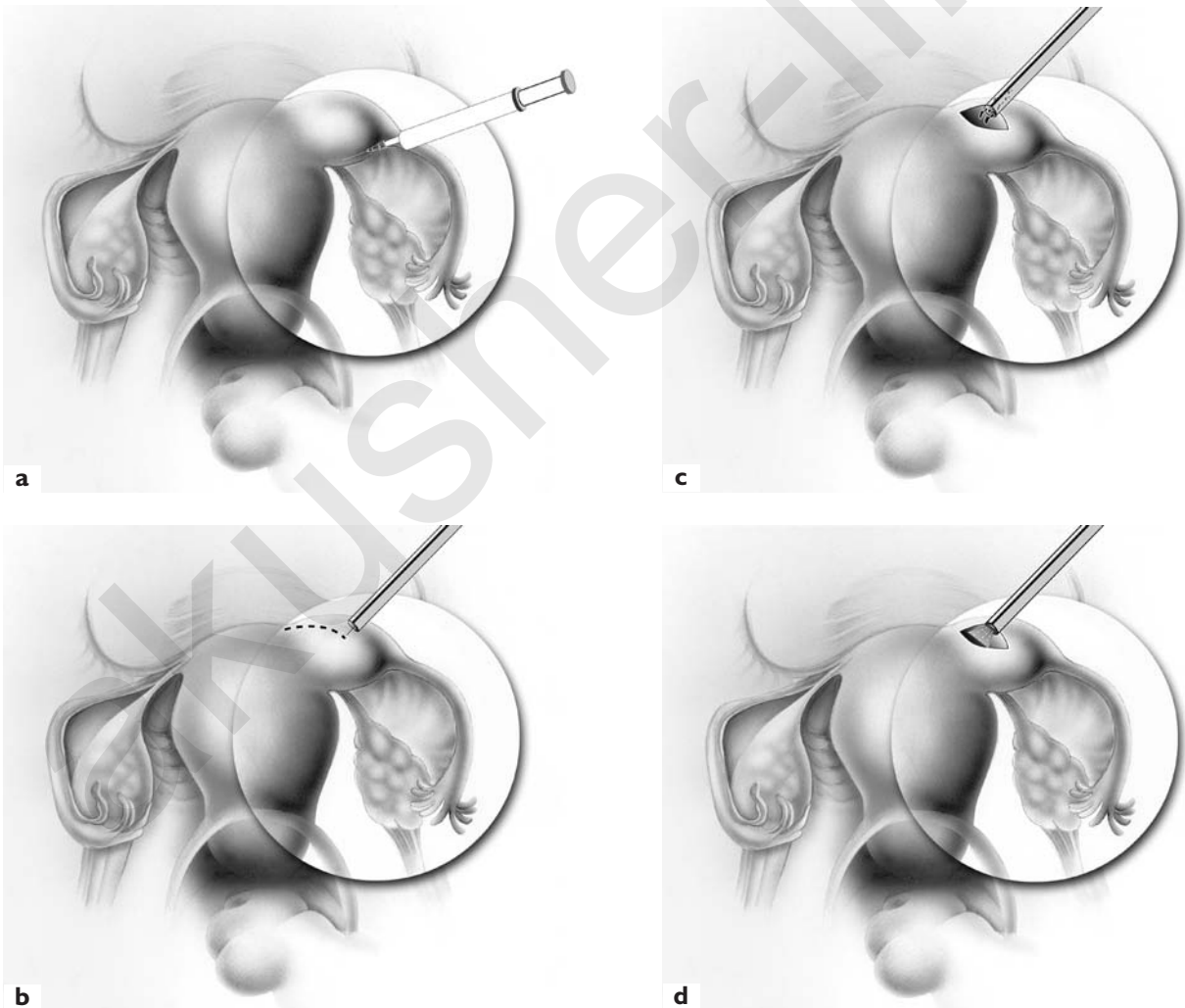


Figure 13.2 (a)–(d) Laparoscopic linear incision of cornual pregnancy after injection of diluted vasopressin (2–5 IU/20 ml saline) and subsequent injection of a mixed solution of methotrexate

In one of the four cases, closure of the defect was achieved with one stitch (Vicryl® 2-0).

Some authors have recently published other modalities, which probably do not offer any advantages over the previously described methods. In 1999, Rahimi²⁷ described the successful management of an interstitial ectopic pregnancy using three endoloops. In 2000, Moon *et al.*²⁸ reported a new approach to the endoscopic management of interstitial pregnancies (endoloop and encircling suture methods), without the uterine rupture encountered in pregnancies subsequent to these methods of endoscopic management. Laparoscopy-controlled hysteroscopic removal of an interstitial pregnancy and expectant management have also been described²⁹. Most authors generally suggest that interstitial pregnancies larger than 4 cm in size may be better managed by cornual excision.

Non-surgical management: methotrexate

Methotrexate is generally preferred, but, as already discussed, in the case of heterotopic pregnancy, KCl injection could also be recommended. Different modalities of treatment with methotrexate exist: systemic, puncture and injection under laparoscopic or ultrasonographic guidance.

In 1996, Fernandez and Benifla¹³ reported their experience of the management of cornual pregnancy with methotrexate. Complete resolution was obtained in 13 out of 15 cases (86.6%) with local injection of methotrexate (1 mg/kg) or KCl under transvaginal ultrasound guidance, or during a laparoscopic procedure. In this series, three of the 15 cases were heterotopic pregnancies. However, Agarwal *et al.*³⁰ reported only one successful methotrexate treatment in a series of four cases of cornual pregnancy. Transvaginal ultrasound-guided puncture has been proposed for the treatment of cornual pregnancy. However, the risks of ectopic rupture and profuse bleeding following needle extraction still exist, even if potentially safer routes for puncture and injection of cornual pregnancies are used, as recommended by Timor-Tritsch *et al.*³¹.

In 1997, Batioglu *et al.*³² reported a case of cornual pregnancy which was successfully treated with two doses of methotrexate under laparoscopic and ultrasonographic guidance.

Anecdotal: triplet cornual pregnancy

We reported a case of triplet cornual pregnancy in a woman who underwent IVF-ET¹⁷. Transvaginal echography performed 35 days after embryo transfer showed three gestational sacs with heartbeats in a very lateral position in the uterine cavity, and also asymmetric development of the right uterine horn. MRI confirmed the sonographic suspicion of the localization of the three gestational sacs in the right uterine horn (Figure 13.3).

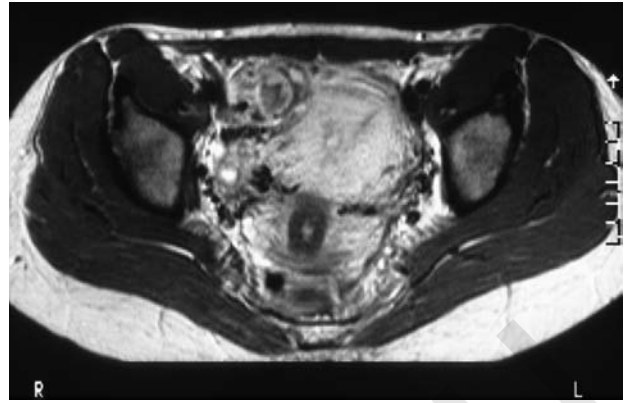


Figure 13.3 Triplet cornual pregnancy: magnetic resonance imaging confirmed the cornual localization of the three gestational sacs in the right uterine 'horn'

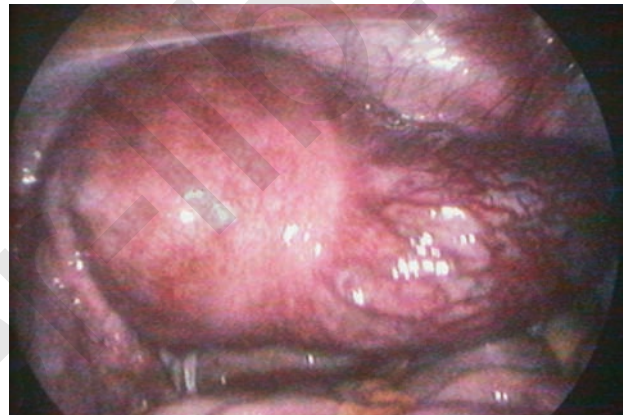

Figure 13.4 Laparoscopic view: very enlarged hypervascularized uterine horn of the case described in Figure 13.3

Laparoscopy confirmed the cornual pregnancy, with a very enlarged hypervascularized uterine horn without rupture (Figure 13.4). Immediate laparotomy permitted conservative treatment and uterine horn reconstruction.

Anecdotal: intramyometrial implantation

We encountered a case of intramyometrial implantation diagnosed after laparoscopy. Indeed, because of a suspected ruptured tubal pregnancy (raised hCG and intraperitoneal hemorrhage), laparoscopy was carried out, which detected a myometrial and serosal defect on the posterolateral side of the uterus. Because the patient had undergone D&C 7 days before, perforation was suspected. Coagulation was performed, and, after the removal of blood clots and peritoneal lavage, methotrexate was injected into this area. There was a substantial decrease in the hCG level. Hysterosalpingography, carried out 2 months later, revealed a diverticulum in the myometrium (Figure 13.5). Two years later, the patient experienced a

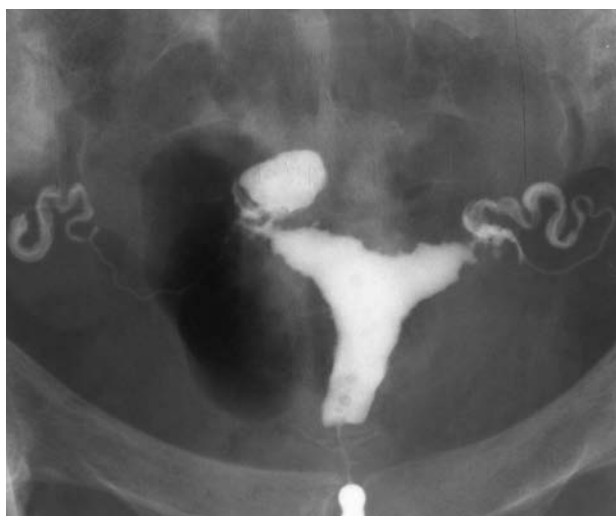

Figure 13.5 After myometrial pregnancy treated by local injection of methotrexate, hysterosalpingography carried out 2 months later revealed a diverticulum in the myometrium

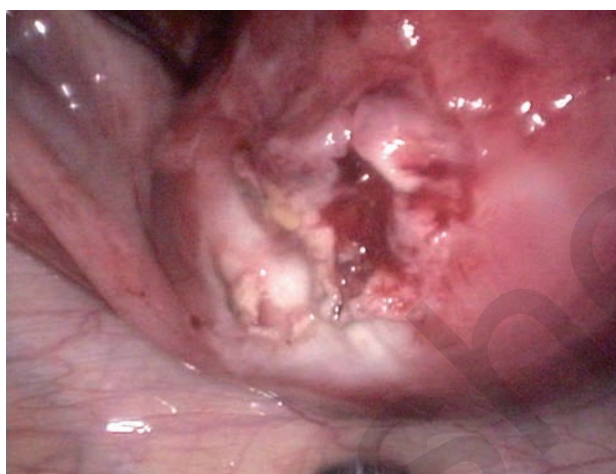

Figure 13.6 Myometrial defect observed at laparoscopy for diagnosis of suspected extrauterine pregnancy. The pregnancy was again located in the myometrial defect

recurrence of implantation in this 'myometrial' diverticulum. A laparoscopy performed because of hemoperitoneum with an hCG level of 2082 mIU/ml showed a suspected ovarian pregnancy, which was not confirmed according to the criteria of ovarian pregnancy (see section below on 'Ovarian pregnancy'). The myometrial defect was visible (Figure 13.6), but, at the time, intramyometrial pregnancy was not suspected. The hCG levels increased over the following days, and vaginal echography revealed an intramyometrial pregnancy (Figure 13.7) with only a 2-mm distance between the sac and the serosa. This sac was not visible on the day of laparoscopy. Methotrexate (40 mg) was administered, and hCG levels decreased rapidly, proving the efficacy of methotrexate. After an

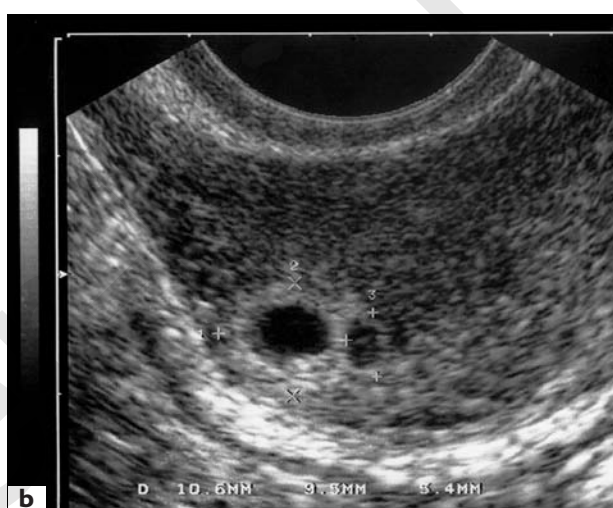
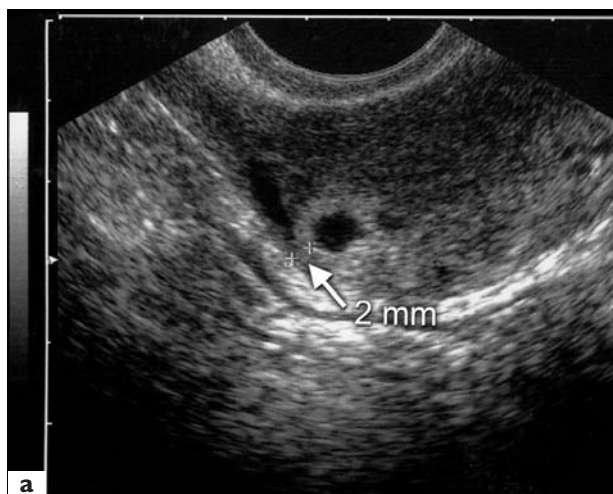

Figure 13.7 Vaginal echography: (a) intramyometrial pregnancy is obvious with only a 2-mm distance between sac and serosa (b)

increase to 5648 mIU/ml (day 3 post-methotrexate), hCG levels decreased (Figure 13.8). A second methotrexate injection (40 mg) was then given.

Results from a review

In 1999, Lau and Tulandi³³ carried out a review of 41 patients with interstitial pregnancy who were treated with methotrexate, or by a conservative laparoscopic technique, or with KCl injection (in the case of heterotopic pregnancy). Methotrexate had a success rate of 83%. Conservative laparoscopic techniques had a success rate of 100% ($n=22$). In the case of heterotopic pregnancy, after treatment (KCl or conservative surgery), 67% of coexisting intrauterine pregnancies resulted in successful deliveries.

There is insufficient evidence to recommend any single treatment modality, and the decision should be based on factors such as clinical presentation, the surgeon's

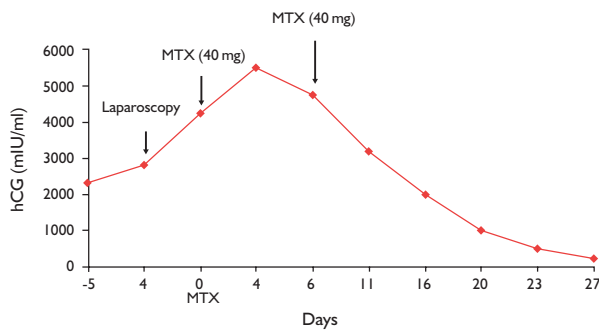


Figure 13.8 Intramyometrial pregnancy: human chorionic gonadotropin (hCG) level following intramuscular injection of 40 mg methotrexate (MTX)

expertise, side-effects, overall cost and the mother's wish to conceive again. Cornual resection by laparotomy should no longer be the first-line treatment for a hemodynamically stable patient with an interstitial pregnancy. Whatever treatment is chosen, the patient must be informed that any subsequent pregnancy must be followed very carefully because of the risk of future complications, such as recurrence or uterine rupture. Indications for cesarean section at term, prior to the onset of labor, must be decided before the next pregnancy occurs.

Ovarian pregnancy

Incidence and risk factors

The incidence of ovarian pregnancy is approximately 1/2000–1/7000 deliveries³⁴, i.e. less than 3% of all ectopic pregnancies, following natural conception. However, the incidence of ovarian pregnancy after IVF-ET increases to 11% of all ectopic pregnancies. Apart from several reports of ovarian pregnancies following IVF-ET^{34–38} or gamete intrafallopian transfer (GIFT)³⁹, only two cases after intrauterine insemination^{40,41} have been reported so far. The common feature of all these cases is an enlargement of the ovary due to stimulation with gonadotropins, often with several hemorrhagic lutein cysts or corpora lutea. The increased vulnerability and vascularity of the ovary constitutes a higher risk of rupture, with serious bleeding and, possibly, hemorrhagic shock. This complicates considerably manipulation of the ovary for diagnosis and therapy during operation, and localization of the pregnancy in cases without rupture may be difficult⁴². Some cases will not be diagnosed because they may be mistaken for a ruptured corpus luteum during laparoscopy, or because of the use of medical management without performing prior laparoscopy.

According to Spiegelberg⁴³, the distinction between primary ovarian pregnancy and distal tubal pregnancy, a

condition that can secondarily involve the ovary on its surface (secondary ovarian implantation), is based on four criteria:

- The Fallopian tubes with their fimbriae should be intact and separated from the ovary
- The gestation should occupy the normal position in the ovary
- The gestation should be connected to the uterus by the utero-ovarian ligament
- Ovarian tissue must be present in the specimen attached to the gestational sac

The risk factors are controversial. Globally, they are the same as those for ectopic pregnancy, except that the woman must have at least one patent tube, or a fistula which allows the sperm, or the embryo, to pass⁴⁴. The use of an intrauterine contraceptive device could be a more important risk factor than for other ectopic pregnancies⁴⁵.

Diagnosis

Ovarian pregnancy still presents problems of diagnosis, both in cases of ovarian stimulation and after natural conception.

Most of the time, the diagnosis of ectopic pregnancy is suspected by the clinical presentation of hCG levels and an empty uterus found on vaginal echography (with or without signs of an adnexal mass or fluid in the pouch of Douglas) (Figure 13.9), but, in most cases, the localization of the pregnancy is not known exactly before performing the operation. Vaginal echography can lead to the incorrect diagnosis of an ovarian cyst (corpus luteum, endometrioma) and threatened abortion.

When a patient undergoes IVF-ET or ovulation stimulation, the ultrasonic aspect of the ovaries changes, which increases the risk of misdiagnosis. However, even during laparoscopy, it is not easy to localize a pregnancy when it is surrounded by several corpora lutea^{42,46}. If a gestational sac has been clearly identified on vaginal echography, intraoperative transvaginal ultrasonography can be helpful after filling the lower pelvis with saline solution, but laparoscopy remains the gold standard for the diagnosis of ovarian pregnancy (Figure 13.10). In some cases, definitive diagnosis must await histological confirmation, which will show microscopic ovarian tissue around the gestational sac. However, this is not always possible, due to coagulation artifacts and the small tissue volume available.

Etiology

Three mechanisms can explain ovarian implantation:

- Fertilization occurs normally and implantation in the ovary follows reflux of the conceptus from the tube
- Various disturbances in ovum release are responsible for ovarian implantation

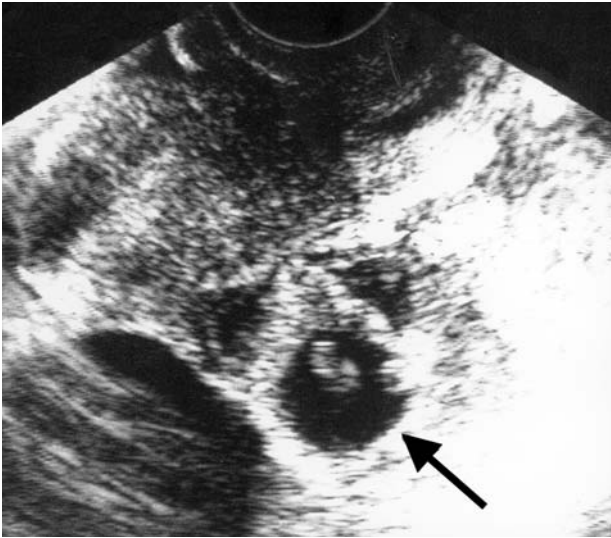


Figure 13.9 Vaginal echography revealed an embryonic ovarian ectopic pregnancy (arrow)

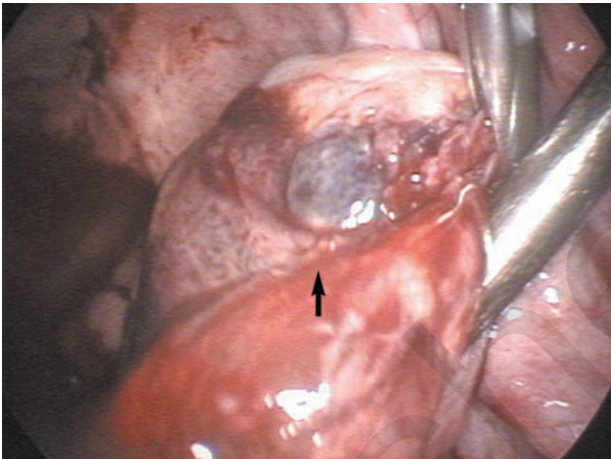


Figure 13.10 Laparoscopic view of ovarian pregnancy (arrow)

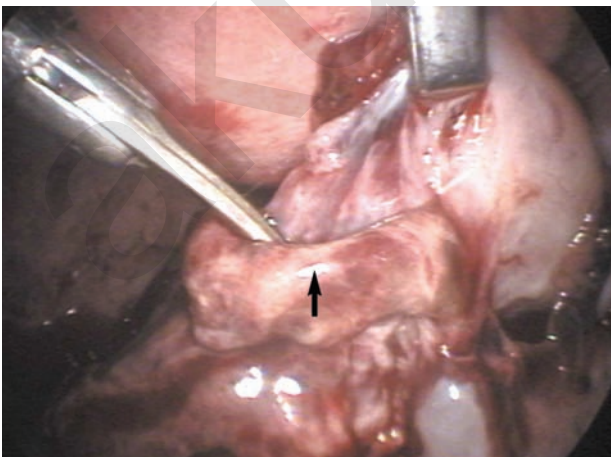


Figure 13.11 Laparoscopic removal of ovarian pregnancy (arrow)

- Intrauterine insemination could push some spermatozoa all the way to the ovarian surface and lead to ovarian implantation⁴¹

Treatment by surgical management

Compared with laparotomy, laparoscopy has the advantage of reducing morbidity, hospitalization and probably the risk of postoperative adhesion formation, which is important to women of child-bearing age⁴⁶.

Van Coevering and Fisher⁴⁷ were the first, in 1988, to report a laparoscopic approach used at an early stage of ovarian pregnancy. In fact, they removed what they believed to be a hemorrhagic corpus luteum cyst, but pathological examination showed an ovarian pregnancy. After performing laparoscopy, copious pelvic lavage of the hemoperitoneum is carried out to facilitate the exploration of the pelvis and both ovaries. The pregnancy can be removed using biopsy forceps or enucleation (Figure 13.11). Deeper trophoblastic invasion of the ovarian stroma requires aggressive thermal coagulation for hemostasis. We prefer to use bipolar coagulation with 2-mm-wide bipolar forceps for hemostasis of the placental site, because extensive thermal damage could cause superficial ovarian injury. Moreover, the site of ovarian implantation causes a relative defect of the ovarian surface, which could lead to adhesion formation. In order to avoid this type of complication, the ovary may be covered with a piece of Interceed® (Johnson & Johnson, NY, USA). The use of a CO₂ laser has also been described⁴⁸ in order to vaporize the placental site.

Partial ovariectomy (ovarian wedge resection), including the site of implantation, or ovarian cystectomy must be performed if possible. Ovariectomy or adnexectomy is performed when a more conservative treatment is not possible. In all cases, one must take into consideration the patient's desire for future pregnancy, and the operative feasibility.

Medical management

Medical management of ovarian pregnancy has been reported by some authors. They described the use of methotrexate⁴⁹, prostaglandin, prostaglandin and estrogen, and mifepristone. We believe that, as laparoscopy is generally needed to confirm the diagnosis, surgical treatment must be carried out at the same time. Methotrexate is, in our opinion, only indicated as a secondary option for organ-preserving operations with primary incomplete resection or trophoblast persistence, as shown by the disappointing decrease in hCG levels after the operation.

Cervical pregnancy

Incidence

The incidence of cervical pregnancy ranges from 1/2400 to 1/50 000 pregnancies; it occurs in 0.15% of all ectopic pregnancies and in 0.1% of IVF pregnancies.

Diagnosis

When an embryo implants and grows within the endocervical canal, it can lead to life-threatening bleeding. Previously, diagnosis was often made only at the time of D&C, when extensive hemorrhage occurred.

Early diagnosis is now facilitated by the use of transvaginal ultrasound. Sonographic criteria of cervical pregnancy include endocervical localization of the gestational sac and trophoblastic invasion. Differential diagnosis from Naboth eggs (Figure 13.12) must be considered. MRI can be performed to eliminate any doubt, and to confirm the ectopic location of the implantation site.

Etiology and risk factors

The pathogenesis of cervical pregnancy is poorly understood. Prior surgical uterine manipulation and tubal disease are implicated as risk factors for cervical pregnancy, but it remains unclear. In certain cases of IVF, reflux of the embryo into the cervix after transfer, or trauma to the cervix during embryo transfer, are two possible contributory factors⁵⁰.

Treatment by a non-conservative surgical technique

Before 1979, hysterectomy was performed to save the life of the patient in about 90% of cases. This type of surgery has now become obsolete, thanks to conservative (surgical and medical) procedures.

Treatment by conservative surgical techniques

In order to preserve women's fertility, conservative surgical techniques have been developed. The main problem with conservative treatment is life-threatening hemorrhage after pregnancy evacuation. Cervical curettage can be followed by intracervical balloon tamponade, cervical cerclage or local prostaglandin instillation. Angio-embolization of the uterine artery and bilateral ligation of the hypogastric arteries are other possibilities for hemorrhage control, when the previously described techniques have failed. In a review by Ushakov *et al.*⁵¹, the use of cervical canal tamponade with a Foley catheter balloon after pregnancy evacuation led to reliable hemostasis in 92.3% of cases.

Ash and Farrell⁵² reported a case of hysteroscopic resection of a 6-week cervical pregnancy.

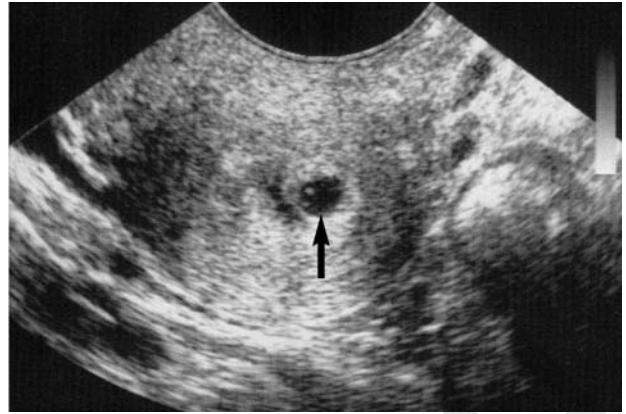


Figure 13.12 Vaginal echography: differential diagnosis from a Naboth egg (arrow) is not always easy

Non-surgical treatment techniques

In 1998, Hung *et al.*⁵³ reported a review of 52 cases of cervical pregnancy primarily treated by methotrexate (locally, systemically or both). The overall success rate was 61.5% (32/52): 90.9% (20/22) and 40% (12/30) for cervical pregnancy without or with embryonic cardiac activity, respectively.

From the pooled data derived from the literature review⁵⁴, factors that increased the risk for unsatisfactory primary methotrexate treatment were:

- Gestational age 9 weeks
- hCG 10 000 mIU/ml
- Embryonic cardiac activity
- Crown-rump length > 10 mm

In this review⁵³, the number of previous D&Cs, previous cesareans and the maximal diameter of the gestational sacs did not influence the results. In some cases, two techniques can be associated to improve results. Concomitant feticide (with intracardiac KCl injection) and methotrexate can be performed to minimize the potential risk of methotrexate failure, if embryonic cardiac activity is evident. In their series, the failure of methotrexate treatment was noted in a total of 20 cases. Reasons for abdominal intervention included massive or uncontrollable bleeding ($n=6$), a rise in serum β -hCG levels ($n=6$), persistent cervical ectopic gestations ($n=7$) and the appearance or persistence of embryonic cardiac activity ($n=7$). Of these 20 patients, 15 were successfully treated with one of the following additional therapeutic modalities:

- Systemic methotrexate administration
- Intra-amniotic methotrexate instillation
- Intracardiac injection of KCl (feticide)
- D&C

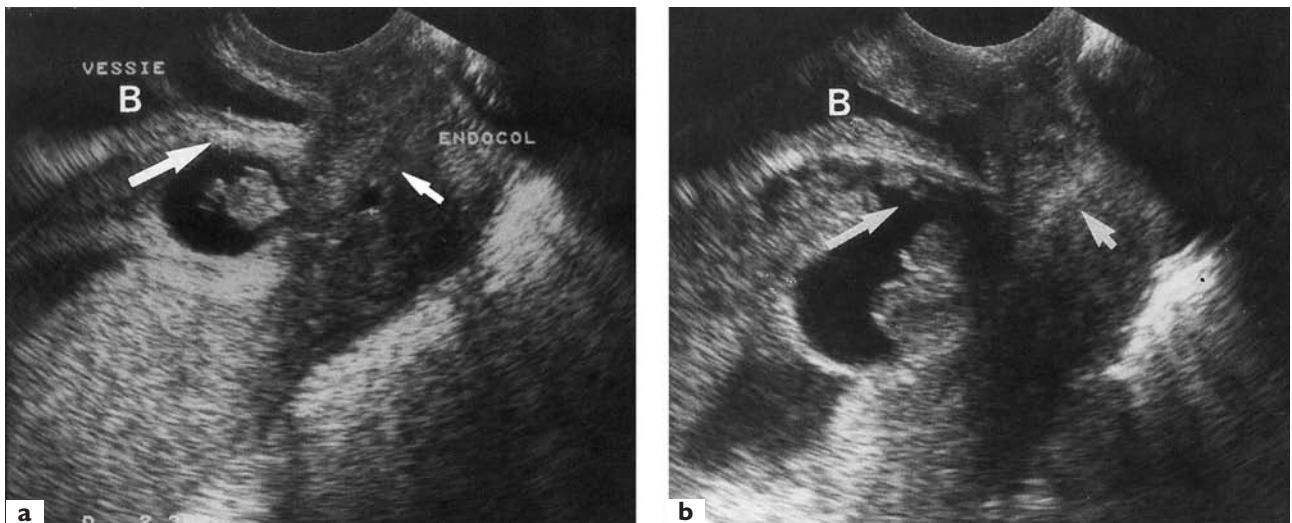


Figure 13.13 (a) The gestation (7 weeks of amenorrhea) was surrounded by myometrium (1.2 mm) (long white arrow) bulging from the serosal surface of the uterus. Short white arrow, endocervical canal; B, bladder. (b) At 9 weeks of amenorrhea, the embryo had a crown–rump length of 24 mm. No myometrium (long white arrow) was visualized between the sac and the bladder. White arrowhead, endocervical canal; B, bladder

- Embolization of uterine arteries
- Conservative abdominal surgery

The five remaining patients needed more than one additional operation. Among them, three underwent hysterectomy due to uncontrollable bleeding.

More recently, Kim *et al.*⁵⁵ have reported their series of 31 patients treated for cervical pregnancy with or without methotrexate. Of the nine patients who were treated with surgical procedures without methotrexate, three underwent total abdominal hysterectomy. In the methotrexate group, 14 patients were treated with methotrexate only and eight patients underwent concomitant procedures. In this group, no hysterectomies were performed.

Conclusions

Whatever treatment is used, they are all associated with some degree of failure. A combination of treatments is possible. Sometimes after treatment, rapid and massive bleeding from the non-involutive and atonic cervix may occur unexpectedly and indicate hysterectomy.

Conservative treatment with methotrexate (followed or not by other conservative treatment) yields a 91% success rate for preservation of the uterus^{54,56}.

Ectopic pregnancy in a cesarean section scar

This entity must be clearly distinguished from cervical pregnancy⁵⁷. A pregnancy developing in a previous cesarean section scar is the rarest type of ectopic pregnancy. Its true incidence is difficult to establish, because so few cases have been reported in the literature.

Nevertheless, in their paper, Maymon *et al.*⁵⁸ recorded 66 cases published since 2002. This increase could reflect the increased number of cesarean procedures currently performed⁵⁹ and the improvement in ultrasound diagnosis of such pregnancies⁶⁰.

The risk involved in this type of pregnancy is that of uterine rupture and hemorrhage, requiring emergency hysterectomy^{61–63}. The most reasonable hypothesis to explain this entity is that the conceptus enters the myometrium through a microscopic dehiscence tract of the cesarean section scar. In 1993, a case was diagnosed by echography, and required hysterectomy due to rupture and extensive bleeding at week 24 of gestation⁶². In 1995, another case was treated conservatively by methotrexate, but laparotomy was required 2 weeks after injection because of extensive bleeding⁶⁴. Still more recently, hysterectomy was performed to achieve pregnancy termination⁶⁵.

In our report^{57,66}, the first case of ectopic pregnancy developing in a previous cesarean section scar diagnosed by vaginal echography and MRI was treated successfully by local injection of KCl and methotrexate. This minimally invasive non-surgical approach can preserve fertility without any major risk to the mother.

Since the advent of endovaginal echography (Figure 13.13) and MRI (Figure 13.14), it has been possible to make the diagnosis earlier in the gestation and to use a more conservative approach. Strict imaging criteria must be applied to assess the diagnosis: empty uterus, empty cervical canal, development of the sac in the anterior part of the isthmic portion and an absence of healthy myometrium between the bladder and the sac. This last criterion allows us to differentiate a pregnancy implanted

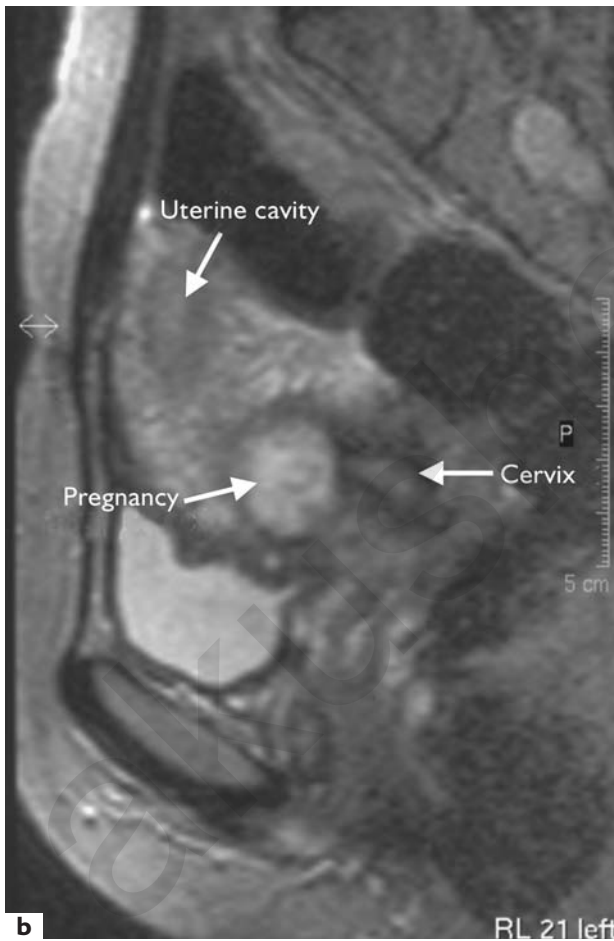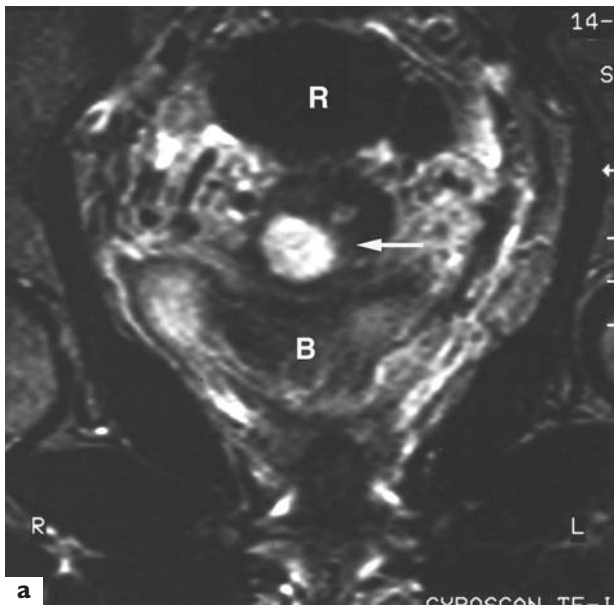


Figure 13.14 (a) Magnetic resonance imaging (MRI): transverse section clearly demonstrated the pregnancy (arrow) implanted in the anterior portion of the cervix, outside the endocervical canal. R, rectum; B, bladder. (b) Sagittal section demonstrated the pregnancy implanted in the anterior portion of the cervix. The cervical canal as well as the uterine cavity are clearly visible

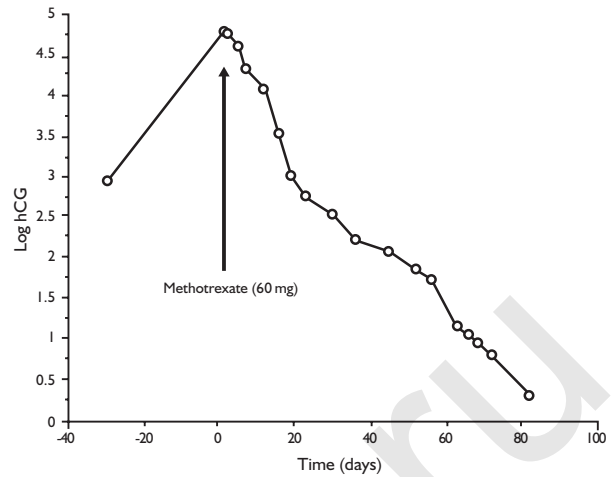


Figure 13.15 Cesarean section scar pregnancy: evolution of human chorionic gonadotropin (hCG) levels following intrauterine methotrexate administration

in a cesarean scar from a cervical or cervicoisthmic pregnancy.

At 9 weeks of amenorrhea, the embryo had a crown-rump length of 24 mm and persistent cardiac activity. No myometrium was visible between the bladder and the sac, which obviously bulged in a 'prerupture' stage (Figure 13.13). The uterine cavity remained empty. To confirm the diagnosis, MRI was carried out. The uterine cavity was empty, although trophoblastic tissue and an embryo were seen on a transverse section in the anterior portion of the cervix (Figure 13.14), outside the endocervical canal, in a previous cesarean section scar. Because of the risk of uterine rupture, it was decided to interrupt the pregnancy. Under the guidance of endovaginal sonography, a 22-gauge needle was introduced transvaginally into the gestational sac through the cervix, 8 mmol KCl (2 mmol/ml) was injected directly into the fetal thorax to stop cardiac motion and 60 mg of methotrexate was injected into the sac and the surrounding myometrium.

The subsequent course was characterized by a steady progressive resorption of the pregnancy, as demonstrated by the decrease in the hCG level. The hCG levels were 62 000, 39 800, 11 900, 552 and 114 mIU/ml on days 0, 5, 12, 23 and 45, respectively. It was finally undetectable on day 82 (Figure 13.15). Sonographic findings showed a rapid disappearance of the fetal pole, with persistent amorphous echoes. On day 96, an ultrasound examination demonstrated a normal non-gravid uterus and cervix. There was no change in either liver function or bone marrow suppression. Bleeding and uterine cramps were intermittent and minimal.

The patient experienced menstrual bleeding 16 weeks after the methotrexate injection. Hysterosalpingography was performed and demonstrated a dehiscent cesarean

section scar. Because of the very low risk of recurrence of an ectopic pregnancy in this site, it was decided that the patient could attempt to conceive. She delivered a healthy baby 14 months later by cesarean section performed at 38 weeks.

In the literature, different treatment (medical and surgical) approaches have been proposed when such a pregnancy is diagnosed (for a summary, see reference 58). However, no universal treatment guidelines have been established to date⁶⁷, and there is no consensus on the treatment of choice⁵⁸.

REFERENCES

1. Steptoe PC, Edwards RG. Reimplantation of the human embryo with subsequent tubal pregnancy. *Lancet* 1976; 1: 880–2
2. Marcus SF, Brinsden P. Analysis of the incidence and risk factors associated with ectopic pregnancy following in-vitro fertilization, and embryo transfer. *Hum Reprod* 1995; 10: 190–203
3. Abusheikha N, Salha O, Brinsden P. Extra-uterine pregnancy following assisted conception treatment. *Hum Reprod Update* 2000; 6: 80–92
4. Lesny P, Killick SR, Robinson J, et al. Transcervical embryo transfer as a risk factor for ectopic pregnancy. *Fertil Steril* 1999; 72: 305–9
5. Tal J, Haddad S, Godon N, et al. Heterotopic pregnancy after ovulation induction and assisted reproductive technologies: a literature review from 1971 to 1993. *Fertil Steril* 1996; 66: 1–12
6. Bassil S, Pouly JL, Canis M, et al. Advanced heterotopic pregnancy after in-vitro fertilization and embryo transfer, with survival of both the babies and the mother. *Hum Reprod* 1991; 6: 1008–10
7. Fernandez H, Gervaise A. Ectopic pregnancies after infertility treatment: modern diagnosis and therapeutic strategy. *Hum Reprod Update* 2005; 6: 503–13
8. Reece EA, Petrie RH, Sirmans MF, et al. Combined intrauterine and extrauterine gestations: a review. *Am J Obstet Gynecol* 1983; 146: 323–30
9. Verhulst G, Camus M, Bollen N, et al. Analysis of the risk factors with regard to the occurrence of ectopic pregnancy after medically assisted procreation. *Hum Reprod* 1993; 8: 1284–7
10. Felmus LB, Pedowitz P. Interstitial pregnancy: a survey of 45 cases. *Am J Obstet Gynecol* 1953; 66: 1271–9
11. Carreno CA, King M, Johnson MP, et al. Treatment of heterotopic cervical and intrauterine pregnancy. *Fetal Diagn Ther* 2000; 15: 1–3
12. Habana A, Dokras A, Giraldo JL, et al. Cornual heterotopic pregnancy: contemporary management options. *Am J Obstet Gynecol* 2000; 182: 1264–70
13. Fernandez H, Benifla JL. Medical treatment of cornual pregnancy? *Fertil Steril* 1996; 66: 862
14. Hsieh BC, Hwang JL, Pan HS, et al. Heterotopic Caesarean scar pregnancy combined with intrauterine pregnancy successfully treated with embryo aspiration for selective embryo reduction: case report. *Hum Reprod* 2004; 19: 285–7
15. Gyamfi C, Cohen S, Stone JL. Maternal complication of cervical heterotopic pregnancy after successful potassium chloride fetal reduction. *Fertil Steril* 2004; 82: 940–3
16. Thompson JD, Rock JA, Te Linde's Operative Gynecology, 8th edn. Philadelphia: JB Lippincott, 1997
17. Bassil S, Gordts S, Nisolle M, et al. A magnetic resonance imaging approach for the diagnosis of a triplet cornual pregnancy. *Fertil Steril* 1995; 5: 1029–31
18. Hill GA, Segars JH, Herbert CA. Laparoscopic management of interstitial pregnancy. *J Gynecol Surg* 1989; 5: 209–12
19. Tulandi T, Vilos G, Gomel V. Laparoscopic treatment of interstitial pregnancy. *Obstet Gynecol* 1995; 85: 465–7
20. Reich H, Johns DA, DeCaprio J, et al. Laparoscopic treatment of 109 consecutive ectopic pregnancies. *J Reprod Med* 1988; 33: 885–90
21. Reich H, McGlynn F, Budin R, et al. Laparoscopic treatment of ruptured interstitial pregnancy. *J Gynecol Surg* 1990; 6: 135–8
22. Pasic R, Wolfe WM. Laparoscopic diagnosis and treatment of interstitial ectopic pregnancy: a case report. *Am J Obstet Gynecol* 1990; 163: 587–8
23. Pansky M, Bukovsky I, Golan A, et al. Conservative management of interstitial pregnancy using operative laparoscopy. *Surg Endosc* 1995; 9: 515–16
24. Gleicher N, Karande V, Rabin D, et al. Laparoscopic removal of twin cornual pregnancy after in vitro fertilization. *Fertil Steril* 1994; 61: 1161–2
25. Donnez J, Nisolle M. Endoscopic management of ectopic pregnancy. *Bailliere's Clin Obstet Gynaecol* 1994; 8: 707–22
26. Grobman WA, Milad MP. Conservative laparoscopic management of a large cornual ectopic pregnancy. *Hum Reprod* 1998; 13: 2002
27. Rahimi MA. A new laparoscopic approach for the treatment of interstitial ectopic pregnancy. *J Am Assoc Gynecol Laparosc* 1999; 6: 205–7
28. Moon HS, Choi YJ, Park YH, et al. New simple endoscopic operations for interstitial pregnancies. *Am J Obstet Gynecol* 2000; 182: 114–21
29. Woodland MB, DePasquale SE, Molinari JA, et al. Laparoscopic approach to interstitial pregnancy. *J Am Assoc Gynecol Laparosc* 1996; 3: 439–41
30. Agarwal SK, Wisot AL, Garzo G, et al. Cornual pregnancies in patients with prior salpingectomy undergoing in vitro fertilization and embryo transfer. *Fertil Steril* 1996; 65: 659–60
31. Timor-Tritsch IE, Monteagudo A, Lerner JP. A 'potentially safer' route for puncture and injection of cornual ectopic pregnancies. *Ultrasound Obstet Gynecol* 1996; 7: 353–5
32. Batioglu S, Haberal A, Yesilyurt H, et al. Successful treatment of cornual pregnancy by local injection of methotrexate under laparoscopic and transvaginal ultrasonographic guidance. *Gynecol Obstet Invest* 1997; 44: 64–6

33. Lau S, Tulandi T. Conservative medical and surgical management of interstitial ectopic pregnancy. *Fertil Steril* 1999; 72: 207–15
34. Riethmuller D, Sautiere JL, Benoit S, et al. Ultrasonic diagnosis and laparoscopic treatment of an ovarian pregnancy. A case report and review of the literature. *J Gynecol Obstet Biol Reprod Paris* 1996; 25: 378–83
35. Rizk B, Lachelin CL, Davies MC, et al. Ovarian pregnancy following in-vitro fertilization and embryo transfer. *Hum Reprod* 1990; 5: 763–4
36. Marcus SF, Brinsden PR. Primary ovarian pregnancy after in vitro fertilization and embryo transfer: report of seven cases. *Fertil Steril* 1993; 60: 167–9
37. Ranieri DM, Vicino MG, Simonetti S, et al. Gravidanza eterotopica ovarica dopo fertilizzazione in vitro ed embryo transfer e gravidanza tubarica controlaterale dopo trasferimento intratubarico dei gameti. *Minerva Ginecol* 1994; 46: 365–8
38. Shibahara H, Funabiki M, Shiotani T, et al. A case of primary ovarian pregnancy after in vitro fertilization and embryo transfer. *J Assist Reprod Genet* 1997; 14: 63–4
39. Lehmann F, Baban N, Harms B, et al. Ovarialgravidität nach Gametentransfer (GIFT). *Geburtshilfe Frauenheilkd* 1991; 51: 945–7
40. El-Lakany NEH, Hock YL, Boyd NRH. Primary ovarian pregnancy following intra-uterine insemination. *J Obstet Gynecol* 1995; 15: 182–3
41. Bontis J, Grimbizis G, Tarlatzis BC, et al. Intrafollicular ovarian pregnancy after ovulation induction/intrauterine insemination: patho-physiological aspects and diagnostic problems. *Hum Reprod* 1997; 12: 376–8
42. Einkenkel J, Baier D, Horn LC, et al. Laparoscopic therapy of an intact primary ovarian pregnancy with ovarian hyperstimulation syndrome: case report. *Hum Reprod* 2000; 15: 2037–40
43. Spiegelberg O. Zur Kasuistik der Ovarialschwangerschaft. *Arch Gynecol* 1878; 13: 73–5
44. Hsu CC, Yang TT, Hsu CT. Ovarian pregnancy resulting from corneal fistulae in a woman who had undergone bilateral salpingectomy. *Fertil Steril* 2005; 83: 205–7
45. Ercal T, Cinar O, Mumcu A, et al. Ovarian pregnancy; relationship to an intrauterine device. *Aust NZ J Obstet Gynaecol* 1997; 37: 362–4
46. Seiner P, Di-Gregorio A, Arisio R, et al. Ovarian pregnancy and operative laparoscopy: report of eight cases. *Hum Reprod* 1997; 12: 608–10
47. Van Coevering RJ, Fisher JE. Laparoscopic management of ovarian pregnancy. A case report. *J Reprod Med* 1988; 33: 774–6
48. Godenberg M, Bider D, Maschiach S, et al. Laparoscopic laser surgery of primary ovarian pregnancy. *Hum Reprod* 1994; 9: 1337–8
49. Chelmow D, Gates E, Penzias AS. Laparoscopic diagnosis and methotrexate treatment of an ovarian pregnancy: a case report. *Fertil Steril* 1994; 62: 879–81
50. Ginsburg ES, Fox JH, Frates MC. Early diagnosis and treatment of cervical pregnancy in an in vitro fertilization program. *Fertil Steril* 1994; 61: 966–9
51. Ushakov FB, Elchalal U, Aceman PJ, et al. Cervical pregnancy: past and future. *Obstet Gynecol Surv* 1997; 52: 45–59
52. Ash S, Farrell SA. Hysteroscopic resection of a cervical ectopic pregnancy. *Fertil Steril* 1996; 66: 842–4
53. Hung TH, Shau WY, Hsieh TT, et al. Prognostic factors for an unsatisfactory primary methotrexate treatment of cervical pregnancy: a quantitative review. *Hum Reprod* 1998; 13: 2636–42
54. Kung FT, Chang SY, Tsai YC, et al. Subsequent reproduction and obstetric outcome after methotrexate treatment of cervical pregnancy: a review of original literature and international collaborative follow-up. *Hum Reprod* 1997; 12: 591–5
55. Kim TJ, Seong SJ, Lee KJ, et al. Clinical outcomes of patients treated for cervical pregnancy with or without methotrexate. *J Korean Med Sci* 2004; 19: 842–52
56. Kung FT, Chang SY. Efficacy of methotrexate treatment in viable and nonviable cervical pregnancies. *Am J Obstet Gynecol* 1999; 181: 1438–44
57. Godin PA, Bassil S, Donnez J. An ectopic pregnancy developing in a previous Caesarian section scar. *Fertil Steril* 1997; 67: 398–400
58. Maymon R, Halperin R, Mendlovic S, et al. Ectopic pregnancies in a Caesarean scar: review of the medical approach to an iatrogenic complication. *Hum Reprod Update* 2004; 10: 515–23
59. Shannon AH. Recent developments in obstetrics. *Br Med J* 2003; 327: 604–8
60. Jurkovic D, Hillaby K, Woelfer B, et al. First-trimester diagnosis and management of pregnancies implanted into the lower uterine segment Caesarean section scar. *Ultrasound Obstet Gynecol* 2003; 21: 220–7
61. Herman A, Weinraub Z, Avrech O, et al. Follow-up and outcome of isthmic pregnancy located in a previous caesarean section scar. *Br J Obstet Gynaecol* 1995; 102: 839–41
62. Wehbe A, Ioan A, Allart JP, et al. A case of cervicoisthmic pregnancy with delayed development. *Rev Fr Gynecol Obstet* 1993; 88: 439–44
63. Rempen A, Albert P. [Diagnosis and therapy of an in the caesarean section scar implanted early pregnancy]. *Z Geburtshilfe Perinatol* 1990; 194: 46–8
64. Lay YM, Lee JD, Lee CL, et al. An ectopic pregnancy embedded in the myometrium of a previous caesarean section scar. *Acta Obstet Gynecol Scand* 1995; 74: 573–6
65. Valley MT, Pierce JC, Daniel TB, et al. Cesarean scar pregnancy: imaging and treatment with conservative surgery. *Obstet Gynecol* 1998; 91: 838–40
66. Donnez J, Godin PA, Bassil S. Successful methotrexate treatment of a viable pregnancy within a thin uterine scar. *Br J Obstet Gynaecol* 1997; 104: 1255
67. Fylstra DL. Ectopic pregnancy within a cesarean scar: a review. *Obstet Gynecol Surv* 2002; 57: 537–43

Medical treatment: the place of methotrexate

J Donnez, C Pirard

METHOTREXATE AS FIRST-LINE THERAPY

Since the first reports by Stovall *et al.* in 1989 and 1991^{1,2}, methotrexate (MTX) has been extensively studied, and may offer an alternative to laparoscopic surgery. This treatment can be proposed when a diagnosis of unruptured ectopic pregnancy (EP) is made.

MTX allows the effective treatment of unruptured EP at a low cost, but the question is, how can one establish that the EP is not ruptured, or that there is no active bleeding, without performing a laparoscopy? Also, if laparoscopy is needed to confirm the diagnosis of unruptured pregnancy, it is then less expensive and more logical to treat it by laparoscopy.

The rupture rate of tubal pregnancies, confirmed by laparoscopy, is 18–36% (42% in 1991)³. According to Mol *et al.*⁴, abdominal pain, rebound tenderness on abdominal examination, fluid in the pouch of Douglas at transvaginal ultrasound and a low serum hemoglobin level are independent predictive factors for tubal rupture and/or active bleeding. However, the most sensitive predictive factor is abdominal pain (sensitivity of 95%). Surprisingly, Mol *et al.* found that pregnancy obtained by *in vitro* fertilization–embryo transfer (IVF–ET) and the presence of an ectopic gestational sac or an ectopic mass at echography reduced the risk of tubal rupture.

Fernandez *et al.*^{5–9} have proposed using a predictive pretherapeutic score for the medical treatment of EP. Six criteria are assessed and graded on a scale of 1–3:

- Gestational age
- Level of human chorionic gonadotropin (hCG)
- Progesterone level
- Presence of abdominal pain
- Echographic evaluation of hemoperitoneum volume
- Hematosalpinx diameter

The success rate of medical treatment is more than 90% when the pretherapeutic score is less than 13 (which represents ± 30 –40% of patients with EP).

Different means of administration are described: systemic (intramuscular or intravenous), oral, locally injected at laparoscopy or under ultrasound guidance. There is also great heterogeneity in the use of MTX at doses ranging from 0.4 to 1 mg/kg per day, given one to four times:

- Multiple-dose protocol: four intramuscular (IM) injections of 1 mg/kg methotrexate (on days 0, 2, 4,

6), alternating with four oral doses of 0.1 mg/kg folic acid (on days 1, 3, 5, 7) (initially proposed by Tanaka *et al.*¹⁰)

- Single-dose protocol: one IM injection of 1 mg/kg or 50 mg/m² methotrexate⁹
- *In situ* protocol: one injection *in situ* (or IM, if impossible) of 1 mg/kg methotrexate⁸

Single-dose MTX (1 mg/kg) seems to be as effective as the multidose regimen^{8,9}.

Injection under ultrasonic guidance

Transvaginal ultrasound aims to localize the EP. The procedure is carried out without anesthesia, with an 18-gauge needle inserted into a needle introducer. First, the gestational sac is aspirated and then the MTX is injected (1 mg/kg). In some cases, this technique allows confirmation of the diagnosis by histological examination. In fact, it constitutes an association between mechanical and medical management.

In a study by Fernandez *et al.*⁸, MTX was administered into the sac in 29 women, and was given intramuscularly to 22 women, whose sac could not be safely or easily punctured. Patients followed up by telephone were aware of the possibility of treatment failure, which was defined by the persistence of high hCG concentrations or the onset of abdominal pain, or both. In such cases, patients were treated either by laparoscopy or by a second injection of MTX, if they were asymptomatic. The success rate (88.2%) obtained after MTX injection was similar to the rate after laparoscopic salpingotomy (95.9%)⁹.

There was no statistical difference between local and intramuscular administration of MTX. Nevertheless, it is important to note that four of the six failures occurred among patients who received an intramuscular injection.

In conclusion, local MTX treatment under ultrasound guidance was associated with high tissue MTX concentrations with fewer systemic side-effects than after intramuscular administration. The study by Fernandez *et al.*⁸ demonstrates that, when the ectopic sac is easily visualized by echography, direct puncture and injection of a minimal dose of 1 mg/kg MTX is as effective as systemic treatment, with no side-effects for the patient. Indeed, side-effects were rare in their study^{8,9}. However, an initial rise in hCG plasma levels after medical treatment might reflect an increase in hCG metabolism due to intracellular polyglutamation of MTX and/or trophoblastic cell necrosis, with release of hCG into the maternal circulation.

Injection at laparoscopy

In 1993, Pansky *et al.*¹¹ published a study of 77 unruptured EPs treated by laparoscopic injection of MTX (12.5 or 25 mg), and concluded that local MTX injection does not modify tubal or pelvic anatomy and does not impair subsequent reproductive performance, compared with laparoscopic salpingotomy. We do not fully agree, however. Indeed, we consider that, when an ectopic sac is found at laparoscopy, a linear salpingotomy to remove the trophoblast or a salpingectomy should be performed immediately. During laparoscopy, local injection of MTX should be indicated only in the case of cornual ectopic pregnancy or in cases of large tubal pregnancy with embryos with cardiac activity.

Systemic treatment (Table 14.1)

In 1994, it was concluded that, when echo-guided local injection of MTX appears difficult or is not readily available, systemic MTX injection (1 mg/kg, intramuscularly) should be administered⁸. Systemic MTX therapy is associated with a prolonged duration of treatment, potential drug toxicity, pain during treatment and the need for scrupulous follow-up. Repeat injection of MTX (or laparoscopic treatment) is required only when the hCG level increases above the normal regression curve. Many authors (see the review by Morlock *et al.*²²) have proposed the systemic approach as first-line therapy. The selection criteria are those already described, involving determination of the pretherapeutic score⁵⁻⁹.

Following the first reports^{1,2}, a review by Morlock *et al.* in 2000²² clearly analyzed the pros and cons of this approach.

The resolution rates of women treated by laparoscopy and single-dose MTX used in the baseline model were

analyzed. The published resolution rates of studies with laparoscopy ranged from 72 to 100%^{14,20,23-34}, whereas the overall resolution rates for MTX therapy ranged from 75 to 90%^{11,13,15-17,21,35,36}. The average rate of laparoscopic resolution was 90%. The average resolution rate in studies that included first- and second-dose MTX therapy was 84%. This has placed the medical treatment of EP securely within the therapeutic options of general practice by gynecologists, because of the ease of application and the low incidence of serious side-effects. However, the high success rates reported by Stovall and Ling³⁷ have been difficult to reproduce in other studies. Many believe that randomized clinical trials are required before MTX treatment can be considered anything other than second-line or experimental therapy³⁸. In terms of fertility sparing, laparoscopy successfully resolves pregnancies in more than 90% of cases, with relatively low complication rates.

Follow-up

Regression of the hCG level must be followed until it reaches the assay detection limit. The timing of regression is well known, and regression curves are often used.

It is interesting to note that, after injection of MTX, there is, initially, an increase in hCG (between days 1 and 4), which might reflect an increase in hCG metabolism, as stated earlier in this chapter. The hCG resolution time is shorter when a salpingotomy is performed than when MTX is used¹⁹.

Failure of treatment

When non-surgical treatment is not successful, even after repeat MTX injection, surgical management must be decided upon. The most frequent reason to perform laparoscopy is unusual abdominal pain, an inadequate

Table 14.1 Success rates of systemic methotrexate

Study	Number of women	Type of protocol	Success rate (n (%))
Lipscomb <i>et al.</i> ¹²	352	Single intramuscular dose	322 (91.5)
Stovall <i>et al.</i> ²	100	Multiple intramuscular doses	96 (96.0)
Henry and Gentry ¹³	61	Single intramuscular dose	52 (85.2)
Hajenius <i>et al.</i> ¹⁴	51	Multiple intramuscular doses	44 (86.3)
Thoen and Creinin ¹⁵	47	Single intramuscular dose	43 (91.5)
Stika <i>et al.</i> ¹⁶	50	Single intramuscular dose	39 (78.0)
Corsan <i>et al.</i> ¹⁷	44	Single intramuscular dose	33 (75.0)
Schafer <i>et al.</i> ¹⁸	40	Various single intravenous doses	37 (92.5)
Saraj <i>et al.</i> ¹⁹	38	Single intramuscular dose	36 (94.7)
Lecuru <i>et al.</i> ²⁰	37	Single intramuscular dose	34 (91.9)
Glock <i>et al.</i> ²¹	35	Single intramuscular dose	30 (85.7)
Fernandez <i>et al.</i> ⁹	22	Single intramuscular dose	18 (47.4)
Total	877		784 (89.4)

decrease in hCG plasma levels, an acute hemoperitoneum and an increase in hematosalpinx observed by echography. Conservative laparoscopic treatment is then advocated.

Discussion

In 1993, Stovall and Ling³⁷ reported a resolution rate of 94% in a series of 120 patients treated with single-dose intramuscular MTX (50 mg/m²). Post-treatment hCG demonstrated tubal patency on the ipsilateral side in 82% of patients.

In 1999, Lipscomb *et al.*¹² reported the results of their study of 350 patients treated with intramuscular MTX according to a single-dose protocol. They observed a success rate of 91%. They concluded that the pretreatment hCG concentration was the most important factor contributing to the failure rate.

According to Morlock *et al.*²², who carried out a cost-effectiveness comparison between single-dose MTX and laparoscopic treatment of EP, MTX is \$3000 less expensive than laparoscopy as front-line therapy for unruptured EP. In this review, they mentioned that the average resolution rate was 87% with MTX and 91% with laparoscopy.

In conclusion, MTX given intramuscularly is a valid option when laparoscopy does not offer a diagnosis and the ectopic mass is smaller than 4 cm, when the gestational sac is no longer viable and when the ectopic pregnancy cannot be safely and easily punctured under echographic guidance. In the presence of cardiac activity in the EP, we consider MTX treatment to be contraindicated, and we prefer to perform laparoscopy and salpingotomy. When cardiac activity is present, vasopressin injection in the broad ligament beneath the EP could be helpful before salpingotomy. We consider that MTX injection in the broad ligament should be performed during laparoscopy if trophoblast removal is difficult or possibly incomplete.

In a recent review published in the *New England Journal of Medicine*, Lipscomb *et al.*³⁹ still consider selective suction curettage as part of the algorithm for EP diagnosis. Even if some arguments are given to support this, such as eliminating the possibility of giving MTX unnecessarily to a patient with a non-viable intrauterine pregnancy, or the decreased need for unnecessary serial monitoring of hCG levels, we disagree with this view.

Indeed, in the majority of cases, serial hCG monitoring and high-quality vaginal echography make suction curettage obsolete, by providing a highly probable diagnosis of extrauterine pregnancy. The risk of intrauterine synechiae (Figure 14.1), due to unnecessary suction curettage, has to be considered and compared with the administration of a chemotherapeutic agent that has no benefit in this instance and is potentially toxic.

METHOTREXATE AS SECOND-LINE THERAPY

MTX can be given as second-line therapy in the case of failure of laparoscopic linear salpingotomy.

Diagnosis of persistent trophoblast

The diagnosis of persistent trophoblast after laparoscopic salpingotomy is made by measuring hCG levels postoperatively. It has been shown and proved in one of our studies⁴⁰ that, 2 days postoperatively, the hCG level should be less than 50% of the preoperative level, and, after 4 days, less than 25% of the preoperative level. Figure 13.2 illustrates the postoperative decrease in hCG: if the postoperative hCG level is within the dark purple area, the laparoscopic treatment is considered to have been successful. If the postoperative hCG level is within the blue area, the diagnosis of persistent ectopic tissue is made. Indeed, an absence of any decrease proves the active secretion of hCG by persistent and well-vascularized trophoblastic tissue. However, if the hCG level falls within the light purple intermediate area (between the dark purple and blue), then a follow-up evaluation must be made by repeated hCG level monitoring 2 days later, in order to evaluate the presence or absence of any significant decrease.

In our department, if the 2-day postoperative hCG level remained higher than 50% of the initial (before laparoscopy) value, MTX (40 mg, intramuscularly) was administered. The hCG level was evaluated 4 days postoperatively and, if necessary, MTX was again given intramuscularly if hCG levels were >25% of the initial value.

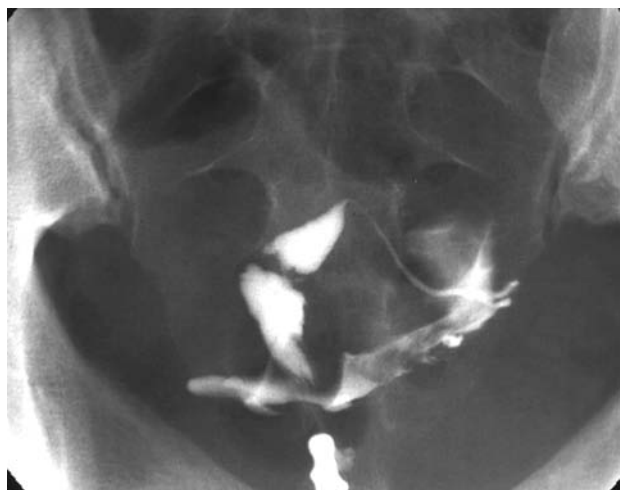

Figure 14.1 Synechiae due to suction curettage performed for diagnosis of extrauterine pregnancy

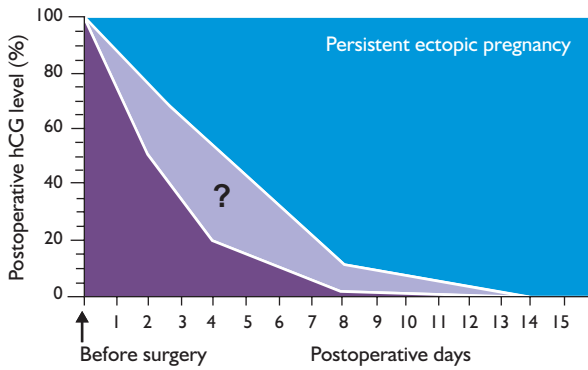


Figure 14.2 Graph illustrating postoperative decrease in human chorionic gonadotropin (hCG) level: the purple area is the successful area; the blue area is the failed area; the intermediate light purple area is the repeated monitoring area

Prevalence and management

In a first series of 300 patients⁴⁰ treated conservatively by laparoscopic salpingotomy (Table 14.2), two cases in 1982 required second-look laparotomy for recurrent bleeding due to persistent trophoblast. In 15 other cases, persistent trophoblast was also observed. All were treated successfully with MTX (Figure 14.3). The incidence of persistent ectopic gestation following conservative surgery was 5%. This incidence was similar to that observed in the literature review by Morlock *et al.*²², who estimated the average failure rate to be 10%.

In a second series of 320 patients who underwent conservative laparoscopic treatment, persistent trophoblastic tissue was observed in 41 cases (13%) (Table 14.2). Again, all patients were treated with intramuscular MTX. However, in this second series, eight failures were encountered, despite MTX administration.

Thus, two important questions remained to be answered, namely: why was there an increased persistent EP rate in the second series, and why, in this series, did the administration of MTX fail in eight cases?

Concerning the increased use of MTX, a distinction must be made between true and false failures. True failures can be explained by the fact that, in a university teaching hospital setting, residents are in the process of learning when performing laparoscopic procedures. The rate of such failures in our series was 8.5%, higher than the rate observed in the first series of 300 patients treated by the same surgeons (i.e. JD and MN). In these cases, MTX was required because of the abnormal decrease in the hCG level. After an initial decrease, the hCG level increased into the dark blue area. The diagnosis of persistent trophoblast was made, and MTX was administered intramuscularly twice or three times, if needed (Figure 14.4). False failures can be accounted for by the inadequate use of MTX

Table 14.2 Tubal pregnancy: laparoscopic procedures

	1980–1986 (n=300)	1987–1990 (n=320)
Persistent ectopic pregnancy	n = 15 (5%)	n = 41 (13%)
Therapy	Methotrexate	Methotrexate
Failure	0	8

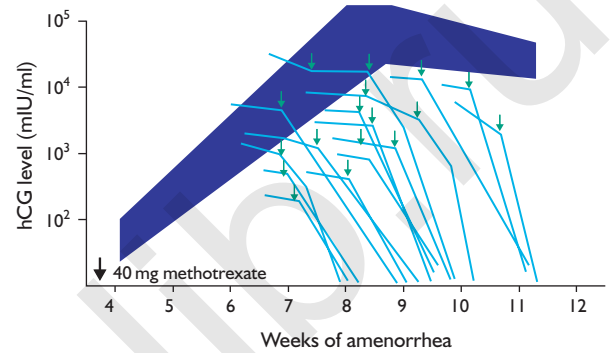


Figure 14.3 Levels of human chorionic gonadotropin (hCG) before and after administration of 40 mg of methotrexate intramuscularly in 15 cases of persistent trophoblast (first series) (n = 300)

(4.5%). Indeed, in a few cases, MTX was given when it was not required, when the hCG level decrease was normal.

In conclusion, the failure rate of 8.5% observed in the second series was higher than that noted in the first series, as a result of necessary internship in the department.

The second question to be addressed was why the administration of MTX failed in eight cases of the second series published in 1994³⁸ (Table 14.3). In patients receiving medication for ovulation, the EP risk may be double. In one case, we observed a heterotubal pregnancy, and another patient presented with a double tubal implantation site. Both patients had received clomiphene citrate and both underwent second-look laparoscopy. In the case of the heterotubal pregnancy, a successful salpingotomy was carried out. The second patient underwent a third laparoscopy because of recurrent bleeding after the second salpingotomy. Laparoscopic salpingectomy was then carried out. There was one implantation site in the ampulla and another in the isthmus. In this case, the first procedure (ampullary salpingotomy) was well chosen, as proved by the anatomic aspect observed at the time of the third laparoscopy. The recurrent bleeding was provoked by persistent trophoblast in the isthmic tubal portion.

In two cases, the laparoscopy was performed too early (< 6 weeks of amenorrhea) and the EP was not visible (too

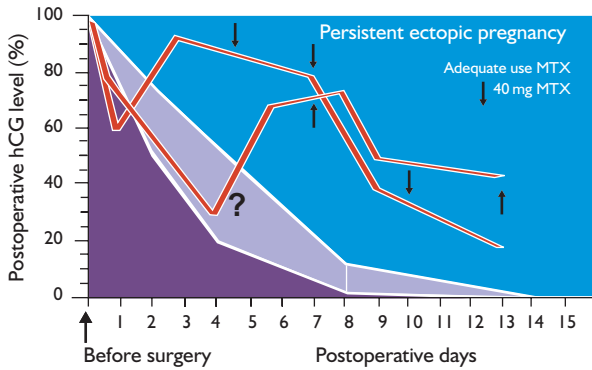


Figure 14.4 Adequate use of methotrexate: 4–5 days postoperatively, the human chorionic gonadotropin (hCG) level was abnormal (blue area) and methotrexate (MTX) was required

small); no surgical therapy was administered. A salpingotomy was performed 2 weeks later in one case. In the second case, an echo-guided MTX injection was given: the hCG level decreased, but the hysterosalpingography performed 3 months later showed ampullary dilatation and occlusion at the EP site.

In four cases, the laparoscopic procedure itself was at fault. The salpingotomy site was incorrect in three cases, requiring a second salpingotomy. In one case, the trophoblastic aspiration was insufficient and a salpingotomy and injection of MTX into the broad ligament were required.

In a series of 321 patients who had undergone conservative laparoscopic surgery, Pouly *et al.*³³ reported 15 cases with residual trophoblast. Of these patients, seven underwent a second laparoscopic procedure, and six required a salpingectomy via laparotomy³⁴ (Table 14.4). Rivlin *et al.*^{42,43} reviewed five case reports of persistent ectopic gestation, and recommended that salpingectomy be the standard procedure undertaken.

In 1987, DiMarchi *et al.*⁴⁵ reported four cases (4.8%) of EP out of 84 patients who had undergone a salpingotomy or fimbrial expression. Three patients required a repeat laparotomy and salpingectomy, and one was managed expectantly.

Table 13.4, showing more recent results, demonstrates that MTX is the therapy of choice to manage persistent ectopic trophoblast.

In a series of 20 patients undergoing linear salpingectomy^{44,46}, two patients demonstrated a postoperative rise in serum β -hCG levels, suggesting the persistence of trophoblastic tissue. Both patients were asymptomatic and were managed expectantly.

Discussion

After conservative surgical treatment of EP, a decrease in hCG levels must ensue until non-pregnant levels are achieved, because persistent EP may cause delayed intra-abdominal hemorrhage.

The risk of persistent tubal pregnancy must be considered if the hCG level falls by less than 50% on day 2, according to Donnez and Nisolle³⁸.

Spandorfer *et al.*⁴⁷ were even stricter in their criteria in 1997, claiming that the hCG level must fall by more than 50% on day 1. Hagstrom⁴⁸ and Kemmann⁴⁹ and their groups found that the risk of persistent tubal pregnancy could be predicted by progesterone and hCG levels observed 24 h preoperatively. In our opinion, a decrease in the hCG level to less than 50% of the initial value on day 2 is the main criterion.

Persistent ectopic pregnancy can appear as an increasing hCG titer or as ‘slow-falling hCG’ after conservative surgery. If a stable clinical condition is present, intramuscular MTX injection can be proposed as second-line therapy; otherwise, surgical treatment must be repeated. We do not consider the proposal of Gracykowski and Mishell⁵⁰, to administer prophylactic MTX (1 mg/kg) to reduce the incidence of persistent EP,

Table 14.3 Failures of methotrexate (MTX) used as therapy for persistent ectopic pregnancy ($n = 8$). Series published by Donnez and Nisolle in 1994³⁸

Problem	<i>n</i>	Post-methotrexate procedure
Heterotubal pregnancy (clomiphene citrate)	1	Salpingotomy (second-look)
Double implantation site (clomiphene citrate)	1	Salpingotomy (second-look) Salpingotomy (third-look)
(Too) early laparoscopic procedure	2	Salpingotomy (second-look) Echo-guided MTX injection
Imperfect laparoscopic procedure		
incorrect salpingotomy site	3	Salpingotomy (second-look)
insufficient trophoblastic aspiration	1	Salpingotomy and injection of MTX into the broad ligament (second-look)

Table 14.4 Management of persistent ectopic pregnancy after laparoscopic treatment

	Number of patients	Primary procedure	Management
Donnez ⁴¹	2	Salpingotomy	Salpingotomy and coagulation
Rivlin <i>et al.</i> ^{42,43}	1	Salpingotomy	Salpingectomy
Cartwright <i>et al.</i> ⁴⁴	2	Salpingotomy	Expectant
Pouly <i>et al.</i> ³³	11	Salpingotomy	Salpingotomy
	4	Fimbrial expression	Salpingectomy
DiMarchi <i>et al.</i> ⁴⁵	3	Salpingotomy	Salpingectomy
	1	Fimbrial expression	Expectant
Donnez and Nisolle ⁴⁰	13	Salpingotomy	Methotrexate
Donnez and Nisolle ³⁸	56	Salpingotomy	Methotrexate
Seifer <i>et al.</i> ²⁸	50	Salpingotomy	Repeat salpingotomy ($n = 16$) or salpingectomy ($n = 18$)
Hoppe <i>et al.</i> ²⁷	19	Salpingotomy	Methotrexate

to be ethically acceptable. Indeed, this would constitute unnecessary treatment in more than 90% of cases. Administration of MTX is definitely the therapy of choice for persistent EP diagnosed by an insufficient decrease in hCG after salpingotomy.

OTHER MEDICAL TREATMENT ASSOCIATED WITH METHOTREXATE

Mifepristone is the first clinically effective antiprogesterone. It is already being used to induce first-trimester abortion. It has been used as treatment for ectopic pregnancy, but alone it has proved unsuccessful⁶¹.

Several other authors have investigated the possibility of adding mifepristone to MTX, with the aim of increasing the success rate of the medical treatment of extrauterine pregnancy^{52,53}. In their non-randomized phase II study, Perdu *et al.*⁵² have reported a significantly lower failure rate in patients treated with both mifepristone and MTX than in patients treated by MTX alone. In another study, Gazvani *et al.*⁵³ investigated the interval to resolution of β -hCG levels in unruptured ectopic pregnancies treated by MTX and mifepristone, or by MTX alone. It appeared that the interval to resolution of β -hCG was significantly shorter when both medications were used together.

Rozenberg *et al.*⁵⁴ have compared, in a large randomized multicenter study, the efficacy of MTX and mifepristone (600 mg given orally) versus MTX and a placebo as treatment for ectopic pregnancy. They failed to demonstrate any benefit of the addition of mifepristone to MTX (success rate 79.6% in the mifepristone group and 74.2% in the placebo group; $p = 0.41$). They only found a benefit in adding mifepristone to MTX when the progesterone level was ≥ 10 ng/l (success rate 83.3% in the mifepristone group and 38.5% in the placebo group).

In conclusion, at the moment, there is no evidence that mifepristone should be added to MTX for the treatment of extrauterine pregnancy.

PROGNOSIS FOR FUTURE FERTILITY

Postoperative fertility after linear salpingotomy

In a review in 1994³⁸, Donnez and Nisolle observed an intrauterine pregnancy rate of 57% and a recurrent EP rate of 16% after linear salpingotomy (Table 14.5).

In a series of 120 patients without any history of infertility who wished to become pregnant, an intrauterine pregnancy rate of 54% was achieved (Table 14.6). The recurrent tubal pregnancy rate after laparoscopy was similar to that obtained in another series of 148 patients who underwent conservative surgery (linear salpingotomy) by laparotomy (8% in both groups). Among patients with a history of microsurgical tuboplasty, the postoperative intrauterine pregnancy rate was significantly lower ($p < 0.005$) than that obtained in the group of patients without a history of infertility (27% vs. 54%). The recurrent tubal pregnancy rates were also significantly different ($p < 0.005$; 22% vs. 8%). Similar data were obtained from the group of patients who underwent a conservative approach using laparotomy.

Among patients with a single tube, the review by Donnez and Nisolle in 1994³⁸ revealed an intrauterine pregnancy rate of 51% and a recurrent tubal pregnancy rate of 22%. In another review by Yao and Tulandi⁵⁵ of a series of 1514 women, the intrauterine pregnancy rate was 61.4%, with a 15.4% risk of recurrent EP. Linear salpingotomy seems to result in a higher rate of subsequent

Table 14.5 Pregnancy rates following linear salpingotomy for ectopic pregnancy in women desiring to become pregnant. From reference 38

<i>Laparoscopy</i>	<i>Number of patients</i>	<i>Intrauterine pregnancy (n (%))</i>	<i>Ectopic pregnancy (n (%))</i>
Pouly <i>et al.</i> ³³	118	75 (64)	26 (22)
Donnez and Nisolle ⁴⁰	138	70 (51)	14 (10)
Total	256	145 (57)	40 (16)

Table 14.6 Postoperative fertility after conservative management of ectopic pregnancy. Comparison of laparotomy vs. laparoscopy. From references 38 and 40

	<i>Number of patients</i>	<i>Intrauterine pregnancy (n (%))</i>	<i>Ectopic pregnancy (n (%))</i>
<i>Laparotomy</i>			
No history of infertility	148	92 (62)	12 (8)
After microsurgical tuboplasty	64	19 (30)	13 (20)
Total	212	111 (52)	25 (12)
<i>Laparoscopy</i>			
No history of infertility	120	65 (54)	10 (8)
After microsurgical tuboplasty	18	5 (27)*	4 (22)*
Total	138	70 (51)	14 (10)

* $p < 0.005$, significantly different from the group of women without any history of infertility

intrauterine pregnancy than either total or partial salpingectomy. However, the more favorable reproductive outcome may, in part, reflect a selection bias, since linear salpingotomy was performed in the case of unruptured gestation, whereas salpingectomy was usually performed in the case of ruptured ectopic gestation. The advantage of conservative surgery over radical surgery is clear when treating ectopic gestations, when there is only one tube. In these cases, a conservative approach is the only one that preserves reproductive potential. Although tubal rupture seriously affects the immediate health of the women concerned, it seems to have no independent effect on subsequent fertility⁵⁵.

Is medical or surgical treatment better for subsequent fertility?

In 1998, Fernandez *et al.*⁹ published a study comparing MTX injected transvaginally, or administered intramuscularly, with laparoscopic salpingotomy, and concluded: ‘Spontaneous reproductive performance was similar in both groups, but overall intrauterine pregnancy was higher, and repeat EP lower, after methotrexate treatment. The difference was not, however, statistically significant.’

More recently, Gervaise *et al.*⁵⁶ (Fernandez’ team) reported the reproductive outcomes in women previously treated with MTX for ectopic pregnancy, who sought to become pregnant after this treatment. Out of 93 patients, 76 succeeded (81.7%). The cumulative pregnancy rate was 75.5% after 1 year and 66.9% after 2 years. The cumulative EP rate was 15.4% after 1 year and 23% after 2 years. In the authors’ opinion, previous history of infertility was the only factor associated with poor reproductive performance.

Do ruptured EPs have an adverse effect on subsequent pregnancies?

Job-Spira *et al.*⁵⁷ concluded, in their study in 1999, that there was no decrease in the rate of intrauterine pregnancy in the year following treatment, except if the woman was over 35 years of age, had a previous history of infertility or had previous tubal damage (all factors that were present before the rupture).

Conclusion

The patient’s history is the essential prognostic factor for future fertility⁵³. Careful examination of the contralateral tube should be carried out, at the time of laparoscopy,

because fertility after ectopic pregnancy is affected much more by the status of the contralateral tube than by the procedure performed, with fertility rates exceeding 80% after salpingectomy when the opposite tube is normal⁵⁸.

REFERENCES

1. Stovall TG, Ling FW, Buster JE. Outpatient chemotherapy of unruptured ectopic pregnancy. *Fertil Steril* 1989; 51: 535–8
2. Stovall TG, Ling FW, Gray LA, et al. Methotrexate treatment of unruptured ectopic pregnancy: a report of 100 cases. *Obstet Gynecol* 1991; 77: 749–53
3. Hitara AJ, Soper DE, Bump RC, et al. Ectopic pregnancy in an urban teaching hospital: can tubal rupture be predicted? *South Med J* 1991; 84: 1467–9
4. Mol BWJ, Hajenius PJ, Engelsbel S, et al. Can noninvasive diagnosis tools predict tubal rupture or active bleeding in patients with tubal pregnancy? *Fertil Steril* 1999; 71: 167–73
5. Fernandez H, Lelaidier C, Thouvenez V, et al. The use of a pretherapeutic predictive score to determine inclusion criteria for the non-surgical treatment of ectopic pregnancy. *Hum Reprod* 1991; 6: 995–8
6. Fernandez H, Lelaidier C, Baton C, et al. Return of reproductive performance after expectant management and local treatment for ectopic pregnancy. *Hum Reprod* 1991; 6: 1474–7
7. Fernandez H, Benifla JL, Lelaidier C, et al. Methotrexate treatment of ectopic pregnancy: 100 cases treated by primary transvaginal injection under sonographic control. *Fertil Steril* 1993; 59: 773–7
8. Fernandez H, Bourget P, Ville Y, et al. Treatment of unruptured tubal pregnancy with methotrexate: pharmacokinetic analysis of local versus intramuscular administration. *Fertil Steril* 1994; 62: 943–7
9. Fernandez H, Cappella-Allouc S, Vincent Y, et al. Randomized trial of conservative laparoscopic treatment and methotrexate administration in ectopic pregnancy and subsequent fertility. *Hum Reprod* 1998; 13: 3239–43
10. Tanaka T, Hayashi H, Kutsuzawa T, et al. Treatment of interstitial ectopic pregnancy with methotrexate: report of a successful case. *Fertil Steril* 1982; 37: 851–2
11. Pansky M, Bukovsky J, Golan A, et al. Reproductive outcome after laparoscopic local methotrexate injection for tubal pregnancy. *Fertil Steril* 1993; 60: 85–7
12. Lipscomb GH, McCord ML, Stovall TG, et al. Predictors of success of methotrexate treatment in women with tubal ectopic pregnancy. *N Engl J Med* 1999; 341: 1974–8
13. Henry MA, Gentry WL. Single-injection of methotrexate for treatment of ectopic pregnancies. *Am J Obstet Gynecol* 1994; 171: 1584–7
14. Hajenius P, Engelsbel S, Mol B, et al. Randomised trial of systemic methotrexate versus laparoscopic salpingostomy in tubal pregnancy. *Lancet* 1997; 350: 774–9
15. Thoen LD, Creinin MD. Medical treatment of ectopic pregnancy with methotrexate. *Fertil Steril* 1997; 68: 727–30
16. Stika CS, Anderson L, Frederiksen MC. Single-dose methotrexate for the treatment of ectopic pregnancy: Northwestern Memorial Hospital three-year experience. *Am J Obstet Gynecol* 1996; 174: 1840–8
17. Corsan GH, Karacan M, Qasim S, et al. Identification of hormonal parameters for successful systemic single-dose methotrexate therapy in ectopic pregnancy. *Hum Reprod* 1995; 10: 2719–22
18. Schafer D, Kryss J, Pfuhl J, et al. Systemic treatment of ectopic pregnancies with single-dose methotrexate. *J Am Assoc Gynecol Laparosc* 1994; 1: 213–18
19. Saraj AJ, Wilcox JG, Najmabadi S, et al. Resolution of hormonal markers of ectopic gestation: a randomized trial comparing single-dose intramuscular methotrexate with salpingostomy. *Obstet Gynecol* 1998; 92: 989–94
20. Lecuru F, Robin F, Bernard JP, et al. Single-dose methotrexate for unruptured ectopic pregnancy. *Int J Gynaecol Obstet* 1998; 61: 253–9
21. Glock JL, Johnson JV, Brumsted JR. Efficacy and safety of single-dose systemic methotrexate in the treatment of ectopic pregnancy. *Fertil Steril* 1994; 62: 716–21
22. Morlock RJ, Lafata JE, Eisenstein D. Cost-effectiveness of single-dose methotrexate compared with laparoscopic treatment of ectopic pregnancy. *Obstet Gynecol* 2000; 95: 407–12
23. Vermesh M, Silva PD, Rosen GF, et al. Management of unruptured ectopic gestation by linear salpingostomy: a prospective randomized clinical trial of laparoscopy versus laparotomy. *Obstet Gynecol* 1989; 73: 400–4
24. Yao M, Tulandi T, Falcone T. Treatment of ectopic pregnancy by systemic methotrexate, transvaginal methotrexate, and operative laparoscopy. *Int J Fertil* 1996; 41: 470–5
25. Tan H, Tay S. Laparoscopic treatment of ectopic pregnancies – a study of 100 cases. *Ann Acad Med Singapore* 1996; 25: 665–7
26. Shalev E, Peleg D, Bustan M, et al. Limited role for intratubal methotrexate treatment of ectopic pregnancy. *Fertil Steril* 1995; 63: 20–4
27. Hoppe DE, Bekkar BE, Nager CW. Single-dose systemic methotrexate for the treatment of persistent ectopic pregnancy after conservative surgery. *Obstet Gynecol* 1994; 83: 51–4
28. Seifer DB, Gutmann JN, Grant WD, et al. Comparison of persistent ectopic pregnancy after laparoscopic salpingostomy versus salpingostomy at laparotomy for ectopic pregnancy. *Obstet Gynecol* 1993; 81: 378–82
29. Lundorff P, Hahlin M, Sjoblom P, et al. Persistent trophoblast after conservative treatment of tubal pregnancy: prediction and detection. *Obstet Gynecol* 1991; 77: 129–33

30. Letterie GS, Fasolak WS, Miyazowa K. Laparoscopy and minilaparotomy as operative management of ectopic pregnancy. *Mil Med* 1990; 155: 305–7
31. Mecke H, Semm K, Lehmann-Willenbrock E. Results of operative pelviscopy in 202 cases of ectopic pregnancy. *Int J Fertil* 1989; 34: 93–100
32. DeCherney AH, Diamond MP. Laparoscopic salpingostomy for ectopic pregnancy. *Obstet Gynecol* 1987; 70: 948–50
33. Pouly JL, Manhes H, Mage G, et al. Conservative laparoscopic treatment of 321 ectopic pregnancies. *Fertil Steril* 1986; 46: 1093–7
34. Bruhat MA, Manhes H, Mage G, et al. Treatment of ectopic pregnancy by means of laparoscopy. *Fertil Steril* 1980; 33: 411–14
35. Jimenez-Caraballo A, Rodriguez-Donoso G. A 6-year clinical trial of methotrexate therapy in the treatment of ectopic pregnancy. *Eur J Obstet Gynecol* 1998; 79: 167–71
36. Lipscomb GH, Bran D, McCord ML, et al. Analysis of three hundred and fifteen ectopic pregnancies treated with single-dose methotrexate. *Am J Obstet Gynecol* 1998; 178: 1354–8
37. Stovall TG, Ling FW. Single-dose methotrexate: an expanded clinical trial. *Am J Obstet Gynecol* 1993; 168: 1759–65
38. Donnez J, Nisolle M. Postoperative management and reproductive outcome after conservative laparoscopic procedures. In Donnez J, Nisolle M, eds. *An Atlas of Laser Operative Laparoscopy and Hysteroscopy*. Carnforth, UK: Parthenon Publishing, 1994: 131–44
39. Lipscomb GH, Stovall TG, Ling FW. Nonsurgical treatment of ectopic pregnancy. *N Engl J Med* 2000; 343: 1325–9
40. Donnez J, Nisolle M. Laparoscopic treatment of ampullary tubal pregnancy. *J Gynecol Surg* 1989; 5: 19–24
41. Donnez J. Conservative treatment of ectopic pregnancy. A first series of 50 cases. *Acta Endosc* 1982; 4: 62
42. Rivlin ME, Meeks GR, Cowan BD, et al. Persistent trophoblastic tissue following salpingostomy for unruptured ectopic pregnancy. *Fertil Steril* 1985; 43: 323–4
43. Rivlin ME. Persistent ectopic pregnancy: complication of conservative surgery. *Int J Fertil* 1985; 30: 12–14
44. Cartwright PS, Herbert CM, Mawson WS. Operative laparoscopy for the management of tubal pregnancy. *J Reprod Med* 1986; 31: 589–91
45. DiMarchi JM, Losasa TS, Kobara TY, et al. Persistent ectopic pregnancy. *Obstet Gynecol* 1987; 70: 555–9
46. Cartwright PS, Etmann SS. Repeat ipsilateral tubal pregnancy following partial salpingectomy: a case report. *Fertil Steril* 1984; 42: 647–8
47. Spandorfer SD, Sawin SW, Benjamin I, et al. Postoperative day 1 serum human chorionic gonadotropin level as a predictor of persistent ectopic pregnancy after conservative surgical management. *Fertil Steril* 1997; 63: 430–4
48. Hagstrom HG, Hahlin M, Bennegard-Eden B, et al. Prediction of persistent ectopic pregnancy after laparoscopic salpingostomy. *Obstet Gynecol* 1994; 84: 798–802
49. Kemmann E, Trout S, Garcia A. Can we predict patients at risk for persistent ectopic pregnancy after laparoscopic salpingotomy? *J Am Assoc Gynecol Laparosc* 1994; 1: 122–6
50. Graczykowski JW, Mishell DR Jr. Methotrexate prophylaxis for persistent ectopic pregnancy after conservative treatment by salpingostomy. *Obstet Gynecol* 1997; 89: 118–22
51. Paris FX, Henry-Suchet J, Tesquier L, et al. The value of antiprogestosterone steroid in the treatment of extra-uterine pregnancy. Preliminary results. *Rev Franc Gynecol Obstet* 1986; 81: 33–5
52. Perdu M, Camus E, Rozenberg P, et al. Treating ectopic pregnancy with the combination of mifepristone and methotrexate: a phase II non-randomized study. *Am J Obstet Gynecol* 1998; 179: 640–3
53. Gazvani MR, Baruah DN, Alfirevic Z, Emery SL. Mifepristone in combination with methotrexate for the medical treatment of tubal pregnancy: a randomized, controlled trial. *Hum Reprod* 1998; 13: 1987–90
54. Rozenberg P, Chevret S, Camus E, et al. Medical treatment of ectopic pregnancies: a randomized clinical trial comparing methotrexate–mifepristone and methotrexate–placebo. *Hum Reprod* 2003; 18: 1802–8
55. Yao M, Tulandi T. Current status of surgical and nonsurgical management of ectopic pregnancy. *Fertil Steril* 1997; 67: 421–33
56. Gervaise A, Masson L, de Tayrac R, et al. Reproductive outcome after methotrexate treatment of tubal pregnancies. *Fertil Steril* 2004; 82: 304–8
57. Job-Spira N, Fernandez H, Bouyer J, et al. Ruptured tubal ectopic pregnancy: risk factors and reproductive outcome: results of a population-based study in France. *Am J Obstet Gynecol* 1999; 180: 938–44
58. Rulin MC. Is salpingostomy the surgical treatment of choice for unruptured tubal pregnancy? *Obstet Gynecol* 1995; 86: 1010–13

akusher-lib.ru

The laparoscopic management of ectopic pregnancy

J L Pouly, G Mage, M Canis, B Rabischong, R Botroschvili, C Jardon

In 2006, the surgical management of ectopic pregnancy should be carried out using laparoscopy. The place of laparotomy is limited to rare cases of extremely severe, acute rupture when no competent laparoscopic surgeon is available.

In this chapter we discuss in turn the technical aspects of the various techniques, the indications for surgical treatment and the influence of choice of treatment on the subsequent results.

TECHNICAL ASPECTS

The laparoscopic conservative treatment of ectopic pregnancy was reported by Manhes and Bruhat more than 25 years ago^{1,2}. Some improvements to the initial technique were made in the 1980s³. Since then, the technique has not been substantially modified.

The first report of the radical procedure was published by Dubuisson *et al.* in 1987⁴. It has not been greatly modified since then.

In the following section we underline some aspects of the operative technique used to prevent the risk of complications.

Conservative treatment

The various steps of the conservative treatment are shown in Figures 15.1–15.10.

Despite some descriptions of success, 'milking' of the tube must be avoided in all cases where a hematosalpinx is found. In our first publications, we emphasized that 'milking' was complicated by persistent trophoblast in 25% of cases, versus 5% when a salpingotomy was performed². Twenty-five years later, this position has not changed, and explains partially the high failure rate reported in some series.

The salpingotomy must be as non-traumatic as possible. Scissors section, CO₂ laser section or monopolar electrosection are the best methods, although there are no data to support one above another. The most common technique is monopolar electrosection, because it is the easiest and cheapest method. The crucial point is to avoid large coagulation of the tubal wall, which can lead to a tuboperitoneal fistula. Therefore, it must be achieved with a fine electrode and a cutting current. The electrode must not be pressed on the tube, but rather should just touch it slightly to increase the power density. The speed of movement along the incision must be sufficiently fast to

maximize the cutting effect and limit the collateral coagulation. Bipolar coagulation is forbidden for this step.

The salpingotomy must be carried out at the internal part of the hematosalpinx. The trophoblast is located there, and the distal part contains generally only clots.

Aspiration of the trophoblast must be performed with a suction device that is at least 7 mm in internal diameter. With a narrower device, the risk of partial removal of the trophoblast increases. The high rate of failure in some

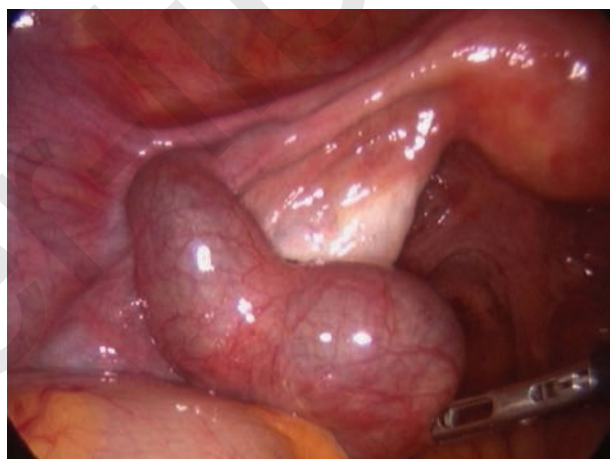

Figure 15.1 Exposure of an unruptured ampullar left ectopic pregnancy

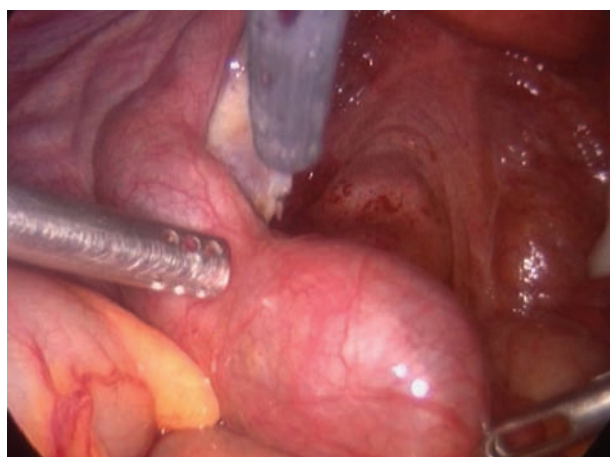


Figure 15.2 A forceps, a monopolar electrode and a suction device are introduced into the abdomen

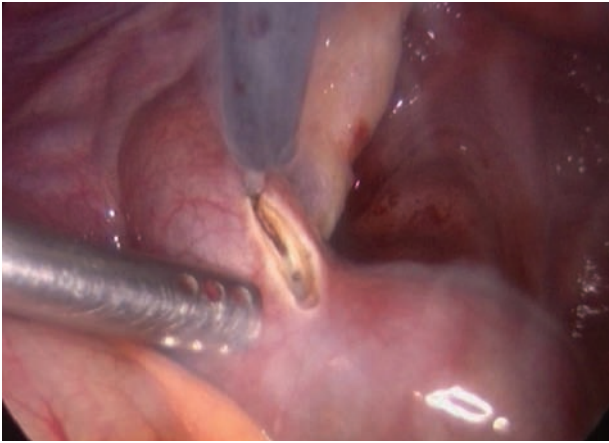


Figure 15.3 The salpingostomy is performed at the proximal part of the hematosalpinx

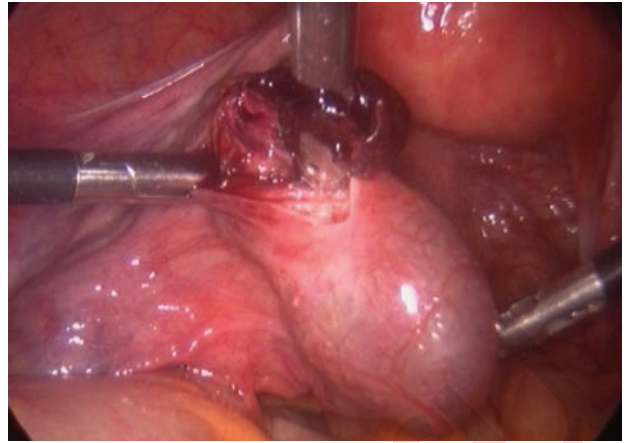


Figure 15.6 The robust, large suction device permits removal of the trophoblast through gentle and progressive traction

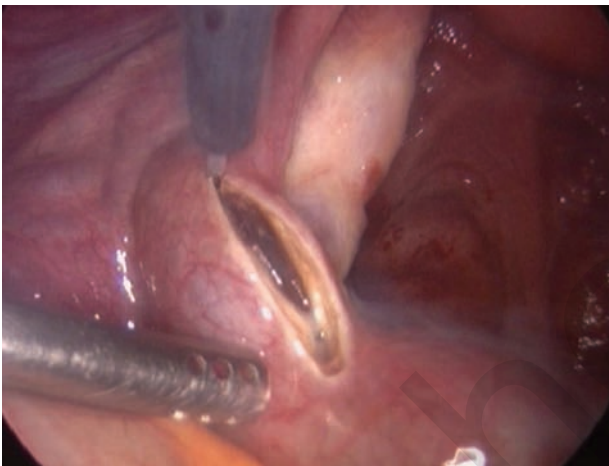

Figure 15.4 The salpingostomy is completed

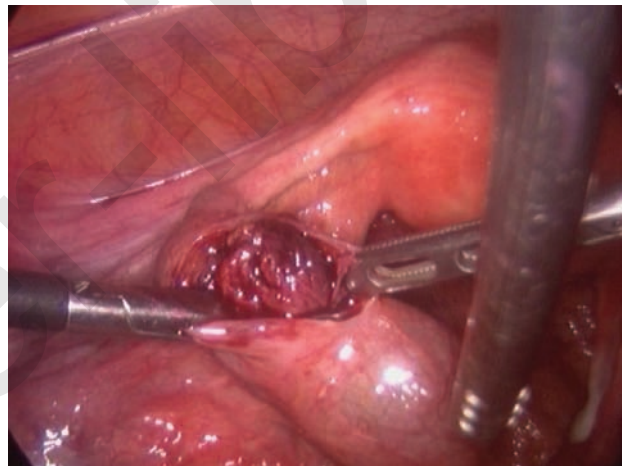


Figure 15.7 Manipulation of the tube reveals that part of the trophoblast is still in place

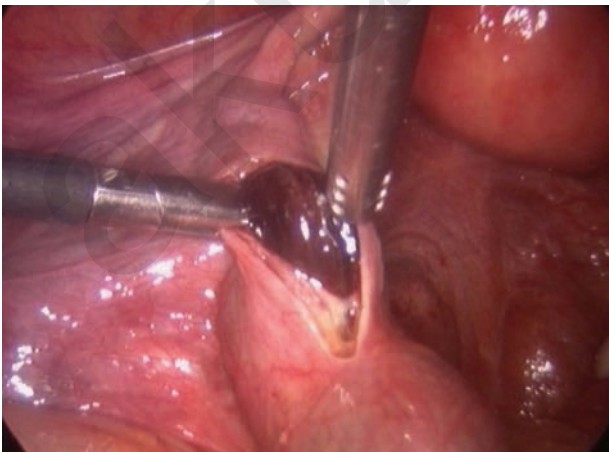


Figure 15.5 The suction device is introduced into the tube

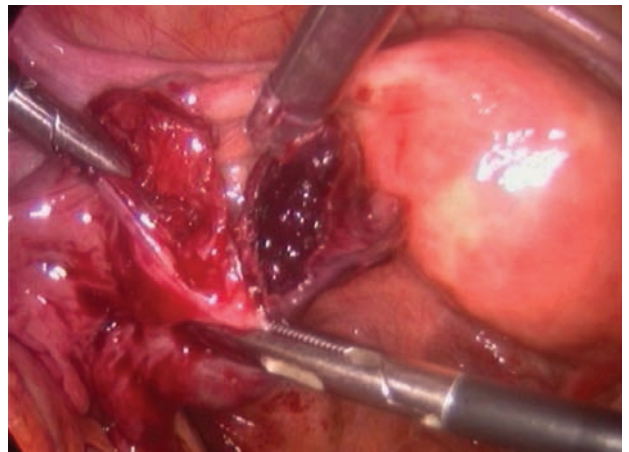


Figure 15.8 A repeat suction is performed

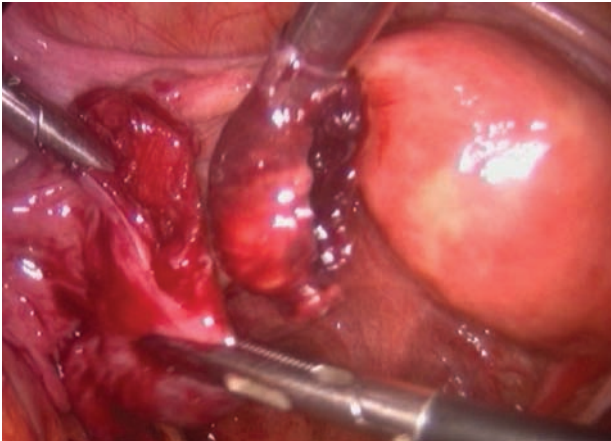


Figure 15.9 The second suction has allowed the trophoblast to be removed completely

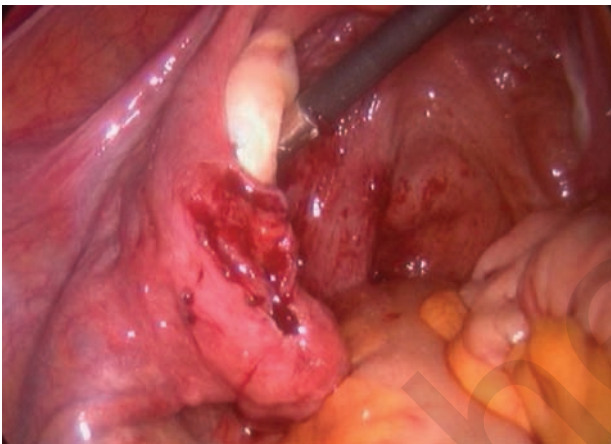

Figure 15.10 This minimal bleeding does not require further hemostasis and coagulation. The abdominal cavity must simply be washed

series is largely explained by the use of inefficient suction devices. Our initial study led to this conclusion, and to the development of a special device (Triton)³.

The tube must be washed and explored to ensure complete removal of the trophoblast. It appears as a white tissue that can be removed using repeated suction or by grasping it gently with forceps.

Complete hemostasis of the tube is unnecessary or even deleterious. If no vasoconstrictive drugs are used, the bleeding generally comes from the trophoblast implantation area. Bipolar electrocoagulation, used to achieve hemostasis, leads to large destruction of the tube, and is not efficient. Generally, the bleeding stops by itself after 5–10 minutes. In the case of severe bleeding, removal of the tube must be considered, but only after mechanical compres-

sion of the mesosalpinx for at least 5 minutes. A preventive injection of vasoconstrictive drugs (Pitressin[®], ornithine-vasopressin) is an elegant and efficient alternative when permitted³.

The salpingotomy must not be sutured. In the initial study³, suturing was not performed for technical reasons. Later on, it was proved that suturing the tube increases the risk for obstruction and decreases postoperative fertility⁵, and that the tubal scar quality is better without a suture.

Salpingectomy

In the initial study³, thermocoagulation was used. This has been replaced by bipolar or even monopolar coagulation. No data support a difference in the use of any of these technologies, even though bipolar cautery is generally considered to be less dangerous. There is no difference in the direction of the salpingectomy: it can be carried out from the isthmus to the infundibulopelvic ligament or vice versa.

Extraction of the tubes from the abdominal cavity must be done in an endobag or through a culdotomy, rather than pulling the tube through a trocar incision.

CONTRAINDICATIONS TO LAPAROSCOPIC TREATMENT

There are few contraindications to laparoscopic treatment, but they differ for salpingectomy and salpingostomy.

Salpingectomy

Laparoscopic salpingectomy is rarely contraindicated. Acute bleeding with shock is not a contraindication for experienced personnel. Control of the hemodynamic pattern is as efficient during laparoscopy as during laparotomy. The patient must be quickly insufflated, the trocars set up and the uterus cannulation put in place. As soon as the optic is introduced, the patient is put in an accentuated Trendelenburg position. The tube is located eventually with the help of blood aspiration; then, bipolar coagulation of the tube either at the site of the ectopic pregnancy or away from the ectopic pregnancy is done in order to achieve hemostasis. Thereafter, salpingectomy is carried out normally. This procedure must be performed rapidly by a trained laparoscopist and nurse and an anesthesiologist.

The two main contraindications are interstitial pregnancies and massive adhesions.

In the first case, the ectopic pregnancy cannot be removed through a simple salpingectomy, and medical treatment must be considered, rather than a cornual resection. In the second case, to achieve a salpingectomy can require extensive and potentially dangerous adhesiolysis, and it can be safer to perform a salpingostomy if the hematosalpinx is visible.

Salpingostomy

The contraindications to salpingostomy are generally relative. Interstitial pregnancy must be considered as a contraindication because the incision can be followed by an acute hemorrhage which may be difficult to control. Massive bleeding with tubal rupture is a relative contraindication because it can be impossible to stop the bleeding without salpingectomy.

The other contraindications are associated with the risk of persistent trophoblast:

- Hematosalpinx larger than 4 cm
- High human chorionic gonadotropin (hCG) level (> 10 000 IU)
- Ectopic pregnancy with a living fetus

POSTOPERATIVE WORK-UP

Postoperative complications are rare, but include persistent trophoblast after conservative treatment. Secondary hemorrhages are exceptional.

The persistence of trophoblast is infrequent after salpingectomy (0.2%). It occurs in cases when the tube is milked during a 'transabdominal wall' or 'trans-trocar' extraction. Part of the trophoblast drops back into the abdomen and implants. For this reason, one is advised to monitor the hCG level 1 week after surgery. This level must be less than 2% of the initial level.

After salpingotomy, this risk is greater. The incidence differs largely from one series to another. In the Epidemiological Register for Ectopic Pregnancy in Auvergne (EREPA), the risk was less than 5%^{6,7}, but some series have reported risks at over 20%.

These failures occur for two different reasons. Poor operative technique explains largely the failures in the high-frequency series. This is the reason why we have underlined some of the technical aspects, such as the place of salpingostomy, the size of the aspiration device and the danger of 'milking'.

However, even with a perfect technique, a risk exists, related to deep infiltrating trophoblast in cases of active pregnancy. Hagström *et al.*⁸ demonstrated that a rapid kinetics of the hCG, a high hCG level and a high progesterone level are predictive of this risk of failure.

The early detection of a failure forms part of the treatment: the drop in hCG must be monitored. In 1992, we published a monitoring algorithm that is still up to date⁹. The relative hCG level must be measured on the second postoperative day and later if necessary. If it is still over 35% on the second day, failure is extremely probable, and subsequent treatment must be applied. Methotrexate (MTX) injection is the first option rather than a second laparoscopy, as it will solve the problem in more than 95% of cases.

SYSTEMATIC ADJUNCTION WITH METHOTREXATE

The risk of failure has led some authors to propose systematic adjunction with methotrexate (MTX, 50 mg) after any laparoscopic conservative treatment. Graczykowski and Mishell added systematically 1 mg of MTX/kg at the end of laparoscopy¹⁰. The failure rate in their series dropped from 14 to 1.9%.

Although these data are impressive, such a high failure rate without MTX is surprising. On the other hand, the potential risk of using MTX at this dose is limited, and it seems logical to add it in some cases where a risk of failure appears possible at the end of laparoscopy:

- High hCG level (> 5000 IU)
- High progesterone level (> 10 ng/ml)
- Difficulty in extraction of the trophoblast
- Ectopic pregnancy over 4 cm in diameter

In all other cases we think that postoperative monitoring by measuring the drop of hCG level permits the decision regarding complementary treatment to be made in a more logical manner.

INDICATIONS FOR CONSERVATIVE SURGICAL TREATMENT

As the gold-standard is laparoscopic conservative treatment, its indications must be discussed from two aspects:

- Versus salpingectomy
- Versus medical treatment

Versus salpingectomy

The main advantage of salpingectomy is the security and simplicity. The risk of failure is extremely low, and the technique does not require any special skill. The second theoretical advantage is a decrease in the risk of recurrence.

On the other hand, salpingectomy results in a decrease in post-ectopic fertility. Some publications have cast doubt on this point¹¹. In the following paragraph, we provide data that demonstrate that conservative treatment increases the chance for a subsequent pregnancy without increasing significantly the risk of recurrence.

Also, it is logical to propose an attempt at conservative treatment for all patients who still want to become pregnant.

The only exception is in the case of an ectopic pregnancy in a patient with a major history of tubal infertility (tubal surgery and/or repeated ectopics). In this case, the chance of an intrauterine pregnancy can be lower than the risk of a subsequent ectopic pregnancy. Then, salpingectomy with contralateral sterilization must be

proposed before referring such a patient to an *in vitro* fertilization (IVF) program.

Of course, radical treatment is also logical for patients who no longer desire to have children.

Versus medical treatment

This issue is far from being determined. In some cases, medical treatment is not available because of the risk of acute hemorrhage:

- In cases of hemoperitoneum
- In cases of fetal heartbeat
- In cases of large hematosalpinx (> 4 cm)

However, the main problem comes from the risk of medical treatment failures that are more frequent in the case of evolutive ectopic pregnancy. In these cases, MTX is unable to destroy the trophoblast. The difficulty is in defining the criteria¹². A high hCG level is a factor, but, according to the literature, the upper limit varies from 1000 to 5000 IU. The progesterone level is a second factor, but again the upper limit ranges from 5 to 20 ng. The debate is far from finished, but according to the level of contraindication, the risk of failure can vary largely from 15 to 40%. Moreover, the definition and the diagnosis of failure are both unclear. It is evident that there is a large overestimation of failures: a stable hCG level associated with pain, 5–7 days after injection of MTX, can lead to unnecessary laparoscopy. The absence of valuable data to predict the efficacy of MTX is still restrictive to use of this medical treatment on a large scale.

Some other factors can help in the decision: patients must agree to, and be able to have, a long follow-up, to receive medical treatment; in cases of ipsilateral recurrence it is more logical to perform salpingectomy.

In all other cases discussion is warranted, and the final decision is often the result of a balance between two aspects: avoidance of a surgical procedure and interest in exploring the status of the tubes.

RESULTS OF TREATMENT

The immediate postoperative results are discussed above, and we now focus on postoperative fertility^{13,14}.

Of course, the ideal situation would be to design some prospective, randomized series to answer the following questions:

- Which treatment offers the best chance of a subsequent intrauterine pregnancy?
- Which treatment exposes the woman to the highest risk of a further ectopic pregnancy?

A small number of randomized series have been published which partially answer these questions, but most of them are poorly designed or have low power owing to a limited number of cases.

We set up the EREPA (Epidemiological Register for Ectopic Pregnancy in Auvergne), which has now collected data from 2000 ectopic pregnancies over a 12-year period with a subsequent fertility follow-up. A multivariate analysis carried out using this large collection of data has permitted some interesting conclusions^{6,15}.

Among 741 patients wishing to become pregnant, with a 2–10-year follow-up, 501 (67.6%) presented with an intrauterine pregnancy without IVF. A multivariate analysis was carried out to evaluate the pattern of post-ectopic infertility. As previously demonstrated, fertility is largely dependent on the patient history. The relative risk (RR) of an intrauterine pregnancy, based on the treatment given, was 0.8 (95% confidence interval (CI) 0.6–0.9) after salpingectomy versus conservative treatment. After MTX, this RR was 1.1 (95% CI 0.8–1.5). The group was divided into two: 267 patients with other infertility factors (such as previous ectopic, tuboplasty, salpingitis, etc.) and 304 patients without. (Patients who had presented with ectopic pregnancy in association with the use of an intrauterine device were excluded from the study because of the excellent fertility results.) In the first subgroup, the RR was 0.68 (95% CI 0.48–1.0) after salpingectomy versus salpingotomy and 1.4 (95% CI 0.87–2.3) after MTX. In the subgroup without infertility factors the RR after salpingectomy was 0.93 (95% CI 0.64–1.4), and after MTX it was 0.92 (95% CI 0.55–1.6), versus salpingotomy. In our opinion, these data permit the conclusion that conservative treatment offers a better chance of intrauterine pregnancy than radical treatment, mainly among patients with a poor prognosis. This is not surprising. However, based on the second part of the study, it is tempting to conclude that in good-prognosis cases it makes no difference. In fact, it would be necessary to perform a 1000 cases per arm, randomized study to be able to demonstrate a difference. Again, it is tempting to justify salpingectomy based on these results.

Concerning MTX, this study does not permit a conclusion to be drawn, but suggests that the difference, if any, is small between surgical and medical conservative treatment.

The risk of recurrence was also investigated. The rate was 10.7% after salpingectomy, 12.1% after salpingotomy ($p = \text{not significant}$) and 20% after MTX ($p < 0.03$). These results confirm previous data that have demonstrated that a unilateral salpingectomy cannot prevent a recurrence. The highest risk of recurrence after MTX cannot be considered a definitive conclusion, according to the small number of cases and the absence of randomization.

Finally, there is strong evidence that the best treatment in order to prevent infertility is a conservative treatment that can be achieved by laparoscopy or by the injection of MTX. The prevention of recurrence requires a bilateral salpingectomy that can be proposed in high-risk cases that are also those with the lowest chance of obtaining an intrauterine pregnancy¹⁶.

CONCLUSION

There is really nothing new in laparoscopic treatment for ectopic pregnancy, but we wish to emphasize that strict respect of the operative procedure is the best guarantee to prevent persistent trophoblast after salpingostomy. The main discussion concerns the indications, mainly the relative indications, for laparoscopic salpingotomy and methotrexate treatment. To date, laparoscopic treatment remains the 'gold standard'.

REFERENCES

1. Bruhat M, Manhes H. Trial treatment of extra-uterine pregnancy during celioscopy. *Nouv Presse Med* 1977; 6: 2606
2. Bruhat MA, Manhes H, Mage G, Pouly JL. Treatment of ectopic pregnancy by means of laparoscopy. *Fertil Steril* 1980; 33: 411–14
3. Manhès H, Mage G, Pouly JL, et al. Améliorations techniques du traitement coelioscopiques de la grossesse extra-utérine. *Nouv Presse Med* 1983; 12: 1431–3
4. Dubuisson JB, Aubriot FX, Cardone V. Laparoscopic salpingectomy for tubal pregnancy. *Fertil Steril* 1987; 47: 225–8
5. Tulandi T, Guralnick M. Treatment of tubal ectopic pregnancy by salpingotomy with or without tubal suturing and salpingectomy. *Fertil Steril* 1991; 55: 53–5
6. Bouyer J, Fernandez H, Coste J, et al. Fertility after ectopic pregnancy: 10-year results in the Auvergne Registry. *J Gynecol Obstet Biol Reprod (Paris)* 2003; 32: 431–8
7. Seifer DB, Gutmann JN, Doyle MB, et al. Persistent ectopic pregnancy following laparoscopic linear salpingostomy. *Obstet Gynecol* 1990; 76: 1121–5
8. Hagström HG, Hahlin M, Bennegarg-Eden B, et al. Prediction of persistent ectopic pregnancy after laparoscopic salpingostomy. *Obstet Gynecol* 1994; 84: 798–802
9. Pouly JL, Chapron C, Wattiez A, et al. The drop in the level of hCG after conservative laparoscopic treatment of ectopic pregnancy. *J Gynecol Surg* 1992; 7: 211–17
10. Graczykowski JW, Mishell DR Jr. Methotrexate prophylaxis for persistent ectopic pregnancy after conservative treatment by salpingostomy. *Obstet Gynecol* 1997; 89: 118–22
11. Dubuisson JB, Morice P, Chapron C, et al. Salpingectomy – the laparoscopic surgical choice for ectopic pregnancy. *Hum Reprod* 1996; 11: 1199–203
12. Fernandez H, Lelaidier C, Thouvenez V, Frydman R. The use of a pretherapeutic, predictive score to determine inclusion criteria for the non-surgical treatment of ectopic pregnancy. *Hum Reprod* 1991; 6: 995–8
13. Pouly JL, Manhes H, Mage G, et al. Conservative laparoscopic treatment of 321 ectopic pregnancies. *Fertil Steril* 1986; 46: 1093–7
14. Soriano D, Yefet Y, Oelsner G, et al. Operative laparoscopy for management of ectopic pregnancy in patients with hypovolemic shock. *J Am Assoc Gynecol Laparosc* 1997; 4: 363–7
15. Bouyer J, Job-Spira N, Pouly JL, et al. Fertility following radical, conservative, surgical or medical treatment for tubal pregnancy: a population-based study. *Br J Obstet Gynaecol* 2000; 107: 714–21
16. Pouly JL, Chapron C, Wattiez A, et al. Multifactorial analysis of fertility following conservative laparoscopic treatment of ectopic pregnancies. *Fertil Steril* 1991; 56: 453–60
17. Thorburn J, Lundorff P, Lindblom B. Fertility after ectopic pregnancy evaluated in relation to background factors and surgical treatment. *Fertil Steril* 1988; 49: 595–601

Laparoscopic microsurgical tubal anastomosis

C H Koh

LAPAROSCOPIC MICROSURGERY: A NEW TOOL FOR CONTINUOUS MICROSURGERY

Laparoscopic microsurgery is a new discipline that synergizes the potential of classical microsurgery and laparoscopy. It can overcome the deficits inherent in each. With classical microsurgery, the delicate and precise surgery can only happen after laparotomy, retraction, packing and crude macro-adhesiolysis to bring the adnexae under the operating microscope, a situation responsible for *de novo* adhesions. On the other hand, the superior and atraumatic exposure obtainable by laparoscopy has often not been matched by delicate surgery, causing concern for irreparable tissue damage¹. These problems are well addressed by this new tool. In fact, as our experience and technique of laparoscopic microsurgery have evolved and improved, it is becoming evident that we are exceeding our surgical expectations, moving beyond 'new access, old technique'¹ into the era of what we would call 'new access, new technique'.

This is the technique of *continuous microsurgery*, only achievable via laparoscopy. Reproductive surgery can now be performed in ways that were not possible for either operative laparoscopy or classical microsurgery. In the performance of tubal anastomosis, one can be truly minimally interventionist, by omitting the use of retractors and packing, while the treatment of severe adhesions, endometriosis of the cul-de-sac and microsurgical repair of the ureters, for example, were not previously achievable under conditions of continuous microsurgery and minimal collateral trauma. With the further evolution of technology, this tool is poised for applications as yet unimagined.

INDICATIONS FOR LAPAROSCOPIC TUBAL ANASTOMOSIS

- Reversal of sterilization
- Mid-tubal block secondary to various pathology
- Tubal occlusion secondary to ectopic pregnancy treatment
- Salpingitis isthmica nodosa
- Failed tubal cannulation for proximal block
- Failed previous macrosurgical sterilization reversal

EQUIPMENT AND INSTRUMENT REQUISITES FOR LAPAROSCOPIC MICROSURGERY

Magnification, resolution and digital enhancement

Magnification of 25–40 times is essential to identify healthy mucosa and muscularis before anastomosis can be performed. For microsuturing, magnification at 10–15 times is adequate. We measure laparoscopic magnification by using a 20-inch (50-cm) monitor and determining the ratio of the size of the image on the monitor to actual life size. We call this the 'magnification factor of video laparoscopy'. With the current three-chip cameras available with zoom capability, magnification up to 40 times is achievable.

Magnification requires a correspondingly high resolution for it to be usable, and this is achieved by cameras and monitors capable of at least 800 lines of resolution. The three-chip camera is also indispensable for accurate color resolution. An 8-0 suture, which is 45 µm in diameter, is easily seen using such a video system.

To enhance contrast further, some companies have built digital enhancement into their cameras or as an add-on unit. This enhances small vessels and edge detail, thus improving discrimination. An extremely sensitive auto-iris built into the camera provides rapid control of illumination, avoiding the dreaded 'white-out' when the telescope is brought close to tissue. This is particularly important in microsuturing, as the telescope has to be panned in and out frequently during the case. We use the Storz three-chip camera which incorporates all the above features as standard.

Micro-instrumentation

Micro-instrumentation has been designed that allows laparoscopic microsuturing to be performed with precision and ease (Storz 'Koh Ultramicro Series'TM). This avoids the inefficiency and frustration caused by suture fraying and breakage and poor needle stability.

Special design elements include sand-blasted tips to reduce glare, atraumatic terminal serrations, jaw apposition without slippage of 8-0 suture, with a responsive and sensitive handle design.

Sutures and needles

A more rigid needle is necessary for laparoscopic microsutures than for classical microsurgery. Furthermore, it is often easier to insert the needle directly into tissue without the use of a counter-pressing grasper. To achieve this, the needle needs low-force penetration characteristics and superior rigidity. Suitable examples include the BV 175-6 needle swaged to 7-0 and 8-0 Prolene™ or a BV 130-5 needle swaged to 8-0 polypropylene (Ethalloy TruTaper needle; Ethicon). Another excellent needle we have used recently is the Surgipro™ 135-5 needle swaged to 8-0 polypropylene (US Surgical Corporation). Although black nylon would give better discrimination laparoscopically, the needle is not ideal. Plain Vicryl® is the most difficult to see laparoscopically and becomes limp when wet. Monofilament sutures tend not to fray and allow easier intracorporeal suturing.

Other equipment

Trocars

Reusable 3-mm trocars are available with the Ultramicro Series, or 5-mm trocars with rubber valves that allow 3-mm instruments to be used without reducers. Three-millimeter suction irrigators are available and provide a more suitable jet for microsurgery than the 5-mm counterparts.

Stents

These are not used as it can be traumatic to cannulate the distal Fallopian tube.

Uterine manipulator

The Rumi™ uterine manipulator (Cooper Surgical, USA), with its superior anteversion mechanism, is indispensable for tubal anastomosis as multiple permutations of uterine position can be obtained, thereby presenting the proximal tube at a favorable angle for microsutures. The lateral openings of the Rumi intrauterine tip facilitate retrograde chromopertubation. Uterine manipulators having a terminal opening tend to be lodged in the endometrium and cause intravasation of dye and a false diagnosis of a proximal block.

Energy

A 150-µm microneedle unipolar electrode (Storz 'Koh Ultramicro Series'™) is used for incision and dissection, powered from a low-voltage generator. Power settings of 15–20 W for cutting and 15 W for fulguration are adequate. When the mesenteric vasculature is inadvertently cut, causing more vigorous bleeding, a microbipolar electrode of 1-mm diameter is used.

PREREQUISITES OF THE SURGEON

The aspiring laparoscopic microsurgeon should be highly experienced in classical microsurgery and have highly developed two-handed laparoscopic skills for intracorporeal knotting. Extracorporeal techniques for 7-0 and 8-0 sutures are impractical and crude and cause 'cutting through', or disruption, of tissue.

TYPES OF ANASTOMOSIS

Isthmic–isthmic anastomosis

Although the lumen may be as small as 500 µm to 1 mm, equivalent luminal size and a thick muscularis allow a technically easier anastomosis, particularly if 8-0 suture is used.

Isthmic–ampullary anastomosis

Luminal disparity is a potential problem. Preliminary dissection of the serosa and visualization of the proximal stump make it possible to create a lumen only slightly larger than the proximal ostium.

Ampullary–ampullary anastomosis

The awkwardness in these cases is due to the thin muscularis and the tendency for prolapse or extrusion of the mucosal folds. The angled probe can be used to delineate the muscularis as well as push the redundant mucosa back into the lumen after tying the muscularis sutures.

Tube–cornual anastomosis

A linear slit at 12 o'clock is made in the cornual muscularis, using the microneedle electrode after Pitressin® injection. This allows some mobility of the interstitial tube so that it can be aligned to the needle and needleholder to effect suturing.

Selection of cases for the learning curve

The easiest cases for laparoscopic microsurgical anastomosis are mechanical sterilizations. The tissue damage is predictable and there is enough proximal and distal tube available with equivalent luminal sizes. In particular, the availability of proximal tube allows its mobilization to conform with the needle position whereas, with cornual anastomosis, extra steps are needed to mobilize the intramural tube and the suture placement may be inaccurate without a considerable amount of experience. Therefore, cases of electrosurgical sterilization, salpingitis isthmica nodosa and failed tubal cannulation are not suitable for anastomosis until the operator has performed more than 50 cases of isthmic anastomosis with good outcome. In this

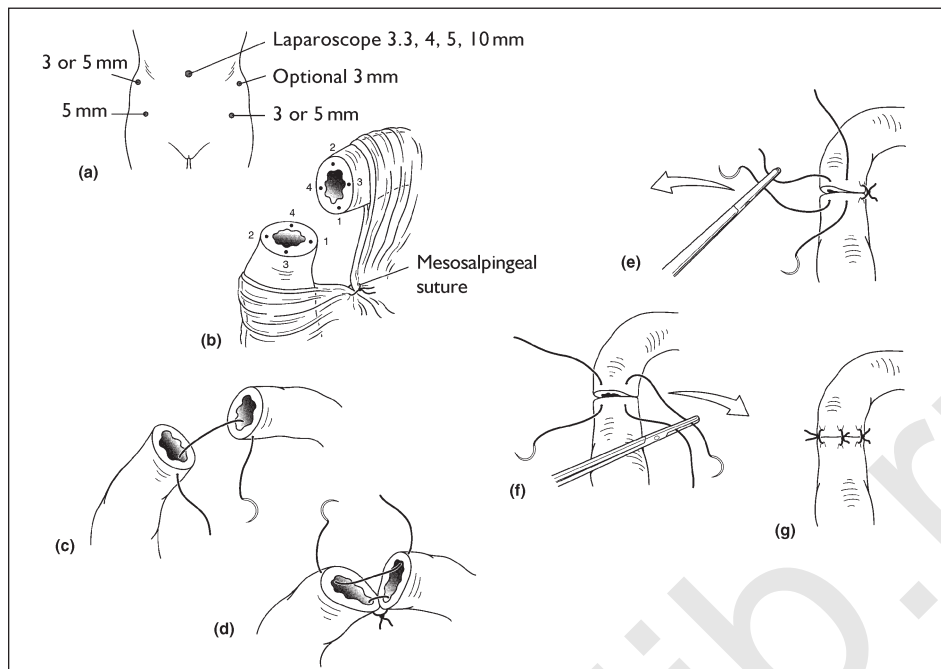


Figure 16.1 Surgical technique for anastomosis. (a) Placement of secondary ports; (b) suturing of the mesosalpinx; (c)–(g) suturing of the proximal tube to the distal tube

regard, a preoperative hysterosalpingogram may provide good prescreening.

SURGICAL TECHNIQUE

After insertion of a Foley catheter, the Rumi uterine manipulator with diagnostic tip is inserted into the uterus for mobilization. The intrauterine balloon is inflated with 3 ml saline. Dilute methylene blue is attached via a syringe to the chromopertubation port. After sterile preparation and draping, the trocars are inserted.

We employ the direct puncture technique using a 10-mm disposable trocar through the umbilical incision. After pneumoperitoneum has been created under direct visualization, the 3- or 5-mm secondary ports are then placed according to the position in the diagram (Figure 16.1a). The surgeon stands on the patient's right side.

Following this, the uterus is mobilized and anteverted and retroverted to inspect the pelvis. The lengths of the proximal and distal tubes are examined, as well as the condition of the fimbria. Any paratubal and periovarian adhesions are treated at this point, using the microelectrode. If all conditions are satisfactory for anastomosis, the operation proceeds.

The instruments described are all part of the complete Storz 'Koh Ultramicro Series'™ set.

The Pitressin injector is inserted through the right lower port and 1:30 dilute Pitressin is injected into the terminal serosa of the proximal tube, just enough to bulge

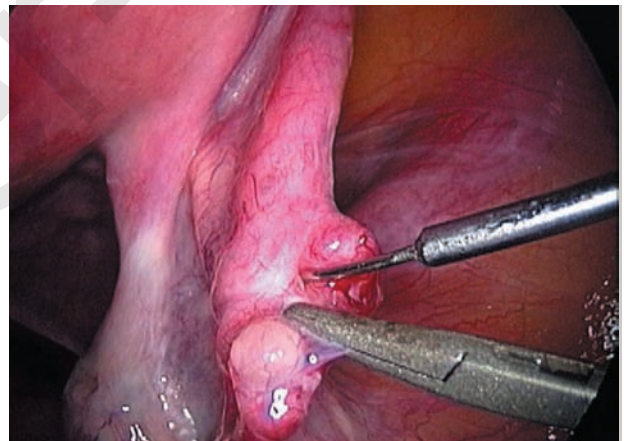


Figure 16.2 A grasper stabilizes the proximal tip of the tube. The surgeon circumscribes the serosa of the proximal tube

the serosa. Next, using the Ultramicro I grasper with his left hand to stabilize the tip of the tube, the operator introduces the microneedle electrode through the right lower port, to circumscribe the serosa of the proximal tube about 5 mm away from the tip (Figure 16.2). If the tubal length is generous and there is obvious bulbous dilatation of the tip, more tube can be sacrificed and the serosal cut would be 1 cm away from the tip. Following this, the microneedle is used to divide the tubal mesentery up to the chosen point for transection. By keeping this incision close to the tube, the mesosalpingeal vessels are not damaged and, therefore, do not require cautery, which may

compromise the blood supply to the Fallopian tube (Figure 16.3).

The guillotine is inserted into the right lower port and a right-angled cut is made of the proximal tube (Figure 16.4). Chromopertubation is performed retrogradely by means of the syringe attached to the Rumi uterine manipulator. When dye emerges freely from the proximal tube, the laparoscope is brought to within 1 cm of the tissue to examine the muscularis and the mucosa at 40 times magnification (Figure 16.5). Normal isthmic mucosa stains blue and exhibits three to four folds. The muscularis is found to be circular and non-fibrotic.

The proximal end of the distal tube is now held up and Pitressin is injected, via the right lower port, subserosally. Following this, the microelectrode is used to dissect and expose the proximal stump of the distal tube, which is regrasped using the Ultramicro II grasper at the very tip (Figure 16.6). At this point, the tubal lumen is compared with that of the proximal tube by using the straight chromopertubator, which has 1-mm markings along its tip.

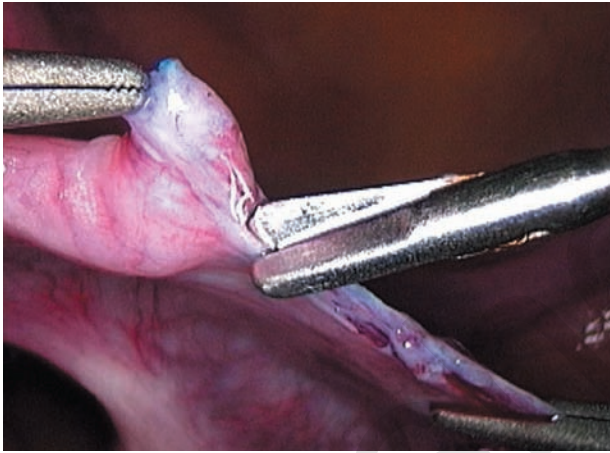

Figure 16.3 During dissection, care is taken to avoid damage to mesosalpingeal vessels

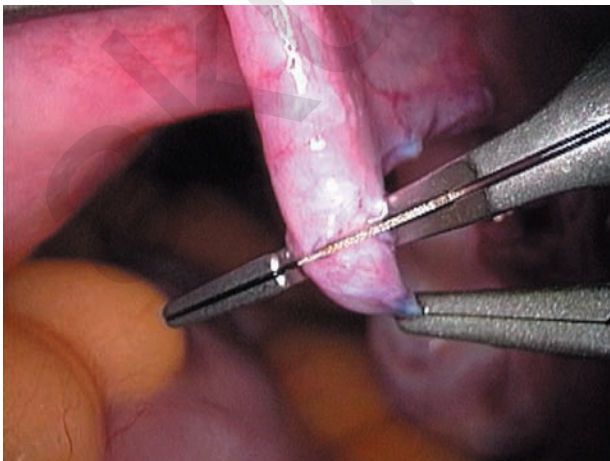


Figure 16.4 By using a guillotine, a right-angled cut is made of the proximal tube

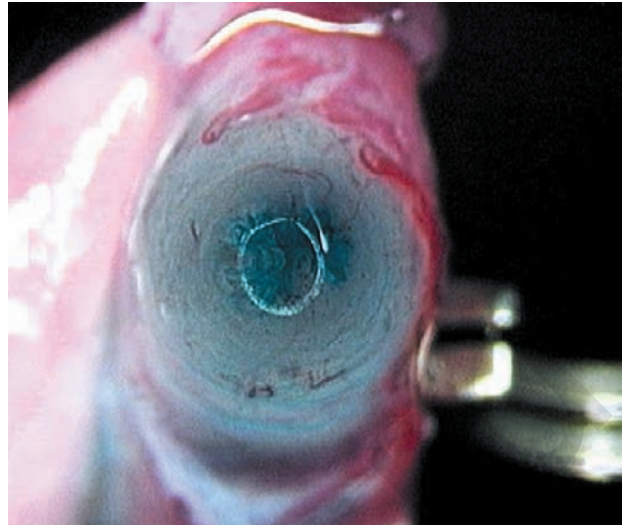


Figure 16.5 The laparoscope is brought to within 1 cm of the tissue to examine the muscularis and the mucosa at 40 times magnification

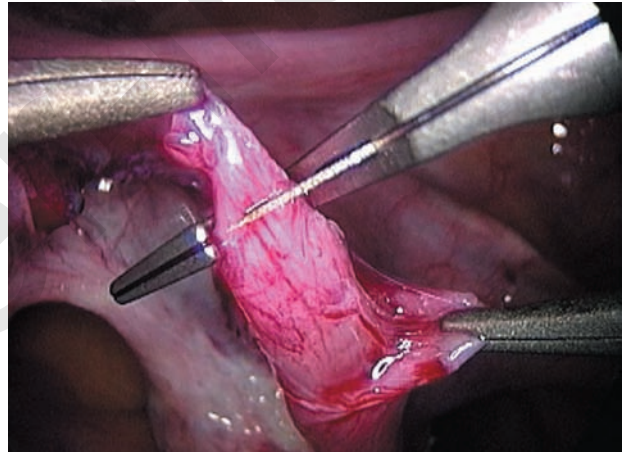


Figure 16.6 Dissection of the proximal end of the distal tube. The guillotine is also used to make a right-angled cut

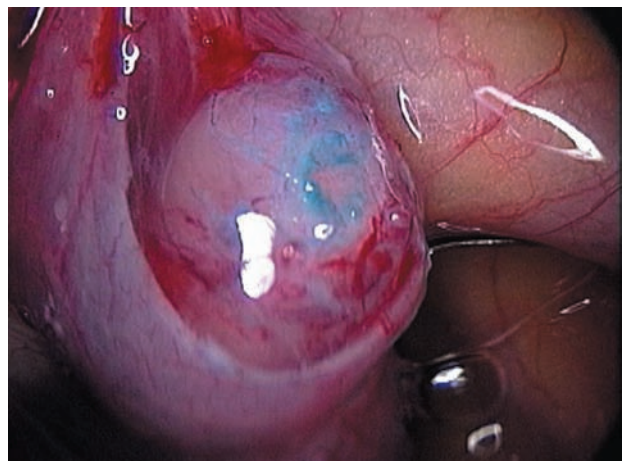


Figure 16.7 The aim is to obtain a distal lumen that is no more than 1 mm larger than the proximal stump

The aim is to obtain a distal lumen that is no more than 1 mm larger than the proximal stump (Figure 16.7).

The guillotine is then reintroduced to cut the distal stump. The curved chromopertubator is introduced to inject methylene blue dye through the proximal lumen, gently, to see that it emerges through the fimbria. When this has been achieved, it confirms patency of the distal tube without the need for cannulation, which is traumatic and difficult to achieve laparoscopically. The lumen is inspected to ensure that the size is adequate and, if not, further cuts are made with the guillotine. Pinpoint hemostasis is performed as necessary. Any redundant segment of Fallopian tube with attached loop or clip may now be removed using the unipolar electrode.

An 8-cm length of 6-0 polydioxanone (PDS) or Prolene is now introduced by holding the suture 2 cm from the needle with the Ultramicro needleholder through the right lower 5-mm port. A grasper (Ultramicro I) is introduced through the right upper quadrant with the operator's left hand. The needle is grasped by the grasper, oriented and then grasped by the needleholder. The mesosalpinx is sutured together using an intracorporeal knot, tying about 5 mm away from the Fallopian tube (Figure 16.8). Care should be taken not to approximate the mesosalpinx too near the tube as it will hinder subsequent anastomosis (Figure 16.1b).

A 6-cm length of 7-0 or 8-0 suture is now introduced in the same way as previously and the needle is positioned on the needleholder similarly. The Ultramicro II grasper is used in the left hand for this suture. Using clockwise rotation of the wrist, the muscularis at 6 o'clock on the distal tube is pierced, including the mucosa (Figure 16.9). The needle is then inserted at 6 o'clock of the proximal tube from mucosa through muscularis, again maintaining the clockwise motion of the wrist (Figure 16.1c). Intracorporeal knot-tying is performed, with three knots thrown (Figure 16.10). Facilitation with intracorporeal

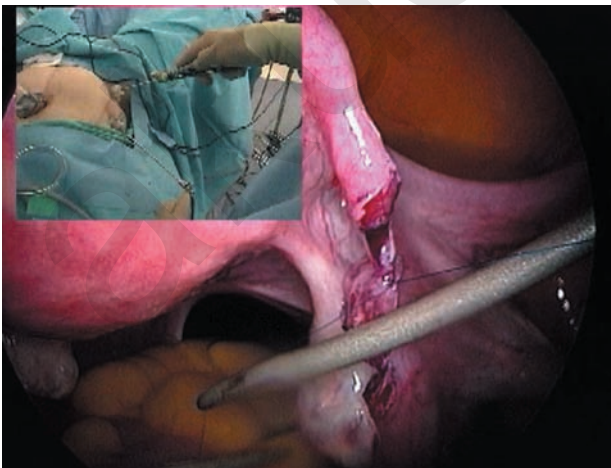


Figure 16.8 The mesosalpinx is sutured together using intracorporeal knot-tying about 5 mm away from the Fallopian tube

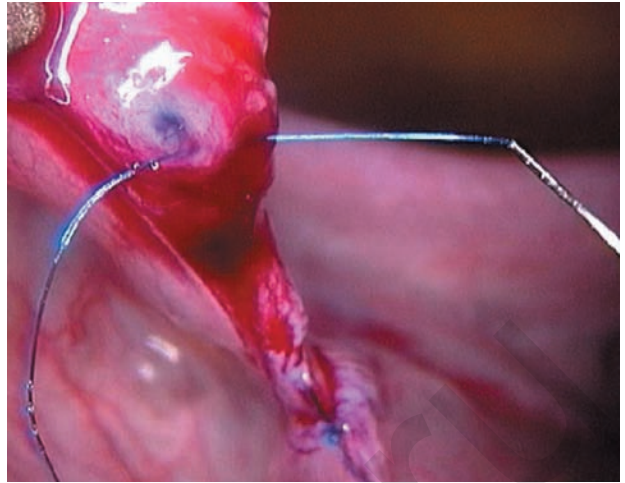


Figure 16.9 Using a 6-cm length of 7-0 or 8-0 suture, the muscularis at 6 o'clock on the distal tube is pierced, including the mucosa

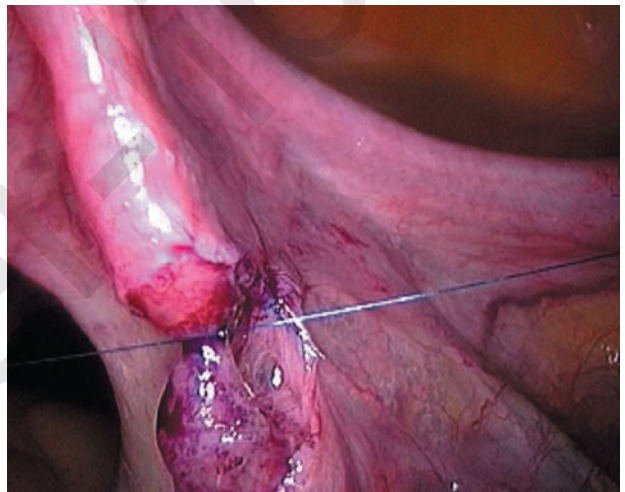


Figure 16.10 Intracorporeal knot-tying is performed

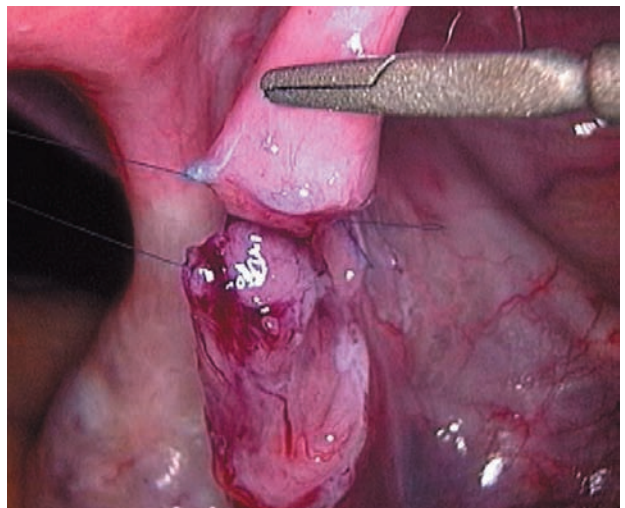


Figure 16.11 Another 7-0 or 8-0 suture is placed at 12 o'clock

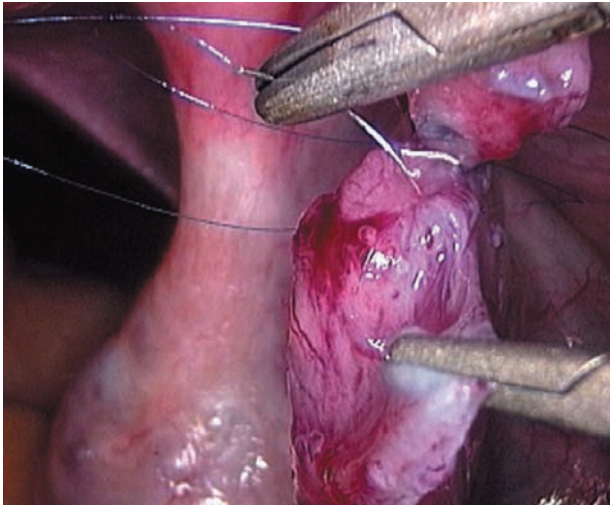


Figure 16.12 Using the Ultramicro II grasper, one is able to rotate the tube so that both the 3 and 9 o'clock positions become available for accurate suture placement

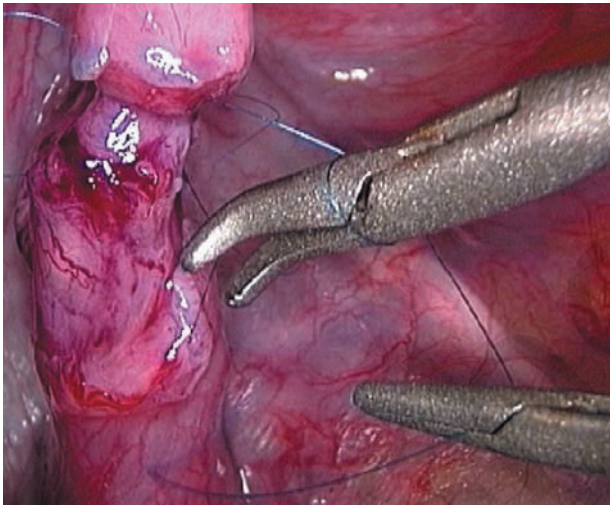


Figure 16.13 The 3 o'clock suture

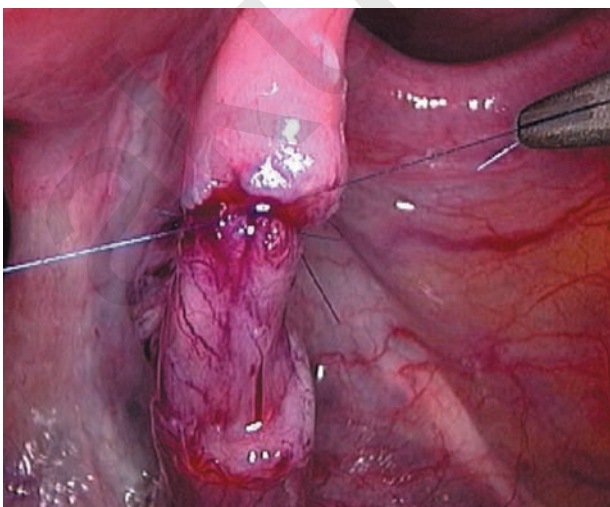


Figure 16.14 Finally, the 12 o'clock suture is tied

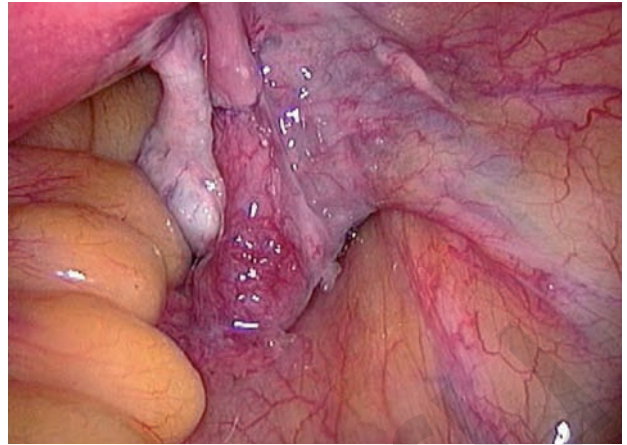


Figure 16.15 The 6-0 Prolene™ is then used to place one or two interrupted serosal sutures which may incorporate the outer muscularis to maintain support of the anastomosis

knitting can be achieved using a curved Ultramicro II grasper. The suture is then cut precisely using the Ultramicro suture scissors. Another 7-0 or 8-0 suture (Figure 16.11) is placed at 12 o'clock of the proximal tube from muscularis to submucosa or mucosa and then to the 12 o'clock position of the distal tube with the needle entering from mucosa/submucosa through muscularis (Figure 16.1d). This suture is now held by the assistant using the Ultramicro II grasper and, together with the use of the uterine manipulator, one is able to rotate the tube so that both the 3 and 9 o'clock positions become available for accurate suture placement (Figures 16.1e and f, 16.12 and 16.13). These are placed next and tied and, finally, the 12 o'clock suture is tied (Figure 16.14). Chromo-peritubation is performed via the uterine manipulator and the patency of the tube can now be demonstrated. Slight leakage at the anastomotic site is no cause for concern as long as dye emerges from the distal fimbria. The 6-0 or 7-0 Prolene or PDS is then used to place one or two interrupted serosal sutures (Figure 16.15). These sutures may incorporate the outer muscularis to maintain support of the anastomosis (Figure 16.1g). Any gaps evident in the mesosalpinx are similarly closed using 6-0 nylon. The opposite tube is then treated in the same manner (Figure 16.16).

CONCLUSIONS

Laparoscopic microsurgery is an exciting new tool with great promise, like classical microsurgery before it. However, the learning curve is steep, and skill development very intensive. It requires at least 20 midtubal cases before operators begin to develop a fluid rhythm. After 50 cases, one can perform bilateral midtubal anastomosis in 90 min, making it a very efficient procedure.

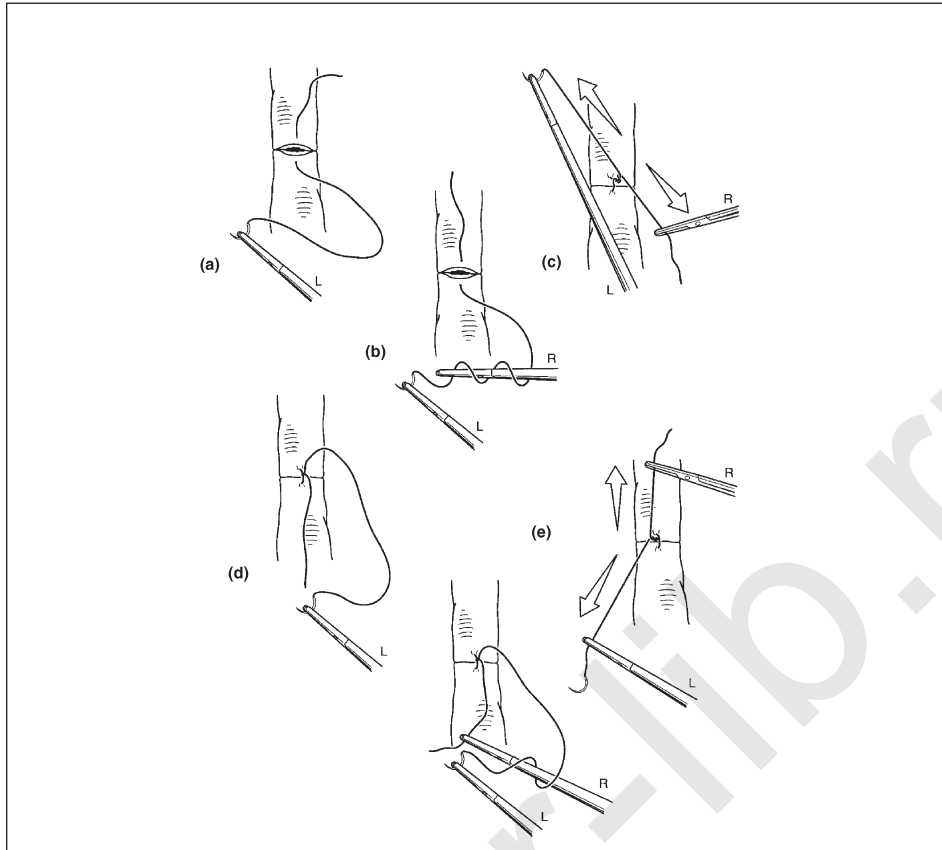
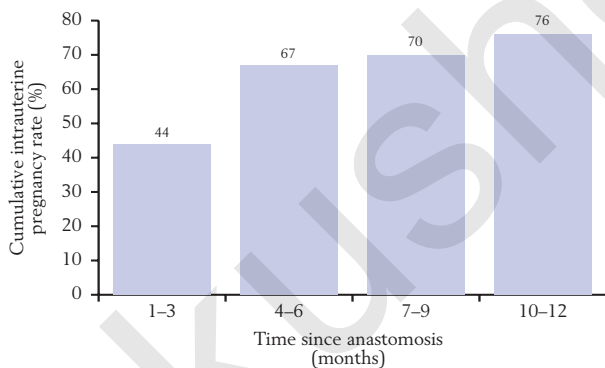


Figure 16.16 Ipsilateral intracorporeal microsuturing using Ultramicro instrumentation with 7-0 and 8-0 Prolene



$n = 54$; intrauterine pregnancy = 41 (76%); ectopic pregnancy = 4 (7.4%)

Figure 16.17 Cumulative intrauterine pregnancy rate (%) 1992–1997 (follow-up 6–12 months). Reproductive Specialty Center, Milwaukee, USA

Laparoscopic microsurgery will introduce a new dimension to reproductive surgery and over time will replace laparotomy for microsurgery (Figure 16.17). It is important to realize, however, that the learning curve is considerable and the technique may not be attainable by all, despite their best efforts. The reproductive surgeon of tomorrow will be an expert in microendoscopy and laparoscopic microsurgery, with sufficient numbers of cases to maintain and develop his expertise.

REFERENCE

1. Brosens IA. Risks and benefits of endoscopic surgery in reproductive medicine. In Proceedings of the 15th World Congress on Fertility and Sterility. ASRM 1995; 47: 339–43

akusher-lib.ru

Laparoscopic management of ovarian cysts

J Donnez, J Squifflet, P Jadoul

In most clinical circumstances, a unilocular ovarian cyst does not require aspiration, but does require medical therapy (such as oral contraceptives) for 3 months. If the cyst does not disappear after a 3-month course of therapy, it requires careful evaluation (echography, CA125 level and, in some instances, computed tomography (CT) and magnetic resonance imaging (MRI)), and, finally, laparoscopic diagnosis and management.

The most frequent types of cysts found in young women are:

- The unilocular clear-fluid cyst (mucous or serous)
- The dermoid cyst
- The endometrial cyst (endometrioma)

Laparoscopic removal of benign ovarian cysts is an effective technique, involving little risk of complications^{1,2}. Nevertheless, several criteria must be taken into account before performing this procedure. Various diagnostic methods have been used to discriminate between benign and malignant ovarian tumors: physical examination, transvaginal ultrasound color flow imaging and tumor markers such as CA125.

PREOPERATIVE EVALUATION

Ultrasound examination

Using high-frequency transvaginal sonography, it is possible to detect malignant ovarian tumors more efficiently than by transabdominal echography³. The vaginal approach produces greater image resolution than the abdominal, thus allowing a more detailed morphological assessment of ovarian masses (Figure 17.1a and b).

The following criteria must be assessed: size and location, borders of the mass and free pelvic fluid (ascites). The internal structure of a mass is considered to be the most important sonographic criterion for distinguishing benign from malignant disorders. The tumor can be purely cystic, complex (mainly cystic, or mainly solid) or purely solid. Loculations, thick septa, irregular solid parts within a mass, undefined margins, and the presence of ascites are considered as malignant patterns (Figure 17.1c). Such cases certainly require conventional surgery by laparotomy. A sonographic diagnosis of benign disease is generally accurate; indeed, a predictive non-malignant rate of 95.6% was found by Herrmann *et al.*⁴.

Transvaginal Doppler ultrasound with color flow imaging

Transvaginal Doppler ultrasound with color flow imaging is a new technique for the evaluation of ovarian masses⁵⁻⁷. It allows positioning of the probe closer to the tumor and reflects visually the state of blood flow of the ovarian tumor (Figure 17.2a and b); it permits the detection of low-resistance intratumoral blood vessels, characteristic of malignant tumors (Figure 17.2c).

The pulsatility index (PI), defined as the difference between the peak systolic and the end-diastolic flow velocity divided by the mean flow velocity, is calculated. Bourne *et al.*⁵ reported that this method can be used to differentiate between primary ovarian cancer and other forms of benign pelvic masses. In their study, low impedance to ovarian blood flow was associated with malignant ovarian tumors (PI < 1).

Weiner *et al.*⁸ made an attempt to compare transvaginal color flow imaging with conventional sonographic findings and other screening procedures to predict ovarian malignancy. They found that suspicious sonographic findings had low specificity, and were inadequate in distinguishing between benign and malignant ovarian tumors. They concluded that transvaginal color flow imaging provided high sensitivity and specificity and was superior to other methods used for the preoperative evaluation of ovarian masses.

A simple measurement of the PI in the newly formed intratumoral blood vessels can discriminate accurately between malignant and non-malignant ovarian tumors. Moreover, because early development of neovascularity may precede tumor growth, screening for ovarian malignancy with transvaginal color flow imaging may detect early ovarian neoplasms before sonography. According to the results of Bourne *et al.*⁵, Fleischer *et al.*⁹ and Kurjak *et al.*⁶, transvaginal color Doppler is a valuable method of differentiating benign from malignant ovarian tumors. However, others¹⁰ have recently been unable to reproduce their results.

CA125

The preoperative evaluation of serum CA125 levels must be made before endoscopic surgery, especially in premenopausal and postmenopausal patients, in order to determine malignant disease preoperatively. Values of CA125 in excess of 65 IU/ml distinguished malignant from benign disease with a specificity of 92% and a sensitivity of

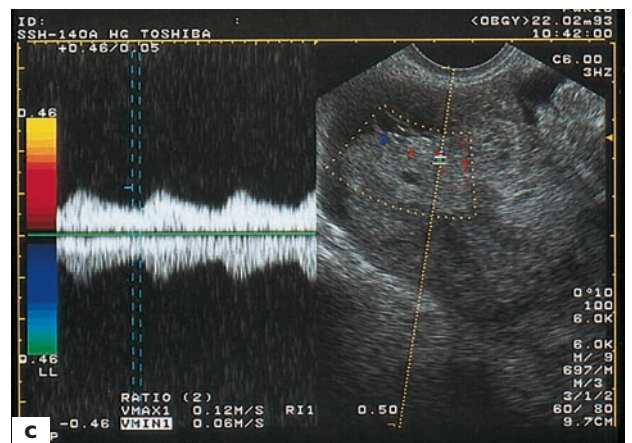
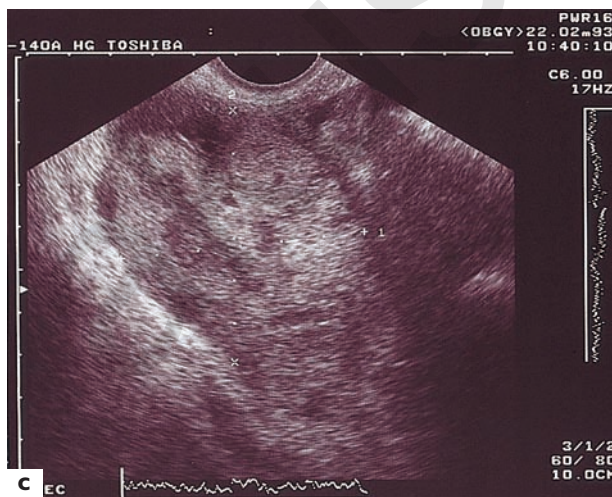
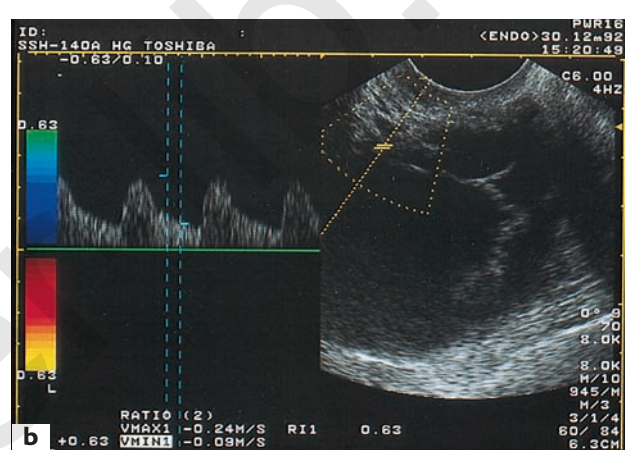
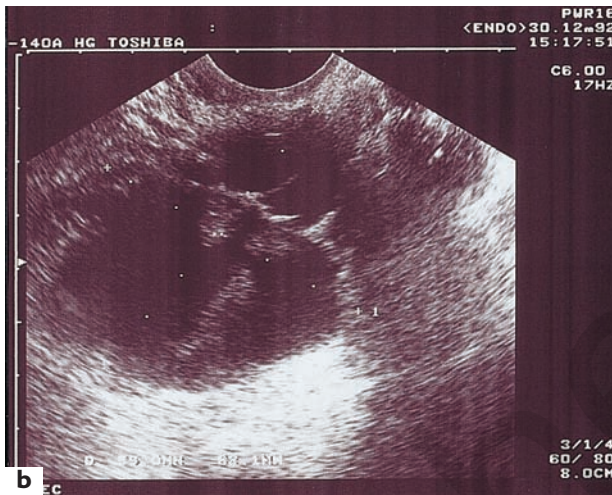
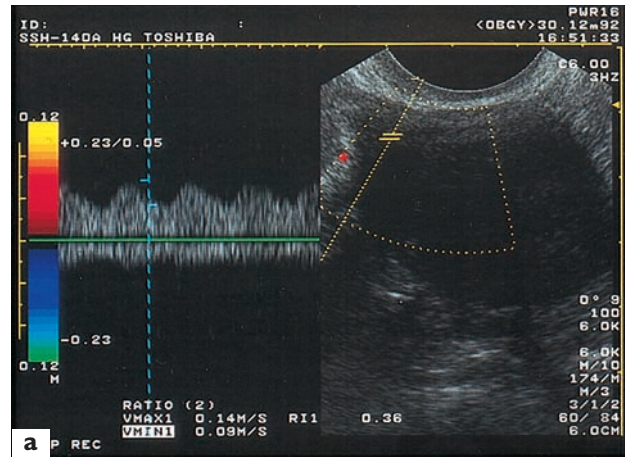
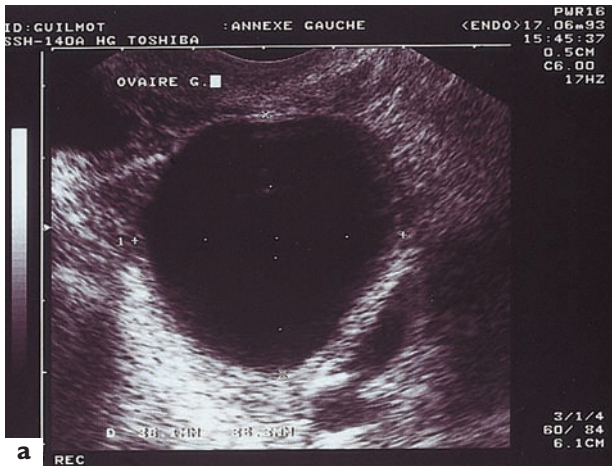


Figure 17.1 Transvaginal sonography: (a) unilocular cyst, without solid structures; (b) multilocular cyst; (c) cyst with thick septa and irregular solid parts suspected to be malignant

Figure 17.2 Transvaginal Doppler ultrasound with color flow imaging (corresponding to the cysts shown in Figure 16.1): (a) unilocular cyst: normal pulsatility index; (b) multilocular cyst: normal pulsatility index; (c) multilocular cyst with hyperechogenic areas. Low-resistance intratumoral blood vessels, suggesting malignancy

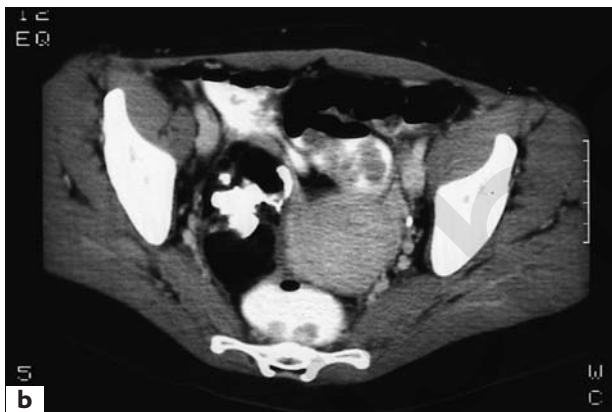
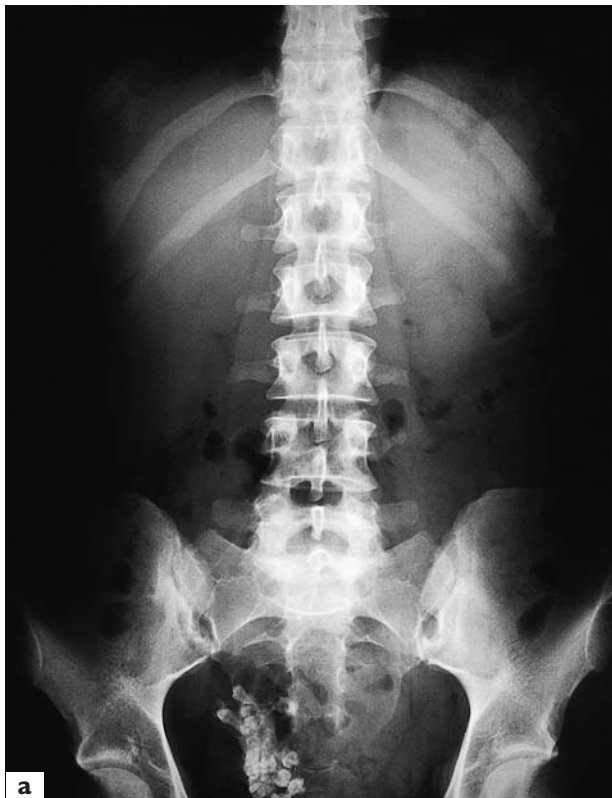

Figure 17.3 (a) and (b) Computed tomography. In the case of dermoid cyst, high-quality images are obtained

75% when both premenopausal and postmenopausal patients were studied together¹¹. Greater specificity and sensitivity were observed in postmenopausal subjects, in whom the specificity of the assay was 97% and the sensitivity 78%¹¹.

CT and MRI

CT provides high-quality images of the ovaries but does not give more information than ultrasound, except in cases of dermoid cysts (Figure 17.3). In our experience, CT is less sensitive and less specific than transvaginal echography

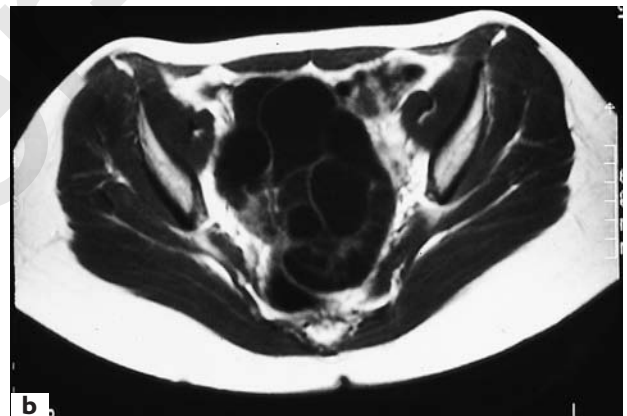
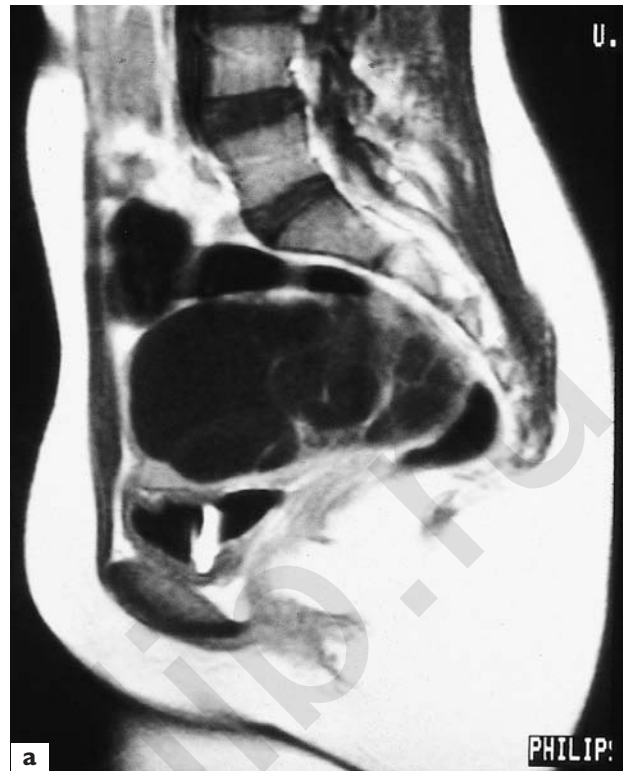

Figure 17.4 (a) and (b) Magnetic resonance imaging provides soft tissue contrast and clear pictures of pelvic organs. Multilocular cyst (histology: mucinous cyst)

in the detection of intracystic structures or septa (Figure 17.3).

MRI provides soft-tissue contrast and clear pictures of pelvic organs (Figure 17.4). This modality is biologically safe and more sensitive than CT in the diagnosis of intracystic structures, and more sensitive and specific than either CT or ultrasound in the evaluation of an ovarian mass.

As a result of the accuracy, convenience, relatively low cost and availability of high-resolution ultrasound equipment, this technique has remained the principal imaging modality in assessing pelvic pathology. In our

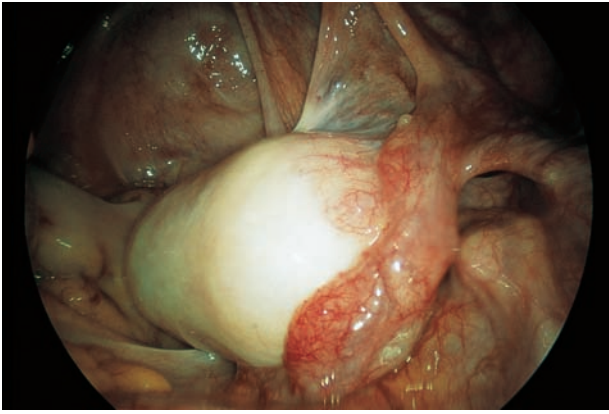


Figure 17.5 Laparoscopic examination of the external cyst wall which must have a smooth appearance

department, CT and MRI are indicated in cases of suspected malignant lesions.

INDICATIONS

Indications for laparoscopic cystectomy include serous, mucous, dermoid and endometriotic cysts. The internal wall of the endometriotic cyst, the complete dissection of which from the ovarian cortex could be difficult, can also be vaporized with the CO₂ laser, as previously described^{12,13}.

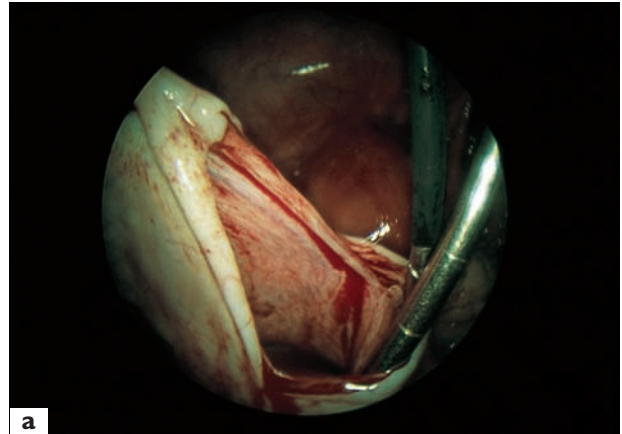
The indications for laparoscopic oophorectomy usually include large endometriotic cysts and benign ovarian cysts in patients aged over 40 years.

The laparoscopic aspiration of unilocular, smooth-walled, translucent ovarian cysts remains controversial. The main concern is spillage of malignancy. Thorough preoperative evaluation of the patient, combining ultrasonography of ovarian tumors with the measurement of tumor markers, may greatly improve the accuracy of diagnosis of ovarian malignancy. Moreover, laparoscopy is, in the first place, used as a diagnostic tool whereby the pelvis and the abdominal cavity are thoroughly evaluated.

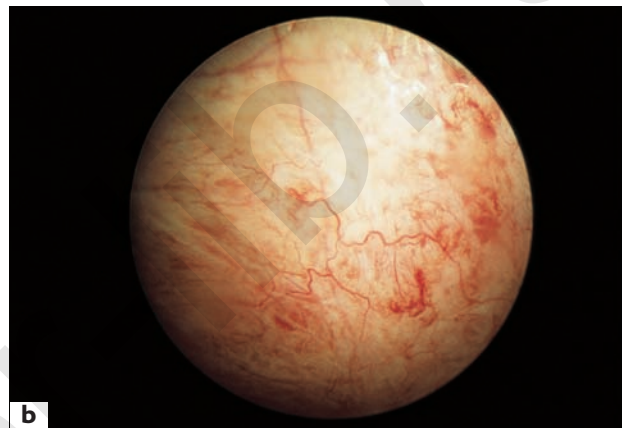
The ovaries are inspected carefully to ensure that the cyst wall is smooth and that there is no vegetation (Figure 17.5). The interior wall of the cyst can also be carefully examined (Figure 17.6), and a biopsy with frozen histological evaluation can be carried out.

In a retrospective study of 226 patients, Mage *et al.*¹⁴ reported that the diagnosis of malignant tumors by laparoscopy was 100% accurate. The anatomopathological examination of specimens in benign conditions was never wrong. They concluded that laparoscopy is a reliable way of diagnosing the type of ovarian cyst.

According to these data, we have proposed the scheme outlined in Figure 17.7 for the laparoscopic management of ovarian cysts. In patients aged under 35 years, hormonal therapy is first attempted for 3 months if echography



a



b

Figure 17.6 (a) Laparoscopic examination of the internal cyst wall; (b) internal view of the cyst. Note the absence of intracystic vegetations (no biopsy required)

reveals a unilocular, smooth-walled cyst without septa or intracystic structures. If the cyst persists, an ultrasound examination is carried out and the CA125 level is measured, in order to exclude a malignant lesion. In patients under 40 years of age, a cystectomy is usually performed.

In patients aged over 40 years, the preoperative evaluation (echography and CA125) is made directly. If data suggest malignancy, a laparotomy is performed after CT and/or MRI have been performed. Only when a malignant lesion can be excluded is a laparoscopy carried out. If at all possible, the cyst is removed intact. Otherwise, the interior wall of the cyst is examined to exclude the presence of any suspect vegetation, which would require a biopsy and a frozen histological examination. In patients over age 40 years, a cystectomy is rarely performed and a unilateral oophorectomy is the preferred procedure. If the frozen histological examination reveals the presence of malignant cells, a laparotomy and total abdominal hysterectomy are mandatory.

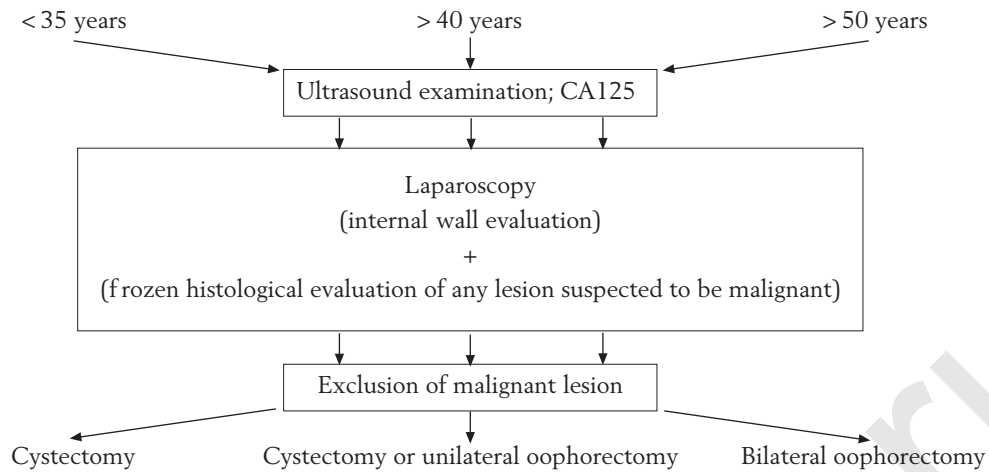


Figure 17.7 Laparoscopic management of ovarian cysts

Table 17.1 Laparoscopic criteria for differentiation between functional and organic cysts. From reference 14

Criterion	Organic cysts	Functional cysts
Utero-ovarian ligament	Lengthened	Normal
Cyst wall	Thick	Thin
Ovarian vessels	Numerous and regular starting from the mesovarium	More scanty, coral-like
Cyst fluid	Clear, dark, brown, or dermoid	Saffron yellow
Internal cyst wall appearance	Smooth or fibrotic with areas of hypervascularization	Retina-like aspect

In patients aged over 50 years, after all the same precautions have been taken, a bilateral oophorectomy is carried out, even if the contralateral ovary is normal.

SURGICAL PROCEDURES

The procedure is performed under general anesthesia. After the induction of a pneumoperitoneum, a 12-mm trocar is inserted subumbilically. The laparoscope is connected to a video camera. Three 5-mm trocars are systematically inserted suprapubically: one in the midline approximately 3 cm above the symphysis pubis, and the other two a few centimeters on either side, taking care to avoid the epigastric vessels.

The initial phase of the laparoscopy is purely diagnostic. First, the abdominal cavity is inspected thoroughly and a peritoneal sampling is sent for cytology. The ovaries are examined carefully in order to exclude the presence of excrescences or other evidence suggesting malignancy.

It is important to differentiate between organic and functional cysts during laparoscopy; 10–20% of functional cysts do not disappear after 3 months of treatment with combination oral contraceptive pills containing 50 µg of ethinylestradiol. According to Mage *et al.*¹⁴, there are five laparoscopic criteria which allow us to distinguish between functional and organic cysts (Table 17.1).

Intraperitoneal cystectomy

The utero-ovarian ligament is grasped with an atraumatic forceps introduced on the side of the tumor, in order to expose the ovary completely (Figure 17.8).

The first step consists of making an incision in the ovarian cortex with the scissors or with the CO₂ laser (Figure 17.9). The incision must be made in the ovarian cortex overlying the cyst, and it must be long enough to permit a straightforward cystectomy. In some cases, the cyst is first aspirated and the liquid examined.

The interior wall of the cyst can be checked by introducing the laparoscope into the ovarian cyst. If there

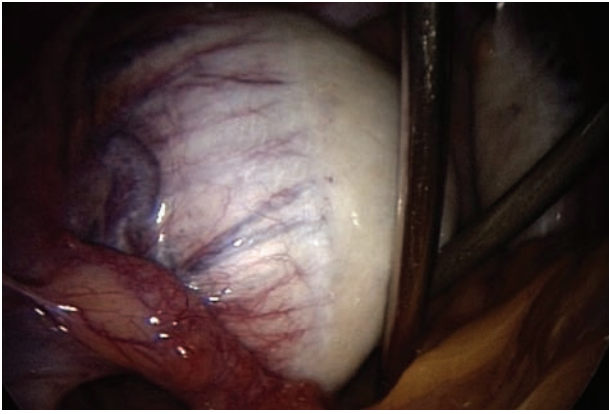


Figure 17.8 The ovarian cyst is exposed

is any intracystic vegetation, a biopsy with frozen histological evaluation can be carried out before a decision is made whether to perform a cystectomy or oophorectomy. In fact, ideally, the cyst should be removed intact from the ovary, without aspirating any of the contents.

The second step is separation of the ovarian cyst capsule from the surrounding ovarian cortex. The ovarian cyst is held using an atraumatic forceps and the ovarian cortex is grasped with another forceps placed close to the ovarian cyst (Figure 17.10). By traction and countertraction, the dissection is easily carried out and the cyst is removed.

Nezhat *et al.*¹⁵ inject 3–5 ml of dilute vasopressin between the capsule and ovarian cortex, to create a tissue plane (hydrodissection) and to reduce oozing from the ovarian bed. We do not consider this procedure to be useful, and it is not used in our department.

The surgeon must constantly observe the tissue tension, and the grasping forceps must be moved often in order to apply the traction in just the right place to avoid tearing the ovary.

At the ovarian hilus, the dissection is often more difficult, but nevertheless, dissection should continue until the cyst is completely removed from the ovary.

Thereafter, the interior ovarian surface is examined and rinsed. Hemostasis is usually achieved spontaneously but, if necessary, bipolar coagulation can be used. However, aggressive electrocoagulation can be the cause of ovarian destruction and premature ovarian failure.

Generally, there is no bleeding and the ovary is left to heal without suturing (Figure 17.11). Indeed, the ovarian edges approximate spontaneously. In cases of large cysts where approximation does not occur spontaneously, closure can be undertaken using the following techniques.

Suturing

The ability to suture during laparoscopy was initially developed by Semm and Mettler¹⁶. Loop ligation using the endoloop or Roeder loop is most often used as an adjuvant

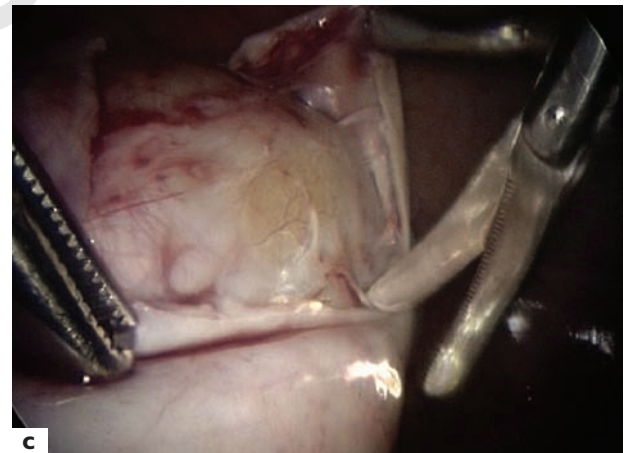
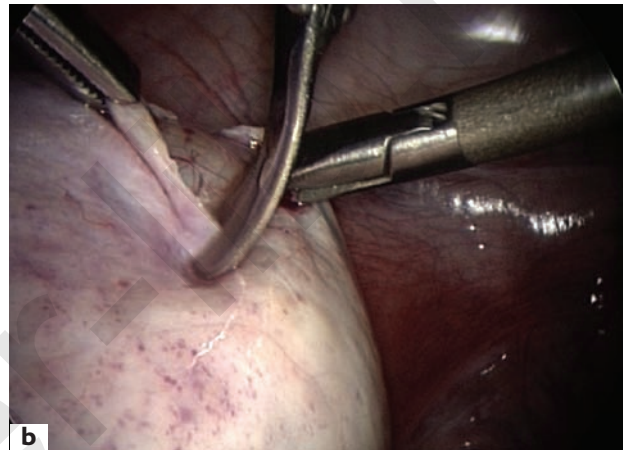
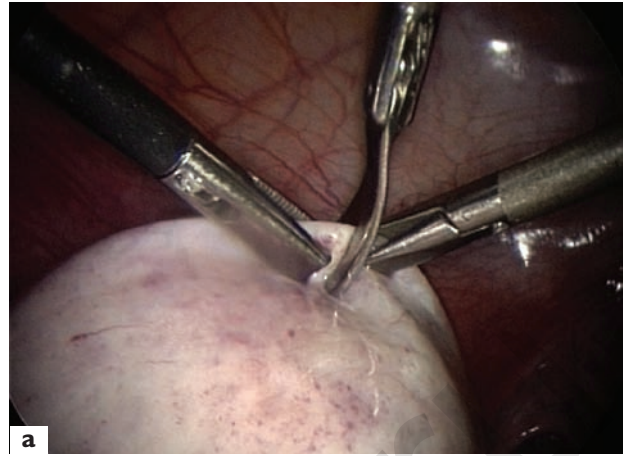


Figure 17.9 (a)–(c) Ovarian cortex incision with scissors

to hemostasis, and as a classic ligature in the case of salpingo-oophorectomy or oophorectomy.

With the advent of endoligature and the intra- and extracorporeal operative knotting techniques, classic methods used at laparotomy were introduced in endoscopic surgery and have become a mainstay. The intracorporeal knotting technique has been recommended by

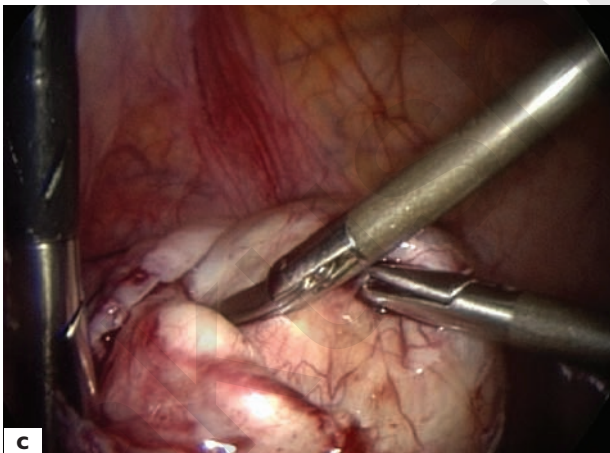
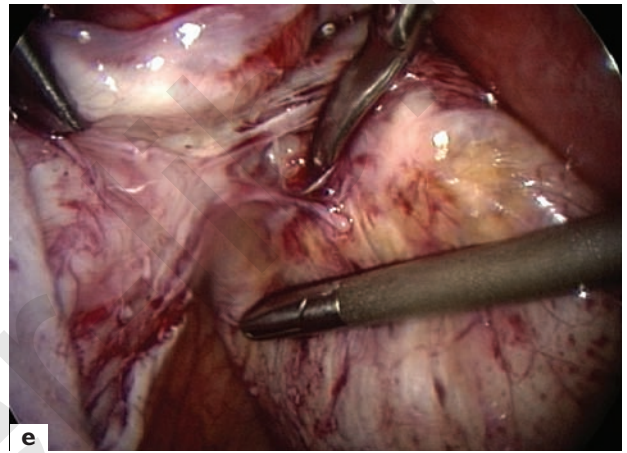
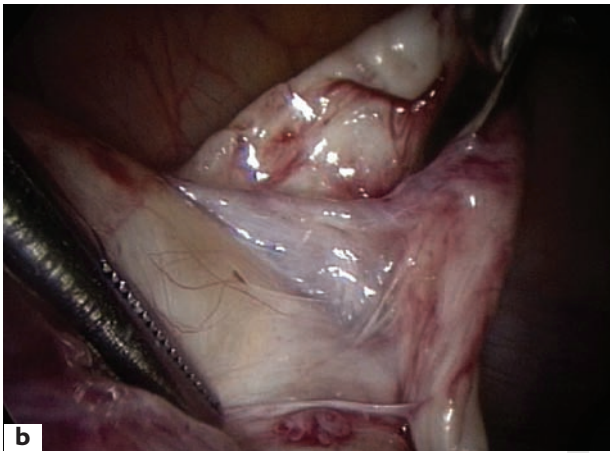
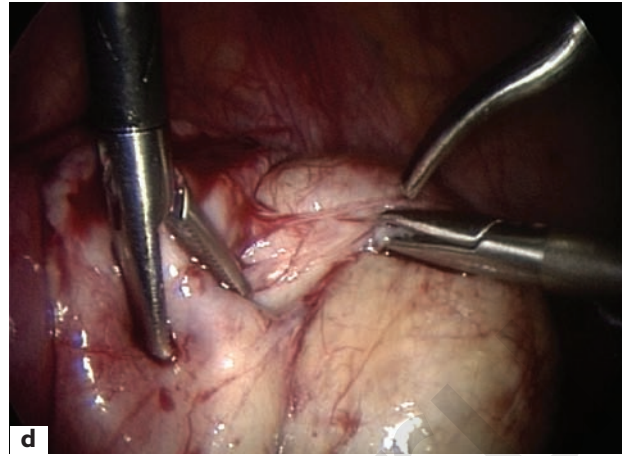
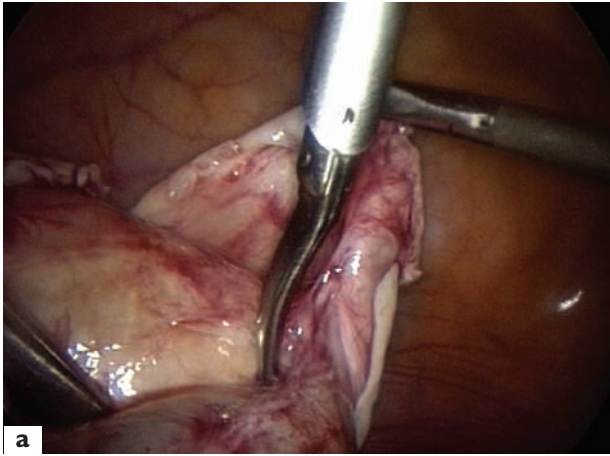


Figure 17.10 (a)–(e) Separation of the ovarian cyst from the ovarian cortex using two atraumatic forceps

Semm and Mettler¹⁶ for fine ovarian sutures. Two lower-abdominal puncture sites are necessary, and, through these, laparoscopic needle holders are introduced to manipulate the suture, needle and involved tissue. The suture material used is 4-0 or 6-0 polydioxanone.

Clips

Clips can also be used for closing the ovarian cortex after cystectomy. The clip is of medium to large size and is made

of titanium, an inert, non-reactive metal (Autosuture™ (Endo Hernia®); Ethicon). Three to four clips are applied using the 10-mm clip applicator; this is usually sufficient to achieve ovarian closure. For ovarian surgery, a titanium clip is preferred to one made of polydioxanone material.

Fibrin sealant

Fibrin sealant¹³ is useful in controlling microvascular or capillary bleeding from ruptured or surgically dissected tissue. It is particularly beneficial during surgery in patients with increased bleeding tendencies. It might also be used to seal tissue with different kinds of biomaterials. Thus, fibrin sealant has a place in all surgical disciplines for the purposes of tissue sealing, hemostasis and support of wound healing. There seem to be a few drawbacks, such as the risk of viral transmission; however, the benefits of combining fibrin sealing with modern-day surgery far outweigh any known risks.

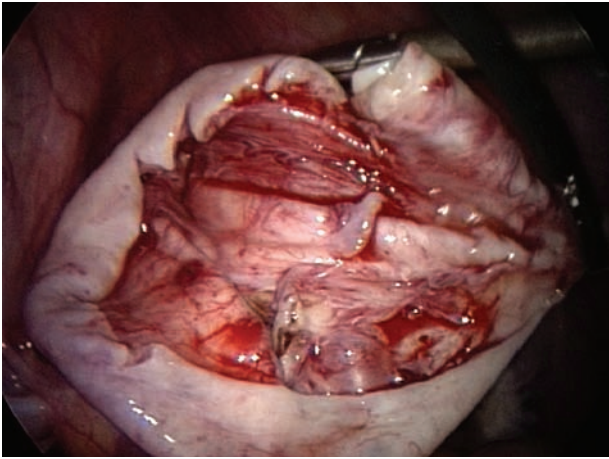


Figure 17.11 Final aspect of the ovarian cortex. There is no bleeding and the ovary is left to heal without suturing

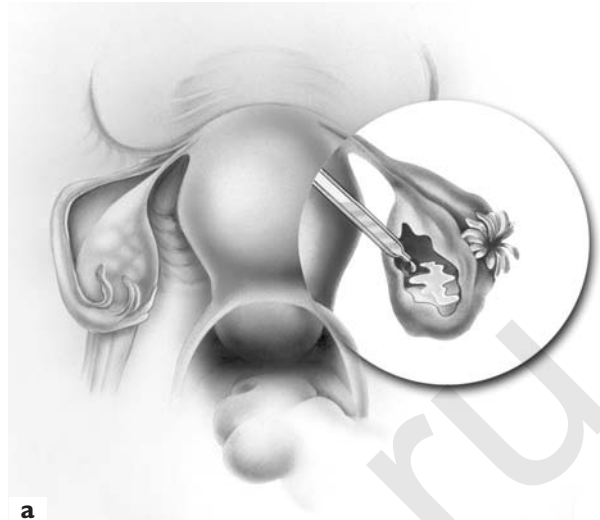
For the optimal use of fibrin sealant, the application technique should meet the following requirements:

- The sealant components should be fully dissolved and kept at a temperature of 37°C (which is easy with the Fibrinotherm system)
- The wound surfaces should be as dry as possible (although application to wet surfaces is feasible)
- The components should be mixed thoroughly on application
- The thrombin and aprotinin concentrations may be adjusted to the purpose of application
- The sealant should be applied as a thin film through a catheter introduced into one of the trocars
- After clotting has occurred, further mechanical stresses should be avoided for about 3–5 min. The edges of the ovarian cortex are approximated with atraumatic forceps (Figure 17.12)

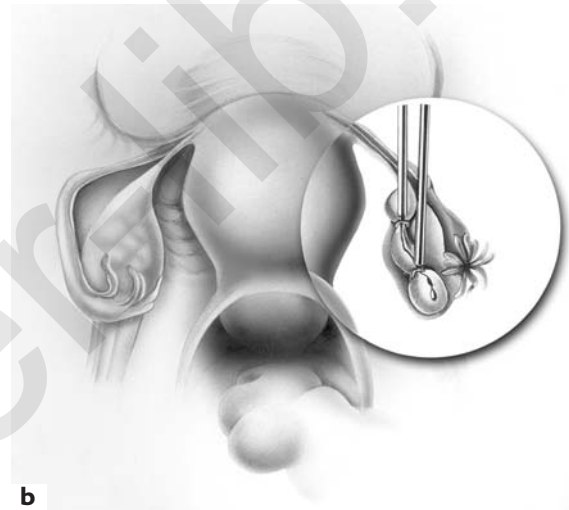
Laparoscopic oophorectomy

In most cases, the tube is removed with the ovary intact unless a previous salpingectomy has been performed. Different methods of laparoscopic oophorectomy have been described. The initial technique described the placement of pre-tied loop ligatures¹⁶; three chromic endoloop sutures were placed around the ovary and the tube and pulled tight. The ovary was then cut away from its pedicle, cut into strips and removed laparoscopically.

The second method of laparoscopic oophorectomy was bipolar coagulation with excision (Figure 17.13). This technique involved four punctures, with traction on the adnexum. A bipolar coagulation forceps was then used to coagulate the ovarian pedicle. After total desiccation of the tissue, 5-mm scissors or the CO₂ laser were used to cut. Successive portions of the meso-ovarium and mesosalpinx



a



b

Figure 17.12 (a) Ovarian closure using fibrin sealant; (b) approximation of the ovarian cortex with two atraumatic forceps

were treated in a similar fashion, and the proximal tube and ovarian ligament were also coagulated and cut. Once the tube and ovary had been separated, they were removed laparoscopically using a LapSac®. Recent studies have shown equally good results using tissue desiccation with bipolar coagulation followed by excision without ligatures.

The most recent technique for laparoscopic oophorectomy is the automatic laparoscopic stapling device. Disposable stapling instruments for laparoscopic surgery are now available. The Multifire GIA™ surgical stapler (United States Surgical Corporation, Newark, NJ, USA) is readily available and is proving to be effective for appendectomy, hysterectomy and adnexectomy.

A staple cartridge 3 cm in length is fired across the infundibulopelvic vessels. Two triple-staggered lines of titanium staples are automatically placed, with a knife

cutting between them. In most cases, two firings of the automatic stapling device are necessary to accomplish removal of the tube and ovary. They are then extracted in a similar way to that used in other laparoscopic techniques. The automatic stapling device reduces operating time, but is nevertheless more expensive than bipolar coagulation.

In certain cases, it is impossible to use pre-tied ligatures as the primary method, because the ovary adheres too strongly to the side-wall to allow placement of the ligature around the adnexa. In such cases, dissection and bipolar coagulation are necessary before beginning the oophorectomy. Similarly, the automatic stapling device, which is 12 mm in diameter, cannot be placed around the whole adnexa; it must be mobile and free before the automatic stapling device can be used¹⁷. Hydrodissection, blunt probing, scissors and judicious use of bipolar coagulation are necessary in certain cases to mobilize the ovary for laparoscopic removal using any of the three techniques described. Aggressive ovariolysis increases the risk of ureteral or bowel injury, or severe bleeding.

The absence of ovarian adhesiolysis before oophorectomy can lead to the incomplete removal of all functional ovarian tissue. The endoloop sutures must be placed below the ovary, to avoid trapping ovarian tissue in the pedicle. Persistent ovarian remnant syndrome after laparoscopic oophorectomy has been described by several authors¹⁵.

Cyst and adnexa removal

There are several techniques for the removal of a cyst or of the adnexa.

After enucleation from the ovaries or after oophorectomy, the tissue is grasped with the grasping forceps introduced through the operating channel of the laparoscope and removed from the abdominal cavity. Such removal can be performed only in cases of small ovarian cysts or after aspiration of the cyst.

However, in cases where spillage should be avoided at all costs (septated cysts or CA125 >35 IU/ml), an impermeable bag can be used (LapSac; Ethicon or Cook) (Figure 17.13l-o). The bag is introduced through a second

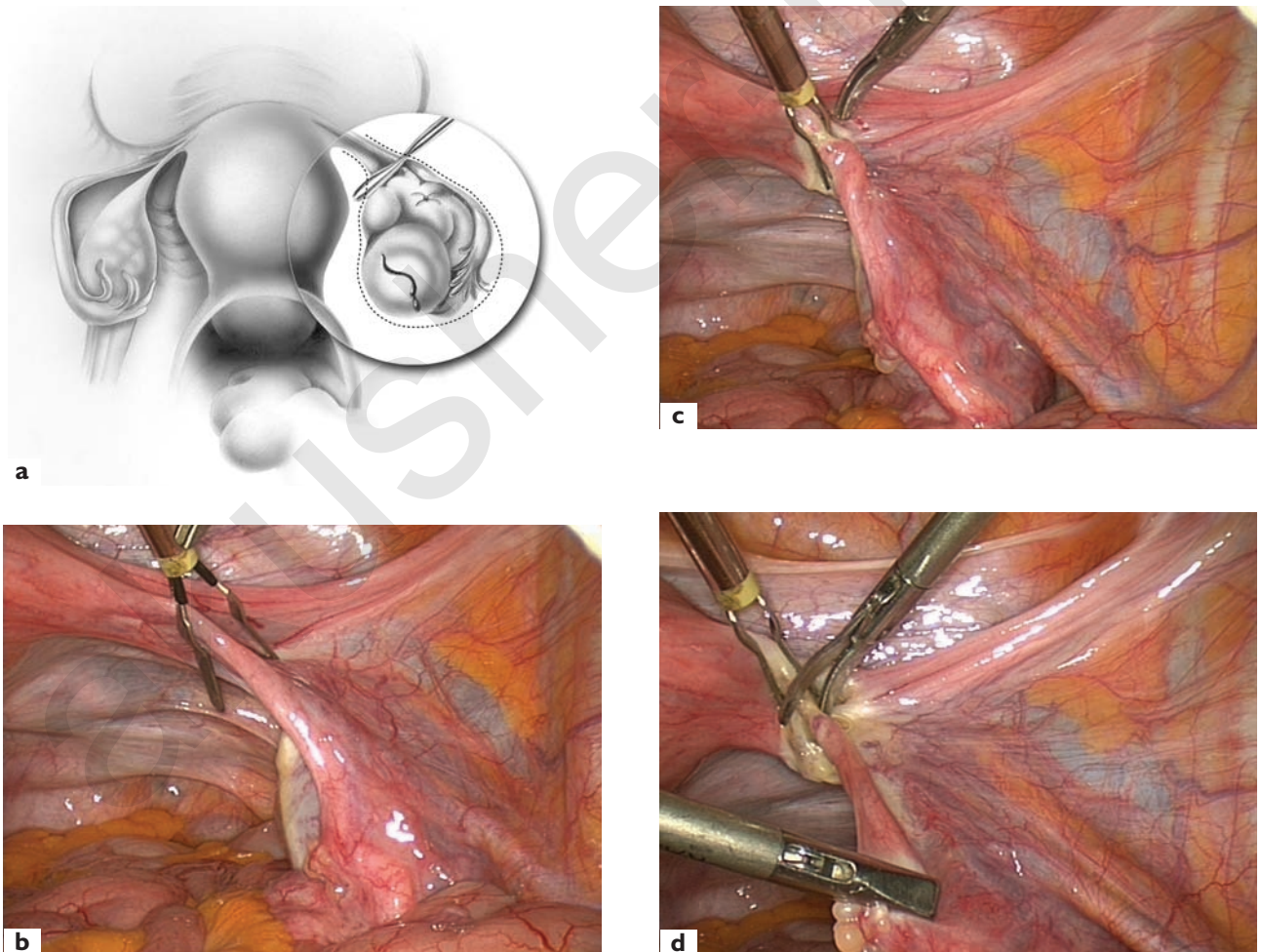


Figure 17.13 Laparoscopic adnexectomy. (a) Illustration of the technique: coagulation of the ovarian pedicle, the ligament, the Fallopian tube and the utero-ovarian ligament; (b)–(d) coagulation and section of the Fallopian tube and the utero-ovarian ligament;

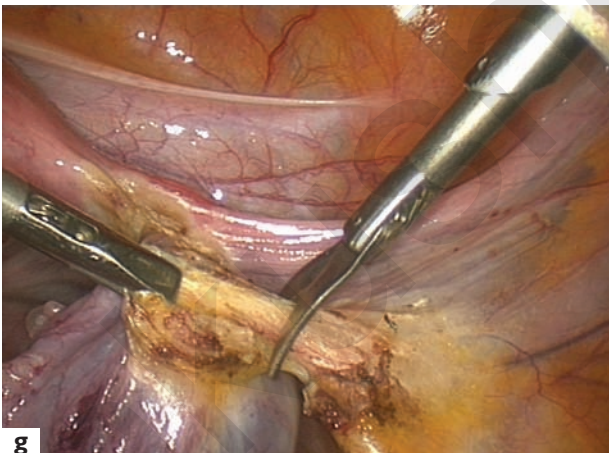
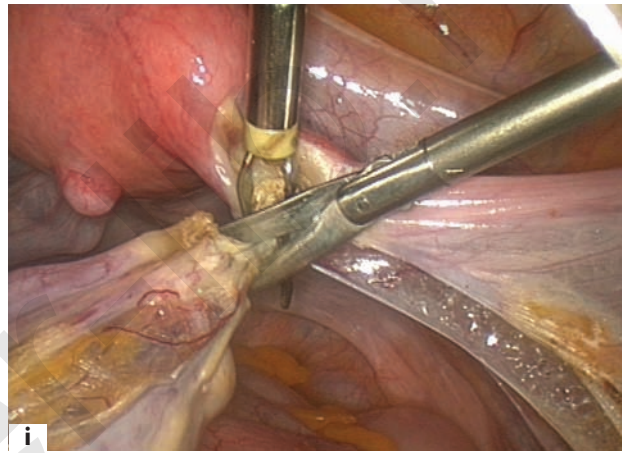
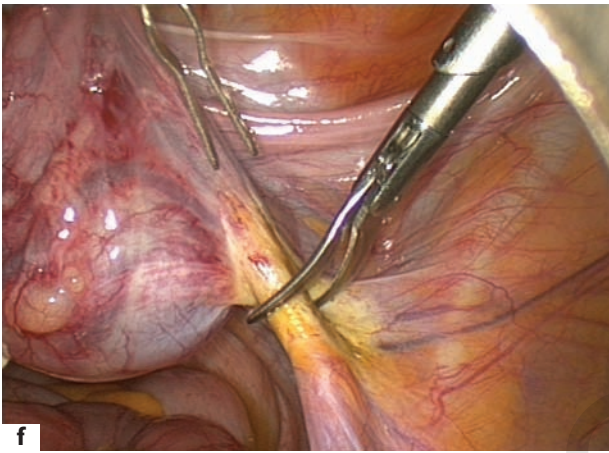
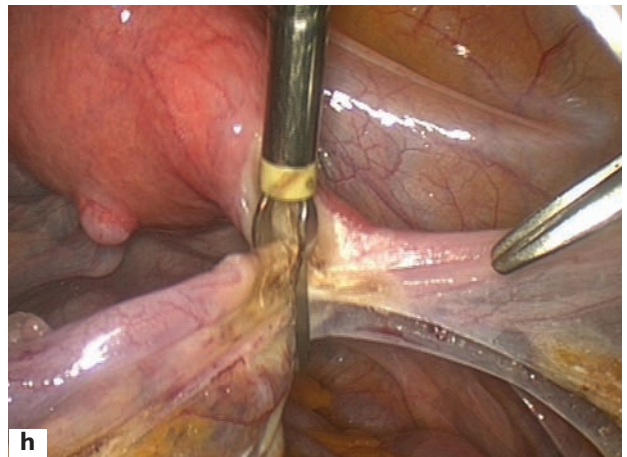
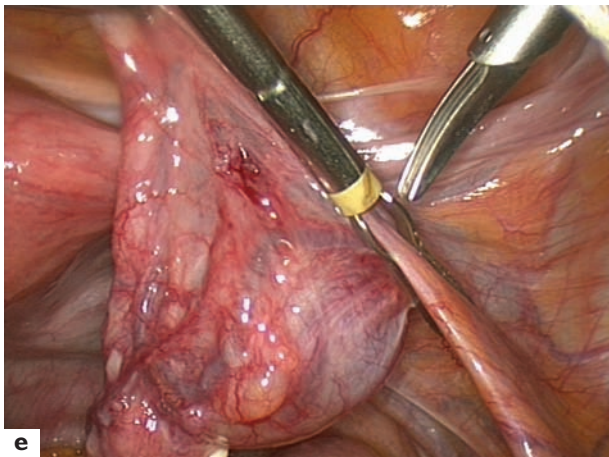


Figure 17.13 continued (e)–(g) coagulation and section of the ovarian pedicle; (h) and (i) coagulation and section of the broad ligament;

puncture trocar. The cyst or the ovary with the intact cyst is placed in the bag, which is closed by pulling its drawstring. The bag is raised to just beneath the abdominal wall and a needle is introduced into the bag in order to aspirate the cyst and decompress it. Then the bag is removed without spillage from the abdominal cavity through a 2-cm suprapubic incision. Reich¹⁸ describes a different technique: the bag is inserted intraperitoneally

through the colpotomy incision and it is removed by pulling the drawstring through the posterior vaginal incision. The bag is opened and the intact specimen visually identified, decompressed and removed.

In some cases, the tissue is grasped directly with an instrument introduced through a suprapubic incision, without using a bag. Theoretically, removing the cyst through a puncture site could lead to a surviving ovarian remnant in the abdominal wall. Nezhath *et al.*¹⁵ have not observed this phenomenon in their 1–3-year follow-up of patients who underwent this technique of cyst wall removal. However, Canis (personal communication) has recently reported induced endometriosis at the trocar site after removal of an endometriotic cyst through the abdominal wall. A metastatic tumor has been reported in three cases on the anterior abdominal wall at the trocar site, following biopsy of ovarian cancer¹⁹. It is suggested

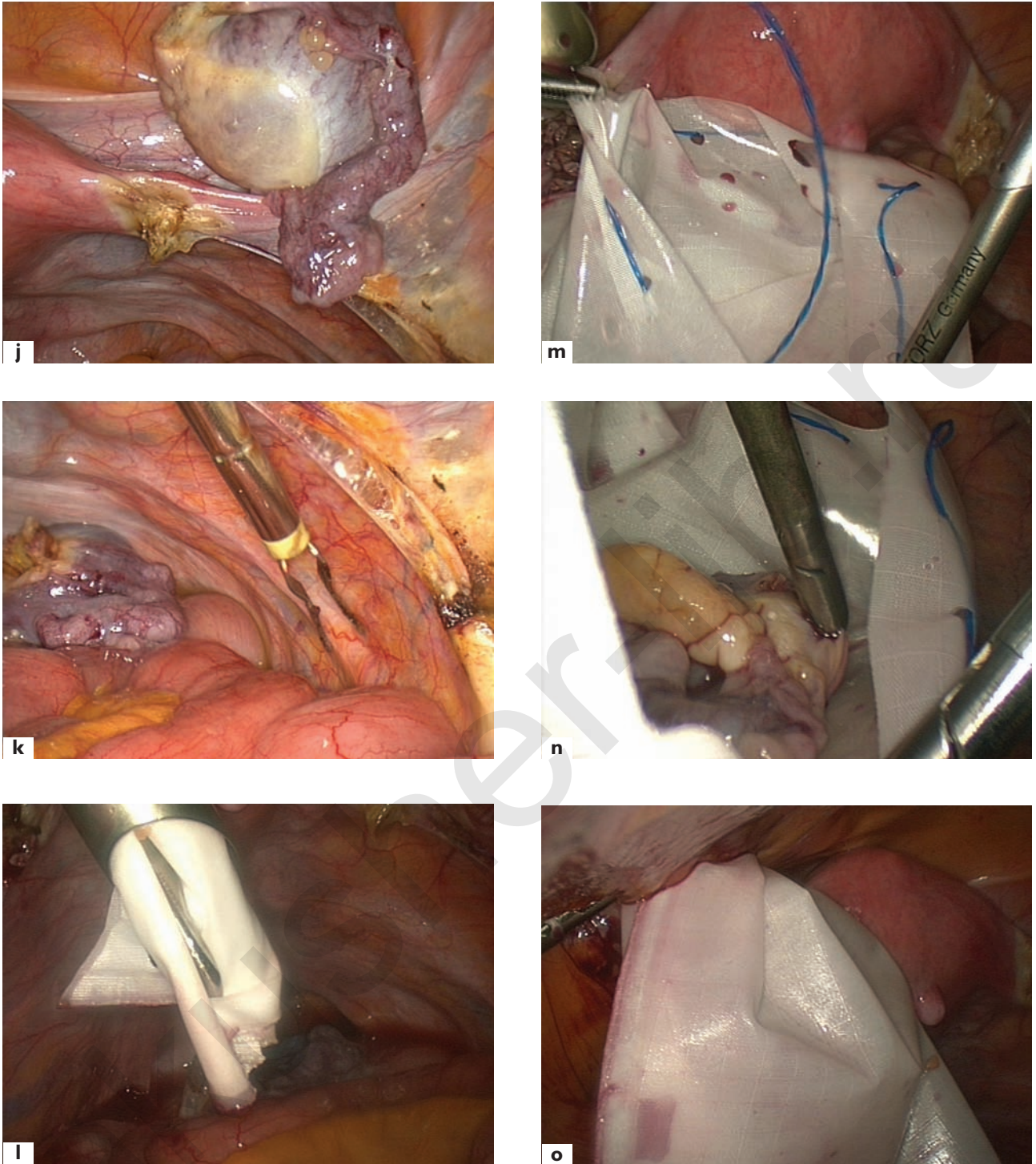


Figure 17.13 continued (j) the adnexa is completely freed; (k) the ureter remains at a safe distance; (l)–(n) to avoid spillage, the ovary is placed in a bag; (o) the bag is removed

that any suspicious ovarian tissue must be removed from the abdomen while avoiding direct contact with the abdominal incision.

In cases of large dermoid cysts, the cyst can be placed in the cul-de-sac of Douglas using a grasping forceps. A colpotomy incision is made and the cyst is then removed intact or aspirated through the vagina²⁰: a needle is

directed through the vagina for cyst decompression. The thick cyst contents can be evacuated by introducing the suction cannula into the cyst after making an incision of 5–6 mm. When the mass is small enough, it can be pulled through the vaginal incision. Copious vaginal and intraperitoneal irrigation with antiseptic solution is performed after cyst removal.

Table 17.2 Bilateral adnexectomy ($n = 114$ postmenopausal women)

<i>Pathology</i>	<i>n</i>
Serous or mucinous cystadenoma	78
Endometrial cyst	10
'Parovarian' cyst (Wolffian)	8
Dermoid	14
Borderline tumor	4

Table 17.3 Borderline tumors ($n = 4$): preoperative check-up

<i>Case</i>	<i>Echography</i>	<i>CA125 (IU/ml)</i>	<i>Frozen pathology</i>
1	Multilocular	<35	Negative
2	Multilocular	<35	Negative
3	Unilocular	56	Negative
4	Unilocular	<35	Negative

In our department, a colpotomy incision is made through the vagina and the overlying peritoneum using scissors. We have never encountered any complications – no bleeding, rectal injuries or infections – using this technique.

However, Reich¹⁸ suggests that a posterior colpotomy incision using the CO₂ laser or electrocautery through the cul-de-sac of Douglas into the vagina is preferable to a vaginal incision, because complete hemostasis is obtained while making the colpotomy incision. The anatomic relationship between the rectum and the posterior vagina must be confirmed before making the laparoscopic colpotomy incision, to avoid cutting the rectum. Reich^{18,21,22} uses an instrument placed in the uterus for elevation and anteversion. The posterior vaginal fornix is identified by placing a wet sponge in a ring forceps just behind the cervix. A rectal probe can also be used to ensure that the rectum is out of the way.

DISCUSSION

Risk of borderline tumor

The advantages of laparoscopic treatment of ovarian cysts have been described for women under the age of 35 years with simple ovarian cysts, for whom the overall risk of malignancy is only 4.5 per 100 000 cases¹⁴.

The risk is much higher in postmenopausal women. Indeed, a 10-year study²³ suggested that, when a postmenopausal woman undergoes surgery for an ovarian neoplasm, the rate of malignancy may be as high as 45%.

Very often, a malignant tumor is diagnosed or suspected by means of echography, CA125, CT or MRI. We have tried to evaluate the 'true' risk of underdiagnosing an ovarian tumor preoperatively.

In a series of 114 postmenopausal women who underwent bilateral adnexectomy, 78 were found to have a serous or mucinous cystadenoma, ten an endometrial cyst, eight a paraovarian cyst, 14 a dermoid cyst and four (<4%) a borderline tumor (Table 17.2). In this series, all patients had a preoperative check-up including measurement of the CA125 level and an ultrasound examination. Three of the four borderline-tumor cases presented abnormalities at the preoperative check-up (Table 17.3). Indeed, in two cases, in spite of a normal CA125 level, echography showed a multilocular cyst. In one case, the cyst was unilocular, but the CA125 level was elevated. In the last case, however, there were no evident abnormalities (unilocular cyst, normal CA125 level); therefore, an accurate preoperative diagnosis was impossible (0.9%) (Figure 17.14). In these four borderline cases, the abnormal cells could not be detected on frozen pathology. These four patients underwent hysterectomy 2 weeks later. Peritoneal sampling for cytology did not reveal any abnormal cells, and the histology did not show any residual malignant tissue; to date, no sign of recurrence has been demonstrated.

The preoperative check-up of a mass diagnosed in postmenopausal women is, in most cases, accurate. Indeed, in our series, only one case (<1%) went undetected preoperatively. However, when an abnormality is observed (Figure 17.15), certain perioperative precautions must be taken to avoid spillage of the intracystic contents.

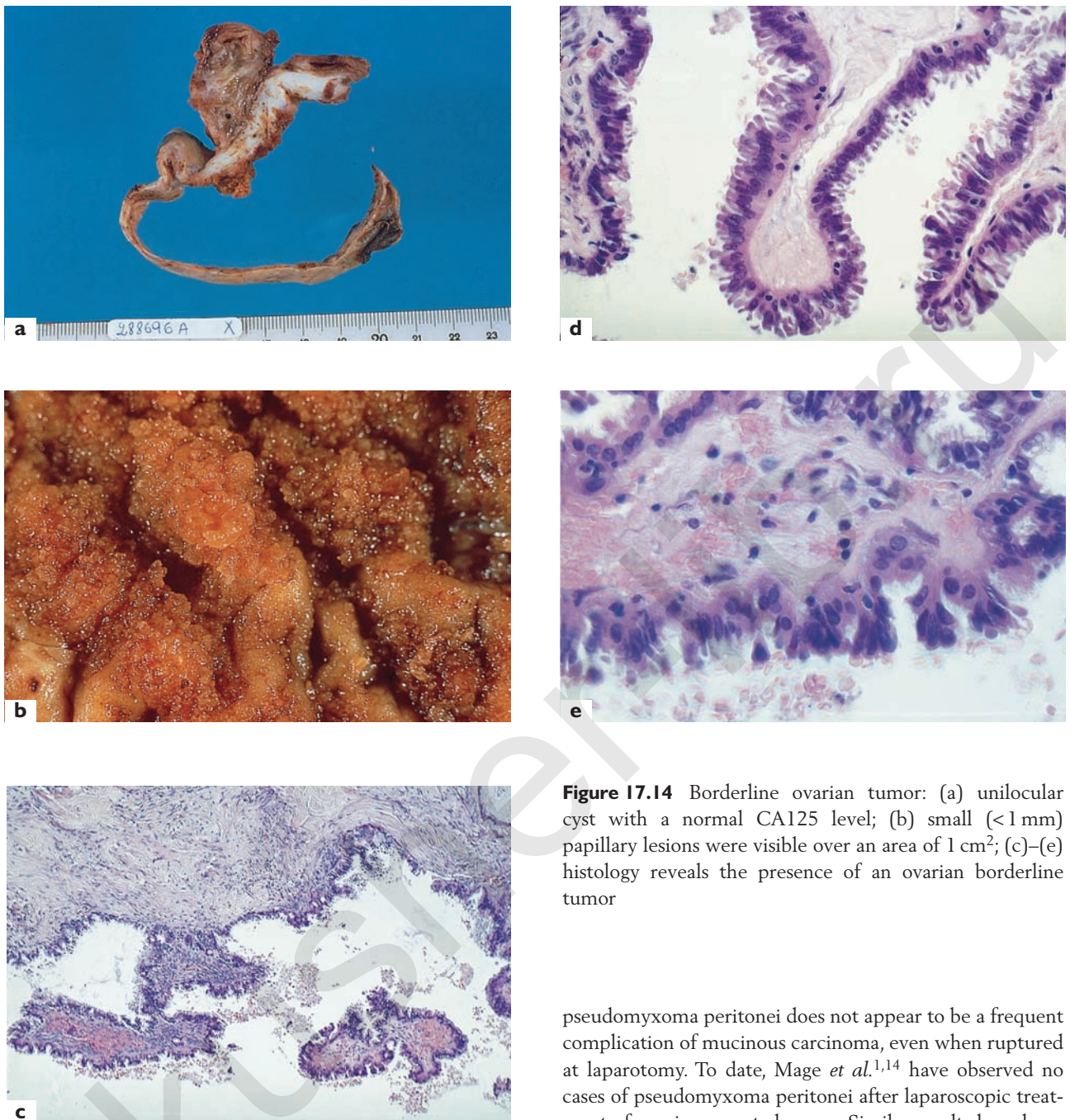


Figure 17.14 Borderline ovarian tumor: (a) unilocular cyst with a normal CA125 level; (b) small (<1 mm) papillary lesions were visible over an area of 1 cm²; (c)–(e) histology reveals the presence of an ovarian borderline tumor

Risk of spillage

Spillage of benign material in cases of benign cystic teratomas or endometriomas can theoretically produce chemical peritonitis. Intraoperative spillage of a mucinous cystadenoma may theoretically initiate pseudomyxoma peritonei. The risk appears to be very low, since pseudomyxoma peritonei, when reported, is usually present at the time of initial surgery²⁴. According to several authors, pseudomyxoma peritonei is almost always associated with mucinous cystadenocarcinoma²⁵. Furthermore,

pseudomyxoma peritonei does not appear to be a frequent complication of mucinous carcinoma, even when ruptured at laparotomy. To date, Mage *et al.*^{1,14} have observed no cases of pseudomyxoma peritonei after laparoscopic treatment of mucinous cystadenoma. Similar results have been reported after laparotomy with cyst rupture. Treatment of the cyst must include careful and copious peritoneal lavage performed immediately, using several liters of Ringer's lactate, with the patient in a reverse Trendelenburg position. Operative spillage should be avoided as much as possible by using 5-mm aspiration systems or a LapSac. In cases of large cysts, the cyst can be punctured before it is placed in the LapSac, which is positioned directly beneath the cyst in order to catch any possible spillage. Moreover, peritoneal lavage and the appropriate surgical treatment, carried out immediately after diagnosis, seem to make the risks of spillage negligible^{1,26} (also Donnez and Nisolle, present study). A recent re-evaluation of intraoperative spillage at laparotomy has demonstrated no adverse effect

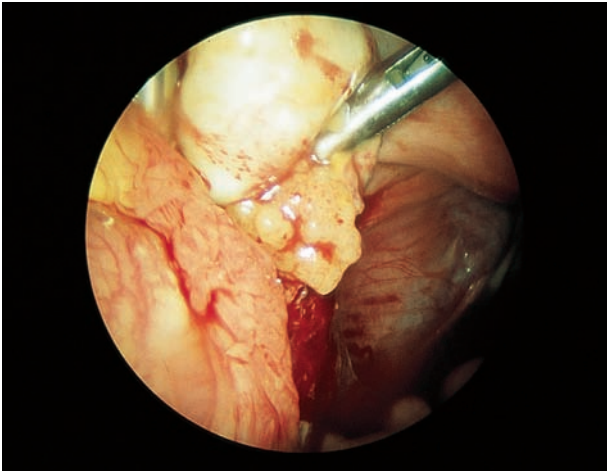


Figure 17.15 Laparoscopic diagnosis of small vegetations on the surface of the ovary. These were not suspected by echography. Frozen histology revealed a 'borderline' tumor. Ovariectomy was carried out. The ovary was removed using a LapSac®

on the prognosis of stage I ovarian cancer²⁷. According to this study, the survival term depends primarily on three factors:

- The tumor grading
- The density of adhesions
- Ascites >250 ml

However, the capsule penetration, the tumor size, the histological type, the age of the patient and the rupture of the tumor were found to have no influence on the prognosis.

It is generally agreed that ovarian cancer should not be managed laparoscopically. One of the drawbacks of operative laparoscopy may be that, in certain cases, malignant cysts cannot be detected.

Risk of postoperative adhesions

What is the risk of postoperative adhesion formation following closure versus non-closure of ovarian defects? It is well known that the ovary is particularly sensitive to surgical trauma, as demonstrated by the high incidence of adhesions after ovarian wedge resection. Buttram and Vaquero²⁸ performed bilateral ovarian wedge resection for polycystic ovarian disease in 173 patients. Of these, 34% underwent endoscopy or laparotomy at some time after bilateral wedge resection. Although the degree of severity varied, all 59 women were found to have adhesions.

Of nine women of reproductive age who underwent removal of dermoid cysts via laparoscopy without an ovarian suture, Nezhat *et al.*¹⁵ performed a repeat laparoscopy in four for the evaluation of possible pelvic adhesion formation. Only one had mild periovarian adhesions, and she had experienced no previous spillage of

cyst contents; in the other three women without adhesions at the time of their second laparoscopy, spillage had previously occurred during cystectomy. Because there is little adhesion formation after intraperitoneal cystectomy, most authors consider that no suture is required, and that the ovary can be left open. In our department, ovarian closure is performed only in cases of large endometriotic cysts. Indeed, such cysts are vaporized using the CO₂ laser instead of dissection. Following this type of procedure, the ovarian edges do not approximate spontaneously, and adhesion formation can occur between the vaporized area and the fimbria^{12,13}. For this reason, Tissucol® or clips can be used for the ovarian closure¹³.

CONCLUSION: THE RIGHT WAY IS THE SELECTION OF PATIENTS

Selection of patients for laparoscopic treatment can be accomplished successfully by excluding those with elevated CA125 levels, suspect ultrasound appearances of cysts containing >3-mm thick septations, solid components within a cyst, matted loops of bowel or ascites. Large series have demonstrated a reassuringly low incidence of inadvertently encountered malignancy at laparoscopy (0.4%^{29,30}, 0.9% (Nisolle and Donnez, present study), 1.1%²⁴, 1.2%¹), but intraoperative surveillance and numerous biopsies are necessary if unsuspected cancer is to be correctly diagnosed.

We are of the opinion that careful preoperative and perioperative examination will eliminate the high rate of mistakes, published in 1991 by Maiman *et al.*³¹. For us, this manuscript reveals a lack of experience, or the absence of strict guidelines, for the 29 respondents who took part in a survey concerning the 'laparoscopic management of ovarian neoplasms subsequently found to be malignant'.

REFERENCES

1. Mage G, Canis M, Manhes H, et al. Laparoscopic management of adnexal cystic masses. *J Gynecol Surg* 1990; 6: 71–9
2. Bruhat MA, Mage G, Chapron C, et al. Present day endoscopic surgery in gynecology. *Eur J Obstet Gynecol Reprod Biol* 1991; 41: 4–13
3. Campbell S, Bhan V, Royston P, et al. Transabdominal ultrasound screening for early ovarian cancer. *Br Med J* 1989; 299: 1363–7
4. Herrmann UJ, Locher GW, Goldhirsch A. Sonographic patterns of ovarian tumors: prediction of malignancy. *Obstet Gynecol* 1987; 69: 777–81
5. Bourne T, Campbell S, Steer C, et al. Transvaginal colour flow imaging: a possible new screening technique for ovarian cancer. *Br Med J* 1989; 299: 1367–70
6. Kurjak A, Schulman H, Sosic A, et al. Transvaginal ultrasound, color flow, and Doppler waveform of the

- postmenopausal adnexal mass. *Obstet Gynecol* 1992; 80: 917-21
7. Kawai M, Kano T, Kikkawa F, et al. Transvaginal Doppler ultrasound with color flow imaging in the diagnosis of ovarian cancer. *Obstet Gynecol* 1992; 79: 163-7
 8. Weiner Z, Thaler I, Beck D, et al. Differentiating malignant from benign ovarian tumors with transvaginal color flow imaging. *Obstet Gynecol* 1992; 79: 159-62
 9. Fleischer AC, McKee MS, Gordon AN, et al. Transvaginal sonography of postmenopausal ovaries with pathologic correlation. *J Ultrasound Med* 1990; 9: 637-44
 10. Hata K, Hata T, Manabe A, et al. A critical evaluation of transvaginal Doppler studies, transvaginal sonography, magnetic resonance imaging, and CA-125 in detecting ovarian cancer. *Obstet Gynecol* 1992; 80: 922-6
 11. Malkasian GD, Knapp RC, Lavin PT, et al. Preoperative evaluation of serum CA-125 levels in premenopausal and postmenopausal patients with pelvic masses: discrimination of benign from malignant disease. *Am J Obstet Gynecol* 1988; 159: 341-6
 12. Donnez J, Nisolle M, Karaman Y, et al. CO₂ laser laparoscopy in peritoneal endometriosis and in ovarian cyst. *J Gynecol Surg* 1990; 5: 391
 13. Donnez J, Nisolle M. Laparoscopic management of large ovarian endometrial cysts: use of fibrin sealant. *J Gynecol Surg* 1991; 7: 163-7
 14. Mage G, Canis M, Manhes G, et al. Kystes ovariens et coelioscopie. A propos de 226 observations. *J Gynecol Obstet Biol Reprod* 1987; 16: 1053-61
 15. Nezhat C, Winer WK, Nezhat F. Laparoscopic removal of dermoid cyst. *Obstet Gynecol* 1989; 73: 278-80
 16. Semm K, Mettler L. Technical progress in pelvic surgery via operative laparoscopy. *Am J Obstet Gynecol* 1980; 138: 121-7
 17. Daniell JF, Kurts BR, Lee J. Laparoscopic oophorectomy: comparative study of ligatures, bipolar coagulation, and automatic stapling devices. *Obstet Gynecol* 1992; 80: 325-8
 18. Reich H. Difficulties in removing large masses from the abdomen. In Corfman RS, Diamond MP, DeCherney A, eds. *Complications of Laparoscopy and Hysteroscopy*. New York: Blackwell Scientific Publications, 1993: 103-7
 19. Hsiu JG, Given FT, Kemp GM. Tumor implantation after diagnostic laparoscopic biopsy of serous ovarian tumors of low malignant potential. *Obstet Gynecol* 1986; 68: 91-3
 20. Nisolle M, Donnez J. Laparoscopic ovarian cystectomy. Presented at the Seventh International Symposium on Laser Endoscopic Surgery, Brussels, 1992
 21. Reich H. Laparoscopic oophorectomy and salpingo-oophorectomy in the treatment of benign tuboovarian disease
 22. Reich H. New techniques in advanced laparoscopic surgery. *Baillières Clin Obstet Gynaecol* 1989; 3: 655-82
 23. Koonings RP, Campbell K, Mishell DR, et al. Relative frequency of primary ovarian neoplasms: a 10-year review. *Obstet Gynecol* 1989; 74: 921-6
 24. Tasker M, Langley FA. The outlook for women with borderline epithelial tumours of the ovary. *Br J Obstet Gynaecol* 1985; 92: 969
 25. Fernandez RN, Daly JM. Pseudomyxoma peritonei. *Arch Surg* 1980; 115: 409
 26. Lueken RP. Laparoscopic-ovarian surgery. In Lueken RP, Gallinat A, eds. *Endoscopic Surgery in Gynecology*. Berlin: Demeter Verlag, 1993: 43-7
 27. Dembo AJ, Davy M, Stenwig AE, et al. Prognostic factors in patients with stage I epithelial ovarian cancer. *Obstet Gynecol* 1990; 75: 263-73
 28. Buttram VC, Vaquero C. Post-ovarian wedge resection adhesive disease. *Fertil Steril* 1975; 26: 874
 29. Nezhat C, Nezhat F. Complications of laparoscopic ovarian cystectomy. In Corfman RS, Diamond MP, DeCherney A, eds. *Complications of Laparoscopy and Hysteroscopy*. New York: Blackwell Scientific Publications, 1993: 108-12
 30. Nezhat F, Nezhat C, Welander CE, et al. Four ovarian cancers diagnosed during laparoscopic management of 1011 women with adnexal masses. *Am J Obstet Gynecol* 1992; 167: 790-6
 31. Maiman M, Seltzer V, Boyce J. Laparoscopic excision of ovarian neoplasms subsequently found to be malignant. *Obstet Gynecol* 1991; 77: 563-5

akusher-lib.ru

Laparoscopic management of adnexal torsion

M Canis, H Manhes, B Rabischong, R Botchorishvili, K Jardon, J L Pouly, G Mage

INTRODUCTION

Adnexal torsion is an infrequent but not rare gynecological disorder. Classical surgical management was adnexectomy without unwinding by laparotomy. As laparoscopy is useful in the diagnosis of adnexal torsion^{1,2}, we have been performing laparoscopic management since 1978^{3,4}. Besides its well known advantages, we think that the main contribution of the laparoscopic approach has been to re-emphasize the value and effectiveness of the conservative treatment of adnexal torsion. This type of management, which was first proposed by Way in 1946⁵, is highly desirable, since torsion occurs most often in women of reproductive age. Recently, a review of the literature concluded that the risk of pulmonary embolism after adnexal torsion was 0.2%, and was not increased when the adnexa was untwisted⁶. We report here our experience of 48 cases of conservative management from a series of 72 cases.

PATIENTS AND METHODS

Seventy-two cases of adnexal torsion were diagnosed between June 1978 and December 1994. Only cases with at least a 360° rotation of the pedicle were included in the study. Malignant ovarian tumors and cases of chronic torsion with an axial rotation of <180° and fixed by adhesions were excluded. The mean age was 27.8 years (range 13–55). According to their clinical data, patients were divided into two groups.

Group 1

Fifty-three patients (73.6%) presented with acute pelvic pain. In this group, the preoperative diagnosis was accurate in only 35 cases (66.0%). Other preoperative diagnoses were ectopic pregnancy, salpingitis, hyperstimulation syndrome with sign of acute abdomen^{7,8} and corpus luteum hemorrhage.

Group 2

Nineteen patients (26.4%) presented with chronic pelvic pain or were referred for surgical evaluation of an adnexal cyst. The delay between the first visit and surgery ranged from 1 to 3 months. In these cases adnexal torsion was never suspected before laparoscopy.

Method

The laparoscopic technique and the instruments used have been described previously⁹. Two or three 5-mm ancillary trocars were inserted into the suprapubic area. Laparoscopic management involved three steps: diagnosis, management of ischemic lesions and treatment of the etiology (Figures 18.1 and 18.2).

Management of ischemic lesions

As recommended by Way⁵ the organs involved were untwisted whenever possible to assess ischemic lesions. To untwist the adnexa, blunt manipulation was preferred to grasping, thus avoiding additional damage and bleeding.

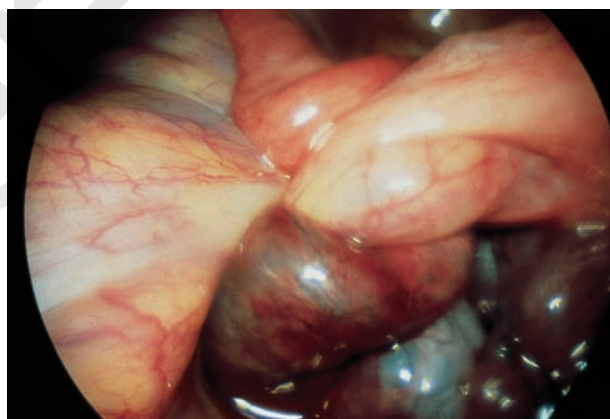


Figure 18.1 Torsion of the right adnexa

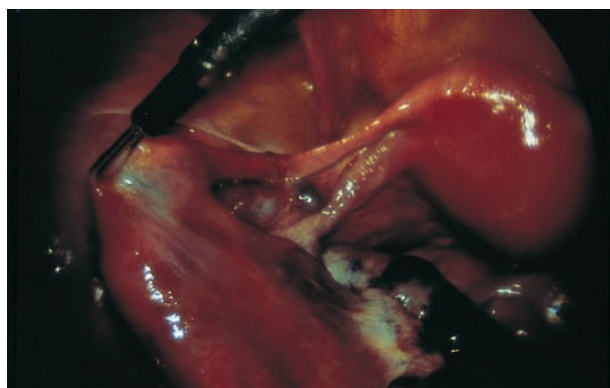

Figure 18.2 Partial ovarian recovery at the end of the laparoscopy

Using an atraumatic forceps or a 5-mm probe, the twisted organs were moved slowly and gently according to 'Kustner's law': Kustner noted that on the left side the pedicle of the twisted organs was rotated in a clockwise direction, whereas it would rotate in a counterclockwise direction on the right side¹⁰. When adhesions were found on the twisted adnexa, adhesiolysis was the first step of the procedure. Finally, in patients with a very large adnexal cyst, untwisting was sometimes possible after puncture and aspiration of the cyst. According to the initial ischemic lesions and immediate recovery^{3,4}, the women were assigned to one of the three following groups:

- Group A: no evidence of ischemia or mild lesions with immediate and complete recovery
- Group B: severe ischemia (tube and ovary were dark red or black colored at the time of diagnosis) with partial recovery 10 minutes after the pedicle was untwisted
- Group C: gangrenous adnexa without recovery

In groups A and B, conservative management was chosen whenever it was possible to treat the etiology in this manner. Gangrenous adnexae were removed either by laparotomy or by laparoscopy. In group B a second-look laparoscopy was proposed 6–8 weeks after the initial procedure to assess definitive recovery. Close clinical and sonographic follow-up looking for recurrence of torsion was requested for patients treated conservatively.

Treatment of the etiology

Adnexal cysts were managed as previously described¹¹, and were treated by laparotomy before 1980 and by laparoscopy in most cases during the last years of this study. Suspicious and/or malignant adnexal cysts were treated by immediate laparotomy. Other causes were managed using previously described laparoscopic procedures^{9,11}.

RESULTS

Laparoscopy always enabled a definitive diagnosis of adnexal torsion. The right adnexa was involved in 38 cases (52.8%) and the left in 33 cases (45.8%), and one patient had bilateral torsion associated with ovarian hyperstimulation. Laparoscopic unwinding of the torsion was possible in 64 cases (88.9%). In three cases, gentle manipulation of a gangrenous tube resulted in a salpingectomy without any bleeding. In three patients, laparoscopic unwinding of a gangrenous ovary was impossible, and in two patients, adnexectomy was decided upon before the surgical procedure. Indications were a suspicious mass at ultrasound in one case, and the age of the patient in the second case (70 years).

Etiology

Adnexal cysts (72.1%) were the most common cause of torsion. Other causes are listed in Table 18.1. In three cases the etiology was thought to be congenital as we found abnormal ovarian ligaments, either a too-short mesovarium or a too-long utero-ovarian ligament. When the adnexa appeared normal, several punctures were routinely performed to rule out the presence of a small ovarian cyst.

Management

Ischemic lesions were mild in 40 cases (group A, 55.5%), severe in 17 cases (group B, 23.6%) and beyond recovery in 15 cases (group C, 20.8%) (Table 18.2). The incidence of necrosis increased during the last period of the study, as a consequence of the phlegmatic management of torsion by general practitioners who tended to treat acute abdominal syndrome using potent oral anti-inflammatory drugs. All patients with chronic pelvic pain had mild ischemic lesions and were included in group A.

Table 18.1 Etiology encountered ($n = 72$)

	<i>n</i>	%
Ovarian cysts	31	43.1
Functional cysts	11	15.2
Organic ovarian cysts	20	27.8
Para-oophoric cysts	17	23.6
Ovarian hyperstimulation	5	6.9
Ectopic pregnancy	3	4.2
Hydrosalpinx	3	4.2
Adhesions	3	4.2
Malformation	3	4.2
Normal adnexa	7	9.7

Table 18.2 Treatment according to ischemic lesions ($n = 72$)

<i>Ischemic lesions</i>	<i>n</i>	<i>Conservative</i>	<i>Radical</i>
<i>All patients</i>			
Mild	40	33 (82.5%)	7 (17.5%)
Severe	17	14 (82.3%)	3 (17.7%)
Not gangrenous	57	47 (82.5%)	10 (17.5%)
Gangrenous	15	1 (6.6%)	14 (93.4%)
Total	72	48 (66.6%)	24 (33.3%)
<i>Patients <40 years old</i>			
Mild	32	28 (87.5%)	4 (12.5%)
Severe	14	14 (100%)	0 (0.0%)
Not gangrenous	46	42 (91.3%)	4 (9.7%)
Gangrenous	6	1 (16.6%)	5 (83.3%)
Total	52	43 (82.7%)	9 (17.3%)

In groups A and B, conservative treatment was achieved for 47 of 57 patients (82.5%) (Table 18.2). Overall, conservative management was achieved in 48 of 72 patients (66.6%) and in 43 of the 52 patients (82.7%) who were less than 40 years old.

The immediate postoperative course was always uneventful. Although heparin was never used, we observed no thromboembolic complications.

In six of the 17 patients included in group B, we found a complete and even surprising recovery at second-look laparoscopy (Figures 18.1–18.3). An ovarian biopsy was obtained in only one case; histological examination showed a thickened ovarian capsule with a normal follicular population. In the seventh second-look laparoscopy, the twisted ovary had disappeared^{12,13}. This patient had been treated by unilateral salpingectomy without oophorectomy, despite complete necrosis of the tube. From this case, we assume that the ovary should be removed when the tubal lesions are beyond recovery, i.e. when the tube does not recover within 10 minutes of the detorsion.

Follow-up

Six patients were lost to follow-up 1–2 months after laparoscopic treatment. For the remaining 66 patients, the duration of follow-up ranged from 8 months to 16 years.

We observed five recurrences of torsion.

The first patient had an ovariopexy using a Fallopian ring to treat an overly long utero-ovarian ligament with a normal ovary; 12 months later, another laparoscopy, performed to evaluate a 6-cm diameter ovary, showed a recurrence of torsion without ischemia. A bilateral ovariopexy was performed by laparotomy.

The second recurrence was discovered during laparoscopy performed for chronic pelvic pain, 12 months after a right ovariopexy and ovarian cystectomy. We found

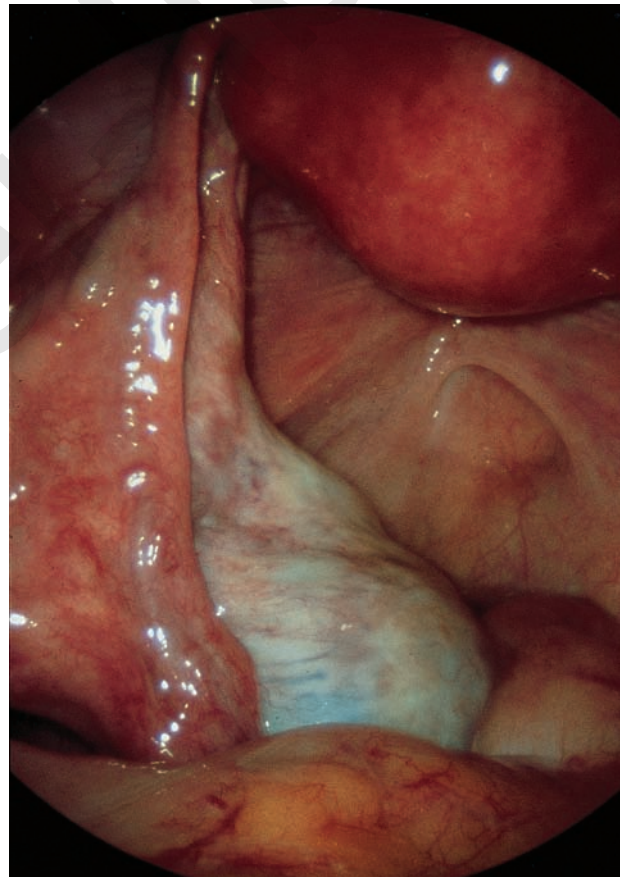


Figure 18.3 Complete recovery at second-look laparoscopy.

torsion of the contralateral ovary, the utero-ovarian ligament was absent and the ovary was fixed by adhesions to the posterior wall of the broad ligament. Conservative management with a left ovariopexy was achieved.

Table 18.3 Fertility after laparoscopic management of an adnexal torsion ($n = 72$)

	Conservative treatment ($n = 48$)	Radical treatment ($n = 24$)
Contraception	31 (64.6%)	11 (45.8%)
Lost to follow-up	0	6 (25.0%)
N1 tumor	17 (35.4%)	8 (33.3%)
Infertile	4 (23.5%)	2 (25.0%)
Spontaneous pregnancy	12 (70.6%)	4 (50.0%)
Pregnancy after IVF	1 (5.9%)	1 (12.5%)

The third case involved our patient treated after *in vitro* fertilization (IVF), who was again pregnant after a fourth IVF procedure and again had a torsion, 6 weeks after embryo transfer; this recurrence was managed conservatively without postoperative abortion.

The fourth recurrence involved the first patient of this study; she was treated in 1978 for torsion of a solitary adnexa with severe ischemia, became pregnant 1 year later and had a recurrence in 1988, and again was managed conservatively with an ovariopexy.

The fifth recurrence was torsion of the contralateral adnexa, which occurred several years after the first laparoscopic procedure. With increased experience, this recurrence would have been anticipated, as it can be seen from Figure 18.3 that the utero-ovarian ligament of this solitary adnexa was too long.

Postoperative fertility

Fertility results are presented in Table 18.3. The spontaneous pregnancy rate was 70.6% after conservative management, and only 50% after radical treatment. In the patients who became pregnant after IVF, this management was decided because of previous tuberculosis in one case and associated male infertility in the second case. Interestingly, five of the six patients who did not become pregnant had an infertility problem before the torsion.

DISCUSSION

In our experience, laparoscopy always permits accurate diagnosis of adnexal torsion. Despite recent progress with the color Doppler technique^{14,15}, preoperative diagnosis is often difficult, and adnexal torsion can be confused with many other gynecological conditions. The surgical evaluation of these patients should be performed by laparoscopy, probably avoiding many unnecessary laparotomies. Furthermore, as previously emphasized, we think that prompt diagnosis is essential in order to preserve the involved organs^{2,16}. In our study, most gangrenous adnexae

were diagnosed more than 72 hours after the onset of pain. A delayed surgical procedure will find a gangrenous adnexa which must be removed, and spontaneous evolution probably results in spontaneous tubo-ovarian amputation^{12,13}. Among the last cases included in this series and in cases of adnexal torsion after laparoscopic hysterectomy¹⁷, we observed that by using potent oral analgesic and non-steroidal anti-inflammatory drugs it is possible to manage an acute abdominal syndrome, particularly adnexal torsion, in a phlegmatic manner, thus delaying the surgical procedure for many hours and increasing the risk of ovarian necrosis. This explains why the incidence of gangrenous adnexae increased in our recent experience.

It is essential to stress, particularly for general practitioners, that the treatment of adnexal torsion is a surgical emergency, even if the acute pelvic pain may be effectively relieved using oral drugs.

The unwinding of torsion was previously condemned, for fear of freeing a potentially fatal embolus. We and others^{2,5,18-22} have never observed this complication. Again, prompt diagnosis and treatment, before the adnexal vascular supply has become thrombosed, may explain this result. Furthermore, in six of 15 cases of gangrenous adnexae, unwinding was impossible, which resulted in immediate spontaneous salpingectomy or oophorectomy. Since we observed no bleeding in these cases, we feel that no embolus is likely to be freed during this procedure. Recently, McGovern *et al.* reported that in the literature this complication is more common after radical management⁶. Thus, concern about this complication, which was most probably encountered after delayed diagnosis, should no longer be the main indication for radical management, especially in cases of mild ischemia, which represent 55.5% of our patients.

However, one case of postoperative fibrinolysis was reported by Lopes *et al.* after conservative treatment of a young patient with severe ischemic lesions²³. From this case and our case of absent ovary at second-look laparoscopy, which suggested that when tubal lesions are

beyond recovery, ovarian lesions are likely to be too severe to recover, we would like to emphasize that conservative management should be indicated very carefully, taking into account patient age and tubal recovery. Furthermore, the value of routine postoperative coagulation tests should be determined after the treatment of severely damaged adnexae. Finally, complications observed after this 'new and unusual' management should be reported extensively in the literature.

Conservative management has been criticized even in cases of mild ischemia. Indeed, Azoury *et al.*¹ reported that histological examination of an excised tube, in spite of complete recovery from mild ischemia, showed definitive mucosal damage. This finding can, however, be countered by several arguments. First, we and Way both observed an intrauterine pregnancy following conservative management of a solitary adnexa with severe ischemic lesions⁵; second, one can suppose that immediate histological examination is not the best way to evaluate recovery from ischemia, since edema makes histological examination difficult; and third, several studies have confirmed tubal patency after conservative management of torsion using hysterosalpingography^{3,4}.

Adnexal cysts were the most common cause of torsion (Table 18.1). Sonographic examination may be helpful in showing an adnexal mass and/or demonstrating an adnexal cyst. Indeed, during the surgical procedure, differential diagnosis between an enlarged edematous normal ovary and an enlarged cystic ovary may be difficult, and hence preoperative diagnosis of the cyst is helpful for adequate conservative management. To exclude malignancy the laparoscopic management should be careful, as previously described¹¹. A complete cystectomy should be performed for histological examination, since infarction makes both laparoscopic and histological diagnosis of adnexal cystic tumors quite difficult; Lomano *et al.* reported 26 non-specific cysts among 44 cases of twisted ovarian cysts²⁴. Most studies^{2,24,25} found a low incidence of malignant tumors in association with torsion. Koonings and Grimes concluded from their study of 19 postmenopausal women that among twisted adnexal tumors the risk of malignancy is low (5.2%)²⁵. Finally, benign ovarian neoplasms were found to have a 12.9-fold increased risk of undergoing torsion when compared with malignant ovarian neoplasm²⁶. The low risk of malignancy may be explained by the fact that inflammation, large size and adhesion formation caused by ovarian malignancy all contribute to prevent torsion. By contrast, Lee and Welch²⁷ found malignancy in 15% of 135 patients. Although the risk of malignancy appears to be low, this issue is crucial. However, laparoscopic management seems to be safe, since we have demonstrated that laparoscopic diagnosis of malignancy in adnexal masses is reliable¹¹.

Because of the hematosalpinx induced by ischemia, drawing a distinction between torsion of a normal tube and that of a tubal pregnancy is quite difficult; hence, if a hematosalpinx is discovered in a woman of reproductive

age, salpingotomy with aspiration of the tubal contents must be performed in every case managed conservatively. Similarly, the distinction between a twisted hydrosalpinx or a twisted pyosalpinx may be possible only after tubal incision. Three of our cases of torsion were attributed to unusual congenital ovarian attachment. In one of these patients with an overly long utero-ovarian ligament, laparoscopic ovariopexy using a Fallopian ring was performed. As a recurrence with complete disappearance of the utero-ovarian ligament occurred, this procedure should not be used again, although we do not know whether the disappearance of the ligament was explained by application of the ring or by long-term evolution of the recurrence.

From the five recurrences which occurred in this series, we propose the following technique and indications for ovariopexy. Ovariopexy should be performed using non-absorbable suture either by laparotomy or by laparoscopy. Our current laparoscopic technique is the following. We shorten the utero-ovarian ligament and suture its ovarian end to the posterior aspect of the broad ligament. Finally, when an ovariopexy is decided upon, it is performed on both adnexae. However, the efficacy of this procedure has to be evaluated in a long-term study.

Ovariopexy should be performed in cases of unusual ovarian attachment and/or immediate recurrence of torsion. This procedure is questionable in the case of a normal adnexa; indeed, if ischemic lesions are mild, careful examination of the ovarian ligament will probably discover in some cases an abnormality of this ligament, which should be treated. On the other hand, when ischemic lesions are severe, the ovarian ligament is always very long due to massive ovarian edema; in such cases ovariopexy should be selected and performed at second-look laparoscopy. When a cause is found and correctly treated, the risk of recurrence is low, and routine ovariopexy is not required in all cases, especially in the case of an organic ovarian cyst which always induces a lengthening of the utero-ovarian ligament¹¹. In such a case, ovariopexy may be required only when one finds a bilateral unusual ovarian attachment, whereas the ovarian cyst is unilateral. However, as adnexal cysts are frequent and adnexal torsion uncommon, one should always bear in mind that a torsion may have several causes; therefore, the contralateral utero-ovarian ligament should be carefully inspected, and bilateral ovariopexy performed when the 'normal' ligament is as long as the twisted one. These indications of ovariopexy arise from our experience of recurrent torsion. We think that four out of five recurrences could have been avoided using these rules. The fifth patient had both torsions during pregnancies which begun after ovarian hyperstimulation for IVF, and this recurrence appeared difficult to avoid.

We conclude that conservative management is possible in about 75% of cases, and that most patients can be safely managed laparoscopically.

REFERENCES

1. Azoury RS, Chehab RM, Mufarrij IK. The twisted adnexa; a clinical and pathological review. *Diagn Gynecol Obstet* 1980; 2: 185–91
2. Hibbard LT. Adnexal torsion. *Am J Obstet Gynecol* 1985; 152: 456–61
3. Manhes H, Canis M, Mage G, et al. Place de la coelioscopie dans le diagnostic et le traitement des torsions d'annexes. *J Gynecol Obstet Biol Reprod* 1984; 13: 825–9
4. Mage G, Canis M, Manhes H, et al. Laparoscopic management of adnexal torsion. A review of 35 cases. *J Reprod Med* 1989; 34: 520–4
5. Way S. Ovarian cystectomy of twisted cysts. *Lancet* 1946; 2: 47–8
6. McGovern PG, Noah R, Koenigsberg R, Little AB. Adnexal torsion and pulmonary embolism: case report and review of the literature. *Obstet Gynecol Surv* 1999; 54: 601–8
7. Chin NW, Friedman CI, Awadalla SG, et al. Adnexal torsion as a complication of superovulation for ovum retrieval. *Fertil Steril* 1987; 48: 149–51
8. Hurwitz A, Milwidsky A, Yagel S, et al. Early unwinding of torsion of an ovarian cyst as a result of hyperstimulation syndrome. *Fertil Steril* 1983; 40: 393–5
9. Bruhat MA, Mage G, Pouly JL, et al. *Operative Laparoscopy*. New York: McGraw Hill, 1992
10. Kustner O. Das Gesetzmässige in der torsionsspirale torquirter Ovariumtumorstiele. *Zentralbl Gynakol* 1981; 15: 209–13
11. Canis M, Mage G, Pouly JL, et al. Laparoscopic diagnosis of adnexal cystic masses: a 12-year experience with long-term follow-up. *Obstet Gynecol* 1994; 83: 707–12
12. Ali V, Lynn S, Schmidt W. Unilateral absence of distal tube and ovary with migratory calcified intraperitoneal mass. *Int J Gynaecol Obstet* 1980; 17: 328–31
13. Beyth H, Baron E. Tuboovarian autoamputation and infertility. *Fertil Steril* 1984; 42: 932–4
14. Albayram F, Hamper UM. Ovarian and adnexal torsion: spectrum of sonographic findings with pathologic correlation. *J Ultrasound Med* 2001; 20: 1083–9
15. Fleischer AC, Brader KR. Sonographic depiction of ovarian vascularity and flow: current improvements and future applications. *J Ultrasound Med* 2001; 20: 241–50
16. Nichols DH, Julian PJ. Torsion of the adnexa. *Clin Obstet Gynecol* 1985; 28: 375–80
17. Mashiach R, Canis M, Jardon K, et al. Adnexal torsion after laparoscopic hysterectomy: description of seven cases. *J Am Assoc Gynecol Laparosc* 2004; 11: 336–9
18. Bider D, Ben-Rafael Z, Goldenberg M, et al. Pregnancy outcome after unwinding of twisted ischemic hemorrhagic adnexa. *Br J Obstet Gynaecol* 1989; 96: 428–30
19. MacGowan L. Torsion of cystic or diseased adnexal tissue. *Am J Obstet Gynecol* 1964; 88: 135–6
20. Reich H, DeCaprio J, McGlynn F, Taylor PJ. Laparoscopic diagnosis and management of acute adnexal torsion. *Gynaecol Endosc* 1992; 2: 37–8
21. Wagaman R, Williams RS. Conservative therapy for adnexal torsion. A case report. *J Reprod Med* 1990; 35: 833–4
22. Oelsner G, Cohen SB, Soriano D, et al. Minimal surgery for the twisted ischaemic adnexa can preserve ovarian function. *Hum Reprod* 2003; 18: 2599–602

Part 3
Uterine and pelvic floor pathology

akusherlib.ru

akusher-lib.ru

Laparoscopic repair of wide and deep uterine scar dehiscence following cesarean section

O Donnez, P Jadoul, J Squifflet, J Donnez

INTRODUCTION

Cesarean section is the most commonly performed surgery in obstetrics, and its incidence is on the increase with rates as high as 17–25% in some countries¹. In certain cases, resulting scar dehiscence may lead to uterine rupture during pregnancy and delivery procedures, with ensuing maternal and fetal morbidity. Nevertheless, in 1997, the Clinical Audit Unit of the Royal College of Obstetricians and Gynaecologists (RCOG) recommended that women who have previously had a cesarean section should be actively considered for subsequent vaginal delivery². Following cesarean section, the risk of uterine rupture in women with previous vaginal delivery is low (<1%) when labor is induced³. However, without prior vaginal delivery, the risk of uterine rupture is likely to be between 1 and 5%, and is unlikely to be reduced by the use of modern technologies. Moreover, cesarean scar dehiscence can be a site for developing extrauterine pregnancy. In such cases, uterine rupture can be prevented by a medical approach or surgical procedures⁴. Extrauterine pregnancy in a dehiscent cesarean scar has also been described after embryo transfer in the case of *in vitro* fertilization⁵.

Vaginal or laparoscopy-assisted vaginal approaches can be undertaken for the repair of suspected scar dehiscence following cesarean section⁶. Here we report a hitherto undescribed technique of cesarean scar dehiscence repair done exclusively by laparoscopy, following diagnosis of the scar dehiscence by magnetic resonance imaging (MRI), ultrasound and hystero-graphy.

CASE 1

A 31-year-old woman underwent a cesarean section for her first pregnancy, followed by two miscarriages treated by dilatation and aspiration. She experienced 1 year of secondary sterility and metrorrhagia before she was referred to our department by her gynecologist. Hystero-graphy was then performed, revealing a septate uterus with synechiae in the right uterine horn and a large scar at the level of the cesarean section incision (Figure 19.1). Ultrasonographic evaluation showed the thickness of the anterior uterine wall to be less than 1 mm at the site of the cesarean scar. Hystero-graphic examination of the cavity revealed a uterine septum and extensive cesarean scar dehiscence. Chocolate liquid was visible in the scar, highly suggestive of the retention of old menstrual blood. As shown in Figure 19.2a and 19.2b, MRI allowed us to

confirm the presence of scar dehiscence on the anterior uterine wall. The thickness of the lower uterine segment, which was less than 1 mm, was observed on sagittal and transverse images of the MRI scan. A hyperintensive signal on T2-weighted and T1-weighted images with saturation of fatty tissue could be seen, suggestive of menstrual blood retention in the cesarean scar (Figure 19.2c). Hystero-graphy allowed us to visualize the dehiscence of the cesarean scar running along the entire breadth of the anterior uterine wall, and to confirm the presence of residual hematometra (Figure 19.2d).

CASE 2

A 31-year-old woman underwent a cesarean section at 38 weeks for fetal reasons. Ultrasound at a further consultation revealed a very thin lower uterine anterior wall, less than 1 mm thick. As shown in Figure 19.3a, hystero-graphy revealed the presence of wide dehiscence of the anterior uterine wall at the level of the cesarean scar. As observed in Figure 19.3b and 19.3c, the depth of the dehiscence could be seen in sagittal and transverse views of T2-

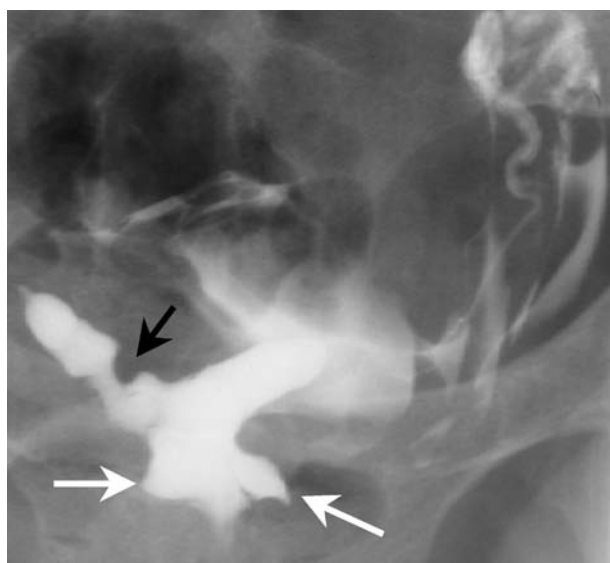


Figure 19.1 Hystero-graphy after cesarean section revealed a septate uterus with synechiae in the right uterine horn (black arrow) associated with a wide and deep scar at the level of the subisthmic incision (white arrows)

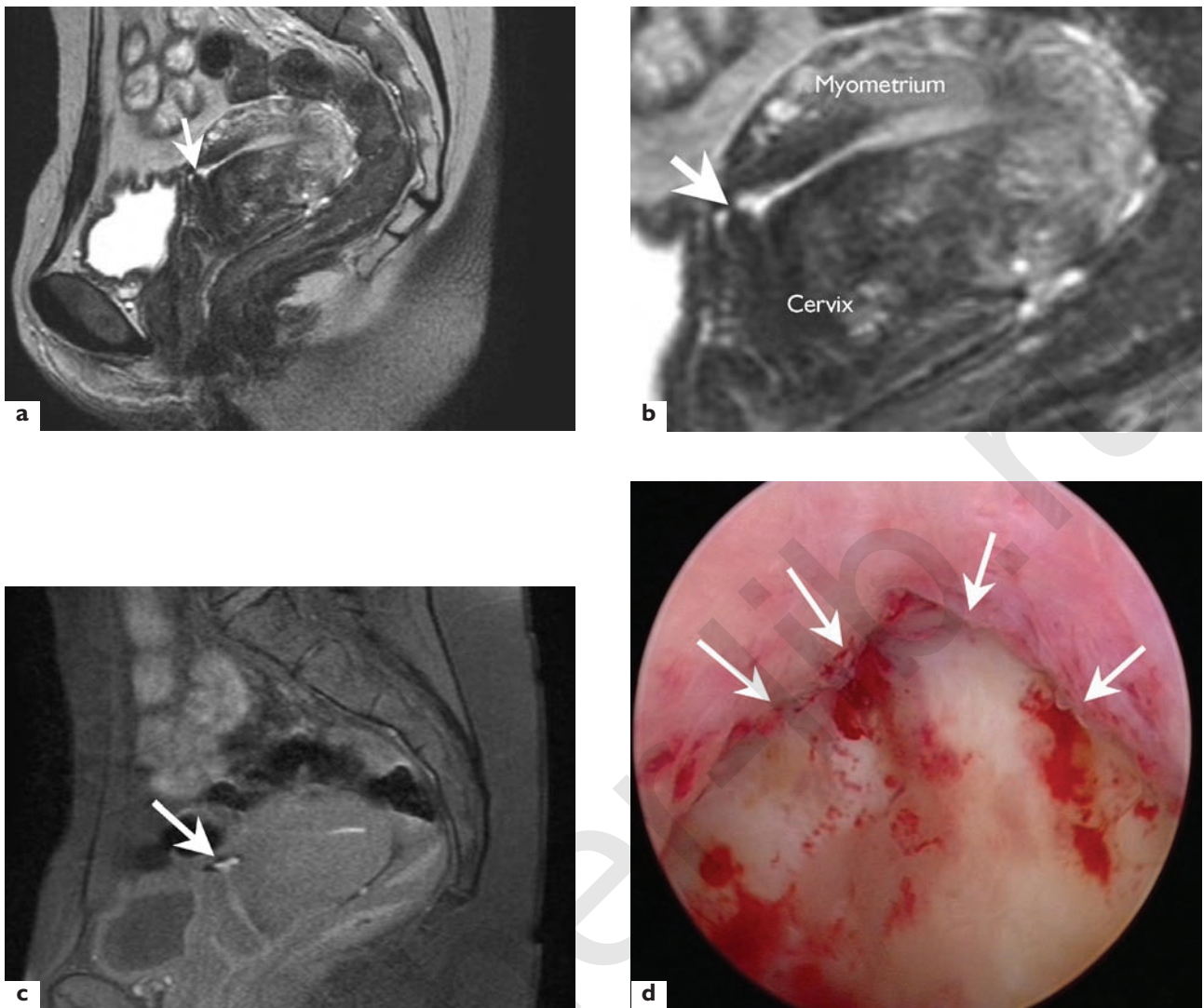


Figure 19.2 (a) and (b) Magnetic resonance imaging (MRI) showing the thickness of the anterior uterine wall (white arrow), highly suggestive of a wide and deep dehiscence cesarean scar. MRI evaluates the residual thickness between the dehiscence scar and the peritoneum at less than 1 mm. (c) Sagittal view of the lower uterine part in T1-weighted image with fatty tissue saturation. Hyperintense signal (white arrow) is highly suggestive of old blood retention in the cesarean scar dehiscence. (d) Hysteroscopic view of the scar dehiscence (white arrows)

weighted images. As in case 1, a hyperintense signal on T1-weighted images with saturation of fatty tissue could be seen in the uterine cavity and the cesarean scar (Figure 19.3d). This hyperintense signal is highly suggestive of old blood retention. Hysteroscopic evaluation of the cervix and the subisthmic area allowed us to evaluate the width of the dehiscence. In Figure 19.3e, we can see the presence of old blood retention in a large scar opened from side to side.

SURGICAL TECHNIQUE

Laparoscopic repair was therefore proposed to the patients, after having explained the risk of uterine rupture

in the case of a subsequent pregnancy if the dehiscence scar was not repaired. A Foley catheter was placed in the bladder in order to ensure an empty bladder throughout surgery. Operative hysteroscopy was then performed in both cases to visualize the dehiscence from the cervix. It allowed us to treat the uterine septum observed in case 1. We used a Nd : YAG (neodymium : yttrium–aluminum–garnet) laser to perform hysteroscopic septoplasty, as previously described⁷. In both cases, laparoscopy revealed a normalized uterus associated with normal adnexa. As observed in Figure 19.4a, the cesarean scar was easily distinguishable. A probe was then inserted through the cervix, into the dehiscence scar (Figure 19.4b). The peritoneum was then opened to separate the bladder from the anterior wall

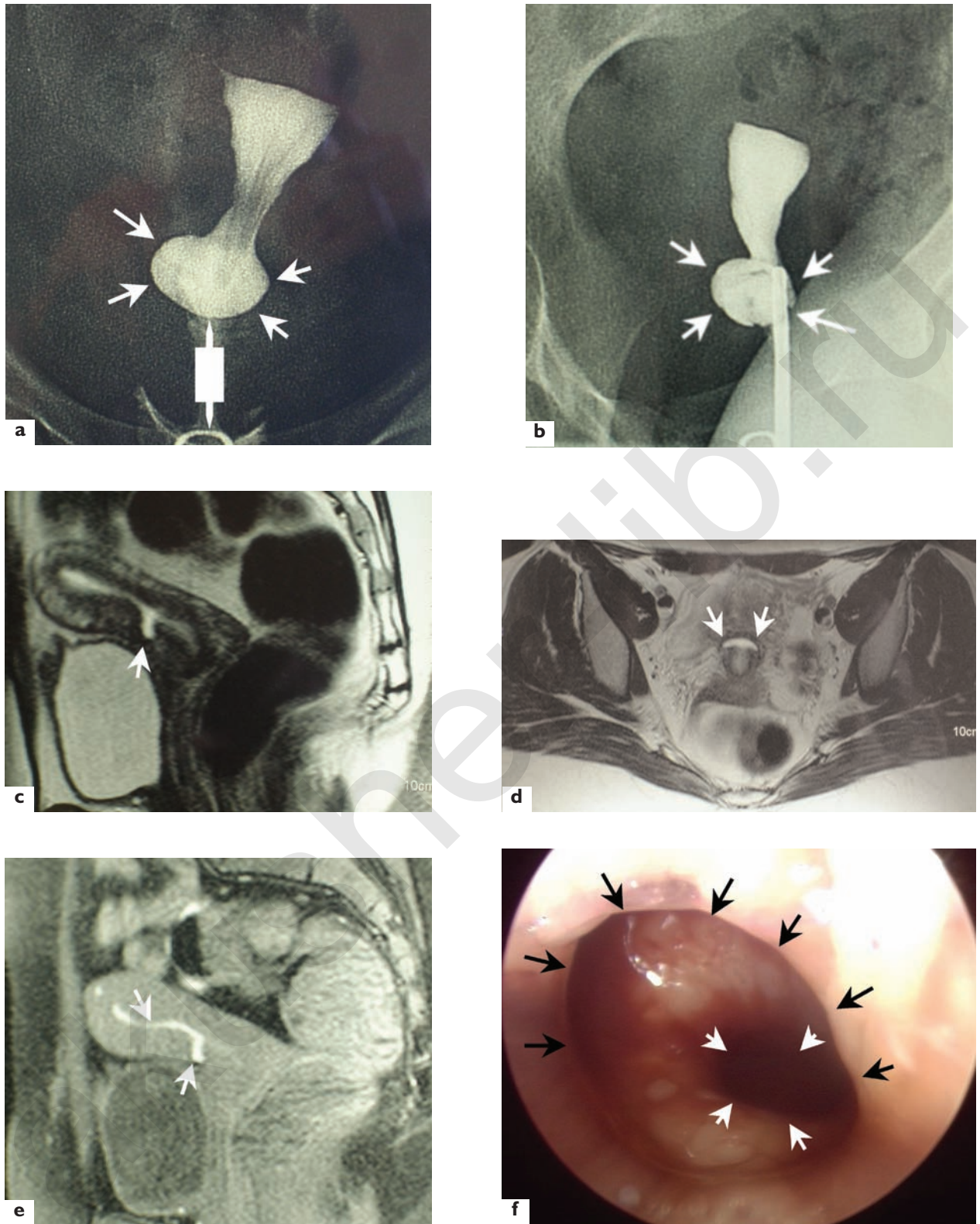


Figure 19.3 (a and b) In case 2, hysterocontrast sonography revealed wide dehiscence (white arrows) at the level of the cesarean scar. (c) and (d) Sagittal and transverse views (T2-weighted images) confirmed the ultrasound findings: the residual myometrium covering the dehiscence was very thin (white arrows). (e) As in case 1, a T1-weighted image with fatty tissue saturation revealed a hyperintensive signal (white arrows), highly suggestive of old blood retention in the dehiscence scar and the uterine cavity. (f) Hysteroscopic view of the subisthmic area confirmed the presence of old blood retention in the scar. The dehiscence scar (black arrows) is visible from side to side in the anterior wall area. The beginning of the uterine cavity can be seen higher than the scar (white arrows)

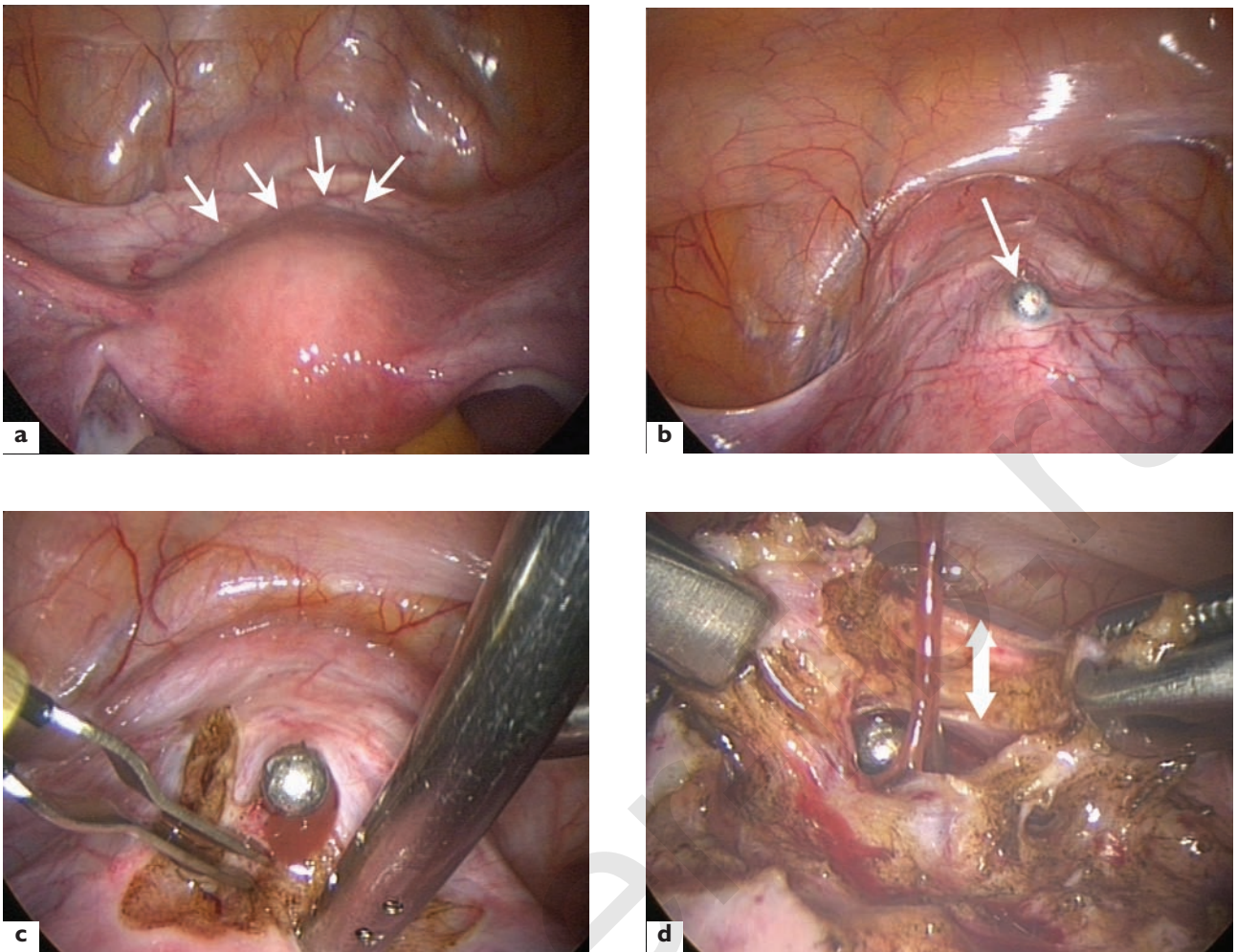


Figure 19.4 (a) The scar (white arrows) could be easily distinguished by a laparoscopic view. (b) A probe (white arrow) was inserted through the cervix into the dehiscent scar. (c) The peritoneum was opened using a CO₂ laser. The laparoscopic approach offered a wide-open view of the vesicovaginal space in order to perform safe dissection of the bladder. (d) The anterior uterine wall (white arrow) was composed of a thin layer of fibrotic tissue covered with peritoneum

safely (Figure 19.4c). The lower uterine segment was composed of only a thin layer of fibrotic tissue covered by peritoneum (Figure 19.4d). A laparoscopic approach gave us wide-open access to the vesicovaginal space, compared with the vaginal approach, and allowed us to avoid bladder injuries during surgery.

Using the CO₂ laser, we completely opened the scar from side to side. The fibrotic tissue was then excised from the edges of the cesarean scar to facilitate further healing. Special care had to be taken on the lateral side of the scar to avoid injury to the uterine blood vessels. The final view of the wide-open scar can be observed in Figure 19.5a. Before closing the scar, a Hegar probe was inserted into the cervix in order to preserve the continuity of the cervical canal to the uterine cavity (Figure 19.5b). Using Vicryl® 2-0SH+, two separate sutures were first placed on the two lateral sides of the scar (Figure 19.5c and 19.5d). The scar

was finally closed using two more 2-0 sutures, as shown in Figure 19.5e. The scar was then covered with peritoneum. The final view of the repair can be seen in Figure 19.5f. At the end of surgery, we performed hysteroscopy to visualize the repair from the cervical canal (Figure 19.6). It showed complete correction of the defect and normal permeability of the cervix. During these two surgical procedures, no complications occurred. The Foley catheter was removed the day after surgery and the two patients were discharged from hospital on day 1. We recommend waiting 3 months before attempting pregnancy. In the case of pregnancy, the lower uterine segment must be carefully monitored and cesarean section should be performed at 38 weeks of pregnancy to avoid the risk of uterine rupture.

Three months after surgery, hysterosalpingography revealed a uterine cavity with a normal supraisthmic area at the level of the cesarean section in both cases. The resec-

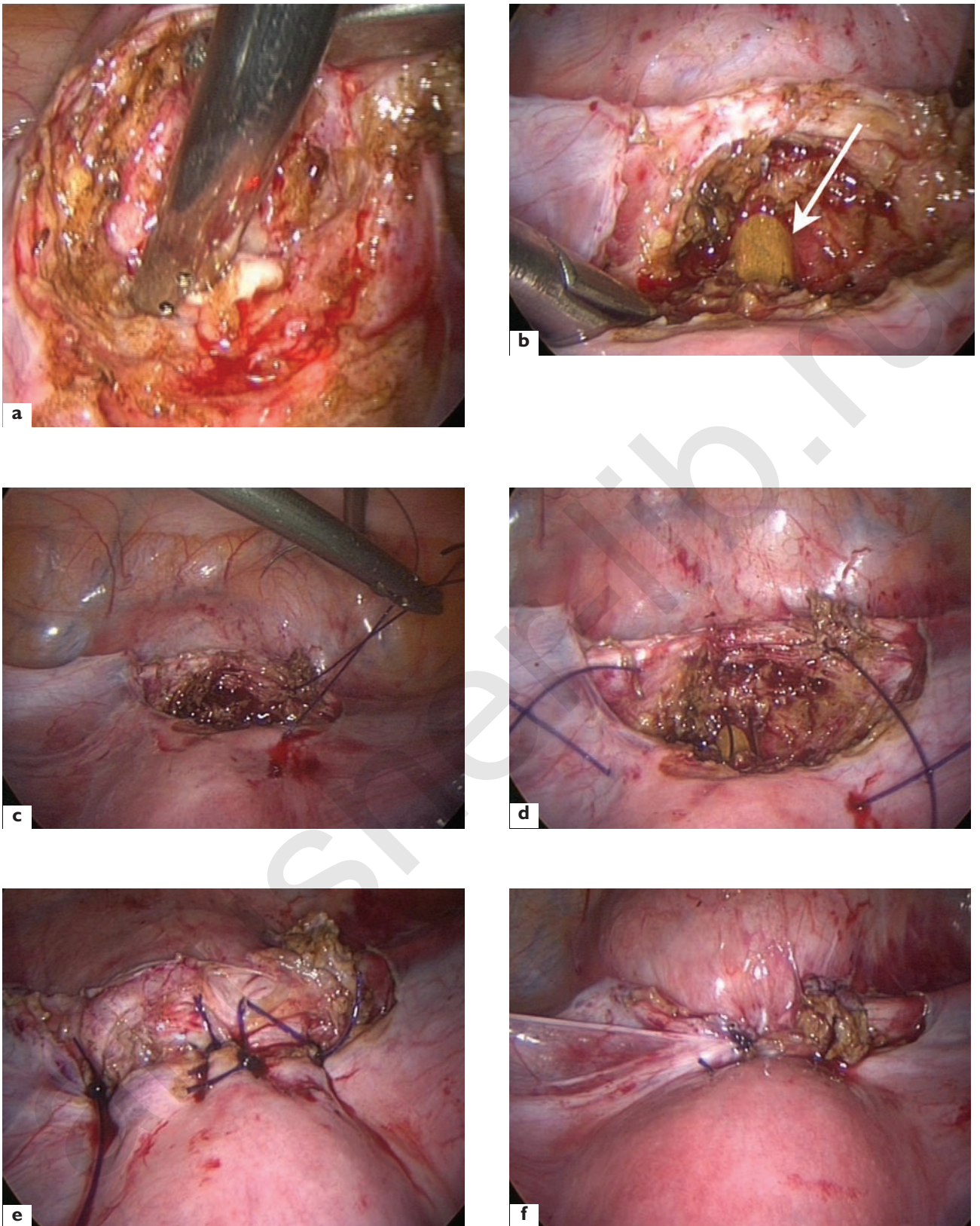


Figure 19.5 (a) Final view of the opened dehiscence after resection of the fibrotic tissue with use of the CO₂ laser. (b) A Hegar probe (white arrow) was inserted through the cervix to preserve the permeability of the cervical canal before performing the suture. (c) and (d) Two separate sutures were placed on each side of the scar. (e) The scar was finally closed with two more sutures. (f) A separate suture completed closure of the scar. Final view of the scar after covering it with peritoneum

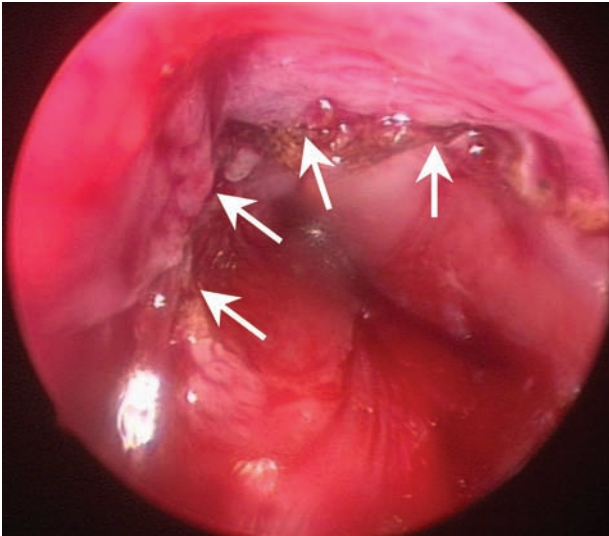


Figure 19.6 Hysteroscopic view of the scar after the suture was completed

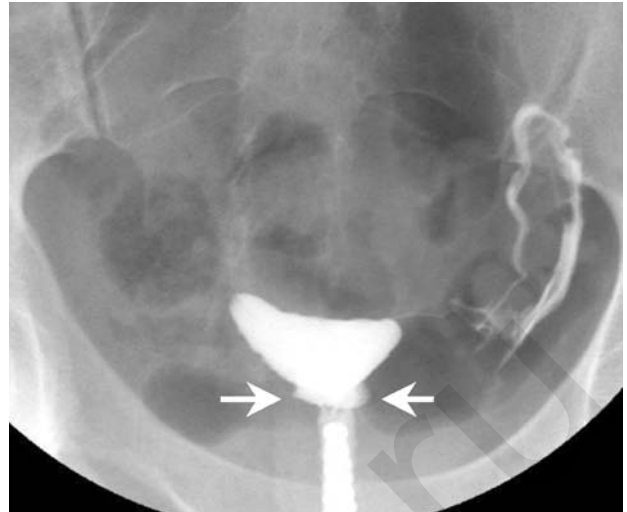


Figure 19.7 Three months after surgery, hysterography was performed in case 1. Resection of the septum and the depth of the cesarean scar were easily assessed and found to be wholly acceptable compared with the preoperative investigations. The uterine cavity was found to be normal and the dehiscence had disappeared

tion of the septum and depth of the cesarean scar were easily assessed in case 1, and found to be wholly acceptable compared with the preoperative investigations (Figure 19.7). The uterine cavity was found to be normal and the dehiscence had disappeared. Ultrasonographic evaluation of the lower uterine segment confirmed the integrity of the anterior uterine wall.

DISCUSSION

Uterine rupture remains the most feared complication of pregnancy and labor in women with previous cesarean delivery. Different imaging modalities, from hysterography to ultrasonographic evaluation, have been used to evaluate the integrity of the anterior uterine wall. Even if hysterography has not proved especially useful^{8,9}, we found that it provided good visualization of the depth and width of dehiscence at the level of the cesarean scar.

In the literature, ultrasonographic monitoring of the lower uterine segment during pregnancy has been described. The critical cut-off value for lower uterine segment thickness that allows trials of labor is 2.5 mm¹⁰. Ultrasonographic evaluation of a 1.5-mm lower uterine segment during pregnancy has a sensitivity of 88.9% and a negative predictive value of 96.2% in predicting a dehiscent lower uterine segment, suggesting that ultrasonography can potentially be used to predict the risk of uterine rupture during labor¹¹.

In these cases, the patients were not pregnant, and the lower uterine segment thickness was less than 1 mm using transvaginal ultrasonography in both women. MRI confirmed the thickness of the anterior wall and the

presence of old blood (hematometra) in the scar dehiscence, correlating with the hysteroscopic findings. In the literature, there is a lack of information on the ability of MRI to detect cesarean scar dehiscence. In our cases, ultrasonographic and MRI findings were found to concur with respect to lower uterine segment thickness, which was less than 1 mm. These findings were confirmed by laparoscopy, which revealed the presence of a very thin layer of fibrotic tissue covering the cesarean scar.

Schneider *et al.*⁶ used combined laparoscopic/vaginal as well as purely vaginal approaches to repair defects due to dehiscent cesarean scars in five patients. We report a hitherto undescribed laparoscopic technique. The laparoscopic approach offers an optimal view during dissection of the vesicovaginal space to separate the bladder from the anterior uterine wall safely and thereby avoid bladder injuries. Compared with laparotomy, the time to recovery is now widely recognized to be shorter with the laparoscopic technique. Hospital stay is also shorter. CO₂ laser was used to excise the fibrotic tissue in order to restore normal tissue to the edges of the wound. Then, a one-layer laparoscopic suture could be easily placed. The advantage of this technique is recovering the integrity of the anterior uterine wall, as confirmed by further ultrasonographic and hysterographic evaluation. In the case of subsequent pregnancy, special care has to be proposed to follow closely the measurement of the anterior uterine wall in order to prevent uterine rupture. cesarean section at 38 weeks should also be proposed.

CONCLUSION

Ultrasonographic evaluation of the anterior uterine wall is mandatory to evaluate the thickness of the lower uterine segment in a case of previous cesarean section, but, in the cases we describe, MRI provided an objective evaluation of the dehiscence scar. In the case of deep cesarean scar dehiscence with residual myometrial thickness of less than 2.5 mm, laparoscopic surgical repair may be proposed. We report a laparoscopic technique involving resection of the fibrotic tissue in order to restore normal tissue to the edges of the scar. After laparoscopic suture, evaluation of the repaired scar can be performed by ultrasonography and hysterosalpingography. In the present cases, no further dehiscence was visible. However, investigations such as follow-up of pregnancy and evolution of the anterior uterine wall are mandatory to evaluate the strength of the new scar tissue.

REFERENCES

1. Seffah JD. Re-laparotomy after cesarean section. *Int J Gynaecol Obstet* 2005; 88: 253–7
2. Benbow A, Semple D, Maresh M. *Effective Procedures in Maternity Care Suitable for Audit*. London: Royal College of Obstetricians and Gynaecologists, 1997: 34
3. Kayani SI, Alfirovic Z. Uterine rupture after induction of labour in women with previous cesarean section. *Br J Obstet Gynaecol* 2005; 112: 451–5
4. Godin PA, Bassil S, Donnez J. An ectopic pregnancy developing in a previous cesarean section scar. *Fertil Steril* 1997; 67: 398–400
5. Ito M, Nawa T, Mikamo H, Tamaya T. Lower segment uterine rupture related to early pregnancy by in vitro fertilization and embryo transfer after previous cesarean delivery. *J Med* 1998; 29: 85–91
6. Klemm P, Koehler C, Mangler M, et al. Laparoscopic and vaginal repair of uterine scar dehiscence following cesarean section as detected by ultrasound. *J Perinat Med* 2005; 33: 324–31
7. Donnez J, Nisolle M. Endoscopic laser treatment of uterine malformations. *Hum Reprod* 1997; 12: 1381–7
8. Poidevin L, Bockner V. A hystero-graphic study of uteri after caesarean section. *J Obstet Gynaecol Br Emp* 1958; 65: 278–83
9. Bockner V. Hystero-graphy and ruptured uterus. *J Obstet Gynaecol Br Emp* 1960; 67: 838–9
10. Sen S, Malik S, Salhan S. Ultrasonographic evaluation of lower uterine segment thickness in patients of previous caesarean section. *Int J Gynaecol Obstet* 2004; 87: 215–19
11. Cheung VY. Sonographic measurement of the lower uterine segment thickness in women with previous caesarean section. *J Obstet Gynaecol Can* 2005; 27: 674–81

akusher-lib.ru

Laparoscopic myomectomy

J B Dubuisson, A Fauconnier

The indications for operative laparoscopy have expanded greatly over recent decades as its many advantages over laparotomy have been recognized. Myomectomy may be performed by laparoscopy in selected cases, particularly in subserous and interstitial myomas¹⁻⁴. At present, a large number of teams use laparoscopic myomectomy, proving that this technique has many advantages. Nevertheless, it is a difficult operation in some cases.

PREOPERATIVE EVALUATION

Preoperative detection and evaluation of the myomas should be particularly meticulous, because with the laparoscopic approach it is impossible to palpate the myometrium thoroughly. This preoperative work-up must include: abdominal and transvaginal ultrasonography with Doppler, and measurement of preoperative hemoglobin levels. Examination of the uterine cavity is performed by diagnostic hysteroscopy if submucous myomas are suspected at ultrasonography.

Abdominal and transvaginal ultrasound examination must include measurement of the diameters of the entire uterus (length, depth and width), the number of myomas and characteristics of the dominant myomas, i.e. their type (intramural, subserous or pedunculated), size and location (anterior, posterior, fundus, broad ligament or isthmus). It should also include measurement of the distance between the endometrium and the myoma⁵, and between the serosa and the myoma. Furthermore, it is important to include a systematic search for adenomyosis. Adenomyosis may modify the indication of myomectomy; also, cleavage of the myoma can be more difficult, with more bleeding^{6,7}. It is also fundamental to evaluate the vascularization of the dominant myoma, which may be responsible for abnormal bleeding during enucleation and suture. Doppler examination gives important information concerning the origin of the vessels irrigating the dominant myoma: right or left uterine artery, both uterine arteries or the ovarian arteries. In our experience, a left-side myoma is vascularized by the left uterine artery (or both uterine arteries), a right-side myoma by the right uterine artery (or both) and a fundic myoma may be vascularized by the uterine arteries but also by the ovarian arteries. A hypervascularized myoma will grow rapidly. Such information may play a role in determination of the operative strategy.

Diagnostic hysteroscopy must be performed in selected cases: menometrorrhagia, multiple myomas, suspected

intrauterine abnormalities at ultrasound and in infertile patients. Hysteroscopy allows the surgeon to differentiate between a deep interstitial myoma and a submucous myoma or a polyp. Comparison of the results of ultrasound and hysteroscopy is important to determine the operative strategy.

Magnetic resonance imaging (MRI) is mandatory when the ultrasound examination is difficult to analyze and in cases of associated adnexal pathology, e.g. a suspected ovarian cyst. Hysterosonography might be useful for evaluating the relationship between the myomas and the uterine cavity⁸.

In all cases, it is important to obtain good information with the minimum of exploration for both psychological and economic reasons.

In infertile patients, the investigation should be completed by including a hysterosalpingogram, a study of ovarian function (monthly temperature curve; levels of anti-Müllerian hormone, follicle stimulating hormone, luteinizing hormone and estradiol) and analysis of the partner's semen. In the presence of an associated male or ovulatory factor, the postoperative fertility results are poor⁹, and in these cases the perioperative and postoperative strategy should be carefully discussed.

A blood count and serum ferritin test provide information regarding whether to give oral iron (see section below on 'Preoperative treatment'), particularly in patients with menometrorrhagia.

PREOPERATIVE TREATMENT

The correction of sideropenic anemia by giving oral iron is essential in order to reduce the risk of blood transfusion. In some cases it is necessary to postpone laparoscopic myomectomy, until the blood count has been normalized.

Gonadotropin-releasing hormone agonists (GnRH) agonists cause myoma shrinkage by reducing the circulating estrogen levels¹⁰. The maximal reduction of myoma size is achieved by 12 weeks of therapy, with no further change observed after 24 weeks of treatment¹¹. Matta *et al.*¹² observed that GnRH agonists reduce uterine blood flow.

In patients undergoing laparoscopic myomectomy, preoperative treatment with GnRH agonists may have controversial effects. A marked reduction in blood loss during laparotomic myomectomy has been demonstrated¹³. During laparoscopic myomectomy, the preoperative use of GnRH agonists also had the advantage of

reducing blood loss in two studies^{14,15}. However, in our experience, we have found that preoperative treatment with GnRH agonists (whatever the duration of treatment) increases the risk of conversion⁵. We consider, with others^{16–18}, that preoperative treatment with GnRH agonists may increase the difficulties in identifying and dissecting the cleavage plane between the myoma and its pseudocapsule. In addition, their use could increase the risk of recurrence of myoma¹⁹ by making it more difficult to detect small intramural nuclei perioperatively. In our opinion, preoperative use of GnRH agonists should only be made in the case of sideropenic anemia in a bleeding patient^{20,21}. However, these cases are usually selected for laparotomy because of the presence of a large and polymyomatous uterus.

INDICATIONS FOR OPERATIVE LAPAROSCOPY

The indications depend on the number, size, type and localization of myomas. Analysis of the main published series of laparoscopic myomectomy shows that the operation is used for medium-sized myomas (about 5 cm) which are relatively few in number (one or two per patient)²².

The number of myomas may be a problem during operative laparoscopy. In our opinion, this procedure should not be attempted when more than two or three myomas are present at ultrasound investigation, for several reasons. First, the conversion rate increases with the number of myomas²³. Second, in our experience, operative time and difficulties increase with the number of myomas, leading to strain on the surgeon. Third, when myomas are numerous, ultrasound investigation might underestimate the true number of myomas.

We recommend that laparoscopic myomectomy should only be performed for myomas not exceeding 8–10 cm^{22,24,25}, although other teams have far higher limits, indeed up to 15 cm^{26,27}. Difficulties increase with myoma size for many reasons: the biggest myomas will have a highly distended perimyomatous vascularization due to compression by the myoma^{16,28,29}; the growth of certain myomas results in reorganization of the myomatous tissues and neighboring myometrium, making the attachments of the myomas difficult to cleave; the time required for laparoscopic myomectomy increases with the size of the myoma²²; and, finally, the large dimensions of the myoma can cause a lack of operating space. In fact, the upper limit that should be proposed depends mostly on other characteristics including those of the myomas (location, depth of penetration)⁵ and the patient (body mass index, pelvic adhesions).

Subserous and interstitial myomas are an indication for elective operative laparoscopy. Although the ablation of an entirely submucous myoma must be performed by operative hysteroscopy when its diameter is less than

4–5 cm, cases of deep intramural myoma with a submucosal component are difficult to treat by this method, and usually require repeat procedures^{30,31}. Cases of medium-sized (4–7 cm) myomas involving the uterine cavity appear to be easy to treat by the laparoscopic approach⁵, thus providing an interesting alternative to hysteroscopic resection. On the other hand, in cases where an entirely submucous myoma of small diameter (2–3 cm) is associated with other subserous or interstitial myomas, the submucous myoma is treated first by operative hysteroscopy. Laparoscopic treatment of the other myomas is discussed later, and depends on the efficacy of operative hysteroscopy to treat the symptoms (menorrhagia, infertility). We rarely associate operative hysteroscopy with operative laparoscopy, because operative hysteroscopy provokes distension of the uterus which may cause bleeding during hysterotomy and enucleation. Totally transmural myomas (submucous myoma reaching the serosa) should also be treated by laparoscopy.

An anterior location of the dominant myoma increases the difficulties and conversion rate^{5,24}. This may be explained by the fact that the anterior wall of the uterus is less accessible to the operating trocars when the myoma is large. This is particularly true for the step of hemostasis and suturing. It is difficult to close an anterior hysterotomy. Indeed, the curved needles have to penetrate through the myometrium perpendicularly to ensure a good approximation and hemostasis. Myomas situated in the broad ligament or at the uterine isthmus can also be treated by operative laparoscopy, taking care not to damage the ureters and the uterine vessels.

OPERATIVE TECHNIQUE

Technical principles

The main complications with this operation, as with myomectomy by laparotomy, are the risk of perioperative hemorrhage and the risk of postoperative adhesions. The use of the laparoscopic access for the myomectomy also raises particular problems; bloodless enucleation of the myomas is absolutely essential for a clear view and to continue the procedure. As for laparotomy, a perfect suture must be achieved to obtain a good-quality scar. Hence, use of the technique of laparoscopic myomectomy is based on several basic principles:

- (1) The principles of atraumatic surgery must be applied to laparoscopic myomectomy to avoid iatrogenic lesions of the other pelvic organs (ovary, tube, bowel).
- (2) To avoid perioperative hemorrhage during enucleation and suture of the hysterotomy of hypervascularized myomas, we consider that preventive occlusion of the uterine artery which vascularizes the myoma, using a clip, is mandatory. One or two

uterine arteries may be involved, according to the preoperative Doppler examination³².

- (3) With laparoscopic myomectomy, each myoma must be excised via its own hysterotomy: it is not possible to use the same incision to remove all the myomas as in laparotomy^{33,34}. Indeed, a long anterior sagittal hysterotomy is too hemorrhagic, and takes too long to suture by laparoscopy.
- (4) Dissection must take place in every case along the cleavage plane separating the myoma from the adjacent myometrium. This cleavage plane is bounded by a pseudocapsule made up of compressed muscular fibers and diverted uterine vessels^{16,29}. This allows healthy adjacent myometrium to be preserved, and damage is avoided to the perimyomatous vessels which are often distended due to compression by the myoma²⁸, and could be the origin of considerable hemorrhage.
- (5) Electrocoagulation must be used as sparingly as possible to achieve hemostasis of the edges after myomectomy. Certain cases of uterine rupture during pregnancy reported after laparoscopic myomectomy^{35,36} and after myolysis³⁷ suggest that the use of electrocoagulation may induce necrosis of the myometrium, resulting in a postoperative fistula or in a low-quality scar.
- (6) Suture of the hysterotomy must always respect a certain number of principles. Indeed, any technical deficiency when carrying it out may result in uterine rupture during a subsequent pregnancy³⁵. Apart from pedunculated myomas or a subserosal myoma with a small implantation surface (<1 cm²), myomectomy sites must always be sutured. In the experience of certain teams at the beginning, when no suture was carried out, the resulting scars were fine or dehiscant^{4,27}. The uterine suture uses one or two planes, but must always take up the full depth of the edges of the hysterotomy and result in total contact over the whole of the myomectomy defect in order to avoid secondary constitution of a hematoma. This kind of hematoma can cause weakness in the scar tissues and the constitution of a secondary fistula^{27,38}. When the uterine cavity has been opened or when the myomectomy defect is deep it is necessary to make a suture in two planes³⁹⁻⁴¹. However, if this is difficult, there should be no hesitation in using laparoscopic-assisted myomectomy to complete it successfully. This procedure is an alternative, between laparotomy and laparoscopic myomectomy: laparoscopy is used to perform myoma(s) exposure and to begin or achieve enucleation; the uterine suture is then carried out by minilaparotomy in a traditional fashion^{42,43}. The myoma is then removed by minilaparotomy.

Instrumentation

In addition to the standard instrumentation for any operative laparoscopy, certain specific instruments are useful when carrying out laparoscopic myomectomy. A monopolar needle enables incision of the myometrium. Curved scissors enable section of the tracts between the myoma and myometrium. Other instruments are useful when making the intra- or extracorporeal sutures: needle holders, atraumatic forceps with no slot or claws and a suture pusher. A strong, grasping, 10-mm forceps (tenaculum or claw forceps) is useful for performing efficient traction during enucleation. High-frequency electro-surgical generators are employed.

Ideally, an electric morcellation device such as the Steiner™ morcellator (Storz, Germany) or the Gynecare X-tract™ morcellator (Ethicon, USA) allows large myomas to be extracted using a 12- or 15-mm suprapubic port. Such a device has proved easy to use after a certain learning phase, and reduces operation times⁴⁴.

Installation

The patient lies with thighs spread, with abduction providing access to the vagina, and buttocks protruding generously over the edge of the table in order to be able to manipulate the uterus with an intrauterine cannula. The main surgeon stands to the patient's left with the first assistant opposite, and the second assistant between the patient's legs.

In infertile patients with no previous tubal investigation, an injection of diluted methylene blue into the uterine cavity is useful to confirm tubal patency and enable the endometrium to be identified during surgery. The uterus is then cannulated, enabling it to be manipulated during the operation for anteversion, retroversion and also rotation.

Laparoscopy can be performed transumbilically or 2 cm supraumbilically depending on the uterine size. Two 5-mm lateral trocars and one 12-mm midline trocar are inserted suprapubically. The position of the trocars should be adapted whenever possible to the size and location of the myomas. Generally speaking, the two lateral trocars should be placed high and outside the epigastric vessels so that good access is provided to myomas in various locations, and to ensure that the surgeon has sufficient operating space for movement when performing enucleation or carrying out the sutures.

Description of the operative technique

The technique of laparoscopic myomectomy that we use in our institutions^{32,45} comprises four main phases, schematically speaking: hysterotomy and revelation of the myoma; enucleation; suture of the myomectomy site; and extraction of the myoma.

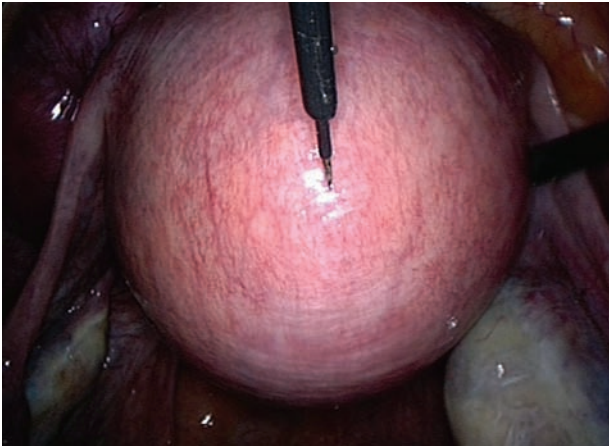


Figure 20.1 Hysterotomy of a posterior intramural myoma

Incision of the myometrium and exposure of the myoma

The hysterotomy is direct, lined up with the myoma. In the case of a posterior myoma, we use sagittal hysterotomies. In the case of an anterior myoma, we tend to use oblique hysterotomies because they are easier to suture. The myometrium is incised with a laparoscopic needle using a low-voltage monopolar current in cutting mode in order to safeguard the myometrium as far as possible (Figure 20.1). Hemostasis of the intramyometrial vessels is carried out progressively, using a bipolar forceps. The myoma is easy to recognize by its smooth appearance and pearly white color, which contrasts with the adjacent myometrium (Figure 20.2).

Enucleation (Figure 20.3)

Dissection of the myoma should run inside the avascular plane surrounding the myoma, leaving the pseudocapsule around the outside and the uterine vessels pushed back. Identification of this avascular plane is assisted by the magnifying effect of the laparoscopic images (Figure 20.3). The myoma is grasped with a strong 10-mm grasping forceps designed specifically for myomas (with claw or tenaculum), and pulled hard towards the anterior abdominal wall or upwards; at the same time the surgeon or his assistant exerts traction in the opposite direction using the endouterine cannula, or by pushing on the edges of the hysterotomy with an instrument. This dissection proceeds from the superficial areas inwards, and always under visual control in order to identify the fine tracts adhering to the myoma (Figure 20.4). The tip of a blunt instrument is used to press against the myoma. The tracts adhering to the myoma are coagulated, then sectioned. The bed of the myomectomy is most often free from hemorrhage at the end of dissection, if care has been taken to follow the avascular cleavage plane, and there is no need to take further steps for hemostasis.

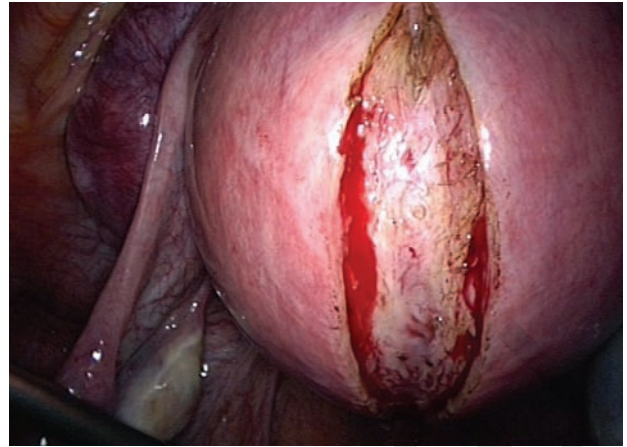


Figure 20.2 Visualization of the myoma after opening of the pseudocapsule

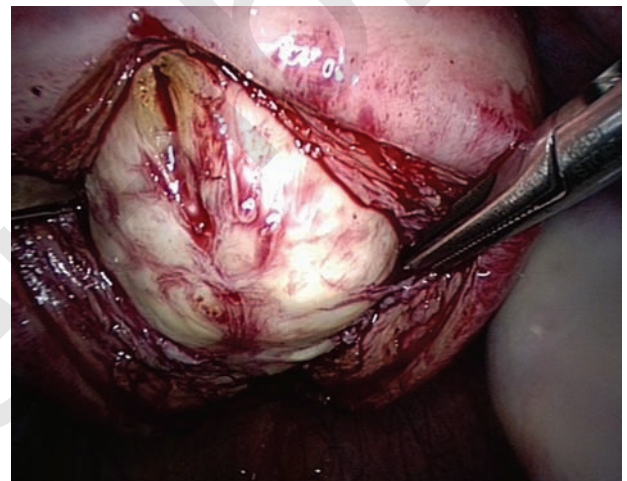


Figure 20.3 Enucleation of the myoma

Hysterotomy suture (Figures 20.5 and 20.6)

We use fine resorbable suture, diameter 00 or 0 gauge, mounted on a curved needle with an atraumatic tip (Vicryl® (polyglactin 910); Ethicon). In the case of a subserosal myoma, the suture is usually carried out in a single plane. We use single, separate intracorporeal knots. The stitches go through the whole thickness of the edges of the hysterotomy, and through the uterine serosa. They are placed sufficiently close for the edges to be approximated completely, yet far enough apart to avoid making the myometrium too fragile (Figure 20.6). When the myomectomy is located deeply, or the uterine cavity has been opened, two planes are performed. We suture along a deep plane with a few single stitches deep in the myometrium, and along a superficial plane taking in the serosa and the superficial part of the myometrium. The superficial plane can be dealt with using a running suture or with individual stitches. When suturing the deep plane,

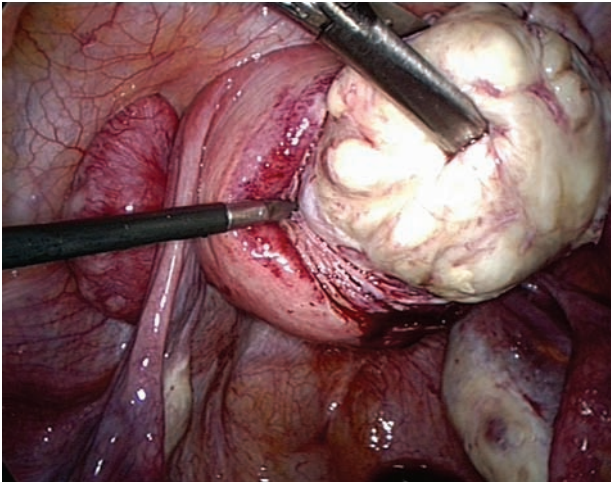


Figure 20.4 End of the myomectomy

it can sometimes be difficult to take the needle through the thickness of the defect. In this case it can be an advantage to use Vicryl 1 with a large curved needle, and to perform a U-shaped transfixing stitch²⁷, running through the uterine serosa and taking in the whole thickness of the edges of the myomectomy. One or two of these stitches are sufficient to ensure that all the deep part of the hysterotomy is brought into contact. When the uterine suture proves difficult to carry out it is essential to know when to stop and use a minilaparotomy for the suture. We recommend, in particular, its use for large anterior or deep intramural myomas.

Extraction of myomas

There are various methods for extraction: direct suprapubic extraction; electric morcellation; and extraction via posterior colpotomy.

Direct suprapubic extraction is appropriate only for small myomas. Extraction takes place through the midline suprapubic incision which may be enlarged (>2 cm). If needed, a manual morcellation is carried out: with one or two single-tooth tenaculums, the myoma is brought up to the suprapubic incision and held against the peritoneum to prevent loss of CO₂ and then fragmented under laparoscopic control, using a small blade passed through the incision.

Electric morcellation is carried out with the use of an electrical morcellator (see above, 'Instrumentation'). This device is an external rotating cylindrical blade that is introduced via a 12- or 15-mm suprapubic trocar. A forceps with 10-mm jaws is inserted through the morcellator channel to grasp the myoma and cut it progressively, like peeling an orange. The position of the rotating blade must be carefully controlled in order to avoid any risk of damaging any neighboring organs.

Posterior colpotomy also allows large myomas to be extracted⁴⁶. The colpotomy may be performed by

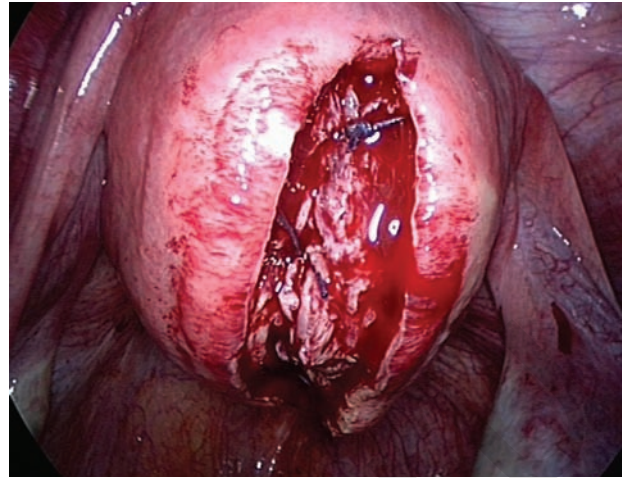


Figure 20.5 Uterine suture: first layer using separate stitches

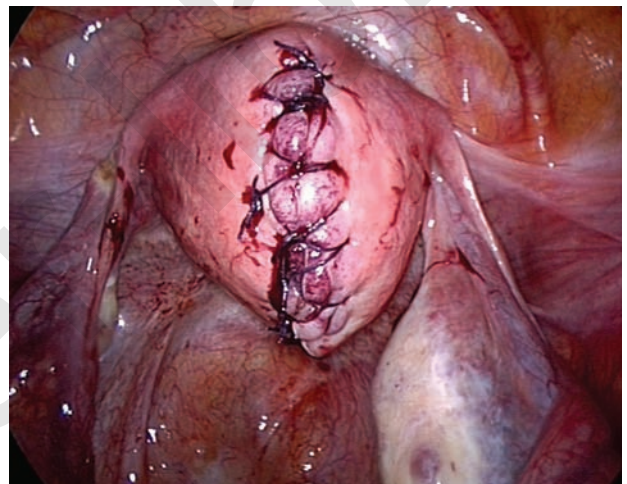


Figure 20.6 Final result

laparoscopy using the monopolar needle, or conventionally through the vagina. The myoma is then grasped with a forceps with 10-mm jaws, inserted through the colpotomy under laparoscopic control. The myoma is extracted vaginally either directly or after morcellation. In the case of large or numerous myomas, the CCL vaginal extractor (Storz, Germany) is useful to prevent leakage of gas.

Preventive uterine artery occlusion combined with laparoscopic myomectomy

In highly vascularized myomas, it is important to limit blood loss during myoma enucleation and myometrium suture. Before 2001, in some cases of excessive bleeding during laparoscopic myomectomy, we had to perform the occlusion of one or two uterine arteries during the procedure to stop the hemorrhage. The decrease in bleeding after uterine artery occlusion was clinically evident. The combined procedure allowed us to carry out

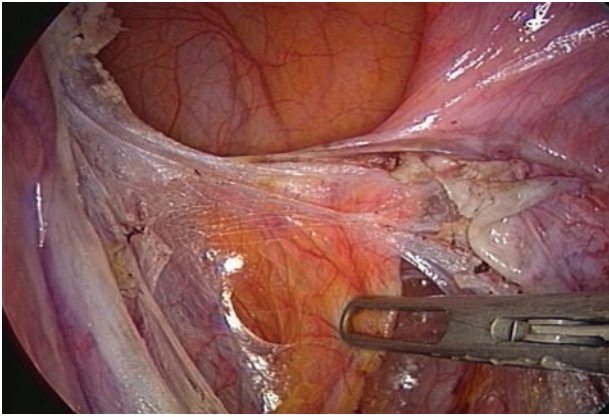


Figure 20.7 Preventive occlusion of the uterine artery before hysterotomy: dissection of the right broad ligament

the end of the myomectomy by laparoscopy without any complication. This prompted us to perform a comparative study in order to demonstrate the advantages of this combined procedure³². Now, in the case of a highly vascularized myoma of more than 6 cm, we systematically perform, at the beginning of laparoscopy, uterine artery occlusion on either one or both sides according to the information given by Doppler ultrasonography. This procedure is not indicated when the myoma is poorly vascularized or has a typical aspect of necrobiosis at ultrasonography or at laparoscopy. There is no indication when the myoma is exclusively vascularized with the ovarian vessels. This procedure is not feasible when the myoma is too large and fixed, with no access to the uterine arteries before the myomectomy.

Broad ligament access to the uterine artery (Figures 20.7 and 20.8) Before the myomectomy, we perform a 3-cm incision of the peritoneum with scissors on the upper part of the broad ligament, behind the round ligament. The umbilical artery is then dissected and followed until the origin of the uterine artery is reached. The origin of the uterine artery is then dissected from the uterine veins. Inside the artery the ureter is also visualized, adherent to the peritoneum. To occlude the artery, one or two non-absorbable clips (titanium Ligaclip™, Storz) are placed at its origin. The hemostasis of small vessels is performed if necessary. A few minutes after the occlusion, the myoma turns white before the uterus (Figure 20.9). At the end of the laparoscopic myomectomy, the peritoneum of the broad ligament is closed using a 00 Vicryl running suture. The same procedure is performed on the other broad ligament if necessary. Then the hysterotomy is performed.

Posterior access to the uterine artery (Figures 20.10–20.15) The occlusion of the uterine artery may be performed using a posterior access (Figures 20.10–20.15). The uterus is pulled hard towards the anterior abdominal wall using the intrauterine cannula. On the chosen side, the uterine artery is visualized under the peritoneum at the inferior

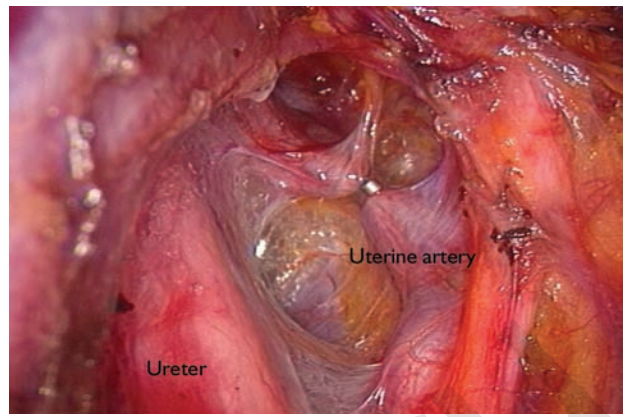


Figure 20.8 Dissection of the right uterine artery after visualization of the right ureter

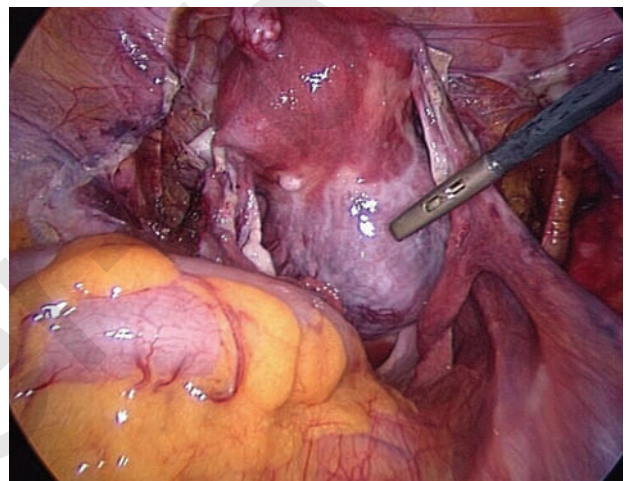


Figure 20.9 Immediate aspect of the uterus after occlusion of the uterine arteries: the myoma turns white before the uterus

area of the posterior leaf of the broad ligament, close to the uterus, just above the origin of the homolateral uterosacral ligament. The ureter is also visualized under the pulsating artery. A 1-cm direct incision of the peritoneum gives immediate access to the uterine artery. One or two clips are then placed, with permanent control of the ureter located under the artery. This second procedure is very quick and easy to perform if access is possible. The peritoneum is then sutured with a 00 Vicryl single suture.

Second-look laparoscopy

A second-look laparoscopy should be proposed to patients desiring pregnancy and who have sutured uterine scars, in order to eliminate adhesions after myomectomy and to assess the strength of the uterine scar^{47,48}. The systematic use of second-look laparoscopy could reduce adhesions after myomectomy and consequently enhance fertility^{49,50}.

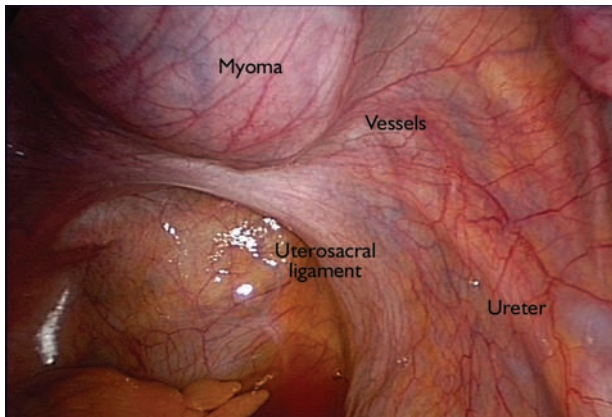


Figure 20.10 Posterior access to perform occlusion of the uterine artery

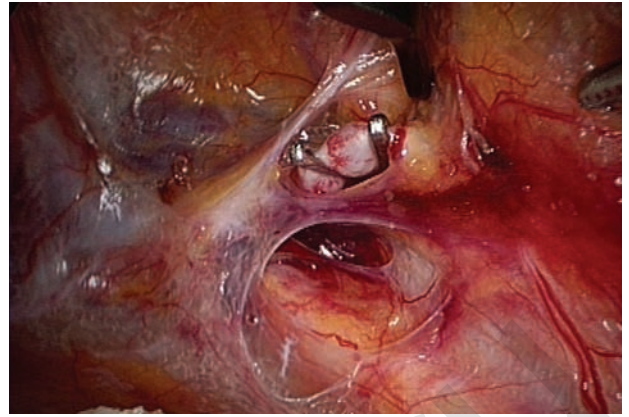


Figure 20.13 Clips are placed, with permanent control of the ureter which is under the artery

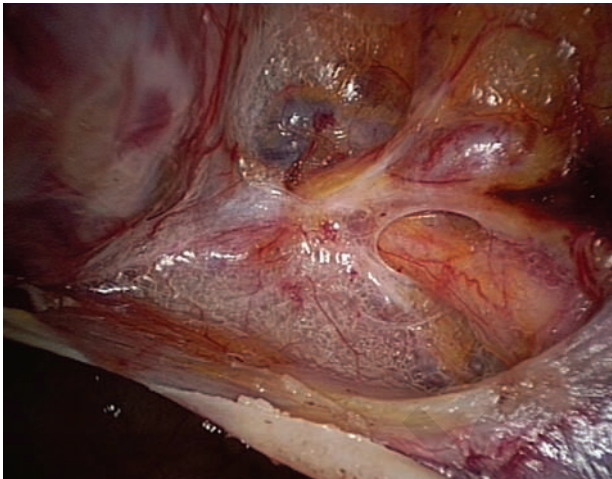


Figure 20.11 Dissection of the right uterine artery, visualized under the peritoneum

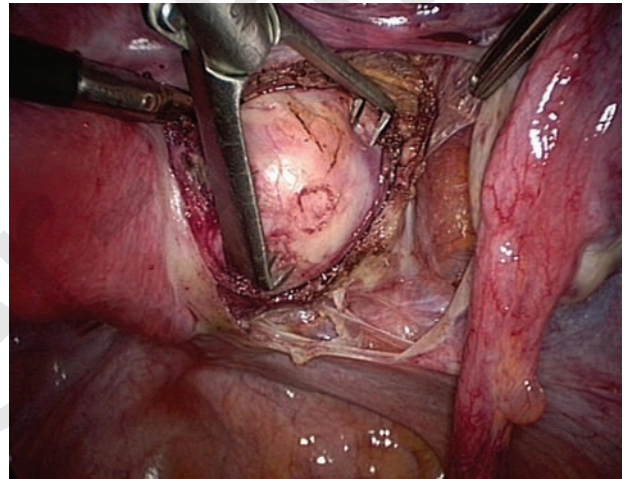


Figure 20.14 The myomectomy is then performed without any bleeding

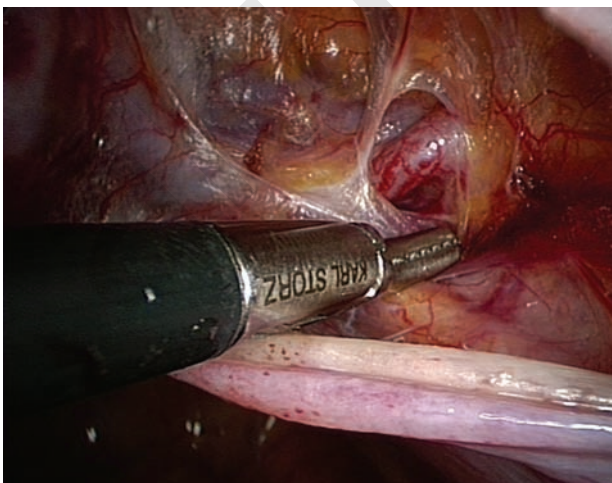


Figure 20.12 The uterine artery is individualized from the ureter

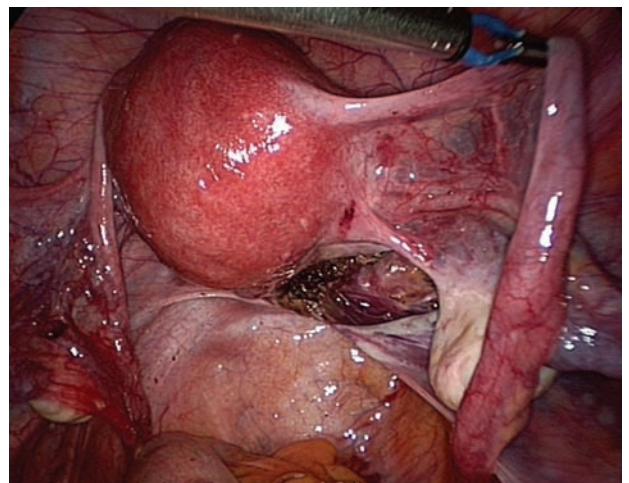


Figure 20.15 Final aspect after myomectomy

The thickness and quality of the hysterotomy scar is assessed on this occasion, using a methylene blue test. It is a useful guide for the management of future obstetric practice⁵¹. This procedure should take place 2 or 3 months after laparoscopic myomectomy to evaluate the uterine scar properly.

RESULTS

Conversion rate and operation time

The percentage of conversions to laparotomy reported in retrospective studies varies from 0 to 41%^{22,52}. In our experience with 426 laparoscopic myomectomies, the rate of conversion to an open procedure (either laparotomy or laparoscopic-assisted myomectomy) was 11.3%. Several independent factors were found to increase the risk of conversion: size of the dominant myoma at ultrasonography; anterior location; intramural type; or preoperative use of GnRH agonists⁵. Because of the difficulties in identifying the cleavage plane, the presence of an adenomyoma or associated adenomyosis make laparoscopic myomectomy very problematic²⁴. In one study where the use of laparoscopic myomectomy was not restricted to cases with a low number of myomas, the conversion rate was found to increase with the number of myomas²³.

The mean operation time is about 2 h for the main series published²². This could be considered to be rather long. Indeed, two controlled studies comparing laparoscopic myomectomy with myomectomy by laparotomy^{53,54} found an increase in operation time when it was carried out by the laparoscopic route. The size and depth of penetration in the myometrium of the dominant myoma are the most important parameters to consider. In the case of large, deeply infiltrating myomas, the time will increase with enucleation, suturing and morcellation. The surgeon must also take into account his/her own experience.

We consider that the initial occlusion of one or two uterine arteries before hysterotomy in the case of a highly vascularized myoma limits the risk of conversion.

Risk of hemorrhage

Myomectomy itself has the reputation of being a hemorrhagic operation. However, use of the laparoscopic approach reduces the hemorrhagic risk connected with myomectomy. Indeed, in three controlled studies^{53–55} there was a significant reduction of the hemoglobin decrease connected with the use of laparoscopic myomectomy. The laparoscopic route presents two advantages over laparotomy in terms of limiting the hemorrhagic risk during myomectomy: the pressure of the pneumoperitoneum prevents blood extravasation from the

intramyometrial capillaries and veins, and the magnification provided by the laparoscope lens helps to identify the cleavage plane more precisely and enables selective coagulation of the small vessels feeding the myoma.

It can be useful to take certain steps to reduce perioperative bleeding. Meticulous preventive coagulation of the tracts connecting the myoma to the adjacent myometrium must be carried out²⁴. Preoperative use of GnRH agonists is efficient in reducing perioperative bleeding^{14,15}, but problems with their use have already been discussed (see above 'Preoperative treatment'). One author⁴¹ has proposed a technique for temporary hemostasis which can be used with laparoscopy (compression of the uterine pedicles at the isthmus, using a broad, single-strand suture). We have no experience of this technique. Infiltration of the adjacent myometrium with vasoconstrictive agents is very useful for limiting the bleeding. However, in several European countries the use of powerful vasoconstrictors such as vasopressin derivatives are not recommended because of the high risks of severe cardiovascular complications.

Postoperative course

Two randomized clinical trials have demonstrated that laparoscopic myomectomy has proven advantages compared with the laparotomic approach in terms of the postoperative course. The laparoscopic approach may offer the benefits of less postoperative pain and shorter recovery time in comparison with laparotomy⁵⁵. It also reduces the hospital stay and transient episodes of febrile morbidity⁵³.

Postoperative adhesions

There are several arguments suggesting that the laparoscopic approach reduces the risk of postoperative adhesions after myomectomy. In a non-randomized comparative study, Bulletti *et al.*⁵⁶ found a statistically significant decrease in the degree of postoperative adhesions and the proportion of patients with adhesions associated with the use of the laparoscopic route. In this study the potential confounding factors were taken into account, because a match was made for size, location and type of myoma. Furthermore, in retrospective studies with a systematic laparoscopic second-look after myomectomy, the percentage of patients presenting adhesions (wherever these were located) after laparoscopic myomectomy were 51.1% (95% confidence interval (CI) 42.6–59.6) and 89.6% (95% CI 84.5–94.8) after laparotomy. The proportions of patients presenting adnexal adhesions connected to the myomectomy scar were 30.5% (95% CI 21.3–39.8) after laparoscopic myomectomy and 68.9% (95% CI 58.4–79.5) after laparotomy²². Laparoscopic surgery offers the advantage of respecting the principles of microsurgery by its very nature (atraumatic manipulation, fine instruments, thorough washing). In addition, it avoids

intraperitoneal contamination and has less effect on the equilibrium of the peritoneum²⁵.

Obstetric quality of laparoscopic myomectomy scars

There is considerable debate concerning the strength of hysterotomy scars after laparoscopic myomectomy^{57,58} because of the possibility of uterine rupture during pregnancy after laparoscopic myomectomy. To date, six cases have been reported over a short period^{35–37,58–60}. All these cases of rupture occurred after small (3–5 cm), single myomas were removed, and quite remarkably they took place before labor actually began. However, it is difficult to draw any definite conclusions from these cases because it is not known how frequently this accident occurs: the cases are reported in isolation, without any indication of the number of pregnancies occurring after laparoscopic myomectomy.

The incidence of uterine rupture after laparoscopic myomectomy is probably low. Between 1989 and 1996 in our institution, the risk of uterine rupture specifically due to laparoscopic myomectomy was 1.0% (95% CI 0.0–5.5) among 100 deliveries after laparoscopic myomectomy⁵¹. Recently, a spontaneous uterine rupture occurred at 33 weeks subsequent to previous superficial laparoscopic myomectomy³⁷. This case report confirms that it is difficult to evaluate the predictive risk factor of rupture. To date, apart from our study, seven teams have reported pregnancies after laparoscopic myomectomy, and none has observed any uterine rupture^{3,38,61–65}. It is difficult to say whether this risk is greater than after myomectomy by laparotomy. The good reputation in obstetrics of scars after myomectomy by laparotomy is based on the observation that many pregnancies have been reported after this operation without any case of rupture^{16,66–76}. However, the largest series are old, and the rate of cases lost to follow-up is not specified. Furthermore, observations of uterine rupture after laparotomy have been reported regularly in the literature^{77–82}. Finally, in a retrospective study carried out in Trinidad Maternity Hospital, the rate of rupture observed during labor after myomectomy by laparotomy was 4.4% (95% CI 0.5–14.8)⁸³. All these elements suggest, in fact, that the risk of rupture after myomectomy by laparotomy is underestimated. In the randomized clinical trial of Seracchioli *et al.*⁵³, 27 women in the laparotomy group and 20 women in the laparoscopic myomectomy group had deliveries after myomectomy. There was no uterine rupture in either group. However, comparative studies covering a larger number of cases are still needed to investigate whether the risk of rupture differs according to the approach.

At present, we consider that this risk is acceptable, and that it should not prevent the laparoscopic approach being used when myomectomy is needed. However, when performing laparoscopic myomectomy, particular care must be given to uterine closure (see above, 'Operative

technique'). Indeed, laparoscopic sutures should be performed by surgeons who are well experienced in laparoscopic surgery.

Fertility after laparoscopic myomectomy

In our series of 91 infertile women treated with laparoscopic myomectomy, the 2-year cumulative rate of spontaneous intrauterine pregnancy was 44% after laparoscopic myomectomy. This rate was 70% when no infertility factor associated with myoma was found and 32% when one or more infertility factors were associated with myoma⁴⁸. The fertility results in our population are comparable to those observed in a series of infertile women treated by laparotomy⁸⁴. In particular, if we take into account only those patients who present no associated infertility factor, the conception rate observed in our series is at least equivalent to that of the series of women treated by laparotomy⁴⁸. In the randomized clinical trial of Seracchioli *et al.*⁵³ including patients with infertility and at least one myoma of more than 4 cm, the fertility rate did not differ between laparotomic and laparoscopic approaches.

Recurrence after laparoscopic myomectomy

Only one study has been devoted specifically to the risk of recurrence after laparoscopic myomectomy⁸⁵. The cumulative rate at 5 years (51%) is distinctly higher than those observed in the series of myomectomy by laparotomy^{17,71,86}, and the time lapse before recurrence is shorter. With the laparoscopic route it is impossible to palpate the myometrium thoroughly, and small intramural nuclei which do not deform the uterine serosa can be overlooked, resulting in incomplete exeresis more often than when the myomectomy uses laparotomy. If these results are confirmed, then considerable caution should be exercised before using the laparoscopic route for multiple myomas.

CONCLUSIONS

Laparoscopic myomectomy is a safe technique which has several advantages, including less postoperative pain, shorter recovery time and reduced post-myomectomy adhesion formation in comparison with the laparotomic approach. However, it is a difficult operation, and the surgeon needs to be well experienced in laparoscopic surgery. Because of increasing difficulties during laparoscopic myomectomy, it is essential to respect limits. We recommend the following:

- Preoperative evaluation of the myomas should be meticulous, in particular concerning ultrasound and hysteroscopic examination

- The preoperative blood count should be controlled, and sideropenic anemia should be corrected
- High-frequency electrosurgical generators and monopolar needles should be used
- Particular care must be paid when suturing the uterus to prevent bleeding and weakening of the myometrium
- An electric morcellator or posterior colpotomy should be employed for the extraction of large myomas

REFERENCES

1. Daniell JF, Gurley LD. Laparoscopic treatment of clinically significant symptomatic uterine fibroids. *J Gynecol Surg* 1991; 7: 37–9
2. Dubuisson JB, Lecuru F, Foulot H, et al. Myomectomy by laparoscopy: a preliminary report of 43 cases. *Fertil Steril* 1991; 56: 827–30
3. Hasson HM, Rotman C, Rana N, et al. Laparoscopic myomectomy. *Obstet Gynecol* 1992; 80: 884–8
4. Nezhat C, Nezhat F, Silfen SL, et al. Laparoscopic myomectomy. *Int J Fertil* 1991; 36: 275–80
5. Dubuisson J-B, Fauconnier A, Fourchette V, et al. Laparoscopic myomectomy: predicting the risk of conversion to an open procedure. *Hum Reprod* 2001; 16: 1726–31
6. Atri M, Reinhold C, Mehio AR, et al. Adenomyosis: US features with histologic correlation in an in-vitro study. *Radiology* 2000; 215: 783–90
7. Chiang CH, Chang MY, Hsu JJ, et al. Tumor vascular pattern and blood flow impedance in the differential diagnosis of leiomyoma and adenomyosis by color Doppler sonography. *J Assist Reprod Genet* 1999; 16: 268–75
8. Cohen LS, Valle RF. Role of vaginal sonography and hysterosonography in the endoscopic treatment of uterine myomas. *Fertil Steril* 2000; 73: 197–204
9. Fauconnier A, Dubuisson J-B, Ancel P-Y, et al. Prognostic factors of reproductive outcome after myomectomy in infertile patients. *Hum Reprod* 2000; 15: 1751–7
10. Friedman AJ, Harrison-Atlas D, Barbieri RL, et al. A randomized, placebo-controlled, double-blind study evaluating the efficacy of leuprolide acetate depot in the treatment of uterine leiomyomata. *Fertil Steril* 1989; 51: 251–6
11. Lumsden MA, West CP, Baird DT. Goserelin therapy before surgery for uterine fibroids. *Lancet* 1987; 1: 36–7
12. Matta WH, Stabile I, Shaw RW, et al. Doppler assessment of uterine blood flow changes in patients with fibroids receiving the gonadotropin-releasing hormone agonist buserelin. *Fertil Steril* 1988; 49: 1083–5
13. Friedman AJ, Rein MS, Harrison-Atlas D, et al. A randomized, placebo-controlled, double-blind study evaluating leuprolide acetate depot treatment before myomectomy. *Fertil Steril* 1989; 52: 728–33
14. Campo S, Garcea N. Laparoscopic myomectomy in premenopausal women with and without preoperative treatment using gonadotrophin-releasing hormone analogues. *Hum Reprod* 1999; 14: 44–8
15. Zullo F, Pellicano M, De Stefano R, et al. A prospective randomized study to evaluate leuprolide acetate treatment before laparoscopic myomectomy: efficacy and ultrasonographic predictors. *Am J Obstet Gynecol* 1998; 178: 108–12
16. Acien P, Quereda F. Abdominal myomectomy: results of a simple operative technique. *Fertil Steril* 1996; 65: 41–51
17. Beyth Y. Gonadotropin-releasing hormone analog treatment should not precede conservative myomectomy [Letter]. *Fertil Steril* 1990; 53: 187–8
20. Reich H, Thompson KA, Nataupsky LG, et al. Laparoscopic myomectomy: an alternative to laparotomy or hysterectomy? *Gynaecol Endosc* 1997; 6: 7–12
19. Fedele L, Vercellini P, Bianchi S, et al. Treatment with GnRH agonists before myomectomy and the risk of short-term myoma recurrence. *Br J Obstet Gynaecol* 1990; 97: 393–6
20. Crosignani PG, Vercellini P, Meschia M, et al. GnRH agonists before surgery for uterine leiomyomas. A review [see Comments]. *J Reprod Med* 1996; 41: 415–21
21. Zullo F, Pellicano M, Di Carlo C, et al. Ultrasonographic prediction of the efficacy of GnRH agonist therapy before laparoscopic myomectomy. *J Am Assoc Gynecol Laparosc* 1998; 5: 361–6
22. Dubuisson J-B, Fauconnier A, Babaki-Fard K, et al. Laparoscopic myomectomy: a current view. *Hum Reprod Update* 2000; 6: 558–94
23. Darai E, Deval B, Darles C, et al. Myomectomie: coelioscopie ou laparotomie. *Contracept Fertil Sex* 1996; 24: 751–6
24. Dubuisson JB, Chapron C, Lévy L. Difficulties and complications of laparoscopic myomectomy. *J Gynecol Surg* 1996; 12: 159–65
25. Benhaim Y, Ducarme G, Madelenat P, et al. Les limites de la myomectomie coelioscopique. *Gynecol Obstet Fertil* 2005; 33: 44–9
26. Adamian LV, Kulakov VI, Kiselev SI, et al. Laparoscopic myomectomy in treatment of large myomas. *J Am Assoc Gynecol Laparosc* 1996; 3: S1
27. Hasson HM. Laparoscopic myomectomy. *Infertil Reprod Med Clin North Am* 1996; 7: 143–59
28. Farrer-Brown G, Beilby J, Tarbit MH. Venous changes in the endometrium of myomatous uteri. *Obstet Gynecol* 1971; 38: 743–51
29. Vollenhoven BJ, Lawrence AS, Healy DL. Uterine fibroids: a clinical review. *Br J Obstet Gynaecol* 1990; 97: 285–98
30. Donnez J, Polet R, Smets M, et al. Hysteroscopic myomectomy. *Curr Opin Obstet Gynecol* 1995; 7: 311–16
31. Wamsteker K, Emanuel MH, de Kruif JH. Transcervical hysteroscopic resection of submucous

- fibroids for abnormal uterine bleeding: results regarding the degree of intramural extension. *Obstet Gynecol* 1993; 82: 736–40
32. Dubuisson JB, Malartic C, Jacob C, et al. Preventive uterine artery occlusion combined with laparoscopic myomectomy: a valid procedure to prevent bleeding. *J Gynecol Surg* 2004; 20: 105–12
 33. Bonney V. The technique and results of myomectomy. *Lancet* 1931; 220: 171–3
 34. Buttram VC, Reiter R. Uterine leiomyomata: etiology, symptomatology and management. *Fertil Steril* 1981; 36: 433–45
 35. Dubuisson JB, Chavet X, Chapron C, et al. Uterine rupture during pregnancy after laparoscopic myomectomy. *Hum Reprod* 1995; 10: 1475–7
 36. Harris WJ. Uterine dehiscence following laparoscopic myomectomy. *Obstet Gynecol* 1992; 80: 545–6
 37. Pelosi M, Pelosi MA. Spontaneous uterine rupture at thirty-three weeks subsequent to previous superficial laparoscopic myomectomy. *Am J Obstet Gynecol* 1997; 177: 1547–9
 38. Vilos GA, Daly LJ, Tse BM. Pregnancy outcome after laparoscopic electromyolysis. *J Am Assoc Gynecol Laparosc* 1998; 5: 289–92
 39. Miller CE, Johnston M, Rundell M. Laparoscopic myomectomy in the infertile woman. *J Am Assoc Gynecol Laparosc* 1996; 3: 525–32
 40. Dubuisson JB, Chapron C, Chavet X, et al. Traitement coelioscirurgical des volumineux fibromes utérins. Technique opératoire et résultats. *J Gynecol Obstet Biol Reprod* 1995; 24: 705–10
 41. Ostrzenski A. A new laparoscopic myomectomy technique for intramural fibroids penetrating the uterine cavity. *Eur J Obstet Gynecol Reprod Biol* 1997; 74: 189–93
 42. Nezhat C, Nezhat F, Bess O, et al. Laparoscopically assisted myomectomy: a report of a new technique in 57 cases. *Int J Fertil Menopausal Stud* 1994; 39: 39–44
 43. Tulandi T, Youseff H. Laparoscopy assisted myomectomy of large uterine myomas. *Gynaecol Endosc* 1997; 6: 105–8
 44. Carter JE, McCarus SD. Laparoscopic myomectomy. Time and cost analysis of power vs. manual morcellation. *J Reprod Med* 1997; 42: 383–8
 45. Dubuisson JB, Chapron C, Fauconnier A, et al. Laparoscopic myomectomy and myolysis. *Curr Opin Obstet Gynecol* 1997; 9: 233–8
 46. Mangeshkar PR. New instrumentation and technique for laparoscopic myomectomy. *J Am Assoc Gynecol Laparosc* 1995; 2: S29
 47. Dubuisson JB, Fauconnier A, Chapron C, et al. Second look after laparoscopic myomectomy. *Hum Reprod* 1998; 13: 2102–6
 48. Dubuisson JB, Fauconnier A, Chapron C, et al. Reproductive outcome after laparoscopic myomectomy in infertile women. *J Reprod Med* 2000; 45: 23–31
 49. Tulandi T, Murray C, Guralnick M. Adhesion formation and reproductive outcome after myomectomy and second look laparoscopy. *Obstet Gynecol* 1993; 82: 213–15
 50. Ugur M, Turan C, Mungan T, et al. Laparoscopy for adhesion prevention following myomectomy. *Int J Gynecol Obstet* 1996; 53: 145–9
 51. Dubuisson J-B, Fauconnier A, Deffarges J-V, et al. Pregnancy outcome and deliveries following laparoscopic myomectomy. *Hum Reprod* 2000; 15: 869–73
 52. Malzoni M, Rotond M, Perone C, et al. Fertility after laparoscopic myomectomy of large uterine myomas: operative technique and preliminary results. *Eur J Gynecol Oncol* 2003; 24: 79–82
 53. Seracchioli R, Rossi S, Govoni F, et al. Fertility and obstetric outcome after laparoscopic myomectomy of large myomata: a randomized comparison with abdominal myomectomy. *Hum Reprod* 2000; 15: 2663–8
 54. Stringer NH, Walker JC, Meyer PM. Comparison of 49 laparoscopic myomectomies with 49 open myomectomies. *J Am Assoc Gynecol Laparosc* 1997; 4: 457–64
 55. Mais V, Ajossa S, Guerriero S, et al. Laparoscopic versus abdominal myomectomy: a prospective, randomized trial to evaluate benefits in early outcome. *Am J Obstet Gynecol* 1996; 174: 654–8
 56. Bulletti C, Polli V, Negrini V, et al. Adhesion formation after laparoscopic myomectomy. *J Am Assoc Gynecol Laparosc* 1996; 3: 533–6
 57. Nezhat C. The 'cons' of laparoscopic myomectomy in women who may reproduce in the future. *Int J Fertil Menopausal Stud* 1996; 41: 280–3
 58. Friedmann W, Maier RF, Luttkus A, et al. Uterine rupture after laparoscopic myomectomy. *Acta Obstet Gynecol Scand* 1996; 75: 683–4
 59. Mecke H, Wallas F, Brocker A, et al. Pelviskopsische Myomenukleation: Technik, Grenzen, Komplikationen. *Geburtshilfe Frauenheilk* 1995; 55: 374–9
 60. Soriano D, Dessolle L, Poncelet C, et al. Pregnancy outcome after laparoscopic and laparoconverted myomectomy. *Eur J Obstet Gynecol Reprod Biol* 2003; 108: 194–8
 61. Daraï E, Dechaud H, Benifla JL, et al. Fertility after laparoscopic myomectomy: preliminary results. *Hum Reprod* 1997; 12: 1931–4
 62. Nezhat CH, Nezhat F, Roemisch M, et al. Pregnancy following laparoscopic myomectomy: preliminary results. *Hum Reprod* 1999; 14: 1219–21
 63. Reich H. Laparoscopic myomectomy. *Obstet Gynecol Clin North Am* 1995; 22: 757–80
 64. Ribeiro SC, Reich H, Rosenberg J, et al. Laparoscopic myomectomy and pregnancy outcome in infertile patients. *Fertil Steril* 1999; 71: 571–4
 65. Seiner P, Arisio R, Decko A, et al. Laparoscopic myomectomy: indications, surgical technique and complications. *Hum Reprod* 1997; 12: 1927–30
 66. Berkeley AS, DeCherney AH, Polan ML. Abdominal myomectomy and subsequent fertility. *Surg Gynecol Obstet* 1983; 156: 319–22

67. Brown AB, Chamberlain R, Te Linde RW. Myomectomy. *Am J Obstet Gynecol* 1956; 71: 759–63
68. Brown JM, Malkasian GD, Symmonds RE. Abdominal myomectomy. *Am J Obstet Gynecol* 1967; 90: 126–8
69. Davids A. Myomectomy: surgical technique and results in series of 1150 cases. *Am J Obstet Gynecol* 1952; 63: 592–604
70. Egwuatu VE. Fertility and fetal salvage among women with uterine leiomyomas in a Nigerian Teaching Hospital. *Int J Fertil* 1989; 34: 341–6
71. Finn WF, Muller PF. Abdominal myomectomy: special reference to subsequent pregnancy and to the reappearance of fibromyomas of the uterus. *Am J Obstet Gynecol* 1950; 60: 109–14
72. Loeffler FE, Noble AD. Myomectomy at the Chelsea Hospital for Women. *J Obstet Gynaecol Br Commonw* 1970; 77: 167–70
73. Mussey RD, Randall LM, Doyle LW. Pregnancy following myomectomy. *Am J Obstet Gynecol* 1945; 49: 508–12
74. Sirjusingh A, Bassaw B, Roopnarinesingh S. The results of abdominal myomectomy. *West Indian Med J* 1994; 43: 138–9
75. Smith DC, Uhlir JK. Myomectomy as a reproductive procedure. *Am J Obstet Gynecol* 1990; 162: 1476–9
76. Sudik R, Husch K, Steller J, et al. Fertility and pregnancy outcome after myomectomy in sterility patients. *Eur J Obstet Gynecol Reprod Biol* 1996; 65: 209–14
77. Garnet JD. Uterine rupture during pregnancy. *Obstet Gynecol* 1964; 23: 898–902
78. Georgakopoulos PA, Bersis G. Sigmoido-uterine rupture in pregnancy after multiple myomectomy. *Int Surg* 1981; 66: 367–8
79. Golan D, Aharoni A, Gonon R, et al. Early spontaneous rupture of the post myomectomy gravid uterus. *Int J Gynecol Obstet* 1990; 31: 167–70
80. Ozeren M, Ulusoy M, Uyanik E. First-trimester spontaneous uterine rupture after traditional myomectomy: case report. *Isr J Med Sci* 1997; 33: 752–3
81. Palerme GR, Friedman EA. Rupture of the gravid uterus in the third trimester. *Am J Obstet Gynecol* 1966; 94: 571–6
82. Quakernack K, Bordt J, Nienhaus H. [Placenta percreta and rupture of the uterus]. *Geburtshilfe Frauenheilk* 1980; 40: 520–3
83. Roopnarinesingh S, Suratsingh J, Roopnarinesingh A. The obstetric outcome of patients with previous myomectomy or hysterotomy. *West Indian Med J* 1985; 34: 59–62
84. Vercellini P, Maddalena S, De Giorgi O, et al. Determinants of reproductive outcome after abdominal myomectomy for infertility. *Fertil Steril* 1999; 72: 109–14
85. Nezhat FR, Roemisch M, Nezhat CH, et al. Recurrence rate after laparoscopic myomectomy. *J Am Assoc Gynecol Laparosc* 1998; 5: 237–40
86. Candiani GB, Fedele L, Parazzini F, et al. Risk of recurrence after myomectomy. *Br J Obstet Gynaecol* 1991; 98: 385–9

Laparoscopic myomectomy and myolysis: to whom should it be proposed?

P Jadoul, J Donnez

Leiomyomas of the uterus are the most common solid pelvic tumors, estimated to occur in 20–50% of women¹.

Two issues that need to be addressed when dealing with uterine myomas are: which myomas should be removed, and which procedure should be performed to remove them. To answer these questions, the classic risk–benefit ratio analysis must be applied. The best treatment is that which improves symptoms with the fewest side-effects and complications, and the lowest risk of recurrence.

When treatment is indicated, the art is choosing the right one. Medical treatment, abdominal myomectomy, laparoscopic myomectomy or myolysis, hysteroscopic myomectomy, myoma embolization and hysterectomy all have a place in the treatment of myomas. While hysterectomy is the best option in older women, for women wishing to preserve their fertility, the indications and choice of treatment are more problematic.

This chapter sets out to determine the correct indications for myomectomy and to define the place of laparoscopic myomectomy and myolysis in women wishing to maintain their fertility.

INDICATIONS FOR MYOMECTOMY

At least 50% of leiomyomas remain asymptomatic. While there is no disputing that myomas may cause menorrhagia, dysmenorrhea, pelvic discomfort and bladder and bowel compression symptoms, the relationships between leiomyomas and infertility and also between leiomyomas and obstetric complications remain subjects of debate.

Myomas causing menorrhagia, pain or signs of bladder or bowel compression should be treated. In women who have completed their families, hysterectomy might be considered the most effective treatment, and is very often successful. In symptomatic women who still wish to conceive, conservative treatment should be proposed.

The question is, are there indications for myomectomy in asymptomatic patients?

MYOMECTOMY FOR INFERTILITY?

Ideally, to prove a relationship between fibroids and infertility, prospective randomized studies should be performed, comparing women desiring pregnancy with and without myomas, in order to compare pregnancy rates and possibly the time needed to achieve pregnancy. Such

studies have not been performed. Another possibility would be to compare pregnancy rates of infertile women with and without myomas, in whom other infertility factors have been excluded.

There is only one publication comparing spontaneous conception in infertile women with and without myomas, in whom andrological and tubal infertility factors had been excluded². Bulletti found a significant difference in pregnancy rates between infertile women with and without myomas (11% fertility rate in women with myomas versus 25% in those without). However, the methodology of this article is questionable, as the follow-up was short and the different groups too small to allow conclusions to be drawn as to the influence of myoma location, number and size.

Our knowledge of the relationship between myomas and fertility results from indirect proof.

In vitro fertilization (IVF) provides a good model for assessing the role of myomas in infertility, since other factors, such as tubal or andrological factors, are excluded, allowing us to investigate the influence of myomas on embryo implantation for embryos of the same ‘quality’.

It is generally accepted that the anatomic location of a fibroid is an important factor, with submucosal myomas most likely to cause infertility, followed by intramural and finally subserosal myomas. Myomas may also be associated with implantation failure or gestation discontinuation due to focal endometrial vascular disturbance, endometrial inflammation, secretion of vasoactive substances or an enhanced endometrial androgen environment^{3,4}. On the other hand, myomas may cause dysfunctional uterine contractility, which may interfere with sperm migration, ovum transport or nidation^{4–6}. This possible interference of myomas with sperm migration and ovum transport cannot be assessed by the IVF model.

Another indirect way of assessing the influence of myomas on fertility is to analyze the effect of myomectomy on fertility outcome in infertile women.

Myomas and assisted reproduction

Several authors have compared the results of IVF in women with untreated myomas and without myomas.

Submucosal leiomyomas significantly decrease IVF pregnancy rates^{7–10}, while hysteroscopic resection of submucosal myomas results in a significantly higher pregnancy rate compared with controls with a normal uterine cavity¹¹.

For intramural and subserosal fibroids, there seems to be no consensus. In patients with a distorted uterine cavity, a significant decrease in pregnancy rates has been described⁸.

The impact on fertility of fibroids that do not deform the uterine cavity is uncertain. For Fahri⁸, Ramzy¹², Jun¹³ and Yarali¹⁴ and their groups, the presence of myomas that do not distort the cavity, even those measuring up to 10 cm¹⁴, does not impact negatively on pregnancy rates. In contrast, for Eldar-Geva⁹, Stovall¹⁵, Hart¹⁶, Check¹⁷ and Oliveira¹⁸ and their groups, intramural myomas that deform the cavity do indeed decrease pregnancy rates. Hart *et al.*¹⁶ and Check *et al.*¹⁷ claim that even myomas of less than 5 cm can influence pregnancy rates, while Oliveira *et al.*¹⁸ believe that only myomas of 4 cm or more have a negative effect on pregnancy rates.

Effects of myomectomy on fertility outcome in infertile patients

Numerous studies on fertility outcome after myomectomy in infertile patients have been published, and were reviewed by us in 2002 (Table 21.1)²¹. Most of them were retrospective analyses. Some focused on myoma location, but others did not distinguish myoma type. The global pregnancy rate after myomectomy in infertile women, regardless of the kind of surgery undertaken, varies between 9.6 and 76.9%.

How can we explain this discrepancy?

Considerable differences in results persist even when different kinds of surgery are considered separately. After hysteroscopic myomectomy, pregnancy rates are between 16.7 and 76.9%, and after laparoscopic or laparotomic myomectomy, between 9.6 and 75%.

The differences encountered with the same surgical approach demonstrate the influence of different factors on pregnancy rates. Factors implicated are age, number of myomas, myoma size, myoma location and technical factors.

Age over 35 years and an association with other infertility factors decrease pregnancy rates^{12,20-22}.

In the study of Fauconnier *et al.*²¹, fertility rates were found to be lower in women who had associated tubal pathology, or male or ovulatory factors. Vercellini *et al.*²⁰ showed decreased pregnancy rates after myomectomy in women over 35 years of age, and when the duration of infertility before myomectomy exceeded 2 years.

With regard to the number of myomas, some authors observed a lower pregnancy rate when more fibroids were removed^{23,24}, while others noted no difference^{20,21,25}.

For Sudik *et al.*²³, pregnancy rates were higher after the removal of myomas with a volume of >100 ml (± 8 cm diameter). Others, however, found no difference according to myoma size^{20,21,25}.

Ancien and Querada²⁶ and Sudik *et al.*²³ demonstrated no influence of myoma location. Fauconnier *et al.*²¹ found a lower pregnancy rate with posterior myomas. Dessolle *et*

*al.*²⁴ detected better results when there was distortion of the uterine cavity before myomectomy.

Technical factors, such as surgeon's skill and experience, and probably the material and techniques used, surely also play a role.

All in all, the conclusions on the impact on pregnancy rates of the number, size and location of myomas, and their capacity to distort the cavity, are somewhat contradictory. These contradictions, and the influence of a patient's age and associated fertility factors, coupled with the probable role of technical factors, lead us to question the real impact of myomas on fertility.

Myomectomy is therefore indicated only after complete evaluation of other potential infertility factors²⁷.

MYOMECTOMY TO IMPROVE PREGNANCY OUTCOME?

Although our objective is to analyze the impact of myomas on fertility, the goal for the infertile couple is not the pregnancy itself, but the birth of a 'healthy' child. We should therefore also concentrate on the impact of myomas and myomectomy on pregnancy outcome. Benson *et al.*²⁸ showed a significant increase in miscarriage rates in women with myomas, particularly women with multiple myomas.

In a retrospective study by Sheiner *et al.*²⁹, women with uterine myomas during pregnancy had a 3.5-fold increase in the incidence of intrauterine growth retardation, a 4-fold increase in placental abruption, a 5-fold increase in the incidence of transverse lie or breech presentation, a 5-fold increase in the cesarean section rate and a 70% increase in premature rupture of the membranes.

According to Li³⁰, Vercellini²⁰ and Marchionni³¹ and their groups, miscarriage rates are significantly reduced after myomectomy.

LAPAROSCOPIC MYOMECTOMY AND MYOLYSIS

Myomas can be treated conservatively by medical treatments or uterine artery embolization, or surgically by myomectomy (abdominal, laparoscopic or hysteroscopic) or myolysis.

When comparing techniques for conservative treatment of myomas in women of reproductive age, important issues are:

- Safety
- Short- and long-term efficiency

Submucosal myomas should be removed by hysteroscopy. For intramural and subserosal myomas, our aim is to compare laparoscopic myomectomy and myolysis with abdominal myomectomy and uterine artery embolization.

Table 21.1 Fertility outcome after myomectomy in infertile patients. From reference 19

Author(s)	Study	n	Myoma	Treatment	Pregnancy rate (%)	
					Lps/Lpt	Hsc
Starks, 1998	Prospective	32	SS, IM, SM	Lpt	62.5	
Brooks <i>et al.</i> , 1989	Retrospective	15	SM	Hsc		33.3
Gatti <i>et al.</i> , 1989	Retrospective	30	—	Lpt	43.3	
Egwuatu, 1989	Retrospective	52	SS, IM, SM	Lpt	9.6	
Prien-Larsen and Kjer, 1989	Retrospective	33	—	Lpt	31	
Loffer, 1990	Retrospective	12	SM	Hsc		58.3
Vollen-hoven <i>et al.</i> , 1990	Prospective	13	—	Lpt	46	
Donnez <i>et al.</i> , 1990	Retrospective	24	SM	Hsc		67
Valle, 1990	Retrospective	16	SM	Hsc		62
Corson and Brooks, 1991	Retrospective	13	SM	Hsc		76.9
Hucke <i>et al.</i> , 1992	Retrospective	14	SM	Hsc		28.6
Verkauf, 1992	Retrospective	24	SS, IM, SM	Lpt	58.3	
Liu <i>et al.</i> , 1993	Prospective	8	IM, SM	Lpt	75	
Gehlbach <i>et al.</i> , 1993	Retrospective	37	SS, IM, SM	Lpt	57	
Tulandi <i>et al.</i> , 1993	Prospective	26	SS, IM	Lpt	61.5	
Fayez and Dempsey, 1993	Retrospective	38	SS, IM, SM	Lpt	63	
Abramovici <i>et al.</i> , 1994	Prospective	10	—	Lpt	50	
Nezhat <i>et al.</i> , 1994	Retrospective	14	SS, IM, SM	LAM	28.3	
Sirjusingh <i>et al.</i> , 1994	Retrospective	38	SS, IM, SM	Lpt	37	
Goldenberg <i>et al.</i> , 1995	Retrospective	15	SM	Hsc		46.6
Hallez, 1995	Retrospective	32	SM	Hsc		56
Cravello <i>et al.</i> , 1995	Retrospective	16	SM	Hsc		25
Darai <i>et al.</i> , 1996	Retrospective	52	SS, IM	Lpt, Lps	30.8	
Dubuisson <i>et al.</i> , 1996	Prospective	21	> 50 mm	Lps	33.3	
Ancien and Querada, 1996	Retrospective	20	SS, IM, SM	Lpt	15	
Hasson <i>et al.</i> , 1996	Retrospective	17	SS, IM, SM	Lps	71	
Miller <i>et al.</i> , 1996	Prospective	41	—	Lps	73.1	
Sudik <i>et al.</i> , 1996	Retrospective	67	—	Lpt, Lps	58.2	
Darai <i>et al.</i> , 1997	Retrospective	29	SS, IM, SM	Lps	48.2	
Kuhlman <i>et al.</i> , 1997	Retrospective	41	—	Lpt, Lps	61	
Seineira <i>et al.</i> , 1997	Retrospective	30	SS, IM, SM	Lps	16.7	
Preuthipan and Theppisai, 1998	Retrospective	12	SM	Hsc		16.7
Campo and Garcea, 1999	Prospective	24	SS, IM	Lps	54.1	
Vercellini <i>et al.</i> , 1999	Retrospective	138	SS, IM	Lpt	55	
Vercellini <i>et al.</i> , 1999	Retrospective	40	SM	Hsc		37.5
Giatras <i>et al.</i> , 1999	Retrospective	41	SM	Hsc		60.9
Varasteh <i>et al.</i> , 1999	Retrospective	36	SM	Hsc		53
Li <i>et al.</i> , 1999	Retrospective	30	SS, IM	Lpt	43	
Ribeiro <i>et al.</i> , 1999	Retrospective	28	> 50 mm	Lps	64.3	
Seracchioli <i>et al.</i> , 2000	Prospective	115	> 50 mm	Lpt, Lps	54.8	
Dubuisson <i>et al.</i> , 2000	Retrospective	81	SS, IM	Lps	53	
Bernard <i>et al.</i> , 2000	Retrospective	31	SM	Hsc		35.5
Fernandez <i>et al.</i> , 2001	Retrospective	59	SM	Hsc		27.1
Dessolle <i>et al.</i> , 2001	Retrospective	88	SS, IM	Lps	47.7	
Zollner <i>et al.</i> , 2001	Retrospective	49	SS, IM, SM	Lpt, Lps, Hsc	41	
Rossetti <i>et al.</i> , 2001	Retrospective	29	SS, IM	Lps	65.5	
Total		1631			49 (615/1255)	45 (168/376) 48 (783/1631)

SS, subserosal; IM, intramural; SM, submucosal; Lpt, laparotomy; Lps, laparoscopy; Hsc, hysteroscopy; LAM, laparoscopy-assisted myomectomy; —, not mentioned

Laparoscopic techniques

Laparoscopic myomectomy

Classic laparoscopy is performed using a 12-mm trocar umbilically and three suprapubic trocars of 5, 5 and 10 mm. The 10-mm trocar is useful for introducing strong grasping forceps to apply traction to the myoma.

The surgical procedure starts with incision of the myometrium in line with the myoma. This hysterotomy can be performed with monopolar scissors or with the CO₂ laser (Figure 21.1).

Hemostasis of the intramyometrial vessels is carried out progressively using a bipolar current (Figure 21.2).

The myoma is easily recognizable by its smooth white appearance. Dissection of the myoma should run along the avascular plane around the myoma, leaving the pseudocapsule. The myoma is grasped using strong grasping forceps, and the dissection is carried out with traction and countertraction to the uterus (Figure 21.3). The fine vessels going to the myoma are coagulated and sectioned. The bed of the myoma is often free from hemorrhage at the end of dissection.

Suture of the myometrium is performed in one or two layers depending on the depth of the incision. We use resorbable suture, diameter 1 or 2, to perform single, separate stitches tied intracorporeally (Figure 21.4). The stitches go through the whole thickness of the edges of the hysterotomy, and through the uterine serosa. When the myomectomy is deep or the uterine cavity has been opened, a two-layer suture is performed using single stitches deep in the myometrium, followed by more superficial stitches incorporating the serosa and the superficial part of the myometrium.

To remove the myoma, morcellation is carried out (Figure 21.5).

Myolysis

Laparoscopy is performed transumbilically using a 10-mm endoscope adapted to a video camera. The instruments are introduced through three suprapubic puncture sites (5 mm in diameter). The bare laser fiber (Nd (YAG: neodymium yttrium–aluminum–garnet) laser) is introduced as perpendicularly as possible into the fibroid through a second puncture trocar to a depth depending on the myoma diameter (Figure 21.6). During the application of laser energy, the fiber is inserted, reaching the central part of the fibroid, and is then slowly removed in order to provoke 'strong' coagulation. The power used is 80 W. The procedure is repeated across the entire surface of the myoma in order to coagulate most of the myoma volume. The surface of the myoma is rinsed with 0.9% saline solution during laser application to reduce thermal conduction through the uterine wall. The distance between the holes is about 5–7 mm (Figure 21.7).

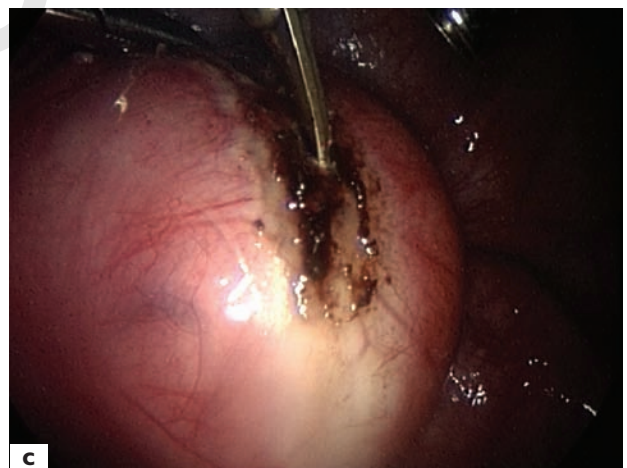
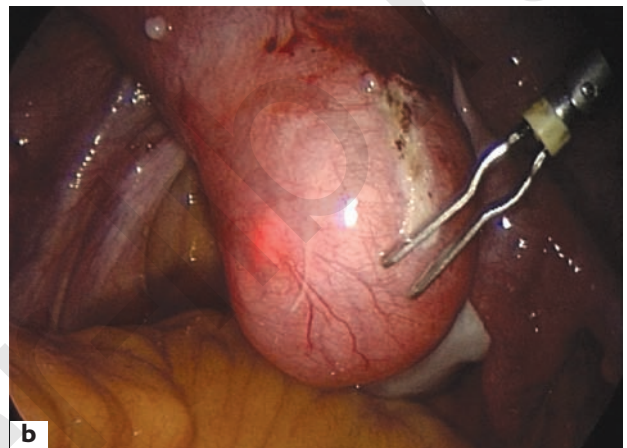
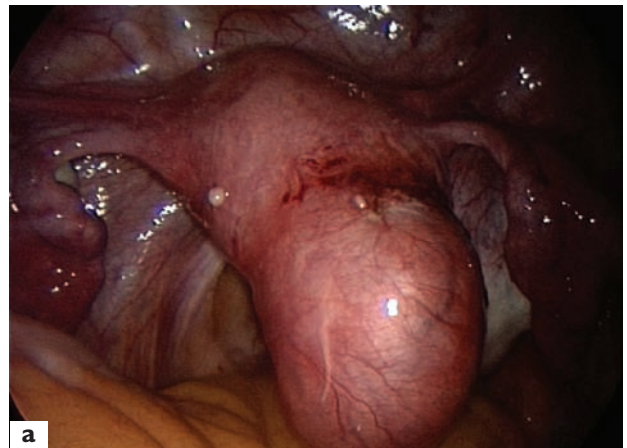


Figure 21.1 Laparoscopic myomectomy: (a) exposure of the myoma; (b) coagulation of the serosa; (c) incision of the myometrium with monopolar scissors

In our series of 48 patients³², vasopressin (POR8; Sandoz, Brussels, Belgium) was never used to infiltrate the myometrium adjacent to the fibroid to induce temporary myometrial ischemia, reducing blood loss. However, in one case, diluted vasopressin was required to obtain complete uterine hemostasis: 5 IU of vasopressin in 20 ml of saline

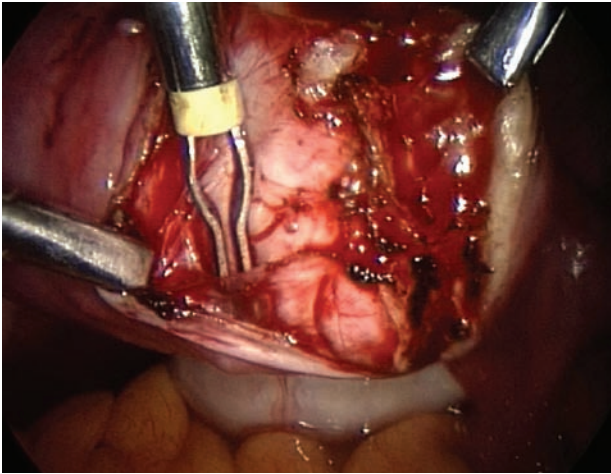


Figure 21.2 Laparoscopic myomectomy: hemostasis of the intramyometrial vessels is carried out progressively using bipolar current

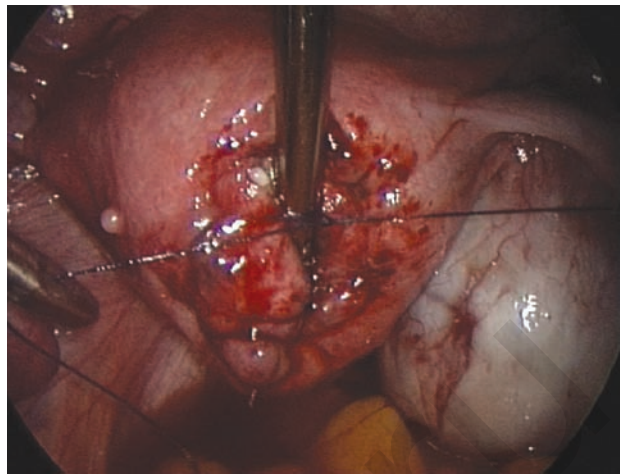


Figure 21.4 Laparoscopic myomectomy: suture of the myometrium

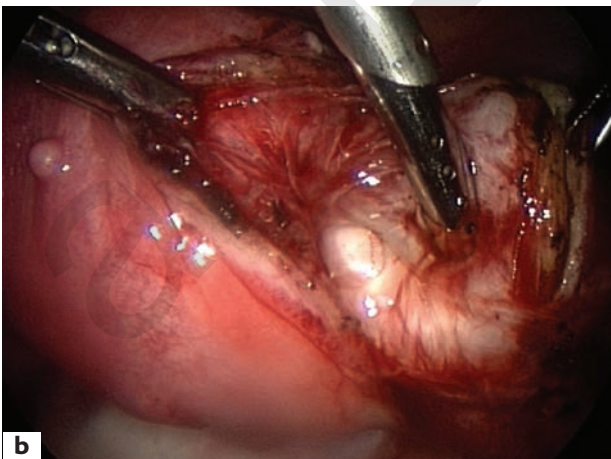
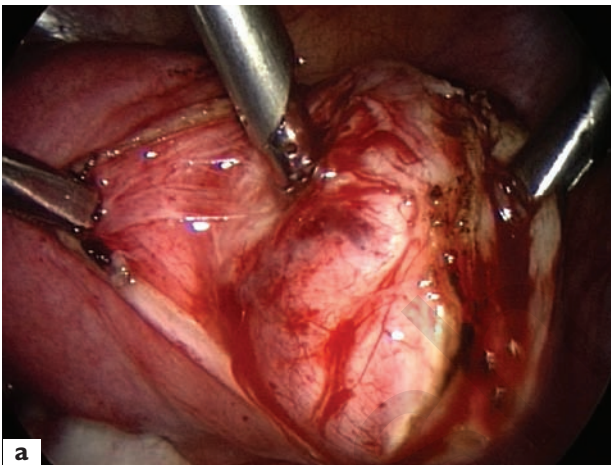


Figure 21.3 (a) and (b) Laparoscopic myomectomy: the myoma is grasped using a strong grasping forceps and the dissection is pursued using traction and countertraction on the uterus

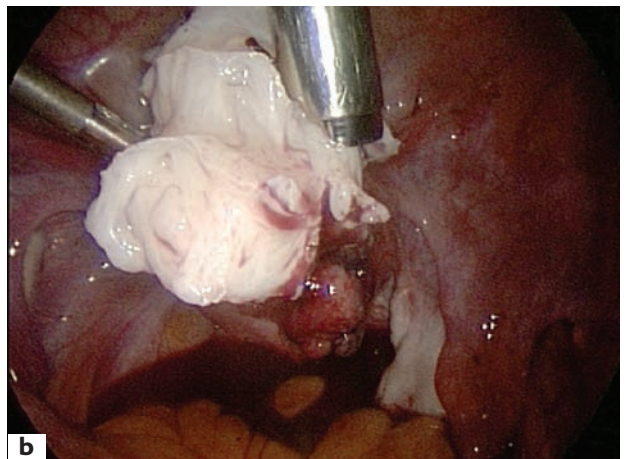
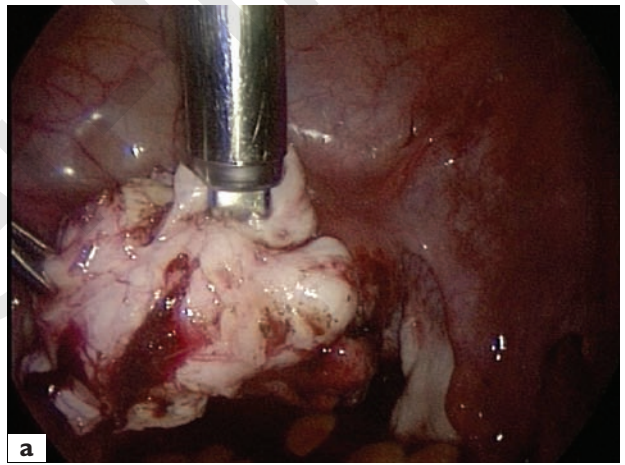


Figure 21.5 (a) and (b) Laparoscopic myomectomy: morcellation of the removed myoma

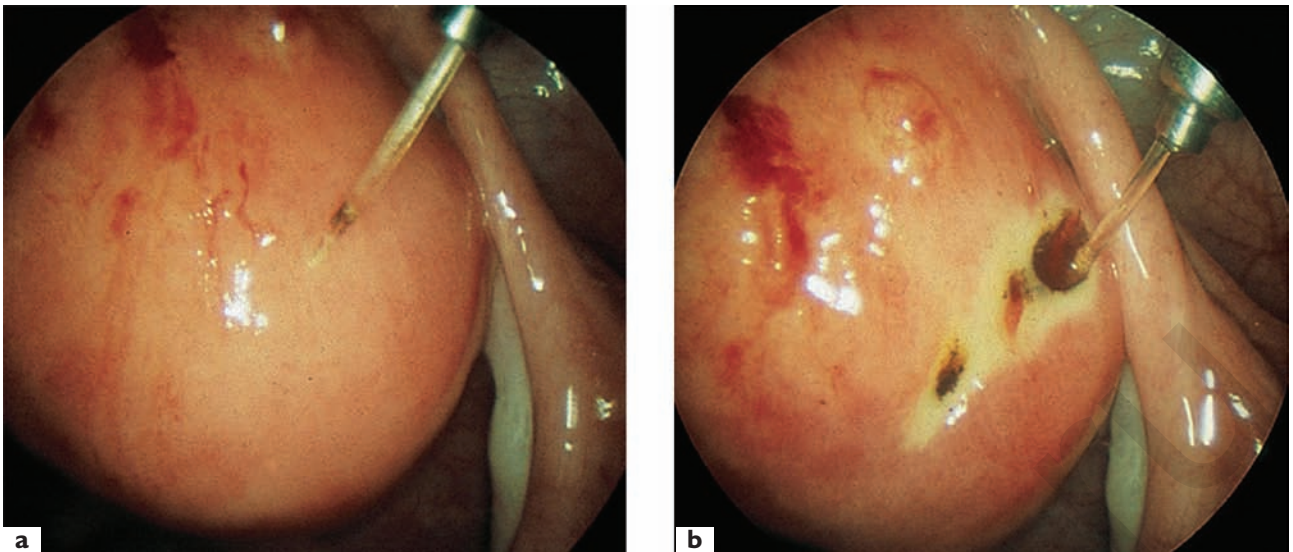


Figure 21.6 (a) and (b) Laparoscopic myolysis: the laser fiber is introduced at an angle perpendicular to the fibroid and removed during the application of energy

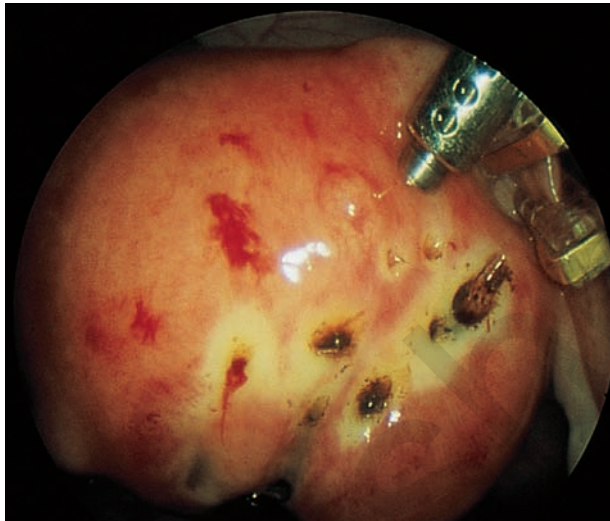

Figure 21.7 Laparoscopic myolysis: the distance between the holes is about 5–7 mm. At the end of the procedure, numerous laser scars are seen. The pale color of the myoma is due to the coagulation

solution was injected around the hemorrhagic site at the end of the procedure.

Immediately following myolysis, many laser scars can be seen on the myoma, which appears paler than normal (Figure 21.7).

In the last ten cases, an Interceed® graft (Johnson & Johnson, New Brunswick, NJ) was used to cover the coagulated area after hemostatic control was obtained, in order to decrease the risk of adhesions (Figure 21.8). Careful aspiration of peritoneal fluid was then carried out and a suction catheter was left in the pouch of Douglas.

In our first series of 48 patients, none required laparotomy for bleeding, and no bladder or bowel injuries

were reported. During surgery, some problems arose because of difficult access to posterior myomas by the laser fiber, introduced through a second puncture. In such cases, the laser fiber can be introduced directly through the laparoscope to achieve better access. The estimated blood loss was minimal (<50 ml) in all cases but one. The operating time varied from 20 to 45 min, depending on the diameter and number of myomas. All patients were released in good physical condition the following day; none experienced any postoperative infection or hemorrhage.

The number, size and location of the myomas were evaluated by vaginal echography before laparoscopic myolysis and postoperatively at weeks 3, 6 and 12, after 6 months and after 1 year; 15 patients were evaluated after 3 years. Fibroids treated by myolysis ranged from 3 to 8 cm in diameter. The mean decrease in myoma diameter after myolysis was 4% (range 0–6%) at week 6, 12% (range 2–18%) at week 12 and 41% (range 18–62%) after 6 months. The echostructure of the coagulated myoma was such that only experienced echographers could really distinguish its boundaries. The results observed after 1 year were similar to those seen after 6 months; there was neither any further decrease in size nor a regrowth of the myoma.

After 3 years, 15 patients were evaluated by echography. In ten of them, who had two or three myomas (between 3 and 5 cm in diameter), echography revealed only small areas (<1 cm in diameter) whose echographic structure was slightly different from normal myometrium. Among the five remaining patients, three were stable and two experienced recurrence of myomas in other sites. The last two patients underwent laparoscopic subtotal hysterectomy. Only a few adhesions were present. Failure of treatment, indicated by an absence of any significant decrease in myoma diameter, was never observed.

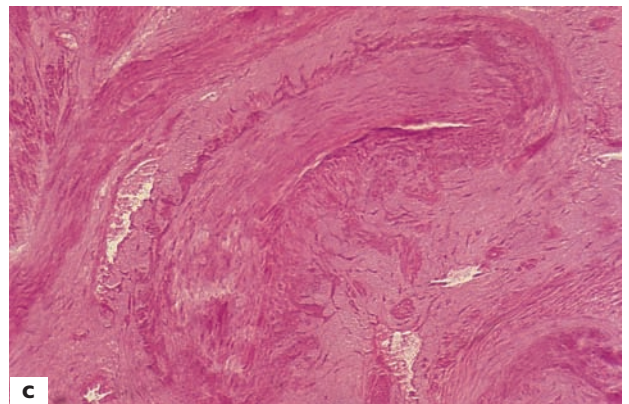
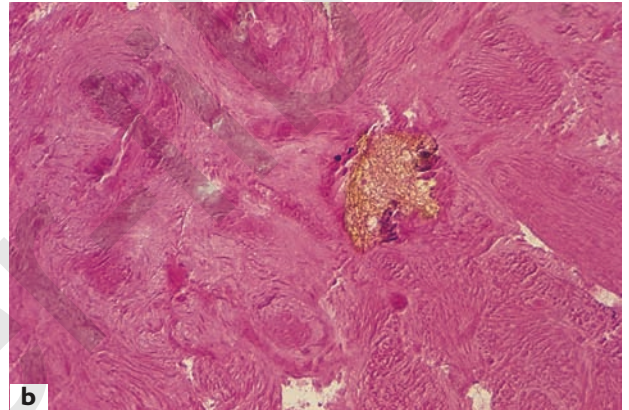
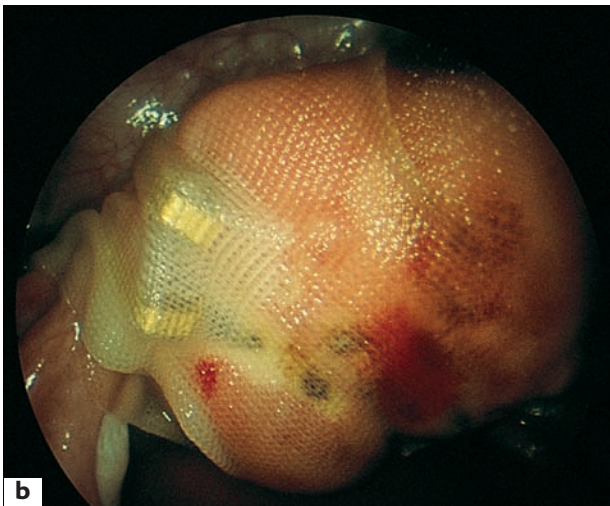
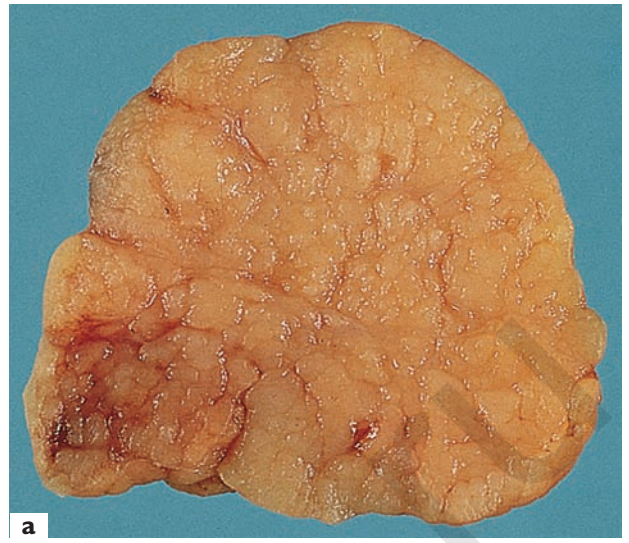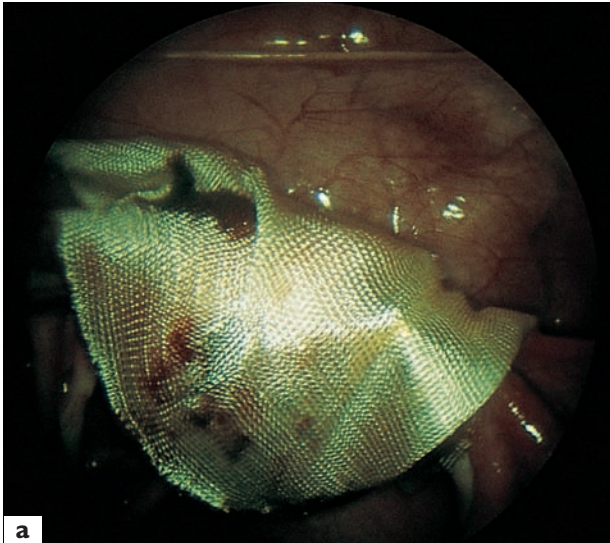


Figure 21.8 (a) and (b) Laparoscopic myolysis: to avoid adhesions, Interceed® is used to cover the laser scars

In 15 patients, second-look laparoscopy was carried out more than 6 months after myolysis for other reasons (ovarian cysts, sterilization, etc.). The appearance of the myoma was noted. In eight cases, dense and fibrous adhesions were observed between the myoma and, most frequently, the small bowel and/or epiploon. After adhesiolysis, the myoma appeared white, without any apparent vessels. In two cases, we decided to remove the myoma. Dissection of myomas from the normal myometrium proved surprisingly easy, and they were removed in order to evaluate histologically the efficacy of myolysis. There was necrosis in most myoma areas, characterized by edema and an absence of viable cells (Figure 21.9). In other areas, giant cells and macrophages containing carbonized particles (Figure 21.10) very close to the necrotic sites suggested that necrosis was actually induced by laser coagulation.

Figure 21.9 Specimen of myoma: (a) 6 months after myolysis; (b) and (c) necrosis characterized by edema and the absence of viable cells

Safety

Three prospective randomized studies have compared abdominal and laparoscopic myomectomy^{33–35}.

Mais and Seracchioli's groups showed that laparoscopic surgery is associated with shorter hospitalization, faster

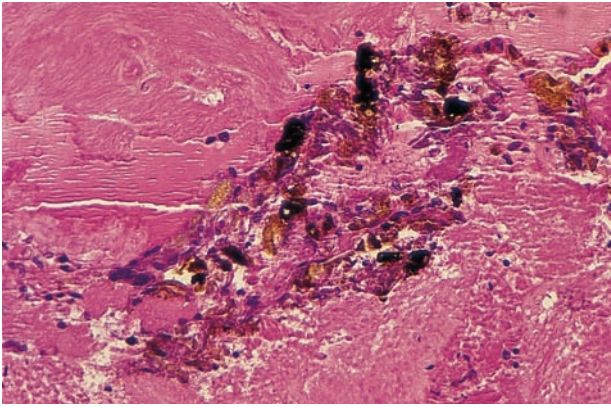


Figure 21.10 Histological evaluation of the myoma after myolysis: in some areas, giant cells and macrophages containing carbonized particles very close to the necrotic sites suggest that necrosis is induced by laser coagulation

recovery, less expense, less blood loss, less fever and fewer surgical complications than is abdominal myomectomy. Case-control studies by Stringer *et al.*³⁶ and Silva *et al.*³⁷ confirmed the benefits of laparoscopic myomectomy over abdominal myomectomy. In these two studies, however, surgery time was longer in the laparoscopy group.

Several case series have confirmed the feasibility and safety of laparoscopic myomectomy^{19,38-44}. Overall, these studies reveal a low complication rate. Surgery may take longer than with open procedures, but the recovery time is shorter. In these studies, the conversion rate to laparotomy was less than 2% of cases, even when large, deep myomas were resected. Some authors have reported the laparoscopic removal of very large myomas, up to 21 cm^{43,45,46}.

The main drawback of laparoscopic myomectomy is the risk of hemorrhage. In the three randomized studies, laparoscopy was not accompanied by increased blood loss, but in the study of Stringer *et al.*³⁶, blood loss was greater with laparoscopic myomectomy.

Are there objective factors predicting possible blood loss during laparoscopic myomectomy?

Blood loss seems to be correlated to myoma size. In the study of Sinha *et al.* of 91 women with myomas of at least 9 cm in size⁴⁶, 20 required transfusion during or after myomectomy. A woman in whom a 21-cm myoma was resected laparoscopically lost 2000 ml of blood and eventually underwent abdominal hysterectomy for dilutional coagulopathy.

In Takeuchi and Kinoshita's series⁴⁵, blood loss was significantly greater when myomas were over 10 cm in size. There was no association between blood loss and the number of myomas.

From these studies, it is reasonable to conclude that blood loss is related to myoma size. It is also reasonable to assume that blood loss is influenced by the surgeon's technical skill and experience.

How can blood loss be reduced during laparoscopic myomectomy?

Some surgeons inject vasopressin into myomas to reduce bleeding⁴⁴⁻⁴⁷. Others remove large myomas without the use of vasopressin³⁸. To our knowledge, no studies to date have proved the efficacy of vasopressin.

Another possibility is to perform ligation or coagulation of the uterine artery⁴⁸. The safety of this technique in women desiring pregnancy has not been proved, however.

In theory, preoperative gonadotropin-releasing hormone (GnRH) agonist therapy might shrink myomas, thereby simplifying myomectomy and diminishing blood loss. Three prospective randomized studies have evaluated the effect of preoperative treatment with GnRH agonists for laparoscopic myomectomy⁴⁹⁻⁵¹.

The principal advantage of GnRH agonists appears to be correction of anemia before surgery, and a slight reduction in blood loss. However, GnRH agonists make the procedure more difficult by occulting the plane of cleavage and increasing operating time and the risk of conversion⁵². Moreover, they may be associated with a higher recurrence rate⁵³. Preoperative GnRH therapy should not therefore be routinely used.

It is difficult to compare laparoscopic myomectomy with uterine artery embolization (UAE), as they involve two completely different techniques. In a review of published data from trials involving between 60 and 305 patients who underwent UAE, the symptom improvement rate was between 80 and 92% and the hysterectomy rate was between 0 and 2%⁵⁴.

Procedural complications secondary to arterial puncture, contrast injection, arterial catheterization and non-target-organ embolization are intrinsic to all embolization procedures, but are fortunately rare and minimized by the radiologist's experience.

Chronic discharge is relatively benign, affecting 7% of patients⁵⁵. Serious sequelae of UAE are infectious complications in 1-2% of cases⁵³. Infection can occur even months after the procedure, and is more common in case of large myomas. At least one case of death due to septicemia as a result of pyometrium has been reported⁵⁶.

Laparoscopic myolysis is not associated with safety problems other than the classic complications of laparoscopy.

Efficiency

As the purpose of myomectomy is to preserve fertility, the main short- and long-term issues are fertility outcome and pregnancy outcome.

Pregnancy after laparoscopic myomectomy and myolysis

The only prospective randomized study comparing laparoscopic and abdominal myomectomy³⁴ shows no difference in pregnancy rates between the two groups (54% v. 56%).

In the retrospective study of Campo *et al.*, comparing 22 women who underwent laparoscopic myomectomy with 19 women who underwent abdominal myomectomy, the pregnancy rates were found to be similar⁵⁷.

Overall, one can expect pregnancy rates to be similar after laparoscopic and abdominal myomectomy.

It is logical to assume that pregnancy rates are influenced by the presence of adhesions. There are no prospective randomized studies comparing adhesion formation between laparoscopic and abdominal myomectomy. However, prospective studies and surgical case series seem to point to an advantage with laparoscopy. Dubuisson *et al.*'s analysis of the literature shows that the rate of postoperative adhesions after laparoscopic myomectomy is, on average, 41.3%, and after abdominal myomectomy, 98%⁴⁰. However, the incidence of adhesions is very variable, ranging from less than 2% in Di Gregorio *et al.*'s report⁴² to 66% in the series of Hasson *et al.*⁵⁸.

These figures should be viewed with caution, however, as they are often derived from retrospective data, and there are a great many other confounding variables such as methodology, number of sites checked and types of adhesions.

Interestingly, when prospective studies are conducted to analyze the efficacy of adhesion barriers during laparoscopic myomectomy, the overall incidence of adhesions seems to be higher than in the retrospective case series.

Three prospective, randomized, controlled studies have evaluated the efficacy of these adhesion barriers. Mais *et al.*³³ concluded that oxidized regenerated cellulose (Interceed®; Gynecare) significantly reduced, but did not prevent, adhesions after laparoscopic myomectomy. Pellicano *et al.*⁵⁹ showed that, during second-look laparoscopy, 72% of patients were adhesion-free with the use of hyaluronic acid gel, compared with an adhesion-free rate of only 22% in the control group. Mettler *et al.*⁶⁰ reported a decrease in adhesion formation with the use of SprayGel®, a synthetic absorbable adhesion barrier. Whether any of these interventions enhance pregnancy rates or reduce clinical symptoms of pelvic adhesive disease remains to be proved.

No data are available on pregnancy rates after laparoscopic myolysis. However, very dense adhesions have been demonstrated in 10–50% of cases^{61,62}, which might impair fertility.

There are no randomized studies comparing pregnancy rates after laparoscopic myomectomy and uterine artery embolization. Although successful pregnancies have been achieved after UAE^{63–65}, serious complications of UAE can impair fertility. Amenorrhea complicates 1% of procedures⁵⁴. One to 2% of subjects experience ovarian failure⁶⁶, and postprocedural hysterectomy is necessary in 1–2% of patients, mostly for infectious complications⁶⁷. Olive *et al.*⁶⁸ described a significant rate of premature

ovarian failure and occasional damage to endometrial vasculature with atrophy and adhesion formation.

Laparoscopic myomectomy must therefore be considered a far better option for women wishing to preserve their fertility.

Pregnancy outcome after laparoscopic myomectomy and myolysis

In the only randomized trial to compare pregnancy outcome after laparoscopic and abdominal myomectomy³⁴, no significant differences were found in postoperative miscarriage rates or preterm deliveries. The cesarean section rate was 78% in the abdominal myomectomy group and 65% in the laparoscopic myomectomy group.

In other, non-controlled studies^{39,43,44,50}, cesarean section rates were between 45 and 80%. Overall, cesarean section rates vary widely, and seem to be similar after laparoscopic and abdominal myomectomy.

The only study to compare obstetric outcome after laparoscopic myomectomy and uterine artery embolization is a retrospective study by Goldberg *et al.*⁶⁹, which compared 53 pregnancies after uterine artery embolization with 139 pregnancies after laparoscopic myomectomy. This study showed a significant increase in preterm delivery and malpresentation after UAE.

A major concern after laparoscopic myomectomy is the risk of uterine rupture during pregnancy or labor due to insufficient closure or healing of the uterine incision. A few case reports in the literature report uterine rupture after laparoscopic myomectomy^{70–76}. Dubuisson *et al.* describe three uterine ruptures, all occurring before labor⁷⁷.

Extensive thermal damage due to the overaggressive use of electrosurgery has been blamed for poor vascularization and tissue necrosis, with adverse effects on scar strength⁷⁷. This risk does not appear to be related to the depth of the myoma, as in the case of Lieng *et al.*, the myoma removed was subserosal with a pedicle of 2–3 cm⁷⁶. Their patient achieved pregnancy by IVF 6 weeks after myomectomy. Lieng *et al.* therefore recommend waiting 3 months after myomectomy before attempting pregnancy.

However, these case reports do not allow us to draw any conclusions as to the relative risk, compared with abdominal hysterectomy. Moreover, there are no recent reports on the risk of uterine rupture after abdominal myomectomy.

Cases of uterine rupture during pregnancy after laparoscopic myolysis have also been published^{78–80}.

Overall, the prognosis for pregnancy in women who have undergone laparoscopic myomectomy appears to be comparable to that in published reports on abdominal myomectomy. Data are insufficient, however, to determine whether cesarean section should be routinely advocated for delivery after myomectomy.

Recurrence

In Rossetti *et al.*'s randomized trial, recurrence rates after laparoscopic and abdominal myomectomy were similar (23% and 27%)³⁵. Seracchioli *et al.* also showed no significant difference in a randomized trial³⁴. Marret *et al.* retrospectively analyzed 126 laparoscopic and 176 abdominal myomectomies, and found a 2.5% and 3.6% recurrence rate, respectively, at 2 years of follow-up⁸¹. In Doridot *et al.*'s retrospective analysis of 196 women who underwent laparoscopic myomectomy, recurrence was 12.7% at 2 years of follow-up and 16.7% at 5 years⁴¹. The risk of recurrence in this study was related to the number of myomas, and was higher in nulliparous women.

Figures on recurrence rates must be interpreted with caution, as imaging modality and duration of follow-up are likely to influence findings greatly.

Recurrence risk seems to be comparable after laparoscopic and abdominal myomectomy.

CONCLUSION

The two main issues that need to be addressed when uterine myomas are encountered are: which myomas should be removed, and which procedure should be used for this purpose. Myomas causing menorrhagia, pain or signs of bladder or bowel compression should generally be treated. In older women who have completed their families, hysterectomy might be considered the best option, and is indeed very successful in most cases. In symptomatic women with a desire for pregnancy, conservative treatment should be proposed. In asymptomatic women who present with infertility or who wish to conceive, there is no consensus on the indications for myomectomy.

Submucosal myomas should be removed. As far as intramural myomas are concerned, those distorting the uterine cavity should be removed. There is no general consensus on myomas not distorting the uterine cavity. We feel that it is acceptable to propose myomectomy for myomas of 4–5 cm in size.

Laparoscopic myomectomy is feasible, safe and comparable to abdominal myomectomy with respect to fertility and pregnancy outcomes. Its main advantage over abdominal myomectomy is the faster recovery time and shorter hospital stay. Its drawback is the risk of hemorrhage. This risk seems to be related to myoma size and influenced by the surgeon's experience.

In women of reproductive age, laparoscopic myomectomy must be favored over uterine artery embolization. Indeed, the latter technique is associated with complications impairing fertility, and further prospective trials should be conducted before proposing it to women wishing to preserve their fertility.

Laparoscopic myolysis is a feasible technique, but associated with a risk of adhesions and therefore not appropriate for young women.

REFERENCES

1. Verkauf BS. Myomectomy for fertility enhancement and preservation. *Fertil Steril* 1992; 58: 1–15
2. Bulletti C, De Ziegler D, Polli V, et al. The role of leiomyomas in infertility. *J Am Assoc Gynecol Laparosc* 1999; 6: 441–5
3. Deligdish L, Lowenthal M. Endometrial changes associated with myomata of the uterus. *J Clin Pathol* 1970; 23: 676–80
4. Buttram VC, Reiter RC. Uterine leiomyomata: etiology, symptomatology, and management. *Fertil Steril* 1981; 36: 433–45
5. Hunt JE, Wallach EE. Uterine factor in infertility: an overview. *Clin Gynecol* 1974; 17: 44–64
6. Vollen-Hoven BJ, Lawrence AS, Healy DL. Uterine fibroids: a clinical review. *Br J Obstet Gynaecol* 1990; 97: 285–8
7. Seoud MA, Patterson R, Muasher SJ, et al. Effects of myomas or prior myomectomy on in vitro fertilization performance. *J Assist Reprod Genet* 1992; 9: 217–21
8. Fahri J, Ashkenazi J, Feldberg D, et al. Effect of uterine leiomyomata on the results of in vitro fertilization treatment. *Hum Reprod* 1995; 10: 2576–8
9. Eldar-Geva T, Meagher S, Healy DL, et al. Effect of intramural, subserosal and submucosal uterine fibroids on the outcome of assisted reproductive technology treatment. *Fertil Steril* 1998; 70: 687–91
10. Healy DL. Impact of uterine fibroids on ART outcome. *Environ Health Perspect* 2000; 108: 845–7
11. Narayan R, Rajat Goswamy, K. Treatment of submucous fibroids, and outcome of assisted conception. *J Am Assoc Gynecol Laparosc* 1994; 1: 307–11
12. Ramzy AM, Satta M, Amin Y, et al. Uterine myomata and outcome of assisted reproduction. *Hum Reprod* 1998; 13: 198–202
13. Jun SH, Ginsburg ES, Racowsky C, et al. Uterine leiomyomas and their effect on in vitro fertilization outcome: a retrospective study. *Assist Reprod Genet* 2001; 18: 139–43
14. Yarali H, Bukulmez O. The effect of intramural and subserous uterine fibroids on implantation and clinical pregnancy rates in patients having intracytoplasmic sperm injection. *Arch Gynecol Obstet* 2002; 266: 30–3
15. Stovall DW, Parrish SB, Van Voorhis BJ, et al. Uterine leiomyomas reduce the efficacy of assisted reproduction cycles: results of a matched follow-up study. *Hum Reprod* 1998; 13: 192–7
16. Hart R, Khala Y, Yeong CT, et al. A prospective controlled study of the effect of intramural uterine fibroids on the outcome of assisted conception. *Hum Reprod* 2001; 16: 2411–17
17. Check JH, Choe JK, Lee G, Dietterich C. The effect on IVF outcome of small intramural fibroids not compressing the uterine cavity as determined by a prospective matched control study. *Hum Reprod* 2002; 17: 1244–8

18. Oliveira FG, Abdelmassih VG, Diamond MP, et al. Impact of subserosal and intramural uterine fibroids that do not distort the endometrial cavity on the outcome of in vitro fertilization–intracytoplasmic sperm injection. *Fertil Steril* 2004; 81: 582–7
19. Donnez J, Jadoul P. What are the implications of myomas on fertility? A need for a debate? *Hum Reprod* 2002; 17: 1424–30
20. Vercellini P, Maddalena S, De Giorgio O, et al. Determinants of reproductive outcome after abdominal myomectomy for infertility. *Fertil Steril* 1999; 72: 109–14
21. Fauconnier A, Chapron C, Babaki-Fard K, et al. Recurrence of leiomyomata after myomectomy. *Hum Reprod Update* 2000; 6: 595–602
22. Zollner U, Classen V, Steck T, et al. Fertility and pregnancy outcome after myomectomy. *Geburtshilfe Frauenheilk* 2001; 61: 213–19
23. Sudik R, Husch K, Steller J, et al. Fertility and pregnancy outcome after myomectomy in sterility patients. *Eur J Obstet Gynecol Reprod Biol* 1996; 65: 209–14
24. Dessolle L, Soriano D, Poncelet C, et al. Determinants of pregnancy rate and obstetric outcome after laparoscopic myomectomy for infertility. *Fertil Steril* 2001; 76: 370–4
25. Rossetti A, Sizzio O, Soranna L, et al. Fertility outcome: long-term results after laparoscopic myomectomy. *Gynecol Endocrinol* 2001; 15: 129–34
26. Ancien P, Querada F. Abdominal myomectomy: results of a simple operative technique. *Fertil Steril* 1996; 65: 41–51
27. American Society for Reproductive Medicine Practice Committee. Myomas and reproductive function. American Society for Reproductive Medicine Practice Committee Report, Nov 2001. Available on-line at <http://www.asrm.org/membersonly/practice/myomas.pdf>
28. Benson CB, Chow JS, Chang-Lee W, et al. Outcome of pregnancies in women with uterine leiomyomas identified by sonography in the first trimester. *J Clin Ultrasound* 2001; 29: 261–4
29. Sheiner E, Bashiri A, Levy A, et al. Obstetric characteristics and perinatal outcome of pregnancies with uterine leiomyomas. *J Reprod Med* 2004; 49: 182–6
30. Li TC, Mortimer R, Cooke ID. Myomectomy: a retrospective study to examine reproductive performance before and after surgery. *Hum Reprod* 1999; 14: 1735–40
31. Marchionni M, Fambrini M, Zambelli V, et al. Reproductive performance before and after abdominal myomectomy: a retrospective analysis. *Fertil Steril* 2004; 82: 154–9
32. Nisolle M, Smets M, Gillerot S, et al. Laparoscopic myolysis with the Nd:YAG laser. *J Gynecol Surg* 1993; 9: 95–9
33. Mais V, Ajossa S, Piras B, et al. Prevention of de-novo adhesion formation after laparoscopic myomectomy: a randomized trial to evaluate the effectiveness of an oxidized regenerated cellulose absorbable barrier. *Hum Reprod* 1995; 10: 3133–5
34. Seracchioli R, Rossi S, Govoni F, et al. Fertility and obstetric outcome after laparoscopic myomectomy of large myomata: a randomized comparison with abdominal myomectomy. *Hum Reprod* 2000; 15: 2663–8
35. Rossetti A, Sizzi O, Soranna L, et al. Long term results of laparoscopic myomectomy: recurrence rate in comparison with abdominal myomectomy. *Hum Reprod* 2001; 16: 770–4
36. Stringer NH, Walker JC, Meyer PM. Comparison of 49 laparoscopic myomectomies with 49 open myomectomies. *J Am Assoc Gynecol Laparosc* 1997; 4: 457–64
37. Silva BA, Falcone T, Bradley L, et al. Case-controlled study of laparoscopic versus abdominal myomectomy. *J Laparoendosc Adv Surg Tech* 2000; 10: 191–7
38. Adamian LV, Kulakov VI, Kiselev SI, Murashkov AV. Laparoscopic myomectomy in treatment of large myomas. *J Am Assoc Gynecol Laparosc* 1996; 3 (Suppl): S1
39. Seineira P, Arisio R, Decko A, et al. Laparoscopic myomectomy: indications, surgical technique and complications. *Hum Reprod* 1997; 12: 1927–30
40. Dubuisson JB, Fauconnier A, Deffarges JV, et al. Pregnancy outcome and deliveries following laparoscopic myomectomy. *Hum Reprod* 2000; 15: 869–73
41. Doridot V, Dubuisson JB, Chapron C, et al. Recurrence of leiomyomata after laparoscopic myomectomy. *J Am Assoc Gynecol Laparosc* 2001; 8: 495–500
42. Di Gregorio A, Maccario S, Raspollini M. The role of laparoscopic myomectomy in women of reproductive age. *Reprod Biomed Online* 2002; 4: 55–8
43. Malzoni M, Rotond M, Perone C, et al. Fertility after laparoscopic myomectomy of large uterine myomas: operative technique and preliminary results. *Eur J Gynaecol Oncol* 2003; 24: 79–82
44. Landi S, Fiaccavento A, Zaccoletti R, et al. Pregnancy outcomes and deliveries after laparoscopic myomectomy. *J Am Assoc Gynecol Laparosc* 2003; 10: 177–81
45. Takeuchi H, Kinoshita K. Evaluation of adhesion formation after laparoscopic myomectomy by systematic second-look microlaparoscopy. *J Am Assoc Gynecol Laparosc* 2002; 9: 442–6
46. Sinha R, Hegde A, Warty N, Patil N. Laparoscopic excision of very large myomas. *J Am Assoc Gynecol Laparosc* 2003; 10: 461–8
47. Hurst BS, Matthews ML, Marshburn PB. Laparoscopic myomectomy for symptomatic uterine myomas. *Fertil Steril* 2005; 83: 1–23
48. Sinha RY, Hegde A, Warty N, Jain R. Laparoscopic devascularization of uterine myomata followed by enucleation of the myomas by direct morcellation. *J Am Assoc Gynecol Laparosc* 2004; 11: 99–102
49. Zullo F, Pellicano M, DeStefano R, et al. A prospective randomised study to evaluate leuprolide acetate treatment before laparoscopic myomectomy; efficacy and ultrasonographic predictors. *J Am Assoc Gynecol Laparosc* 1998; 178: 108–12

50. Campo S, Garcea N. Laparoscopic myomectomy in premenopausal women with and without pre-operative treatment using gonadotrophin-releasing hormone analogues. *Hum Reprod* 1999; 14: 44–8
51. Palomba S, Morelli M, Noia R, et al. Short-term administration of tibolone plus GnRH analog before laparoscopic myomectomy. *J Am Assoc Gynecol Laparosc* 2002; 9: 170–4
52. Dubuisson JB, Fauconnier A, Fourchette V, et al. Laparoscopic myomectomy: predicting the risk of conversion to an open procedure. *Hum Reprod* 2001; 16: 1726–31
53. Vercellini P, De Giorgi O, Aimi G, et al. Abdominal myomectomy for infertility: a comprehensive review. *Hum Reprod* 1998; 13: 973–9
54. Belli AM. Uterine artery embolization for the treatment of fibroids. *CME Radiol* 2002; 3: 20–5
55. Reidy JF, Bradley EA, Forman RG, et al. Uterine artery embolisation. Results in 234 patients [Abstract]. *Minim Invasive Ther Allied Technol* 1999; 8 (Suppl): 26
56. Vashisht A, Studd J, Carey A, Burn P. Fatal septicaemia after fibroid embolisation. *Lancet* 1999; 354: 307–8
57. Campo S, Campo V, Gambadauro P. Reproductive outcomes before and after laparoscopic or abdominal myomectomy for subserous or intramural myomas. *Eur J Obstet Gynecol Reprod Biol* 2003; 110: 215–19
58. Hasson HM, Rotman C, Rana N, et al. Laparoscopic myomectomy. *Obstet Gynecol* 1992; 80: 884–8
59. Pellicano M, Bramante S, Cirillo D, et al. Effectiveness of autocrosslinked hyaluronic acid gel after laparoscopic myomectomy in infertile patients: a prospective, randomized, controlled study. *Fertil Steril* 2003; 80: 441–4
60. Mettler L, Audebert A, Lehmann-Willenbrock E, et al. A randomised, prospective, controlled, multicenter clinical trial of a sprayable, site-specific adhesion barrier system in patients undergoing myomectomy. *Fertil Steril* 2004; 82: 398–404
61. Zreik T, Rutherford T, Palter S. Cryomyolysis: a new procedure for the conservative treatment of uterine fibroids. *J Am Assoc Gynecol Laparosc* 1998; 1: 33–8
62. Donnez J, Squifflet JL, Polet R. Laparoscopic myolysis. *Hum Reprod Update* 2000; 6: 609–13
63. Forman RG, Reidy J, Nott V, et al. Fibroids and fertility. Presented at the SMIT/CIMIT 11th annual scientific meeting, Boston, MA, September 1999
64. Ravina JH, Vigneron NC, Aymard A, et al. Pregnancy after embolization of uterine myoma: report of 12 cases. *Fertil Steril* 2000; 73: 1241–3
65. McLucas B, Goodwin S, Adler L, et al. Pregnancy following uterine fibroid embolization. *Int J Gynecol Obstet* 2001; 74: 1–7
66. Hurst BS, Stachhouse DJ, Matthews ML, Marshburn PB. Uterine artery embolization for symptomatic uterine myomas. *Fertil Steril* 2000; 74: 355–69
67. Godfrey CD, Zbella EA. Uterine necrosis after uterine artery embolisation for leiomyoma. *Obstet Gynecol* 2001; 98: 950–2
68. Olive DL, Lindheim SR, Pritts EA. Non-surgical management of leiomyoma: impact on fertility. *Curr Opin Obstet Gynecol* 2004; 16: 239–43
69. Goldberg J, Pereira L, Berghella V, et al. Pregnancy outcomes after treatment for fibromyomata: uterine artery embolization versus laparoscopic myomectomy. *Am J Obstet Gynecol* 2004; 191: 18–21
70. Harris WWJ. Uterine dehiscence following laparoscopic myomectomy. *Obstet Gynecol* 1992; 80: 545–6
71. Mecke H, Wallas F, Brocher A. Pelviskopische Myomenukleation: Technik, Grenzen, Komplikationen. *Geburtshilfe Frauenheilk* 1995; 55: 374–9
72. Friedman W, Maier RF, Luttkus A. Uterine rupture after laparoscopic myomectomy. *Acta Obstet Gynecol Scand* 1996; 75: 683–4
73. Pelosi M, Pelosi MA. Spontaneous uterine rupture at thirty-three weeks subsequent to previous superficial laparoscopic myomectomy. *Am Obstet Gynecol* 1997; 177: 1547–9
74. Hockstein S. Spontaneous uterine rupture in the early third trimester after laparoscopically assisted myomectomy. *J Reprod Med* 2000; 45: 139–41
75. Malberti S, Ferrari L, Milani R. Spontaneous uterine rupture in the third trimester of gestation after laparoscopic myomectomy. A case report. *Minerva Ginecol* 2004; 56: 479–80
76. Lieng M, Istre O, Langebrekke A. Uterine rupture after laparoscopic myomectomy. *J Am Assoc Gynecol Laparosc* 2004; 11: 92–3
77. Dubuisson JB, Chavet X, Chapron C, et al. Uterine rupture after laparoscopic myomectomy. *Hum Reprod* 1995; 10: 1475–7
78. Arcangeli S, Pasqualette M. Gravid uterine rupture after myolysis. *Obstet Gynecol* 1997; 49: 857
79. Vilos G, Daly L, Tse B. Pregnancy outcome after laparoscopic electromyolysis. *J Am Assoc Gynecol Laparosc* 1998; 5: 289–92
80. Nkemayim DC, Hammadeh ME, Hippach M, et al. Uterine rupture in pregnancy subsequent to previous laparoscopic electromyolysis. Case report and review of literature. *Arch Gynecol Obstet* 2000; 264: 154–6
81. Marret H, Chevillot M, Giraudeau B. Study Group of the French Society of Gynaecology and Obstetrics. A retrospective multicentre study comparing myomectomy by laparoscopy and laparotomy in current surgical practice. What are the best patient selection criteria? *Eur J Obstet Gynecol Reprod Biol* 2004; 117: 82–6

LASH: laparoscopic subtotal hysterectomy – a series of 1400 cases

J Donnez, J Squifflet, O Donnez, M Smets, P Jadoul

INTRODUCTION

The development of new accessories and improved technology has enabled gynecologists to perform laparoscopic hysterectomy. Reich *et al.*¹ described the technique of laparoscopic hysterectomy for the first time in 1989. Laparoscopy-assisted vaginal hysterectomy and bilateral salpingo-oophorectomy have been routinely performed since 1990² in cases of endometrial cancer and benign gynecological disease in our department as well as others^{3–5}. Several series^{2,6–8} have documented shorter hospital stays and recovery times in women undergoing laparoscopic hysterectomy.

In 1990, we performed the first ever laparoscopic subtotal (supracervical) hysterectomy in our department, which we named LASH, and the first series of 32 cases was published in 1993⁷. Subsequently, a series of 500 cases was described⁹. From 1994 to 2005, 1363 laparoscopic supracervical hysterectomies were performed in our department (Table 22.1).

The incidence of LASH in our series of hysterectomies was 40%. It increased from an incidence of 2% (1990) to 46% (1995) and then remained around 40%, with a small drop between 2000 and 2003 in favor of total laparoscopic hysterectomy (LH).

During 2004–2005, the incidence of the various techniques was 41% LASH, 49% LH, 8.5% vaginal hysterectomy (VH) and 1.5% abdominal hysterectomy (AH). The rate of abdominal hysterectomy is 1.5% in our department, although, as cited in a recent review by

Garry¹⁰, most hysterectomies are performed as abdominal hysterectomies (UK 64%, USA 63%).

One of our publications in the *New England Journal of Medicine* has demonstrated that the laparoscopic approach is not expensive if non-disposable material is used¹¹.

SURGICAL PROCEDURE

All patients had a standard Papanicolaou smear, colposcopy and hysteroscopic cervical canal evaluation, and all received general anesthesia. Following the induction of general intratracheal anesthesia, the patient was placed in the dorsal lithotomy position. The abdomen and the vagina were prepared with a diluted iodine solution. A Foley catheter was inserted. Two Pozzi forceps were placed on the cervix, and a non-metallic intrauterine cannula was inserted into the uterine cavity in order to manipulate the uterus easily. A four-puncture technique was used for LASH. Three 5-mm second-puncture trocars were inserted: one 3 cm above the symphysis pubis and the others 4–5 cm laterally, in each lower quadrant within the safety triangles (between the midline and the epigastric artery area). A 10-mm laparoscope connected to a video camera was placed intraumbilically. After careful inspection of the entire peritoneal cavity, the patient was moved into the Trendelenburg position. Only one surgical method was used to transect pelvic ligaments and achieve hemostasis: bipolar coagulation and transection. Because endoscopic staplers are very expensive, bipolar coagulation (Storz bipolar grasping forceps, 3 mm wide) and

Table 22.1 A series of 3405 hysterectomies for benign diseases

Procedures	1994–1995		1996–1997		1998–1999		2000–2001		2002–2003		2004–2005		Total	
	n	%	n	%	n	%	n	%	n	%	n	%	n	%
LASH	236	46	240	41.5	248	43.5	205	38	179	30	255	41	1363	40
LAVH/LH*	130	26	127	22	177	31	203	37.5	294	50	302	49	1233	36
Vaginal hysterectomy	82	16	159	27.5	111	19.5	102	19	94	16	53	8.5	601	18
Abdominal hysterectomy	60	12	52	9	32	6	31	5.5	24	4	9	1.5	208	6
Total	508		578		568		541		591		619		3405	

*In 2000 we switched from LAVH to LH; LASH, laparoscopic subtotal hysterectomy; LAVH, laparoscopy-assisted vaginal hysterectomy; LH, laparoscopic hysterectomy

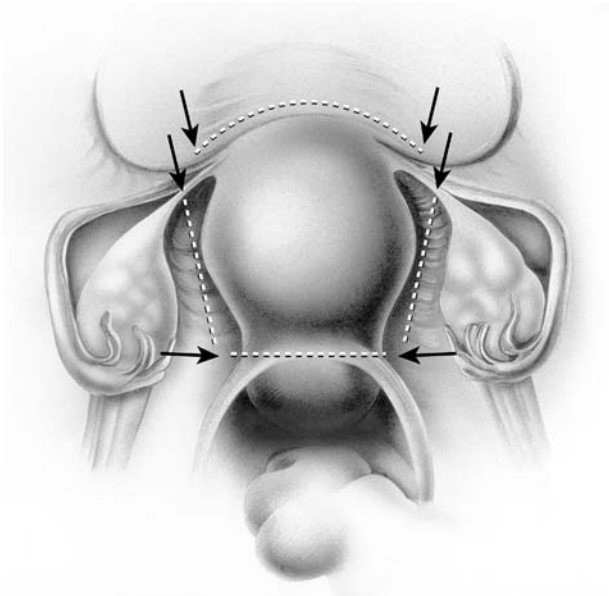
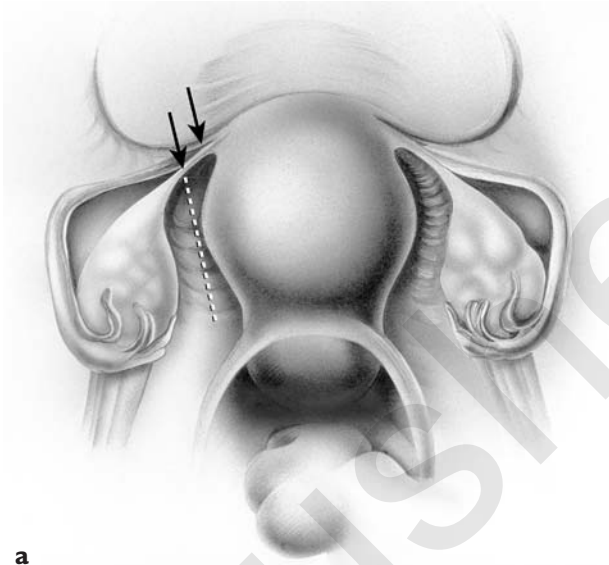


Figure 22.1 Laparoscopic subtotal hysterectomy technique

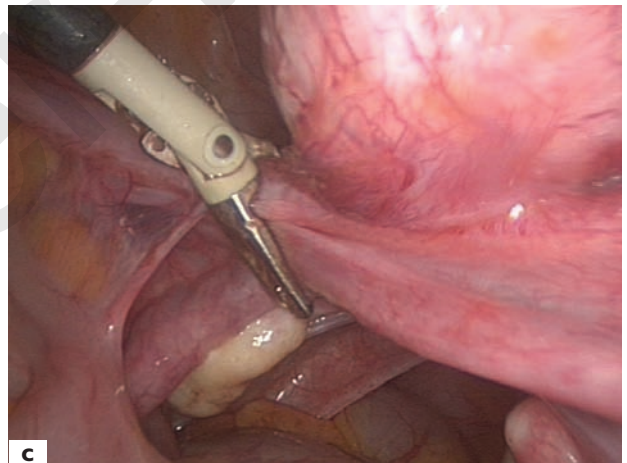
transection were systematically performed. Bipolar coagulation was used to desiccate the utero-ovarian ligaments and vessels and the isthmic portion of both Fallopian tubes (Figures 22.1–22.4).

Scissors were then used to transect the structures within the coagulated areas. Meticulous hemostasis was achieved by repeated bipolar coagulation of transected vessels. If a bilateral (or unilateral) salpingo-oophorectomy was required, the infundibulopelvic ligaments were similarly coagulated and transected. The round ligaments were treated in the same way.

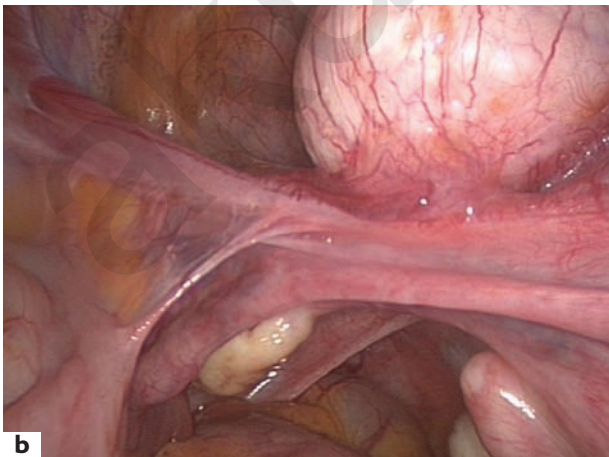
The anterior leaf and the posterior leaf of the broad ligament were then opened with scissors. Hydrodissection facilitated the procedure and allowed the surgeon to expose the uterine vessels. The vesicouterine peritoneum was then opened with scissors (Figure 22.5). The vesicocervical space was dissected no more than 2 cm below the limit between the cervix and the corpus uteri. After careful identification of the uterine vessels and ureters, the uterine vessels were electrocoagulated with the bipolar coagulation forceps and transected (Figures 22.6 and 22.7). The



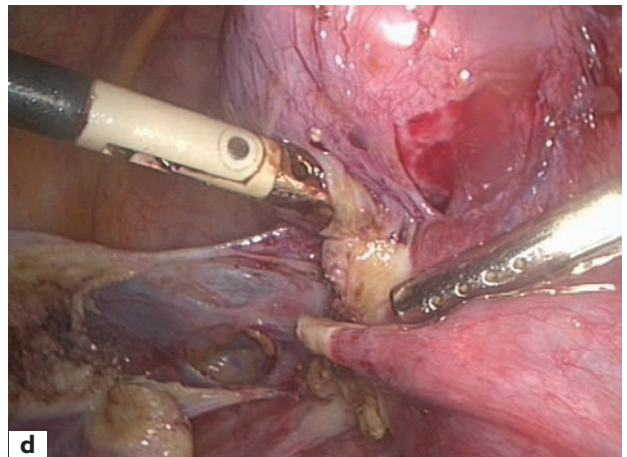
a



c

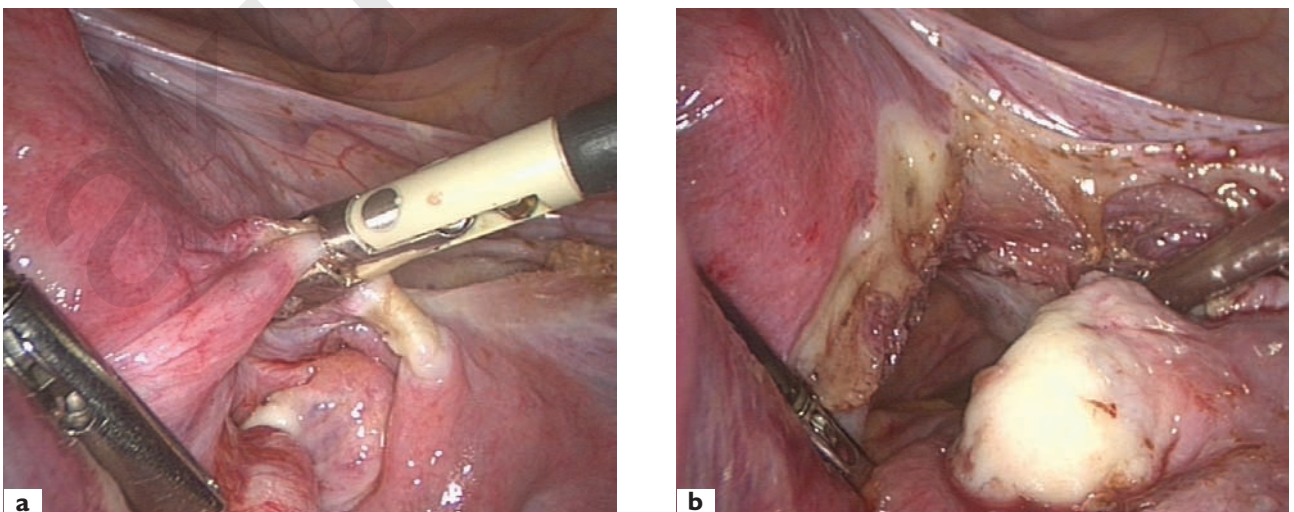
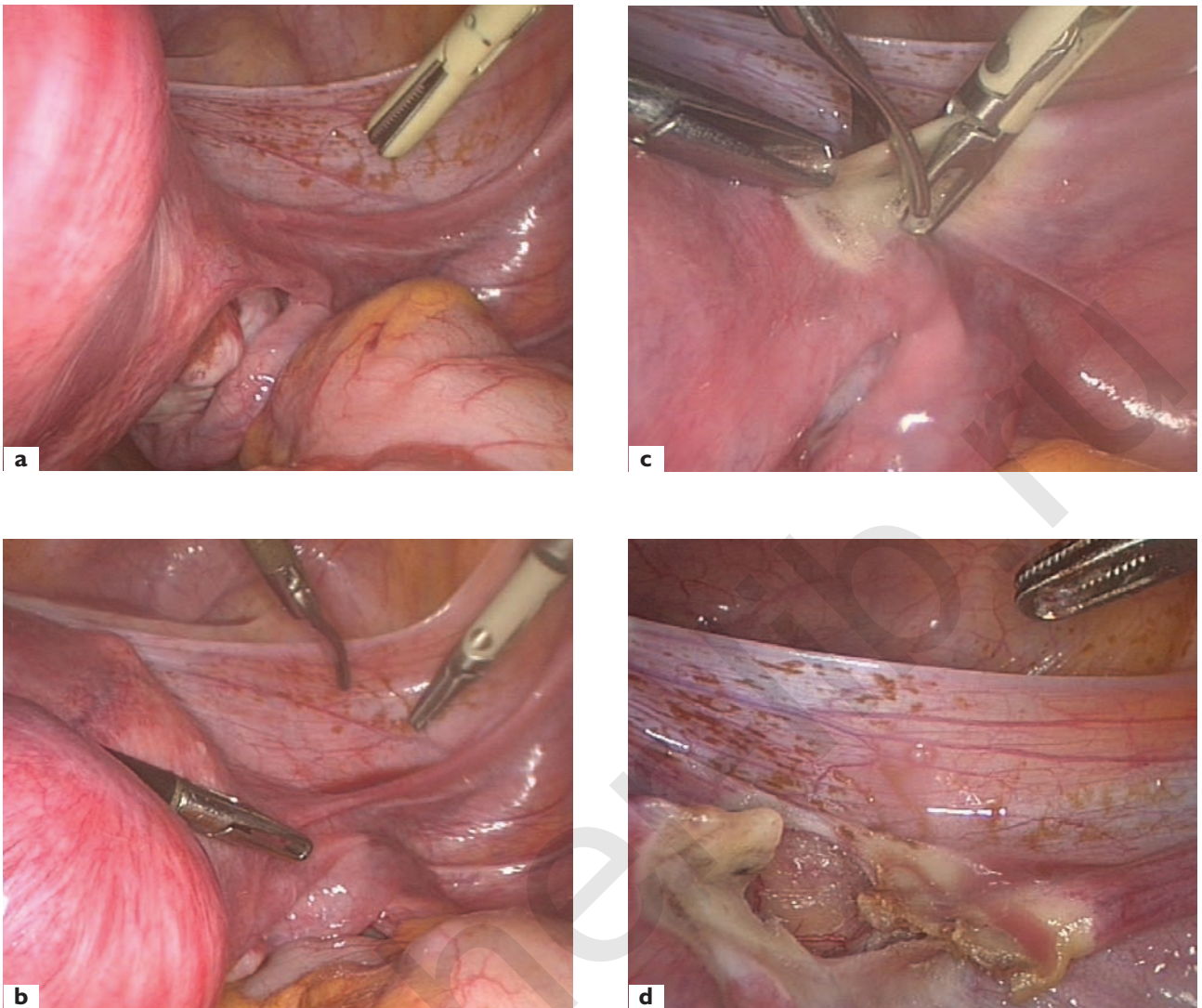


b



d

Figure 22.2 (a) First step: coagulation of the round ligament, Fallopian tube and uterolateral ovarian ligament. (b)–(d) Coagulation and section of the round ligament, Fallopian tube and utero-ovarian ligament on the left side



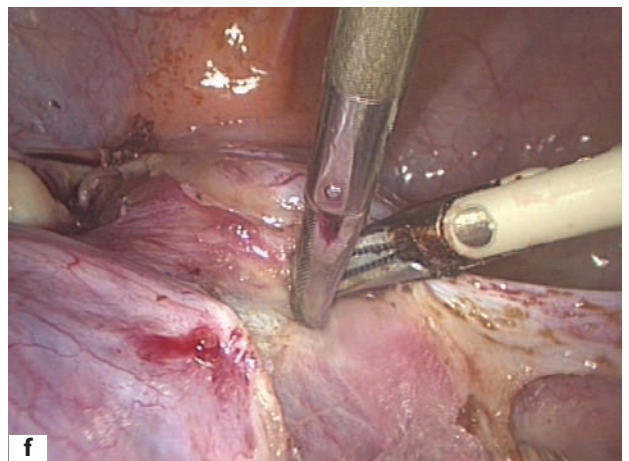
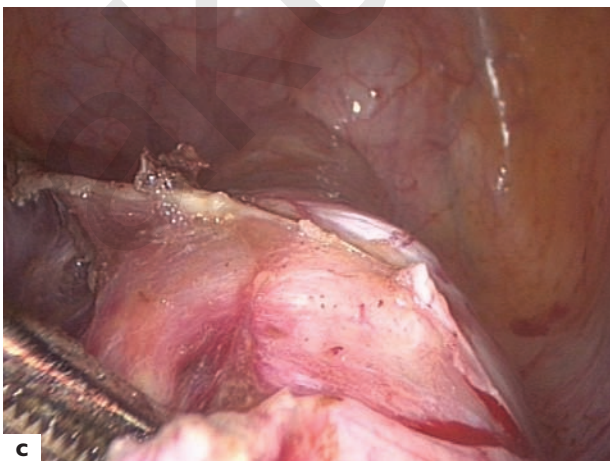
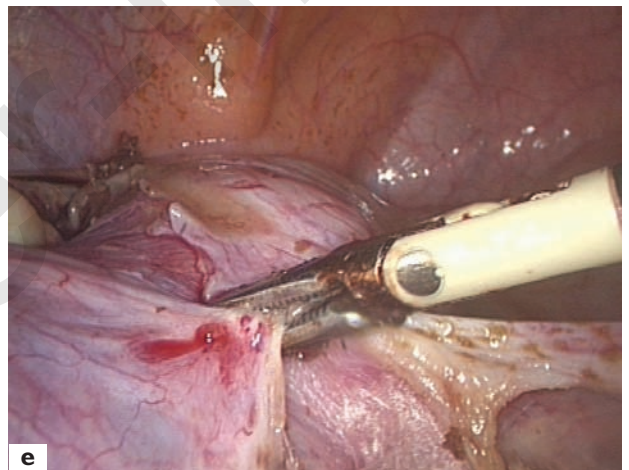
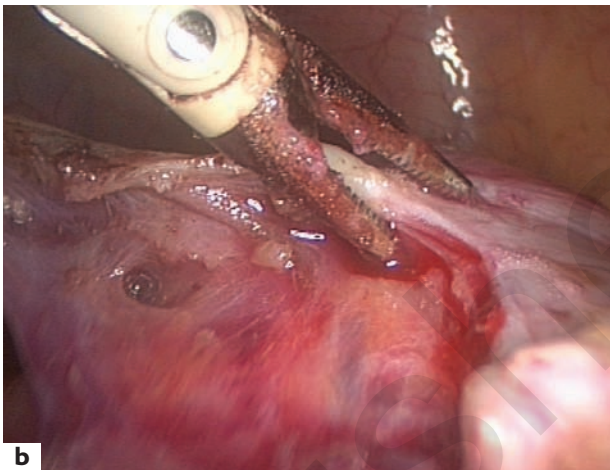
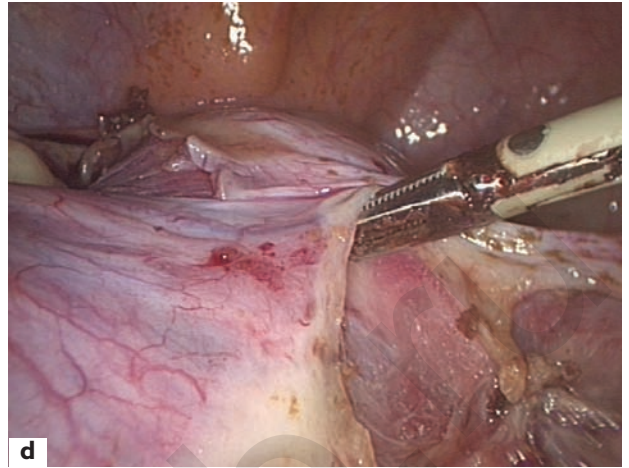
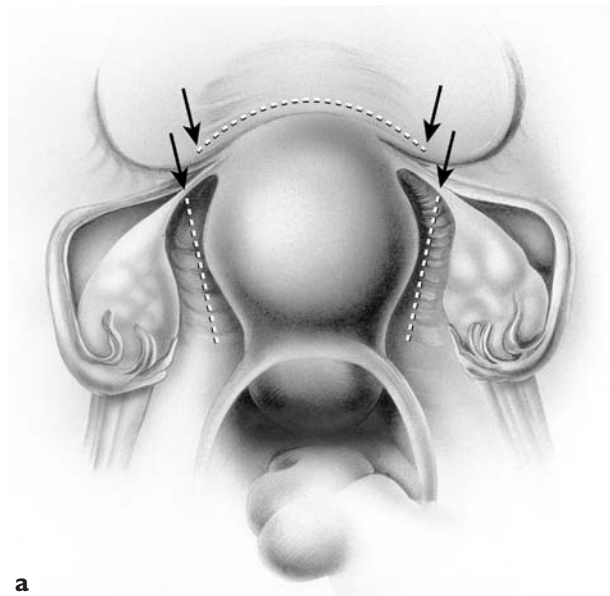


Figure 22.5 (a)–(f) Dissection and section of the vesicouterine peritoneum

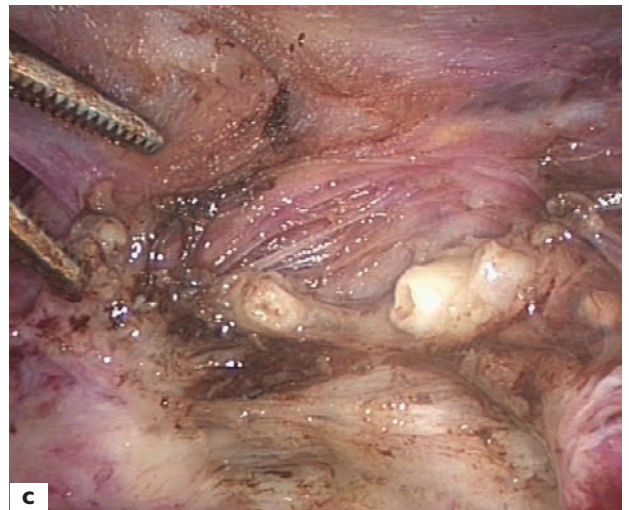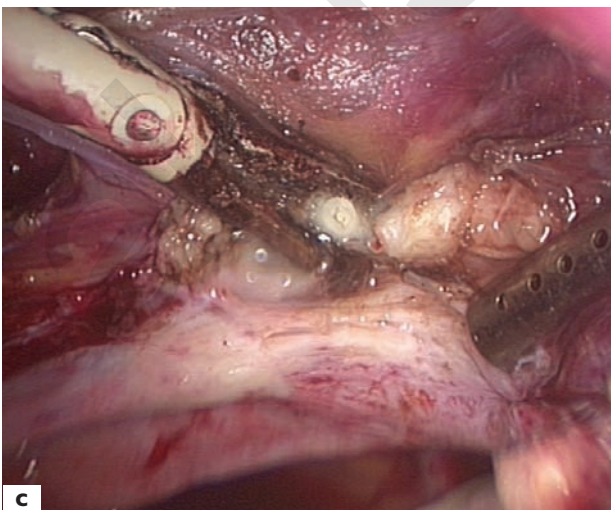
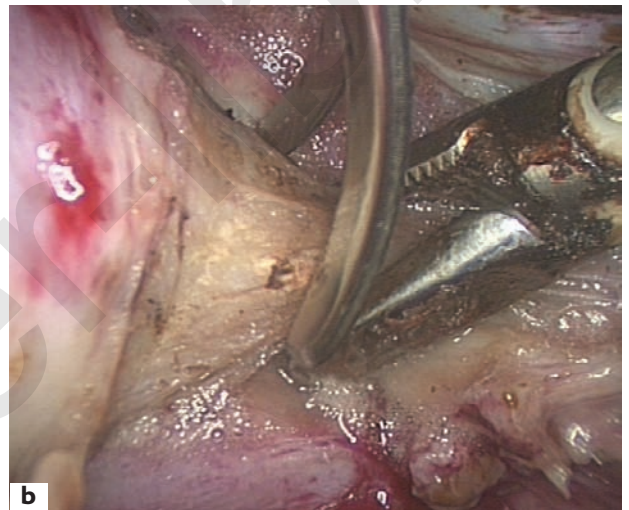
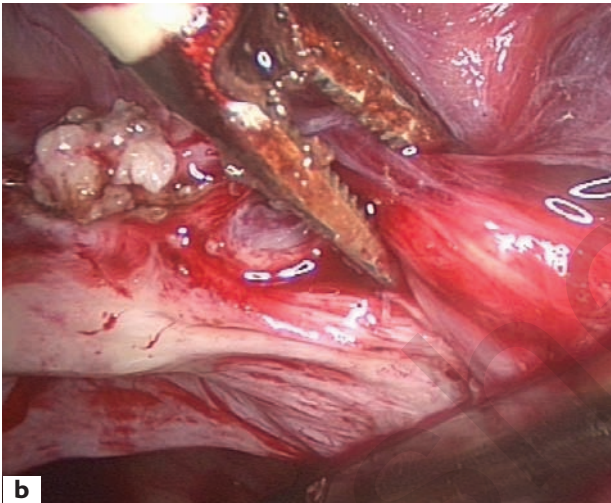
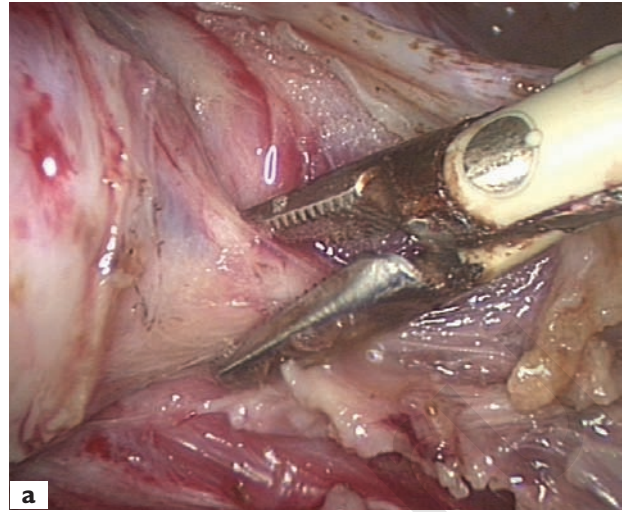
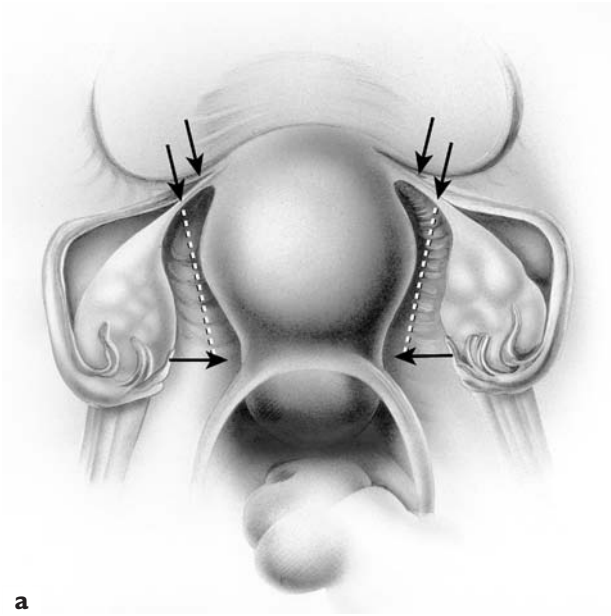


Figure 22.6 (a)–(c) Grasping coagulation and section of the left uterine artery

Figure 22.7 (a)–(c) Coagulation and section of the right uterine artery

unipolar knife or unipolar scissors were then used to cut the cervix below the level of the internal os and separate the cervix from the corpus (Figures 22.8 and 22.9). Hemostasis was achieved by meticulous coagulation.

Until November 1993, longitudinal (vertical or horizontal) posterior colpotomy was performed, either by laparoscopy or through the vagina. Since then, however, the uterus has been removed through a 12-mm trocar after morcellation using Steiner's morcellator¹² (Figures 22.10–22.12). A new morcellator enables the time of morcellation to be reduced (Figure 22.13) (Rotocut™; Storz, Tuttlingen).

Irrigation fluid was instilled into the pelvis and the operative sites were inspected. A titanium clip was then applied to the uterine artery to ensure complete hemostasis.

The cervical stump was never reperitonealized. The instruments were removed from the abdomen and the four incisions were reapproximated with 2-0 nylon suture.

Prophylactic antibiotics (cephalosporin (Zinacef®) 2 g/dl) were administered just before the procedure (5 min before the incision).

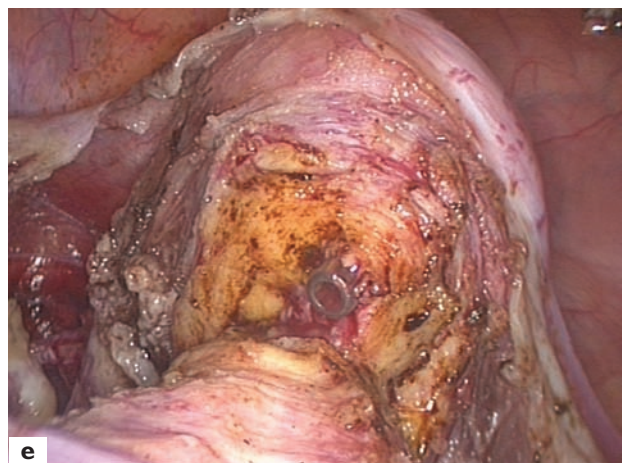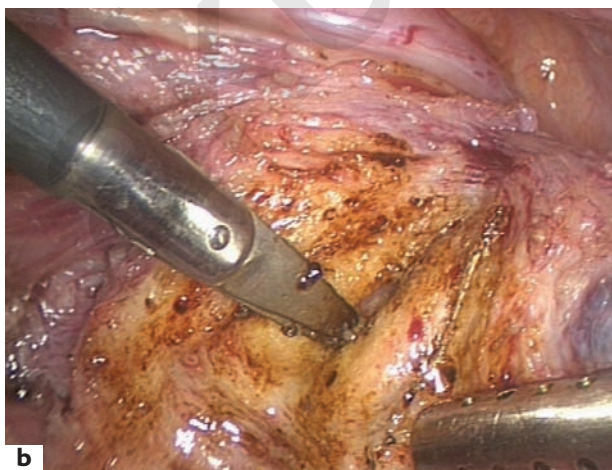
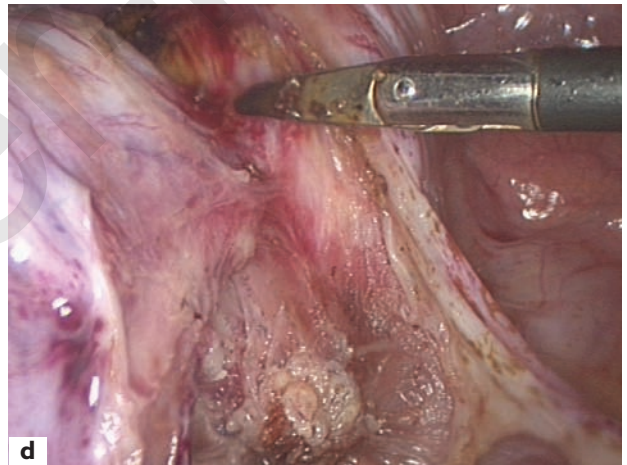
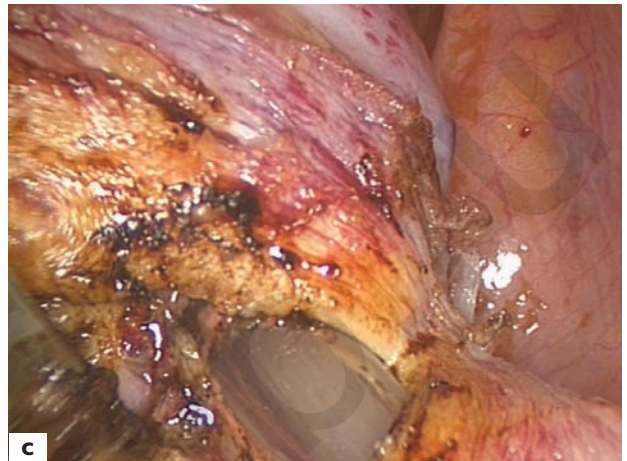
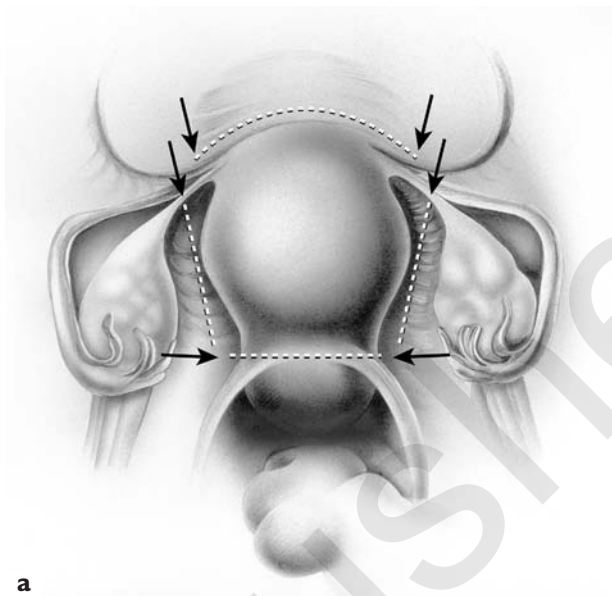


Figure 22.8 (a)–(g) Section of the cervix; the plastic uterine cannula becomes visible

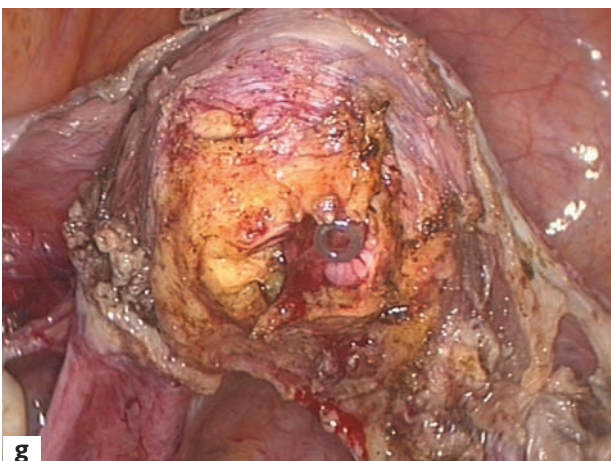
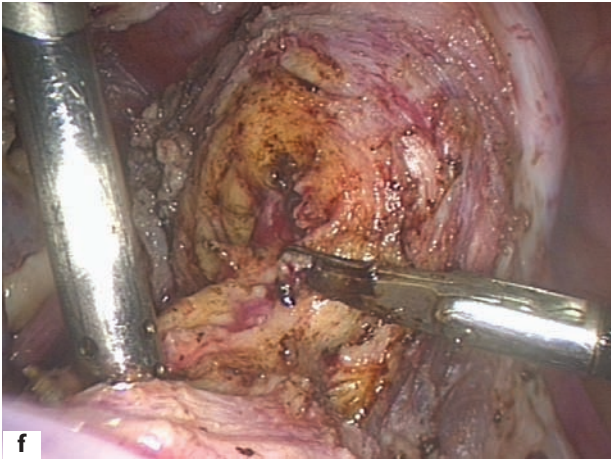


Figure 22.8 *continued* (a)–(g) Section of the cervix; the plastic uterine cannula becomes visible

RESULTS

All of our LASH procedures were successful. The patients' ages ranged from 34 to 57 years. The mean duration of surgery was 72 min (morcellation included), depending essentially on the uterus weight. In the majority of cases, in experienced hands, the average duration is about 45 min, although in university teaching hospitals the learning curve of registrars leads to an increase in surgery duration. The estimated blood loss was systematically less than 100 ml. There were no intraoperative bowel injuries (Table 22.2). Three ureteral injuries occurred. One ureter was found to be 'blanching' during surgery. A double JJ stent was immediately placed. Two cases of ureteral fistula, caused by thermal damage, were treated by JJ stent. Three patients experienced postoperative fever. All patients were theoretically able to leave the hospital the first day following surgery. Many, however, preferred to stay 2 days,

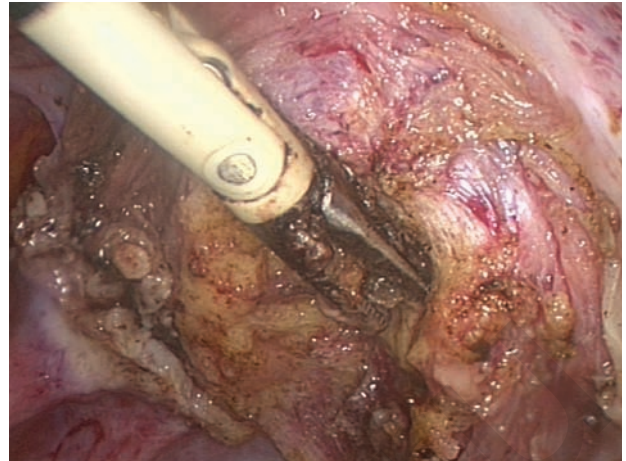


Figure 22.9 Coagulation of the endocervical canal

knowing that the Belgian insurance system offers reimbursement for up to 7 days' hospitalization.

In 2000, the length of hospital stay after surgery ranged from 4 to 5 days for vaginal hysterectomy, 3 to 4 days for laparoscopy-assisted vaginal hysterectomy (LAVH) and 5 to 8 days for abdominal hysterectomy (mostly dependent on the age of the patient). Patients who underwent LASH reported much less discomfort than patients who underwent other types of hysterectomy. No patients required major analgesic drugs. Only 8% of patients required analgesic drugs a few hours after surgery, but no patients required drugs the day after surgery.

Patients were able to ambulate very soon after LASH (the same day), similar to patients who underwent laparoscopic adhesiolysis, ovarian cystectomy or salpingo-oostomy.

Sexual intercourse was permitted 2 weeks after surgery. There was only one case of cervical prolapse, and no signs of enterocele were observed in patients reviewed in a 5-year follow-up ($n = 349$). There were no complaints of genuine urinary incontinence except in one case. This patient, however, had already complained of genuine urinary incontinence before LASH, and physiotherapy and biofeedback therapy were proposed at this time. As no improvement was seen after 1 year, surgery was required, and the patient underwent a laparoscopic Burch procedure in 1994.

In seven patients, laparoscopy was performed because of a 'tumor' located in the pouch of Douglas, causing deep dyspareunia. Symptoms were due to iatrogenic 'adenomyomas', specimens of endometrium and myometrium of the morcellated uterus, which had not been removed during the first laparoscopy (LASH). Laparoscopy allowed us to dissect the 'forgotten' specimen, which was covered with peritoneum (submitted for publication).

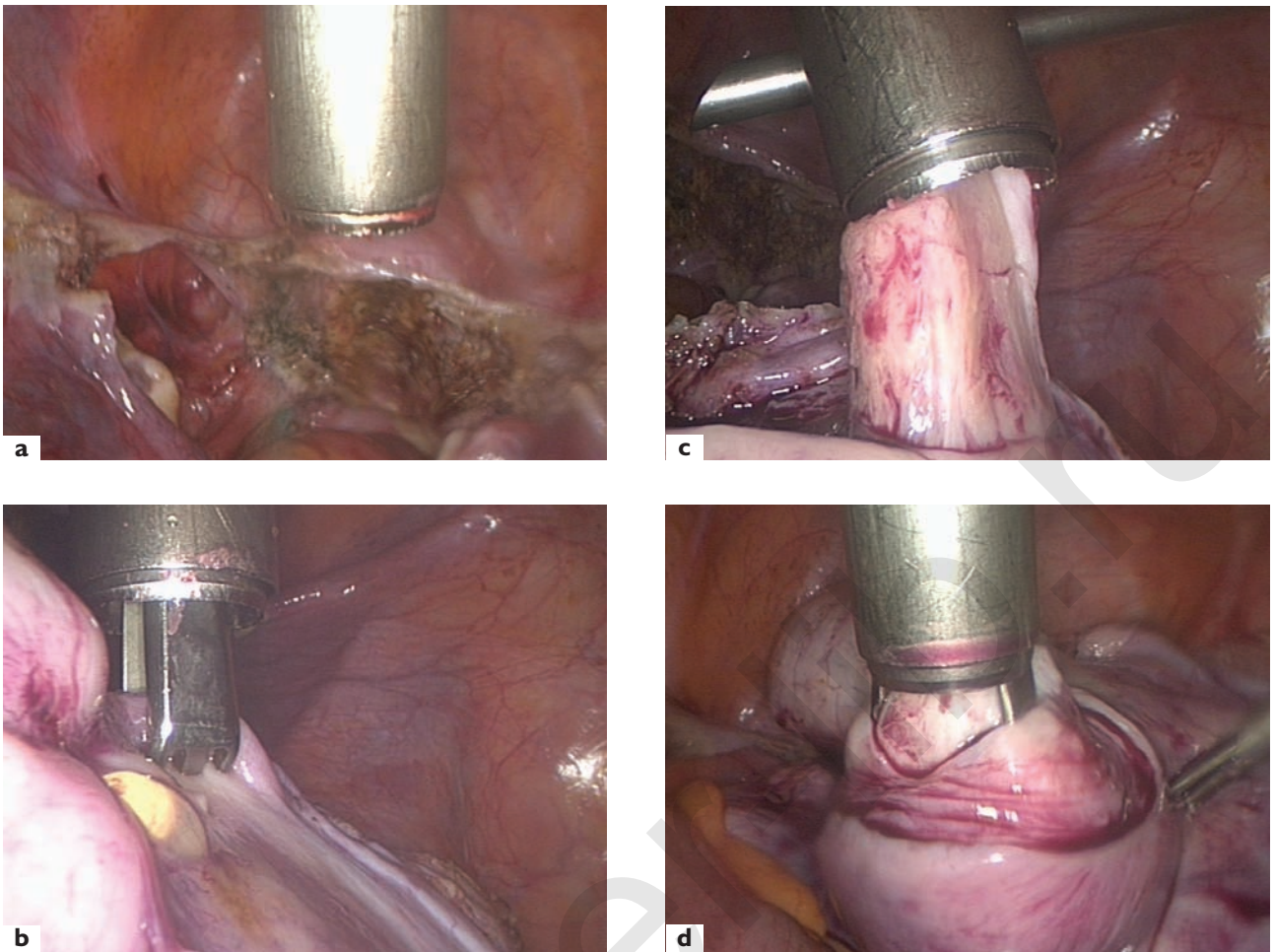


Figure 22.10 (a)–(d) Morcellation of the uterus with a morcellator

COMMENTS

The indications for laparoscopic surgery have expanded greatly over recent decades. An increase has also been seen in the field of hysteroscopic surgery. Endometrial ablation performed endoscopically has been proposed as an alternative to hormonal therapy or hysterectomy in dysfunctional bleeding without intrauterine lesions¹³. Hysteroscopic myomectomy has also been proposed for large submucosal myomas. In our team, the long-term results of hysteroscopic myomectomy were found to be excellent in cases of large submucosal fibroids fewer than three in number. Indeed, in our series, recurrence of menorrhagia did not exceed 5% after a 2-year follow-up. However, in cases of multiple (more than four) submucosal fibroids, recurrence of bleeding due to recurrent myomas was found to be as high as 25%, even when endometrial ablation was performed concomitantly^{13–16}. This is why hysteroscopic management of uterine bleeding cannot be systematically proposed, and why an alternative surgical approach was suggested.

In 1990, the LASH technique was not frequently used in our department. Indeed, in a series of 204 hysterectomies carried out in the department in 1990, only four LASH procedures (2%) were performed. At the time, the disadvantage of the technique, which is the remaining cervix, was considered a potential risk factor for cervical cancer. It is obvious that the risk is low in some groups of the population.

Moreover, this question is never asked when endometrial ablation is performed. Subsequently, the incidence of LASH increased from just 2% to 46% of all hysterectomies (Table 22.1). Since the uterus can be removed laparoscopically with the help of Steiner's morcellator or with the new Rotocut (Figure 22.13), LASH must be considered as a strictly laparoscopic approach to hysterectomy. No patients required major analgesics the day after surgery.

Indeed, a serious complication rate of 11% was recently reported after LAVH and LH in two randomized controlled trials in the UK¹⁷. Ureteral and/or bladder damage occurred at a rate of 2% after LH. Six ureteral and

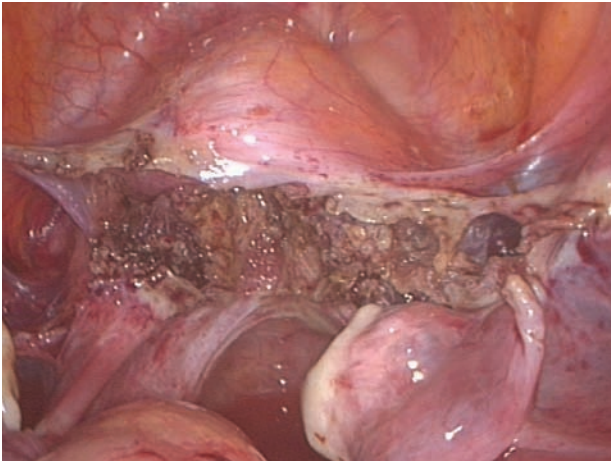


Figure 22.11 Final view



Figure 22.13 New Rotocut™ G1 morcellator allows faster morcellation

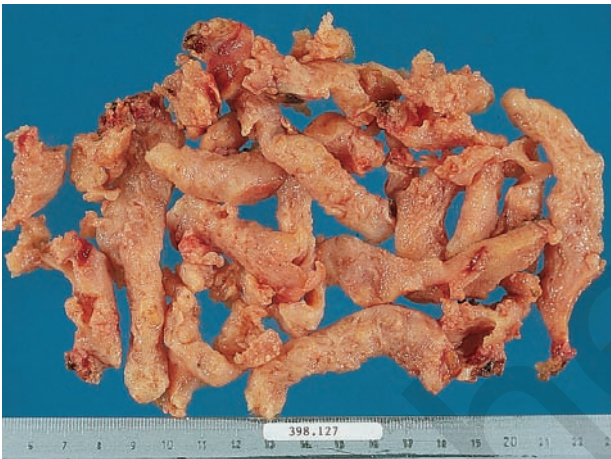

Figure 22.12 Uterus after morcellation

15 bladder injuries occurred in 920 laparoscopic hysterectomies, whereas no ureteral lesions and only five bladder injuries were seen in a series of 460 abdominal or vaginal hysterectomies. This increased risk of urinary tract injuries during laparoscopic hysterectomy compared with abdominal hysterectomy was confirmed in a meta-analysis by Johnson *et al.* in 2005¹⁸.

In this review, 27 trials were included, taking into account that only randomized controlled trials were selected. The increased incidence of urinary tract injury remained the major concern in relation to the laparoscopic surgery. Indeed, ureteral injury occurred in one of 78 women having laparoscopic hysterectomy and one in 492 women having abdominal hysterectomy.

In our series, ureteral injury occurred in two of 1400 women having LASH, thus with a lower incidence than

Table 22.2 Complications in a series of 1363 laparoscopic subtotal hysterectomies

Complication	n
<i>Perioperative</i>	
Hemorrhage*	1 (0.07%)
Bladder incision [†] (< 1 cm)	3 (0.22%)
Ureteral lesion (blanching treated by JJ stent)	1 (0.07%)
Fever (after second day)	3 (0.22%)
<i>Postoperative</i>	
Urinary tract lesion [‡]	2 (0.15%)
Colon or rectal perforation	0
Iatrogenic adenomyoma [§]	7 (0.51%)

*External iliac artery lesion during section of the cervix with monopolar scissors, treated by emergency laparotomy; [†]sutured laparoscopically (in three patients with previous history of two cesarean sections); [‡]fistula caused by thermal damage, treated by JJ stent; [§]residual specimens of myometrium and endometrium after morcellation

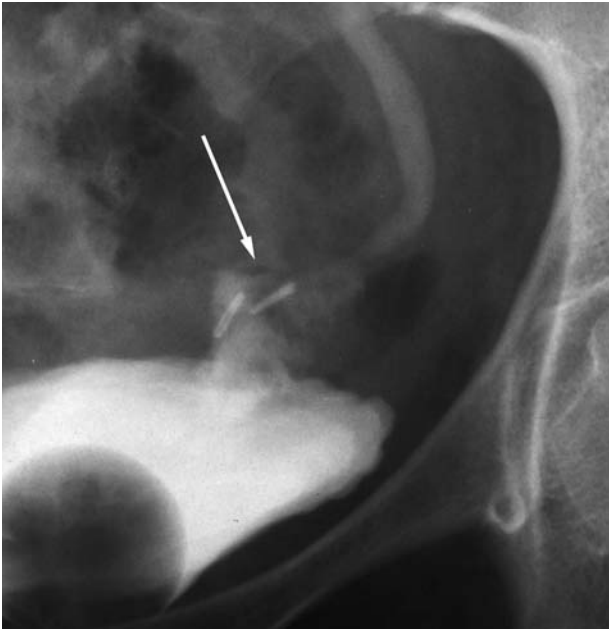

Figure 22.14 Ureteral fistula (arrow) provoked by thermal damage diagnosed 7 days after the procedure. A double JJ stent was placed for 2–3 months. Three months after removal of the JJ stent, intravenous pyelography revealed a normal ureter at the site of the fistula

that reported by Johnson *et al.* There is no doubt that laparoscopic hysterectomy requires greater surgical expertise, and that the complication rate is related to the surgeon's skill.

In our series, ureteral complications were rarely noted (only three cases in our series of 1400 laparoscopic subtotal hysterectomies). The LASH technique reduces the risk of ureteral injury, but does not eliminate it. Indeed, thermal damage due to the coagulation process can provoke ureteral fistulas (Figure 22.14). Nevertheless, three cases of bladder injury (laparoscopically repaired) occurred in patients with a medical history of two or three cesarean sections.

One other advantage of LASH is preservation of the cardinal and uterosacral ligaments, which probably play a role in pelvic organ suspension and bladder continence control¹⁷. According to Kilkku *et al.*¹⁹ and Virtanen *et al.*²⁰, libido and orgasmic frequency are not affected by subtotal hysterectomy but are significantly reduced by total hysterectomy. Preliminary results of a prospective study carried out in our department confirm that sexual satisfaction is not affected by LASH. Recently, El-Toukhy *et al.*²¹ compared urinary and sexual function after abdominal, vaginal, laparoscopic total and laparoscopic subtotal hysterectomies. In all these techniques, no adverse effects on sexual function were observed at 6 months after surgery.

Because of the feasibility of the technique, the very low morbidity rate and the fast recovery, LASH could be

proposed as a 'strictly laparoscopic approach' in some indications, and especially in cases where the uterus presents with multiple submucosal myomas. Indeed, we know that, in such cases, the recurrence rate of bleeding after hysteroscopic myoma resection and endometrial ablation is more than 25% after a 2-year follow-up¹⁵, and therefore LASH could be proposed instead of hysteroscopic surgery to women with this type of pathology. Failures of endometrial laser ablation and partial endometrial laser ablation for dysfunctional bleeding in a normal-sized uterus occur in about 3–5% of cases¹³. Failed endometrial ablation must also be considered as an indication for LASH. Because of the good results and the absence of complications, the LASH technique is proposed in our department in cases of:

- Enlarged uterus with multiple fibroids (up to a 14-week gestational volume) and normal cervix (even in nulligravida)
- Failure of endometrial ablation and/or myomectomy (failure demonstrated by the recurrence of menometrorrhagia)
- Myomatous uterus in women who have a medical history of Cesarean section
- Multiple submucosal myomas even if the uterine volume is < 7 gestational weeks
- Uterine prolapse as a step in laparoscopic sacrofixation

The risk induced by preservation of the cervix has long been considered to be the development of a cervical stump carcinoma, although this risk is only 0.1–0.4%^{19,22}. Historically, however, subtotal hysterectomy was condemned well before cervical smears became the norm. Today, systematic cervical smears, colposcopy and biopsy, if required, are determining factors in the selection of cases and the postoperative follow-up of patients.

How many cases of invasive cervical carcinoma are observed in consultations every year? Because the incidence of this disease is very low in the group of women followed up every year by Papanicolaou smears, and because we now have accurate means to keep a close check on the cervix, the risk of encountering invasive cervical cancer is virtually nil.

We consider that patients suffering from uterosacral ligament endometriosis with dyspareunia and dysmenorrhea must be excluded. Indeed, total hysterectomy with resection of the uterosacral ligaments is more appropriate in these cases.

So far, more than 1400 cases have been performed in our department with an excellent follow-up to date because of the low rate of complications and good acceptance by the patients. This suggests that this strictly laparoscopic approach is the hysterectomy procedure of choice in selected cases (Table 22.3).

In a recent review¹⁰, Garry clearly noticed that most hysterectomies were still performed as total abdominal

Table 22.3 Advantages noted

-
- Rapid recovery similar to that observed after laparoscopic surgery for infertility
 - Reduced postoperative discomfort and shorter hospital stay
 - Lower rate of complications when compared with laparoscopic hysterectomy (LH) and laparoscopy-assisted vaginal hysterectomy (LAVH)
 - Decreased risk of vaginal vault prolapse
 - Decreased risk of post-hysterectomy urine incontinence
 - Absence of decreased libido
-

hysterectomies, and that most hysterectomies include removal of the cervix in continuity with the body of the uterus. In the UK, the cervix is retained in only 3% of cases. In Denmark, the rate of subtotal hysterectomies has increased over recent years (28%). It should be noted that, in the UK as well as in Denmark, the rate of laparoscopic hysterectomy (total or subtotal) is very low, 3% and 6%, respectively. From his meta-analysis, Garry concluded that vaginal hysterectomy should be the preferred approach for hysterectomy. We do not agree with this concept. In the hands of Clermont-Ferrand (France) and Louvain (Brussels) gynecologists, a laparoscopic hysterectomy (total and subtotal) takes less than 1 hour, and is associated with a shorter hospital stay and recovery time than is vaginal hysterectomy. Also, the rate of ureteral complications is very low.

REFERENCES

1. Reich H, De Caprio J, MacGlynn F. Laparoscopic hysterectomy. *J Gynecol Coll Surg* 1989; 5: 213
2. Nezhat C, Nezhat F, Silfen SL. Laparoscopic hysterectomy and bilateral salpingo-oophorectomy using multifire GIA surgical stapler. *J Gynecol Coll Surg* 1990; 6: 287
3. Mage G, Canis M, Wattiez A, et al. Hystérectomie et coelioscopie. *J Gynecol Obstet Biol Reprod* 1990; 19: 573–6
4. Garcia Padias JG, Sotolongo J, Casey MJ, et al. Laparoscopy assisted vaginal hysterectomy: report of seventy-five consecutive cases. *J Gynecol Surg* 1992; 8: 81–5
5. Liu CVY. Laparoscopic hysterectomy. Report of 215 cases. *Gynecol Endosc* 1992; 1: 73–7
6. Reich H, MacGlynn F, Sekel L. Total laparoscopic hysterectomy. *Gynecol Endosc* 1990; 2: 59–63
7. Donnez J, Nisolle M. LASH: laparoscopic supracervical (subtotal) hysterectomy. *J Gynecol Surg* 1993; 9: 91–4
8. Phipps JH, John M, Hassanaïen M, et al. Laparoscopic and laparoscopically assisted vaginal hysterectomy: a series of 114 cases. *Gynecol Endosc* 1993; 2: 7–12
9. Donnez J, Nisolle M, Smets M, et al. LASH: laparoscopic supracervical (subtotal) hysterectomy. A first series of 500 cases. *Gynecol Endosc* 1997; 6: 73–6
10. Garry R. The future of hysterectomy. *Br J Obstet Gynaecol* 2005; 112: 133–9
11. Nisolle M, Donnez J. Alternative technique of hysterectomy. *N Engl J Med* 1997; 336: 291–2
12. Steiner RA, Wight A, Tadir Y, et al. Electrical cutting device for laparoscopic removal of tissue from the abdominal cavity. *Obstet Gynecol* 1993; 81: 471–4
13. Nisolle M, Grandjean P, Gillerot S, et al. Endometrial ablation with the Nd:YAG laser in dysfunctional bleeding. *Minim Invasive Ther* 1991; 1: 35–9
14. Donnez J, Gillerot S, Bourgonjon D, et al. Neodymium:YAG laser hysteroscopy in large submucous fibroids. *Fertil Steril* 1990; 54: 999
15. Donnez J, Nisolle M. Hysteroscopic surgery. *Curr Opin Obstet Gynecol* 1992; 4: 439
16. Donnez J. Nd:YAG laser hysteroscopic myomectomy. In Sutton C, Diamond M, eds. *Endoscopic Surgery for Gynecologists*. London: WB Saunders Company, 1993: 331–7
17. Garry R, Fountain J, Mason S, et al. The eVALuate study: two parallel randomised trials, one comparing laparoscopic with abdominal hysterectomy, the other comparing laparoscopic with vaginal hysterectomy. *BMJ* 2004; 328: 129
18. Johnson N, Barlow D, Lethaby A, et al. Methods of hysterectomy: systematic review and meta-analysis of randomised controlled trials. *BMJ* 2005; 330: 1478
19. Kilkku P, Gronroos M, Rauramon L. Supravaginal uterine amputation with peroperative electrocoagulation of endocervical mucosa. Description of the method. *Acta Obstet Gynecol Scand* 1985; 64: 175–7
20. Virtanen H, Makinen J, Tenho T, et al. Effects of abdominal hysterectomy on urinary and sexual symptoms. *Br J Urol* 1993; 72: 868–72
21. El-Toukhy TA, Hefni M, Davies A, et al. The effect of different types of hysterectomy on urinary and sexual functions: a prospective study. *J Obstet Gynaecol* 2004; 24: 420–5
22. Storm HH, Clemmensen IH, Manders T, et al. Supravaginal uterine amputation in Denmark 1978–1988 and risk of cancer. *Gynecol Oncol* 1992; 45: 198–201

akusher-lib.ru

Laparoscopic hysterectomy in benign diseases: a series of 1233 cases

J Donnez, M Smets, J Squifflet, P Jadoul

INTRODUCTION

In the United States, hysterectomy is one of the most commonly performed surgical procedures (656 000 hysterectomies in 1987 alone¹). Approximately 70% are performed using the abdominal approach and 30% are performed vaginally². Contraindications to vaginal hysterectomy depend essentially on the skill of the surgeon²⁻⁵. The most frequent contraindications previously cited in the literature are:

- Endometriosis (moderate or severe)
- Previous cesarean section
- Significant uterine enlargement or limited uterine mobility in a nulligravida
- Previous pelvic surgery
- Previous uterine suspension

In many cases, however, careful examination of the pelvis by diagnostic laparoscopy reveals the absence of contraindications to vaginal hysterectomy. In addition, a large proportion of patients are candidates for vaginal hysterectomy after adhesiolysis.

Endoscopic procedures can be applied to treat adhesions, extensive pelvic endometriosis, adnexal disease and myomas, and hysterectomies that require an abdominal approach may be performed with laparoscopic dissection (partial or total) followed by vaginal removal. A major benefit of both laparoscopic and vaginal hysterectomy is the avoidance of an abdominal incision, which

typically requires longer hospitalization (5 days) and recuperation (4-6 weeks) compared with the combination of laparoscopy and vaginal removal. Laparoscopic hysterectomy⁶ is a substitute for abdominal hysterectomy, not for vaginal hysterectomy, and since the rate of laparoscopic hysterectomy has increased considerably in recent times, the rate of abdominal hysterectomy is now as low as 1.5%.

DEFINITIONS

Laparoscopic hysterectomy was first performed by Reich in January 1988⁶. According to Reich⁶, Mage *et al.*⁷ and Donnez *et al.*⁸, there are at least five types (Table 23.1).

Another staging system was devised in order to standardize the terminology (Table 23.2)⁵.

Laparoscopic supracervical hysterectomy has recently regained advocates after Kilkku⁹ reported a reduction in orgasms after hysterectomy, compared with supravaginal amputation. Laparoscopic subtotal hysterectomy (LASH) was first described by Donnez and Nisolle, whose group performed the first procedure in 1990¹⁰.

INDICATIONS

Indications for laparoscopic hysterectomy include benign pathologies such as endometriosis, fibroids, adnexal masses, adhesions from a previous cesarean section,

Table 23.1 Types of laparoscopic hysterectomy

Type	
1	Laparoscopy performed for diagnostic purposes, where indications for a vaginal approach are equivocal, in order to determine whether vaginal hysterectomy is possible
2	Laparoscopy-assisted vaginal hysterectomy (LAVH), involving an initial laparoscopic surgical procedure after which vaginal hysterectomy is carried out
3	Laparoscopic hysterectomy, consisting of laparoscopic ligation of the uterine arteries ⁶
4	Complete laparoscopic hysterectomy, where laparoscopic dissection continues until the uterus is free from all attachments in the peritoneal cavity
5	Laparoscopic closure of the vagina

Table 23.2 Laparoscopy-assisted vaginal hysterectomy staging according to Johns⁵

Stage	
0	Diagnostic laparoscopy without laparoscopic procedure prior to vaginal hysterectomy
1	Procedure including laparoscopic adhesiolysis and/or excision of endometriosis
2	One or both adnexa freed laparoscopically
3	Bladder dissected from the uterus
4	Uterine artery transected laparoscopically
5	Anterior and/or posterior colpotomy or entire uterus freed

inflammatory disease or prior surgery, which previously required an abdominal approach to hysterectomy.

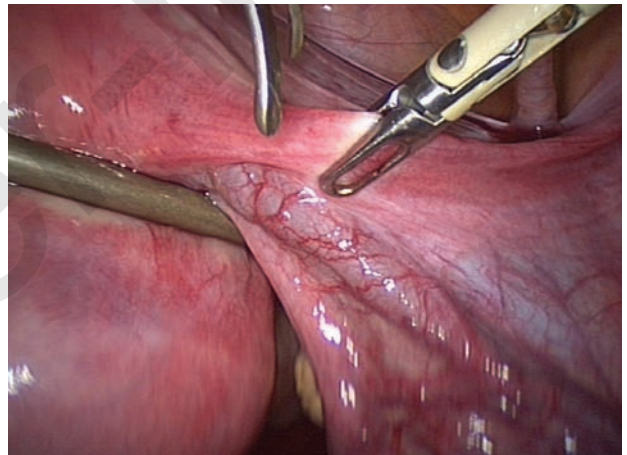
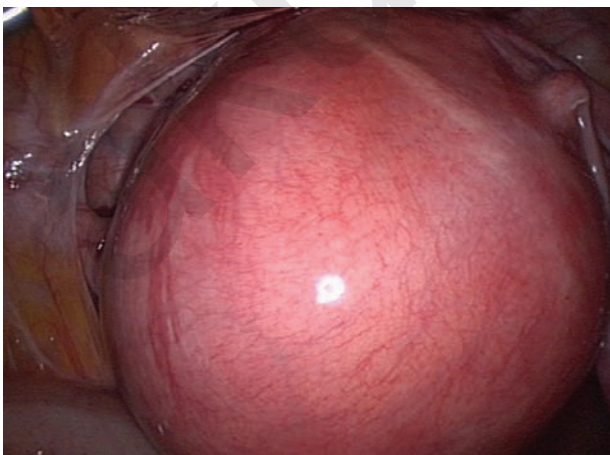
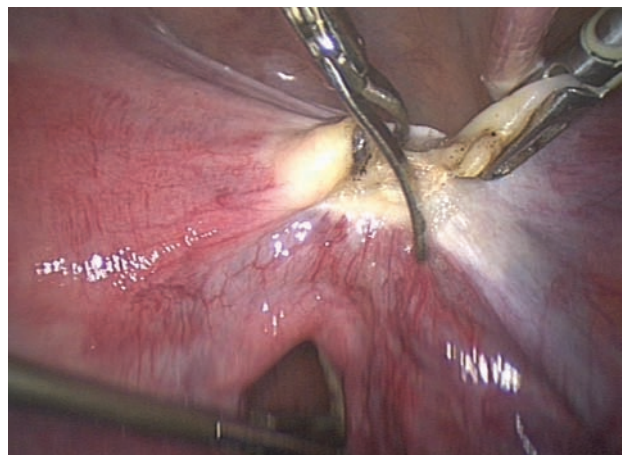
Laparoscopic hysterectomy may also be considered for stage I endometrial cancer^{7,11-13}.

TECHNIQUES (Figures 23.1–23.27)

All surgical procedures after uterine vessel ligation, including anterior and posterior vaginal incision, cardinal and intersacral ligament division, intact uterine removal and vaginal closure, can be performed vaginally or laparoscopically. A Foley catheter is inserted during surgery to empty the bladder. Four laparoscopic puncture sites, including the umbilicus, are used: 10 mm umbilical, 5 mm right, 5 mm medial and 5 mm left lower quadrant, just above the pubic hairline; lateral incisions are made next to the deep epigastric vessels. A cannula is placed in the cervix for appropriate uterine mobilization.

Abdominal and adnexal adhesions, if present, are lysed to mobilize the uterus, and the ureters are identified. When adnexectomy is required, the adnexa are freed first. The infundibulopelvic ligament is identified and exposed by applying traction to the adnexa with an opposite forceps. Bipolar forceps are used to compress and desiccate

the vessels, which are then cut with scissors. Bipolar coagulation is used to coagulate the pedicle, or staples or sutures may be applied. Scissor division is carried out close to the line of desiccation to ensure that the pedicle remains compressed. The peritoneum between the infundibulopelvic ligament and the round ligament is then cut. The round ligaments are then desiccated and cut with scissors.

**Figure 23.2** Grasping of the right round ligament**Figure 23.1** Fibromatous uterus**Figure 23.3** Coagulation and section of the right round ligament

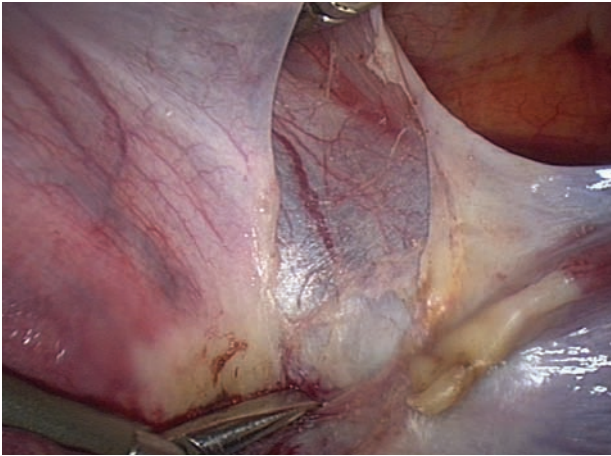


Figure 23.4 Opening of the vesicouterine peritoneum

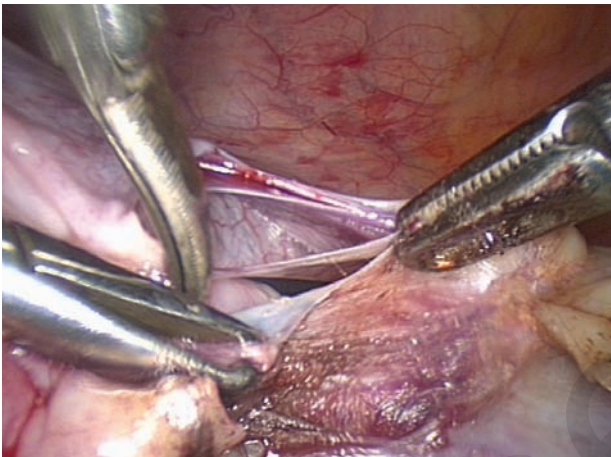


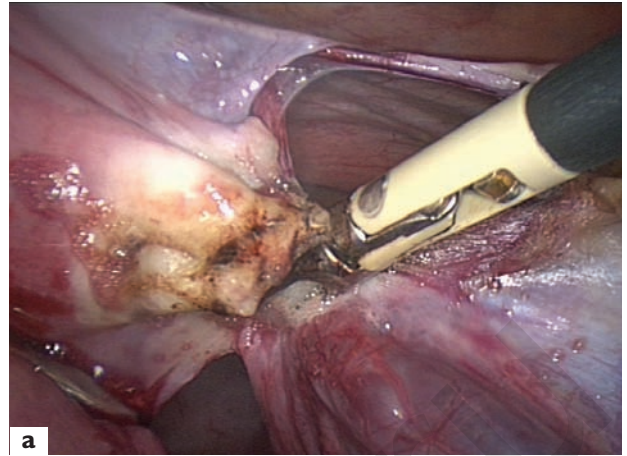
Figure 23.5 Incision of the posterior leaf of the cardinal ligament

When no adnexectomy is required, the surgical procedure starts with the grasping, coagulation and section of the round ligament. The vesicouterine peritoneum is then opened with scissors to expose the posterior leaf of the cardinal ligament. This posterior leaf is coagulated and opened with scissors.

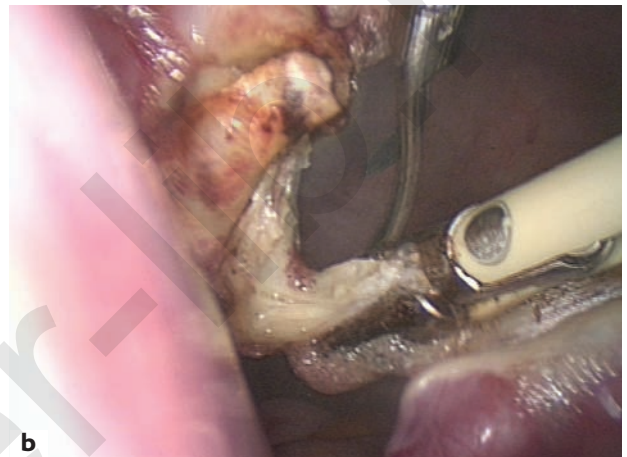
A window is thus created allowing easy grasping, coagulation and section of the proximal part of the Fallopian tube and the utero-ovarian ligament. The same procedure is then performed on the opposite side.

The peritoneum of the vesicouterine space is then grasped and elevated with forceps, while scissors are used to dissect the vesicouterine space. Hydrodissection may be used to separate the leaves of the broad ligament, distending the vesicouterine space and defining the tendinous attachments of the bladder in this area; these are coagulated and cut. Sharp dissection can also be used to divide the peritoneum down to the uterosacral ligaments.

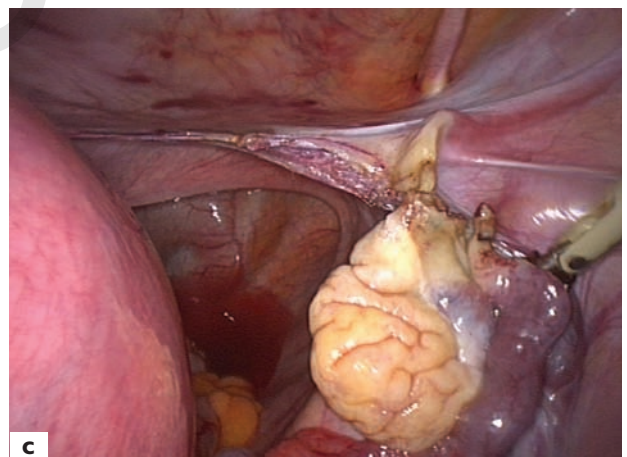
The uterine vessels are identified and skeletonized using hydrodissection. When these are well identified, and



a



b



c

Figure 23.6 (a)–(c) Coagulation and section of the proximal part of the Fallopian tube and the utero-ovarian ligament on the right side

after confirming the position of the ureters, the uterine vessels are desiccated with bipolar coagulation and cut. The same procedure is performed on the opposite side. In some departments, staples or specialized equipment (such as ultra-scissors) is used, but this is very expensive. Some

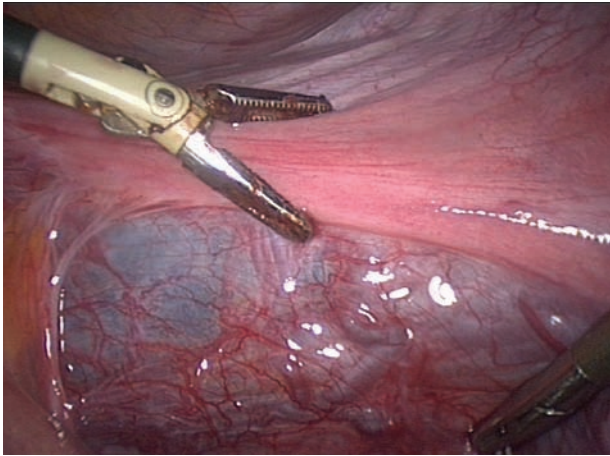


Figure 23.7 Grasping of the left round ligament

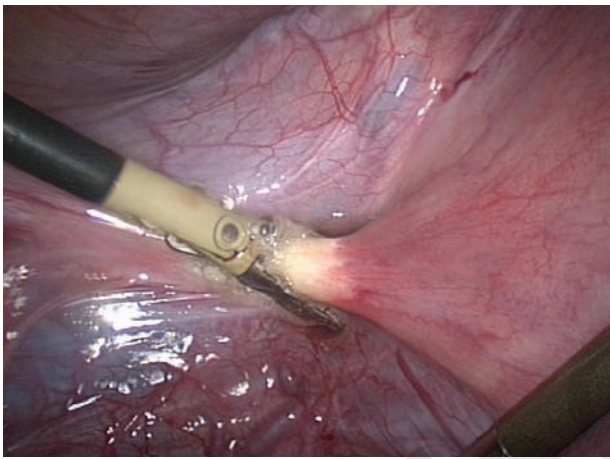


Figure 23.8 Coagulation and section of the left round ligament

authors¹⁴ prefer suture ligation of the vascular bundle. Ligation of the uterine vessels can also be performed by the vaginal approach.

The total hysterectomy procedure (type 4 according to Reich; stage 5 according to Johns) may be performed laparoscopically. Vaginal incision is achieved over a sponge placed between the vaginal anterior wall and the cervix, or on a uterine mobilizer equipped with a vaginal cupula. The vagina is entered using a unipolar cutting current or scissors. The same procedure is performed posteriorly, exposing the area in the cul-de-sac where an incision can be made.

The completely freed uterus is then pulled into the vagina. The vagina may be sutured from below or laparoscopically with three sutures. The first suture joins the uterosacral ligaments across the midline. The second brings the cardinal ligaments and underlying vagina across the midline. The third closes the anterior vagina and its fascia^{5,6}. A running suture can also be used, but care must

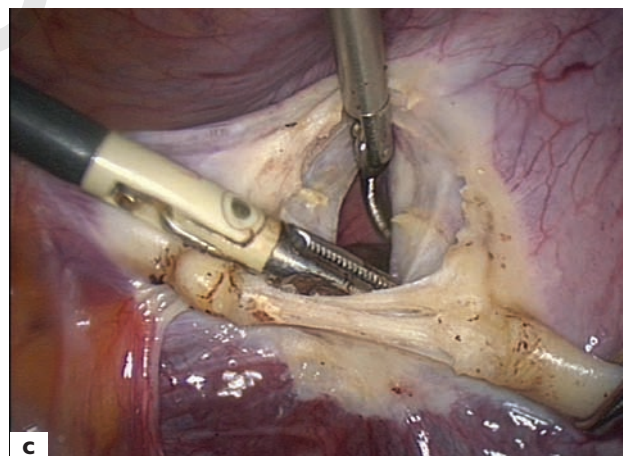
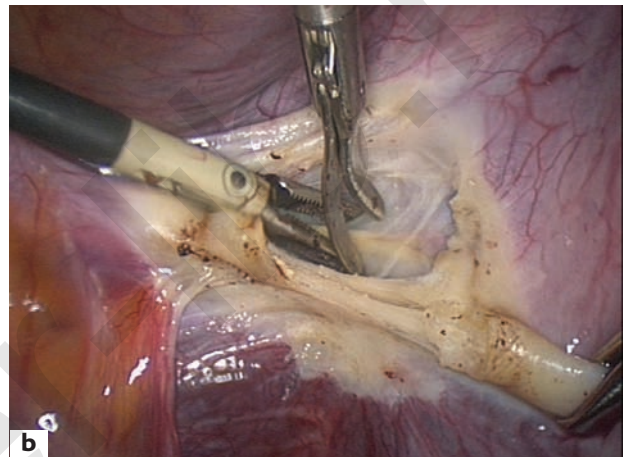
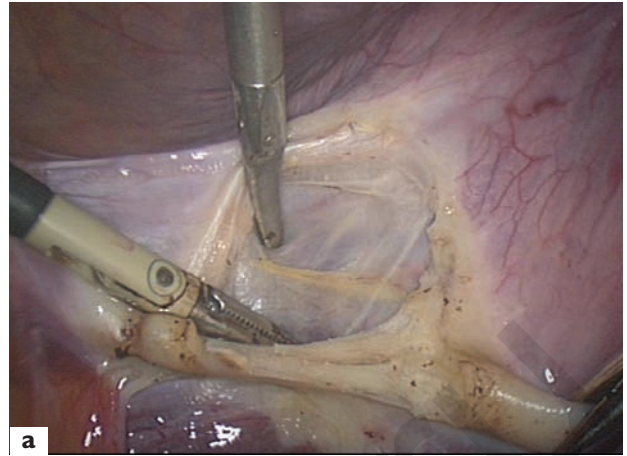


Figure 23.9 (a)–(c) Opening of the vesicouterine peritoneum; coagulation and section of the posterior leaf of the cardinal ligament on the left side

be taken to incorporate the uterosacral ligaments into the suture.

The pelvis is rinsed with saline solution. Blood clots are removed. A drain catheter can be left in the pelvic cavity. Antibiotics (Zinacef[®] 2 g/day, Flagyl[®] 2 g/day) are given preoperatively (one shot).

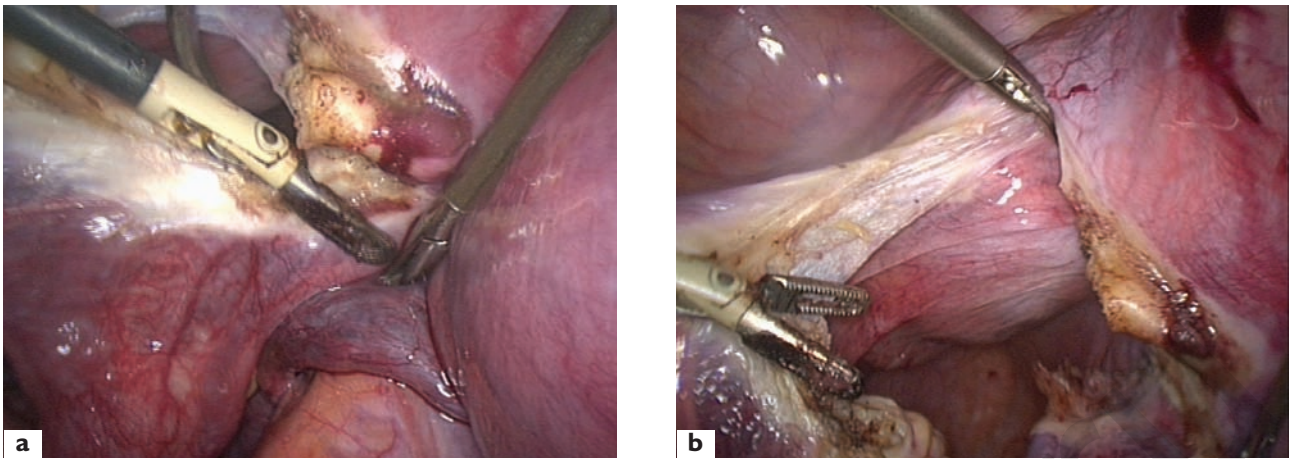


Figure 23.10 (a) and (b) Coagulation and section of the Fallopian tube and the utero-ovarian ligament on the left side

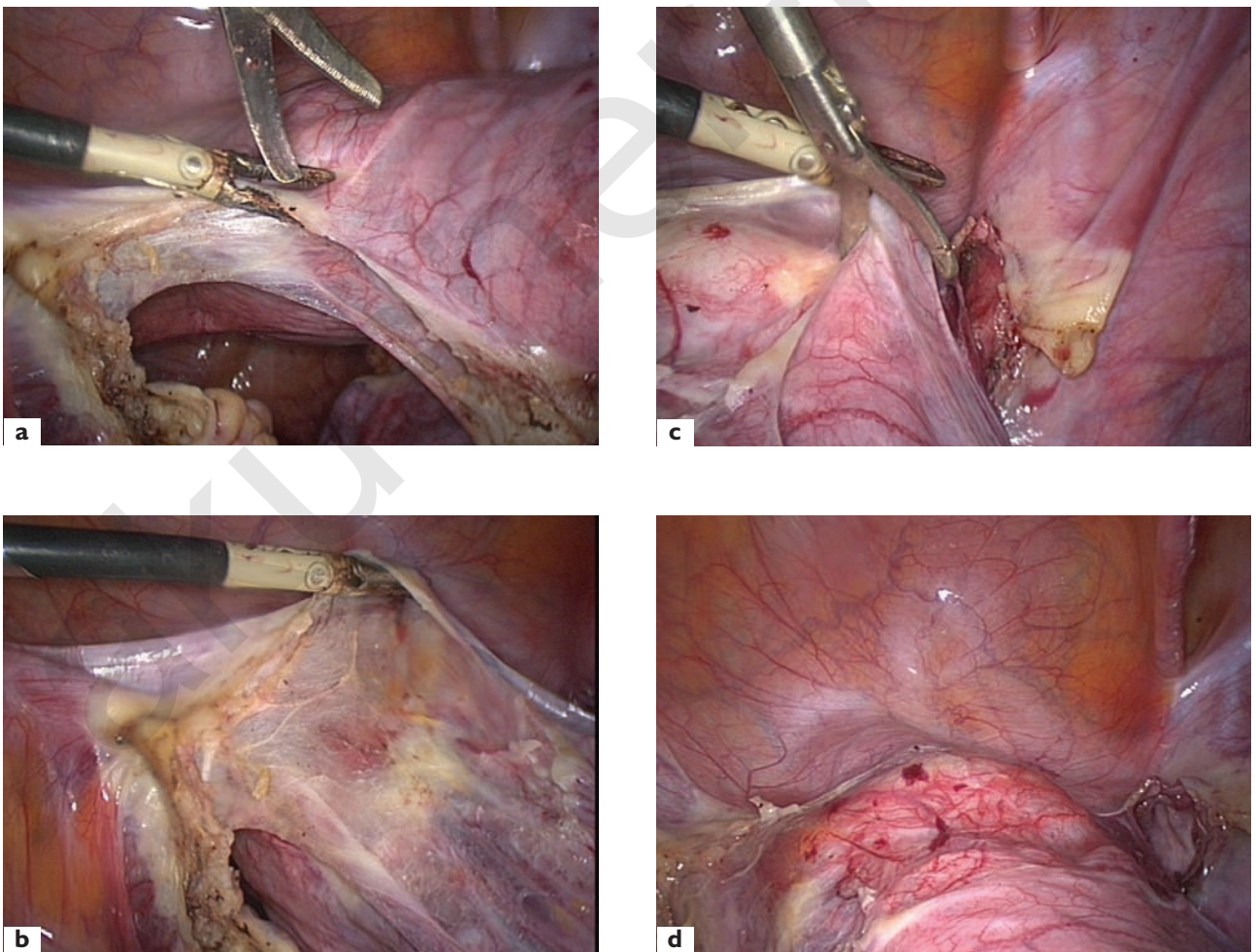


Figure 23.11 (a)–(d) Section of the vesicouterine peritoneum

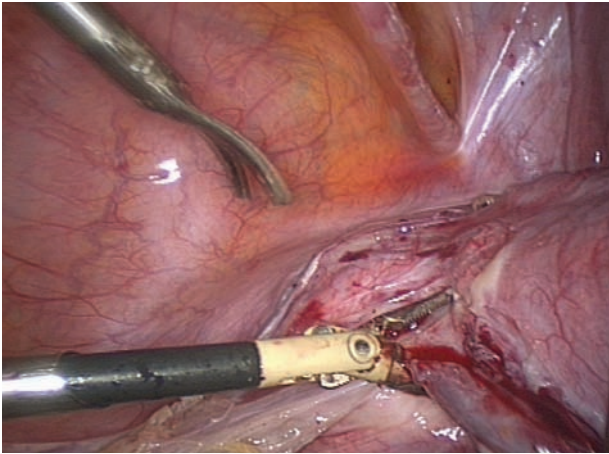


Figure 23.12 Grasping of the left uterine artery

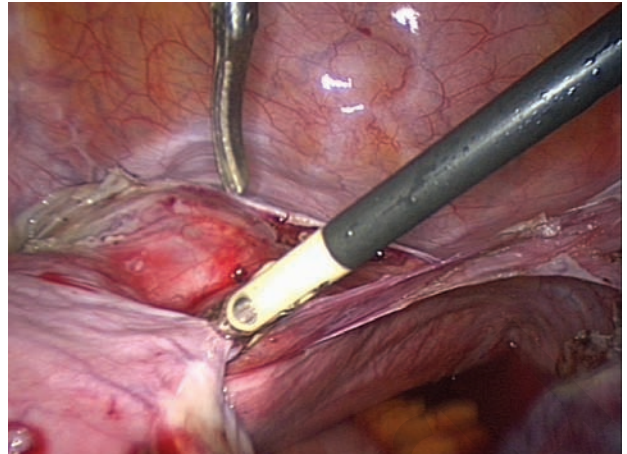


Figure 23.15 Grasping of the right uterine artery

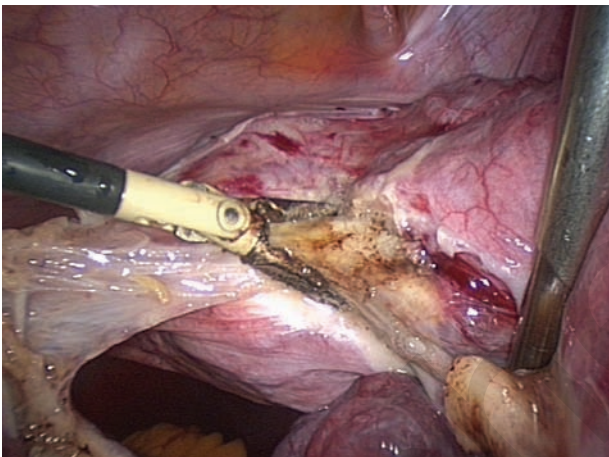


Figure 23.13 Coagulation of the left uterine artery

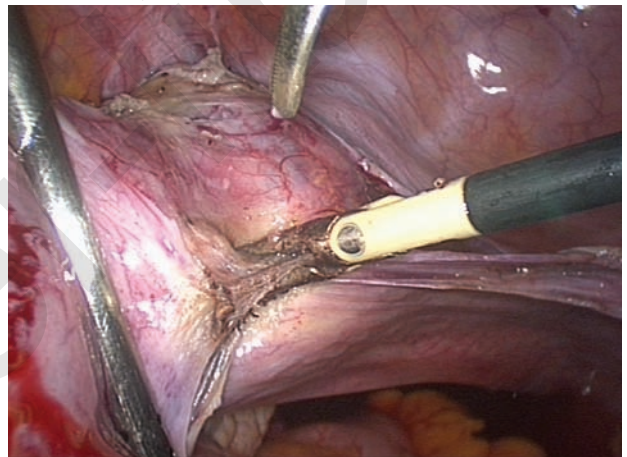


Figure 23.16 Coagulation of the right uterine artery

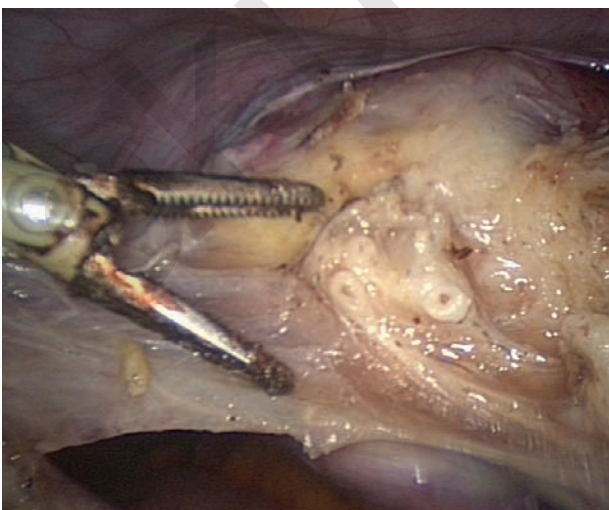


Figure 23.14 Section of the left uterine artery

SPECIFIC EQUIPMENT AND COMMENTS

Bipolar coagulation

Monitoring electrical current flow with a flow meter ensures total coagulation of the tissue between the tips of the bipolar forceps. Current flow between the tips of the bipolar electrodes ceases only when complete desiccation (dehydration) has occurred.

Kleppinger bipolar forceps are excellent for large-vessel hemostasis. Specially insulated bipolar forceps allow the current to pass only through their tips, so that precise hemostasis can be obtained. Bipolar forceps with a matched power source are an indispensable tool for all operative laparoscopies¹⁴. The visual current flow meter ensures that desiccation of the tissue held by the forceps is complete.

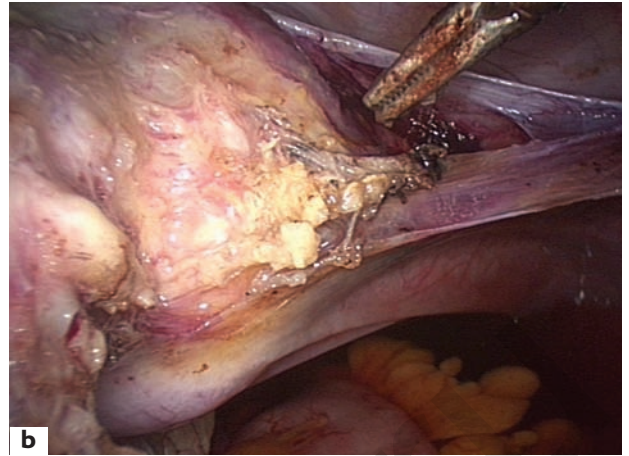
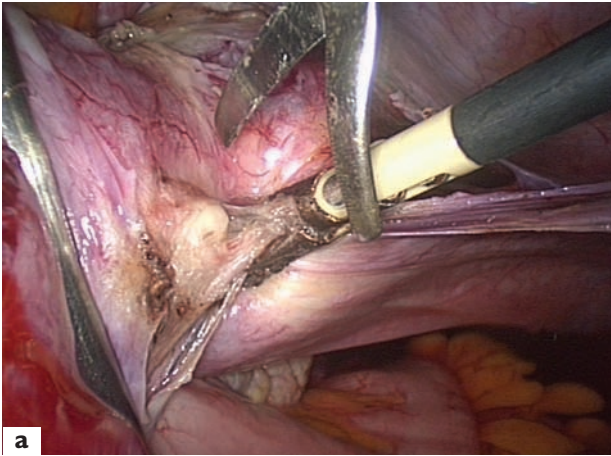


Figure 23.17 (a) and (b) Section of the right uterine artery

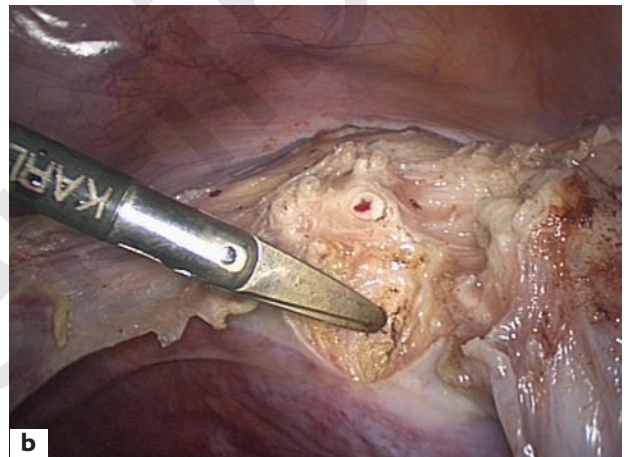
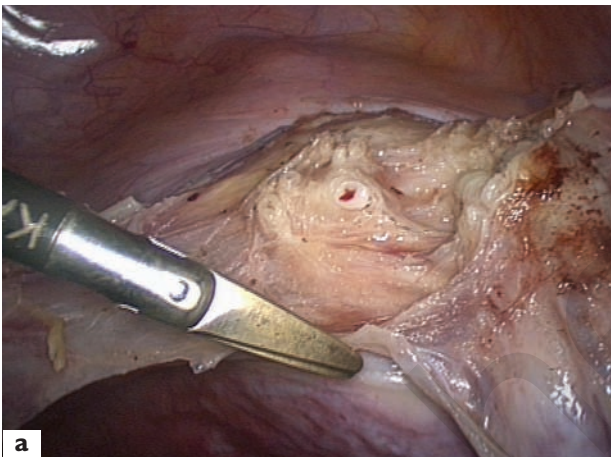


Figure 23.18 (a) and (b) Dissection of the left uterine artery with monopolar scissors in the direction of the vaginal cupula

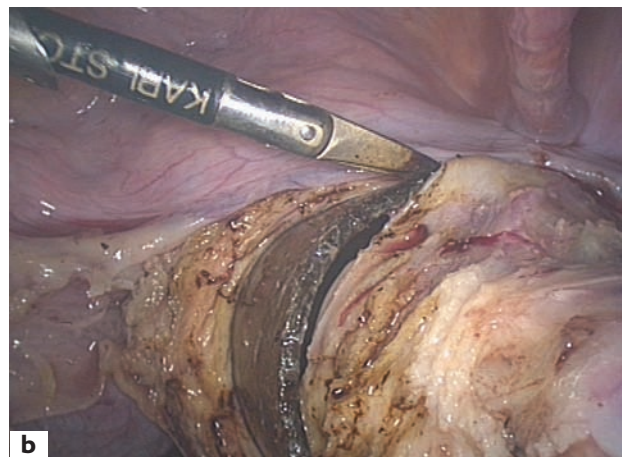
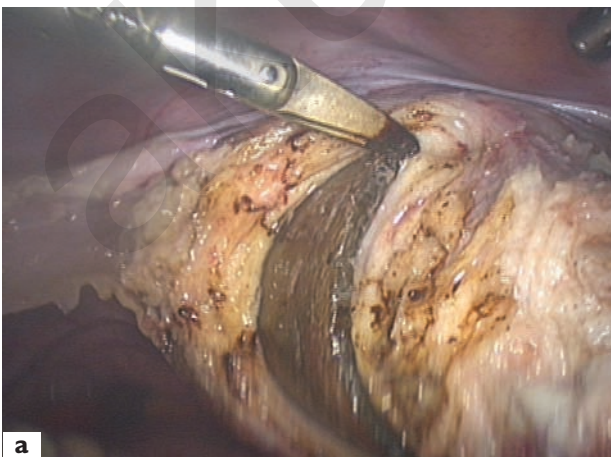
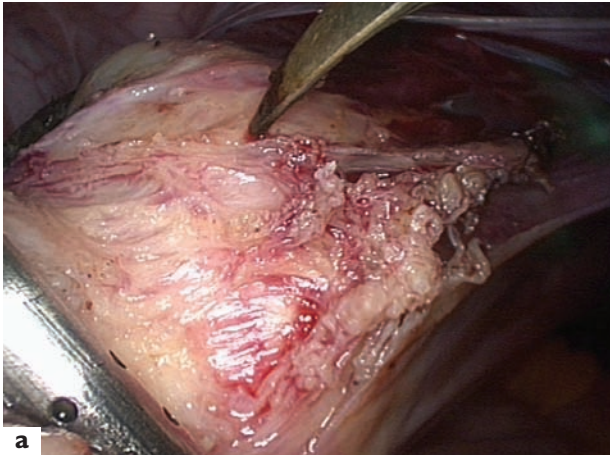
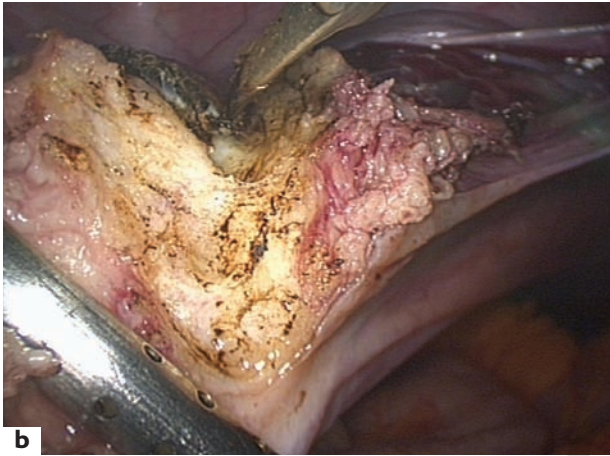


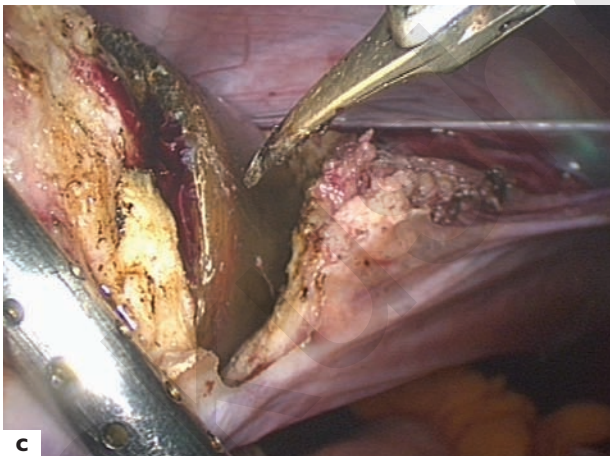
Figure 23.19 (a) and (b) The vaginal cupula becomes visible



a



b



c

Figure 23.20 (a)–(c) Section of the anterior and right side of the vagina on the cupula with monopolar scissors

All instrument companies have now developed excellent bipolar forceps.

Uterine mobilizer

The uterine mobilizer is inserted to antevert the uterus and delineate the posterior vagina. Reich¹⁴ uses the

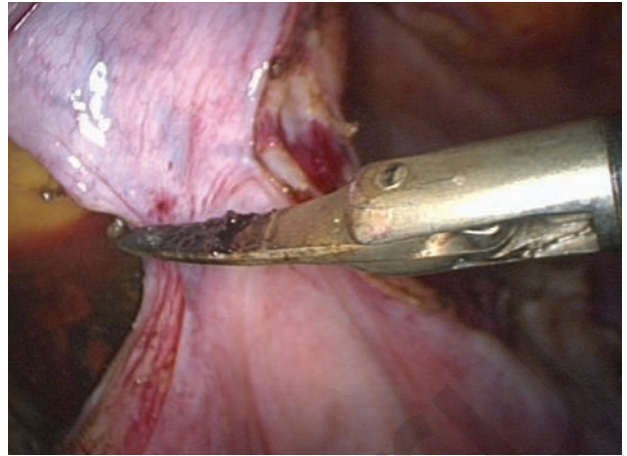


Figure 23.21 Section of the posterior part of the vagina

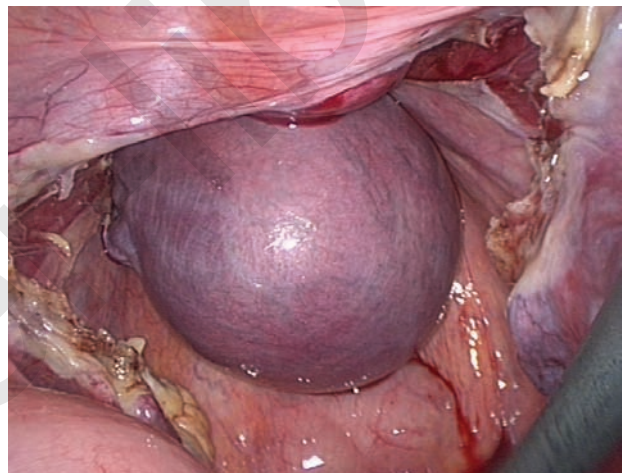


Figure 23.22 The uterus is removed through the opened vagina

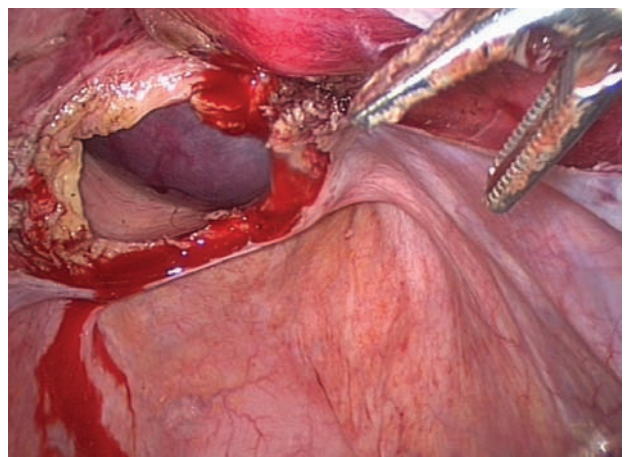


Figure 23.23 The uterus is left in the vagina to prevent loss of pneumoperitoneum

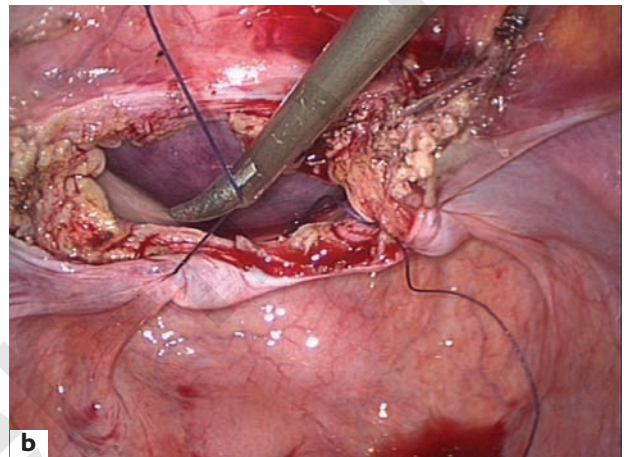
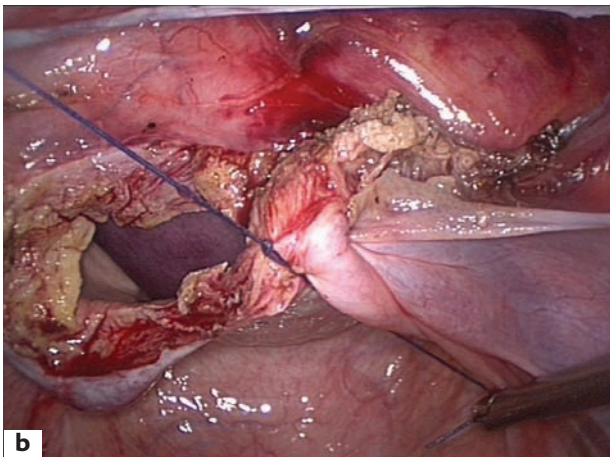
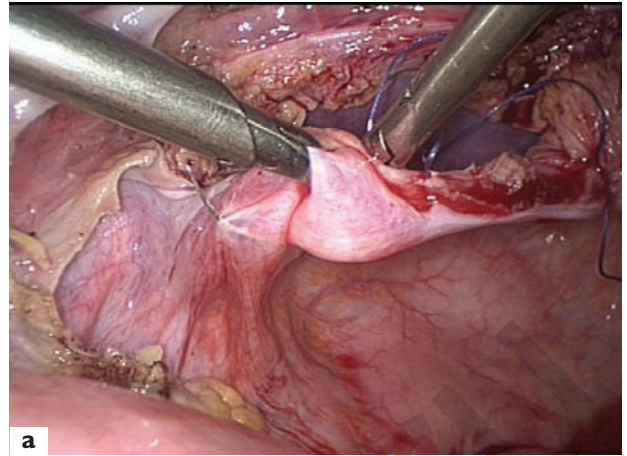
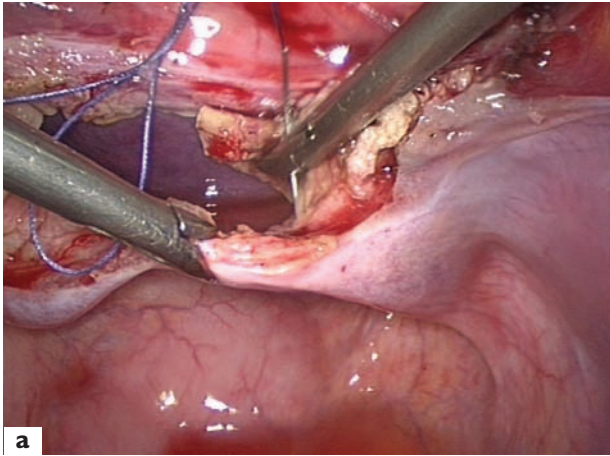


Figure 23.24 (a) and (b) The suture is performed on the right uterosacral ligament

Valtchev uterine mobilizer. We prefer to use a manipulator equipped with a vaginal cupula to delineate the ‘anterior’ and ‘posterior’ vaginal, as well as lateral, cul-de-sac. This inexpensive manipulator (Figures 23.28 and 23.29) allows mobilization and incision of the uterus and incision of the vaginal cul-de-sac.

Ureter dissection

Some authors^{6,14} begin surgery with identification of the ureters, usually at the pelvic brim, followed by their subsequent mobilization. Their dissection requires medial reflection of the rectosigmoid, to expose the ovarian vessels and ureters as they cross the iliac artery to enter the true pelvis.

The positions of the previously dissected ureters in the broad ligament are again checked before desiccation, stapling or suturing of the uterine vessels. When the ureter is situated far from the uterine vessels, bipolar desiccation or stapling is carried out. Inspection of the ureter after positioning the stapler has been known to reveal its

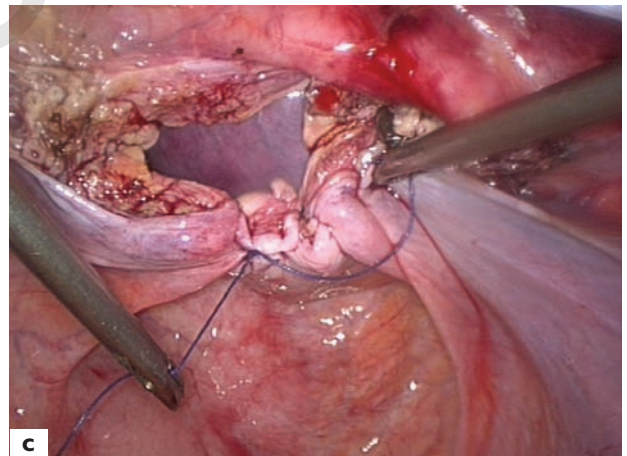


Figure 23.25 (a)–(c) The suture is performed on the left uterosacral ligament

entrapment. Suture ligation of the vascular bundle is preferred by Reich¹⁴: this technique avoids such injury, as the ureter is visualized directly throughout the ligation process. Mage *et al.*^{7,15} and Donnez *et al.*¹³ prefer bipolar coagulation. In our department, the ureter is identified, but only dissected in the case of endometriosis.

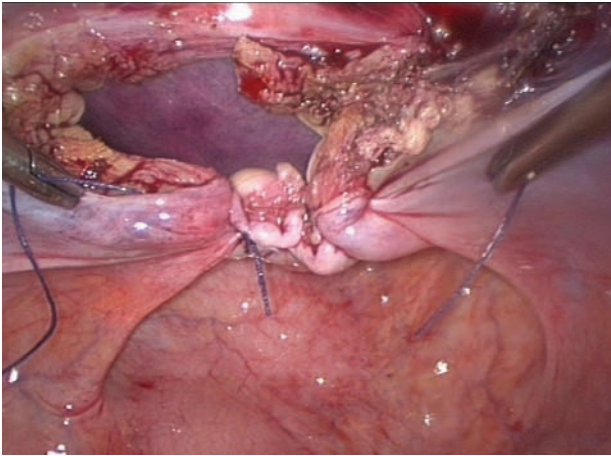


Figure 23.26 The two uterosacral ligaments are sutured together

Vaginal closure

Laparoscopic vaginal closure, which joins the ligaments to the vaginal epithelium, can be easily achieved. In our department, this closure is performed through the vagina or by laparoscopy. The vaginal and laparoscopic techniques share the same principle: the peritoneum and uterosacral ligaments are brought together, and the vaginal mucosa is closed.

Drainage

One of the intraoperative advantages of a laparoscopic approach to hysterectomy is the ability to achieve complete hemostasis and evacuate all blood clots at the end of the procedure. This removal of all remaining clots and pelvic lavage may reduce postoperative infection associated with vaginal hysterectomy. The drain is left in the Douglas pouch.

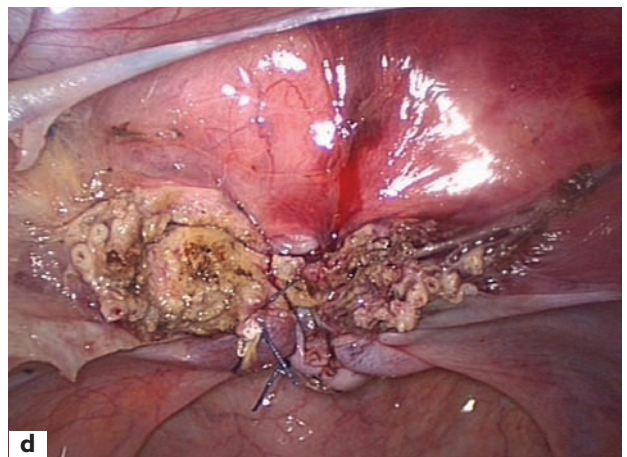
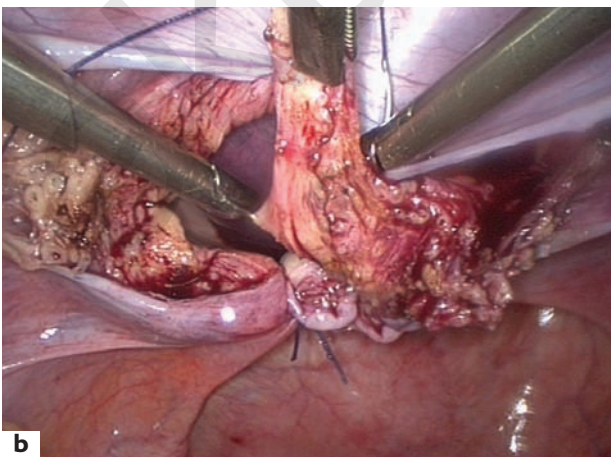
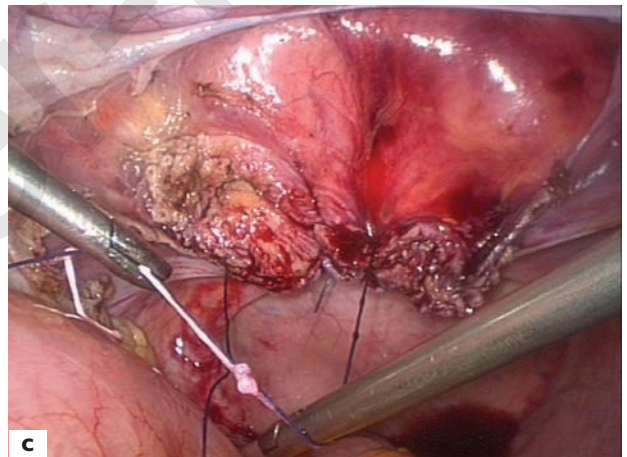
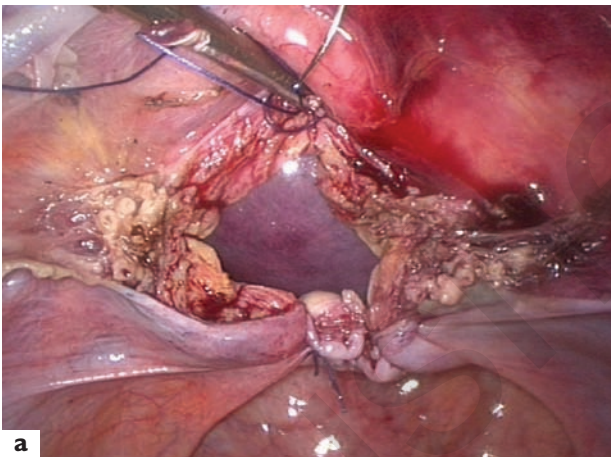


Figure 23.27 (a)–(d) The vagina is closed



Figure 23.28 Uterine mobilizer

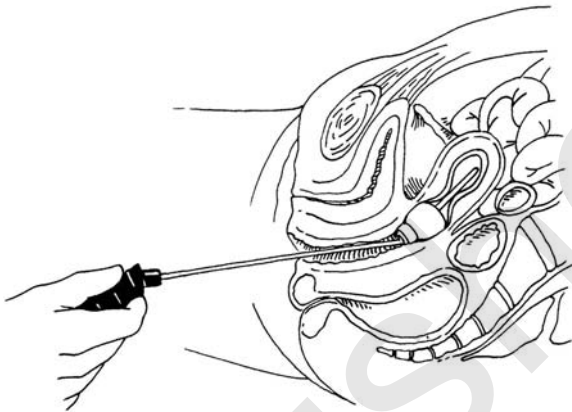


Figure 23.29 The uterine mobilizer is put around the cervix

Is preoperative administration of a gonadotropin-releasing hormone agonist useful?

Gonadotropin-releasing hormone (GnRH) analogs may reduce the total uterine volume in patients with uterine leiomyomata by between 35 and 50%^{16,17}. When hysterectomy is planned for the treatment of large myomas, women should be pretreated with a GnRH analog for at least 3 months, since shrinkage of the myoma should facilitate laparoscopic hysterectomy. This preoperative therapy may also be used in women with an enlarged uterus of

more than 14–15 weeks, but less than 20 weeks, in order to decrease its volume.

DISCUSSION

Opponents of laparoscopic hysterectomy argue that vaginal hysterectomy is faster, is less expensive, causes fewer complications and results in a similar short hospital stay and convalescence. Garry *et al.*¹⁸ published data from the eVALuate study that we critically analyzed in a paper published in the *British Medical Journal*¹⁹. They conducted two parallel randomized studies to evaluate the effects of laparoscopic hysterectomy compared with abdominal and vaginal hysterectomy. Considerable bias in their method unfortunately led them to the wrong conclusion.

The primary end-point was the occurrence of major complications, which was as high as 11.1% in the laparoscopic hysterectomy group. This rate is totally unacceptable, and may be explained by the major bias encountered.

First, 43 gynecologists from 30 centers took part. The mean number of laparoscopic hysterectomies ($n = 584$) per gynecologist was therefore 13 over 4 years. Second, the experience of the 43 gynecologists most certainly differed from center to center. The rate of complications is not analyzed according to the gynecologists' experience.

Third, the learning curve greatly exceeds 25 cases²⁰. In our series of more than 3000 laparoscopic hysterectomies (Table 23.3), the rate of major complications was 0.6% after laparoscopic subtotal hysterectomy and 2% after laparoscopic hysterectomy. All but two of the complications occurred from 1990 to 1995 (laparoscopic subtotal hysterectomy, $n = 295$; laparoscopic hysterectomy, $n = 136$)²³. Later, the rate of major complications was exactly the same as that observed after abdominal hysterectomy (Table 23.4).

Furthermore, four different laparoscopic surgical approaches (laparoscopic hysterectomy, laparoscopic vaginal hysterectomy, laparoscopic subtotal hysterectomy, total laparoscopic hysterectomy) were used. This also constitutes a serious bias. Differences in the rate of complications, depending on technique, have been described, especially during the learning curve. This should be pointed out in the paper.

The conclusion reached by Garry *et al.* is thus not admissible, because of all the bias identified. The high complication rates are probably due more to the relative inexperience of the surgeons in laparoscopic hysterectomy than to the technique of laparoscopic hysterectomy itself.

Initially, the Cochrane Review published by Johnson *et al.*²² in 2005 concluded that vaginal hysterectomy should be performed in preference to abdominal hysterectomy where possible; where vaginal hysterectomy is not possible, a laparoscopic approach may be used to avoid the need for abdominal hysterectomy. Here too, the authors considered that laparoscopic hysterectomy was a longer

Table 23.3 A series of 3405 hysterectomies for benign diseases

Procedures	1994–1995		1996–1997		1998–1999		2000–2001		2002–2003		2004–2005		Total	
	n	%	n	%	n	%	n	%	n	%	n	%	n	%
LASH	236	46	240	41.5	248	43.5	205	38	179	30	255	41	1363	40
LAVH/LH*	130	26	127	22	177	31	203	37.5	294	50	302	49	1233	36
Vaginal hysterectomy	82	16	159	27.5	111	19.5	102	19	94	16	53	8.5	601	18
Abdominal hysterectomy	60	12	52	9	32	6	31	5.5	24	4	9	1.5	208	6
Total	508		578		568		541		591		619		3405	

*In 2000 we switched from LAVH to LH; LASH, laparoscopic subtotal hysterectomy; LAVH, laparoscopy-assisted vaginal hysterectomy; LH, laparoscopic hysterectomy

Table 23.4 Complications in a series of 1323 laparoscopic hysterectomies

Complication	n
Fever >38.5°C (after second day) requiring 5–7 days of antibiotherapy	9 (0.6%)
Bladder incision (sutured by laparoscopy)	3 (0.2%)
Hemorrhage	1 (0.1%)
Conversion	0 (0%)
Vesicoperitoneal fistula diagnosed by computed tomography (treated by Foley catheter for 14 days) (Figure 23.30)	1 (0.1%)
Urinary tract lesion (two cases treated by JJ stent, one case by ureteral reimplantation (1992))	3 (0.2%)
Rectal perforation (treated by colostomy)	1 (0.1%)

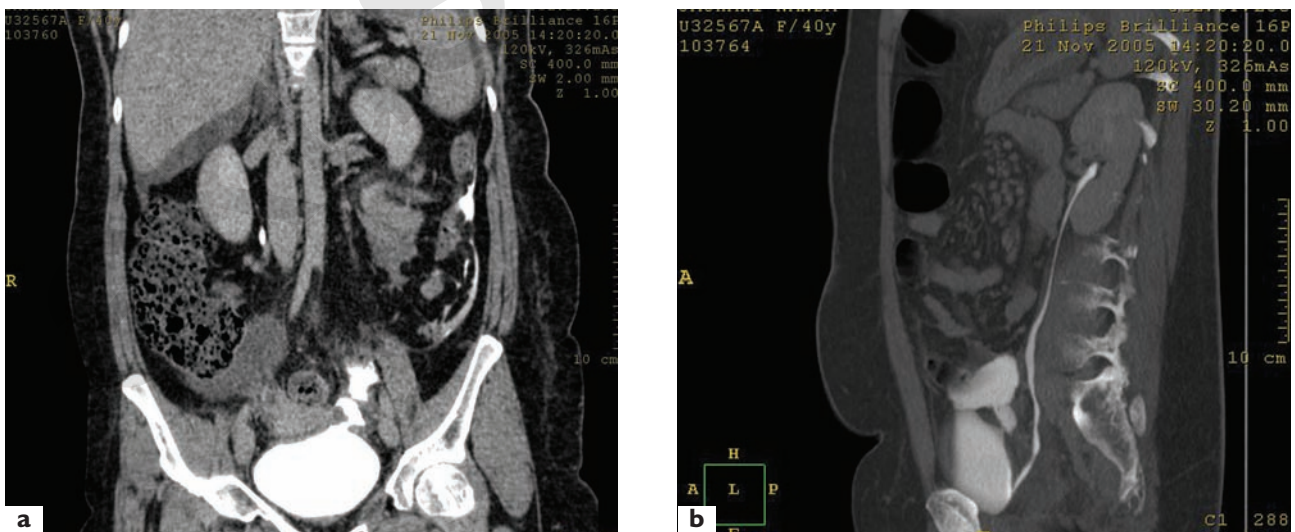


Figure 23.30 Complication: case of vesicoperitoneal fistula. Computed tomography scan (a) and (b). Leakage of contrast medium from the bladder to the peritoneal cavity. The diagnosis was made on day 6 post-op. A Foley catheter was left in place for 14 days

operation, carrying a greater risk of damaging the bladder or ureter, and, once again, we disagree.

Indeed, the experience and skill of the surgeons included in the review (which analyzed randomized trials comparing two surgical approaches to hysterectomy) obviously differed, with some of them still in the learning curve. More experienced laparoscopists would never be associated with such a complication rate, but their rates will never be included in a Cochrane Review, since they are not about to start a randomized study evaluating vaginal hysterectomy, abdominal hysterectomy and laparoscopic hysterectomy at this stage.

We clearly demonstrated, in a paper in the *New England Journal of Medicine*, that laparoscopic hysterectomy was less expensive than any other approach if non-disposable instruments were used²³. In the United States and in Europe, however, 75% of hysterectomies are performed by an abdominal approach. If laparoscopic hysterectomy is added to our surgical armamentarium, almost all hysterectomies (95%) would be carried out without an abdominal incision. In our department (Table 23.3), the rate of abdominal hysterectomy is less than 5%. The remaining indications for abdominal hysterectomy are myomas >14–15 weeks (unless a GnRH agonist can be administered in order to reduce the volume), malignant (or suspected to be malignant) ovarian masses and cervical cancer stage Ib (Wertheim–Meigs)²⁴ and frozen pelvis, when a hysterectomy is mandatory.

REFERENCES

- Findlay S. The health-insurance factor. *US News World Rep* 1990; 30: 57
- Kovak SR, Cruikshank SH, Retto HF. Laparoscopic assisted vaginal hysterectomy. *J Gynecol Surg* 1990; 6: 185–90
- Isaacs JH. *Gynecology and Obstetrics*. Clinical Gynecology. Philadelphia: JB Lippincott, 1990; 1: 1–11
- Smith HO, Thompson JD. Indications and technique for vaginal hysterectomy. *Contemp Obstet Gynecol* 1986; 27: 125
- Johns A. Laparoscopic assisted vaginal hysterectomy (LAVH). In Sutton C, Diamond D, eds. *Endoscopic Surgery for Gynecologists*. London, UK: WB Saunders, 1993: 179–86
- Reich H. New techniques in advanced laparoscopic surgery. *Clin Obstet Gynecol* 1989; 3: 655–81
- Mage G, Wattiez A, Chapron C, et al. Hystérectomie per-coelioscopique: résultats d'une série de 44 cas. *J Gynecol Obstet Biol Reprod* 1992; 21: 436–44
- Donnez J, Nisolle M, Squifflet J, Smets M. Laparoscopy-assisted vaginal hysterectomy and laparoscopic hysterectomy in benign diseases. In Donnez J, Nisolle M, eds. *An Atlas of Operative Laparoscopy and Hysteroscopy*. Carnforth, UK: Parthenon Publishing, 2001: 251–60
- Kilkku P. Supravaginal uterine amputation vs hysterectomy: effects on libido and orgasm. *Acta Obstet Gynecol Scand* 1983; 62: 141–5
- Donnez J, Nisolle M. LASH: laparoscopic supracervical hysterectomy. *J Gynecol Surg* 1993; 9: 91–4
- Querleu D, Leblanc E, Castelain G. Laparoscopic pelvic lymphadenectomy in the staging of early carcinoma of the cervix. *Am J Obstet Gynecol* 1991; 164: 579–81
- Reich H, McGlynn F, Wickie W. Laparoscopic management of stage I ovarian cancer: a case report. *J Reprod Med* 1990; 35: 601–4
- Donnez J, Nisolle M, Anaf V. Place de l'endoscopie dans le cancer de l'endomètre. In Dubuisson JB, Chapron CH, Bouquet de Jolinière J, eds. *Coelioscopie et Cancerologie en Gynecologie*. Paris: Arnette, 1993: 77–82
- Reich H. New laparoscopic techniques. In Sutton C, Diamond M, eds. *Endoscopic Surgery for Gynaecologists*. London, UK: WB Saunders, 1993: 28–39
- Canis M, Mage G, Wattiez A, et al. Vaginally assisted laparoscopic radical hysterectomy. *J Gynecol Surg* 1992; 8: 103–5
- Donnez J, Schrurs B, Gillerot S, et al. Treatment of uterine fibroids with implants of gonadotropin releasing hormone agonist: assessment by hystero-graphy. *Fertil Steril* 1989; 51: 947–50
- Donnez J, Gillerot S, Bourgonjon D, et al. Neodymium:YAG laser hysteroscopy in large submucous fibroids. *Fertil Steril* 1990; 54: 999–1003
- Garry R, Fountain J, Mason S, et al. The eVALuate study: two parallel randomised trials, one comparing laparoscopic with abdominal hysterectomy, the other comparing laparoscopic with vaginal hysterectomy. *Br Med J* 2004; 328: 1229–36
- Donnez J, Squifflet J, Jadoul P, Smets M. High rate of complications need explanation [Letter]. *Br Med J* 2004; 328: 643
- Wattiez A, Soriano D, Cohen SB, et al. The learning curve of total laparoscopic hysterectomy: comparative analysis of 1647 cases. *J Am Assoc Gynecol Laparosc* 2002; 9: 339–45
- Donnez J, Nisolle M, Smets M, et al. LASH: laparoscopic subtotal hysterectomy. In Donnez J, Nisolle M, eds. *An Atlas of Operative Laparoscopy and Hysteroscopy*. Carnforth, UK: Parthenon Publishing, 2001: 243–50
- Johnson N, Barlow D, Lethaby A, et al. Surgical approach to hysterectomy for benign gynaecological disease [Review]. *Cochrane Database Syst Rev* 2005; (1): CD003677
- Nisolle M, Donnez J. Alternative techniques of hysterectomy [Letter to the Editor]. *N Engl J Med* 1997; 336: 291–2
- Canis M, Mage G, Wattiez A, et al. La chirurgie endoscopique at-elle une place dans la chirurgie radicale du cancer du col utérin? *J Gynecol Obstet Biol Reprod* 1990; 19: 921

akusher-lib.ru

Laparoscopic approach for prolapse

A Wattiez

INTRODUCTION

From its beginnings in our department back in 1991, the laparoscopic approach for prolapse has changed considerably. Initially limited to strict reproduction of the techniques carried out by laparotomy, the addition of a number of complementary procedures has since enriched it so that, today, it provides an answer to all the situations encountered in the context of female prolapse repair.

The usual advantages of laparoscopy – less post-operative discomfort, shorter hospital stay, etc. – were rapidly eclipsed by the innovating aspect of this technique. By combining the precision of endoscopic vision and the positive pressure of the pneumoperitoneum, access has been gained to anatomical spaces that were difficult to exploit before, and the repair procedures can be adjusted under strict visual control. The results have been encouraging from the outset and are now excellent, with perfect anatomical correction and remarkable functional results. The time has now come to simplify the techniques and to render them reproducible by others, with acceptable operating times.

PREOPERATIVE WORK-UP

The preoperative work-up must be very meticulous. Thorough evaluation of the lesions is the only way to ensure a comprehensive repair under one anesthesia, thus preventing functional sequelae and recurrence.

Evaluating the prolapse

Clinical diagnosis of the lesions is the crucial phase of this evaluation. It is essential to stage the lesions for each sector. Standard clinical examination must seek to establish the degree to which the uterus, bladder and rectum are prolapsed. Lateral cystocele with vaginal folds still present must be distinguished from central cystocele with elimination of the vaginal folds. The former is due to detachment of the vagina from the arcus tendineus fasciae pelvis while the latter is due to a lesion in the vesicovaginal fascia. A systematic check must be made to detect any enterocele.

The tone of the levator ani muscles should be assessed for both quality and quantity. A high rectocele corresponds to a fascia pathology, and must be distinguished from a low rectocele due to deficient levator muscle support.

The functional symptoms must be evaluated. Particular attention needs to be paid to urinary continence, and three groups of patients need to be distinguished: patients in whom pure urinary stress incontinence is associated with the prolapse, patients presenting with masked urinary incontinence and patients without any urinary problems.

Similarly, rectal problems must be surveyed, for example, constipation and/or incontinence of fecal matter or gas. The anal sphincter needs to be checked, using ultrasound investigation if necessary.

Modern imaging techniques associated with clinical examination enable these problems to be visualized. Thanks to the recent progress made with dynamic magnetic resonance imaging and when conditions are optimum, lesions in all three areas can be visualized simultaneously. Most importantly, any enterocele can be detected.

Evaluation of urinary function

Urinary function needs to be assessed not only by questioning the patient but also by urodynamic investigation, which should be systematic. The main point to be determined is whether there is any deficit in the urethral sphincter which would require a change in the surgical strategy.

Evaluation of the feasibility of laparoscopy

Although the degree of feasibility of endoscopy has changed fundamentally over the past few years, it is still necessary to select the patients. Laparoscopic treatment of prolapse means that the patients have to undergo anesthesia that is generally protracted, a pneumoperitoneum and a protracted Trendelenburg position. The counter indications are most often connected with the anesthesia. However, the indications must also be established correctly for older patients and obese patients for whom the vaginal route should still be preferred.

PATIENT PREPARATION

The preparation of the patient is a crucial factor to obtain the best results from surgery. It must include preparation of the tissues to encourage healing and bowel preparation to optimize the endoscopic space.

Bowel preparation

The reason for this preparation is to empty the bowel and make it easier to push the loops of bowel out of the way and flatten them so as to enlarge the operating space. Preparing the bowel in case of accidental injury is not the prime purpose. Preparation starts with a standard low-residue diet which the patient is required to follow for the 5 days prior to the operation. Two days before the operation, the bowel is emptied by administering a laxative solution such as Xprep®. Finally, the day before the operation, the lower bowel should be cleaned with an enema. It is important to follow this chronological order in order to avoid any loss from the anus onto the table, which would give rise to a high risk of infection.

Vaginal estrogens

These should be prescribed for at least 1 month prior to surgery. The purpose is to improve the vaginal trophic condition. Improved tone will enable better healing.

Vaginal and parietal disinfection

Vaginal disinfection is essential. It should take place the day before surgery, by vaginal irrigation with an antiseptic solution and the installation of a pessary of Bétadine®. The abdominal wall must also be disinfected. After showering the day before the operation, the patient is shaved and then the abdominal wall is cleaned using an antiseptic solution, paying particular attention to the inner surfaces of the umbilicus. A dilute solution of Bétadine is applied and the skin covered with a closed sterile dressing fixed in place.

INSTALLATION OF THE PATIENT

Endoscopic surgery is long and difficult. The procedure needs to be optimized and the operating time kept as short as possible by ergonomic organization of the operation, for which correct installation of the patient is of prime importance.

Anesthesia

Anesthesia is generally administered with endotracheal intubation. Curare is not systematically used but only when parietal distension is not obtained at 12 mmHg pneumoperitoneum pressure. This general anesthesia may be associated with locoregional anesthesia of the epidural or spinal block type to ensure the most comfortable post-operative conditions possible.

Installation

The patient is placed on her back with legs apart and half-bent. This position creates three operating spaces: one on the left occupied by the surgeon, another on the right occupied by the first assistant and the third between the legs for the second assistant. The patient's arms are placed along her body to avoid any brachial injury. It is best to have two shoulder rests level with the acromion, but without any pressure on the neck muscles. The patient's hands must be carefully arranged to avoid any compression of the fingers. A system to warm the patient can be used to avoid any chilling.

The patient must be placed right at the edge of the table to optimize the movements of the uterine manipulator. The greater the range of movement the manipulator has, the better the tissues will be exposed.

The patient's abdominal wall and vagina must be generously disinfected and the drapes installed before the Foley catheter and uterine manipulator. It is essential that the perineal area is in a sterile environment and accessible to the surgeon who will need to position the manipulator or carry out a vaginal or rectal examination.

Bladder catheter

A permanent number 18 Foley catheter is installed; the balloon is filled with 15 ml normal saline and the catheter pulled back as far as possible in order to reveal the bladder neck as clearly as possible. The catheter is connected to a pouch placed where it can be seen easily, in order to keep a check on the urine (quantity, color, presence of any air in the pouch).

PREOPERATIVE ASSESSMENT

Clinical examination

It is essential to reassess the prolapse on the operating table once the patient has been anesthetized. This examination under general anesthesia may provide new information that might modify the operating strategy. It is carried out using vaginal valves and, most importantly, enables the appearance of the vaginal structure to be properly assessed together with the difference in collapse between the upper and lower areas. Similarly, any retroversion of the vagina can be better evaluated. If hysterectomy is to take place, the size and mobility of the uterus need to be assessed, and this element will guide the positioning of the trocars.

Appearance of the abdomen

The patient's general morphology and the appearance of the abdomen are decisive factors when deciding how to organize the operating field and position the trocars. The

ergonomics of movements during the operation are highly dependent on this.

A number of elements need to be taken into account:

- (1) The patient's morphology: the most important point to note is the distance between the pubis and the umbilicus. This governs the distance between the umbilical trocar and the suprapubic trocar. This suprapubic trocar needs to be located sufficiently high up to make it easy to approach the promontory, open the space of Retzius and perform the suturing. If the distance is short, the optics trocar will need to be placed above the umbilicus and the suprapubic trocar moved to the umbilical position.
- (2) The distance between the iliac spines: suturing is easier when the trocars are spaced well apart. For a patient in whom this distance is short, the trocars should be moved up in order to gain more space.
- (3) The quantity of fat present in the abdominal wall needs to be checked, so that the trocars can be positioned where the wall is thinnest. This will reduce the degree of rebound and the difficulty of reinsertion.
- (4) The laxity of the abdominal wall will give an idea of how much operating space there will be, and will also affect the positioning of the trocars.

POSITIONING THE TROCARS

As a general rule, four trocars are needed: three suprapubic trocars and one umbilical trocar. The first trocar to be inserted is always the umbilical trocar. This is 10 mm in diameter. The final position of this trocar is decided after carrying out a visual internal inspection and comparison with known data (size of the uterus, patient's morphology). If the uterus is normal or below normal in size and there is sufficient distance between the pubis and umbilicus, this will be the optics trocar. If, on the other hand, there is a large uterus or a short puboumbilical distance, then it will be the central operating trocar.

In the great majority of cases, there are thus three suprapubic trocars and one umbilical trocar.

- (1) For the suprapubic trocars, we prefer to use disposable trocars 5 mm in diameter. We have selected trocars made by mtp® (reference 020105 or 020106, Tuttlingen, Germany). They present the advantages of being light and transparent, with external tapping making them stable in the abdominal wall, and have a star-shaped valve which provides a leak-proof seal, even when making the sutures. Finally, they are reasonable in cost. The lateral trocars are positioned level with the anterior superior iliac spines, about two fingers inside the spines and outside the external edge of the rectus abdominis muscles. This means that they are located in the vicinity of the oblique

and transversus abdominis muscles. The abdominal wall in this area is generally thin, making movements easier. The central trocar is located more or less halfway along the puboumbilical line. There should be about 6 cm at least between the umbilical optics trocar and the central trocar. In any case, the central trocar must be located no lower than the line running between the two external trocars.

- (2) If the umbilical trocar is intended to hold the optics unit, a simple reusable steel trocar is used. We prefer the Karl Storz model (Tuttlingen, Germany), the reason being that it has a valve that the surgeon can lower when introducing the optics. This helps to keep the lens clean during insertion and consequently saves considerable time. If the umbilical trocar is to be the central operating trocar, we prefer to use a disposable trocar with a removable reducer device located at the top of the trocar. For reasons outlined above, we prefer the model by mtp (reference 020174 or 020107, Tuttlingen, Germany).

Under standard conditions (three suprapubic trocars and one umbilical trocar), we prefer to start the operation with three 5-mm trocars for dissection procedures, replacing the central trocar later when suturing takes place (once hysterectomy has been completed).

ORGANIZATION OF THE OPERATING FIELD

Positioning the manipulator (Figure 24.1)

The uterine manipulator is an essential piece of equipment for presenting the uterus. It allows manipulation in all directions: pushing, anteversion, retroversion, lateralization and flexing of the uterus forwards and laterally. In addition, it enables the vaginal fornices to be presented and provides

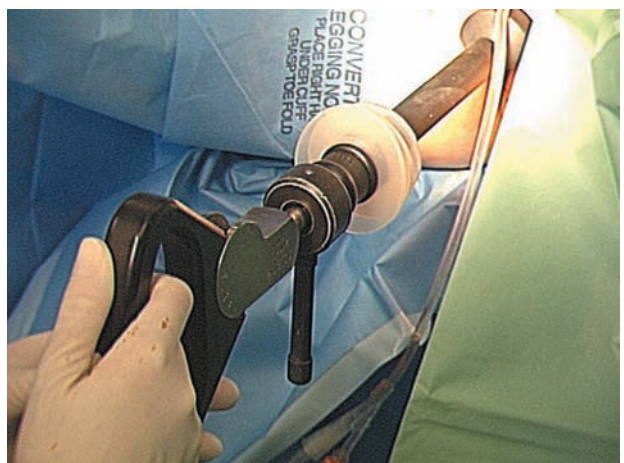

Figure 24.1 Positioning the uterine manipulator

a leak-proof seal for the pneumoperitoneum and a seal for the vagina after extraction of the uterus.

The device presents several concentric shafts. The central shaft has a screwed tip which is inserted in the uterus. Several sizes of screw are available but the size is chosen according to the size of the uterus. The end of the manipulator with the screw can be bent by tipping the distal handle. Around this shaft there is a valve, covered with ceramic material. This unique valve can rotate through 360°, and is used to expose the fornices. Finally, around the valve, there is a system of seals made up of three flexible disks. These are not introduced into the vagina until near the end of the operation when the vagina is opened.

Insertion

The Clermont-Ferrand manipulator (Karl Storz, Tuttlingen, Germany) must not be inserted until after the patient has been swabbed and draped. It needs to be manipulated by the surgeon under sterile conditions. After exposing the cervix, a hystrometer is used to measure the size of the uterine cavity. The screw is chosen according to the size found. The cervix is then dilated up to bougie no. 8; the device is locked in the zero position and presented at the opening of the cervix. It is important to screw the device home until the screw is completely inside the uterine cavity. Once this has been achieved, the handle-locking control lies on the right.

Exposure: the various possibilities for manipulation

In most cases, each manipulation is preceded by a movement thrusting the uterus towards the patient's head. Anteversion is achieved by combining two movements: pushing on the uterus and anteversion by lowering the handle of the device. This movement places the two uterosacral ligaments under tension and exposes the pouch of Douglas. Similarly, the adnexa are exposed by pushing and moving the handle laterally underneath the patient's legs, which are in a lithotomy position, being spread and half-bent. The valve can be manipulated at any time and enables the vaginal fornices to be exposed correctly.

Fixation of the intestine (Figure 24.2)

The operating field needs to be carefully organized right at the beginning of the operation. This helps to obtain stable exposure without the assistant needing to intervene. With this in mind, the pouch of Douglas is cleared by fixing the sigmoid to the abdominal wall. We use two different techniques to achieve this. The first technique uses a straight needle swaged to a length of nylon suture material. The needle is introduced through the abdominal wall about 5 cm above the left lateral trocar. The needle is then taken through the fatty tissues of the parasigmoid each side of the sigmoid itself, then back out through the abdominal

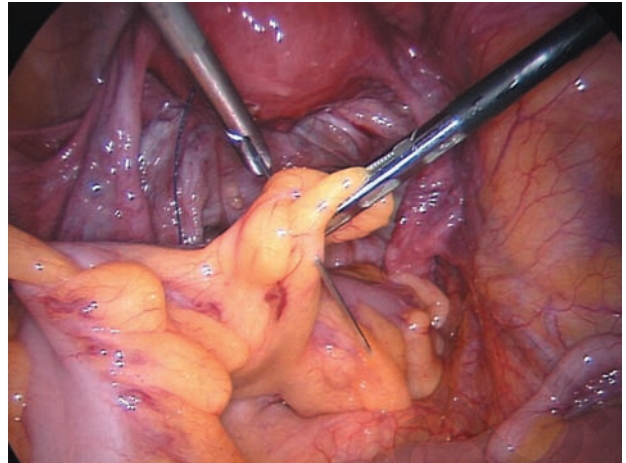


Figure 24.2 Fixation of the intestine so that the operating field is organized at the beginning of the operation

wall at the same place as before. The sigmoid is lifted with a forceps and the suture tightened over a pad, thus holding the sigmoid in position. The same effect can be achieved with a curved needle introduced into the abdominal cavity. The parasigmoid fatty tissue is taken up and the needle taken back out via the trocar. The needle is then cut, and a Reverdin's needle introduced through the abdominal wall above the left trocar, to grasp the ends of the suture inside the abdomen and bring them back out. They are then fixed using a forceps. After the hysterectomy, the vagina or stump of the cervix is suspended against the anterior abdominal wall in a similar fashion, using a Reverdin's needle.

Identification of the origin of the uterosacral ligaments

The origin of the uterosacral ligaments can be identified at the beginning of the operation. This is where culdoplasty will start. The means of identification may be a mark left by bipolar coagulation or, even better, by leaving a length of suture as a marker.

OPERATING STRATEGY

Strategic chronology of the phases

The strategic chronology of the operating procedures is important. A clear distinction must be drawn between the dissection and the fixing phases.

Dissection phases

The dissection phases take place in the following chronological order: dissection of the promontory, dissection of the right lateral peritoneum, dissection of the rectovaginal space and then the hysterectomy during which bladder

dissection is taken very low. There is a good reason for this specific order. The promontory must be dissected first because it often needs the Trendelenburg position to be more marked. In many cases, this is possible only at the beginning of the operation. Once this part of the dissection has been completed, the patient can be laid flat if the anesthesiologist decides this is better. Dissection of the spaces where the prostheses are to be installed is made easier by use of the uterine manipulator which improves access to the various areas. Thus, this part of the dissection should be carried out prior to the hysterectomy.

Fixing phases

The posterior prosthesis is positioned first, then the culdoplasty takes place before the prosthesis is fixed at the front. Next comes peritonealization of the lower areas which continues until half of the right peritoneal opening has been closed. This is the point at which the timing of a Burch procedure needs to be discussed.

If it is desired to follow the traditional procedure and fix the bladder neck before fixing to the promontory, the prostheses are left waiting and the Burch procedure and any required paravaginal repair are carried out immediately. More often, the prosthesis is fixed to the promontory now, peritonealization is completed and cervicosuspension is carried out later.

The place of hysterectomy

In the classic procedure, the uterus was left in place to avoid opening the vagina with the consequent risks of infection for the prosthesis. This technique is possible with the laparoscopic approach, with dissection of the spaces taking place without sectioning the round ligaments and by taking the prostheses through the broad ligaments.

Today, the trend is to carry out hysterectomy. It may be subtotal or total. In our experience, subtotal hysterectomy is preferable because it offers the advantage of leaving the vagina closed. When the hysterectomy is total, vaginal closure should take place along two planes.

As we have said, the essential difference compared with a simple hysterectomy lies in the chronology of the operating phases. When treating a prolapse, dissection of the rectovaginal and vesicovaginal spaces goes further forward and the uterus is removed only after all these spaces have been dissected. We describe dissection of these spaces in more detail below.

Peroperative antibiotic therapy

We use peroperative antibiotic therapy. This consists of injections of the latest generation of cephalosporins as a 1-g flash which is repeated if the operation lasts more than 4 h.

OPERATING TECHNIQUE

Dissection of the promontory

The promontory is best approached for surgery by increasing the Trendelenburg position, after carefully pushing the loops of small intestine back and fixing the sigmoid. The desired position is opposite disc L5–S1, or the upper part of S1. The anterior common vertebral ligament is separated off. To the inside, the median sacral artery and vein are reclinced or coagulated if necessary. Particular care must be taken concerning the left iliac vein in obese patients and those with a low bifurcation of the aorta (Figures 24.3 and 24.4).

The promontory is identified by palpation with the instruments. After the right ureter and the lower edge of the left primitive iliac vein have been identified, the posterior prevertebral parietal peritoneum is pulled upwards by the assistant and then incised vertically from the promontory, leaving the ureter to the outside. When the peritoneum is opened, the pneumoperitoneum gas rushes into

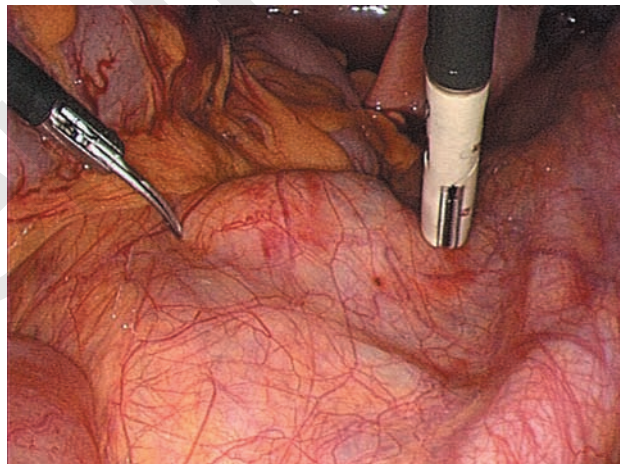


Figure 24.3 Laparoscopic view of the promontory

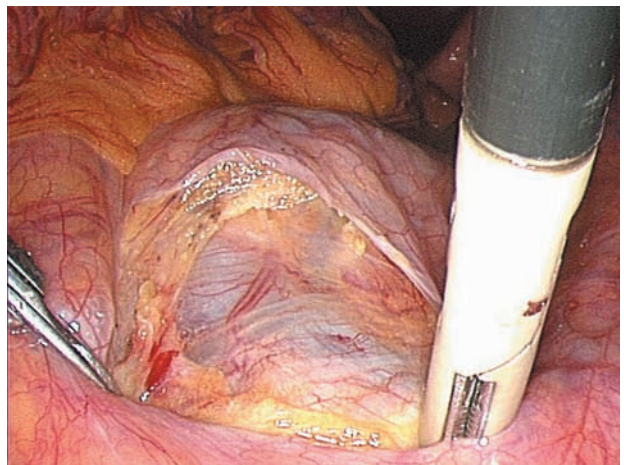


Figure 24.4 Dissection of the promontory

the retroperitoneal space and initiates dissection. Those organs that adhere to the posterior plane remain fixed in place whereas all the elements that are free to do so move away from the promontory (Figure 24.5).

Incision of the right lateral peritoneum

Dissection continues vertically to reach the pouch of Douglas. During this dissection, the surgeon needs to pay particular attention to the internal iliac vein which must be crossed, and the uterosacral ligament area which does not detach easily. The purpose of this incision is to enable the prosthesis to be peritonealized, and it must leave the ureter free. Consequently, it is not enough simply to make an incision, but instead sufficient peritoneum must be freed to enable the prosthesis to be covered without imposing any constraints on the ureter.

Dissection of the rectovaginal space (Figure 24.6)

The point at which the two uterosacral ligaments join at the level of the torus uterinus is identified. The rectum is grasped by the assistant, using a bowel forceps, prior to

applying strong traction downwards. The peritoneum opposite the torus uterinus tightens to form a fold, after which it is coagulated and sectioned 2 cm below its uterine insertion. Dissection then continues towards, and until it meets, the posterior wall of the vagina. The rectovaginal septum is now easier to tackle. Dissection is taken downwards, remaining in contact with the vagina to the front. It continues until the anal area is reached. At this point, dissection is directed outwards to the lateral wall of the pelvis, which is reached in the subobturator area. In this lateral area, the median rectal vessels will be found and can be left intact or coagulated according to the space available. Now the surgeon moves up towards the rectum in order to be sure of identifying the rectopubic bundles of the levator ani muscles.

When dissection has been completed, the levator ani muscles become visible. It is important for them to be seen clearly. The space dissected is now bordered by the following structures: the levator ani muscles and the pelvic wall to the outside, the anal area downwards, the vagina to the front and the rectum to the rear.

Hysterectomy

The standard technique is used to carry out the hysterectomy:

- Installation of a uterine manipulator
- The various dissection phases are part of the preparation for installing the prosthesis: vesicovaginal and rectovaginal spaces
- Coagulation and preliminary section of the round ligaments and dissection of the lateral vesical spaces. Fenestration of the posterior layer of the broad ligament
- The adnexa may be kept or not, depending on the patient's age. The utero-ovarian ligament, tube and adnexal vessels are coagulated and sectioned if the adnexa are to be spared, whereas the lumbo-ovarian

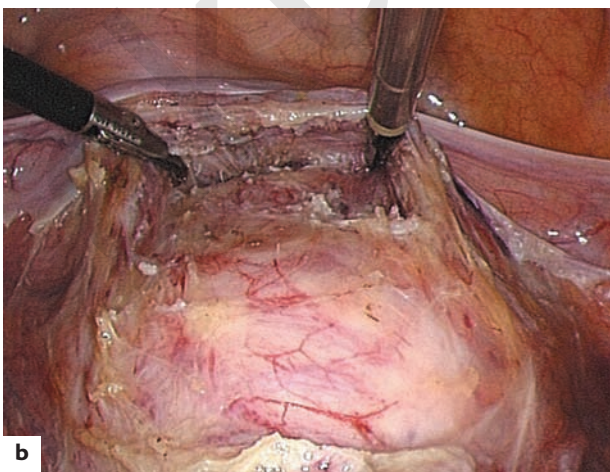
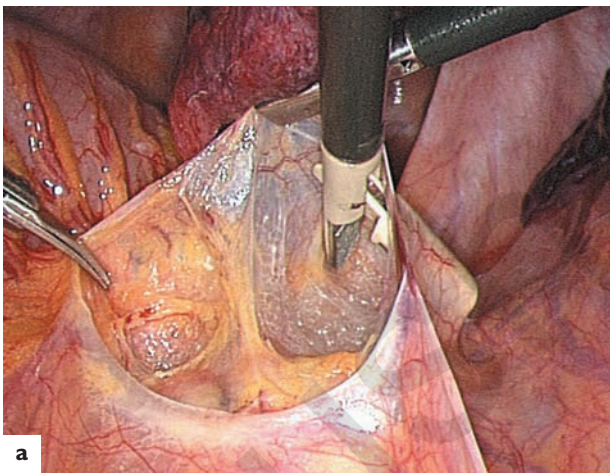


Figure 24.5 (a) and (b) Dissection of the promontory

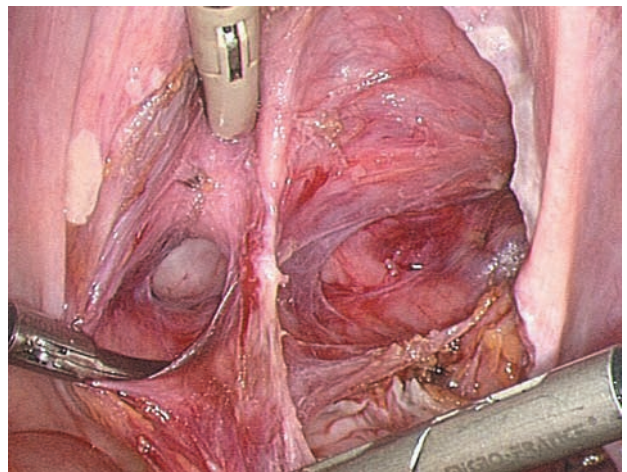


Figure 24.6 Dissection of the rectovaginal space

ligament is coagulated and sectioned if the adnexa are to be removed

- Bladder dissection is taken lower to enable the prosthesis to be installed
- The posterior layers of the broad ligament are dissected down to the origin of the uterosacral ligaments
- The uterine pedicles are identified and then coagulated using the bipolar forceps, or taken up with a suture using Vicryl® 0
- Intrafascial dissection proceeds gradually with coagulation of the cervicovaginal vessels. For total hysterectomy, Halban's fascia needs to be separated off so that closure can be made along two planes
- The vagina is opened through 360°, protected by the uterine manipulator
- The uterus is extracted via the vagina
- The vagina is closed along two planes. The first plane takes up solely the vaginal mucosa and the second plane covers the first using the paracervical fascias. These two planes are sutured using Vicryl 0. It is essential to suture in two planes in order to protect the prosthesis properly from any contamination via the vagina

For subtotal hysterectomy, the cervix is sectioned at the isthmus after controlling the uterine arteries. Section can take place by various means. We prefer to use the cold knife in an endoscopic blade holder.

Fixation of the posterior prosthesis (Figure 24.7)

The strip is fixed at the back first. Once the hysterectomy has been completed, it is convenient to fix the vagina to the anterior abdominal wall in order to free the assistant's instrument so that it is more readily available for suturing.

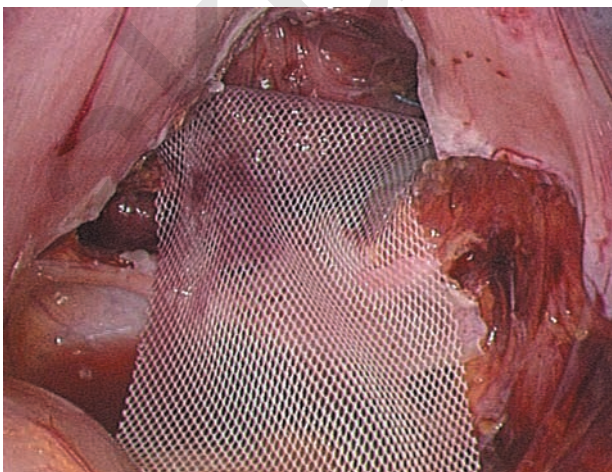


Figure 24.7 Fixation of the posterior prosthesis

Each of the levator muscles is taken up generously using a length of Ethibond™ 0 on a 30-mm needle. The prosthesis is fixed to the right and left. This is the point when myorrhaphy should take place. It is never total, but provides closure of the interlevator hiatus. This closure should be more or less complete depending on individual circumstances. It also forms the lower point of support against which the vagina will rest.

Once the prosthesis has been stretched between the two levator ani muscles, the hiatus between the prosthesis and the vagina is closed by suturing the prosthesis to the vagina, level with the anal area.

The prosthesis is then arranged over the posterior surface of the vagina and anchored to the cardinal ligaments using non-resorbable sutures (Ethibond 0). We avoid making any stitches in the posterior wall of the vagina to prevent any risk of transfixion. Once the prosthesis has been positioned at the back, a McCall type culdoplasty is carried out.

Culdoplasty (Figure 24.8)

The aim of this procedure is to reposition the rectum higher up and restore tension for the vagina towards the back. The posterior part of the Douglas pouch needs to be closed. This can be achieved with or without Douglasectomy and can use one or two points. The suture material needs to be non-resorbable, and we recommend Ethibond 0.

The first step is to take up the fleshy part of the uterosacral ligament, fairly well to the rear. The cardinal ligament is taken up generously, after checking where the ureter is. Finally, the posterior prosthesis and the vagina are taken up and then the knot is tightened. This procedure is repeated on the other side.

Once this plasty has been completed, the vagina will have returned to its normal anatomic location. Consequently, no traction upwards will be needed any more.

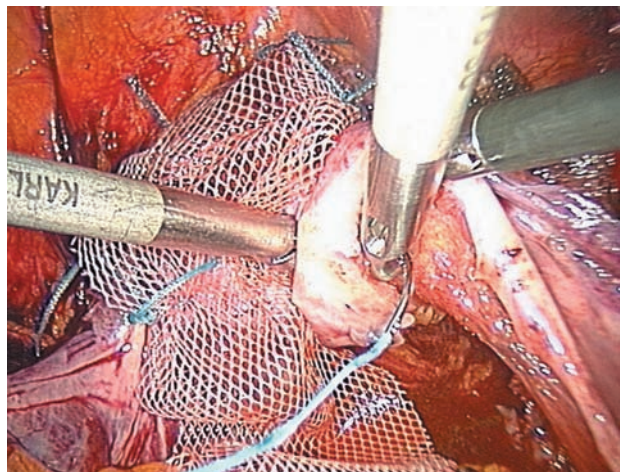


Figure 24.8 Culdoplasty

Fixation of the anterior prosthesis
(Figure 24.9)

The prosthesis is spread out in position in the anterior vesicovaginal space. If the uterus is to be kept, the two branches of the strip are taken down through windows created in the posterior layer of the broad ligament. Then they are knotted behind the isthmus, using a flat knot in the area deperitonealized when the rectovaginal space was opened up.

The prosthesis is fixed to the anterior vaginal wall by non-transfixing stitches of non-resorbable suture material (Ethibond gauge 2-0) with an 18-mm curved needle. These sutures are knotted using extracorporeal knots of the half-hitch type. Between four and six sutures are needed to ensure that the prosthesis is anchored firmly enough.

Peritonealization of the lower area
(Figure 24.10)

At the vaginal level, the purpose of peritonealization is to exclude the prosthesis from the abdominal cavity and

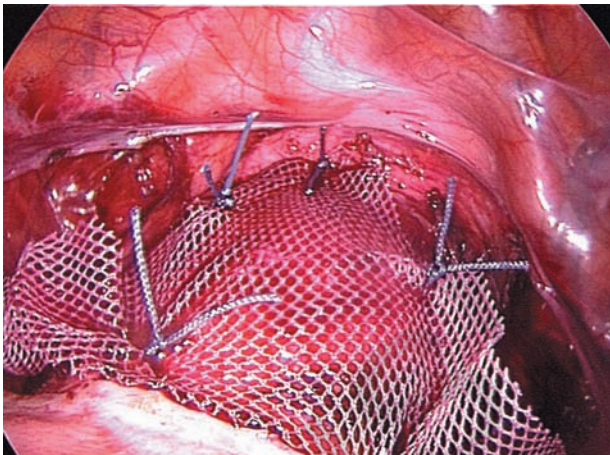


Figure 24.9 Fixation of the anterior prosthesis

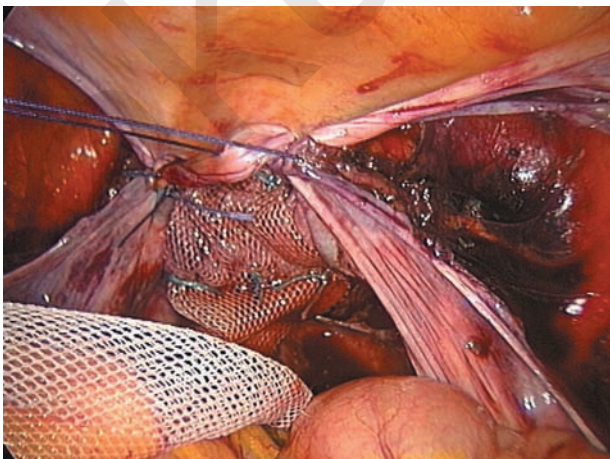


Figure 24.10 Peritonealization of the lower area

bring the bladder up onto the prosthesis. To do this, the surgeon starts on the left and, using Vicryl 0 suture swaged onto a 30-mm curved needle, takes up the supravescical peritoneal layer, the pillar of the bladder, the lateral vaginal peritoneum and then the internal layer of the lateral incision, each in turn. Using the same suture, this procedure is repeated on the right. A series of half-hitches closes the purse formed, simultaneously closing the peritoneum and lifting the bladder.

Promontofixation (Figures 24.11 and 24.12)

Promontofixation is completed by fixing the anterior and posterior prostheses level with the promontory to the common anterior vertebral ligament, using two stitches of Ethibond 1 and a 30-mm curved needle, or staples or Tackers®.

The needle must remain visible by 'transparency' in order to avoid any risk of spondylodiscitis, only taking up the fibrous layer of the aponeurosis, which also means that there is no risk of perforating the substance of the disc itself. Once the stitches have been taken through, firm

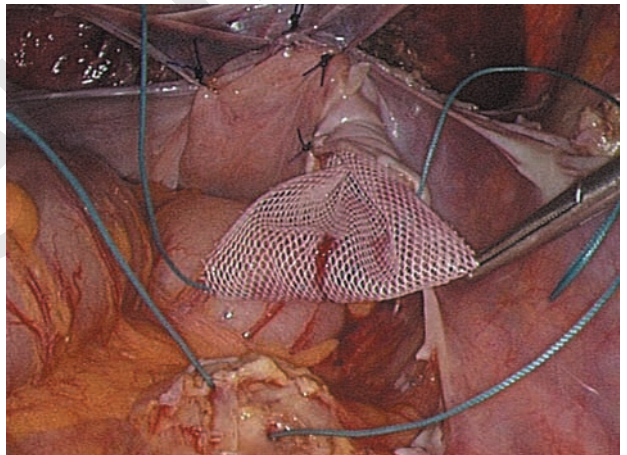


Figure 24.11 Promontofixation

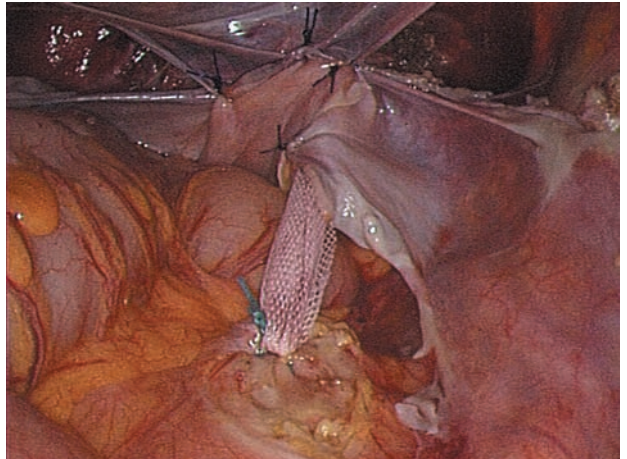


Figure 24.12 Lower peritonealization

traction is applied to check that the anchorage is sufficiently sturdy. The prosthesis needs to be fixed in position. This means that, once all the anatomic corrections have been made, the prosthesis is laid on the promontory and fixed *in situ*. The surgeon's experience is crucial at this point.

Upper peritonealization (Figure 24.13)

The prosthesis must be totally excluded in a retroperitoneal position. A running suture back and forth is therefore needed, taking up the internal and external layers of the lateral peritoneal incision. We use a length of Monocryl® no. 0 suture swaged to a 30-mm curved needle. The slipping qualities of this material make this running suture in each direction easy to achieve, after which it is locked by half-hitches. However, several half-hitches are needed to ensure that the knot remains stable.

These procedures complete the anterior stages. The later phases concern the space of Retzius only.

Opening the space of Retzius

With a transperitoneal incision, the operation starts by identification of the anatomic landmarks, the pubis, Cooper ligaments and the upper edge of the bladder, identified by the beginning of the urachus.

The peritoneum is incised above the fundus of the bladder. The incision must run horizontally from one umbilical artery to the other. The assistant applies downwards traction on the peritoneum using a forceps, while the surgeon uses the instrument in his right hand to pull the plane vertically and incise it using the scissors in his left hand which are connected to the monopolar power source.

The urachus is coagulated then sectioned; the surgeon needs to progress vertically towards the abdominal wall, crossing the prevesical–umbilical aponeurosis to enter the space of Retzius. The space of Retzius is an avascular plane that is dissected by simple divergent traction.

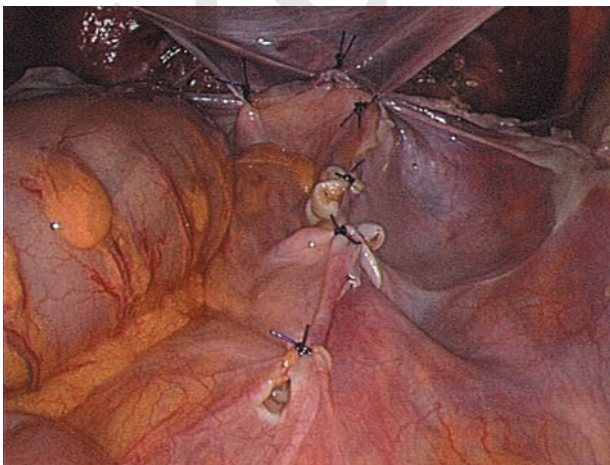

Figure 24.13 Upper peritonealization

Pneumodissection helps to open the space. Remaining in contact with the aponeurosis, the surgeon will reach several tissular planes in succession, which need to be broken down until the fatty tissues located in front of the Cooper ligament indicate that the upper limit of the space of Retzius has been reached. Now, the right and left Cooper ligaments need to be separated off. At this point, the space of Retzius is opened by simply breaking the tissues down until the arcus tendineus fasciae pelvis is found. Dissection continues backwards until just below the obturator fossa.

The vaginal walls are prepared with the help of a finger placed in the fornix. The edge of the bladder is often revealed by the presence of a vein running along it. This must then be carefully separated from the vagina which shows up pearly white.

Paravaginal repair (Figures 24.14 and 24.15)

At this point, the positive pressure from the pneumoperitoneum helps to reveal lateral defects which are nearly always present in complex prolapse cases. They show up as

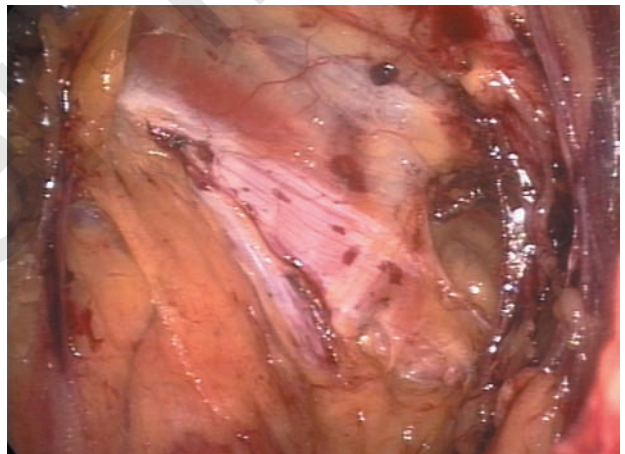


Figure 24.14 Laparoscopic view of the paravaginal defect

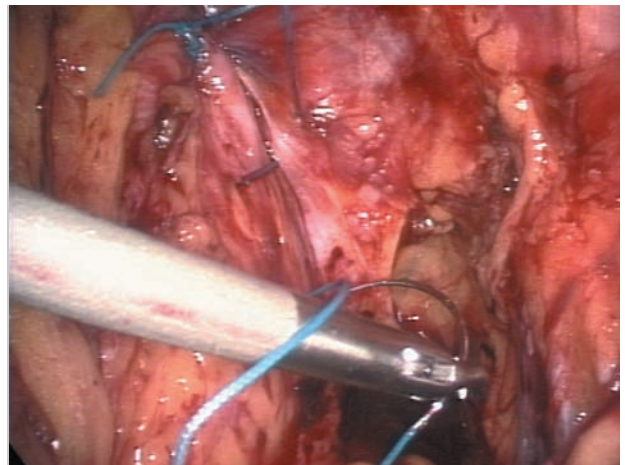


Figure 24.15 Paravaginal repair

hernias running from the arcus tendineus fasciae pelvis to the vagina itself. If there is indeed a paravaginal hernia, it must be repaired. It is closed using separate stitches or a running suture of Ethibond 0 with a size 18 needle. This suture should run from the pubourethral ligaments at the front to the sciatic spine at the back. It may be uni- or bilateral.

Burch bladder neck suspension (Figure 24.16)

Once the previous repair has been completed, bladder neck suspension is carried out. The material used is Ethibond gauge 3.5 (0) with a 26-mm needle.

The suture is taken through the Cooper ligament first, from top to bottom, then through the vagina from inside outwards, trying not to transfix. The passage through the vagina must be sufficiently broad to ensure that the construction will be sturdy. If there is any bleeding during the first passage through, an X-shaped stitch is made. In cases with promontofixation, a single suture is taken through each side. The tension applied must be moderate only. If there has also been paravaginal repair, this will prevent any hypercorrection by the cervicosuspension.

Peritonealization

This is systematic and complete. The purpose is to avoid any bowel becoming trapped in the space of Retzius. We use a length of Vicryl 0 swaged to a 36-mm curved needle. Closure is effected with three runs from right to left. The upper and lower edges of the peritoneum are taken up in turn, and then the suture is fixed using half-hitches.

Final procedures

Uterine morcellation

This is needed for subtotal hysterectomy. We use the Steiner™ morcellation device (Karl Storz, Tuttlingen,

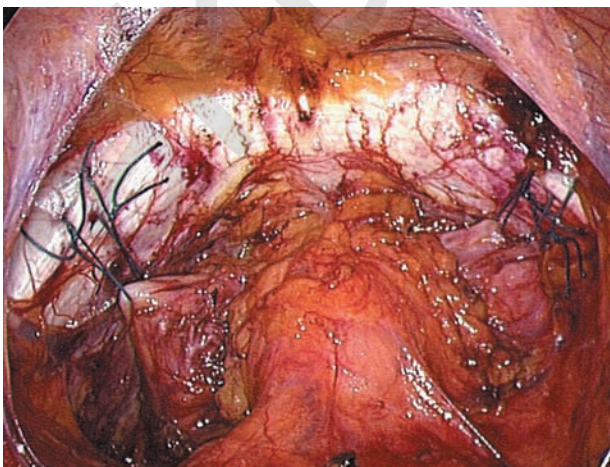


Figure 24.16 Burch bladder neck suspension

Germany). The uterus, which is usually small, is cut into a 10-mm diameter strip which is extracted through the device. It is then sent for examination by the pathologist.

Releasing the attachments

The sutures holding the bowel out of the way are released under visual control and any bleeding areas are coagulated.

Peritoneal lavage

Ringer's lactate is the best substance to use for this cleaning phase, which must be thorough. All the blood clots are aspirated and any hemostasis still needed carried out. At the end of the operation, the rinsing liquid must return completely clear.

Cystoscopy

The ureters must be checked several times during the operation: after the hysterectomy, after peritonealization and after the Burch procedure. By checking after each phase to see whether there is an injury, it will be possible to identify what the cause was, thus helping to achieve the best repair possible. It is also important to keep a check on the color of the urine and any increase in volume of the pouch which could indicate a bladder or ureter injury.

The need for cystoscopy is the subject of debate. Some authors use it systematically whereas others use it only in case of doubt. The indications should be broad. It will confirm that the urine is correctly ejaculated from the urethral meatus and is the only way of certifying that the ureter is intact.

POSTOPERATIVE CARE

Antibiotic therapy

We do not use postoperative antibiotic therapy systematically. We treat only infections that are proven after sampling and an antibiogram.

Prevention of postoperative phlebitis

Our patients are given systematic treatment for the prevention of phlebitis. Low-dose heparin therapy is started on admission to the hospital the day before the operation, and is continued for 15 days.

Foley catheter

The Foley catheter is left in place for at least 24 h, and possibly for longer according to the patient's age and mobility. On removal, a systematic cytobacteriological examination is carried out. Antibiotic therapy is initiated in the event of urinary infection.

Hospital stay

This lasts between 3 and 5 days.

Postoperative regimen

The patient is asked to avoid undue exertion after the operation. No strain or carrying of heavy loads is allowed for 3 months. The recommended diet is normal with plenty of liquids in order to combat the constipation that is almost always experienced during the first 3 weeks post-operatively. Sexual relations can be resumed after 6 weeks.

CONCLUSIONS

Laparoscopy enables the advantages of prolapse treatment by laparotomy to be combined with the low morbidity of the vaginal route. The operating times, which initially were very long, have now been reduced to about 2 h in the hands of experienced surgeons. Naturally enough, studies are required on long-term efficiency and reliability in order to evaluate the technique fully.

BIBLIOGRAPHY

- Addison WA, Livengood CH, Sutton GP, et al. Abdominal sacral colpopexy with Mercilene mesh in the retroperitoneal position in the management of posthysterectomy vaginal vault prolapse and enterocele. *Am J Obstet Gynecol* 1985; 15: 140–6
- Addison WA, Timmons C, Wall LL, et al. Failed abdominal sacral colpopexy: observations and recommendations. *Gynecol Obstet* 1989; 74: 480–3
- Ameline A, Huguier J. La suspension postérieure du disque lombo-sacré: techniques de remplacement des ligaments utéro-sacrés par voie abdominale. *Gynecol Obstet* 1957; 56: 94–8
- Baker KR, Beresford JM, Campbell C. Colpo-sacropey with Prolene mesh. *Gynecol Obstet* 1990; 171: 51–4
- Caubel P, Lefranc JP, Foulkes H, et al. Traitement par voie vaginale des prolapsus génitaux récidivés. *J Chir* 1989; 126: 446–70
- Hoff S, Manelfe A, Portet R, et al. Promonto-fixation ou suspension par bandelettes transversales? Etude comparée de ces deux techniques dans le traitement des prolapsus génitaux. *Ann Chir* 1984; 38: 363–7
- Nichols D, Milley P. Significance of restoration of vaginal depth and axis. *Obstet Gynecol* 1970; 36: 251–5
- Querleu D, Parmentier D, Delodinance P. Premiers essais de la coelio-chirurgie dans le traitement du prolapsus génital et de l'incontinence urinaire d'effort. In Blanc M, Boublil L, Baudrant E, D'Ercale C, eds. *Les Troubles de la Statiques Pelviennes*. Paris: Arnette, 1995: 155–8
- Randall C. Surgical treatment of vaginal inversion. *Obstet Gynecol* 1971; 38: 327–32
- Robert HG. *Nouveau traité de techniques chirurgicales gynécologiques*. Paris: Masson et Cie, 1969: 128–30
- Sutton JP, Addison WA, Livengood CH, et al. Life threatening hemorrhage complicating sacral colpopexy. *Am J Obstet Gynecol* 1981; 140: 836–7
- Wattiez A, Aimi G, Finkeltin F, et al. Cure chirurgicale des prolapsus vesico-uterins par voie coelioscopie exclusive. *Gynaïkeia* 1997; 2: 50–5
- Wattiez A, Boughizane S, Alexandre F, et al. Laparoscopic procedures for stress incontinence and prolapse. *Curr Opin Obstet Gynecol* 1995; 7: 317–21
- Wattiez A, Canis M, Mage G, et al. Promontofixation dans le traitement des prolapsus: intérêt et technique de la voie coelioscopie. *J Coeliochir* 1999; 31: 7–11
- Wattiez A, Cucinella G, Giambelli F, et al. Laparoscopic Burch procedure for retropubic colposuspension. *Ital J Gynaecol Obstet* 1997; 9: 114–17

akusher-lib.ru

Laparoscopic sacrocolpexy for severe uterine prolapse and severe vaginal vault prolapse

25

J Donnez, M Smets, J Squifflet, O Donnez, P Jadoul

The surgical treatment of vaginal vault prolapse and cervical or uterine prolapse is a major challenge to the surgeon, especially when the preservation of sexual function is sought. In patients with surgical contraindications, the placement of a vaginal pessary may offer great relief from symptoms without any surgical risk. But when surgery is possible, it is the preferable therapy.

Genital prolapse can be treated by various techniques, with or without synthetic material (prosthesis), by laparotomy, laparoscopy or vaginal surgery. In vaginal surgery, hysterectomy is usually associated with the technique, except for transposition of the uterosacral ligaments in front of the cervix (Shirodkar technique). Some authors have described sacrospinal ligament vaginal fixation by the vaginal route¹. Laparotomy techniques may be associated with total hysterectomy, subtotal hysterectomy or uterus conservation. A synthetic material is then often used to attach the cervix, the uterus or the vagina to the sacrum or the prevertebral ligament. Alloplastic graft materials, such as polytetrafluoroethylene (Teflon®)^{2,3}, propylene (Marlex®)^{2,4-6}, polyester fiber (Mersilene®)^{2,7-11}, Gore-Tex®^{2,7} or polypropylene¹² have been used by many authors. Homologous materials, such as fascia¹³⁻¹⁵ or dura mater¹⁶, have also been used and are well tolerated, although unresorbable sutures covered with peritoneum have been reported too¹⁷. Since 1993, laparoscopic procedures have been proposed in the management of vaginal, cervical or uterine prolapse¹⁸⁻²⁵. All of these recent techniques use a synthetic material, which is attached to the vagina or the cervix towards the promontosacral space^{18,20,22,25} or the anterosuperior iliac spine¹⁹, according to the technique described by Kapandji²⁶. The uterine promontosacropexy is, at present, the most frequently used technique in young women. Ross and Preston recently used a combination mesh consisting of porcine dermis and collagen-coated polypropylene²⁵.

A series of 146 women (Table 25.1) underwent a simple combined vaginal and laparoscopic technique with or without uterus conservation, involving sacral fixation of a tightened polypropylene prosthesis (mesh) attached to the posterior part of the cervix ($n=114$) or the vaginal vault ($n=32$) in cases of vaginal vault prolapse. This mesh was fixed to the body of either the first sacral vertebra or the fifth lumbar vertebra with the help of a novel tacking device (Origin Tacker®, Origin). All the women had a preoperative front and profile lumbosacral junction X-ray to check the promontory.

Table 25.1 Laparoscopic sacrofixation

	<i>n</i>
Combined with LASH	114
Vaginal vault prolapse	32
Total	146

LASH, laparoscopic subtotal hysterectomy

OPERATIVE TECHNIQUE

Cervical or uterine sacrofixation

The patient is placed in the Trendelenburg position. The surgeon stands to the left of the patient and holds the laparoscope in his right hand. The assistant stands between the legs of the patient. Single-tooth vulsellum forceps are placed on the anterior lip of the cervix and a cannula is inserted into the cervix for uterine mobilization if the cervix is present. A Foley catheter is inserted into the bladder. Three 5-mm suprapubic trocars are introduced: one in the midline and two lateral to the epigastric vessels.

First step: exploration

The abdominal cavity is explored first. The peritoneum, the uterus and the adnexa are inspected; the ureters are traced along the pelvic side-wall and the major iliac vessels are carefully located (Figure 25.1). Adhesiolysis is performed if necessary. Laparoscopic subtotal hysterectomy (LASH) may be performed if indicated (Figures 25.2–25.4)^{27,28}. The uterine corpus should then be removed during the next stage of the procedure (colpotomy).

Second step: colpotomy

After careful disinfection of the pouch of Douglas and the vagina with an iodine solution, a posterior colpotomy is performed along a sagittal vaginal incision over a length of 4–5 cm (Figure 25.5). If LASH was performed during the first step, the uterus is removed through the colpotomy (Figure 25.6). After the dissection and opening of the posterior peritoneal cul-de-sac, a right-angled retractor is placed on the posterior lip of the vagina. Another

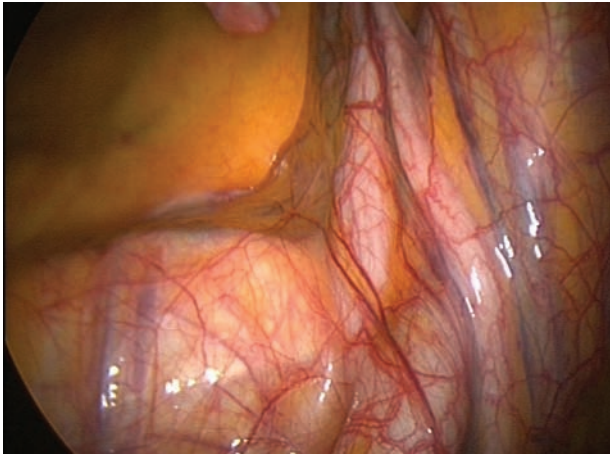

Figure 25.1 The abdominal cavity is explored first. The ureters are traced along the pelvic sidewall and the major iliac vessels are carefully located

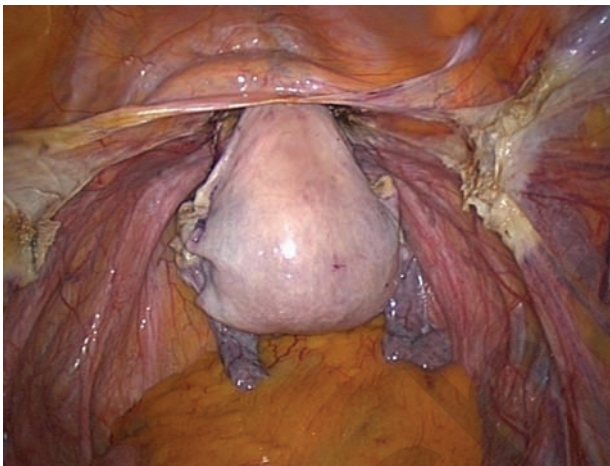


Figure 25.2 Laparoscopic subtotal hysterectomy: the uterus and adnexa have been freed

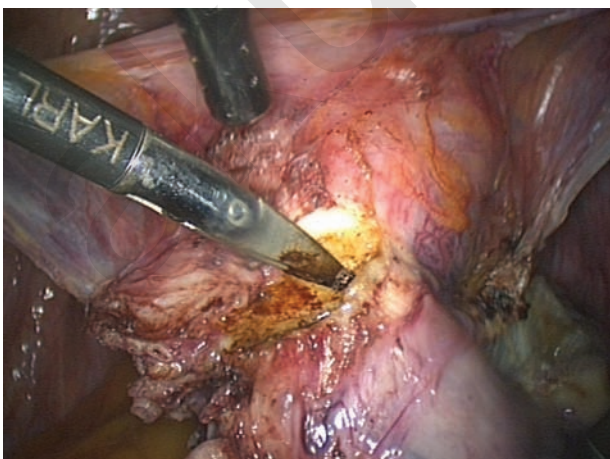


Figure 25.3 Laparoscopic subtotal hysterectomy: section of the cervix

vulsellum holds the posterior lip of the cervix to provide exposure (Figure 25.7). In order to avoid vaginal mesh erosion and to ensure strong fixation, the mesh should be fixed deep in the cervix. The posterior part of the cervix is therefore incised vertically to a depth of approximately 1 cm (Figure 25.8). The polypropylene mesh (Figure 25.9) is then tightly stitched to the posterior part of the cervix with two absorbable stitches (Vicryl® 0 or 1) (Figures 25.10 and 25.11). The mesh is placed in the abdominal cavity. One or two round circumferential sutures are then placed high on the peritoneum in order to carry out a culdoplasty to treat associated enterocele (Figure 25.12).

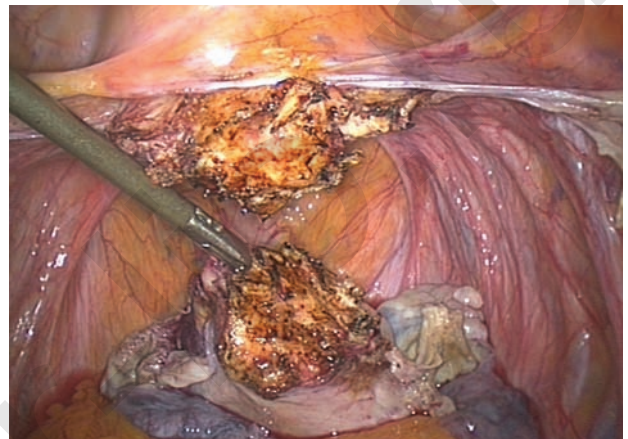


Figure 25.4 Laparoscopic subtotal hysterectomy: final view

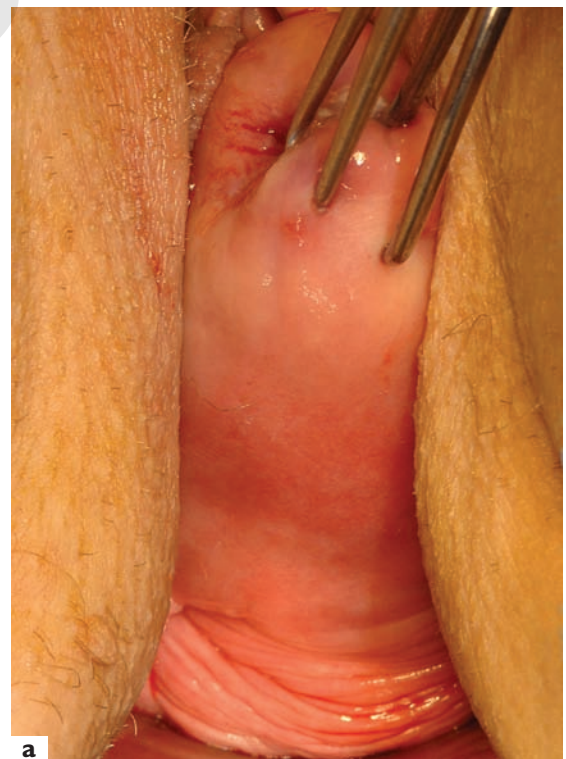
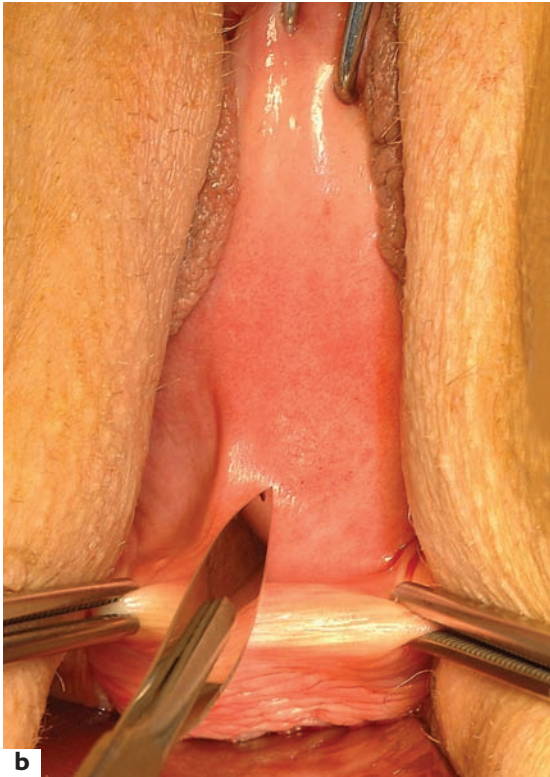


Figure 25.5 (a)–(c) Posterior colpotomy is performed along a sagittal vaginal incision over a length of 4–5 cm



b

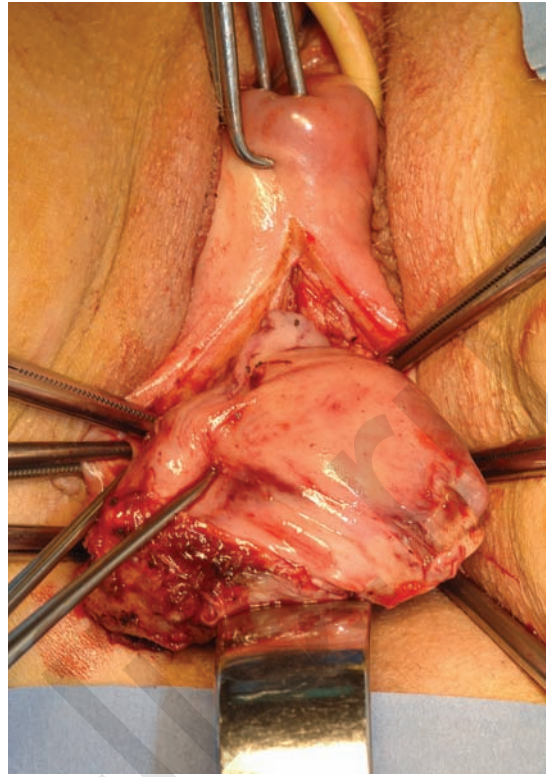
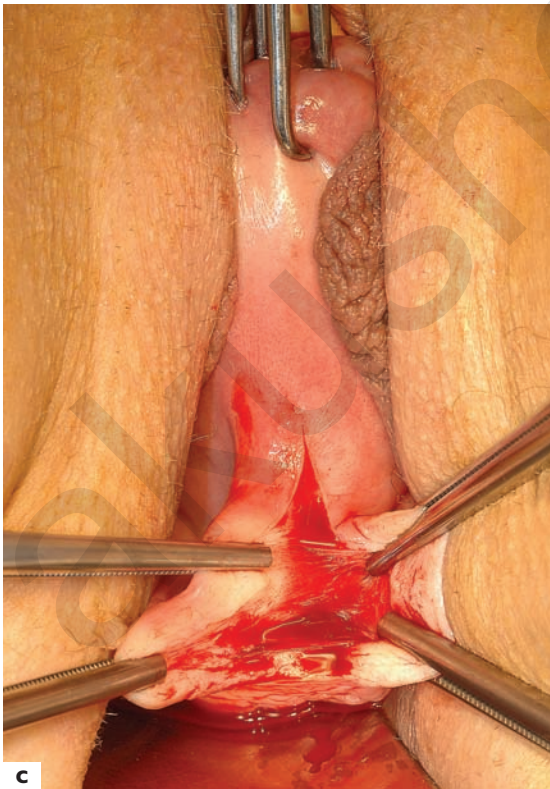


Figure 25.6 The uterus is removed through the colpotomy



c

Figure 25.5 continued

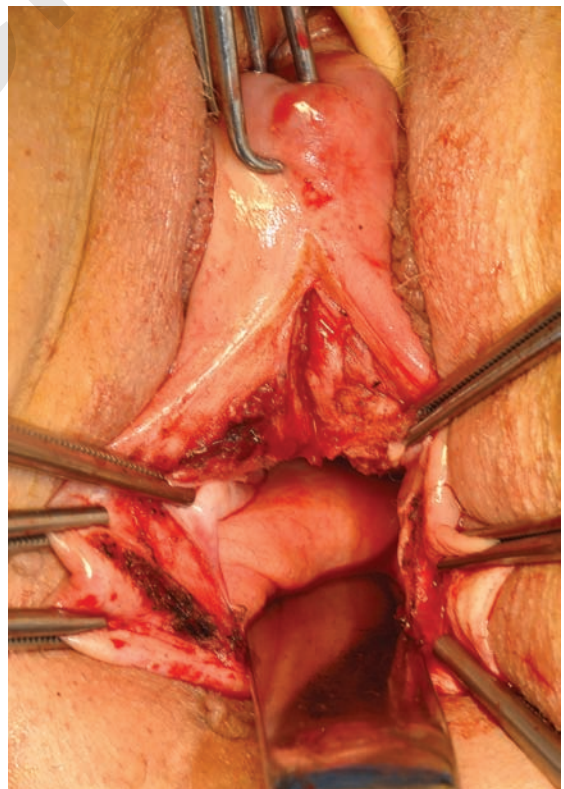


Figure 25.7 A right-angled retractor is placed on the posterior lip of the vagina. Other forceps hold the posterior lip of the cervix to provide exposure

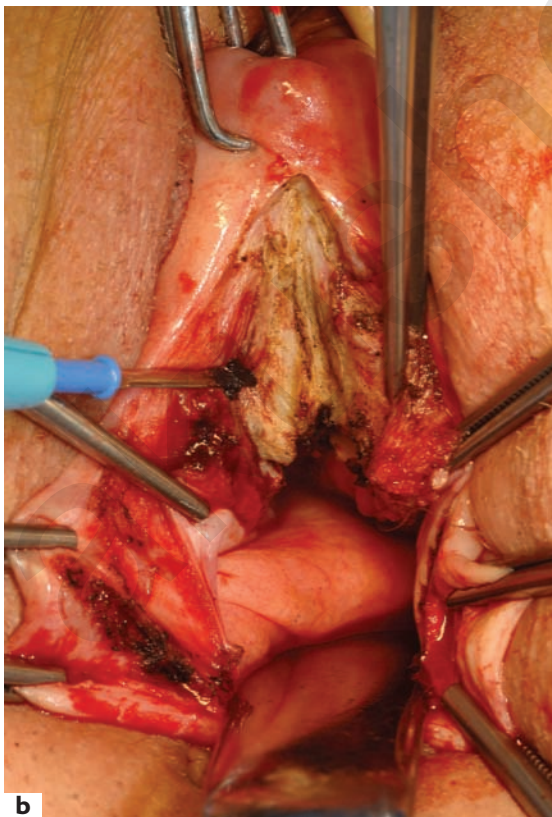
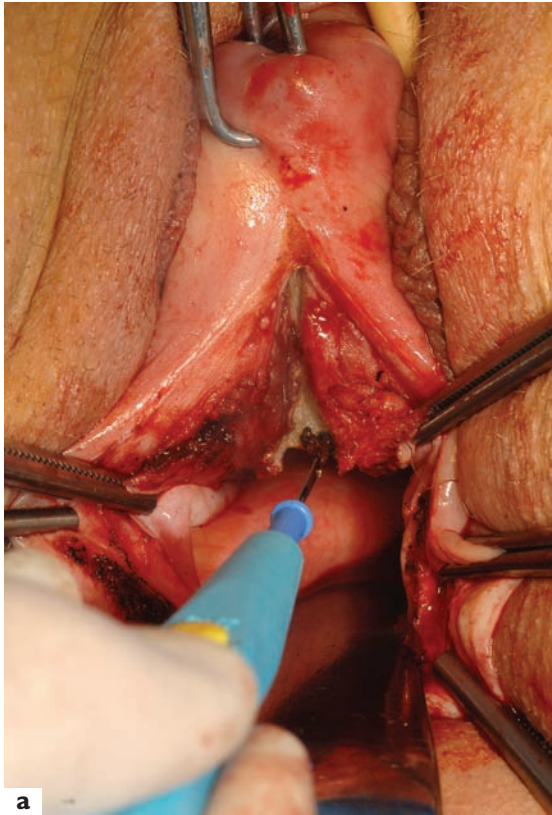


Figure 25.8 (a) and (b) Incision of the posterior part of the cervix

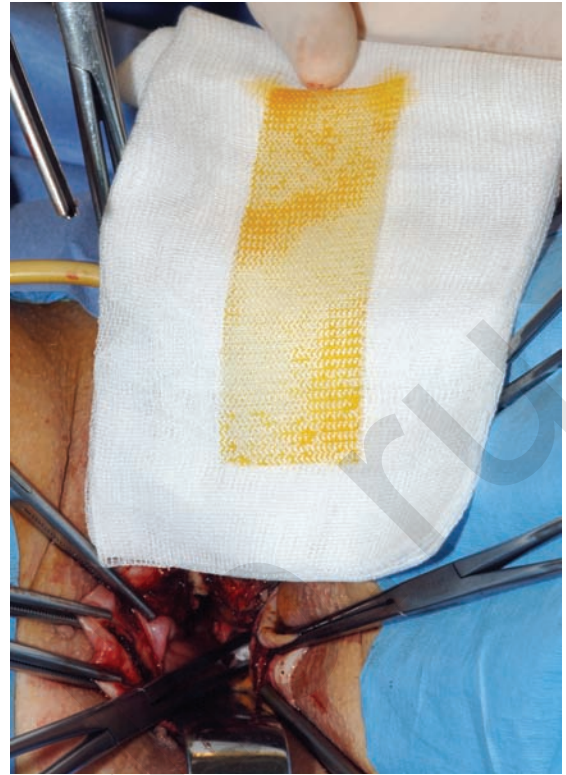

Figure 25.9 Polypropylene mesh

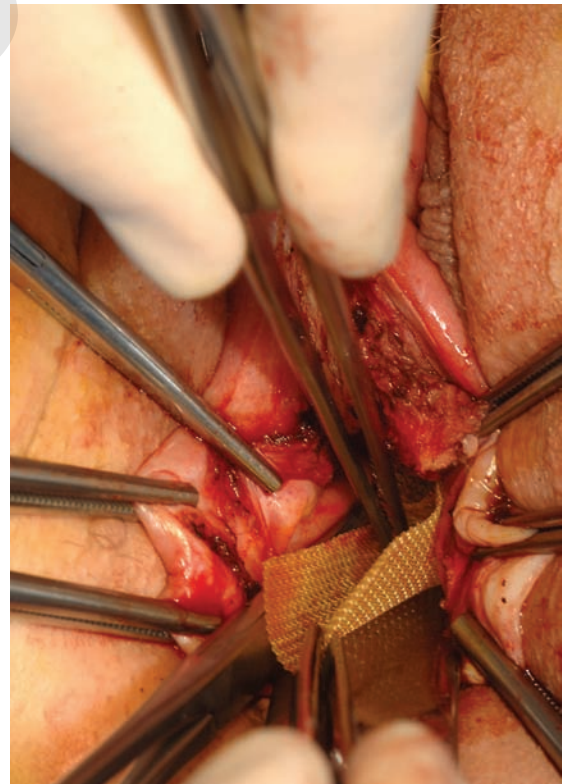
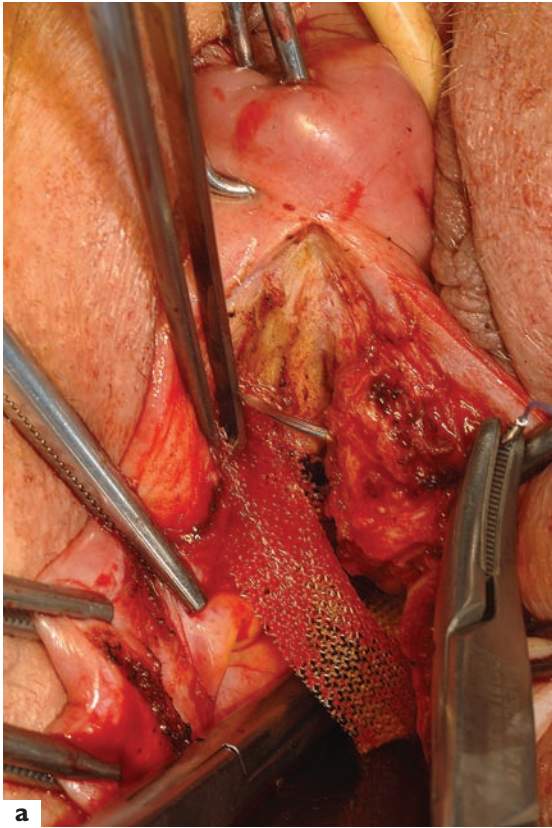


Figure 25.10 Introduction of the polypropylene mesh into the abdominal cavity



The highest suture brings both uterosacral ligaments to the medial line to prevent any future recurrence. The culdotomy is then closed. Separate points or a running suture are applied to both vaginal lips (Figure 25.13).

Third step: laparoscopic dissection of the presacral tissue

The patient, still in the Trendelenburg position, is placed slightly in left lateral decubitus. After careful coagulation of the peritoneum (Figure 25.14), an opening is made with scissors (Figure 25.15) from the lumbosacral joint towards the cervix. The prevertebral space is opened. The presacral peritoneum is grasped with two atraumatic forceps on the right lateral side of the rectum. The right ureter is situated 1–2 cm from the presacral peritoneal incision and is systematically checked over the length of this incision. The sigmoid is pushed laterally, and careful dissection and hemostasis of the presacral tissue provide exposure of the anterior common vertebral ligament. Coagulation and section of the medial sacral artery and vein are sometimes necessary. The most prominent point of the space is the lumbosacral joint (the mesh must be fixed to either the anterior wall of the corpus of the first sacral vertebra or the fifth lumbar vertebra).

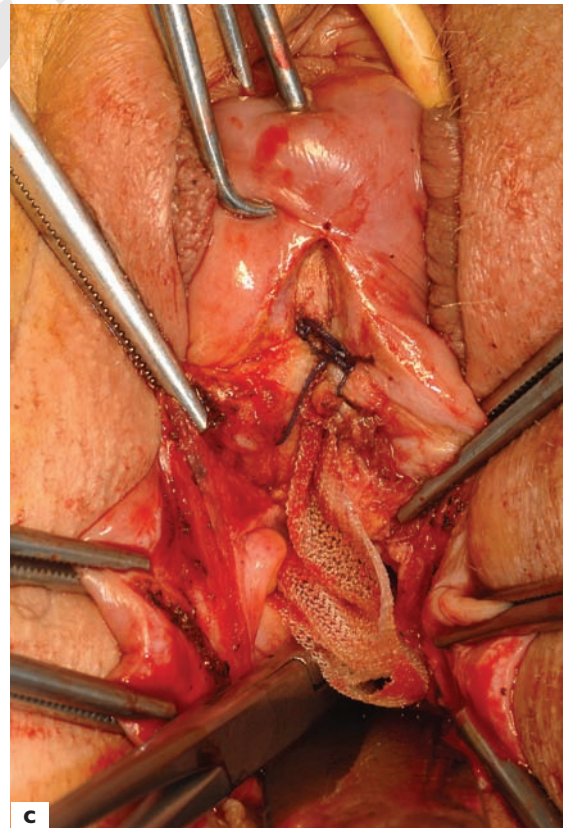
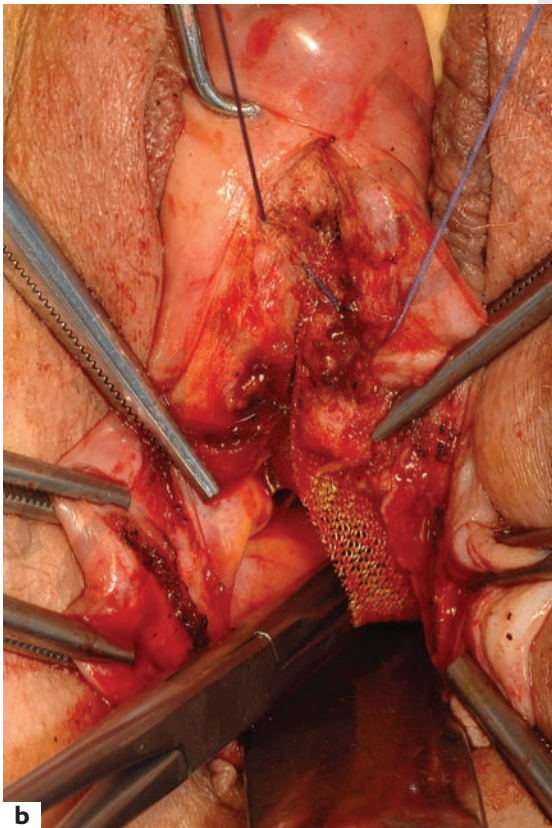
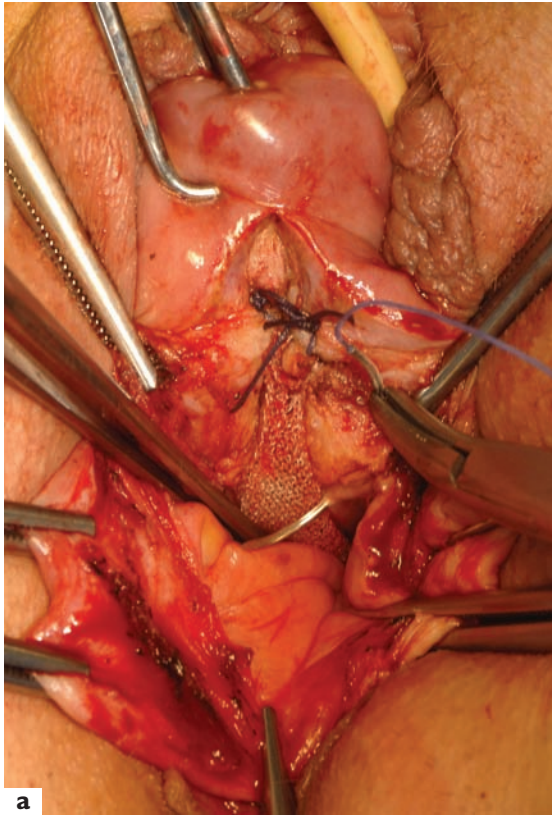
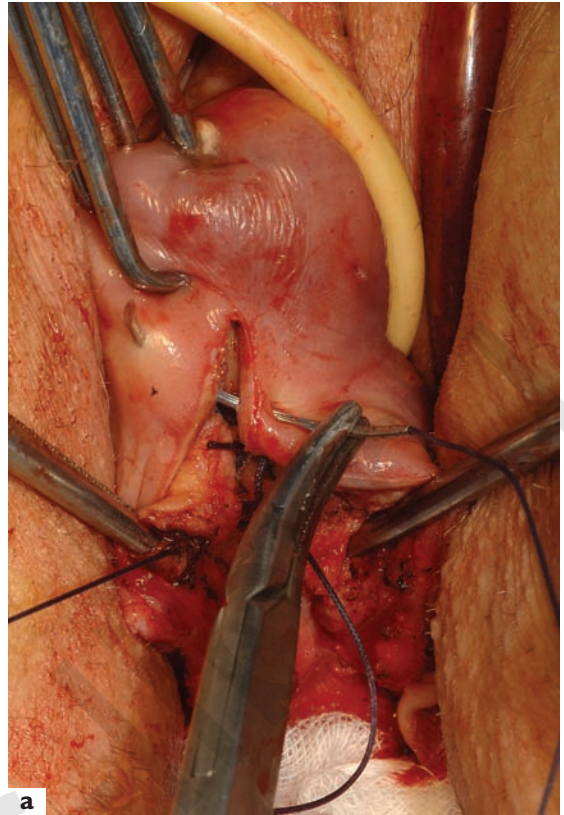


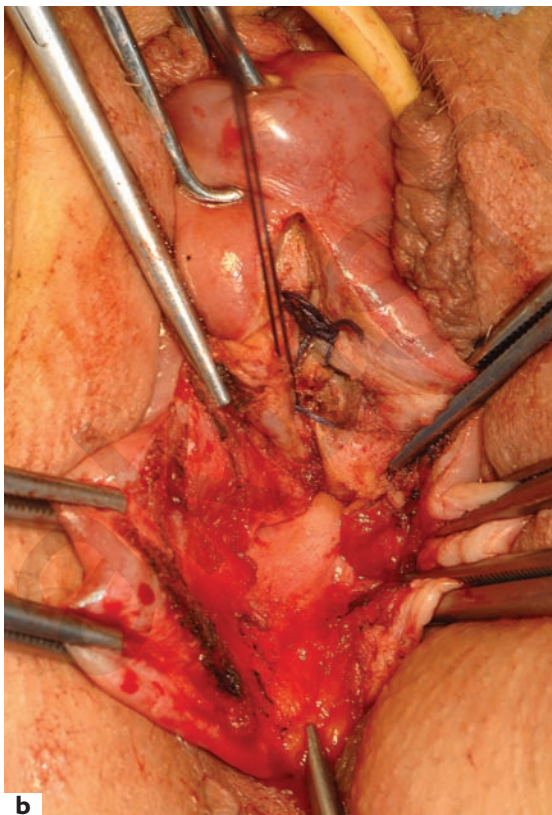
Figure 25.11 (a)–(c) The polypropylene mesh is sutured inside the cervical incision



a

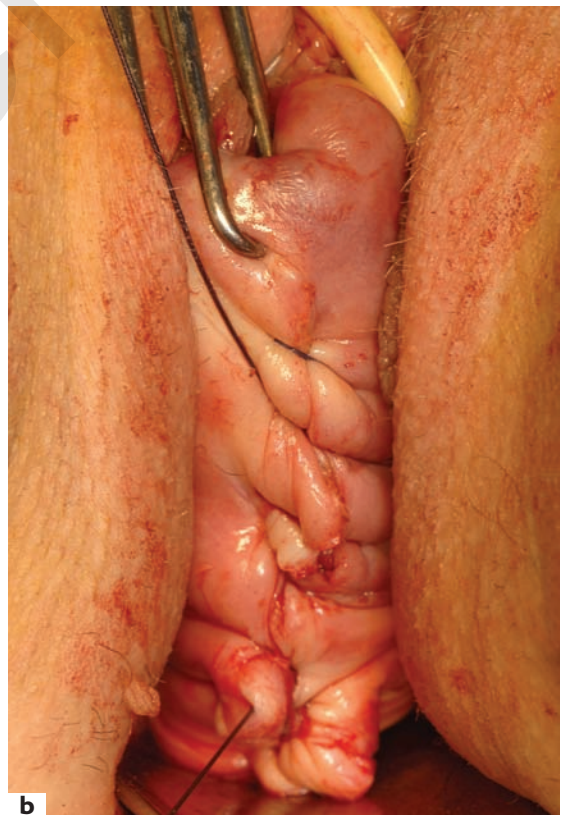


a



b

Figure 25.12 (a) and (b) One or two round circumferential sutures are placed high on the peritoneum in order to carry out a culdoplasty to treat associated enterocele



b

Figure 25.13 (a) and (b) The vagina is closed by a running suture

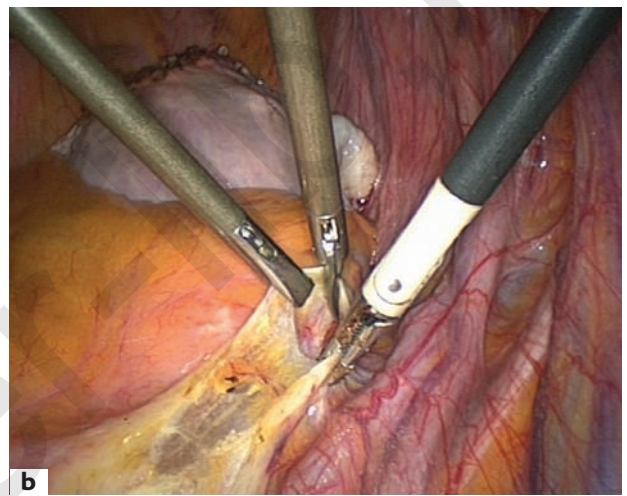
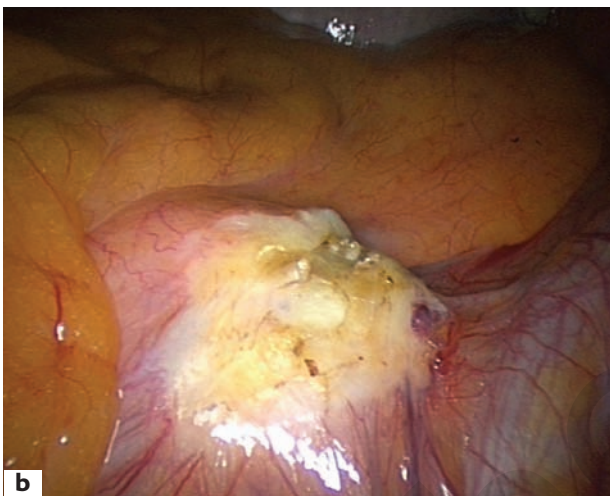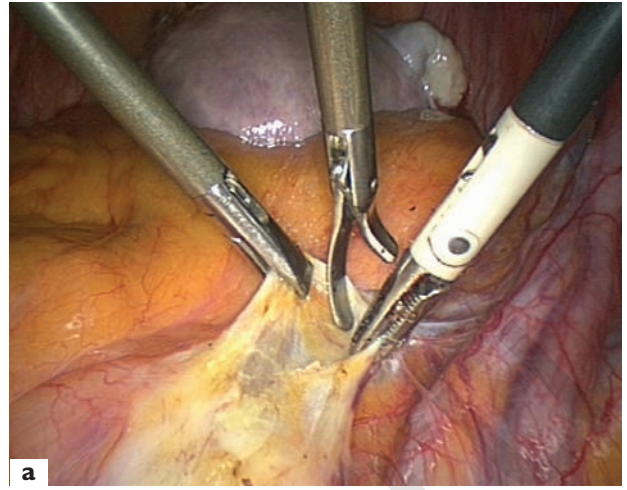
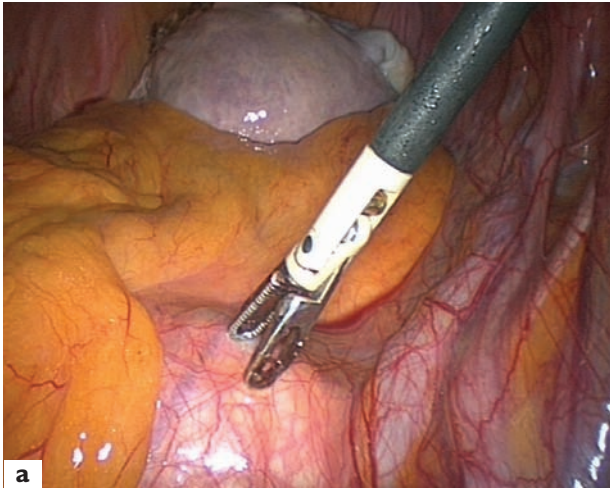


Figure 25.14 (a) and (b) Coagulation and opening of the presacral peritoneum

Fourth step: sacral fixation of the polypropylene mesh

Two grasping forceps hold the edges of the parietal posterior peritoneum to give access to the anterior wall of the first sacral vertebra. The Origin Tacker is introduced through the medial suprapubic trocar. This tacking device utilizes a helical coil of 3.9 mm in diameter to achieve secure fixation to the vertebra. Forceps grasp the prosthesis (Figure 25.16), which is then tightened until the cervix or the uterus recovers its anatomic position. The tip of the Tacker is placed on the mesh, in front of the anterior wall of the first sacral vertebra, and several tacks are inserted through the mesh into the periosteum of the vertebra and the common vertebral ligament (Figure 25.17). Excess mesh is cut away and removed (Figure 25.18).

Fifth step: reperitonealization

Both folds of the peritoneum are sutured with resorbable material (Figure 25.19) or stapled with endoscopic staples.

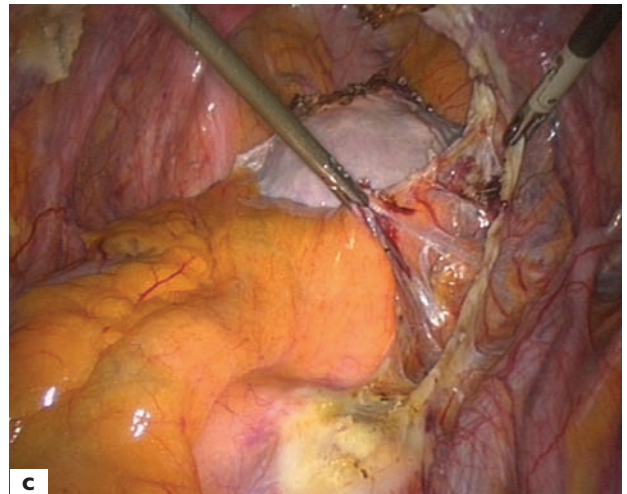


Figure 25.15 (a)–(c) Opening of the peritoneum from the lumbosacral joint towards the cervix

Careful washing of the peritoneal cavity is then performed and an antiseptic solution of Rifocine® (Rifamycin; Merrel Dow, Kansas City, MO) is instilled into the pelvis. Finally, a Douglas catheter is inserted through one of the

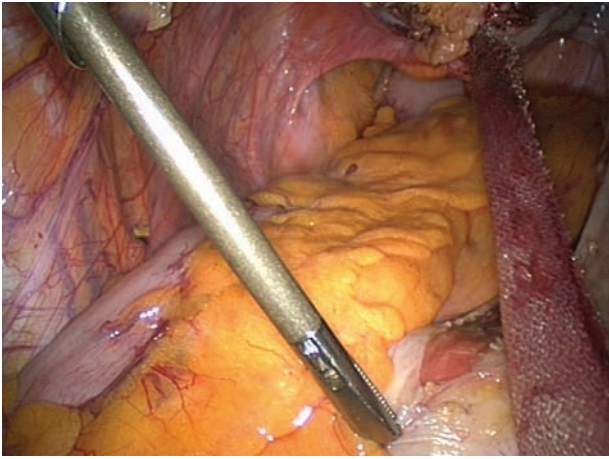


Figure 25.16 Grasping of the polypropylene mesh with forceps

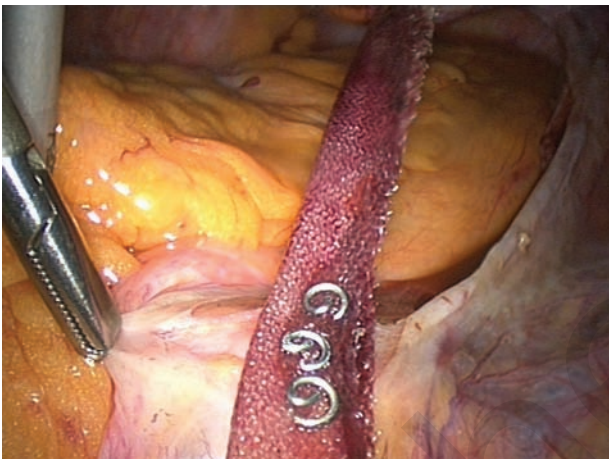
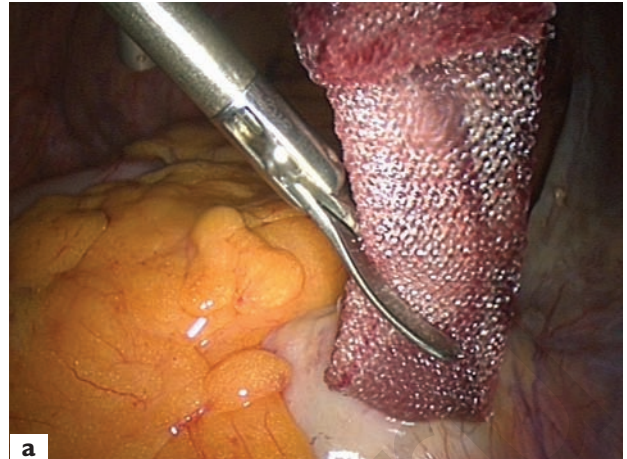


Figure 25.17 The tip of the Tacker® is placed on the mesh, in front of the anterior wall of the first sacral vertebra, and several tacks are inserted through the mesh into the periosteum of the vertebra and the common vertebral ligament

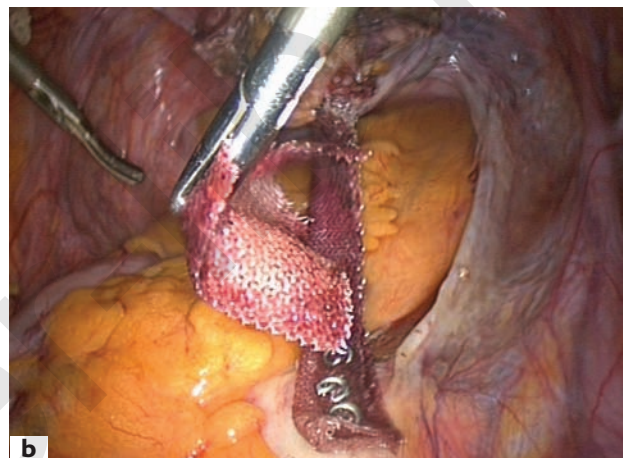
suprapubic trocars. It is clamped for 2–4 h and removed the day after surgery.

Vaginal vault sacrofixation

Fixation of the mesh to the vagina can be performed either vaginally or laparoscopically using the tacking technique, but the vaginal route may be preferred because it allows quick repair of enteroceles. Using the vaginal route, the vagina is opened along its posterior wall with a 4–5-cm incision, perpendicular to the vaginal vault. Dissection is performed to enter the abdominal cavity. The enterocele is then dissected and excess peritoneum is cut away. The polypropylene mesh is fixed to the vaginal vault through the vaginal incision by two or three absorbable stitches.



a



b

Figure 25.18 (a) and (b) Excess mesh is cut away and removed

The mesh is introduced into the peritoneal cavity. The peritoneum is then closed with two high, continuous, round circumferential sutures to close the pouch of Douglas (Douglasorrhaphy). The vagina is finally closed.

It is important to note that none of the patients underwent a concomitant Burch procedure, or a procedure using tension-free vaginal tape (TVT) or transobturator tape (TOT).

Recently, laparoscopic vaginal vault suspension was carried out by a purely laparoscopic approach. With this technique, the ureters are identified and, if an enterocele defect is observed, the enterocele sac is excised, after a rectal probe is inserted to identify the rectal wall. A sponge is then placed in the vagina (Figure 25.20) and the bladder is dissected from the vagina (Figure 25.21). Using a polypropylene mesh (Figure 25.22), the surgeon places an initial suture through the uterosacral ligaments (Figure 25.23), laterally, 2 cm from the ureters and on the anterior peritoneal leaf of the rectosigmoid (Douglasorrhaphy)

(Figure 25.24). This first suture ensures closure of the enterocele, by attaching it to the posterior part of the vaginal apex (Figure 25.25). No gap is left between the vagina and the uterosacral ligaments. The anterior part of

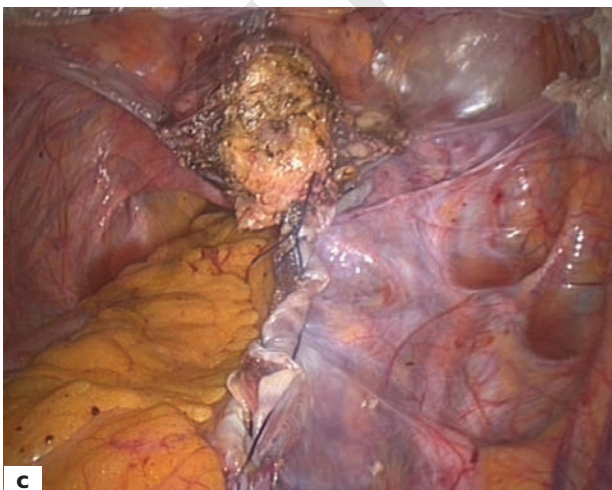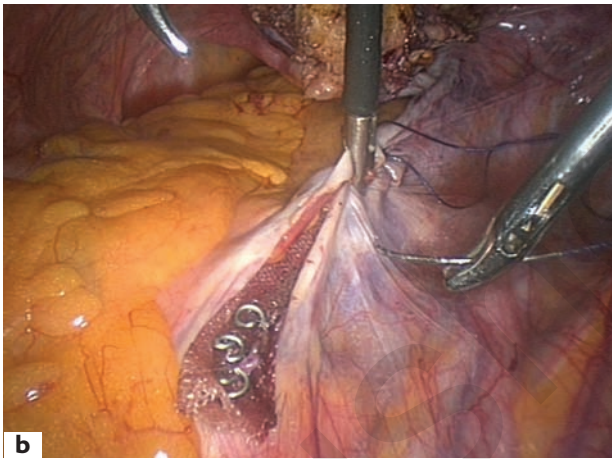
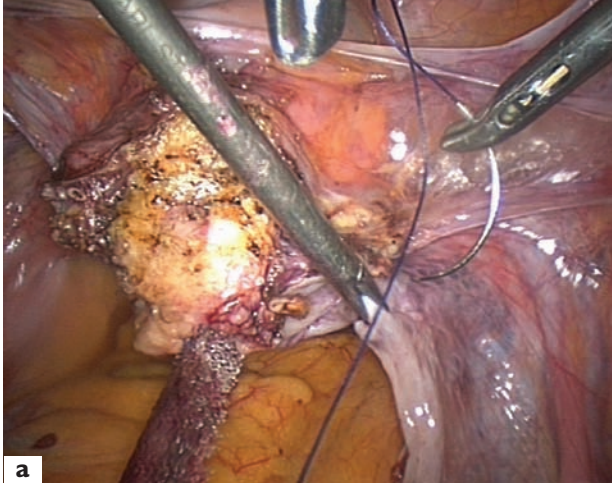


Figure 25.19 (a)–(c) The peritoneum is sutured with resorbable stitches

the mesh (U mesh) is then fixed to the anterior part of the vaginal apex (Figure 25.26). The mesh is subsequently fixed to the promontorium (Figure 25.27) and covered with peritoneum closure (Figure 25.28) using a running Vicryl suture. On postoperative day 3, radiography of the sacrum (Figure 25.29) confirms the correct position of the coils.

COMPLICATIONS

We did not observe any intraoperative complications. No bleeding occurred during the procedure among the 146 patients in this study. There was one immediate postoperative complication (Table 25.2). One patient complained of difficulty in moving her left foot straight after leaving the operating room. It was associated with severe pain in the left buttock and in the upper part of the

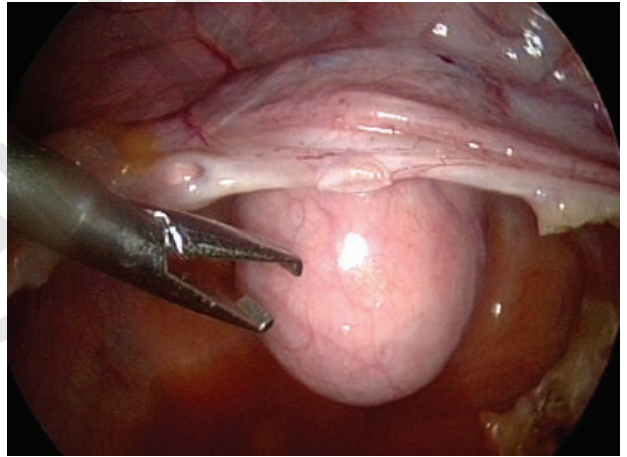


Figure 25.20 Vaginal vault sacrofixation: a sponge is placed in the vagina

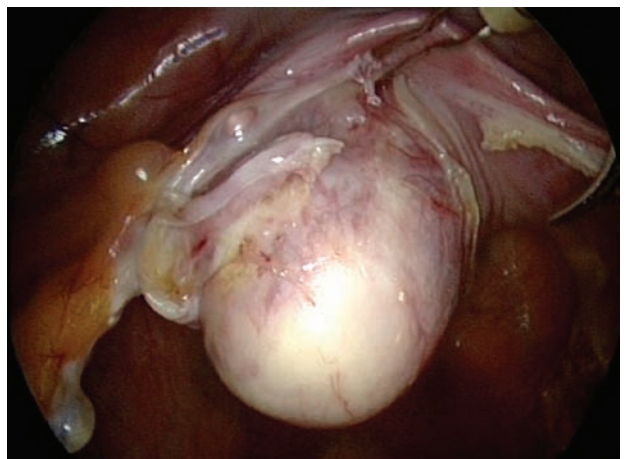


Figure 25.21 The bladder is dissected from the vagina

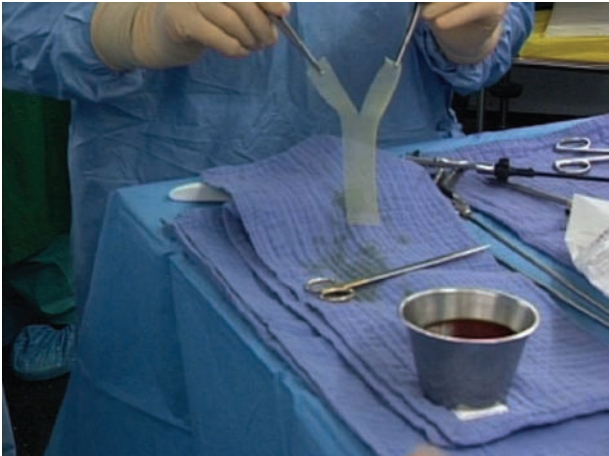


Figure 25.22 Polypropylene mesh

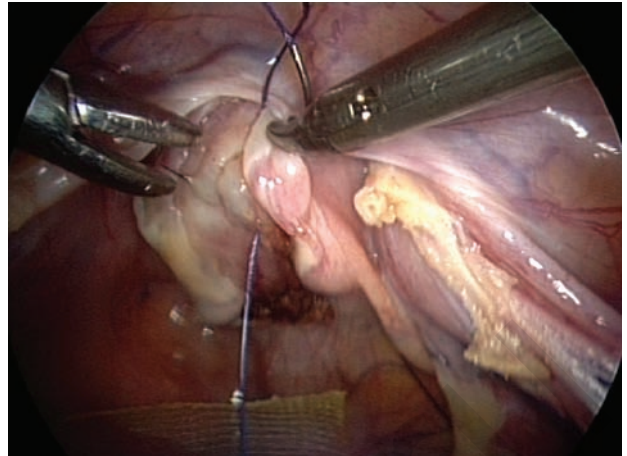


Figure 25.24 Douglasorrhaphy

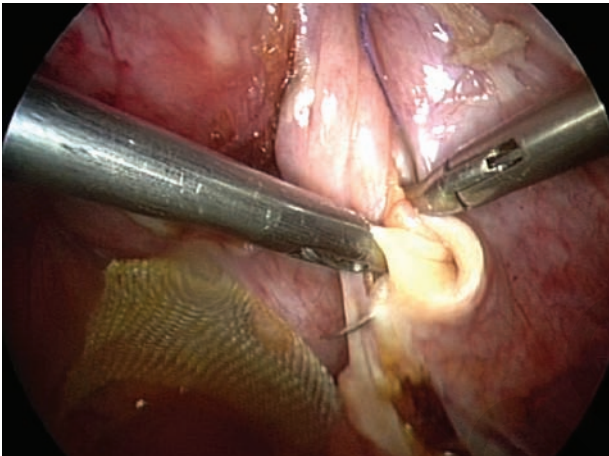


Figure 25.23 Suture of the uterosacral ligaments

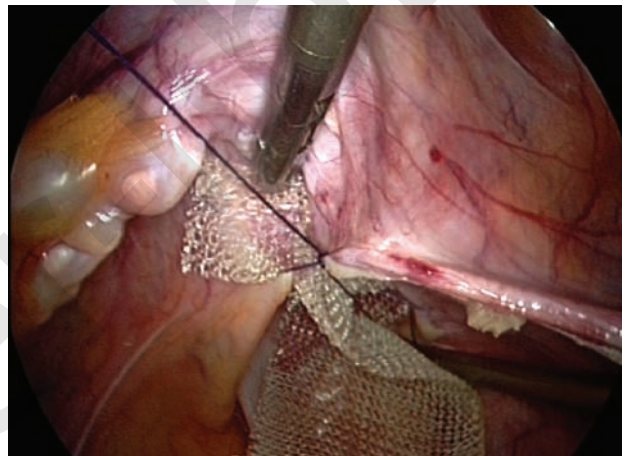


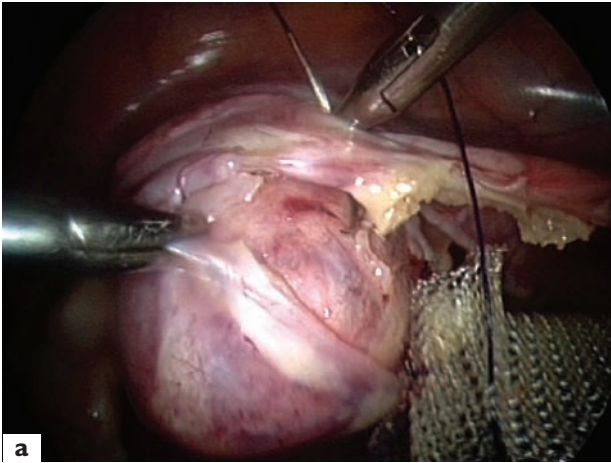
Figure 25.25 No gap is left between the vagina and uterosacral ligaments

left thigh. Electromyography concluded that the fifth left lumbar neural root or one of the first left sacral roots was affected. Radiography of the sacrum showed that one coil was too laterally placed on the left, near the neural root (Figure 25.30a). After magnetic resonance imaging (MRI) (Figure 25.30b) confirmed that one spring had been placed in the foramen intervertebrale of the second root, we decided to perform a laparotomy, and the spring was carefully removed. The patient made a rapid recovery and now has only a slight mobility defect of her left foot.

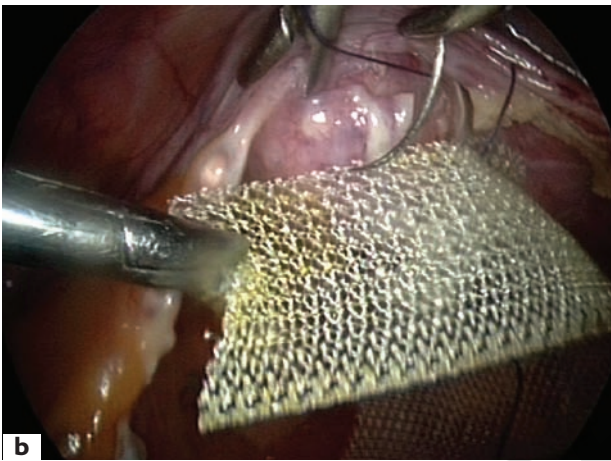
Postoperative discomfort was similar to that observed after any straightforward laparoscopy. Bowel function resumed within 24 h and the patients were able to leave hospital, on average, on day 4 postoperatively. Sexual intercourse was allowed 3 weeks after surgery. Patients were reviewed every 6 months. The average follow-up is now 1–10 years.

Two patients experienced spondylitis, 9 and 12 months postoperatively. The first underwent laparotomy with disc resection and bone transplantation. The second underwent a laparoscopic procedure to remove the mesh and coils from the presacral space. Both patients recovered well without sequelae.

Two cases of mesh erosion with significant symptoms (vaginal discharge, postcoital bleeding) were described, both after vaginal vault suspension. In the first case, resection was carried out to remove the lower part of the mesh, resulting in a recurrence of vaginal vault prolapse, which was treated by laparoscopy with extravaginal suture of the vault. In the second case (Figure 25.31), vaginal examination revealed mesh erosion and the coils were visible. Laparoscopic and vaginal resection of the eroded mesh were carried out and the residual mesh was laparoscopically fixed to the vaginal apex, after 3 cm² of vaginal apex had been removed.



a



b

Figure 25.26 (a) and (b) The anterior part of the mesh is fixed to the anterior part of the vagina

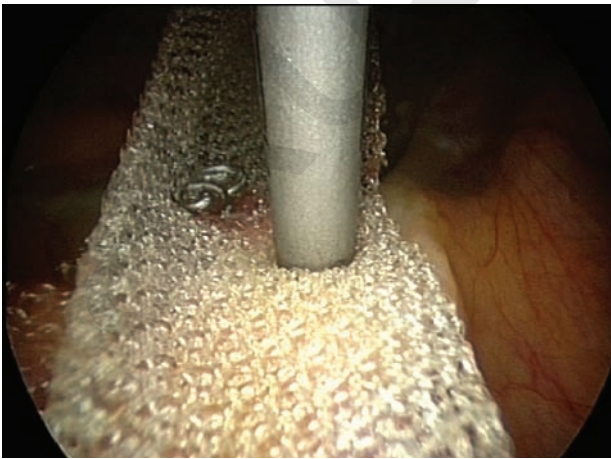


Figure 25.27 The mesh is fixed to the promontorium

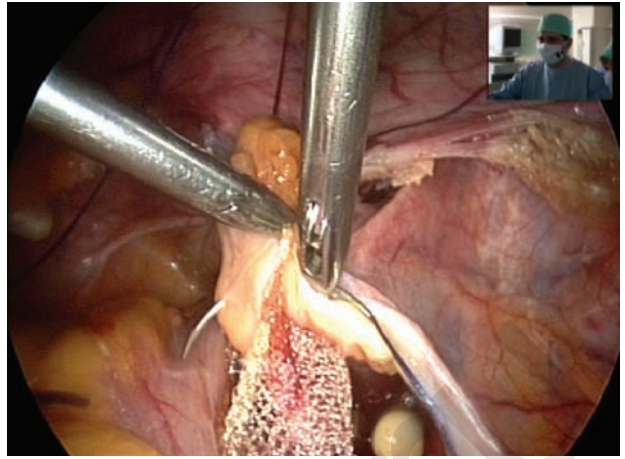


Figure 25.28 The mesh is covered with peritoneum

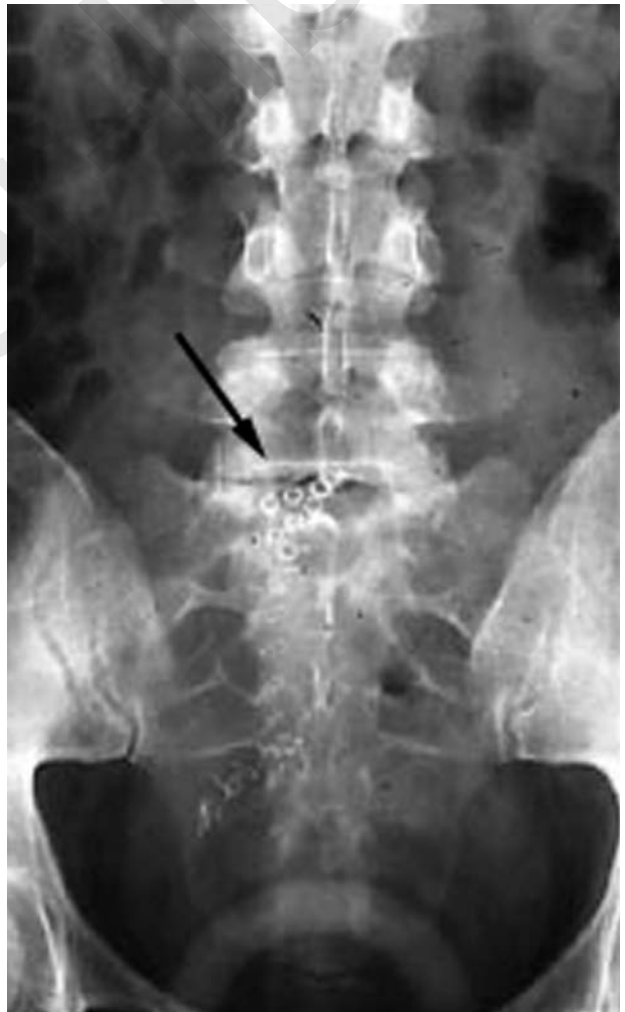

Figure 25.29 Radiography of the pelvis on postoperative day 3 checks the correct position of the coil (arrow) at the level of the first sacral vertebra

Table 25.2 Complications and recurrence after laparoscopic sacrofixation ($n = 146$)

Complications $n = 5$ (3.5%)

compression of sciatic nerve (wrong insertion): $n = 1$

spondylodiscitis (9 and 12 months postoperatively) (1.5%): $n = 2$

mesh erosion (posthysterectomy colpocele) (1.5%): $n = 2$

Recurrence $n = 2$ (1.5%)

defective application to the cervix: $n = 1$

enterocele after vaginal vault prolapse without enterocele repair: $n = 1$

We observed two cases of recurrence. The first case was observed 8 months after surgery in one patient from group II. The patient underwent another laparoscopy which showed that the mesh was well fixed to the sacrum but was detached from the cervix. The mesh was separated from the covering peritoneum and then fixed to the cervix

with the help of two non-absorbable sutures. The second case was due to incomplete surgery. Indeed, this patient, who had undergone fixation of the vaginal vault, developed a severe enterocele several months later. She underwent surgery a second time, and laparoscopy showed that the vaginal vault was well fixed to the mesh but an enterocele had developed below the point of fixation of the mesh to the vagina. Vaginal surgery of the enterocele was easily carried out. There has been no recurrence in more than 2 years of follow-up.

COMMENTS

The goal of pelvic reconstruction is to restore normal anatomy, maintain or restore normal bladder and bowel function and provide a vagina of normal length to ensure pain-free coitus²⁹. A well supported vagina lies on the rectum and levator plate with its axis directed towards the hollow of the sacrum and its apex at or above the ischial spines. It is suspended from the sacrum by the paracolpium. Vaginography³⁰ and contemporary MRI demonstrate this anatomic fact. Vaginal eversion and

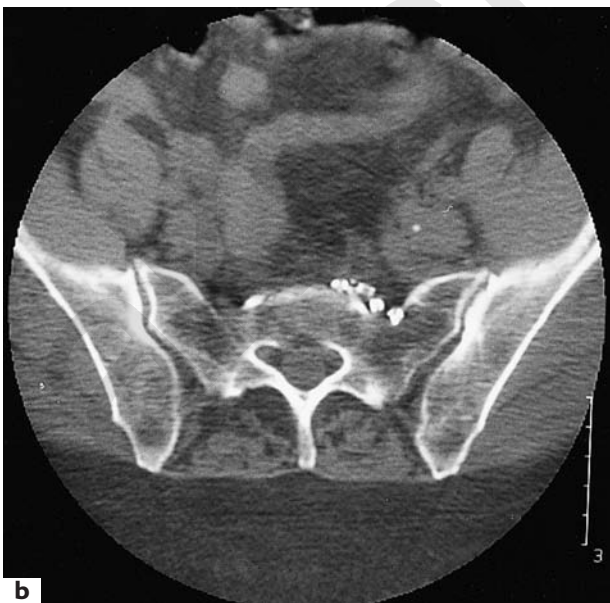
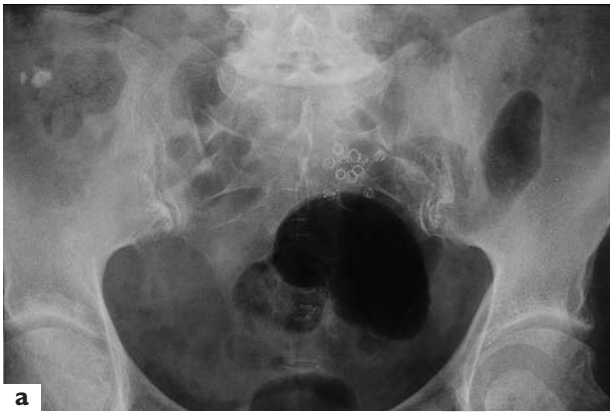

Figure 25.30 (a) Radiography and (b) magnetic resonance imaging confirm the presence of a coil in the foramen intervertebrale of the second sacral root

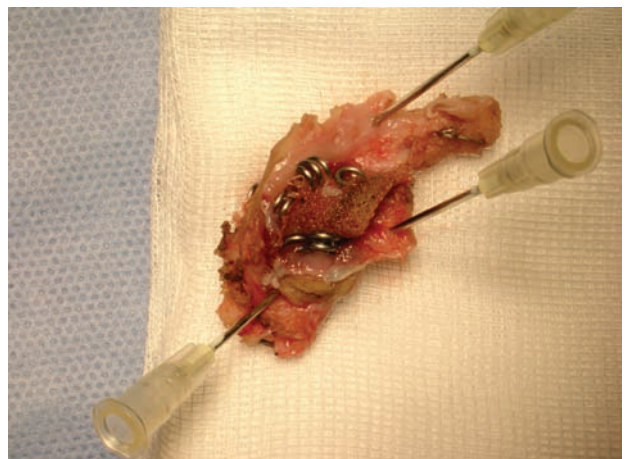


Figure 25.31 Vaginal erosion of the mesh and coils after sacrofixation of the vaginal vault

uterine prolapse are the result of disruption of the upper paracolpium, which includes the fibromuscular tissue of the cardinal and uterosacral ligaments²⁰. Many different corrective procedures use this anatomic principle, and anchor the vaginal apex or cervix to the available supporting tissue at this level, including the sacrospinal ligaments, cliococcygeus or coccygeus fascia, uterosacral ligaments or sacrum. Many authors have advocated vaginal surgery as the only approach to this type of pathology. The main problem is that, in the case of severe attenuation of both uterosacral ligaments, which is frequent in vaginal vault prolapse, vaginal repair of cystocele and rectocele often fails³¹. The technique, first proposed by Amreich³² and later modified by Richter and Albrich¹, involves fixation of the vaginal vault to the sacrospinal ligament. One of the disadvantages of sacrospinal ligament fixation is that the marked vaginal retroversion subsequent to this type of fixation may predispose patients to recurrent support defects in the anterior vagina, resulting in cystocele, urethral hypermobility or both^{33,34}. The majority of cases were asymptomatic, however, and only a small number required a subsequent surgical procedure (5.5%).

A second disadvantage of sacrospinal ligament fixation is the possible neuropathy produced by vaginal dissection³⁵. Such neuropathy may have an effect on subsequent muscle strength and the integrity of muscular tissue support. It can also be related to dysfunction of the lower urinary tract, and explain the higher incidence of incontinence after sacrospinal ligament fixation than after sacrofixation³⁶. In a prospective study comparing the vaginal versus the abdominal approach, Benson *et al.*³⁶ demonstrated that the abdominal approach is more effective in treating uterovaginal prolapse, with the probability for an optimal surgical outcome twice as high with an abdominal operation, and the probability for an unsatisfactory surgical outcome twice as high with a vaginal operation. Among the transabdominal approaches described so far, the most frequently published is fixation of the vaginal vault to the midsacrum or sacral promontory using artificial material.

Sacral colpopexy has a high success rate (85–99%) in vault prolapse repair and does not shorten the vagina^{5,6,8,17,22,23,25,37,38}. Laparoscopic approaches to sacrofixation^{12,20,39} have been described. The advantage of sacrofixation is that it ensures vaginal length with a larger-caliber, normal horizontal vaginal axis and a more anatomic repair³⁶. Sacral colpopexy is performed to correct severe vaginal vault eversion by replacing the upper paracolpium with synthetic mesh, which results in stronger fixation than does a simple culdoplasty²⁰. According to Ameline and Huguier⁴⁰, the only physiological suspension involves placement of suture material into the ligamentous and periosteal fibrous connective tissue in the midline of the anterior sacrum. Although sacral segments 3 and 4 are anatomically ideal, control of the tip of the needle deep in the hollow of the sacrum is difficult, and laceration of presacral veins is an ever-present

risk, leading to life-threatening hemorrhages which are extremely difficult to control⁴¹. Fixation to the first vertebra (beyond the sacrolumbar joint) or the lower part of the fifth lumbar vertebra restores to the genital tube its triple angulation – postero-ascending vaginal obliquity, antelexion of the cervix over the uterine corpus and anteversion – and thus correctly restores the anatomy²². Like Hoff *et al.*⁴², we believe that, in the great majority of cases, anterior colporrhaphy with sacrofixation is not needed to treat associated cystocele, unless the cystocele is of degree 3 or more. Nevertheless, we believe that posterior colporrhaphy can be helpful in treating even a huge rectocele completely. We performed posterior colporrhaphy only in cases where the rectocele was so large that simple fixation of the cervix or vagina did not yield a sufficient reduction.

Like Smith⁶, we believe that osseous anchorage of the prosthesis is stronger than sacrospinal ligament stitching (Tables 25.3 and 25.4). The tacking technique described here allows fixation of the mesh to the vertebra with the same reliability. It is less invasive (no penetration of the bones but only the periosteum), and thus reduces the risk of bone infection. It enables us to avoid difficulties related to a prevertebral suture. The most common complications of sacropexy are intraoperative bleeding and a post-operative temperature. Spondylodiscitis and bleeding due to presacral vessel lesions are rarely observed^{41,43,44}. The mesh should be reperitonealized to prevent bowel adhesions^{45,46}. Undue tension must be avoided to prevent pain⁵.

We observed two prolapse recurrences among the 146 patients who underwent sacrofixation (1.5%) and three cases of recurrence of cystocele, requiring anterior colporrhaphy. It should be noted that, in all cases, the vaginal vault maintained its correct position without prolapse. This rate of recurrent anterior defects led us to repair the anterior compartment either laparoscopically or vaginally at the time of promontofixation in cases of associated cystocele of degree 3 or more.

In contrast to sacrospinal fixation, because of its more anatomic repair, sacrofixation does not favor the development of secondary cystoceles, does not cause vaginal shortening and, providing that particular care is taken to insert the springs into the central part of the body of the vertebra, is without risk for nerves if the prevertebral area dissection is easy and well performed. In overweight women, in whom there is a wide area (with fatty tissue) between the prevertebral peritoneum and the vertebral bone itself, we believe that intraoperative X-rays are indicated in order to determine the exact site of coil insertion.

As stressed by Vancaillie⁴⁷, sacrocolpopexy remains a potentially high-morbidity procedure, with invasion of the presacral space. Nevertheless, recent publications reported a low rate of complications; the most frequent complication in these series was vaginal mesh erosion, which

Table 25.3 Advantages of osseous anchorage (Tacker®) versus stitching

Osseous anchorage of the prosthesis is stronger than sacrospinal stitching
 Lower risk of bleeding than with presacral stitching

Table 25.4 Advantages of laparoscopic subtotal hysterectomy-associated sacrofixation compared with laparoscopic hysterectomy-associated sacrofixation

<i>Vaginal vault</i>	<i>Cervix</i>
No strong tissue	Stronger tissue for prosthesis fixation
Mesh erosion risk	Absence of mesh erosion
Difficult visualization of uterosacral ligaments	By traction, better visualization of uterosacral ligaments
	Better repair during peritonealization

occurred at an incidence varying from 3 to 9%^{22–25}. In our series, no mesh erosion was observed in case of LASH-associated sacrofixation, probably because the mesh was fixed to the cervix well away from the vaginal fornix.

CONCLUSION

A combined (vaginal and laparoscopic) approach can be proposed in cases of uterine or vaginal vault prolapse. Fixation of the mesh by posterior colpotomy has several advantages. First, it allows easy use of non-absorbable sutures. Second, associated surgical procedures can be performed to resolve or prevent enterocele. Third, this technique provides the quickest surgical resolution compared to a purely laparoscopic approach. Laparoscopic fixation of the mesh to the sacrum with the help of springs (Origin Tacker system) also has several advantages. It avoids the risk of presacral vein laceration by the use of a needle. It provides quick and easy fixation of the mesh to the fifth lumbar vertebra or the first sacral vertebra. Finally, it gives an extremely good-quality fixation. For these reasons, we believe that this type of approach can provide a good alternative for the treatment of genital prolapse.

REFERENCES

- Richter K, Albrich W. Long-term results following fixation of the vagina on the sacrospinal ligament by the vaginal route (vaginal fixation sacrospinalis vaginalis). *Am J Obstet Gynecol* 1981; 141: 811–16
- Virtanen H, Hirvonen T, Mäkinen J, et al. Outcome of thirty patients who underwent repair of posthysterectomy prolapse of the vaginal vault with abdominal sacral colpopexy. *J Am Coll Surg* 1994; 178: 283–7
- Birnboum SJ. Rational therapy for the prolapsed vagina. *Am J Obstet Gynecol* 1973; 115: 411–15
- Grundsell H, Lorrson G. Operative management of vaginal vault prolapse following hysterectomy. *Br J Obstet Gynaecol* 1984; 91: 808–11
- Drutz HP, Cha LS. Massive genital and vaginal vault prolapse treated by abdominal vaginal sacropexy with the use of Marlex Mesh. Review of the literature. *Am J Obstet Gynecol* 1987; 156: 387–92
- Smith MR. Colposacropexy: an alternative technique. *Am J Obstet Gynecol* 1997; 176: 1374–5
- Snyder TE, Krantz KE, Litt D. Abdominal retroperitoneal sacral colpopexy for the correction of vaginal prolapse. *Obstet Gynecol* 1991; 77: 944–9
- Addison WA, Timmons MC, Wall LL, et al. Failed abdominal sacral colpopexy: observations and recommendations. *Obstet Gynecol* 1989; 74: 480–2
- Rust JA, Botte JM, Howlett RJ. Prolapse of the vaginal vault. Improved techniques for the management of the abdominal approach or vaginal approach. *Am J Obstet Gynecol* 1976; 125: 768–73
- Creighton SM, Stanton SL. The surgical management of vaginal vault prolapse. *Br J Obstet Gynaecol* 1991; 98: 1150–4
- Timmons MC, Addison WA, Addison SB, et al. Abdominal sacral colpopexy in 163 women with posthysterectomy vaginal vault prolapse and enterocele. *J Reprod Med* 1992; 37: 323–7
- Smets M, Donnez J. Mackar staple fixation for uterus prolapse. *Gynecol Endosc* 1995; 4: 18–19
- Maloney JC, Dunton CJ, Smith K. Repair of vaginal vault prolapse with abdominal sacropexy. *J Reprod Med* 1990; 35: 6–10
- Hendee AE, Berry CM. Abdominal sacropexy for vaginal vault prolapse. *Clin Obstet Gynecol* 1981; 24: 1217–26

15. Kauppila O, Punnonen R, Teisala K. Operative technique for the repair of posthysterectomy vaginal prolapse. *Ann Chir Gynecol* 1986; 75: 242–4
16. Lansman HH. Posthysterectomy vault prolapse: sacral colpopexy with dura mater graft. *Obstet Gynecol* 1984; 63: 577–82
17. Grünberger W, Grünberger V, Wierani F. Pelvic promontory fixation of the vaginal vault in sixty-two patients with prolapse after hysterectomy. *J Am Coll Surg* 1994; 178: 69–72
18. Querleu D, Parmentier D, Debodinance P. Premiers essais de coelochirurgie dans le traitement du prolapsus génital et de l'incontinence urinaire d'effort. In Blanc B, Boubli L, Baudrant E, d'Ercale C, eds. *Les Troubles de la Statique Pelvienne*. Paris: Arnette Editions, 1993: 155
19. Cornier E, Madelenat P. Hystéropexie selon M. Kapanji: technique percoelioscopique et résultats préliminaires. *J Gynecol Obstet Biol Reprod* 1994; 23: 378–85
20. Ross JW. Techniques of laparoscopic repair of total vault eversion after hysterectomy. *J Am Assoc Gynecol Laparosc* 1997; 4: 173–83
21. Godin PA, Nisolle M, Smets M, et al. Combined vaginal and laparoscopic sacrofixation for genital prolapse using a tacking technique: a series of 45 cases. *Gynecol Endosc* 1999; 8: 277–85
22. Donnez J, Nisolle M, eds. *An Atlas of Operative Laparoscopy and Hysteroscopy*, 2nd edn. Carnforth, UK: Parthenon Publishing, 2001
23. Wattiez A, Mashiach R, Donoso M. Laparoscopic repair of vaginal vault prolapse. *Curr Opin Obstet Gynecol* 2003; 15: 315–19
25. Lin LL, Phelps JY, Liu CY. Laparoscopic vaginal vault suspension using uterosacral ligaments: a review of 133 cases. *J Minim Invasive Gynecol* 2005; 12: 216–20
25. Ross JW, Preston M. Laparoscopic sacrocolpopexy for severe vaginal vault prolapse: five-year outcome. *J Minim Invasive Gynecol* 2005; 12: 221–6
26. Kapanji M. Cure des prolapsus uro-génitaux par colpo-isthmo-cystopexie par bandelettes transversales et la Douglassoraphie ligamento-péritonéale étagée et croisée. *Ann Chir* 1967; 21: 32
27. Donnez J, Nisolle M. LASH: laparoscopic supracerical (subtotal) hysterectomy. *J Gynecol Surg* 1993; 9: 91–4
28. Donnez J, Nisolle M, Smets M, et al. Laparoscopic supracerical (subtotal) hysterectomy. A first series of 500 cases. *Gynecol Endosc* 1997; 6: 73–6
29. Shull BL, Capen CV, Riggs MW, et al. Preoperative and postoperative analysis of site-specific pelvic support defects in 81 women treated with sacrospinous ligament suspension and pelvic reconstruction. *Am J Obstet Gynecol* 1992; 166: 1764–71
30. Nichols DH, Milloy AS, Randall CL. Significance of restoration of normal vaginal depth and axis. *Obstet Gynecol* 1970; 36: 251–5
31. Symmonds RE, Williams TJ, Lee RA, et al. Posthysterectomy enterocele and vaginal vault prolapse. *Am J Obstet Gynecol* 1981; 140: 852–9
32. Amreich J. Actrologie und Operation des Schidenstrumpf-Prolapses. *Wien Klin Wodenschr* 1951; 63: 74
33. Cruikshank S, Cox D. Sacrospinous ligament fixation at the time of transvaginal hysterectomy. *Am J Obstet Gynecol* 1990; 162: 1611–19
34. Holley RL, Varner RE, Gleason BP, et al. Recurrent pelvic support defects after sacrospinous ligament fixation for vaginal vault prolapse. *J Am Coll Surg* 1995; 180: 444–80
35. Benson JT, McClellan E. The effect of vaginal dissection on the pubertal nerve. *Obstet Gynecol* 1993; 82: 387–9
36. Benson JT, Lucente V, McClellan E. Vaginal versus abdominal reconstructive surgery for the treatment of pelvic support defects: a prospective randomized study with long-term outcome evaluation. *Am J Obstet Gynecol* 1996; 175: 1418–22
37. Arthure HG, Savage D. Uterine prolapse and prolapse of the vagina treated by sacropexy. *J Obstet Gynaecol Br Commonw* 1957; 64: 355–60
38. Creighton S, Stanton S. The surgical management of vaginal prolapse. *Br J Obstet Gynaecol* 1991; 98: 1150–4
39. Nezhat CH, Nezhat F, Nezhat C. Laparoscopic sacral colpopexy for vaginal vault prolapse. *Obstet Gynecol* 1994; 84: 885–8
40. Ameline A, Huguier J. La suspension postérieure aux disques lombo-sacrés: technique de remplacement des ligaments utéro-sacrés par voie abdominale. *J Gynecol Obstet Biol Reprod* 1957; 56: 94
41. Sutton JP, Addison WA, Livengood CH, et al. Life-threatening hemorrhage complicating sacral colpopexy. *Am J Obstet Gynecol* 1981; 140: 836
42. Hoff S, Manelfe A, Portet R, et al. Promontofixation ou suspension par bandelettes transversales? Etude comparée de ces deux techniques dans le traitement des prolapsus génitaux. *Ann Chir* 1984; 38: 363
43. Baker KR, Beresford JM, Campbell C. Colposacropeky with Prolene mesh. *Obstet Gynecol* 1990; 171: 51–4
44. Addison WA, Livengood CH, Sutton GP, et al. Abdominal sacral colpopexy with Mercilene mesh in the retroperitoneal position in the management of posthysterectomy vaginal vault prolapse and enterocele. *Am J Obstet Gynecol* 1985; 15: 140–6
45. Soichet S. Surgical correction of total genital prolapse with retention of sexual function. *Obstet Gynecol* 1970; 36: 69–75
46. Todd JW. Mesh suspension for vaginal prolapse. *Int Surg* 1978; 63: 91–3
47. Vancaillie T. The role of laparoscopy in the management of pelvic floor relaxation. *J Am Assoc Gynecol Laparosc* 1997; 4: 147–8

akusher-lib.ru

Part 4
Oncology

akusherlib.ru

akusher-lib.ru

Borderline tumors of the ovary or epithelial ovarian tumors of borderline malignancy

J Donnez, A Münschke, P Jadoul, J Squifflet

INTRODUCTION

In 1929, Taylor¹ first described borderline tumors of the ovary (BOT) (Figure 26.1), also known as ‘epithelial ovarian tumors of low malignant potential’. These neoplasms occupy a position somewhere between benign and clearly malignant ovarian epithelial tumors. As a consequence of this histological peculiarity, they were recognized as a special clinical entity by the International Federation of Gynecologists and Obstetricians (FIGO) and included in its classification in 1971, with the World Health Organization (WHO) following 2 years later. When compared with the ‘classic’ malignant ovarian tumor, they are characterized by the following features²:

- Younger age at time of diagnosis (approximately 10–15 years earlier)
- Earlier stage when first diagnosed (almost 70% of all borderlines are discovered when still at stage I)
- Infrequent and late recurrence (recurrence possibly up to 20 years after surgery)
- Excellent long-term survival

EPIDEMIOLOGY, PROGNOSIS AND RISK FACTORS

Borderline tumors account for approximately 10–15% of all epithelial ovarian cancers in Caucasian populations. The mean age at the time of diagnosis ranges (according to different studies) from 38 to 56 years, which is approxi-

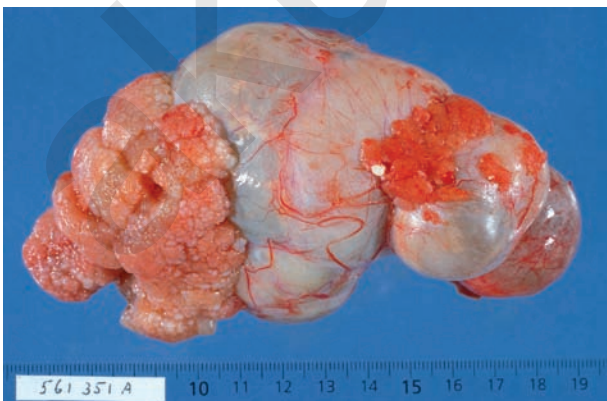

Figure 26.1 A cystic ovary: papillary vegetations and neovascularization can be seen on the outer surface of the ovary

mately 10–15 years younger than for malignant tumors of the ovary³.

In their review, Link *et al.*⁴ found the following distribution at the time of diagnosis: 69.6% of tumors at stage I, 10.3% at stage II, 19.2% at stage III, and 0.6% at stage IV.

The most important adverse factors are^{3,5,6–9}:

- High FIGO stage
- Histological subtype
- Presence of invasive peritoneal implants
- Pseudomyxoma peritonei
- Tumor size
- Patient’s age at the time of diagnosis
- Presence of a residual mass after surgery
- High mitotic index
- Cell atypia
- Ploidy of the tumor: aneuploidy

Survival

One of the most important prognostic elements is the FIGO stage. As for most other cancers, it is one of the oldest prognostic tools, and still the most widely used.

A review of more than 1000 cases by Massad *et al.*¹⁰ showed the following 5-year survival rates: stage I, 98.1%; stage II, 94.1%; stage III/IV, 79.0%; overall survival, 94.6%.

The histological type of the lesion was considered to be of lesser importance until recently. As more epidemic data become available, differences between histological subtypes become increasingly evident. The micropapillary serous subtype in particular is known to be of more prognostic significance. This subtype shows a greater incidence of bilateralism (59–82%), exophytic vegetations are more common (50–65%), stromal microinvasion or invasive peritoneal implants are more frequently encountered (16–91%) and the FIGO stage at the time of diagnosis is significantly higher^{5,11}. The recurrence rates are therefore significantly higher too, and the survival rates not as good as for the typical serous form. Deavers *et al.*⁶ found survival rates for stage II and III typical BOT of 85% after 5 years, while the micropapillary form was associated with survival rates of 72%.

Because of the inherent risk of late recurrence with this disease, overall survival at 20 years drops to approximately 80%⁴. It worsens when patients with pseudomyxoma peritonei are taken into account: their 10-year survival

rates are estimated to be as low as 40%. The chances of recurrence or persistent disease depend on the FIGO stage and on the nature of the peritoneal implants^{4,10,12}. Massad *et al.*¹⁰ encountered the following rates: stage I, 2.1% recurrence or persistent disease; stage II, 7.1%; stage III/IV, 14.4%. Lin *et al.*¹² found 11% recurrence if peritoneal implants were non-invasive and 45% if they were invasive. Deavers *et al.*⁶ compared the recurrence rates for typical and micropapillary serous BOT and reported 31% and 78%, respectively, for stage II and III disease.

Risk factors

The same risk factors as for malignant tumors have been evaluated, but they do not all appear to be equally relevant¹³. No significant relationship has been found with the following parameters:

- Family history
- Hormone replacement therapy (HRT)
- Menstrual history
- Body mass index (BMI)
- Use of an intrauterine device (IUD)

The same protective effects as for invasive cancers have been confirmed¹³:

- Pregnancy and birth (relative risk 0.7)
- Breast-feeding (relative risk 0.5)

The suggested protective effect of oral contraceptives is still a matter of debate^{14,15}.

Infertility and infertility treatment as risk factors for borderline tumors of the ovary

Borderline tumors are encountered more often in patients who suffer from infertility. As a result of this observation, some authors^{16–19} initially blamed infertility treatments. They suggested that the recurrent microtraumas associated with repeatedly induced ovulations might be responsible for the higher risk of malignancies. Nevertheless, evidence^{20,21} shows an equal increase in the incidence of BOT in patients suffering from infertility without any treatment, as in those being treated; furthermore, many BOT are discovered during infertility work-ups. It is therefore suggested that an underlying pathology of the ovary itself, and not the attempts to overcome this problem, might be the cause of BOT. Nowadays, many teams consider ovulation-inducing treatment or even *in vitro* fertilization (IVF) after conservative treatment for BOT in young women wishing to conceive. Several studies have demonstrated the safety of these treatments in carefully chosen cases^{22–26}.

HISTOLOGY

Histological criteria used to diagnose borderline tumors of the ovary include¹²:

- Epithelial budding
- Multilayered epithelium
- Mitotic activity
- Nuclear atypia
- Absence of signs of stromal invasion

To make sure that this last and most important criterion is met, the thorough investigation of a large number of slides must be carried out by an experienced anatomopathologist. Otherwise, the risk of mistaking BOT for invasive epithelial cancer, or for a benign cystadenoma, is high. Indeed, up to 10% of borderline tumors are upstaged to invasive carcinoma after complete anatomopathological examination. The results of frozen section analysis should therefore be treated with caution until confirmation.

Recently, several authors have been inclined to consider borderline tumors with focal microinvasion of the stroma as ordinary BOT^{7,26–28}. Their prognosis seems to be the same as for other BOT, at least in the case of low-stage disease, and in certain carefully selected cases even conservative treatment might be contemplated.

Different subspecies of borderline tumors of the ovary

The most frequent types of tumors of low malignant potential are the serous and mucinous forms. Together, they account for more than 95% of all BOT, and are therefore the most widely studied and understood.

Serous BOT

Fifty-five per cent of all BOT are of the serous subtype (15% of all serous tumors of the ovary being borderline variants). Recently, anatomopathologists divided serous tumors into two different subtypes (Bethesda Workshop^{26–28}, 2003): the more common typical serous BOT and the more aggressive micropapillary variant. New data subsequently proved the clinical interest of this classification, as several authors confirmed the worse prognosis of these subtypes.

Typical serous BOT This variant accounts for 74% of all serous forms, and may be bilateral (38%)¹² and cystic, and have a mean diameter between 6 and 12 cm (generally smaller than mucinous BOT). At the time of diagnosis, serous BOT are confined to the ovaries in 75% of all cases. Ascites is uncommonly encountered, at least in the early stages of the disease. The most common lesion observed is a unilocular cyst, often filled with clear liquid (Figure 26.2), with small papillary structures bordering the inner walls (Figure 26.3). These structures are generally covered with low-grade proliferative epithelium (Figures 26.4).

Exterior vegetations are found more frequently than in mucinous BOT, but they do not appear to constitute an unfavorable element. Psammomas may be present, even extensively in some cases.

Micropapillary serous BOT This variant is also called the cribriform serous type. These tumors are more commonly bilateral than their typical counterparts (59–89%), and involvement of the surface is more frequently encountered (50–65%). This may be the reason for the significantly higher stage at the time of diagnosis (43–84% stage II or higher). Focal microinvasion of the stroma or invasive peritoneal implants are also more common (16–91%)^{6,29–31}.

For these reasons, patients with this subtype might be considered as a population at risk, and conservative

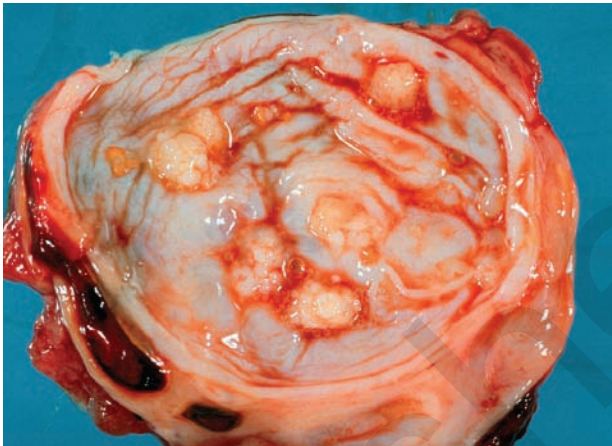


Figure 26.2 Several papillomatous foci can be seen inside a borderline cystic tumor of the ovary



Figure 26.3 A close-up shows the papillary pattern of borderline foci in another serous borderline tumor of the ovary

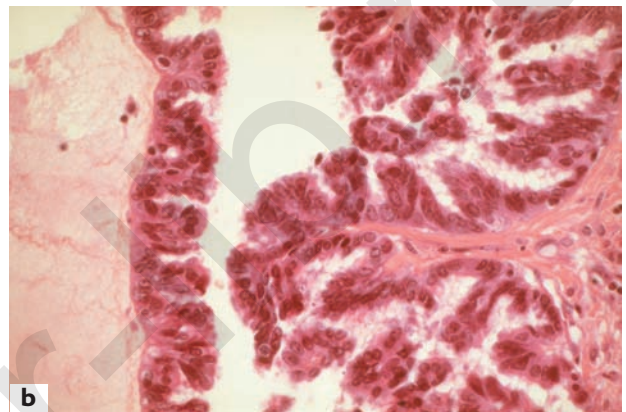
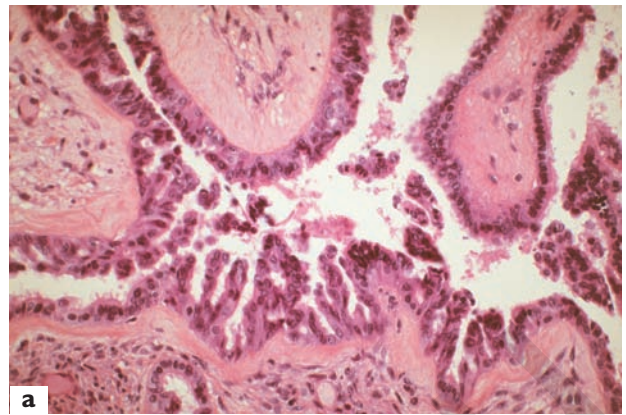


Figure 26.4 (a) and (b) Papillae covered with low-grade proliferative epithelium showing micropapillary tufting. Note the well-differentiated ciliated cells

management should be viewed with caution because of the higher recurrence rate.

Mucinous BOT

The mucinous form accounts for approximately 40% of all borderline tumors. Its spread tends to be limited to one ovary at the time of diagnosis (80–90% of stage I lesions, only 5% bilateral lesions).

Mucinous borderline neoplasms are typically large multilocular cysts (Figure 26.5), with a mean diameter of over 15 cm. Areas of necrosis and hemorrhage can be seen, as well as small papillae or nodules. The presence of surface vegetations is not uncommon, but ascites is rarely present. Histologically, the pseudostratified epithelium shows nuclear atypia (Figure 26.6).

The presence of stromal invasion (by atypical cells) excludes such tumors by definition from the borderline subgroup, but, in some cases, mucin can be found dissecting the stroma (pseudomyxoma ovarii).

Mucinous tumors of low malignant potential can be divided into two different subgroups with different histological characteristics: the Müllerian, endocervical type and the gastrointestinal type.

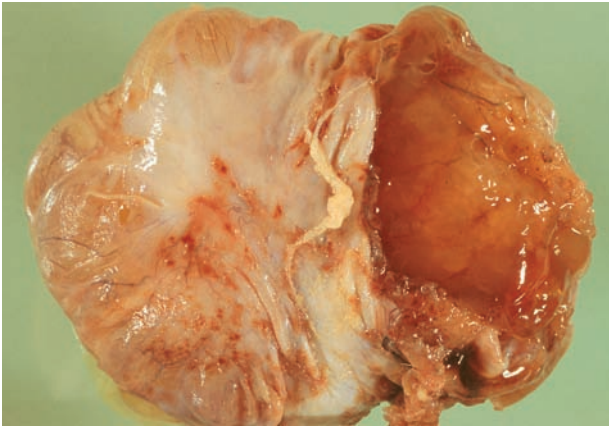


Figure 26.5 A large borderline tumor of the ovary with its mucinous content extruding through the right opening

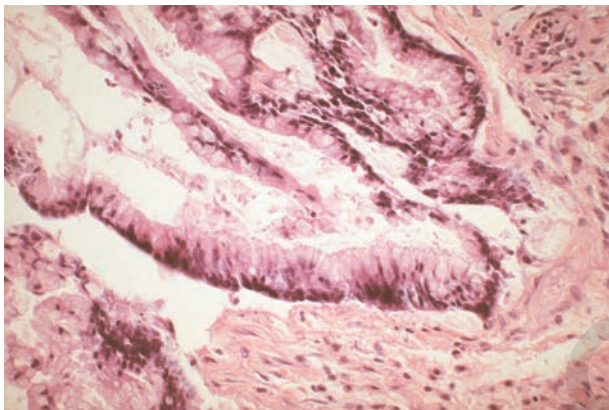


Figure 26.6 Pseudostratified epithelial lining of the cyst showing hyperchromatic nuclei and several goblet cells

Most tumors are of the intestinal variant, and the majority are encountered when still at stage I, with excellent survival rates. The endocervical variant is less frequent. As the micropapillary variant of the serous type, this subgroup more often involves both ovaries, but its prognosis is almost as good as for typical mucinous BOT²⁷.

A particular form is the pseudomyxoma peritonei. It may occur as a complication in all mucinous neoplasms and is characterized by a more or less chronic form of mucinous ascites with peritoneal implants, producing a gelatinous substance. It is generally associated with a defect in the primary cyst wall, leading to spontaneous spillage.

This condition may lead to abdominal pain or discomfort, and even to bowel obstruction.

A concomitant intestinal lesion is found in almost every case, but, even after careful exploration of the intestines, some tumors still appear to be of ovarian origin.

Because of the high probability of an occult intestinal lesion, careful surgical exploration of the appendix and all the intestines is necessary. Furthermore, routine appendec-

tomy should be performed in all cases of pseudomyxoma peritonei.

Endometrioid tumors

These tumors are often associated with peritoneal or ovarian endometriosis (in 30–50% of cases). However, peritoneal implants can be distinguished from endometriosis by the lack of hemorrhage and endometriotic stroma. Two different subtypes are known. The first develops on an adenofibrous background. The second consists of back-to-back glands and shows no adenofibrous matrix. Both types tend to be cystic, and recurrence seems to be infrequent.

Brenner tumors

This very rare variant seems generally to behave as a benign tumor, and stromal invasion is exceptionally infrequent. This BOT is usually cystic and bordered by epithelium formed of several cell layers, resembling a non-invasive papillary urothelial cell carcinoma.

Clear cell tumors

Clear cell tumors are another rare subspecies of borderline tumors, consisting of mostly fibrous tissue with glandular and tubal elements in a one-cell-layer epithelium.

Peritoneal implants

If stromal invasion is observed in the primary ovarian lesion, it should be classified and treated as malignant cancer. On the other hand, the presence of microinvasive lesions on the peritoneal surface is often encountered in higher-stage disease³². These are not considered as metastases but referred to as implants (Figure 26.7). The impact on long-term survival is still uncertain with this type of implant, but they seem to constitute one of the most unfavorable elements in disseminated disease^{4,11}.

Some authors consider these peritoneal lesions not as local dissemination, but as independent primary lesions. This theory of multifocal disease³³ is supported by the polyclonal origin of these lesions. Some cases of BOT could therefore be considered as peritoneal disease, not necessarily of ovarian origin alone.

MOLECULAR BIOLOGY

Genetic alterations are common in most malignant tumors. The semimalignant BOT is no exception. At least 50% of all borderline lesions present with at least one karyotypic anomaly. To date, cases of monosomy or trisomy of 19 different chromosomes have been reported^{34,35}. Several of these anomalies are more specific to one or the other tumor type.

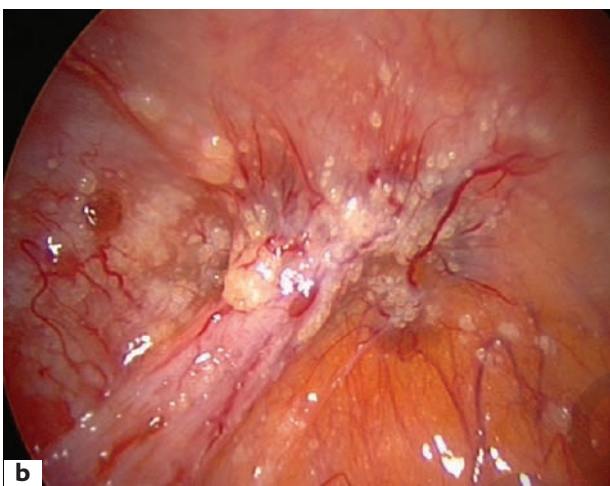
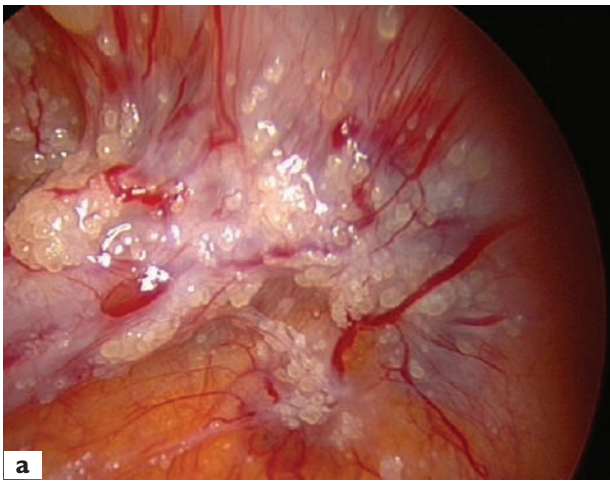


Figure 26.7 (a) and (b) Peritoneal implants of a stage III serous borderline tumor of the ovary (BOT). Even if these lesions with their extensive neovascularization have the appearance of invasive implants, the non-infiltrative nature was confirmed by histological examination

Gain of chromosome 12 is more frequent in serous BOT (23% vs. 8% in mucinous BOT). Gain of chromosome X is observed in 42% of mucinous BOT and 30% of the serous variant, while gain of chromosome 8 has not been noted in typical mucinous BOT. It is, on the other hand, more commonly encountered in serous and endocervical-mucinous borderline lesions or invasive ovarian carcinomas. Loss of chromosome X is much more common in invasive carcinomas.

These data^{36,37} are somewhat at odds with the multistep progression model for the progression of BOT to invasive carcinoma. Future studies might be able to identify some genetic pattern in BOT subgroups predisposing them to malignant transformation.

Several proteins are currently under investigation. One candidate is the HER-2 gene encoding epidermal growth factor. Some series show that this oncoprotein is amplified

in 25–66% of ovarian carcinomas and that its overexpression is less common in BOT³⁸. A possible link between tumor progression and this gene still needs to be confirmed. Other possible genetic markers of poor prognosis and progression towards invasive disease might be the OVCA-1, OVCA-2, BRCA or p53 genes.

The importance of a genetic prognostic tool for borderline disease is understood by most gynecological oncologists, but all studies published so far involve very small series, and much more epidemic data are needed. The low incidence of the different BOT types and the even lower probability of malignant transformation of borderline disease make it very difficult to gather enough material to perform such studies on a larger scale. Multicentric efforts will therefore be needed in the future to enable further progress to be made in this area.

DIAGNOSIS

Symptoms

Borderline tumors of the ovary show the same clinical symptoms as those for invasive epithelial cancers^{4,21,39}:

- Abdominal discomfort or pain
- Abdominal enlargement
- Sensation of an abdominal mass
- Menometrorrhagia

Many patients have no symptoms, and the ovarian mass is detected during a routine check-up, or investigation for an infertility problem. Any newly discovered ovarian mass (mostly cysts) should be carefully evaluated.

Ultrasound scans

The first examination should be a transvaginal ultrasound scan⁴⁰. The proximity of the probe to the ovary allows relatively precise resolution. This examination has high sensitivity (87–95%) if performed by an experienced operator using the latest technology.

Criteria used to evaluate the benign nature of a cyst by ultrasound are the following³⁹:

- (1) The cyst diameter: size below 5 cm suggests a benign cyst. A diameter above 10 cm, on the other hand, suggests either a malignant cyst or a benign mucinous cyst.
- (2) The homogeneity of the cyst content: homogeneous content of low echogenicity in a unilocular cyst is in favor of a non-malignant lesion. On the other hand, the presence of hyperechogenic areas and septa is suspect (Figure 26.8).
- (3) The absence of intracystic vegetations: the presence of such vegetations is certainly not proof of malignancy but is at least suspect (Figure 26.9).

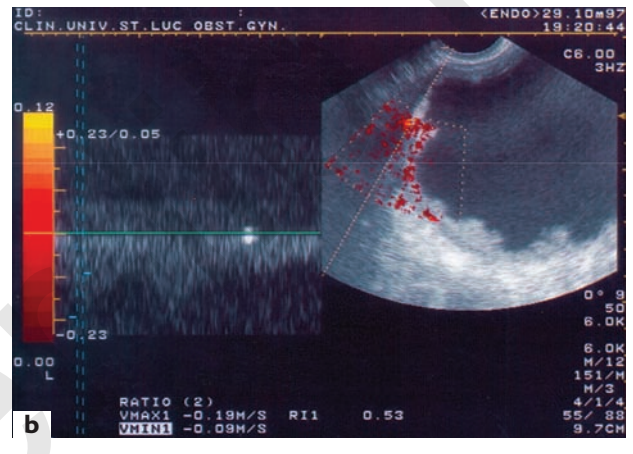
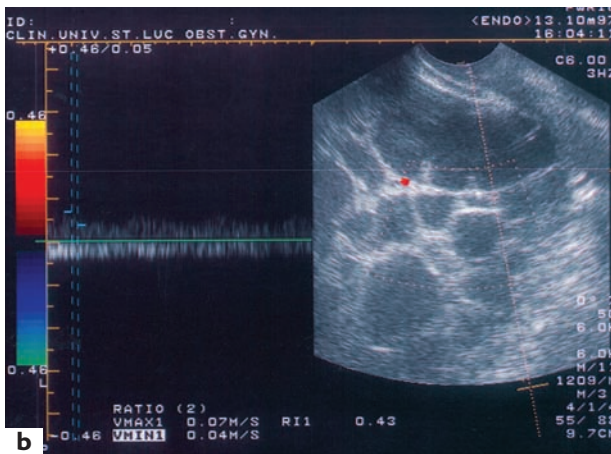
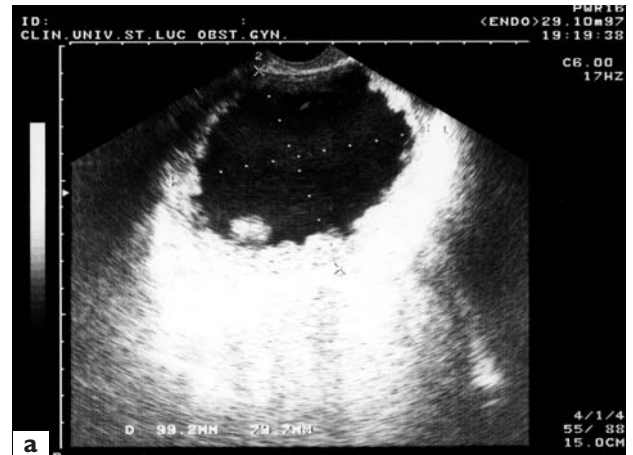
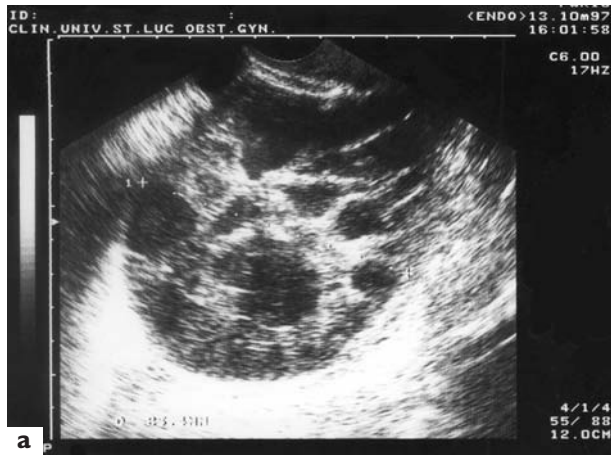
Figure 26.8 (a) and (b) These echographic images show the presence of a cyst of 83 mm in diameter. No normal ovarian cortex can be seen. Hypo- and hyperechogenic areas are visible, with the presence of septa. The visible vascularization is of venous type, resistance index (RI) 0.43. Histological results proved that this cyst was a mucinous borderline tumor of the ovary

Figure 26.9 (a) and (b) Right ovary with serous borderline tumor of the ovary: a cyst with an irregular wall is visible with the presence of multiple vegetations. Resistance index (RI) 0.53

- (4) The thickness and regularity of the cyst wall: a cyst with a wall thick enough to be easily visualized on ultrasound or computed tomography (CT) is a sign of malignancy (Figure 26.10 and 26.11).
- (5) The presence of ascites: the presence of a small amount of ascites in the posterior cul-de-sac can be encountered in physiological circumstances, but a larger volume is suspicious.
- (6) The absence of remaining normal ovarian tissue adjacent to cystic lesions is also a sign of possible (borderline) malignancy.

The use of Doppler ultrasound⁴⁰ (Figures 26.8b and 26.9b) allows the investigation of intracystic blood flow, a sign of proliferative pathology inside the cyst. Pulsed Doppler analysis can be used to measure flow velocity and

the resistance index (RI). RI values lower than 0.4 (or 0.5) are considered abnormal.

Computed tomography scans

Further evaluation of lesions is possible using CT scanning (Figures 26.12 and 26.13) with injection of contrast medium. This allows closer evaluation of the boundaries of the ovarian mass. Invasion of the surrounding tissue often results in unrecognizable boundaries. The detection of significant invasion of the omentum and lymph nodes is possible within the scope of resolution of this technology. The CT scan is also an excellent way to evaluate the presence of ascites and metastatic lesions. Computed tomography evaluation is therefore required for an adequate staging process.

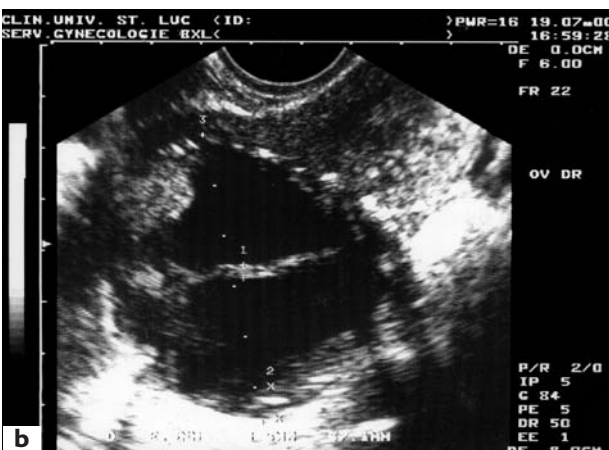
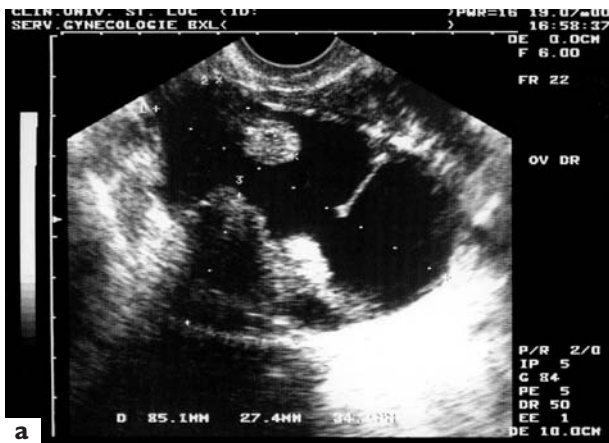
Figure 26.10 (a) and (b) These images show a serous borderline tumor of the ovary of 88.5 × 55.0 mm. The cyst wall is 6.5 mm thick and a heterogeneous area of 34 mm in diameter can be seen. A 2.5-mm thick septum is also visible

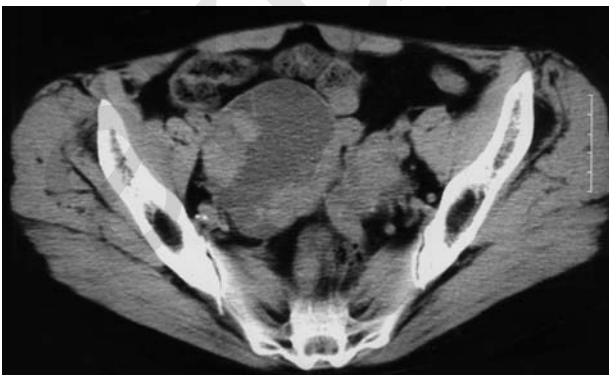


Figure 26.11 Computed tomography (CT) confirms the echographic findings and shows irregularity of the cyst wall. No calcifications, ascites or lymph node invasion are visible

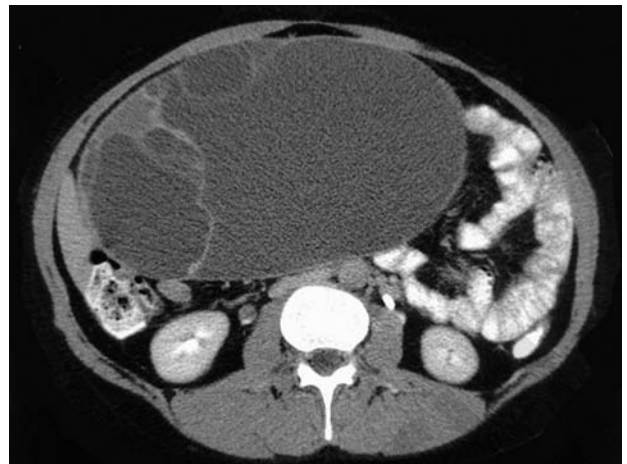


Figure 26.12 Computed tomography (CT) shows a large, hypodense cystic tumor of ovarian origin. Multiple septa can be seen. The cyst wall is, in some areas, thick enough to be easily visible. The suspected mucinous nature of this borderline tumor of the ovary (BOT) was confirmed later by histological examination

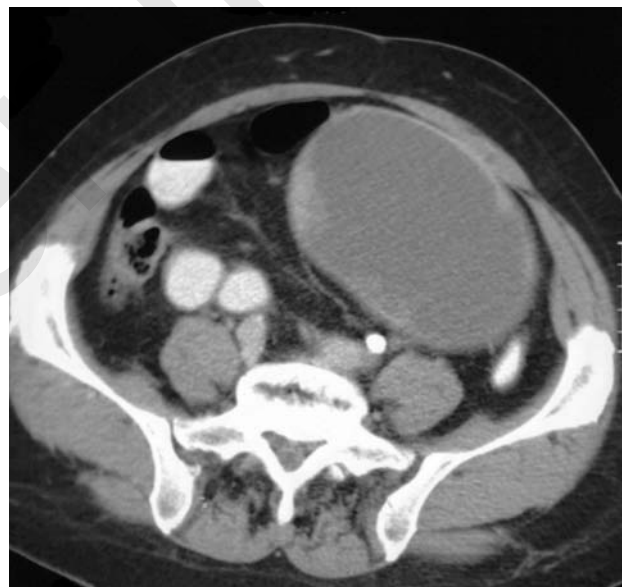

Figure 26.13 The computed tomography (CT) scan shows a large, cystic ovarian mass. The cyst is bordered by an irregular wall with some vegetations visible. No ascites or lymph node involvement can be seen. The mass later proved to be a serous borderline tumor of the ovary (BOT)

CA125

CA125⁴⁰, a tumor marker used to investigate and follow invasive carcinoma of the ovary, is only of limited use for early-stage borderline tumors.

High serum levels of CA125 in stage I serous borderline tumors are relatively uncommon. In some cases (35%), an intermediate value is found (35–100 U/ml). In

stage III lesions, elevated levels are encountered more often (89%)²².

In stage I mucinous borderline tumors, CA125 levels are even more frequently below the 35 U/ml limit. Disseminated lesions tend to have higher levels, but not as often as serous tumors. In all cases, CA125 values drop to normal levels after maximal surgical resection of tumor tissue.

The low sensitivity of this test makes it of little use as a diagnostic tool for BOT on its own. However, it can still be useful in association with other tests, and can help to distinguish BOT from invasive epithelial cancers.

Magnetic resonance imaging

Malignant and most borderline tumors are formed of cells containing a higher than normal amount of triglyceride in their membrane. They show a characteristic spectrum in magnetic resonance imaging (MRI). Therefore, MRI is useful for evaluating the potential malignant character of suspect ovarian masses or peritoneal implants of a certain size¹³.

Today, there is still no non-invasive technique available that can predict the malignant nature of a lesion with 100% accuracy. The best results are achieved with an association of clinical examination, transvaginal ultrasound scanning, measurement of CA125 levels and determination of intracystic blood flow (sensitivity of over 93%)^{39,40}. Of course, only microscopic analysis can provide a definitive diagnosis.

Laparoscopic staging

A laparoscopic procedure (Figure 26.14) allows visual exploration of the abdominal cavity and samples to be taken, necessary to perform adequate staging^{12,13}. Because of the more benign-like behavior of borderline tumors and the absence of effective adjuvant therapy, staging procedures do not need to include lymph node dissection. There is still some controversy as to whether lymph node involvement in purely borderline lesions is actually linked to the borderline condition itself, or occult or misdiagnosed invasive lesions. In any case, there is no evidence of any significant impact on survival or recurrence rates^{8,12,41-43}, and hence lymph node sampling does not appear to be a necessity.

On the other hand, the identification of peritoneal implants, their biopsy and cytological analysis of ascites, if present, are required. Awareness of dissemination of the disease can determine the therapeutic approach of the surgeon, and histological analysis of the implants is useful to evaluate whether they are invasive, which is an important adverse prognostic factor.

Complete staging should therefore include peritoneal cytology and complete evaluation of the abdominal cavity, including the paracolic gutters, the diaphragm and the omentum.

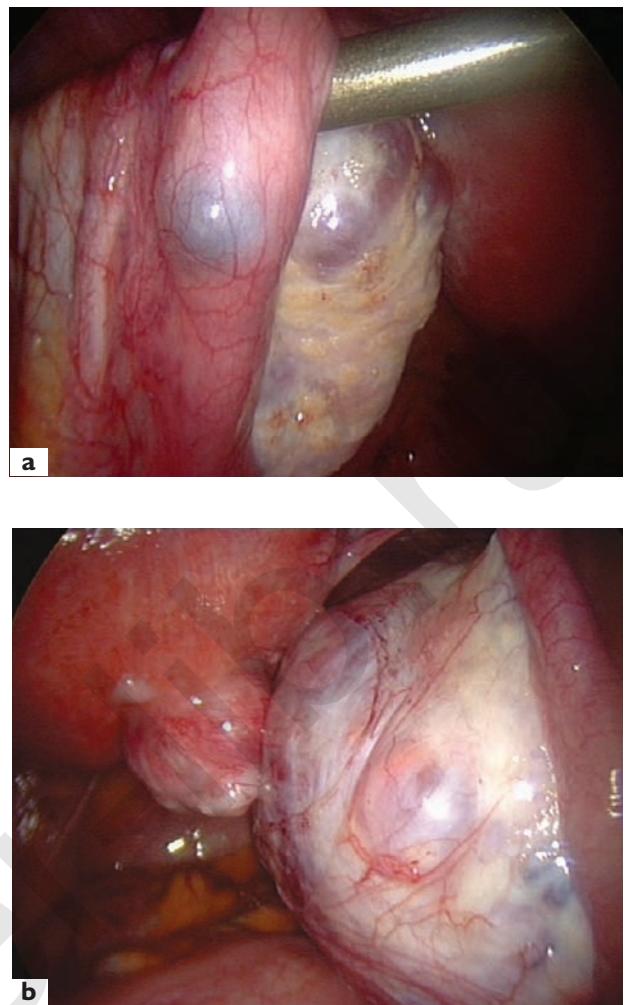


Figure 26.14 (a) and (b) Laparoscopic images showing a bilateral borderline tumor of the ovary (BOT) lesion of the serous form. Peritoneal implants can be seen on the uterine peritoneum and a small amount of ascites was discovered

TREATMENT

Surgery

The treatment of invasive epithelial cancer of the ovary includes total hysterectomy, bilateral adnexectomy, removal of the omentum and lymphadenectomy, usually completed by chemotherapy. Because of the excellent prognosis of borderline tumors, such extensive treatment is not necessary, and a less aggressive approach is generally sufficient^{9,13,25,39,41,44,45}.

The choice of adequate surgical treatment depends on the following factors:

- The stage of the disease
- The age of the patient
- A potential desire for pregnancy

- The nature of the peritoneal implants, if present (invasive or non-invasive)
- The histological subtype

The borderline nature of the disease must, of course, be proven, otherwise one cannot decide upon conservative surgery. The only way to ensure a precise diagnosis is histological analysis of the whole tumor by an experienced anatomopathologist.

Stage I lesions – women of child-bearing age

BOT occur more often than invasive tumors in younger women. Many of these patients have a desire to preserve their fertility. In carefully staged cases with a borderline lesion confined to one ovary, a more conservative approach to treatment is possible.

Unilateral adnexectomy This operation preserves fertility, leaving one functional ovary and the uterus intact. Several groups have reported pregnancies after such treatment^{13,22,23,25,39,46,47}, which can be performed by laparoscopy. The greatest risks of this procedure are intra-abdominal spillage and contamination of the abdominal wall. The use of a LapSac® and abundant peritoneal lavage might reduce this risk to an acceptable level, if performed by an experienced surgeon. Of course, there is a relatively small risk of recurrence in the contralateral ovary (15%)^{44,45}.

We therefore propose the following security measures:

- (1) Close follow-up: frequent clinical examinations, transvaginal ultrasound check-ups and controls of CA125 levels should be performed on a regular basis (every 6–12 months) and over a long period of time because of the late recurrence of this slowly progressing pathology. Morice *et al.*⁴⁷ encountered no recurrence that escaped diagnosis during routine follow-up in their study.
- (2) Removal of the remaining ovary once child-bearing is completed, to reduce the risk of a recurrent contralateral lesion: of the nine recurrences after conservative surgery observed by Morice *et al.*⁴⁷, all occurred in the remaining contralateral ovary. In a study published in *Fertility and Sterility*, recurrence occurred in five among 26 cases²⁶.
- (3) Second-look laparoscopy with multiple biopsies shortly (3–6 months) after the first conservative operation to ensure the absence of residual or recurring disease requiring further surgery: reoperation after diagnosis of recurrence is still feasible and another conservative procedure might even be possible in some cases, as reported by Morice⁴⁷ and Donnez²⁵ and their groups.

Cystectomy A simple cystectomy might be a tempting solution. It preserves fertility better than does unilateral adnexectomy because of the removal of less ovarian tissue.

The great danger of this option is the risk of inadvertently leaving behind some malignant cells.

This procedure should therefore not be the first choice of the gynecologist, and should only be performed in the following circumstances:

- Young patients
- Normal CA125 levels
- Loosely attached cysts
- No suspicious ultrasound findings
- Mucinous or typical serous borderline tumors
- Patient compliance: this important factor should not be overlooked if conservative treatment is considered

Many borderline tumors are incidental histological discoveries after cystectomy for a supposed benign cyst with no prior suspicion of malignancy. No further, more radical, surgical procedure is generally required, and a very close follow-up should be sufficient if the following criteria are met:

- Complete macroscopic exploration of the abdominopelvic cavity has been carried out
- The complete additional work-up is negative
- The borderline lesion is on the inner side of a cyst
- There are no vegetations on the outer side
- There is enough healthy tissue between the lesion and the surgical section

The recurrence rates after this type of surgery vary in the literature, but it is now generally accepted that recurrence is slightly increased^{25,47}.

Bilateral adnexectomy or cystectomy In borderline tumors involving both ovaries, bilateral adnexectomy should be performed, otherwise there is an unacceptably high risk of recurrence²⁶. However, in certain cases, incomplete resection of one ovary might be possible (cystectomy or partial adnexectomy). The same precautions as for simple cystectomy apply here. Even in these cases, there might still be a chance of future pregnancy with embryo cryopreservation, oocyte cryopreservation or oocyte donation, if the uterus can be spared⁴⁸.

Embryo cryopreservation In some cases, IVF might be performed⁴⁸ before the surgical removal of both ovaries. This is, of course, only possible in borderline pathology; for women suffering from malignant cancer, this approach is too dangerous. Indeed, a delay in treatment to allow at least 2 months of IVF cycles with high hormone levels can lead to further life-threatening growth of malignant tumors. However, BOT generally develop slowly enough to justify a limited delay before surgery.

Embryos obtained in this way can be frozen for later implantation after treatment or, in some carefully selected cases, pregnancy can even be continued until delivery, under strict surveillance⁴⁸. This procedure is, of course, not

possible for women without a male partner nor those requiring urgent treatment, who cannot afford the slightest delay.

Ovarian cryopreservation Another way of preserving fertility could be ovarian cortex cryopreservation. Although the thawing process is still problematic, ongoing technological developments have led to considerable progress in this field in recent times.

There are two possible reasons for banking ovarian tissue^{48–50}. A first possibility is autotransplantation of ovarian cortex after complete and lasting recovery⁵¹. We should keep in mind that there is a potential risk to this procedure, which is the possible grafting of malignant cells and resulting relapse. The isolation of oocytes contained in the frozen cortex and their *in vitro* maturation should be proposed. This procedure rules out the risk of grafting cancer cells back into the patient^{49,50}.

In a case of adnexectomy for a unilateral BOT, it might be interesting to remove, during first-look surgery, part of the contralateral ovarian cortex for cryopreservation. The chances of recurrence are real and might affect the whole remaining ovary, compromising the survival of enough oocytes to enable effective cryopreservation⁴⁸. Gynecologists should therefore propose this procedure early on in borderline pathologies, even if conservative surgery is possible. This might help to preserve fertility if further treatment is necessary due to recurrence of the initial tumor.

Oocyte donation This is the last option available to patients who wish to bear children after bilateral adnexectomy. This procedure should, of course, only be applied if no other option exists. The chances of success are comparatively low, but pregnancy still remains possible.

Stage I lesions—Postmenopausal period

In older women, bilateral adnexectomy should be sufficient for lesions confined to the ovary. Total hysterectomy for low-stage disease, as proposed by some authors, seems to be more aggressive than necessary; this type of operation causes higher morbidity, and there is still no evidence of any improvement in survival rates, compared with adnexectomy.

Lesions of stage II or higher

One of the most unfavorable factors is the presence of residual malignant tissue after surgery⁵². Lesions with intra-abdominal extension should therefore be treated more aggressively than localized stages. Complete debulking is the first priority; to this end, bilateral adnexectomy is necessary, and should be performed with resection of the omentum and every macroscopic lesion. Whether a normal uterus without any visible lesions requires removal is still a matter of debate. Recurrence might sometimes be observed in the utero-ovarian

ligament after adnexectomy. Because of the decreasing morbidity associated with hysterectomy in recent decades, it might be a reasonable option to propose.

This procedure is generally performed by laparotomy to reduce the risk of contamination and ensure complete removal of all malignant tissue, but, in some cases with limited extension of the disease, a laparoscopic procedure performed by a competent gynecologist is feasible²⁶.

Sometimes, in carefully selected cases of young women without serious risk factors, the uterus and some functional ovarian tissue can be spared. Bilateral salpingo-oophorectomy and omentectomy should still be performed in most cases. More epidemic data on histological subtypes and genetic prognostic factors might provide us with more effective prognostic tools to identify patients who could benefit from conservative surgery in cases of higher-stage disease, without increasing their risk of recurrence.

Pseudomyxoma peritonei

This particular form of disseminated mucinous BOT requires repeated surgical removal of as much tumor tissue and mucous ascites as possible. The prognosis of this form is relatively poor, compared with simple mucinous BOT, even after optimal surgical management.

Because of the frequent association between appendix lesions and pseudomyxoma peritonei, removal of the appendix should also be performed.

Adjuvant treatment

Because of the low mitotic activity and benign-like behavior of borderline tumors, they are not very sensitive to any adjuvant treatment. To date there is no epidemic evidence that adjuvant chemotherapy, as proposed by several teams only a few years ago for high-stage lesions, has any benefit^{4,33,41,53,54}. There is no proof of longer disease-free survival or better long-term survival.

Optimal surgical debulking is therefore the most appropriate treatment in this pathology.

However, there might be a very small subgroup of patients who could benefit from such treatment because of the presence of negative prognostic factors. Today's challenge is to identify this subpopulation. Borderline ovarian tumors showing a similar genetic pattern to that of their invasive counterparts, or high-stage micropapillary disease in young patients with invasive peritoneal implants, might be the final indication for a more aggressive approach, but further clinical research is necessary to confirm this.

Hormone replacement therapy after surgery

There is no clinical evidence of any adverse effect of hormone replacement therapy. Such treatment should therefore be administered to prevent the known negative

side-effects of the lack of endogenous estrogen (especially osteoporosis) in relatively young patients, in whom bilateral adnexectomy is performed¹³.

FERTILITY

Because of the young age of many patients with borderline tumors, fertility-sparing treatment has been proposed by some surgeons for low-stage disease. This type of procedure (mostly unilateral salpingo-oophorectomy) allows child-bearing in younger patients, even if the loss of half the oocyte reserve might reduce their fertility. More and more pregnancies or even cases of successful IVF are being reported after conservative surgery in young women, who subsequently give birth to normal babies^{14,22,23,25,46,47}. In a series of 97 patients, 26.8% ($n=26$) underwent conservative surgery. Among these women, 15 were known to desire pregnancy and ten of these (66.6%) were pregnant. A total of 17 pregnancies was obtained, and six recurrences in five patients were observed in this series (Table 26.1).

The safety of ovarian stimulation after conservative surgery is becoming more widely accepted. Several authors reported no recurrence after stimulation in their series⁴⁷, but, because of the theoretical risk of relapse, this type of treatment should still be reserved for low-stage disease with a good long-term prognosis, and the number of IVF cycles should be limited.

The results of the different studies shown in Table 26.2 prove that conservative treatment in carefully selected cases might be worth the risk, and that this less radical approach is becoming increasingly popular among gynecologists. However, because of the small number of patients treated this way in the various studies, it is difficult to conduct a statistical analysis of the remaining

fertility of these women, especially because of the higher rate of infertility in borderline groups (13% of infertility²¹ before diagnosis).

RESULTS

We performed a retrospective analysis of patients treated in our hospital for borderline tumors over the past 20 years.

Patients

Ninety-seven patients underwent surgical procedures for borderline pathology of the ovary. The mean age in our population was 52.2 years, with a range from 15 to 90 years. Thirty-four (35.1%) of these patients were under 40 years of age. In the subgroup of patients who underwent conservative surgery ($n=26$), the mean age was obviously lower, ranging from 15 to 38 years, with a mean age of 27.2 years. Patient distribution according to FIGO stage can be seen in Table 26.3.

Histology

Mucinous borderline tumors accounted for 48.5% of all tumors (47/97 cases). One case (1.0%) of pseudomyxoma peritonei was found. Serous borderline tumors were encountered in 48.5% of all cases (47/97 cases). One patient had a mixed, serous–mucinous tumor (1.0%), and one endometrioid BOT was discovered (1.0%).

Most of the women (83/97; 85.6%) had stage I disease. Four had stage II disease (4.2%) and ten stage III (10.6%); in these 14 cases, the peritoneal implants were all non-invasive. In 5 cases, focal micro-invasion of the stroma was

Table 26.1 Fertility outcome in conservatively treated women in our series of 97 patients with borderline tumors of the ovary

	<i>n</i>	%
Conservative treatment	26	26.8
Known desire for pregnancy	15	57.7
Pregnant patients	10	66.6
total pregnancies	17	
total deliveries	15	
Recurrent disease	5	19.2
before pregnancy	4	
after pregnancy	2*	

*One patient had two recurrences: the first time was before pregnancy and the second some months after delivery

Table 26.2 Conservative treatment of borderline tumors in the literature

	Gotlieb ²¹ 1998	Morice ⁴⁷ 2001	Donnez ²⁵ 2003	Chan ⁵⁵ 2003	Olszewska ⁵⁶ 2004	Camatte ⁵⁷ 2005	Fauvet ⁴⁶ 2005	Boran ⁵⁸ 2005	Present study 2005	Total*
Patients (n)	79	174	51	25	42	54	360	142	97	973
Conservative treatment (%)	49	28	20	100	100	100	45	44	27	47
Conservative treatment (n)	39	49	10	25	42	54	162	62	26	459
Recurrent disease (%)	7.7	20.5	18.7	0	'Low'	13	'High'	0	19.2	21.5
Disease-related deaths (n)	0	0	0	0	0	0	0	0	1	1
Known desire for pregnancy (n)	NA	NA	11	0	NA	19	65	NA	15	NA
Pregnant patients (n)	15	14	7	6	10	6	21	10	10	92
Pregnancies (n)	22	17	12	6	14	9	30	13	17	128
Deliveries (n)	NA	NA	12	5	NA	NA	NA	10	15	NA

*Cases of Donnez (2003) are excluded from the total because they are included in the 'present study'; NA, not available

Table 26.3 Prevalence of conservative and radical treatment in a series of 97 patients: patient classification according to International Federation of Gynecologists and Obstetricians (FIGO) stage

FIGO stage	Total (n = 97)	Conservative treatment (n = 26)	Radical treatment (n = 71)
Stage I total	83	21	62
a	55	15	40
b	15	3	12
c	13	3	10
Stage II	4	2	2
Stage III	10	3	7

present in a very small area of the primary lesion. These tumors were still considered to be BOT.

The criteria we used to decide whether or not to perform conservative treatment were the following:

- Young age (below 40)
- Low parity (mostly nulliparous)
- Low FIGO stage (mostly stage I)
- Possibility of close follow-up
- Patient compliance

This last important factor should not be overlooked when considering conservative treatment.

Treatment

Surgery

Seventy-one (73.2%) women underwent radical treatment, defined as bilateral adnexectomy, with or without hysterectomy. Omentectomy was associated in 34 cases when echographic findings led to the suspicion of a malignant lesion, if high-stage disease was suspected or when exophytic lesions were present on the surface of the ovary.

In twenty-six patients (26.8%), conservative, fertility-sparing treatment was performed. This group accounted

Table 26.4 Recurrence rates among patients after either conservative or radical treatment in a series of 97 patients

Treatment	n	Recurrent disease	Disease-related deaths
Conservative	26	5 (19.2%)	1 (3.8%)
Radical	71	0	0

for 76.4% of all women aged under 40 years in our population. As conservative treatment, the following procedures were considered:

- Unilateral cystectomy
- Unilateral adnexectomy
- Unilateral adnexectomy and contralateral cystectomy
- Bilateral cystectomy (no patients in our series)
- Omentectomy, performed in four out of 26 cases (15.4%)

Chemotherapy

In the early years of this study, chemotherapy was associated in 15 cases (15.5%). These included one case of conservative management and one case of pseudomyxoma peritonei.

Recurrence and survival

After radical treatment, there were no recurrences in our series (Table 26.4).

In the conservatively treated cohort, five patients (19.2%) suffered a relapse, one of them twice. One patient underwent conservative treatment for a stage Ia typical mucinous lesion. Recurrence occurred in the form of very aggressive invasive stage III disease. Despite adjuvant chemotherapy this young patient died after a few months. This was the only disease-related death we encountered, but it shows the inherent dangers of this semimalignant disease. We still need an efficient prognostic tool to identify those patients who, despite an initial apparently good prognosis, will develop invasive disease.

Fertility

In the group treated by conservative surgery, 17 pregnancies occurred in ten patients (one after a second conservative surgical procedure for recurrent disease) (Table 26.3).

It is difficult to estimate the real rate of infertility in this group of patients. The pregnancies obtained in ten

patients probably underestimate the remaining fertility potential in this group. Several women were treated recently, and have not yet manifested any desire for pregnancy. The youngest patient treated conservatively has not yet had sexual intercourse. Two other patients underwent IVF treatment with cryopreservation of embryos. One of these two women is about to undergo embryo transfer.

An actual documented desire for pregnancy seems to be present in 15 out of 26 patients at best (ten of these 15 patients have actually given birth to healthy babies).

These results show that child-bearing is possible in a significant number of cases after conservative treatment, without affecting survival rates.

CONCLUSION

The first publication on conservative treatment of borderline ovarian tumors dates back to 1998²⁰. At the same time, Gotlieb *et al.*²¹ published the first series of 39 patients treated conservatively. Other pioneers followed several years later (Morice *et al.*⁴⁷ in 2001 and Donnez *et al.*²⁵ in 2003). Since then, we have seen a rapid increase in publications on conservative treatments and even ovulation induction or IVF in BOT patients. To date, more than 120 pregnancies have been achieved in over 400 conservatively treated women (Table 26.2)

All current data show that recurrence rates encountered after radical treatment are significantly lower than after fertility-sparing treatment. The highest recurrence rates are observed after cystectomy, suggesting that this procedure should be reserved for carefully selected cases, and only if close surveillance can be assured.

Despite the more frequent relapse after conservative treatment, almost all cases of recurrent disease may be managed by surgery alone, sometimes even a second fertility-sparing procedure.

The overall pregnancy rate is 21.5% in a series of eight different studies. However, one must bear in mind that fertility estimation remains difficult because nothing is known about the desire for pregnancy in a significant number of young patients in numerous studies.

ACKNOWLEDGMENTS

We especially thank Dr Marbaix and his colleagues in the Department of Anatomopathology of the Catholic University of Louvain, Cliniques Universitaires St Luc, for providing figures and for useful advice.

REFERENCES

- Taylor HC. Malignant and semimalignant tumors of the ovary. *Surg Gynecol Obstet* 1929; 48: 204
- Morrow CP, Curtin JP, Townsend DE. *Synopsis of Gynecologic Oncology*, 4th edn. New York: Churchill Livingstone, 1993
- Auranen A, Grénman S, Mäkinen J, et al. Borderline ovarian tumors in Finland: epidemiology and familial occurrence. *Am J Epidemiol* 1996; 144: 548–53
- Link CJ, Reed E, Sarosy G, et al. Borderline ovarian tumors. *Am J Med* 1996; 101: 217–25
- Trope CG, Kristensen G, Makar A. Surgery for borderline tumors of the ovary. *Semin Surg Oncol* 2000; 19: 69–75
- Deavers MT, Gershenson DM, Tortolero-Luna G, et al. Micropapillary and cribriform patterns in ovarian serous tumors of low malignant potential: a study of 99 advanced stage cases. *Am J Surg Pathol* 2002; 26: 1129–41
- Smith Sehdev AE, Sehdev PS, Kurman RJ, et al. Noninvasive and invasive micropapillary (low-grade) serous carcinoma of the ovary: a clinicopathologic analysis of 135 cases. *Am J Surg Pathol* 2003; 27: 725–36
- Seidman JD, Kurman RJ. Ovarian serous borderline tumors: a critical review of the literature with emphasis on prognostic indicators. *Hum Pathol* 2001; 25: 419–32
- Münschke A, Nisolle M, Donnez J. Borderline tumors of the ovary or epithelial ovarian tumors of borderline malignancy. In Donnez J, Nisolle M, eds. *An Atlas of Operative Laparoscopy and Hysteroscopy*, 2nd edn. Carnforth, UK: Parthenon Publishing, 2001: 297–310
- Massad LSJ, Hunter VJ, Szpak CA, et al. Epithelial ovarian cancers of low malignant potential. *Obstet Gynecol* 1991; 78: 1027–32
- Gershenson DM, Silvia EG, Levy L, et al. Ovarian serous borderline tumors with invasive peritoneal implants. *Cancer* 1998; 15: 1096–103
- Lin PS, Gershenson DM, Bevers MW, et al. The current status of surgical staging of ovarian serous tumors. *Cancer* 1999; 85: 905–11
- Markmann M, Hoskins WJ. *Cancer of the Ovary*. New York: Raven Press, 1993
- Riman T, Dickman PW, Nilsson S, et al. Risk factors for epithelial borderline ovarian tumors: results of a Swedish case-control study. *Gynecol Oncol* 2001; 83: 575–85
- Modugno F, Ness RB, Wheeler JE, et al. Reproductive risk factors for epithelial ovarian cancers according to histologic type and invasiveness. *Ann Epidemiol* 2001; 11: 568–74
- Goldberg GL, Runowicz CD. Ovarian carcinoma of low malignant potential, infertility and induction of ovulation: is there a link? *Am J Obstet Gynecol* 1992; 166: 853–4
- Atlas M, Meriger J. Massive hyperstimulation and borderline malignancy carcinoma of the ovary: a possible association. *Acta Obstet Gynecol Scand* 1982; 61: 261–3
- Parazzini F, Negri E, La Vecchia C. Treatment for fertility and risk of ovarian tumors of borderline malignancy. *Gynecol Oncol* 1998; 68: 226–8
- Grimbizi G, Tarlatzis BC, Bontis J, et al. Two cases of ovarian tumors in women who had undergone multiple ovarian stimulation attempts. *Hum Reprod* 1995; 10: 520–3
- Mosyad BJ, Lindegaard O, Kjaer S. Ovarian stimulation and borderline tumors: a case control study. *Fertil Steril* 1998; 70: 1049–55
- Gotlieb WH, Flikker S, Davidson B, et al. Borderline tumors of the ovary: fertility treatment, conservative management, and pregnancy outcome. *Cancer* 1998; 82: 141–6
- Morris RT, Gershenson DM, Silva EG, et al. Outcome and reproductive function after conservative surgery for borderline ovarian tumors. *Obstet Gynecol* 2000; 95: 541–7
- Camatte S, Morice P, Pautier P, et al. Fertility results after conservative treatment of advanced stage serous borderline tumours of the ovary. *Br J Obstet Gynaecol* 2002; 109: 376–80
- Fasouliotis SJ, Davis O, Schattman G, et al. Safety and efficacy of infertility treatment after conservative management of borderline ovarian tumors: a preliminary report. *Fertil Steril* 2004; 82: 568–72
- Donnez J, Münschke A, Berliere M, et al. Safety of conservative management and fertility outcome in women with borderline tumors of the ovary. *Fertil Steril* 2003; 79: 1216–21
- Seidman JD, Soslow RA, Vang R, et al. Borderline ovarian tumors: diverse contemporary viewpoints on terminology and diagnostic criteria with illustrative images. *Hum Pathol* 2004; 35: 918–33
- Siverberg SG, Bell DA, Kurman RJ, et al. Borderline ovarian tumors: key points and workshop summary. *Hum Pathol* 2004; 35: 910–17
- Bell DA, Longacre TA, Prat J, et al. Serous borderline (low malignant potential, atypical proliferative) ovarian tumors: workshop perspectives. *Hum Pathol* 2004; 35: 934–48
- Seidman JD, Kurman RJ. Subclassification of serous borderline tumors of the ovary into benign and malignant types. *Am J Surg Pathol* 1996; 20: 1331–45
- Burks RT, Sherman ME, Kurman RJ. Micropapillary serous carcinoma of the ovary. A distinctive low-grade carcinoma related to serous borderline tumors. *Am J Surg Pathol* 1996; 20: 29–36
- Eichhorn JH, Bell DA, Young RH, et al. Ovarian serous borderline tumors with micropapillary and cribriform patterns: a study of 40 cases and

- comparison with 44 cases without these patterns. *Am J Surg Pathol* 1999; 23: 397–409
32. Prat J. Ovarian tumors of borderline malignancy (tumors of low malignant potential): a critical appraisal. *Adv Anat Pathol* 1999; 6: 247–74
 33. Kehoe S, Powell J. Long-term follow up of women with borderline ovarian tumors. *Int J Gynecol Obstet* 1996; 53: 139–43
 34. Pejovic T, Iosif CS, Mitelman F, et al. Karyotypic characteristics of borderline malignant tumors of the ovary: trisomy 12, trisomy 7 and r(1) as nonrandom features. *Cancer Genet Cytogenet* 1997; 96: 166–73
 35. Deger RB, Faruqi SA, Noumoff JS. Karyotypic analysis of 32 malignant epithelial ovarian tumors. *Cancer Genet Cytogenet* 1997; 96: 95–8
 36. Hu J, Khanna V, Jones MM, et al. Genomic imbalances in ovarian borderline serous and mucinous tumors. *Cancer Genet Cytogenet* 2002; 139: 18–23
 37. Watson RH, Neville PJ, Roy WJ Jr, et al. Loss of heterozygosity on chromosomes 7p, 7q, 9p and 11q is an early event in ovarian tumorigenesis. *Oncogene* 1998; 17: 207–12
 38. Heinrich JK, Bottcher-Luiz F, Andrade LL, et al. HER-2 and cancer antigen 125 evaluation in ovarian borderline tumors by immunohistochemistry and fluorescence in situ hybridization. *Int J Gynecol Cancer* 2004; 14: 1078–85
 39. Nicoloso E, d'Ercole C, Boubli L, et al. Tumeurs borderline et cancer de l'ovaire: evaluation coelichirurgicale. *Presse Méd* 1995; 24: 1421–4
 40. Gotlieb WH, Soriano D, Achiron R, et al. CA-125 measurement and ultrasonography in borderline tumors of the ovary. *Am J Obstet Gynecol* 2000; 183: 541–6
 41. Kennedy AW, Hart WR. Ovarian papillary serous tumors of low malignant potential (serous borderline tumors). *Cancer* 1996; 78: 278–86
 42. Laeke JF, Currie JL, Rosenshein NB, et al. Long-term follow-up of serous ovarian tumors: a case control study. *Gynecol Oncol* 1992; 47: 150–8
 43. Rota SM, Zanetta G, Ieda N, et al. Clinical relevance of retroperitoneal involvement from epithelial ovarian tumors of borderline malignancy. *Int J Gynecol Cancer* 1999; 85: 905–11
 44. Gershenson DM. Contemporary treatment of borderline ovarian tumors. *Cancer Invest* 1999; 17: 206–10
 45. Trope C, Kaern J. Management of borderline tumors of the ovary: state of the art. *Semin Oncol* 1998; 25: 372–80
 46. Fauvet R, Boccara J, Dufournet C, et al. Laparoscopic management of borderline ovarian tumors: results of a French multi-center study. *Ann Oncol* 2005; 16: 403–10
 47. Morice P, Camatte S, El Hassan J, et al. Clinical outcomes and fertility after conservative treatment of ovarian borderline tumors. *Fertil Steril* 2001; 75: 92–6
 48. Donnez J, Bassil S. Indications for cryopreservation of ovarian tissue. *Hum Reprod Update* 1998; 4: 248–59
 49. Aubard Y, Newton H, Oktay K, et al. Follicle freezing and autografting. A new method of medically assisted procreation? *Presse Méd* 1996; 25: 921–3
 50. Oktay K, Newton H, Aubard Y, et al. Cryopreservation of immature human oocytes and ovarian tissue: an emerging technology? *Fertil Steril* 1998; 69: 1–7
 51. Donnez J, Dolmans MM, Demylle D, et al. Livebirth after orthotopic transplantation of cryopreserved ovarian tissue. *Lancet* 2004; 364: 1405–10
 52. Lackman F, Carey MS, Kirk ME, et al. Surgery as sole treatment for serous borderline tumors of the ovary with non invasive implants. *Gynecol Oncol* 2003; 90: 407–12
 53. Barnhill DR, Kurman RJ, Brady MF, et al. Preliminary analysis of the behavior of stage I ovarian serous tumors of low malignant potential: a Gynecologic Oncology Group Study. *J Clin Oncol* 1995; 13: 2752–6
 54. Hoffman JS, Laird L, Benadiva C, et al. In vitro fertilization following conservative management of stage 3 borderline tumor of the ovary. *Gynecol Oncol* 1999; 74: 515–18
 55. Chan JK, Lin YG, Loizzi V, et al. Borderline ovarian tumors in reproductive-age women. Fertility-sparing surgery and outcome. *J Reprod Med* 2003; 48: 756–60
 56. Olszewska H, Lapinska-Szumczyk S, Kobierski J, et al. Fertility of women after conservative operation for borderline ovarian tumors. *Ginekol Pol* 2004; 75: 533–7
 57. Camatte S, Deffieux X, Castaigne D, et al. Laparoscopic treatment of borderline ovarian tumor: analysis of 54 patients and clinical outcomes. *Gynecol Obstet Fertil* 2005; 33: 395–402
 58. Boran N, Cil AP, Tulunay G, et al. Fertility and recurrence results of conservative surgery for borderline ovarian tumors. *Gynecol Oncol* 2005; 97: 845–51

akusher-lib.ru

Laparoscopic reimplantation of cryopreserved ovarian tissue

27

J Donnez, M M Dolmans, D Demylle, P Jadoul, C Pirard, J Squifflet, B Martinez-Madrid, A Van Langendonck

INTRODUCTION

The treatment of childhood malignant disease is becoming increasingly effective. Aggressive chemotherapy and radiotherapy, and bone-marrow transplantation, can cure more than 90% of girls and young women affected by such disorders. However, the ovaries are very sensitive to cytotoxic treatment, especially to alkylating agents and ionizing radiation, generally resulting in loss of both endocrine and reproductive function¹. Moreover, uterine irradiation at a young age reduces adult uterine volume².

By 2010, about one in 250 people in the adult population will be childhood-cancer survivors³. Several potential options are available to preserve fertility in patients facing premature ovarian failure, including immature and mature oocyte cryopreservation, and embryo cryopreservation^{4,5}. For patients who need immediate chemotherapy, the cryopreservation of ovarian tissue is a possible alternative^{4,6,7}. The aim of this strategy is to reimplant ovarian tissue into the pelvic cavity (orthotopic site) or a heterotopic site such as the forearm once treatment is completed and the patient is disease-free^{4,8–10}.

Oktay *et al.* reported laparoscopic transplantation of frozen–thawed ovarian tissue to the pelvic side wall⁸, forearm⁹, and beneath the skin of the abdomen. A four-cell embryo was obtained from 20 oocytes retrieved from tissue transplanted to the abdomen, but no pregnancy occurred after transfer¹¹. Radford *et al.*¹⁰ reported a patient with a history of Hodgkin's disease treated by chemotherapy, in whom ovarian tissue had been biopsied and

cryopreserved 4 years after chemotherapy and later reimplanted. In this case, histological section of ovarian cortical tissue revealed only a few primordial follicles because of the previous chemotherapy. After reimplantation, the patient had only one menstrual period.

In 1995, the Catholic University of Louvain ethics committee approved a protocol to assess the safety and efficacy of the cryopreservation of ovarian tissue in women treated with high doses of chemotherapy, which could induce ovarian failure.

Here, we describe the outcome of orthotopic autotransplantation of cryopreserved ovarian tissue in three patients.

METHODS

Patient I

In 1997, a 25-year-old woman presented with clinical stage IV Hodgkin's lymphoma. Ovarian tissue cryopreservation was undertaken before chemotherapy. We obtained written informed consent. By laparoscopy, we took five biopsy samples – about 12–15 mm long and 5 mm wide – from the left ovary (Figure 27.1). Freezing of ovarian tissue was carried out according to the protocol described by Gosden *et al.*⁶. We immediately transferred biopsy samples to the laboratory in Leibovitz L-15 medium supplemented with GlutaMAX™ (Invitrogen, Paisley, UK), where the remaining stromal tissue was gently removed. We cut four biopsy samples of cortex into 70 small cubes of 2×2 mm, and one strip of 12×4 mm was left whole. These fragments of ovarian tissue were suspended in the cryoprotective medium. We placed all the fragments into precooled 2-ml cryogenic vials (Simport, Quebec, Canada) filled with Leibovitz medium, supplemented with 4 mg/ml of human serum albumin (Red Cross, Brussels, Belgium) and 1.5 mmol/l DMSO (dimethylsulfoxide) (Sigma, St Louis, MO, USA). The cryotubes were cooled in a programmable freezer (Kryo 10, Series III; Planer, Sunbury-on-Thames, UK) using the following program: (1) cooled from 0 to –8°C at –2°C/min; (2) seeded manually by touching the cryotubes with forceps prechilled in liquid nitrogen; (3) cooled to –40°C at –0.3°C/min; (4) cooled to –150°C at –30°C/min; and (5) transferred to liquid nitrogen (–196°C) immediately for storage.

Removal of the whole ovary was not an option, because one can never exclude recovery of ovarian function after

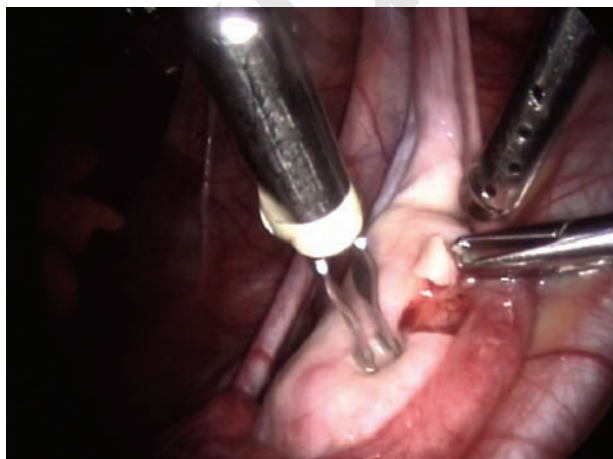


Figure 27.1 Biopsy of the cortex. Only cortical pieces 12–15 mm long and 5 mm wide must be biopsied

chemotherapy. Indeed, premature ovarian failure after chemotherapy is dependent on age, drug used and dose given, and does not happen in all cases. After laparoscopy, the patient received MOPP/ABV hybrid chemotherapy (mechlorethamine, vincristine, procarbazine, prednisone, doxorubicin, bleomycin, vinblastine) from August 1997 to February 1998, followed by radiotherapy (38 Gy).

The patient became amenorrheic shortly after the initiation of chemotherapy. After chemotherapy and radiotherapy, concentrations of follicle stimulating hormone (FSH) were 91.1 mIU/ml, luteinizing hormone (LH) 85 mIU/ml and estradiol 17 pg/ml, confirming castration. This ovarian failure profile was confirmed 3 months later. Hormone replacement therapy (HRT) was started in June 1998 and then stopped in January 2001 because the patient wanted to become pregnant. A thorough evaluation by oncologists showed that she was disease-free.

After the cessation of HRT, concentrations of FSH, LH and 17 β -estradiol returned to levels consistent with ovarian failure. From January 2001 to December 2002 the patient had only one ovulatory cycle.

Reimplantation

We performed the first laparoscopy 7 days before reimplantation to create a peritoneal window by means of a large incision just beneath the right ovarian hilus, followed by coagulation of the edges of the window (Figure 27.2a). The goal was to induce angiogenesis and neovascularization in this area.

We performed a second laparoscopy 7 days after creation of the peritoneal window. A biopsy sample of 4–5 mm in size was taken from each of the atrophic ovaries to check for the presence or absence of primordial follicles.

We thawed the cryogenic vials at room temperature (between 21 and 23°C) for 2 min and immersed them in a water bath at 37°C for another 2 min. We immediately transferred ovarian tissue from the vials to tissue culture dishes (Becton Dickinson, NY, USA) in Leibovitz medium and subsequently washed the tissue three times with fresh medium to remove cryoprotectant before further processing.

Thawed ovarian cortical tissue was placed in sterile medium and immediately transferred to the operating theater. We pushed the large strip and 35 small cubes of frozen–thawed ovarian tissue into the furrow created by the peritoneal window, very close to the ovarian vessels and fimbria on the right side (Figure 27.3). No suture was used. An extensive neovascular network was clearly visible in this space (Figure 27.2b). We used vital fluorescent staining (Molecular Probes, Leiden, The Netherlands) to confirm the survival of primordial follicles after freeze–thawing¹².

After long discussions with the oncologists and the patient, a third laparoscopy was proposed. At least three reasons were given to justify the procedure: (1) to check the viability of the orthotopic grafts, 4 months after

transplantation, by laparoscopic visualization and histological analysis; (2) to check for the absence of any cellular growth anomalies (peritoneal fluid, histology), the cortical strip and cubes having been biopsied before chemotherapy; and (3) to reimplant the remaining ovarian cortical cubes, by request of the patient, who was now aged 32 years. Indeed, if pregnancy had not ensued from the reimplanted tissue, she would have considered oocyte donation. A validated technique will probably not need so many surgical procedures in the future.

Results

FSH and LH concentrations were at castrated levels, and vaginal echography failed to show any ovarian activity, until 5 months after reimplantation. The day before the third laparoscopy, ultrasonography clearly showed the presence of a follicle outside the ovaries, both of which appeared atrophic. The atrophic ovaries were visualized as

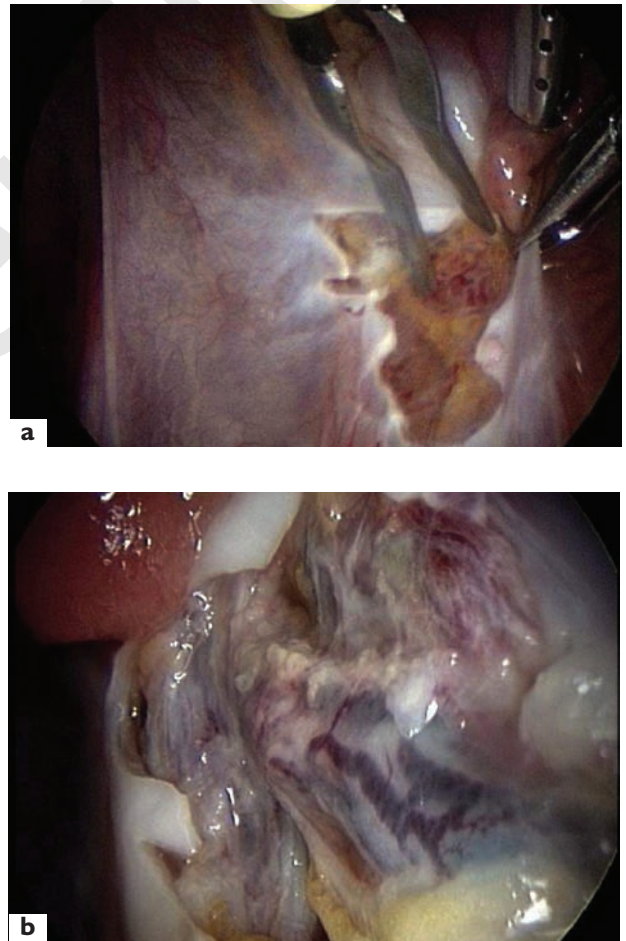


Figure 27.2 Site of transplantation. (a) During the first laparoscopy (7 days before transplantation), a peritoneal window was created and the edges of the window were coagulated. (b) Seven days later (day of reimplantation), an extensive vascular network was clearly visible in this space

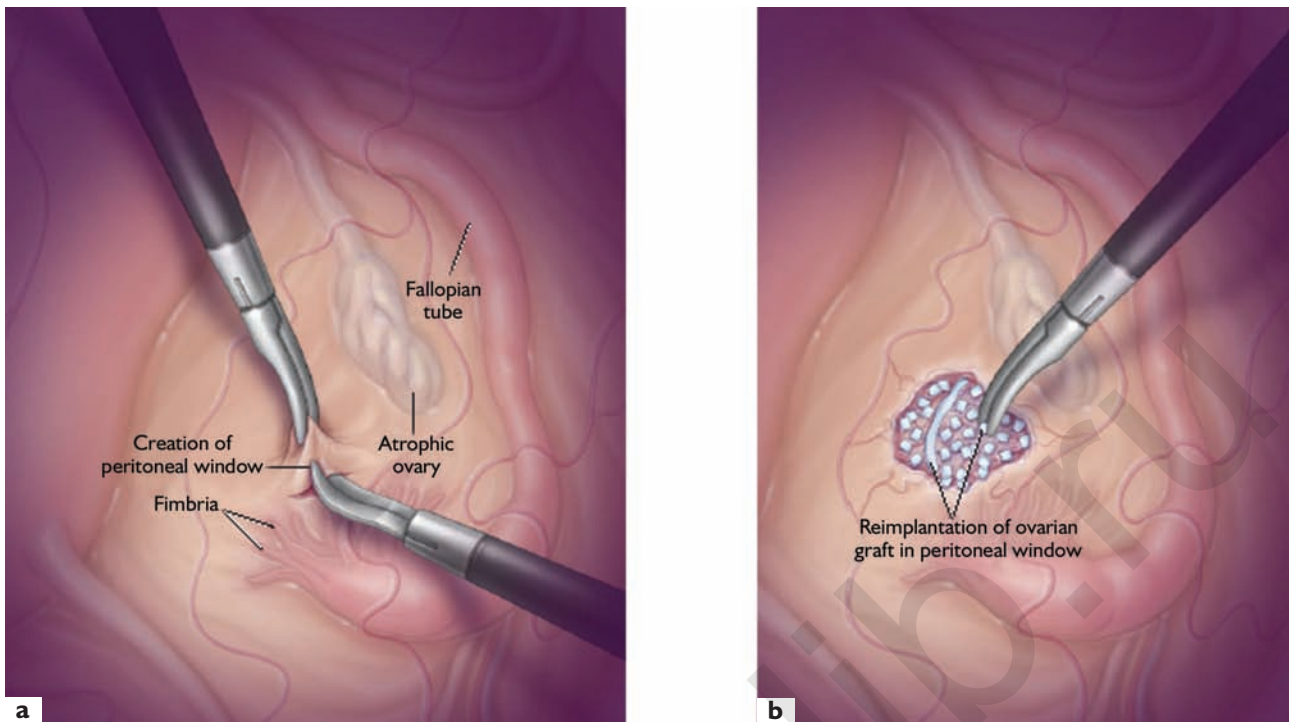


Figure 27.3 Laparoscopic creation of a peritoneal window and subsequent development of a vascular network. During the first laparoscopy (7 days before transplantation), a peritoneal window was created, and the edges of the window were coagulated (a). The large strip and small cubes were then placed in the peritoneal window (b)

dense echogenic structures measuring about 2 cm long and 0.75–1 cm wide. The follicular structure could be seen clearly separated (0.5–1 cm) from the right ovary. At this laparoscopy, the ovaries were still atrophic, without any signs of ovarian activity. At the site of reimplantation, the follicular structure seen at vaginal echography was visible, and was subsequently biopsied (Figure 27.4a). The biopsy sample showed that granulosa cells were present, as proved by the presence of cells immunohistochemically expressing inhibin A (Figure 27.4b)¹³. The grafted cubes could also be seen, and one of them was biopsied for the assessment of primordial follicle survival (Figure 27.5). Follicular viability was proved by the presence of two primordial follicles, which were colored by vital fluorescent staining (Figure 27.5). The remaining 32 cubes were then reimplanted at the site of the ovarian graft biopsy on the right side. At that time, a slight reduction in LH and FSH was noted, concomitantly with follicular development in the grafted area.

From 5 to 9 months after reimplantation, ultrasonography revealed the development of a follicle, followed by corpus luteum formation with every menstrual cycle at the site of reimplantation; this corresponded with an estradiol concentration of more than 100 pg/ml and a progesterone level of 12–37 ng/ml. Amounts of LH and FSH were lower than those observed before reimplantation. This change led to the restoration of consecutive menstrual bleeding every month. At 9.5

months, FSH concentrations rose to 78.7 mIU/ml, and returned to normal values 7 days later. Three weeks later, a follicle of 2.6 cm in size had developed on the right side, clearly outside the right ovary (Figure 27.6a). Both native ovaries were well visualized and obviously atrophic. Eighteen days after ovulation, calculated by basal body temperature, the concentration of human chorionic gonadotropin was 2853 mIU/ml. We should stress that conception arose spontaneously, since neither ovarian stimulation nor *in vitro* fertilization (IVF) had been carried out. Because we do not yet know whether transplanted tissue can sustain ovarian steroid hormone support during pregnancy, we initiated progesterone treatment (administered vaginally at a dose of 600 mg per day). Vaginal ultrasonography at 8 weeks confirmed a viable intrauterine pregnancy (Figure 27.6b). Triple test evaluation and ultrasonography did not reveal any anomalies. The pregnancy resulted in the live birth of a healthy girl, weighing 3.72 kg, with an Apgar score of 9 at 1 min, 9 at 5 min and 9 at 10 min.

Patient 2

In 1999, a 21-year-old woman presented with complications (spleen abscess and cerebral thrombosis) due to homozygous sickle cell anemia. Bone marrow transplantation (BMT) was proposed to the patient, her sister being human leukocyte antigen (HLA)-compatible.

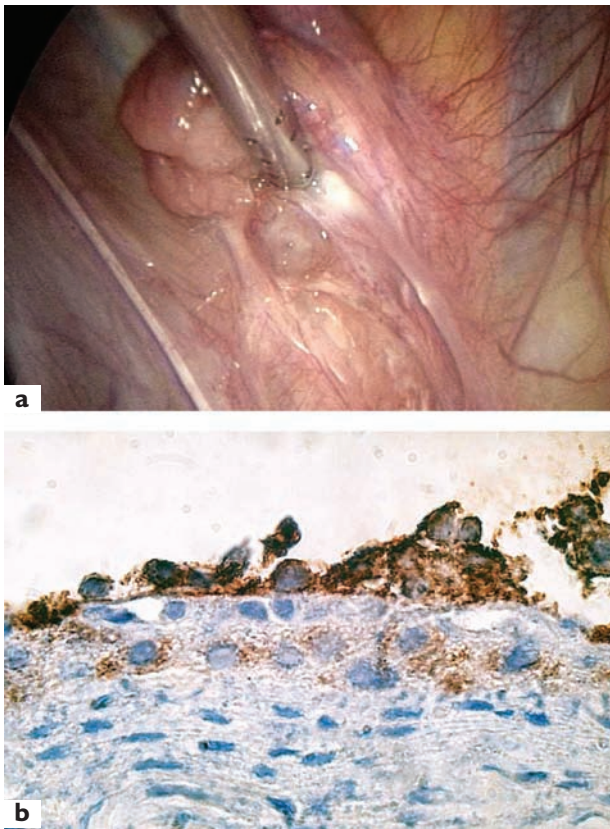


Figure 27.4 Follicle from the grafted tissue. (a) Laparoscopic view of the follicular structure at the site of the large strip implantation. (b) Histology of the follicular wall showing the presence of cells expressing inhibin A (brown). Original magnification $\times 100$

Ovarian tissue cryopreservation was undertaken before chemotherapy.

Using laparoscopy, we performed a right oophorectomy. Removal of the whole ovary was decided upon in the present case, because ovarian failure is almost always induced after chemotherapy given prior to BMT^{14,15}.

After laparoscopy, the patient received two alkylating agents (busulfan 16 mg/kg; cyclophosphamide 120 mg/kg). In July of that year, bone marrow transplantation was carried out.

The patient became amenorrheic immediately after the initiation of chemotherapy. Concentrations of follicle stimulating hormone (FSH) were 48.2 mIU/ml, luteinizing hormone (LH) 18.5 mIU/ml and estradiol <10 pg/ml, confirming castration. This ovarian failure profile was confirmed 3 and 5 months later, and HRT was started in December 1999 and stopped in December 2002.

After the cessation of HRT, bimonthly measurements of FSH, LH and 17β -estradiol concentrations proved the absence of ovulatory cycles from December 2002 to August 2004. The measurement of ovarian volume by ultrasound revealed a volume of $14.1 \times 1 \times 1$ cm. No remaining follicles were visible by ultrasound during this

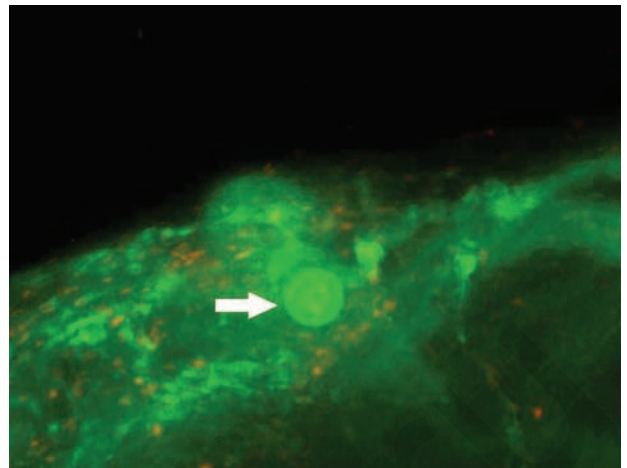


Figure 27.5 Biopsy sample of a frozen-thawed cube, 5 months after reimplantation. Vital fluorescent staining by calcein-AM and ethidium homodimer 1 indicated viable primordial follicles, colored in green (arrow). Original magnification $\times 20$

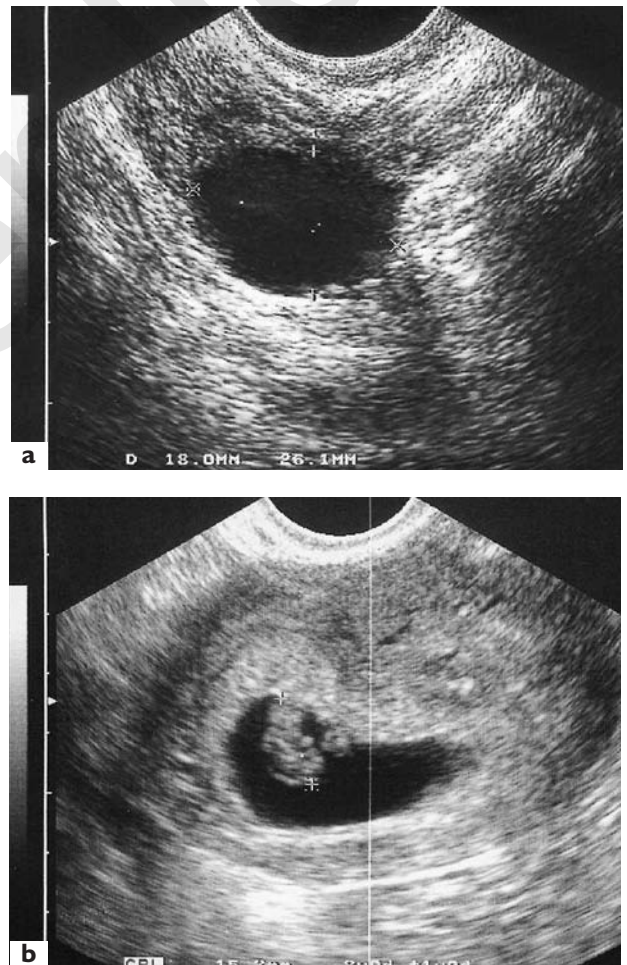


Figure 27.6 Vaginal ultrasonography. (a) Vaginal echography showing a follicle of 18×26 mm in size at the site of ovarian cortex transplantation. (b) Ongoing intrauterine pregnancy (8 weeks). Crown-rump length 15 mm, cardiac activity +

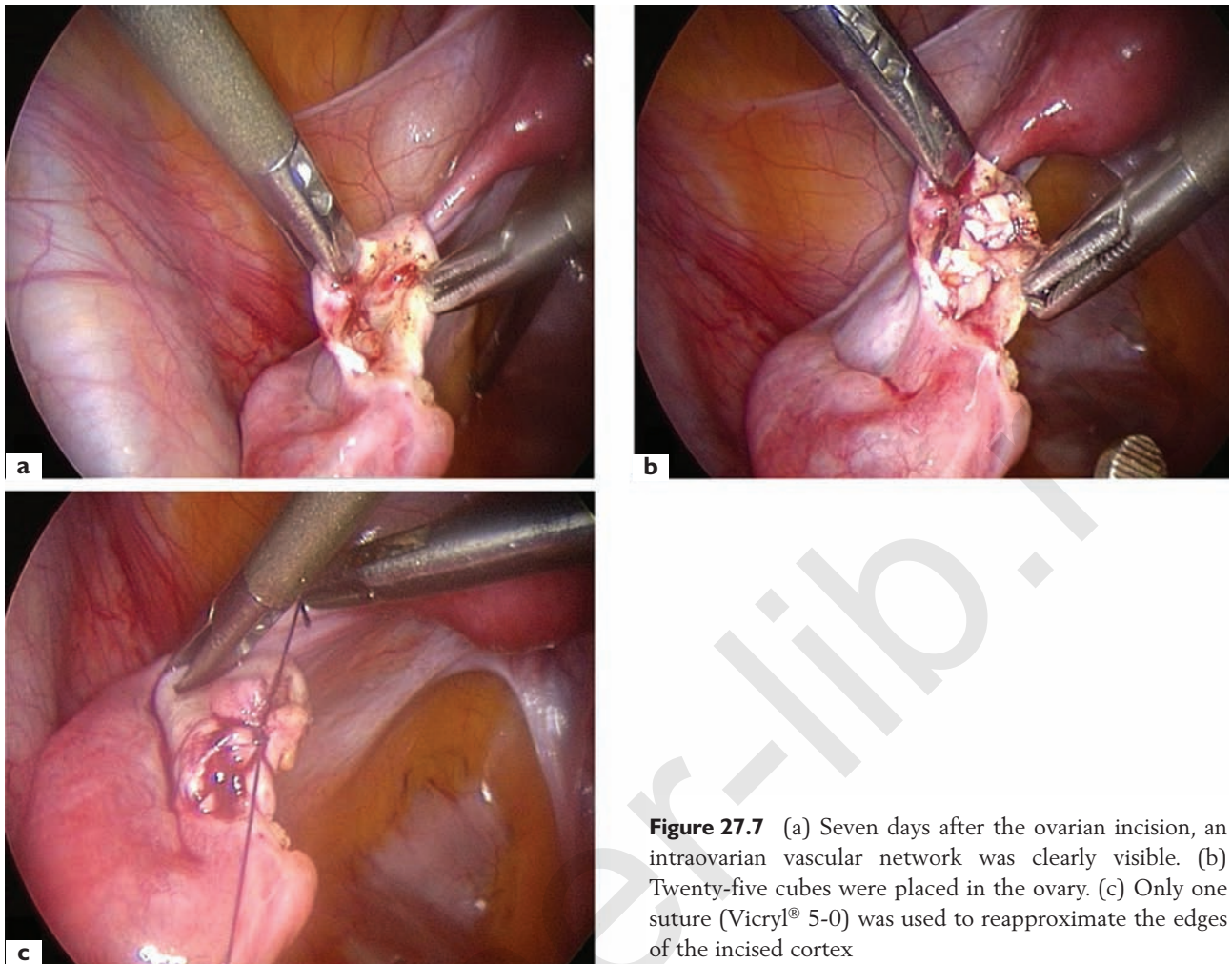


Figure 27.7 (a) Seven days after the ovarian incision, an intraovarian vascular network was clearly visible. (b) Twenty-five cubes were placed in the ovary. (c) Only one suture (Vicryl® 5-0) was used to reapproximate the edges of the incised cortex

20-month period. The decision to reimplant the cryopreserved tissue was therefore taken.

Reimplantation

A first laparoscopy was performed 7 days before reimplantation, not only to create a peritoneal window just beneath the left ovarian hilus, as previously described, but also to perform an ovarian incision along the longitudinal ovarian axis. The edges of the window and the ovarian incision were coagulated in order to induce neovascularization in this area.

Knowing from experimental data that the ovary itself, even if atrophic, may be an ideal site for reimplantation, we decided to prepare simultaneously two sites for reimplantation^{16,17} (and Dolmans *et al.*, personal communication).

A biopsy measuring 0.5 cm in size was taken from the left atrophic ovary (1.5 × 1 cm in size). A second laparoscopy was carried out 8 days later. It was decided to thaw only part of the cryopreserved tissue. Forty cubes were thawed according to the previously described technique, and immediately transferred to the operating

theater. We placed 15 cubes in the peritoneal window and 24 cubes in the intraovarian area (Figure 27.7).

Results

On the day of reimplantation, the left ovary was atrophic, but the intraovarian area, which had been incised and slightly coagulated, demonstrated an extensive vascular network. Angiogenesis was less pronounced in the area of the peritoneal window.

No primordial follicles were found in serial sections of the biopsy of 0.5 cm in size taken from the left atrophic ovary. This biopsy from an atrophic ovary (measuring 1 × 1.5 cm) must be considered representative, since it corresponds to about 10% of the residual value.

From the day of reimplantation to 4 months later, FSH, LH and 17 β -estradiol levels ranged from 32 to 45 mIU/ml (FSH), 15 to 22 mIU/ml (LH) and 10 to 14 pg/ml (17 β -estradiol) (Figure 27.8). At 4.5 months, FSH and LH concentrations decreased to 20.8 and 10.2 mIU/ml, respectively, while the 17 β -estradiol level rose to 58 pg/ml. Ultrasonography demonstrated the presence of an intraovarian follicle of 9.2 mm, which grew to 14 mm (Figure

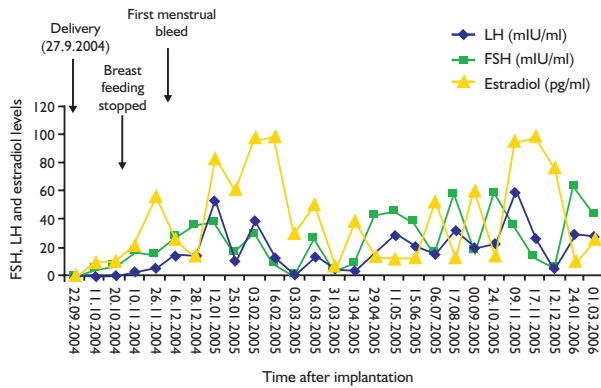


Figure 27.8 Follicle stimulating hormone (FSH), luteinizing hormone (LH) and 17 β -estradiol levels of patient 2

27.9a). Three days later, sequential serum concentrations of LH demonstrated a peak, leading to the development of a corpus luteum of 21.2 mm in size (Figure 27.9b). The luteal phase was confirmed by a progesterone level of 6.5 ng/ml. During the luteal phase, FSH and LH concentrations decreased to 15 and 10 mIU/ml, respectively. The patient menstruated 14 days after the LH peak.

After this first cycle, FSH levels rose to 34 mIU/ml for 6 weeks, concomitant with 17 β -estradiol levels of \leq 15 pg/ml. Thereafter, 17 β -estradiol concentrations rose from 15 to 42 pg/ml, concomitant with a decrease in FSH, which nevertheless remained at around 20 mIU/ml. Ultrasonography revealed the presence of two small intraovarian follicles, which achieved a maximum size of 11 mm. The patient experienced menstrual bleeding.

Following this cycle, FSH and 17 β -estradiol values returned to castrated levels, 35.2 mIU/ml and 11 pg/ml, respectively, for another 4–5 weeks, before hormone measurements and ultrasound proved the presence of follicular maturation. Indeed, the 17 β -estradiol level increased to 53 pg/ml and the FSH concentration decreased to 18.2 mIU/ml. Ultrasound revealed a follicle of 16 mm in size emerging from the tissue grafted into the peritoneal window, close to the ovary, but clearly separated from it. After these three cycles, FSH and LH values returned to castrated levels. No ovarian activity was detected, and a second transplantation was recently carried out.

Patient 3

A third transplantation of cryopreserved tissue was carried out in June 2005.

A patient of 25 years of age presented with a clinical diagnosis of stage IIIa Hodgkin's disease. She received ABVD (doxorubicin, bleomycin, vinblastine, dacarbazine) chemotherapy in November 1997. In April 1998, a relapse was diagnosed, and ovarian tissue cryopreservation was carried out by means of a left oophorectomy. In May 1998,

she received MOPP chemotherapy and total body irradiation before peripheral stem cell transplantation.

As complications, the patient presented with vascular necrosis of the left knee and both hips, alveolitis and premature ovarian failure (FSH 72 mIU/ml).

With the agreement of both the oncology department and the ethics committee, the reimplantation of five pieces ($\sim 1 \times 0.5$ cm) of frozen–thawed ovarian tissue was carried out on the medulla of the remaining ovary (Figure 27.10). At the time of reimplantation, Ovidol[®] and gonadotropin-releasing hormone (GnRH) antagonists were given.

Five months after reimplantation, LH and FSH were still at castrated levels. Six months after reimplantation, we observed the first follicular maturation (to a size of 20 mm) and an increase of estradiol level to 194 pg/ml.

DISCUSSION

Unfortunately, in most female cancer patients, aggressive chemotherapy and radiotherapy lead to ovarian failure. The restoration of ovarian function after such treatment has two main goals: to improve quality of life and restore reproductive function. For patients who need immediate chemotherapy, ovarian tissue cryopreservation, undertaken before cancer treatment starts, could be a means of preserving fertility without delaying the initiation of chemotherapy. However, one major concern surrounding the use of ovarian cortical strips for orthotopic auto-transplantation is the potential risk that the frozen–thawed ovarian cortex might harbor malignant cells, which could induce recurrence of disease after reimplantation. Shaw *et al.*¹⁸ reported that ovarian grafts from AKR mice (a strain with high incidence of spontaneous T cell lymphomas) could transfer lymphoma to recipient animals. Nevertheless, findings of other studies have suggested that ovarian tissue transplantation in Hodgkin's disease is safe^{19–21}.

In our study, the histological assessment of ovarian cortex before and after reimplantation found no evidence of disease. However, confirmation of the absence of malignant cells by light microscopy might not be sufficient, especially in other types of cancer (e.g. hematogenous or systemic neoplasms)²². Screening methods to detect minimal residual disease must be developed to eliminate the risk of cancer cell transmission with reimplantation⁵.

To date, ovarian tissue has been successfully cryopreserved and transplanted in rodents, sheep and marmoset monkeys^{11,23,24}. Successful fertilization and pregnancy has been described²⁵ after egg collection from fresh transplanted ovarian tissue in a primate: the grafted tissue functioned without any surgical connection to major blood vessels. Experimental studies have indicated that the fall in number of primordial follicles in grafted tissue is due to hypoxia, and the delay before reimplanted cortical tissue becomes revascularized. The loss of primordial

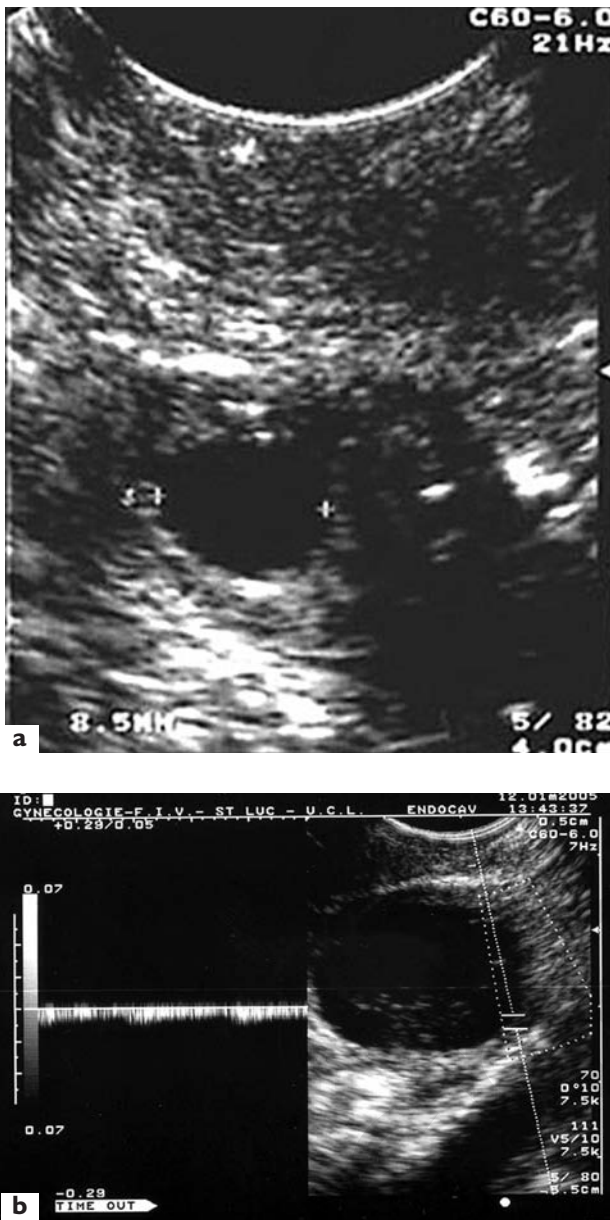


Figure 27.9 (a) Four and a half months after reimplantation, ultrasonography demonstrated the presence of a follicle of 9.2 mm in size, which reached 14 mm 3 days before the luteinizing hormone peak. (b) One week later, a corpus luteum of 21.2 mm was clearly visible, concomitant with the presence of a serum progesterone level of 6.5 ng/ml

follicles in cryopreserved ovarian tissue after transplantation is estimated to be 50–65% in some studies^{7,26,27}. In one trial, in which ovarian cortex was grafted onto the uterine horn and under the skin, the loss was more than 90%²⁸.

Oktay *et al.*¹¹ suggested that oocyte quality might be compromised by transplantation to a heterotopic site. Indeed, they only obtained a four-cell embryo from 20 oocytes retrieved from tissue transplanted under the skin

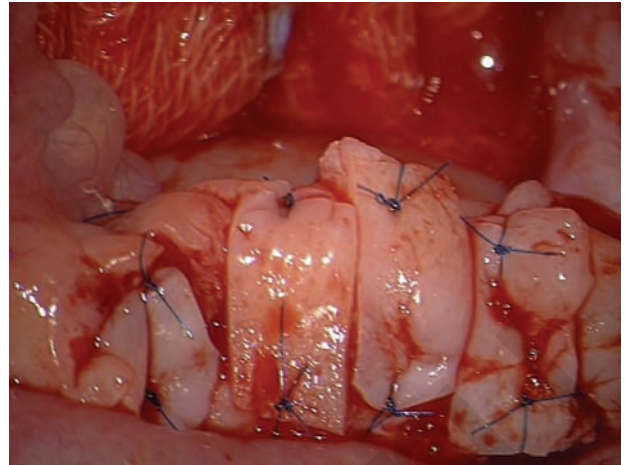


Figure 27.10 Five pieces of cryopreserved ovarian tissue were sutured to the medulla of the remaining ovary

of the abdomen. Temperature and pressure changes in the subcutaneous space could damage oocytes.

We have previously shown that peritoneal tissue is superior to subcutaneous tissue as a site of transplantation, with the loss of fewer follicles in peritoneal tissue¹⁰. Our model also showed effective revascularization in the peritoneal layer, and led us to propose orthotopic transplantation. In the first three cases we describe, vaginal echography and laparoscopy revealed a follicular structure 5 months after frozen–thawed ovarian tissue transplantation. The grafted tissue was biopsied, and histological analysis and fluorescent probe staining revealed the presence of viable primordial follicles and a follicular structure with inhibin A-marked cells. Follicles at an early growth stage need more than 85 days to reach the antral stage²⁹. Primordial follicles obviously need even more. The appearance of the first follicle in the grafted tissue 5 months after reimplantation in patients 1, 2 and 3 is totally consistent with the expected time course. This time interval observed in our study between the implantation of cortical tissue and the first estradiol peak (5 months) is also consistent with data obtained from sheep and human-beings^{10,27}.

The relatively high level of FSH (>20 mIU/ml) must be associated with a decline in inhibin secretion, as suggested by the sheep model^{30,31}, or with slower follicular growth from a poor follicular reserve in the graft. Indeed, because of the loss of primordial follicles in the transplants, the follicular density was low, but in any case, the total amount of cortical tissue transplanted is fairly unimportant. After transplantation, the patients would have been regarded as poor responders, because, of the 500–1000 primordial follicles that would have been transplanted, more than 50% would have been lost due to hypoxia²⁶.

Cryopreservation should not be reserved solely for women with malignant disease. Indeed, bone marrow transplantation (BMT) has been increasingly used for non-cancerous diseases in recent decades, but the high doses of

chemo- and/or radiotherapy given prior to BMT lead to ovarian failure in almost all cases, children and adults alike³². Indeed, the risk of premature ovarian failure has been estimated at 92% in a study by Meirow and Nugent¹⁴, and 100% in a study by Teinturier *et al.*³³.

A common non-total body irradiation conditioning protocol for BMT is the busulfan–cyclophosphamide (Bu–Cy) regimen. Our patient received this regimen, which was shown to induce premature ovarian failure in 98.6% of women treated with the ‘big’ Bu–Cy protocol (200 mg/kg Cy) and in 100% of women treated with decreasing doses (120 mg/kg)^{34,35}. This very high known risk of premature ovarian failure led us to remove an entire ovary instead of just cortical strips. As recently reviewed by Wallace *et al.*¹⁵, when the risk is low or moderate, we recommend the removal of cortical strips, as the fertility outcome is not predictable. Indeed, in these women, the chance of recovery of ovarian function is much higher.

In the present case, however, we decided to remove a whole ovary, even if generally we do not consider this procedure to be the best option, as one can never completely exclude the recovery of ovarian function after chemotherapy. Here, the removal of an entire ovary was justified, because premature ovarian failure was considered an inevitable consequence of the patient receiving high doses of two alkylating agents before bone marrow transplantation. The risk of premature ovarian failure was therefore estimated to be almost 100%.

The fall in the number of primordial follicles found in cryopreserved tissue ranges from 50–65% in some studies^{7,26,27} to more than 90% in one study²⁸. The loss of primordial follicles in grafted tissue is due to hypoxia, and the delay that occurs before the grafted tissue becomes revascularized. Although primordial follicles are more resistant to ischemia than are stromal cells, there is a correlation between ischemic tissue damage and the duration of ischemia³⁶. In an experimental model, Israely *et al.* analyzed angiogenic events following ovary xenotransplantation³⁷. The characterization of neovascularization by dynamic contrast-enhanced magnetic resonance imaging (MRI) revealed that functional vessels within the graft could be detected from day 7 onwards.

We should, nevertheless, bear in mind that follicle distribution is not homogeneous³⁸. Indeed, we and others^{38–40} have demonstrated large variations in follicle density from ovary to ovary, as well as within the same ovary, when multiple samples are examined. Primordial follicles are located in clusters, and are not equally distributed in the ovarian cortex. By extrapolation, in the present case, about 500 primordial follicles would have been transplanted, taking into account a loss of more than 50% owing to hypoxia^{1,26}.

Another very interesting finding was the persistence of relatively high FSH levels during the follicular phase. FSH levels remained as high as 22 mIU/ml during the follicular phase and decreased to 18 mIU/ml during the luteal phase.

As previously explained in the present paper, the number of surviving primordial follicles is relatively low, and these patients should be considered poor responders. Recently, Baird *et al.*⁴¹ also observed raised basal levels of FSH in the sheep model, and suggested that it was the consequence of a reduction in antral follicles and the secretion of inhibin A in the transplanted strip of cryopreserved ovarian cortex. In their opinion, the rate of recruitment may be accelerated after transplantation. Indeed, they observed a massive recruitment of primordial follicles, demonstrated by a higher proportion of growing follicles, in the first 2 months following grafting.

The return to an FSH level of more than 35 mIU/ml immediately after each menstrual bleed is one argument supporting the theory that some inhibitory mechanisms, such as inhibin A or anti-Müllerian hormone (AMH) normally produced by developing follicles in an intact ovary, are probably almost non-existent in transplanted tissue.

REFERENCES

1. Donnez J, Godin PA, Qu J, Nisolle M. Gonadal cryopreservation in the young patient with gynaecological malignancy. *Curr Opin Obstet Gynecol* 2000; 12: 1–9
2. Larsen EC, Schmiegelow K, Rechnitzer C, et al. Radiotherapy at a young age reduces uterine volume of childhood cancer survivors. *Acta Obstet Gynecol Scand* 2004; 83: 96–102
3. Blatt J. Pregnancy outcome in long-term survivors of childhood cancer. *Med Pediatr Oncol* 1999; 33: 29–33
4. Donnez J, Bassil S. Indications for cryopreservation of ovarian tissue. *Hum Reprod* 1998; 4: 248–59
5. Rao GD, Chian RC, Son WS, et al. Fertility preservation in women undergoing cancer treatment. *Lancet* 2004; 363: 1829–30
6. Gosden RG, Baird DT, Wade JC, Webb R. Restoration of fertility to oophorectomised sheep by ovarian autografts stored at -196°C . *Hum Reprod* 1994; 9: 597–603
7. Meirow D, Fasouliotis SJ, Nugent D, et al. Laparoscopic technique for obtaining ovarian cortical biopsy specimens for fertility conservation in patients with cancer. *Fertil Steril* 1999; 71: 948–51
8. Oktay K, Karlikaya G. Ovarian function after transplantation of frozen, banked autologous ovarian tissue. *N Engl J Med* 2000; 342: 1919
9. Oktay K, Economos K, Kan M, et al. Endocrine function and oocyte retrieval after autologous transplantation of ovarian cortical strips to the forearm. *JAMA* 2001; 286: 1490–3
10. Radford JA, Lieberman BA, Brison D, et al. Orthotopic reimplantation of cryopreserved ovarian cortical strips after high-dose chemotherapy for Hodgkin's lymphoma. *Lancet* 2001; 357: 1172–5

11. Oktay K, Buyuk E, Veeck L, et al. Embryo development after heterotopic transplantation of cryopreserved ovarian tissue. *Lancet* 2004; 363: 837–40
12. Cortvrintd R, Smits J. Fluorescent probes allow rapid and precise recording of follicle density and staging in human ovarian cortical biopsies. *Fertil Steril* 2001; 75: 588–93
13. Galant C, Berlière M, Dubois D, et al. Focal expression and final activity of matrix metalloproteinases may explain irregular dysfunctional endometrial bleeding. *Am J Pathol* 2004; 165: 83–94
14. Meirou D, Nugent D. The effects of radiotherapy and chemotherapy on female reproduction. *Hum Reprod Update* 2001; 7: 535–43
15. Wallace WH, Anderson RA, Irvine DS. Fertility preservation for young patients with cancer: who is at risk and what can be offered? *Lancet Oncol* 2005; 6: 209–18
16. Almodin CG, Minguetti-Câmara VC, Meister H, et al. Recovery of fertility after grafting of cryopreserved germinative tissue in female rabbits following radiotherapy. *Hum Reprod* 2004; 19: 1287–93
17. Donnez J, Dolmans MM, Demylle D, et al. Restoration of ovarian function after orthotopic (intraovarian and periovarian) transplantation of cryopreserved ovarian tissue in a woman treated by bone marrow transplantation for sickle cell anaemia: case report. *Hum Reprod* 2006; 21: 183–8
18. Shaw JM, Bowles J, Koopman P, et al. Fresh and cryopreserved ovarian tissue samples from donors with lymphoma transmit the cancer to graft recipients. *Hum Reprod* 1996; 11: 1668–73
19. Kim SS, Radford JA, Harris M, et al. Ovarian tissue harvested from lymphoma patients to preserve fertility may be safe for autotransplantation. *Hum Reprod* 2001; 16: 2056–60
20. Kim SS, Battaglia DE, Soules MR. The future of human ovarian cryopreservation and transplantation: fertility and beyond. *Fertil Steril* 2001; 75: 1049–56
21. Kim SS. Ovarian tissue banking for cancer patients: to do or not to do? *Hum Reprod* 2003; 18: 1759–61
22. Meirou D, Yehuda DB, Prus D, et al. Ovarian tissue banking in patients with Hodgkin's disease: is it safe? *Fertil Steril* 1998; 69: 996–98
23. Candy CJ, Wood MJ, Whittingham DG. Restoration of a normal reproductive lifespan after grafting of cryopreserved mouse ovaries. *Hum Reprod* 2000; 15: 1300–4
24. Candy CJ, Wood MJ, Whittingham DG. Follicular development in cryopreserved marmoset ovarian tissue after transplantation. *Hum Reprod* 1995; 10: 2334–8
25. Lee DM, Yeoman RR, Battaglia DE, et al. Live birth after ovarian tissue transplant. *Nature* 2004; 428: 137–8
26. Nisolle M, Casanas-Roux F, Qu J, et al. Histologic and ultrastructural evaluation of fresh and frozen-thawed human ovarian xenografts in nude mice. *Fertil Steril* 2000; 74: 122–9
27. Baird DT, Webb R, Campbell BK, et al. Long-term ovarian function in sheep after ovariectomy and transplantation of autografts stored at -196°C . *Endocrinology* 1999; 140: 462–71
28. Aubard Y, Piver P, Cognié Y, et al. Orthotopic and heterotopic autografts of frozen-thawed ovarian cortex in sheep. *Hum Reprod* 1999; 14: 2149–54
29. Gougeon A. Dynamics of follicular growth in the human: a model from preliminary results. *Hum Reprod* 1986; 1: 81–7
30. Callejo J, Salvador C, Miralles A, et al. Long-term ovarian function evaluation after autografting by implantation with fresh and frozen-thawed human ovarian tissue. *J Clin Endocrinol Metab* 2001; 86: 4489–94
31. Campbell BK, Telfer EE, Webb R, Baird DT. Ovarian autografts in sheep as a model for studying folliculogenesis. *Mol Cell Endocrinol* 2000; 163: 131–9
32. Meirou D, Levron J, Hardan I, et al. IVF and ovarian tissue cryopreservation as fertility preservation procedures in a patient recently exposed to chemotherapy. The ovaries do not respond to stimulation while transplanted tissue resumes function. *Fertil Steril* 2004; 82: 58
33. Teinturier C, Hartmann O, Valteau-Couanet D, et al. Ovarian function after autologous bone marrow transplantation in childhood: high-dose busulfan is a major cause of ovarian failure. *Bone Marrow Transplant* 1998; 22: 989–94
34. Saunders JE, Hawley J, Levy W, et al. Pregnancies following high dose cyclophosphamide with or without high dose busulfan or total body irradiation and one marrow transplant. *Blood* 1996; 87: 3045–52
35. Grigg AP, McLachlan R, Zaja J, Szer J. Reproductive status in long-term bone marrow transplant survivors receiving busulfan-cyclophosphamide (120 mg/kg). *Bone Marrow Transplant* 2000; 26: 1089–95
36. Kim SS, Yang HW, Kang HG, et al. Quantitative assessment of ischemic tissue damage in ovarian cortical tissue with or without antioxidant (ascorbic acid) treatment. *Fertil Steril* 2004; 82: 679–85
37. Israely T, Dafni H, Nevo N, et al. Angiogenesis in ectopic xenotransplantation: multiparameter characterization of the neovasculature by dynamic contrast-enhanced MRI. *Magn Reson Med* 2004; 52: 741–50
38. Qu J, Godin PA, Donnez J. Expression of transforming growth factor- α , epidermal growth factor and epidermal growth factor receptor in follicles of human ovarian tissue before and after cryopreservation. *Fertil Steril* 2000; 74: 113–21
39. Schmidt KL, Byskow AG, Nyboe AA, et al. Density and distribution of primordial follicles in single pieces of cortex from 21 patients and in individual pieces of cortex from three patients using xenografting. *Hum Reprod* 2003; 18: 1158–64
40. Lass A. Assessment of ovarian reserve: is there still a role for ovarian biopsy in the light of new data? *Hum Reprod* 2004; 19: 467–9
41. Baird DT, Campbell B, de Souza C, Telfer E. Long-term ovarian function in sheep after ovariectomy and autotransplantation of cryopreserved cortical strips.

akusher-lib.ru

Ovarian tissue cryopreservation and existing alternatives

M M Dolmans, B Martinez-Madrid, A Van Langendonck, A Camboni, D Demylle, J Donnez

INTRODUCTION: FERTILITY PRESERVATION IN CANCER PATIENTS – DIFFERENT CRYOPRESERVATION OPTIONS

Advances in the diagnosis and treatment of childhood, adolescent and adult cancer have greatly enhanced the life expectancy of premenopausal women with cancer. As a result, there is a growing population of adolescent and adult long-term survivors of childhood malignancies¹. For the majority of women, ovarian damage caused by radiotherapy and/or chemotherapy will result in a premature menopause.

A number of options are currently available to preserve fertility in cancer patients, and give them the opportunity to become mothers when they have overcome cancer: embryo cryopreservation, oocyte cryopreservation or ovarian tissue cryopreservation^{2,3}. The choice of the most suitable strategy for preserving fertility depends on different parameters: the type and timing of chemotherapy, the type of cancer, the patient's age and the partner status.

The only established method of fertility preservation is embryo cryopreservation⁴, but this option requires the patient to be of pubertal age, have a partner or use donor sperm, and be able to undergo a cycle of ovarian stimulation, which is not possible when the chemotherapy has to be initiated immediately or when stimulation is contraindicated according to the type of cancer. The cryopreservation of oocytes can be performed in single women who can undergo a stimulation cycle, although the effectiveness of this technique is very low, with pregnancy and delivery rates from just 1 to 5% per frozen oocyte⁵. The cryopreservation of ovarian tissue is the only option for prepubertal girls, and for women who cannot delay the start of chemotherapy. Ovarian tissue can be frozen in three different forms: as fragments of ovarian cortex, as the entire ovary with its vascular pedicle or as isolated follicles. Ovarian cryopreservation and transplantation procedures have so far been almost exclusively limited to avascular cortical fragments, in both experimental and clinical studies, and, for now, this is the only procedure that has yielded live births in humans after autologous transplantation^{6,7}.

Advances in reproductive technology have made fertility preservation techniques a real possibility for patients whose gonadal function is threatened by

premature menopause, or by treatments such as radiotherapy, chemotherapy or surgical castration.

Decision-making in this area is particularly difficult because of the experimental nature of some of these techniques. With the continual development and optimization of these techniques, however, it may one day be possible to offer an individualized approach to management⁸. We first describe the technique of embryo cryopreservation and then investigate the more experimental techniques of cryopreservation of oocytes and ovarian tissue (isolated follicles, fragments or whole ovary)⁹.

EMBRYO CRYOPRESERVATION

Embryo cryopreservation has become a routine technique in all *in vitro* fertilization (IVF) centers, and has proven efficacy in terms of pregnancy and 'take-home-baby' rates. Although this method has already been used for young cancer patients¹⁰, there are significant drawbacks to its use.

First, medical reasons might impede its application if (1) the beginning of cancer treatment cannot be delayed and there is no time to complete ovarian stimulation, or (2) the stimulation procedure might be (theoretically) harmful to patients with hormone-sensitive tumors, such as breast cancer. Even if IVF can theoretically be undertaken on the basis of a spontaneous ovarian cycle¹¹, the small number of obtainable oocytes (and subsequently viable embryos for transfer) makes it extremely unlikely that any live births will be obtained in these conditions. Recently, tamoxifen and letrozole have been employed to stimulate the ovaries for IVF and embryo cryopreservation with some success, whilst possibly providing a safe alternative to traditional ovarian stimulation methods in these patients^{12,13}.

Second, the partner status of the patient may also impede embryo cryopreservation. If the patient has no partner or is an adolescent, the only available solution is using donor sperm to ensure fertilization of her oocytes. Finally, this technique is inappropriate for children, who have not reached puberty.

In conclusion, embryo cryopreservation is an efficient technique, but only an option for patients from whom mature oocytes can be collected and who have a partner (or accept donor sperm).

OOCYTE CRYOPRESERVATION

Progress in clinical research has been slow in the area of oocyte freezing compared with other techniques in the field of assisted reproduction. Human oocyte cryopreservation is still often relegated to the research domain and regarded as an experimental technique, while other procedures have been rapidly incorporated into clinical practice¹⁴.

Oocyte cryopreservation is an alternative option in the case of patients with the same characteristics as those described above for embryo cryopreservation, but who are not with a partner and do not wish to use donated sperm. In this case, IVF of their oocytes to produce embryos to be frozen for future implantation is not possible. Thus, these oocytes must be cryopreserved, as either mature or immature oocytes.

Mature oocyte cryopreservation

Mature oocyte freezing appears to be the most logical way of storing female germ cells, comparable to the routinely performed sperm banking. It is an attractive option for women without a partner, if they have time to complete ovarian stimulation before cancer therapy. However, oocytes are not available in large numbers, and ovarian stimulation and oocyte collection is not applicable for young patients, especially children².

Still, this procedure has been largely disappointing. Since the first report of a live birth from a frozen oocyte¹⁵, the results of this procedure worldwide have been variable, with a reported success rate of < 2%, despite the improved success rate when combined with intracytoplasmic sperm injection (ICSI)¹⁶. Data on frozen-thawed mature oocytes from 21 studies in peer-reviewed journals were examined by Sonmezer and Oktay⁸, and they report a mean survival rate of 47%, a mean fertilization rate of 52.5% and a mean pregnancy rate per thawed oocyte of 1.52%.

There are three main reasons for these poor results. Indeed, the metaphase-II oocyte is a large and highly specialized cell which is extremely fragile. First, the zona pellucida hardens during the freezing process, probably as a consequence of premature exocytosis of the cortical granules. It could then act as a fence, impairing spermatozoon penetration and normal fertilization, although micromanipulation techniques (ICSI) can, to a certain extent, bypass this problem¹⁷⁻²⁰. Second, in the mature oocyte, the metaphase chromosomes are lined up by the meiotic spindle along the equatorial plate, but the spindle apparatus is easily damaged by intracellular ice formation during the freezing or thawing process. The cellular cooling process induces depolymerization of the meiotic spindle, which is a dynamic structure (microtubules being continually assembled at one of its ends, and separated at the other). The cell is thus at risk of losing chromosomes and suffering aneuploidy. This is the main reason why interest in mature oocyte cryopreservation has declined in clinical

use^{21,22}, although studies do not agree on the extent of the problem; some even argue that spindle alterations do not systematically imply the presence of stray chromosomes²³, and that a higher rate of aneuploidy is encountered in any IVF process. Third, the damage caused to the cytoskeleton is able to modify the organelles and molecular organization of the oocyte²⁴.

In conclusion, mature oocyte banking is still limited by its low success rate; oocytes are sensitive to chilling, often fail to survive freeze-thawing processes, and are susceptible to cytoskeletal damage and aneuploidy. Currently, even the most optimistic success rates offer patients only a slim chance of pregnancy if few oocytes are available²⁵. Ultra-rapid freezing with vitrification may offer advantages over conventional equilibrium cooling protocols, and needs to be investigated further. Despite the few promising studies of vitrification^{26,27}, even less is known about the potentially detrimental effects of vitrification when compared with conventional cryopreservation techniques²⁸, and, to date, slow freezing and rapid thawing is the protocol of choice for freezing human oocytes²⁹.

Immature oocyte cryopreservation and *in vitro* maturation

Oocytes at the diplotene stage of prophase I, or 'germinal vesicle (GV) stage', survive the cryopreservation procedure better than those frozen at the metaphase II stage³⁰. One could say that these oocytes, obtained from Graafian follicles, are 'competent but less fragile'. These cells have reached full size and complete meiotic competence, but have not yet resumed their maturation process and initiated their second metaphase. Although the risk of hardening of the zona pellucida or damage to the cytoskeleton cannot be avoided, the absence of a spindle guarantees the absence of cytogenetic anomalies during further cellular divisions.

Freezing immature oocytes followed by *in vitro* maturation thus offers practical and theoretical advantages²⁵, but this method is still suboptimal. Indeed, even though GV oocytes have a superior thawing survival rate and a lower incidence of meiotic spindle damage, the continued inefficiency of *in vitro* maturation protocols results in a final yield of mature oocytes that is similar to that obtained with cryopreserved metaphase II oocytes²⁸.

Although there are several reports of pregnancies achieved after *in vitro* maturation of fresh GV oocytes^{31,32}, only one live birth has resulted from an immature oocyte cryopreserved at the GV stage, with subsequent *in vitro* maturation³³. To date, this remains the only one reported. Frozen-thawed immature oocytes have to follow a process of *in vitro* maturation before they are ready to be fertilized. Oocyte maturation is considered as the reinitiation and completion of the first meiotic division from the germinal vesicle stage (prophase I) to metaphase II, and the accompanying cytoplasmic maturation phase for fertilization and

early embryonic development³⁴. Co-ordination of nuclear and cytoplasmic maturation *in vitro* has proved very difficult to achieve.

The oocyte in its immature state is surrounded by layers of granulosa cells, forming a structure called the cumulus–oocyte complex (COC). Nuclear and cytoplasmic maturation of human oocytes is a complex process, in which intercommunications between the oocyte and surrounding granulosa cells seem to play a crucial role^{35–40}. Therefore, apart from determining the conditions required for *in vitro* maturation, the possibility of using frozen immature oocytes depends on the ability to preserve not only the viability of the female gamete, but also the structural and functional integrity of the entire COC. Because cumulus cells and the oocyte are totally different, the development of adequate freezing protocols might involve major complications.

OVARIAN TISSUE CRYOPRESERVATION

Fragments of cortical ovarian tissue

Human ovarian tissue can be successfully cryopreserved, with good survival and function after thawing (Figures 28.1 and 28.2). Experimental animal studies carried out on ovarian tissue cryopreservation, resulting in live-born offspring, preceded the present freezing systems in humans⁴¹.

Adequate penetration of the cryoprotectant through the stroma and granulosa cells to the oocytes is necessary, while at the same time avoiding possible toxicity of the cryoprotectant. Ice crystal formation has to be minimized by choosing optimal freezing and thawing rates. The choice of cryoprotectant with optimal permeation but the lowest toxicity and the least ice crystal formation is specific to each cell and tissue type⁴². In the ovary, it is a compromise between the stroma and the follicles⁴¹. On the basis of current knowledge, the standard method for human ovarian cryopreservation is slow programmed freezing, using human serum albumin-containing medium, and propanediol, dimethylsulfoxide (DMSO) or ethylene glycol as cryoprotectant, combined or not with sucrose.

Following the success of animal experiments^{43,44}, reports have been published about ovarian tissue cryopreservation for cancer patients^{45–47}. The storage of ovarian tissue could provide a means of restoring long-term fertility to patients undergoing treatment that may irreversibly damage the oocyte population. There are a number of possible motives for banking ovarian tissue. It could be performed with a view to autotransplantation at a later date, or it may be a means of storing oocytes prior to their isolation and maturation *in vitro*. However, there are still considerable technical and biological hurdles to overcome, principally in the field of follicular maturation.

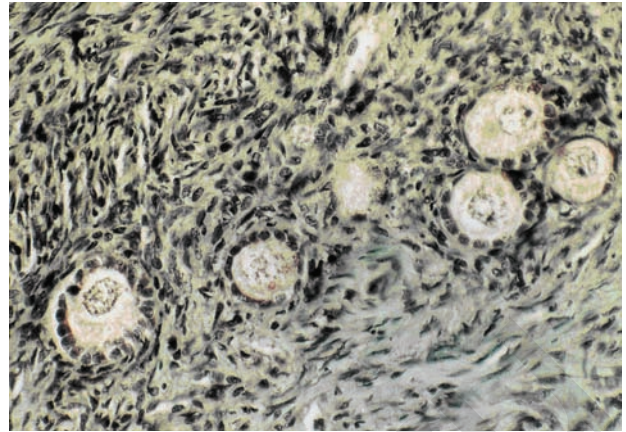


Figure 28.1 Primordial and primary follicle morphology in fresh ovarian tissue

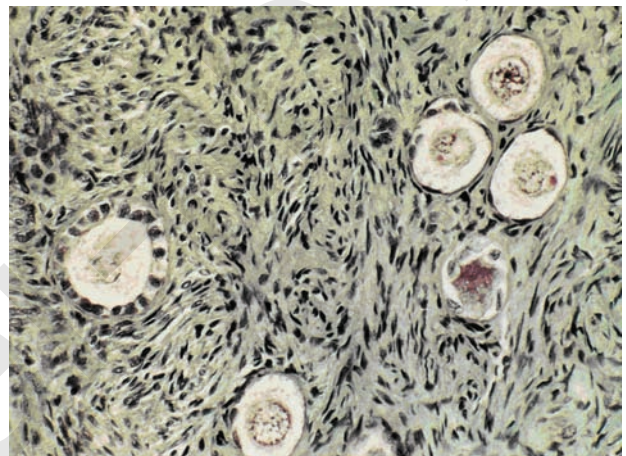


Figure 28.2 Primordial and primary follicle morphology in frozen–thawed ovarian tissue

To date, ovarian tissue has been successfully cryopreserved and transplanted into rodents, sheep and marmoset monkeys^{48,49}. Successful fertilization and pregnancy after egg collection from fresh transplanted ovarian tissue has been described in a primate⁵⁰: the grafted tissue functioned without any surgical connection to major blood vessels. Experimental studies have indicated that the fall in the number of primordial follicles in grafted tissue is due to hypoxia, and the delay before reimplanted cortical tissue becomes revascularized. The loss of primordial follicles in cryopreserved ovarian tissue after transplantation is estimated to be 50–65% in some studies.

Gook *et al.* showed the development of a metaphase II oocyte from frozen–thawed human ovarian cortical strips implanted in immunodeficient mice⁵¹.

In 2004, the first live birth after the orthotopic transplantation of cryopreserved ovarian tissue was reported in *The Lancet*⁶. Laparoscopy performed four and a half months after reimplantation demonstrated, by direct visualization, the development of a follicle from the grafted

tissue. Furthermore, on histological examination, the biopsy samples demonstrated not only the survival of primordial follicles in the grafted tissue, but also the maturation of a follicle (granulosa cells marked by inhibin A). These findings have opened up new perspectives for young cancer patients facing premature ovarian failure.

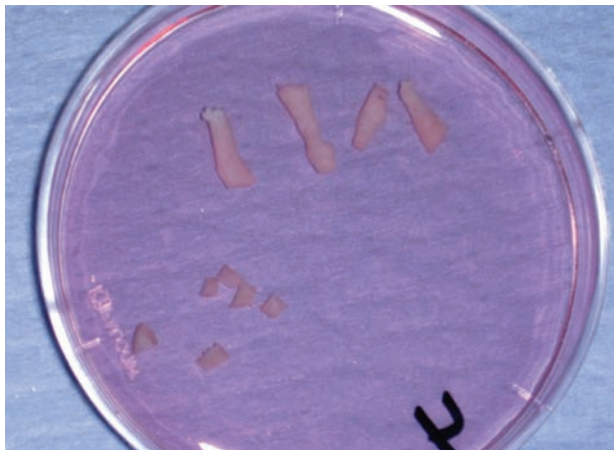

Figure 28.3 Ovarian cortical tissue (four strips and six fragments) prepared for cryopreservation

Table 28.1 Indications for cryopreservation of ovarian tissue in case of malignant disease

Extrapelvic diseases

Bone cancer (osteosarcoma – Ewing’s sarcoma)
Breast cancer
Melanoma
Neuroblastoma
Bowel malignancy

Pelvic diseases

Non-gynecological malignancy
 pelvic sarcoma
 sacroblastoma
 rhabdomyosarcoma
 sacral tumors
 rectosigmoid tumors
Gynecological malignancy
 early cervical carcinoma
 early vaginal carcinoma
 early vulvar carcinoma
 selected cases of ovarian carcinoma (stage IA)
 ovarian borderline tumors

Systemic disease

Hodgkin’s disease
non-Hodgkin’s lymphoma
leukemia
medulloblastoma

Retrieval and cryopreservation of ovarian tissue (Figure 28.3) is done prior to the initiation of cancer treatment with the aim of reimplanting the tissue once the patient is disease-free. With the latest advances in cryobiology, ovarian tissue cryopreservation is rapidly becoming a more widely offered technique by many medical centers around the world.

Oncological indications for ovarian tissue cryopreservation

In this field, there have been no major modifications since our review published in 1998⁵² (Table 28.1).

In the case of gynecological malignancies, a conservative fertility approach is only valuable if the uterus can be spared during surgery. This includes cases of early cervical carcinoma⁵³, early vaginal carcinoma⁵⁴, ovarian tumors of low malignancy^{55–57} and some selected cases of unilateral ovarian carcinoma (stage IA)^{52,58}. The choice of a possible conservative surgical approach in these patients, and the issue of implementing such treatment alone, remain controversial, and all the published results were obtained on the basis of retrospective studies and/or case reports. The fertility outcome is conditioned by the adjuvant therapy, i.e. local radiotherapy and/or chemotherapy. For chemotherapy, the risk appears to be dose- and age-dependent⁵⁹. Complete amenorrhea was reported after a dose of 5 g of cyclophosphamide in women over 40 years of age, and after doses of 9 g and 20 g in women of 30–40 and 20–30 years of age, respectively⁶⁰. A combination of various chemotherapeutic agents further increases gonadal toxicity.

For radiotherapy, it has been stated that a dose of 5–20 Gy administered to the ovary is sufficient to impair gonadal function completely⁶¹, whatever the age of the patient. The dose of radiation required to destroy 50% of oocytes has been found to be < 2 Gy⁶². Moreover, uterine irradiation at a young age reduces adult uterine volume⁶³. The practitioner should be aware of this effect of radiotherapy on the uterus, and also recognize that such patients may not be good candidates for ovarian tissue grafting.

The transmission of lymphoma via grafts of ovarian tissue from diseased donor mice to healthy recipients was reported by Shaw *et al.*⁶⁴. This study highlighted the risks of clinical transplantation of ovarian biopsy samples to women recovering from cancer, especially a blood-borne cancer^{64,65}. However, there are certain circumstances where the risk of cancerous involvement of the ovary is absent or minimal⁶⁶, and where autografting would present little or no danger^{67–69}. Future experiments should help us address questions about the relevance of replacing residual malignant cells with grafted tissue in such cases. Screening methods must be developed to eliminate the risk of cancer cell transmission with reimplantation. In some diseases, other options must be considered, such as the transplantation of isolated follicles. The survival of isolated follicles has recently been described in our depart-

ment⁷⁰. Nevertheless, the debate is ongoing, and the Practice Committee of the American Society for Reproductive Medicine (ASRM) has recently summarized some important points to be taken into consideration²⁸.

Isolated primordial follicles

The primordial follicle is resistant to cryoinjury, because the oocyte it contains has a relatively inactive metabolism, as well as a lack of metaphase spindle, zona pellucida and cortical granules. The small size of primordial follicles also greatly facilitates penetration of the cryoprotectant. Nevertheless, the procedure to isolate primordial follicles remains difficult, and, to date, it has not been possible to grow human isolated primordial follicles *in vitro* to the mature oocyte stage².

Although safe transplantation of ovarian tissue from lymphoma patients has been reported in severe combined immunodeficient (SCID) mice⁶⁹, the possibility of reintroducing tumor cells into cancer patients by autografting of ovarian tissue cannot be excluded. To avoid transferring malignant cells, ovarian tissue culture with *in vitro* follicle maturation could be performed. Culturing isolated follicles from the primordial stage is a particularly attractive proposition, since they represent >90% of the total follicular reserve and show high cryotolerance⁷¹. However, isolated primordial follicles do not grow properly in culture^{72,73} and further studies are clearly needed to identify factors sustaining follicular maturation and growth in humans⁷¹, and to assess the contribution of stromal cells to these processes. Encouraging results were achieved by Hovatta⁷⁴ when human primordial follicles were grown in organ culture. However, follicle isolation, or partial follicle isolation, severely impairs follicular viability in culture (Figure 28.4). After isolation, primordial and primary follicles degenerate within the first 24 h of

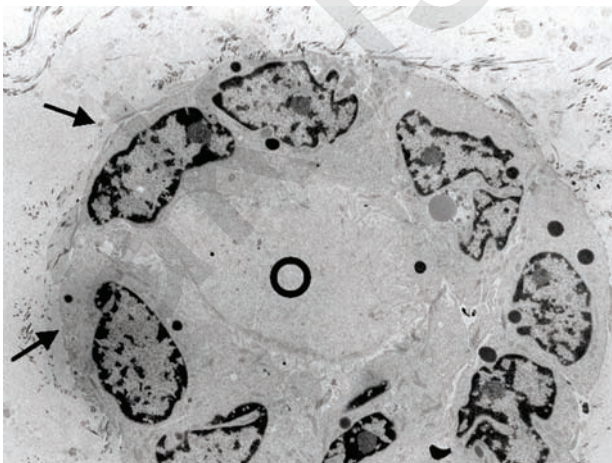


Figure 28.4 Fully isolated follicle analyzed by transmission electron microscopy. The oocyte (O) is surrounded by a single layer of cuboid follicular cells, bordered by a discontinuous basal lamina (arrows)

culture⁷³, and only more advanced, multilaminar preantral follicular stages can survive in short-term culture, a few reaching the early antral stage^{75,76}.

Another approach could be to transplant a suspension of isolated follicles. As the follicular basal lamina encapsulating the membrana granulosa excludes capillaries, white blood cells and nerve processes from the granulosa compartment⁷⁷, grafting fully isolated follicles could be considered safer. Moreover, this would allow the introduction of a high and known number of follicles into the host, obtaining faster angiogenesis and minimizing ischemic and reperfusion damage⁷⁸. The transplantation of frozen-thawed isolated primordial follicles has indeed been successfully achieved in mice⁷⁹, yielding normal offspring. For human primordial follicles, however, mechanical isolation is not possible due to their size (30–40 μm) and their fibrous and dense ovarian stroma, and therefore enzymatic digestion has to be used (see Chapter 29). In order to enhance the chances of follicular survival and reproductive function restoration, enzymatic digestion procedures for human ovarian tissue need to be optimized and standardized⁸⁰.

Whole ovary

One of the potential limitations of ovarian tissue cryopreservation and transplantation is the loss of a large proportion of follicles during the initial ischemia occurring after transplantation⁸¹. Previous studies have indicated that, whereas the loss due to freezing is relatively small, up to two-thirds of follicles are lost after transplantation^{82–84}. Reducing the ischemic interval between transplantation and revascularization is therefore essential to maintaining the viability and function of the graft. The best way to achieve this is by the transplantation of an intact ovary with vascular anastomosis, allowing immediate revascularization of the transplant.

Recently, Martinez-Madrid *et al.*⁸⁵ demonstrated a very high rate of primordial follicle survival after freeze-thawing of an entire human ovary (Figure 28.5). Bedaiwy and Falcone also reported restoration of ovarian function after the autotransplantation of intact frozen-thawed sheep ovaries with microvascular anastomosis⁸⁶.

Our results have led us seriously to consider proposing this option to women in the future, without running the risk of transmitting malignant cells via the graft after transplantation. Developing new cryochambers and improving protocols for whole ovary cryopreservation must be considered as vital directions in ongoing research to make transplantation of an entire ovary a feasible objective⁸⁷. The research and development of technology to cryopreserve whole organs, as well as surgical techniques for the autotransplantation of an ovary with its vascular pedicle, should be encouraged. This could lead to the transplantation of intact ovaries with microvascular anastomosis, carried out to restore immediate

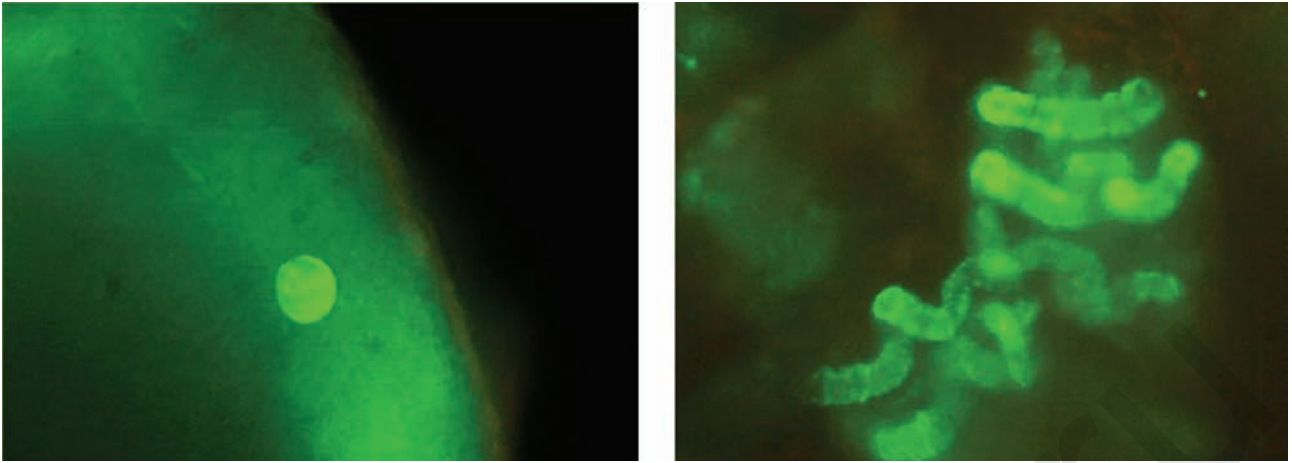


Figure 28.5 High survival rate of stromal cells, follicles and vessels in a cryopreserved whole ovary (viable cells are stained green with calcein-AM and dead cells are stained red with ethidium homodimer 1)

vascularization and minimize post-transplantation ischemia responsible for the reduction in follicular density.

CONCLUSION

The cryopreservation of ovarian tissue should be seriously considered for any patient undergoing treatment likely to impair future fertility, the indications being pelvic, extrapelvic and/or systemic diseases. The age of the patient should be taken into consideration, because the contents of the ovary are not the same in prepubertal and postpubertal women. Because a decline in fertility is now well documented after the age of 38 years, the procedure should probably be restricted to patients below this limit. In any case, irradiation and chemotherapy appear to be less harmful to the gonads of prepubertal than those of postpubertal women⁸⁸⁻⁹⁰.

There may be many potential indications for ovarian tissue cryopreservation. Indeed, careful evaluation of all the parameters, such as the type of disease, survival prognosis, age and the dose and type of treatment, should be carried out before candidate selection for such procedures. On the other hand, respecting the code of good practice, all patients who may become infertile have the right to receive proper consideration of their interests for future possibilities in the field of ovarian function preservation. The selection of cases should be carried out on the basis of a multidisciplinary staff discussion including oncologists, gynecologists, biologists, psychologists and pediatricians. Counseling should be given, and informed consent obtained from the patient.

We believe that it is preferable to remove only one ovary if possible, to avoid the psychological stress of surgical castration in a young patient, because cases of spontaneous pregnancy have been described after total body irradiation⁹¹⁻⁹³ and because, in many cases, the remaining ovary will be able to resume all endocrine

functions after some years. Moreover, the thousands of primary follicles that are contained in a single ovary of a young patient are more than sufficient to ensure fertility after cryopreservation.

After unilateral ovariectomy and/or cryopreservation of multiple cortical slices, different options are now available:

- Isolation of immature oocytes or preantral follicles and *in vitro* maturation to metaphase II oocytes
- Autotransplantation, either orthotopic with restoration of natural fertility⁶, or heterotopic, requiring ovarian stimulation and IVF⁹⁴
- Heterotransplantation in patients suffering from premature ovarian failure⁹⁵

It has been demonstrated that cryopreserved primordial follicles can survive after thawing, and that growth and maturation are possible under certain conditions. Research must now focus on the best way to use thawed tissue. It is probable that the answer lies in the use of culture environments adapted to each stage of follicular development. If autografting is the aim of cryopreservation of ovarian tissue, testing for malignant cells in the tissue must be carried out using adequate techniques. This is especially true for hematological malignancies. The idea of 'oocyte banking' is attractive, but it requires sustained efforts to achieve better results with ovarian tissue cryopreservation techniques and *in vitro* oocyte maturation procedures.

Live births obtained after transplantation of frozen-thawed ovarian tissue give hope to young cancer patients, but great efforts are still required in research programs in order to determine whether active angiogenesis can be induced to accelerate the process of neovascularization in grafted tissue, whether isolated human follicles can be grafted or indeed whether grafting an entire ovary with its vascular pedicle is a valuable option.

REFERENCES

1. Blatt J. Pregnancy outcome in long-term survivors of childhood cancer. *Med Pediatr Oncol* 1999; 33: 29–33
2. Torrents E, Boiso I, Barri PN, et al. Applications of ovarian tissue transplantation in experimental biology and medicine. *Hum Reprod Update* 2003; 9: 471–81
3. Donnez J, Dolmans MM, Martinez-Madrid B, et al. The role of cryopreservation for women prior to treatment of malignancy. *Curr Opin Obstet Gynecol* 2005; 17: 333–8
4. The Ethics Committee of the American Society for Reproductive Medicine. Fertility preservation and reproduction in cancer patients. *Fertil Steril* 2005; 83: 1622–8
5. Stachecki JJ, Cohen J. An overview of oocyte cryopreservation. *Reprod Biomed Online* 2004; 9: 152–63
6. Donnez J, Dolmans MM, Demylle D, et al. Livebirth after orthotopic transplantation of cryopreserved ovarian tissue. *Lancet* 2004; 364: 1405–10
7. Meirow D, Levron J, Eldar-Geva T, et al. Pregnancy after transplantation of cryopreserved ovarian tissue in a patient with ovarian failure after chemotherapy. *N Engl J Med* 2005; 353: 318–21
8. Sonmezer M, Oktay K. Fertility preservation in female patients. *Hum Reprod Update* 2004; 10: 251–66
9. Seli E, Tangir J. Fertility preservation options for female patients with malignancies. *Curr Opin Obstet Gynecol* 2005; 17: 299–308
10. Winkel CA, Fossum GT. Current reproductive technology: considerations for the oncologist. *Oncology (Huntingt)* 1993; 7: 40–51
11. Brown JR, Modell E, Obasaju M, et al. Natural cycle *in-vitro* fertilisation with embryo cryopreservation prior to chemotherapy for carcinoma of the breast. *Hum Reprod* 1996; 11: 197–9
12. Oktay K, Buyuk E, Davis O, et al. Fertility preservation in breast cancer patients: IVF and embryo cryopreservation after ovarian stimulation with tamoxifen. *Hum Reprod* 2003; 18: 90–5
13. Oktay K, Buyuk E, Libertalla N, et al. Fertility preservation in breast cancer patients: a prospective controlled comparison of ovarian stimulation with tamoxifen and letrozole for embryo cryopreservation. *J Clin Oncol* 2005; 23: 4347–53
14. Porcu E. Cryopreservation of oocytes: indications, risks and outcome. Abstracts of the 21st Annual Meeting of the European Society of Human Reproduction and Embryology. *Hum Reprod* 2005; 20 (Suppl 1): i50, O–137
15. Chen C. Pregnancy after human oocyte cryopreservation. *Lancet* 1986; 1: 884–6
16. Lutchman Singh K, Davies M, Chatterjee R. Fertility in female cancer survivors: pathophysiology, preservation and the role of ovarian reserve testing. *Hum Reprod Update* 2005; 11: 69–89
17. Porcu E, Fabbri R, Seracchioli R, et al. Birth of a healthy female after intracytoplasmic sperm injection of cryopreserved human oocytes. *Fertil Steril* 1997; 68: 724–6
18. Fabbri R, Porcu E, Marsella T, et al. Human oocyte cryopreservation: new perspectives regarding oocyte survival. *Hum Reprod* 2001; 16: 411–16
19. Nagy ZP, Cecile J, Liu J, et al. Pregnancy and birth after intracytoplasmic sperm injection of *in-vitro* matured germinal vesicle stage oocytes: case report. *Fertil Steril* 1996; 65: 1047–50
20. Gook DA, Schiewe MC, Osborn SM, et al. Intracytoplasmic sperm injection and embryo development of human oocytes cryopreserved using 1,2-propanediol. *Hum Reprod* 1995; 10: 2637–41
21. Pickering SJ, Braude PR, Johnson MH, et al. Transient cooling to room temperature can cause irreversible disruption of the meiotic spindle in the human oocyte. *Fertil Steril* 1990; 54: 102–8
22. Gook DA, Osborn SM, Johnston WI. Cryopreservation of mouse and human oocytes using 1,2-propanediol and the configuration of the meiotic spindle. *Hum Reprod* 1993; 8: 1101–9
23. Gook DA, Osborn SM, Bourne H, et al. Fertilization of human oocytes following cryopreservation: normal karyotypes and absence of stray chromosomes. *Hum Reprod* 1994; 9: 684–91
24. Vincent C, Johnson MH. Cooling, cryoprotectants, and the cytoskeleton of the mammalian oocyte. *Oxf Rev Reprod Biol* 1992; 14: 73–100
25. Gosden RG. Prospects for oocyte banking and *in vitro* maturation. *J Natl Cancer Inst Monogr* 2005; 34: 60–3
26. Yoon TK, Chung HM, Lim JM, et al. Pregnancy and delivery of healthy infants developed from vitrified oocytes in a stimulated *in vitro* fertilization–embryo transfer program. *Fertil Steril* 2000; 74: 180–1
28. Katayama KP, Stehlik J, Kuwayama M, et al. High survival rate of vitrified human oocytes results in clinical pregnancy. *Fertil Steril* 2003; 80: 223–4
28. The Practice Committee of the American Society for Reproductive Medicine. Ovarian tissue and oocyte cryopreservation. *Fertil Steril* 2004; 82: 993–8
29. Falcone T, Attaran M, Bedaiwy M, et al. Ovarian function preservation in the cancer patient. *Fertil Steril* 2004; 81: 243–57
30. Boiso I, Marti M, Santalo J, et al. A confocal microscopy analysis of the spindle and chromosome configurations of human oocytes cryopreserved at the germinal vesicle and metaphase II stage. *Hum Reprod* 2002; 17: 1885–91
31. Cha KY, Koo JJ, Ko JJ, et al. Pregnancy after *in vitro* fertilization of human follicular oocytes collected from nonstimulated cycles, their culture *in vitro* and their transfer in a donor oocyte program. *Fertil Steril* 1991; 55: 109–13
32. Trounson A, Wood C, Kausche A. *in vitro* maturation and the fertilization and developmental competence of oocytes recovered from untreated polycystic ovarian patients. *Fertil Steril* 1994; 62: 353–62
33. Tucker MJ, Wright GH, Morton PC, et al. Birth after cryopreservation of immature oocytes with subsequent *in vitro* maturation. *Fertil Steril* 1998; 70: 578–9

34. Cha KY, Chian RC. Maturation *in vitro* of immature human oocytes for clinical use. *Hum Reprod Update* 1998; 4: 103–20
35. Coticchio G, Bonu M, Borini A, et al. Oocyte cryopreservation: a biological perspective. *Eur J Obstet Gynecol Reprod Biol* 2004; 115S: S2–7
36. De Loos FA, Zeinstra E, Bevers MM. Follicular wall maintains meiotic arrest in bovine oocytes cultured *in vitro*. *Mol Reprod Dev* 1994; 39: 162–5
37. Kalous J, Sutovsky P, Rimkevics Z, et al. Pig membrana granulosa cells prevent resumption of meiosis in cattle oocytes. *Mol Reprod Dev* 1993; 34: 58–64
38. Isobe N, Maeda T, Terada T. Involvement of meiotic resumption in the disruption of gap junctions between cumulus cells attached to pig oocytes. *J Reprod Fertil* 1998; 113: 167–72
39. Dekel N, Beers WH. Development of rat oocytes *in vitro*: inhibition and induction of maturation in the presence or absence of cumulus–oophorus. *Dev Biol* 1980; 75: 247–54
40. Fagbohun CF, Downs SM. Metabolic coupling and ligand-stimulated meiotic maturation in the mouse oocyte–cumulus cell complex. *Biol Reprod* 1991; 45: 851–9
41. Hovatta O. Methods for cryopreservation of human ovarian tissue. *Reprod Biomed Online* 2005; 10: 729–34
42. Fuller B, Paynter S. Fundamentals of cryobiology in reproductive medicine. *Reprod Biomed Online* 2004; 9: 680–91
43. Gosden RG, Boulton M, Grant R, et al. Follicular development from ovarian xenografts in SCID mice. *J Reprod Fertil* 1994; 11: 619–23
44. Newton H, Aubard J, Rutherford A, et al. Low temperature storage and grafting of human ovarian tissue. *Hum Reprod* 1996; 11: 1487–91
45. Bahadur G, Steele SJ. Ovarian tissue cryopreservation for patients. *Hum Reprod* 1996; 11: 2215–16
46. Nugent D, Meirow D, Brook PF, et al. Transplantation in reproductive medicine: previous experience, present knowledge and future prospect. *Hum Reprod Update* 1997; 3: 267–80
47. Law C. Freezing ovary tissue may help cancer patients preserve fertility. *J Natl Cancer Inst* 1996; 88: 1184–5
48. Candy CJ, Wood MJ, Whittingham DG. Restoration of a normal reproductive lifespan after grafting of cryopreserved mouse ovaries. *Hum Reprod* 2000; 15: 1300–4
49. Candy CJ, Wood MJ, Whittingham DG. Follicular development in cryopreserved marmoset ovarian tissue after transplantation. *Hum Reprod* 1995; 10: 2334–8
50. Lee DM, Yeoman RR, Battaglia DE, et al. Live birth after ovarian tissue transplant. *Nature* 2004; 428: 137–8
51. Gook DA, Edgar DH, Borg J, et al. Oocyte maturation, follicle rupture and luteinization in human ovarian tissue following xenografting. *Hum Reprod* 2003; 18: 1772–81
52. Donnez J, Bassil S. Indications for cryopreservation of ovarian tissue. *Hum Reprod Update* 1998; 4: 248–59
53. Burnett AF, Roman LD, O'Meara AT, et al. Radical vaginal trachelectomy and pelvic lymphadenectomy for preservation of fertility in early cervical carcinoma. *Gynecol Oncol*. 2003; 88: 419–23
54. Hicks M, Piver M. Conservative surgery plus adjuvant therapy for vulvovaginal rhabdomyosarcoma diethylstilbestrol clear cell adenocarcinoma of the vagina and unilateral germ cell tumors of the ovary. *Obstet Gynecol Clin North Am* 1992; 19: 219–33
55. Tinelli R, Tinelli A, Tinelli FG, et al. Conservative surgery for borderline ovarian tumors: a review. *Gynecol Oncol* 2006; 100: 185–91
56. Boran N, Cil AP, Tulunay G, et al. Fertility and recurrence results of conservative surgery for borderline ovarian tumors. *Gynecol Oncol* 2005; 97: 845–51
57. Fauvet R, Poncelet C, Boccara J, et al. Fertility after conservative treatment for borderline ovarian tumors: a French multicenter study. *Fertil Steril* 2005; 83: 284–90
58. Kleine W. Results of fertility preserving operations in malignant ovarian tumors. *Zentralbl Gynakol* 1996; 18: 317–21
59. Meirow D, Nugent D. The effects of radiotherapy and chemotherapy on female reproduction. *Hum Reprod Update* 2001; 7: 534–43
60. Shalet S. Effects of cancer chemotherapy on gonadal function of patients. *Cancer Treat Rev* 1980; 7: 41
61. Wallace WH, Thomson AB, Saran F, et al. Predicting age of ovarian failure after radiation to a field that includes the ovaries. *Int J Radiat Oncol Biol Phys* 2005; 62: 738–44
62. Wallace WH, Thomson AB, Kelsey TW. The radiosensitivity of the human oocyte. *Hum Reprod* 2003; 18: 117–21
63. Larsen EC, Schmiegelow K, Rechnitzer C, et al. Radiotherapy at a young age reduces uterine volume of childhood cancer survivors. *Acta Obstet Gynecol Scand* 2004; 83: 96–102
64. Shaw SM, Bowles S, Koopman P, et al. Fresh and cryopreserved ovarian tissue samples from donors with lymphoma transmit the cancer to graft recipients. *Hum Reprod* 1996; 11: 1668–73
65. Shaw J, Trounson A. Oncological implications in the replacement of ovarian tissue. *Hum Reprod* 1997; 12: 403–5
66. Meirow D, Ben Yehuda D, Prus D, et al. Ovarian tissue banking in patients with Hodgkin's disease: is it safe? *Fertil Steril* 1998; 69: 996–8
67. Gosden RG, Rutherford AJ, Norfolk DR. Ovarian banking for cancer patients: transmission of malignant cells in ovarian grafts. *Hum Reprod* 1997; 12: 403–5
68. Moomjy M, Rosenwaks Z. Ovarian tissue cryopreservation: the time is now. Transplantation or *in vitro* maturation: the time awaits. *Fertil Steril* 1998; 69: 999–1000
69. Kim SS, Radford J, Harris M, et al. Ovarian tissue harvested from lymphoma patients to preserve ferti-

- ity may be safe for autotransplantation. *Hum Reprod* 2001; 16: 2056–60
70. Martinez-Madrid B, Dolmans MM, Van Langendonck A, et al. Ficoll density gradient method for recovery of isolated human ovarian primordial follicles. *Fertil Steril* 2004; 82: 1648–53
 71. Smitz JE, Cortvrindt RG. The earliest stages of folliculogenesis *in vitro*. *Reproduction* 2002; 123: 185–202
 72. Hovatta O, Wright C, Krausz T, et al. Human primordial, primary and secondary ovarian follicles in long-term culture: effect of partial isolation. *Hum Reprod* 1999; 14: 2519–24
 73. Abir R, Fisch B, Nitke S, et al. Morphological study of fully and partially isolated early human follicles. *Fertil Steril* 2001; 75: 41–6
 74. Hovatta O. Cryopreservation and culture of human ovarian cortical tissue containing early follicles. *Eur J Obstet Gynecol Reprod Biol* 2004; 5: 113 (Suppl 1): S50–4
 75. Roy SK, Treacy BJ. Isolation and long-term culture of human preantral follicles. *Fertil Steril* 1993; 59: 783–90
 76. Abir R, Franks S, Mobberley MA, et al. Mechanical isolation and *in vitro* growth of preantral and small antral human follicles. *Fertil Steril* 1997; 68: 682–8
 77. Rodgers RJ, Irving-Rodgers H, Russell DL. Extracellular matrix of the developing ovarian follicle. *Reproduction* 2003; 126: 415–24
 78. Laschke MW, Menger MD, Vollmar B. Ovariectomy improves neovascularization and microcirculation of freely transplanted ovarian follicles. *J Endocrinol* 2002; 172: 535–44
 79. Carroll J, Gosden RG. Transplantation of frozen-thawed mouse primordial follicles. *Hum Reprod* 1993; 8: 1163–7
 80. Dolmans MM, Michaux N, Camboni A, et al. Evaluation of Liberase, a purified enzyme blend, for the isolation of human primordial and primary ovarian follicles. *Hum Reprod* 2006; 21: 413–20
 81. Bedaiwy M. Strategies for fertility preservation and gonadal protection during gonadotoxic chemotherapy and radiotherapy. *Middle East Fertil Soc J* 2005; 10: 1–21
 82. Baird, DT, Webb R, Campbell BK, et al. Long-term ovarian function in sheep after ovariectomy and transplantation of autografts stored at -196°C . *Endocrinology* 1999; 140: 462–71
 83. Aubard Y. Ovarian tissue graft: from animal experiment to practice in human. *Eur J Obstet Gynecol Reprod Biol* 1999; 86: 1–3
 84. Nisolle M, Godin PA, Casanas-Roux F, et al. Histological and ultrastructural evaluation of fresh and frozen-thawed human ovarian xenografts in nude mice. *Fertil Steril* 2000; 74: 122–9
 85. Martinez-Madrid B, Dolmans MM, Van Langendonck A, et al. Freeze-thawing intact human ovary with its vascular pedicle with a passive cooling device. *Fertil Steril* 2004; 82: 1390–4
 86. Bedaiwy MA, Falcone T. Ovarian tissue banking for cancer patients. Reduction of post-transplantation ischaemic injury: intact ovary freezing and transplantation. *Hum Reprod* 2004; 19: 1242–4
 87. Donnez J, Martinez-Madrid B. Freeze-thawing intact human ovary with its vascular pedicle with a passive cooling device [Author reply to Bedaiwy and Falcone]. *Fertil Steril* 2005; 83: 1069–70
 88. Meirow D, Nugent D. The effects of radiotherapy and chemotherapy on female reproduction. *Hum Reprod Update* 2001; 7: 534–43
 89. Haie-Meder C, Mlika-Cabanne N, Michel G, et al. Radiotherapy after ovarian transposition: ovarian function and fertility preservation. *Int J Radiat Oncol Biol Phys* 1993; 25: 419–24
 90. Sanders J, Hawley J, Levy W, et al. Pregnancies following high-dose cyclophosphamide with or without high-dose busulfan or total body irradiation and bone marrow transplantation. *Blood* 1996; 87: 3045–52
 91. Dalle JH, Huot C, Duval M, et al. Successful pregnancies after bone marrow transplantation for Fanconi anemia. *Bone Marrow Transplant* 2004; 34: 1099–100
 92. Spinelly S, Chiodi S, Bacigalupo A, et al. Ovarian recovery after total body irradiation and allogeneic transplantation: long term follow-up of 79 females. *Bone Marrow Transplant* 1994; 14: 373–80
 93. Atkinson HG, Apperley JF, Dawson K, et al. Successful pregnancy after allogeneic bone marrow transplantation for chronic myeloid leukemia. *Lancet* 1994; 344: 199
 94. Oktay K, Buyuk E, Veeck L, et al. Embryo development after heterotopic transplantation of cryopreserved ovarian tissue. *Lancet* 2004; 363: 837–40
 95. Silber SJ, Lenahan KM, Levine DJ, et al. Ovarian transplantation between monozygotic twins discor-

akusher-lib.ru

Technical aspects of ovarian tissue cryopreservation

M M Dolmans, B Martinez-Madrid, A Van Langendonck, A Camboni, D Demylle and J Donnez

IN VITRO FERTILIZATION AND EMBRYO CRYOPRESERVATION

Cancer treatments may compromise fertility, and female cancer patients have few options for fertility preservation. Therefore, for those who have a steady partner, *in vitro* fertilization (IVF) with embryo cryopreservation is an applicable option. However, ovarian stimulation is time-consuming, and, in most cancer patients, chemotherapy cannot be delayed. For this reason, some centers offer IVF and embryo cryopreservation in the interval between two chemotherapy regimens (or cycles). We tried to establish whether IVF with embryo cryopreservation could be performed in the course of a chemotherapy treatment¹. To this end, we compared two groups of young cancer patients: women undergoing ovarian stimulation with embryo cryopreservation before chemotherapy, and those beginning ovarian stimulation immediately after 1–3 courses of chemotherapy. This latter group included all those suffering from hematological malignancies (acute myeloblastic or lymphoblastic leukemia). Indeed, in these patients, chemotherapy was started immediately after diagnosis and their oncologist referred them to our department for IVF and embryo cryopreservation during their remission phase before bone marrow transplantation.

Patients who received chemotherapy prior to IVF had a very poor response to ovarian stimulation, ranging from

a complete lack of ovarian response to just one embryo available for cryopreservation. Our study demonstrated that, even after one regimen of chemotherapy, the ovarian response was dramatically reduced despite high gonadotropin doses (Table 29.1). The acute toxicity of the chemotherapeutic treatment may explain the very poor results of ovarian stimulation².

In the group who underwent ovarian stimulation before chemotherapy, all the patients had significantly more embryos to cryopreserve, with at least four embryos per patient. Their quality (66.7% good-quality embryos) was comparable to the mean quality of all the embryos obtained in our IVF unit, including a majority from non-cancer patients³. The embryo stage at the time of freezing was found to correlate with the day of freezing, and corresponded well to normal developmental kinetics.

Even if studies of pregnancy outcome in cancer survivors show no increase in the malformation rate when these patients achieve pregnancy several years after chemotherapy^{4–6}, these results cannot be extrapolated to women who undergo IVF for embryo cryopreservation immediately after chemotherapy because, in long-term survivors, growing follicles were at the quiescent stage during previous chemotherapy.

IVF efficacy is thus dramatically reduced after chemotherapy, even after only one regimen. IVF should therefore be performed prior to chemotherapy. For those

Table 29.1 IVF outcome in cancer patients during (patients 1–4) or before (patients 5–11) chemotherapy¹

Patient	Age (years)	Pathology	Chemotherapy before IVF	E ₂ at hCG (pg/ml)	Ampules used	Oocytes	Cryopreserved embryos
1	32	NHL	1 regimen*	671	102	6	1
2	22	AML	2 regimens [†]	121	78	0	0
3	26	AML	2 regimens [†]	< 10	82	0	0
4	24	ALL	3 regimens [‡]	< 10	74	0	0
5	31	MA	0	2430	32	10	6
6	24	HL	0	2500	24	13	10
7	28	HL	0	2610	27	25	11
8	33	NHL	0	1202	24	8	5
9	25	BOT	0	6750	104	12	5
10	26	HL	0	1576	34	11	4
11	26	OC II	0	1540	63	9	4

*One regimen of ACVBP (adriamycin, cyclophosphamide, vincristine, bleomycin, prednisone); [†]Two regimens of cytarabine and idarubicin;

[‡]One regimen of COP followed by two regimens of COPADM (cyclophosphamide, oncovin, prednisone, adriamycin, methotrexate; ALL, acute lymphoblastic leukemia; AML, acute myeloblastic leukemia; BOT, borderline ovarian tumor; HL, Hodgkin's lymphoma; MA, medullar aplasia; NHL, non-Hodgkin's lymphoma; OC II, ovarian carcinoma, stage II; E₂, estradiol; hCG, human chorionic gonadotropin

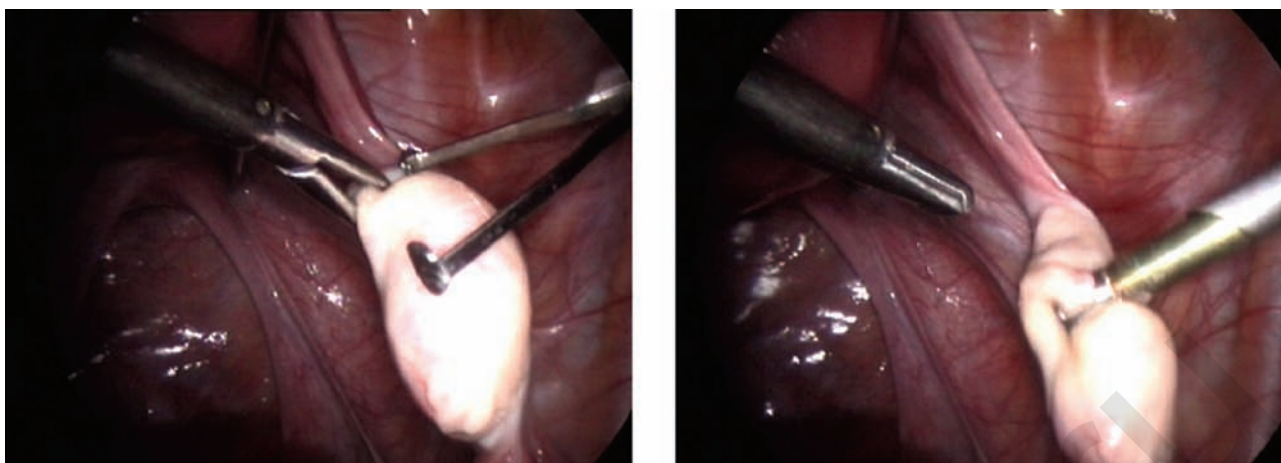


Figure 29.1 (a) and (b) Ovarian tissue biopsy using Palmer forceps

who require immediate chemotherapy, ovarian tissue cryopreservation and/or oocyte cryopreservation can be proposed before treatment.

Stimulation protocols

All cancer patients who undergo IVF with embryo cryopreservation are given a short stimulation protocol with down-regulation by either nasal buserelin spray or subcutaneous injections of triptorelin, 0.1 mg a day. On the third day following the start of down-regulation, ovarian stimulation is begun with daily injections of purified follicle stimulating hormone (FSH; Humegon®, Organon, Oss, The Netherlands). An adapted stimulation protocol is chosen according to age and individual ovarian reserve estimated by ultrasound. The starting dose of FSH varies between three and eight ampules (maximum dose) in our patients.

In vitro fertilization

Oocyte recovery, fertilization, embryo culture scoring and freezing are performed according to the protocols published by our team in 2001³. However, fertilization is always achieved by intracytoplasmic sperm injection (ICSI) to avoid the risk of no fertilization, as only one IVF attempt is authorized. All the embryos are frozen on day 2 or 3, depending on the day of pick-up, but regardless of quality.

OVARIAN TISSUE CRYOPRESERVATION

In most female cancer patients, aggressive chemotherapy and radiotherapy lead to ovarian failure. The restoration of ovarian function after chemotherapy or radiotherapy has two main goals: to improve quality of life and restore reproductive function. For patients who need immediate

chemotherapy, ovarian tissue cryopreservation, undertaken before cancer treatment, could be a means of preserving fertility without delaying the initiation of chemotherapy. The aim of this strategy is to reimplant ovarian tissue into the pelvic cavity⁷ (orthotopic site) or a heterotopic site (such as the forearm⁸) once treatment is completed and the patient is disease-free. The first live birth after orthotopic reimplantation of cryopreserved ovarian tissue was recently published in *The Lancet*⁷.

Ovarian biopsy sample

Ovarian tissue cryopreservation is undertaken before chemotherapy. Written informed consent is obtained from the patient or her parents if she is under 18 years of age. It is considered an emergency, and ovarian biopsy is performed as soon as possible in order not to delay the start of chemotherapy.

Follicles are located inside the ovarian cortex, and thus tissue samples collected for cryopreservation have to come from the surface of the organ. The biopsy can be taken during any gynecological procedure, by laparoscopy or laparotomy, and may be composed of one or several cortical fragments, or even a whole ovary, depending on the surgical indications and the risk of premature ovarian failure after the treatment. Nevertheless, if no widespread surgery (mainly the case in the treatment of pelvic malignancies) is needed, biopsies should be obtained by simple laparoscopy performed under general anesthesia. Palmer forceps⁹ (Figure 29.1) are inserted through one of the 5-mm trocars placed in the iliac fossa, and are used to grasp the ovary and cut a fragment from its surface. The cortical biopsy can also be easily done with laparoscopic scissors. The number of biopsies taken varies according to the size of the patient's ovaries and the estimated risk of premature ovarian failure. Indeed, premature ovarian failure after chemotherapy is dependent on age, drug used and dose given. Biopsy samples are immediately transferred to the

laboratory in Leibovitz L-15 medium supplemented with Glutamax™ (Invitrogen, Paisley, UK), on ice. To minimize any tissue damage due to ischemia, the samples are transferred within minutes to the laboratory for processing.

Freezing procedure

The whole procedure is performed on a laminar air-flux table, using sterile disposable materials, to ensure optimal sterility of the tissue fragments. The samples are transferred to a Petri dish containing a sterilized glass slide and 1–2 ml of L-15 medium. The tissue temperature is kept close to 4°C by placing the dish on top of a glass box containing crushed ice. The ovarian medulla is then separated from the cortex using forceps and surgical scissors, and disposed of. The remaining cortex is cut on the glass slide into strips of 2 × 6–8 mm. These strips are transferred into 2-ml cryovials (Simport, Quebec, Canada) containing 800 µl of L-15 medium and stored at 0°C in a cooler box (Nalgene® Labtop cooler, Cat. No. 5116-0032; Nalge Nunc International, Rochester, NY, USA), each of the tubes containing 2–5 strips. Two strips are randomly put aside and immersed in a 37% paraformaldehyde solution for histological examination. Leibovitz medium is then twice replaced by 800 µl of freshly prepared cryoprotective solution containing 88% L-15 medium, 2% human albumin 20% (Red Cross, Brussels, Belgium) and 10% dimethylsulfoxide (Sigma-Aldrich Co., Irvine, UK).

The freezing of ovarian tissue is carried out according to the protocol described by Gosden *et al*¹⁰.

The cryovials are cooled in a programmable freezer (Kryo 10, Series III; Planer, Sunbury-on-Thames, UK) as follows:

- At 0°C, place cryovials inside freezer, keep stable at 0°C for 15 min
- From 0 to –8°C, cool at a rate of –2°C/min
- Keep stable at –8°C for 8 min for soaking
- Seed manually (induction of the formation of ice crystals) by grasping the cryovials (for 5–10 s each) with forceps prechilled in liquid nitrogen (Figure 29.2)
- Keep stable at –8°C for 15 min
- From –8 to –40°C, cool at a rate of –0.3°C/min
- From –40 to –150°C, cool at a rate of –30°C/min

The cryovials are then transferred to liquid nitrogen (–196°C) for storage.

Thawing procedure

For thawing, the patient's cryovials are taken out of the liquid nitrogen, and left at room temperature for 2 min. Thawing is subsequently completed by immersing the cryovials in a warm (37°C) water bath for 2 min. The tissue

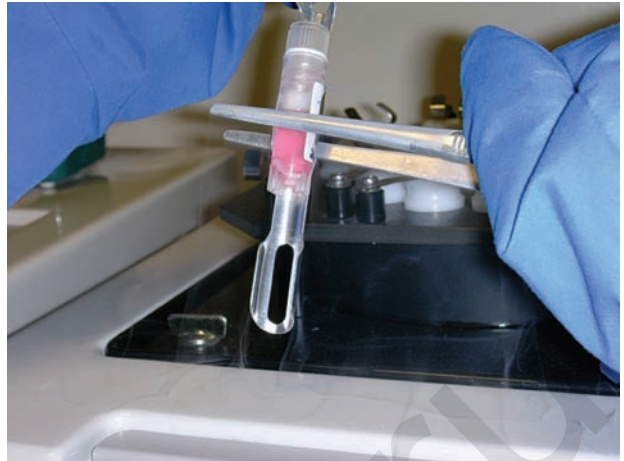


Figure 29.2 Manual seeding using prechilled forceps

samples are then grasped with small forceps and placed in a Petri dish containing L-15 medium, which is replaced three times (5 min each wash) to remove the cryoprotectant completely.

WHOLE OVARY FREEZING WITH ITS VASCULAR PEDICLE

Ovarian cryopreservation and transplantation procedures have so far been almost exclusively limited to avascular cortical fragments. These small cortical pieces are grafted without vascular anastomosis and are completely dependent on the establishment of neovascularization after grafting. Consequently, the cells in the graft undergo significant ischemic and reperfusion damage, which can induce a high rate of follicular loss^{11–13}. Therefore, reducing the ischemic interval between transplantation and revascularization is essential to maintaining the viability and function of the graft. The best way to achieve this is by transplantation of an intact ovary with vascular anastomosis, allowing immediate revascularization of the transplant.

Ovarian vascular transplantation has been successfully performed with intact fresh ovaries in rats^{14,15}, sheep¹⁶, monkeys¹⁷ and humans¹⁸. It appears that, in large mammals and humans, anastomosis of the ovarian pedicle is technically feasible, and more straightforward than the difficult surgical procedure required for ovarian transplantation in rats. However, in these species, cryopreserving such a large-sized intact ovary is problematic because of the difficulty of adequate diffusion of cryoprotective agents into large tissue masses, and because of vascular injury caused by intravascular ice formation. Nevertheless, successful vascular transplantation of intact frozen–thawed ovaries has been reported in rats, sheep^{19,20} and cows²⁰. However, because sheep ovaries are about one-tenth the size of human ovaries, problems related to heat and mass transfer during the freezing and thawing of human ovaries are presumed to be more marked.

Cryopreservation of intact ovary¹⁸

The ovary is removed *en bloc*, with its artery and veins attached. Dissection is carried out in order to identify a long vascular pedicle. In the operating room, the ovarian artery is cannulated, and the ovary is perfused with heparinized physiological solution and transported to the laboratory, where it is perfused and immersed in a bath containing a cryoprotective solution of 88% Leibovitz L-15 medium (Invitrogen), 10% dimethylsulfoxide (DMSO; Sigma, St Louis, MO, USA) and 2% human serum albumin 20% (Red Cross) for 5 min at 4°C (Figure 29.3). Ovarian perfusion is performed with a precalibrated pump (Terumo Corporation, Tokyo, Japan) to maintain a flow rate of 2.5 ml/min. The point of cannula insertion is marked with 8-0 sewing thread, and the ovary is placed in a cryovial where it is pre-equilibrated at 4°C in a bath with the cryoprotective solution for 10 min, with gentle shaking. After pre-equilibration, the cryovial containing the ovary is placed in a 5100 Cryo 1°C freezing container

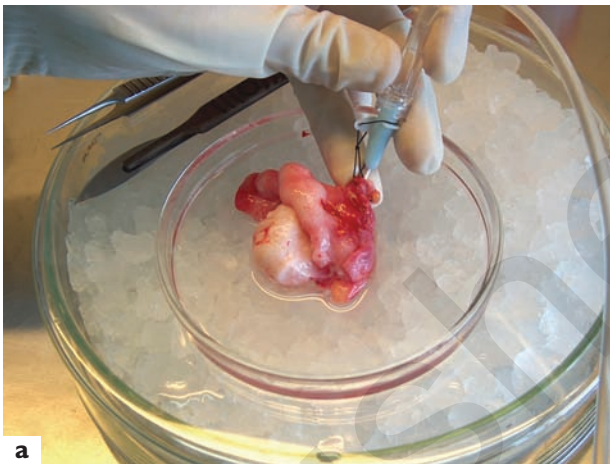


Figure 29.3 (a) Ovarian perfusion through the ovarian artery. (b) Passive cooling device (5100 Cryo 1°C freezing container)

(Nalgene) precooled at 4°C, and deposited in a –80°C freezer. This confers a cooling rate of –1°C/min. After 24 h in the –80°C freezer, the cryovial containing the ovary is transferred to liquid nitrogen.

Thawing of intact ovary

For thawing, the cryovial is directly transferred from the liquid nitrogen to a water bath at 60°C, where it is immersed until the ice melts. To remove the cryoprotectant, the ovary is bathed and perfused in three steps, for 10 min each at room temperature, with a reversed sucrose concentration gradient (0.25, 0.1 and 0 mol/l sucrose) in L-15 medium, to avoid osmotic injuries. It is perfused using the same flow rate as described earlier.

PRIMORDIAL FOLLICLE ISOLATION

Isolating primordial follicles (oocyte with a single layer of surrounding pregranulosa cells) can only be achieved by mechanical dissection or enzymatic digestion. For human primordial follicles, however, mechanical isolation is not possible due to their size (30–40 µm) and their fibrous and dense ovarian stroma. The only feasible method is enzymatic digestion, by incubating the follicles in proteolytic enzymes. Collagenase is currently used for the enzymatic isolation of ovarian follicles. Different types of collagenase (Ia, II, IX, XI) have been employed for this purpose, either alone or in combination with DNAase or mechanical isolation. However, the drawback of collagenase, which is a crude preparation derived from *Clostridium histolyticum*, is that it may contain high endotoxin levels, show substantial variations in effectiveness between batches and cause alterations in the basal lamina of the isolated follicles²², as well as oocyte extrusion²³. A new enzymatic digestion method for follicle isolation using the Liberase enzyme has recently been described, yielding good-quality isolated follicles²⁴. Obtaining good-quality isolated follicles is an absolute prerequisite for the further successful processing of these follicles, for either culture or transplantation.

Collection and dissection of ovarian tissue

An ovarian tissue biopsy is taken by laparoscopy and immediately transported from the operating room to the laboratory in HEPES-buffered Modified Eagle's Medium (HEPES-MEM) (Invitrogen), on ice. The medullar part is removed from the biopsy using surgical scissors. The cortical part is placed in a tissue sectioner (McIlwain Tissue Chopper; Mickle Laboratory, Guildford, UK), adjusted to 0.5 mm. The cutting procedure is swift (less than 5 min), and uniform-sized pieces of 0.5×0.5×1 mm are obtained.

Enzymatic digestion of ovarian tissue

The fragments are transferred to 50-ml conical tubes (Greiner Bio-One, Belgium) containing 10 ml of Dulbecco's phosphate-buffered saline (PBS) medium (Biochrom AG, Berlin, Germany) supplemented with tissue digestion enzymes. The concentrations used are 1 mg/ml collagenase type IA (Sigma) or 0.04 mg/ml Liberase blendzyme 3 (Roche, Indianapolis, USA). Incubation is then performed in a water bath at 37°C with gentle agitation for 60 min (collagenase) or 75 min (Liberase). The ovarian digest is shaken every 15 min with a pipette, to disrupt digested tissue mechanically. Digestion is terminated by the addition of an equal volume of PBS medium at 4°C supplemented with 10% fetal bovine serum (FBS) (Sigma).

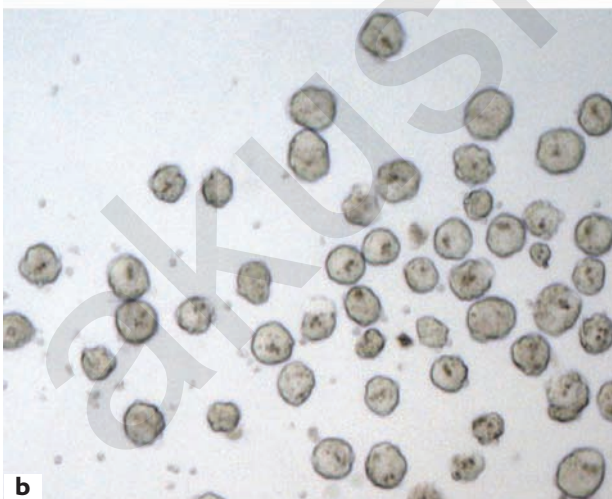
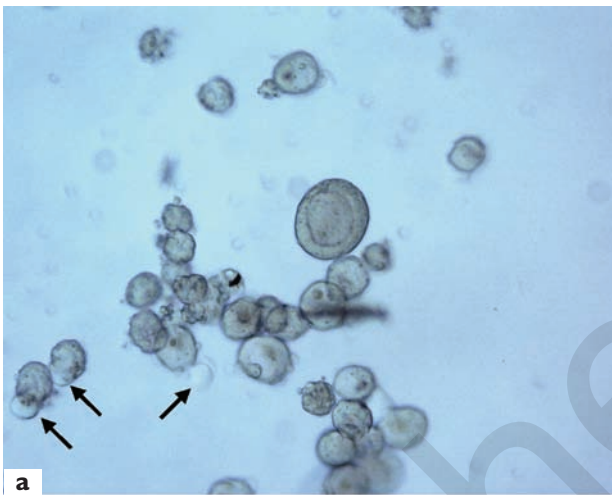


Figure 29.4 Enzymatically isolated human follicles. (a) Collagenase-isolated follicles, 30–100 μm in size, under the microscope. The arrows show three freshly extruded oocytes (original magnification $\times 200$). (b) Follicles fully isolated by Liberase digestion (original magnification $\times 200$)

Recovery of isolated follicles

After enzymatic digestion, the resulting suspension is centrifuged at 50 g for 10 min at 4°C. The supernatant is then discarded and the pellet further processed as described below.

The pellets are transferred to Petri dishes and investigated for follicles under a stereomicroscope (Leica, Leica Microsystems, Wetzlar, Germany). The follicles are picked up using a polycarbonate micropipette (Flexipet™ micromanipulation pipettes, 130 μm inner diameter; Cook Ob/Gyn, Spencer, IN, USA), taking care to avoid the stromal cells (Figure 29.4), and stored in PBS medium supplemented with 10% FBS at 4°C, where they are left until the process of follicular retrieval is complete.

REFERENCES

1. Dolmans MM, Demylle D, Martinez-Madrid B, Donnez J. Efficacy of an IVF attempt following chemotherapy. *Fertil Steril* 2005; 83: 897–901
2. Meirou D, Epstein M, Lewis H, et al. Administration of cyclophosphamide at different stages of follicular maturation in mice: effects on reproductive performance and fetal malformations. *Hum Reprod* 2001; 16: 632–7
3. Van Langendonck A, Demylle D, Wyns C, et al. Comparison of G1.2/G2.2 and Sydney IVF cleavage/blastocyst sequential media for the culture of human embryos: a prospective, randomized, comparative study. *Fertil Steril* 2001; 76: 1023–31
4. Arnon J, Meirou D, Lewis-Roness H, et al. Genetic and teratogenic effects of cancer treatments on gametes and embryos. *Hum Reprod Update* 2001; 7: 394–403
5. Blatt J. Pregnancy outcome in long-term survivors of childhood cancer. *Med Pediatr Oncol* 1999; 33: 29–33
6. Green DM, Fiorello A, Zevon MA, et al. Birth defects and childhood cancer in offspring of survivors of childhood cancer. *Arch Pediatr Adolesc Med* 1997; 151: 379–83
7. Donnez J, Dolmans MM, Demylle D, et al. Livebirth after orthotopic transplantation of cryopreserved ovarian tissue. *Lancet* 2004; 364: 1405–10
8. Oktay K, Economos K, Kan M, et al. Endocrine function and oocyte retrieval after autologous transplantation of ovarian cortical strips to the forearm. *JAMA* 2001; 286: 1490–3
9. Meirou D, Fasouliotis SJ, Nugent D, et al. Laparoscopic technique for obtaining ovarian cortical biopsy specimens for fertility conservation in patients with cancer. *Fertil Steril* 1999; 71: 948–51
10. Gosden RG, Baird DT, Wade JC et al. Restoration of fertility to oophorectomised sheep by ovarian autografts stored at -196°C . *Hum Reprod* 1994; 9: 597–60
11. Nisolle M, Casanas-Roux F, Qu J, et al. Histologic and ultrastructural evaluation of fresh and

- frozen-thawed human ovarian xenografts in nude mice. *Fertil Steril* 2000; 74: 122-9
12. Baird DT, Webb R, Campbell BK, et al. Long-term ovarian function in sheep after ovariectomy and transplantation of autografts stored at -196°C . *Endocrinology* 1999; 140: 462-71
 13. Demirci B, Salle B, Frappart L, et al. Morphological alterations and DNA fragmentation in oocytes from primordial and primary follicles after freezing-thawing of ovarian cortex in sheep. *Fertil Steril* 2002; 77: 595-600
 14. Wang X, Chen H, Yin H, et al. Fertility after intact ovary transplantation. *Nature* 2002; 415: 385
 15. Yin H, Wang X, Kim SS, et al. Transplantation of intact rat gonads using vascular anastomosis: effects of cryopreservation, ischemia and genotype. *Hum Reprod* 2003; 18: 1165-72
 16. Jeremias E, Bedaiwy MA, Gurunluoglu R, et al. Heterotopic autotransplantation of the ovary with microvascular anastomosis: a novel surgical technique. *Fertil Steril* 2002; 77: 1278-82
 17. Scott JR, Keye WR, Poulson AM, Reynolds WA. Microsurgical ovarian transplantation in the primate. *Fertil Steril* 1981; 36: 512-15
 18. Mhatre P, Mhatre J, Magotra R. Ovarian transplant: a new frontier. *Transplant Proc* 2005; 37: 1396-8
 19. Bedaiwy A, Jeremias E, Gurunluoglu R, et al. Restoration of ovarian function after autotransplantation of intact frozen-thawed sheep ovaries with microvascular anastomosis. *Fertil Steril* 2003; 79: 594-602
 20. Arav A. Animal models for whole ovary cryopreservation and transplantation. Invited presentation. In Program and Symposium Syllabus of the Workshop on Mammalian Oogenesis and Folliculogenesis: in vivo and in vitro approaches. European Society of Human Reproduction and Embryology, Frascati, Italy, 2003: 46
 21. Martinez-Madrid B, Dolmans MM, Van Langendonck A, et al. Freezing entire human ovaries with a passive cooling device. *Fertil Steril* 2004; 82: 1390-4
 22. Eppig JJ. Further reflections on culture systems for the growth of oocytes in vitro. *Hum Reprod* 1994; 9: 974-6
 23. Hovatta O, Wright C, Krausz T, et al. Human primordial, primary and secondary ovarian follicles in long-term culture: effect of partial isolation. *Hum Reprod* 1999; 14: 2519-24
 24. Dolmans MM, Michaux N, Camboni A, et al. Evaluation of Liberase, a purified enzyme blend, for the isolation of human primordial and primary ovarian follicles. *Hum Reprod* 2006; 21: 413-20

P Jadoul, J Squifflet, J Donnez

INTRODUCTION

Pelvic radiotherapy is frequently used to treat pelvic tumors in premenopausal women. It has already been stated that a dose of 5–20 Gy administered to the ovary is sufficient to impair gonadal function completely^{1–3}, whatever the age of the patient.

Ovarian transposition should be indicated in all women requiring radiotherapy for gynecological or non-gynecological malignancy.

All the indications for laparoscopic ovarian transposition should also be indications for ovarian tissue cryopreservation, and ovarian tissue-banking facilities should be available. Indeed, even if chemotherapy is not initially proposed to the patient, it must always be considered as a possibility after surgery which could impair gonadal function, even in a transposed ovary.

EFFECTS OF RADIOTHERAPY ON OVARIAN FUNCTION

Several procedures have been proposed^{1,4–6} to preserve ovarian function when radiotherapy is needed in the pelvis. In 1993, Haie-Meder *et al.*³ reported the outcome of ovarian preservation after lateral transposition in young women requiring radiotherapy with or without chemotherapy. In their study, the predictive factors of ovarian function preservation after radiotherapy were age, irradiation field and dose, and the association of chemotherapy.

Age and hormonal status at diagnosis

Age in itself is a predictive factor of ovarian function. The physiological decrease in the number of primordial follicles with age makes the ovaries more sensitive to any aggressive treatment, such as chemotherapy and/or radiotherapy. In patients treated for Hodgkin's disease, Schilsky *et al.*⁷ reported a significantly shorter time from diagnosis to amenorrhea in patients >25 years of age. Gradishar and Schilsky⁸ suggested that patients <25 years of age would not experience any significant therapy-related dysfunction for 5–10 years following the completion of chemotherapy.

From the literature published to date, it is impossible to determine whether the prepubertal ovary is less susceptible to the effects of irradiation than is the adult ovary. An alternative explanation for an apparently

increased resistance to damage of a young girl's ovary may simply be a reflection of the earlier age and larger number of oocytes within the ovary, rather than any effect of puberty. Furthermore, in addition to direct gonadal damage, irradiation may also affect the uterus, thus decreasing the chance of successfully carrying a pregnancy to full term.

Irradiation field and dose

Ovarian preservation according to the type of irradiation is determined by measurements on a phantom³. There is a significant difference in ovarian preservation according to the irradiation field. Pelvic irradiation and inverted irradiation carry the highest probability of ovarian failure (Table 30.1).

In cases of supradiaphragmatic irradiation, the risk of impairment of gonadal function is ~10%, while with infradiaphragmatic irradiation, this risk increases to 35%³. These percentages are dependent on the total dose and distribution of the dose administered. The risk of ovarian failure according to the dose of radiotherapy is summarized in Table 30.2.

Women who received a dose of ≤5 Gy of ovarian irradiation had a higher probability of ovarian function preservation than patients who received >5 Gy³. In addition to dose, age also has an impact on ovarian function preservation.

Lushbaugh and Casaren¹ suggested that the total dose inducing menopause was 6 Gy in women ≥40 years of age, while it could be as high as 20 Gy in girls. In the study by Haie-Meder *et al.*³, all the prepubescent girls became pubescent, while the same range of doses caused menopause in 32% of patients >25 years of age. The dose to the ovaries, however, was the most important predictive factor of ovarian function preservation (≤5 Gy vs. >5 Gy).

Table 30.1 Toxicity of radiotherapy according to irradiation field

Site of radiotherapy	Risk of premature ovarian failure (%)
Supradiaphragmatic	10
Infradiaphragmatic	35
Total body irradiation	>50

Table 30.2 Risk of ovarian failure according to the dose of radiotherapy

Ovarian dose (rads)	Results
60	No deleterious effect
150	No deleterious effect in young women Some risk for women >40 years
250–500	In women aged 15–40 years, 60% permanent POF In women >40 years, 100% permanent POF
500–800	In women aged 15–40 years, 60–70% permanent POF
>800	100% permanent POF

POF, premature ovarian failure

Association with chemotherapy

An association of radiotherapy and chemotherapy is indicated in many cancers, mostly arising during adolescence, including Hodgkin's disease, non-Hodgkin's lymphoma, leukemia, medulloblastoma and other systemic malignant conditions. In such cases, bone marrow transplantation may be indicated.

The most frequent chemotherapy combination is mechlorethamine, vincristine, procarbazine and prednisone (MOPP). When associated with radiotherapy, the incidence of ovarian function failure was found to be significantly higher than in patients who had other or no chemotherapy³.

OVARIAN TRANSPOSITION BEFORE RADIOTHERAPY

Iatrogenic destruction of the follicular reserve by radiation therapy may be avoided by ovarian transposition into the paracolic gutter. Ovarian transposition performed by laparotomy was first described by McCall *et al.* in 1958 in patients treated for cervical carcinoma⁹. Nowadays, ovarian suspension is laparoscopically performed before irradiation^{10–20}.

However, it has also been demonstrated that, even if ovarian transposition is performed, it cannot be considered completely safe, because patients receive infra-diaphragmatic irradiation²¹ and, in many cases, there is an association between radiation and chemotherapy^{4,21}. For women who are to receive chemotherapy and/or radiotherapy, not only ovarian transposition, but also cryopreservation of ovarian tissue should be proposed^{22,23}, even if *in vitro* maturation of oocytes has not yet been proved to be routinely effective after cryopreservation.

All patients need to be informed of the long-term consequences of cancer and its therapy, even if not all treatments cause infertility.

SURGICAL TECHNIQUE

The procedure is performed under general endotracheal anesthesia. After the induction of a pneumoperitoneum, a 12-mm trocar is inserted subumbilically. The laparoscope is connected to a video camera. Three 5-mm trocars are systematically inserted suprapubically: one in the midline approximately 3 cm above the symphysis pubis, and the other two a few centimeters on either side, taking care to avoid the epigastric vessels. The surgical procedure of laparoscopic ovarian transposition is identical to that performed by laparotomy. Usually, the right ovary is preferred for transposition because of easier access, as the bowel may be pushed out of the way. However, if radiotherapy is localized on the right, the left ovary is transposed. The right adnexa are grasped and mobilized. The isthmic portion of the tube and the utero-ovarian ligament are coagulated using bipolar forceps and cut off at their uterine origin (Figure 30.1). The peritoneum is incised along the infundibulopelvic ligament to mobilize the adnexa completely. The course of the ureter is visualized and care is taken to avoid damage to the ureter. Dissection of the infundibulopelvic vessels using bipolar coagulation and scissors is continued until adnexal transposition to the paracolic gutter is achieved, without any traction or torsion to the ovarian vascular pedicle (Figure 30.2). Using Vicryl® 1-0, the right ovary is anchored to the peritoneum of the anterior abdominal wall very high in the right paracolic gutter. In order to facilitate fixation of the ovary, a curved needle is inserted into the right lateral flank, in front of the desired anchoring of the ovary.

Titanium clips are placed on the two opposite borders of the ovary to allow radiological identification prior to radiotherapy (Figure 30.3). To avoid bowel incarceration between the transposed ovary and the abdominal wall, the vascular pedicle is attached to the anterolateral abdominal wall with three or four titanium clips.

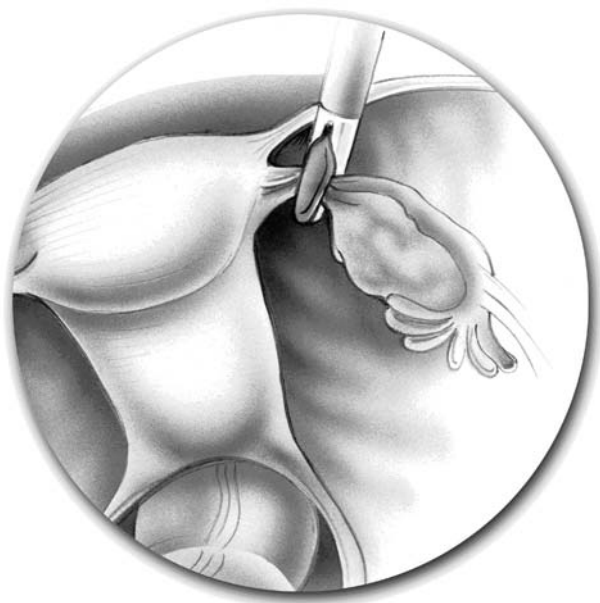


Figure 30.1 Coagulation of the proximal part of the adnexus

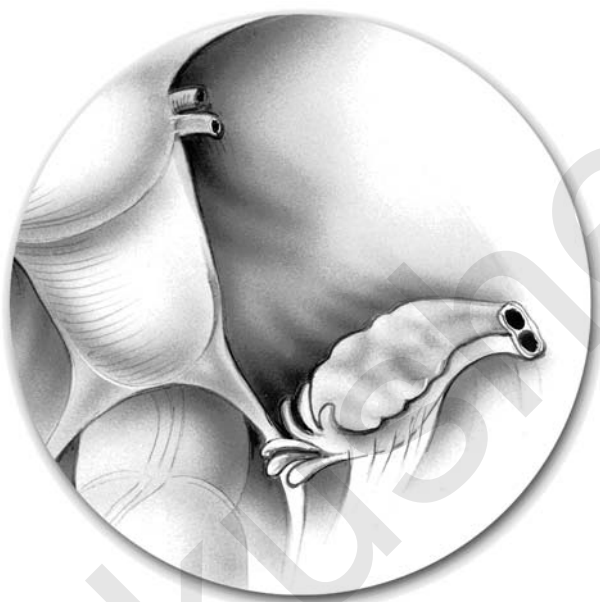


Figure 30.2 Adnexal transposition avoiding traction to the ovarian vascular pedicle

INDICATIONS

The classic indications for ovarian transposition in cases of malignant disease are summarized in Table 30.3.

In our department, ovarian cryopreservation has been available since April 1997, and has been performed in 180 patients suffering from different types of cancer. In this series of patients, five also underwent ovarian transposition because of the indication for radiotherapy. Ovarian

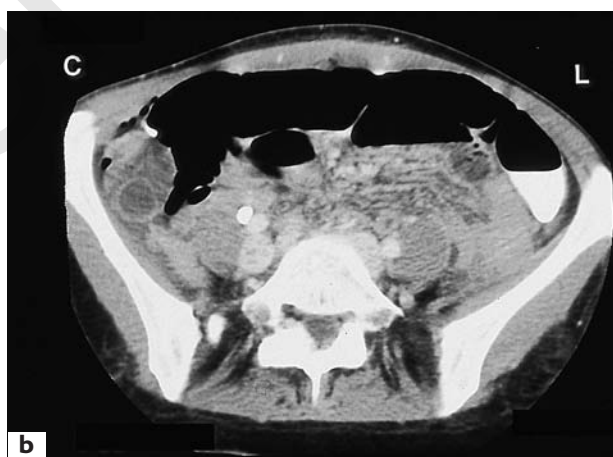
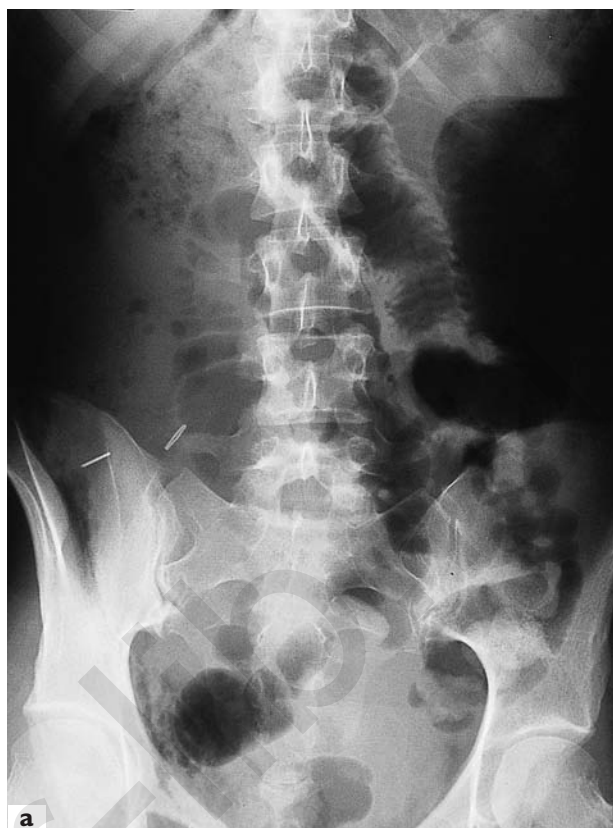
Figure 30.3 Postoperative identification of the transposed ovary before radiotherapy using (a) radiography and (b) computed tomography

transposition was performed laparoscopically in three cases, and by laparotomy in two. The indications for radiotherapy were two rectosigmoid tumors, one cervical carcinoma, one quadriceps liposarcoma and one medulloblastoma.

The main indication for ovarian transposition in gynecological malignancy is the detection of early cervical carcinoma. Transposition is usually performed during the surgical treatment of the cervical carcinoma.

Table 30.3 Indications for ovarian transposition in cases of malignant disease*Gynecological malignancy*

Early cervical carcinoma
 Early vaginal carcinoma
 Early vulvar carcinoma

Non-gynecological malignancy

Rectosigmoid tumor
 Pelvic or extrapelvic sarcoma
 Bone cancer (osteosarcoma, Ewing's sarcoma)
 Lymphoma
 Medulloblastoma

In cases of rectosigmoid tumors in young patients, laparoscopic ovarian transposition is usually performed before radiotherapy indicated to decrease tumor size, and before removal of the tumor.

OVARIAN FUNCTION AND FERTILITY AFTER OVARIAN TRANSPOSITION AND RADIOTHERAPY

Haie-Meder *et al.*³ found that the measured dose of radiotherapy reaching the transposed ovaries was 10% of the delivered dose when the ovaries were located under shielding blocks, and 4.4% when the ovaries were outside the irradiation field.

Nevertheless, results in terms of pregnancy outcome must be evaluated with caution. In the series of Haie-Meder's group³, the pregnancy outcome was just 19%, although ovarian function was apparently preserved. This rate was significantly lower than the rate in the general population.

Interpretation is difficult, however, because this low rate could also reflect a patient's personal choice, or an effect of radiotherapy on the uterus itself, which could affect implantation.

A very large prospective series of ovarian transposition in patients with cervical carcinoma treated by a radiosurgical combination was published by Morice *et al.*²⁴. Ovarian transposition to the paracolic gutters with radical hysterectomy and lymphadenectomy was performed on 107 patients (bilaterally in 98% of cases). This procedure was recommended for patients <40 years of age with a small invasive cervical carcinoma (≤ 3 cm) treated by initial surgery. The rates of ovarian preservation were 90% in patients treated by postoperative vaginal brachytherapy and 60% in patients treated by postoperative external radiation therapy and vaginal brachytherapy.

In conclusion, there is a place for ovarian transposition in cases of radiotherapy directed exclusively at the lowest parts of the pelvis, but there is still a lack of knowledge concerning the effect of radiotherapy on uterine receptivity.

All the indications for laparoscopic ovarian transposition should therefore also be indications for ovarian tissue cryopreservation.

REFERENCES

1. Lushbaugh CC, Casaren GW. The effect of gonadal irradiation in clinical radiation therapy: a review. *Cancer* 1976; 37: 1111–20
2. Mulvihill JJ, McKeen EA, Rosner F, et al. Pregnancy outcome in cancer patients. Experience in a large cooperative group. *Cancer* 1987; 60: 1143–50
3. Haie-Meder C, Mlika-Cabanne N, Michel G, et al. Radiotherapy after ovarian transposition: ovarian function and fertility preservation. *Int J Radiat Oncol Biol Phys* 1993; 25: 419–24
4. Hodel K, Rich WM, Austin P, et al. The role of ovarian transposition in conservation of ovarian function in radical hysterectomy followed by pelvic radiation. *Gynecol Oncol* 1982; 13: 195–202
5. Nahhas WA, Nisce LZ, D'Angio GJ, et al. Lateral ovarian transposition. *Obstet Gynecol* 1971; 38: 785–8
6. Leporrier M, Van Theobald P, Roffe JL, et al. A new technique to protect ovarian function before pelvic irradiation. Heterotopic ovarian transplantation. *Cancer* 1987; 60: 2001–4
7. Schilsky RL, Sherins RJ, Hubbard SM, et al. Longterm follow up of ovarian function in women treated with MOPP chemotherapy for Hodgkin's disease. *Am J Med* 1981; 71: 552–6
8. Gradishar WJ, Schilsky RL. Effects of cancer treatment on the reproductive system. *CRC Crit Rev Oncol Hematol* 1988; 8: 153–71
9. McCall ML, Keaty EC, Thompson JD. Conservation of ovarian tissue in the treatment of carcinoma of the cervix with radical surgery. *Am J Obstet Gynecol* 1958; 75: 590–600
10. Lee C, Lai Y, Soong Y, et al. Laparoscopic ovariopexy before irradiation for medulloblastoma. *Hum Reprod* 1995; 2: 372–4
11. Covens A, Putten H, Fyles A, et al. Laparoscopic ovarian transposition. *Eur J Gynaecol Oncol* 1996; 3: 177–82
12. Clough KB, Goffinet F, Labib A, et al. Laparoscopic unilateral ovarian transposition prior to irradiation: prospective study of 20 cases. *Cancer* 1996; 77: 2638–45
13. Treisman MJ, Miller D, McComb PF. Laparoscopic lateral ovarian transposition. *Fertil Steril* 1996; 65: 1229–31
14. Howard FM. Laparoscopic ovarian transposition before radiation: treatment of Hodgkin's disease. *J Am Assoc Gynecol Laparosc* 1997; 5: 601–4

15. Tulandi T, Al-Took S. Laparoscopic ovarian suspension before irradiation. *Fertil Steril* 1998; 70: 381–3
16. Hart R, Sawyer E, Magos A. Case report of ovarian transposition and review of literature. *Gynecol Endosc* 1999; 8: 51–4
17. Williams RS, Littell RD, Mendenhall NP. Laparoscopic oophoropexy and ovarian function in the treatment of Hodgkin disease. *Cancer* 1999; 86: 2138–45
18. Yarali H, Demirel A, Bukulmez O, et al. Laparoscopic high lateral transposition of both ovaries before pelvic irradiation. *J Am Assoc Gynecol Laparosc* 2000; 7: 237–9
19. Visvanathan DK, Cutner AS, Cassoni AM, et al. A new technique of laparoscopic ovariopexy before irradiation. *Fertil Steril* 2003; 79: 1204–13
20. Bisharah M, Tulandi T. Laparoscopic preservation of ovarian function: an underused procedure. *Am J Obstet Gynecol* 2003; 188: 367–70
21. Baker TG. Radiosensitivity of mammalian oocytes with particular reference to the human female. *Am J Obstet Gynecol* 1971; 110: 746–61
22. Donnez J, Qu J, Nisolle M. Gonadal cryopreservation in the young patient with gynecological malignancy. *Curr Opin Obstet Gynecol* 2000; 12: 1–9
23. Donnez J, Bassil S. Indications for cryopreservation of ovarian tissue. *Hum Reprod Update* 1998; 4: 248–59
24. Morice P, Juncker L, Rey A, et al. Ovarian transposition for patients with cervical carcinoma treated by radiosurgical combination. *Fertil Steril* 2000; 74: 743–8

akusher-lib.ru

Laparoscopic preservation of female fertility

H Baakdah, T Tulandi

It is estimated that about 650 000 new cases of cancer in females are diagnosed annually¹, and 8% occur in women under the age of 40 years². Fortunately, advances in cancer therapy have improved the long-term survival of young patients suffering from malignancies. In fact, many childhood lymphomas and leukemias can now be cured. However, cancer treatment sometimes carries adverse side-effects, including loss of gonadal function and sterility in both sexes.

The preservation of fertility in males by sperm freezing is already well established, although it is still an imperfect technology. There have been few options for young women undergoing cancer treatment, but the advent of new methods for preserving gonadal function and fertility is promising. Today, we can cryopreserve embryos, oocytes and ovarian tissue, and in those undergoing pelvic irradiation, laparoscopic ovarian suspension can be considered³. In this review, we discuss the use of laparoscopy in the preservation of fertility in females.

LAPAROSCOPIC OVARIAN SUSPENSION

In women undergoing pelvic irradiation, the ovaries can be moved out of the radiation field to avoid the direct effects of ionizing radiation; this procedure is called ovarian suspension, ovarian transposition or oophoropexy. The procedure has been performed for more than three decades in women with Hodgkin's disease receiving pelvic or para-aortic lymph-node irradiation at staging laparotomy⁴⁻⁷.

There are two types, lateral or medial ovarian transposition. In medial ovarian transposition, the ovaries are transposed behind the uterus and protected with a lead block during irradiation. However, considerable amounts of radiation are still received. Lateral ovarian transposition, repositioning the ovaries out of the radiation field, is more effective. It can be done during the initial staging laparotomy or during laparotomy for debulking the tumor. In patients who do not need a laparotomy, ovarian transposition can be performed by laparoscopy. The laparoscopic approach is certainly less invasive and yet effective.

Ovaries have been transposed to a variety of sites and levels, from the base of the round ligament to the level of the lower kidney pole⁸⁻²². It seems that the ovaries should be transposed at least to a level above the pelvic brim. Transposition to this level can be achieved without separating the Fallopian tubes from their uterine origin. This

allows the possibility of spontaneous conception²³. However, transient ovarian failure following this procedure has been reported²⁴.

Concerns with ovarian transposition include the uncommon development of radiation-induced cancer in the transposed ovaries²³. Anderson *et al.*²⁵ studied 82 premenopausal women with early-stage carcinoma of the cervix who underwent ovarian transposition. Only one patient was found to have metastatic disease to the ovary 17 months later. Similar to normally located ovaries, ovarian cysts can be found in the transposed ovaries.

Technique of laparoscopic lateral ovarian transposition

To facilitate relocation of the ovaries above the pelvic brim, we use three trocars: the primary trocar is inserted 2 cm above the umbilicus and two secondary trocars are inserted at the same level. Peritoneal lavage for cytological examination is first done. A thorough examination of the abdominal cavity, including the liver and diaphragm, should be carried out. The course of the ureter is first followed, and then the ovarian ligament is electrocoagulated and transected. Dissection is continued on the mesovarium as far as the infundibulopelvic ligament, but the vascular pedicle inside the ligament is left intact¹³.

The ovary is then mobilized superiorly and laterally to the site above the pelvic brim. If mobilization is inadequate, a relaxing incision on the peritoneum inferior to the ovary is performed. In our experience, the tubes do not have to be transected. This helps future spontaneous conception^{13,23}. To prevent the return of the ovaries to the pelvic cavity, the transposed ovaries should be securely anchored to the peritoneum. We use two sutures of 4-0 polydioxanone. In a case where the ovaries were anchored with hemoclips only²⁶, the ovaries slipped back into the pelvic cavity and the patient became menopausal after irradiation. At the end of the procedure, the ovary is marked with a metal clip bilaterally. This is to facilitate future location of the ovaries by ultrasound or other imaging techniques.

OVARIAN CRYOPRESERVATION

The treatment of childhood malignant disease is becoming increasingly effective. More than 90% of girls and young women affected by malignant diseases can be treated by aggressive chemotherapy and radiotherapy, and bone

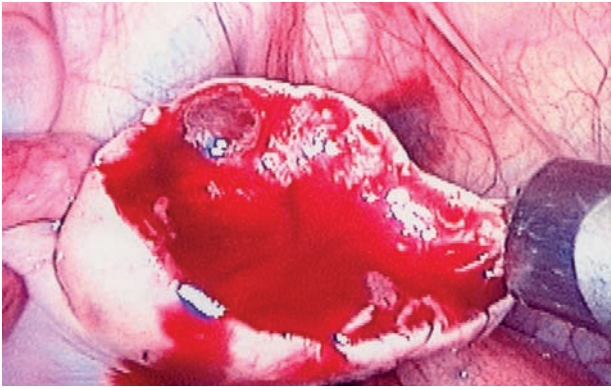


Figure 31.1 Laparoscopic ovarian resection for cryopreservation. Approximately one-third to a half of the ovary has been excised. Reproduced from reference 37, with permission

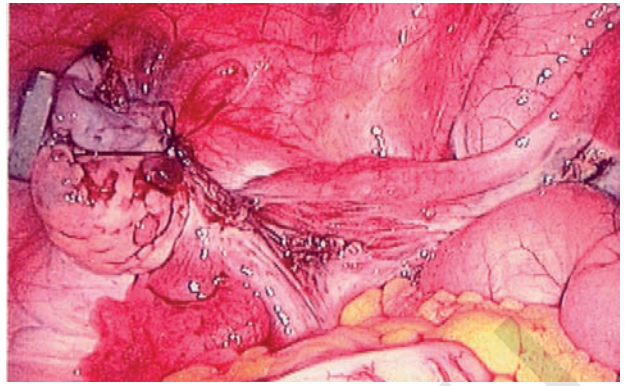

Figure 31.2 Laparoscopic ovarian transposition. The left ovary has been transposed above the pelvic brim. A Filshie clip has been placed on the ovarian tissue. Reproduced from reference 37, with permission

marrow transplantation. However, the ovaries are very sensitive to cytotoxic treatment and ionizing radiation, generally resulting in the loss of both endocrine and reproductive function²⁷. Experimental protocols for removing and freezing ovarian cortical tissue exist²⁸. The objective is to reimplant ovarian tissue into the pelvic cavity (orthotopic site) or a heterotopic site such as under the skin in the forearm. This can be performed once treatment is complete and the patient is disease-free²⁹⁻³⁴.

A major problem of ovarian cryopreservation is ischemic damage to the tissue pending transplant and revascularization, and there is a theoretical possibility of reintroducing malignant tumor cells³⁵. Alternatives include oocyte retrieval using ultrasound-guided techniques for *in vitro* maturation (IVM) or *in vitro* fertilization (IVF) treatments. IVM and IVF are beyond the scope of this chapter.

Ovarian cryopreservation is a novel method for preserving fertility and is performed in a few centers only. Oktay *et al.* performed a unilateral oophorectomy in a patient with stage IIb breast cancer before treatment with high-dose chemotherapy³¹. The ovarian tissue was frozen, thawed 6 years later and transplanted beneath the skin of her abdomen. The patient underwent eight oocyte retrievals percutaneously and 20 oocytes were retrieved. Of the eight oocytes suitable for IVF, one was fertilized normally and developed into a four-cell embryo³¹. However, the first live birth after ovarian cryopreservation and transplantation was reported by Donnez *et al.* Their patient was a woman with premature ovarian failure following chemotherapy for stage IV Hodgkin's lymphoma³⁶. It appears that peritoneum provides a better environment for ovarian transplantation than does subcutaneous tissue.

One of the concerns with allotransplantation of ovarian tissue in cancer patients is the risk of transmission of microscopic disease. It is important, therefore, to examine the removed ovarian tissue histopathologically.

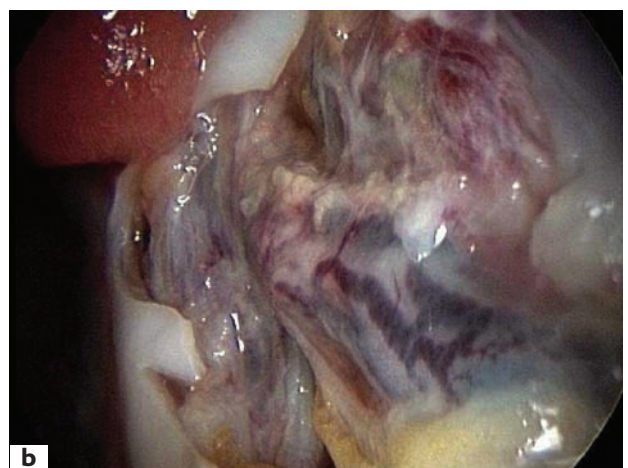
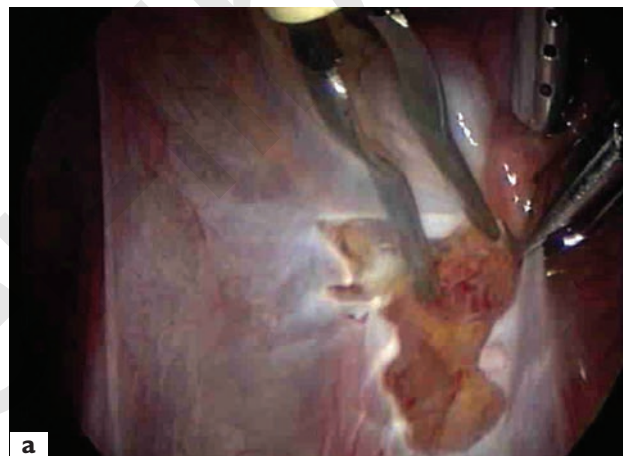
Figure 31.3 Laparoscopic ovarian transplantation. (a) During the first laparoscopy (7 days before transplantation), a peritoneal window was created and the edges of the window were coagulated. (b) Seven days later (day of reimplantation), an extensive vascular network was clearly visible in this space. Reproduced from reference 36, with permission

Operative technique

Laparoscopic excision of ovarian tissue for cryopreservation

The technique depends on how much ovarian tissue is to be excised. If one knows that the treatment will make the patient menopausal, it is logical to remove both ovaries. However, the psychological aspect of the removal of both ovaries should be taken into account. Currently, the authors excise only about half of the ovary. When the treating oncologist feels strongly that the patient will become menopausal, we remove the whole ovary unilaterally. A few days before surgery, the embryologist should ascertain that the cryoprotective solution is available and not expired, and he or she will be available to retrieve the specimen upon removal.

The excision is performed by laparoscopy. No special technique is required to remove the ovary³⁷. A portion of the ovary is excised using laparoscopic scissors. Because of potential thermal damage to the ovarian tissue, electrocoagulation should not be used. The excised specimen is left attached to the ovary until the embryologist is ready to receive it. The tissue is removed from the abdominal cavity through a 10-mm port. The ovarian opening is then sutured using a few interrupted sutures of 4-0 polydioxanone (PDS). A small piece of ovarian tissue is sent for histopathology examination. In those undergoing radiation treatment, ovarian resection can be done during laparoscopic ovarian transposition.

Laparoscopic ovarian tissue transplantation

Several techniques have been described^{37,38}. Radford *et al.* reported that the orthotopic transplantation of frozen-thawed ovarian cortical strips was associated with a return of ovarian hormone production³⁴. The frozen-thawed ovarian tissue was transplanted through an opening in the cortex of an atrophic ovary, and then the ovarian opening was closed with 3-0 polyglactin sutures. On the opposite side, where the ovary had been removed, the tissue was transplanted, stromal surface down, on the peritoneum of the ovarian fossa and attached with two sutures of polyglactin.

Oktay *et al.* created a peritoneal window in the ovarian fossa and superior to the ureters³⁹. The frozen-thawed ovarian tissues were anchored to Surgicel® (Ethicon, Somerville, NJ) and placed in the peritoneal pocket and secured with sutures. These authors used size 6-0 to 0 Vicryl® sutures. The use of large suture material might cause inflammation and adhesion formation.

Donnez *et al.* performed a two-step procedure and reported the first live birth after the transplantation of frozen-thawed ovarian tissue³⁶. At the first laparoscopy, they created a large peritoneal window just beneath the ovarian hilus of the atrophic ovary. This was followed by coagulation of the peritoneal edges. A second laparoscopy

was performed 7 days later. The frozen-thawed ovarian tissue was pushed into the channel created by the peritoneal window, close to the ovarian vessels and tubal fimbria. They did not use any suture³⁶.

CONCLUSIONS

In attempts to preserve fertility, two laparoscopic approaches can be offered: ovarian transposition for women undergoing local irradiation of the pelvis or low abdomen, and laparoscopic removal of ovarian tissue for ovarian cryopreservation. Laparoscopic ovarian transposition is a well-established procedure. In women aged less than 40 years, it is associated with the preservation of ovarian function in 88.6% of cases²³. Ovarian cryopreservation and the transplantation of frozen-thawed ovarian tissue is relatively new, but promising. These procedures offer some hope for patients, including children, who wish to preserve their fertility.

REFERENCES

1. Jemal A, Murray T, Samuels A, et al. Cancer statistics 2003. *CA Cancer J Clin* 2003; 53: 5–26
2. Oktay KH, Yih M. Preliminary experience with orthotopic and heterotopic transplantation of ovarian cortical strips. *Semin Reprod Med* 2002; 20: 63–74
3. Tulandi T. Laparoscopy for preservation of fertility and ovarian cryopreservation. In Tulandi T, Gosden R, eds. *Preservation of Fertility*. London: Taylor & Francis, 2004: 83–8
4. Ray GR, Trueblood HW, Enright LP, et al. Oophorectomy: a means of preserving ovarian function following pelvic megavoltage radiotherapy for Hodgkin's disease. *Radiology* 1970; 96: 175–80
5. Nahhas WA, Nisce LZ, D'Angio GJ, et al. Lateral ovarian transposition. Ovarian relocation in patients with Hodgkin's disease. *Obstet Gynecol* 1971; 38: 785–8
6. LeFloch O, Donaldson SS, Kaplan HS. Pregnancy following oophorectomy and total nodal irradiation in women with Hodgkin's disease. *Cancer* 1976; 38: 2263–8
7. Thomas PR, Winstanly D, Peckham MJ, et al. Reproductive and endocrine function in patients with Hodgkin's disease: effects of oophorectomy and irradiation. *Br J Cancer* 1976; 33: 226–31
8. Lee C, Lai Y, Soong Y, et al. Laparoscopic ovariopexy before irradiation for medulloblastoma. *Hum Reprod* 1995; 10: 372–4
9. Covens A, Putten H, Fyles A, et al. Laparoscopic ovarian transposition. *Eur J Gynaecol Oncol* 1996; 3: 177–82
10. Clough KB, Goffinet F, Labib A, et al. Laparoscopic unilateral ovarian transposition prior to irradiation: prospective study of 20 cases. *Cancer* 1996; 77: 2638–45

11. Treissman MJ, Miller D, McComb PF. Laparoscopic lateral ovarian transposition. *Fertil Steril* 1996; 65: 1229–31
12. Howard FM. Laparoscopic lateral ovarian transposition before radiation: treatment of Hodgkin's disease. *J Am Assoc Gynecol Laparosc* 1997; 4: 601–4
13. Tulandi T, Al-Took S. Laparoscopic ovarian suspension before irradiation. *Fertil Steril* 1998; 70: 381–3
14. Classe J, Mahe M, Moreau P, et al. Ovarian transposition by laparoscopy before radiotherapy in the treatment of Hodgkin's disease. *Cancer* 1998; 83: 1420–4
15. Morice P, Castaigne D, Haie-Meder C, et al. Laparoscopic ovarian transposition for pelvic malignancies: indications and functional outcomes. *Fertil Steril* 1998; 70: 956–60
16. Williams RS, Littell RD, Mendenhall NP. Laparoscopic oophorectomy and ovarian function in the treatment of Hodgkin disease. *Cancer* 1999; 86: 2138–42
17. Hart R, Sawyer E, Magos A. Case report of ovarian transposition and review of literature. *Gynecol Endosc* 1999; 8: 51–4
18. Schulz-Lobmeyr I, Schratte-Sehn A, Huber J, Wenzl R. Laparoscopic lateral ovarian transposition before pelvic irradiation for a non-Hodgkin lymphoma. *Acta Obstet Gynecol Scand* 1999; 78: 350–2
19. Yarali H, Demiroglu A, Bukulmez O, et al. Laparoscopic high lateral transposition of both ovaries before pelvic irradiation. *J Am Assoc Laparosc* 2000; 7: 237–9
20. Giacalone P, Laffargue F, Benos P, et al. Successful in vitro fertilization – surrogate pregnancy in a patient with ovarian transposition who had undergone chemotherapy and pelvic irradiation. *Fertil Steril* 2001; 76: 388–9
21. Visvanathan DK, Cutner AS, Cassoni AM, et al. A new technique of laparoscopic ovariopexy before irradiation. *Fertil Steril* 2003; 79: 1204–6
22. Steigrad S, Hacker NF, Kolb B. In vitro fertilization surrogate pregnancy in a patient who underwent radical hysterectomy followed by ovarian transposition, lower abdominal wall radiotherapy, and chemotherapy. *Fertil Steril* 2005; 83: 1547–9
23. Bisharah M, Tulandi T. Laparoscopic preservation of ovarian function: an underused procedure. *Am J Obstet Gynecol* 2003; 188: 367–70
24. Treissman MJ, Miller D, McComb PF. Laparoscopic lateral ovarian transposition. *Fertil Steril* 1996; 65: 1229–31
25. Anderson B, LaPolla J, Turner D, et al. Ovarian transposition in cervical cancer. *Gynecol Oncol* 1993; 49: 206–14
26. Covens A, Putten H, Fyles A, et al. Laparoscopic ovarian transposition. *Eur J Gynaecol Oncol* 1996; 3: 177–82
27. Donnez J, Godin PA, Qu J, et al. Gonadal cryopreservation in the young patient with gynaecological malignancy. *Curr Opin Obstet Gynecol* 2000; 12: 1–9
28. The Ethics Committee of the American Society for Reproductive Medicine. Fertility preservation and reproduction in cancer patients. *Fertil Steril* 2005; 83: 1622–6
29. Donnez J, Bassil S. Indications for cryopreservation of ovarian tissue. *Hum Reprod* 1998; 4: 248–59
30. Oktay K, Buyuk E, Veeck L, et al. Embryo development after heterotopic transplantation of cryopreserved ovarian tissue. *Lancet* 2004; 363: 837–40
31. Oktay K, Economos K, Kan M, et al. Endocrine function and oocyte retrieval after autologous transplantation of ovarian cortical strips to the forearm. *JAMA* 2001; 286: 1490–3
32. Nisolle M, Casanas-Roux F, Qu J, et al. Histologic and ultrastructural evaluation of fresh and frozen-thawed human ovarian xenografts in nude mice. *Fertil Steril* 2000; 74: 122–9
33. Baird DT, Webb R, Campbell BK, et al. Long-term ovarian function in sheep after ovariectomy and transplantation of autografts stored at -196°C . *Endocrinology* 1999; 140: 462–71
34. Radford JA, Lieberman BA, Brison D, et al. Orthotopic reimplantation of cryopreserved ovarian cortical strips after high-dose chemotherapy for Hodgkin's lymphoma. *Lancet* 2001; 357: 1172–5
35. Morice P, Thiam-Ba R, Castaigne R, et al. Fertility results after ovarian transposition for pelvic malignancies treated by external irradiation or brachytherapy. *Hum Reprod* 1998; 13: 660–3
36. Donnez J, Dolmans MM, Demylle D, et al. Livebirth after orthotopic transplantation of cryopreserved ovarian tissue. *Lancet* 2004; 364: 1405–10
37. Tulandi T, Al-Shahrani A. Laparoscopic fertility preservation. *Obstet Gynecol Clin North Am* 2004; 31: 611–18
38. Tulandi T. Oophorectomy and laparoscopic orchiectomy. In Tulandi T, ed. *Atlas of Laparoscopy and Hysteroscopy Technique*. London: WB Saunders, 1999: 69–75
39. Oktay K, Aydin BA, Karlikaya G. A technique for laparoscopic transplantation of frozen-banked ovarian tissue. *Fertil Steril* 2001; 75: 1212–16

The place of endoscopy in malignancy

J Donnez, M Berlière, J Squifflet, P Jadoul

Indications for gynecological surgery have increased in recent years, but in the case of gynecological malignancies, the use of laparoscopy is still in its infancy. More clinical data are required before laparoscopic techniques are accepted as new surgical standards. Ongoing prospective clinical studies will help to answer many questions regarding the safety and efficacy of gynecological laparoscopy. Until more data are available, operative laparoscopy will remain a promising but unproven tool in the management of patients with gynecological malignancies.

INDICATIONS FOR LAPAROSCOPIC PROCEDURES IN ENDOMETRIAL CANCER

Evaluation of the anatomosurgical stage is crucial in the therapeutic strategy for endometrial cancer. Lymph node involvement plays a major role in this evaluation, as an indicator of both prognosis and the need for adjuvant therapy. Lymph node metastasis is related to tumor size and grade, tumor stage and invasion of the myometrium (Table 32.1). In our department, bilateral laparoscopic adnexectomy and laparoscopic hysterectomy are performed in cases of atypical hyperplasia and stage 0–I, grade 1 endometrial cancer. Stage I, grade 2–3 endometrial cancer requires additional lymphadenectomy (Table 32.2). Laparoscopic lymphadenectomy is also performed 2 weeks after laparoscopic hysterectomy, if histology reveals either myometrial invasion of more than two-thirds of the depth of the myometrium, histological invasion of the cervix or a histological grade more severe than that suspected from the preoperative biopsy.

Stage II endometrial cancer requires laparoscopic lymphadenectomy, followed by radical vaginal hysterectomy,

as described by Schauta¹. This technique should only be attempted by experienced surgeons who are experts in the vaginal approach. In many departments, stage II endometrial cancer is treated by a Wertheim–Meigs surgical procedure with lymphadenectomy.

In stage III and IV endometrial cancer, the role of laparoscopy is not yet clearly defined. It may be an indication for performing multiple biopsies in different sites of the peritoneal cavity.

In patients with endometrial cancer, initial laparoscopic lymphadenectomy, together with bilateral adnexectomy, allows subsequent hysterectomy to be performed, either vaginally or laparoscopically^{2,3}. The few studies which have been reported^{2,4} suggest that more extensive investigation is needed to determine the possible future role of laparoscopic surgery in the treatment of endometrial cancer.

In our department, laparoscopic bilateral adnexectomy and laparoscopic hysterectomy are the procedures of choice in the treatment of stage I endometrial cancer. Laparoscopic lymphadenectomy is also performed in case of non-differentiated endometrial cancer.

INDICATIONS FOR LYMPHADENECTOMY IN VAGINAL CANCER

Primary carcinoma of the vagina is a malignant lesion that appears in the vagina and does not involve the cervix or

Table 32.1 Prevalence of lymph node metastasis in relation to tumor size and tumor grade in endometrial cancer

Tumor grade	Tumor size		Entire surface
	≤ 2 cm diameter	> 2 cm diameter	
1	0/15 (0%)	0/14 (0%)	0/3 (0%)
2	0/10 (0%)	4/12 (33%)	1/3 (33%)
3	2/10 (20%)	6/20 (30%)	3/4 (75%)

Table 32.2 Indications for laparoscopic procedures in endometrial cancer

Diagnosis	Proposed therapy
Atypical hyperplasia	Laparoscopic adnexectomy and hysterectomy
Adenocarcinoma stage 0–I; grade 1	Laparoscopic adnexectomy and hysterectomy + laparoscopic lymphadenectomy
Adenocarcinoma stage I; grade 2–3	Laparoscopic lymphadenectomy followed by radical vaginal hysterectomy (Schauta)
Adenocarcinoma stage II	+ Multiple biopsies?
Adenocarcinoma stage III–IV	

vulva. It is rare, representing 1–2% of all gynecological malignancies. In an extensive review of the literature, Plentl and Friedman⁵ found that 51.7% of primary vaginal cancers occurred in the upper third of the vagina, and 57.6% were on the posterior wall. Tumors originating in the vagina may spread along the vaginal wall to involve the cervix or the vulva. However, if biopsies of the cervix or vulva are positive at diagnosis, the tumor cannot be considered a primary vaginal lesion.

Lymphatic drainage of the vagina involves an extensive intercommunicating network. The lymphatics in the upper portion of the vagina drain primarily via the lymphatics of the cervix, whereas those in the lower portion of the vagina either drain to cervical lymphatics or follow drainage patterns of the vulva into femoral and inguinal nodes. The anterior vaginal wall usually drains into the deep pelvic nodes, including the interiliac and parametrial nodes.

The incidence of positive pelvic nodes at diagnosis varies with the stage and location of the primary tumor. Because the lymphatic system of the vagina is so complex, any of the nodal groups may be involved, regardless of the location of the lesion. Involvement of inguinal nodes is most common, however, when the lesion is located in the lower third of the vagina. The reported incidence of clinically positive nodes at diagnosis varies from 5.1%⁶ to 20.8%⁷. Radiation therapy is the preferred treatment for most carcinomas of the vagina. Surgical procedures may be reserved for the treatment of irradiation failures and for non-epithelial tumors. For tumors of the upper third of the vagina (Figures 32.1 and 33.2), surgery can be an excellent alternative, especially if the tumor is near the cervix. In this case, laparoscopic lymphadenectomy (Figure 32.3) can be performed before radical hysterectomy (Figure 32.4).

CERVICAL CANCER

Laparoscopic surgery offers two possible options to avoid laparotomy in cervical cancer:

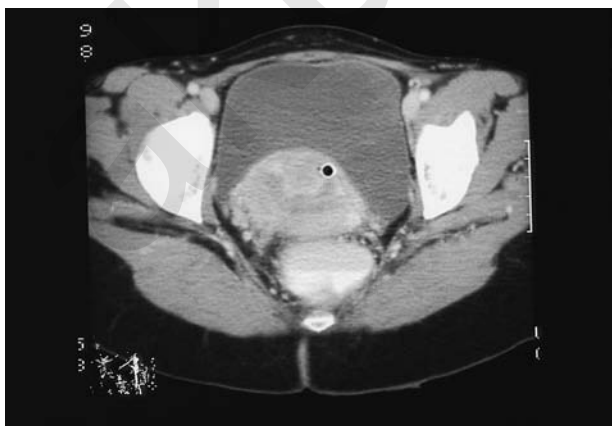

Figure 32.1 Computed tomography (CT) scan: cancer of the vagina located in the upper third of the posterior wall

- Laparoscopic lymphadenectomy followed by the vaginal operative approach according to Schauta’s technique^{6,8–10}
- Lymphadenectomy followed by an extended laparoscopic hysterectomy^{10,11}

The presence of lymph node metastasis is the most significant prognostic factor in cervical cancer. Squamous

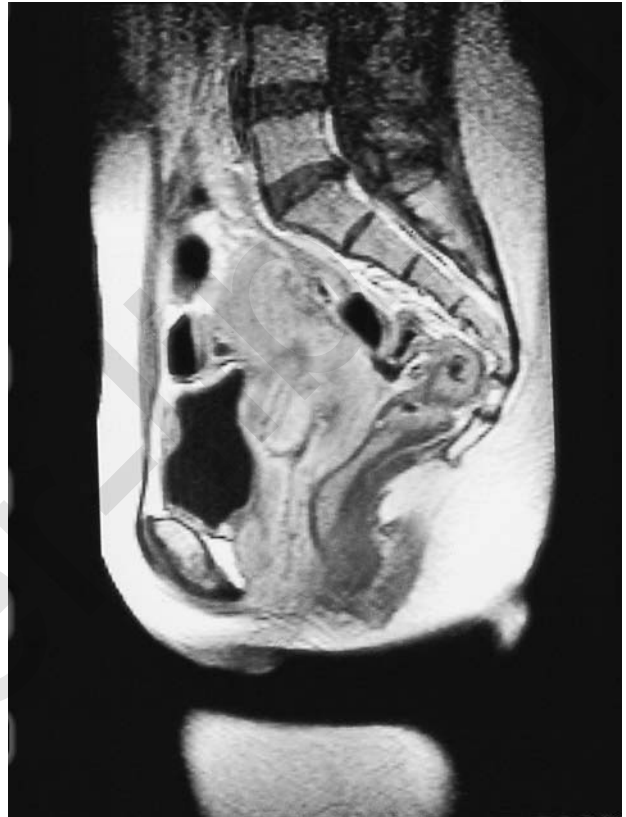

Figure 32.2 Magnetic resonance imaging (same patient as in Figure 32.1) provides an excellent view of vaginal involvement

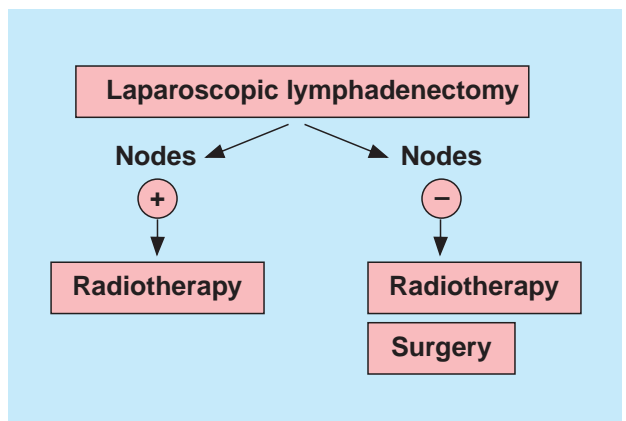


Figure 32.3 Proposed therapy for carcinoma of the upper third of the vagina

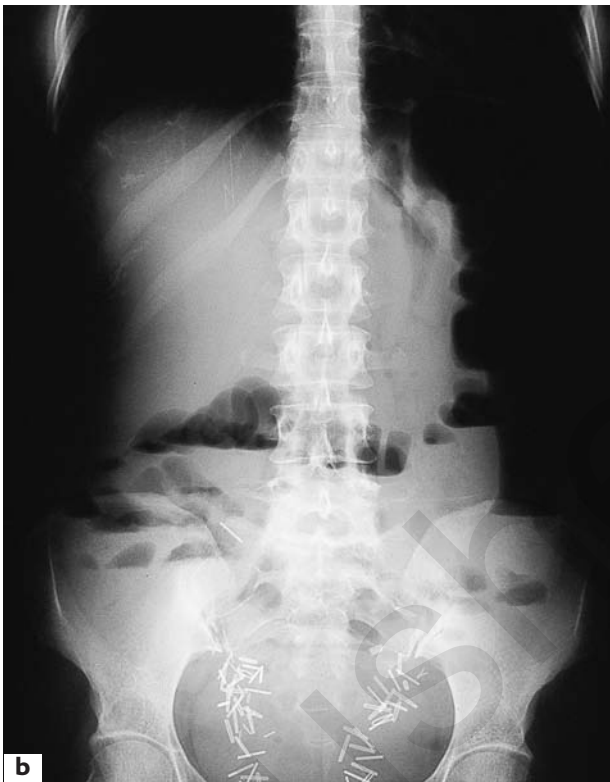
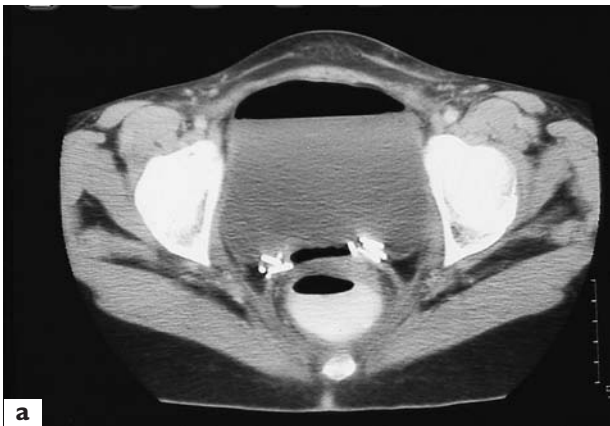

Figure 32.4 Computed tomography (CT) scan (a) and radiography (b) after hysterectomy and colpectomy in a case of primary carcinoma (same patient as in Figure 32.1)

carcinoma of the cervix spreads principally by direct local invasion to adjacent tissue and by lymphatics^{12,13}, and less commonly through blood vessels. Initially, the tumor grows by direct continuity along tissue spaces of least resistance, the perineural and perivascular tissues, into the paracervical and parametrial areas and into the cardinal and uterosacral ligaments. Ultimately, lateral spread may reach the bony pelvis and obstruct one or both ureters. Direct extension may also involve the uterine cavity and vagina, with extension into the urinary bladder and rectum, resulting in vesicovaginal and rectovaginal fistulas.

Lymph node metastasis
= prognostic factor of cervical carcinoma

Diagnosis

1. Lymphangiography
2. Computed tomography (Figure 32.6)
3. Nuclear magnetic resonance imaging
4. PET tomography (Figure 32.7)
5. Laparoscopic lymphadenectomy

Figure 32.5 Diagnosis of lymph node metastasis. PET positron emission tomography

The spread of cervical cancer via lymphatics occurs relatively early in the course of the disease, and is found in 25–50% of patients with stage Ib and II carcinomas. The preferential course of dissemination is via the paracervical, hypogastric and external iliac lymph nodes, followed by extension to the lateral sacral, common iliac, para-aortic and inguinal nodes. Isolated invasion of the sacral, external iliac and hypogastric nodes is occasionally observed. Metastases to distant lymph nodes above the diaphragm, including the supraclavicular lymph nodes, are uncommon, and a feature of widespread disease. In these cases, cancer cells are transported from the para-aortic nodes into the mediastinum and then into the thoracic duct. Diagnosis of lymph node metastasis can be made by lymphography, computed tomography and/or nuclear magnetic resonance imaging (Figure 32.5). The low sensitivity of lymphography (<30%)¹⁴, computed tomography (Figure 32.6) (between 30 and 70%)^{14–16}, nuclear magnetic resonance imaging and lymphoscintigraphy⁸ in the detection of potentially malignant adenopathies has prompted some authors to perform retroperitoneal lymph node sampling^{17,18}. Positron emission tomography (PET) (Figure 32.7) provides a view of lymph node involvement, and is, at the present time, under evaluation.

The first laparoscopic lymphadenectomies were performed by Dargent and Salvat¹⁸, Reich¹⁹, Querleu *et al.*^{2,8,20}, Canis *et al.*¹² and Nezhat *et al.*¹¹. The results are very encouraging, with a 100% sensitivity rate in a series of 75 patients and a very low postoperative complication rate^{2,8}. The primary indication for laparoscopic lymphadenectomy in gynecological oncology is the staging of early, operable carcinoma of the cervix². The risk of skip metastases to the para-aortic nodes without pelvic node involvement is very low (<1%); it occurs almost exclusively in patients with large tumors (>4 cm). Patients with stage Ib, IIa or IIb disease and negative pathological staging may be cured by radical or abdominal surgery.

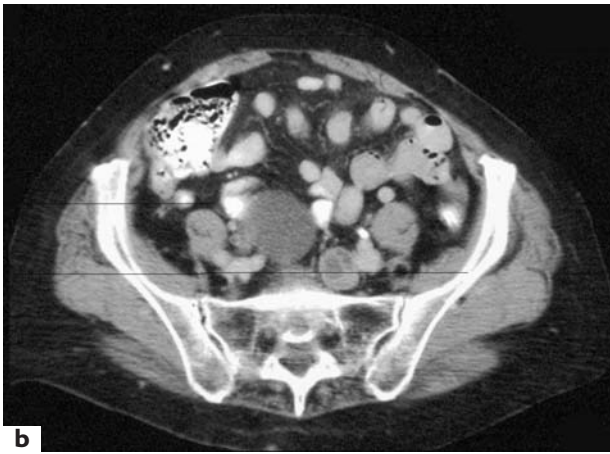
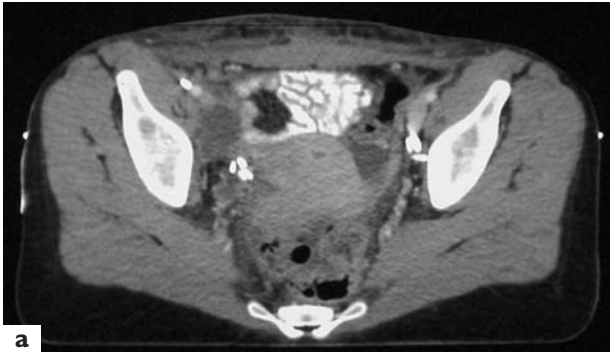


Figure 32.6 (a) and (b) Computed tomography (CT) scan reveals a necrotic metastatic lymph node

However, radical hysterectomy does not seem justified when the nodes are invaded by metastatic disease^{15,19} (Figure 32.8).

In stage IV carcinoma extension (to the urinary bladder) (Figure 32.9), laparoscopic lymphadenectomy must be carried out before performing an anterior pelvicotomy. A new technique¹³ for detection of the sentinel lymph node is being investigated in early-stage cervical cancer, and this procedure is described in Chapter 34.

INDICATIONS FOR LAPAROSCOPIC PROCEDURES IN OVARIAN CANCER

In advanced ovarian cancer, laparoscopy might prove to be a valuable tool when evaluating patients prior to debulking surgery²¹. Retrospective analyses suggest that a subgroup of patients with stage III and IV ovarian carcinoma can, after staging by laparoscopy, be treated by neoadjuvant chemotherapy, followed by interval debulking surgery²¹.

For patients with advanced ovarian cancer who can be treated, the feasibility and reliability of a laparoscopic second-look procedure, and comparison with second-look

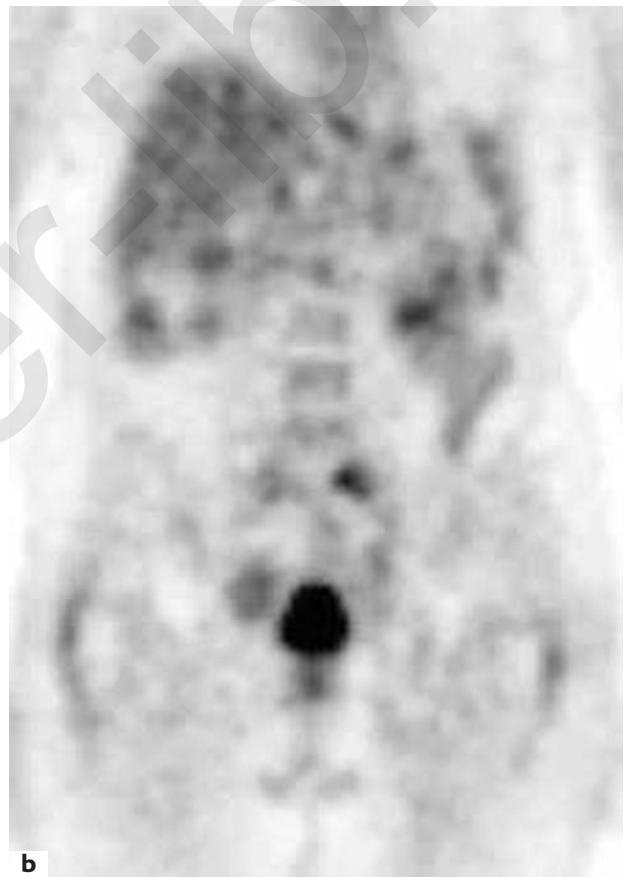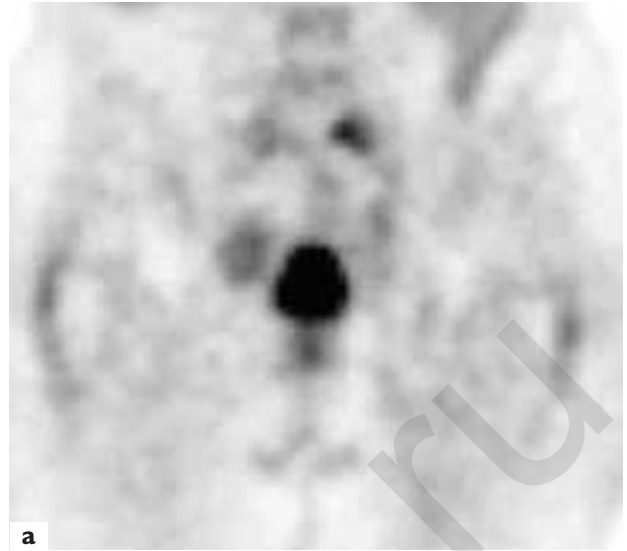


Figure 32.7 (a) and (b) Positron emission tomography (PET) provides a view of lymph node involvement

laparotomy, have been investigated in a French study²². The conclusions are that, after treatment of ovarian cancer, second-look laparoscopy appears to be less reliable than second-look laparotomy. The presence of severe post-operative adhesions is the main obstacle to an exhaustive, reliable and safe laparoscopic second-look procedure.

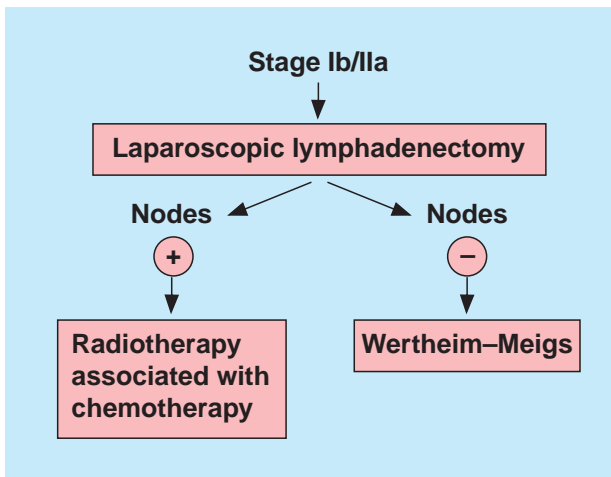


Figure 32.8 Proposed therapy for cervical carcinoma of stage Ib, IIa and IIb

Current guidelines for the surgical staging of ovarian cancer (stage I and II) include the removal of retroperitoneal lymph nodes (pelvic and aortic)^{23–25}. In most centers, this is achieved by means of laparotomy, but advanced laparoscopic techniques have been performed²⁴.

If laparoscopy is useful in the staging of established and advanced ovarian cancer, it may also play a role in early-stage epithelial ovarian carcinoma²⁵. Especially for young women, the laparoscopic procedure allows fertility-sparing surgery and looks both safe and promising. It also appears to be the most appropriate surgical procedure for prophylactic oophorectomy in patients with an inherited risk of ovarian cancer²⁶ (carriers of BRCA1/BRCA2 mutations). Surgeons may of course convert to laparotomy if ovarian cancer is discovered during the procedure.

The application of laparoscopic surgery in malignant ovarian pathology shows encouraging results, but they need confirmation by prospective randomized trials and studies of long-term survival.

TECHNIQUE

Laparoscopic hysterectomy

Endometrial cancer typically occurs in obese, high-risk women. Use of the laparoscope precludes an abdominal incision-wound infection in these patients. Atypical hyperplasia and stage 0–I, grade 1 endometrial cancer do not require lymphadenectomy. Treatment may be by laparoscopy-assisted vaginal hysterectomy (LAVH) or laparoscopic hysterectomy (LH) (see Chapter 23): all maneuvers following internal vessel ligation can be performed vaginally or laparoscopically, including anterior and posterior vaginal entry, cardinal and intersacral ligament division, intact uterine removal and vaginal closure.

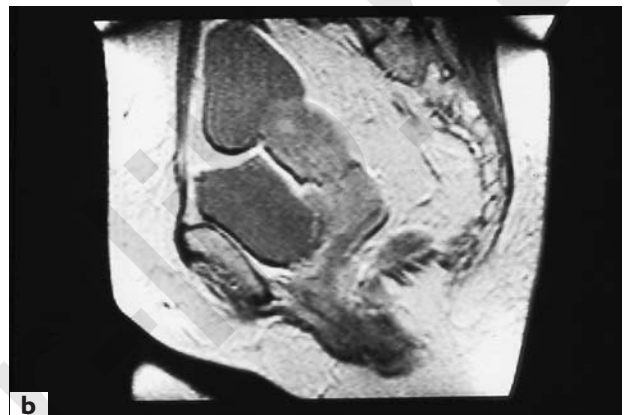
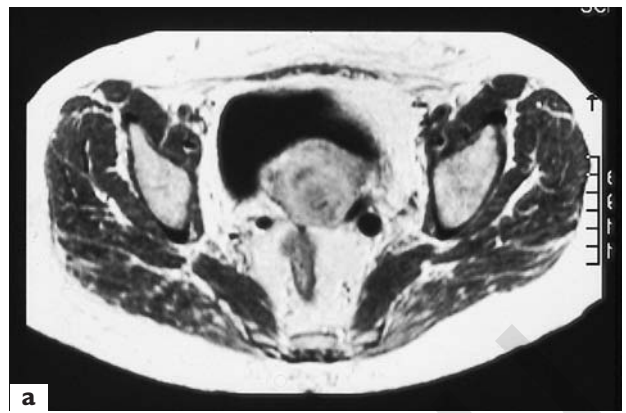


Figure 32.9 (a) and (b) Magnetic resonance imaging of stage IV cervical carcinoma. The involvement of the urinary bladder wall is clearly seen

The adnexa are removed first. The infundibulopelvic ligament is identified and exposed by applying traction to the adnexa with opposite forceps. Bipolar forceps are used to compress and desiccate the vessels, which are then cut with scissors. Alternatively, staples or sutures may be applied. The other steps are described in Chapter 22. Ligation of the uterine vessels can also be performed by the vaginal approach. Some authors prefer suture ligation of the vascular bundle. If LAVH is performed, the rest of the operation is done vaginally, as is suture of the vaginal vault.

Laparoscopic lymphadenectomy

Preparation of the patient for surgery follows standard procedures. In order to avoid any possible disturbance due to an overdistended large bowel, cleansing of the digestive system must be undertaken. A pneumoperitoneum is achieved through the subumbilical incision. Three suprapubic incisions are made. The operation begins with peritoneal cytology and abdominopelvic exploration. The ureters are visualized. The peritoneum is incised between the round and lumbo-ovarian ligaments. The subperitoneal

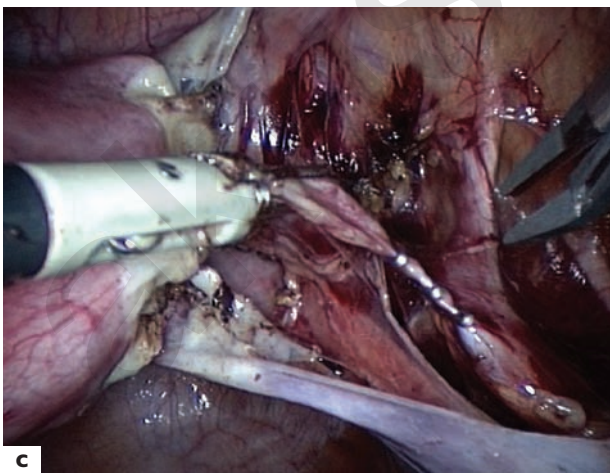
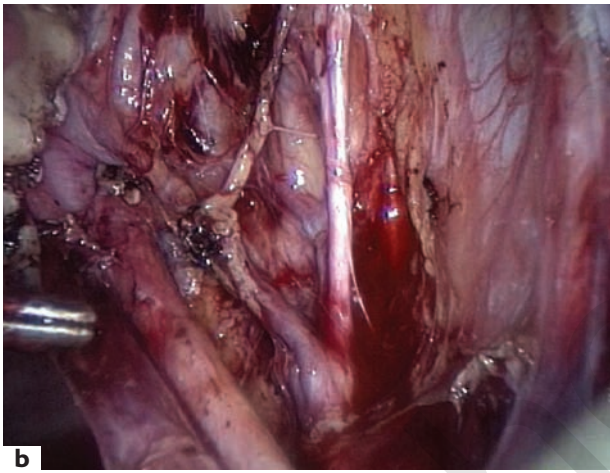
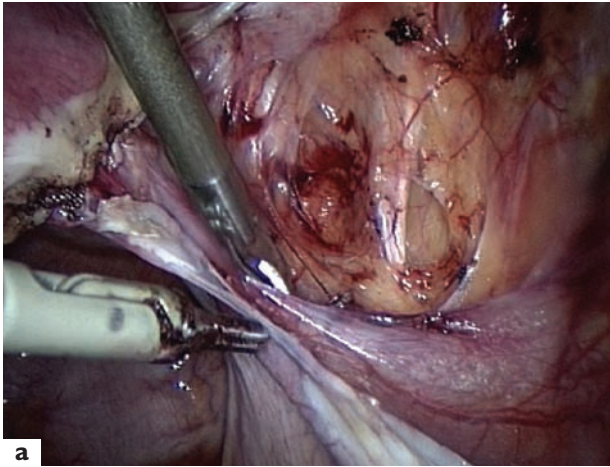


Figure 32.10 (a) Incision of the peritoneum between the round ligament and the lumbo-ovarian ligament. (b) Dissection of the ureter, the uterine artery and the umbilical artery. (c) Hemostatic clips are placed on the uterine artery

space is opened using scissors and the iliac vessels are identified (Figure 32.10).

During the entire operation, the round ligament is grasped and kept in an elevated and medial position. This allows identification of the umbilical artery, the internal limit of node sampling. The obturator nerve is then identified, located against the pelvic wall under the iliac vessels.

Node sampling can begin with the subvenous group, which is the lowest one; this ensures that any bleeding does not make further dissection more difficult.

The operation can also begin by sampling of the supra-arterial nodes. Dissection is performed towards the origin of the external iliac vein (Figure 32.11) with gentle traction on the nodes. Careful lymphostasis with clips is performed throughout the dissection when a large lymphatic channel is encountered.

Once the space between the pelvic wall and the inferior side of the internal iliac vein has been treated, dissection of the internal retrocrural nodal group is begun (Figure 32.12). The obturator nerve is clearly seen. During this procedure, anastomosis between the external iliac vein and the obturator vein may be encountered; careful dissection is required to avoid venous injury.

Forceps (celioextractor)⁹⁻¹⁹ can be used to remove nodes from the abdominal cavity without any risk of abdominal wall contamination. They can also be removed through the laparoscope trocar or through a 10-mm trocar (Figure 32.13) with forceps. Analysis of suspect nodes may be indicated in order to avoid further dissection in the case of node positivity. Querleu *et al.*⁶ reported false-negative analyses in 14 cases of cervical cancer. The duration of lymphadenectomy varies from 75 to 150 min, depending largely on the associated surgical procedures, such as hysterectomy. The number of nodes removed varies; the average number of lymph nodes has been reported as 13–22^{10,19-24}, while in our series of lymphadenectomies, the number of nodes ranged from 20 to 37.

COMPLICATIONS

Vascular injury is the major potential risk of laparoscopic pelvic lymphadenectomy, but is much less frequent than expected. Significant bleeding may occur due to injury to pelvic arteries or veins. Injury to the branches of the hypogastric artery (uterine artery, superior vesical artery or umbilical artery) is managed by direct application of vascular clips or bipolar hemostasis to the vessel. Injury to the external iliac vein or a main branch of the internal iliac vein is the most serious potential complication of pelvic lymphadenectomy, because its management is more difficult than for arterial injury.

When fixed lymph nodes are encountered, any attempt at their dissection is hazardous, and cytological examination (needle aspiration) must be carried out in order to prevent venous injury²⁰. If bleeding of the external iliac

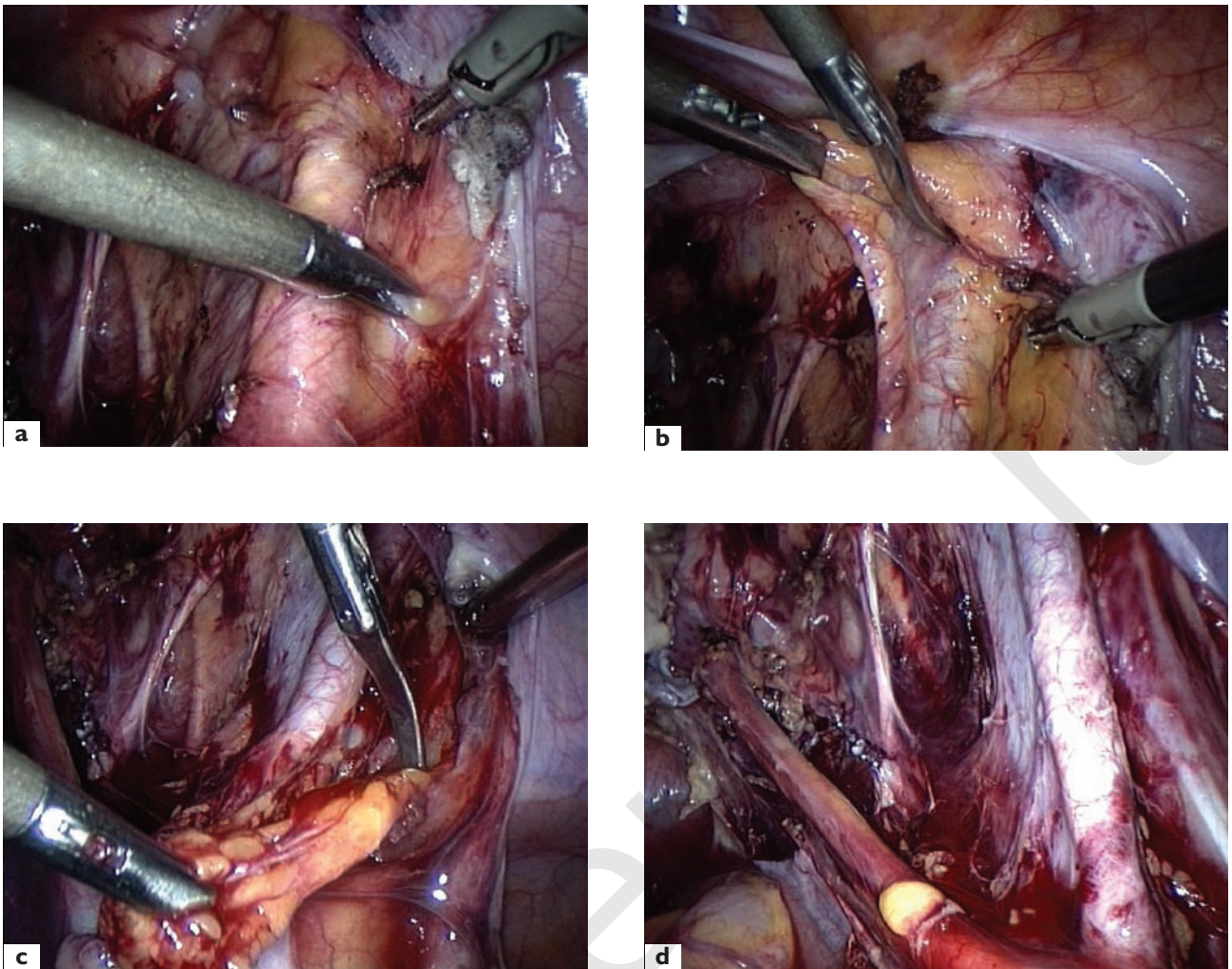


Figure 32.11 (a)–(d) Dissection of the external and subvenous lymph nodes

vein occurs, compression may be successful; a closed forceps may be firmly applied to compress the vessel against the pelvic side wall. If hemorrhage persists, the use of clips or coagulation may worsen the laceration; laparotomy must be performed in order to manage an external iliac vein laceration.

The risk of accidental section of the obturator nerve is very low. Ureteral injury during lymphadenectomy is also extremely infrequent; indeed, the ureter is not in the operative field. The ureter may, however, be identified under the peritoneum and dissected free.

Lymphocyst formation is a complication of lymph node sampling. It may be prevented by the use of surgical clips during lymph node dissection and by drainage of the retroperitoneum. Querleu and Leblanc²⁰ do not, however, place preventive clips for lymphostasis or any drain in the dissection area, and report no cases of significant lymphocyst formation.

Scarring may follow peritoneal or retroperitoneal repair. The peritoneum usually heals with minimal scarring

and no or minimal adhesions. The tissue in the retroperitoneal space heals with dense fibrosis, making any subsequent dissection difficult. If indicated, radical hysterectomy must be performed no more than 7 days after laparoscopic lymphadenectomy^{9,20}.

DISCUSSION AND CONCLUSION

The main advantage of the laparoscopic approach is that bilateral adnexectomy can be carried out laparoscopically, making a laparotomy unnecessary. Hysterectomy can then be performed either by the vaginal approach or by laparoscopy. The intraoperative advantages of this laparoscopic approach are numerous. It allows ureteral identification, complete hemostasis and evacuation of all blood clots at the end of the procedure. The removal of blood clots and instillation of intra-abdominal antiseptics or antibiotics may reduce the incidence of postoperative

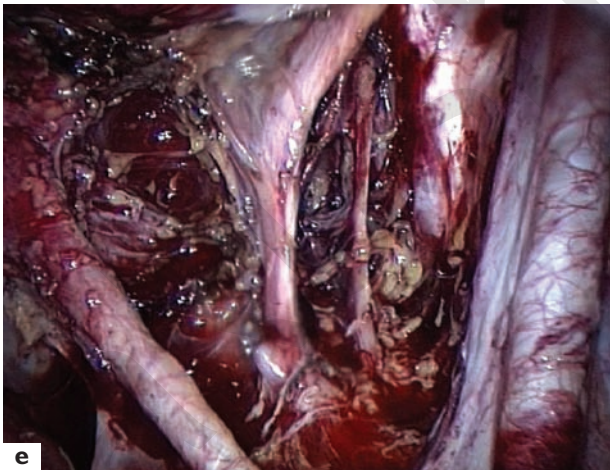
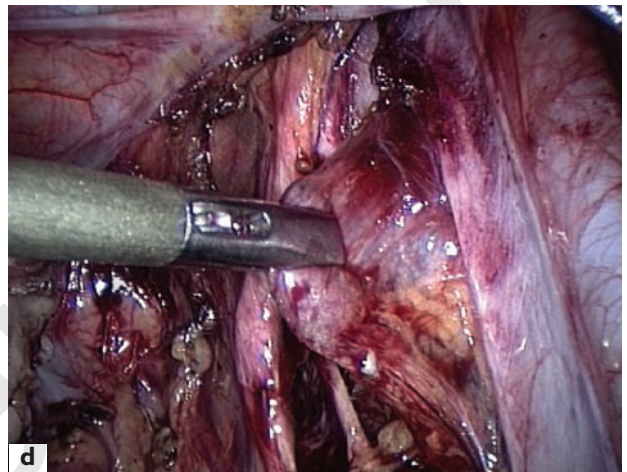
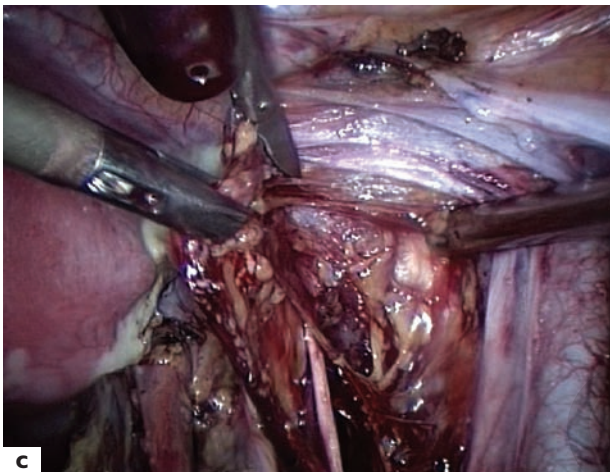
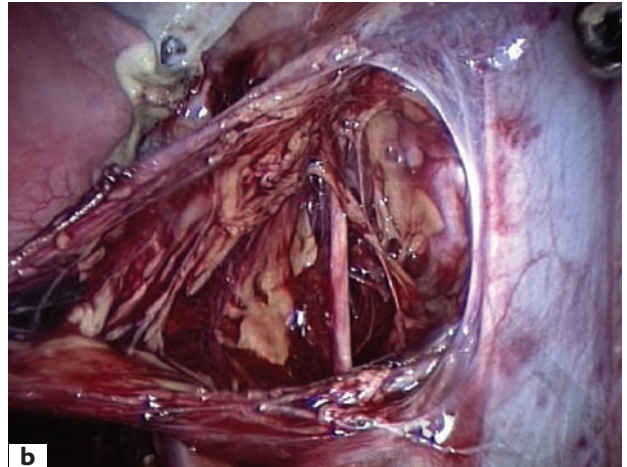
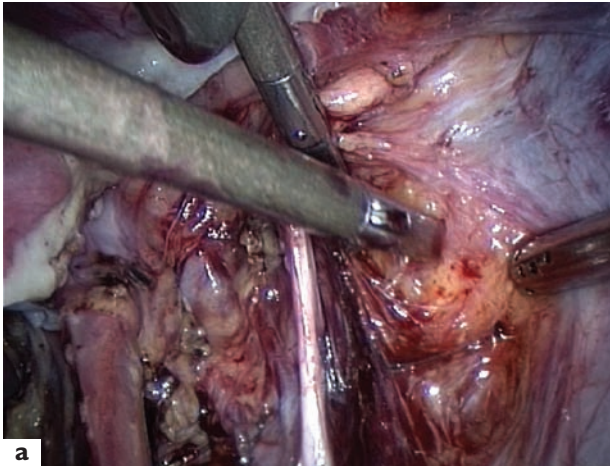


Figure 32.12 (a) Dissection of the obturator fossa. (b) Identification of the obturator nerve. (c)–(e) Resection of the lymph nodes and fatty tissue of the obturator fossa

infection associated with vaginal hysterectomy, thus decreasing the postoperative hospitalization and recovery time.

The results of radical laparoscopic hysterectomy ('Wertheim's' procedure) performed with lymphadenectomy are clearly less favorable. In spite of the less painful postoperative convalescence, significantly faster recovery

of bowel movement, less pronounced drop in the hemoglobin rate and reduced hospitalization costs²⁷, the procedure has several disadvantages. The relatively long operating time (6–8 h) and the rather difficult technical approach of this procedure^{12,27} lead us to conclude that this technique (of which only a few cases have been published) still requires further research and evaluation,

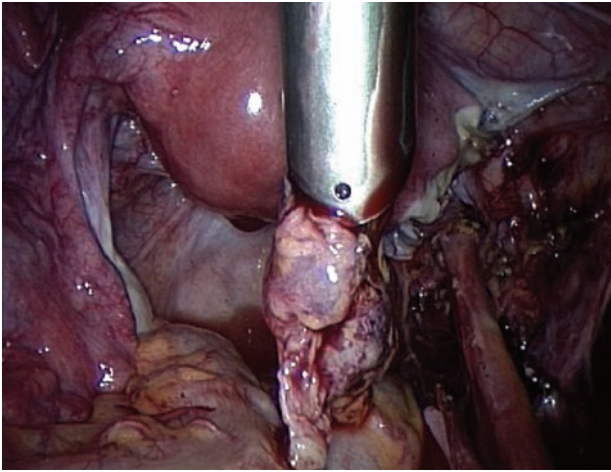


Figure 32.13 The lymph nodes are removed through a 10-mm trocar

especially in oncological surgery. Continued studies involving greater numbers of women should thus demonstrate the potential advantages of laparoscopic surgery compared with laparotomy, but also its harmful effects, such as tumor dissemination due to internal trauma during uterine mobilization or lymph node removal.

All surgical maneuvers are more or less feasible by laparoscopy; the important thing to consider with regard to this new approach to radical uterine surgery is not its feasibility, but rather whether it is justifiable and safe²⁷. As already stated in this chapter, lymphangiography is unable to visualize internal iliac and other medical node groups. Computed tomography scanning and magnetic resonance imaging are not sufficiently sensitive if the nodes are not macroscopically enlarged. PET appears to be an interesting tool, and is being evaluated in different malignancies. It is probably a very sensitive method, but not specific enough²⁸. As a consequence, lymph node biopsy remains the only reliable method for appraising the status of pelvic lymph nodes.

Pelvic lymph node sampling by a retroperitoneal endoscopic approach has been described¹⁸. Progress in laparoscopic surgery allows a surgically satisfactory pelvic lymphadenectomy to be performed, removing the obturator, external iliac and hypogastric lymph nodes. Dargent and Salvat¹⁸ have described a panoramic retroperitoneal approach, while Querleu and Leblanc have reported the technique of pelvic lymphadenectomy^{6,20} and para-aortic lymphadenectomy by laparoscopy²⁰.

The principal indication for laparoscopic lymphadenectomy in gynecological oncology is the staging of carcinoma of the cervix⁶. The risk of involvement of para-aortic nodes is very low (<1%) if the pelvic nodes are negative histologically. Stage Ib–IIa–IIb cancer with negative pathological staging may be cured by radical vaginal or abdominal surgery. However, radical hysterectomy

is not justified when metastatic nodes are present. Pretreatment laparoscopic staging of stage I endometrial carcinoma is not very useful, since the prevalence of lymph node metastasis is very low in this condition. Laparoscopic lymphadenectomy may be included in the surgical step of treatment, in association with vaginal surgery³.

REFERENCES

- Schauta R. Techniques chirurgicales. In *Encyclopedie Médico Chirurgicale*. Paris: Elsevier Science, 1961: 41–735
- Mage G, Wattiez A, Chapron C, et al. Hystérectomie per-coelioscopique: résultats d'une série de 44 cas. *J Gynecol Obstet Biol Reprod* 1992; 21: 436–44
- Donnez J, Nisolle M, Anaf V. Place de l'endoscopie dans le cancer de l'endomètre. In Dubuisson JB, Chapron C, Bouquet de Jolinière J, eds. *Coelioscopie et Cancerologie en Gynecologie*. Paris: Arnette, 1993: 77–82
- Photopoulos GJ, Stovall TG, Summitt RL Jr. LAVH, bilateral salpingo-oophorectomy, and pelvic lymph node sampling for endometrial cancer. *J Gynecol Surg* 1992; 8: 91–4
- Plentl AA, Friedman EA. *Lymphatic System of the Female Genitalia: The Morphologic Basis of Oncologic Diagnosis and Therapy*. Philadelphia: WB Saunders, 1971: 57–74
- Querleu D, Leblanc E, Castelain G. Laparoscopic pelvic lymphadenectomy in the staging of early carcinoma of the cervix. *Am J Obstet Gynecol* 1991; 164: 579–81
- Perez CA, Korba A, Sharma S. Dosimetric considerations in irradiation of carcinoma of the vagina. *Int J Radiol Oncol Biol Phys* 1977; 2: 639–45
- Querleu D, Leblanc E, Castelain B. Lymphadénectomie pelvienne sous contrôle coelioscopique. *J Gynecol Biol Reprod* 1990; 19: 576–8
- Dargent D. A new future for Schauta's operation through presurgical retroperitoneal pelviscopy. *Eur J Gynecol Oncol* 1987; 8: 292–6
- Svardi J, Vidaurreta J, Bermudez A, et al. Laparoscopically assisted Schauta operation: learning experience at the gynecologic oncology unit, Buenos Aires, University Hospital. *Gynecol Oncol* 1999; 75: 361–5
- Nezhat GR, Burrell MO, Nezhat FR, et al. Laparoscopic radical hysterectomy with para-aortic and pelvic node dissection. *Am J Obstet Gynecol* 1992; 166: 864–5
- Canis M, Mage G, Wattiez A, et al. La chirurgie endoscopique a-t-elle une place dans la chirurgie radicale du cancer du col utérin? *J Gynecol Obstet Biol Reprod* 1990; 19: 921–6
- Dargent D, Martin X, Mathevel P. Laparoscopic assessment of the sentinel lymph node in early stage cervical cancer. *Gynecol Oncol* 2000; 79: 411–15
- Vercamer R, Janssens J, De P Usewils RI, et al. Computerised tomography and lymphography in the

- presurgical staging of early carcinoma of the uterine cervix. *Cancer* 1987; 60: 1745–50
15. King LA, Talledo OE, Gallup DG, et al. Computed tomography in evaluation of gynecological malignancies: a prospective analysis? *Am J Obstet Gynecol* 1986; 60: 1055–61
 16. Walsh JM, Goplerud DR. Prospective comparison between clinical and CT staging in primary cervical carcinoma. *Am J Roentgenol* 1981; 137: 997–1003
 17. Wurtz A, Mazman E, Gosselin B, et al. Bilan anatomique des adénopathies rétropéritonéales par endoscopie chirurgicale. *Ann Chir* 1987; 41: 258–63
 18. Dargent D, Salvat J. *L'Envahissement Ganglionnaire Pelvien*. Paris: Midsi/McGraw-Hill, 1989
 19. Reich H. New techniques in advanced laparoscopic surgery. *Clin Obstet Gynecol* 1989; 3: 655–81
 20. Querleu D, Leblanc E. Laparoscopic pelvic lymphadenectomy. In Sutton C, Diamond M, eds. *Endoscopic Surgery for Gynecologists*. London: WB Saunders, 1993: 172–8
 21. Vergote I, De Wever I, Tjalma W, et al. Neoadjuvant chemotherapy or primary debulking surgery in advanced ovarian carcinoma: a retrospective analysis of 285 patients. *Gynecol Oncol* 1998; 71: 431–6
 22. Clough KB, Ladonne JM, Nos C, et al. Second look for ovarian cancer: laparoscopy or laparotomy? A prospective comparative study. *Gynecol Oncol* 1999; 72: 411–17
 23. Reich H, McGlynn F, Wickie W. Laparoscopic management of stage I ovarian cancer: a case report. *J Reprod Med* 1990; 35: 601
 24. Dexus S, Cusido MT, Suris JC, et al. Lymphadenectomy in ovarian cancer. *Eur J Gynaecol Oncol* 2000; 21: 215–22
 25. Leblanc E, Querleu D, Narducci F, et al. Surgical staging of early invasive epithelial ovarian tumors. *Semin Surg Oncol* 2000; 19: 36–41
 26. Morice P, Pautier P, Mercier S, et al. Laparoscopic prophylactic oophorectomy in women with inherited risk of ovarian cancer. *Eur J Gynaecol Oncol* 1999; 20: 202–4
 27. Canis M, Mage G, Wattiez A, et al. Vaginally assisted laparoscopic radical hysterectomy. *J Gynecol Surg* 1992; 8: 103–5
 28. Anderson H, Price P. What does positron emission tomography offer oncology? *Eur J Cancer* 2000; 36: 2028–35

Indications for lymphadenectomy in stage I/Ia endometrial cancer

J Squifflet, J Donnez

Endometrial carcinoma is the most common pelvic malignancy in the Western world. Because most patients present with early-stage disease, the prognosis of endometrial carcinoma is generally good, with a survival rate between 90 and 95%. Due to this favorable outcome in most cases, the goal is to select patients at increased risk of relapse who might benefit from more extensive surgical procedures and adjuvant therapies, and to avoid over-treatment of low-risk cases that would be exposed to the risk of excess morbidity.

The decision to perform lymphadenectomy is dependent upon preoperative assessment and the risk of nodal metastases.

The number of early-stage versus advanced-stage cases observed in clinics depends on different factors. First, we know that the longer a patient experiences postmenopausal bleeding, the more advanced the stage of disease may be. If patients were more aware of the need to present for treatment as soon as possible in the case of postmenopausal bleeding, we would diagnose the disease at an earlier stage. In populations of lower socioeconomic status and education potential, with no medical follow-up or screening, the time between the onset of symptoms and diagnosis could be even longer, and the stage of disease more advanced.

MEDICAL ADVICE

In our department, all patients presenting with postmenopausal bleeding undergo a classic clinical evaluation (Papanicolaou (PAP) smear with evaluation of the size and mobility of the uterus). A normal PAP smear is not sufficient to exclude endometrial cancer in symptomatic women, but an abnormal result is more frequently associated with more advanced disease. The presence of

atypical glandular cells (AGUS) or normal endometrial cells increases the risk of extrauterine disease¹⁻³.

The normal thickness of the endometrium during transvaginal sonography is less than 4–5 mm. It appears as a thin symmetrical and regular line. In these conditions, the risk of endometrial cancer is very low. Above this threshold, or in the case of an irregular or asymmetrical appearance of the endometrium, an office hysterectomy (Storz optic 2.7 mm) or endometrial biopsy is proposed.

A recent comparison of saline infusion sonography and office hysteroscopy revealed similar patient ratings of pelvic pain during the procedures. Sensitivity and specificity coefficients, as well as negative and positive predictive values, were higher with office hysteroscopy⁴. Office hysteroscopy can evaluate the range of the disease, and even its extension through the cervix. Endometrial biopsy is performed after hysteroscopy to determine the histological grade and differentiation, and the histological type of the lesions.

An elevated CA125 level could be a marker of extrauterine disease in a case of endometrial cancer. In a non-multivariable evaluation, it is difficult to identify a cut-off value below which lymphadenectomy can be avoided, and above which lymphadenectomy should be proposed. Dotters showed that a CA125 level >20 U/ml, with a grade 3 tumor, correctly predicted 87% of patients requiring complete surgical staging. In stage I disease with a histological grade of 1 or 2 and a CA125 level below 20 U/ml, the risk of nodal metastases is low^{5,6}.

Magnetic resonance imaging (MRI) could be proposed for the evaluation of myometrial invasion and retroperitoneal node involvement (pelvic and lumboaortic area). In the case of more advanced disease, a computed tomography (CT) scan of the abdomen and the chest should be proposed (Table 33.1).

Table 33.1 Clinicopathological prognostic factors in endometrial cancer

FIGO stage (1998)	Corpus–cervix and peritoneal cytology
Histological subtype	Endometrioid or non-endometrioid (serous–papillary and clear cell)
Myometrial invasion	
Lymphovascular space invasion	
Tumor size	
Age	

FIGO, International Federation of Gynecologists and Obstetricians

Table 33.2 Risks of pelvic lymph node metastases in stage I disease⁷

Depth	Grade 1 (%)	Grade 2 (%)	Grade 3 (%)
Endometrium	0	3	0
Inner third	3	5	9
Middle third	0	9	4
Outer third	11	19	34

In stage I disease, the risk of nodal involvement depends on the grade of the lesion and the myometrial invasion. We have identified three different types of disease in terms of nodal involvement (Table 33.2):

- Low risk of nodal involvement with a 5-year survival rate >90% (grade 1, stage Ia or Ib; grade 2, stage Ia and Ib)
- Intermediate risk of nodal involvement with a 5-year survival rate between 80 and 90% (grade 1, stage Ic; grade 2, stage Ic; grade 3, stage Ia and Ib)
- High risk of nodal involvement with a 5-year survival rate below 70% (grade 3, stage Ic)

RATIONALE FOR LYMPHADENECTOMY

Since 1988, pelvic node involvement has represented stage IIIc disease in the International Federation of Gynecologists and Obstetricians (FIGO) classification of endometrial cancer, and hence avoiding lymphadenectomy could result in incomplete staging of the neoplasia.

The rate of positive nodes found in stage I disease ranges from 4.7 to 11%. The size of pelvic lymph nodes does not predict metastatic involvement in patients with endometrial cancer. Fewer than 30% of positive nodes are palpable⁸. In 1996, Reich *et al.*⁹ showed that 54% of positive nodes measured less than 10 mm, while at least 29% of negative nodes were larger than 10 mm.

Palpation during intraoperative evaluation is not reliable to detect node metastases¹⁰. Furthermore, nodes may be positive even in low-risk patients^{11,12}.

In a meta-analysis, Nijman *et al.*¹³ found an average of 11 nodes (range 0–42) removed during lymphadenectomy for endometrial cancer, with seven at the 10th centile. For Kilgore *et al.*¹⁴ and Cragun *et al.*¹⁵, the extent of lymphadenectomy (more than 11 nodes removed) in high-risk patients (poorly differentiated tumors, stage Ic, grade 3) correlates with better survival. For these reasons, simple node sampling is unreliable for diagnosis

Furthermore, lymphadenectomy in intermediate- and high-risk patients may identify subgroups of patients at

very low risk of recurrence, who could avoid total pelvic radiotherapy.

When brachytherapy is performed after complete staging surgery in endometriotic carcinoma, we observe a mean recurrence of 6%, with all recurrences located outside the pelvis^{16–19}. Thus, external pelvic radiotherapy may be avoided in a case of negative nodes, and brachytherapy should be proposed in the case of a high-risk patient (Gynecologic Oncology Group (GOG) study, reference 24).

WHICH NODES SHOULD BE REMOVED?

Lymphatic spread is more common in external iliac nodes. For Mariani *et al.*²⁰, external iliac and obturator nodes are more frequently the first site of metastases in cases of involvement of the uterine corpus.

In stage II disease (cervical involvement), the first sites of metastases are the common iliac nodes. In a review of the use of sentinel lymph node identification in endometrial cancer, the sentinel lymph node was found between the common iliac vessels and the ilio-obturator vessels in 60–92% of cases²¹.

EFFECTIVENESS OF RADIOTHERAPY

Three large randomized controlled trials are presented. In 1980, Aalders *et al.*²² (Norwegian Radium Hospital Study) published a study of 540 stage I patients. Total abdominal hysterectomy with bilateral salpingo-oophorectomy was systematically performed, with a follow-up of 10 years. The patients were randomized between brachytherapy and brachytherapy with pelvic irradiation. Overall survival was not statistically significantly different (90% vs. 87%), but locoregional recurrence rates were lower in the pelvic irradiation group (1.9% vs. 6.9%; $p < 0.01$).

A subgroup of cases (grade 3, stage Ic) benefited more from pelvic irradiation, showing a decrease in local recurrence and death from the disease. Significantly more deaths and recurrences were encountered among patients with tumor cells in endothelial spaces than among those without vessel invasion (26.7% vs. 9.1%; $p < 0.01$).

In 2000, Creutzberg *et al.* published a randomized controlled trial of 715 cases (Post Operative Radiation Therapy in Endometrial Cancer (PORTEC) I study)²³. Patients presenting with stage I disease underwent total abdominal hysterectomy with bilateral salpingo-oophorectomy, without lymphadenectomy.

Stage Ic, grade 3 and all Ia stages were excluded. The median follow-up was 52 months. After surgery, patients received either external radiation (46 Gy) or no further treatment. The 5-year locoregional recurrence rate was 4% in the radiation group vs. 14% in the control group ($p < 0.001$). There was no difference in distant metastases between the two groups (8% vs. 7% for the control group).

As vaginal recurrence could be controlled by surgery and/or radiotherapy if none was previously given, the 3-year survival rate after recurrence was 69%. In the case of vaginal recurrence after pelvic radiotherapy, overall survival at 3 years was less than 25%. However, in the case of pelvic or distant relapse, the prognosis was very poor; the 3-year survival rate was just 13%.

Overall survival was 85% in the control group and 81% in the radiotherapy group. Most of the deaths that occurred were not related to the endometrial disease (Tables 33.3 and 33.4).

In 2004, Keys *et al.* (GOG study) presented a study of 392 patients who underwent total abdominal hysterectomy with bilateral salpingo-oophorectomy, and with lymphadenectomy²⁴. In the case of negative nodes,

patients were further randomized to receive pelvic radiotherapy (50 Gy) or not. The disease-free survival rate after 4 years was 86% in the no-treatment group versus 92% in the radiotherapy group, but there was no difference in overall survival. A decreased pelvic recurrence rate was observed in the radiotherapy group compared with the control group: 1.7% vs. 12%.

In this study, a high-intermediate-risk subgroup was identified: grade 3, presence of lymphovascular space involvement, deep myometrial invasion and age (above 70 years). A high intermediate risk is defined as: above 70 years of age with one of the risk factors; or above 50 years of age with two of the risk factors; or three of the risk factors. This corroborates the findings of other studies that lymphadenectomy and radiotherapy may have an impact on survival in a subgroup of patients with poor prognosis.

INDICATIONS FOR LYMPHADENECTOMY

Lymphadenectomy may clearly be avoided in endometrioid adenocarcinoma of stage I, grade 1 or 2, when the disease is limited to the inner part of the myometrium and the size of the lesion is less or equal to 2 cm²⁵. In these circumstances, the risk of nodal metastases is less than 5%, and may even be 0%. However, numerous studies suggest that at least 20% of stage I patients are understaged by surgery²⁶.

Table 33.3 Complications

Study	Treatment	Gastrointestinal grade 3 or 4 (%)
PORTEC ²³	Radiotherapy	3
GOG ²⁴	Lymphadenectomy + radiotherapy	8
	Brachytherapy	0-1

PORTEC, Post Operative Radiation Therapy in Endometrial Cancer; GOG, Gynecologic Oncology Group

Table 33.4 Recurrence rate

Study	No radiotherapy (%)	Radiotherapy (%)	p Value
PORTEC ²³	14	4	< 0.05
Aalders <i>et al.</i> ²²	7 (brachytherapy)	2	< 0.05
GOG ²⁴	12	3	< 0.05
vaginal and pelvis site only after 24 months	7.4	1.6	< 0.05
GOG ²⁴ Hir	26	6	< 0.05
GOG ²⁴ Lir	6	2	Ns

PORTEC, Post Operative Radiation Therapy in Endometrial Cancer; GOG, Gynecologic Oncology Group; Hir, high intermediate risk; Lir, low intermediate risk

In stage I disease with pelvic lymphadenectomy and no brachytherapy, Orr *et al.*²⁷ observed survival rates of 100%, 97% and 93% in stage Ia, Ib and Ic disease, respectively. Good results may therefore be obtained in correctly staged patients even in the absence of radiotherapy.

The challenge is correctly evaluating all the low- and high-risk patients preoperatively. Of course, anatomopathological evaluation is the only available technique to evaluate lymphovascular space involvement.

The grade of the lesions may also be under- or overestimated between the preoperative evaluation and post-surgery²⁸. Tumor grade was found to change, from the diagnostic dilatation and curettage (D&C) specimen to the definite surgical specimen, in 31% of all cases and in 50% of all grade 3 lesions. Sixteen per cent of grade 1 and 2 lesions were overgraded to grade 3, and up to 50% of grade 3 lesions may have been undergraded to grade 1 or 2.

Myometrial invasion may be assessed by ultrasonography, transvaginal ultrasonography or MRI, but, in clinical practice, these evaluations do not always correlate with anatomopathological findings.

Preliminary data from the UK Medical Research Council ASTEC study (Randomized Trial of Lymphadenectomy and of Adjuvant External Beam Radiotherapy in the Treatment of Endometrial Cancer) were recently presented at the 14th Congress of the European Society of Gynecological Oncology in Istanbul. This multicenter randomized trial evaluated the impact of pelvic lymphadenectomy on the treatment of endometrial cancer located in the uterus.

More than 1400 patients were recruited between 1998 and March 2005. All patients were fit to receive lymphadenectomy, and all centers able to offer lymphadenectomy. Less than 10% of surgery was done by laparoscopy. After a median duration of 3 years of follow-up, disease-free survival and overall survival were not statistically different in the two groups. The incidence of complications, however, was higher in the lymphadenectomy group (8% vs. 3% in the control group).

More than 80% of the lesions were classified as stage I. In the lymphadenectomy group, 9% of removed nodes were positive, and the mean number of nodes removed was 14. These data are preliminary, and need to be completed by further studies.

After surgical treatment, depending on the anatomopathological findings, two groups were identified: a low-risk group and a high-risk group. The high-risk group was further randomized to receive either radiotherapy or not. These data have not yet been presented.

In the future, with a longer follow-up, different subgroups may be identified. Indeed, we know that some groups have shown statistically significant survival benefits in poorly differentiated neoplasia with more than 11 nodes removed. In the study by Cragun *et al.*¹⁵, the rates of pelvic and aortic nodal metastases were 5% and 3%, respectively, due to the exclusion of patients with grossly involved nodes.

Survival analysis showed a significant survival benefit for patients with grade 3 disease who had 11 or more nodes removed (5-year survival rate of 82% vs. 64%; $p < 0.01$). Patients with grade 1 or 2 disease did not show any survival difference, based on the number of nodes removed. Aortic node removal did not significantly influence survival (hazard ratio 1.29). The exclusion of patients with pelvic or aortic nodal metastases from the analysis still resulted in a significant survival benefit among patients with grade 3 cancer who had more than 11 nodes removed. Patients with 11 or more nodes removed had a lower rate of pelvic recurrence (1% vs. 5%; $p < 0.02$) and a similar rate of vaginal recurrence (2% vs. 3%).

The analysis by Cragun *et al.* suggests that lymphadenectomy should be considered for patients with grade 3 cancer, but there is no benefit for grade 1 or 2 disease. Lymphadenectomy should yield more than 11 pelvic nodes from multiple sites. This cut-off of 11 nodes is arbitrary, however. It is simply supported by statistical analysis. While it reflects the completeness of lymphadenectomy, its effectiveness is nevertheless dependent on the pathologist's evaluation of the surgical specimens.

The number of sections obtained per node and the application of immunohistochemistry for the detection of metastases also influences the results and the conclusions in the literature. In the study by Cragun *et al.*¹⁵, it is interesting to note the persistence of improved survival rates among patients with grade 3 cancer from whom more than 11 nodes were removed, even in those with positive nodes who were excluded from the analysis.

The authors hypothesize that the removal of occult (micro) metastatic disease, not seen during histological examination, may have a therapeutic effect.

In conclusion, pelvic lymphadenectomy may be omitted in stage I endometrial cancer in cases of grade 1 or 2 lesions with less than 50% myometrial invasion and lesions less than 2 cm in size.

In cases of grade 3 lesions, factors such as deep myometrial invasion, vascular space involvement and especially age above 70 years seem to be correlated with a poorer prognosis. Nevertheless, physical status, life expectancy and associated morbidity could influence the feasibility and indications for lymphadenectomy in these patients. Indeed, lymphadenectomy could determine the risk of recurrence after surgery (low risk or high risk) and identify the necessary adjuvant treatment: extension of radiotherapy (external beam, brachytherapy, extension field) and/or chemotherapy.

In grade 3 lesions with deep myometrial invasion or non-endometrioid histological cancer, pelvic lymphadenectomy may even have a therapeutic effect.

This proves that preoperative evaluation of the patient has to be as complete as possible in order to identify the risk factors of pelvic node involvement.

REFERENCES


- Fukuda K, Mori M, Uchiyama M, et al. Preoperative cervical cytology in endometrial carcinoma and its clinicopathologic relevance. *Gynecol Oncol* 1999; 72: 273–7
- Larson DM, Johnson KK, Reyes CN Jr, Broste SK. Prognostic significance of malignant cervical cytology in patients with endometrial cancer. *Obstet Gynecol* 1994; 84: 399–403
- DuBeshter B, Deuel C, Gillis S, et al. Endometrial cancer: the potential role of cervical cytology in current surgical staging. *Obstet Gynecol* 2003; 101: 445–50
- Garuti G, Cellani F, Grossi F, et al. Saline infusion sonography and office hysteroscopy to assess endometrial morbidity associated with tamoxifen intake. *Gynecol Oncol* 2002; 86: 323–9
- Dotters DJ. Preoperative CA125 in endometrial cancer: is it useful? *Am J Obstet Gynecol* 2000; 182: 1328–34
- Kurihara T, Mizunuma H, Obara M, et al. Determination of a normal level of serum CA125 in postmenopausal women as a tool for preoperative evaluation and postoperative surveillance of endometrial carcinoma. *Gynecol Oncol* 1998; 69: 192–6
- Creasman WT, Morrow CP, Bundy BN, et al. Surgical pathologic spread patterns of endometrial cancer; a Gynecologic Oncology Group study. *Cancer* 1987; 60: 2035–41
- Creasman WT, Bornow RC, Morrow CP, et al. Adenocarcinoma of the endometrium: its metastatic lymph node potential. A preliminary report. *Gynecol Oncol* 1976; 4: 239–43
- Reich O, Winter R, Pickel H, et al. Does the size of pelvic lymph nodes predict metastatic involvement in patients with endometrial cancer? *Int J Gynecol Cancer* 1996; 6: 445–7
- Arango HA, Hoffman MS, Roberts WS, et al. Accuracy of lymph node palpation to determine need for lymphadenectomy in gynecologic malignancies. *Obstet Gynecol* 2000; 95: 553–6
- Takehima N, Umezawa S, Shimizu Y, et al. Pelvic lymph node metastasis in endometrial cancer. *Nippon Sanka Fujinka Gakkai Zasshi* 1994; 46: 883–8
- Watanabe M, Aoki Y, Kase H, et al. Low risk endometrial cancer: a study of pelvic lymph node metastasis. *Int J Gynecol Cancer* 2003; 13: 38–41
- Nijman HW, Khalifa M, Covens A. What is the number of lymph nodes required for an 'adequate' pelvic lymphadenectomy? *Eur J Gynaecol Oncol* 2004; 25: 87–9
- Kilgore LC, Partridge EE, Alvarez RD, et al. Adenocarcinoma of the endometrium: survival comparisons of patients with and without pelvic node sampling. *Gynecol Oncol* 1995; 56: 29–33
- Cragun J, Havrilesky L, Calingaert B, et al. Retrospective analysis of selective lymphadenectomy in apparent early-stage endometrial cancer. *J Clin Oncol* 2005; 23: 3668–75
- Fanning J, Nanavati PJ, Hilgers RD. Surgical staging and high dose rate brachytherapy for endometrial cancer: limiting external radiotherapy to node-positive tumors. *Obstet Gynecol* 1996; 87: 1041–4
- Orr JW Jr. Surgical staging of endometrial cancer: does the patient benefit? *Gynecol Oncol* 1998; 71: 335–9
- Larson DM, Broste SK, Krawisz BR. Surgery without radiotherapy for primary treatment of endometrial cancer. *Obstet Gynecol* 1998; 91: 355–9
- Mohan DS, Samuels MA, Selim MA, et al. Long-term outcomes of therapeutic pelvic lymphadenectomy for stage I endometrial adenocarcinoma. *Gynecol Oncol* 1998; 70: 165–71
- Mariani A, Webb MJ, Keeney GL, et al. Predictors of lymphatic failure in endometrial cancer. *Gynecol Oncol* 2002; 84: 437–42
- Barranger E, Cortez A, Grahek D, et al. Laparoscopic sentinel node procedure using a combination of patent blue and radiocolloid in women with endometrial cancer. *Ann Surg Oncol* 2004; 11: 344–9
- Aalders J, Abeler V, Kolstad P, et al. Postoperative external irradiation and prognostic parameters in stage I endometrial carcinoma: clinical and histopathologic study of 540 patients. *Obstet Gynecol* 1980; 56: 419–27
- Creutzberg CL, van Putten WL, Koper PC, et al. Surgery and postoperative radiotherapy versus surgery alone for patients with stage-I endometrial carcinoma: multicentre randomized trial – PORTEC Study Group. *Post Operative Radiation Therapy in Endometrial Carcinoma. Lancet* 2000; 355: 1404–11
- Keys H, Roberts J, Brunetto V, et al. A phase III trial of surgery with or without adjunctive external pelvic radiation therapy in intermediate-risk endometrial adenocarcinoma: a Gynecologic Oncology Group study. *Obstet Gynecol Surv* 2004; 59: 516–18
- Mariani A, Webb MJ, Keeney GL, et al. Low-risk corpus cancer: is lymphadenectomy or radiotherapy necessary? *Am J Obstet Gynecol* 2000; 182: 1506–19
- Orre JW, Roland PY, Leichter D, Orr PF. Endometrial cancer: is surgical staging necessary? *Curr Opin Oncol* 2001; 13: 408–12
- Orr JW, Holimion JL, Orr PF. Stage I corpus cancer: is teletherapy necessary? *Am J Obstet Gynecol* 1997; 176: 777–9
- Sant Cassia LJ, Weppelmann B, Shingleton H, et al. Management of early endometrial carcinoma. *Gynecol Oncol* 1989; 35: 362–6

Dedication

Professor Dargent was one of the great pioneers of endoscopic surgery, especially in the field of oncological endoscopy. A brave and enterprising surgeon, he performed the first lymphadenectomy by laparoscopy, as well as the first radical conservative surgical procedure for cervical cancer in young patients, in an attempt to preserve their fertility. He championed the technique and never swayed from his convictions, even in the face of strong opposition. And his tenacity paid off. Today the technique is routinely performed by gynecologists all over the world.

As suggested by Professor Querleu, this surgical technique should now be named after him, as a tribute to his dedication and perseverance. From now on, this procedure should be known as Dargent's operation.

He shall be greatly missed but his contribution to endoscopic surgery will never be forgotten.



Place of laparoscopic surgery in the management of cervical cancer: the Dargent techniques

34

D Dargent, P Mathevet

INTRODUCTION: WARNING

It is in the field of cervical cancer management that laparoscopic surgery first entered the realm of oncology. It was in 1986 that we started using the laparoscope to assess the pelvic lymph nodes, before taking a decision in the management of early-stage cervical cancer¹. In the following years, the 'staging laparoscopy' became more and more popular, and spread to the management of other intraperitoneal or retroperitoneal malignancies. At the same time, laparoscopy also started being used to assist extirpative surgery, the role played by laparoscopic preparation becoming larger and larger.

As soon as laparoscopy was used in the dissection of malignant tumors, it appeared that the chances for abdominal recurrence and intraperitoneal tumor seeding were increased². Adenocarcinomas are more likely to give rise to such complications, but these complications can also occur in the handling of epidermoid cancers. The use of the open technique (which includes the necessity of an abdominal closure) and the use of the gasless technique could lessen the risk. However, it is clear that laparoscopic surgery is dangerous in itself, because tumor manipulation is more important. For these reasons, laparoscopy can only be accepted if the dissections are carried out at a distance from the tumor bulk³.

Laparoscopic lymphadenectomy is an acceptable operation, providing that the lymph nodes are not enlarged and not infiltrated and fixed. Accurate imaging is necessary before taking the decision. The endoscopic dissection has to be discussed in the case of suspicious findings, or similarly, if suspicious symptoms appear at the beginning of the endoscopic assessment. It is only in cases where the nodes are of normal size that the dissection can be carried out using the laparoscope. One knows that metastasis can exist in normal-size nodes (that is the reason why systematic lymphadenectomy is scheduled), but the chances are low for an involvement and, even more, for rupture of the capsule.

Assistance by radical surgery is also an acceptable operation, the condition being that the surgical divisions are also made at a distance from the tumor itself. This rule, in fact, is not different from the rules of conventional radical surgery. As far as cervical cancer is concerned, it means that radical surgery must be limited to early-stage cases. If the laparoscopic technique is chosen, the use of a uterine manipulator must be prohibited, as this increases the chances for peritoneal diffusion⁴. On the other hand, it is

better to use laparoscopic vaginal radical surgery than purely laparoscopic surgery, since, by starting the surgery while making a vaginal cuff and closing it with appropriate forceps, one completely isolates the tumor for the remainder of the operation.

LAPAROSCOPIC LYMPHADENECTOMY

Pelvic and aortic lymphadenectomies are part of the current standard management of cervical cancer. They can be carried out with the laparoscope. Before undertaking the laparoscopic dissection, one has to make sure, using magnetic resonance imaging (MRI) for the pelvic area and computed tomography (CT) scan for the aortic area, that lymph nodes more than 2 cm in size are not present. If not, the laparoscope can be used on the condition that its use is stopped if unexpected obvious metastatic involvement is found.

Laparoscopic pelvic lymphadenectomy

The most popular technique used for performing laparoscopic pelvic lymphadenectomy is the transumbilical, transperitoneal one. The set-up is the same as for routine laparoscopy. The ancillary ports are opened rather high (just underneath the line joining the two iliac spines): one in the midline (10–12 mm) and the other two medial to the iliac spines, lateral to the inferior epigastric vessels (5 mm). A fourth port (5 mm) is required in the para-umbilical area, either on the right or the left side, if para-aortic lymphadenectomy has to be carried out.

The surgeon intending to perform the pelvic dissection stays on the patient's left side. The video monitor is put at the foot of the operating table. The peritoneum is divided alongside the pelvic brim (Figure 34.1) between the round ligament and the infundibulopelvic ligament, which is best left undivided until the dissection is finished. Prior to peritoneal opening, the umbilical ligament is located, which lifts an oblique peritoneal fold on the posterior surface of the abdominal wall. By following this 'Ariadne's thread' from front to back, it is easy, once the broad ligament is opened, to identify the superior vesical artery of which the umbilical ligament is a ventral continuation (Figure 34.2). The superior vesical artery is the first surgical landmark in the pelvic dissection. Pushing it medially enables one to open the paravesical space and free up the pelvic side wall. This also reveals the external iliac vessels at the point at which they cross the Cooper's ligament. In obese patients,

whose anatomical structures are covered with fatty tissue, it is recommended first to locate the Cooper's ligament (Figure 34.3). This can be identified by palpation with a blunt instrument driven on the posterior surface of the abdominal wall, lateral to the umbilical ligament – acting the same way as a blind man seeking the edge of the pavement with his white stick.

The dissection is started by grasping the tissues located caudally to the external vein and gently pulling on them, while at the same time a second instrument tears the connective fibers and lymphatic channels joining the node-bearing tissues to the surrounding structures. It is common to find an inferior obturator vein at this level which crosses the nodes that are required; blunt dissection is generally enough to circumvent this. Once the subvenous nodes are freed, revealing the obturator nerve, the external iliac vein is traced back to point where it meets the internal iliac

vein. The same is done for the tissues located between the external iliac artery and the external iliac vein. The ascending dissection leads to bifurcation of the common iliac artery.

The next step concerns the node-bearing tissues located between the external iliac artery and the psoas muscle. One starts ventrally, at the level of the origin of the circumflex artery, and continues dorsally to the level of the common iliac artery. At this time, it is often necessary to make a lateral peritoneal incision in order to reflect upwards the ileocecal junction on the right side and the sigmoid colon on the left side. The ureter is identified at the level it crosses the vessels. If the infundibulopelvic ligament has not been divided and the posterior sheet of the broad ligament is intact, the ureter remains attached to its natural support. Both are pushed medially. The pararectal space is then opened (Figure 34.4). The node-bearing

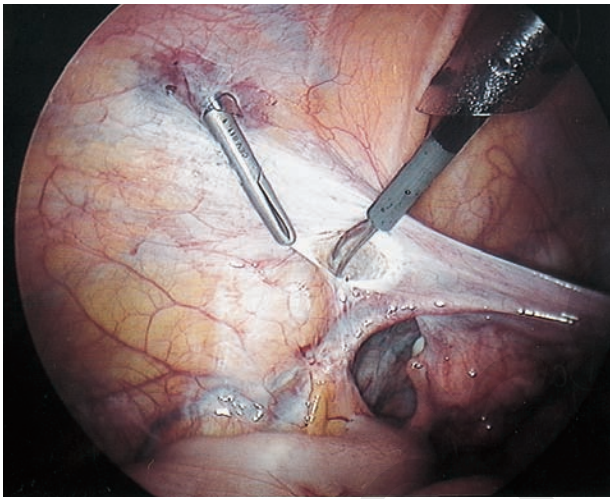


Figure 34.1 Incision of the peritoneum between the round ligament and the infundibulopelvic ligament (left side)

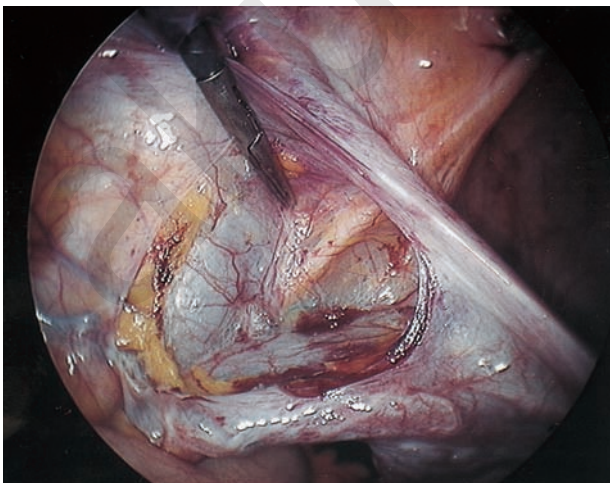


Figure 34.2 Identification of the superior vesical artery: traction medially onto the umbilical ligament

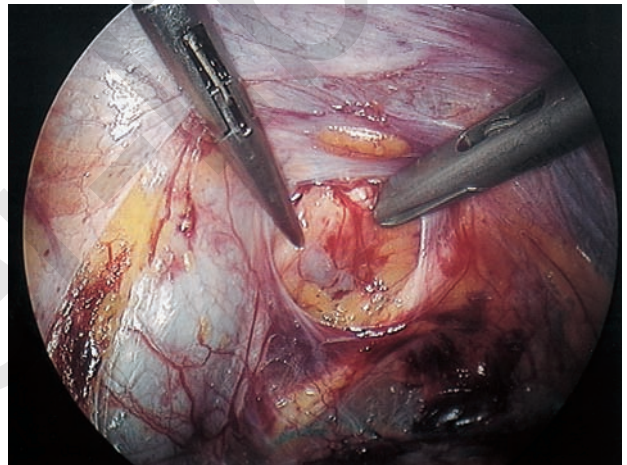


Figure 34.3 Identification of the Cooper's ligament which is crossed vertically by a collateral of the external iliac vein: the inferior obturator vein

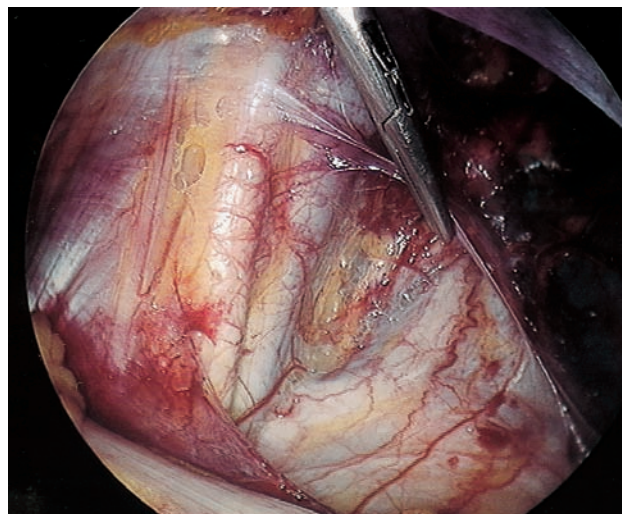


Figure 34.4 Opening the pararectal space

tissues alongside the inferior aspect of the common iliac artery and posterior aspect of the internal iliac artery are freed up.

The order in which the landmarks are identified and the different steps and techniques of dissection are performed varies from surgeon to surgeon. As for the technique of dissection, the simplest is the best, i.e. grasping the nodes with 'grasping forceps' (crocodile forceps) and tearing the surrounding structures with 'dissecting forceps' (cobra forceps). Such a technique (Figure 34.5) requires skill, but once this skill is acquired it is certainly less bloody: only the resistant structures, the blood vessels, have to be controlled before being divided, and they are few if the dissection is made in the appropriate way, not too far from and not too close to the nodes.

Two options are offered for removal of the nodes. The first is gathering them somewhere (in the uterovesical space, for example) and extracting them at the end of the procedure using an extracting bag. The second, and our preferred technique, is to use the Coelio-extractor[®], which enables us to deliver the nodes one by one without contaminating the abdominal wall.

Querleu *et al.*⁵ were the first to give data concerning the feasibility and safety of transumbilical transperitoneal laparoscopic pelvic dissection. For the 39 procedures they performed on patients affected by cancer of the cervix, stage Ib/IIb, the mean duration of the procedure was 80 min. No conversion to laparotomy was needed. The mean yield of nodes was 8.7. Positive nodes were found in five patients who were submitted to exclusive radiotherapy, as the 34 other patients were operated on and submitted either to abdominal radical hysterectomy (32 patients) or to vaginal radical hysterectomy (two patients). All the patients were reassessed after 5 years. The 5-year life-table survival rate was similar to the survival of a historical group matched for age, stage and therapy. Childers *et al.*⁶

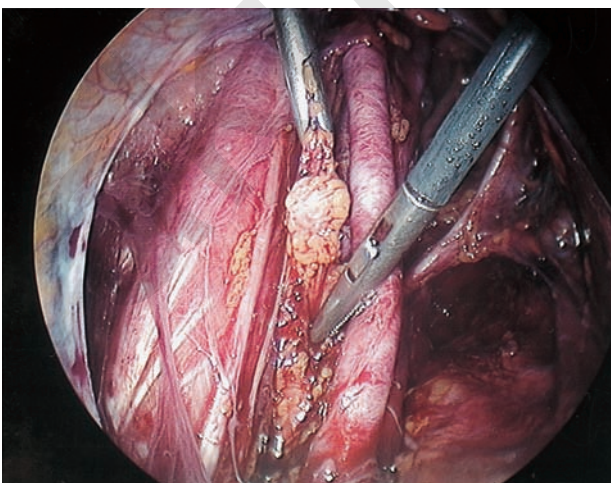


Figure 34.5 Dissection of the dorsal external iliac nodes: 'two forceps technique'

reported data collected from 18 procedures performed for cervical cancer, among which five were immediately submitted to abdominal radical hysterectomy and 13 were assessed before radiotherapy. No complications were observed. The duration of the staging procedure was 75–175 min for the patients assessed before radiotherapy. The lymph node yield was medially 31.4 (17–37) for the patients submitted to abdominal radical hysterectomy. One year later, data about 53 patients affected by endometrial cancer were presented⁷. All the patients were assessed with the laparoscope and 29 of them were submitted to pelvic lymphadenectomy plus aortic sampling. Three intra-operative complications occurred (one pneumothorax, one transection of the ureter and one bladder lesion) and three postoperative complications (two bowel obstructions and one left-side pulmonary collapse). The issue was addressed again 5 years later⁸ for 125 patients. The rate of complications did not vary. However, the rate of conversion to laparotomy dropped from 8% (2/25) to 0% (0/100). At the same time, the operation time decreased from 196 min to 128 min ($p < 0.02$) and the hospital stay from 3.2 days to 1.8 days ($p < 0.0001$).

Since 1993, most of the published series^{9–18} include data concerning the low aortic lymph node sampling, which was added to the pelvic dissection. Summarizing the data (Table 34.1), one can assume that the mean number of nodes retrieved with the scope was about 25 (plus five to ten aortic nodes). This number is close to the number of nodes retrieved in open surgery. Comparative studies confirmed that the numbers were about the same. Fowler *et al.*⁹ pointed out that 25% of the pelvic nodes were still present at laparotomy after the patient had undergone a laparoscopic lymphadenectomy. However, no patient with negative nodes at laparoscopy had positive nodes at laparotomy. Moreover, Spirtos *et al.*¹³, in a comparative study, obtained medially 20 pelvic nodes (plus eight para-aortic) in 13 patients operated on with a laparoscope versus 22 (plus seven para-aortic) in 16 patients operated on by laparotomy.

Concerning the safety of laparoscopic lymphadenectomy, the data collected in the Gynecologic Oncology Group (GOG) study¹⁹ are the most informative. The mean number of retrieved nodes is 32.1 (16.6 on the left side and 15.5 on the right side). In spite of this record number, the results were judged incomplete in six of the 40 patients submitted to laparotomy after the laparoscopic lymphadenectomy. In fact, removing a high number of nodes is meaningless. The point is to remove the significant nodes. The extreme rarity of pelvic side-wall recurrences in laparoscopically pN₀ patients managed without laparotomic lymphadenectomy or radiotherapy indicates that laparoscopy enables us to remove the significant nodes, even if the total number of nodes is low (see later). If a criterion of safety had to be elected, photographic records taken at the end of the laparoscopic procedure would be the best. In the GOG study, the result was judged inadequate in three of the patients whose photographic records

Table 34.1 Lymph node yield after laparoscopic pelvic lymphadenectomy

Reference	Number of cases	Cancer	Associated OP	Number of nodes ± aortic
Querleu <i>et al.</i> ⁵	39	Cervix I II	ARH 32	8.7 LAVRH 2
Childers <i>et al.</i> ⁶	18	Cervix	ARH 5	31.4
Childers <i>et al.</i> ⁷	29	Endometrium	LAVRH 29	?
Fowler <i>et al.</i> ⁹	12	Cervix Ib	ARH 12	23.5 + 6.5
Nezhat <i>et al.</i> ¹⁰	19	Cervix Ia IIa	LAVRH 11 LRH 7	21.5 + 5.5
Spirtos <i>et al.</i> ¹¹	40	Endometrium	LAVH 38	20.8 + 7.9
Hatch <i>et al.</i> ¹²	37	Cervix	LAVRH 37	35.5 + 11.3
Spirtos <i>et al.</i> ¹³	10	Cervix Ia2 Ib	LAVRH 10	18.3 + 6.5
Roy <i>et al.</i> ¹⁴	25	Cervix Ia2 IIa	LAVRH 27	27
Chu <i>et al.</i> ¹⁵	34	Cervix Ia2 Ib	LAVRH 6	26.7
Possover <i>et al.</i> ¹⁶	150	Cervix 96 Endometrium 41 Ovary 13	LAVRH 70 LAVH 24 LARH 2	26.8 ± 7.3
Yoon Soon Lee ¹⁷	19	Cervix 17 Vagina I Endometrium I	ARH 9 LAVRH 10	AR 23.9 LAVRH 23.2
Lee <i>et al.</i> ¹⁸	24	Cervix Ia IIa	LAVRH 24	13.2 (macroscopic)

ARH, abdominal radical hysterectomy; LAVRH, laparoscopically assisted vaginal radical hysterectomy; LRH, laparoscopic radical hysterectomy; LAVH, laparoscopically assisted vaginal hysterectomy; LARH, laparoscopically assisted radical hysterectomy

were reviewed by two independent observers. If the requirement of identifying clearly the dorsal part of the obturator nerve and lumbosacral nerve is fulfilled, the risk of missing a positive pelvic node is nil, at least in cervical cancer and endometrial cancer.

Besides the transumbilical transperitoneal technique, an extraperitoneal approach can be used for performing pelvic lymphadenectomy. New trocars, designed for entering the successive layers of the abdominal wall, and the visual control (Visiport®, Tyco; Optiview®, Ethicon) enable penetration of the extraperitoneal space, starting with a curved low umbilical incision. Once entered, the space is insufflated with CO₂. An ancillary port is opened on the midline in the suprapubic area. The peritoneum is separated from the abdominal wall using a forceps introduced through this trocar and two more ancillary ports are opened. Then the pelvic dissection can be performed, following a technique similar to the standard one. The extraperitoneal approach has the advantage of respecting the peritoneal serosa and lessening the chances for postop-

erative adhesions. However, the risk of postoperative collections (hematoma, seroma, lymphocyst) is increased. On the other hand, the operating room time is more because of the 15–20 min one needs for development of the extraperitoneal space.

Laparoscopic aortic lymphadenectomy

Laparoscopic aortic dissection is, from the technical viewpoint, just the opposite of pelvic dissection. Transumbilical transperitoneal techniques can be used, but the extraperitoneal route is surely the better one.

The transumbilical technique uses the same set-up as used for pelvic lymphadenectomy. As far as aortic lymphadenectomy is concerned, two techniques are available. In the first⁶, the set-up is the same as that used for pelvic dissection. Two details, only, differ: the video monitor is put on the side of the patient opposite the side where the surgeon stays and the video camera is turned clockwise through 90° so that the axis of the aorta appears

horizontal. The intestinal loops are pushed into the diaphragmatic domes. The dorsal peritoneum is opened longitudinally beside this axis. The upper peritoneal flap is developed upwards. The right ovarian vessels and the right ureter are identified and pushed upwards. The ventral aspect of the vena cava is cleared out, then the inter-aorticocaval space. Finally, the anterior aspect of the aorta is cleared out. The origin of the inferior mesenteric artery is identified, then the nodes lying on the left side of the aorta are mobilized and delivered.

In the second technique²⁰, the surgeon stands in between the patient's legs with the monitor at the head of the bed. The dorsal peritoneum is opened transversally alongside the axis of the right common iliac vessels. The upper peritoneal flap is pushed cranially at the same time as the last ileal loop. The right gonadal vessels are identified at the same time as the third part of the duodenum. After having mobilized it (and eventually divided the ovarian vessels), one finds the left renal vein and can start the dissection, which is performed alongside the anterior aspect of the vena cava, then continued in the inter-aorticocaval space, alongside the ventral aspect of the aorta and, finally, alongside the left aspect of the aorta. Obtaining access to the retroaortic and retrocaval spaces necessitates mobilizing the vessels laterally and medially in order to clear out each of the spaces in two steps. The lumbar arteries and veins represent a great danger during this final part of the job.

The extraperitoneal approach to aortic dissection²¹ is performed with the patient in the dorsal decubitus position, the surgeon standing to the left of the patient and the assistant to the left of the surgeon. The surgeon and assistant watch the monitor placed to the right of the patient. A 15-mm incision is performed at the left MacBurney point, i.e. 3 cm medial to the left anterior superior iliac spine. Skin, subcutaneous fat and fascia are opened sharply along the same oblique axis. Large muscles are opened bluntly while separating their horizontally orientated bundles lateral to their fascial insertion. The fascia parietalis must be opened, but the fascia peritonealis is preserved, as far as possible, to protect the peritoneum. The surgeon introduces his right forefinger into the incision to develop the extraperitoneal space under the control of transperitoneal laparoscopy. Digital dissection is performed caudally until the anterior surface of the psoas muscle is identified. Dissection is then continued cranially along the psoas muscle to the level of the iliac crest and then laterally. Once the preperitoneal space has been prepared, a 10-mm Blunt Tip trocar (Origin) is introduced and the laparoscope is transferred to this point. The preperitoneal space is insufflated through the trocar sheath and the peritoneal cavity is simultaneously exsufflated. The extraperitoneal insufflation pressure is identical to that used for transperitoneal laparoscopy (12 mmHg). Two additional trocars are then introduced in the mid-axillary line, in the preperitoneal space, under laparoscopic guid-

ance. A 5-mm trocar is placed immediately above the iliac crest for introduction of a cannula, to which the insufflation tube is connected. This cannula is used to extend the preperitoneal cavity cranially and a 10-mm trocar is then introduced just below the ribs. The left psoas muscle is released from the peritoneum by using these two ancillary trocars and by extending the peritoneum medially. The left ureter, identified on the anterior surface of the psoas muscle, is retracted with the peritoneum. Extending more medially, the left common iliac artery and aorta are identified and dissection is continued cranially as far as the inferior mesenteric artery and left renal vein. Lymph node dissection is commenced below the left renal vein. This dissection is performed bluntly using two forceps, one grasping forceps (Manhes 'Crocodile' forceps) and one dissection forceps (Manhes 'Cobra' forceps). Scissors and monopolar and bipolar diathermy are rarely used. A Coelio-extractor (Lépine) enables retrieval of the dissected nodes. All nodes between the aorta and psoas muscle are removed. The left and ventral surfaces of the aorta and left common iliac artery are then dissected, while preserving collateral vessels (ovarian, inferior mesenteric and lumbar arteries). The next step of dissection involves the dorsal aspect of the aorta. The fourth and/or fifth lumbar arteries are clipped and cut to open the retrovascular space. As soon as the lumbar vessels are divided, the space between the aorta and the common vertebral ligament opens, and it is often possible to go on and join the interaorticocaval space and, further, the dorsal and ventral aspects of the vena cava. If not, a third ancillary port must be opened as medially as possible, in order to introduce a third instrument to elevate the aorta.

Our 1992–1998 experience²² enables the feasibility and safety of the elected technique to be assessed. During this period, we attempted to achieve access to the aortic nodes in 44 patients affected by advanced or recurrent cervical cancer. In the first part of the study, the transumbilical access was the favorite access; we met with two failures (conversion to laparotomy) in nine attempts. Then we moved to the extraperitoneal approach, which led, in a population of 35 patients, to a failure in two additional cases. Among the 35 operations performed using the extraperitoneal approach, the first 14 were carried out using two successive incisions and the 21 successive operations used only the left-side incision. In the cases where a systematic dissection was accomplished, the operating room time was less in the unilateral approach (12 cases) than in the bilateral approach (six cases; 119 ± 14 min vs. 153 ± 22 min) while the number of retrieved nodes was about the same (15 ± 3 vs. 16 ± 2). However, one has to mention that the right-side aortic nodes were fewer in number (2.4 ± 2 vs. 7.7 ± 1.7). When assessing patients affected by cervical cancer, this under-representation of the right-side aortic nodes (and the subsequent 'over'-representation of the left-side aortic nodes) is not crucially

important, because the aortic metastases of cervical cancer in three out of four cases are located on the left side.

LAPAROSCOPICALLY ASSISTED HYSTERECTOMIES

The aim of laparoscopic assistance in the frame of cancer hysterectomy is to lessen the aggression of the procedure, whilst not violating the rules of radical surgery. Laparoscopically assisted simple hysterectomy is not described here because the indications for simple hysterectomy are few in cervical cancer (stage Ia1 only) and the technique is not different from the routine technique. As far as laparoscopically assisted radical hysterectomy is concerned, we do not describe the purely laparoscopic radical hysterectomy because we disagree with the use of a uterine manipulator, which cannot be avoided when carrying out this operation. We describe here only the different techniques of laparoscopically assisted vaginal radical hysterectomy.

Schauta operation after laparoscopic lymphadenectomy

In the combination 'laparoscopic pelvic lymphadenectomy–Schauta operation', the laparoscope is used in the same way as it is used in those patients one intends to submit to vaginal hysterectomy for benign disease, since they are in a situation which, theoretically, prevents the use of the vaginal approach: previous laparotomic pelvic surgery, for example. In fact, most of the alleged contraindications to the vaginal approach do not actually prevent its use, and laparoscopy provides evidence of that. It is the same for early-stage cervical cancer, where the vast majority of the patients can be submitted to vaginal radical hysterectomy since the cancer does not spread outside the uterus. That was the rationale we followed at the time we started using the laparoscope: performing, at first, laparoscopy to be sure the regional lymph nodes were not involved and, if positive (85% of cases), performing vaginal radical hysterectomy.

During the years 1986–1992, we operated on 146 patients affected by primary infiltrative cancer using the combination 'laparoscopic pelvic lymphadenectomy–vaginal radical hysterectomy'. In 98 cases, the hysterectomy was carried out as usual. In the remaining 48 cases, it was done while leaving in place the uterine body, the tubes and the ovaries (radical trachelectomy, see later). In 68 patients, radical hysterectomy was carried out following the Amreich technique, which includes a paravaginal incision and is similar in radicality to the Piver 3 abdominal operation. In the 78 other patients, a modified radical hysterectomy was performed following the Stoeckel technique, carried out without a paravaginal incision and removing a specimen like the one retrieved after a Piver 2 abdominal operation. For patients operated on after the

Amreich operation, the mean operating room time was 139 min and the rates of blood transfusion, visceral injuries (one cystotomy, four ureterotomies and one rectotomy), reoperation and bladder dysfunction (retention and/or incontinence) persisting more than 6 months after surgery were 8.8%, 14.7%, 8.8% and 59%, respectively. For patients operated on after a Stoeckel operation, the mean operating room time was 132 min and the rates of blood transfusion, visceral injuries, reoperation and persisting bladder dysfunction were 13.3%, 0%, 7% and 26.7%, respectively. No fistula occurred in either population.

Schauta–Amreich operation assisted by laparoscopy

Rather than being used only as a tool enabling us to select the indications to vaginal radical surgery, the laparoscope can also be used for preparing for radical surgery. This has been proposed by both us²³ and Kadar and Reich²⁴. The new operation is nothing but a Schauta–Amreich operation prepared laparoscopically.

In the Schauta–Amreich operation assisted by laparoscopy, the paracervical ligaments are divided. In this technique, the paracervical ligament is divided during the laparoscopic step of the combined operation. After the lymphadenectomy has been achieved, the paravesical and pararectal spaces are opened and the ligament located in between is divided. As for performing the division, the Endo GIA™ stapler (USSC) is used. If the instrument is introduced through the ipsilateral ancillary door, i.e. following the adequate axis, the division is made very close to the pelvic insertion of the ligament; the amount of removed parauterine tissue is very large. Two cartridges are usually enough; Schneider *et al.*²⁵ make the same very lateral division, while controlling (bipolar cauterization) and dividing each of the vessels which represent the vascular skeleton of the paracervical ligament.

Performing the Schauta–Amreich operation after laparoscopic preparation enables the removal of parauterine tissues, which is more than can be obtained with the reference technique, while avoiding the paravaginal incision. However, the morbidity is not decreased. This appears in all the published series^{12,14,18,24–26}. From 1992 to 1994 we operated on 28 patients using this technique. The mean operating room time was 196 min. The rates of blood transfusion, visceral injuries, reoperation and persisting bladder dysfunction were 28.6%, 14.3%, 14.3% and 50%, respectively.

Schauta–Stoeckel operation assisted by laparoscopy

Another way to prepare the Schauta operation by laparoscopy is by making a 'lateral parametrial lymphadenectomy' with the laparoscope. After laparoscopic cleaning out of the lateral route of the parametrium, one can perform, through the vaginal route, a modified

radical hysterectomy. This Schauta–Stoeckel operation assisted by laparoscopy has the same radicality as the Schauta–Amreich operation while keeping the advantage of the less aggressive procedure. It involves two steps.

Laparoscopic step

The modified laparoscopy-assisted vaginal radical hysterectomy starts with a laparoscopic pelvic dissection, to which a so-called parametrial or, better, paracervical dissection is added, to ensure that less radical parauterine tissue removal, achieved at the time of the forthcoming modified vaginal radical hysterectomy, does not lead to an increased risk of pelvic side-wall recurrence. This lymphadenectomy is carried out while removing all the lymph node-bearing tissues located in the vasculonervous web making up the parauterine ligaments. One starts with the so-called deep obturator nodes, which are removed from front to back, until arriving at the origin of the obturator artery, i.e. at the level where the internal iliac vessels give rise to their ventral collaterals. Thus, the ventral aspect of the paracervical ligament is made free. In a second step, the pararectal space is opened while pushing, medially, the dorsal sheet of the broad ligament, to which the ureter is attached. It is just lateral and dorsal to the point where the ureter crosses the uterine artery that one has to enter the dry space, which is made free up to the level of the pelvic floor, as was the paravesical space during the prior step. The lymph node-bearing tissues located at the contact of the posterior aspect of the internal iliac vessels are removed. The paracervical lymphadenectomy (Figure 34.6) finishes with the cleaning out of the space located between the iliac vessels and the pelvic wall. The vessels are pushed medially. The celluloadipose tissues, lying between the external iliac vessels, and the psoas muscle are retrieved. The obturator nerve is exposed and, then, followed from front to back. The space located cranial to the sacroiliac joint is opened

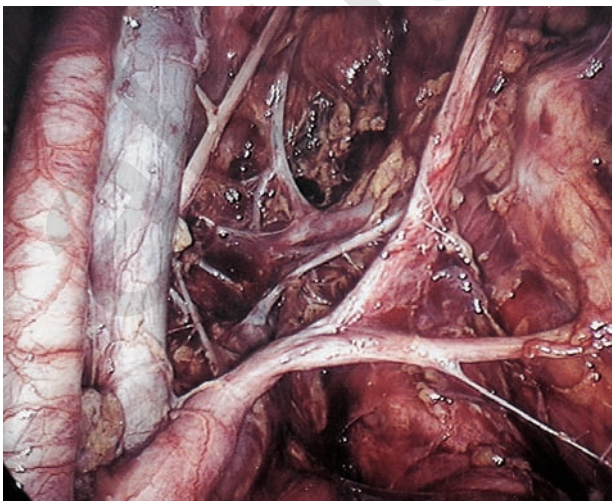


Figure 34.6 The pelvic side wall after parametrial dissection

and emptied. At the end of the procedure, the obturator nerve is visible along its entire length at the same time as the sacrolumbar nerve, which runs parallel and caudal to the former, crosses the superior gluteal vessels, then disappears in the upper sciatic channel. Identification of this anatomic structure witnesses the radicality of the cellulotomy better than any lymph node count (Figure 34.7).

Transvaginal step (Figures 34.8–34.18)

In contrast to the classic Stoeckel operation, the modified laparoscopy-assisted vaginal radical hysterectomy does not require performance of the paravaginal incision (Stoeckel himself did not perform one but two, one on each side). The prior laparoscopic dissection relaxes the natural supports of the uterus and vagina and makes it easier to accomplish, even in nulliparous women, the successive (and rather complex) moves involved in the extended operations. A median episiotomy can be helpful for certain patients but the true paravaginal incision is not necessary.

Making the vaginal cuff is the first part of the operation. The separation of the upper third of the vagina is carried out while first creating a sort of internal prolapse of the vagina, which is obtained while putting on a circular line of a series of Kocher forceps and exerting on them a downwards traction (Figure 34.8). The incision is made on the external surface of the prolapsed cylinder (Figure 34.9). In order not to enter the deep sheet of the fold after having divided the superficial one, it is recommended that first an infiltration of saline (\pm vasopressin) is made. The incision is made with a cold knife. As soon as the saline drop becomes apparent, the pressure on the blade is released. In fact it is only on the anterior and posterior vaginal walls that the incision has to be a full-thickness incision. In the posterolateral parts (between the forceps put at 3 o'clock and 4 o'clock), the incision has to be limited to the vaginal skin. This detail is highly important.

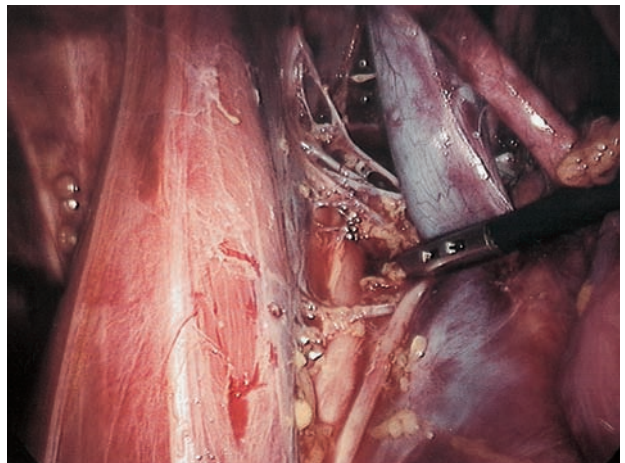


Figure 34.7 The space between the psoas muscle and the iliac vessels after parametrial dissection: the dorsal part of the obturator nerve and the lumbosacral trunk are visible

Making a deep incision on the parts where the parauterine tissues are inserted on the vaginal fornices leads to an incomplete removal and increases the risk of local recurrence. Furthermore, maintaining the relationship between the vaginal cuff and its lateral supports makes the next steps easier (Figure 34.10).

Freeing the ventral aspect of the specimen to come is the second procedure of the operation. The dorsal aspect of the bladder floor and the ventral aspect of the specimen to come are separated by cellular tissue which is crossed by the ureters lateral to the cervix and cranial to the vaginal fornices. This tissue is denser at the level of the ureteral orifices and the bladder neck. Traction exerted on the vaginal cuff make this dense part appear as pseudoaponeurosis and pseudoligaments, whose division is the key for making free the ventral aspect of the specimen to come. The first step is the opening of the 'supravaginal septum' (Figure 34.11) which joins the bladder neck to the vagina on the midline. The pseudoaponeurotic curtain is opened with the scissors handled perpendicular to the vagina until the moment when the smooth cellular tissue of the vesicovaginal space appears (Figure 34.12). At this moment, the development of the space is achieved with the forefinger.

The management of the bladder pillars follows the aperture of the vesicovaginal space. Each of these pseudoligaments is made by a condensation of the pelvic cellular tissue located lateral and medial to the ureter at the point it joins the bladder floor. The tractions exerted on the vaginal cuff pull down the ureter (which takes a 'knee' shape) and makes the ligament denser at the same time. For identifying and, then, managing the bladder pillar, one

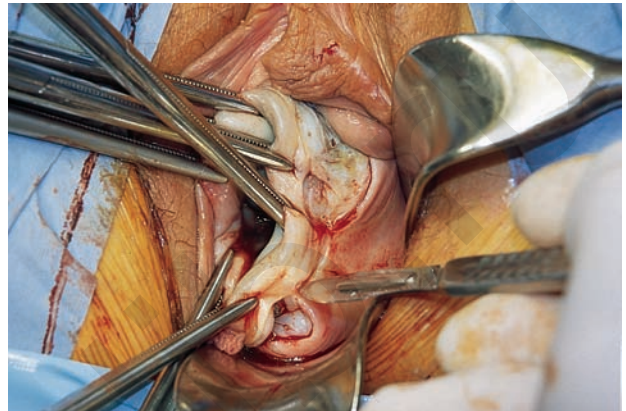


Figure 34.10 Lateral incision of the vaginal skin

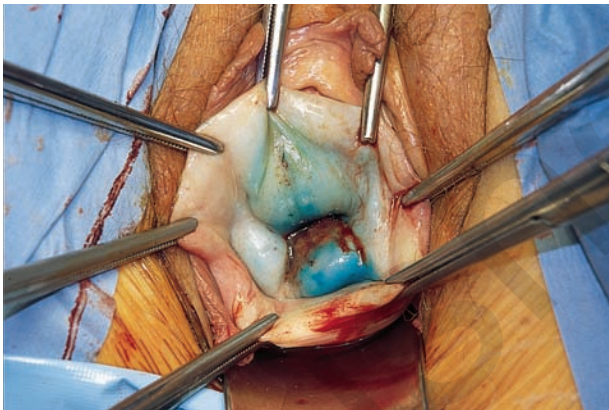


Figure 34.8 Kocher forceps making 'the vaginal prolapse'

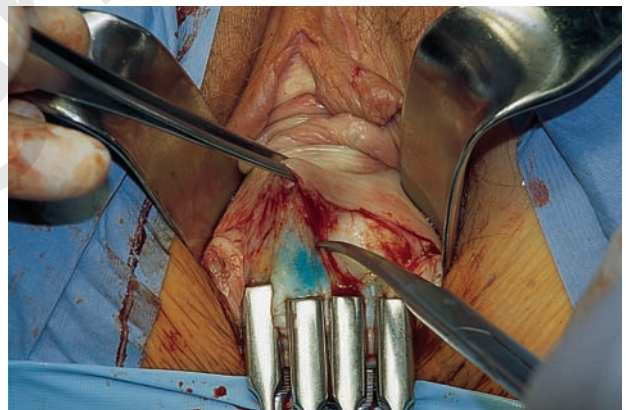


Figure 34.11 Dividing the 'supravaginal septum'

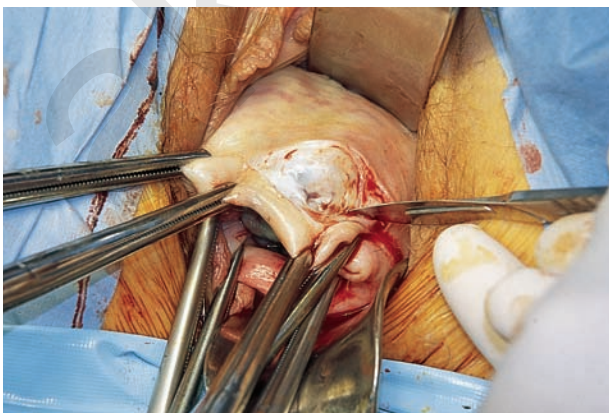


Figure 34.9 Incision of the three layers of the vagina

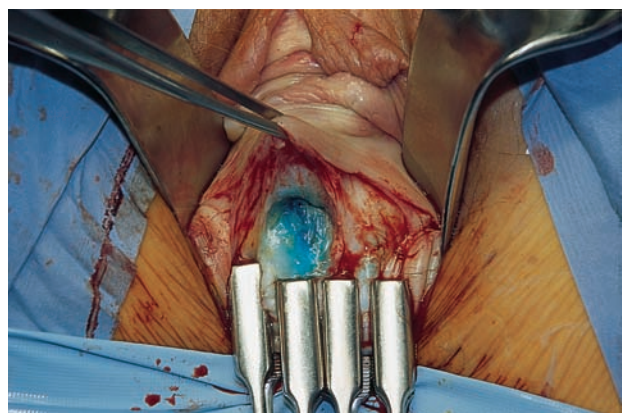


Figure 34.12 The vesicovaginal space

has, at first, to open the paravesical space, which is made by pulling on the vagina laterally, and entering the smooth space located at the contact of the deep aspect of the flap (Figure 34.13). A retractor being put in the paravesical space (Figure 34.14), the pseudoligament separating this space from the previously opened midline space is divided into two steps. The fibers located lateral to the ureter are divided first (Figure 34.15). The knee of the ureter being exposed (Figure 34.16), the medial fibers are divided, giving access to the 'paraisthmic window' where the arch of the uterine artery is lying. This window is located above the superior brim of the paracervical ligament, which is made sharp by traction exerted downwards and contralaterally. This situation makes it easy, in cases where the visual assessment is not informative, to find, by pressure of the forefinger, the place where the window is, i.e. the place where the uterine artery arrives in the operative field (Figure 34.17). The afferent branch of the arch is dissected laterally and the uterine artery is divided close to its origin. The two bladder pillars being divided successively, one moves to the next step of the operation.

Freeing the dorsal aspect of the specimen to come and the inferior rim of the paracervical ligament is much easier than managing the ventral aspect. The traction exerted by

the vaginal cuff being inverted, the pouch of Douglas is opened. Then, each of the rectouterine peritoneal folds is divided, after having been separated from the dorsal surface of the paracervical ligament, i.e. after the pararectal space has been opened. This division gives access to the dorsal aspect of the paraisthmic window, which is identified by palpation. The forefinger which identifies the anatomic defect provides guidance for introducing the tip

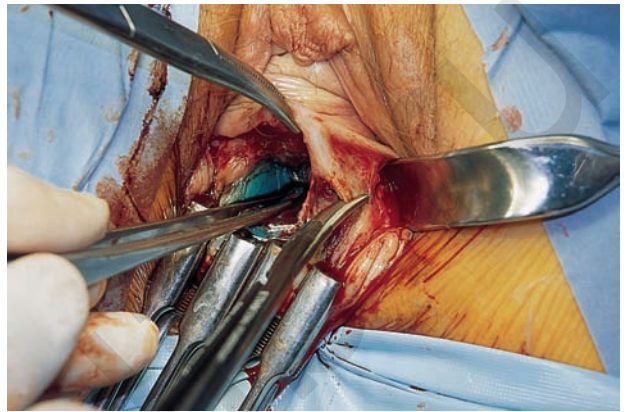


Figure 34.15 The lateral part of the pseudoligament is divided

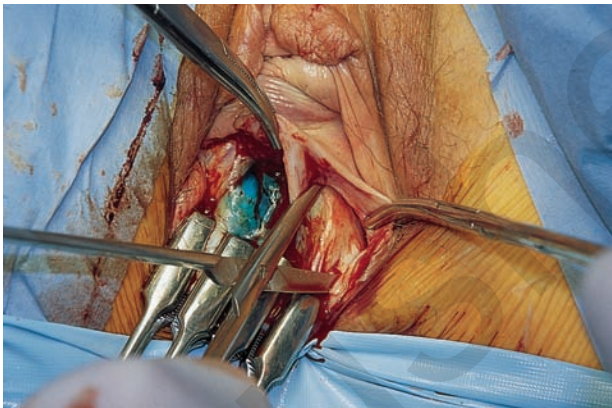


Figure 34.13 Opening the paravaginal space

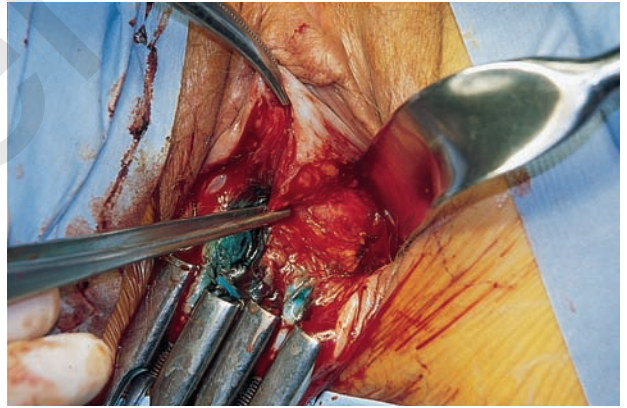


Figure 34.16 The knee of the ureter

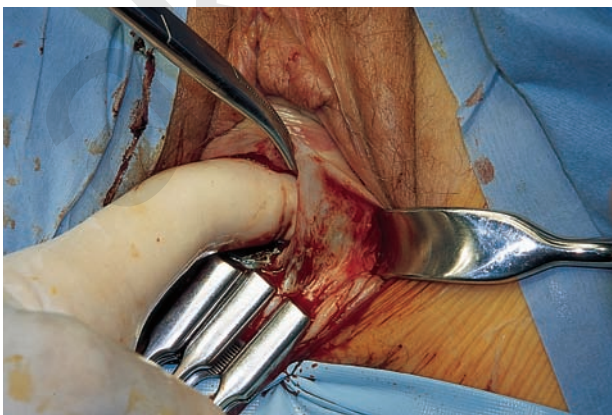


Figure 34.14 The 'click' maneuver to localize the ureter

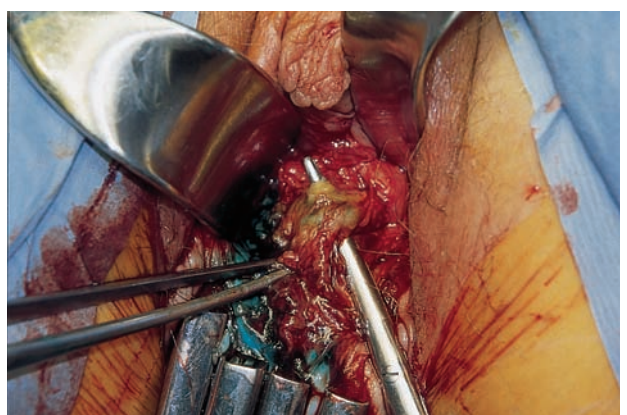


Figure 34.17 The afferent branch of the uterine artery

of a right-angle forceps, which is pushed ventrally at the same time as the traction exerted on the vaginal cuff is inverted. The tip of the instrument appears on the ventral aspect. The instrument is opened, which frees the superior brim of the paracervical ligament. Then, it is used as a means to push the specimen to come medially, in order to make freeing the inferior brim of the paracervical ligament, and dividing it, easier. A contralateral traction being exerted on the vaginal cuff, the superficial incision performed at the very beginning in the posterolateral part of the circular incision is deepened and the vagina is pushed into the incision, leaving a 1.5–2.0-cm space. A first clamp is put on the paracervical ligament. A second clamp is placed, lateral to the first one, on which a centripetal attraction is exerted before the second clamp is closed, in order to take the maximal amount of parauterine tissue. The second instrument is just at the contact of the knee of the ureter (Figure 34.18). If the length of the tissues taken between the two clamps appears too small, the ureter can be pushed more dorsally while cutting some more lateral fibers of the bladder pillar. Both cervical ligaments being divided, retrieval of the specimen is done in the same way as in simple vaginal hysterectomy. The successive steps of this retrieval are not described, nor the different steps of the reconstruction.

During the years 1994–1999, we operated on 67 patients using the laparoscopically assisted Schauta–Stoeckel operation. The mean operating room time was 177 min. The rates of blood transfusion, visceral injuries, reoperation and persisting bladder dissection were 8.2%, 0%, 2.0% and 6.9%, respectively. From the surgical viewpoint, the laparoscopically assisted Schauta–Stoeckel operation appears equivalent to the reference technique (if not better, but the differences are not statistically significant) and significantly better than the Schauta–Amreich operation, either performed with the paravaginal incision or without. On the other hand, while being less traumatic, the operation has the same curative value, as is demonstrated in the following section.

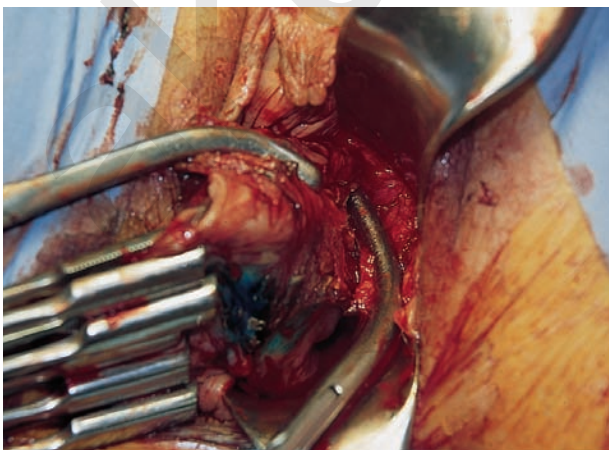


Figure 34.18 The clamps on the parauterine tissue

PLACE OF LAPAROSCOPIC SURGERY IN THE DIFFERENT PRESENTATIONS OF CERVICAL CANCER

As far as the place of laparoscopic surgery in the management of cervical cancer is concerned, two situations have to be distinguished. In early-stage cases (stage Ia2 and Ib1), laparoscopic surgery allows confirmation of the staging, at the same time as assisting radical surgery, in those cases where the staging procedure makes this surgery necessary. In advanced cases, the role of laparoscopic surgery is only carrying out the staging before choosing the therapy, in which laparoscopic surgery cannot play a direct role.

Early-stage cases

The first role of laparoscopic surgery in early-stage cervical cancer is dismissing those patients who are not suitable for radical surgery. Before undertaking the laparoscopic staging, one has to request imaging (MRI and CT scan) in order to identify those patients with obvious metastatic involvement. For these patients, laparoscopy is useless. As far as the other patients are concerned, laparoscopy can, from the very beginning, illustrate an unexpected bulky lymph node metastatic involvement. If debulking is likely to be feasible, it must be carried out. However, this debulking must be carried out with an open abdomen, even in those cases where it looks possible to perform it laparoscopically. For the other cases, a systematic dissection has to be undertaken and the nodes have to be sent to the laboratory, where they will be either assessed after frozen sections or fixed, then embedded in paraffin before being assessed microscopically. The first option carries the advantage of greater ease. The second includes higher safety while erasing the chances for false negatives. Whatever the elected solution, only the node-negative patients need to be kept for radical hysterectomy, which will be carried out either in the same session or in a second session scheduled in the following 10 days (a longer delay makes the surgery harder).

As far as radical surgery is concerned, two solutions can be offered: the purely laparoscopic radical hysterectomy and the laparoscopically assisted vaginal radical hysterectomy. The laparoscopic radical hysterectomy is potentially dangerous. On the other hand, the few data available are not convincing. As a matter of fact, in the only series²⁷ (including a rather long follow-up (8–80 months)), no recurrence was observed in 41 patients (12 stage Ia, 24 stage Ib and five stage II), which means that a bias of selection makes the data unacceptable. The laparoscopically assisted vaginal radical hysterectomy (VRH) has more convincing data. In our series of 241 cases submitted to laparoscopically assisted VRH between December 1986 and December 1999 (47 stage Ia, 160 stage Ib1, 34 stage Ib2), the number of failures was, at the end-point (December 2000) 38 (16%), including 22 pelvic failures (9%) and 11 pelvic side-wall recurrences (5%). As far as

the technique itself is concerned, the laparoscopically assisted Schauta–Stoeckel operation, whose surgical advantages are pointed out in the preceding section, is also likely to offer the lowest risk of failures: no recurrence for the 32 patients stage Ia and Ib less than 2 cm in size, three failures for the 27 patients stage Ib 2 cm or more but less than 4 cm in size (11%), one failure for the eight patients stage Ib2 (12.5%). Interestingly, no pelvic side-wall recurrences were observed in the patients submitted to the laparoscopically assisted Schauta–Stoeckel operation.

Globally, the chances of cure appear, after laparoscopic management, to be equivalent to those offered by abdominal radical hysterectomy. However, they are not better. On the other hand, the quality-of-life issue and the cost-effectiveness, at the moment, have not been clearly assessed. The advantages of laparoscopic surgery remain questionable. The only certainty concerns the conservative variant of laparoscopically assisted radical hysterectomy, i.e. radical trachelectomy²⁸ (Figure 34.19). In this operation, which is performed following the same technique, the uterine body, the tubes and the ovaries are left in place. As far as the risk of failure is concerned, no difference has been observed among the subpopulation of 71 patients submitted to radical trachelectomy and the subpopulation of 170 patients submitted to radical hysterectomy. The 29

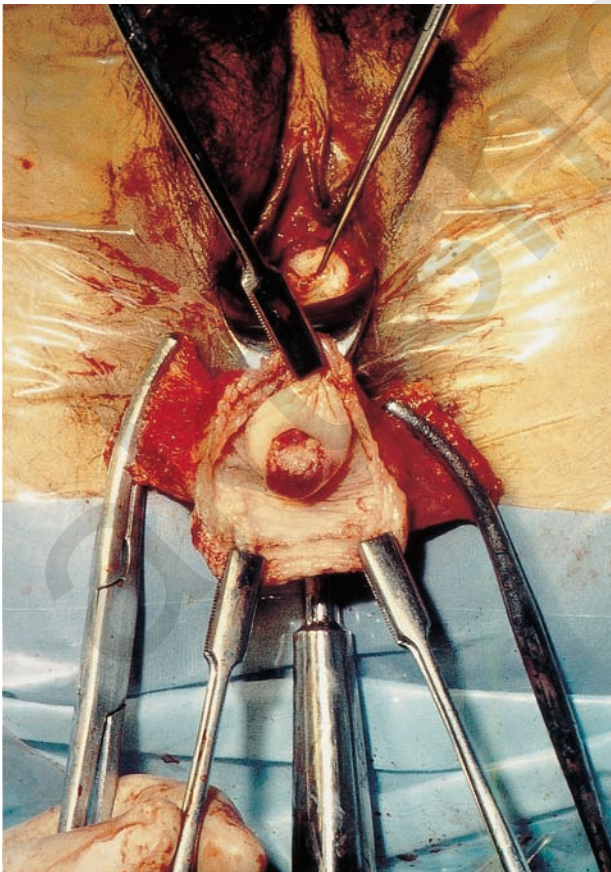


Figure 34.19 Specimen of radical trachelectomy

of the 38 patients who wanted to be, and were able to, become pregnant succeeded. Among the 47 pregnancies they obtained, 27 finished with the birth of a normal living baby. Such a result cannot be obtained if the same operation is performed using laparotomy²⁹.

Advanced-stage cases

Advanced-stage cervical cancer includes bulky stage Ib (stage Ib2: more than 4 cm in size) and stage II. These cancers could be managed using primary radical surgery, but most gynecologists/oncologists prefer to use radiotherapy (and concomitant chemotherapy). Stage III and IV cancers, with some exceptions, cannot be managed any other way. Surgery, in these presentations, has only an adjuvant role. It can be used systematically as ‘intervention surgery’ once the radiotherapy is completed and whatever the response to it. It can be reserved for poor responders and carried out either after an intermediate assessment or after completion of the primary treatment; in cases where pelvic examination, imaging and/or biopsies show that the response is not complete, intervention surgery is scheduled. A third option is waiting until the next check-up illustrates a recurrence. Laparoscopic surgery cannot be used for either performing this intervention surgery or assisting it, since the actinic alteration of the pelvic cellular tissue makes the laparoscopic dissection hazardous. In contrast, laparoscopic staging surgery is of definite interest for the different steps of management.

Laparoscopic lymphadenectomy is helpful at the very beginning of the management of advanced-stage cases in order to assess the spread of the disease before undertaking radiotherapy. Pelvic lymphadenectomy is of low interest because the pelvic side walls (and the pelvic lymph nodes) are inside the irradiated fields. Knowing the status of these nodes does not influence the management. On the other hand, if intervention surgery has to be performed, the alterations of the pelvic cellular tissues linked with the prior laparoscopic dissection (and successive radiotherapy) make this surgery much more difficult. Aortic lymphadenectomy does not encompass this drawback and is more helpful. As a matter of fact, if the aortic nodes are involved, the management has to be changed and extended-field radiotherapy has to be administered. It is not certain that such a modification to the therapeutic tool actually saves many patients, especially in those cases where bulky metastases are present. However, it is certain that managing these patients without appealing to extended-field radiotherapy cannot cure them.

Laparoscopic aortic lymphadenectomy in advanced cases is nothing but a revival of staging laparotomy. This staging laparotomy encompasses a lot of inconvenient per- and postoperative complications, plus enhancement of the actinic complications because of postoperative adhesions limiting the mobility of the intestine and increasing the chances for actinic enteritis. In the GOG study published in 1999³⁰, the rates of grade 3 actinic complications were

21% in the patients assigned to the intraperitoneal approach and 15.3% in the patients assigned to the extraperitoneal approach. Using the extraperitoneal left-side laparoscopic approach, the rate of intra- and perioperative complications was low (see preceding section). As far as the actinic complications are concerned, their rate was also very low: two cases of radiation enteritis only (2.7%) in the 48 patients that we gathered with Denis Querleu²¹. So far, the extraperitoneal left-side laparoscopic aortic lymphadenectomy, which has the same informative value as the staging laparotomy while not carrying the same costs (hospital stay and surgical complications) or risks (actinic complications), deserves to be used widely in the pretherapeutic work-up of advanced-stage cervical cancer.

Laparoscopic aortic lymphadenectomy recognizes another helpful indication in the pre-exenteration work-up. If a recurrence occurs in a patient who has not been submitted to aortic dissection prior to the primary treatment, and if the indication is to perform a pelvic exenteration, one knows that this operation, which carries a high risk and exposes the patient to troublesome sequelae, is contraindicated in cases where the aortic nodes are involved because the chances for cure are very low. Rather than exposing this contraindication at the time the laparotomy has already been performed, one obtains a big advantage in exposing it by laparoscopic staging. In our experience³¹, patients referred between April 1994 and June 1998 for recurrent cervical cancer confined to the pelvis according to the preoperative work-up (including normal CT scan) underwent a laparoscopic para-aortic assessment. All but one of the procedures were completely performed by laparoscopy. This patient was submitted to laparotomy for controlling a bleed from the right ovarian artery. Aortic nodes were not involved, but pelvic debulking was impossible. Among the seven other patients, aortic lymph node metastases were in evidence in two patients who were not submitted to pelvic exenteration. Among the five patients with no para-aortic lymph node involvement who were submitted to the exenteration, one developed a liver metastasis 4 months after surgery, one died with pelvic recurrence 16 months after surgery and three were still alive 2, 4 and 28 months after the surgery.

THE FUTURE: LAPAROSCOPIC ASSESSMENT OF THE SENTINEL NODE?

The concept of sentinel node assessment was born in 1992 at the time that the urologist Cabanas proposed the replacement of inguinofemoral dissection by the removal of the only node that was dyed after injection of blue dye close to the penile tumor that one had to manage. Such a policy enables avoidance of the heavy consequences that inguinofemoral dissection carries, while not increasing the chance for inguinofemoral recurrence. The same argument is put forward in the management of breast cancer and vulvar cancer. The conditions for such a lightening of the

management policy are, first, that the identification of the sentinel node is easy to perform and, second, that the negative predictive value of the assessment of this node is 100% or close to 100% as far as the status of the other regional nodes is concerned. Another and very important question concerns the therapeutic value of lymphadenectomy which is dismissed on the pretext that, as the sentinel node is not involved, the other regional nodes are also not involved.

Identification of the sentinel node in cervical cancer seems, according to the literature, to be difficult. O'Boyle *et al.*³² tried to obtain it while injecting blue dye into the cervix before an abdominal radical hysterectomy was performed. Among the 40 assessed areas (20 patients), sentinel nodes were identified in 15 cases only. Verheijen *et al.*³³ injected technetium 99m colloidal albumin and blue dye around the tumor. In six out of ten eligible women who had a Wertheim–Meigs operation for cervical cancer stage Ib, one or more sentinel nodes could be detected by scintigraphy prior to the surgery. Intraoperative gamma-probe detection was successful in eight of the ten women, where visual detection found sentinel nodes in only four. Kamprath *et al.*³⁴ used colloidal technetium in 16 of 18 patients in whom sentinel nodes were detected. A median of 2.1 pelvic sentinel nodes was found in 16 patients and a median of 1.4 para-aortic sentinel nodes was found in five patients. No false negatives were registered by these authors; after systematic dissection, no metastatic nodes were found if the sentinel nodes were not involved. However, the practical interest of such a statement is low. As a matter of fact, the only drawback of systematic dissection is that it takes time; postoperative lymphedema is very rare, especially if no postoperative radiotherapy is given. Using laparotomy for identifying the sentinel node does not spare time. The same is true if laparoscopy is used, but the colloidal technetium technique leads in most cases to performance of an extended dissection.

The technique we propose differs from the others in that, first, we use the laparoscope, second, we do not use colloidal technetium but a blue dye and, third, we do not look directly for the blue-dyed nodes but for the blue-dyed lymphatic channels which are followed from inside to outside and lead to the sentinel node which, in most cases, is unique. Between October 1998 and September 2000, we operated on 52 patients using this technique. One or more lymphatic channels were identified in 87% of the cases which led to one blue-dyed node in 95% of the cases and to two separate nodes in 5% of the cases. While being more selective than the colloidal technetium technique, this technique has the same safety. Among the 95 sentinel nodes which were assessed, 13 were involved and 82 were not. Systematic dissection performed after sentinel node removal never showed in these 82 cases that other regional nodes were involved. Another advantage of the technique we propose is that it actually spares time in most cases. As a matter of fact, the sentinel node in 82 of the 95 cases (86%) was located at the contact of the external vein,

either medial to it or caudal to it (between it and the obturator nerve (Figure 34.20)) or cephalic to it (between it and the external iliac artery). In all these cases, the place where the sentinel node was lying was ventral to the origin of the uterine artery. This means that we were able to identify and remove it less than 10 min after the start of the dissection.

Following the data given here, it seems that laparoscopic dissection undertaken after the injection of a blue dye into the cervix can, in most of the cases, be very much shortened. However, it is not certain that dismissing systematic dissection does not include a risk of enhancement of the rate of pelvic recurrences and, more precisely, of pelvic side-wall recurrences. In our 1986–1999 already-quoted personal experience, laparoscopically assisted vaginal radical hysterectomy, which was reserved for patients with no pelvic node involvement, was performed without appealing to the parametrial lymphadenectomy (see section ‘Schauta–Stoekel operation assisted by laparoscopy’) in 168 cases and with parametrial lymphadenectomy in 73 cases. The rates of pelvic recurrence were 15.5% and 5.3%, respectively. No pelvic side-wall recurrences were observed in the second population. That means that, by increasing the radicality of the dissection, one lessens the chances for recurrence, even in patients apparently free of lymph node metastasis. Such a phenomenon could be explained by the data of molecular biology, which show that cancer can be present even if not morphologically evident. From the practical view, it seems not to be sensible to renounce systematic lymphadenectomy even if the sentinel node is not involved, with the exception of very early tumors (stage Ia and stage Ib less than 2 cm in size), in the management of which we have

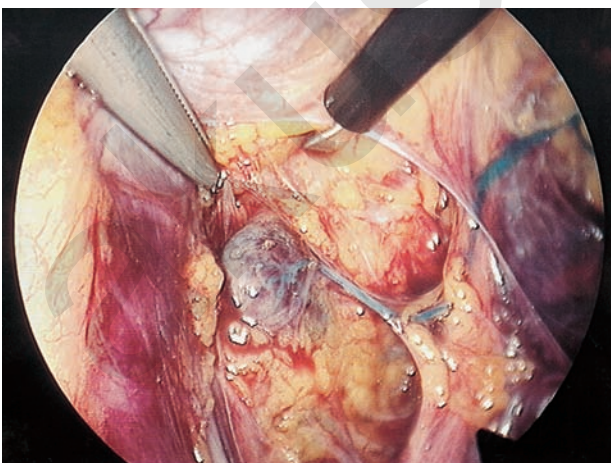


Figure 34.20 Main lymphatic channel and main lymphatic node (sentinel node) after injection of Patent Blue Violet in the cervix: the main lymphatic channel crosses the superior vesical artery and joins a node located alongside the podalic surface of the external vein

never observed recurrences whatever the technique of lymphadenectomy (176 cases).

CONCLUSION: WARNING!

Laparoscopic surgery does not improve the outcomes in the management of cancer. Worse than that, this surgery can be deleterious if the rules of safety are not respected. It is mandatory to avoid direct manipulation of the tumor. Therefore, the place of laparoscopic surgery has to be restricted to staging and to assisting radical surgery. A careful preoperative work-up is necessary to dismiss those cases at risk. On the other hand, one must not hesitate to convert to laparotomy if unexpected tumor bulk prevents the avoidance of direct manipulations. Actually, the advantage of laparoscopic surgery is only the lessening of surgical trauma while respecting better the forms and the functions. But that can lead, in the cases of early-stage cervical cancer in young patients, to surgery that makes possible the birth of normal babies. This result is worth the efforts of gynecological oncologists.

REFERENCES

1. Dargent D. A new future for Schauta's operation through pre-surgical retroperitoneal pelviscopy. *Eur J Gynecol Oncol* 1987; 8: 292–6
2. Whelan RL, Lee SW. Review of investigations regarding the etiology of port site tumor recurrence. *J Laparoendosc Adv Surg Tech A* 1999; 9: 1–16
3. Canis M, Botchorishvili R, Wattiez A, et al. Cancer and laparoscopy, experimental studies: a review. *Eur J Obstet Gynecol Reprod Biol* 2000; 91: 1–9
4. Sonoda Y, Zerbe M, Barakat RR, et al. High incidence of positive peritoneal cytology in low-risk endometrial cancer treated by laparoscopically assisted vaginal hysterectomy (LAVH). Presented at the 31st Annual Meeting of the SGO, February 2000: Abstr 21
5. Querleu D, Leblanc E, Castelain B. Laparoscopic pelvic lymphadenectomy. *Am J Obstet Gynecol* 1991; 164: 579–81
6. Childers JM, Hatch K, Surwit EA. The role of laparoscopic lymphadenectomy in the management of cervical carcinoma. *Gynecol Oncol* 1992; 47: 38–43
7. Childers JM, Brzechffa PR, Hatch KD, et al. Laparoscopically assisted surgical staging (LASS) of endometrial cancer. *Gynecol Oncol* 1993; 51: 33–8
8. Melendez TD, Childers JM, Nour M, et al. Laparoscopic staging of endometrial cancer: the learning experience. *J Soc Laparoendosc Surg* 1997; 1: 45–9
9. Fowler JM, Carter JR, Carlson JW, et al. Lymph node yield from laparoscopic lymphadenectomy in cervical cancer: a comparative study. *Gynecol Oncol* 1993; 51: 187–92
10. Nezhat CR, Nezhat FR, Vurrel MO, et al. Laparoscopic radical hysterectomy and laparoscopi-

- cally assisted vaginal radical hysterectomy with pelvic and paraaortic node dissection. *J Gynecol Surg* 1993; 9: 105–20
11. Spirtos NM, Schaert JB, Spirtos TW, et al. Laparoscopic bilateral pelvic and paraortic lymph node sampling: an evolving technique. *Am J Obstet Gynecol* 1995; 173: 105–11
 12. Hatch KD, Hallum AV, Nour M. New surgical approaches to treatment of cervical cancer. *J Natl Cancer Inst* 1996; 21: 71–5
 13. Spirtos NM, Schlaerth JB, Gros GM, et al. Cost and quality of life analyses of surgery for early endometrial cancer: laparotomy versus laparoscopy. *Am J Obstet Gynecol* 1996; 174: 1795–9
 14. Roy M, Plante M, Renaud MC, et al. Vaginal radical hysterectomy versus abdominal radical hysterectomy in the treatment of early stage cervical cancer. *Gynecol Oncol* 1996; 62: 336–9
 15. Chu KK, Chang SD, Chen FP, et al. Laparoscopic surgical staging in cervical cancer – preliminary experience among Chinese. *Gynecol Oncol* 1997; 64: 49–53
 16. Possover M, Krause N, Plaul K, et al. Laparoscopic para-aortic and pelvic lymphadenectomy: experience with 150 patients and review of the literature. *Gynecol Oncol* 1998; 71: 19–28
 17. Yoon Soon Lee. Early experience with laparoscopic pelvic lymphadenectomy in women with gynecologic malignancy. *J Am Assoc Gynecol Laparosc* 1999; 6: 59–63
 18. Lee CL, Huang KG, Wang HY, et al. New approach in laparoscopically assisted radical vaginal hysterectomy. *Int Surg* 1997; 82: 266–8
 19. Schlaerth JB, Spirtos NM, Boike GM, Fowler JM. Laparoscopic retroperitoneal lymphadenectomy followed by laparotomy in women with cervical cancer [Abstract]. *Gynecol Oncol* 1999; 72: 443
 20. Querleu D. Laparoscopic para-aortic node sampling in gynecologic oncology: a primary experience. *Gynecol Oncol* 1993; 49: 24–9
 21. Querleu D, Dargent D, Ansquer Y, et al. Extraperitoneal endosurgical aortic and common iliac dissection in the staging of bulky or advanced cervical carcinomas. *Cancer* 2000; 88: 1883–91
 22. Dargent D, Ansquer Y, Mathevet P. Technical development and results of left extraperitoneal laparoscopic para-aortic lymphadenectomy for cervical cancer. *Gynecol Oncol* 2000; 77: 87–92
 23. Dargent D, Mathevet P. Hysterectomie élargie laparoscopico-vaginale. *J Gynecol Biol Reprod* 1992; 21: 709–10
 24. Kadar N, Reich H. Laparoscopically assisted radical Schauta hysterectomy and bilateral laparoscopic pelvic lymphadenectomy for the treatment of bulky stage IB carcinoma of the cervix. *Gynecol Endosc* 1993; 2: 135–42
 25. Schneider A, Possover M, Kamprath S, et al. Laparoscopy-assisted radical vaginal hysterectomy modified according to Schauta–Stoeckel. *Obstet Gynecol* 1996; 88: 1057–60
 26. Dargent D. Radical vaginal hysterectomy in the primary management of invasive cervical cancer. In Rubin S, Hoskins W, eds. *Cervical Cancer and Preinvasive Neoplasia*. New York: Raven Press, 1996: 142–8
 27. Canis M, Dauplat J, Pomel C, et al. Laparoscopic radical hysterectomy for cervical cancer. Results about 41 cases [IGCS Abstract]. *Int J Gynecol Cancer* 1997; 7: 3
 28. Dargent D, Martin X, Sacchetoni A, et al. Laparoscopic vaginal trachelectomy: a treatment to preserve the fertility of cervical carcinoma patients. *Cancer* 2000; 88: 1877–82
 29. Novak F. Radical abdominal subcorporeal extirpation of the cervix with bilateral pelvic lymph nodes dissection in cancer in situ of the cervix uteri. *Acta Med Yugoslavica* 1952; 6: 59–71
 30. Weiser FB, Bundy BN, Hoskins WJ, et al. Extraperitoneal versus transperitoneal selective para-aortic lymphadenectomy in the treatment surgical staging of advanced cervical cancer (a GOG study). *Gynecol Oncol* 1999; 33: 283–9
 31. Dargent D, Ansquer T, Mathevet P. Can laparoscopic paraaortic lymphadenectomy help to select patients with pelvic relapse of cervical cancer eligible for pelvic exenteration? *Gynecol Oncol* 1999; 73: 172
 32. O’Boyle JD, Coleman RL, Bernstein SG, et al. Intraoperative lymphatic mapping in cervix cancer patients undergoing radical hysterectomy: a pilot study. *Gynecol Oncol* 1999; 74: 322
 33. Verheijen RH, Pijpers R, Van Diest PJ, et al. Sentinel node detection in cervical cancer. *Obstet Gynecol* 2000; 96: 135–8
 34. Kamprath S, Possover M, Schneider A. Laparoscopic sentinel node detection in patients with cervical cancer [Letter]. *Am J Obstet Gynecol* 2000; 182: 1648

Part 5
Endoscopy during pregnancy

akusherlib.ru

akusher-lib.ru

Fetal endoscopy

C Hubinont

INTRODUCTION

The first fetal endoscopic visualization was reported in 1954, using a 10-mm hysteroscope in early pregnancy¹. In the 1970s, before the development of real-time ultrasound, fetoscopy was used for prenatal diagnosis and therapy, despite a limited optical system²⁻⁵. In the 1980s, the fetoscopic approach was progressively replaced by percutaneous ultrasound-guidance techniques as the resolution of modern equipment improved. Finally, it was abandoned until the early 1990s.

Owing to technological progress in the size, field of view and image quality of fiberoptic endoscopes, Quintero *et al.*⁶ described a new approach with a 21-gauge trocar introduced transabdominally, even during the first trimester of pregnancy, for early prenatal diagnosis and for some specific therapeutic alternatives.

A review of fetal endoscopy diagnostic and surgical applications is discussed in this chapter.

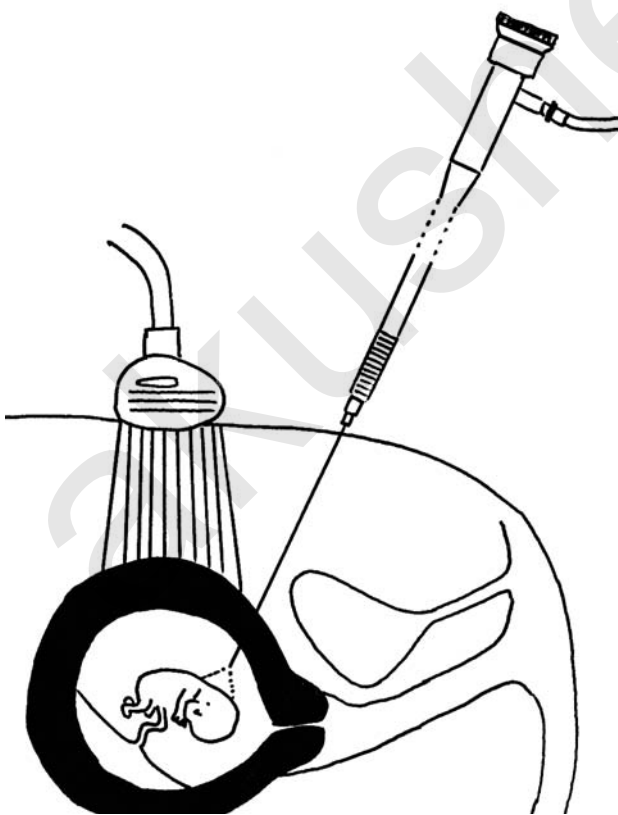

Figure 35.1 Fetoscopy technique

TECHNIQUES

The types of fetal endoscopy reported in the literature (embryoscopy and fetoscopy) relate more to the gestational age at which the procedure is performed than to the route used (either transabdominal or transcervical).

Embryoscopy

Embryoscopy (between weeks 8 and 12) was first performed using transcervical introduction of the endoscope into the extraembryonic celom^{7,8}. The material used was a rigid 1.7 fiber endoscope in a 2-mm sheath, equipped with a side-channel for saline infusion.

The technique was improved using smaller-size endoscopes (20-gauge needle and 0.7-mm endoscope) and a safer transabdominal route (Figure 35.1). It was reported in the literature under the name of transabdominal thin-gauge embryofetoscopy, or TGEF⁶. In our experience as well as that of others⁹ (Figure 35.2), a semirigid 1-mm diameter endoscope (11510 A Rigid Telescope, Storz, Tuttlingen, Germany) introduced in an 18-gauge trocar can be used transabdominally as early as at 10 weeks' gestation, and, in most cases, provides a clear view of the fetus (Figures 35.3–35.5).

Fetoscopy

Fetoscopy (from the second to the third trimester) has previously been reported¹⁻⁵. The first endoscopes used for this purpose had a large diameter of up to 6.8 mm. Their applications included both diagnostic (Figure 35.6) and therapeutic aspects.

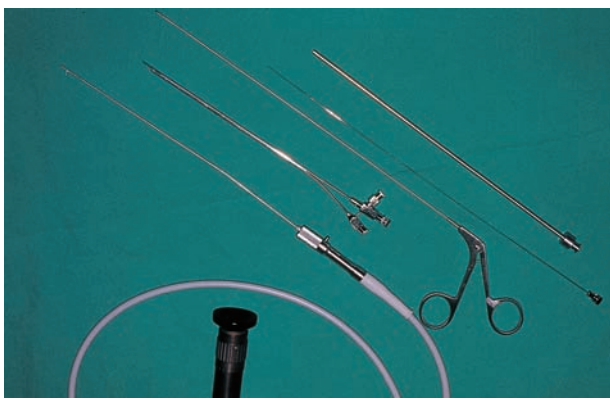


Figure 35.2 Fetoscopy equipment

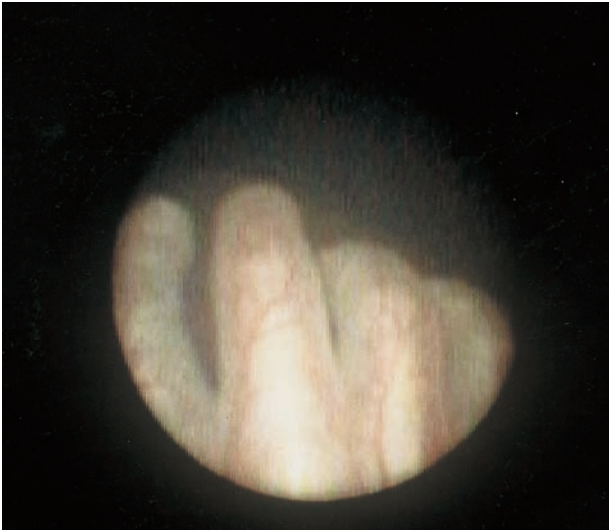


Figure 35.3 Normal fetal hand

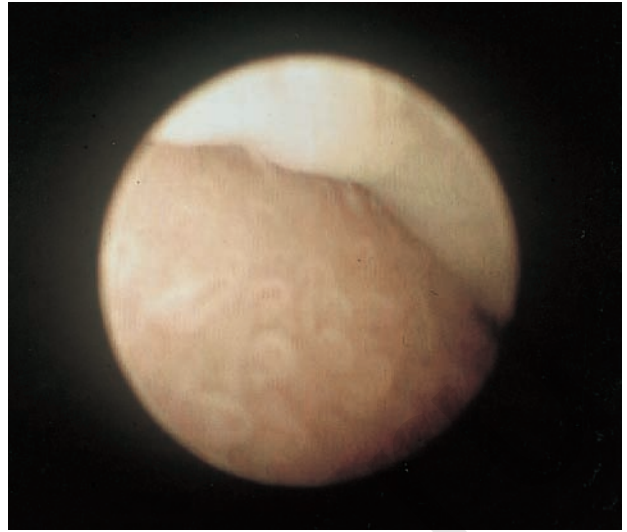


Figure 35.6 Third-trimester fetoscopy showing a normal fetal upper lip without cleft and, below, the tongue

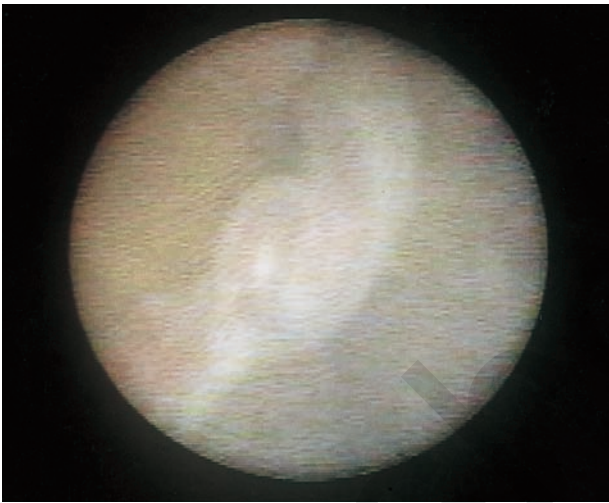


Figure 35.4 Umbilical cord and vessels

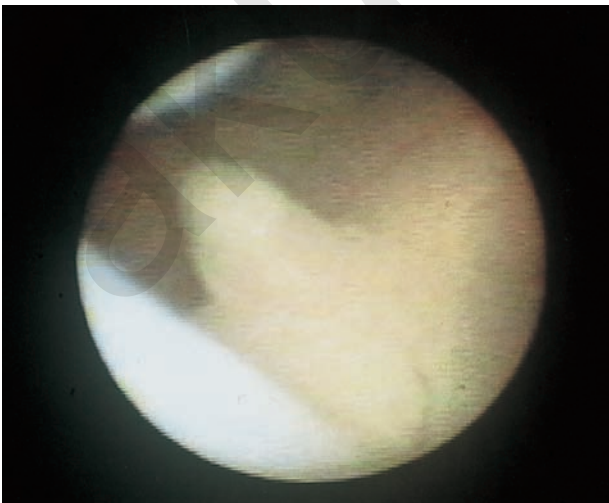


Figure 35.5 Normal female genitalia at 11th week

Ultrasound guidance is necessary for both routes in order to avoid the placenta and rule out any unknown multiple pregnancy or miscarriage. In the case of bleeding, saline or Ringer's lactate may be amnioinfused in order to improve the fetal view⁶. The use of CO₂ could induce acidosis, and should be avoided¹⁰. Glycine, used safely in animal models, may be a potential alternative¹¹. The procedure can be performed on an outpatient basis under local or locoregional anesthesia. For both fetal immobilization and maternal sedation, remifentanyl has been shown to give similar results to those with diazepam, with better control of the maternal respiratory pattern¹². Anti-D prophylaxis should be administered to rhesus-negative patients. Antibiotics should be given routinely in the case of transcervical procedures⁷.

However, with improvements in ultrasound (endovaginal first-trimester scan), diagnostic interest in embryoscopy and fetoscopy has decreased, while their role as a fetal surgery tool has emerged during the past decade.

INDICATIONS

Diagnostic endoscopy

Prenatal diagnosis by fetal endoscopy should be offered in three distinct clinical conditions.

Suspicion of a first-trimester abnormality

As early endovaginal ultrasound is now able to diagnose major congenital anomalies¹³, and as amniocentesis is indicated for aneuploidy diagnosis, fetoscopy may be done to confirm rapidly the final diagnosis. Fetoscopy may also be performed prior to dilatation and curettage for fetal

anomaly in order to exclude an unsuspected polymalformative syndrome. We previously reported two cases of conjoined twins in which combined ultrasound and endoscopy enabled us to confirm the diagnosis and allow early termination of the pregnancy¹⁴ (Figure 35.7). Several cases of first-trimester anomalies confirmed by fetoscopy have been reported, such as multiple amniotic-band syndrome¹⁵ and omphalocele¹⁶. A suspicion of neural tube defects in the presence of increased α -fetoprotein and a non-contributive ultrasound was also excluded by fetoscopy⁸.

Polymalformative syndromes

Patients at risk of polymalformative syndromes affecting at least the face and/or the limb extremities are listed in Table 35.1. In patients with genetic syndromes transmitted with either recessive or dominant inheritance, fetoscopic diagnosis of a small defect may be performed at an earlier gestational age than can ultrasound. Among hand anomalies, mono-, a-, syn-, brachy-, campo-, clino- and polydactylysm (Figure 35.8) may be diagnosed. A week-10 prenatal diagnosis of polydactylysm associated with

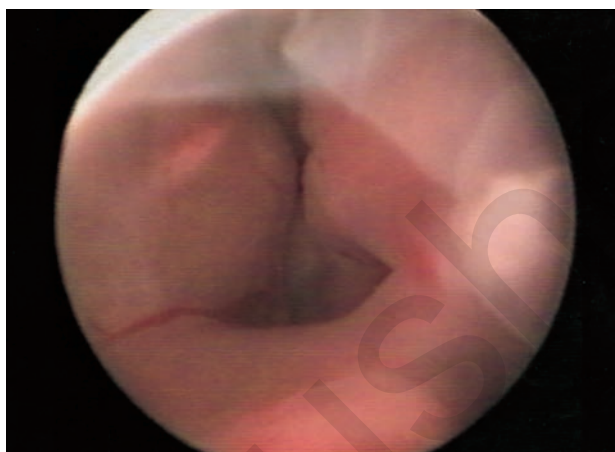


Figure 35.7 Thoraco-omphalopagus conjoined twins

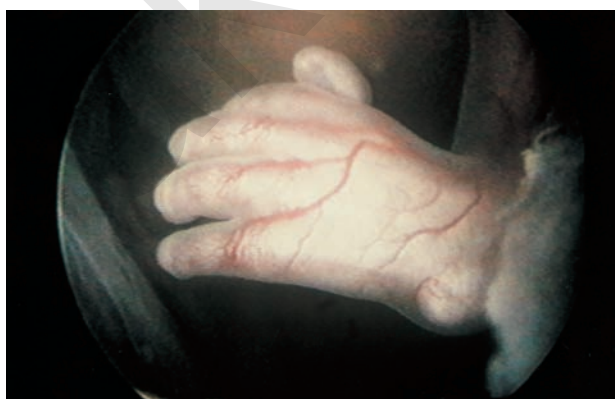

Figure 35.8 Hexadactylysm

recurrent Meckel–Gruber syndrome has been reported¹⁷. Ellis–van Creveld syndrome⁶ was diagnosed at the 11th week in the presence of polydactylysm. Gross facial anomalies such as cleft lip, anophthalmia and ear aplasia may be confirmed by fetoscopy as early as at the 10th week, as reported in the prenatal diagnosis of Smith–Lemli–Opitz and Fraser’s cryptophthalmos syndromes^{18,19}. Roberts’ syndrome was excluded at 12 weeks, as no gross facial and limb malformations were seen²⁰. Albinism was also diagnosed by fetoscopic view of the fetal hair color²¹. Club foot may also be diagnosed by fetoscopy (Figure 35.9).

Early fetal tissue sampling

Evans *et al.* reported two cases of endoscopically assisted fetal muscle biopsy performed for the prenatal diagnosis of Duchenne’s muscular dystrophy²². Endoscopic guidance allowed diagnosis at an earlier gestational age, with an accurate site of biopsy. First-trimester umbilical vessel sampling was reported using transabdominal fetoscopy at between 8 and 12 weeks²³. Directed skin biopsies in order to diagnose rare genodermatoses such as junctional epidermolysis bullosa²⁴ or trichothiodystrophy²⁵ have recently been reported.

Therapeutic endoscopy

Endoscopic fetoplacental surgery is now recognized as an effective alternative therapy in severe twin-to-twin transfusion syndrome (TTTS) and umbilical cord ligation in an abnormal twin pregnancy. Other experimental applications, such as for obstructive uropathy and congenital diaphragmatic hernia, have also been reported. For these indications, a larger-diameter sheath (>2 mm) and parallel ports should be employed in order to use graspers, scissors, knot pushers and laser fibers. Fetal

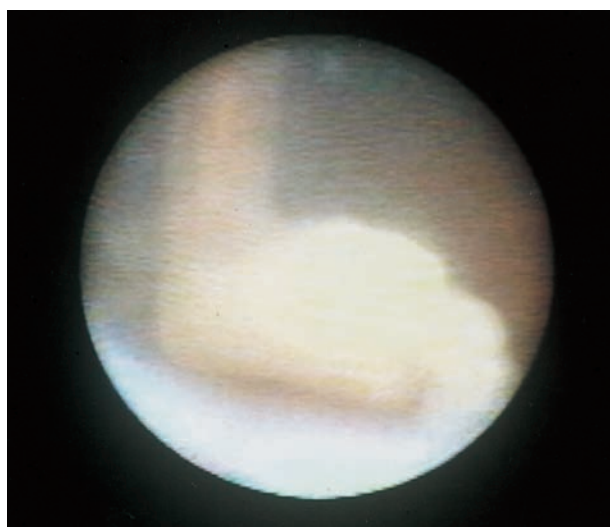


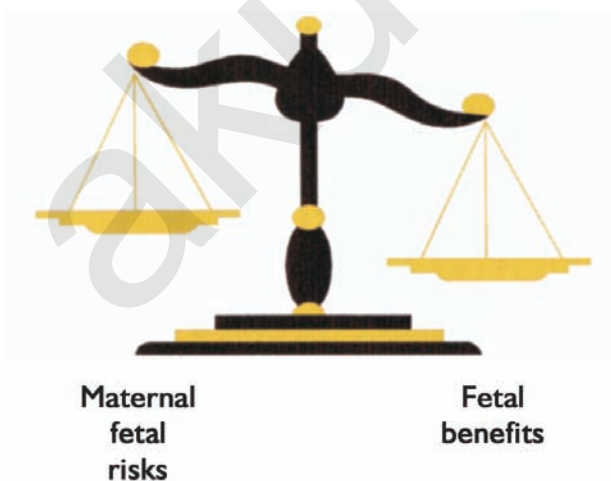
Figure 35.9 Club foot associated with neural tube defect

Table 35.1 Polymalformative syndromes and teratogenic embryopathy*Polymalformative syndromes associated with facial anomalies*

Antley–Bixler (midfacial hypoplasia, dysplastic ear, radiohumeral synostosis) (AR)
 EEC (ectodermic dysplasia, syndactyly, cleft lip) (AD)
 Fraser's cryptophthalmos (hidden eyes, syndactyly, renal, genital anomalies) (AR)
 Frontonasal dysplasia sequence (unknown)
 Hay–Wells (cleft lip, ectodermal dysplasia) (AD)
 Majewsky's short rib–polydactyly type II (cleft lip, polysyndactyly) (AR)
 Meckel–Gruber (encephalocele, polydactyly, kidney dysplasia) (AR)
 Mohr's or OFD type II (bilateral feet and hand polysyndactyly, partial cleft) (AR)
 Neu–Laxova (clino-, syndactyly, cleft lip, exophthalmos, microcephaly) (AR)
 Orofacialdigital (OFD) type I (partial cleft, clino-, syn-, polydactyly) (X-linked dominant)
 Popliteal pterygium or faciogenitopopliteal (cleft lip, genital dysplasia, popliteal web) (AD)
 Roberts–SC phocomelia (midfacial defect, pseudothalidomide hypomelia) (AR)
 Treacher–Collins (malar hypoplasia, ear dystrophy) (AD)
 Van der Woude's (lip pit, cleft lip) (AD)

Polymalformative syndromes including limb anomalies

Apert's (syndactyly, cleft palate, craniosynostosis) (AD)
 Baller–Gerold (radial and thumb aplasia or hypoplasia, craniosynostosis) (AR)
 Barbet–Biedl (clino-, syn-, polydactyly, obesity, retinal pigmentation) (AR)
 Carpenter's (syn-, brachy-, polydactyly, acrocephaly) (AR)
 Catel–Manzke (index hyperphalangy, cleft palate) (sporadic)
 Cerebrocostomandibular (clinodactyly of fifth finger, pterygium colli, micrognathia) (AR)
 CHILD (unilateral hypomelia, cardiac defect) (X-linked)
 Coffin–Siris (hypoplastic fifth finger, hypoplastic toenails, coarse facies) (AR?)
 Ellis–van Creveld chondroectodermal dysplasia (polydactyly, nail hypoplasia) (AR)
 Escobar's (multiple pterygia, cleft palate, campto-, syndactyly) (AR)

continued**Figure 35.10** Ethical dilemma of fetal endoscopy

endoscopic surgery ('Fetendo') requires ethical consideration of its related risks and potential benefits for the fetus (Figure 35.10).

Twin-to-twin transfusion syndrome

TTTS is a severe complication of monochorionic diamniotic twin pregnancy, with an incidence ranging from 2 to 35%²⁶. The pathophysiological mechanism is an unbalanced intertwin hemodynamic flow at the level of some type of placental vascular anastomosis^{26,27}. Preferential blood transfer from one twin to the other is responsible for the polyhydramnios and plethoric aspect of the recipient twin. The donor twin is generally growth-restricted, and has oligohydramnios with a typical aspect of 'stuck twin'^{28,29}. In the absence of treatment, the mortality rate of severe TTTS in the previable period reaches 100%^{30,31} due to recipient cardiac failure responsible for hydrops and

Table 35.1 Continued

FG syndrome (clino-, campto, syndactyly, face dysmorphism) (X-linked)
Golaby–Rosen (polydactyly) (X-linked)
Grebe’s (distal limb deficiency, polydactyly) (AR)
Greig’s cephalopolysyndactyly (frontal bossing, feet and hand polydactyly) (AD)
Holt–Oram (distal limb hypoplasia, syndactyly, heart defect) (AD)
Levy–Hollister (syn-, clino-, absent thumb and radius) (AD)
Miller’s (postaxial limb deficiency, syndactyly, facial dysmorphism) (AR)
Multiple synostosis (synphalangism, clino-, brachydactyly, face dysplasia) (AD)
Nager’s syndrome (radial limb hypoplasia, mandibular hypoplasia, ear defects) (?)
Oculodentodigital (microphthalmos, campto-, syndactyly, finger aplasia) (AD)
Otopalatodigital (OPD) type II (face dysmorphism, syn-, polydactyly) (X-linked)
Poland’s (hand syn-, oligodactyly, thoracic defect) (?)
Rothmund–Thomson (poikiloderma, cataract, absent thumb, syndactyly, club feet) (AR)
Saldino–Noonan or short rib–polydactyly type I (syn-, polydactyly, cardiac defect) (AR)
Smith–Lemli–Opitz (syn-, polydactyly, microcephaly, genital anomalies) (AR)
TAR or radial aplasia thrombocytopenia (bilateral radial aplasia) (AR)
Taybi’s (otopalatodigital (OPD) type I) (broad digits, short nails, cleft palate) (X-linked)
Townes–Brocks (hypoplastic fingers, clinodactyly fifth finger)
<i>Teratogenic agent embryopathy</i>
Aminopterin/methotrexate (facial hypoplasia, syndactyly, talipes)
Herpes zoster or fetal varicella (limb hypoplasia, skin scars)
Hydantoin (cleft lip, syndactyly, distal limb hypoplasia)
Retinoic acid (facial dysmorphism, cleft palate, micro- or aniotia, cardiopathy, NTD)
Trimethadione (cleft lip, cardiopathy)
Valproate (cleft lip, midface hypoplasia, neural tube defect (NTD))
Warfarin (nasal hypoplasia, limb hypoplasia)

AR, autosomal recessive; AD, autosomal dominant; ?, unknown inheritance

intrauterine fetal death (IUFD)^{32,33}. The surviving twin is also at risk of IUFD or, when surviving, may have severe sequelae. Another cause of fetal morbidity in TTTS is the high incidence of preterm labor due to polyhydramnios. It is associated with an increased risk of late miscarriage, and severe prematurity and its neonatal sequelae³⁵.

In view of this high fetal mortality rate, TTTS should be treated; medical therapies such as digoxin³⁵ and indomethacin³⁶ have been reported to give poor results. Invasive therapies are now currently offered, including serial amniodrainage^{37–41}, endoscopic selective coagulation of placental anastomoses^{42–44} and interfetal septum amniotomy^{45–50}. Selective feticide, with endoscopic clamping of the umbilical cord, is an alternative when the survival of both twins is not attainable^{51,52}.

Endoscopic coagulation of placental anastomoses (Figures 35.11 and 35.12) The rationale of this therapy is to

interrupt the anastomotic blood flow and then to offer a causal treatment^{42–44}. It is often combined with amniodrainage, which may increase its efficacy. Recently, a prospective randomized trial of TTTS treatment by endoscopic laser surgery, versus serial amnioreduction alone, reported in the laser group a higher survival rate of at least one fetus (76% vs. 56%) and a lower incidence of cystic periventricular leukomalacia (6% vs. 14%). The authors concluded that laser coagulation of the anastomoses should be considered as the first-line treatment of severe TTTS⁴². This was in agreement with the preliminary study of Hecher *et al.*, which reported a similar survival rate of 51% versus 61% but a lower incidence of intrauterine demise and neonatal ultrasound brain anomalies in the laser-treated group⁴³. The procedure is generally performed percutaneously under local anesthesia, with a miscarriage rate of 7%, placental abruption rate of 2% and premature rupture of the

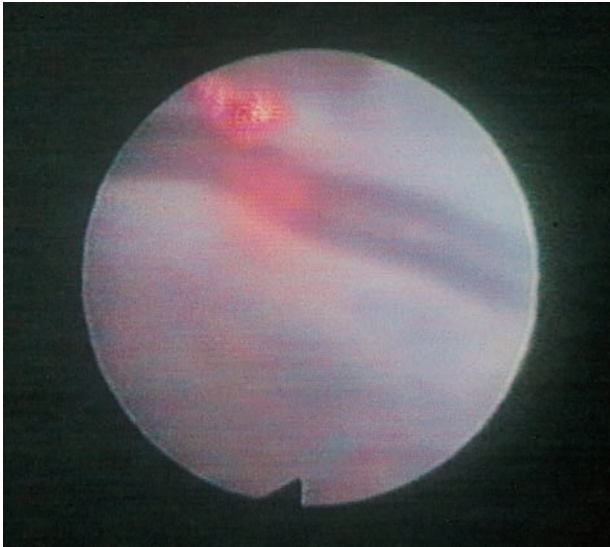


Figure 35.11 Endoscopic view of placental anastomoses in twin-to-twin transfusion syndrome (pre-laser coagulation)

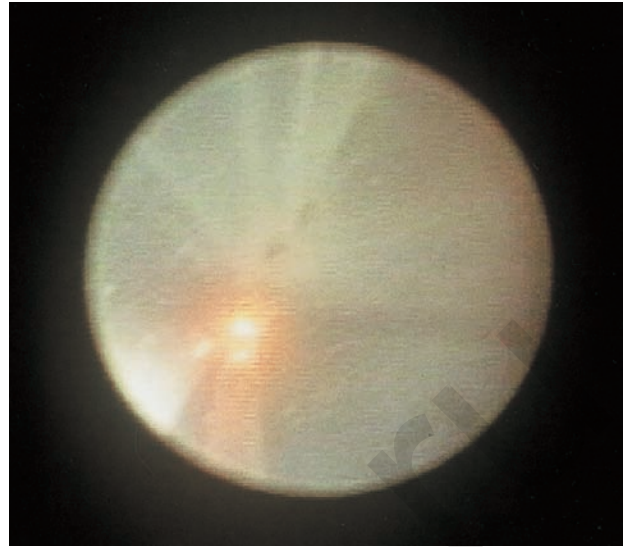


Figure 35.13 Fetoscopic view of an intertwin membrane with laser-operated septostomy

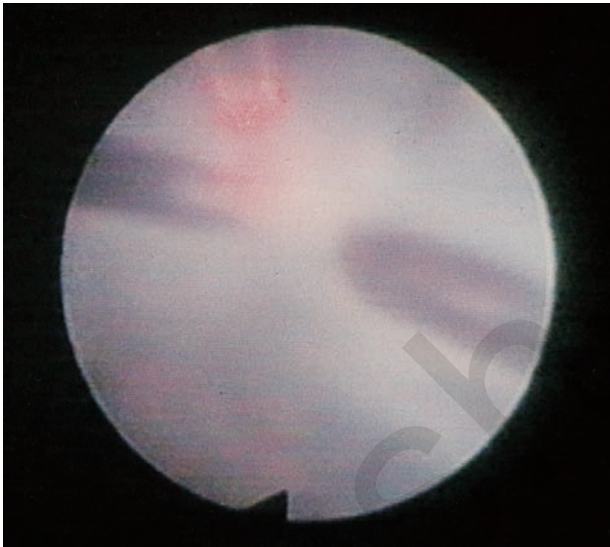


Figure 35.12 Endoscopic view of placental anastomoses in twin-to-twin transfusion syndrome (post-laser coagulation)

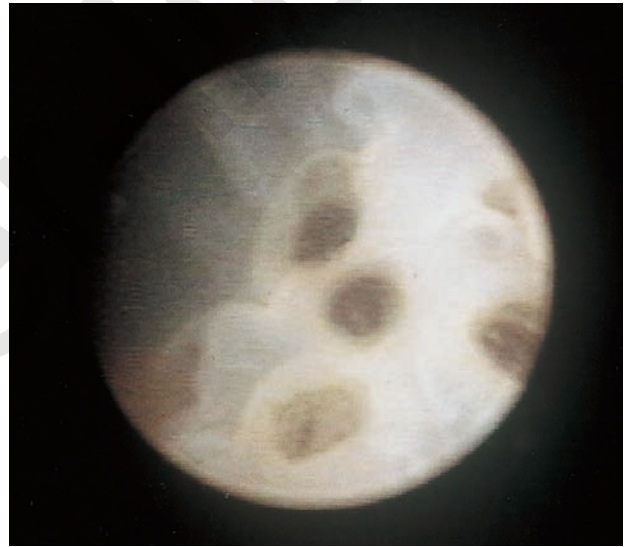


Figure 35.14 Fetoscopic view of an intertwin membrane with several laser shots

membranes (PROM) rate of 28%^{43,44}. In the early cases, anterior placenta was associated with laparotomy, but in later studies laparotomy is not considered to be a contraindication to fetoscopy-guided laser coagulation^{42,44}.

Even if the study of Senat *et al.*⁴² answered partly the question about efficacy of the technique in terms of fetal results, the associated maternal risk should still be borne in mind.

Septostomy This technique, involving intentional rupture of the intertwin septum, was reported by our team following one case of unintentional septostomy which led to an improvement in TTTS⁴⁵, and also by Saade *et al.*⁴⁶.

Other cases of septostomy have been reported, with differing outcomes^{47,48}, and a prospective randomized trial of amnioreduction versus septostomy before 24 weeks reported a similar survival rate (at least one infant, 78% vs. 80%)⁴⁹. This study supports, however, the advantage of a single procedure in septostomy. A possible mechanism for the therapeutic effect of septostomy could be the equilibration of amniotic fluid between the two sacs, associated with correction of the unbalanced flow, mainly in the donor umbilical vessels and on the placental surface^{50,53}. The involvement of amniotic fluid pressure changes has been suggested, but one article based on only two cases reports a similarly increased pressure in both

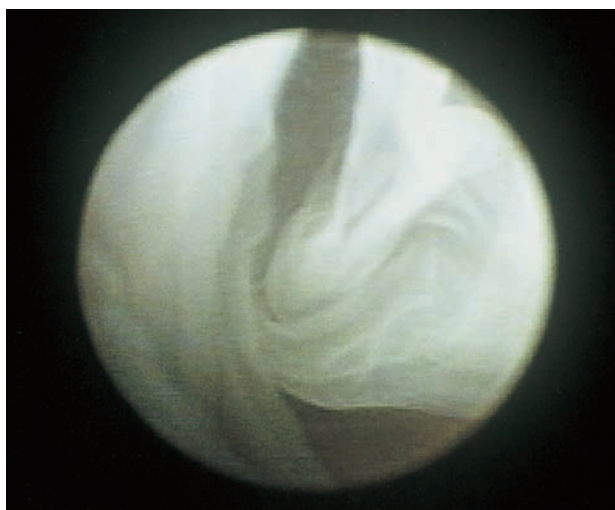

Figure 35.15 Fetoscopic view of an intertwin membrane rupture following laser-operated coagulation

sacs⁵⁴. In the donor twin, the filling of the amniotic sac may decrease cord compression, mainly when there is a velamentous insertion, a common finding in TTTS⁵⁵. Another argument for the therapeutic effect of septostomy is the role of the intertwin septum in TTTS, as it is rare in monoamniotic twin pregnancy despite the presence of numerous placental anastomoses⁵⁵.

Technically, septostomy could be performed by fetoscopic Nd:YAG (neodymium:yttrium–aluminum–garnet) laser fulguration alone, or associated with placental anastomosis coagulation (Figures 35.13–35.15). However, in our latest cases, it was performed under ultrasound guidance by intentional needling of the intertwin membrane, as shown in Figure 35.16. Table 35.2 gives the combined results of the pioneer centers using this technique, with a mean survival rate of 65%^{45,46,49}. The results of improved fetal hemodynamics (mainly umbilical artery Doppler)^{46,50} are associated with increased donor urine production. This factor has been reported to be associated with a better survival rate⁵⁶.

The main specific risk associated with amniotomy is the iatrogenic creation of a pseudomonoamniotic twin pregnancy with cord entanglement⁵⁷. However, this may be reduced by creating a small hole, as in twin pregnancy transeptal diagnostic amniocentesis⁵⁸. Another potential

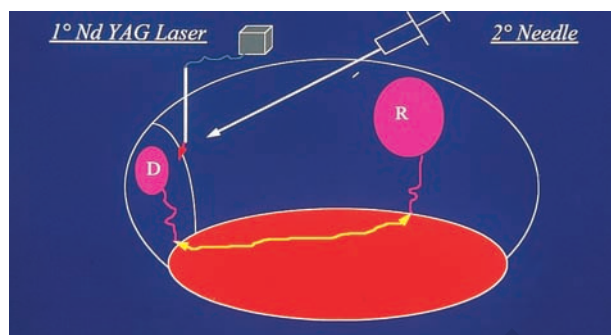


Figure 35.16 Septostomy techniques. Nd:YAG, neodymium:yttrium–aluminum–garnet; D, donor twin; R, recipient twin

risk associated with septostomy is the presence of membrane flaps, which may induce amniotic band syndrome⁵⁹, and further compromising fetoscopic procedures such as cord ligation^{60,61}.

Cord occlusion in abnormal twin pregnancy

In cases of acardiac twin pregnancy or in monochorionic multiple pregnancy with a compromised twin, selective feticide may be an ethically acceptable option, aiming to improve the healthy cotwin outcome. As KCl injection cannot be used because of placental anastomosis, fetoscopic cord obliteration may be offered as a safe alternative. Cord occlusion techniques aim mainly to decrease the morbidity and mortality of the surviving twin. It may be performed by cord ligation using two or three ports^{51,52} (Figures 35.17–35.20) with the increased risk of side-effects or by a recently described single-port technique using a 2.5-mm bipolar coagulation forceps under ultrasound guidance^{62,63}. In terms of results, studies of cord coagulation in 23 and 46 cases, respectively, reported a 71–87% survival rate with 40% and 12% rates of preterm labor^{62,63}.

Obstructive uropathies

Fetal lower urinary tract obstruction, such as in the case of posterior urethral valve, is associated with a risk of chronic renal failure, oligohydramnios and pulmonary hypopla-

Table 35.2 Survival rate of fetuses with twin-to-twin transfusion syndrome (TTTS) treated by septostomy

	Hubinont <i>et al.</i> ⁴⁵ (<i>n</i> = 7)	Saade <i>et al.</i> ⁴⁶ (<i>n</i> = 9)	Moise <i>et al.</i> ⁴⁹ (<i>n</i> = 73)
Second-trimester TTTS (<i>n</i>)	7	5	73 (below 24 weeks)
Survival rate (%)	57	83	78

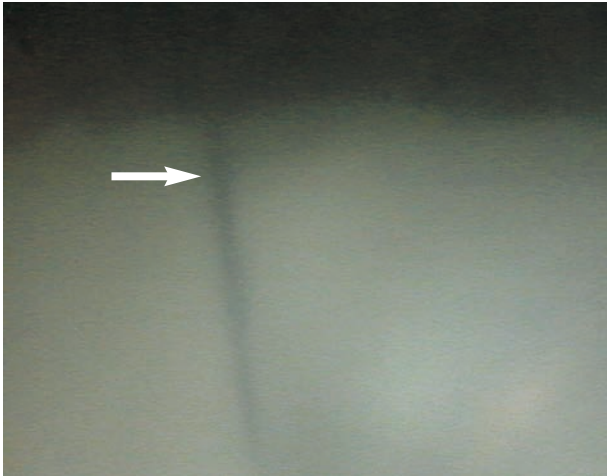

Figure 35.17 Fetoscopically operated cord ligation in abnormal monochorionic twin pregnancy: looping of the cord by a black-colored suture (arrow)



Figure 35.19 Fetoscopically operated cord ligation in abnormal monochorionic twin pregnancy: cord with the knot (arrow)

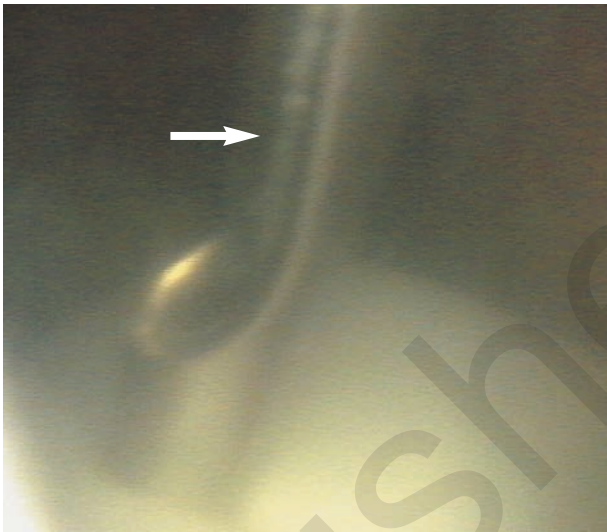


Figure 35.18 Fetoscopically operated cord ligation in abnormal monochorionic twin pregnancy: the knot is tied by using a knot pusher (arrow)

sia⁶⁴. *In utero* therapy may be offered in these pregnancies either by open fetal surgery⁶⁴ or, more often, by percutaneous ultrasound-guided vesicoamniotic shunt⁶⁵. The high morbidity associated with open surgery and displacement or obstruction of the catheter has recently opened the door to a third therapeutic alternative: percutaneous fetal cystoscopy with laser fulguration of the urethral valve^{66,67}. This procedure improves the diagnosis (visualization of thickened bladder neck, dilated proximal urethra, ureteral orifices) and can exclude other abnormalities such as urethral atresia or persistent cloaca. However, the survival rate and the urological outcome should be studied in a larger series before being routinely applied.

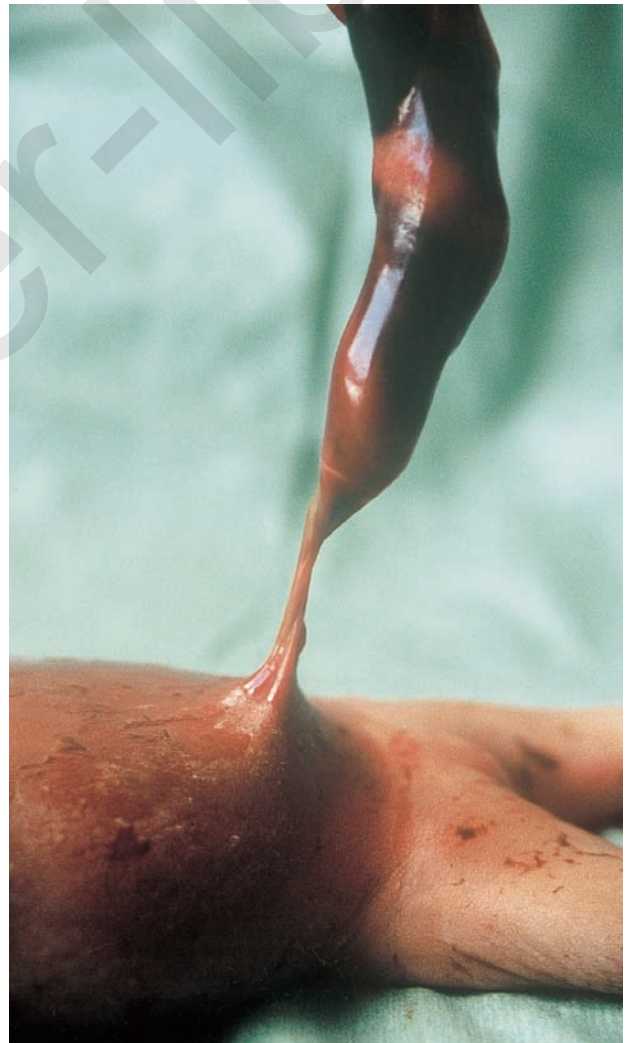


Figure 35.20 Fetoscopically operated cord ligation in abnormal monochorionic twin pregnancy: postmortem aspect of cord ligation

Congenital diaphragmatic hernia

This abnormality is associated with a risk of severe pulmonary hypoplasia and a high neonatal mortality rate⁶⁸. Prenatal surgery based on animal studies involves performing a fetal tracheal occlusion either by an open procedure⁶⁹ or, more recently, by fetoscopy⁷⁰. Two techniques have been reported: tracheal occlusion⁷¹ and fetoscopic endoluminal tracheal occlusion using a detachable balloon⁷². This can prevent abnormal lung fluid dynamics and enhances lung growth. Preliminary results of a randomized trial suggest that fetoscopic tracheal occlusion does not increase the survival rate compared with postnatal management⁷¹. Endotracheal placement of the balloon, performed in 20 cases with bad-prognosis congenital diaphragmatic hernia, was technically successful in 65%. Survival rate was 50%, with a normal neurological assessment in ten infants⁷². However, long-term follow-up will be required to confirm the benefits of these new surgical approaches.

Myelomeningocele

This neural tube defect with a prevalence of five cases for every 10 000 births is associated with various degrees of paraplegia, neurogenic sphincter dysfunction and severe mental retardation in the presence of associated hydrocephaly⁷³. A recent article reported four second-trimester cases of myelomeningocele, which underwent endoscopic coverage of the defect using a maternal skin graft⁷⁴. Only two of them survived at birth, and these remaining two had a satisfactory neurological outcome. Even if the technique is feasible and seems attractive, randomization and long-term follow-up are needed.

Sacroccygeal teratoma

This rare tumor is generally treated surgically at birth, but in some cases, large tumors associated with substantial blood sequestration may induce high-output heart failure and fetal hydrops, with a poor prognosis. Several fetal surgical approaches have been reported, including *ex utero* surgery⁷⁵, endoscopic laser coagulation⁷⁶, cystic decompression by needling⁷⁷ and, in our department, a trial of thermocoagulation of the feeding vessels using a needle-sized device introduced transabdominally under ultrasound guidance (unpublished data).

Placental chorioangioma

A case report of a large chorioangioma treated successfully by laser coagulation of the feeding vessel introduces the opportunity to treat this severe complication by fetoscopy⁷⁸.

Fetal cardiac surgery

Fetal catheterization has been successfully performed in sheep⁷⁹, and could be a potential approach for treating fetal heart-block using a pacemaker, as well as performing valvuloplasty in cases of severe vessel stenosis.

RISKS, SAFETY AND COMPLICATIONS

Before performing a fetoscopy, both the risks and potential benefits should be clearly explained to the patient. Potential risks for maternal and/or fetal injury have been previously reported⁶⁻⁸; fetal loss is the most common complication, with an incidence between 3%^{5,6} and 9%⁸. In diagnostic fetoscopy, premature rupture of the membranes occurs in approximately 5–7% of cases⁶. It may reach 10% in a group of therapeutic endoscopy procedures (TTTS treated by laser coagulation)⁴³, and even 30% in fetoscopic cord ligation⁶¹. Amniotic fluid leakage may be avoided by reducing trocar size and the number of ports, and perhaps by using a gelatin sponge⁸⁰ or a collagen plug⁸¹, as demonstrated in animal models. Recently, a trial of closure of iatrogenic membrane defects following fetoscopy, using platelet sealant, fibrin glue and powered collagen injection, was successful in 7/8 cases⁸². The risk of fetal eye injury by endoscopic white light has been excluded in fetal lamb and rat models^{83,84}.

Quintero *et al.* reported a failure rate of 16% in diagnostic endoscopy, mainly due to early gestation (5th and 6th weeks), obesity and severely retroverted uterus⁶.

Maternal risks are not negligible⁸⁵, and include hemorrhage (one case in our experience; unpublished data), chorioamnionitis and pulmonary and potential amniotic embolism. Amniotic air insufflation was found to be safe in a sheep model⁸⁶.

CONTRAINDICATIONS

Fetal endoscopy should not be performed in pregnant patients with active bleeding, suspicion of premature rupture of the membranes and intrauterine infection^{6,8,85}.

CONCLUSIONS

Fetoscopy is now a well-established tool in fetal medicine. Embryofetoscopy allows the confirmation of first-trimester prenatal diagnosis of structural anomalies affecting mainly the face and/or limb extremities. It can confirm early ultrasound diagnosis prior to dilatation and curettage, allowing, in some cases, genetic counseling. Early tissue sampling is feasible in early gestation.

Minimally invasive fetal surgery by endoscopy is used routinely in specific fetal conditions. In complicated multiple pregnancies (TTTS, selective cord ligation), these

invasive antenatal procedures still carry a high fetal loss rate, shown recently to be similar in twin and triplet pregnancies⁸⁷. It will have a greater therapeutic role in the future, with both technical improvements in the equipment and improvements in the prevention of complications.

Several indications have been reviewed in this chapter, and others are still under investigation in animal models, such as cleft lip repair^{88,89}. Ethical considerations relating to the balance of risks and benefits should always be kept in mind and not be underestimated.

Future developments, such as access to embryos for either stem-cell injection to treat some immunological disorders *in utero*⁹⁰ or gene therapy⁹¹, will be among the challenges in fetal therapy for the coming years.

REFERENCES

- Westin B. Hysteroscopy in early pregnancy. *Lancet* 1954; 2: 872
- Kan YW, Valenti C, Guidotti R, et al. Fetal blood sampling in utero. *Lancet* 1974; 1: 79–80
- Rodeck CH, Campbell S. Sampling pure fetal blood by fetoscopy in the second trimester of pregnancy. *Br Med J* 1978; 2: 728–30
- Valenti C. Endoamniocopy and fetal biopsy: a new technique. *Am J Obstet Gynecol* 1972; 114: 561–4
- Rodeck CH. Fetoscopy guided by real-time ultrasound for pure fetal blood samples, fetal skin samples and examination of the fetus in utero. *Br J Obstet Gynaecol* 1980; 87: 449–56
- Quintero RA, Puder KS, Cotton DB. Embryoscopy and fetoscopy. *Obstet Gynecol Clin North Am* 1993; 3: 563–81
- Dumez Y, Oury JF, Duchetel F. Embryoscopy and congenital malformations. In *Proceedings of the International Conference on Chorionic Villus Sampling and Early Prenatal Diagnosis*, Athens, Greece, 1988
- Reece EA, Homko C, Golstein I, Wiznitzer A. Toward fetal therapy using needle embryoscopy. *Ultrasound Obstet Gynecol* 1995; 5: 281–5
- Ville Y, Bernard JP, Multon O, et al. Transabdominal fetoscopy in fetal anomalies diagnosed by ultrasound in the first trimester of pregnancy. *Ultrasound Obstet Gynecol* 1996; 8: 11–15
- Luks FI, Deprest J, Marcus M, et al. Carbon dioxide pneumoamnios causes acidosis in fetal lamb. *Fetal Diagn Ther* 1994; 9: 105–9
- Ford WDA, Cool JC, Byard R, Allanson M. Glycine as a potential window for minimal access fetal surgery. *Fetal Diagn Ther* 1997; 12: 145–8
- Van De Velde M, Van Schoubroeck D, Lewi LE, et al. Remifentanyl for fetal immobilization and maternal sedation during fetoscopic surgery: a randomized, double-blind comparison with diazepam. *Anesth Analg* 2005; 101: 251–8
- Cullen MT, Green J, Whetham J, et al. Transvaginal ultrasonographic detection of congenital anomalies in the first trimester. *Am Obstet Gynecol* 1990; 163: 466–76
- Hubinont C, Kollmann P, Bernard P, et al. First trimester diagnosis of conjoined twins by means of ultrasound and embryoscopy *Fetal Diag Ther* 1997; 12: 185–7
- Schwarzler P, Moscoso G, Senat MV, et al. The cobweb syndrome: first trimester sonographic diagnosis, multiple amniotic bands confirmed by fetoscopy and pathological examination. *Hum Reprod* 1998; 13: 2966–9
- Reece EA, Rotmensch S, Whetham J, et al. Embryoscopy: a closer look at first trimester diagnosis and treatment. *Am J Obstet Gynecol* 1992; 166: 775–80
- Quintero RA, Abuhamad A, Hobbins JC, Mahoney MJ. Transabdominal thin-gauge embryofetoscopy: a technique for early prenatal diagnosis and its use in the diagnosis of a case of Meckel–Gruber syndrome. *Am J Obstet Gynecol* 1993; 168: 1552–7
- Hobbins JC, Jones OW, Gottesfeld S, Persutte W. Transvaginal ultrasonography and transabdominal embryoscopy in the first trimester diagnosis of Smith-Lemli-Opitz syndrome, type II. *Am J Obstet Gynecol* 1994; 171: 546–9
- Kabra M, Gulati S, Ghosh M, Menon PS. Fraser cryptophthalmos syndrome. *Indian J Pediatr* 2000; 67: 775–8
- Reece EA, Homko CJ, Koch S, Chan L. First trimester needle embryoscopy and prenatal diagnosis. *Fetal Diagn Ther* 1997; 12: 136–9
- Wu Y, Sun N, Wang F. Antenatal diagnosis of albinism fetuses by fetoscopy. *Chung Hua Fu Chan Ko Tsai Cih* 1998; 33: 482–3
- Evans MI, Quintero RA, King M, et al. Endoscopically assisted ultrasound guided fetal muscle biopsy. *Fetal Diagn Ther* 1995; 10: 167–72
- Reece EA, Goldstein I, Chatwani A, et al. Transabdominal needle embryofetoscopy: a new technique paving the way for early fetal therapy. *Obstet Gynecol* 1994; 84: 634–6
- Seubert DE, Feldman B, Krivchenia EL, et al. Molecular and fetal tissue biopsy capabilities are needed to do prenatal diagnosis of junctional epidermolysis bullosa: fetal biopsy using a 1 mm microendoscope. *Fetal Diagn Ther* 2000; 15: 89–92
- Quintero RA, Morales WJ, Gilbert Barnes E, et al. In utero diagnosis of trichothiodystrophy by endoscopically fetal eyebrow biopsy. *Fetal Diagn Ther* 2000; 15: 152–5
- Weiner CP, Ludomirski A. Diagnosis, pathophysiology and treatment of chronic twin to twin transfusion syndrome. *Fetal Diagn Ther* 1994; 9: 283–90
- Radestad A, Thomassen AA. Acute polyhydramnios in twin pregnancy. A retrospective study with special reference to therapeutic amniocentesis. *Acta Obstet Gynaecol Scand* 1990; 69: 297–300
- Mahony BS, Petty CN, Nyberg DA, et al. The stuck twin phenomenon. *Am J Obstet Gynecol* 1990; 163: 1513–21

29. Reisner DP, Mahoney BS, Petty CN, et al. Stuck twin syndrome: outcome in 37 consecutive cases. *Am J Obstet Gynecol* 1993; 169: 991–5
30. Bernischke K, Kim CK. Multiple pregnancy. *N Engl J Med* 1973; 288: 1276–80
31. Weir PE, Raten GJ, Beisher NA. Acute polyhydramnios – a complication of monozygous pregnancy. *Br J Obstet Gynaecol* 1979; 86: 846–53
32. Fusi L, McParland P, Fisk NM, et al. Acute twin-twin transfusion: a possible mechanism for brain-damaged survivors after intrauterine death of a monochorionic twin. *Obstet Gynecol* 1991; 78: 517–20
33. Bajoria R, Wee LY, Anwar S, Ward S. Outcome of twin pregnancies complicated by intrauterine death in relation to vascular anatomy of the monochorionicity. *Hum Reprod* 1999; 14: 2214–30
34. Dickinson JE, Evans SF. Obstetric and perinatal outcomes from the Australian and New Zealand twin-twin transfusion syndrome registry. *Am J Obstet Gynecol* 2000; 182: 706–12
35. De Lia Jr, Emery MG, Sheator SA, Jennison TA. Twin transfusion syndrome: successful in utero treatment with digoxin. *Int J Obstet Gynecol* 1985; 23: 197–201
36. Ash K, Harman CR, Gritter H. TRAP sequence successful outcome with indomethacin. *Obstet Gynecol* 1990; 76: 960–2
37. Elliott JP, Urig MA, Clewell WH. Aggressive therapeutic amniocentesis for the treatment of twin-twin transfusion syndrome. *Obstet Gynecol* 1991; 77: 537–40
38. Saunders NJ, Snijders RJM, Nicolaides KH. Therapeutic amniocentesis in TTTS appearing in the second trimester of pregnancy. *Am J Obstet Gynecol* 1992; 166: 820–4
39. Dennis LG, Winkler CL. Twin to twin transfusion syndrome: aggressive amniocentesis. *Am J Obstet Gynecol* 1997; 177: 342–7
40. Fesslova V, Villa L, Nava S, et al. Fetal and neonatal echographic findings in twin-twin transfusion syndrome. *Am J Obstet Gynecol* 1998; 179: 1056–62
41. Gary D, Lysikiewicz A, Mays J, et al. Intraamniotic pressure reduction in twin-twin transfusion syndrome. *J Perinatol* 1998; 18: 284–6
42. Senat MV, Deprest J, Boulvain M, et al. Endoscopic laser surgery versus serial amnioreduction for severe twin-to-twin transfusion syndrome. *N Engl J Med* 2004; 351: 136–44
43. Hecher K, Plath H, Bregenzler T, et al. Endoscopic laser surgery versus serial amniocenteses in the treatment of severe twin twin transfusion syndrome. *Am J Obstet Gynecol* 1999; 180: 717–24
44. Yamamoto M, El Murr L, Robyr R, et al. Incidence and impact of perioperative complications in 175 fetoscopy-guided laser coagulations of chorionic plate anastomoses in severe twin-twin transfusion syndrome before 26 weeks of gestation. *Am J Obstet Gynaecol* 2005; 193: 1110–16
45. Hubinont C, Bernard P, Mwebesa W, et al. Nd : YAG laser and needle disruption of the interfetal septum: a possible therapy in severe twin-twin transfusion syndrome. *J Gynecol Surg* 1996; 12: 183–9
46. Saade GR, Belfort MA, Berry DA, et al. Amniotic septostomy for the treatment of twin oligohydramnios polyhydramnios sequence. *Fetal Diagn Ther* 1998; 13: 86–93
47. Pistorius LR, Howarth GR. Failure of amniotic septostomy in the management of 3 subsequent cases of severe previable twin twin transfusion syndrome. *Fetal Diagn Ther* 1999; 14: 337–40
48. Suzuki S, Ishikawa G, Sawa R, et al. Iatrogenic monoamniotic twin gestation with progressive twin twin transfusion syndrome. *Fetal Diagn Ther* 1999; 14: 98–101
49. Moise KJ, Dorman K, Lamvu G, et al. A randomized trial of amnioreduction versus septostomy in the treatment of twin-twin transfusion syndrome. *Am J Obstet Gynecol* 2005; 193: 701–7
50. Hubinont C, Bernard P, Pirot N, et al. Twin to twin transfusion syndrome: treatment by amniodrainage and septostomy. *Eur J Obstet Gynecol Reprod Biol* 2000; 92: 141–5
51. Hubinont C, Donnez J. Possible indications for cord ligation: endoscopy. In *The Uterus Throughout the Woman's Life. Proceedings of the 4th Congress of the European Society for Gynaecological Endoscopy*. Bologna, Italy: Monduzzi Editore, 1995
52. Deprest JA, Van Ballaer PP, Evrard VA, et al. Experience with fetoscopic cord ligation. *Eur J Obstet Gynecol Reprod Biol* 1998; 81: 157–64
51. Fisk NM, Tannirandorm Y, Nicolini U, et al. Amniotic pressure in disorders of amniotic fluid volume. *Obstet Gynecol* 1990; 76: 210–14
52. Hartung J, Chaoui R, Bollmann R. Amniotic fluid pressure in both cavities of twin-to-twin transfusion syndrome: a vote against septostomy. *Fetal Diagn Ther* 2000; 15: 79–82
53. Fries M, Goldstein RB, Kilpatrick SJ, et al. The role of velamentous cord insertion in the etiology of twin twin transfusion syndrome. *Obstet Gynecol* 1993; 81: 569–74
54. Tessen JA, Zlatnik FJ. Monoamniotic twins: a retrospective controlled study. *Obstet Gynecol* 1991; 77: 832–4
55. Hubinont C, Bernard P. Syndrome transfuseur-transfusé: prise en charge par amnioreduction itérative et amniotomie. *Med Foetale Echogr Gynécologie* 1999; 38: 18–21
56. Trespidi L, Boschetto C, Caravelli E, et al. Serial amniocentesis in the management of twin-twin transfusion syndrome: when is it valuable? *Fetal Diagn Ther* 1997; 12: 15–20
57. Cook TL, Shaughnessy R. Iatrogenic creation of a monoamniotic twin gestation in severe twin-twin transfusion syndrome. *J Ultrasound Med* 1997; 16: 853–5
58. Van Vugt JM, Nieuwint A, van Geijn HP. Single needle insertion: an alternative technique for early second trimester genetic twin amniocentesis. *Fetal Diagn Ther* 1995; 10: 178–81
59. Deprest J, Van Schoubroeck D, Evrard V, et al. Chirurgie endoscopique intrautérine: invasion

- minimale pour le foetus? *Gunaikieia* 1996; 1: 3115–19
60. Robyr R, Lewi L, Salomon LJ, et al. Twin-to-twin transfusion syndrome. *Am J Obstet Gynecol* 2006 Mar; 194: 796–803
 61. Yamamoto M, EI Murr L, Robyr R, et al. Incidence and impact of perioperative complications in 175 fetoscopy-guided laser coagulations of chorionic plate anastomoses in fetofetal transfusion syndrome before 26 weeks of gestation. *Am J Obstet Gynecol* 2005; 193: 1110–16
 62. Yesidaglar N, Zikulnig L, Gratacos E, et al. Bipolar coagulation with small diameter forceps in animal models for in utero cord obliteration. *Hum Reprod* 2000; 15: 865–8
 63. Robyr R, Yamamoto M, Ville Y. Selective feticide in complicated monochorionic twin pregnancies using ultrasound-guided bipolar cord coagulation. *Br J Obstet Gynaecol* 2005; 112: 1344–8
 64. Harrison M. *Atlas of Fetal Surgery*. London: Chapman & Hall, 1996; Part II: 63–79
 65. Goldbus MS, Filly RA, Callen PW, et al. Fetal urinary tract obstruction: management and selection for treatment. *Semin Perinatol* 1985; 9: 91–101
 66. Quintero RA, Morales WJ, Allen MH, et al. Fetal hydrolaparoscopy and endoscopic cystotomy in complicated cases of lower urinary tract obstruction. *Am J Obstet Gynecol* 2000; 183: 324–30
 67. Hofmann R, Becker T, Meyer-Wittkopf M, et al. Fetoscopic placement of a transurethral stent for intrauterine obstructive uropathy. *J Urol* 2004; 171: 384–6
 68. Adzick NS, Nance ML. Pediatric surgery Part two. *N Engl J Med* 2000; 342: 1726–32
 69. Harrison M. *Atlas of Fetal Surgery*. London: Chapman & Hall 1996; Part II: 93–145
 70. Harrison MR, Mychaliska GB, Albanese CT, et al. Correction of congenital diaphragmatic hernia in utero: those with poor prognosis (liver herniation and low lung to head ratio) could be saved by fetoscopic temporary tracheal occlusion. *J Pediatr Surg* 1998; 33: 1017–22
 71. Cass DL. Fetal surgery for congenital diaphragmatic hernia: the North American experience. *Semin Perinatol* 2005; 29: 104–11
 72. Deprest J, Jani J, Gratacos E, et al., FETO Task Group. Fetal intervention for congenital diaphragmatic hernia: the European experience. *Semin Perinatol* 2005; 29: 94–103
 73. Steinbok P, Irvine B, Cochrane DD, Irwin BJ. Long term outcome and complications in children born with meningomyelocele. *Childs Nerv Syst* 1992; 8: 92–6
 74. Bruner JP, Richards O, Tulipan NB, Arney TL. Endoscopic coverage of fetal myelomeningocele in utero. *Am J Obstet Gynecol* 1999; 180: 153–8
 75. Chiba T, Albanese CT, Jennings RW, et al. In utero repair of rectal atresia after complete resection of sacrococcygeal teratoma. *Fetal Diagn Ther* 2000; 15: 187–90
 76. Hecher K, Hackelloer BJ. Intrauterine endoscopic laser surgery for fetal sacrococcygeal teratoma. *Lancet* 1996; 347: 470–2
 77. Garcia AM, Morgan WM, Bruner JP. In utero decompression of a cystic grade IV sacrococcygeal teratoma. *Fetal Diagn Ther* 1998; 13: 305–8
 78. Quarello E, Bernard JP, Leroy B, Ville Y. Prenatal laser treatment of a placental chorioangioma. *Ultrasound Obstet Gynecol* 2005; 25: 299–301
 79. Kohl T, Stumper D, Witteler R, et al. Fetoscopic direct fetal cardiac access in sheep: an important experimental milestone along the route to human fetal cardiac intervention. *Circulation* 2000; 102: 1602–4
 80. Luks FI, Deprest JA, Peers KHE, et al. Gelatin sponge plug to seal fetoscopy port sites: technique in ovine and primate models. *Am J Obstet Gynecol* 1999; 181: 995–6
 81. Gratacos E, Wu J, Yesidaglar N, et al. Successful sealing of fetoscopic access sites with collagen plug in a rabbit model. *Am J Obstet Gynecol* 2000; 182: 142–6
 82. Young BK, Roman AS, McKensie AP, et al. The closure of iatrogenic membrane defects after amniocentesis and endoscopic intrauterine procedures. *Fetal Diagn Ther* 2004; 19: 296–300
 83. Deprest J, Luks F, Peers KHE, et al. Natural protective mechanisms against endoscopic white-light injury in the fetal lamb eye. *Obstet Gynecol* 1999; 94: 124–7
 84. Bonnett ML, Quintero RA, Carreno C, Crossland WJ. Effect of endoscopic white light on the developing rat retina. *Fetal Diagn Ther* 1997; 12: 76–80
 85. Gratacos E, Deprest J. Current experience with fetoscopy and the Eurofoetus registry for fetoscopic procedures. *Eur J Obstet Gynecol Reprod Biol* 2000; 92: 151–9
 86. Kohl T, Reckers J, Strumper D, et al. Amniotic air insufflation during minimally invasive fetoscopic fetal cardiac interventions is safe for the fetal brain in sheep. *J Thorac Cardiovasc Surg* 2004; 128: 467–71
 87. Van Schoubroeck D, Lewi L, Ryan G, et al. Fetoscopic surgery in triplet pregnancies: a multi-center case series. *Am J Obstet Gynecol* 2004; 191: 1529–32
 88. Harrison M. Fetal surgery. *Am J Obstet Gynecol* 1996; 174: 1255–64
 89. Papadopoulos NA, Papadopoulos MA, Kovacs L, et al. Foetal surgery and cleft lip and palate: current status and new perspectives. *Br J Plast Surg* 2005; 58: 593–607
 90. Cowan MJ, Goldbus MS. In utero hematopoietic stem cell transplants for inherited diseases. *Am J Pediatr Hematol Oncol* 1994; 16: 35–42
 91. Yang EY, Cass DL, Sylvester KG, et al. Fetal gene therapy: efficacy, toxicity and immunologic effects of early gestation recombinant adenovirus. *J Pediatr Surg* 1999; 34: 235–41

Laparoscopic abdominal cerclage

R Al-Fadhli, T Tulandi

Recurrent second-trimester pregnancy loss, due to inability of the cervix to hold the pregnancy, is commonly known as cervical insufficiency. Characteristically, it is associated with painless dilatation of the cervix without uterine contraction. The membranes then protrude into the vagina and rupture, leading to rapid and painless delivery of the fetus. In many cases there is a clear history of traumatic injury to the cervix, such as traumatic delivery or a surgical procedure to the cervix, or congenital conditions such as uterine anomaly and diethylstilbestrol (DES) exposure. It is thought that the condition is due to a defect in the strength of the cervical tissue, either congenitally or acquired, resulting in the inability to maintain a pregnancy¹. The incidence of cervical insufficiency is very difficult to determine because there are no clear clinical criteria for the diagnosis. However, cervical incompetence can be diagnosed in 0.1–1.0% of all pregnancies, and in 8% of women with repeated mid-trimester pregnancy loss².

The treatment consists of placing a purse-string suture around the cervix. The conventional method is by placing the sutures vaginally. This was first described by Lash and Lash in 1950³, whereby they applied the suture in non-pregnant women. Subsequently, Shirodkar described his technique of insertion of a cervical suture in pregnancy⁴. The procedure is performed by first incising the anterior vaginal wall and pushing the bladder upward. The suture is placed under the vaginal wall around the cervix at the level of the internal os. Five women were also operated on in the non-pregnant state: three conceived. McDonald, in 1957, described a simpler purse-string suture around the body of the cervix without burying the sutures under the vaginal wall⁵. Although there is no good randomized study, clinical evidence strongly suggests that cervical cerclage decreases the occurrence of second-trimester pregnancy loss^{6–13}.

In a small proportion of women, cervical cerclage cannot be performed. In attempts to overcome this problem, several authors have advocated abdominal cerclage^{14–16}. The indications to perform abdominal cervical cerclage are: short cervix, preventing adequate application of the suture, or when vaginal cerclage has previously failed.

ABDOMINAL CERCLAGE

Most women requiring cervical cerclage can be managed by a vaginal operation. However, those with an extremely short, deformed, scarred or absent cervix cannot be treated

by the vaginal approach. Here, the cerclage has to be placed via an abdominal approach. Benson and Durfee described the first transabdominal cervicoisthmic cerclage (TCC) in 1965¹⁷. Most series have described TCC placement in pregnancy towards the end of the first trimester. However, preconception or interval placement of TCC has also been described, and many suggest some benefits over TCC placement in pregnancy. Groom *et al.* reported that preconception transabdominal cervicoisthmic cerclage was associated with a postoperative fetal survival rate of 100% for pregnancies that reached more than 12 weeks of gestation, compared with a preoperative fetal survival rate of 12%¹⁸. Anthony *et al.*¹⁵ reported that this procedure increased the successful pregnancy rate from 16 to 86.6%. Nine of their 13 abdominal cerclages were performed in the non-pregnant state. In a review of 111 patients, the success rate was 89%, compared with only 19% before TCC¹⁹.

The procedure is performed under anesthesia through a transverse suprapubic incision. The peritoneum overlying the bladder and uterus is divided, and the bladder is pushed caudally. The uterine vessels are identified and displaced laterally, and a suture is then placed around the cervix at the level of the internal os. The suture is tied posteriorly; this is to allow removal of the suture by posterior colpotomy if necessary¹⁹. The high anatomic placement of TCC compared with transvaginal cervical cerclage is believed to lead to improved results.

Potential advantages of the abdominal approach include high placement of the suture, no slippage of the suture, lack of a foreign body inside the vagina that could predispose to ascending infection and premature labor and the ability to leave the suture in place between pregnancies²⁰.

Until recently, abdominal cerclage required a laparotomy. The uterine vessels have to be dissected from the cervix to allow insertion of the suture medially. The technique is more demanding than that by the vaginal approach, and might lead to excessive bleeding from the uterine vessels. Transillumination of the uterine vessels and their branches with a laparoscope, and placing the suture through the avascular area of the paracervical tissue medial to the vessels, have been proposed. However, a laparotomy is still needed²¹. Excessive manipulation of the pregnant uterus could also lead to pregnancy loss. A simpler and less invasive abdominal cerclage would be beneficial.

Contraindications to abdominal cerclage are similar to those of the vaginal approach, including bulging

membrane, ruptured membranes, intrauterine infections, fetal death, vaginal bleeding and a life-threatening maternal condition. Specific indications for trans-abdominal cerclage are: congenital short or absent cervix or extensively amputated cervix, marked scarring of the cervix, deep and jagged multiple cervical defects or previous failed vaginal cerclage. The efficacy of trans-abdominal cerclage has been established over more than three decades.

LAPAROSCOPIC ABDOMINAL CERCLAGE

A less invasive approach is laparoscopic abdominal cerclage^{20,22}. This approach carries the advantages of the laparoscopic procedure, including no hospitalization, less pain and faster recovery. It can be done with minimal uterine manipulation and minimal dissection. Instead of tracking the uterine vessels and creating a window in the broad ligament, we and others²⁰ have found that the use of a disposable laparoscopic suturing device, piercing the broad ligament medial to the uterine vessels (Endo Close™; Tyco Healthcare, Gosport, UK), facilitates the procedure without the need for vessel dissection. The result of laparoscopic abdominal cerclage is as good as with abdominal cerclage^{20,22-28}.

Most cases of abdominal cerclage have been performed during pregnancy, usually after 10 weeks of gestation. Abdominal cerclage by laparotomy and by laparoscopy have been performed in the pregnant and non-pregnant states. In the pregnant state, an enlarged uterus and the potential risks to the fetus might be problems. However, some authors have suggested performing cerclage as an interval procedure (before pregnancy). In patients whose need for abdominal cerclage is clear, performing the procedure in the non-pregnant state has some advantages. These include decreased fetal or maternal risks, easy manipulation and exposure, and minimal bleeding.

CONCERNS ABOUT ABDOMINAL CERCLAGE IN NON-PREGNANT STATE

Many concerns have been raised about interval cerclage. One such concern is that the chance of conceiving following abdominal cerclage may be impaired. However, in patients who underwent laparoscopic radical trachelectomy and prophylactic cervical cerclage, the pregnancy rate was 55% by the 36th month of exposure²⁹. One of the theoretical concerns relating to cerclage as an interval procedure is when the patient suffers another miscarriage. However, the cervix can easily be dilated to 8 mm, and curettage can be performed in the presence of a cerclage. Alternatively, laparoscopic removal of the cerclage can be performed. A pregnancy of >24 weeks' gestation clearly requires a cesarean delivery.

TECHNIQUE OF LAPAROSCOPIC ABDOMINAL CERCLAGE

The procedure is performed under general anesthesia. The patient is placed in the dorsal lithotomy position followed by insertion of an indwelling catheter. In a non-pregnant state, a uterine manipulator is inserted into the uterine cavity. Laparoscopy is done in the usual fashion, using two secondary trocars at low abdominal quadrants. Depending on the height of the uterus, the secondary trocars are inserted higher than those in the non-pregnant condition, and they should be inserted under direct vision. They are placed higher than the level of the uterine fundus.

The peritoneum of the uterovesical reflection is injected with normal saline to facilitate separation of the bladder from the cervix (Figures 36.1 and 36.2). In contrast to others²², we identify but do not dissect the uterine vessels.

Cerclage is performed using a 5-mm Mersilene® polyester tape. The tape is first prepared by removing the needles from its ends, and the end of the tape is tapered. The adequate length is about 15 cm. The tape is then passed into the pelvis and positioned behind the uterus.

A disposable Endo Close suturing device is passed into the abdominal cavity suprapubically. Its tip is directed toward the isthmus, medial to the uterine vessels (Figure 36.2). The cardinal ligament and the cervical body are pierced, and the tip can be seen at the posterior leaf of the broad ligament just above the insertion of the uterosacral ligament. The end of the tape is grasped with the device, and the device is withdrawn anteriorly, bringing with it the tape (Figures 36.3 and 36.4). The procedure is then repeated on the opposite side, bringing the other end of the tape anteriorly. Using two laparoscopic needle holders, the two ends of the tape are tied anteriorly with a square knot (Figure 36.5). It is secured by another knot. The excess suture material is trimmed. The presence of the

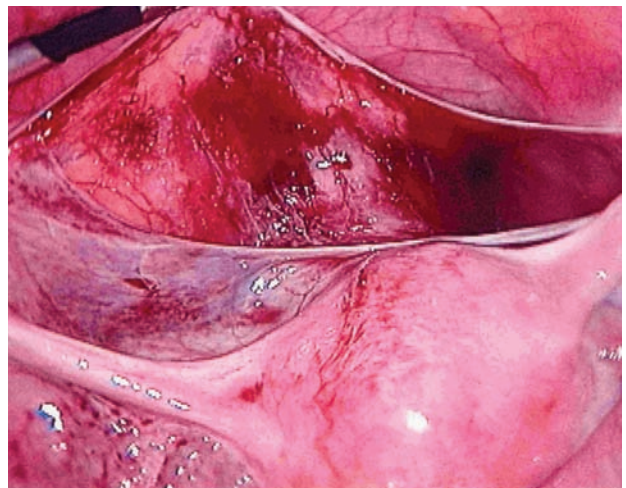


Figure 36.1 The bladder has been separated from the cervix. Reproduced from reference 20, with permission

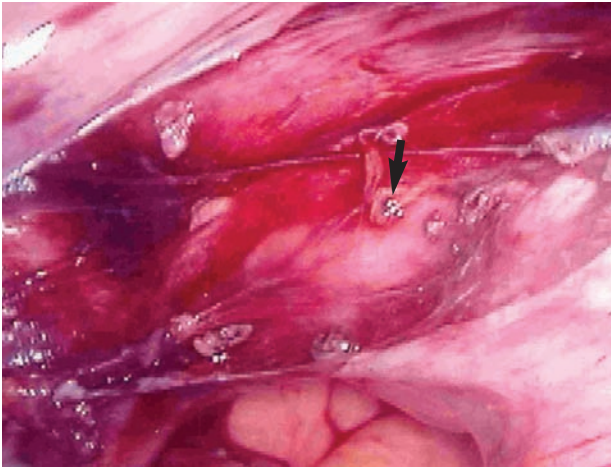


Figure 36.2 An arrow indicates the entry site of the suturing device. Note that the uterine vessels are located medially. Reproduced from reference 20, with permission

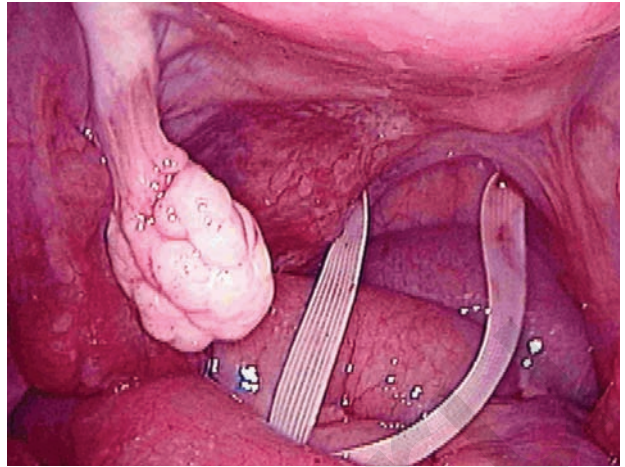


Figure 36.3 Posterior view of the uterus. Note that the suture has been placed around the posterior cervix

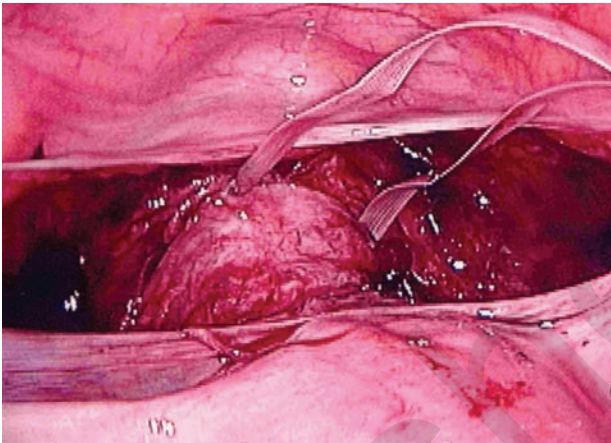


Figure 36.4 The suture has been properly placed

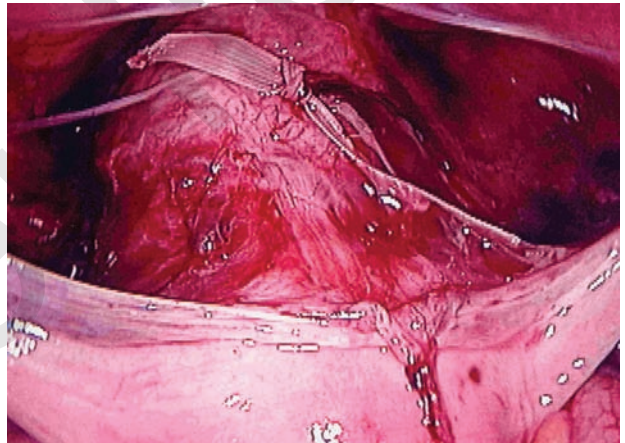


Figure 36.5 The suture has been tied with square knots

uterine manipulator inside the cervix prevents strangulation of the cervix. The abdominal cavity is irrigated with normal saline solution and homeostasis is confirmed.

SUMMARY

In women with an extremely short, deformed, scarred or absent cervix, abdominal cerclage is needed. It is conventionally performed by the laparotomy approach. Laparoscopic abdominal cerclage is a less invasive technique that could replace the laparotomy technique. It should be performed by laparoscopic surgeons with expertise in laparoscopic suturing. The authors have shown that dissection of the uterine vessels is not needed. Laparoscopic abdominal cerclage does not require

hospitalization, is associated with less pain and leads to faster recovery.

In patients whose need for abdominal cerclage is clear, performing the procedure in the non-pregnant state has some advantages. These include decreased fetal or maternal risk, easy manipulation and exposure, and minimal bleeding. Laparoscopic abdominal cerclage is equal to, or may be better than, abdominal cerclage by laparotomy.

REFERENCES

1. Ludmir J. Sonographic detection of cervical incompetence. *Clin Obstet Gynecol* 1988; 31: 101–9

2. Drakeley AJ, Quenhy S, Farquharson RC. Mid trimester loss – appraisal of the screening protocol. *Hum Reprod* 1998; 13: 1975–80
3. Lash AF, Lash SR. Habitual abortion: the incompetent internal os of the cervix. *Am J Obstet Gynecol* 1950; 59: 68–76
4. Shirodkar VN. Reorientation de nos idées sur l'anatomie des ligaments de l'utérus et nouvelles techniques opératoires pour le traitement du prolapsus utérin [Reorientation of our ideas regarding ligaments of the uterus and new surgical techniques for the treatment of uterus prolapse]. *Rev (Fr) Gynecol Obstet* 1954; 49: 332–4
5. McDonald IA. Suture of the cervix for inevitable miscarriage. *J Obstet Gynecol Br Emp* 1957; 64: 346–50
6. Drakeley AJ, Roberts D, Alfirevic Z. Cervical stitch (cerclage) for preventing pregnancy loss in women. *Cochrane Database Syst Rev* 2003; (1): CD003253
7. Althuisius S, Dekker G, Van Geijjan H. Cervical incompetence: a reappraisal of an obstetric controversy. *Obstet Gynecol Surv* 2002; 57: 377–87
8. Harger J. Cerclage and cervical insufficiency: an evidence based analysis. *Obstet Gynecol* 2002; 100: 1313–27
9. Hassan S, Romero R, Maymone E, et al. Does cervical cerclage prevent preterm delivery in patients with short cervix? *Am J Obstet Gynecol* 2001; 184: 1325–31
10. Drakeley A, Roberts D, Alfirevic Z. Cervical cerclage for prevention of preterm delivery: meta-analysis of randomized trials. *Obstet Gynecol* 2003; 102: 621–7
11. Novy M, Gupta A, Wothe D, et al. Cervical cerclage in the second trimester of pregnancy: a historical cohort study. *Am J Obstet Gynecol* 2001; 184: 1447–56
12. Althuisius SM, Dekker GA, Hummel P, et al. Final results of the cervical incompetence prevention randomized cerclage trial (CIPRACT): therapeutic cerclage with bed rest versus bed rest alone. *Am J Obstet Gynecol* 2001; 185: 1106–12
13. MRC/RCOG working party on cervical cerclage. Final report of the Medical Research Council/ Royal College of obstetricians and Gynecologists multi-centre randomized trial of cervical cerclage. *Br J Obstet Gynecol* 1993; 100: 516–23
14. Mackey R, Geary M, Dorman J, McKenna P. A successful pregnancy following transabdominal cervical cerclage hypoplasia. *Br J Obstet Gynaecol* 2001; 108: 1111–12
15. Anthony GS, Walker RG, Cameron AD, et al. Transabdominal cervico-isthmic cerclage in the management of cervical incompetence. *Eur J Obstet Gynecol Reprod Biol* 1997; 72: 127–30
16. Oslen S, Tobiassen T. Transabdominal isthmic cerclage for the treatment of incompetent cervix. *Acta Obstet Gynecol Scand* 1982; 61: 473–5
17. Benson RC, Durfee RB. Transabdominal cervicoisthmic cerclage for the management of repetitive abortion and premature delivery. *Obstet Gynecol* 1965; 25: 145–55
18. Groom KM, Jones BA, Edmonds K, et al. Preconception transabdominal cervicoisthmic cerclage. *Am J Obstet Gynecol* 2004; 191: 230–4
19. Novy MJ. Transabdominal cervicoisthmic cerclage: a reappraisal 25 years after its introduction. *Am J Obstet Gynecol* 1992; 164: 1635–41
20. Al-Fadhli R, Tulandi T. Laparoscopic abdominal cerclage. In *Advances in Laparoscopy and Hysteroscopy Techniques*. *Obstet Gynecol Clin North Am* 2004; 31: 497–504
21. Olatunbosun O, Turnell R, Pierson R. Transvaginal sonography and fiberoptic illumination of uterine vessels for abdominal cervicoisthmic cerclage. *Obstet Gynecol* 2003; 102: 1130–3
22. Scibetta JJ, Sanko SR, Phipps WR. Laparoscopic trans-abdominal cervicoisthmic cerclage. *Fertil Steril* 1998; 69: 161–3
23. Gallot D, Savary D, Laurichesse H, et al. Experience with three cases of laparoscopic trans-abdominal cervico-isthmic cerclage and two subsequent pregnancies. *Br J Obstet Gynaecol* 2003; 110: 696–700
24. Henricus A, Brolmann M, Swan G. The laparoscopic approach of the trans-abdominal cerclage of the uterine cervix in case of cervical incompetence. *Gynecol Endosc* 2000; 9: 191–4
25. Darwish A, Hassan Z. Feasibility of laparoscopic abdominal cerclage in the second trimester. *Gynecol Endosc* 2002; 11: 327–9
26. Ind T, Mason P. Endoscopic trans-abdominal cervical cerclage (case report). *Gynaecol Endosc* 2000; 9: 199–200
27. Mingione M, Scibetta J, Sanko S, et al. Clinical outcomes following interval laparoscopic trans-abdominal cerclage placement: case series. *Hum Reprod* 2003; 18: 1716–19
28. Cho CH, Kim TH, Kwon SH, et al. Laparoscopic transabdominal cervicoisthmic cerclage during pregnancy. *J Am Assoc Gynecol Laparosc* 2003; 10: 363–6
29. Bernardini M, Barrett J, Seaward G, Covens A. Pregnancy outcomes in patients after radical trachelectomy. *Am J Obstet Gynecol* 2003; 189: 1378–82

Part 6
Robotics: the future

akushnerlib.ru

akusher-lib.ru

Improving ergonomics in laparoscopic gynecological surgery

R Polet, J Donnez

Laparoscopic surgery has benefited greatly from technological developments in the past 20 years. Paradoxically, as patient comfort continues to increase with minimally invasive surgical procedures, the surgical comfort of the operator has somewhat decreased due to the particular working conditions of endoscopic surgery. This problem was not addressed as long as the range of indications for laparoscopic surgery was being explored.

Today, the use of cameras, self-regulated insufflators, new light sources, new trocar designs and new multifunctional instruments demonstrate the ongoing and highly desirable trend to increase the laparoscopic surgeon's comfort. As the scope of what can be done and what should not be done in laparoscopic surgery becomes more clearly defined, it is time to think about improving surgical comfort.

ERGONOMICS IN SURGERY

Ergonomics is the scientific study of people at work, with the aim of improving accuracy, productivity, training, satisfaction and safety. Its relevance to surgery seems obvious, although it has been applied less often to surgery in a formal way than to other kinds of work. Ergonomics in surgery aims to increase the surgeon's comfort within his environment. The attainment of comfort depends on physical ergonomics (surgical instrumentation and the workspace), cognitive ergonomics (how humans handle information) and organizational ('macro') ergonomics (how players in the operating room work together).

To some extent, assistance is part of the instrumentation, and raises two ergonomic issues: loss of autonomy by the operator, and dependence on a variable human parameter, subject to skill, fatigue and availability factors.

HUMAN ASSISTANCE IN LAPAROSCOPIC SURGERY

One of the constraints of laparoscopic surgery is the need to work with an assistant, experienced if possible. The assistant manages the visual operative field and helps to hold instruments. He is actually the 'eye' of the operating surgeon. Problems of cooperation between the two naturally arise, limiting concentration and restricting the eye-hand coordination of the surgeon. If the quality of assistance is suboptimal, surgery is less comfortable. In fact,

the quality of the assistant goes hand in hand with the quality of surgery.

Because the endoscope is so narrow, the view obtained through the laparoscope and transmitted to the video screen represents only part of the surgical field; loss of the global view of the operative field creates difficulties in the space orientation of the surgeon. To center the operative field, the telescope must be moved along the tissue of interest. Initially, the telescope was manipulated by the surgeon himself. However, in doing so, the surgeon sacrifices one hand to the visual control of his operation. Manipulation of the laparoscopic instruments (laparoscopic scissors, forceps, cautery, suction-irrigation cannulas, etc.), visually controlled through the telescope, is done with only one functional hand. This means that the surgeon operates endoscopically with one hand only, the other instruments being delegated to an assistant, whose quality and level of interest may be inconsistent.

An alternative that emerged to counter this flaw was to assign manipulation of the laparoscope to an assistant; in such a situation, the surgeon gains more fluency and speed in his surgery, recovering the control of two hands working in symbiosis. Unfortunately, the management of his optical field is dependent on the qualities of the assistant, whose capacity of anticipation is not always optimal; not uncommonly, the assistant is unaware of what the next step of the operation will be. As a solution, the surgeon often operates with a colleague, but, considering the loss of time and money spent on surgical assistance, this scenario is not ideal.

The ideal solution would clearly be to restore personal control of his own two hands and eyes to the surgeon, without the need for intermediaries.

LAPAROSCOPE HOLDING SYSTEMS: THE LAPMAN® PROJECT

In 1995, we launched a project to design a laparoscope holding system able to respond, in real time, to the surgeons's commands.

Static laparoscope holders (Table 37.1) exist, but are associated with a serious flaw: the impossibility to move the endoscope without putting down one of the two operative instruments held by the surgeon. The static laparoscope holder gives the most stable image on the video screen, but is unable to follow dynamically, in real time, the changes in the operative field required by the surgeon.

Table 37.1 Classification of laparoscopic artificial assistance devices*Laparoscope holders: hold the laparoscope only*

Static: the surgeon moves the laparoscope holder manually

Kronner™ (Kronner Prototypes Inc, Roseburg, OR, USA)

PASSIST

Tiska® (Karlsruhe Research Center, Karlsruhe, Germany)

Dynamic: the surgeon moves the laparoscope holder by voice, finger or head control

Aesop (Computer Motion): voice

ImagTrack™ (Olympus, Tokyo, Japan): finger

LapMan® (Medsys, Bembloux, Belgium): finger

EndoAssist™ (Armstrong, Healthcare Ltd, Wycombe, UK): head

Laparoscope holders and instrument manipulators

Zeus™ (Computer Motion, Goleta, CA, USA)

da Vinci™ (Intuitive Surgical, Sunnyvale, CA, USA)

The idea of a dynamic laparoscope holder, able to displace the endoscope along the three axes under the command of an ergonomic control unit, was therefore conceived. This laparoscope manipulator was developed in collaboration with the surgical material firm, Medsys (Gembloux, Belgium).

At the same time, an ergonomic external control unit was developed. The challenge was to find which neuromuscular function could be used to achieve the command of six degrees of freedom, corresponding to displacement in three dimensions. A foot pedal requires eye control and can be uncomfortable in the long run, as noted by Mettler *et al.*¹. Besides, the foot is already often used to command coagulation. Voice interface is an attractive idea but limited by two drawbacks: answering the order takes longer, slowing down the operation when the surgeon needs to move about a lot, and it is impossible to move obliquely.

We initially designed a remote control activated by the left fingers of the surgeon, fitting into the palm under the surgeon's glove; the left fingers were chosen because they belong to the surgically minor hand, and their function in dissection is limited to traction, retraction and irrigation, relatively trivial tasks compared with their potential. A variant in the form of a joystick box clipping onto the instrument under the index finger is now also available.

General description

The LapMan® (Figures 37.1 and 37.2) uses inexpensive technology, based on the electromechanical control of brakes regulating the displacement of a series of articulated arms, constructed to cover the three dimensions of space.

The assistant, of low bulk and mobile on motorized wheels, is composed of a rolling base and a sterile auto-clavable shaft, which comes connected to the scope through an easy-release system. The machine displaces the shaft in the three dimensions, translating the displacement of the laparoscope connected to it. A laser pointer indicates the geometric center of the assistant.

The first human-machine interface we developed – the hand control (Figure 37.3) – is a small embedded electronic circuit, molded on the palm of one of the authors, to raise the thenar eminence towards the fingers in their natural flexed position. Six knobs corresponding to the six directions are distributed on the pad, which can be disposed along two schemes according to personal preference: three rows of two knobs, using the last three fingers, or two rows of three knobs using the last two. The unit holds to the index finger under a sterile glove. Pressing a button leads to a radiofrequency emission that is recognized by the receiver of the equipment. Pressing several buttons at once, according to a defined scheme, enables set-up actions to be realized during the calibration phase, such as switching on the laser pointer, backward/forward, upward/downward movements of the whole device or placing the arm in the neutral position. This pad is auto-clavable, and the batteries allow 1 hour of uninterrupted activation.

We later developed another intuitive interface (Figure 37.4) in the form of a free, radiofrequency-emitting clipable joystick designed to be attached to the edge of the laparoscopic instrument, just under the index finger of the operator. The set-up phase on the right side of the patient is rapid; approximation of the scope holder to the umbilicus requires a 2-minute laser calibration.

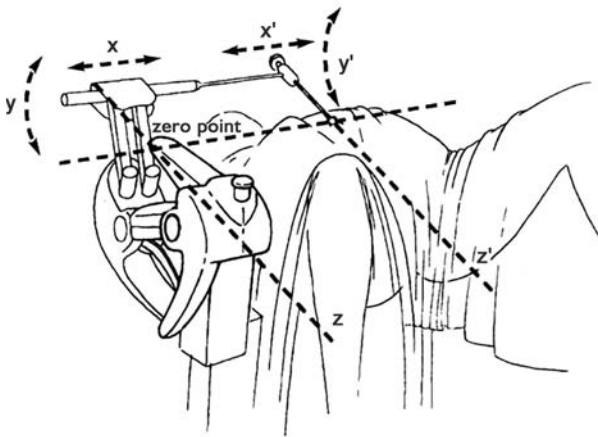


Figure 37.1 LapMan®: principle

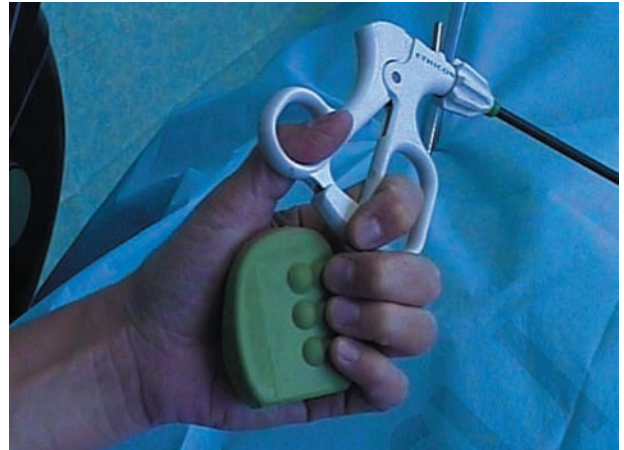

Figure 37.3 LapMan: hand control (under the glove)

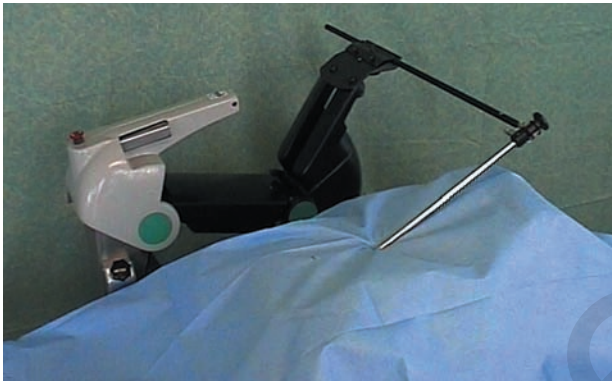

Figure 37.2 LapMan: external view

As there is a learning curve to familiarize oneself with the position of the buttons on the pad, software was developed allowing navigation in a three-dimensional pelvic environment using a palm-pad joystick, connected to the serial port of the surgeon's office PC; it is then possible to train effectively out of theater.

Advantages

This laparoscopic manipulator has several advantages. It provides the surgeon with a steady image and offers a simultaneous response to the surgeon's commands, positively influencing the fluency of the operation. Steadiness is obviously useful for suturing and helps in orientation. Besides restoring autonomy of vision, it allows work in conditions of reduced personnel; solo surgery for straight-forward cases is carried out in very comfortable conditions. Compared with other laparoscopic assistance systems, the LapMan is not cumbersome, is easy to move on its rolling base and, for these reasons, could surely be labeled 'nurse-friendly'. The electromechanical technology is simple and robust; it is also by far the cheapest of all engine-driven



Figure 37.4 LapMan: joystick clipped onto the instrument

laparoscope holders ever produced. The polyvalence of the LapMan must be emphasized, as it allows one to perform abdominal surgery by rotating the LapMan cranially and permits operation from either side of the patient. In the list of advantages, compared with other modalities, the LapMan has the essential characteristic of answering instantaneously to the surgeon's command, important on two levels: (1) it will probably function better in operative fields with a frequently moving scope; (2) it is safer, as release of the knob stops the move instantaneously.

In common with all laparoscope holders, dynamic scope holders do not cope well with the need to move frequently on the target (as the movements are sequential, not oblique). These situations are encountered in severe adhesiolysis cases, large structures (large uteri, ovarian cysts, etc.) and in operations covering two distant fields (laparoscopic promontofixation).

Indications in gynecological surgery

Considering the first version of the hand control, we initially stated that use of the LapMan was indicated in reduced personnel conditions for straightforward, uncomplicated cases of laparoscopic surgery, which in gynecology represents all adnexal surgery and small- to medium-size uterus surgery (myomectomy, laparoscopic subtotal hysterectomy (LASH), laparoscopic hysterectomy (LH)), and in digestive surgery and gallbladder and hiatal surgery.

The latest developments of the interface, which produced a more sophisticated joystick by increasing the ergonomics and intuitiveness, definitely enable the surgeon to operate on more complex pathologies in restricted personnel conditions and yield increased satisfaction from being able to reoperate bimanually with visual operative field control.

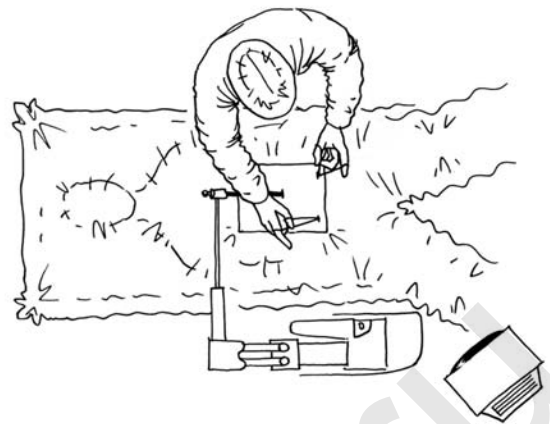The concept of solo surgery: response to lack of operating room staff (Figure 37.5)

The development of surgeon-controlled laparoscope holders has an interesting implication: it allows the surgeon to operate in restricted personnel conditions for straightforward, uncomplicated procedures. Adnexal surgery of moderate size (5–6 cm) and subtotal hysterectomy cases of (sub) normal size are ideally suited to laparoscopic solo surgery, because the target organ is mobile and the range of scope manipulation is somewhat limited. In the event of reduced personnel resources, these artificial arms render these procedures possible; solo surgery sessions can therefore be performed in emergency cases (bleeding ectopic pregnancy, acute adnexal pathology) or planned on an elective basis, grouping, for example, trans-hysteroscopic resections and simple laparoscopic surgery cases. Table 37.2 lists the procedures which may be performed in these conditions.

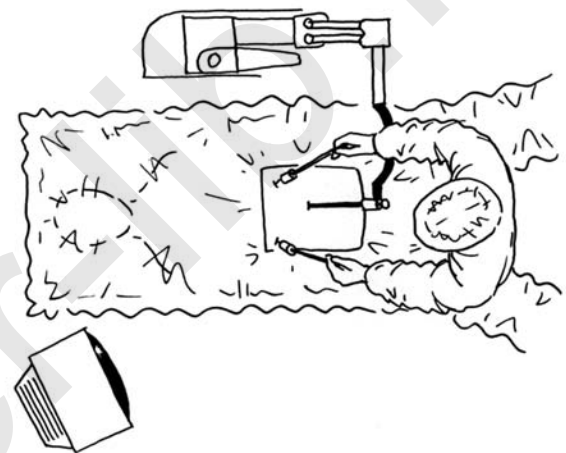
OTHER LAPAROSCOPE HOLDERS²

Passive laparoscope holders

Several laparoscope holders are available on the market today (Table 37.2). They attach to the rail side of the oper-



a



b

Figure 37.5 Solo surgery with the LapMan: (a) in gynecology, (b) in abdominal surgery

ating table. Their use depends essentially on the resistance to movement that they can provide and the facility to change position comfortably. These holders can also be used to hold instruments. The Tiska[®] endoarm^{3,4} has been widely investigated, and gives surgeons a great deal of satisfaction. Also worthy of note is the Kronner telescopic arm laparoscope holder (Figure 37.6); pressing an electronic control attached to the camera releases the joints for quick

Table 37.2 Indications for the LapMan in laparoscopic solo surgery

Adnexal surgery (ovariectomy, adnexectomy, salpingotomy, salpingectomy, ectopic pregnancy, ovarian cystectomy)
Small- to mid-size laparoscopic hysterectomy (LH, LASH)
Myomectomy (subserosal)

LH, laparoscopic hysterectomy; LASH, laparoscopic subtotal hysterectomy



Figure 37.6 Kronner laparoscope holder

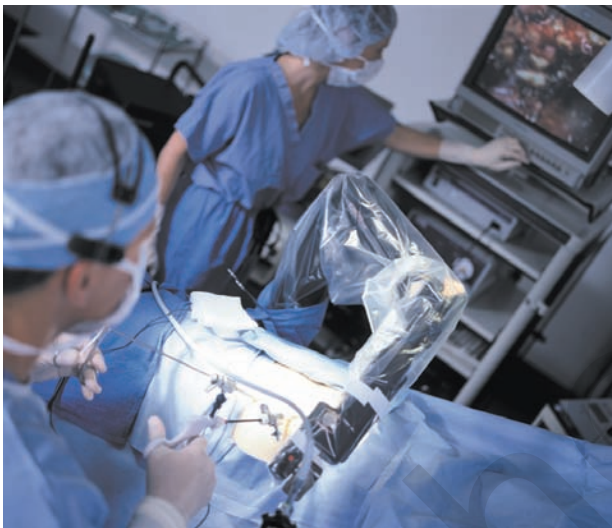

Figure 37.7 Aesop™ laparoscope holder (interface: voice)

position changes. The position is held by gas pressure available in the operating room.

Passive laparoscope holders offer image steadiness and a substitution for human assistance, when necessary.

Active laparoscope holders

To move in the operative field, passive laparoscope holders need to be moved by the surgeon's hand; this interrupts his concentration and limits eye-hand coordination. Besides providing steadiness and a substitute for human assistance, active laparoscopic holders (see Table 37.1) have been developed to offer simultaneous vision and instrument control, as is the case in classic surgery.

Active machines differ in technology, some being much more expensive than others, and the interface used for command. The ideal characteristics should take into account cost, robustness, cumbersomeness, set-up time, user-friendliness of the control unit and response time.

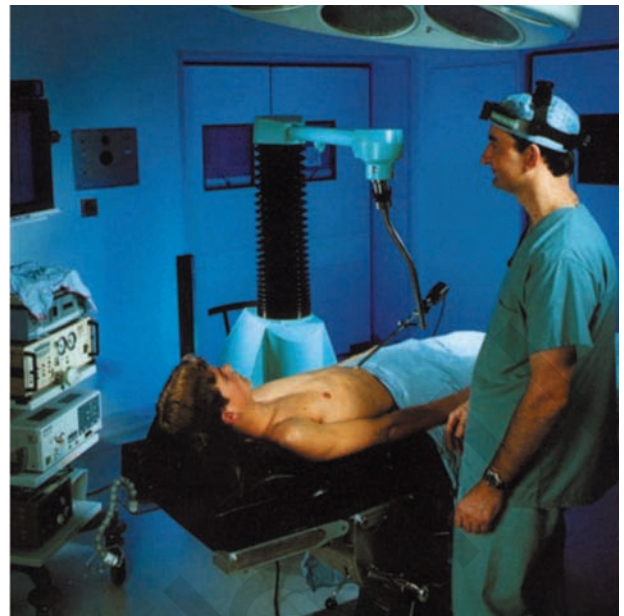


Figure 37.8 EndoAssist™ laparoscope holder (interface: head tilt)

Aesop™ 3000 (Computer Motion)

Aesop (Figure 37.7) has come up with several control units: foot, hand and voice operated. Comparative studies tend to consider voice control as being preferable to the other options^{1,4-6}. The Aesop 3000 is a voice-controlled surgical robot imitating the form and function of the human arm. By orally introducing simple spoken commands, the robotic arm moves the scope in the three dimensions of space. The response is almost instantaneous. Speech-recognition technology requires the surgeon to familiarize the system with his voice. Each order must be specifically introduced, for the machine not to become confused with background theater noise. The displacement in space is the sum of simple displacements, and obliquity is not achieved. This model was inspired by robotic technology, which makes it the most expensive in its category, although cost-effectiveness has been demonstrated⁷.

EndoAssist™ (Armstrong)

This system (Figure 37.8) holds a conventional laparoscope and camera, and moves them in accordance with the surgeon's head, which it tracks using a headband pointer. Thus, a glance at the right-hand side of the monitor causes the camera to pan in that direction. The robot only moves if the surgeon presses a foot switch, but allows different head movements at other times⁵.

FIPS

The FIPS (Figure 37.9)^{4,8} is a remote-controlled arm capable of moving a rigid endoscope with about four

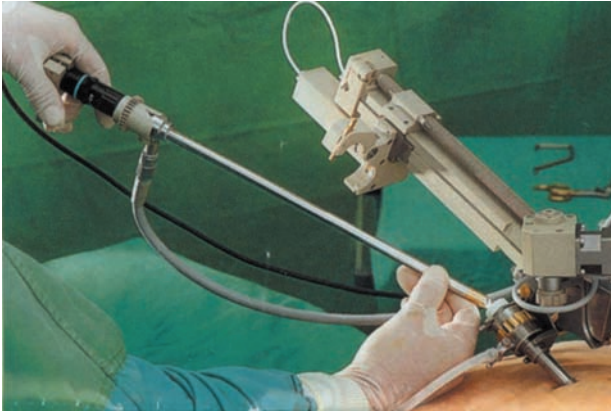


Figure 37.9 FIPS laparoscope holder (interface: voice or finger)



Figure 37.10 ImagTrack laparoscope holder (interface: finger)

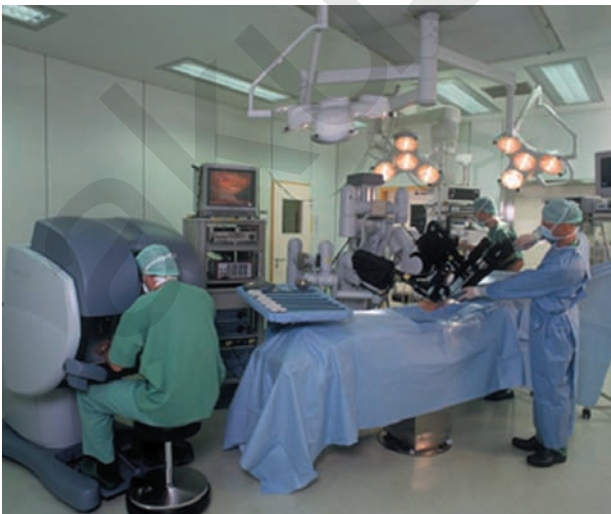

Figure 37.11 da Vinci™ robot

degrees of freedom, while maintaining an invariant point of constrained motion coincident with the trocar puncture site through the abdominal wall. The system is driven by means of speaker-independent voice control or a finger-ring joystick clipped onto the instrument shaft close to the handle. When the joystick is used, the motion of the endoscope is controlled by the fingertip of the operating surgeon, which is inserted into the small ring of the controller in such a way as to make the motion of the fingertip correspond directly to the motion of the tip of the endoscope.

ImagTrack (Olympus)

A 13-mm integrated camera/laparoscope (Figure 37.10)^{9,10} with an 80° visual field is inserted intraumbilically. Inside this immobile field (the laparoscope stands still), a mobile charge coupled device (CCD) chip is displaced in an x - y axis, under voice or fingertip control, through a unit attached to the handle of the left instrument. In/out is obtained by a zooming effect. This system has already proved its feasibility in simple laparoscopic surgery. The main advantage is rapid manipulation of the lens displacement, but the inability to approach organs physically could result in a reduced sense of depth perception. The integrated aspect of the camera/scope makes multiuse of the camera for other forms of surgical endoscopy impossible.

Others

There has been very active interest in this field, and other systems have been conceived, some still under development. A self-guided robotic camera control system (SGRCCS)¹¹ is based on color tracking. The tip of one instrument is marked with a specific color and the camera is programmed to follow this unnatural dye, moving the laparoscope holder so that the color always stays in the operative field. Blood does not significantly interfere. The inconvenience is that this instrument must always remain in the field.

INSTRUMENT MANIPULATION

With the manipulation of instruments by fully integrated robots (Figure 37.11) a new dimension is reached compared with simple laparoscope holders, and these robots will serve different purposes. This development responds to the need to refine the precision of movements, essentially microsuturing, but not the concept of solo surgery, as the set-up and change of instruments nevertheless requires the presence of an assistant at the side of the patient.

Indeed, associated with the automated scope holder, there has been extensive development in the robotic enhancement of instrument manipulation itself. The

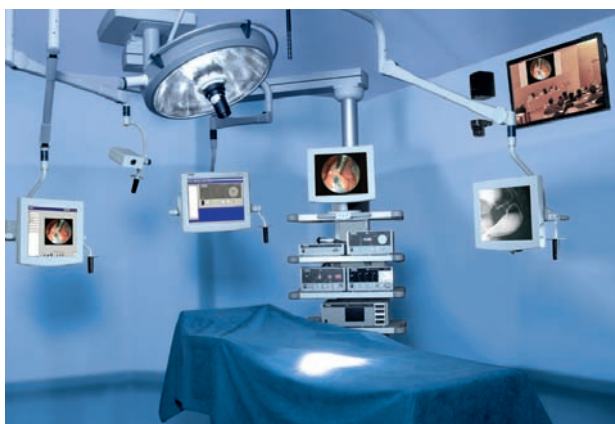

Figure 37.12 Karl Storz ORI™

instruments are supported by robotic arms and no longer by the human hand; the surgeon operates from a console at a distance from the patient, in the same or another room, in the same hospital or even from another country, through Internet connections.

A description of these fully integrated robots and their performance in the field of laparoscopic gynecological surgery is presented in Chapter 38.

FULLY INTEGRATED OPERATING ROOM

Several companies are now integrating the management of the operative laparoscopic surgery theater suite into a fully surgeon-controlled environment¹². Surgical robotic companies are adapting their robot products to this type of technology, maximizing, more than ever, the concept of surgical ergonomics. Karl Storz is among those leading the way in this integration process. The main idea behind the Karl Storz ORI™ (Figure 37.12) integration concept is a standardized communication bus (SCB). This interface forms the basis for the entire system. Endoscopic devices, such as video cameras, cold light sources, insufflators and suction and irrigation pumps, as well as the operating table, blinds and operating light, are controlled via the SCB.

An integrated digital recording system simplifies the archiving of image, video and audio data of important surgical steps and results. This information can be used for both patient documentation and scientific evaluations. Connection to the hospital information system (HIS) and picture archiving and communication system (PACS) optimizes quick access to patient and image data.

In addition, telemedicine applications, such as video conferences and live operations for teaching and training purposes, can be controlled directly from the operating area, owing to the integration of state-of-the-art audio and video technology. This also allows the 'virtual presence' of

a remotely placed expert, who would be able to provide a second opinion to an ongoing live operative procedure.

There is no doubt that working conditions in laparoscopic surgery will evolve in the future towards better comfort. It is difficult to believe that basic straightforward laparoscopic cases will always need two operators; staff shortages should not be an obstacle to performing endoscopic surgery. In this respect, future developments in the field of artificial assistance need to be followed with the greatest interest.

REFERENCES

1. Mettler L, Ibrahim M, Jonat W. One year of experience working with the aid of a robotic assistant (the voice-controlled optic holder AESOP) in gynaecological surgery. *Hum Reprod* 1998; 13: 2748–50
2. Jaspers JE, Breedveld P, Herder JL, Grimbergen CA. Camera and instrument holders and their clinical value in minimally invasive surgery. *Surg Laparosc Endosc Percutan Tech* 2004; 14: 145–52
3. Shurr MO, Arezzo A, Neisius B, et al. Trocar and instrument positioning system TISKA. An assist device for endoscopic solo surgery. *Surg Endosc* 1999; 13: 528–31
4. Arezzo A, Ulmer F, Weiss O, et al. Experimental trial on solo surgery for minimally invasive therapy. Comparison of different systems in a phantom model. *Surg Endosc* 2000; 14: 955–9
5. Yavuz Y, Ystgaard B, Skogvoll E, Marvik R. A comparative experimental study evaluating the performance of surgical robots Aesop and Endosista. *Surg Laparosc Endosc Percutan Tech* 2000; 10: 163–7
6. Mettler L. Robotics versus human golden fingers in gynaecological endoscopy. Presented at the First World Congress on Controversies in Obstetrics, Gynecology and Infertility, Prague, Czech Republic, 1999
7. Dunlop KD, Wanzer L. Is the robotic arm a cost-effective surgical tool? *AORN J* 1998; 68: 265–72
8. Buess GF, Arezzo A, Schurr MO, et al. A new remote-controlled endoscope positioning system for endoscopic solo surgery. The FIPS endoarm. *Surg Endosc* 2000; 14: 395–9
9. Niebuhr H, Born O. Image tracking system. A new technique for safe and cost-saving laparoscopic operation. *Chirurg* 2000; 71: 580–4
10. Kimura T, Umehara Y, Matsumoto S. Laparoscopic cholecystectomy performed by a single surgeon using a visual field tracking camera: early experience. *Surg Endosc* 2000; 14: 825–9
11. Omote K, Feussner H, Ungeheuer A, et al. Self-guided robotic camera control for laparoscopic surgery compared with human camera control. *Am J Surg* 1999; 177: 321–4
12. Berci G, Phillips EH, Fujita F. The operating room of the future: what, when, and why? *Surg Endosc* 2004; 18: 1–5

akusher-lib.ru

Robotically assisted gynecological surgery

T Falcone, J M Goldberg

INTRODUCTION

The evolution of operative laparoscopy has enabled the gynecologist to perform surgery using minimally invasive techniques. However, many advanced laparoscopic procedures are performed by few gynecologists in limited centers. This is especially true if the procedures require skill in laparoscopic suturing. Other reasons include the lack of depth perception with the two-dimensional view of conventional laparoscopy, and lack of tactile feedback. Precise dissection of delicate structures, such as a ureter surrounded by endometriosis, or the Fallopian tube during a tubal anastomosis, may be difficult with these limitations of conventional laparoscopic instruments. Robotic technology has attempted to address these limitations. This topic has been summarized in depth in a recent review¹.

The first two of four phases in the evolution of robotic surgery have been completed. Phase one was the development of a fully functional robot which takes into account patient safety, practicality and reliability in the operating room and cost. The second phase was the performance of feasibility studies to document that it actually functioned as needed in clinical situations. The next phases will involve conducting randomized trials to compare the same laparoscopic procedures performed with and without robotic assistance. This will determine whether the robot provides any significant advantages to offset the additional operating room time and cost of the robot itself, its consumable items and maintenance. The fourth phase involves further refinements to reduce size, add haptic feedback and additional instruments, allow programmability to automate specific tasks such as knot tying, improve the ability to perform long-distance telesurgery and incorporate the robot into augmented and virtual reality surgery.

INITIAL EXPERIENCE

The first surgical robot was the voice-controlled Aesop™ laparoscope holder, which provides a steady image while allowing the surgeon to operate with both hands. Only one degree of freedom can be activated at a time and the movements are kept slow for safety reasons, making adjustments inefficient. The development of speech algorithms, which interpret speech patterns from different individuals, made voice control possible. The use of Aesop as a laparoscope holder was assessed in gynecological surgery². The authors compared the system with a human

laparoscope holder. They found that the time required to perform the surgery was faster with the robotic holder, because it allowed two surgeons to use both hands to perform the procedure.

A comparative study of laparoscopic skills performance in the dry laboratory between the Zeus™ (Computer Motion, Goleta, CA) and da Vinci™ (Intuitive Surgical, Mountain View, CA) robotic systems and standard laparoscopy reported that basic laparoscopic task performance was faster using standard instruments, compared with either robot. The robotic systems showed an improvement in fine precision³.

All of the preliminary clinical studies comparing standard laparoscopy with robotic-assisted laparoscopy suffer from non-randomization and small sample size. The first use of the robot in gynecology was to perform a reversal of a tubal ligation^{4,5}. However, the operation times were longer with the use of the robot, compared with conventional laparoscopy⁶. Recently, several other reports in the gynecology literature have exemplified the potential use and limitation of robotics. These include hysterectomy, myomectomy, vaginal vault suspension and ovarian transposition. In the laparoscopic-assisted vaginal hysterectomy (LAVH) trial in ten patients using the da Vinci system, the mean operating time was 253 min, with blood loss between 50 and 1500 ml⁷. In the myomectomy trial, the mean operating time to perform the procedure with the da Vinci robot was 230 min⁸. In this series of 35 patients, the mean weight of the myomas was 223 g and the mean number of myomas was 1.6 (range 1–5). Three conversions to laparotomy occurred. In a case series of 20 patients who underwent sacrocolpopexy, the mean operating time was 3 h and 42 min⁹. The robot was used to suture the mesh in place and not for dissection of the vagina or presacral space. Essentially, preliminary reports have shown that robotic laparoscopic gynecological surgery is feasible, but with prolonged operating room time. Cost analysis has not been reported, but the longer operation times and use of disposable items significantly increases the cost of these procedures.

Robotic surgery should be considered as being in a transition phase. Its future lies in the ability to perform remote telesurgery and its integration with virtual and assisted reality. Telementoring, whereby an expert observes and directs surgery being performed elsewhere is already feasible and the mentor may even control the laparoscope remotely with Aesop. Telesurgery enables the surgeon to operate on a patient many miles away, thus centralizing

expert care without requiring patients to travel. The main difficulty with telesurgery has been the lack of a rapid and secure means of transmitting signals between the surgeon and the operating room, as the signal latency must be less than 330 ms to prevent perceptible delay. Anvari *et al.* recently reported performing 21 telesurgical procedures between two hospitals in Canada, 250 miles apart, using an existing commercial Internet fiberoptic network, with the goal being to provide telementoring and telesurgery between eight teaching hospitals and 32 rural communities in Canada over the next 3 years¹⁰. Ultimately, a wireless system could allow telesurgery to be performed on ships, or even in space.

SURGICAL TRAINING AND PREOPERATIVE PLANNING

Virtual reality trainers could augment operative experience by enabling physicians to practice both basic skills and actual surgical procedures of varying degrees of difficulty, as well as with variations in anatomic and pathological states. The movements and forces of the instruments can be tracked and recorded for later review by a mentor as a more efficient, less costly and safer way to educate and credential physicians.

Virtual surgical planning would involve planning, practicing and viewing the outcome of a procedure using a virtual three-dimensional (3D) model of the patient generated by preoperative imaging studies, anatomic atlases and other data, such as organ deformation with surgical manipulation. The next step would be to superimpose this model over the 3D image of the patient on a monitor or head-mounted display in the operating room, such that deep structures could be 'seen'. It may even be possible to record the movements of the instruments from the surgical planning session and program them into the robot, which could then carry out the process with greater precision.

TECHNIQUE

The procedure described is a robotically assisted reversal of a tubal ligation. The advantage of robotic access is the ability of the robot to perform precise, fine movements required for tubal surgery.

Specific equipment

The only robotic system that is still marketed for gynecological surgery is the da Vinci system. The basic robotic set-up consists of a console, a video cart and a robotic tower (Figure 38.1). The surgeon sits at a console away from the surgical field (Figure 38.2). In the da Vinci procedure, the surgeon looks into a console that has a dual lens system within the 12-mm laparoscope. The system provides true

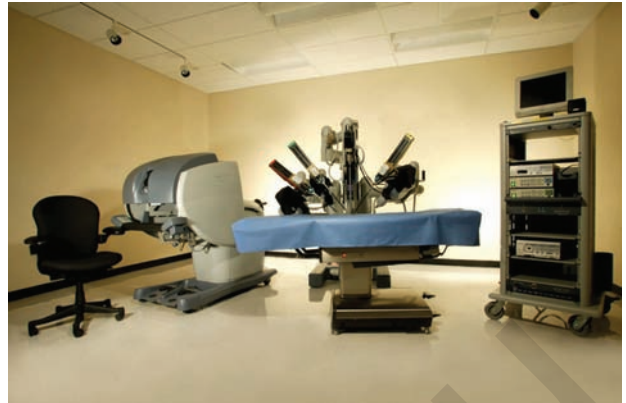

Figure 38.1 The complete robotic unit consists of a console, the robotic tower and the video cart. Courtesy of Intuitive Surgical

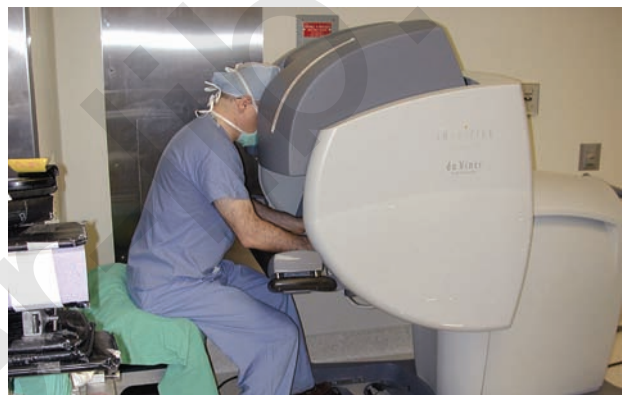

Figure 38.2 The surgeon is seated at the console to perform the surgery. Courtesy of Intuitive Surgical

binocular 3D vision that is seen with the use of a microscope. Movement of the laparoscope is accomplished through movement of the handles at the console. Movement of the handles at the console allows movement of the robotic arms at the operative site. Motion scaling, the ability to reduce the motion of the surgeon's hands at the surgical site, allows fine, delicate movements. For example, a scaling ratio of 10:1 means that for every 1 cm the surgeon moves the handles at the console, the robotic surgical instruments would move 1 mm at the surgical site. The console has infrared beams to deactivate the robotic arms when the surgeon's head is out of the console.

The console is connected by a cable to the video cart and robotic tower (Figure 38.1 and 38.3). The video cart includes the equipment to attach the laparoscope and light sources. The robotic tower supports three or four robotic arms (Figure 38.3). The robotic arms hold the specifically designed instruments that perform the surgery. The instruments have an intra-abdominal articulation 2 cm from the tip. This articulation serves the same function as a human wrist (Figure 38.4). The movement of the instrument tip is intuitive and requires minimal training.

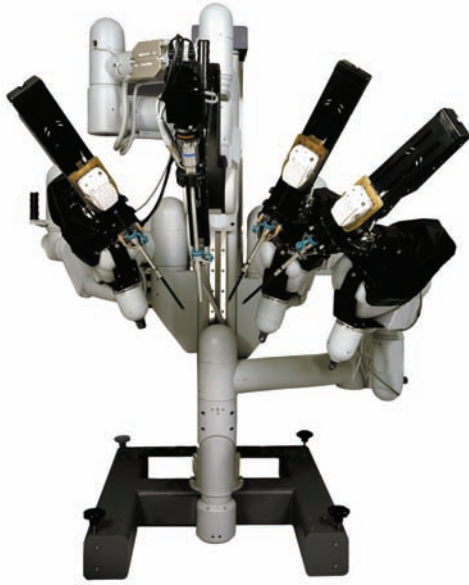

Figure 38.3 The robotic tower has three or four arms that hold instruments or the laparoscope. Courtesy of Intuitive Surgical



Figure 38.4 The special feature of the robotic arm is the ability for seven degrees of freedom at the effector tip. Courtesy of Intuitive Surgical

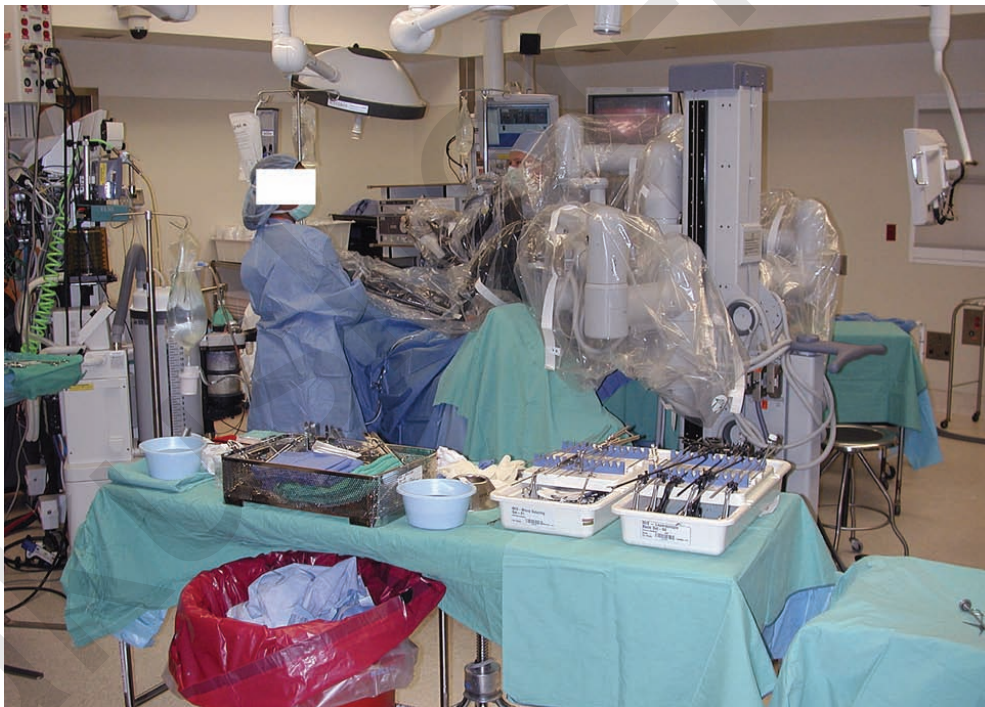

Figure 38.5 Typical operating room set-up of the robot. The tower is placed between the patient's legs and the robotic arms are attached to the instruments in the lateral ports

There are several disadvantages of the surgical robot that warrant mention. Weighing 1200 lb, the da Vinci robot is large and very cumbersome. The operating table cannot be repositioned once the robot is in place. The surgical assistant's access to ancillary ports and the uterine manip-

ulator are severely compromised (Figure 38.5). There is no haptic feedback, and therefore the surgeon will need to use visual cues to assess the limit to which a tissue or suture can be pulled. During initial experience, sutures can be broken, adding to operating time. Port placement for the

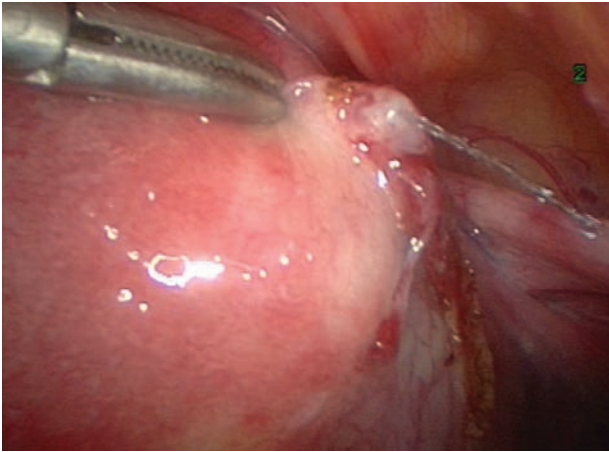


Figure 38.6 The proximal anastomosis site has been prepared and patency is demonstrated

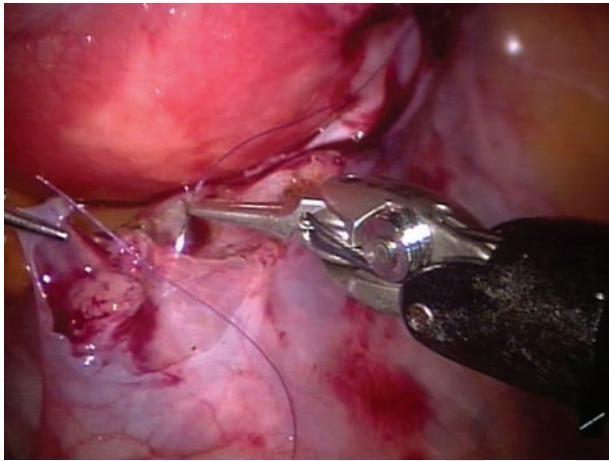


Figure 38.7 The robotic arm is about to drive the needle into the distal mesosalpinx. This is the first stitch

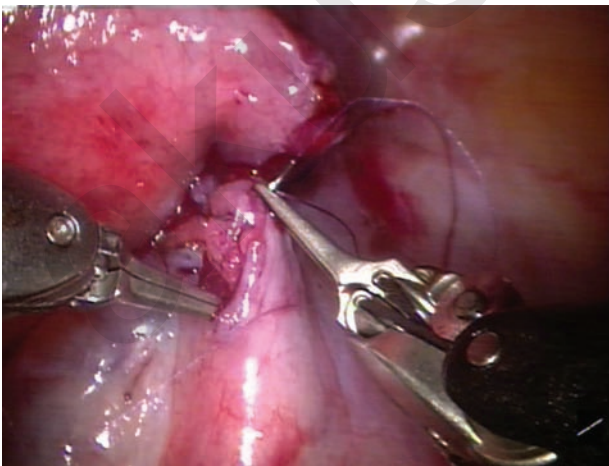


Figure 38.8 The first 8-0 suture has been placed through the muscularis and through the mucosa of the distal anastomosis site. The needle tip is seen through the lumen. The subsequent stitch will be through the proximal site

robotic arms is necessarily higher on the abdomen and is less cosmetic. Experience is required to place these ports for the robotic arms properly so that access to different areas of the pelvis is possible. If for some reason, the surgeon needs to convert to conventional laparoscopy the robotic port sites may not be useful.

Procedure

For a tubal reversal procedure, a four-puncture technique is utilized. The patient is placed in the lithotomy position. A 12-mm trocar is required at the umbilicus for the laparoscope. Two specially designed 8-mm trocars are placed in the right and left lateral abdominal areas. These sites are typically lateral to the rectus muscle and 3–4 cm below the level of the umbilicus. These trocars attach directly to the arms that come off the robotic cart. A fourth 5-mm trocar that serves as an accessory port is placed just suprapubically. This allows introduction of the fine 6-0 and 8-0 suture into the peritoneal cavity with minimal movement of the panoramic view of the laparoscope. Once peritoneal access is gained with all four trocars, the patient is placed in steep Trendelenburg position. The robotic cart is placed between the legs and the robotic arms are attached to the instruments in the lateral ports (Figure 38.5).

The proximal and distal anastomosis sites are prepared. Microscissors and cautery are available on the robot, or this can be accomplished conventionally before attaching the robot (Figure 38.6). The next step is to approximate the mesosalpinx using a Vicryl® 6-0 suture (Figure 38.7). Once the proximal and distal site are closely aligned, Vicryl 8-0 is used for the classical two-layered closure. The first layer is the mucosal–muscularis layer and the second is the serosal layer. Three to four interrupted stitches are used for each layer. The first is placed at 6 o'clock, so as to tie the knot outside the lumen (Figure 38.8). The next step is to place the 12 o'clock stitch. Typically it is not tied, to allow continued visibility of the lumen. The individual stitches are tied using the standard 'instrument' tie technique (Figure 38.9). A few final serosal stitches are placed (Figure 38.10), and patency of the anastomosis is confirmed by visualizing spill of transcervically injected indigo carmine dye through the fimbriated end of the tube.

CONCLUSION

The da Vinci system can enable the less experienced laparoscopic surgeon to operate on more advanced cases. In situations where fine motor skills are required, such as tubal reversal, there may be an immediate role. Randomized studies looking at short- and long-term outcome data are required to assess the current role of the surgical robot.

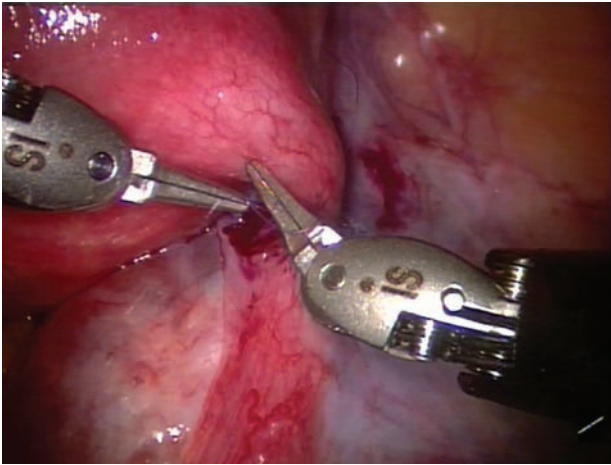


Figure 38.9 The left robotic needle holder is about to circle around the right needle holder to tie the stitch

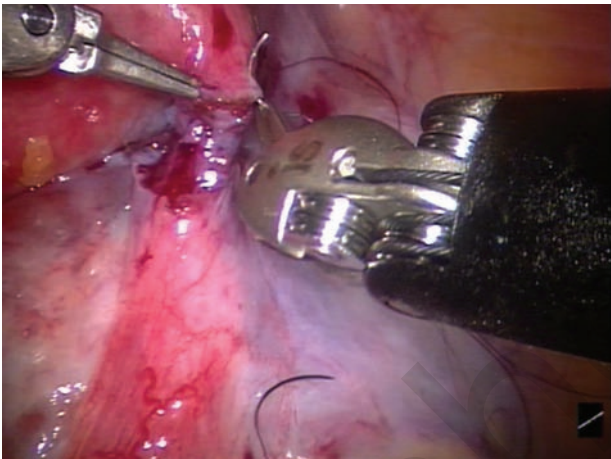


Figure 38.10 This image shows the capability of the robot to place easily the stitch in a reverse direction

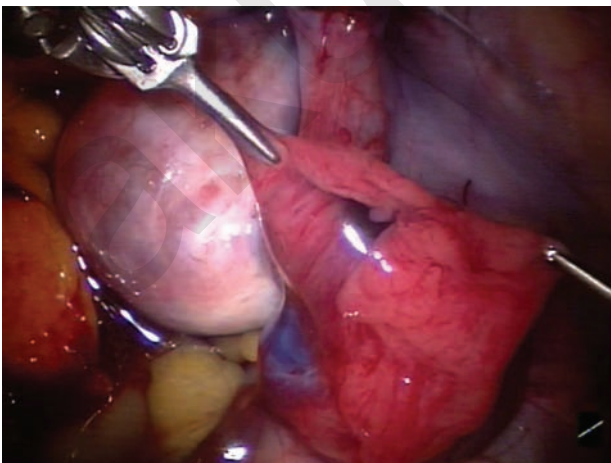


Figure 38.11 The completed anastomosis shows spill of indigo carmine dye through the fimbriated end of the tube

REFERENCES

1. Dharia SP, Falcone T. Robotics in reproductive medicine. *Fertil Steril* 2005; 84: 1–12
2. Mettler L, Ibrahim M, Jonat W. One year of experience working with the aid of a robotic assistant (the voice-controlled optic holder AESOP) in gynecologic endoscopic surgery. *Hum Reprod* 1998; 13: 2748–50
3. Dakin GF, Gagner M. Comparison of laparoscopic skills performance between standard instruments and two surgical robotic systems. *Surg Endosc* 2003; 17: 574–9
4. Falcone T, Goldberg JM, Margossian H, Stevens L. Robotically assisted laparoscopic microsurgical anastomosis: a human pilot study. *Fertil Steril* 2000; 73: 1040–2
5. Degueldre M, Vandromme J, Huong PT, Cadiere GB. Robotically assisted laparoscopic microsurgical tubal reanastomosis: a feasibility study. *Fertil Steril* 2000; 74: 1020–3
6. Goldberg JM, Falcone T. Laparoscopic microsurgical tubal anastomosis with and without robotic assistance. *Hum Reprod* 2003; 18: 145–7
7. Diaz-Arrastia C, Jurnalov C, Gomez G, Townsend C Jr. Laparoscopic hysterectomy using a computer-enhanced surgical robot. *Surg Endosc* 2002; 16: 1271–3
8. Advincula AP, Song A, Burke W, Reynolds RK. Preliminary experience with robot-assisted laparoscopic myomectomy. *J Am Assoc Gynecol Laparosc* 2004; 11: 511–18
9. Elliott DS, Frank I, Dimarco DS, Chow GK. Gynecologic use of robotically assisted laparoscopy: sacrocolpopexy for the treatment of high-grade vaginal vault prolapse. *Am J Surg* 2004; 188 (Suppl 4A): 52–6S
10. Anvari M, McKinley C, Stein H. Establishment of the world's first telerobotic remote surgical service: for provision of advanced laparoscopic surgery in a rural community. *Ann Surg* 2005; 241: 460–4

akusher-lib.ru

Part 7
Complications

akusherlib.ru

akusher-lib.ru

Complications of laparoscopic surgery in gynecology

P Jadoul, J Donnez

INTRODUCTION

Over the past 20 years, laparoscopy has developed into a major tool in gynecological surgery. Initially used as a diagnostic procedure in female infertility and for tubal sterilization, it now allows one to perform almost any surgery previously performed by laparotomy (including tubal and ovarian surgery, hysterectomy and lymphadenectomy). Its advantages over laparotomy have been well documented (e.g. reduced postoperative pain, smaller surgical scars, shorter hospital stay, reduced costs). However, even if laparoscopy is a relatively safe procedure, complications do occur.

The multitude of indications, the increasing number of surgeons using endoscopy, the introduction of new instruments (forceps, trocars, electrocoagulation, lasers) and the growing number of major laparoscopic surgical procedures have given rise to new types of complications.

Larger reviews of laparoscopic complications reveal an overall complication rate of approximately 4/1000. A retrospective analysis of 32 205 laparoscopies in Finland between 1995 and 1996 showed a total complication rate of 4 per 1000: 0.6 per 1000 for diagnostic laparoscopy, 0.5 per 1000 for tubal sterilization and 12.6 per 1000 for operative surgery (treatment of endometriosis, ectopic pregnancy, adhesiolysis, ovarian cysts, myomectomy and hysterectomy)¹. Data files from the National Patient Insurance Association and the Finnish Hospital Discharge Register were used. Seventy-five per cent (88 of 118) of major complications in operative laparoscopy occurred during hysterectomy. All major complications during operative laparoscopies increased, from 0 per 1000 in 1990 to 14 per 1000 in 1996, but this increase could be attributed in part to the growing proportion of laparoscopic hysterectomies. The authors also mentioned that complications were more frequently encountered in local rather than university hospitals.

In a retrospective study of complications occurring during 29 966 laparoscopies in seven top French centers for laparoscopy, Chapron *et al.*² reported a complication rate of 4.64/1000 (1.84/1000 for diagnostic surgery, 0.84/1000 for minor surgery, 4.3/1000 for major surgery and 17.45/1000 for advanced surgery)². However, the operative procedures were performed by top gynecological surgeons, and so the results cannot be generalized. The mortality rate observed in this study was 3.33 per 100 000 laparoscopies. Furthermore, one in three complications

occurred while setting up for laparoscopy, and one in four was not diagnosed during the operation.

Increased experience in laparoscopic surgery has had three consequences: a statistically significant drop in the number of bowel injuries ($p=0.0003$), a significant decrease in the rate of complications requiring laparotomy for those laparoscopic surgical procedures that are well defined and a change in the way complications are treated, with a significant increase in the proportion of incidents treated by laparoscopy. In a nationwide, prospective, multicenter, observational study of 25 764 laparoscopies in The Netherlands, where data were registered from 1 January to 31 December 1994 by 72 hospitals, the overall complication rate reached 5.7/1000, again correlated to the difficulty of the procedure³. The complication rates were 2.7/1000, 4.5/1000 and 17.9/1000 for diagnostic, sterilization and operative laparoscopies, respectively. In 57% of cases, the complication was caused by the surgical approach, while in the other 43%, the technique was at fault. The most frequently observed complications were hemorrhage of the epigastric vein and intestinal injuries.

In these three analyses, the majority of complications occurred during hysterectomy.

What then are the risk factors for complications during laparoscopy?

Several publications⁴⁻⁶ have analyzed risk factors for complications. Older age, malignancy, previous radiation therapy, body mass index greater than 30 kg/m², presence of adhesions and previous abdominal surgery were all identified as significant risk factors for complications and/or conversion to laparotomy. Surgical experience was also found to be a major factor influencing the risk of complications^{4,7}. Wattiez *et al.*⁷ compared complication rates during total laparoscopic hysterectomy performed in the periods 1989–1995 and 1996–1999. A substantial drop in the major complication rate was noted, from 5.6 to 1.3% (Table 39.1). This decrease in major complications occurred despite a significant increase in median uterine weight (179.5–292.0 g) and a reduction in the operating time (115 min vs. 90 min), highlighting the importance of the surgeon's experience.

It could explain why, in a recent paper from the UK, laparoscopic hysterectomy was found to be associated with a higher rate of major complications than was vaginal hysterectomy.

In this chapter, the technical and general surgical aspects of laparoscopic complications, their management and recommendations for prevention are described.

Table 39.1 Complications of laparoscopic hysterectomy. Values are expressed as *n* (%). From reference 7, with permission

Complication	1989–1995 (<i>n</i> = 695)	1996–1999 (<i>n</i> = 952)
Excessive hemorrhage	13 (1.9)	1 (0.1)*
Blood transfusion	15 (2.2)	1 (0.1)*
Major vessel injury	0	0
Urinary tract injury	16 (2.3)	9 (0.9)*
Bladder laceration	11 (1.6)	6 (0.6)
Ureteral injury	4 (0.6)	2 (0.2)
Vesicovaginal fistula	1 (0.1)	1 (0.1)
Bowel injury	1 (0.1)	0
Bowel obstruction	1 (0.1)	0
Neurological injury	4 (0.6)	0
Thromboembolism	2 (0.3)	2 (0.2)
Reoperation	9 (1.3)	3 (0.3)*
Laparotomy	6	0
Laparoscopy	3	3

**p* < 0.005

Each laparoscopic procedure may be divided into two steps:

- The first step or 'blind step' includes induction of the pneumoperitoneum and installation of the laparoscope
- The second step or 'visual step' includes installation of the operating trocars and surgical procedures

COMPLICATIONS OF THE FIRST STEP

Subcutaneous emphysema

Subcutaneous emphysema is reported to occur during laparoscopy at a rate between 0.4 and 2.3%^{8–10}. This phenomenon results from improper positioning of the insufflation needle. The introduction of CO₂ into the preperitoneal space provokes its dissection up along the anterior chest wall, neck and face.

Diagnosis The diagnosis is made by palpation of CO₂ bubbles under the skin.

Management After introduction of the laparoscope, the suprapubic trocar must be inserted into the preperitoneal space, with the valve in the open position. The operator must then press the skin with his hands to push the CO₂ out of the preperitoneal space.

Prevention This is not a major complication, but distension of the preperitoneal space could involve the area of

operation and thus make exposure of organs more difficult. Furthermore, this iatrogenic emphysema may cause and/or increase postoperative pain and extend recovery time. Preventing this complication is easy, if the technique of introducing the insufflation needle and the limits of the insufflating pressure are respected.

Tests based on negative intra-abdominal pressure may be helpful to avoid this occurrence in cases of difficulty inducing the pneumoperitoneum.

Besides preperitoneal insufflation, other risk factors for subcutaneous emphysema have been reported⁶, such as operating time greater than 200 minutes and the use of six or more surgical ports. For some authors, direct trocar insertion is associated with a lower risk of subcutaneous edema¹¹.

Vascular injury

We must distinguish 'major vascular injury' from 'minor vascular injury'. Major vascular injuries include lesions to the principal vessels, arteries and veins. Perforations to the aorta, vena cava, common right and left iliac arteries and veins, and superior mesenteric and inferior epigastric vessels have all been reported.

Major vascular injury

In the Finnish study of 32 205 laparoscopies¹, four major vascular injuries occurred (0.12/1000), one to the aorta and three to the iliac vessels. Injuries were caused by a trocar in two patients, electrocoagulation in one and

laparoscopic scissors in one. All injuries were treated by laparotomy without any further complications. Eight hemorrhages of smaller vessels (epigastric, mesenteric, uterine) were also described (0.25/1000).

In 1997, Hulka *et al.*¹² published a review of 14911 laparoscopic hysterectomies and noted a major vascular injury rate of 1/1000. Most of these complications were linked to the insertion of the Verres needle, but one fatal aortic injury was sustained at the time of skin incision. Furthermore, in this study, most vessel injuries occurred with the use of large (>10 mm) disposable pyramidal trocars.

In a review of 408 trocar-related major vascular injuries reported to the Food and Drug Administration (FDA) by the medical device industry between 1993 and the end of 1996, 26 deaths were noted, thus representing a mortality rate of 6.37% for vascular laparoscopic injuries¹³.

A more recent report found a total of four deaths resulting from 37 major vascular injuries to the aorta, vena cava and iliac vessels, giving a mortality rate of 10.81%¹⁴.

In our series, we observed two cases of major vascular injury, both to the vena cava. The lesions occurred at the time of Verres needle insertion. Diagnosis was made when the laparoscope was installed. A retroperitoneal hematoma was observed (Figure 39.1). Because it was a venous lesion, management was expectant. There was no drop in blood pressure. Complete healing of the injury was achieved after spontaneous hematoma resorption.

Diagnosis A vascular injury is suspected in the presence of one of these signs:

- Return of blood from the open insufflation needle
- Sudden deterioration in blood pressure of a previously stable patient after needle or trocar insertion, especially if the positioning of the needle was difficult

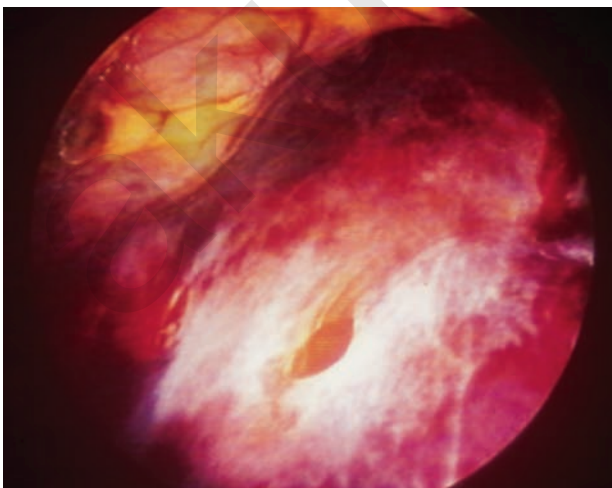


Figure 39.1 Retroperitoneal hematoma due to vena cava injury with the Verres needle

- The presence of an unexplained volume of blood in the peritoneal cavity, and if this blood reappears after aspiration¹⁵
- Dark color and increase in volume of the retroperitoneal space

In over half of the cases reported in the literature^{16–18} the diagnosis was made immediately, and a laparotomy was performed. In one case, injury to the left common iliac artery and vein was recognized 3 hours after the end of laparoscopic surgery. In other cases, the diagnosis was significantly delayed (6–21 days), and one patient¹⁹ was found to have a 3-month-old laparoscopic lesion and was treated on suspicion of a ruptured aortic aneurysm.

Intraperitoneal CO₂ pressure on the bleeding vessels and decreased venous return caused by the steep Trendelenburg position may explain the failure to recognize the injury during the laparoscopy itself. These factors can sometimes delay the diagnosis of venous injuries²⁰.

Management If vascular injury with the insufflation needle is strongly suspected, the needle is left in place to help mark the site of injury while an expeditious midline incision is made for laparotomy. Trocar injury to the major vessels is more serious, and the measures described above must be applied forthwith. Usually, in a case of major vessel injury, the retroperitoneal hematoma occupies all the fields of view, and, once laparotomy is performed, the first priority is compression of the aorta. This can be accomplished with the hand or a vascular clamp, and may reduce bleeding until a vascular surgeon arrives. If vascular injury is not ascertained and the blood pressure is stable, the insufflation needle is left in place and the pneumoperitoneum can be achieved by other means. A 5-mm laparoscope is introduced through a suprapubic trocar.

If bleeding is very minimal, endoscopic repair should be considered for small vessels, but laparotomy is necessary for major vessel injury. In the case of delayed symptoms, a computed tomograph and/or magnetic resonance image are helpful for diagnosis, and management is decided upon in collaboration with a vascular surgeon. Sometimes, in the case of small venous injuries (insertion of the Verres needle, for example), expectant management with spontaneous blood resorption can be attempted, as in our two patients presenting with a vena cava hematoma after Verres needle insertion. If the injury is an arterial lesion, operative treatment is indicated, because spontaneous healing of an active bleeding artery is almost impossible.

Prevention Success in preventing such an injury depends on the surgeon's experience, knowledge of anatomy and understanding of the procedure. Indeed, there are numerous important points to consider.

Thin patients have the highest risk of vascular injury; the aorta may lie less than 3 cm below the skin in these women. The introduction of an insufflation needle or

trocars must be done with due consideration of this anatomy.

The position of the tip of the needle must be checked before any mobilization. Many tests have been proposed for this, and all of them depend on the principle of negative abdominal pressure. In a case of malpositioning of the insufflation needle, it must be removed and the pneumoperitoneum re-established. Manipulation of the needle in an attempt to position it correctly intra-abdominally exposes the patient to a high risk of vascular injury. If blood returns from the open insufflation needle, the needle must be left in place without any manipulation, because this may induce wide laceration to the vascular wall.

Elevation of the abdominal wall is recommended prior to needle insertion. This will increase the distance over which the needle must travel to reach the major vessels²¹. This must be done manually; attempts to elevate the abdominal wall with towel clips merely give the illusion of safety. They elevate the skin or subcutaneous space only, and do nothing to the peritoneum²². It is important to ensure that an adequate pneumoperitoneum is created, prior to inserting the trocar.

Both blunt trocars and disposable sharp trocars have been implicated in major vessel trauma^{23,24}. The use of blunt needles and trocars increases the risk of vascular injury, because blunt instruments need increased force for insertion and this may cause the trocar to slip²⁵.

Disposable sharp trocars can also provoke vascular injuries, because the introduction of this type of trocar does not need much pressure. For a surgeon who normally works with non-disposable trocars, it can be dangerous to introduce such a sharp instrument into the abdomen. In the 1995 survey by the American Association of Gynecologic Laparoscopists¹², the vast majority of vessel injuries occurred with disposable trocars. In another study²⁶, disposable trocars were associated with a higher, but not statistically significant, complication rate. Furthermore, disposable trocars were not cost-effective. Therefore, for the authors, the more expensive disposable trocars were not to be recommended. Clearly, sharp instruments and safety shields do not preclude significant injury to large vessels. Indeed, the FDA requested manufacturers and distributors of shielded trocars to withdraw claims of increased safety, because they gave the surgeon a false sense of security.

Introducing the laparoscope trocar without creating a pneumoperitoneum has been attempted by some authors²⁷⁻³¹, who have not reported any vascular injuries in more than 10 000 laparoscopies. According to Nezhat *et al.*³², direct trocar insertion reduces the risk of omental injuries and subcutaneous emphysema. We do not have any experience of this technique, but it should be taken into consideration in difficult cases.

Minor vascular injury

Essentially, this involves injury to the omentum or presacral vessels. In most cases, it is unlikely that this injury will induce acute shock, and management depends on the experience of the surgeon.

Diagnosis Minor vascular injury is suspected when blood returns from the open insufflation needle, or when blood is present in the peritoneal cavity. In both cases, the blood pressure remains stable, without shock. In the first case, the diagnosis can be made by visualization of the bleeding using a 5-mm suprapubic laparoscope introduced after creating a pneumoperitoneum in another site with another insufflation needle. In the second case, the bleeding is visualized when the laparoscope is introduced.

Management Usually, the bleeding is controlled by bipolar coagulation or with laparoscopic suture. It is rare for this type of bleeding to necessitate a laparotomy.

Prevention The same preventive measures as for major vascular injury apply for minor vascular injury.

Gastrointestinal injury

In a recent review by van de Voort *et al.*³³, the incidence of laparoscopy-induced gastrointestinal injury was found to be 0.13% (430/329 935) and of bowel perforation, 0.22% (66/29 532). The small intestine was the most frequently injured organ (55.8%), followed by the large intestine (39.6%). In at least 66.8% of bowel injuries, the diagnosis was made during the laparoscopy itself or within the next 24 hours. A trocar or Verres needle caused the most bowel injuries (41.8%), followed by a coagulator or laser (25.6%). In 68.9% of cases of bowel injury, adhesions or a previous laparotomy were noted. Management was mainly by laparotomy (78.6%). The mortality rate associated with laparoscopy-induced bowel injury was 3.6%.

Stomach injury

Gastric perforation with the insufflation needle or trocar is a rare occurrence. Its incidence was evaluated at 0.027% by Loffer and Pent³⁴. In the literature, more than 30 cases have been reported³⁵⁻³⁷.

Chapron *et al.*³⁸ investigated 56 patients with 62 gastrointestinal injuries from the SFEG (French Society of Gynecological Endoscopy) complications register. Just one of the 62 injuries involved the stomach (1.6%). Furthermore, in this study, one-third of the complications (32.2%) occurred during the installation phase of laparoscopy, and 10.7% of all gastrointestinal injuries were provoked by the pneumoperitoneum needle.

In our series, two cases of stomach perforation occurred during the installation phase. The first was caused by the Verres needle. Diagnosis was made at the moment of introduction of the laparoscope, when the lesion was

visualized during routine control of the abdominal cavity. No further treatment was necessary because the lesion healed spontaneously. In the second case, a 5-mm trocar was inserted into the upper left quadrant, as adhesions were suspected in the umbilical region. After introducing the telescope (4 mm), the stomach mucosa was visualized. The telescope was gently removed from the stomach, and only a small red area without any obvious perforation was noted on the surface of the stomach. The patient was treated for 5 days with prophylactic antibiotics and a stomach sound. No suture was required. The recovery was uneventful.

Diagnosis The main sign of gastric perforation by the insufflation needle is the occurrence of bouts of eructation. Perforation with the trocar is diagnosed by visualization of the gastric mucosa.

Management In a case of gastric perforation with the insufflation needle without any tearing, no further therapy is needed because its small diameter leaves no defect. In all other cases of such injury, suture of the stomach by laparotomy or laparoscopy must normally be performed. The patient in our series who presented with a stomach injury caused by a 5-mm trocar was treated by medical therapy with broad-spectrum antibiotics and a nasogastric sound for 5 days. Food and fluids were forbidden during this time, and recovery was normal.

Prevention The most common conditions leading to gastric injury are distortion of the abdominal anatomy by previous surgery, difficult induction of anesthesia^{34,36,39} and acrophagia³⁵.

In the presence of one of these conditions, some precautions are mandatory:

- Inserting a nasogastric or oropharyngeal tube after the induction of anesthesia
- Placing the patient in a 15° Trendelenburg position prior to insertion of the insufflation needle

- Lifting the abdominal wall and respecting an angle of 45° with the skin upon needle insertion
- Ensuring that an adequate pneumoperitoneum is created to prevent injury to the stomach at the time of trocar insertion

Stomach aspiration by insertion of a nasogastric sound or tube should be performed systematically after the induction of anesthesia but before the insertion of any laparoscopic instruments. This technique is routinely applied by our anesthetists for every procedure performed in our operating theater.

Bowel injury

Inadvertent traumatic perforation of the bowel is a widely recognized potential complication of laparoscopy. This complication has been reported to occur at a rate of 0.06–0.30%^{38,40,41}. Insertion of the insufflation needle and the initial trocar into the peritoneal cavity is the most common cause of bowel perforation^{42,43}.

Indeed, in our series, two cases of small-bowel perforation were observed. The first occurred when introducing the Verres needle. The diagnosis was made immediately, because the gas pressure was not correct and a foul smell was detected. The needle was left in place and a 4-mm telescope was introduced into the upper left quadrant, which confirmed the small-bowel perforation. To treat this complication, the umbilical incision was enlarged (minilaparotomy) and the bowel lesion was sutured.

The second case involved complete perforation of the small bowel by the 10-mm umbilical trocar (Figure 39.2).

Careful inspection of the abdominal cavity led to a suspicion of bowel adhesions close to the umbilical trocar. The diagnosis was made by introducing a 5-mm hysteroscope into the 5.5-mm suprapubic trocar. The umbilical trocar was slowly retrieved with the laparoscope

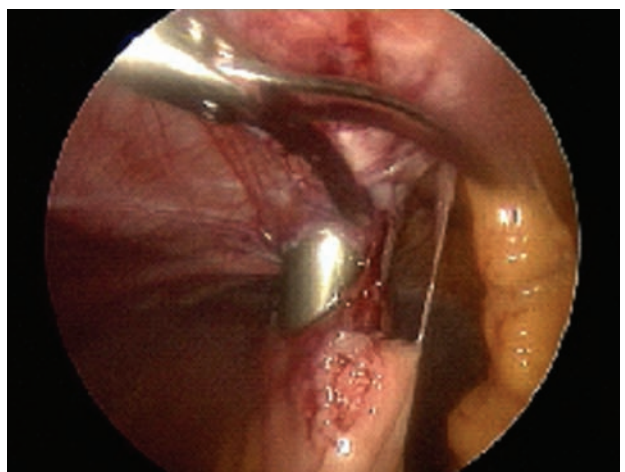
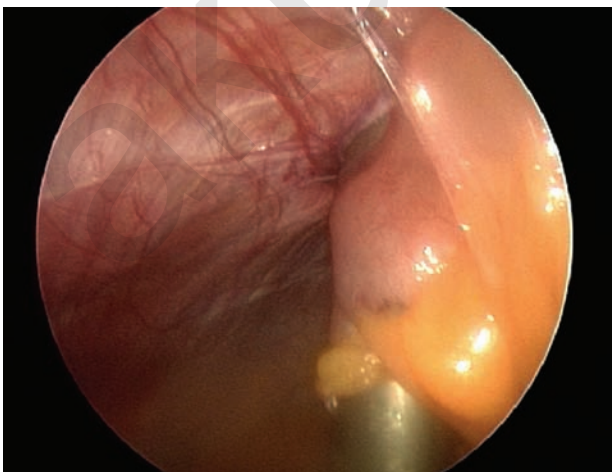


Figure 39.2 Perforation of the small bowel by 10-mm trocar

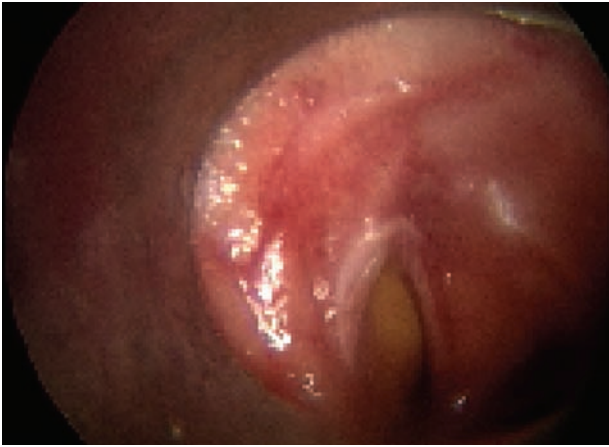


Figure 39.3 Bowel mucosa seen when retrieving the laparoscope and umbilical trocar

in place, and the bowel mucosa could be visualized (Figure 39.3).

A minilaparotomy was performed, with the removal of 10 cm of small intestine and immediate end-to-end anastomosis.

After several days of observation in hospital with broad-spectrum antibiotic cover, the patients were discharged and a normal recovery ensued.

Diagnosis Injuries to the bowel can be treacherous, because they may not be recognized at the time of surgery. Diagnosis is made immediately in the presence of stools on the tip of the needle or trocar, if fecal material is seen in the abdominal cavity, if the surgeon notices a foul smell when introducing the laparoscope, if a hematoma is noted on the bowel serosa or if the laparoscope is introduced into the lumen of the intestine. In a review by Chapron *et al.*³⁸, the diagnosis of gastrointestinal injuries was made during surgery in only 35.7% of cases, and the mean time before diagnosis was 4 days (range 0–23). In the case of delayed diagnosis, especially with through-and-through perforation of the bowel, signs of peritonitis may be present postoperatively and the diagnosis is confirmed by laparotomy. A through-and-through injury to a loop of bowel may only be detected at the time of surgery by removing the laparoscope under direct visualization to catch a glimpse of the bowel lumen.

Management The treatment of bowel injury depends on its etiology. Perforation with the insufflation needle without any laceration to the intestinal wall does not require surgical repair, and a medical approach with broad-spectrum antibiotics may be sufficient. In the case of trocar perforation or wide laceration, surgical repair is mandatory, and the method of repair depends on the instruments available and the proficiency of the laparoscopist. Laparotomy with suture repair is probably the preferred treatment for most laparoscopists. However, laparoscopic repair is possible, providing that the injury is not extensive

and stool contamination of the abdominal cavity is limited. In a case of delayed diagnosis with fecal peritonitis, laparotomy is indicated.

Prevention Certain predisposing factors, such as a dilated gastrointestinal tract or an atypical anatomic laceration secondary to adhesions, may increase the risk of bowel injury. Care must be taken in patients who have undergone previous laparotomy, in those with confirmed or suspected adhesions and when using blunt instruments. The trocar insertion technique should be standardized; with the patient in a completely horizontal position, an angle of 45° with the skin must be respected when introducing the trocar. Premature Trendelenburg positioning does nothing to avoid bowel injury. Exploration of the anterior abdominal wall with a syringe and needle to check for the presence of bowel adhesions is a helpful test in patients with previous laparotomy. After the pneumoperitoneum has been established, a 10-ml syringe containing 3 ml of normal saline is connected to a short 18-gauge spinal needle, which is inserted through the umbilicus. If there is adequate peritoneal space to accommodate the trocar, gas bubbles will appear in the saline. The limits of the potential space can be further defined by gradually advancing the needle. In patients suspected of having subumbilical bowel adhesions, which might lead to injury even with Hasson's⁴⁴ 'open' technique, Soderstrom⁴⁵ insufflates with the Verres needle placed in the upper left quadrant. After insufflation is accomplished, a 5-mm trocar sleeve is inserted, again in the upper left quadrant. Through this trocar sleeve, a 4.5-mm telescope is inserted to view the subumbilical area before placing the laparoscope trocar under direct vision⁴⁶. This technique is also used in our department when we suspect subumbilical adhesions. Much attention has been directed toward the disposable trocar, because of its sharp tip and spring-loaded safety shield⁴⁷. Nevertheless, there have been no large-scale clinical trials to establish the advantage of single-use trocars²⁵.

Urinary tract injury

Inadvertent urinary tract injury can also occur as a result of instrument insertion. Injury to the bladder is rare. The incidence is not well known, and ranges from 0.01 to 0.06% in large studies. In a review of the literature (from 1970 to 1996), the incidence of bladder injury during laparoscopic procedures ranged from 0.02 to 8.3%, depending on the type of institution and the surgeon's experience⁴⁸. A frequent and known cause of bladder injury is second trocar insertion, with an incidence of approximately 1.6% of all laparoscopic procedures⁴⁹. Essentially, this happens with an overdistended bladder because of a lack of catheterization before the procedure.

The diagnosis is made when urine leaks out of the insufflation needle; no surgical repair is required in this

case. A small hole (less than 5 mm in size) may require only Foley catheter drainage for a few days⁵⁰.

COMPLICATIONS OF THE SECOND STEP

During the second step, complications may occur while inserting the secondary trocars or during the surgical procedures. Vascular, urinary or intestinal structures may be injured by the trocars or in the course of electrosurgery, laser surgery or sharp dissection.

Secondary trocar injury

Major vascular injury or bowel injury is diagnosed and managed as previously described. Epigastric vessel perforation and bladder injury are managed differently, as described further.

Epigastric vessel perforation by secondary trocars

Perforation of the inferior and/or superficial epigastric vessels is the most common complication encountered during laparoscopic surgery (Figure 39.4). The inferior epigastric artery extends from the external iliac artery and lies beneath the rectus muscle and above the peritoneum. The superficial epigastric artery extends from the femoral artery near the inguinal ring and courses medially over the rectus muscle toward the midline.

Diagnosis If injured, these large vessels can produce a rapid and massive hemorrhage. One fatal injury to an epigastric vessel is described in the literature⁵¹. While an injured inferior epigastric artery provokes retroperitoneal or intraperitoneal bleeding, superficial epigastric vessel

damage induces intramuscular or subcutaneous bleeding. In most cases, blood spillage around the trocar sleeve announces the injury.

Management An essential rule to bear in mind is that the sleeve cannot be removed, as it is the only mark of the vessel's location. In a case of minimal bleeding and a small hematoma, no repair is required. Sometimes the bleeding can be extremely swift, and repair using several techniques might be necessary. Both ends of the transected vessel must be secured for adequate hemostasis. Bipolar coagulation of the vessel through the peritoneum is the best and fastest way to ensure optimal hemostasis, but is only effective when there is no hematoma in the field of view, impeding the vessel's identification. Laparoscopic ligation of the vessel usually guarantees hemostasis. A large curved or straight needle can be passed through the abdominal wall and into the abdomen. The needle is then passed back through the abdominal wall and tied just outside, cephalocaudal to the sleeve. At the end of surgery, the ligature can be removed without any recurrence of bleeding. Another similar suture technique using two sutures with straight needles is described by Chatzipapas and Magos⁵². Hemostasis can also be achieved by simple compression. As soon as rapid bleeding is noticed around the sleeve, a no. 12 Foley catheter is passed through the sleeve into the abdominal cavity⁵³. The Foley balloon is inflated with fluid. The sleeve is then pulled out and the Foley balloon is pulled up against the abdominal wall. The pressure maintained on the Foley balloon occludes the bleeding vessel. As soon as hemostasis is obtained, a second trocar is inserted and the operation can continue. In some rare cases, where hemostasis cannot be achieved, the skin incision must be enlarged around the trocar sleeve and the vessel promptly secured by ligature.

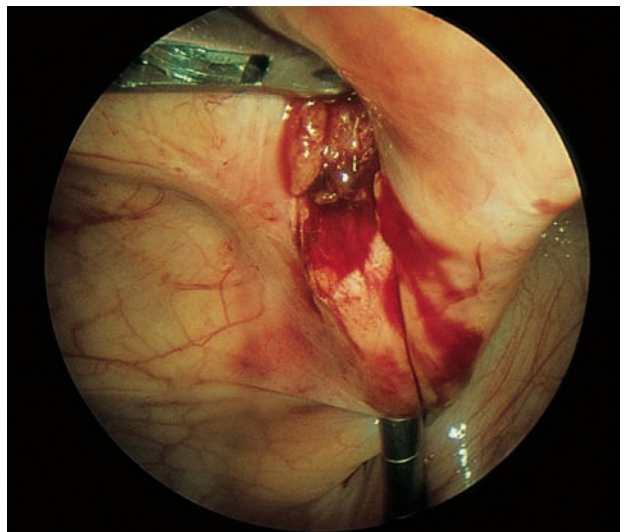
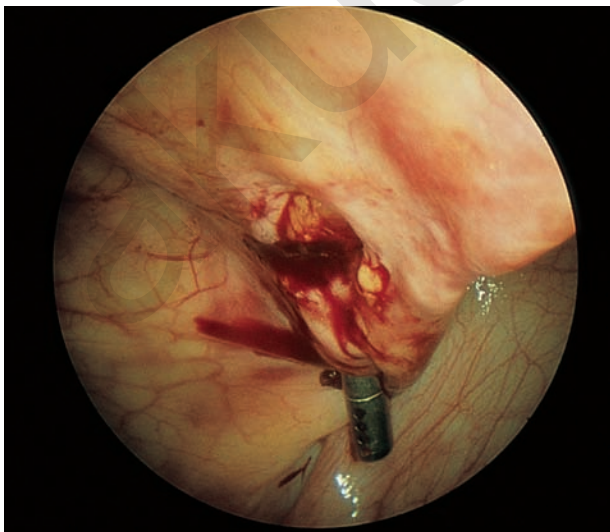


Figure 39.4 Epigastric vessel perforation

Prevention An injury to the superficial and/or inferior epigastric vessels may occur during any laparoscopy, but is more likely to happen under specific circumstances. Obese women, or patients who have undergone previous abdominal surgery, are prone to having an epigastric vessel obscured by the fat panniculus or an incisional scar. Marret *et al.*⁵⁴, investigating complications caused by trocars, observed that 70% of patients presenting with a complication had previous abdominal surgery and 50% of them were obese. Removing and replacing trocars of different sizes and/or repeatedly attempting to place the second trocar increase the risk of such injury. During laparoscopy, a security triangle should be visualized using the obliterated umbilical arteries as the lateral sides of the triangle and the dome of the bladder as the third side of the triangle. Secondary puncture trocars must be inserted within the margins of this triangle. The epigastric vessels rarely lie within the confines of this area. Sometimes, close laparoscopic inspection of the peritoneal side of the anterior abdominal wall allows visualization of these vessels, so that the surgeon can choose a safe location to introduce the suprapubic trocar. Another technique is to localize the epigastric vessels by transillumination⁵⁵. Superficial abdominal wall vessels may be located by transillumination in the majority of women of normal weight, but the technique is of less value in overweight and obese women. The deep (inferior) epigastric vessels cannot be effectively located by transillumination.

Bladder injury by secondary trocars

Bladder injuries are more common with secondary trocars and occur in approximately 1.6% of all laparoscopic procedures⁵⁶. A lack of bladder catheterization is the main reason for such injuries. Although the bladder heals rapidly, intraoperative detection of the injury is crucial because it facilitates management and postoperative recovery. Delay in the diagnosis can result in abdominal distension and azotemia, although ascites, urinoma and vesicocutaneous fistulas are sometimes encountered.

Diagnosis The diagnosis is made intraoperatively if the bladder muscularis is seen to be separated by the trocar, or if urine spillage is noted around the trocar sleeve. If a Foley catheter is left in place, the appearance of gas in the Foley bag or hematuria must be investigated. To detect and visualize the lesion, contrast medium (methylene blue) can be injected through the urinary catheter into the bladder. If the blue liquid is seen in the abdominal cavity at laparoscopy, the injury is confirmed. Otherwise, the diagnosis is made postoperatively in the presence of hematuria, decreased urinary output, anuria, abdominal swelling or peritoneal signs. In the absence of infected urine, peritoneal signs rarely occur. A retrograde cystogram localizes the leak from the bladder and abdominal sonography confirms the presence of liquid in the abdominal cavity.

Management The first rule in the treatment of a bladder injury is 10-day drainage. In the case of small leaks (< 1 cm) or extraperitoneal damage, drainage may be sufficient. In other cases, immediate surgical repair is necessary. Prolonged manipulation of perforating instruments increases the degree of damage. If the damage is recognized intraoperatively, the trocar is left in place, and a purse-string (one- or two-layer closure) is immediately performed by minilaparotomy^{57,58} or by laparoscopy, as carried out by the majority of endoscopists. Laparoscopic repair with a two-layer closure must be considered only by experienced laparoscopists⁵⁹. If damage is suspected intraoperatively without any demonstrable leak or intraperitoneal spillage, drainage and observation may be useful⁶⁰. In the case of delayed diagnosis, bladder injuries are handled in the same way as for other traumatic ruptures. Intraperitoneal leaks are repaired and drained⁵⁰. Prior to catheter removal, a cystogram may be performed. If the leak persists, drainage is extended up to 30 days, prior to repeating the cystogram.

Prevention The first step before inserting the suprapubic trocar is to check that the bladder is well catheterized. For short procedures, this can be an in-and-out catheterization. For longer procedures, a Foley catheter must be drained constantly in a sterile closed system. This may prove very useful if the surgeon has to replace the secondary trocar often. After emptying the bladder, the second step to prevent trocar damage is visualization of the dome of the bladder when inserting the trocar. Patients who have undergone previous cesarean section or multiple pelvic surgery could present with an anatomic distortion, and hence trocars have to be placed taking this anatomy into consideration. In difficult cases, the insertion side can be modified.

Injury during surgical procedures

A host of instruments have been developed for a range of purposes during laparoscopic procedures. In addition to sharp and blunt dissection, there are special laser and electrosurgical devices specifically designed for laparoscopic application. It has been documented that tissue damage can extend up to 5 cm beyond the point of contact using monopolar electrosurgery⁶¹, up to 5 mm with bipolar electrosurgery⁶² and up to 2.7 mm with the CO₂ laser⁶³. Two major complications have been described with the use of these devices: bowel and ureteral injury.

Besides incautious use of these instruments, some complications can also be related to the degree of adhesions. The management of severe adhesions can result in vascular, bowel and ureteral injuries.

Bowel injury during surgical procedures

Bowel perforation may occur during laparoscopic dissection. Apart from instances directly related to dense

Table 39.2 Our series of 2147 laparoscopic resections of adenomyotic nodules: injuries due to nodule surgery and outcome

<i>Period</i>	<i>Diagnosis</i>	<i>Treatment</i>	<i>Outcome</i>
1990–2001	Intraoperative, <i>n</i> = 6	Direct repair by laparotomy or colpotomy, <i>n</i> = 6	Complications, <i>n</i> = 0
	Postoperative, <i>n</i> = 2		
	rectovaginal fistula, <i>n</i> = 1	Conservative after 3 months	Spontaneous healing
	rectovaginal fistula with peritonitis, <i>n</i> = 1	Temporary colostomy	Reanastomosis 3 months later
2002–2005	Intraoperative, <i>n</i> = 6	Direct repair by laparoscopy, <i>n</i> = 6	Complications, <i>n</i> = 0

adhesions and the dissection plane, complications may be induced by the use of a thermal energy device⁴³. In 1993, 27 bowel traumas were described⁶⁴, which occurred during 17 531 laparoscopies (1.54/1000). Twenty of them arose during adhesiolysis and the incidence was correlated to the difficulty of the procedure.

Out of 66 bowel injuries reported by Soderstrom, 60 were traumatic and six were due to electrocoagulation⁶⁵.

In our series of 2147 cases of deep adenomyotic nodular lesions, rectal injury (incision from 1 to 3 cm) occurred in 14 cases (0.7%) (Table 39.2).

In a first series of six rectal injuries in 1125 laparoscopies published in 2002, the rectum was repaired by laparotomy in three cases and by posterior colpotomy in three cases. In all six cases, the postoperative phase was uneventful. In this series of 1125 resections of deep nodular lesions, one rectovaginal fistula was encountered after laparoscopic resection of a rectovaginal adenomyotic nodule with suture of the vaginal dome by a vaginal approach, completed by left salpingectomy (Figure 39.5).

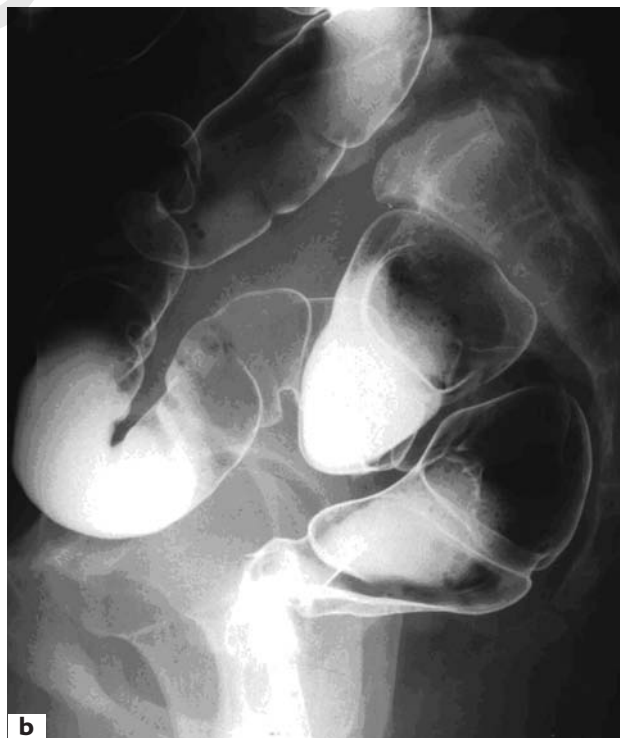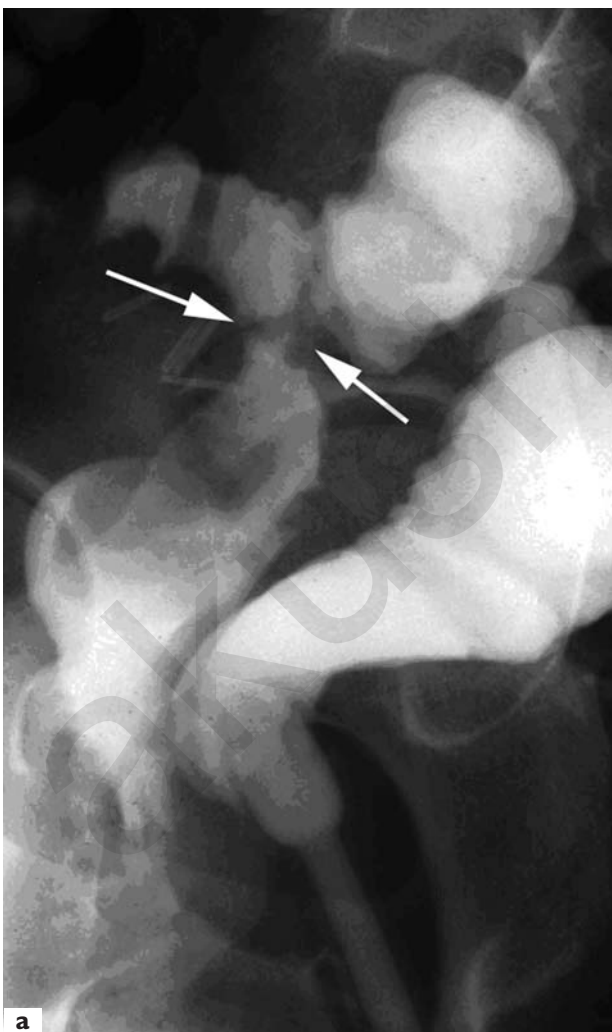


Figure 39.5 (a) Visualization of rectovaginal fistula (arrows) by retrograde bowel contrast injection. The vagina is obviously filled with contrast medium; (b) control X-ray showing complete healing after conservative treatment for 3 months

Two weeks after surgery, the patient mentioned loss of stools vaginally. Conservative treatment (antibiotics and a diet with no fiber) was applied for several weeks. Three months later, a control X-ray of the bowel with contrast injection confirmed complete healing. This lesion was probably due to a thermal injury.

In this same series, one case of fecal peritonitis occurred 10 days after adenomyotic nodule resection. A bowel enema (with Gastrografin®) revealed a large lateral defect 8–10 cm from the anal margin. A first treatment involving insertion of a drain through the vagina was insufficient (Figure 39.6). A laparotomy was carried out for peritoneal lavage and drainage, and to perform a colostomy.

Since the publication of this first series, the number of laparoscopies performed for adenomyotic rectovaginal nodules increased up to 2147 cases in the series completed in August 2005. Six rectal injuries occurred during ‘shaving’ of the rectum, and were diagnosed immediately during laparoscopy (Figure 39.7). As all the patients received a prior bowel preparation, immediate laparoscopic suture could be performed in one or two layers (Figure 39.8). Tissucol® was applied to aid healing (Figure

39.9). All the patients ate a fiberless diet for 3 weeks and recovered without any further complications.

We recommend avoiding laser or electrosurgery when performing adhesiolysis of the bowel (Figure 39.10). Indeed, injuries caused by scissors can be more easily managed, with a lower risk of secondary perforation due to necrosis.

Diagnosis In some cases, diagnosis is delayed, and patients present with signs of peritonitis or bowel occlusion. Intraoperatively, the diagnosis is made by direct visualization of the damage.

Management Management of perforations of the bowel is related to the site and extent of the damage, and to when the injury is discovered. For large perforations provoked by the laser beam or an electrosurgical device and diagnosed intraoperatively, a laparotomy with resection of the necrotic zone could be necessary, especially if the endoscopist is not trained for this type of surgery. If the patient has had a preoperative bowel preparation, repair by laparoscopic suture is possible for an experienced surgeon⁶⁶. The bowel must be repaired with two-layer sutures. This type of closure is appropriate only if the damage is limited and superficial. In the presence of a

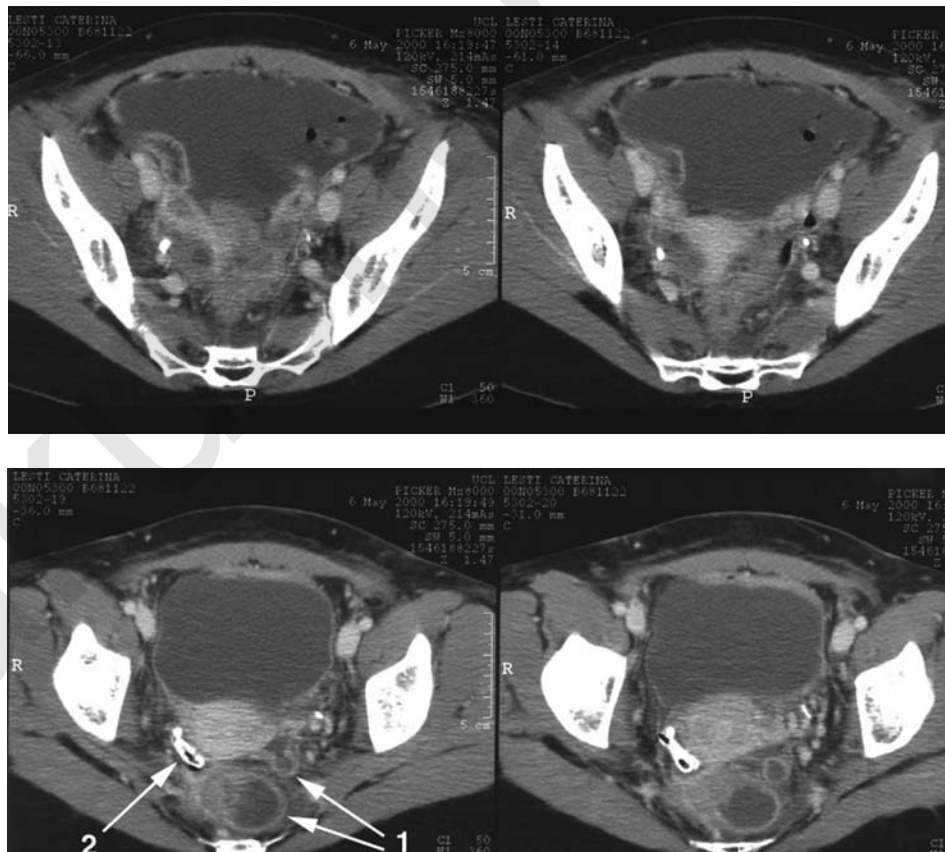


Figure 39.6 Liquid collection in the abdominal cavity, 10 days after adenomyotic nodule resection. Diagnosis of fecal peritonitis was made. 1, 3-cm collection in the left pararectal space; 2, vaginal drain

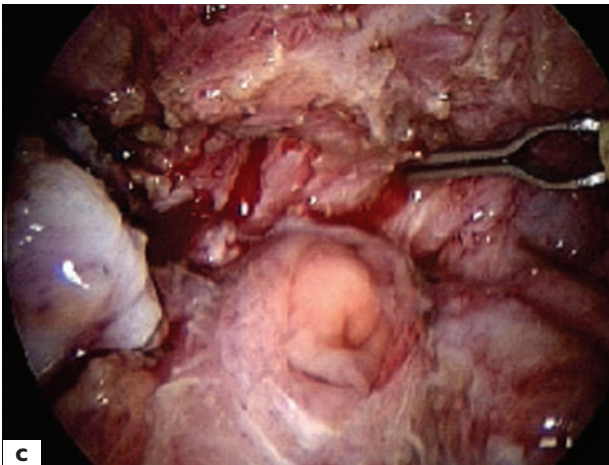
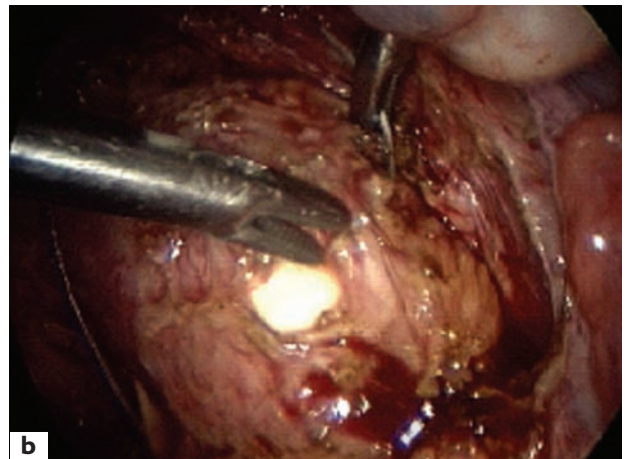
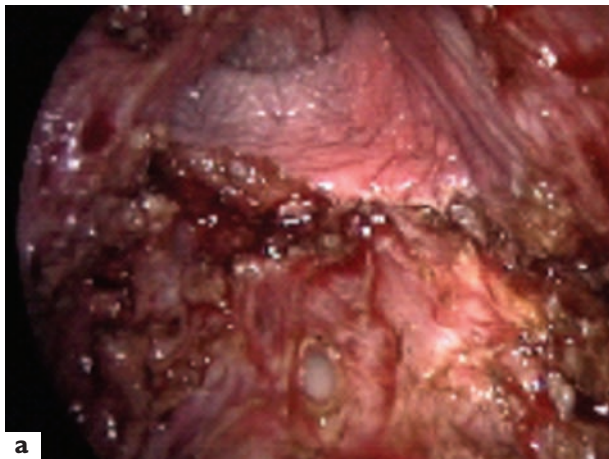


Figure 39.7 Rectal perforations. (a) and (b) The rectal cannula is seen through the rectal lesion. (c) Rectal mucosa

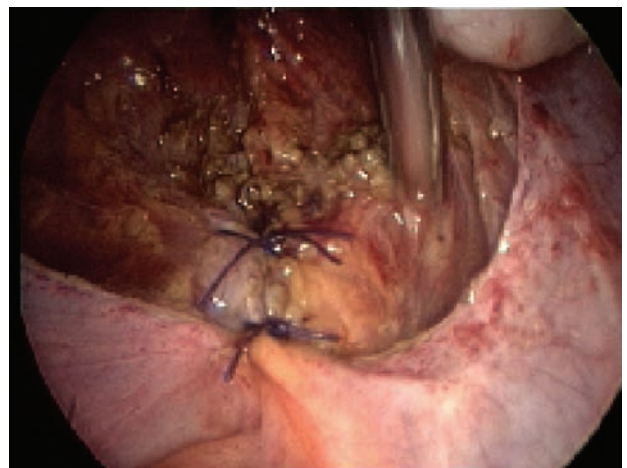
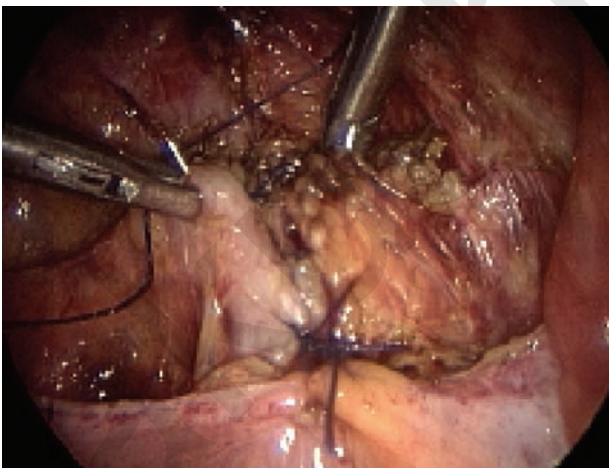


Figure 39.8 Laparoscopic rectal suture in two layers

significant bowel lesion or peritonitis, a timely intraoperative consultation with the general surgeon is mandatory to decide how to handle the damage.

Prevention Surgery must only be carried out by an experienced surgeon, with adequate instruments⁶⁷,

especially when bowel adhesiolysis is required. Care must be taken when using monopolar electrocautery to ensure that the patient's return plate is properly attached, the instruments are well insulated and the bowel is out of the field of energy application. With bipolar coagulation, the

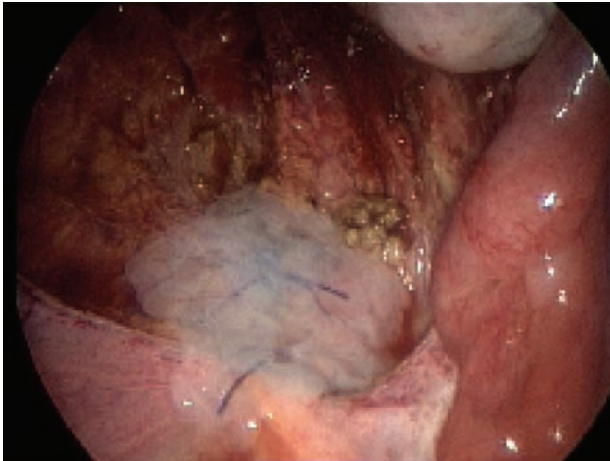


Figure 39.9 Tissucol® applied to rectal suture

forceps must not come into contact with the bowel when activated or immediately after inactivation.

In our department, if difficult laparoscopic surgery (resection of a rectovaginal adenomyotic nodule, suspicion of numerous adhesions) is to be performed, the patient receives a bowel preparation. Thus, in the case of bowel lesions diagnosed during surgery, direct suture can be performed. This technique avoids the temporary colostomy that is normally indicated in this type of complication without a bowel preparation.

Bladder injury during surgical procedures

This complication occurs more frequently in the case of patients who have a history of cesarean section or previous surgery, or whose bladder is not empty before surgery. The injury can happen during the installation phase (insertion of the insufflation needle or trocars) or during the operative procedure, by thermal injury (electrocoagulation, laser) and blunt dissection.

Mode of diagnosis Urine may be seen in the pelvis, usually secondary to an extraperitoneal perforation or laceration. If an injury is suspected but no definitive urine is seen, two tests for diagnosis are possible. First, 5 ml of indigo carmine or methylene blue can be administered intravenously. Another possibility is to inject methylene blue, diluted in 500 ml of saline solution, retrogradely through a urine catheter, so that the bladder can be checked laparoscopically for leakage. Because the bladder is hidden within the true pelvis, injuries to the lateral and posterior wall may be missed visually. Therefore, if bladder damage is suspected postoperatively, a gravity cystogram should be performed immediately. Approximately 250 ml of contrast medium is infused into the bladder by gravity drainage, and an X-ray film is obtained. If a rupture is seen, a catheter is inserted to allow gravity drainage, which starts immediately. Small bladder perforations may be seen on the lateral, oblique or drain-out films. Radiographically,

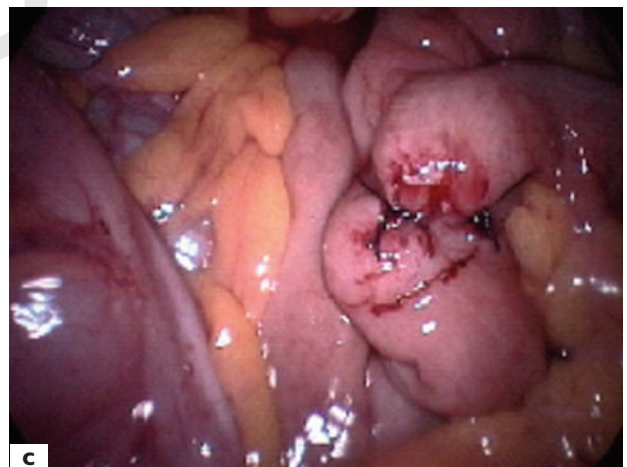
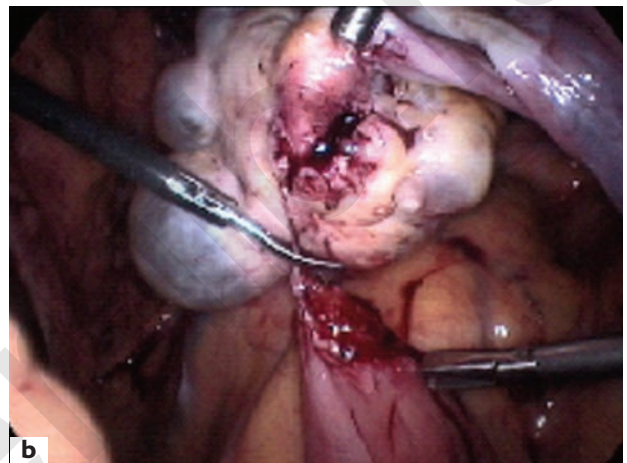
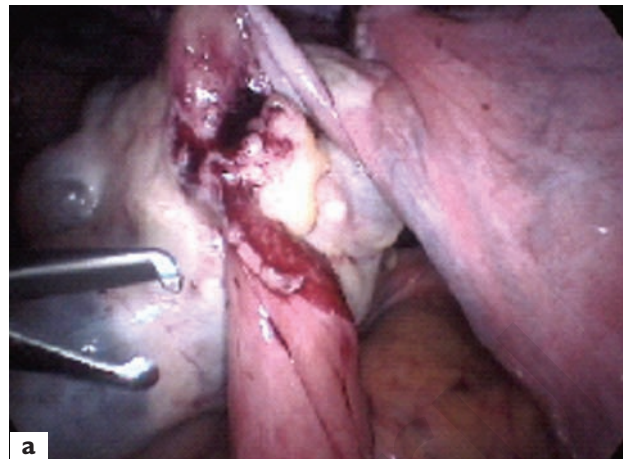


Figure 39.10 (a) and (b) Adhesiolysis of the small intestine with scissors. (c) Sutured bowel

intraoperative injuries will allow contrast medium to fill the cul-de-sac, outline loops of bowel and extend along the pericolic gutter.

Suprapubic pain and fullness, with or without diminished urine output, may suggest bladder injury. If an intraperitoneal bladder injury has been missed, a dramatic increase in blood urea nitrogen (BUN), due to urinary

contact with the peritoneum, is observed. The definitive diagnosis is made by cystography.

Thermal injuries to the bladder may not manifest themselves initially. Sudden hematuria, well into the postoperative period, may be a sign of thermal damage. A true perforation may not yet be present and, therefore, a negative cystogram may be misleading. Cystoscopy should be performed to identify any areas of devitalized tissue.

Management The first rule in the treatment of a bladder injury is a 10-day drainage. In the case of small leaks (<1 cm) or extraperitoneal damage, drainage may be sufficient. A gravity cystogram is performed on day 8–10, and, if no extravasation is noted, the catheter is removed.

In other cases, immediate surgical repair is necessary.

In a case of significant bladder laceration, open surgery may be required to identify the lesion clearly and close the perforation carefully in one or two layers, with Vicryl® 2-0. In most cases, laparoscopic repair can be easily performed. A one- or two-layer suture must be carried out. The bladder catheter is left in place for 10 days. Prior to catheter removal, a cystogram can be performed. If the leak persists, drainage is prolonged for up to 20 days before repeating the cystogram.

In the case of bladder laceration in our first series, the diagnosis was made during the vaginal approach in laparoscopy-assisted vaginal hysterectomy. The closure of the laceration was performed vaginally, using 2-0 chromic catgut.

In the case of delayed diagnosis, bladder injuries are handled in the same way as for other traumatic ruptures. Intraperitoneal leaks are repaired and drained.

Prevention The first step before inserting the suprapubic trocar is to check that the bladder is well catheterized. After emptying the bladder, the second step to prevent trocar damage is visualization of the dome of the bladder when inserting the trocar. Patients who have had a previous cesarean section, or who have undergone multiple pelvic surgery, could present with an anatomic distortion in peritoneal bladder repair; thus, the anatomy has to be taken into consideration.

Ureteral injury during surgical procedures

The incidence of this type of injury has risen during the past 10–15 years, essentially due to three different factors. The increasing number of surgeons using these techniques and the use of new instruments inevitably contribute to the growing incidence. But another important reason is the increased use of laparoscopy for complicated surgical procedures such as hysterectomy, lymphadenectomy and extensive endometriotic lesions of the uterosacral ligaments and rectovaginal septum.

In 1994, we published a review of the literature and personal cases before that year⁶⁸. Ureteral lesions occurred during surgery for sterilization and endometriosis.

In our personal series from 1986 to 2000⁶⁹, ten ureteral lesions were encountered (Table 39.3) in more than 19 000 gynecological laparoscopies, giving an incidence of 0.05%. The prevalence was 2/12 000 (0.016%) until 1992, and then 8/7000 (0.11%), i.e. 6.8 times higher than in the first series. In this second series, injuries were sustained during hysterectomies and laparoscopies for severe endometriosis.

In our series of 2147 laparoscopic surgical procedures performed for deep nodular lesions, the rate of ureteral lesions was 0.4%. Indeed, three cases of ureteral transection and three cases of ureteral fistula due to thermal damage occurred in our series. The three cases of ureteral transection were diagnosed on the first or second day postoperatively due to the presence of urine in the abdominal drain. In one case, ureteral catheterization could be performed by cystoscopy. In the other two cases, cystoscopic catheterization failed and nephrostomy was performed. The patients were scheduled for surgery involving reimplantation of the ureter into the bladder 3 months later. In the first patient, in whom cystoscopic ureteral catheterization was successful, pyelography after 3 months of catheterization showed spontaneous healing, and no surgery was required. The other two patients underwent laparotomy and reimplantation of the ureter into the bladder. Recovery was uneventful. The three ureteral fistulas were diagnosed on days 7 and 8 postoperatively. The patients presented with abdominal pain and fever. Abdominal examination revealed peritoneal irritation and a computed tomography (CT) scan showed the presence of contrast medium in the retroperitoneal space after injection of a contrast medium. Intravenous pyelography confirmed the presence of a ureteral fistula. In all patients, cystoscopic ureteral catheterization could be performed. Intravenous pyelography after 3 months showed complete healing with an absence of fistulas. The ureteral catheters were removed.

In the literature, the incidence ranges from 0.12 to 0.25%^{1,70,71}.

A recent review by Ostrzenski *et al.*⁷³ of 70 ureteral injuries that occurred during laparoscopy reports incidences ranging from <1 to 2%. Ureteral injuries reported in peer-reviewed journals often lack detailed presentation of the initial laparoscopic surgery, or of the location, type and instrumentation involved in the ureteral injury. Laparoscopy-assisted vaginal hysterectomy was the procedure during which most injuries occurred, and instruments involved in electrocoagulation were the main offenders.

Ureteral injury is often not due to the actual transection, but to the application of thermal energy near the ureter, causing tissue necrosis with subsequent stenosis and fistulas. Therefore, symptoms do not usually appear before 7 days after surgery. Indeed, a period of 7 days is generally required for the development of a ureteral fistula.

Table 39.3 Personal series of ureteral injuries between 1986 and 2000

Case number	Time of presentation	Indication for initial procedure	Treatment modality	Method of diagnosis	Treatment
1 (1986)	7 days	Endometriosis (LUNA)	Monopolar coagulation	IVP–CT scan	Retrograde stent (JJ)
2 (1987)	7 days	Salpingo-ovariolysis	Bipolar coagulation	IVP	Retrograde stent (JJ)
3 (1992)	7 days	Endometriosis (LUNA)	Bipolar coagulation	IVP	Retrograde stent (JJ)
4 (1994)	13 days	LAVH	Extensive coagulation	IVP	Uretero-ureterostomy
5 (1994)	8 days	LAVH	Bipolar coagulation	IVP	Retrograde stent (JJ)
6 (1998)	Intraoperatively	LASH	Bipolar coagulation	Intraoperatively	Retrograde stent (JJ)
7 (1998)	2 months	LASH	Extensive coagulation	VP	Retrograde stent (JJ)
8 (1998)	48 hours	Rectovaginal nodule	Dissection, CO ₂ laser (transection)	IVP	Failed stenting, nephrostomy, spontaneous healing without surgery
9 (2000)	5 days	LH	Bipolar coagulation	IVP–CT scan	Retrograde stent (JJ)
10 (2000)	3 weeks	LASH	Bipolar coagulation	IVP	Failed stenting, vesicoureteral implantation

IVP–CT, intravenous pyelography–computed tomography; LUNA, laser uterine nerve ablation; LAVH, laparoscopy-assisted vaginal hysterectomy; LASH, laparoscopy-assisted supracervical hysterectomy; LH, laparoscopic hysterectomy

Diagnosis In Ostrzenski's review, 8.6% of injuries were diagnosed intraoperatively⁷². In our series, one diagnosis of ureteral injury was made intraoperatively. Immediate retrograde JJ stenting was performed. If ureteral lesions are suspected intraoperatively, intravenous injection of indigo carmine can help to detect the injury. Patients usually tend to present between 48 h and 7 days postoperatively, with symptoms of abdominal pain, peritonitis, leukocytosis and fever. Flank tenderness or hematuria is rarely described. In some cases, an evaluation of abdominal fluid drainage, with measurement of urea and creatinine, may aid the diagnosis. In a few rare cases, diagnosis was made 2–3 weeks after surgery. One of our patients presented with a uretero-vesical fistula 3 weeks after surgery, causing a watery vaginal discharge. The clinical diagnosis was made upon examination. In a recent review, delays ranging from 3 to 640 days to diagnosis were observed⁷³. In one case in our series, diagnosis was made 2 months after surgery, when the patient presented with pyelonephritis. Repair was achieved by ureteral stenting. The presence of ascites and/or a pelvic mass is revealed by sonography, and the diagnosis is confirmed by intravenous pyelography, which

shows whether the cause of the pelvic mass is a urinoma, and also demonstrates the site of a fistula (Figure 39.11). A CT scan can be helpful in some instances (Figure 39.12). Late complications in the form of stenosis can also be seen by intravenous pyelography (Figure 39.13).

Management The repair of ureteral injuries must be undertaken in collaboration with a urological surgeon. Percutaneous or cystoscopic techniques can probably be used to manage most such injuries. Exploratory laparoscopy and/or laparotomy can be employed for surgical repair in cases requiring end-to-end reanastomosis, reimplantation of the ureter into the bladder, transureteral ureterostomy and similar procedures. Some cases of primary repair of transected ureters by laparoscopy have been reported^{74,75}. In our series, one patient with ureteral transection showed spontaneous healing after successful cystoscopic catheterization of the ureter.

Often, if the diagnosis is made postoperatively and the lesion is not too fibrotic, the insertion of a ureteral stent can be attempted, as we already suggested in 1994⁶⁸. This stent allows the drainage of urine, resolution of the pelvic urinoma and spontaneous healing of the injured site. The

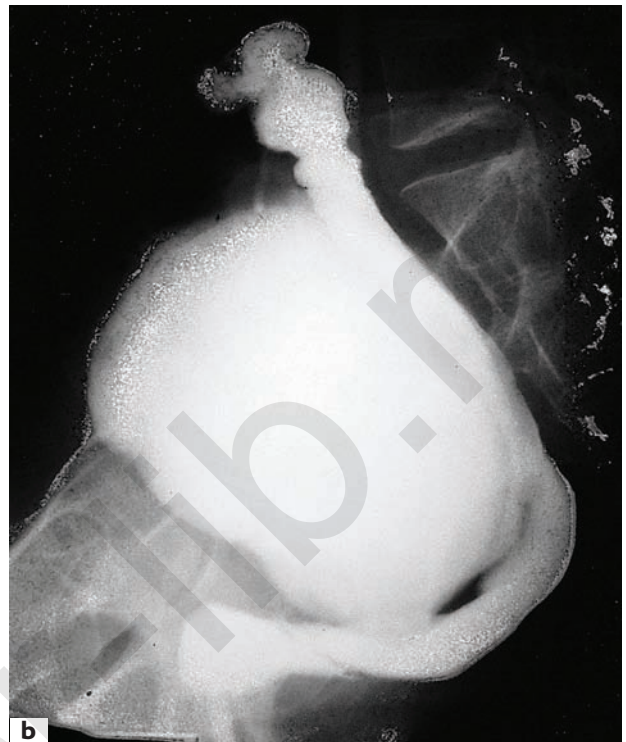
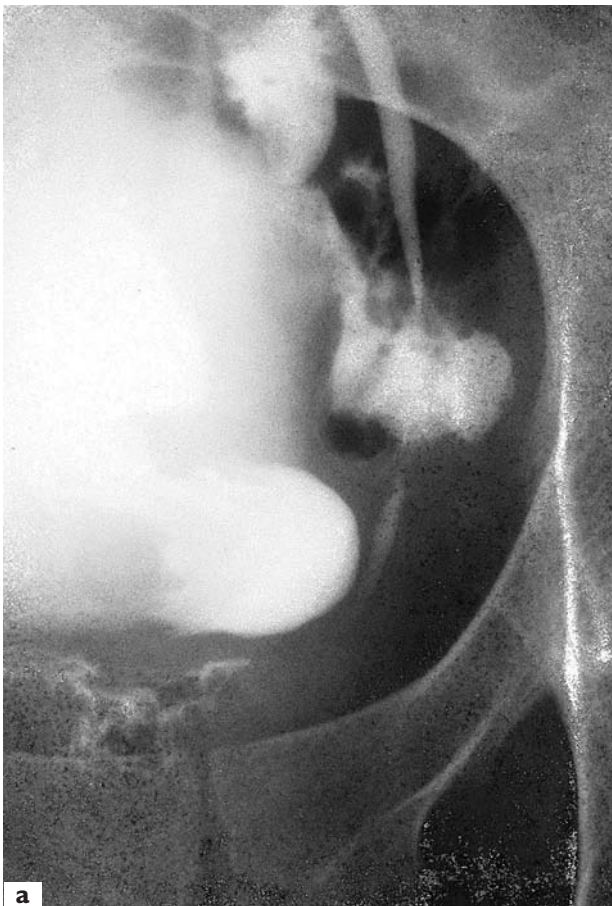
Figure 39.11 (a) Intravenous pyelogram revealing a urinoma; (b) extravasation of urine in a left urinoma after pyelography

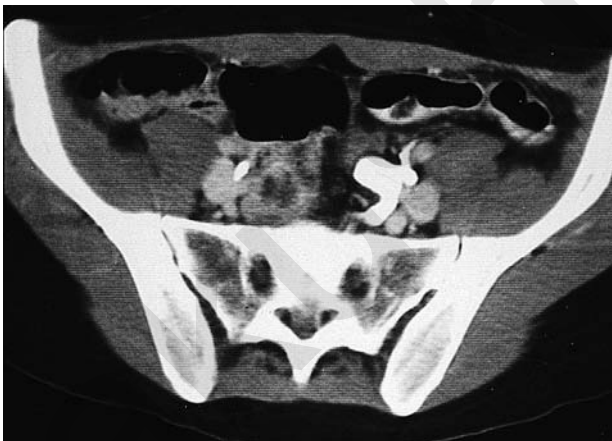

Figure 39.12 Computed tomography scan: presence of contrast medium in the retroperitoneal space after pyelography

placement of such ureteral stents may be accomplished in a retrograde manner. If technically possible, this method of treatment is preferable in managing such types of ureteral injuries. In our series (Table 39.3), insertion of a JJ stent was successful in 70% (7/10) of cases.

Prevention The ureter enters the pelvis at the pelvic brim, crossing over the common iliac artery and vein. It then runs posteriorly, crossing under the uterine artery, along the level of the cervix. At this point, the ureter is 1–1.5 cm lateral and anterior to the uterosacral ligament. Unfortunately, direct visualization of the ureter can prove difficult via pelviscopy, especially in obese women or after previous surgery involving dissection of the retroperitoneal space. Although the ureter may be visualized through the peritoneum in the upper pelvis, it cannot be identified reliably in the area of the uterosacral ligaments. Identification is particularly difficult when endometriosis or pelvic adhesions are present. Although specific guidelines are not available to prevent this serious complication, the following general points should be borne in mind:

- (1) The operator must understand the anatomy of the pelvic ureter and appreciate its proximity to the cervix in cases of endometriosis or when performing laser uterine nerve ablation (LUNA) or other risky surgery.
- (2) Sometimes, dissection of the ureter may help to avoid complications.

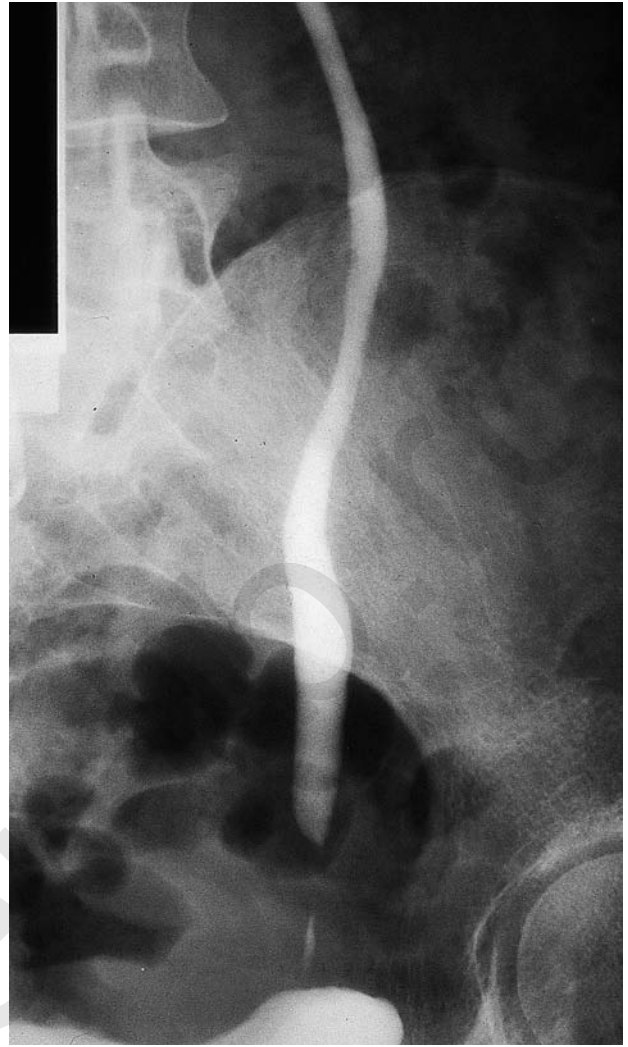
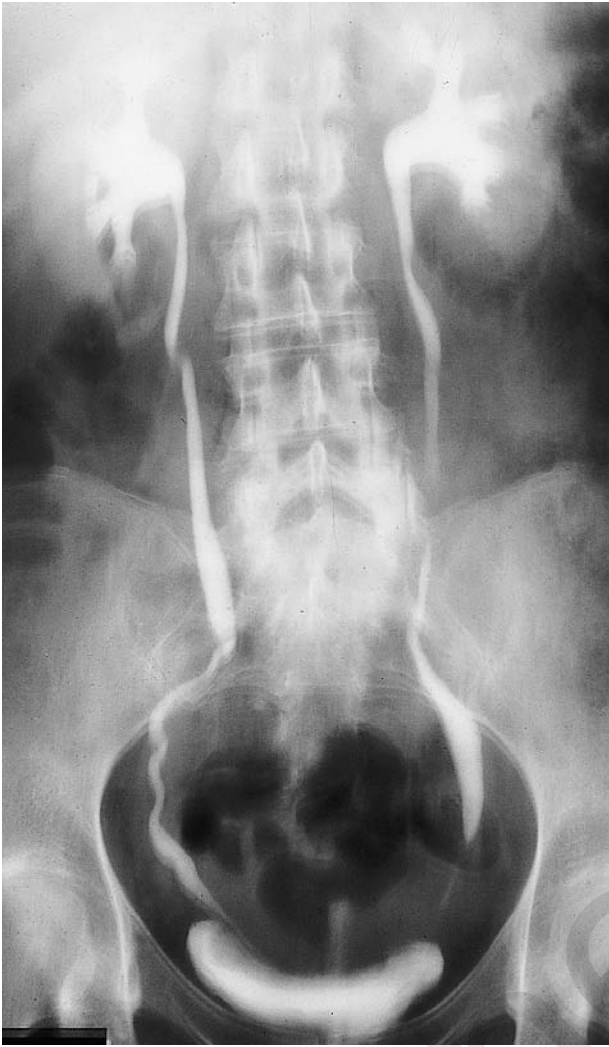

Figure 39.13 Small ureteral stenosis at pyelography

- (3) In addition, some authors have advocated using hydrodissection or hydroprotection to protect retroperitoneal structures^{76,77}. This technique involves making a small incision on the lateral parietal peritoneum and pumping fluid into the retroperitoneal space. Hydroprotection is particularly helpful when a laser is used in the procedure.
- (4) In the case of laparoscopic hysterectomy (LH), ureteral and/or bladder damage occurs at a rate of 1.4%⁷⁸. The technique of laparoscopic supracervical hysterectomy (LASH) appears to reduce the risk of such damage.
- (5) A ureteral marker can be placed before starting the operative procedure or ureteral dissection. Some authors avoid ureteral injury by using an intraoperative stent or the transillumination technique^{79,80}. This technique is, in our opinion, too aggressive for the ureter when compared with careful dissection.
- (6) Electrocauterization must always be performed with strict visual control of the structures lying under and around the field of application.
- (7) Bipolar coagulation is preferred to monopolar coagulation⁸¹. It is sometimes erroneously assumed that bipolar coagulation is 'completely safe'; in fact, it is safe only when the bipolar forceps are correctly positioned a sufficient distance from the ureter and used for a precisely calculated coagulation time⁸². Longer coagulation induces diffusion of thermal energy and the current may damage the vascular supply around the coagulated tissue, leading to delayed tissue necrosis^{83,84}.
- (8) To prevent such problems, the surgeon must check the energy unit (i.e. isolation, return electrode, power setting), and ensure that it functions correctly. In many instances, burn injuries result from faults in the electrocoagulation equipment and its use. Faulty insulation of the cautery device may also cause burns⁸⁵.

- (9) The use of a hyperfrequency electrocautery unit with a low peak voltage of 600 V and a maximum output of 100 W is preferred to other high-energy (3000–8000 V), spark-gap generators^{86,87}.

Major vascular injury during surgical procedures

Although the majority of vascular injuries occur during placement of the Verres needle and secondary trocars, about 20% of vascular complications arise from inadequate manipulation of the instruments^{88,89}.

In our department, two major vascular injuries resulting from instrument manipulation were recently observed. Both procedures were performed by two very experienced laparoscopists. The first occurred during subtotal hysterectomy of a 12-week fibromatous uterus. While sectioning the cervix with unipolar scissors, a 4-mm injury was sustained to the right external iliac artery. Immediate median laparotomy was performed and aorta compression was applied while waiting for the vascular surgeon, who was then able to suture this artery easily. The patient needed a blood transfusion (four units of concentrated blood) and recovery was uneventful.

A second vascular injury occurred during extensive retroperitoneal dissection in a woman presenting with an adenomyotic nodule of the rectovaginal septum following previous hysterectomy. The side wall consisted of fibrous tissue, and dissection of the ureter was difficult. In fact, the iliac vein was surrounded by dense adhesions and not visible. During dissection, the right external iliac vein sustained a 10-mm injury, which was diagnosed immediately (Figure 39.14).

While waiting for the vascular surgeon to arrive, abdominal CO₂ pressure was increased in order to compress the vein, and preparations were made for a laparotomy.

Laparotomy was performed, maintaining the intra-abdominal pressure for as long as possible, and the vein was repaired by the vascular surgeon using a patch of calf pericardium (Figure 39.15).

Diagnosis Arterial injuries are easily diagnosed by the presence of pulsatile red bleeding. In the case of venous injury, however, increased abdominal pressure due to the pneumoperitoneum can mask the injury, and diagnosis may be delayed.

Management In a case of major vessel injury, immediate median laparotomy must be performed. Pfannenstiel laparotomy, although practiced by many gynecologists, is not recommended because it hinders later vascular repair⁸⁸. Bleeding from a venous injury is reduced by the intra-abdominal pressure of the pneumoperitoneum. One should therefore maintain the pneumoperitoneum for as long as possible during conversion to laparotomy.

The first priority is compression of the aorta. This can be accomplished with the hand or with a vascular clamp, and may reduce bleeding until a vascular surgeon arrives.

Consultation with a vascular surgeon should be considered in all cases⁸⁹.

The ideal scenario is to perform complete vascular repair, since it is counterproductive simply to ligate the common or external iliac arteries or veins. An arterial or venous lesion is usually amenable to arteriorrhaphy or venorrhaphy, using interrupted monofilament sutures, so as to avoid stenosis^{88–90}. In lesions where this is not possible, due to a risk of stenosis in the arterial or venous lumen, the use of patch angioplasty (venous, pericardic or synthetic) is indicated.

When the arterial lesion is very large and/or arterial resection is required, implantation of autologous or synthetic grafts is necessary to achieve arterial continuity, either by interposing the graft or in the form of a bypass.

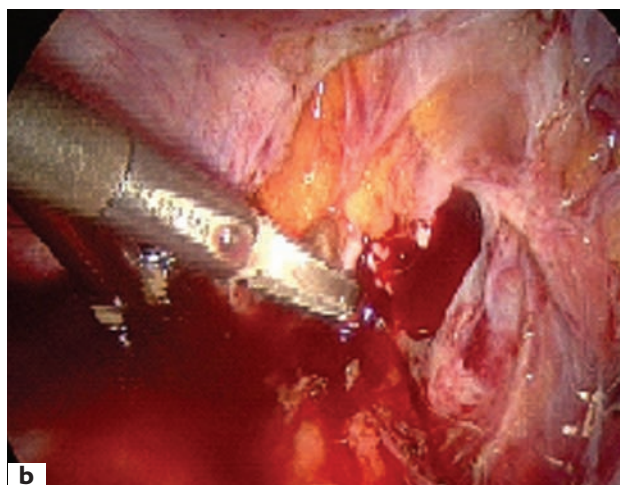
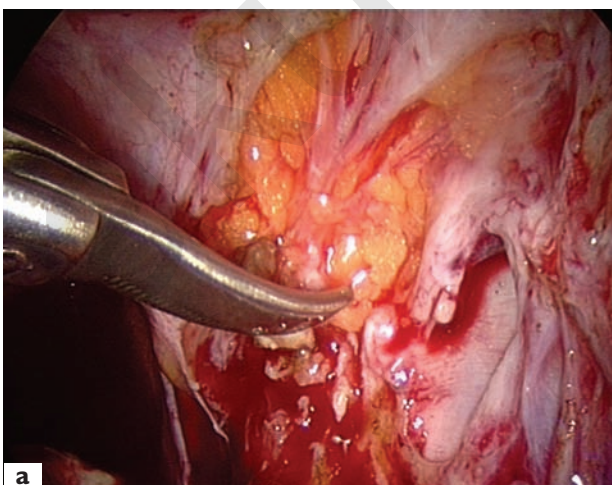


Figure 39.14 (a) A 1-cm injury to the right external iliac vein; (b) the decrease in intra-abdominal pressure is accompanied by increased bleeding

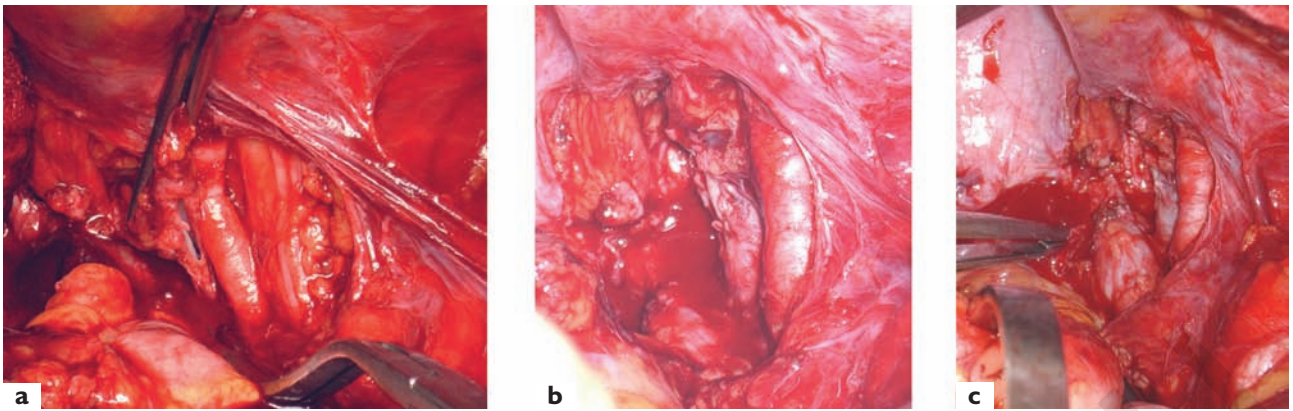


Figure 39.15 (a)–(c) Laparotomy for injury of external iliac vein; suture with the use of calf pericardium

Postoperative surveillance includes antithrombotic therapy, since many specific thrombogenic factors are involved (venorrhaphy, hypovolemia, abdominal surgery, etc.).

Complications due to CO₂ gas insufflation

Venous air embolism is a complication of laparoscopy that can happen at any time during surgery. In gynecological procedures, venous air embolism is usually sudden and it is therefore crucial to detect it immediately. Any delay in exsufflation and treatment can prove fatal^{91,92}. The incidence is very low, however: the reported figures range from 1/63 000 to 1/7500⁹³.

Diagnosis Clinical signs such as decreased blood pressure, tachycardia, arrhythmia and increasing central venous pressure come too late to be useful as warning signals. An easy and non-invasive way to detect embolism is measurement of end-tidal CO₂. As soon as the end-tidal CO₂ drops, abdominal pressure must be immediately reduced. If this maneuver is not followed by an increase in end-tidal CO₂, or if there is any sign of cardiovascular problems, venous air embolism must be considered to have occurred, and appropriate measures must be taken.

Management The patient should immediately be ventilated with 100% oxygen to prevent hypoxemia. The Trendelenburg position should be maintained and the pneumoperitoneum emptied. A large catheter must be inserted into the right atrium through the internal jugular vein to aspirate the gas. Any delay in exsufflation and treatment can indeed prove fatal⁹¹.

Prevention Gynecological laparoscopy should only be performed by trained surgeons in the presence of experienced anesthetists and with adequate time available. Abdominal pressure should be closely observed. The use of continuous end-tidal CO₂ analyzers is required.

Incisional hernias

Herniation of the small bowel or the omentum through the trocar incision is a complication of laparoscopy well described in the literature. Sometimes, other organs can cause herniation, such as tubal herniation after operative laparoscopy⁹⁴. The risk is greater particularly with trocars > 10 mm in size. In a retrospective study by the American Association of Gynecologic Laparoscopists, 933 hernias were reported out of an estimated 4 385 000 laparoscopic procedures (0.02%)⁹⁵. Kadar *et al.* observed an incidence of 0.23% and 3.1% using 10-mm and 12-mm trocars, respectively⁹⁶. These data were confirmed by Nezhat *et al.*⁹⁷, who published an incidence of 0.2% (11 hernias out of 5300 laparoscopies). In our series of 18 500 laparoscopies, we encountered just two hernias, probably because we used 5-mm trocars and because second-trocar incisions of more than 1 cm in size were systematically closed with transperitoneal stitches.

In one case, incarceration of the transverse colon occurred in the umbilical incision. A 59-year-old woman was operated on for bilateral adnexectomy. The principal trocar was introduced three times because insertion was difficult. This provoked a wide laceration of the peritoneal hole. During her hospital stay, the reintroduction of food proved difficult, the patient mentioned abdominal pain and fever was observed. Upon computed tomography (Figure 39.16) performed on day 5, incarceration of an intestinal loop in the umbilical incision was diagnosed. Perforation of the transverse colon in very inflamed tissue was visualized during laparotomy performed with the general surgeon. Temporary colostomy for 3 months was carried out and bowel resection was avoided.

In the other case, the small bowel was herniated in a 12-mm incision. This case occurred in 1996 before we started systematically closing this type of incision. Laparoscopy was carried out to reduce the hernia.

Diagnosis Hernias mostly occur later than 1 week after surgery. However, some cases of early herniation in the

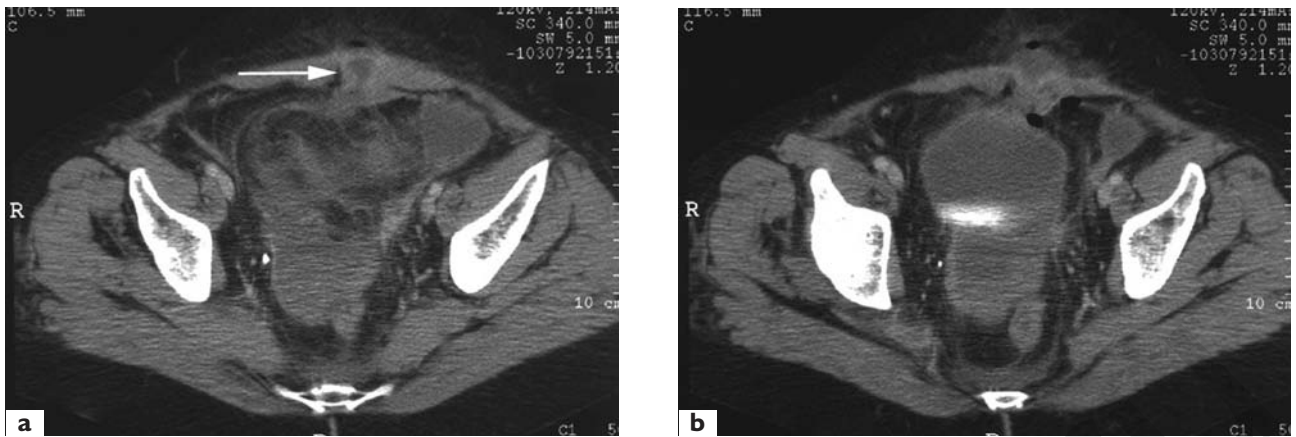


Figure 39.16 (a) and (b) Incarceration of the transverse colon in the umbilical incision

postoperative phase have been reported. Indeed, if reversal of the general anesthesia is carried out too early at the end of the surgical procedure, herniation can be precipitated by the coughing movements of the patient⁹⁸. Symptoms of incisional hernia are (chronic) pain in the region where the trocar was inserted and the classic symptoms of bowel obstruction (nausea, vomiting, pain).

Management If incisional herniation is suspected, a laparoscopy must be performed to reduce the hernia. In some cases, bowel resection is necessary if the tissue is necrotic.

Prevention To avoid this type of complication, suture in two layers (peritoneum and fascia, and skin) is indicated for all cases of trocar incisions larger than 10 mm. In our department, we use a particular technique to suture the aponeurosis and the peritoneum if the incision is > 10 mm. A special needle (Philips needle) (Figure 39.17) is introduced under laparoscopic control. To avoid provoking lesions when retracting the needle, the tip is then covered with a 5-mm trocar. The knot is tied outside the abdominal cavity. Many other suture techniques have also been described^{99,100}.

The underlying fascia and peritoneum should be closed not only when using trocars of 10 mm or more, as previously suggested, but also when extensive manipulation is performed through a 5-mm trocar port, causing extension of the incision.

Port-site metastases

The estimated incidence of port-site metastases among patients undergoing laparoscopic surgery for malignant disease is approximately 1–2%^{101–103}. Port-site metastases have been reported for multiple diseases, including carcinomas of the pancreas¹⁰⁴, esophagus¹⁰⁵, stomach¹⁰⁶, liver¹⁰⁷ and colon¹⁰⁸. The very first case was reported by

Dobronite *et al.*¹⁰⁹ in 1978, in a patient with ovarian cancer. A systematic review by Ramirez *et al.*¹¹⁰ found 31 articles describing 58 patients with port-site metastases and gynecological malignancies: 40 ovarian carcinomas, 12 cervical carcinomas, four endometrial carcinomas, one carcinoma of the Fallopian tube and one vaginal carcinoma.

The median time to the development of port-site metastases was 17 days in patients with ovarian cancer, 5 months in patients with cervical cancer and 13.5 months in patients with uterine cancer.

These port-site metastases could be isolated to the laparoscopic port that was used to insert instruments to obtain biopsies or manipulate and extract the tumor or lymph nodes, or indeed the port used to place the laparoscope.

The presence of ascites and carcinomatosis seems to increase the risk of port-site metastases¹⁰³. Among the most commonly proposed etiologies are wound implantation caused by the surgical technique and instrumentation, leakage of insufflation gas through the ports, known as the 'chimney effect', and the impact of the pneumoperitoneum on local immune reactions¹¹⁰. Several studies have suggested that the risk of port-site metastases may be significantly higher with carbon dioxide than with other insufflation agents^{111,112}.

All in all, there is no conclusive evidence anywhere in the literature as to whether port-site metastases develop as a result of the aggressive nature of the disease itself, or because of risk factors associated only with laparoscopic surgery.

The influence of port-site metastases on the survival of ovarian cancer patients is difficult to evaluate because, in most studies, the median follow-up is short, the outcome is not reported for the majority of patients, and details on the treatment at the time of recurrence are not available¹¹⁰.

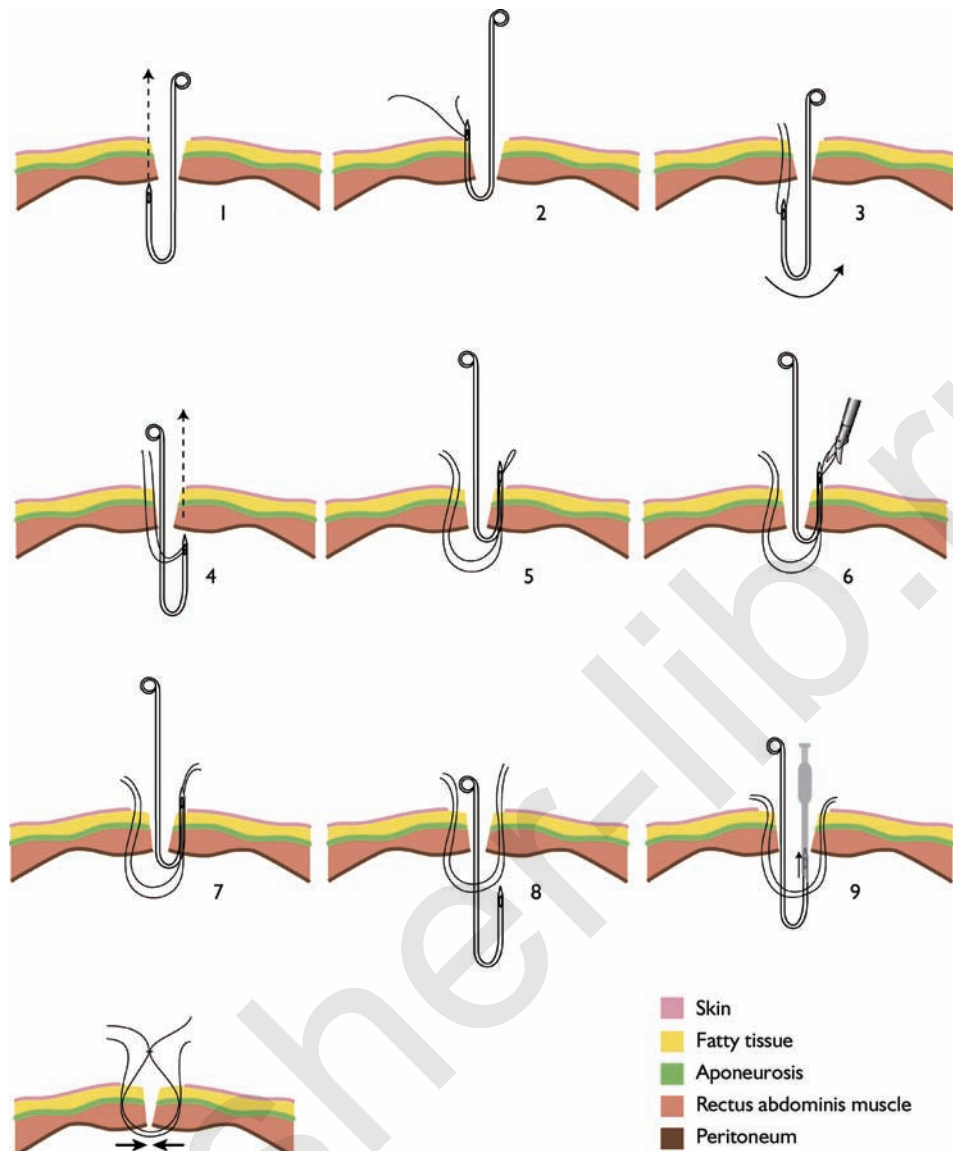


Figure 39.17 Closure of aponeurosis and the peritoneum with a Philips needle

Prevention A number of preventive measures have been suggested, including careful patient selection, lavage of the peritoneal cavity as well as the port wounds with cytotoxic agents^{113–115}, and modification of the surgical technique¹¹⁶ (gasless laparoscopy).

Rare complications reported in the literature

Pneumothorax A first case of a patient presenting with a congenital diaphragmatic defect causing a complete right pneumothorax during operative laparoscopy was reported¹¹⁷. The lesion was identified and appropriately treated intraoperatively.

Diaphragmatic injury Another complication with a diaphragmatic injury occurred in our department in a

25-year-old woman presenting with endometriotic lesions in the pelvis and on the diaphragm. When treating these lesions by CO₂ laser vaporization, perforation (3 mm) of the fibrotic part of the diaphragm occurred. The operation was immediately stopped and a moderate right pneumothorax was diagnosed. Spontaneous healing without any drainage was observed after a few days (Donnez, unpublished results).

Spleen laceration after laparoscopic surgery Salpingoplasty was performed on a 31-year-old woman to correct bilateral hydrosalpinx. Nine hours after surgery, an emergency exploratory laparotomy was performed due to massive abdominal bleeding. The cause was a small tear in the inferior splenic tail. The etiology of this laceration is uncertain. Many complications of laparoscopy are

physiological, and this one might have occurred while establishing the pneumoperitoneum. Distortion and stretching of small vascular adhesions between the spleen and the abdominal wall may also have played a role¹¹⁹.

Bowel subocclusion due to suture of the umbilical incision
 One week after a laparoscopic procedure, a patient presented to the accident and emergency department with signs of subocclusion of the bowel (loss of appetite, abdominal pain), without any signs of peritonitis. Diagnostic laparoscopy (performed through an incision in the upper left quadrant) confirmed a bowel lesion. The small bowel was incarcerated in the umbilical incision. After cutting the suture points, the bowel spontaneously fell into the abdominal cavity. No signs of necrosis were observed and no suture of the bowel was necessary. Reintroduction of food started 2 days after surgery and recovery was uneventful. This complication was probably due to the anesthesia being reversed too soon, as the patient was coughing while the surgeon was suturing. Also,

we should note that the patient had a very thin abdominal wall.

Complications due to the use of synthetic material

For some laparoscopic procedures, synthetic material is used. Laparoscopic sacrocolpopexy is usually performed with a polypropylene mesh. Other materials have been used, such as silicone mesh or biomaterial¹¹⁹. The latter compound is supposed to avoid the erosion sometimes occurring with non-resorbable material. Several cases of vaginal mesh erosion have been described¹¹⁹⁻¹²¹. In our department, we encountered three cases of vaginal mesh erosion in a series of 156 laparoscopic sacrofixations. The three cases occurred after colpopexy for vaginal prolapse after hysterectomy ($n=42$) (Figure 39.18). It was not observed in our series of 114 sacrofixations, with associated laparoscopic subtotal hysterectomy, the mesh being attached to the posterior part of the cervix (see Chapter 26).

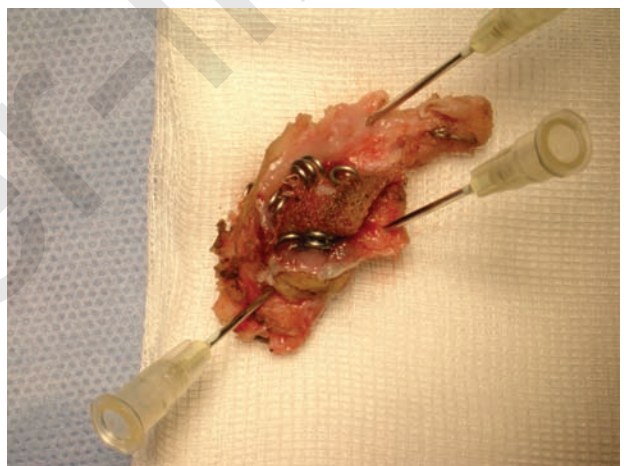
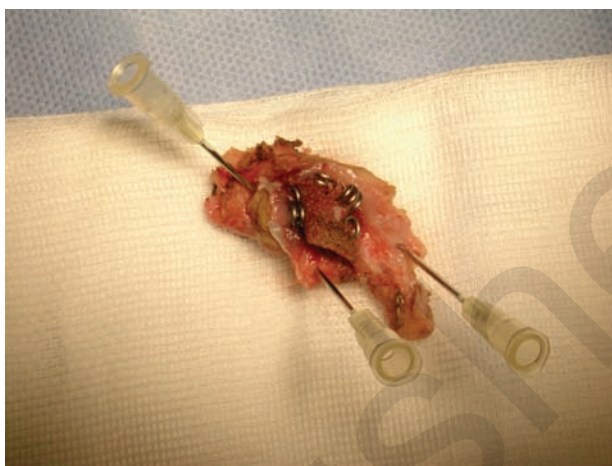
Figure 39.18 Vaginal erosion due to coils used to fix polypropylene mesh

Table 39.4 Number of laparoscopic complications necessitating laparotomy

Reference	n	Laparotomy	
		n	/1000
Henry-Suchet <i>et al.</i> ¹²²	9662	14	1.4
Von Theobald <i>et al.</i> ¹²³	1429	3	2.0
Peterson <i>et al.</i> ¹²⁴	36 928	96	2.6
Bruhat <i>et al.</i> [*]	7604	21	2.8
Chapron <i>et al.</i> ²	29 966	96	3.2
Jansen <i>et al.</i> ³	25 764	84	3.3
Donnez <i>et al.</i> [†]	2147	6	2.7

^{*} personal communication; [†] personal series of 2147 laparoscopies for deep endometriosis

DISCUSSION

The increased use of laparoscopy as a therapeutic method requires a reappraisal of the risks involved. Complications frequently encountered include injuries to the large and small bowel, uterus, bladder, ureters and blood vessels. These risks, in addition to the risk of general anaesthesia, have been further amplified by the addition of new devices and instruments for operative laparoscopy. Each complication has a specific etiology that is usually preventable or treatable if recognized in time. Complications of the first (blind) step and second (visual) step are usually recognized intraoperatively, treated immediately and follow an uneventful course. Complications of surgical procedures, specifically thermal injuries, are generally diagnosed postoperatively.

This is still one of the major problems of operative laparoscopy, because a delayed diagnosis worsens the prognosis and increases morbidity. Moreover, this type of injury often requires repair by laparotomy. The exact percentage of laparoscopic complications is unknown, but in Table 39.4, data from different studies are summarized.

The complication rate requiring laparotomy ranged from 0.14 to 0.33%. The likelihood of laparotomy being required was directly related to the degree of complexity of the laparoscopic surgical procedure and the experience of the surgeon. Intestinal or ureteral injuries represented more than 60% of complications requiring laparotomy, and, in more than 50% of these cases, the diagnosis was delayed. Major vessel injury or bladder injury occurred more commonly with trocars. Bowel and ureteral injuries were more frequently caused by surgical procedures, and complications with thermal energy represented about 40% of these cases. According to data now available, there are numerous possible complications related directly to surgical laparoscopy. However, major complications are relatively rare when there are no technical complications. The rate of complications related to the surgical procedure itself does not appear to be higher than that obtained for laparotomy.

In conclusion, with hundreds of thousands of gynecological operative laparoscopies and hysteroscopies performed all over the world, it has been clearly demonstrated that both procedures are extremely safe and effective. However, the possibility of complications must be borne in mind. Understanding these complications and their causes is the only way to avoid them in the future. Gynecological surgeons are now dealing with a host of new instruments and devices. As well as a thorough knowledge of the anatomy, familiarity with the new instrumentation is highly recommended. For this purpose, the following are required:

- Didactic lectures on both laparoscopic and hysteroscopic procedures and their complications
- Hands-on experience with live laboratory animals

- Preceptorship with experienced operators, or special residency training

Respecting these conditions will enhance endoscopic surgery results and minimize the rate of complications.

REFERENCES

1. Härkki-Siren P, Sjöberg J, Kurki T. Major complications of laparoscopy: a follow-up. Finnish study. *Obstet Gynecol* 1999; 94: 94–8
2. Chapron C, Pierre F, Querleu D, Dubuisson JB. [Complications of laparoscopy in gynecology]. *Gynecol Obstet Fertil* 2001; 29: 605–12
3. Jansen FW, Kapiteyn K, Trimbos-Kemper T, et al. Complications of laparoscopy: a prospective multicentre observational study. *Br J Obstet Gynaecol* 1997; 104: 595–600
4. Sokol AI, Chuang K, Midad MP. Risk factors for conversion to laparotomy during gynecologic laparoscopy. *J Am Assoc Gynecol Laprosc* 2003; 10: 469–73
5. Chi DS, Abu-Rustum NR, Sonoda Y, et al. Ten-year experience with laparoscopy on a gynecologic oncology service: analysis of risk factors for complications and conversion to laparotomy. *Am J Obstet Gynecol* 2004; 191: 1138–45
6. Rafii A, Camatte S, Lelievre L, et al. Previous abdominal surgery and closed entry for gynaecological laparoscopy: a prospective study. *Br J Obstet Gynaecol* 2005; 112: 100–2
7. Wattiez A, Soriano D, Cohen SB, et al. The learning curve of total laparoscopic hysterectomy: comparative analysis of 1647 cases. *J Am Assoc Gynecol Laprosc* 2002; 9: 339–45
8. Kalhan SB, Reaney JA. Pneumomediastinum and subcutaneous emphysema during laparoscopy. *Cleve Clin J Med* 1990; 57: 639–42
9. Vasquez JM, Demarque AM, Diamond MP. Vascular complications of laparoscopic surgery. *J Am Assoc Gynecol Laprosc* 1994; 1: 163–7
10. Murdock CM, Wolff AJ, Van Geem T. Risk factors for hypercapnia, subcutaneous emphysema, pneumothorax and pneumomediastinum during laparoscopy. *Obstet Gynecol* 2000; 95: 704–9
11. Agresta F, De Simone P, Ciardo LF, Bedin N. Direct trocar insertion vs Veress needle in nonobese patients undergoing laparoscopic procedures: a randomized prospective single-center study. *Surg Endosc* 2004; 18: 1778–81
12. Hulka JF, Levy BS, Parker WH, et al. Laparoscopic assisted vaginal hysterectomy: AAGL 1995 membership survey. *J Am Assoc Gynecol Laprosc* 1997; 4: 167–71
13. Bhojru S, Vierra MA, Nezhat CR, et al. Trocar injuries in laparoscopic surgery. *J Am Coll Surg* 2001; 192: 677–83
14. Sharp HT, Dodson MK, Draper ML, et al. Complications associated with optical-access laparoscopic trocars. *Obstet Gynecol* 2002; 99: 553–5

15. Lynn SC, Katz AR, Ross PJ. Aortic perforation sustained at laparoscopy. *J Reprod Med* 1982; 27: 217-19
16. Rust M, Buquoy F, Bonke S. Retroperitoneale Gefäßverletzung bei gynäkologischen Laparoskopien. *Anästh Intensivther Notfallmed* 1980; 15: 356-9
17. Heinrich P, Jahn R, Neumann A. Iatrogene Gefäßschaden im Beckenbereich. *Zentralbl Gynäkol* 1985; 107: 432-4
18. Erkrath KD, Weiler G, Adebahr G. Zur Aortenverletzung bei Laparoskopie in der Gynäkologie. *Geburtshilfe Frauenheilkd* 1979; 39: 687-9
19. Bisler H, Sinde J, Alemany J, et al. Verletzungen der grossen Gefässe bei gynäkologischen Laparoskopien. *Geburtshilfe Frauenheilkd* 1980; 40: 553-6
20. Leron E, Piura B, Ohana E, et al. Delayed recognition of major vascular injury during laparoscopy. *Eur J Obstet Gynecol Reprod Biol* 1998; 79: 91-3
21. Bergqvist D, Bergqvist A. Vascular injuries during gynecologic surgery. *Acta Obstet Gynecol Scand* 1987; 66: 19-23
22. Corson SL. Major vessel injury during laparoscopy. *Am J Obstet Gynecol* 1980; 138: 589-90
23. McDonald PT, Rich NM, Collins GJ, et al. Vascular trauma secondary to diagnostic and therapeutic procedures: laparoscopy. *Am J Surg* 1978; 135: 651-5
24. Shin CS. Vascular injury secondary to laparoscopy. *NY State J Med* 1982; 82: 935-6
25. Oshinsky GS, Smith AD. Laparoscopic needles and trocars: an overview of designs and complications. *J Laparoendosc Surg* 1992; 2: 117-25
26. Ransom SB, McNeeley SG, White C, et al. A cost-effectiveness evaluation of laparoscopic disposable versus nondisposable infraumbilical cannulas. *J Am Assoc Gynecol Laparosc* 1996; 4: 25-8
27. Dingfelder JR. Direct laparoscope trocar insertion without prior pneumoperitoneum. *J Reprod Med* 1978; 21: 45-7
28. Saidi MH. Direct laparoscopy without prior pneumoperitoneum. *J Reprod Med* 1986; 31: 684-6
29. Copeland C, Wing R, Hulka JF. Direct trocar insertion at laparoscopy: an evaluation. *Obstet Gynecol* 1983; 62: 655-9
30. Borgatta L, Gruss L, Barad D, et al. Direct trocar insertion versus Veress needle use for laparoscopic sterilization. *J Reprod Med* 1990; 35: 891-4
31. Woolcott R. The safety of laparoscopy performed by direct trocar insertion and carbon dioxide insufflation under vision. *Aust NZ J Obstet Gynaecol* 1997; 37: 216-19
32. Nezhat FR, Silfen SL, Evans D, et al. Comparison of direct insertion of disposable and standard reusable laparoscopic trocars and previous pneumoperitoneum with Veress needle. *Obstet Gynecol* 1991; 78: 148-50
33. van der Voort M, Heijnsdijk EA, Gouma DJ. Bowel injury as a complication of laparoscopy. *Br J Surg* 2004; 91: 1253-8
34. Loffer FD, Pent D. Indications, contraindications and complications of laparoscopy. *Obstet Gynecol Surg* 1975; 30: 407-27
35. Endler GC, Moghissi KS. Gastric perforation during pelvic laparoscopy. *Obstet Gynecol* 1976; 47 (Suppl): 40-42S
36. Edgerton WD. Laparoscopy in the community hospital: safety, performance, control. *J Reprod Med* 1974; 12: 239-44
37. Hirt PS, Morris R. Gastric bleeding secondary to laparoscopy in a patient with salpingitis. *Obstet Gynecol* 1982; 59: 655-7
38. Chapron C, Pierre F, Harchaoui Y, et al. Gastrointestinal injuries during gynaecological laparoscopy. *Hum Reprod* 1999; 14: 333-7
39. Gautier G, Péchinot M, Galloux Y, et al. Eructation révélatrice d'une perforation gastrique accidentelle lors de la création du pneumopéritoine pour chirurgie laparoscopique. Rôle contributif de l'anestésiste. *Ann Fr Anesth Réanim* 2000; 19: 67-8
40. Birns MT. Inadvertent instrumental perforation of the colon during laparoscopy: nonsurgical repair. *Gastrointest Endosc* 1989; 35: 54-6
41. Levy BS, Soderstrom RM, Dail DH. Bowel injuries during laparoscopy, gross anatomy and histology. *J Reprod Med* 1985; 30: 168-72
42. El-Banna M, Abdel-Atty M, El-Meteini M, et al. Management of laparoscopic-related bowel injuries. *Surg Endosc* 2000; 14: 779-82
43. Krebs HB. Intestinal injury in gynecologic surgery: a ten year experience. *Obstet Gynecol* 1986; 155: 509-14
44. Hasson HM. Open laparoscopy: a report of 150 cases. *J Reprod Med* 1974; 12: 234-8
45. Soderstrom RM. Bowel injury litigation after laparoscopy. *J Am Assoc Gynecol Laparosc* 1993; 1: 74-7
46. Howard FM, El Minawi AM, DeLoach VE. Direct laparoscopic cannula insertion at the left upper quadrant. *J Am Assoc Gynecol Laparosc* 1997; 4: 595-600
47. Corson SL, Batzer FR, Gocial B, et al. Measurement of the force necessary for laparoscopic trocar entry. *J Reprod Med* 1989; 34: 282-4
48. Ostrezenski A, Ostrezenska KM. Bladder injury during laparoscopic surgery. *Obstet Gynecol* 1988; 55: 175-80
49. Godfrey C, Wahle GR, Schilder JM, et al. Occult bladder injury during laparoscopy: report of two cases. *J Laparoendosc Adv Surg Tech A* 1999; 9: 341-5
50. Evans MR, Hulbert CJ, Reddy KP. Complications of laparoscopy. *Semin Urol* 1992; 10: 164-8
51. Norestgaard A, Bodily K, Osborne R, et al. Major vascular injury during gynecologic laparoscopy. *Am J Surg* 1995; 169: 543-5
52. Chatzipapas IK, Magos AL. A simple technique of securing inferior epigastric vessels and repairing the rectus sheath at laparoscopic surgery. *Obstet Gynecol* 1997; 90: 304-6
53. Aharoni A, Condea A, Leibovitz Z, et al. A comparative study of Foley catheter and suturing to

- control trocar-induced abdominal wall haemorrhage. *Gynaecol Endosc* 1997; 6: 31
54. Marret H, Pierre F, Chapron C, et al. Complications de la coelioscopie occasionnées par les trocards. *J Gynecol Obstet Biol Reprod* 1997; 26: 405–12
 55. Quint EH, Wang FL, Hurd WW. Laparoscopic transillumination for the location of anterior abdominal wall blood vessels. *J Laparoendosc Surg* 1996; 6: 167–9
 56. Godfrey C, Wahle GR, Schilder JM, et al. Occult bladder injury during laparoscopy: report of two cases. *J Laparoendosc Adv Surg Tech A* 1999; 9: 341–5
 57. De Cherney AH. Laparoscopy with unexpected viscus penetration. In Nichols DH, ed. *Clinical Problems, Injuries and Complications of Gynecologic Surgery*. Baltimore: Williams & Wilkins, 1988: 63
 58. Peters PC. Intraperitoneal rupture of the bladder. *Urol Clin N Am* 1989; 16: 279–82
 59. Reich H, McGlynn F. Laparoscopic repair of bladder injury. *Obstet Gynecol* 1990; 76: 909–10
 60. Corriere JN Jr, Sandler CM. Management of extraperitoneal bladder rupture. *Urol Clin N Am* 1989; 16: 275–7
 61. Wheelers CR. Thermal gastrointestinal injuries. In Philips JM, ed. *Laparoscopy*. Baltimore: Williams & Wilkins, 1977: 231–5
 62. Hulka JF, Peterson HB, Phillips JM, et al. Operative laparoscopy: AAGL 1991 membership survey. *J Reprod Med* 1991; 28: 569–71
 63. Martin DC. Tissue effects of lasers. *Semin Reprod Endocrinol* 1991; 9: 127
 64. Querleu D, Chevallier L, Chapron C, et al. Complications of gynaecological endoscopic surgery. A French multicenter collaborative study. *Gynaecol Endosc* 1993; 2: 3
 65. Soderstrom RM. Bowel injury litigation after laparoscopy. *J Am Assoc Gynecol Laparosc* 1993; 1: 74–7
 66. Renault B, Elhage A, Querleu D. Bowel complications in gynecologic laparoscopic surgery and their immediate repair without laparotomy. Four cases. *J Gynecol Obstet Biol Reprod* 1996; 25: 360–4
 67. Donnez J. Instrumentation and operational instructions. In Donnez J, ed. *Laser Operative Laparoscopy and Hysteroscopy*. Leuven: Nauwelaerts Printing, 1989: 15
 68. Donnez J, Bassil S, Anaf V, et al. Ureteral and bladder injury during laparoscopic surgery. In Donnez J, Nisolle M, eds. *Atlas of Laser Operative Laparoscopy and Hysteroscopy*. Carnforth, UK: Parthenon Publishing, 1994: 237–43
 69. Donnez J, Jadoul P, Chantraine F, et al. Ureteral and bladder injury during laparoscopic surgery. In Donnez J, Nisolle M, eds. *Atlas of Laser Operative Laparoscopy and Hysteroscopy*, 2nd edn. Carnforth, UK: Parthenon Publishing, 2001: 363–72
 70. Chapron C, Querleu D, Bruhat MA. Surgical complications of diagnostic and operative gynaecological laparoscopy: a series of 29 966 cases. *Hum Reprod* 1998; 13: 867–72
 71. Janse FW, Kapiteyn K, Trimbos-Kemper T. Complications of laparoscopy: a prospective multicenter observational study. *Br J Obstet Gynaecol* 1997; 104: 600
 72. Ostrzenski A, Radolinski B, Ostrzenska DM. A review of laparoscopic ureteral injury in pelvic surgery. *Obstet Gynecol Surv* 2003; 58: 794–9
 73. Adhoute F, Pariente JL, Le Guillou M, Ferriere JM. The ureteric risk in laparoscopic surgery. *Prog Urol* 2004; 14: 1162–6
 74. Nezhat C, Nezhat F. Laparoscopic repair of ureter resected during operative laparoscopy. *Obstet Gynecol* 1992; 80: 543–4
 75. Tulikangas PK, Golberg JM, Gill IS. Laparoscopic repair of ureteral transection. *J Am Assoc Gynecol Laparosc* 2000; 7: 415–16
 76. Donnez J, Nisolle M. Instrumentation and operational instructions. In Donnez J, Nisolle M, eds. *An Atlas of Laser Operative Laparoscopy and Hysteroscopy*. Carnforth, UK: Parthenon Publishing, 1994: 21–4
 77. Nezhat C, Nezhat FR. Safe laser endoscopic excision or vaporization of peritoneal endometriosis. *Fertil Steril* 1989; 52: 149–51
 78. Harkki-Siren P, Sjoberg J, Tiitinen A. Urinary tract injuries after hysterectomy. *Obstet Gynecol* 1998; 82: 113–18
 79. Lee CL, Huang KG, Wang CW, et al. New approaches in laparoscopically assisted radical vaginal hysterectomy. *Int Surg* 1997; 82: 266–8
 80. Ben Hur H, Phipps JH. Laparoscopic hysterectomy. *J Am Assoc Gynecol Laparosc* 2000; 7: 103–6
 81. Seiler JC, Gidwana G, Ballard L. Laparoscopic cauterization of endometriosis for fertility: an controlled study. *Fertil Steril* 1986; 46: 1098–100
 82. Bauman H, Jaeger P, Huch A. Ureteral injury after laparoscopic tubal sterilization by bipolar electrocoagulation. *Obstet Gynecol* 1988; 71: 483–5
 83. Schwimmer WB. Electrosurgical burn injuries during laparoscopy sterilization. *Treatments and prevention*. *Obstet Gynecol* 1974; 44: 526–30
 84. Jaffe RH, Willis D, Bachem A. The effect of electric currents on the arteries. A histologic study. *Arch Pathol* 1929; 7: 244–52
 85. Irvin TT, Goligher JC, Scott JS. Injury to the ureter during laparoscopic tubal sterilization. *Arch Surg* 1975; 110: 1501–3
 86. Levinson CJ, Schwartz SF, Saltzstein CE. Complications of laparoscopic tubal sterilization: small bowel perforation. *Obstet Gynecol* 1973; 41: 253–6
 87. Corson SL, Bolognese RJ. Electrosurgical hazards in laparoscopy. *JAMA* 1974; 927: 1261
 88. Barros MB, Lozano FS, Queral L. Vascular injuries during gynecological laparoscopy – the vascular surgeon's advice. *Sao Paulo Med J* 2005; 123: 38–41
 89. Nehzat C, Childers J, Nehzat F, et al. Major retroperitoneal vascular injury during laparoscopic surgery. *Hum Reprod* 1997; 12: 480–3
 90. Witz M, Lehmann JM. Major vascular injury during laparoscopy. *Br J Surg* 1997; 84: 800

91. Servais D, Althoff H. Fatal carbon dioxide embolism as a complication of endoscopic intervention. *Chirurg* 1998; 69: 773
92. Wadhwa RK, McKenzie R, Wadhwa SR, et al. Gas embolism during laparoscopy. *Anesthesiology* 1978; 48: 74-6
93. Yacoub OF, Cardona I, Coveler LA, et al. Carbon dioxide embolism during laparoscopy. *Anesthesiology* 1982; 57: 533-5
94. Chatman DL. Incarcerated tubal herniation, an unusual complication of operative laparoscopy and an odd cause of pelvic pain. *J Am Assoc Gynecol Laparosc* 2000; 7: 159-60
95. Montz FJ, Holschneider CH, Munro MG. Incisional hernia following laparoscopy: a survey of the American Association of Gynecologic Laparoscopists. *Obstet Gynecol* 1994; 84: 881-4
96. Kadar N, Reich H, Liu CY, et al. Incisional hernias after major laparoscopic gynecologic procedures. *Am J Obstet Gynecol* 1993; 168: 1493-5
97. Nezhat C, Nezhat F, Seidman DS, et al. Incisional hernias after operative laparoscopy. *J Laparoendosc Adv Surg Tech A* 1997; 7: 111-15
98. Leung TY, Yuen PM. Small bowel herniation through subumbilical port site following laparoscopic surgery at the time of reversal of anesthesia. *Gynecol Obstet Invest* 2000; 49: 209-10
99. Goldrath MH, Phillips E. A method of closing laparoscopy port incisions using a modified Veress needle. *J Am Assoc Gynecol Laparosc* 1996; 3: 287-90
100. Stringer NH, Levy ES, Kezmoh MP, et al. New closure technique for lateral operative laparoscopic trocar sites. A report of 80 closures. *Surg Endosc* 1995; 9: 838-40
101. Childers JM, Aqua KA, Surwit EA, et al. Abdominal-wall tumor implantation after laparoscopy for malignant conditions. *Obstet Gynecol* 1994; 84: 765-9
102. Ramirez PT, Wolf JK, Levenback C. Laparoscopic port-site metastases: etiology and prevention. *Gynecol Oncol* 2003; 91: 179-89
103. Nagarsheth NP, Rahaman J, Cohen CJ, et al. The incidence of port-site metastases in gynecologic cancers. *JLS* 2004; 8: 133-9
104. Siriwardena A, Samarji WN. Cutaneous tumour seeding from a previously undiagnosed pancreatic carcinoma after laparoscopic cholecystectomy. *Ann R Coll Surg Engl* 1993; 75: 199-200
105. Freeman RK, Wait MA. Port site metastasis after laparoscopic staging of esophageal carcinoma. *Ann Thorac Surg* 2001; 71: 1032-4
106. Cava A, Roman J, Gonzalez Quintela A, et al. Subcutaneous metastasis following laparoscopy in gastric adenocarcinoma. *Eur J Surg Oncol* 1990; 16: 63-7
107. Russi EG, Pergolizzi S, Mesiti M, et al. Unusual relapse of hepatocellular carcinoma. *Cancer* 1992; 70: 1483-7
108. Wexner SD, Cohen SM. Port site metastases after laparoscopic colorectal surgery for cure of malignancy. *Br J Surg* 1995; 82: 295-8
109. Dobronte Z, Wittmann T, Karacsony G. Rapid development of malignant metastases in the abdominal wall after laparoscopy. *Endoscopy* 1978; 10: 127-30
110. Ramirez PT, Frumovitz M, Wolf JK, Levenback C. Laparoscopic port-site metastases in patients with gynecological malignancies. *Int J Gynecol Cancer* 2004; 14: 1070-7
111. Neuhaus SJ, Ellis T, Rofe AM, et al. Tumor implantation following laparoscopy using different insufflation gases. *Surg Endosc* 1998; 12: 1300-2
112. Gupta A, Watson DI, Ellis T, Jamieson GG. Tumor implantation following laparoscopy using different insufflation gases. *Aust NZ J Surg* 2002; 72: 254-7
113. Neuhaus SJ, Watson DI, Ellis T, et al. Influence of cytotoxic agents on intraperitoneal tumor implantation after laparoscopy. *Dis Colon Rectum* 1999; 42: 10-15
114. Eshraghi N, Swanstrom LL, Bax T, et al. Topical treatments of laparoscopic port sites can decrease the incidence of incision metastases. *Surg Endosc* 1999; 13: 1121-4
115. Braumann C, Ordemann J, Wildbrett P, Jacobi CA. Influence of intraperitoneal and systemic application of taurolidine and taurolidine/heparin during laparoscopy on intraperitoneal and subcutaneous tumor growth in rats. *Clin Exp Metastasis* 2000; 18: 547-52
116. Bouvy ND, Marquet RL, Jeekel H, Bonjer HJ. Impact of gas(less) laparoscopy and laparotomy on peritoneal tumor growth and abdominal wall metastases. *Ann Surg* 1996; 224: 694-701
117. Childers JM, Caplinger P. Spontaneous pneumothorax during operative laparoscopy secondary to congenital diaphragmatic defects. A case report. *J Reprod Med* 1995; 40: 151-3
118. Chang MY, Shiau CS, Chang CL, et al. Spleen laceration, a rare complication of laparoscopy. *J Am Assoc Gynecol Laparosc* 2000; 7: 269-72
119. Govier FE, Kobashi KC, Kozlowski PM, et al. High complication rate identified in sacrocolpopexy patients attributed to silicone mesh. *Urology* 2005; 65: 1099-103
120. Ross JW, Preston M. Laparoscopic sacrocolpopexy for severe vaginal vault prolapse: five-year outcome. *J Minim Invasive Gynecol* 2005; 12: 221-6
121. Kohli N, Walsh PM, Roat TW, Karram MM. Mesh erosion after abdominal sacrocolpopexy. *Obstet Gynecol* 1998; 92: 999-1004
122. Henry-Suchet J, Tort-Grumbach J, Loysel F. Complications des coelioscopies colligées par le Club Gynéco-informatique en 1980-1982. *Contr Fertil Sex* 1984; 12: 901
123. Von Theobald P, Marie G, Herlicoviez M, et al. Morbidité et mortalité de la coelioscopie: étude rétrospective d'une série de 1429 cas. *Rev Fr Gynecol Obstet* 1990; 85: 611-14
124. Peterson HB, Hulka JF, Phillips JM. American Association of Gynecologic Laparoscopists 1988: membership survey on operative laparoscopy. *J Reprod Med* 1990; 35: 587-9

akusher-lib.ru

SECTION II
Operative hysteroscopy

akusherlib.ru

akusher-lib.ru

Instrumentation for hysteroscopy

J Donnez

Carbon dioxide is used as a gas medium. It is a product of the endogenous respiratory chain, has very good optical qualities and has no influence on the course of the illness in the case of inflammatory or malignant processes. Lindemann reports a multicenter study with 185 000 CO₂ hysteroscopies with no serious complications¹. To be able to guarantee this safety rate, however, great care must be taken to restrict the flow rate to < 100 ml/min. In rare case reports of CO₂ embolisms, it could not be clearly explained in retrospect whether it had really been a CO₂ embolism or, rather, another phenomenon, such as an air embolism (see also Chapter 49). No CO₂ embolisms have been reported, up to the time of writing, in non-anesthetized patients. A special hysteroflator must be used for the application of CO₂. It works with a maximum rate of 100 ml/min. When the preselected pressure has been reached, any further gas inflow automatically ceases. Using a laparoflator for hysteroscopy is strictly forbidden because it permits far higher flow rates and, thus, within a very short space of time a lethal CO₂ embolism could occur.

DISTENSION MEDIUM

Either a liquid or a gas medium can be used to distend the uterine cavity. In the case of liquid media, there is a distinction between aqueous solutions, such as 5% glucose solution, physiological saline solution or Ringer's (lactate) solution, and solutions with low viscosity, such as sorbitol/mannitol solution (Purisolet®) or 1.5% glycine solution (glycocol), and solutions with high viscosity such as 32% dextran (Hyskon®). Sorbitol/mannitol and glycine solutions are only used in surgical hysteroscopy, as they are electrolyte-free. Hyskon was used for a while, especially in the United States, but should now no longer be used for hysteroscopy owing to its high-risk profile. Liquids create different optical conditions due to their refractive indexes, which are different from that of air. Aqueous solutions become murky more quickly than does a viscous solution, through being mixed with blood and mucus. This, however, does not pose a problem, provided that irrigation (through the cervix or the Fallopian tube or with a continuous flow system) is possible.

An aqueous isotonic solution, such as 0.9% saline or Ringer's solution, is used for out-patient diagnostic hysteroscopy. An ordinary manually operated pressure cuff is pumped up to 80–120 mmHg and supplies the pressure for distending the cavity.

SET OF INSTRUMENTS FOR OPERATIVE HYSTEROSCOPY

In contrast to diagnostic hysteroscopy, which can be performed in general practice, surgical hysteroscopy is restricted to the operating room. The operation may be performed under general anesthetic or local/regional anesthesia, on an out-patient basis, or with a short stay in hospital. We subdivide surgical hysteroscopies into mechanical, laser and electrosurgical procedures, depending on the energy mode, each of these requiring an appropriate set of instruments.

Mechanical procedures

In this surgical technique, we use a hysteroscopic sheath which is slid over the telescope. Through this sheath, small rigid, semirigid or flexible instruments can be introduced, as well as the distension medium.

Equipment includes: grasping forceps to remove polyps after resection (Figure 40.1); scissors for dissecting the septum, adhesions or the base of polyps; and biopsy forceps for optically controlled biopsy collection. The traditional rigid diagnostic hysteroscope consists of a 30° telescope (Figure 40.2) with 4-mm diameter, integrated fiberoptic light transmission and an outer sheath for distension medium inflow.

Modern miniature hysteroscopes have a 25° or 30° telescope with 2.7–3-mm diameter, integrated fiberoptic

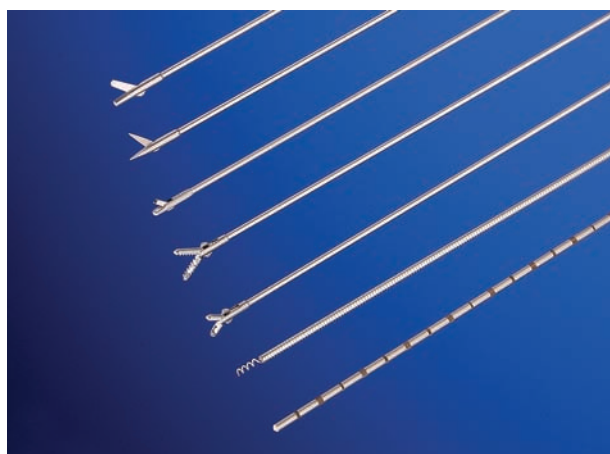

Figure 40.1 Small rigid instruments which can be used through a hysteroscopic sheath

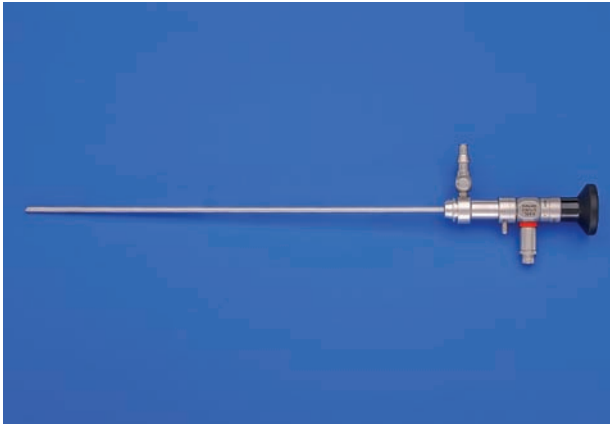



Figure 40.2 Rigid hysteroscope (telescope and sheath)



Figure 40.3 Bettocchi hysteroscope®. From top to bottom: telescope (diameter 2.9 mm), diagnostic sheaths single/continuous flow, sheaths with working channel instruments size 5F

light transmission and a sheath diameter between 3.5 and 4 mm (Figure 40.3). This allows direct access to the uterine cavity in almost all cases, and is associated with significantly fewer complaints in comparison with 5-mm instruments. The field of view and brightness are reduced in these hysteroscopes owing to the smaller diameter of the telescope, and this can cause occasional difficulties in a large, bleeding uterine cavity.


Some manufacturers offer hysteroscopes which allow the optional use of an additional inner sheath that is inserted into the outer sheath (Figure 40.4). By assembling both sheaths, it is possible to create a continuous flow system which can be used for controlled irrigation of the uterine cavity (Figures 40.5 and 40.6). The entire outer diameter can then be extended to 4.5–5 mm.



a



b



c

Figure 40.4 (a) Bettocchi hysteroscope, telescope (diameter 2.9 mm) with continuous flow sheath, outer diameter 4.5 mm. (b) Bettocchi hysteroscopes in different diameters. (c) Bettocchi hysteroscope, telescope (diameter 2.0 mm) with continuous flow sheaths, outer diameter 3.6 mm

Resectoscope (Figure 40.7)

The resectoscope is an instrument borrowed from urology, where it has been used for transurethral prostate resection and the removal of biopsy specimens from the bladder wall. It has a 0°, 12° or 30° rod lens telescope with integrated fiberoptic light transmission.




Figure 40.5 Bettocchi hysteroscope: close-up with 3.8 mm and 4.5 mm outer sheath system

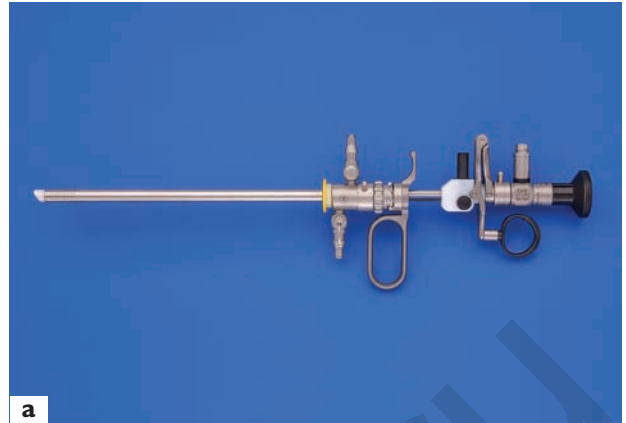


Figure 40.6 (a) Bettocchi hysteroscope, telescope (diameter 2.9 mm), sheaths with working channel (size 5 mm) with (a) grasping forceps size 5 F and (b) bipolar needle size 5 F

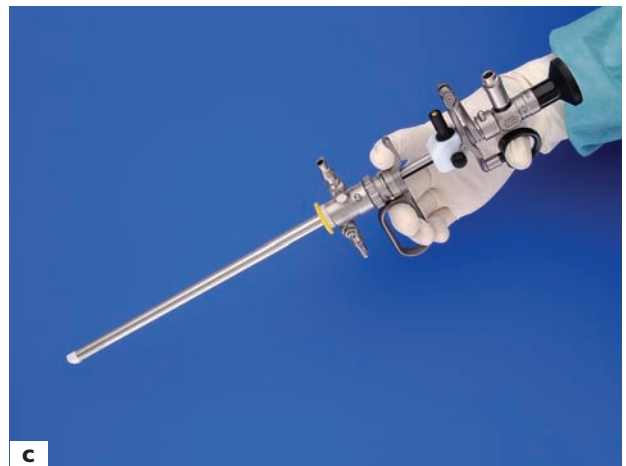

Figure 40.7 (a)–(c) Resectoscope (monopolar system)

Working elements (Figure 40.8)

Various elements, such as resection loops, rollerballs, roller cylinders, dissection needles and vaporization electrodes, are available as working elements. The loop is used in myoma, polyp and endometrial resections. Rollerballs and roller cylinders are applied during endometrial destruction

by means of coagulation technology. The vaporization electrode is generally an oblong electrode with three or four relatively small recesses, equally distanced. It is operated with a very high-performance cutting current.

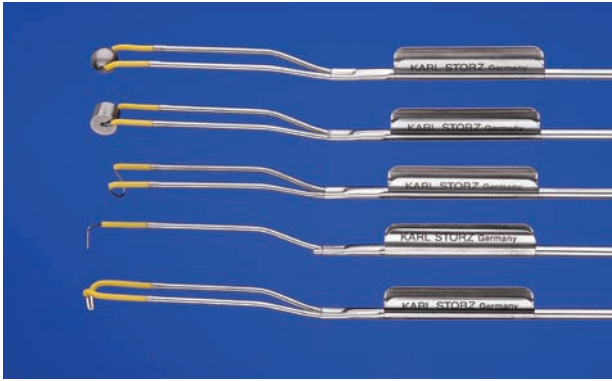

Figure 40.8 Different monopolar electrodes for the resectoscope

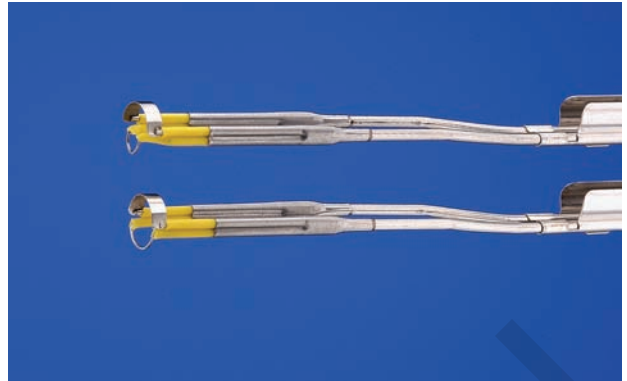

Figure 40.10 Different bipolar electrodes for the resectoscope



a



b



c

Figure 40.9 (a)–(c) Resectoscope (new bipolar system)

High-frequency generator

The resectoscope is operated with monopolar current, supplied from a standard surgical high-frequency generator. There is an option of electro-surgical cutting and coagulation. In order to avoid thermal damage of adjacent organs, the lowest necessary power setting is recommended. The use of modern high-frequency generators, with automatic voltage control, seems favorable.

Bipolar resectoscopes (Figures 40.9 and 40.10)

Bipolar resectoscopes have recently become available.

They allow the use of saline solution as distension medium instead of glycine. Fluid absorption of more than 2l of saline solution is not associated with hyponatremia and its consequences, nor neurotoxicity, as is the case with glycine. Their real efficacy remains to be proved, however.

REFERENCE

1. Lindemann HJ. Complications of CO₂ hysteroscopy. Arch Gynakol 1975; 219: 257–8

Hysterosonography and hysteroscopy in the diagnosis of specific disorders

J Squifflet, J Donnez, P Jadoul

HYSTEROSONOGRAPHY

Hysterosonography is a technique first described in 1988 by Deichert *et al.*¹; it uses saline solution as a contrast medium for evaluation of the uterine cavity during transvaginal ultrasonography. Before performing this examination, the patient must be asked about her gynecological history, number of pregnancies and previous history of pelvic inflammatory disease, sexually transmitted diseases, pelvic surgery, cesarean section, etc. A classic gynecological examination has to be performed first, with a Papanicolaou smear, and vaginal examination to evaluate the size of the uterus and the inclination of the axis of the uterus, to determine whether there is anteversion or retroversion. A colposcopy with cervix visualization serves to predict and estimate the feasibility of the examination, and the catheter size that will be necessary.

A transvaginal ultrasonographic examination is then performed, in which the size of the uterus is measured as well as the thickness of the endometrium; the adnexa are checked to exclude pathologies such as hydrosalpinx or, even worse, suspicion of adnexal neoplasia.

Most echographers experience some difficulty in evaluating the endometrium in obese patients in whom it is along the same axis as the vaginal probe, or who have increased thickness of the endometrial mucosa just before menses. All of these conditions make the detection and correct diagnosis of uterine pathology difficult in terms of screening for or excluding certain pathologies.

Technique

Saline infusion sonohysterography (SIS) is performed via a catheter placed inside the cervical os (female catheter CH10 or CH12, manufactured by Maersk Medical, Denmark) (Figure 41.1).

A speculum is placed and disinfection performed, and the cervix may be secured by grasping the anterior lip with a Pozzi tenaculum (one-tooth tenaculum forceps). Traction is applied to align the cervical canal and uterine cavity, or to introduce the catheter more easily in the case of cervical stenosis.

A catheter fixed onto a fully sterile saline solution syringe is introduced through the cervical canal. It is important to avoid and remove any bubbles in the syringe before introducing it, because they could produce some echogenic disturbance. The Pozzi forceps are removed. A transvaginal ultrasound probe is introduced after speculum removal. The uterus is surveyed in the sagittal and

transverse planes. Adequate SIS visualizes all parts of the uterus from the cervix to the uterine fundus (Figure 41.2). Usually, only a few milliliters of saline solution are needed to evaluate the uterine cavity. In the case of cervical fluid reflux, different-sized catheters may be used, or a Foley catheter could be placed in the cervical canal. All of these catheters are cheap, and there is no need to use more expensive devices to achieve a good evaluation with this technique.

This examination does not require expensive material as required in out-patient hysteroscopy. Pain rating also shows that this examination is less uncomfortable than hysterosalpingography and hysteroscopy. Irradiation is not used. In a case of suspicion of uterine pathology, for example when one is not sure whether the small echogenic structure observed is a blood clot or otherwise, the same investigation may be proposed some days later. This technique could be a useful follow-up for patients who are at high risk of intrauterine pathologies. Good visualization of the intramural part of myomas may be achieved to evaluate the correct size of this pathology, and, if uterine submucosal fibroids are to be removed hysteroscopically, one can correctly evaluate the thickness of the myometrium behind the fibroids (myometrium 'security' between fibroids and the serosa). Correct differential diagnosis between a polyp and a fibroid may sometimes be difficult, but the use of Doppler ultrasound can give a better diagnosis. The Doppler view shows the vascular flux in the pedicles of polyps, while fibroids usually have a

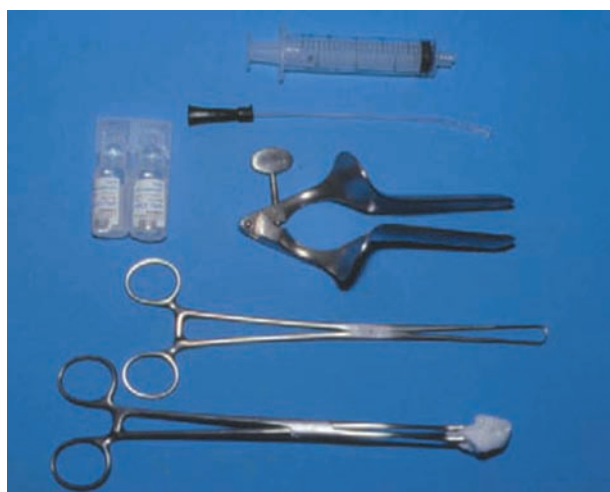

Figure 41.1 Equipment

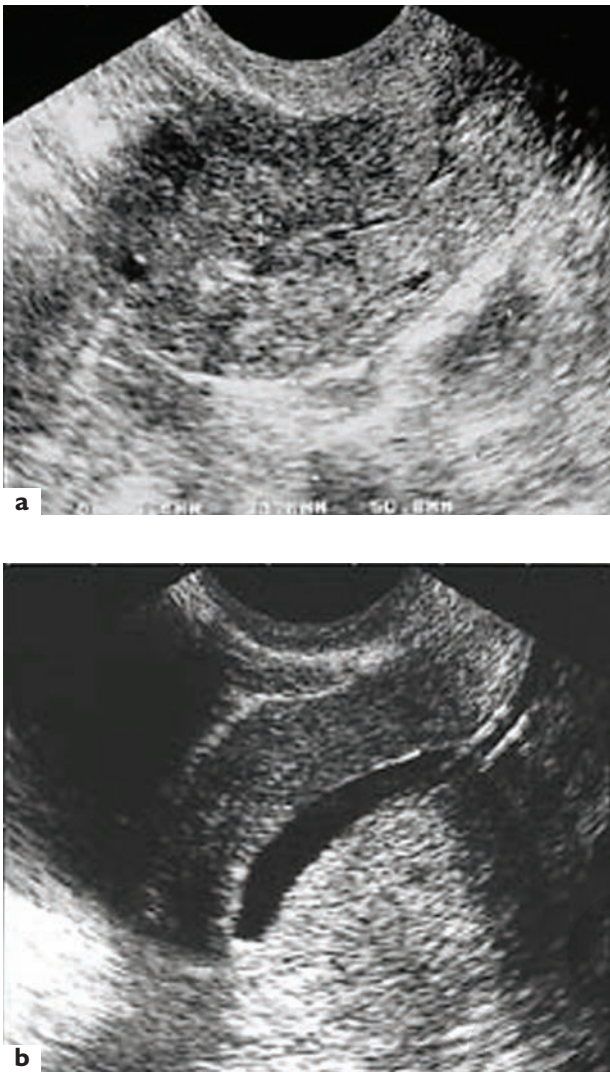


Figure 41.2 (a) Transvaginal sonography provides a sagittal view of the uterus; (b) with saline infusion sonohysterography, after saline infusion, the endometrium appears normal, without pathology

pedicle that is more heterogeneous and with peripheral vascularity.

Certain problems can occur, however. Sometimes, SIS may be impossible to perform because of cervical stenosis, but, in experienced hands, this technique has been carried out in more than 98% of women. In most cases, it takes no longer than 3–5 min.

There have been no reported cases of infection, although, in our series, one woman developed pelvic inflammatory disease after SIS; however, she had undergone hysterosalpingography some days earlier. We do not prescribe antibiotics routinely. In a case of suspected pelvic inflammatory disease or hydrosalpinx, hysterosonography is not performed. The possibility has been raised of retrograde seeding of adenocarcinoma cells in cases of

intrauterine neoplasia. Alcazar *et al.*² observed one case out of 14 in which malignant cells were present in the spilled fluid after SIS in a case of endometrial carcinoma. This observation has already been previously reported after diagnostic dilatation and curettage (D&C) or after hysterosalpingography, and does not appear to have any deleterious impact on the prognosis (in this pathology) of the neoplasia. In the case of cervical incompetence, such as reflux, a Foley catheter can be used.

Indications

Saline infusion sonohysterography is indicated in the following situations:

- Infertility investigation of uterine malformations, submucosal fibroids, polyps or synechiae
- Menorrhagia unsuccessfully treated with medication (Figures 41.3–41.5)
- Metrorrhagia (Figure 41.6)
- Follow-up of endometrial tissue at high risk of neoplasia, such as in patients with high blood pressure or diabetes, tamoxifen-treated patients or the obese (Figure 41.7)
- Endometrial thickness >5 mm in menopausal women (Figure 41.8)
- Poor imaging quality arising from the aspect axis or echogenicity of the endometrium

Transvaginal sonography can be an accurate diagnostic tool in evaluating women with abnormal vaginal bleeding. The endometrial thickness can be measured, and the ovulatory and hormonal status observed. Transvaginal sonography can detect endometrial thickening and heterogeneity and suggest possible masses; however, it is not as useful in determining the exact location of the masses. Saline infusion sonohysterography can enhance visualization of the endometrial lining and possible intracavitary masses.

Contraindications

Saline infusion sonohysterography should not be used in women with:

- Pelvic inflammatory disease
- A positive pregnancy test
- Suspected endometrial neoplasia

Results

Sonohysterography is a highly sensitive, specific and accurate screening procedure for evaluation of the uterine cavity in abnormal uterine bleeding (menorrhagia or metrorrhagia). Chittacharoen *et al.*³ observed a specificity of 83%, a sensitivity of 97%, a positive predictive value of 97% and a negative predictive value of 83% in a study in

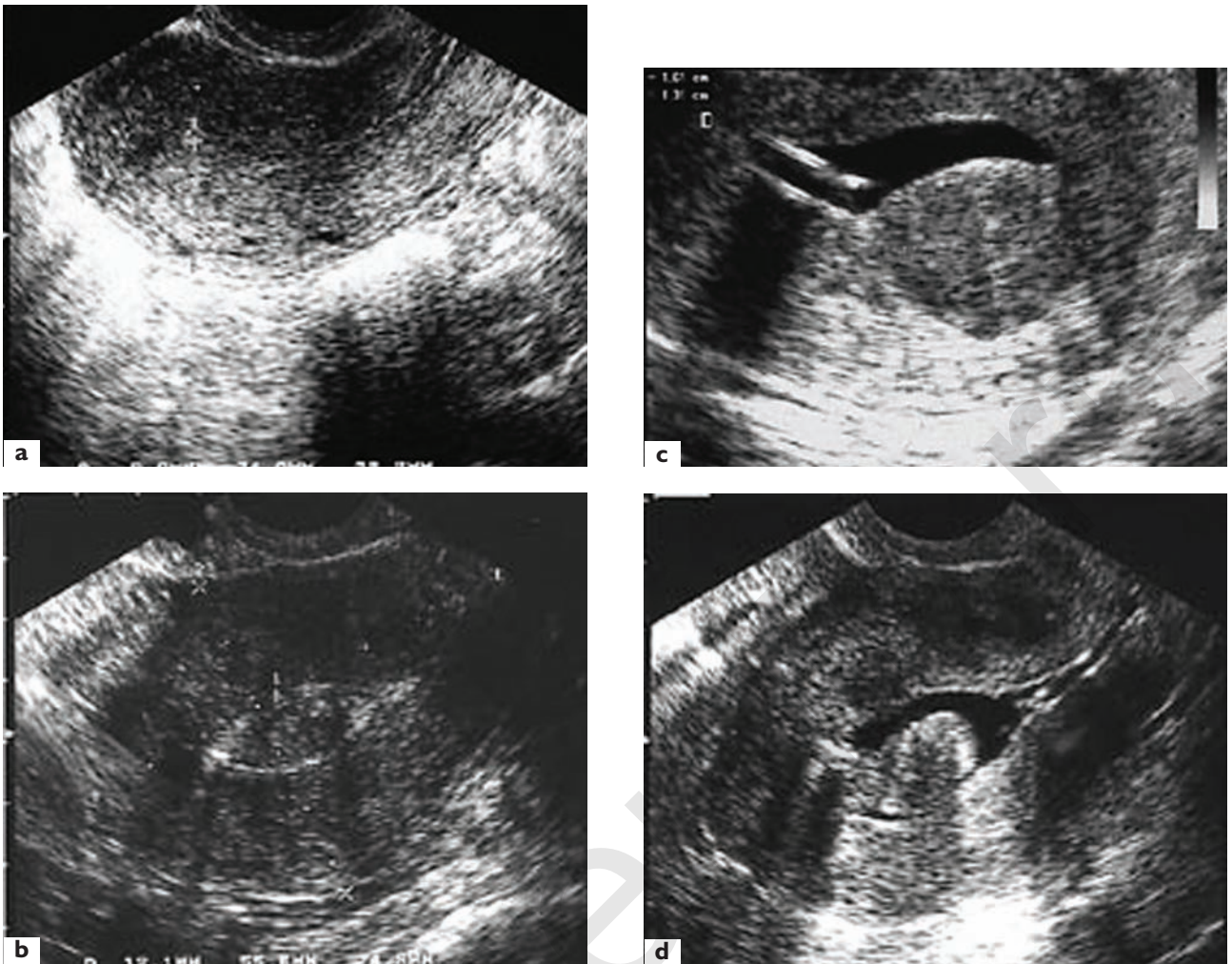


Figure 41.3 A 40-year-old patient with menorrhagia. Transvaginal sonography shows (a) a sagittal view of the endometrium of 6-mm thickness; and (b) endometrial thickness with a small focus at 12 mm; (c) and (d) saline infusion sonohysterography gives visualization of a polyp

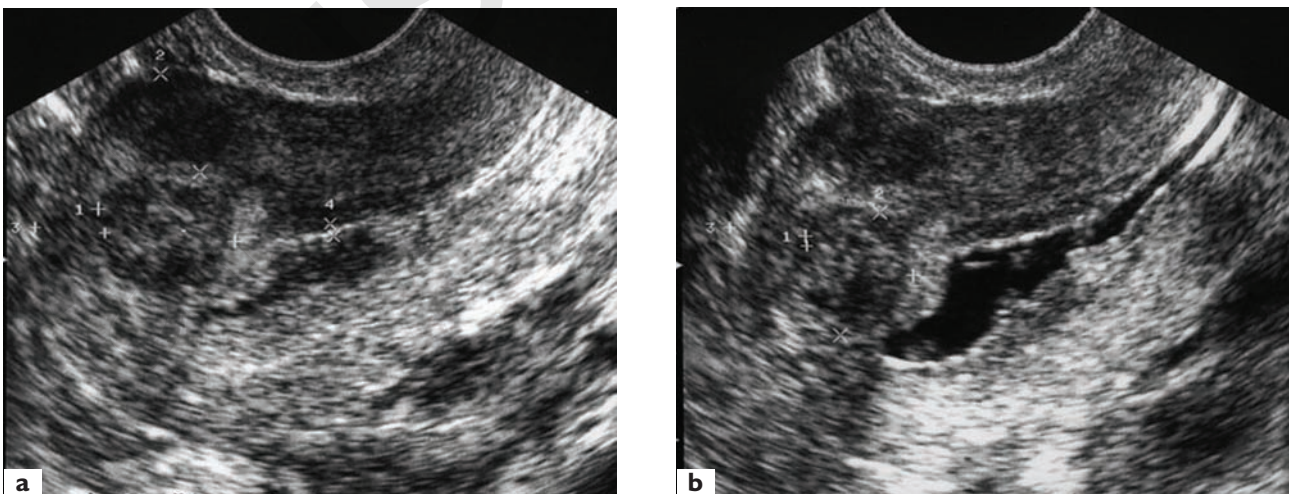


Figure 41.4 A 40-year-old patient with menorrhagia. (a) Transvaginal sonography, sagittal view, shows a normal endometrium and an intramural myoma of 16 mm; (b) deformation of the endometrium by the myoma is visualized with saline infusion sonohysterography. Saline infusion sonohysterography shows that a part of the myoma is submucosal and can be removed by hysteroscopy

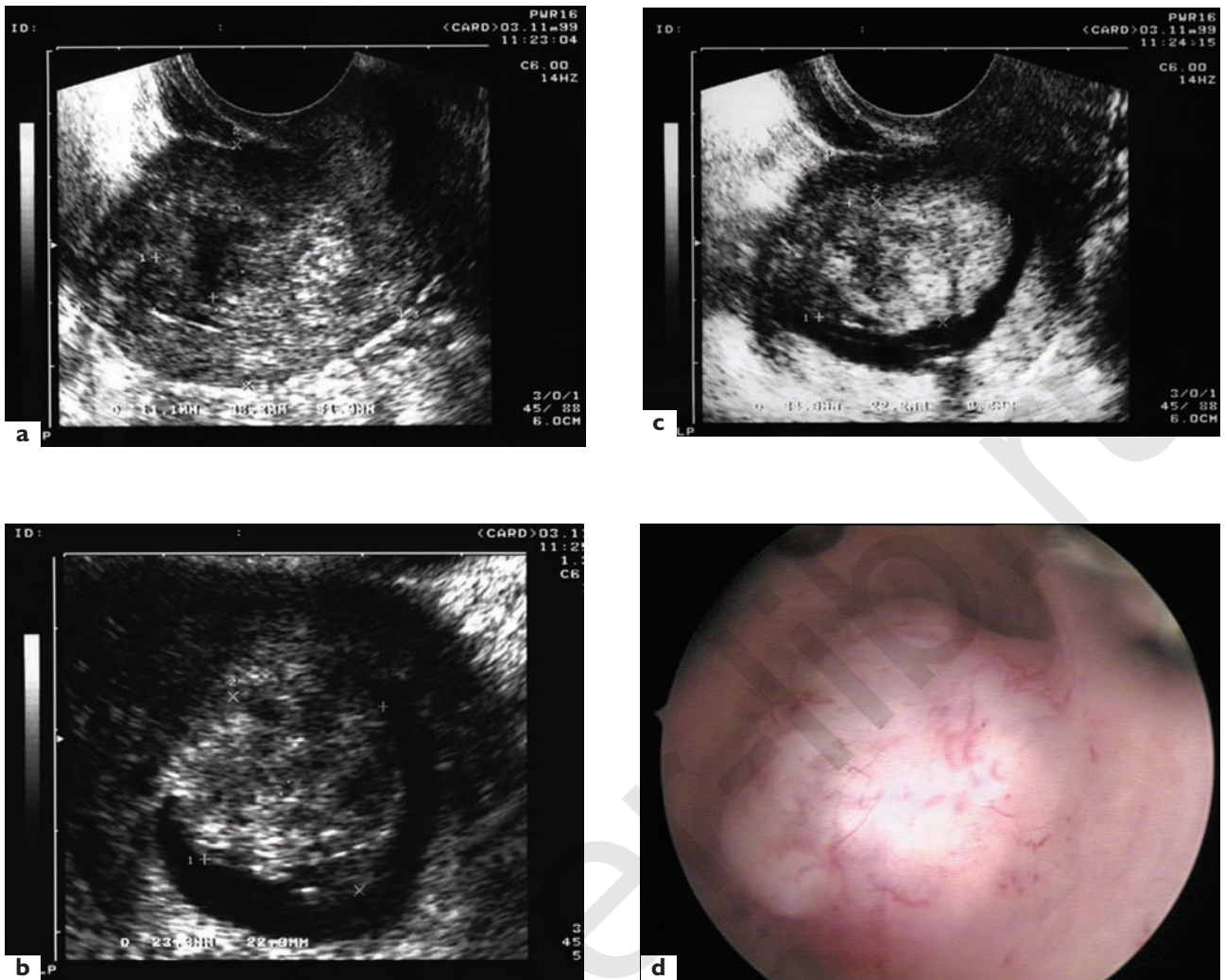


Figure 41.5 A 40-year-old patient with menorrhagia. (a) Transvaginal sonography, sagittal view, shows the normal uterine size, and suspicion of a mass effect inside the uterus with irregular limits; (b) and (c) saline infusion sonohysterography provides visualization of a pure submucosal myoma of 22 × 22 mm; (d) hysteroscopic view (note atrophic endometrium due to gonadotropin releasing hormone (GnRH) agonist treatment)

which SIS was compared with pathological findings in 52 women (mean age 41 years, range 29–58 years). Adenocarcinomas were excluded, and SIS correctly diagnosed two-thirds of cases of endometrial hyperplasia. Clevenger-Hoeft *et al.*⁴ observed that premenopausal women with abnormal bleeding had a higher prevalence of polyps (43%), intracavitary myomas (21%) and intramural myomas (58%) than did premenopausal women without abnormal bleeding (respectively, 10%, 1% and 13%). It is essential that uterine pathologies are diagnosed, and, therefore, if a patient presents with abnormal bleeding, she must undergo the most thorough investigation in order to have the correct treatment. We suggest that women with multifocal or sessile lesions should undergo a guided biopsy procedure (hysteroscopy), and that polyps of

benign appearance should also be removed to control bleeding and eliminate the risk of intraepithelial neoplasia, especially in older women.

In 1998, Schwarzler *et al.*⁵ evaluated the use of transvaginal sonography, sonohysterography and diagnostic hysteroscopy for the preparatory assessment of the uterine cavity. The end-points were uterine abnormalities detected by operative hysteroscopy and histology. More than 100 patients with abnormal uterine bleeding were recruited. Uterine abnormalities were present in 53% of cases. The overall sensitivity of transvaginal sonography improved after sonohysterography (from 67 to 87%), as did the specificity (from 89 to 91%). The positive predictive value increased from 88 to 92% and the negative predictive value from 71 to 86%. The use of SIS also improved the

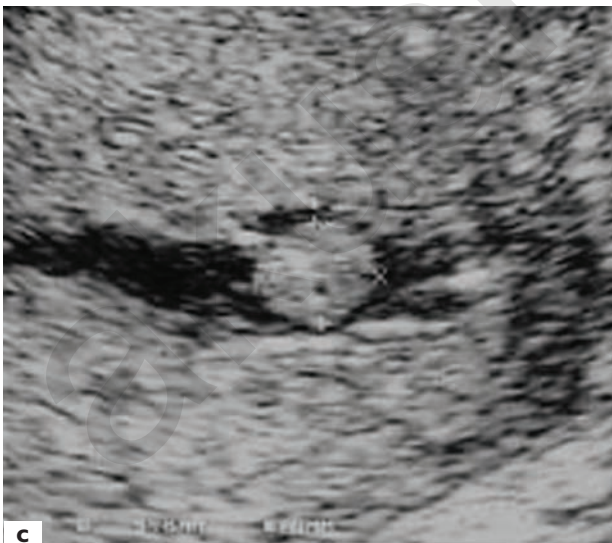
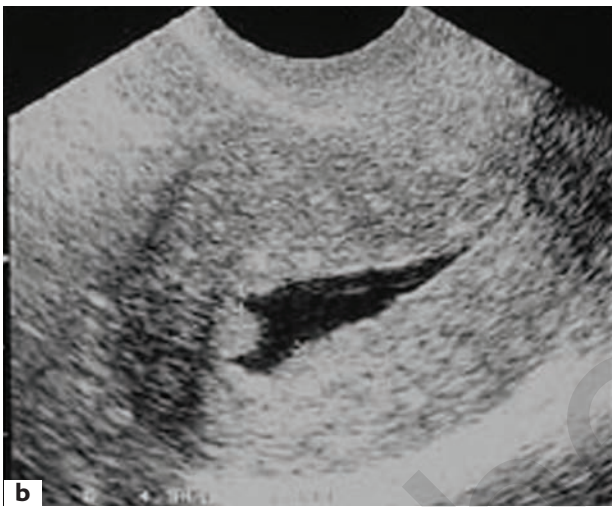
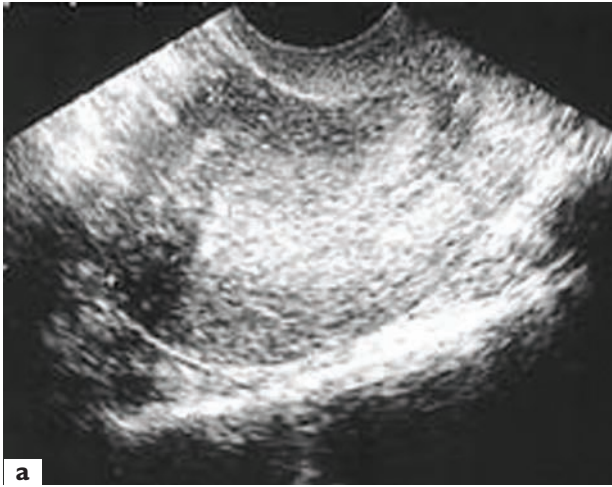
Figure 41.6 A 45-year-old patient with metrorrhagia. (a) Transvaginal sonography shows a normal appearance and thickness of the endometrium; (b) and (c) saline infusion sonohysterography provides visualization of a small fundal polyp

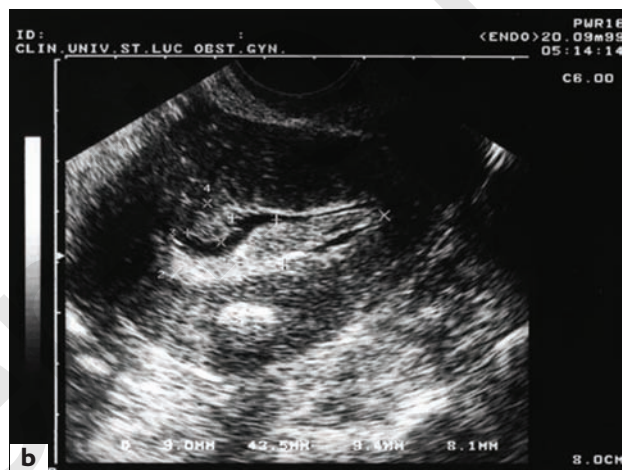
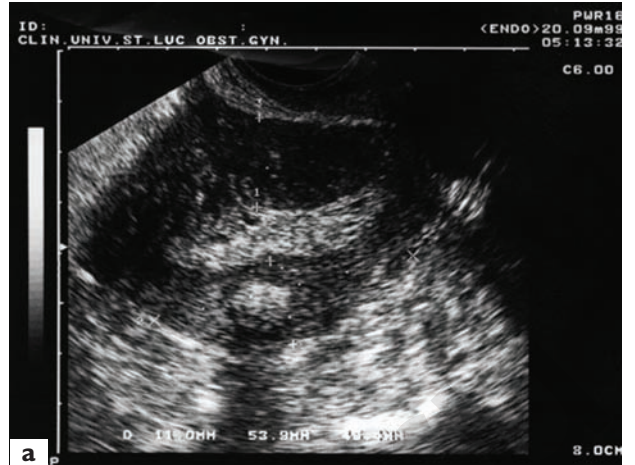
Figure 41.7 A 60-year-old patient taking tamoxifen. (a) Transvaginal sonography: endometrial thickness of 11 mm; (b) saline infusion sonohysterography shows two polyps, anterior 8 mm and posterior 9×20 mm (note atrophic endometrium)

quality of information about the localization and size of polyps and submucosal fibroids.

The use of saline infusion to enhance visualization of the endometrium increased the diagnostic accuracy of transvaginal sonography, and also provided some additional information. Thus, SIS is a simple, non-invasive and effective tool which may be used in the evaluation of patients, instead of diagnostic hysteroscopy.

Infertility and *in vitro* fertilization

Soares *et al.*⁶ evaluated the diagnostic accuracy of sonohysterography in uterine cavity diseases in infertile patients. Each patient underwent SIS, conventional transvaginal sonography, hysterosalpingography and hysteroscopy.

Sonohysterography was, in general, the most accurate test. Its diagnostic accuracy was markedly superior for polypoid lesions and endometrial hyperplasia, and in total agreement with the gold standard. In the diagnosis of intrauterine adhesions, SIS had limited accuracy, with a high false-negative diagnostic rate.

Gronlund *et al.*⁷ confirmed that sonohysterography is a simple, fast, well-tolerated and accurate method of investigating the uterine cavity in patients with metrorrhagia or infertility. However, we believe that, before any attempt at *in vitro* fertilization (IVF) is made, an outpatient hysteroscopy should be performed because, in our opinion, hysteroscopy remains the gold standard.

Hysterosalpingography is an alternative to hysteroscopy in some units, but involves ionizing radiation and referral to a radiology department. However, 10–35% of women with a normal cavity at hysterosalpingography have abnormal hysteroscopic findings. Magnetic resonance imaging is accurate in the diagnosis of congenital uterine abnormalities, but disadvantages include its high cost and limited availability.

In the study by Ayida *et al.*⁸, which compared SIS with office hysteroscopy, SIS had 87.5% sensitivity and 100% specificity (SIS was less able to discover uterine adhesions and small endometrial pathologies). Due to the high cost, and, in some countries, the limited accessibility of IVF, it may be better, from the cost/benefit point of view, to propose hysteroscopy before an IVF attempt.

Perimenopausal bleeding or screening

Cohen *et al.*⁹ proposed carrying out sonohysterography to detect intrauterine pathology before initiating hormone replacement therapy, because an endometrial thickness of less than or equal to 5 mm, measured by transvaginal sonography, excludes hyperplasia but does not eliminate other intrauterine pathologies that may be discovered by sonohysterography.

Postmenopausal bleeding

The endometrium in patients who are receiving hormone replacement therapy undergoes sequential changes, and cyclic bleeding occurs that is similar to the cyclic bleeding of the premenopausal endometrium. However, if other cyclic bleeding occurs, evaluation for hyperplasia, polyps or carcinoma must be performed (Figure 41.8).

For abnormal postmenopausal bleeding, O'Connell *et al.*¹⁰ proposed sonohysterography combined with endometrial biopsy. The combination of these reliable office tools correlated positively with the surgical findings (>95% of the time), with a sensitivity and specificity of 94% and 96%, respectively. More than 100 patients were enrolled, and SIS and endometrial biopsies were compared with fractional curettage with hysteroscopy. The conclusions were that SIS plus endometrial biopsy had a high specificity and predictive value and that SIS increased

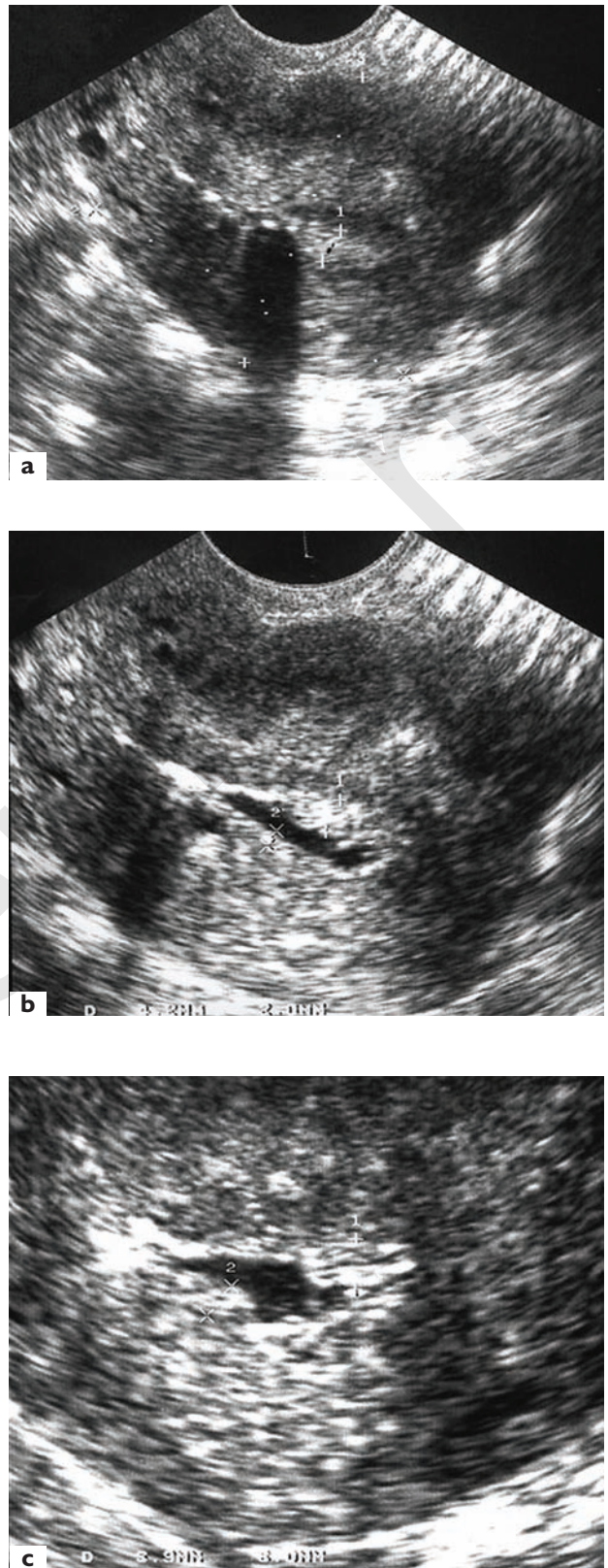


Figure 41.8 A 55-year-old patient with metrorrhagia. (a) Transvaginal sonography shows normal uterine size, and an endometrial thickness of maximum 5 mm but irregular; (b) and (c) saline infusion sonohysterography reveals irregular endometrium and pathological findings of adenocarcinoma

the sensitivity for the detection of intraluminal masses and was superior to routine vaginal probes in diagnosing intrauterine lesions in patients with postmenopausal bleeding.

However, Twu and Chen¹¹ studied women aged 50 years or over who presented with postmenopausal bleeding and underwent either D&C or endometrial biopsy. They followed all patients who experienced 77 cases of recurrent postmenopausal bleeding in the following 5 years, and in whom an initial diagnosis of benign tissue was made. After another D&C or endometrial biopsy, more than 20% of the patients were found to have endometrial cancer or complex endometrial hyperplasia. Patients aged over 65 years had a higher risk than others. For this reason, in order to have the most accurate test to exclude endometrial pathology in patients with postmenopausal bleeding, we always propose hysteroscopy with biopsy. If this examination is normal, transvaginal sonography may be proposed, to exclude benign tumors or ovarian cancer.

Monitoring asymptomatic postmenopausal breast cancer patients taking tamoxifen

In asymptomatic postmenopausal patients with breast cancer who are taking tamoxifen, the endometrial thickness is evaluated by transvaginal ultrasonography (Figure 41.7). If the thickness is more than 7–8 mm or irregular, or there is some doubt as to the measurement, then SIS is performed at the same time (Figure 41.9). In the case of intracavitary pathology, office hysteroscopy with biopsy is proposed to confirm the pathology, or, in the case of neoplasia, to evaluate the spread of the disease (whether the spread is to less than or more than half the uterine cavity or there is cervical invasion). If the intracavitary pathology seems to be benign, a hysteroscopic resection of the endometrial pathology is carried out under general or epidural anesthesia. In cases of neoplasia, a hysterectomy with bilateral salpingo-ovariectomy is carried out.

Summary

Sonohysterography is superior to unenhanced transvaginal sonography^{12,13}. SIS is recommended as a minimally invasive tool in the assessment of endometrial changes in asymptomatic, postmenopausal breast cancer patients on long-term tamoxifen therapy with a thickened endometrium, or inadequately visualized endometrial echo on transvaginal sonography. In cases of metrorrhagia, we always prefer to perform office hysteroscopy with biopsy. There is a place for screening and follow-up of endometrial pathology in patients taking tamoxifen if they have other risk factors, such as high blood pressure, obesity, diabetes or a previous history of endometrial pathology before taking tamoxifen.

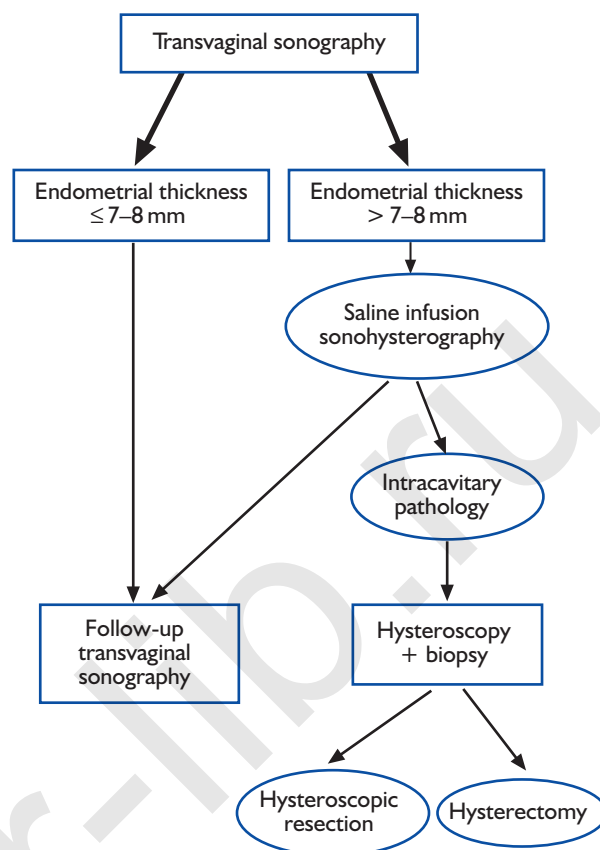


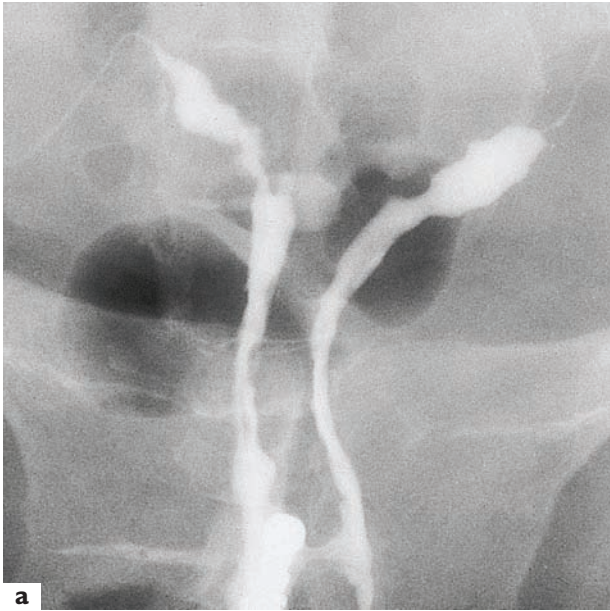
Figure 41.9 Evaluation of postmenopausal patients treated with tamoxifen

HYSTEROSCOPY IN THE DIAGNOSIS OF SPECIFIC DISORDERS

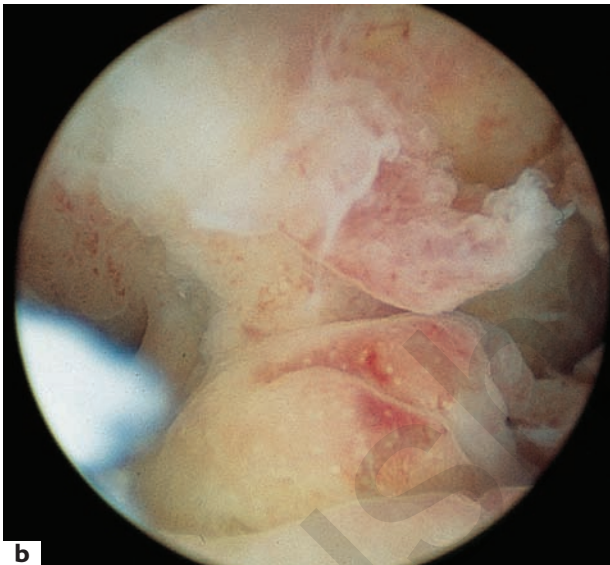
A wide variety of conditions can be diagnosed hysteroscopically, and hysteroscopy has become a diagnostic gold standard against which other methods are assessed. Conditions amenable to hysteroscopic diagnosis include abnormal uterine bleeding, infertility and recurrent abortion, uterine and cervical cancer, location of intrauterine devices, complicated abortion and fetal examination. Physiological studies are also possible.

Infertility

Hysteroscopy is becoming an important tool in the evaluation of infertility in women¹⁴. Evaluation of the endometrial cavity by either hysterosalpingography or hysteroscopy should be performed early. Hysteroscopic abnormalities are common in infertile patients; intrauterine abnormalities have been detected in 19–62% of infertile women in some studies¹⁵. Abnormal findings include intrauterine synechiae, Müllerian fusion defects (arcuate, septate or bicornuate uterus), endometrial polyps and submucous myomas.



a



b

Figure 41.10 Müllerian abnormalities. (a) Hysterothelangiography reveals the presence of a complete uterine septum. Note the presence of fistula between the two cervical canals and of endometrial polyps. (b) Hysteroscopy confirms the diagnosis of both septum and polyps

Müllerian anomalies

Müllerian anomalies may be associated with normal fertility, infertility or recurrent abortion. The extent of the anomaly can range from complete agenesis of the Müllerian system to minimal deformities of the uterine form. Diagnosis usually requires combined hysteroscopy and laparoscopy. The presence of a uterine filling defect at

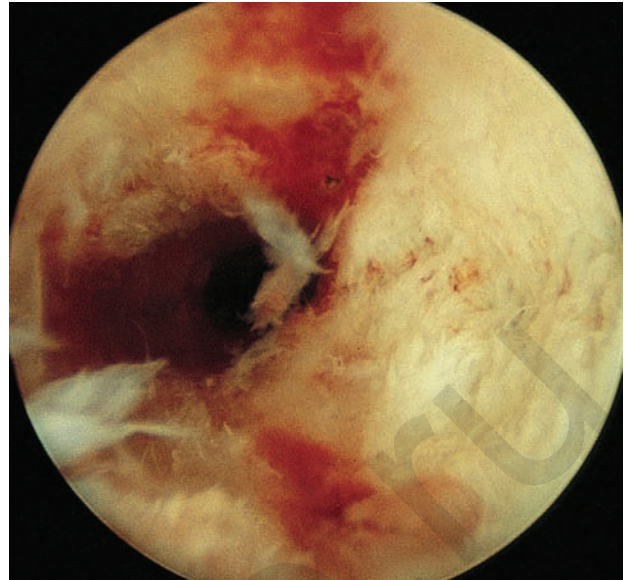


Figure 41.11 Intrauterine adhesions

hysterosalpingography or at hysteroscopy should be further evaluated by laparoscopy. The defect may represent a uterine septum (Figure 41.10), a bicornuate uterus or a submucous myoma. Rudimentary uterine horns, another form of Müllerian anomaly, can be detected laparoscopically and their relationship with the main cavity evaluated hysteroscopically.

Intrauterine synechiae

Traumatic intrauterine adhesions (Asherman's syndrome) (Figure 41.11) usually result from manipulation of the endometrial cavity following pregnancy. Curettage performed postpartum or following an abortion may cause scarring and synechiae secondary to destruction of the basal layer of the endometrium. Patients may present with hypomenorrhea, amenorrhea, infertility or spontaneous pregnancy loss. Recurrent abortion and abnormalities of implantation and placental development have also been described in association with this condition.

Intrauterine synechiae can be diagnosed by hysterosalpingography or hysteroscopy. The hysterosalpingogram shows a small, fragmented and distorted uterine cavity. The hysteroscopic image consists of pale endometrial patches and fibrotic strands, crossing the endometrial cavity. The adhesions are paler than the surrounding endometrium.

A hysteroscopic diagnosis of intrauterine adhesions is essential, as the disease can be missed or mistakenly diagnosed by hysterosalpingography. Hysteroscopy also permits better assessment of the extent of adhesions, an important factor in determining therapy and prognosis.

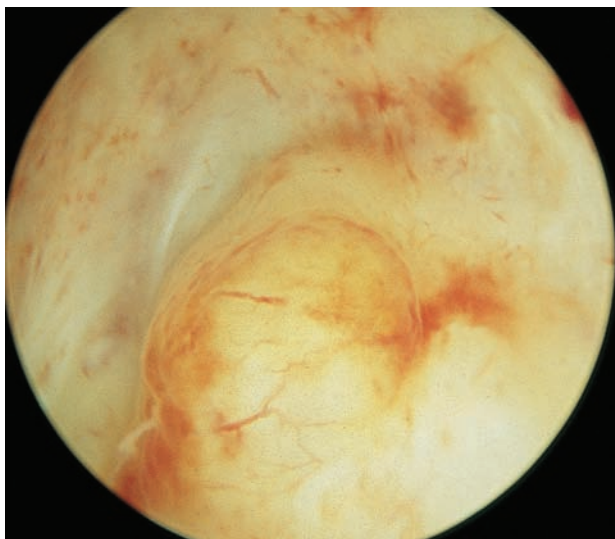


Figure 41.12 Submucous myoma

Submucous myomas

Uterine myomas can be found in a variety of locations. Those protruding into the uterine lumen are a common cause of abnormal uterine bleeding and may lead to infertility. Submucous myomas cause infertility by a variety of mechanisms related to embryo implantation. They can also cause preterm or dysfunctional labor. Submucous myomas are suspected in patients with enlarged uteri and those in whom filling defects are detected by hysterosalpingography. The hysterosalpingographic suspicion of the lesions should be confirmed by hysteroscopy. At hysteroscopy, the tumor is seen to protrude into the uterine cavity (Figure 41.12) and is covered with pale endometrium. Submucous myomas can be distinguished from endometrial polyps. In addition to providing a definitive diagnosis, hysteroscopy can reveal more accurately the localization of the tumor and permit better assessment of its size. The degree of intramural involvement cannot be determined.

Tubal disease

Involvement and occlusion of the intramural portion of the Fallopian tubes may be detected hysteroscopically. The significance of these lesions and their relationship to infertility has not been clearly established. Transuterine evaluation of tubal status prior to tuboplasty has been recommended¹⁶. The value of this method is debatable, however, as it is difficult to perform, and the same information can be obtained from a simple hysterosalpingogram.

Endometritis

Endometritis is a potential cause of infertility and recurrent pregnancy loss.

Sperm migration test

Hysteroscopy has been used to assess the survival of spermatozoa in the upper genital tract. Using a CO₂ hysteroscope, spermatozoa are obtained from the uterine cavity and the tubal ostia following intercourse, and their motility is assessed.

Gamete intrafallopian transfer and zygote intrafallopian transfer

Because the hysteroscope provides an excellent means of delivering instrumentation or substances to the Fallopian tubes from the uterine side, several techniques of intratubal manipulation have been attempted, such as tubal insemination and the postcoital test. More recently, hysteroscopy has been used with the techniques of gamete intrafallopian transfer (GIFT) and zygote intrafallopian transfer (ZIFT) to transfer the gametes or the zygote into the Fallopian tubes from the uterine side, rather than from the fimbriated end by laparoscopy or minilaparotomy.

It is possible that, with experience and the simplification of outpatient hysteroscopy, this may become a routine study for candidates for IVF, to evaluate the maturity or dysmaturity of the endometrium and predict the likelihood of implantation¹⁷. Furthermore, transfer of the early embryo can be accomplished under visual control.

Abortion

In cases of abortion, hysteroscopy is useful to check the presence or absence of trophoblastic tissue (Figure 41.13). Echography, computed tomography, magnetic resonance imaging and hysteroscopy can help in the diagnosis of a suspected hydatidiform mole (Figure 41.14).

Abnormal uterine bleeding

The common causes of abnormal uterine bleeding differ with age. In the early pubertal years, abnormal bleeding is usually dysfunctional, and is only rarely associated with an organic lesion. Dysfunctional bleeding often responds favorably to hormonal manipulation, and hysteroscopy is not usually needed. On occasion, however, persistent or severe bleeding may signal uterine pathology, such as endometrial polyps (Figure 41.15), myomas or adenomyosis (Figure 41.16). In the reproductive years, pregnancy-related complications are the most common cause of abnormal bleeding. Hysteroscopy is of value in some patients with retained products of conception following a spontaneous or induced abortion, which can be

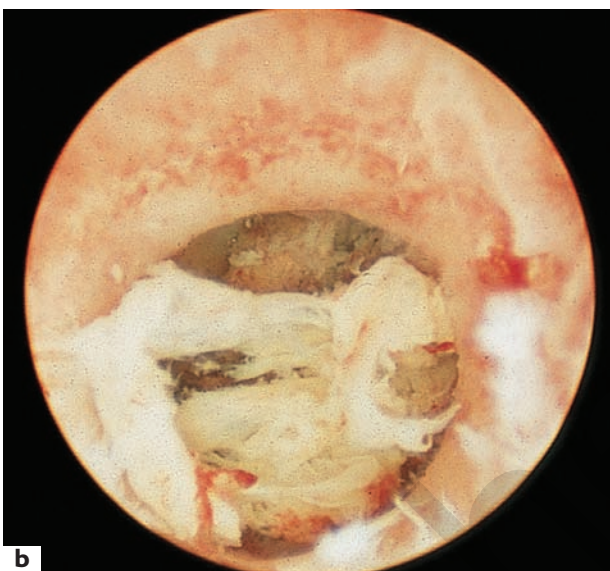
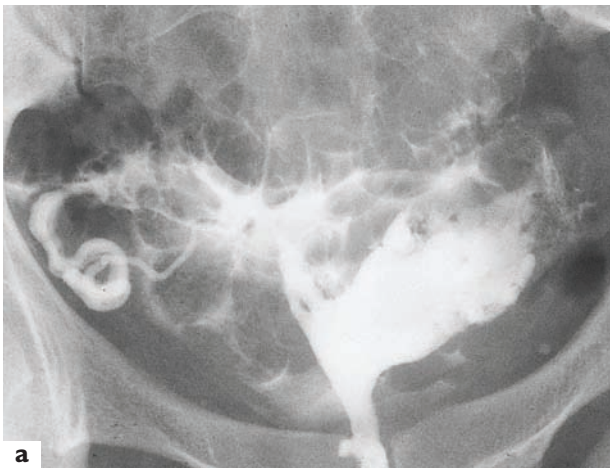


Figure 41.13 Uterine septum with residual trophoblastic tissue in the left horn: (a) hysterothorgraphy; (b) hysteroscopy

difficult to locate by dilatation and curettage. Uterine myomas and endometrial and cervical polyps are also a common cause of abnormal bleeding in this age group. Polyps tend to move with the flow of the distension medium, whereas submucous myomas, which may have a similar appearance, do not. Evaluation should consist of endometrial sampling, hysterosalpingography and hysteroscopy.

In postmenopausal women with abnormal uterine bleeding, uterine and cervical neoplasia must be excluded. Hysteroscopy can serve as an adjunct to other diagnostic methods in patients in whom abnormal bleeding persists. Atrophic endometrium, another common cause of bleeding in this age group, can easily be diagnosed at hysteroscopy. Endometrial polyps can sometimes also be detected in these patients.

Historically, dilatation and curettage (D&C) has been used as a diagnostic and, often, therapeutic tool. The diagnostic accuracy of D&C has been scrutinized in efforts to determine the sensitivity and specificity of the technique. Advantages of the hysteroscope in the evaluation of abnormal uterine bleeding include, most notably, the ability to see lesions and to evaluate the endometrial cavity more objectively¹⁸. Indeed, comparisons have been made between the results of hysteroscopically directed biopsy and D&C in treating patients. Valle¹⁸, Mohr¹⁹ and Gimpelson²⁰ all concluded that panoramic hysteroscopy, especially with directed biopsy, is superior to D&C in patients with uterine bleeding. Alternatively, Goldrath and Sherman combined out-patient panoramic hysteroscopy with suction curettage, and suggested the superiority of this technique to D&C in terms of diagnostic accuracy, cost, safety and convenience²¹.

Endometrial and cervical cancer

Hysteroscopy for abnormal bleeding can detect suspicious areas in the uterus and the cervix. The hysteroscopic appearance of endometrial carcinoma consists of exophytic or endophytic lesions. Polypoid or whitish areas may indicate necrosis within the tumor. The concern about cancer spread secondary to the hysteroscopic procedure has been addressed by various authors, and no evidence for its occurrence has been found^{22,23}. Hysteroscopic examination has been found to be reliable, particularly when difficulties are encountered in assigning the tumor to stage I or II.

The instrument may also be used in detecting premalignant endometrial lesions, such as polypoid or adenomatous lesions with dystrophic or dysplastic hyperplasia. The microhysteroscope can be of great value in detecting such early changes in patients with a known high risk of endometrial cancer, such as diabetics and obese individuals. Hysteroscopy can also provide an excellent view of the cervical canal, and can thus be used in the diagnosis of cervical neoplasia²⁴.

Assessing the extent of involvement

Joelsson *et al.* in 1971, used hysteroscopy to try to distinguish cervical infiltration by tumors²⁵. Clearly, if a tumor is seen growing within the endocervix, the endocervix is involved. However, the diagnosis of stage II carcinoma of the endometrium should be based on the histological contiguity of the endometrial carcinoma to normal cervical tissue (glands and stroma). This is not difficult if cervical glands or even the cervical squamous epithelium are contiguous to the cancer. However, this may be difficult if there is only stromal tissue with cancer, or if there is only cancer and no cervical tissue at all. To make a diagnosis of stage II endometrial cancer in both these cases, the specimen must come from the endocervix.

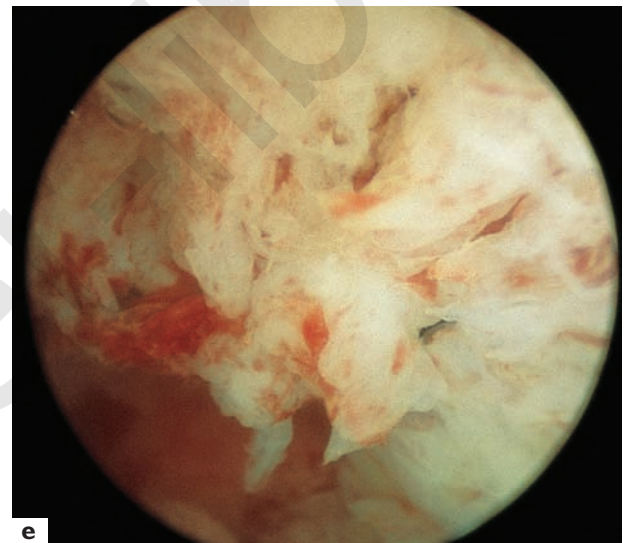
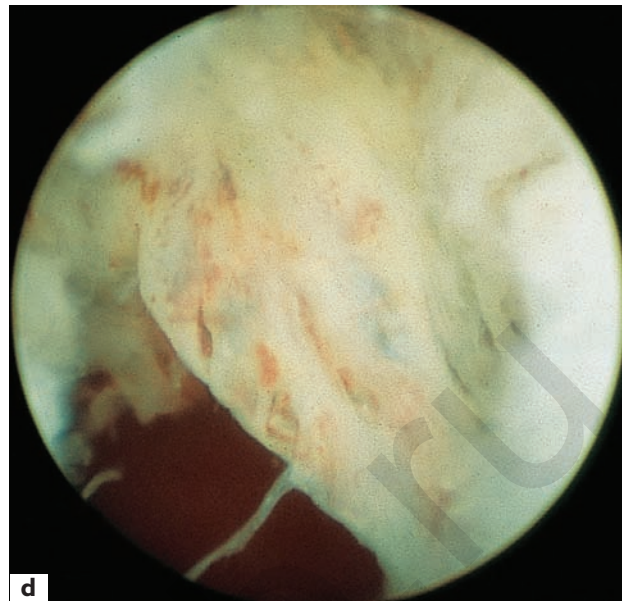
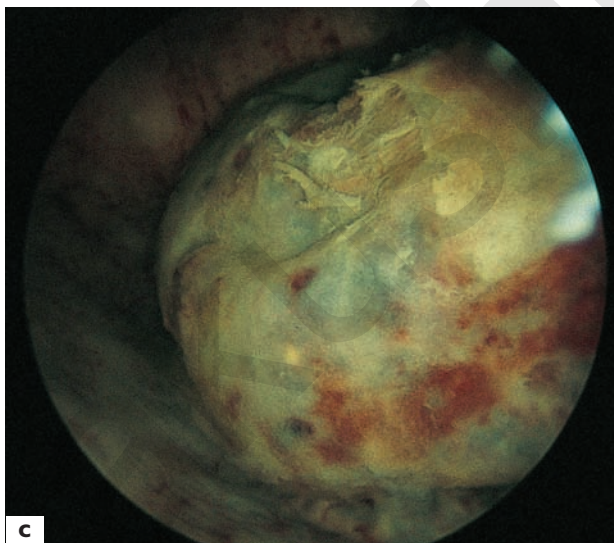
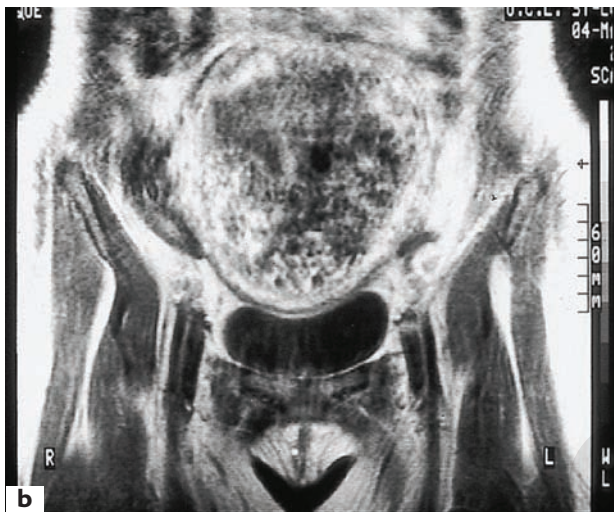
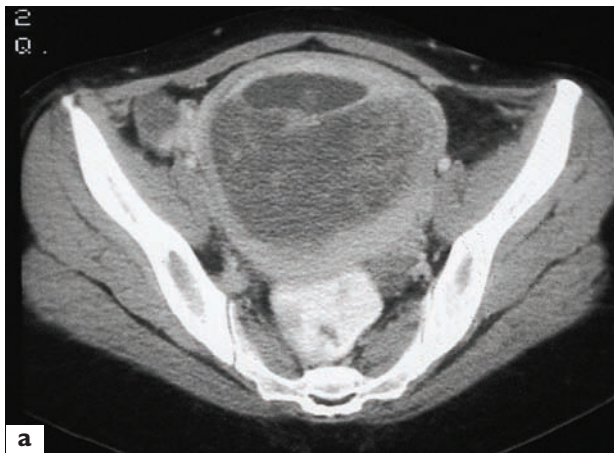


Figure 41.14 Hydatidiform mole: (a) computed tomography; (b) magnetic resonance imaging; (c)–(e) hysteroscopy

Such a biopsy requires experience rather than direct visualization of the biopsy site, because the small cup of even the Storz instrument will not yield sufficiently deep tissue. The most tantalizing aspect of this problem is that the more anaplastic adenocarcinomas and serous uterine papillary tumors may infiltrate the stroma of the

endocervix, but the endocervical canal may appear quite normal. A deep endocervical biopsy may be better than the hysteroscope for detecting such cases of endometrial cancer. In patients with superficial infiltration of the upper endocervix by endometrial cancer, hysteroscopy will certainly provide a precise topographic description of the

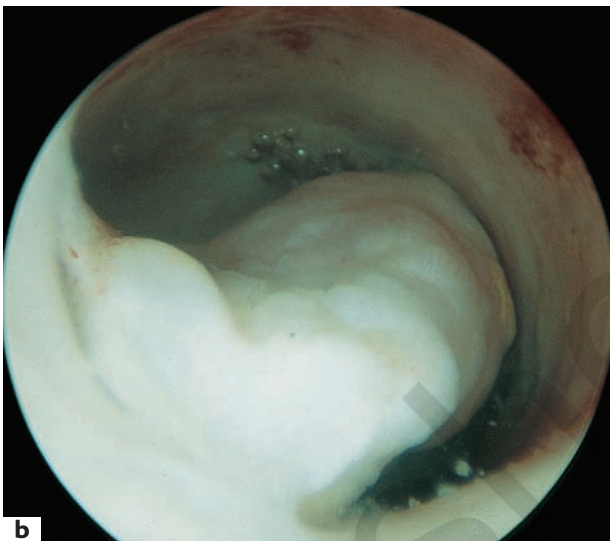
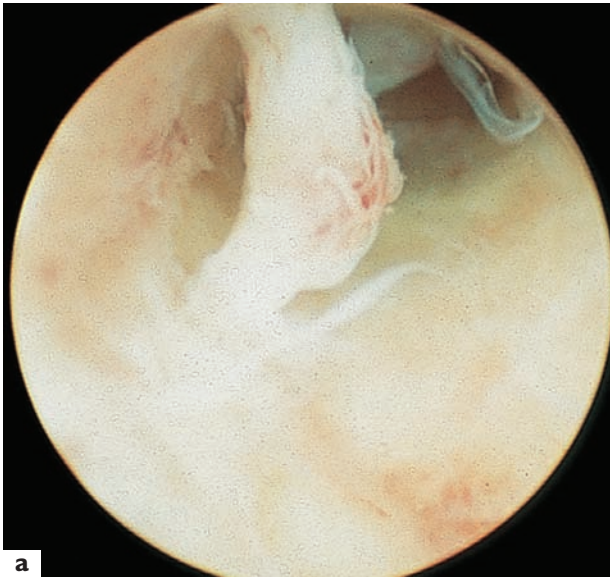

Figure 41.15 (a) Small endometrial polyp in the left uterine horn; (b) larger polypoid structure

lesion. Magnetic resonance imaging allows suspicion or diagnosis of the myometrial infiltration, but the final diagnosis, however, still needs to be histological. Furthermore, such early superficial spread to the endocervix probably carries no worse a prognosis than a stage I lesion. Deep cervical infiltration is a danger signal for deep myometrial invasion and lymph node involvement²⁶. The danger of tumor cell dissemination by Hyskon[®] or saline solution or even by the flow of CO₂ into the uterine veins is probably not great. Data from hysteroographies showed that there was no greater frequency of metastases among patients who had undergone hysteroigraphy than among those who had not²⁷.

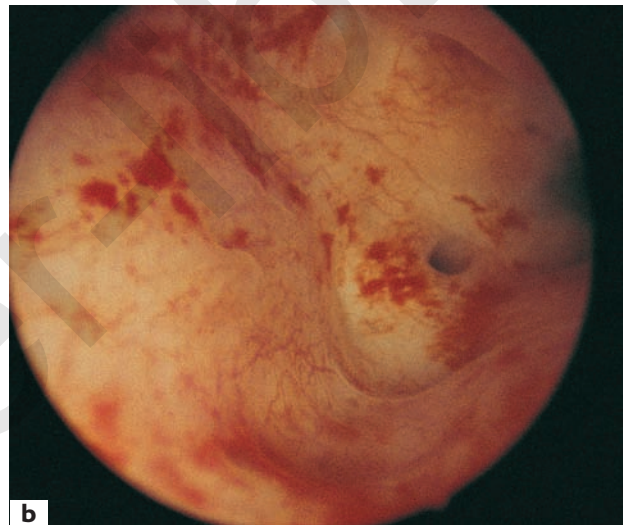
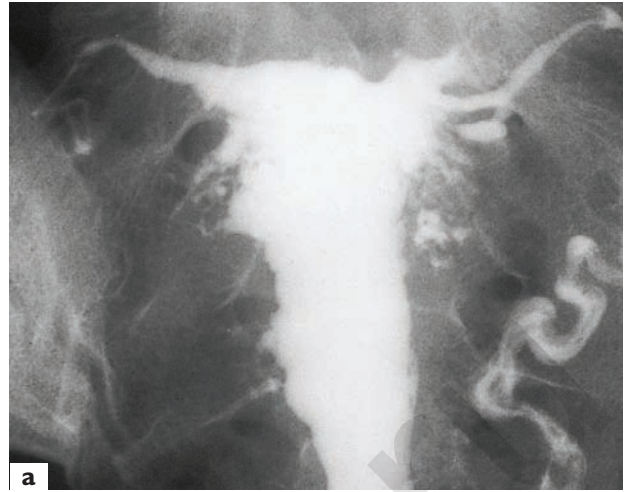


Figure 41.16 Adenomyosis: (a) hysteroigraphy; (b) hysteroscopy reveals holes in the uterine cavity

Intrauterine foreign bodies

Until recently, foreign bodies within the uterine cavity were not uncommon. The most common offender is still the intrauterine device (IUD), which often becomes misplaced, making retrieval desirable. Several papers have described the usefulness of hysteroscopy in locating displaced IUDs²⁷⁻²⁹. Four patients with retained intrauterine fetal bones examined hysteroscopically have been described³⁰. The bones were removed with hysteroscopic instruments in all patients. Other uncommon uses of the hysteroscopic approach include the removal of a Heyman capsule³¹ and the broken tip of a plastic suction curette³².

REFERENCES

1. Deichert U, van de Sandt M, Lauth G, et al. Transvaginal contrast hysterosonography. A new diagnostic procedure for the differentiation of intrauterine and myometrial findings. *Geburtshilfe Frauenheilkd* 1988; 48: 835–44
2. Alcazar JL, Errasti T, Zornoza A. Saline infusion sonohysterography in endometrial cancer: assessment of malignant cells dissemination risk. *Acta Obstet Gynecol Scand* 2000; 79: 321–2
3. Chittacharoen A, Theppisai U, Linasmita V, et al. Sonohysterography in the diagnosis of abnormal uterine bleeding. *J Obstet Gynecol Res* 2000; 26: 277–81
4. Clevenger-Hoeft M, Syrop CH, Stovall DW, et al. Sonohysterography in premenopausal women with and without abnormal bleeding. *Obstet Gynecol* 1999; 94: 516–20
5. Schwarzler P, Concin H, Bosch H, et al. An evaluation of sonohysterography and diagnostic hysteroscopy for the assessment of intrauterine pathology. *Ultrasound Obstet Gynecol* 1998; 11: 337–42
6. Soares SR, Barbosa dos Reis MM, Camargos AF. Diagnostic accuracy of sonohysterography, transvaginal sonography, and hysterosalpingography in patients with uterine cavity diseases. *Fertil Steril* 2000; 73: 406–11
7. Gronlund L, Hertz J, Helm P, et al. Transvaginal sonohysterography and hysteroscopy in the evaluation of female infertility, habitual abortion or metrorrhagia. A comparative study. *Acta Obstet Gynecol Scand* 1999; 78: 415–18
8. Ayida G, Chamberlain P, Barlow D, et al. Uterine cavity assessment prior to in vitro fertilization: comparison of transvaginal scanning, saline contrast hysterosonography and hysteroscopy. *Ultrasound Obstet Gynecol* 1997; 10: 59–62
9. Cohen MA, Sauer MV, Keltz M, et al. Utilizing routine sonohysterography to detect intrauterine pathology before initiating hormone replacement therapy. *Menopause* 1999; 6: 68–70
10. O'Connell LP, Fries MH, Zeringue E, et al. Triage of abnormal postmenopausal bleeding: a comparison of endometrial biopsy and transvaginal sonohysterography versus fractional curettage with hysteroscopy. *Am J Obstet Gynecol* 1998; 178: 956–61
11. Twu NF, Chen SS. Five-year follow-up of patients with recurrent postmenopausal bleeding. *Chung Hua I Hsueh Tsa Chih (Taipei)* 2000; 63: 628–33
12. Elhelw B, Ghorab MN, Farrag SH. Saline sonohysterography for monitoring asymptomatic postmenopausal breast cancer patients taking tamoxifen. *Int J Gynecol Obstet* 1999; 67: 81–6
13. Cohen I, Beyth Y, Tepper R. The role of ultrasound in the detection of endometrial pathologies in asymptomatic postmenopausal breast cancer patients with tamoxifen treatment. *Obstet Gynecol* 1998; 53: 429–38
14. Taylor PJ. Correlations in infertility: symptomatology, hysterosalpingography and hysteroscopy. *J Reprod Med* 1983; 8: 339–42
15. Lindemann HJ. Hysteroscopy for the diagnosis of intrauterine causes of sterility. Presented at the World Congress on Fertility and Sterility, Kyoto, Japan, October 1971
16. Quinones GR, Alvarado DA, Aznar RR. Tubal catheterization: applications of a new technique. *Am J Obstet Gynecol* 1974; 114: 674–9
17. Bordt J, Belkien L, Vancaillie T, et al. Ergebnisse diagnostischer Hysteroskopien in einem IVF/ET Program. *Geburtshilfe Frauenheilkd* 1984; 44: 813–15
18. Valle RF. Hysteroscopic evaluation of patients with abnormal uterine bleeding. *Surg Gynecol Obstet* 1981; 153: 521–6
19. Mohr JW. Hysteroscopy as a diagnostic tool in postmenopausal bleeding. In Philips JM, ed. *Endoscopy in Gynecology*. Downey, CA: American Association of Gynecologic Laparoscopists, 1978: 347–50
20. Gimpelson RJ. Panoramic hysteroscopy with directed biopsies vs. dilatation and curettage for accurate diagnosis. *J Reprod. Med* 1984; 29: 575–8
21. Goldrath MH, Sherman AI. Office hysteroscopy and suction curettage: can we eliminate the hospital diagnostic dilatation and curettage. *Am J Obstet Gynecol* 1984; 152: 220–9
22. Johnson JE. Hysteroscopy and diagnostic curettage in carcinoma of the uterine body. *Acta Radiol* 1973; 326 (Suppl 1): 1–79
23. Sugimoto O. Hysteroscopic diagnosis of endometrial carcinoma: a report of fifty-three cases examined at the Women's Clinic of Kyoto University Hospital. *Am J Obstet Gynecol* 1975; 121: 105–13
24. Hamou J. Microhysteroscopy: a new procedure and its original applications in gynecology. *J Reprod Med* 1981; 26: 375–82
25. Joelsson I, Levine RU, Moberger G. Hysteroscopy as an adjunct in determining the extent of carcinoma of the endometrium. *Am J Obstet Gynecol* 1971; 111: 696–702
26. Anderson B. Hysteroscopy and hysteroscopy in endometrial cancer. In Sciarra JJ, Buchsbaum HJ, eds. *Gynecology and Obstetrics*. New York: Harper & Row, 1980: 850–5
27. Siegler AM, Kemmann E. Location and removal of misplaced or embedded intrauterine devices by hysteroscopy. *J Reprod Med* 1976; 16: 139–44
28. Taylor PJ, Cumming DC. Hysteroscopy in 100 patients. *Fertil Steril* 1979; 31: 301–4
29. Valle RF, Sciarra JJ, Freeman DW. Hysteroscopic removal of intrauterine devices with missing filaments. *Obstet Gynecol* 1977; 49: 55–60
30. Chervenak FA, Amin HK, Neuwirth RS. Symptomatic intrauterine retention of fetal bones. *Obstet Gynecol* 1982; 59: 58–61S
31. Zipkin B, Rosenfeld DL. Hysteroscopic removal of a Heyman radium capsule. *J Reprod Med* 1979; 22: 133–4
32. Sciarra JJ, Valle RF. Hysteroscopy: a clinical experience with 320 patients. *Am J Obstet Gynecol* 1977; 127: 340–8

akusher-lib.ru

Office hysteroscopy

S Bettocchi, O Ceci, L Nappi, G Pontrelli, L Pinto, A Costantino, L Selvaggi

INTRODUCTION

Since the beginning of the 1980s, hysteroscopy has proved to be a powerful diagnostic tool for visualizing the cervical canal and uterine cavity. As an operative tool, it yields better results than those obtained with dilatation and curettage (D&C), or other blind procedures, and it can also be considered an excellent surgical aid in the treatment of endouterine pathologies¹⁻³. However, the two procedures, diagnostic and operative, were long considered separate entities, as they required different instruments and a different approach to the patient⁴. Diagnostic procedures were based on examination of the cervix and uterine cavity through the scope; the reliability of the diagnosis was related to the physician's experience, and was therefore extremely variable.

CERVICAL ANATOMY AND UTERINE INNERVATION

To understand better the 'technical' points that are discussed below, it is important to describe some anatomic details of the uterus.

The cervical canal

The external cervical orifice (ECO) appears circular (4–6 mm in width) in nullipara and as a transverse oval aperture (10–15 mm in width) in multipara. The cervical canal is approximately 3 cm long, including the internal cervical orifice or os (ICO), which has a diameter varying from 4 to 5 mm in nullipara, while it may be as much as 7–8 mm in multipara. The anterior and posterior walls of the cervical cavities, and also those of the corpus, incorporate a system of folds applied one on the other, consisting of a longitudinal ridge along the median line, known as the 'arbor vitae', with smaller secondary crests arising on the left and right of this, the 'plicae palmatae', or palmate folds, which extend mediolaterally and upward. Therefore, the two walls of the neck of the uterus, anterior and posterior, fit into one another. The arbor vitae tapers off and ends 5 mm before the ICO. The cervix is made of thick connective tissue containing relatively little smooth tissue. The innervation of the neck of the uterus includes receptors, syncytial networks and sympathetic and parasympathetic fibers⁵.

The uterine corpus

The myometrial layer consists of bands of muscle fibrocytes arranged on a fibroelastic support. Around each muscular fascia and among the fibrocytes are many different structures, including collagen fibrils running in various directions, isolated connective cells, blood vessels and amorphous matter. No sensitive nerve terminals have been demonstrated on the endometrial layer, unlike in the myometrium, which features medullary fibers branching out⁵.

THE 'TRADITIONAL' TECHNIQUE

The modern hysteroscopic technique was first described by various authors between the end of the 1970s and the beginning of the 1980s⁶⁻¹¹. For more than 10 years, the cervix and uterine cavity were examined using a diagnostic hysteroscope with a total diameter of 5 mm, consisting of a 4-mm rod lens system scope inserted in a simple sheath, necessary to guide the distension medium (CO₂) into the uterine cavity. A speculum was inserted in the vagina to visualize the portio and the ECO, while a tenaculum was used to facilitate insertion of the hysteroscope. To avoid pain related to application of the tenaculum, traction on the cervix and stimulation of the muscle fibers of the cervical canal, local anesthesia or a paracervical block was frequently used¹²⁻¹⁴. Diagnosis was based on 'visual' examination of the cervical canal and the uterine cavity; the reliability of the procedure was strictly related to the gynecologist's experience and, therefore, was not free from mistakes. To perform biopsies there were only two possibilities: 'blind' procedures (such as D&C, Vabra®, Pipelle®, etc.) or targeted hysteroscopic biopsies (THBs) using an operative sheath over the existing 4-mm scope. In the first case, owing to the blind nature of the procedure adopted, hysteroscopy could not really support the final diagnosis, while in the second case the advantage of performing a THB was offset by the need for dilatation of the cervical canal and related anesthesia due to the large diameter of the operative hysteroscope.

For a long time, throughout the 1980s, no significant technological improvements were reported in the field of hysteroscopes, while devices such as electronic pumps or endocameras were not yet available at a reasonable price. These problems, lasting so long a period, resulted in gynecologists failing to consider the possibility of new developments of the technique itself, and regarding the

above-described procedure as the standard (and only) technique.

Nowadays, instead, since new instruments have become available, physicians have the choice of continuing to work in the 'classic' way or modifying the technique to take advantage of new technological improvements.

THE NEW PHILOSOPHY

Since the introduction at the beginning of the 1990s of new scopes (especially fiberscopes) with a diameter ranging between 1.2 and 3 mm, it has been possible to produce not only very thin diagnostic sheaths, but also operative sheaths with a diameter equal to or less than 5 mm. This has enabled physicians to utilize, for diagnostic procedures, an operative scope equipped with mechanical instruments and with a final diameter not exceeding 5 mm. The possibility of visual examination of the uterine cavity and contextual operative facilities has provided endoscopists with the perfect 'diagnostic' tool; they can examine the cavity and take THBs thanks to visualization of the suspected areas.

After acquiring enough experience in 'handling' an operative hysteroscope equipped with miniaturized instruments, physicians will be able in a short time not only to perform a THB but also to treat benign intrauterine pathologies, such as polyps and synechiae, without any premedication or anesthesia. This has been defined as a 'see and treat' procedure⁴; there is no longer a distinction between diagnostic and operative procedures, but rather a single procedure in which the operative part is perfectly integrated with the diagnostic work-up.

One of the newest hysteroscopes is the office continuous flow operative hysteroscope, size 5 (Storz, Tuttlingen, Germany), based on a 2.9-mm rod lens system, with an outer diameter corresponding to 5.0 mm. Recently, a thinner version has been developed based on a revolutionary 2.0-mm rod lens system that reduces the final diameter of the hysteroscope to 4.0 mm (office continuous flow operative hysteroscope, size 4; Storz). Both instruments feature two sheaths (one for irrigation and the other for suction) and an operative 5F canal (approximately 1.6 mm), and are oval in shape, ideal for atraumatic insertion of the scope into the cervix. Distension of the uterus is obtained using an electronic suction-irrigation pump (Endomat®; Storz) that can maintain a constant intrauterine pressure around 30–40 mmHg, necessary to avoid overdistension of the muscle fibers and hence patient discomfort. Various 5F mechanical instruments, as well as 5F bipolar electrodes, are now available.

It is important to remember that, as pointed out above, sensitive innervation in the uterus starts from the myometrium outward, while the endometrium and any fibrotic tissue present are not sensitive. This is the rationale behind assuring that the hysteroscopic procedure can be performed without any analgesia or anesthesia, provided

that some basic rules to avoid patient discomfort are respected.

THE VAGINOSCOPIC APPROACH

The availability of light endocameras at a reasonable price has made it possible for the physician to handle the hysteroscope while seated comfortably on a chair, and without the limits described above. Therefore, the use of a speculum and tenaculum is no longer necessary; the vagina, being a cavity, can be distended by introducing a distension medium, in order to locate the cervical canal, so there is no more need to 'assist' the introduction of the scope into the cervix using the tenaculum. The anatomy can be followed by gentle movements of the hands that will correctly drive the hysteroscope into the cervix and through the ICO.

This method, which has been defined as the 'vaginoscopic approach'¹⁵, has definitively eliminated any patient discomfort associated with the traditional approach to the uterus. The vagina is distended using the same medium (saline solution) and at the same pressure (around 30–40 mmHg) as that used for subsequent distension of the uterine cavity. There is no need to close the vulvar labia using the fingers because the 'weight' of the liquid is enough to distend the vagina and provide correct visualization of the portio.

Our recent data on over 10 000 hysteroscopic procedures performed using the above technique confirm the previously published report¹⁵ of strongly increased patient compliance: 98.9% of patients suffered no discomfort related to the approach to the uterus and insertion of the scope into the cervix.

Those incidental causes of pain that complicated the procedure have thus been eliminated. Only in the presence of clinical or subclinical signs of a vaginal infection is hysteroscopy subordinated to the results of a vaginal smear¹⁵. This technique has permitted complete elimination of any type of premedication, analgesia or anesthesia, making the procedure faster and complication-free.

THE OBSTACLE OF THE INTERNAL CERVICAL OS

One of the major problems for endoscopists is passage of the hysteroscope through the ICO, which usually represents a technical obstacle causing related pain for the patient. It has already been pointed out that the ICO is normally oval, with a transverse main axis and a diameter of approximately 4–5 mm. Therefore, if we want to insert a round hysteroscope of size 5 mm through it, we will have to modify the spatial disposition of the muscle fibers, stretching some of them (Figure 42.1). This maneuver will stimulate the sensitive fibers, causing pain for the patient.

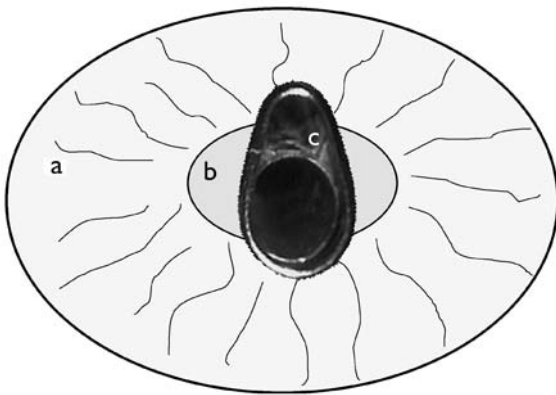


Figure 42.1 Perspective view of the internal cervical os and the hysteroscope profile in a traditional introduction. a, cervix; b, internal cervical os; c, hysteroscope profile

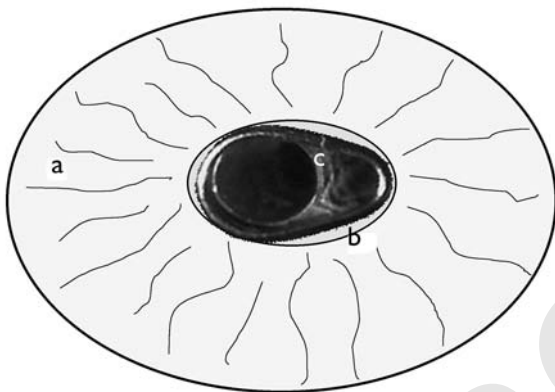


Figure 42.2 Perspective view of the internal cervical os and hysteroscope profile after 90° rotation. a, cervix; b, internal cervical os; c, hysteroscope profile

The new generation of hysteroscopes, featuring an oval profile and a total diameter between 4 and 5 mm, is more strictly correlated to the anatomy of the cervical canal. It is sufficient to rotate the scope on the endocamera by 90°, to align the longitudinal main axis of the scope with the transverse axis of the ICO (Figure 42.2).

Another problem for the physician concerns the view through the hysteroscope, deflected by 12–30° (typical of all modern Rod Lens System-based hysteroscopes), which is particularly useful inside the uterine cavity but can complicate insertion of the scope into the narrow cervical canal. In fact, what the endoscopist sees positioned in the middle of the screen is, in reality, located 30° (or 12°, depending on the scope) lower. Therefore, the required image (i.e. the cervical canal) should appear in the lower half of the screen and not in its center (Figures 42.3 and 42.4). In this way, the scope will be located in the middle of the canal, avoiding stimulation of the muscle fibers.

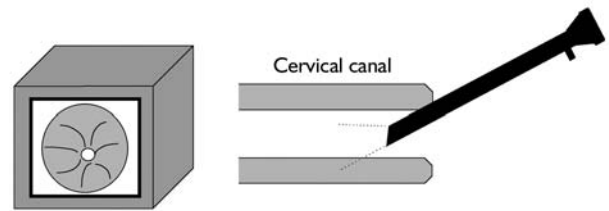


Figure 42.3 Wrong view on the screen, corresponding to wrong alignment of the instrument with the cervical canal

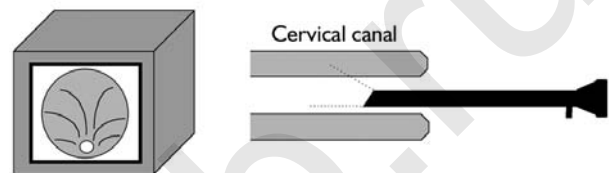


Figure 42.4 Correct view on the screen, corresponding to correct alignment of the instrument with the cervical canal

DISTENSION OF THE UTERINE CAVITY

The approach used to insert the scope, the diameter of the hysteroscope and the distension of the uterine cavity are all factors of extreme importance in reducing patient discomfort during an out-patient examination. A correct flow of between 200 and 350 ml/min, together with negative aspiration of around 0.2 bar, is normally sufficient to obtain good dilatation of the uterine cavity, at approximately 30–40 mmHg¹⁶. These values, lower than the 70 mmHg present within the tubes for the abdominal counter-pressure¹⁷, prevent the distension medium from passing into the abdomen, and thus eliminate pain and the risk of vagal reflex. While it is true that, with the use of CO₂, these principles do not depend on the anatomic situation of the cervical canal, it is still practically impossible to obtain adequate distension and a clear view using liquid distension without a continuous flow hysteroscope. The problem occurs when the cervical canal and the ICO are the same size or smaller than the hysteroscope. The liquid drains into the uterine cavity, because it cannot flow out or pass through the tubes into the abdomen. The view will be unclear due to the presence of hanging mucosa particles. In these cases, many endoscopists use compression cuffs to raise the flow and hence the pressure. However, the compressed liquid, as it cannot flow out of the cervical canal, will be forced to move into the abdomen through the tubes, causing pain and risk to the patient.

Today, owing to improvements in technology and the wide availability of small-diameter continuous flow

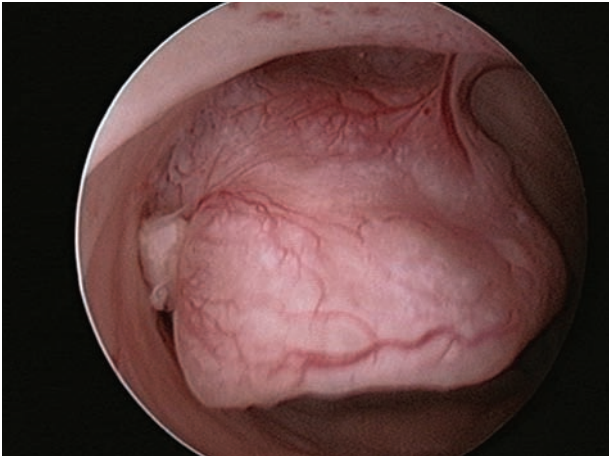


Figure 42.5 Endometrial cystic polyp

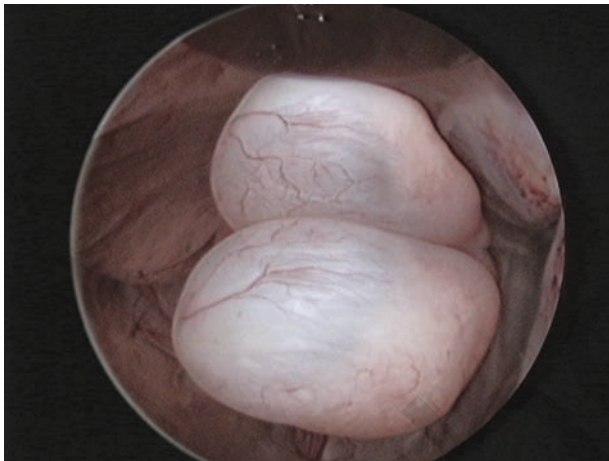


Figure 42.6 Endometrial cystic polyps

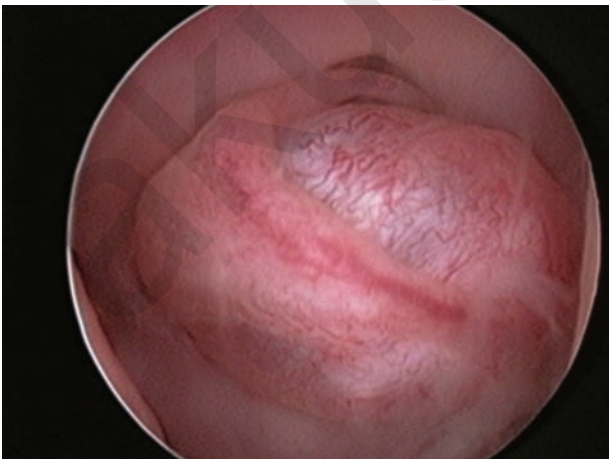


Figure 42.7 Endometrial polyps

hysteroscopes, liquid distension is normally used, together with an electronically controlled irrigation and suction device (Endomat). The various parameters of the device (flow, pressure, aspiration) are set to obtain an average distension of 25–45 mmHg. In the past, before the continuous flow sheath became available, we were compelled to use the single flow sheath designed for CO₂ examinations. In these cases, the saline solution was insufflated at atmospheric pressure (two 5-l bags connected by a urological ‘Y’ outflow and located 1.5 m above the patient). By doing so, we obtained a flow of 150–200 ml/min with a resulting endouterine pressure of around 40 mmHg, which created no problems. This technique worked if there was a positive difference between the diameter of the ICO and the diameter of the instrument. The liquid could flow out of the cavity through the small space around the hysteroscope as if it were a continuous flow sheath, and, in this way, wash the uterine cavity. However, in most cases the size of the cervical canal was insufficient to obtain this effect, and the result was stagnation of the liquid and consequently a poor view. Moreover, to perform even basic operative procedures (i.e. biopsies), the use of a continuous flow system together with an electronic suction–irrigation device is extremely advantageous.

EXAMINATION OF THE UTERINE CAVITY

For correct examination of the uterine cavity and to reduce patient discomfort it is advisable to use 30° lenses. In fact, once the tip of the scope is placed 1–1.5 cm from the fundus, a view of the whole cavity and tubal ostiae can be gained simply by rotating the instrument on its axis, without any other lateral movement of the scope being required, which might cause pain for the patient.

Improvements in technique and instrumentation have allowed physicians to achieve more reliable diagnostic results regarding diagnosis of the absence of pathology, as well as all the endocavitary benign pathologies, such as polyps, myomas, synechiae and septum (Figures 42.5–42.28). The only problem may be differential diagnosis between polyps and myomas, which can be difficult in the presence of large endocavitary pedunculated formations. In any event, bearing in mind that the type of surgical treatment required is the same for both of them, it is possible to claim satisfactory reliability of hysteroscopy also in these cases.

Problems for endoscopists arise, in contrast, when they have to diagnose forms of hyperplasia^{18–20} that, it must be emphasized, can be established only by pathological examination of the endometrium. Compared with traditional methods such as curettage, hysteroscopy offers the possibility of visualizing macroscopic or focal abnormalities suggestive of endometrial hyperplasia inside the uterine cavity, and of taking a biopsy under visual control (THB)^{1,2}. The lack of established hysteroscopic

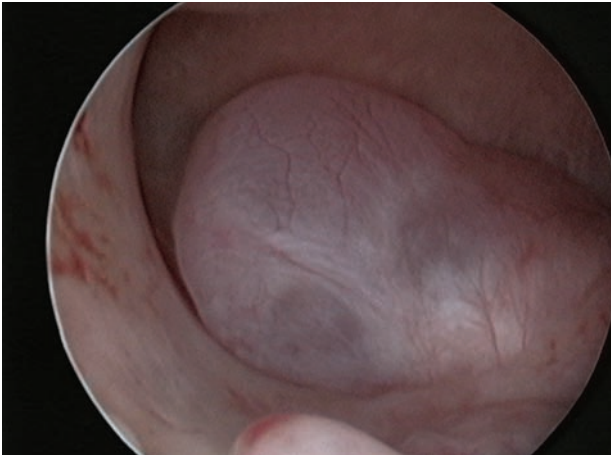


Figure 42.8 Endometrial cystic polyp

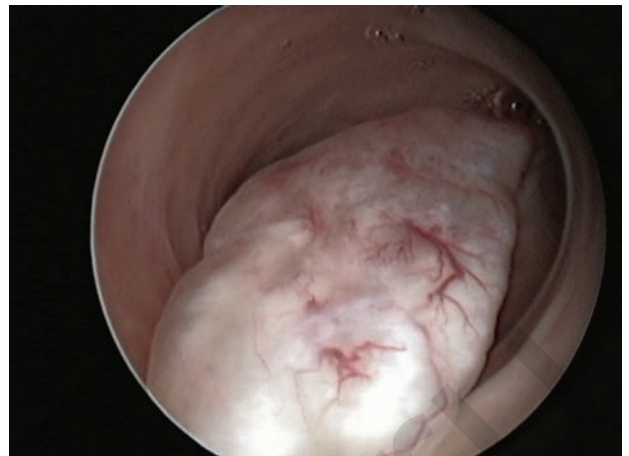


Figure 42.11 Endometrial polyp

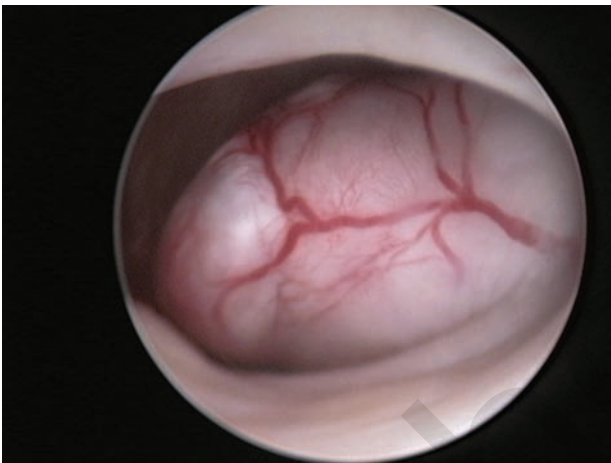


Figure 42.9 Submucous myoma

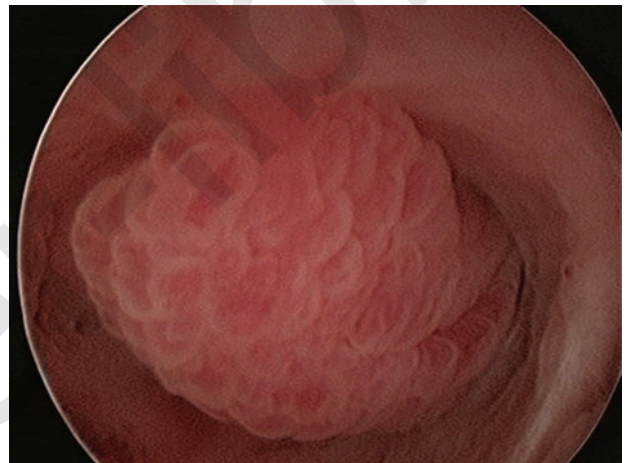


Figure 42.12 Polyp of the cervical canal

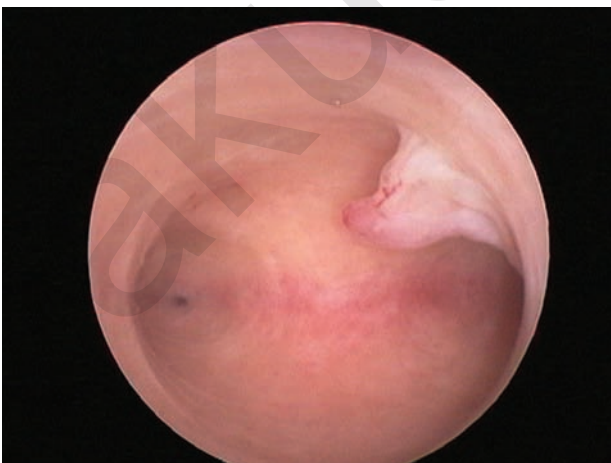

Figure 42.10 Endometrial polyp

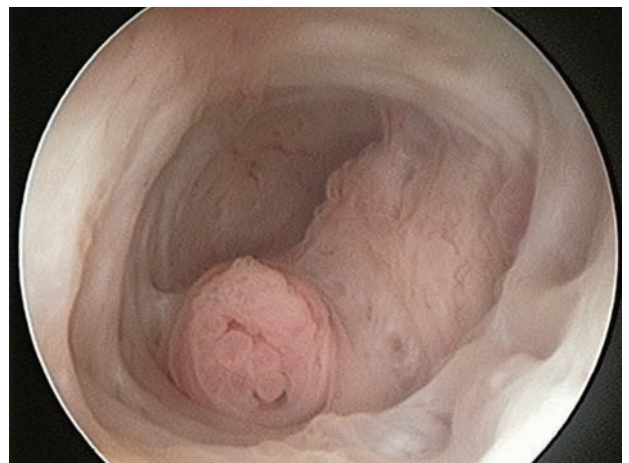

Figure 42.13 Polyp of the cervical canal

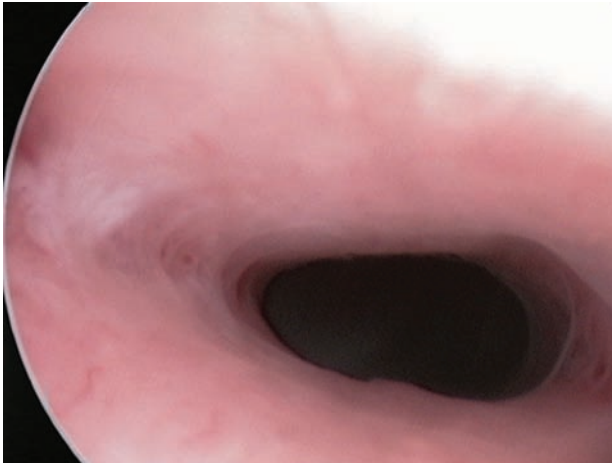


Figure 42.14 The external cervical oritice

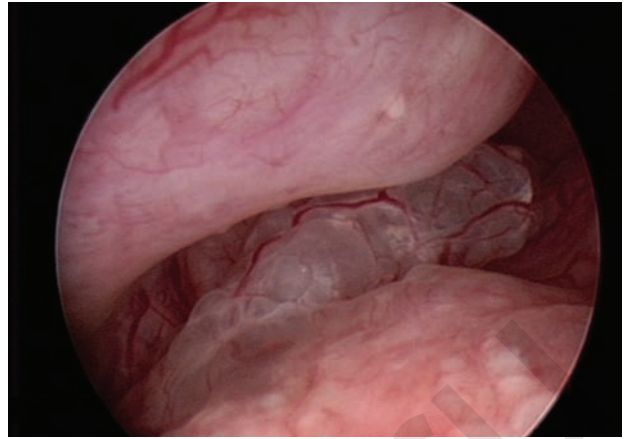


Figure 42.17 Cystic polyp

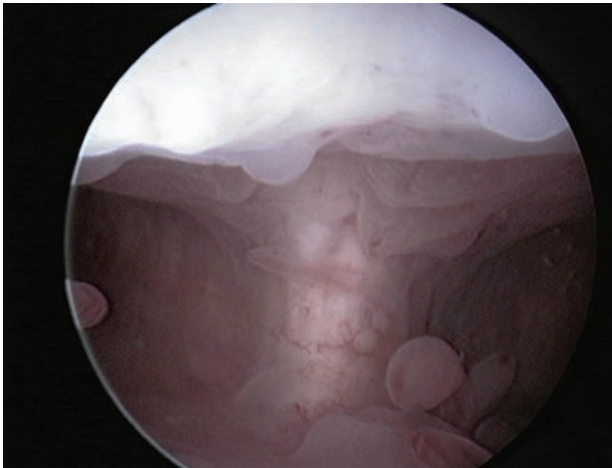


Figure 42.15 Uterine septum

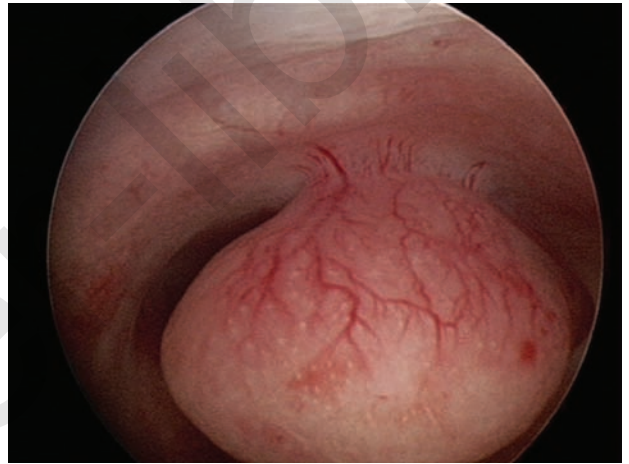


Figure 42.18 Pedunculated endometrial polyp

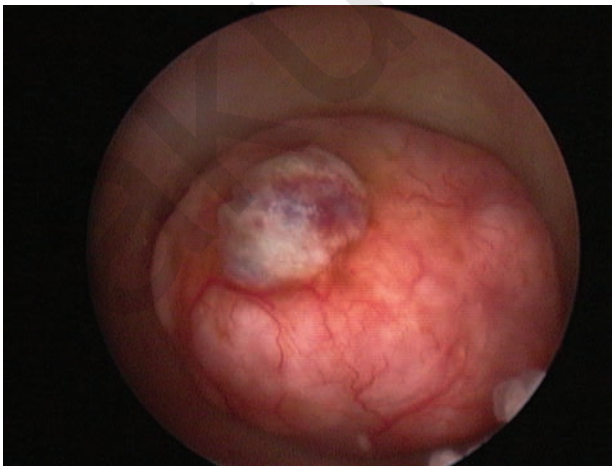


Figure 42.16 Submucous myoma

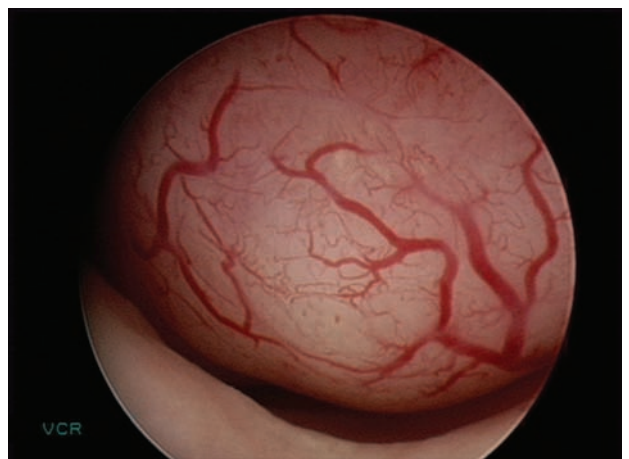


Figure 42.19 Submucous myoma

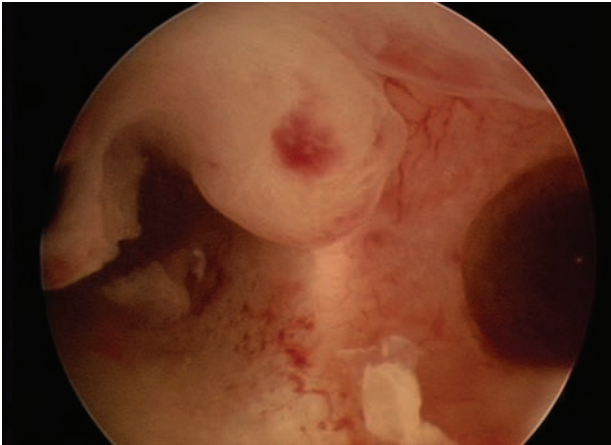


Figure 42.20 Uterine septum and an endometrial polyp

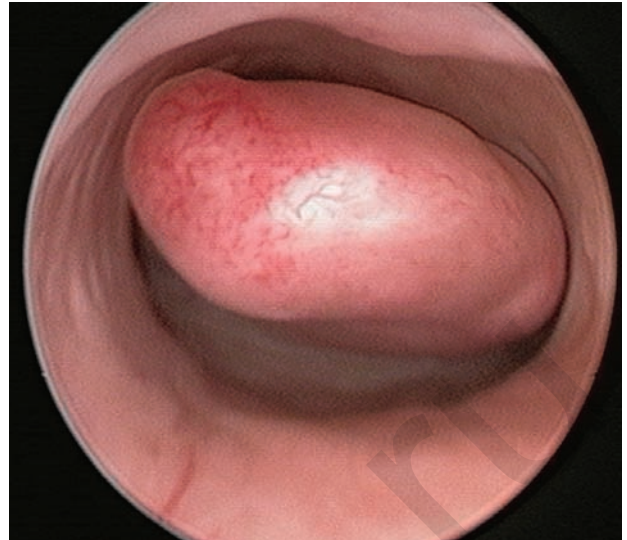


Figure 42.23 Endometrial polyp

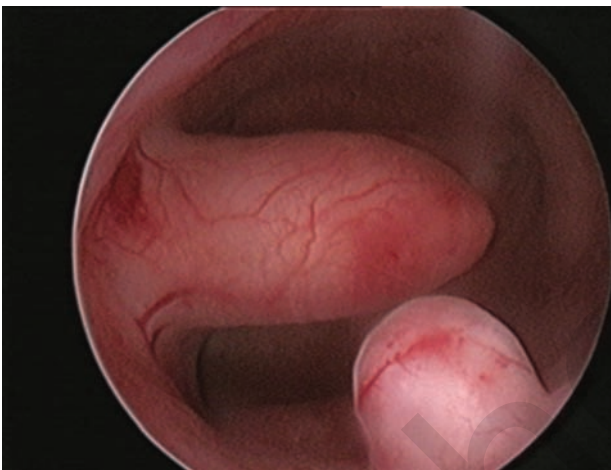


Figure 42.21 Endometrial polyps

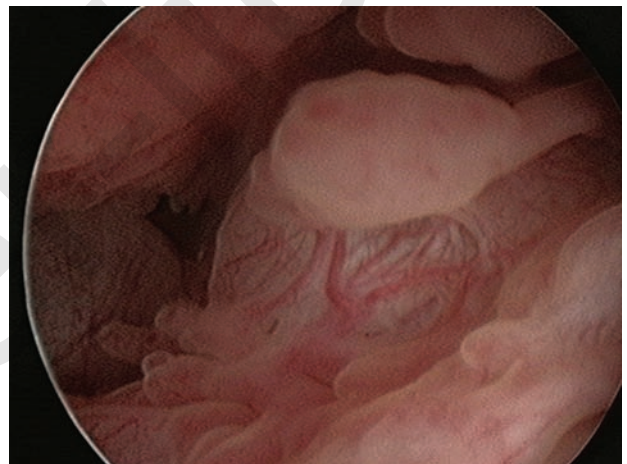


Figure 42.24 Mucous cyst of the cervix

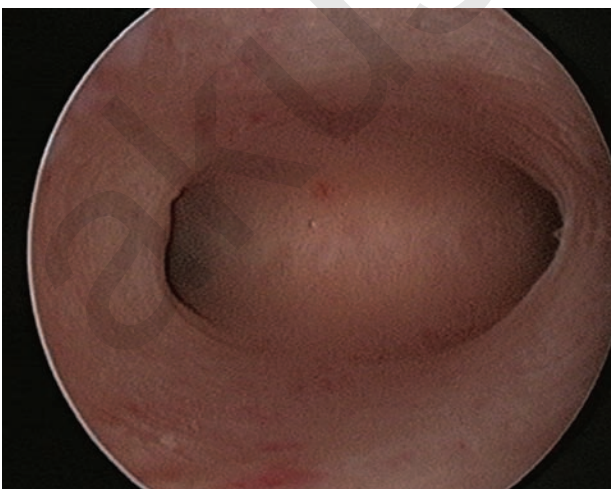


Figure 42.22 Proliferative endometrium

criteria for the diagnosis and classification of endometrial hyperplasia and its overlapping pattern with the normal late secretory endometrium, mainly in premenopausal women, is a drawback that still raises some doubt as to the reliability of this endoscopic procedure if based only on 'visualization' of the uterine cavity²⁰.

Considering the potential malignant evolution of endometrial hyperplasia, early hysteroscopic diagnosis of this condition may represent an important advance for the gynecologist only if associated with THB.

TARGETED HYSTEROSCOPIC BIOPSIES

The opinion that D&C does not ensure adequate, representative sampling of the endometrial cavity for the

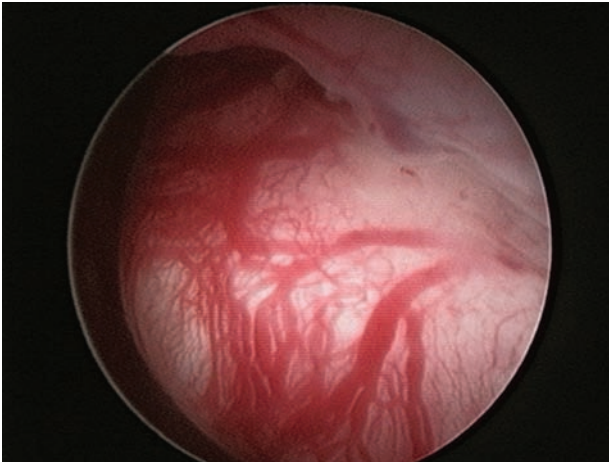


Figure 42.25 Hypervascularized polyp

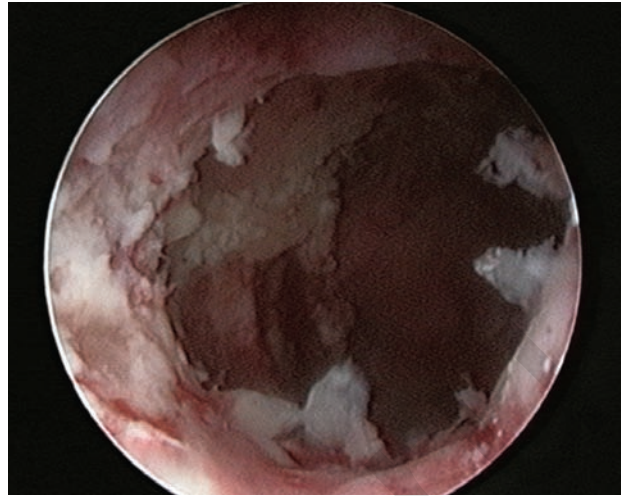


Figure 42.28 Uterine tuberculosis

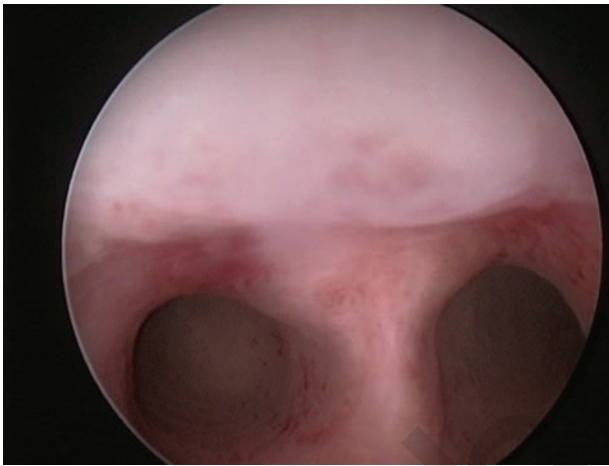


Figure 42.26 Uterine septum

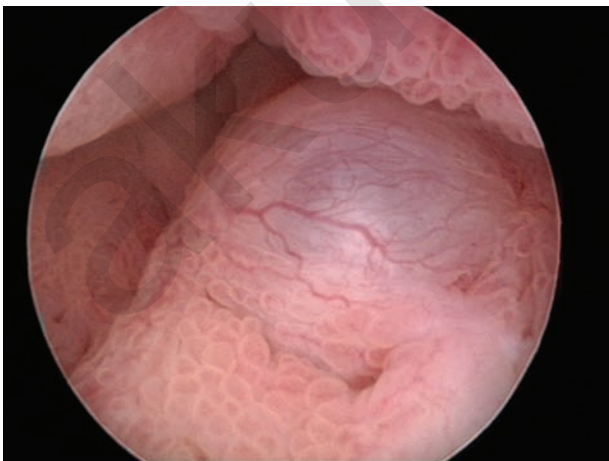


Figure 42.27 Mucous cyst of the cervix

detection of intrauterine pathologies is widely supported in the literature^{2,21-24}. Furthermore, endometrial lesions such as focal endometrial hyperplasia and adenocarcinoma can easily be missed with this technique²³⁻²⁶, as reported above. Endometrial sampling devices such as the Vabra, Pipelle or Novak® lead to the same problems owing to their 'blind' nature²⁶.

The availability of the new smaller hysteroscopes, including a 5F operative channel, has enabled physicians to perform a THB to confirm the endoscopic 'visual' diagnosis.

A number of papers have reported the reliability of such biopsies compared with blind procedures^{21,22,24,26,27}. The 'standard' technique widely used is defined as a 'punch' biopsy: the biopsy forceps bite into the endometrium and are then closed. The mucosa remains inside the jaws and partly around them. The instrument is then extracted through the operative channel while the hysteroscope remains inside the uterine cavity. For this reason, the small diameter of the operative channel shaves the surrounding material away from around the tip of the forceps, and, consequently, the final amount of tissue to be sent to the pathologist is strictly related to the internal volume of the two jaws of the forceps. The critical point in this procedure is the difficulty in obtaining an adequate amount of tissue for histological diagnosis: using small 5F biopsy forceps and the 'punch' technique, Colafranceschi *et al.*²⁸ and Bakour *et al.*²⁹ calculated an adequate amount of tissue to be not less than 0.8 mm².

In order to obtain enough material routinely for histological diagnosis, the 'standard' technique has been modified³⁰, adopting the so-called 'grasp' biopsy: the biopsy forceps are placed, with the jaws open, against the endometrium to be biopsied. Then the forceps are pushed

into the tissue and along it for 0.5–1 cm, avoiding touching the muscle fibers. Once a large portion of mucosa has been detached, the two jaws are closed and the whole hysteroscope is pulled out of the uterine cavity, without pulling the tip of the instrument back into the channel. In this way, not only the tissue inside the forceps jaws but also the surrounding tissue protruding outside the jaws can be retrieved, thus providing the pathologist with a large amount of tissue.

Moreover, the endoscopist has the chance to perform targeted biopsies of suspicious focal lesions²⁶. In some cases, the hysteroscopic visual diagnosis may not correlate with the final histologic diagnosis; it is therefore prudent to carry out endometrial sampling in all doubtful cases.

OPERATIVE TECHNIQUES

Mechanical surgery

Cervical polyps can be treated using sharp scissors; the fibrotic base of these polyps precludes the use of grasping forceps because of the risk of regrowth of the pathology. Endometrial polyps, in menstruating women, can be treated using the 5F 'crocodile' grasping forceps: the base of the polyp is grasped with the open forceps and then gently detached from its implant in the myometrium. In menopausal and perimenopausal women, we prefer to use scissors to separate the polyp from the myometrium, due to the fibrotic or fibrocystic nature of the pathology at that age. In both cases the main problem could be the size of the pathology. If it corresponds to the diameter of the ICO (or is just a little bigger), the detached polyp is easily extracted from the uterine cavity using the crocodile grasping forceps. Bigger polyps have to be brought out of the cavity in pieces, by grasping the polyp with the forceps and pulling, thus tearing off fragments: an arduous, lengthy process.

Anatomic impediments, frequently found in perimenopausal and menopausal women, are widely considered to be an obstacle to correct execution of the hysteroscopic procedure. The use of a small-diameter operative hysteroscope can certainly be a great advantage for the physician, who can now reverse the usual process, by treating the problem before gaining a 'diagnostic' view of the uterine cavity, i.e. first performing an operative procedure and then going into the cavity, to be able to make a diagnosis. All anatomic obstacles, usually fibrotic processes involving the ECO as well as the ICO and resulting in a reduction of the diameter, can easily be treated by cutting the 'fibrotic ring' at two or three points (at 3 and 9 o'clock, for example). The most difficult part of the job is making a correct distinction between fibrotic and muscular tissue, to avoid causing pain.

Intrauterine synechiae are treated using scissors, by cutting them in the middle.

Bipolar surgery

We use the Versapoint[®] bipolar electrosurgical system (Gynecare, Ethicon, NJ, USA), consisting of a dedicated bipolar electrosurgical generator and two types of electrodes: the 'twizzle', specifically for precise and controlled vaporization (resembling cutting), and the 'spring', indicated for diffuse tissue vaporization. Each electrode consists of an active electrode located at the tip and a return electrode located on the shaft, separated by a ceramic insert. Only tissue in contact with the active electrode in the electrical path circuit will be desiccated or vaporized. The generator provides different modes of operation (waveform): the vapor cut waveform, resembling a cut mode (acronyms are VC1, VC2 and VC3, where VC3 corresponds to the mildest energy flowing into the tissue), the blend waveform (BL1, BL2) and the desiccation waveform, resembling a coagulation mode (DES). The generator is connected to the 5F electrode via a flexible cable. Once connected, the generator automatically adjusts to the default setting (VC1 and 100 W).

Instrument settings

After a test period, we concluded that the default settings of the Versapoint bipolar electrical generator were incompatible with our techniques performed without any type of anesthesia or analgesia, and therefore decided to use the mildest vapor cutting mode (VC3) and to reduce the power setting by half (50 W). For the same reason, we chose the 'twizzle' electrode over the 'spring', as in our experience the 'twizzle' electrode is a more precise 'cutting' instrument, and with lower power settings it can work closer to the myometrium with less discomfort.

Operative technique

Polyps are removed intact with the Versapoint 'twizzle' electrode only if the internal cervical os size is wide enough for their extraction. Otherwise, they are sliced, from the free edge to the base, into two or three fragments small enough to be pulled out through the uterine cavity using 5F grasping forceps with teeth. To remove the entire base of the polyp without going too deep into the myometrium, in some cases the 'twizzle' electrode can be bent by 25–30°, sufficient to obtain a kind of hook electrode. A similar technique has been applied on submucosal myomas, but with the difference that, owing to their higher tissue density, they must first be divided into two half-spheres and then each of these must be sliced as described above. Particular attention is paid to the intramural part of the myoma, if present. To avoid any myometrial stimulation or damage, the myoma is first gently separated from the capsule using mechanical instruments (grasping forceps or scissors) as already described for resectoscopic myomectomy³¹. Once the

intramural section becomes submucosal it is sliced with the Versapoint 'twizzle' electrode.

CONCLUSIONS

Diagnostic hysteroscopy has long paid the price of being a purely visual investigation method. On the one hand, the possibility of viewing the uterine cavity after decades of blind procedures aroused considerable enthusiasm, while on the other, the impossibility of taking a biopsy of suspicious tissue under direct visualization limited the diagnostic accuracy of this procedure. Bearing in mind that the anatomy of the cervical canal does not allow the introduction of instruments with an outer diameter greater than 5 mm, the impossibility of performing guided biopsies without the need for dilatation of the cervix (and hence anesthesia) was related to technological problems that, for a long period, precluded the creation of miniaturized hysteroscopes equipped with an instrument channel.

Today, owing to recent advances in instrumentation, operative hysteroscopes with the same outer diameter as that of the previous diagnostic ones are finally available. A new generation of hysteroscopists, familiar with these hysteroscopes and with the modified techniques related to simultaneous use of the scope and the instruments, is finally bringing the hysteroscopic procedure to realization of the full accuracy that has been awaited for the past 20 years.

In the past, we would have been unable to perform these procedures in a 'see and treat' fashion in an outpatient setting without any anesthesia. Improved technology now enables us to perform many operative procedures in an office setting, without significant patient discomfort, reserving operating room time for the resectoscopic treatment of the less common, larger intrauterine pathologies.

There is no longer a distinction between the diagnostic and the operative procedure, but rather a single technique whereby the use of small-diameter operative hysteroscopes together with miniaturized instruments can ensure a final, correct, diagnosis.

REFERENCES

- Gimpelson RJ, Rappold HO. A comparative study between panoramic hysteroscopy with directed biopsies and dilatation and curettage. A review of 276 cases. *Am J Obstet Gynecol* 1988; 158: 489–92
- Loffer FD. Hysteroscopy with selective endometrial sampling compared with D&C for abnormal uterine bleeding: the value of a negative hysteroscopic view. *Obstet Gynecol* 1989; 73: 16–20
- Siegler AM. Therapeutic hysteroscopy. *Acta Eur Fertil* 1986; 17: 467–71
- Bettocchi S, Ceci O, Di Venere R, et al. Advanced operative office hysteroscopy without anaesthesia: analysis of 501 cases treated with a 5 Fr. bipolar electrode. *Hum Reprod* 2002; 17: 2435–8
- Burkitt HG, Young B, Heath JW. The female genital organs. In Young B, Burkitt HG, Heath JW, Wheater PR, eds. *Wheater's Functional Histology*. Edinburgh: Churchill Livingstone, 1993: 335–65
- Valle RF, Sciarra JJ. Hysteroscopy: a useful diagnostic adjunct in gynecology. *Am J Obstet Gynecol* 1975; 122: 230–5
- Baggish MS. Contact hysteroscopy: a new technique to explore the uterine cavity. *Obstet Gynecol* 1979; 54: 350–4
- Valle RF, Sciarra JJ. Current status of hysteroscopy in gynecologic practice. *Fertil Steril* 1979; 32: 619–32
- Barbot J, Parent B, Dubuisson JB. Contact hysteroscopy: another method of endoscopic examination of the uterine cavity. *Am J Obstet Gynecol* 1980; 136: 721–6
- Taylor PJ, Hamou JE. Hysteroscopy. *J Reprod Med* 1983; 28: 359–89
- Valle RF. Hysteroscopy for gynecologic diagnosis. *Clin Obstet Gynecol* 1983; 26: 253–76
- Vercellini P, Colombo A, Mauro F, et al. Paracervical anesthesia for outpatient hysteroscopy. *Fertil Steril* 1994; 62: 1083–5
- Lau WC, Lo WK, Tam WH, Yuen PM. Paracervical anaesthesia in outpatient hysteroscopy: a randomised double-blind placebo-controlled trial. *Br J Obstet Gynaecol* 1999; 106: 356–9
- Zullo F, Pellicano M, Stigliano CM, et al. Topical anesthesia for office hysteroscopy. A prospective, randomized study comparing two modalities. *J Reprod Med* 1999; 44: 865–9
- Bettocchi S, Selvaggi L. A vaginoscopic approach to reduce the pain of office hysteroscopy. *J Am Assoc Gynecol Laparosc* 1997; 4: 255–8
- Soderstrom RM. Distending the uterus: what medium is best? *Clin Obstet Gynecol* 1992; 35: 225–8
- Baker VL, Adamson GD. Intrauterine pressure and uterine distention. *J Am Assoc Gynecol Laparosc* 1996; 3: S53
- Campo R, Van Belle Y, Rombauts L, et al. Office mini-hysteroscopy. *Hum Reprod Update* 1999; 5: 73–81
- Loverro G, Bettocchi S, Cormio G, et al. Diagnostic accuracy of hysteroscopy in endometrial hyperplasia. *Maturitas* 1996; 25: 187–91
- Clark TJ, Voit D, Gupta JK, et al. Accuracy of hysteroscopy in the diagnosis of endometrial cancer and hyperplasia. A systematic quantitative review. *JAMA* 2002; 288: 1610–21
- Brill AI. What is the role of hysteroscopy in the management of abnormal uterine bleeding? *Clin Obstet Gynecol* 1995; 38: 319–45
- Smith JJ, Schulman H. Current dilatation and curettage practice: a need for revision. *Obstet Gynecol* 1985; 65: 516–18
- Grimes DA. Diagnostic dilation and curettage: a reappraisal. *Am J Obstet Gynecol* 1982; 142: 1–6

24. Dijkhuizen FP, Mol BW, Brolmann HA, Heintz AP. The accuracy of endometrial sampling in the diagnosis of patients with endometrial carcinoma and hyperplasia. *Cancer* 2000; 89: 1765–72
25. Valle RF. Office hysteroscopy. *Clin Obstet Gynecol* 1999; 42: 276–89
26. Stock RJ, Kanbour A. Prehysterectomy curettage. *Obstet Gynecol* 1975; 45: 537–41
27. Agostini A, Cravello L, Rojat-Habib MC, et al. Evaluation of two methods for endometrial sampling during diagnostic hysteroscopy. *J Gynecol Obstet Biol Reprod* 1999; 28: 433–8
28. Colafranceschi M, van Herendael B, Perino A, et al. Reliability of endometrial biopsy under direct hysteroscopic control. *Gynaecol Endosc* 1995; 4: 119–22
29. Bakour SH, Khan KS, Gupta JK. Controlled analysis of factors associated with insufficient sample on outpatient endometrial biopsy. *Br J Obstet Gynaecol* 2000; 107: 1312–14
30. Bettocchi S, Di Venere R, Pansini N, et al. Endometrial biopsies using small-diameter hysteroscopes and 5F instruments: how can we obtain enough material for a correct histologic diagnosis? *J Am Assoc Gynecol Laparosc* 2002; 9: 290–2
31. Gimpelson RJ. Hysteroscopic treatment of the patient with intracavitary pathology (myomectomy/polypectomy). *Obstet Gynecol Clin North Am* 2000; 27: 327–37

akusher-lib.ru

akusher-lib.ru

Müllerian duct anomalies

P Jadoul, C Pirard, J Donnez

INTRODUCTION

Uterine malformations are very common. Indeed, if we include minor malformations (hypoplastic and arcuate uterus), they are encountered in 7–10% of all women. If we take into account just the more widely known uterine malformations, they are observed in 2–3% of fertile women, 3% of infertile women and 5–10% of those suffering repeated miscarriage¹.

Three main principles govern the practical approach to malformations of the genital tract:

- (1) The Müllerian and Wolffian ducts are so closely linked embryologically that gross malformations of the uterus and vagina are commonly associated with congenital anomalies of the kidney and ureter.
- (2) The development of the gonad is separate from that of the ducts. Normal and functional ovaries are therefore usually present when the vagina, uterus and Fallopian tubes are absent or malformed.
- (3) Müllerian duct anomalies are usually not associated with anomalies in the sex chromosome make-up of the individual.

EMBRYOLOGY

Gonadal development is not examined in this chapter, which is limited to Müllerian and Wolffian duct development.

Late in the fifth or sixth week of embryonic life, at the level of the third thoracic somite, a precise area of the celomic epithelium invaginates at several points on the lateral surface of the urogenital ridge, and coalesces to form a tube, termed the Müllerian or paramesonephric duct (Figure 43.1a). The duct extends caudally to the urogenital ridge, immediately lateral to the Wolffian duct. The paired Müllerian ducts give rise to the Fallopian tubes, uterus, cervix and upper vagina. For proper Müllerian duct migration to occur, it is essential that the Wolffian duct is present².

Each Müllerian duct, guided by its respective Wolffian duct, migrates and develops independently of the other, and one usually descends ahead of the other. Defects in development of the Wolffian duct lead to Müllerian anomalies. Initially lateral to the Wolffian ducts, the Müllerian ducts cross over to lie medial to them as they enter the pelvis. By the end of the seventh week of embryonic life, the Müllerian ducts fuse to form a single structure

between the two Wolffian ducts. The two Müllerian ducts penetrate the posterior wall of the urogenital sinus, between the orifices of the Wolffian ducts, on a mound called Müller's tubercle. It is important that the point where the tip of the Müllerian duct abuts on the posterior wall of the urogenital sinus is within the patch of mesoderm inserted into the wall of the sinus by the Wolffian ducts. This point defines the site of the future vaginal orifice, the hymenal membrane (Figure 43.1b). Two solid

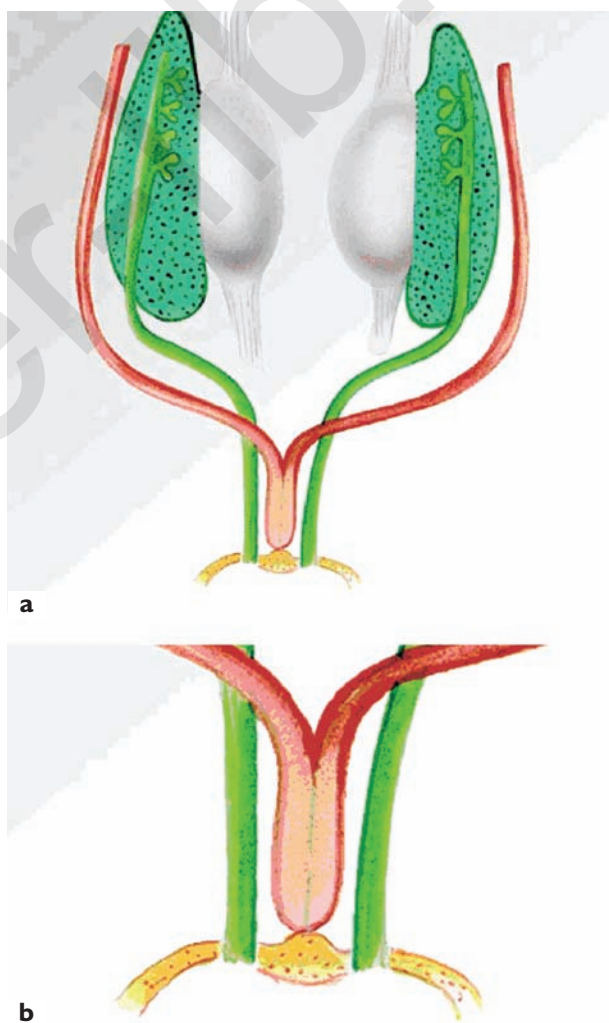


Figure 43.1 (a) The genital ducts in the female at the end of the second month of development. Note the Müllerian tubercle and the formation of the uterine canal: Müllerian ducts (orange), urogenital sinus (yellow). (b) Higher-power detail of the genital ducts in the female at the end of the second month of development

epithelial evaginations (sinovaginal bulbs) grow posteriorly from Müller's tubercle to meet the two solid tips of the fused Müllerian ducts. This epithelial proliferation of sinovaginal bulbs and the caudal ends of the Müllerian ducts form the solid vaginal plate (Figure 43.2a). The vaginal plate and the adjoining Müllerian ducts elongate, canalize and migrate from pelvic to perineal locations. At the same time, the urogenital sinus exstrophies into the vestibule, the urethra elongates and the plate canalizes (Figure 43.2b). The hymen remains as a membrane between the urogenital sinus and the canalized vaginal plate. The vaginal plate is first seen distinctly when the embryo is about 60–75 mm long, and its formation is complete at about 140 mm. Finally, when the cells of the plate desquamate, the vaginal lumen is formed³ (Figure 43.2c).

As early as the end of the first trimester⁴, there is a mesenchymal thickening around that portion of the fused Müllerian duct that is destined to become the endocervix. This mesenchymal thickening includes the Wolffian ducts, so that remnants of the latter, which persist into adulthood, are found within the body of the cervix. At all other levels of the genital canal, remnants of the Wolffian ducts are external to the wall of the adult Müllerian derivative. Smooth muscle appears in the walls of the genital canal between 18 and 20 weeks, and, by approximately 24 weeks, the muscular portion of the uterine wall is well developed⁴. Vaginal, uterine and tubal muscular walls develop around the Müllerian duct alone, so that the Wolffian duct remnants are external to the true wall of the canal. Cervical glands appear at about 15 weeks and rudimentary endometrial glands by 19 weeks, but the endometrium is not well developed even at term in most infants.

CLASSIFICATION OF MÜLLERIAN DUCT ANOMALIES

Müllerian duct anomalies can be classified into those of development and those of fusion (Table 43.1).

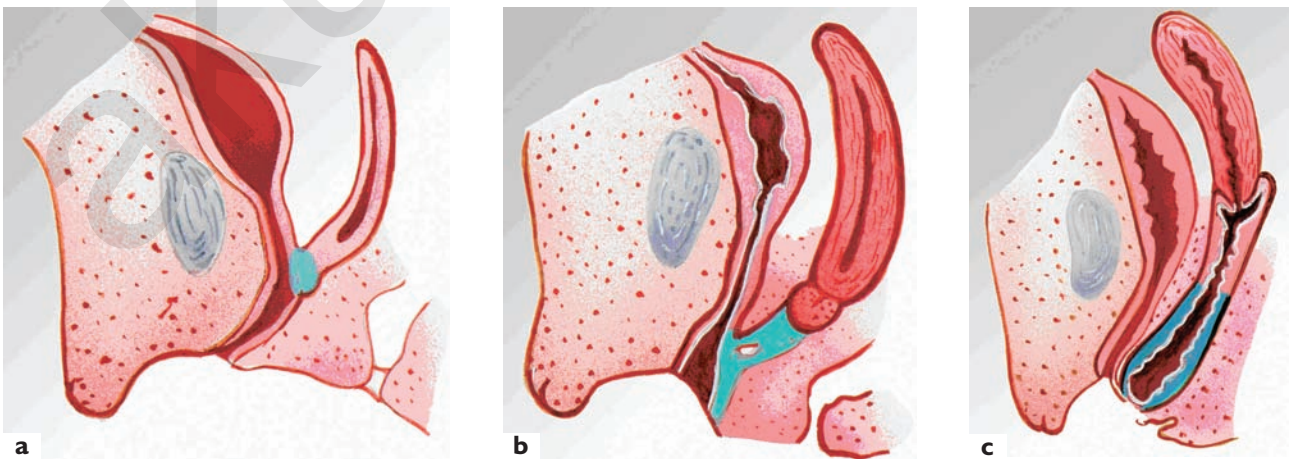


Figure 43.2 (a)–(c) Sagittal section showing the formation of the uterus and vagina during development

Development anomalies

Absence of both Müllerian ducts

Mayer–Rokitansky–Küster–Hauser syndrome is complete failure of the development of the Müllerian ducts resulting in an absence of the Fallopian tubes, uterus and most of the vagina. In such cases, the vulva is likely to be normal, and there may be a depression of variable depth representing the lower (urogenital sinus) part of the vagina. It is usual to find such a depression covered with a normal hymen^{5,6} (Figure 43.3). In most cases, there is complete absence of the uterus and Fallopian tubes. In rare cases, the Fallopian tubes are present with or without associated rudimentary horns (Figures 43.4a and 43.4b). Myoma can develop on these rudimentary horns (Figure 43.4c).

This syndrome affects one in every 4000–5000 females. Although familial aggregates have been described, the defect usually appears sporadically.

Girls with Mayer–Rokitansky–Küster–Hauser syndrome present with primary amenorrhea associated with normal pubertal development. Although nothing can be done to restore fertility, vaginal construction or reconstruction has become well established as a method of permitting or restoring sexual function. A variety of procedures have been described.

The most natural techniques involve progressive dilatation of the vaginal cupula. Frank⁷ reported graduated vaginal dilatation on a bicycle-seat tool, but this technique yielded favorable results in fewer than 50% of patients. Vecchietti⁸ developed a technique whereby continuous traction (1 cm/day) is applied to an acrylic olive placed in the vaginal dimple. This olive is held by threads that are passed through the vaginal cupula and preperitoneal space, right through the skin, where they are fixed to a device on the abdomen (Figure 43.5).

This technique, first performed by laparotomy, has been modified by several authors and is now usually performed by laparoscopy^{9–13}.

Table 43.1 Classification of Müllerian duct anomalies*Development anomalies*

Absence of both Müllerian ducts

Absence of one Müllerian duct

Incomplete development of both Müllerian ducts

Incomplete development of one Müllerian duct

Fusion anomalies

Lateral fusion anomalies

arcuate uterus

uterus subseptus, uterus septus and uterus bicornis

uterus didelphys

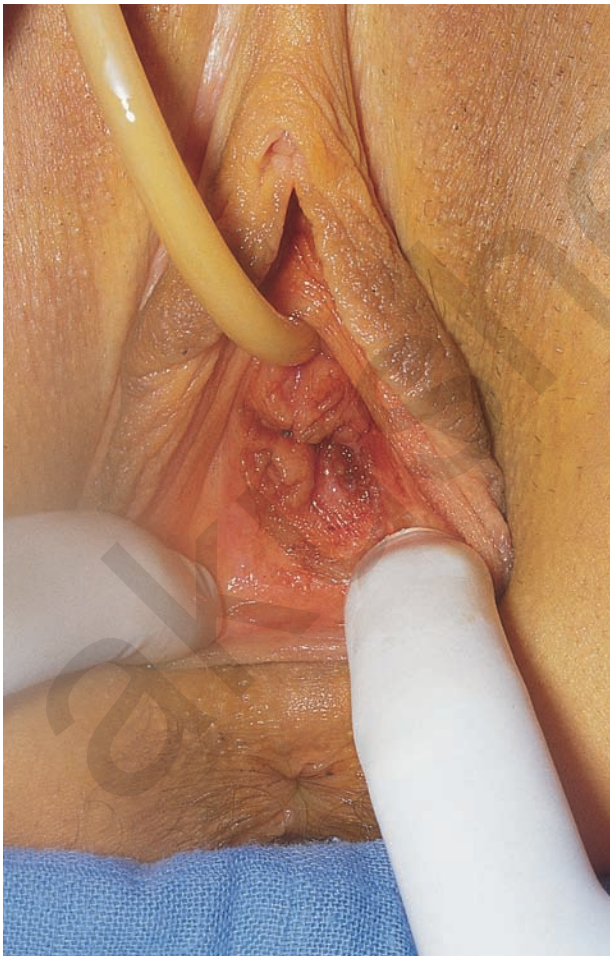
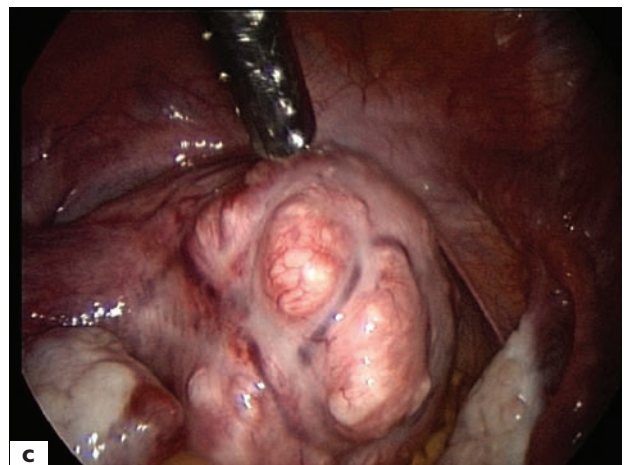
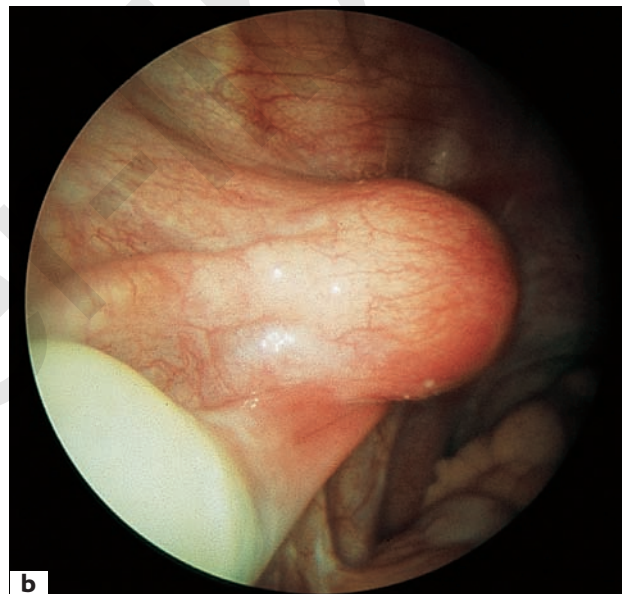
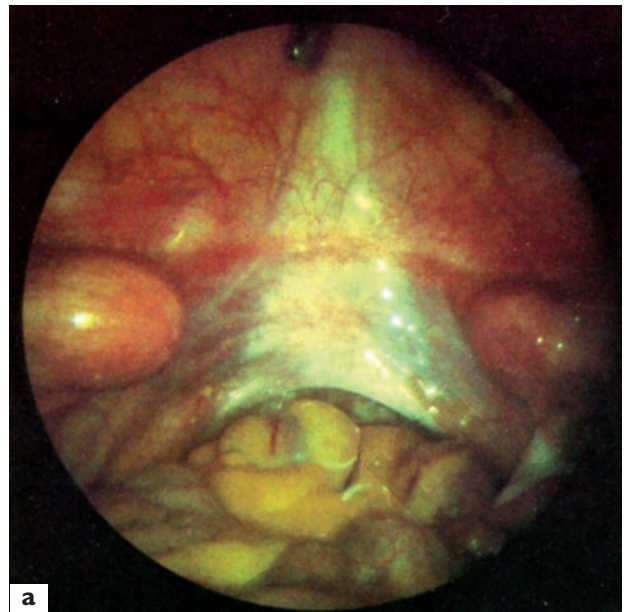
septate and subseptate vagina

Vertical fusion anomalies

cervical atresia

vaginal atresia

transverse vaginal septum

**Figure 43.3** Mayer-Rokitansky-Küster-Hauser syndrome: external genital tract**Figure 43.4** (a) and (b) Mayer-Rokitansky-Küster-Hauser syndrome: presence of rudimentary horns; (c) a myoma can develop on these rudimentary horns

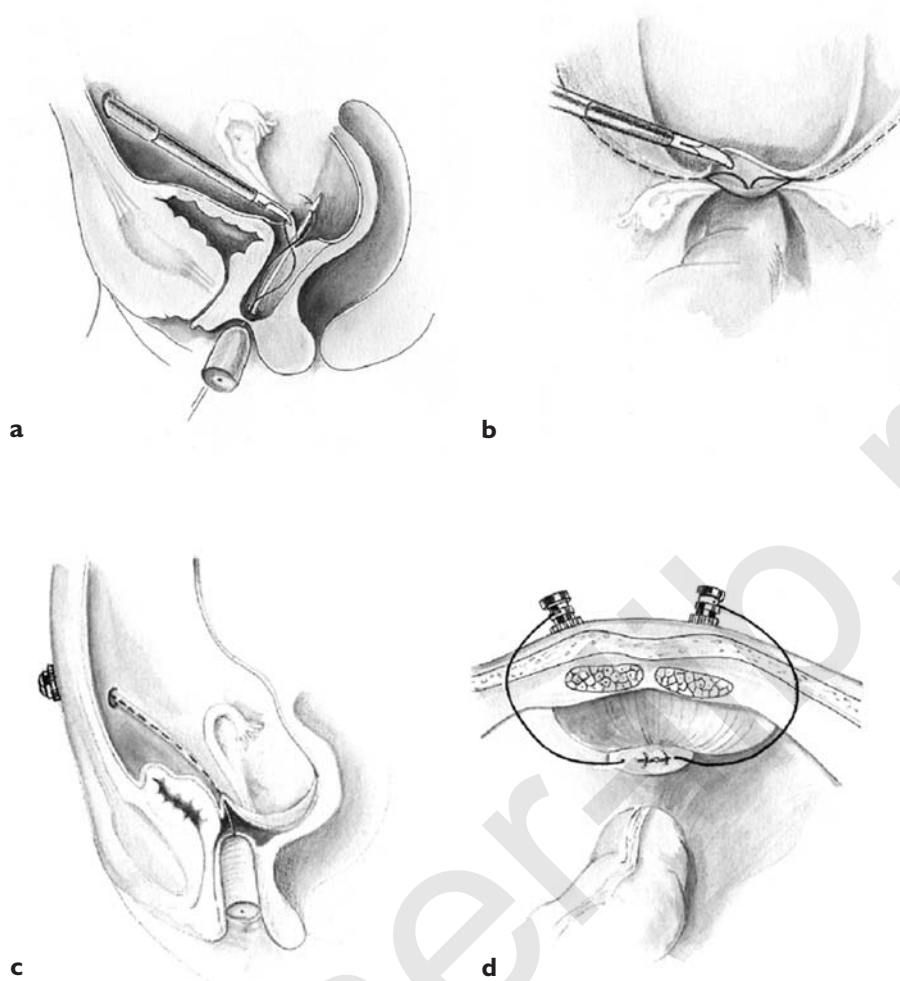


Figure 43.5 (a)–(d) Vecchietti procedure

Other techniques involve creating a tunnel in the vesicorectal space. Whether or not a graft is needed to cover this tunnel and which tissue should be used (skin, intestine, amnion, peritoneum) are still matters of debate.

The use of cecal or sigmoid bowel segments was reported by Baldwin¹⁴, Turner-Warwick and Kirby¹⁵ and O'Connor *et al.*¹⁶. Although some authors claimed good results, this method is a major surgical procedure with significant morbidity and mortality. Moreover, profuse secretions, persistent unpleasant odor and ulceration of the mucosal surface could be major side-effects.

McIndoe and Bannister¹⁷ transplanted a split-thickness skin graft into a newly formed vaginal cavity, held in place by a vaginal mold. Great variations in success rate, a high incidence of postoperative infection, necrosis of the skin graft and scarring make this technique less acceptable. The patient also suffers considerable discomfort from the donor skin site, which may remain visible.

Myocutaneous flaps have been used by several surgeons. The gracilis myocutaneous flap has become very

popular in recent years^{18–21}, but a serious disadvantage is the precarious vascularity of the flaps. In McCraw *et al.*'s series of 22 patients²², six suffered catastrophic loss of the flap. The rectus abdominis flap is another popular flap, but creates a large abdominal donor site defect²³ and requires a long operative procedure. The neurovascular pudendal thigh flap procedure can be used reliably to reconstruct the vagina²⁴. All flap techniques, however, are reported to be associated with an unacceptable failure rate due to partial flap loss and necrosis. Such dissections also cause major scars, and can only be indicated for vaginal reconstruction after pelvicctomy for pelvic cancer, when subsequent irradiation must be carried out.

In order to overcome these difficulties, amnion alone, with the clean mesenchymal surface placed towards the host, has been used by several surgeons^{25–30}. Faulk *et al.*³¹ demonstrated microscopic evidence of new vessel formation, and suggested that an angiogenic factor is produced by amnion. There is no problem with immune rejection because amnion does not express histocompatibility anti-

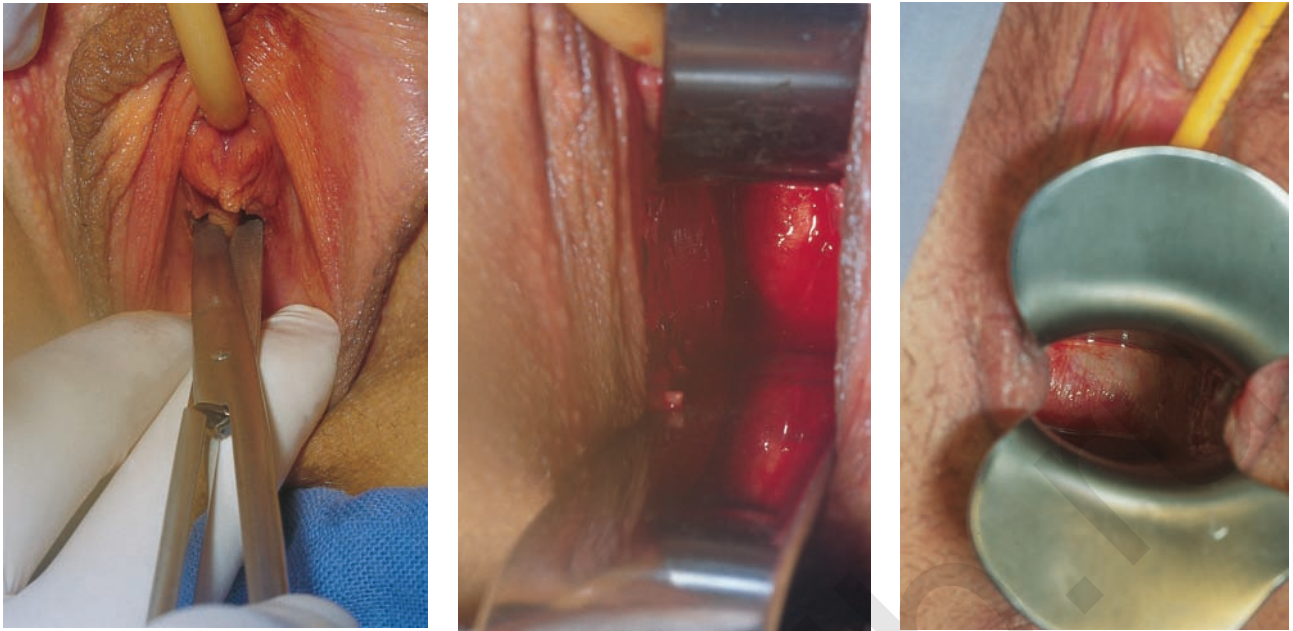

Figure 43.6 Dissection of the vesicorectal space

gens. Akle *et al.*³² found no evidence of tissue rejection when amnion was implanted subcutaneously in volunteers.

Tancer *et al.*³³, Dhall³⁰ and Ashworth *et al.*³⁴ have all reported the successful use of amnion as a graft in vaginoplasties.

In our department, amniotic membranes were used between 1985 and 2002. They were taken immediately postpartum (< 6 h) and rinsed in sterile physiological solution.

Under general anesthesia, the patient is placed in the lithotomy position and vaginal dissection is performed (Figure 43.6). A vaginal pouch is created by blunt dissection using scissors. At the same time, a laparoscopy is performed to confirm the diagnosis and check the blunt dissection. When hemostasis has been achieved, a rigid vaginal mold (Figure 43.7) is selected, just large enough to ensure firm application of the amniotic membranes, with which it is covered (Figure 43.8). The labia majora are approximated with silk sutures to keep the mold in place (Figure 43.9). Laparoscopy is not necessary for the dissection but, when performed to ascertain the diagnosis, it permits visualization of the top of the mold between the bladder and the rectum (Figure 43.10).

The mold is removed under light sedation 7 days later, and the newly constructed vagina is inspected and cleaned. The amniotic membranes are found to be adherent to the vagina. A flexible mold (Figure 43.11) is then inserted and the patient discharged the following day, having been advised to refrain from sexual activity for an additional 2 weeks and to use the mold at night during this period.

All patients had greatly improved vaginal length and capacity as a result of this treatment. Excellent results were achieved in all cases. The vaginal tissue remained supple, with no evidence of fibrous tissue formation. Chronic granulation tissue was not observed and vaginal shrinkage did not occur.

Recently, we used a new product, Surgisis™ Enhanced Strength (Cook, Brussels, Belgium), in order to avoid the application of human tissue with the potential risk of viral transmission in young women (Figure 43.12). Small intestinal submucosa (SIS) is a new biomaterial for the replacement and repair of damaged tissue. It does not contain cells because it is extracted from the porcine small intestine in a manner that removes all cells, but leaves the complex matrix intact. The manufacturing process has been validated to ensure that any virus that might be present in source animals is completely inactivated. The cells of adjacent tissue invade the SIS material. Progressively, capillary growth and progressive degradation of the SIS material should be observed. This new tissue graft has already been used in animal surgery by several authors, and appears encouraging for use in human surgery^{35,36}.

Another way to create a new vagina is to pull down the peritoneum between the bladder and the rectum. The peritoneum is pushed down and sutured to the hymen after opening the vaginal cupula. A peritoneal purse-string is performed to close the neovagina (Figure 43.13). This technique, first performed by Davydov³⁷ in 1969 by laparotomy but nowadays done by laparoscopy^{38–43}, has the advantage of not causing sequelae to the donor site and




Figure 43.7 Rigid vaginal mold (diameter 3.5 cm, length 10 cm). The holes allow drainage of vaginal exudates. Two small holes allow the mold to be fixed

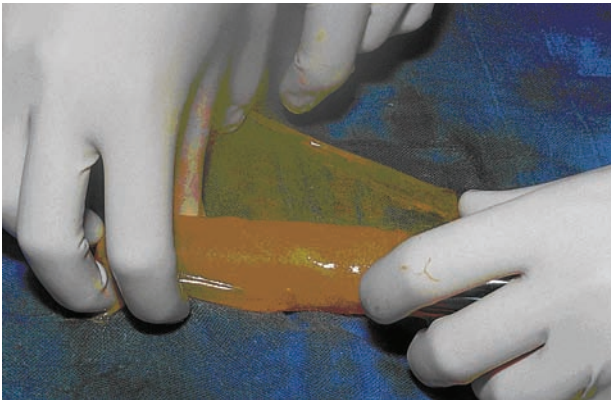


Figure 43.8 A rigid mold is wrapped in amniotic membranes

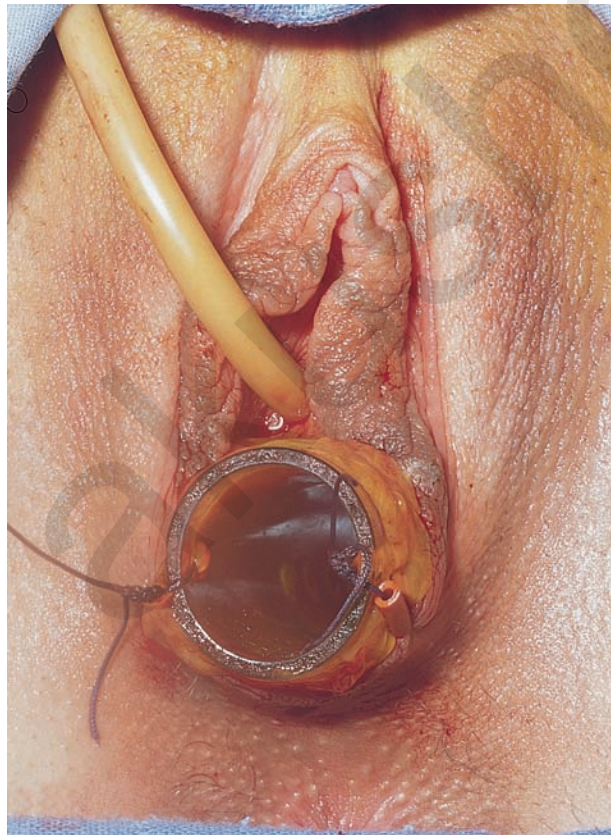

Figure 43.9 The rigid mold is fixed to the skin

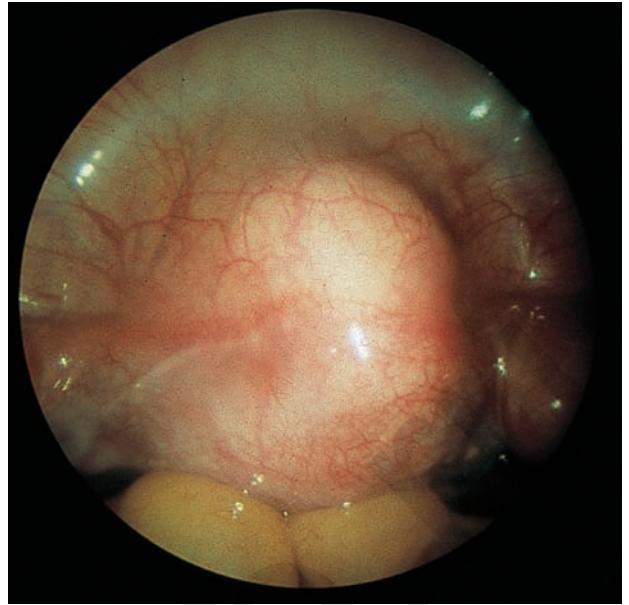


Figure 43.10 Laparoscopic view after blunt dissection and introduction of the mold



Figure 43.11 Non-rigid mold

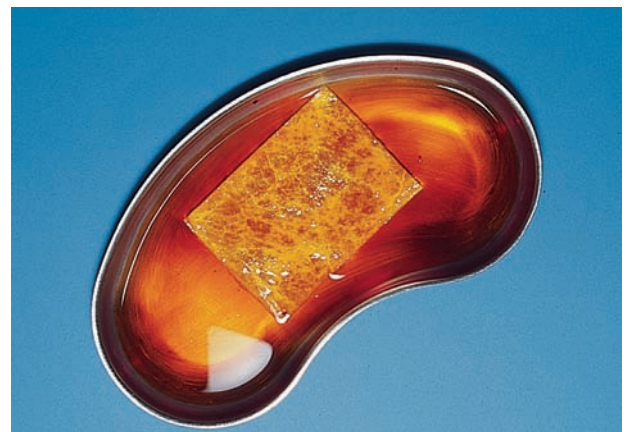


Figure 43.12 A 10 x 7-cm piece of small intestinal submucosa (SIS) placed in Rifocine® solution for 2–3 min before being sutured to the newly created vaginal pouch

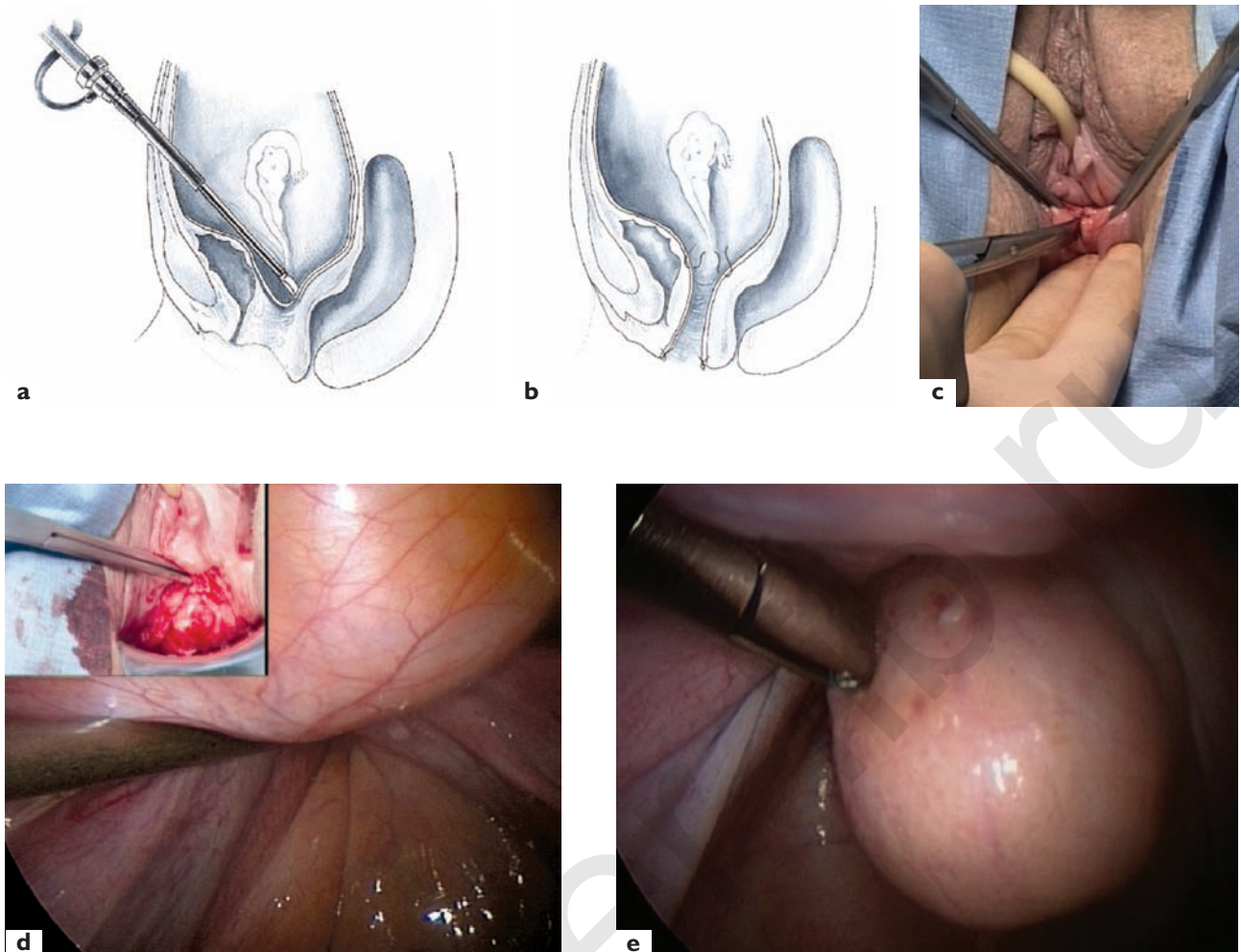


Figure 43.13 (a) and (b) Davydov technique. (c)–(i) Laparoscopic view of colpopoiesis with peritoneum. (c) Incision of the vaginal cupula. (d) The peritoneum is pushed down to the hymen by laparoscopy. (e) The peritoneum is pushed back with a Hegar probe.

not needing an allograft or synthetic or biomaterial. The peritoneum is replaced by normal vaginal mucosa after 5–6 months. The need for a vaginal mold during the healing process varies from 48 h to 6 weeks^{38,43}.

Absence of one Müllerian duct

The absence of one Müllerian duct (Figure 43.14) results in a unicornuate uterus with only one Fallopian tube. The cervix and vagina may be normal in appearance and function, but they strictly represent only one-half of the fully developed organs. A true unicornuate uterus is rare, and is usually associated with an absence or gross malformation of the renal tract on the side of the missing Müllerian duct.

Incomplete development of both Müllerian ducts

Incomplete development sometimes affects the lower parts of the ducts only. Thus, well-formed abdominal ostia

may be associated with hypoplasia or absence of the remainder of the tubes, the uterus or the vagina. It is possible for the tubes and uterus to be present and the vagina to be absent, rudimentary or imperforate. The converse is never true because the ducts grow downwards; a well-formed uterus is never associated with the absence of Fallopian tubes.

Poorly formed ducts of full length result in hypoplasia of the whole genital tract. The anatomic abnormalities induced by *in utero* diethylstilbestrol (DES) exposure can be understood on the basis of embryological development of both the lower and upper genital tracts^{44–46}. DES inhibits development of the vaginal plate, resulting in the Müllerian duct component of the vagina being lower in the adult canal than is normally the case. This results in the presence of columnar, Müllerian-type epithelium as far down the vagina as the hymenal ring in extreme cases. DES also disorganizes stromal differentiation, which is responsible for the overall structure of the cervix, uterus

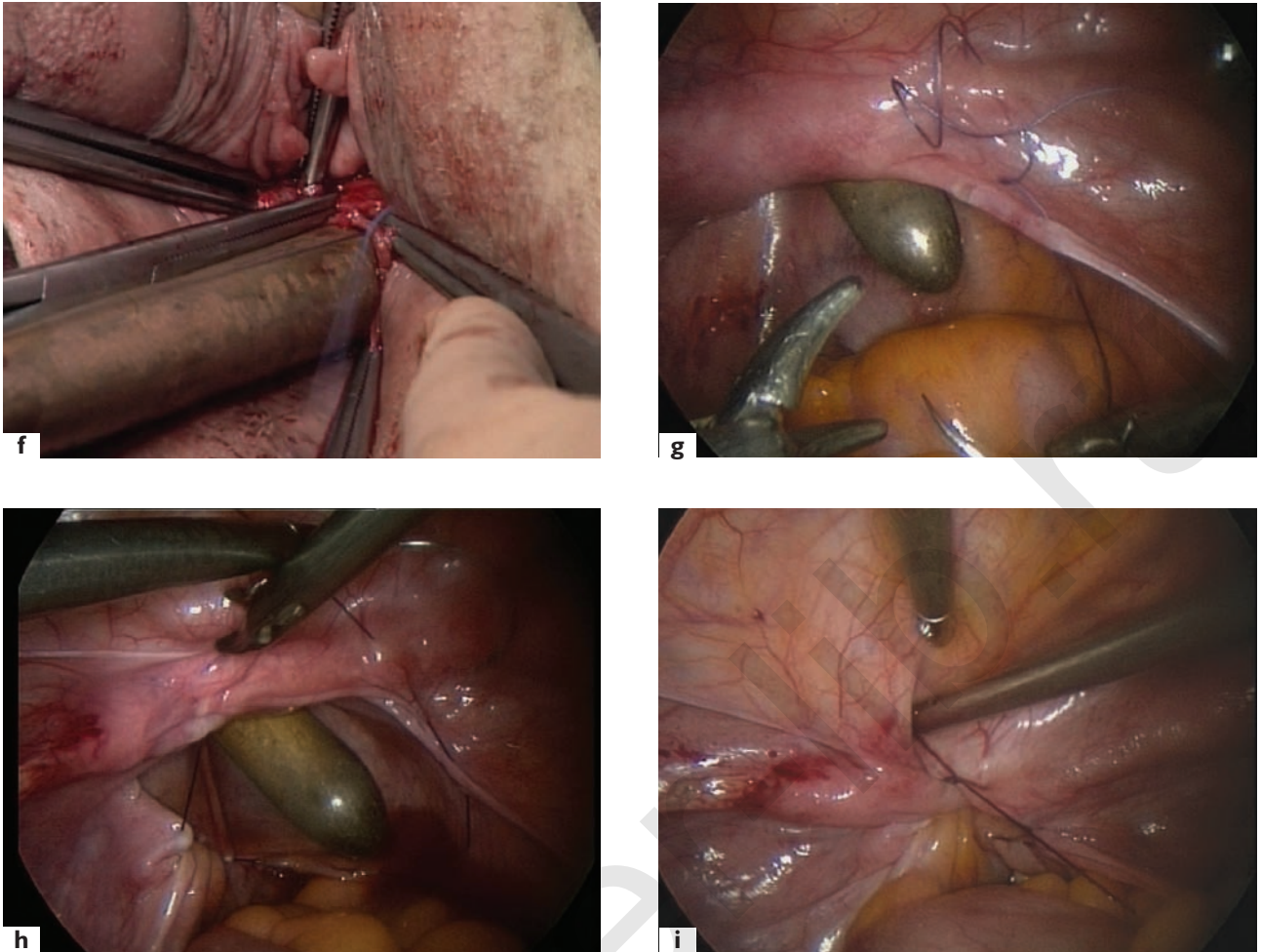


Figure 43.13 *continued* (f) The opened peritoneum is sutured to the hymen. (g)–(i) A purse-string is performed to close the peritoneum above the Hegar probe

and tubes. This may cause gross structural anomalies of the cervix, such as a cervical collar, pseudopolyp or hood, as well as uterine deformities such as a T-shaped endometrial cavity (Figure 43.15).

DES is a non-steroidal synthetic estrogen used between 1941 and 1977 to prevent miscarriage, gravidic hemorrhage and premature delivery⁴⁷. In 1971, it was prohibited in the USA by the Food and Drug Administration (FDA) after Herbst and Scully⁴⁸ showed an increased risk of vaginal clear-cell adenocarcinoma in girls exposed *in utero* to DES. Cervicovaginal, tubal and uterine anomalies, infertility and obstetric complications have been related to DES exposure. Sixty-nine per cent of women exposed to DES present with uterine anomalies at hysterosalpingography⁴⁴. The most frequently encountered anomaly is the T-shaped uterus (55%). Uterine hypoplasia occurs in 44–49% and supraisthmic stenosis in 26% of cases (Figure 43.16).

DES-exposed women have an increased risk of infertility^{44,49} and an increased risk of obstetric complications

such as early and late miscarriage and premature delivery. In the case of a T-shaped uterus or supraisthmic stenosis, hysteroscopic uterine cavity enlargement can be proposed. A lateral 5–7-mm-deep incision is performed in the lateral sides of the myometrium (Figure 43.17). An intrauterine device (IUD) is left in place and high doses of estrogens and progesterone are prescribed for a duration of 2–3 months, allowing re-epithelialization of the incised myometrium. After removal of the IUD, hystero-graphy allows evaluation of the anatomic results (Figure 43.18).

In the literature, we found four retrospective non-controlled studies of hysteroplasty in 82 patients exposed to DES^{50–53}. Hysterosalpingography showed apparent improvement in all cases but no objective criteria were defined. Two postoperative synechiae and two cases of placenta accreta were described. These studies are too limited to allow conclusions to be drawn on the safety and efficacy of hysteroplasty for DES uterus. There are potential risks of intraoperative uterine perforation, cervical incompetence, uterine rupture during pregnancy,

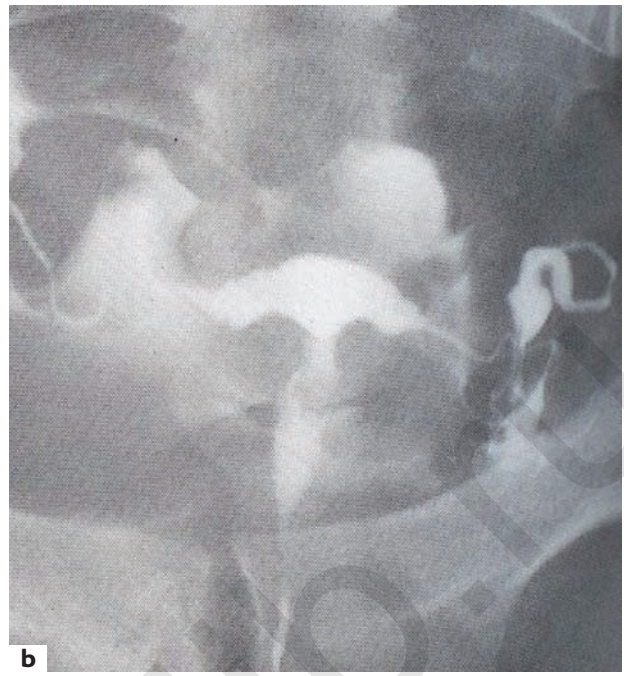



Figure 43.16 (a) T-shaped uterus; (b) supraisthmic stenosis

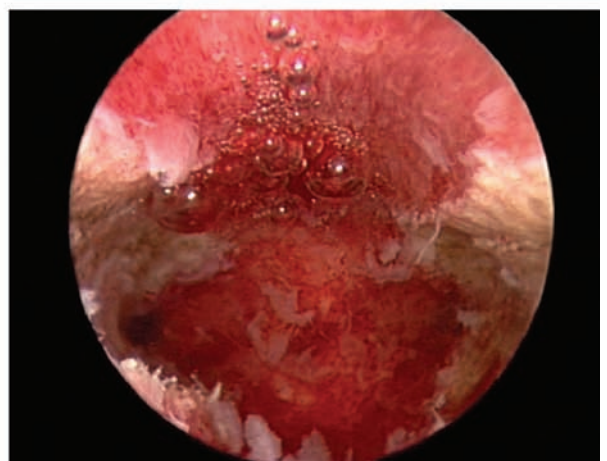
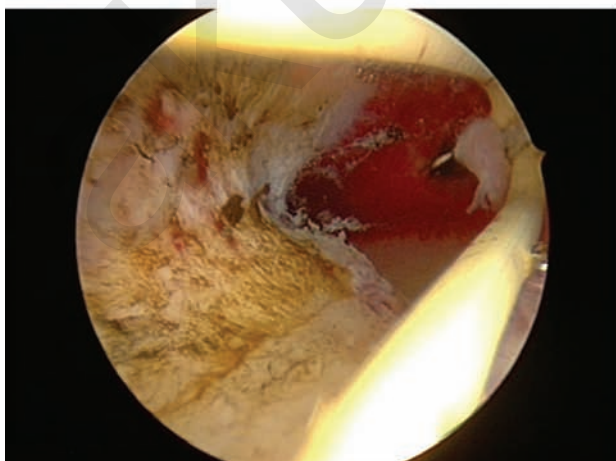
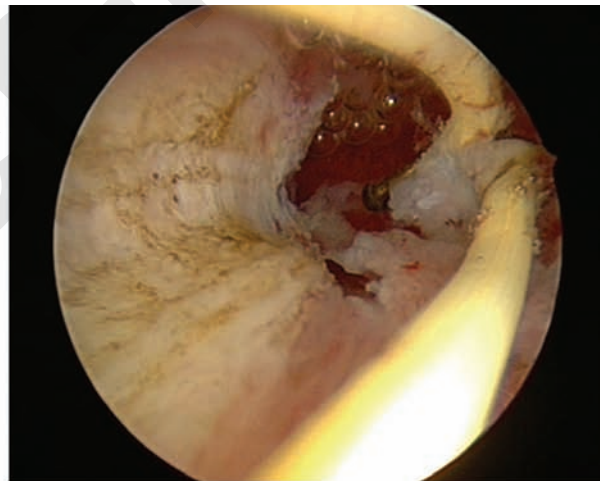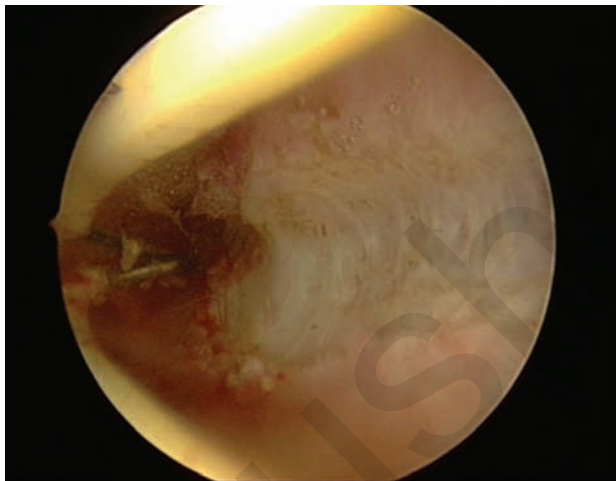


Figure 43.17 Hysteroscopic hysteropectomy

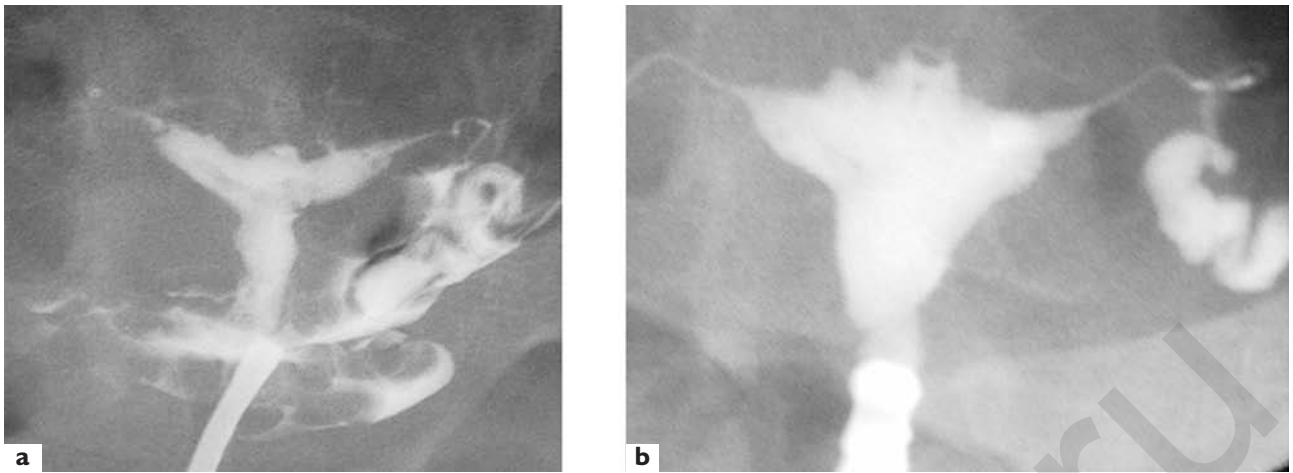


Figure 43.18 Hystero-graphy before (a) and after (b) hysteroplasty

synechia and placenta accreta. Therefore, hysteroplasty should be proposed only if the DES-exposed patient has an abnormal hystero-graphy in association with infertility, unsuccessful medically assisted procreation or repeated miscarriage with no explanation other than the abnormal hystero-graphy itself. Hysteroplasty should always be performed by experienced gynecologists.

Incomplete development of one Müllerian duct

Incomplete development of one Müllerian duct (Figure 43.19) gives rise to the more common unicornuate malformation, distinguished by the discovery of a Fallopian tube and round ligament, rudimentary though they may be, on the affected side. In this condition, two kidneys are usually present, although, occasionally, the one on the affected side may also be hypoplastic and not apparent on intravenous pyelography.

Non-communicating rudimentary horns can lead to dysmenorrhea if endometrium is present. In rare cases, reflux of shed endometrium is the origin of peritoneal endometriosis.

Pregnancy in a non-communicating rudimentary horn is uncommon, and usually results in miscarriage or uterine rupture. At hystero-graphy, a hemiuterus is diagnosed; indeed, the non-communicating rudimentary horn is not opacified. Pregnancy in a non-communicating rudimentary horn is due to transmigration of sperm into the Fallopian tube of the affected horn. Most complications occur within the first 20 weeks, the most severe being uterine rupture and maternal death. In order to avoid maternal complications, we systematically perform excision of the rudimentary horn. A laparoscopic hemihysterectomy can easily be carried out using the same techniques as for laparoscopic hysterectomy. The resected uterine horn can be removed by morcellation (Figure 43.20).

Fusion anomalies

Lateral fusion anomalies

These anomalies result from a failure of lateral fusion of the two Müllerian ducts, a condition which may be obstructive or non-obstructive. Failure of fusion of the Müllerian ducts occurs to varying degrees. If minor degrees affecting uterine shape are taken into consideration, this type of malformation is extremely common. The different nomenclatures and classifications of the resulting deformities can be confusing.

Arcuate uterus This is a flat-topped uterus in which the fundal bulge has not developed after fusion of the ducts (Figure 43.21)

Uterus subseptus and uterus septus The uterus is outwardly normal but contains a complete or incomplete septum, which reflects a failure in the breakdown of the walls between the two ducts. The cervical canal may be single or double, and the vagina whole or septate (Figure 43.22).

Uterine septum is the most common Müllerian fusion defect. Its incidence in the general population is estimated to be 1.8%⁵⁴.

Between 1986 and 1996 in our department, 170 patients underwent hysteroscopic septoplasty⁵⁵. In 83% of cases (141/170), the uterine septum was partial (Figure 43.23), and in 17% of cases (29/170), the uterine septum was complete, with cervical duplication. A vaginal septum was noted in 15 cases (9%). The diagnosis of a complete uterine septum may be delayed, particularly if a vaginal septum is associated⁵⁶. Indeed, the vaginal septum can easily be misdiagnosed by gynecological examination, and at hysterosalpingography the uterus may appear to be unicornuate, unless there is a fistula between the two uterine cavities (Figure 43.24). However, in the absence of

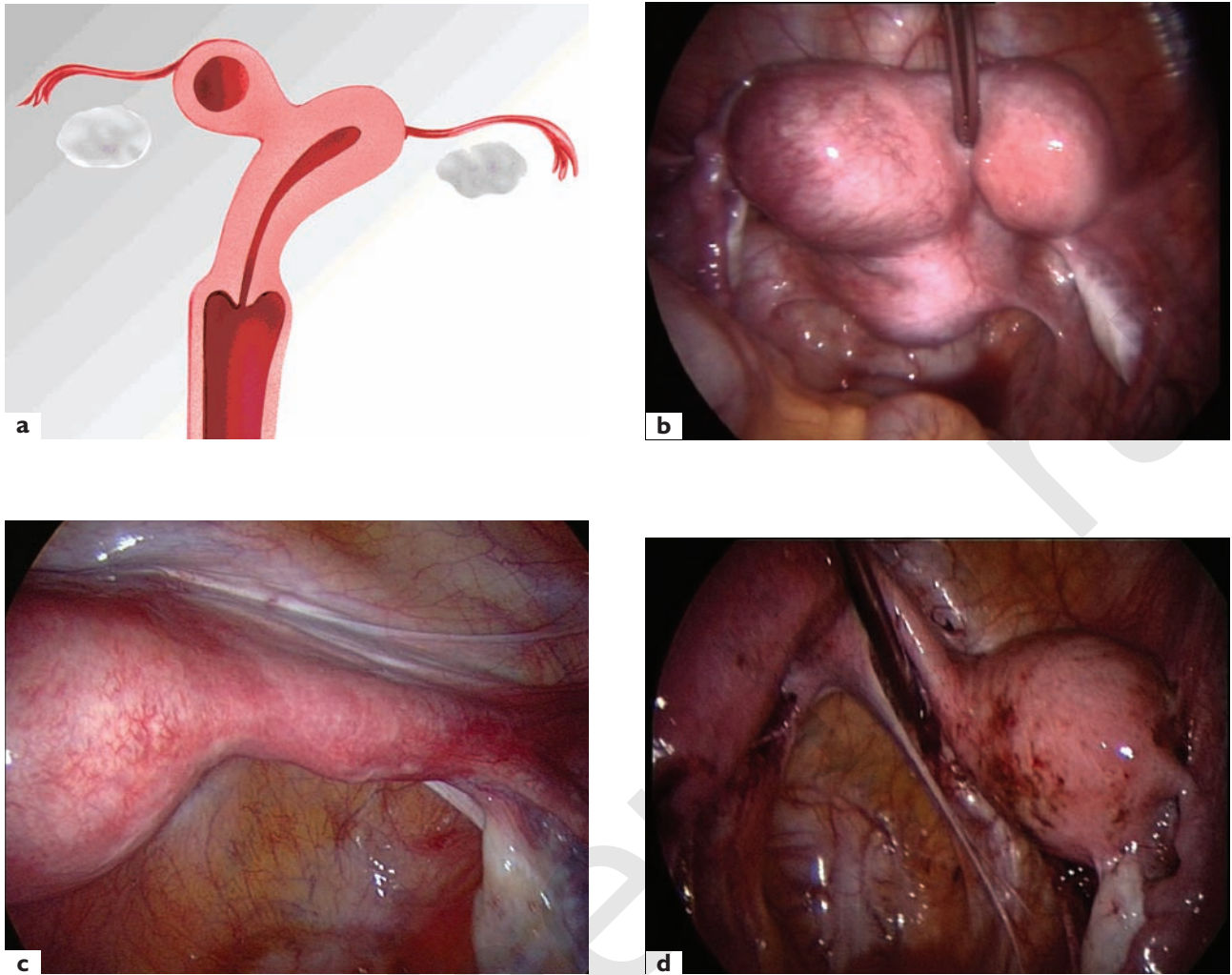


Figure 43.19 (a) Unicornuate uterus with rudimentary horn. (b) and (c) The size of the rudimentary horn can vary. (d) Associated endometriosis is frequently seen

a vaginal septum, the diagnosis is simple, because two distinct external cervical orifices are clearly visible. Opacification through these two orifices allows the diagnosis of a septate uterus with cervical duplication.

It is not clear why uterine anomalies are associated with reproductive failure. According to histological observations, the septum is described as 'fibroelastic tissue'⁵⁷. Using scanning electron microscopy to compare endometrial biopsy specimens obtained from different areas of the uterine cavity, Fedele *et al.*⁵⁸ found that septal endometrium showed defective development, indicative of a reduction in sensitivity to steroid hormones. They subsequently postulated that endometrial septal defects could play a role in the pathogenesis of primary infertility in cases of uterine septa.

Another hypothesis that could explain reproductive failure is that spontaneous miscarriage may be the result of a poor blood supply to the septum, leading to poor implantation dynamics⁵⁹.

In a review published in 2000, Homer *et al.* reported the reproductive outcome of women with an untreated septate uterus⁶⁰. Out of 1376 pregnancies, 1085 (79%) ended in miscarriage and 125 (9%) in preterm delivery. However, if we calculate the percentage of preterm deliveries among ongoing pregnancies, a hefty 42% of patients, who escaped the very high risk of miscarriage, delivered prematurely. It is clearly necessary to try to improve the situation.

In their review, Homer *et al.*⁶⁰ reported data from several series that compared the outcomes of pregnancies before and after hysteroscopic metroplasty in patients with a septate uterus. The miscarriage rate, preterm delivery rate and term delivery rate were 88%, 9% and 3%, respectively, before surgery, and 14%, 6% and 80% after hysteroscopic metroplasty.

More recently, other authors have published their findings on reproductive outcome after hysteroscopic metroplasty for a septate uterus. Hickok⁶¹ reported his

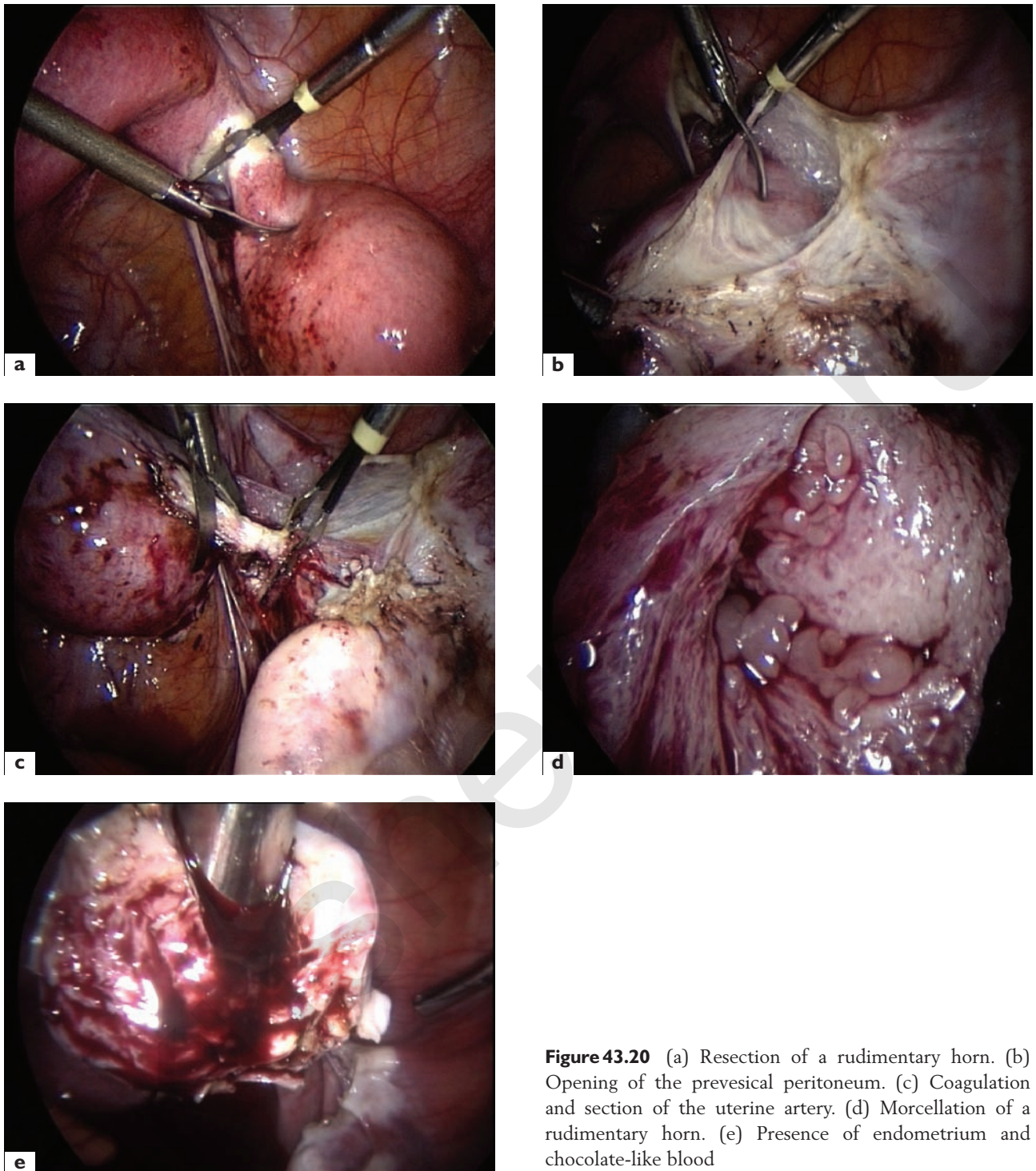


Figure 43.20 (a) Resection of a rudimentary horn. (b) Opening of the prevesical peritoneum. (c) Coagulation and section of the uterine artery. (d) Morcellation of a rudimentary horn. (e) Presence of endometrium and chocolate-like blood

experience with hysteroscopic treatment of uterine septa. The preoperative pregnancy loss rate was 77.4%, while the postoperative miscarriage rate was 18.2%. Patton *et al.*⁶² reported a very similar result. In the specific case of complete uterine septum, duplicated cervix and vaginal septum, 12 out of 16 women conceived after surgery. The pregnancy loss rate was 81% before surgery and 18% after.

Litta *et al.*⁶³ reported their experience with hysteroscopic metroplasty under laparoscopic guidance for patients with a septate uterus. Of 35 patients treated, 26 (75%) achieved pregnancy. Only three patients delivered prematurely.

Table 43.2 summarizes the reproductive outcome after hysteroscopic metroplasty for septate uterus. After surgery, the miscarriage rate is 14.3% (88/617). Out of 529

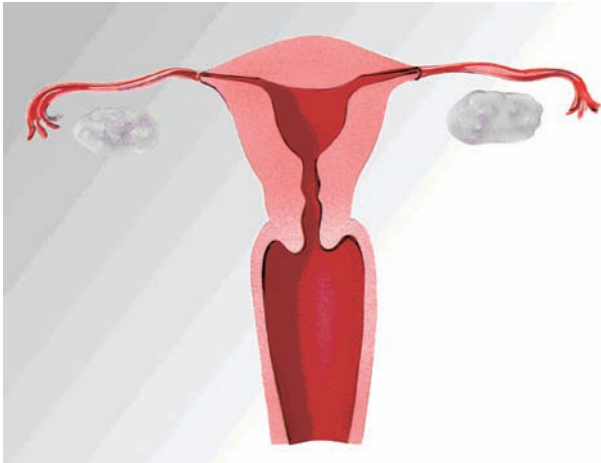


Figure 43.21 Arcuate uterus

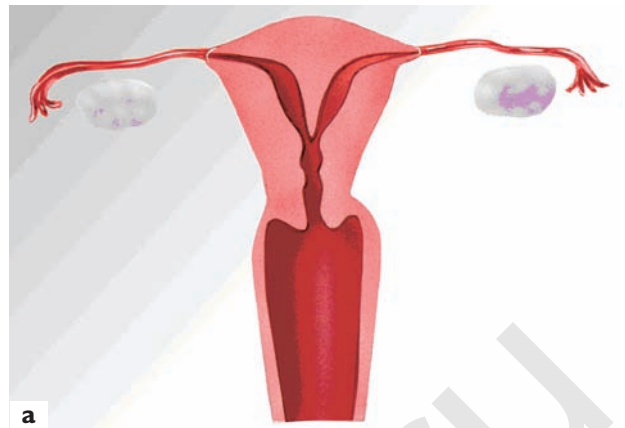
ongoing pregnancies, the preterm delivery rate is 7.2% (38/529) and the term delivery rate 92.8% (491/529)

The endoscopic technique for the management of uterine septa was first proposed in 1970 by Edström and Fernström⁷⁷.

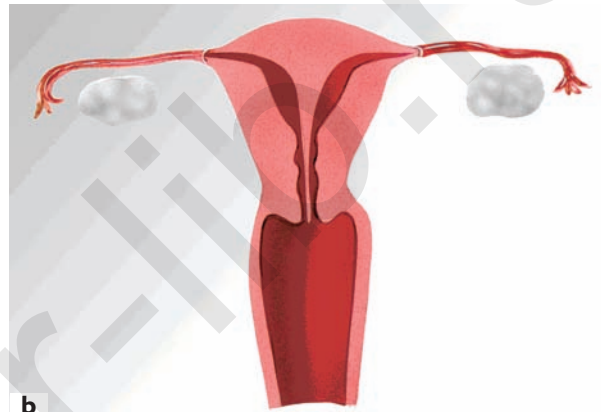
The basic concept involves transcervical observation of the uterine septum by means of hysteroscopy, followed by its resection^{78–81}. The use of an operative hysteroscope allows the passage of surgical instruments.

Various instruments can be used for resection of the septum: miniature scissors or semirigid miniature scissors, which supply the required pressure but are small enough to pass through the hysteroscopic operating sheath and along the cervical canal with no difficulty or risk. The blades can be opened wide enough to allow resection of even thick septa. Other surgeons prefer to use the resectoscope^{82–84}. High-frequency electrical sources are advised for safety reasons. The resectoscope has several advantages: it is inexpensive and readily available in most operating rooms, as well as being simple to operate and highly efficient at removing the septum. Finally, others have suggested the use of lasers for this type of hysteroscopic surgery^{85–87}. Argon, krypton, KTP/532 (potassium–titanyl–phosphate) and Nd:YAG (neodymium:yttrium–aluminum–garnet) lasers have all been successfully employed in the resection of uterine septa.

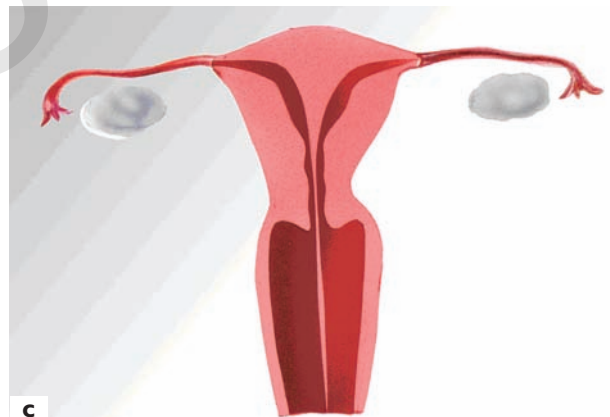
Partial uterine septum: With the help of the 'bare fiber' or the L-shaped electrode of the resectoscope, the surgeon begins resection of the septum (Figure 43.25), continuing until it has been resected almost flush with the surrounding endometrium. Regardless of the type of medium employed, the surgeon must be able to see the right and left cornual regions completely, and keep the septum in view at all times. Concurrent laparoscopy at the time of hysteroscopic resection is recommended to confirm the



a



b



c

Figure 43.22 (a) Incomplete uterine septum, (b) complete uterine septum and (c) complete uterovaginal septum

diagnosis, but is not mandatory if the diagnosis has previously been confirmed.

The most delicate part of the procedure is probably deciding exactly when the resection is sufficient, and when continuing would cause damage to the myometrium and immediate complications such as perforation, or more delayed complications such as uterine rupture during

Table 43.2 Reproductive outcome after hysteroscopic metroplasty for septate uterus

Author(s)	Patients (n)	Pregnancies (n)	Miscarriages (n (%))	Ongoing pregnancies (n)	Ongoing pregnancies with preterm deliveries (n)	Ongoing pregnancies with term deliveries (n)
Chervenak and Neuwirth ⁶⁴	2	2	0	2	0	2
De Cherney and Polan ⁶⁵	15	11	2 (18)	9	0	9
Fayez ⁶⁶	12	16	2 (13)	14	0	14
March and Israel ⁶⁷	57	56	8 (14)	48	4	44
Perino <i>et al.</i> ⁶⁸	24	15	1 (7)	14	0	14
Daly <i>et al.</i> ⁶⁹	55	75	15 (20)	60	5	55
Choe and Baggish ⁷⁰	14	12	1 (8.3)	11	1	10
Fedele <i>et al.</i> ⁵⁸	71	65	10 (16)	55	10	45
Cararach <i>et al.</i> ⁷¹	62	41	12 (29)	29	0	29
Pabuccu <i>et al.</i> ⁷²	49	44	2 (4.5)	42	2	40
Valle ⁷³	115	103	12 (12)	91	7	84
Mencaglia and Tantini ⁷⁴	94	62	4 (6)	58	0	58
Patton <i>et al.</i> ⁶²	16	17	3 (18)	14	0	14
Hickok ⁶¹	40	22	4 (18.2)	18	1	17
Jourdain <i>et al.</i> ⁷⁵	20	12	2 (16.6)	10	0	10
Colacurci <i>et al.</i> ⁷⁶	69	46	10 (21.8)	36	5	31
Litta <i>et al.</i> ⁶³	20	18	0	18	3	15
Total	735	617	88 (14.3%)	529 (85.7%)	38 (7.2%)	491 (92.8%)

complete uterine septa, ten out of 17 women became pregnant, and no signs of cervical incompetence were observed⁵⁶. Prophylactic cerclage was never performed after resection of a complete cervical and uterine septum. Following hysteroscopic metroplasty, cesarean section should be performed only for obstetric reasons. In our series, intraoperative and postoperative complications were encountered in only three cases (1.8%).

Uterus didelphys If the two Müllerian ducts remain separate, the two halves of the uterus remain distinct and each has its own cervix (Figure 43.31). Some distinguish between uterus didelphys and uterus pseudodidelphys, according to the degree of separation between the two ducts.

Septate and subseptate vagina A sagittal septum with a crescentic lower edge may be present in the upper vagina or throughout its length. It can occur alone or in conjunction with a septate or bicornuate condition of the uterus,

and may have one or two cervixes opening into it. This condition arises either because late fusion of the Müllerian ducts gives rise to two Müllerian tubercles, or because of failure of proper canalization of the two sinovaginal bulbs.

In some cases, the hemivagina is not patent, taking the form of a blind vaginal pouch (Figures 43.32 and 43.33). The obstructed hemivagina is associated with either a functioning double uterus or a degenerate remnant of the paramesonephric duct. This uterine remnant is lined with ciliated columnar cells with occasional papillary projections. It may also contain patches of endometrial and/or glandular epithelium that produce a mucoid and/or menstrual discharge. At the time of puberty, absence of the lower part of the hemivagina is responsible for the development of hematocolpos, while the opposite hemivagina is patent. The diagnosis is usually facilitated by magnetic resonance imaging or computed tomography scan (Figure 43.34), which reveals not only hematocolpos but also

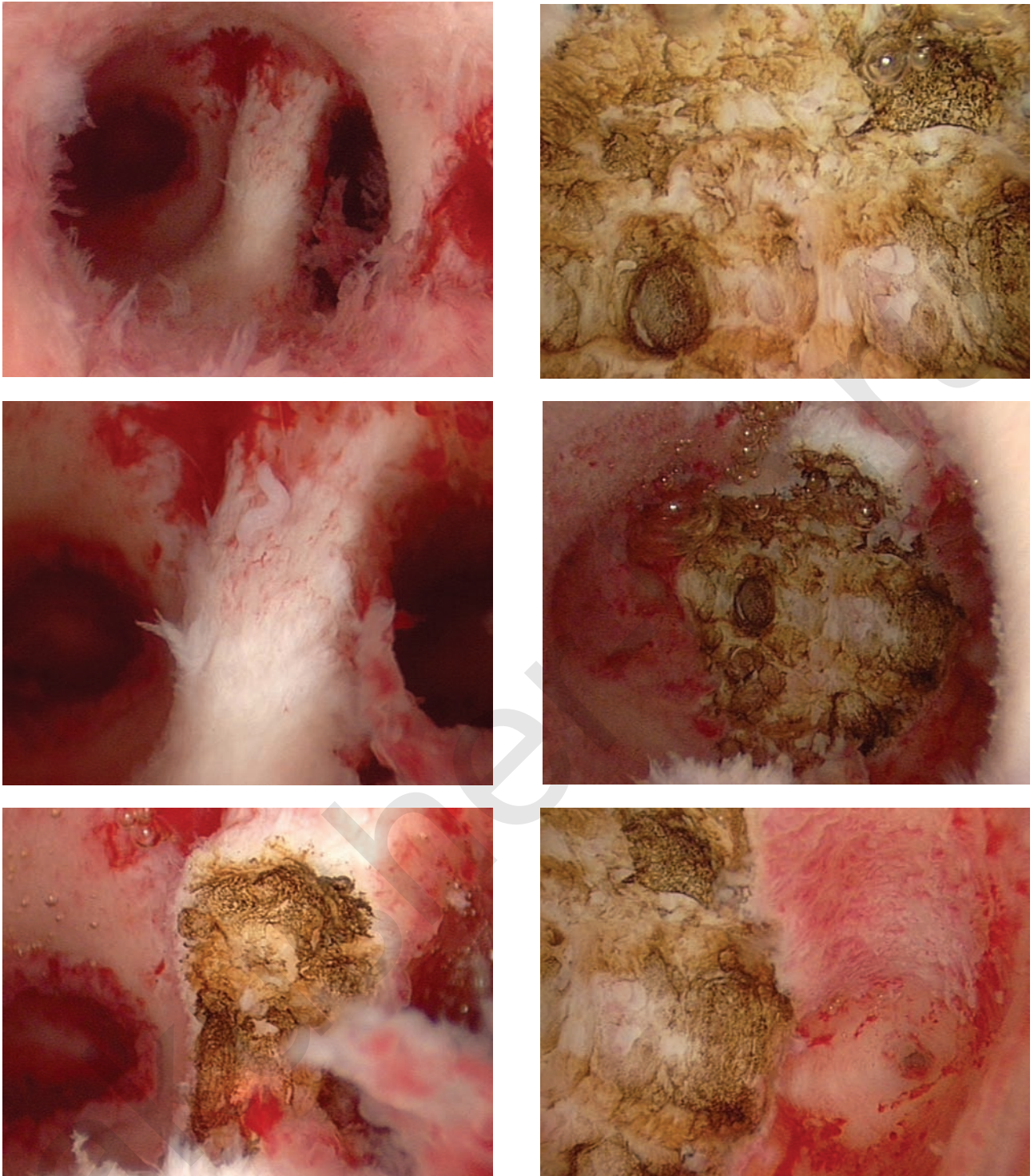


Figure 43.25 Resection of the uterine septum with a Nd:YAG laser. The hysteroscope with the laser fiber is advanced and the septum is melted away by simply advancing the fiber

hematometra and hematosalpinx. In childhood, an obstructed hemivagina is usually asymptomatic unless distended by mucus. In this case, a simple incision and resection of the vaginal septum will allow continued

drainage. With menstruation, the resulting hematocolpos may be evacuated after complete resection of the septum. An obstructed hemivagina and double uterus are almost always associated with ipsilateral renal agenesis^{90,91}.

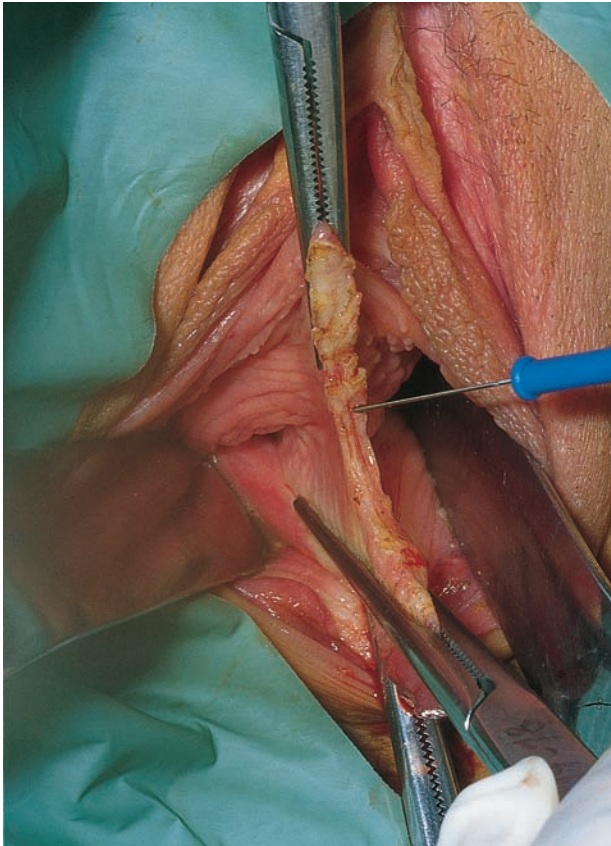


Figure 43.26 Vaginal sagittal septum. Resection of the septum using unipolar coagulation

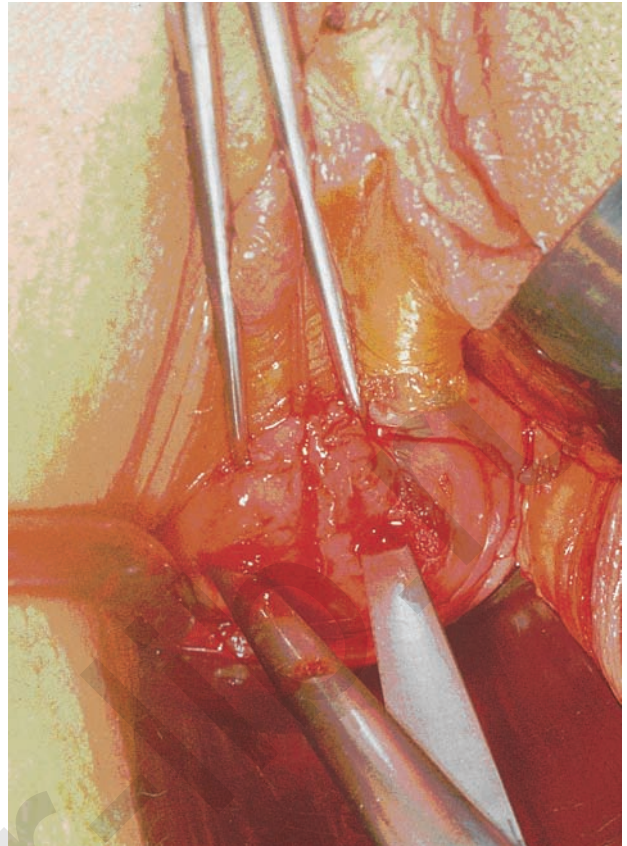

Figure 43.28 The cervical septum is incised with scissors

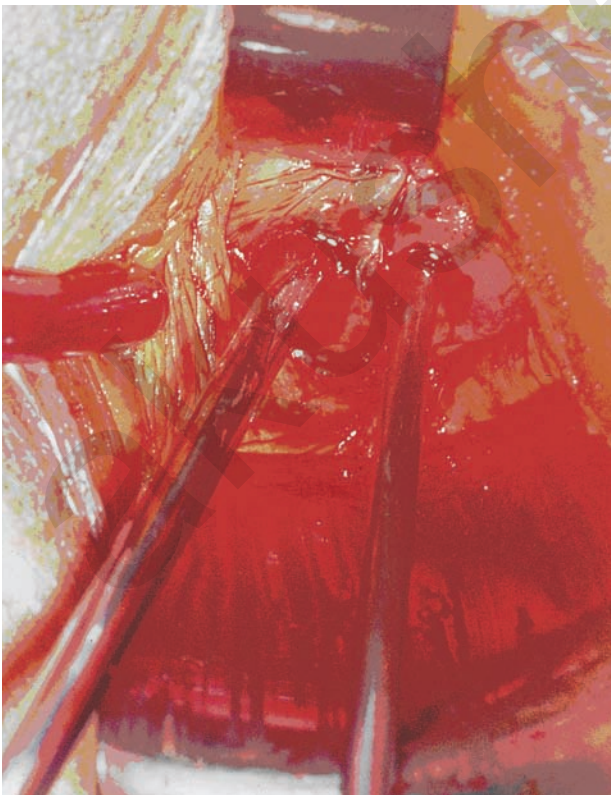


Figure 43.27 Dilatation of both cervical canals

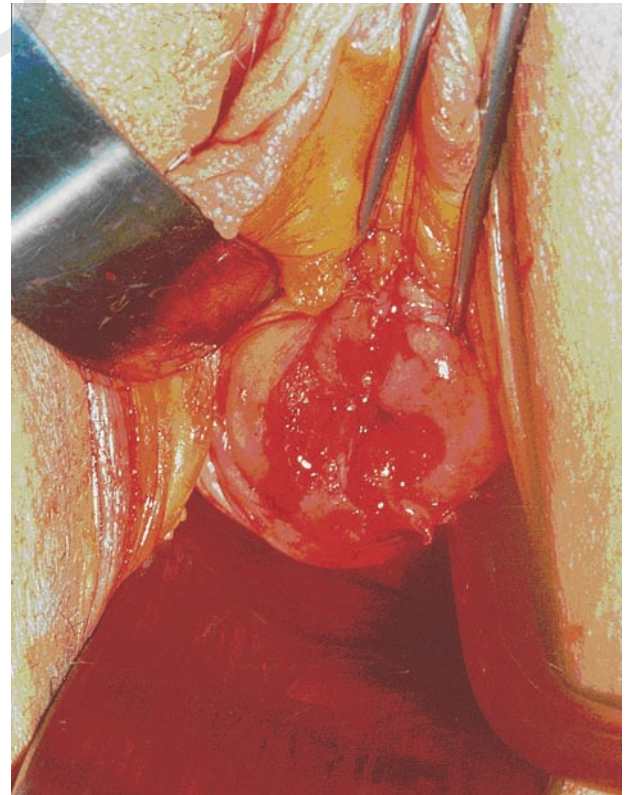


Figure 43.29 The external os is completely normal

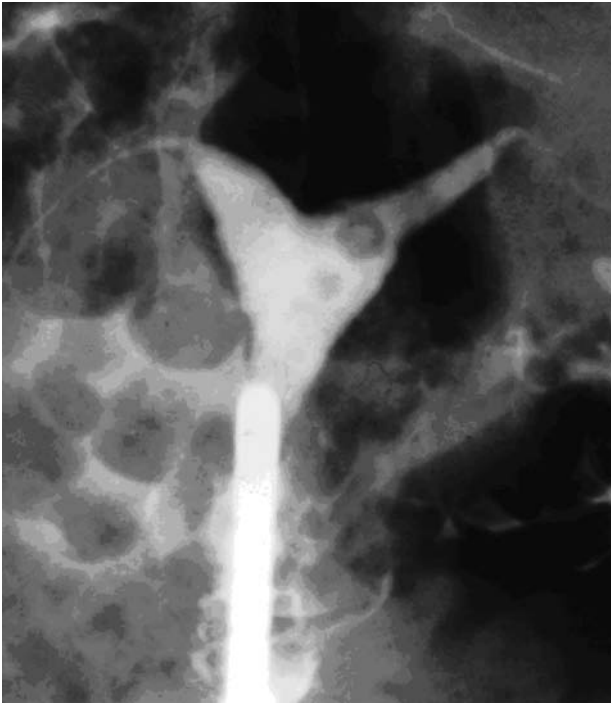

Figure 43.30 Postoperative hysterothorography: the morphology of the uterine cavity resembles an arcuate uterus

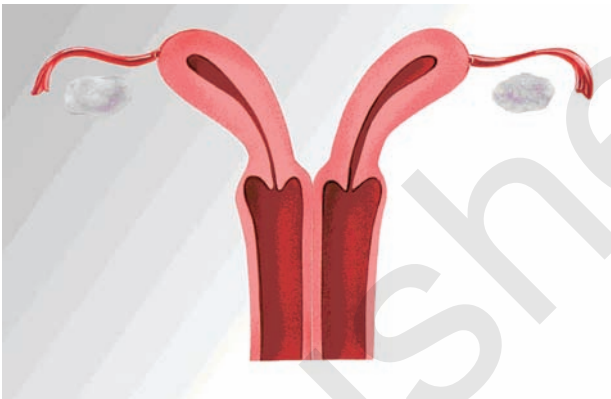

Figure 43.31 Uterus didelphys

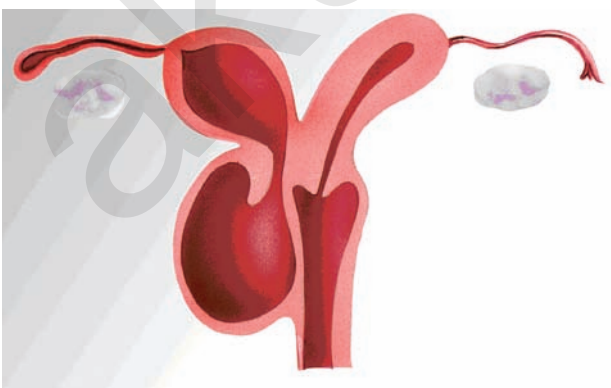


Figure 43.32 Septate vagina. The obstructed hemivagina is associated with a functioning double uterus

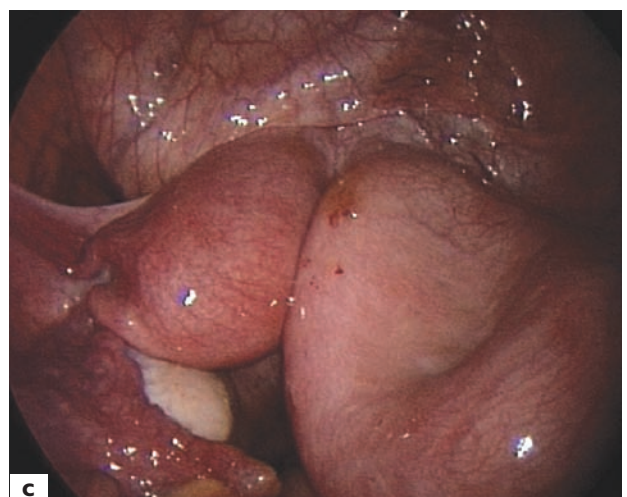
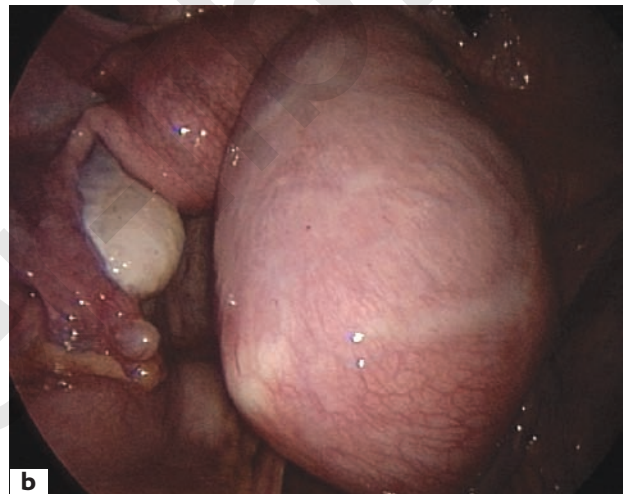
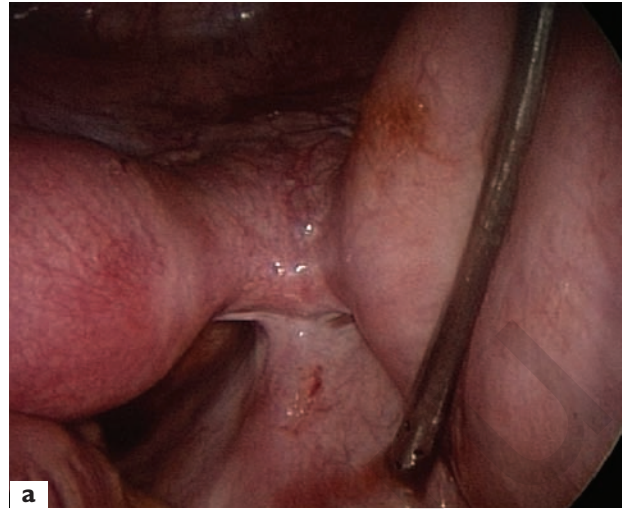


Figure 43.33 (a) Laparoscopic view of a septate vagina associated with uterus didelphys. (b) The right uterus is distended by hematometra. (c) After removal of the vaginal septum, the right uterus is emptied

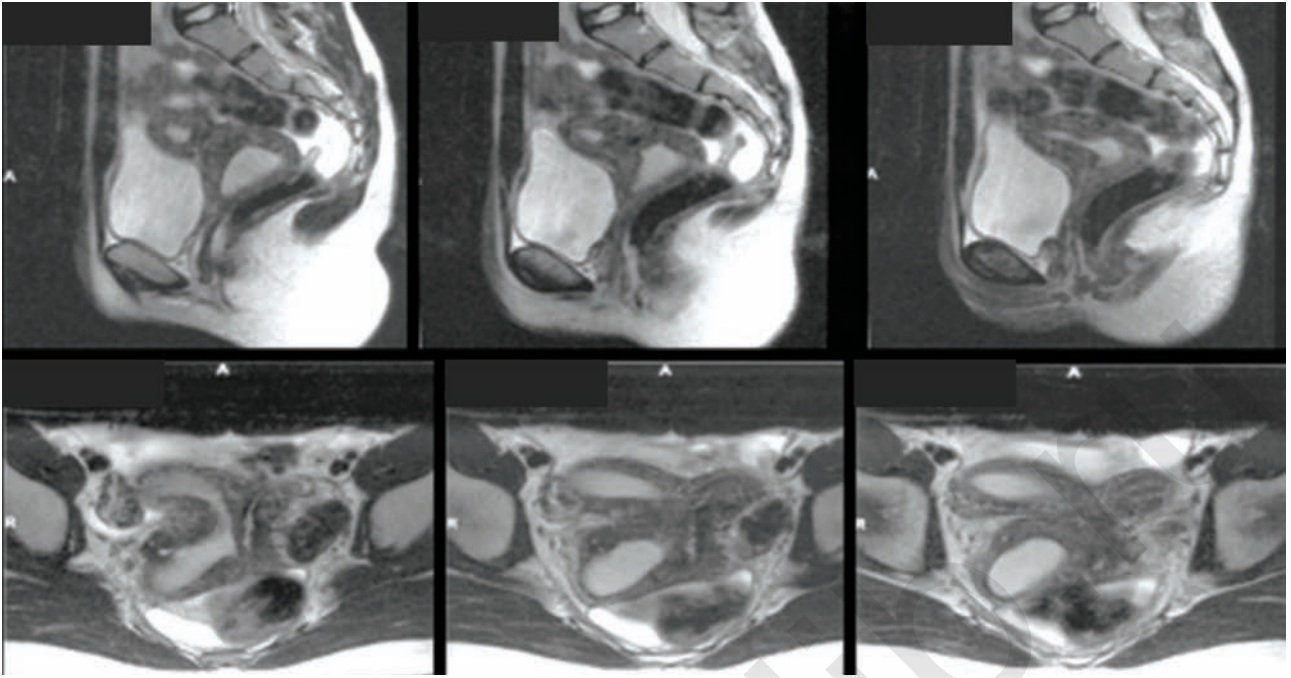


Figure 43.34 Magnetic resonance imaging of a septate vagina with hematocolpos and hematometra on the right side

Vertical fusion anomalies: incomplete canalization

The Müllerian buds have solid tips, behind which canalization takes place progressively. The Müllerian and sinovaginal bulb tissue, which forms the vagina, is also lumenless at first. Failure to canalize results in either solid organs or membranes of varying thickness obstructing the genital canal. Thus, a rudimentary uterus sometimes lacks a cavity and the vagina may be represented by an uncanalized column of tissue. Atresia may affect only one Müllerian duct, so that one horn of a bicornuate uterus may fail to communicate with the cervical canal, or one half of a septate vagina may be a closed cavity. Unilateral hematocolpos, mucocolpos and pyocolpos are not common.

Cervical atresia Congenital atresia of the cervix of an otherwise normal uterus or bicornuate uterus is rare (Figure 43.35). When it does occur, a reasonably normal vagina is invariably present. It is more common to encounter apparent cervical atresia in association with an absence of the lower vagina.

Vaginal atresia and transverse vaginal septum Disorders of vertical fusion result from defects in the union between the downward-progressing Müllerian tubercles and the upgrowing derivative of the urogenital sinus. Similar defects may also occur secondary to failure in canalization of the solid vaginal tube, either because of abnormal proliferation of paravaginal mesoderm or because of some form of intrauterine infection. Partial vaginal atresia is usually diagnosed in young patients at the time of puberty. Indeed, an

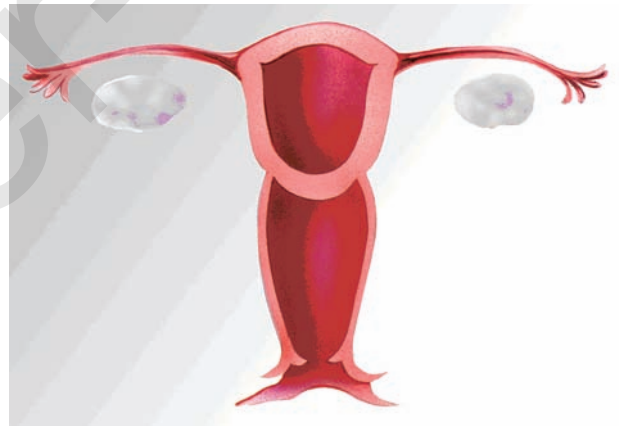


Figure 43.35 Cervical atresia

absence of the lower part of the vagina is responsible for the development of hematocolpos.

Progressive distension of the upper part of the vagina causes hypogastric pain, and, in the case of abundant hematocolpos (> 500 ml), dysuria or urinary retention may be associated. Vulvar and rectal examinations allow us to make the diagnosis of vaginal atresia. A computed tomography scan or magnetic resonance imaging reveal the hematocolpos, associated or not with a uterine malformation (uterine septum) (Figure 43.36).

Transverse vaginal septa are relatively rare, affecting approximately one in every 80 000 females. The septum consists of a central fibromuscular plate or ring of varying

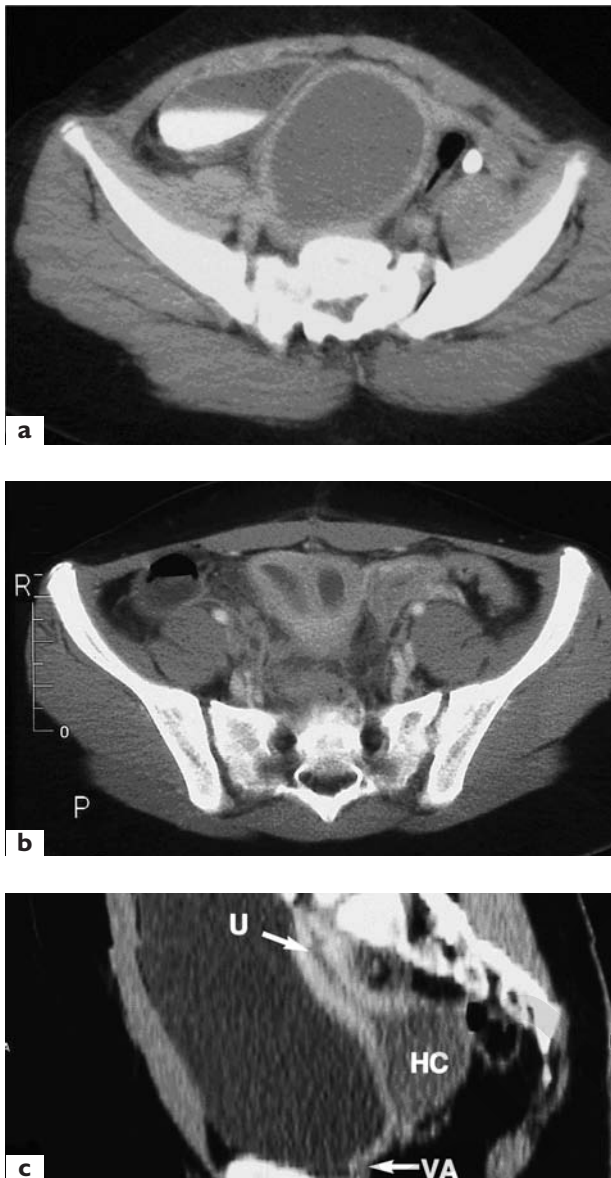


Figure 43.36 (a) Computed tomography reveals hematocolpos. (b) It has been found to be associated with uterine septum. (c) Magnetic resonance imaging reveals partial vaginal atresia (VA), hematocolpos (HC) and the uterus (U)

thickness. When the obstruction is complete, the outer surface is covered with stratified squamous epithelium, while the inner aspect is composed of glandular columnar epithelium. The interruption can occur at any level of the vagina, and may be multiple. The middle and lower zones of the vagina may be imperforate over a length of 0.5–6.0 cm. More frequently, the vagina is obstructed by a thinner membrane situated in the vagina, just above the hymen. Transverse vaginal septa usually go unnoticed in children unless mucocolpos develops or vaginal patency is tested. A rim of hymenal tissue will help to distinguish low transverse septa from an imperforate hymen. Distension of

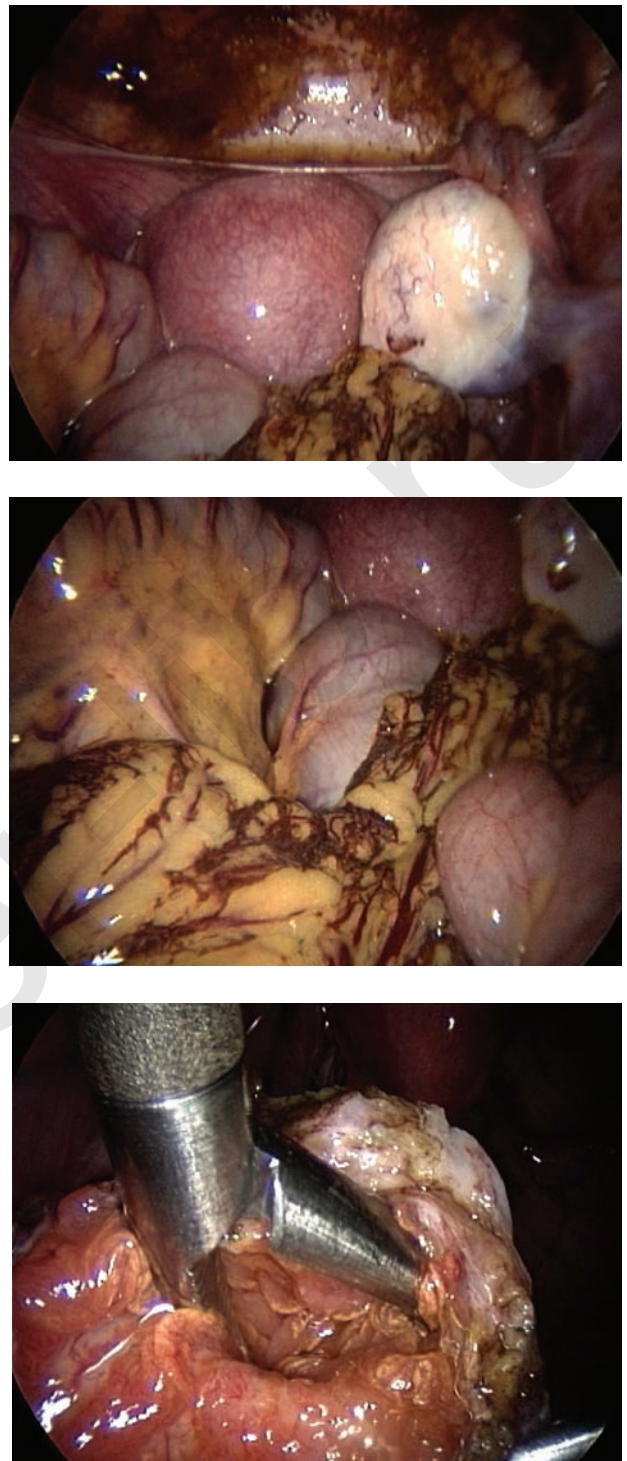


Figure 43.37 Endometriosis related to obstructive malformation

the septum, as seen vaginally, will depend on its thickness and location. As in the case of imperforate hymen, the vulva may be very engorged and swollen. The obstruction of menstrual flow and subsequent endometriosis may result in infertility (Figure 43.37). In a study of 15 teenage patients with pelvic pain and endometriosis, six (40%)

were found to have obstructive anomalies of the genitalia⁹². Goldstein *et al.* reported endometriosis in 52% of 140 adolescents evaluated laparoscopically for pelvic pain⁹³. Of these cases, only 50% of patients had obstructive uterine anomalies.

REFERENCES

- Ancien P, Ancien M, Sanchez-Ferrer M. Complex malformations of the female genital tract. New types and revision of classification. *Hum Reprod* 2004; 19: 2377–84
- Marshall FF, Beisel DS. The association of uterine anomalies. *Obstet Gynecol* 1978; 51: 559–62
- O'Rahilly R. The development of the vagina in the human. *Birth Defects* 1977; 13: 123–36
- O'Rahilly R. The embryology and anatomy of the uterus. In Norris H, Hertig A, eds. *The Uterus*. Baltimore: Williams & Wilkins, 1973
- Nisolle M, Donnez J. Malformations and maldevelopments of the Müllerian ducts. In Donnez J, ed. *Laparoscopic Operative Laparoscopy and Hysteroscopy*. Leuven: Nauwelaerts Printing, 1989: 231–48
- Nisolle M, Donnez J. Vaginoplasty using amniotic membranes in cases of vaginal agenesis or after vaginectomy. *J Endosc Surg* 1992; 8: 25–30
- Frank RT. The formation of an artificial vagina without operation. *Am J Obstet Gynecol* 1938; 35: 1053–5
- Vecchietti G. [Creation of an artificial vagina in Rokitansky–Kuster–Hauser syndrome]. *Actual Ostet Ginecol* 1965; 11: 131–47
- Keckstein J, Buck G, Sasse V, et al. Laparoscopic creation of a neovagina: modified Vecchietti method. *Endosc Surg Allied Technol* 1995; 3 (2–3): 93–5
- Veronikis DK, McClure GB, Nichols DH. The Vecchietti operation for constructing a neovagina: indications, instrumentation, and techniques. *Obstet Gynecol* 1997; 90: 301–4
- Khater E, Fathy H. Laparoscopic Vecchietti vaginoplasty. *J Am Assoc Gynecol Laparosc* 1999; 6: 179–82
- Fedele L, Bianchi S, Zanconato G, Raffaelli R. Laparoscopic creation of a neovagina in patients with Rokitansky syndrome: analysis of 52 cases. *Fertil Steril* 2000; 74: 384–9
- Borruto F, Chasen ST, Chervenak FA, Fedele L. The Vecchietti procedure for surgical treatment of vaginal agenesis: comparison of laparoscopy and laparotomy. *Int J Gynaecol Obstet* 1999; 64: 153–8
- Baldwin JF. The formation of an artificial vagina by intestinal transplantation. *Ann Surg* 1904; 40: 398–403
- Turner-Warwick R, Kirby RS. The construction and reconstruction of the vagina with the colocecum. *Surg Gynecol Obstet* 1990; 170: 132–6
- O'Connor JL, DeMarco RT, Pope JC 4th, et al. Bowel vaginoplasty in children: a retrospective review. *J Pediatr Surg* 2004; 39: 1205–8
- McIndoe AH, Bannister JE. An operation for the cure of congenital absence of the vagina. *J Obstet Gynaecol Br Emp* 1938; 45: 490–4
- Heath PM, Woods JE, Podratz KC, et al. Gracilis myocutaneous vaginal reconstruction. *Mayo Clin Proc* 1984; 59: 21–4
- Lagasse LD, Berman ML, Watring WG, et al. The gynecologic oncology patient: restoration of function and prevention of disability. In McGowan L, ed. *Gynecologic Oncology*. New York: Appleton-Century-Crofts, 1978: 398
- Lacey PM, Morrow CP. Myocutaneous vaginal reconstruction. In Morrow CP, Smart GE, eds. *Gynecologic Oncology*. Berlin: Springer-Verlag, 1986: 255–9
- Wheless CR. Vulvar-vaginal reconstruction. In Coppleson M, ed. *Gynecologic Oncology: Fundamental Principles and Clinical Practice*. Edinburgh: Churchill Livingstone, 1981; 2: 933–6
- McCraw JB, Massey FM, Shanklin KD, et al. Vaginal reconstruction with gracilis myocutaneous flaps. *Plast Reconstr Surg* 1976; 58: 176–83
- Gordon RT, Thomas GD. Vaginal and pelvic reconstruction with distally based rectus abdominis myocutaneous flaps. *Plast Reconstr Surg* 1988; 81: 62–73
- Wee TK, Joseph VT. A new technique of vaginal reconstruction using neurovascular pudendal-thigh flaps: a preliminary report. *Plast Reconstr Surg* 1989; 83: 701–9
- Brindeau A. Creation d'un vagin artificiel à l'aide des membranes ovulaires d'un oeuf à terme. *Gynecol Obstet* 1934; 29: 385
- Burger K. Weitere Erfahrungen über die kunstliche Scheidenbildung mit Eihäuten. *Zentralbl Gynäkol* 1947; 69: 1153
- Trelford JD, Hanson FW, Anderson DG. Amniotic membrane as a living surgical dressing in human patients. *Oncology* 1973; 28: 358–64
- Trelford JD, Anderson D, Hanson F, et al. Amniotic membrane used for radical vulvectomies. *Obstet Gynecol Observ* 1973; 12: 1
- Trelford JD, Hanson FW, Anderson DS. The feasibility of making an artificial vagina at the time of anterior exenteration. *Oncology* 1973; 28: 398–401
- Dhall K. Amnion graft for treatment of congenital absence of the vagina. *Br J Obstet Gynaecol* 1984; 91: 279
- Faulk WP, Matthews R, Stevens PJ, et al. Human amnion as an adjunct in wound healing. *Lancet* 1980; 1: 1156–8
- Akle CA, Adinolfi M, Welsh KI, et al. Immunogenicity of human amniotic epithelial cells after transplantation into volunteers. *Lancet* 1980; 2: 1003–5
- Tancer ML, Katz M, Veridiano NP. Vaginal epithelialization with human amnion. *Obstet Gynecol* 1979; 54: 345–9
- Ashworth MF, Morton KE, Dewhurst J, et al. Vaginoplasty using amnion. *Obstet Gynecol* 1986; 67: 443–6

35. Badylak SF, Kropp B, McPherson T, et al. Small intestinal submucosa: a rapidly resorbed bioscaffold for augmentation cystoplasty in a dog model. *Tissue Eng* 1998; 4: 379–87
36. Kropp BP, Ludlow JK, Spicer D, et al. Rabbit urethral regeneration using small intestinal submucosa onlay grafts. *Urology* 1998; 52: 138–42
37. Davydov SN. [Colpopoiesis from the peritoneum of the uterorectal space]. *Akush Ginekol (Mosk)* 1969; 45: 55–7
38. Adamian LV, Zurabiani ZR, Kiselev SI, Khashukoeva AZ. Laparoscopy in surgical treatment of vaginal aplasia: laparoscopy-assisted colpopoiesis and perineal hysterectomy with colpopoiesis. *Int J Fertil Menop Stud* 1996; 41: 40–5
39. Soong YK, Chang FH, Lai YM, et al. Results of modified laparoscopically assisted neovaginoplasty in 18 patients with congenital absence of vagina. *Hum Reprod* 1996; 11: 200–3
40. Ikuta K, Iida T, Okada H, et al. Laparoscopic-assisted creation of a vagina. *J Am Assoc Gynecol Laparosc* 1996; 4: 53–6
41. Langebrekke A, Istre O, Busund B, et al. Laparoscopic assisted colpoiesis according to Davydov. *Acta Obstet Gynecol Scand* 1998; 77: 1027–8
42. Templeman CL, Hertweck SP, Levine RL, Reich H. Use of laparoscopically mobilized peritoneum in the creation of a neovagina. *Fertil Steril* 2000; 74: 589–92
43. Sheth NP, Chainani MS, Sheth SN. Vaginoplasty from peritoneal tube of Douglas' pouch for congenital vaginal agenesis. *Eur J Pediatr Surg* 2003; 13: 213–14
44. Kaufman RH, Adam E, Binder GL, Gerthoffer E. Upper genital tract changes and pregnancy outcome in offspring exposed in utero to diethylstilbestrol. *Am J Obstet Gynecol* 1980; 137: 299–308
45. Robboy SJ. A hypothetic mechanism of diethylstilbestrol (DES)-induced anomalies in exposed progeny. *Hum Pathol* 1983; 14: 831–3
46. Robboy SJ, Taguchi O, Cunha GR. Normal development of the human female reproductive tract and alterations resulting from experimental exposure to diethylstilbestrol. *Hum Pathol* 1982; 13: 190–8
47. Smith OW. Diethylstilbestrol in the prevention and treatment of complications of pregnancy. *Am J Obstet Gynecol* 1948; 56: 821–34
48. Herbst AL, Scully RE. Adenocarcinoma of the vagina in adolescence. A report of 7 cases including 6 clear-cell carcinomas (so-called mesonephromas). *Cancer* 1970; 25: 745–57
49. Senekjian EK, Potkul RK, Frey K, Herbst AL. Infertility among daughters either exposed or not exposed to diethylstilbestrol. *Am J Obstet Gynecol* 1988; 158: 493–8
50. Nagel TC, Malo JW. Hysteroscopic metroplasty in the diethylstilbestrol-exposed uterus and similar nonfusion anomalies: effects on subsequent reproductive performance; a preliminary report. *Fertil Steril* 1993; 59: 502–6
51. Garbin O, Ohl J, Bettahar-Lebugle K, et al. Hystéroplasties transcervicales: indications, techniques et resultants. A propos de 125 cas. *Contracept Fertil Sex* 1997; 25: 843–51
52. Aubriot FX, Hamou J, Dubuisson JB, et al. L'hystéroplastie d'agrandissement: à propos des résultats. *Gynécol Obstét Fertil* 2001; 29: 888–93
53. Barranger E, Gervaise A, Doumerc S, Fernandez H. Reproductive performance after hysteroscopic metroplasty in the hypoplastic uterus: a study of 29 cases. *Br J Obstet Gynaecol* 2002; 109: 1331–4
54. Ashton D, Amin HK, Richart RM, Neuwirth RS. The incidence of symptomatic uterine anomalies in women undergoing transcervical tubal sterilization. *Obstet Gynecol* 1988; 72: 28–30
55. Donnez J, Nisolle M. Endoscopic laser treatment of uterine malformations. *Hum Reprod* 1997; 12: 1381–7
56. Nisolle M, Donnez J. Unaudited clinical experience. *Fertil Steril* 1995; 63: 934–5
57. Fedele L, Bianchi S. Hysteroscopic metroplasty for the septate uterus. *Obstet Gynecol Clin North Am* 1995; 22: 473–89
58. Fedele L, Arcaini L, Parazzini F, et al. Reproductive prognosis after hysteroscopic metroplasty in 102 women: life-table analysis. *Fertil Steril* 1993; 59: 768–72
59. Burchell RC, Creed F, Rasoulpour M, Whitcomb M. Vascular anatomy of the human uterus and pregnancy wastage. *Br J Obstet Gynaecol* 1978; 85: 698–706
60. Homer HA, Li T-C, Cooke ID. The septate uterus: a review of management and reproductive outcome. *Fertil Steril* 2000; 73: 1–14
61. Hickok L. Hysteroscopic treatment of the uterine septum: a clinician's experience. *Am J Obstet Gynecol* 2000; 182: 1414–20
62. Patton P, Novy M, Lee D, Hickok L. The diagnosis and reproductive outcome after surgical treatment of the complete septate uterus, duplicated cervix and vaginal septum. *Am J Obstet Gynecol* 2004; 190: 1669–78
63. Litta P, Pozan C, Merlin F, et al. Hysteroscopic metroplasty under laparoscopic guidance in infertile women with septate uteri: follow-up of reproductive outcome. *J Reprod Med* 2004; 49: 274–8
64. Chervenak FA, Neuwirth RS. Hysteroscopic resection of the uterine septum. *Am J Obstet Gynecol* 1981; 141: 351–3
65. De Cherney A, Polan ML. Hysteroscopic management of intrauterine lesions and intractable uterine bleeding. *Obstet Gynecol* 1983; 61: 392–7
66. Fayez JA. Comparison between abdominal and hysteroscopic metroplasty. *Obstet Gynecol* 1986; 70: 399–406
67. March CM, Israel R. Hysteroscopic management of recurrent abortion caused by the septate uterus. *Am J Obstet Gynecol* 1987; 156: 834–42
68. Perino A, Mencaglia L, Hamou J, et al. Hysteroscopy for metroplasty of uterine septa: report of 24 cases. *Fertil Steril* 1987; 48: 321–3

69. Daly DC, Maier D, Soto-Albors C. Hysteroscopic metroplasty: six years' experience. *Obstet Gynecol* 1989; 73: 201-5
70. Choe JK, Baggish MS. Hysteroscopic treatment of septate uterus with neodymium-YAG laser. *Fertil Steril* 1992; 57: 81-4
71. Cararach M, Penelle J, Ubeda A, et al. Hysteroscopic incision of the septate uterus: scissors versus resectoscope. *Hum Reprod* 1994; 9: 87-97
72. Pabuccu R, Atay V, Urman B, et al. Hysteroscopic treatment of septate uterus. *Gynaecol Endosc* 1995; 4: 213-15
73. Valle RF. Hysteroscopic treatment of partial and complete uterine septum. *Int J Fertil Menop Stud* 1996; 41: 310-15
74. Mencaglia L, Tantini C. Hysteroscopic treatment of septate and arcuate uterus. *Gynaecol Endosc* 1996; 5: 151-4
75. Jourdain O, Dabysing F, Harle T, et al. Management of septate uterus by flexible hysteroscopy and Nd : YAG laser. *Int J Gynaecol Obstet* 1998; 63: 159-62
76. Colacurci N, De Placido G, Mollo A, et al. Reproductive outcome after hysteroscopic metroplasty. *Eur J Obstet Gynecol Reprod Biol* 1996; 66: 147-50
77. Edström K, Fernström I. The diagnostic possibilities of a modified hysteroscopic technique. *Acta Obstet Gynecol Scand* 1970; 49: 327-30
78. Chervenak FA, Neuwirth RS. Hysteroscopic resection of the uterine septum. *Am J Obstet Gynecol* 1981; 141: 351-3
79. Valle RF, Sciarra JJ. Hysteroscopic resection of the septate uterus. *Obstet Gynecol* 1986; 67: 253-7
80. Valle RF. Hysteroscopic treatment of partial and complete uterine septum. *Int J Fertil* 1996; 41: 310-15
81. Gallinat A. Endometrial ablation using the Nd-YAG laser in CO₂ hysteroscopy. In Leuken RP, Gallinat A, eds. *Endoscopic Surgery in Gynecology*. Berlin: Demeter Verlag, 1993: 109-16
82. De Cherney AH, Russel LJB, Graebe RA, et al. Resectoscopic management of Müllerian defects. *Fertil Steril* 1986; 45: 726-8
83. Corson SL, Batzer FR. CO₂ uterine distension for hysteroscopic septal incision. *J Reprod Med* 1986; 31: 713-16
84. Hamou J. Electroresection of fibroids. In Sutton C, Diamond M, eds. *Endoscopic Surgery for Gynaecologists*. London: WB Saunders, 1993: 327-30
85. Daniell JF, Osher S, Miller W. Hysteroscopic resection of uterine septa with visible light laser energy. *Colposc Gynecol Laser Surg* 1987; 3: 217
86. Nisolle M, Donnez J. Müllerian fusion defects: septoplasty and hemihysterectomy of the rudimentary horns. In Donnez J, Nisolle M, eds. *An Atlas of Laser Operative Laparoscopy and Hysteroscopy*. Carnforth, UK: Parthenon Publishing, 1994: 295-304
87. Nisolle M, Donnez J. Endoscopic treatment of uterine malformations. *Gynecol Endosc* 1996; 5: 155-60
88. Fedele L, Bianchi S, Marchini M, et al. Residual uterine septum of less than 1 cm after hysteroscopic metroplasty does not impair reproductive outcome. *Hum Reprod* 1996; 11: 727-9
89. Donnez J, Nisolle M. Operative laser hysteroscopy in Müllerian fusion defects and uterine adhesions. In Donnez J, ed. *Laser Operative Laparoscopy and Hysteroscopy*. Leuven: Nauwelaerts Printing, 1989: 249-61
90. Woolf RB, Allen WM. Concomitant malformations. *Obstet Gynecol* 1953; 2: 236-65
91. Fekete CN, Nisolle M. Anomalies de fusion ou d'accolement des canaux de Müller. In *Revue Médico-Chirurgicale de l'Hôpital des Enfants Malades*, Paris, 1988: 1
92. Schiffrin BS, Erez S, Moore JG. Teenage endometriosis. *Am J Obstet Gynecol* 1973; 116: 973-80
93. Goldstein DP, Decholnoky C, Emans SJ, Leventhal JM. Laparoscopy in the diagnosis and management of pelvic pain in adolescents. *J Reprod Med Obstet Gynecol* 1980; 24: 251-6

Hysteroscopic lysis of intrauterine adhesions

J Donnez, P Jadoul, J Squifflet

Intrauterine adhesions have been related to recurrent abortion, sterility and menstrual disorders. Relief from adhesions has been associated with pregnancy rates of 50% and the disappearance of menstrual disorders in more than 75% of cases. In 1948, Asherman described 'amenorrhoea traumatica' as amenorrhoea secondary to intrauterine adhesions, following curettage for incomplete or missed abortion and postpartum hemorrhage¹. This condition is thus termed 'Asherman's syndrome'.

ETIOPATHOGENESIS

Infection (endometritis) rarely causes adhesions, except in the case of tuberculous endometritis. Most frequently (>90%), intrauterine adhesions develop after curettage². The most important factor in the development of intrauterine adhesions is traumatic curettage or manipulation of the endometrium during the postpartum or postabortal period. Denudation of the basalis layer and exposure of the muscularis layer produce adhesions by coaptation of the opposing uterine walls.

DIAGNOSIS AND CLASSIFICATION

Dilatation and curettage (D&C) is of no diagnostic value for intrauterine adhesions. In amenorrhoeic women with a biphasic basal body temperature curve, failure of the progesterone challenge test to cause withdrawal bleeding may suggest the diagnosis, if the patient has a medical history of postpartum or postabortal curettage. Hysterosalpingography is the most accurate screening method in the diagnosis of intrauterine adhesions³. Adhesions are suggested by radiographic filling defects. Hysteroscopy confirms the presence of intrauterine adhesions and allows definitive surgical treatment. Although adhesions can be diagnosed by hysterosalpingography or hysteroscopy, both are necessary to confirm their presence and their location. There are many classifications of adhesions based on histology, hystero-graphy, symptomatology and hysteroscopy. To be able to compare the results of treatment and to determine the therapeutic regimen, intrauterine adhesions should be classified on the basis of hysteroscopic and hysterosalpingographic findings according to the European Society of Hysteroscopy (ESH)⁴.

We use our own classification (Table 44.1)³, based essentially on the location of the intrauterine adhesions. We consider location to be one of the most important

prognostic factors in determining the postoperative pregnancy rate. Degree I adhesions are central (Figures 44.1 and 44.2) and are classified as thin or filmy adhesions and myofibrous adhesions. Degree II adhesions are marginal (Figures 44.3 and 44.4). Degree III adhesions are revealed by the absence of the uterine cavity upon hystero-graphy (Figure 44.5). Valle and Sciarra⁵ classified intrauterine adhesions as mild, moderate and severe, based on the degree of intrauterine involvement on hysterosalpingography and the extent and type of adhesions found on hysteroscopy. Mild adhesions are defined as filmy adhesions composed of basalis endometrial tissue, producing partial or complete uterine cavity occlusion; moderate adhesions are fibromuscular, characteristically thick and still covered with endometrium; severe adhesions are composed of connective tissue only⁶. The American Fertility Society⁷ has proposed a classification of intrauterine adhesions based on findings upon hysterosalpingography and hysteroscopy and correlation with menstrual patterns.

Table 44.1 Classification according to the location and the aspect of the adhesions³

<i>Degree</i>	<i>Location</i>
I	Central adhesions (bridge-like adhesions) (a) thin or filmy adhesions (endometrial adhesions) (b) myofibrous or connective adhesions
II	Marginal adhesions (always myofibrous or connective) (a) ledge-like projections (b) obliteration of one horn
III	Uterine cavity 'absent' on hysterosalpingography (a) occlusion of the internal os (upper cavity normal) (pseudo-Asherman's syndrome) (b) extensive coaptation of the uterine walls (absence of uterine cavity) (true Asherman's syndrome)

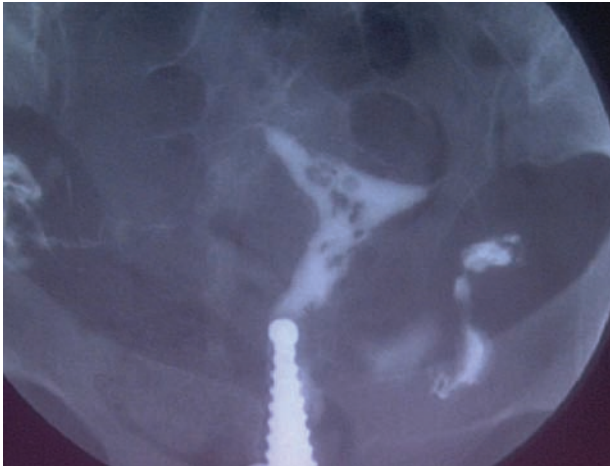


Figure 44.1 Intrauterine adhesions: degree Ia central adhesions (bridge-like adhesions)

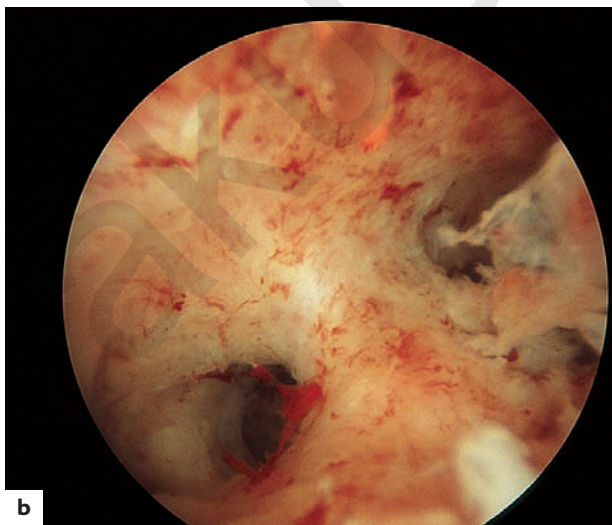
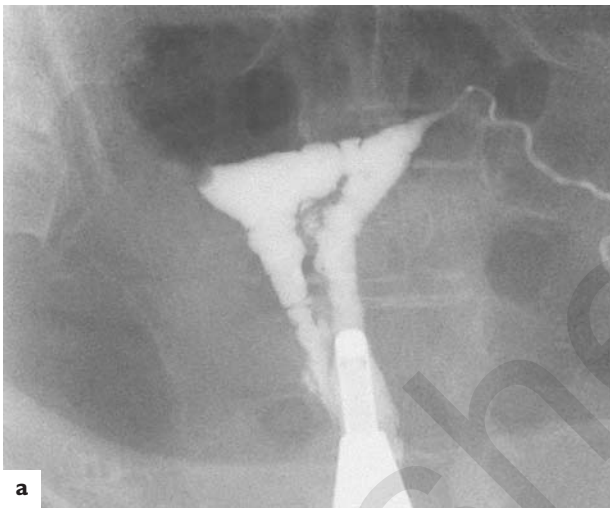

Figure 44.2 (a) and (b) Intrauterine adhesions: degree Ib myofibrous central adhesions

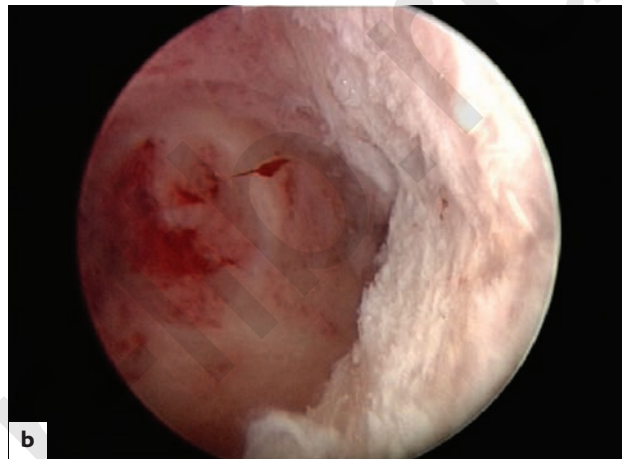
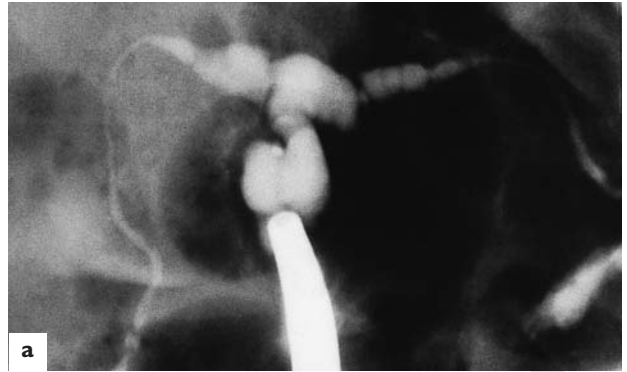


Figure 44.3 (a) and (b) Intrauterine adhesions: degree IIa marginal adhesions (always myofibrous or connective adhesions)

TREATMENT AND RESULTS

Hysterotomies for the division of adhesions and other blind transcervical manipulations are only of historical interest. Blind division of intrauterine adhesions by dilatation does not provide accurate and precise treatment. Thin or filmy endometrial adhesions are often easily removed by pushing with the tip of the hysteroscopic sheath. Myofibrous or connective adhesions require synechiotomy. The surgical treatment of intrauterine adhesions thus consists of dividing the adhesions mechanically, or using electro-surgery and/or fiberoptic lasers. The gynecological resectoscope with a modified knife electrode has been used to divide adhesions electro-surgically. Fiberoptic lasers, such as the argon, krypton (KTP)/532, and neodymium : yttrium–aluminum–garnet (Nd : YAG) laser with sculpted or extruded fibers, have also been used.

In our series, the Nd : YAG laser was used to remove endometrial adhesions, even when they were multiple and fibrous. Degree Ia and b adhesions were easily cut by the

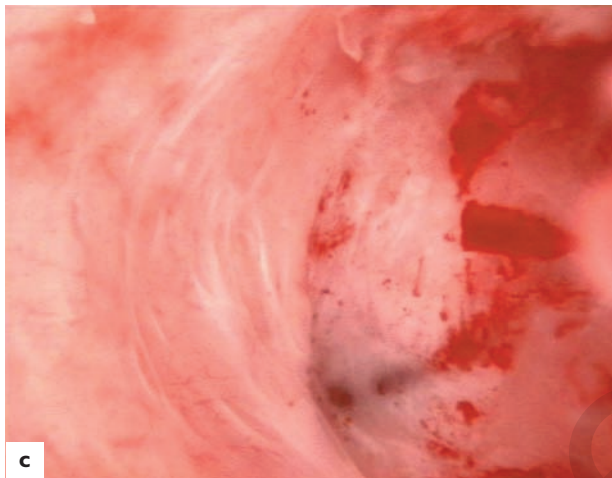
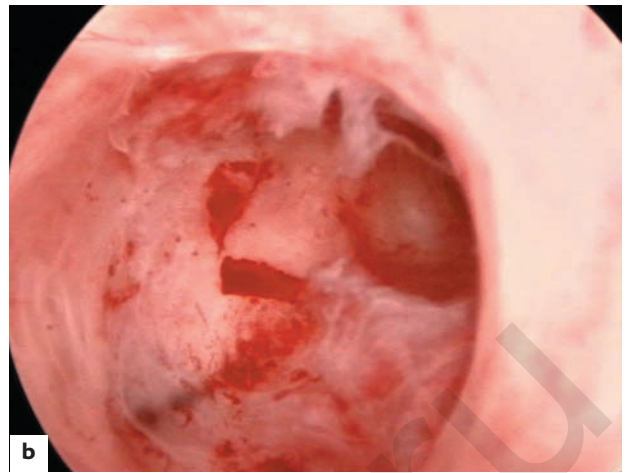
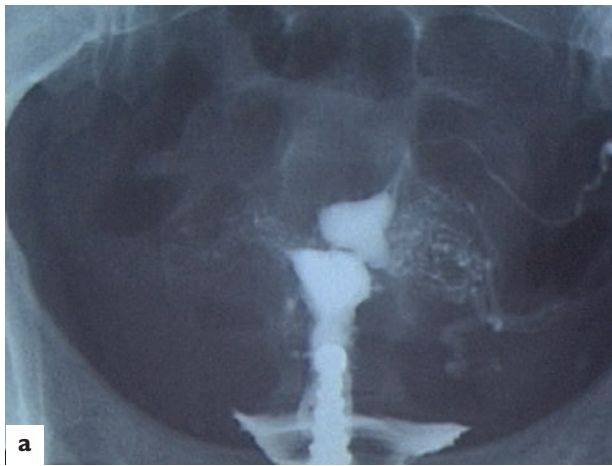


Figure 44.4 (a)–(c) Intrauterine adhesions: degree IIb right marginal adhesions, obliterating the horn

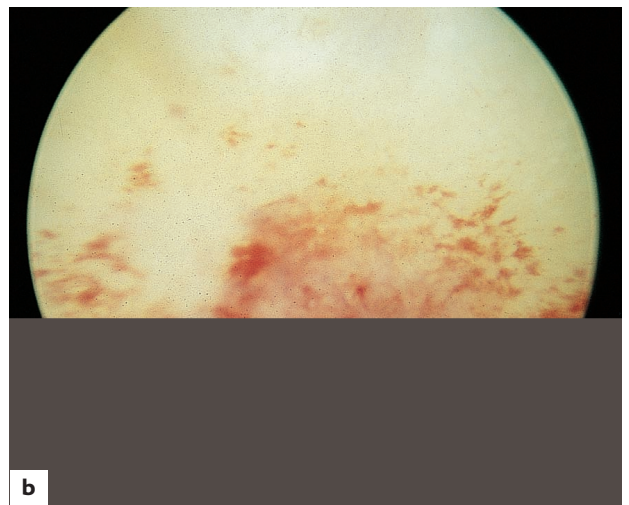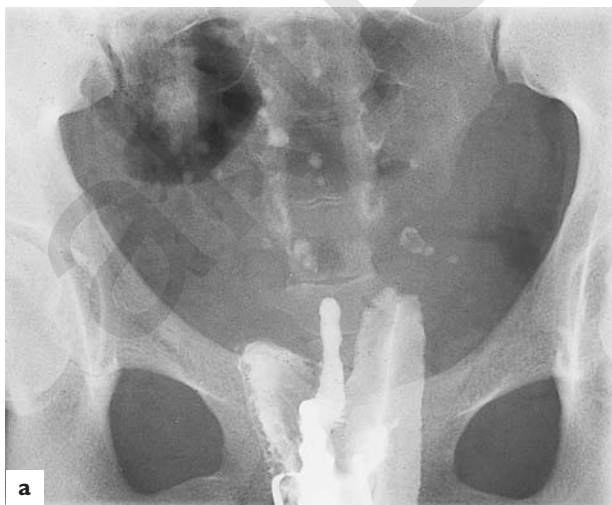


Figure 44.5 (a) and (b) Intrauterine adhesions: degree III. The cervical canal is visible. The uterine cavity is 'absent'. Only preoperative evaluation permits differentiation of pseudo-Asherman's syndrome

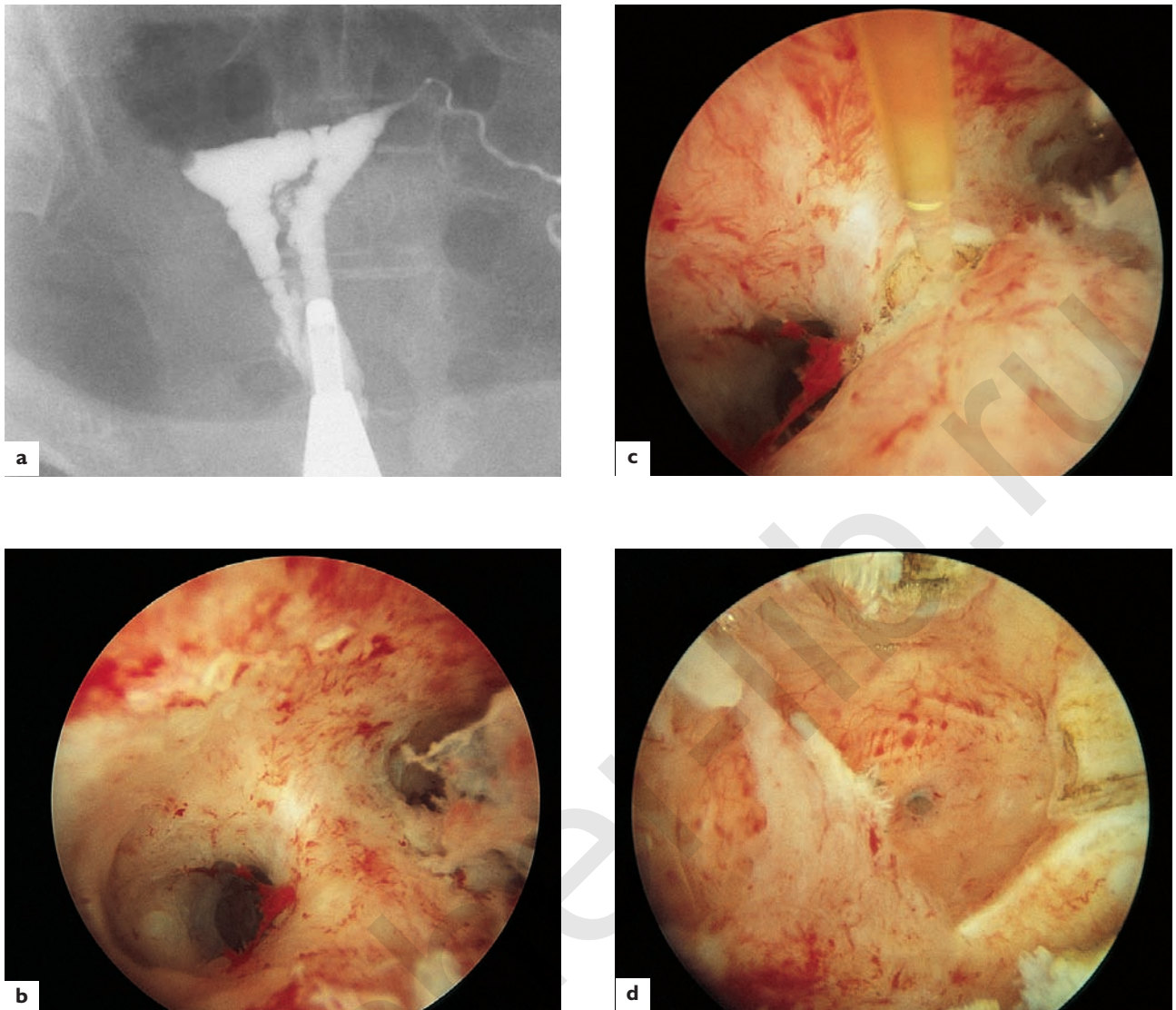


Figure 44.6 Intrauterine adhesions: degree Ib. (a) Hysterosalpingography determines the location. (b) Hysteroscopy determines the type (connective tissue). (c) The adhesion is divided with the laser (Nd:YAG) fiber. (d) Final view: the fundus of the uterine cavity (with tubal ostium)

laser fiber (Figure 44.6). Combined laparoscopy and hysteroscopy can be used, if indicated, to decrease the risk of uterine perforation. The lateral, back and front scattering of KTP and Nd:YAG laser beams may decrease the viability of the surrounding healthy endometrium. When the adhesions partially occlude the uterine cavity (degree Ib), their division is simple: they are divided in the middle, the remaining stumps retract and the uterine cavity distends, providing a panoramic view (Figure 44.6). Marginal or lateral adhesions (degree IIa and b) may be difficult to divide, particularly if they are extensive and fibromuscular or composed of connective tissue (Figures 44.7 and 44.8). The Nd:YAG laser may not be a good tool for the treatment of this type of adhesion. More severe adhesions may even develop, due to the scattering of the laser beam, decreasing the viability of the surrounding

healthy myometrium. For uterine adhesions of degree III (Figure 44.9), hysteroscopic observation of the uterine cavity should begin at the internal cervical os; if the adhesions extend to that area, their selective division begins there. As the adhesions are divided and the uterine cavity opens, the hysteroscope is advanced to the fundal area, and both uterotubal ostia are visualized. Sometimes, increased pressure in the uterine cavity, obtained by increasing the inflow pressure, can facilitate the dissection by distending the uterine cavity. However, although the plane of dissection is better exposed, this procedure can lead to excessive fluid intravasation if prolonged.

Low-viscosity fluids are frequently chosen for operative hysteroscopy because of their ability to remove debris and cleanse the uterine cavity, even in the presence of slight uterine bleeding. Normal saline and Ringer's

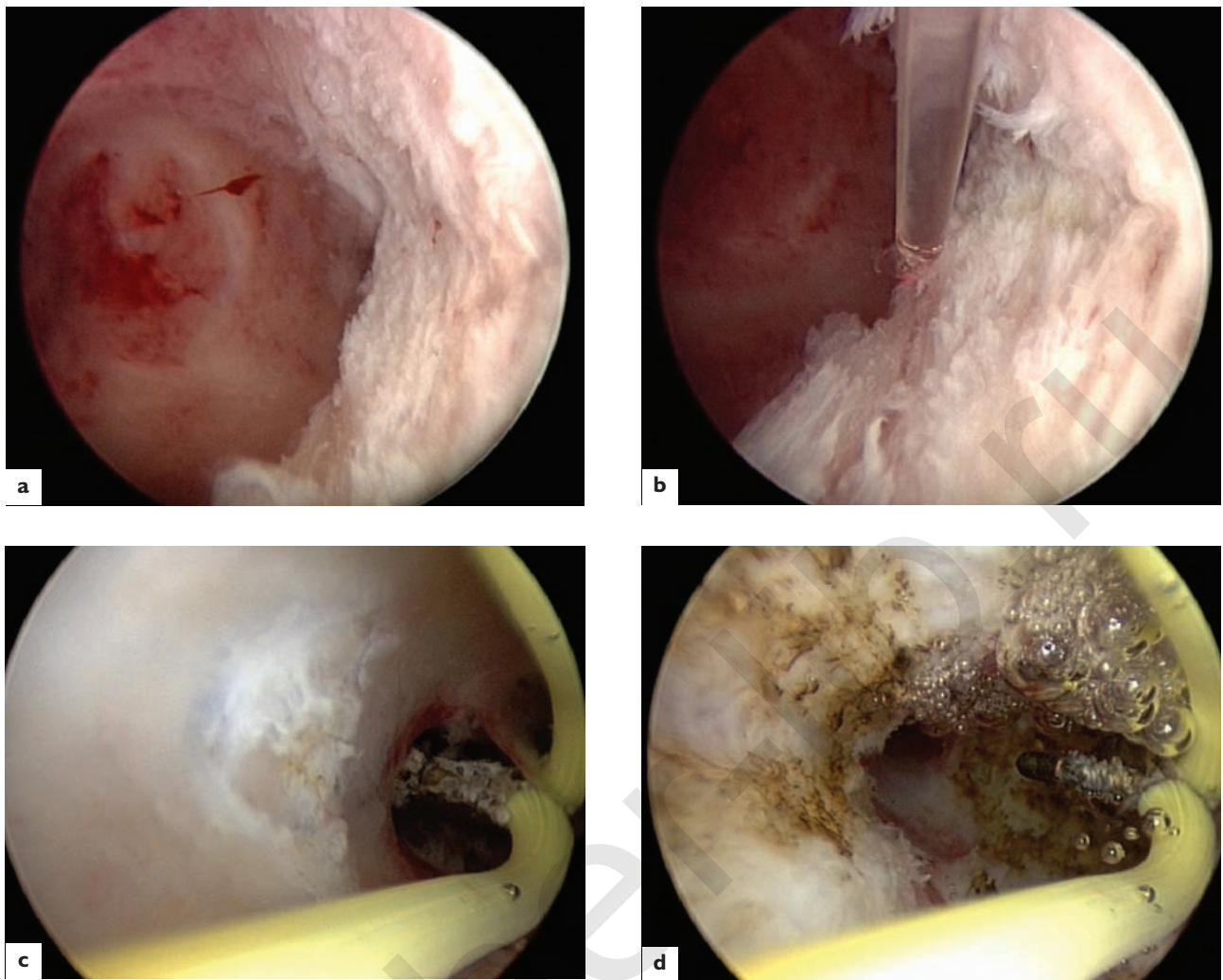


Figure 44.7 Intrauterine adhesions: degree IIa. (a) Left marginal adhesions. (b) Resection of adhesions with the Nd:YAG laser. (c) and (d) Resection of adhesions with an L-shaped electrode

lactate are excellent media for distending the uterine cavity when treating intrauterine adhesions with hysteroscopic scissors or with the Nd:YAG laser. Care must be taken to avoid solutions containing electrolytes when applying electrocoagulation, to control the volume of fluids not accounted for, and to prevent excessive fluid intravasation, particularly in the case of fluids without electrolytes. Intrauterine adhesions of the moderate and severe type require extensive dissection, increasing the risk of excessive intravasation. Prophylactic antibiotics are given 1 h prior to hysteroscopic treatment and for 2–3 days postoperatively, when an intrauterine device (IUD) is left in the uterine cavity. We have not found a second hysteroscopy to be of any particular value. A second therapeutic hysteroscopy is performed only if hysterosalpingography demonstrates residual adhesions. The subsequent insertion of an IUD and hormonal treatment have been associated with increasing success rates. In our department, estrogen and progestogen

replacement therapy is initiated after surgery for 3 months (ethinylestradiol 100 µg/day and lynestrenol 10 mg/day for 6 weeks). The doses are doubled for the following 6 weeks.

SUCCESS RATE

In collective series (Table 44.2), success rates of 74–94% have been obtained⁷. It is very difficult to compare different series because the results have not been evaluated according to the degree of severity. In a review⁷, the pregnancy rate was found to be 60.5%, and 80% of those pregnancies reached term. In our series of 74 patients treated for intrauterine synechiae, eight patients were amenorrheic with an absent uterine cavity at hystero-graphy. Four were classified as degree IIIa, and four as degree IIIb. Surgery was successfully performed in group IIIa, with a pregnancy rate of 100%. In group IIIb, however, adhesions recurred; second-look hysteroscopy showed only

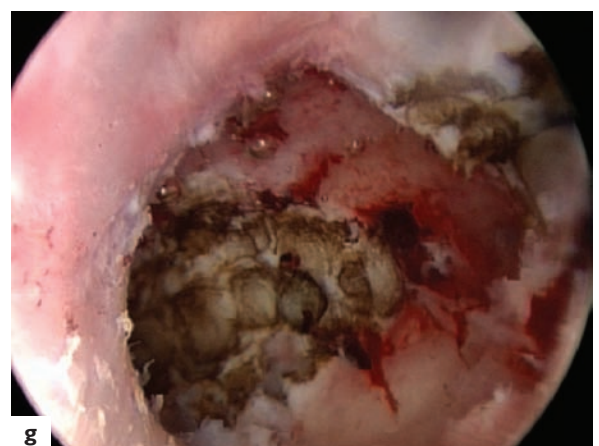
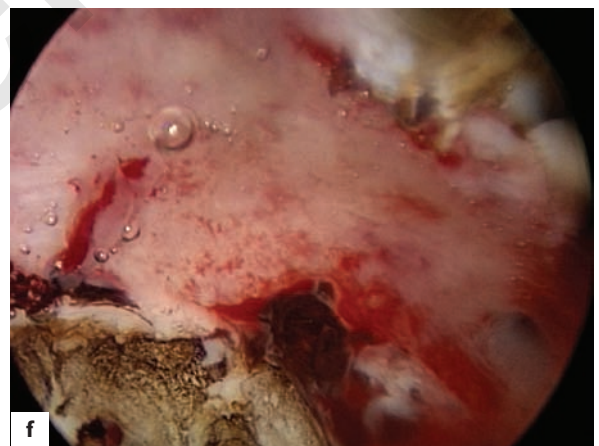
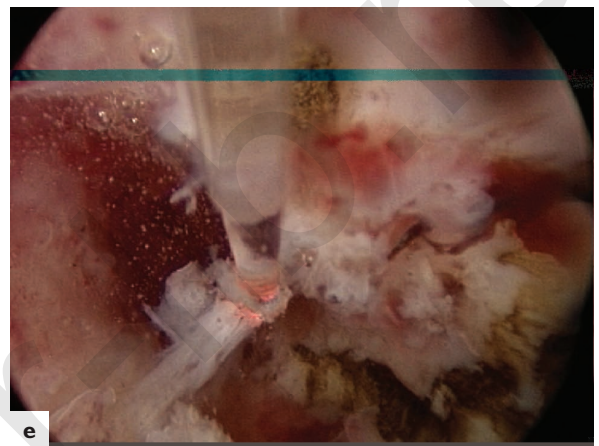
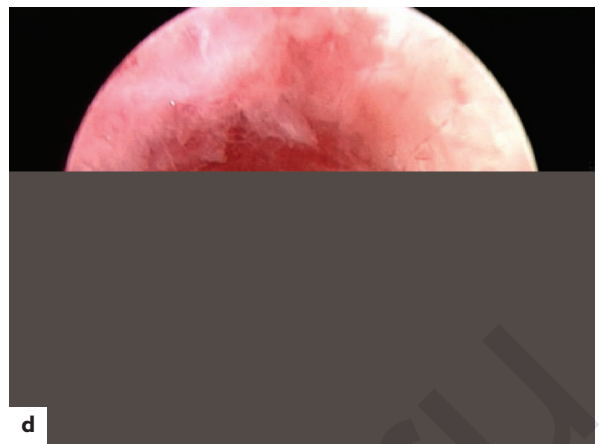
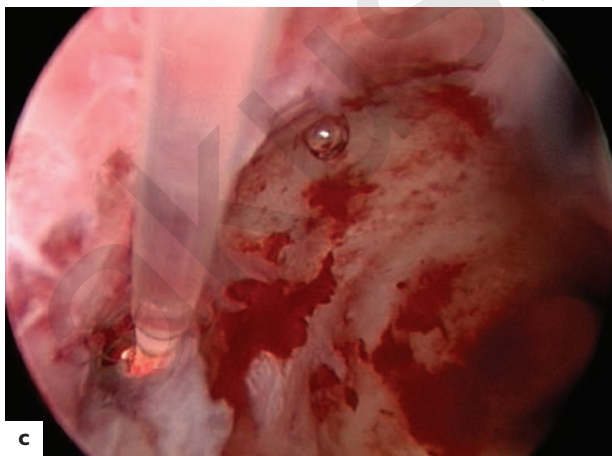
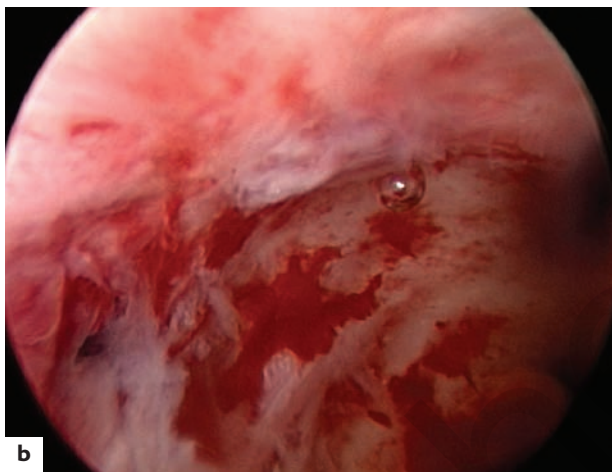
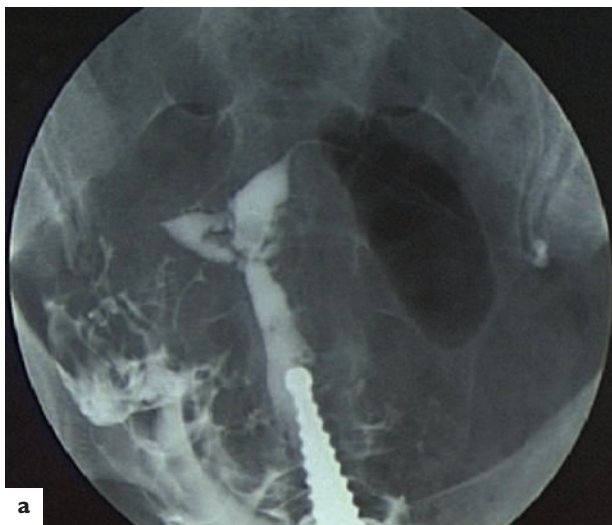

Figure 44.8 Intrauterine adhesions: degree IIb. (a) Hysterothorax. (b) The right tubal ostium is not seen. (c) Nd:YAG laser is used to section the adhesions. (d) The right horn becomes visible. (e) The right tubal ostium is visualized. (f) The left tubal ostium is visualized. (g) Final view

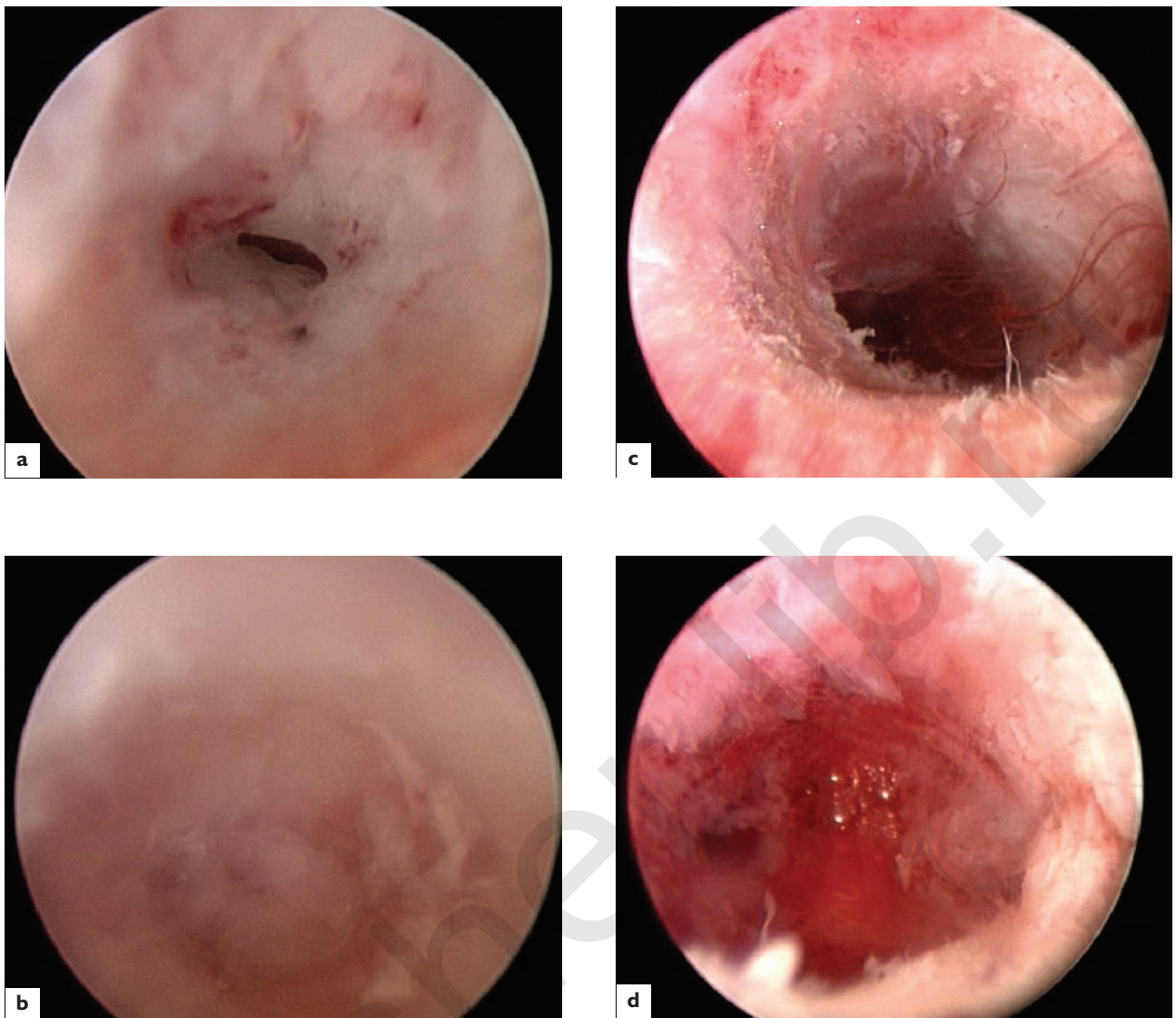


Figure 44.9 Intrauterine adhesions: degree III; pseudo-Asherman's syndrome. (a) Visualization of the internal cervical os. (b) The hysteroscope is advanced to the fundal area. (c) The adhesion is forced and the uterine cavity becomes visible. (d) Visualization of the right tubal ostium and normal endometrium

Table 44.2 Hysteroscopic lysis of intrauterine adhesions

Reference	of patients	Number Technique	Normal menses		Pregnancy		Term pregnancy	
			n	%	n	%	n	%
8	27	Scissors alongside hysteroscope	20	74	14	51.8	13	48.1
4	36	Scissors/biopsy forceps	34	94.4	17	62.9	12	44.4
5	187	Flexible/semirigid/rigid scissors	167	89.3	143	76.4	114	79.7

a tunnel-shaped uterine cavity with an absence of healthy endometrium. Hysterosalpingography, carried out 3 months after surgery, confirmed the presence of adhesions; some were more severe than the initial adhesions.

CONCLUSION

Hysteroscopic treatment of intrauterine adhesions restored normal menstruation in more than 80% of treated patients⁷. The results in terms of normal menses and pregnancy rates are excellent for those with adhesions of degrees Ia, Ib, IIa and IIIa. Degree IIb and IIIb adhesions tended to recur and to be more severe in six out of ten women, and no pregnancy occurred in this group. Patients treated for moderate or severe adhesions should be considered at risk during delivery. Following delivery, care must be taken to make an early diagnosis of any abnormalities, such as placenta accreta or percreta⁵.

REFERENCES

1. Asherman JG. Amenorrhoea traumatica (atretica). *J Obstet Gynaecol Br Emp* 1948; 55: 23–30
2. Schenker JG, Margalioth EJ. Intrauterine adhesions; an updated appraisal. *Fertil Steril* 1982; 37: 593
3. Donnez J, Nisolle M. Operative laser hysteroscopy in Müllerian fusion defects and uterine adhesions. In Donnez J, ed. *Operative Laser Laparoscopy and Hysteroscopy*. Leuven, Belgium: Nauwelaerts Printing, 1989: 249–61
4. Wamsteker K. Hysteroscopy in the management of abnormal uterine bleeding in 199 patients. In Siegler AM, Lindemann HI, eds. *Hysteroscopy, Principles and Practice*. Philadelphia: JB Lippincott, 1984: 128–31
5. Valle RF, Sciarra JJ. Intrauterine adhesions: hysteroscopic diagnosis, classification, treatment, and reproductive outcome. *Am J Obstet Gynecol* 1988; 158: 1459–70
6. Valle R. Lysis of intrauterine adhesions (Asherman's syndrome). In Sutton C, Diamond M, eds. *Endoscopic Surgery for Gynecologists*. London: WB Saunders, 1993: 338
7. American Fertility Society. The American Fertility Society classifications of adnexal adhesions, distal tubal occlusion, tubal occlusion secondary to tubal ligation, tubal pregnancies, Müllerian anomalies and intrauterine adhesion. *Fertil Steril* 1988; 49: 944–55
8. Neuwirth RS, Hussein AR, Schiffman BM, et al. Hysteroscopic resection of intrauterine scars using a new technique. *Obstet Gynecol* 1982; 60: 111–13

Hysteroscopic myomectomy

J Donnez, P Jadoul, M Smets, J Squifflet

Laser energy has some advantages in precision of tissue destruction that are not shared by the electrical energy used in the resectoscope^{1,2}. Since the most popular laser in gynecology has been the carbon dioxide (CO₂) laser, efforts have been made to adapt this for hysteroscopic use. However, several features of the CO₂ laser make it impractical for hysteroscopic use. The neodymium:yttrium–aluminum–garnet (Nd:YAG) laser, however, has three specific features, making it readily adaptable for hysteroscopic myomectomy:

- Its ability to transmit the beam of energy easily into the uterine cavity by means of a flexible quartz fiber
- Its ability to transmit laser energy to the tissue surface through a liquid distending medium
- Its ability to penetrate tissue to a controlled depth

The depth at which tissue destruction will occur can be controlled by varying the power used^{3,4}; this physical quality can be applied for myomectomy and hysteroscopic myolysis^{5,6}. This chapter describes the different techniques of hysteroscopic myomectomy.

HYSTEROSCOPIC EQUIPMENT

The fiber used to carry the laser light consists of quartz, surrounded by a thin plastic jacket, beyond which the tip of the fiber extends for several millimeters. The fiber is gas-sterilized or wiped with alcohol or Cidex® prior to use.

The deflecting arm is not of particular value, but allows the fiber to be stabilized. The hysteroscope is inserted into two different sheaths of varying diameter: one for inflow and the other for outflow. This resembles the classic resectoscope⁷ and permits the constant cleaning of the uterine cavity. A Sharplan 2100 apparatus (Sharplan, Tel Aviv, Israel) is used for generating the laser. A power output of 80 W is used.

THE ROLE OF PREOPERATIVE GONADOTROPIN-RELEASING HORMONE AGONIST THERAPY

In one of our studies, we treated 376 women aged between 23 and 43 years (mean 33 years), with symptomatic submucous uterine fibroids, with a biodegradable gonadotropin-releasing hormone (GnRH) agonist (Zoladex® implant; ICI, Cambridge, UK). The implant was injected subcutaneously at the end of the luteal phase to

curtail the initial gonadotropin stimulation phase always associated with a rise in estrogen. One implant was systematically injected at weeks 0, 4 and 8. Hysteroscopic myomectomy was carried out at 8 weeks. After the initial stimulation of estrogen secretion, GnRH agonist administration produced estrogen levels in the postmenopausal range (15 ± 6 pg/ml). Luteinizing hormone and follicle stimulating hormone levels were significantly suppressed within 2 weeks of treatment. The recovery of ovarian secretion occurred an average of 4–5 weeks after the last injection⁶ (Figure 45.1).

Using the method previously described^{5,6}, the reduction in area of large submucous fibroids was calculated. When more than one fibroid was present, only the largest was evaluated. In all but four patients, the fibroid area decreased by an average of 38%⁸ (range 4–95%). The fibroid area was found to decrease significantly ($p < 0.01$) from the baseline area (7.2 ± 4.7 cm²), to 4.4 ± 3.5 cm² after 8 weeks of therapy. Figure 45.2 shows the mean fibroid area in patients with a pretreatment fibroid area of < 5 cm² versus those with an area of > 5 cm² to < 10 cm² and those with an area of > 10 cm². In all subgroups, a significant decrease ($p < 0.005$) was noted.

There was no significant difference between the different subgroups, but there was a significant difference between individual myomas (Figure 45.3). About 10% of myomas did not appear to respond very well to GnRH agonist treatment.

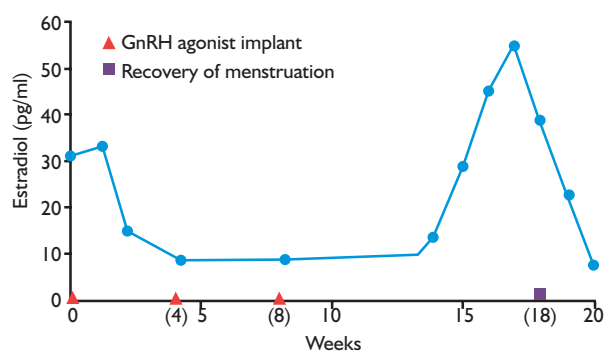


Figure 45.1 Hormonal levels (17 β -estradiol) during gonadotropin-releasing hormone (GnRH) agonist therapy. An implant of Zoladex® was injected at weeks 0, 4 and 8

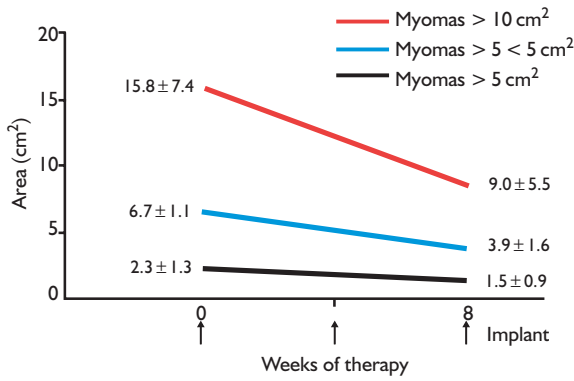


Figure 45.2 Decrease in fibroid area after 8 weeks of gonadotropin-releasing hormone agonist therapy relative to the initial value

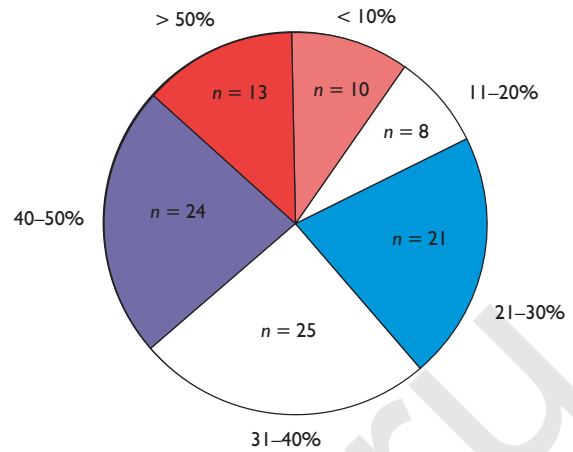


Figure 45.3 Distribution of the myomas according to their size decrease. Ten per cent of patients were non-responders

CLASSIFICATION OF MYOMAS

According to hysterosalpingography data, submucosal fibroids were classified as:

- Submucosal fibroids with the greater portion inside the uterine cavity (Figure 45.4)
- Submucosal fibroids with the larger portion located in the myometrium (Figure 45.5)
- Multiple (>2) submucosal fibroids (myofibromatous uterus with submucosal fibroids and intramural fibroids) diagnosed by hystero-graphy (Figure 45.6) and echography

TECHNIQUES

Submucosal fibroids with the greater portion inside the uterine cavity

All patients (n=233) underwent myomectomy by hysteroscopy and Nd:YAG laser. In all but three patients, the operation was easily performed. The myometrium overlying the myoma was less vascular, and ‘shrinkage’ of the uterine cavity may have accounted for the relative ease with which the myomas could be separated from the surrounding myometrium (Figures 45.7–45.9).

No complications such as infection, bleeding or uterine contractions occurred. No hormonal therapy was given after the procedure. The operating time ranged from 10 to 50 min (mean 24 ± 6 min).

Large submucosal fibroids with the greater portion located in the uterine wall

For large submucous fibroids with the greater portion not inside the uterine cavity but inside the uterine wall

(n = 78), a two-step operative hysteroscopy was proposed⁶. After 8 weeks of preoperative GnRH agonist therapy, partial myomectomy was carried out by resecting the protruding portion of the myoma (Figure 45.10). The laser fiber was then directed, as perpendicularly as possible, at the remaining (intramural) fibroid portion, and was introduced into the fibroid to a depth of 5–10 mm (Figure 45.11).

During the application of laser energy, the fiber was slowly removed so that the deeper areas were coagulated. The end-point of fibroid coagulation with this technique was identifiable by the observation of distinct craters with brown borders on all fibroid areas. The depth of the intramural fibroid portion was already known from the results of echographic examination performed the day before surgery. The aim of this procedure was to decrease the size of the remaining myoma by decreasing its vascularity. This technique induces a necrobiosis (Figure 45.12) and can be called ‘transhysteroscopic myolysis’^{6,19}.

GnRH agonist therapy was administered for another 8 weeks. At second-look hysteroscopy, the myoma was found to protrude inside the uterine cavity, and appeared very white and without any apparent vessels on its surface (Figure 45.13). The shrinkage of the uterine cavity allowed the residual myoma portion to be easily separated from the surrounding myometrium and dissected off (Figure 45.14).

Myomectomy was then carried out. In all but five patients, two-step therapy allowed a successful myomectomy.

In the five remaining cases, ‘third-look’ hysteroscopy was necessary to achieve myomectomy. The myoma revealed areas of histological necrosis (Figure 45.12). In some cases, the residual myoma appeared white and necrotic (Figure 45.15). When performed, hystero-graphy (Figure 45.16) revealed a normal appearance of the uterine cavity, less than 3 months after the procedure.

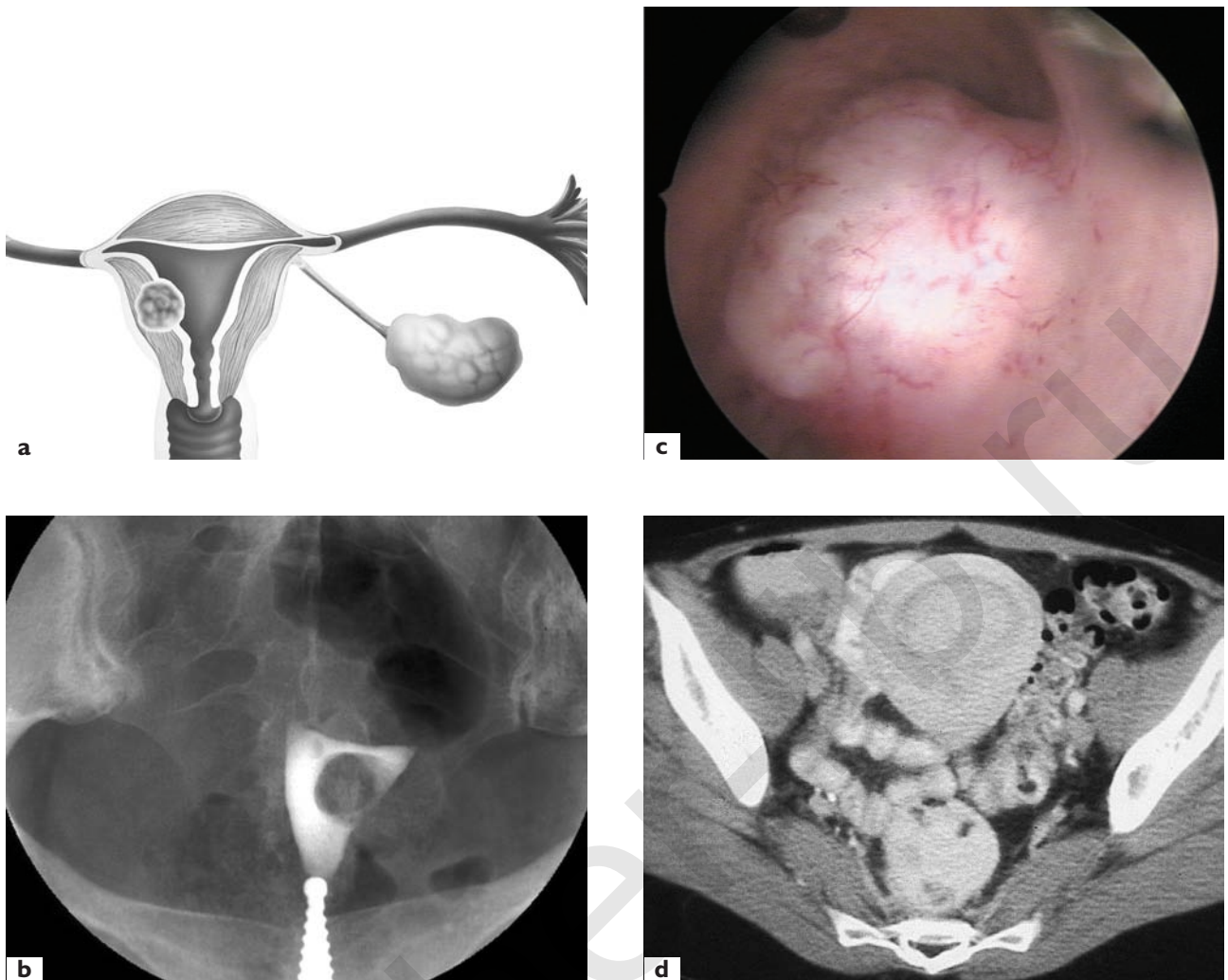


Figure 45.4 (a)–(d) Submucosal fibroids the greatest diameter of which was inside the uterine cavity: (b) hysterothorography; (c) hysteroscopy; (d) computed tomography

Fibromatous uterus

In cases of multiple submucosal fibroids, each myoma was either separated from the surrounding myometrium or totally photocoagulated. When only a small portion of the myoma was visible, the laser fiber was introduced into the intramural portion to a depth depending on the myoma diameter (diagnosed by echography). While firing, the fiber was slowly removed. Each myoma was systematically destroyed.

RESULTS

Table 45.1 shows the long-term results according to myoma classification. Surgery was successful in 230 of 233 patients with large submucous fibroids with the greater

portion inside the uterine cavity. In three cases, a stromal tumor was diagnosed. In one of these (Figure 45.17), dissection of the myoma from the myometrium was impossible because the plane of dissection could not be found. Frozen histology of a biopsy revealed histological characteristics of a stromal tumor (Figure 45.18). Vaginal hysterectomy was then carried out. The other two cases were diagnosed by histological examination of the removed myomas, which appeared hysteroscopically as benign. The incidence of stromal tumors in apparently benign myomas is thus 1.2% (3/233). All three tumors were observed in patients who did not respond very well (<10% decrease) to GnRH agonist therapy. Successful myomectomy permits the restoration of normal menstrual flow. Long-term results show that a recurrence of menorrhagia occurs more frequently (22%) in patients with multiple submucosal myomas than in those with single

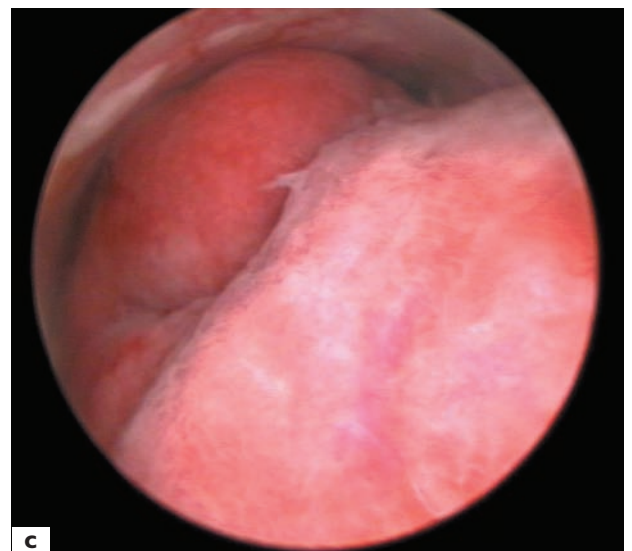
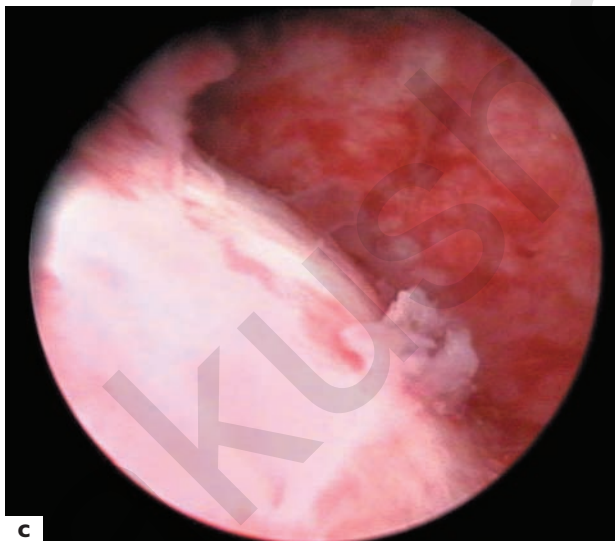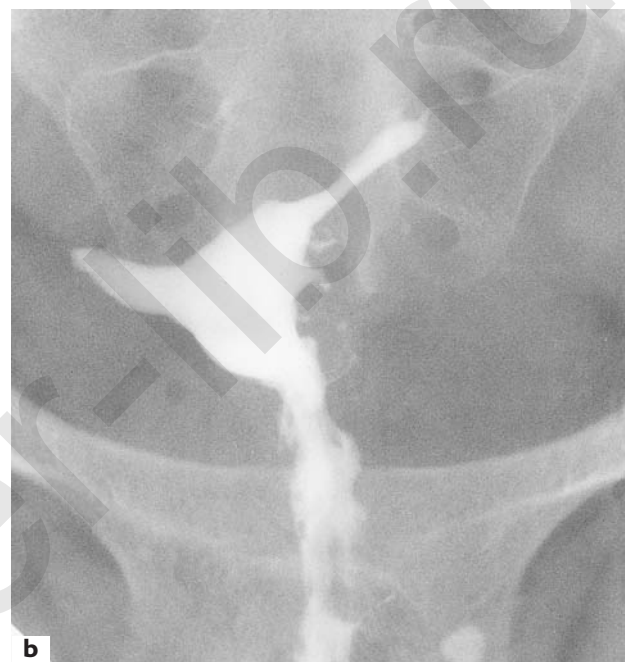
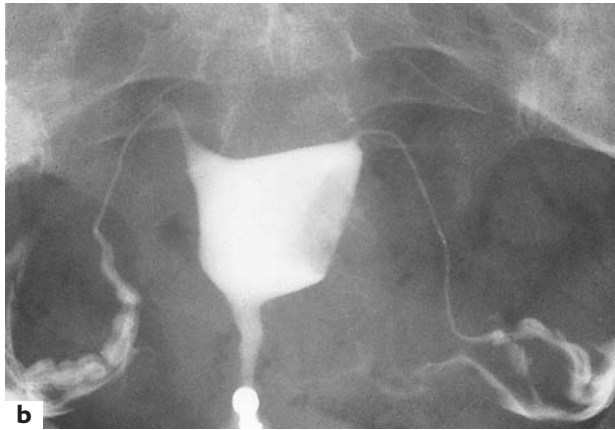
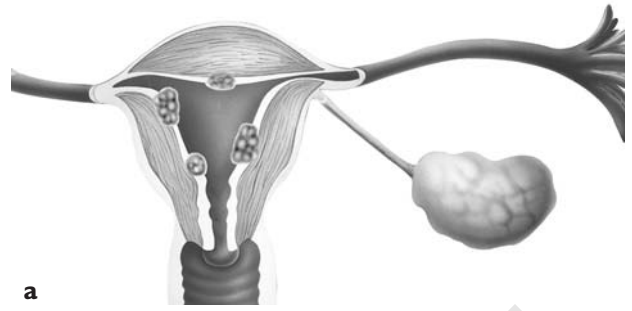
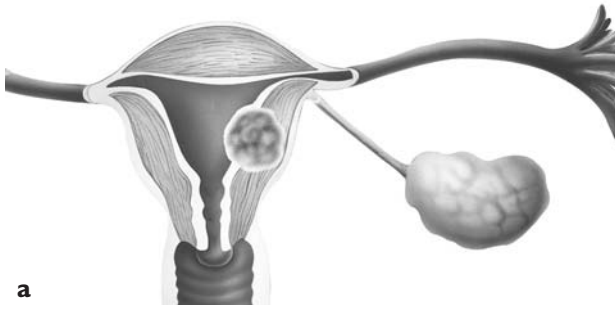
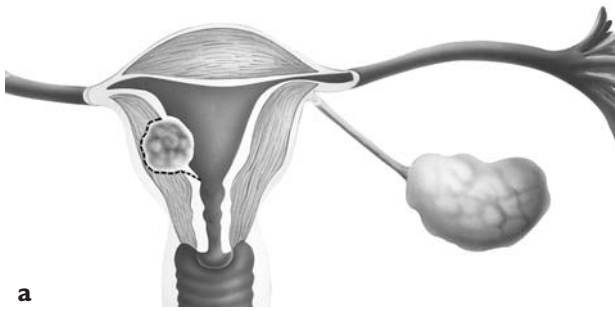
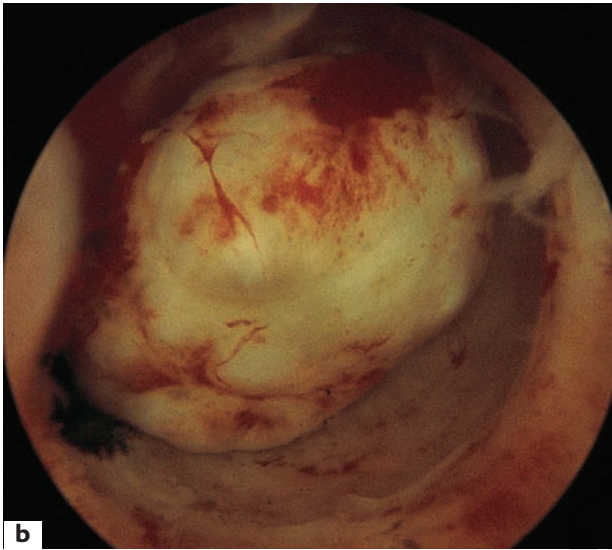


Figure 45.5 (a)–(c) Submucosal fibroids the greater portion of which were located in the myometrium: (b) hystero-contrast sonography; (c) hysteroscopy

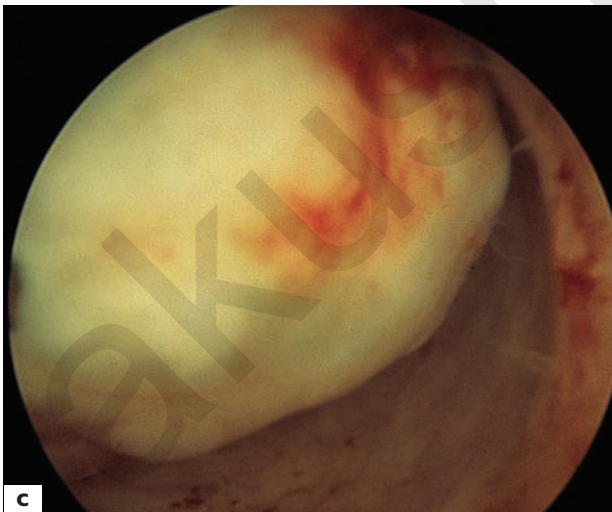
Figure 45.6 (a)–(c) Multiple submucosal myomas: (b) hystero-contrast sonography; (c) hysteroscopy



a

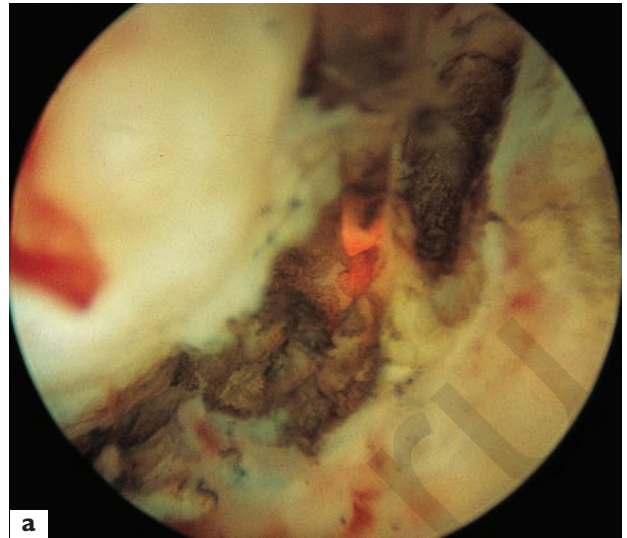


b

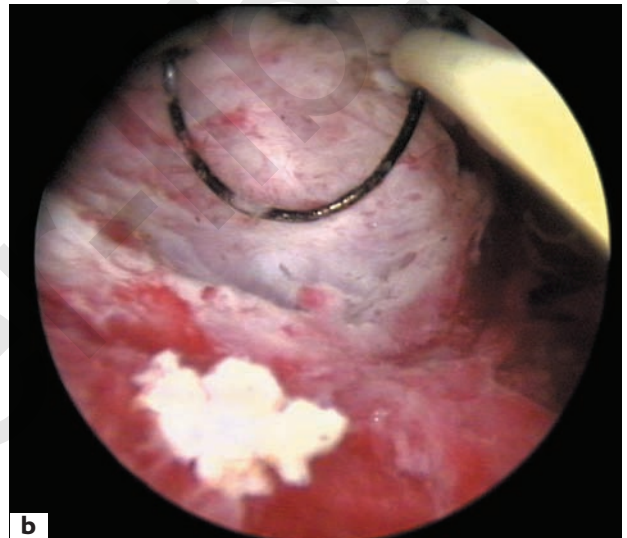


c

Figure 45.7 Hysteroscopy myomectomy in cases of submucosal fibroids with the greater portion inside the uterine cavity: (a)–(c) illustration of the technique



a



b

Figure 45.8 (a) Dissection of a myoma from the surrounding myometrium using the Nd:YAG laser or (b) the resectoscope

submucosal myomas⁸. Recurrence of menorrhagia is provoked by the growth of myomas in other sites, as shown by hystero-graphy and hysteroscopy.

Fertility

A first evaluation of a series of 60 women was published in 1990⁶. Twenty-four of 60 treated women wished to become pregnant and had no other infertility factors. Sixteen (66%) of them became pregnant during the first 8 months after the return of menstruation. No miscarriages or premature labor occurred in these women; one cesarean section was necessary because of fetal distress.

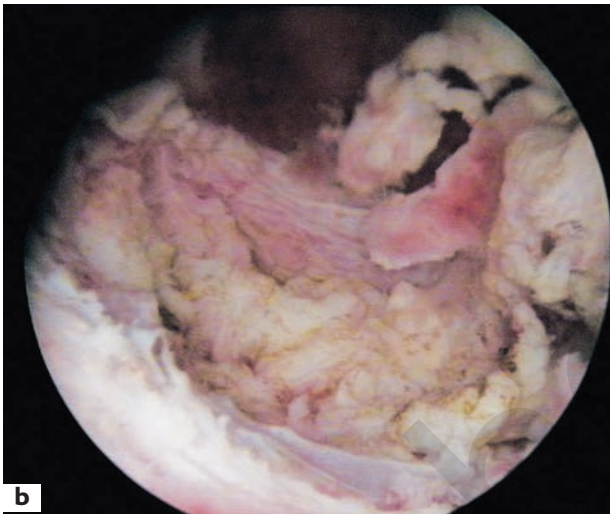
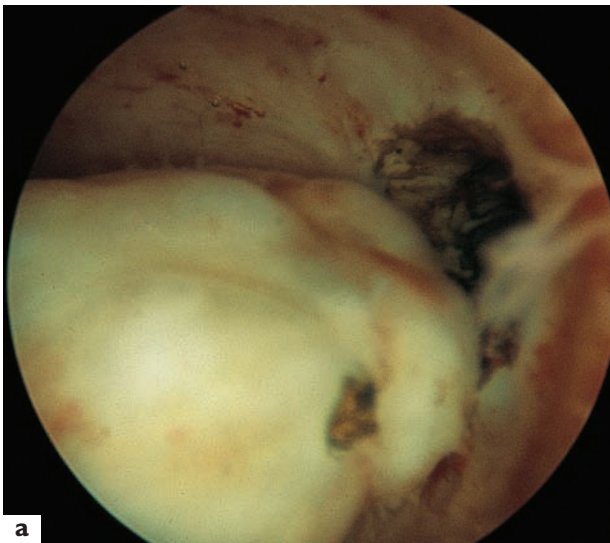


Figure 45.9 (a) and (b) Final view of dissection of the myoma

DISCUSSION

Because most leiomyomas return to pretreatment size within 4 months of the cessation of GnRH agonist therapy, these agents cannot be used as definitive medical therapy¹⁰⁻¹³. Several reports have demonstrated reductions in uterine and fibroid volumes of 52–77% after 6 months of GnRH agonist therapy, as assessed by ultrasound imaging. In our study, hystero-graphic imaging documented an average decrease of 35% in uterine cavity size^{5,14}. Another study⁶ demonstrated reductions in fibroid volume of 38% after 8 weeks of GnRH agonist therapy. The response was variable, however, ranging from 20 to 95%. There was no difference in the extent of the decrease according to pretreatment fibroid area.

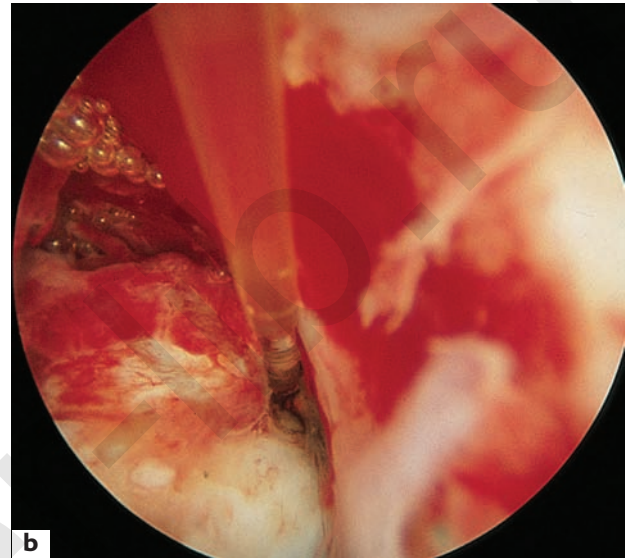
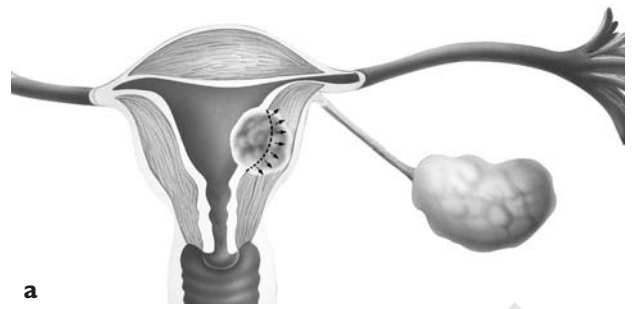

Figure 45.10 Submucosal fibroid with the greater portion located in the myometrium. Resection of the protruding portion of the myoma: (a) illustration; (b) hysteroscopic view

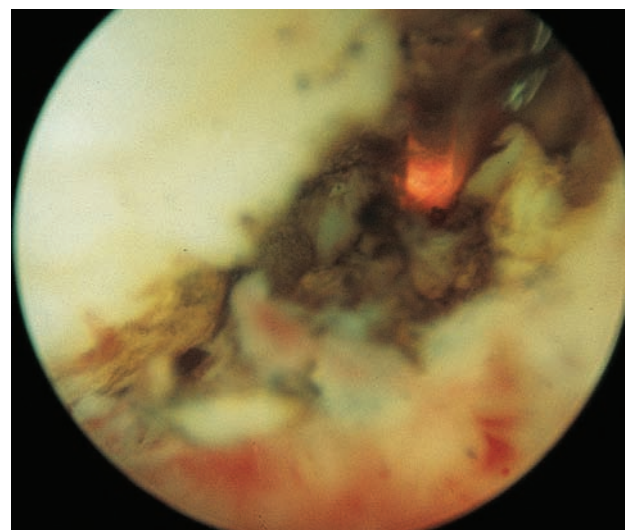


Figure 45.11 The laser fiber is introduced into the remaining fibroid portion to a depth of 5–10mm and slowly removed during the application of laser energy

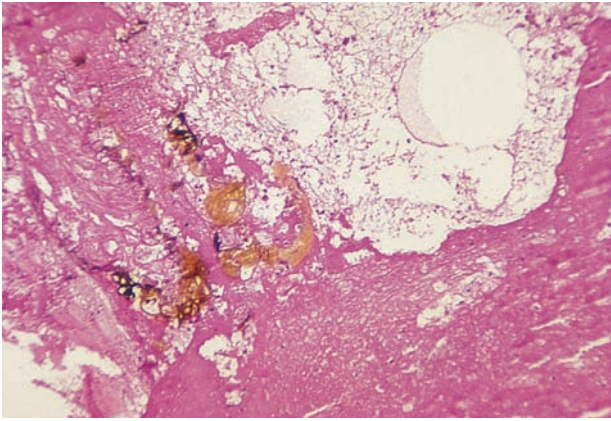


Figure 45.12 Myoma necrobiosis induced by the Nd:YAG laser (Gomori's trichrome, $\times 25$). Carbonized particles phagocytosed by macrophages are clearly seen. In front of them, an area of 'necrobiosis' is visible

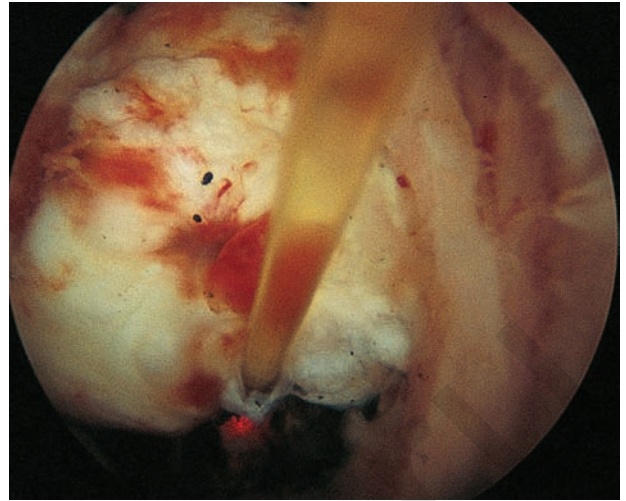


Figure 45.13 Eight weeks after transhysteroscopic myolysis, the intramural portion of the myoma protrudes inside the uterine cavity

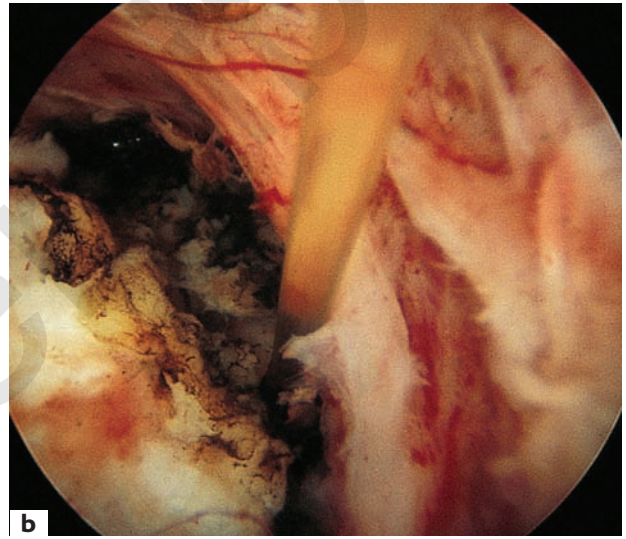
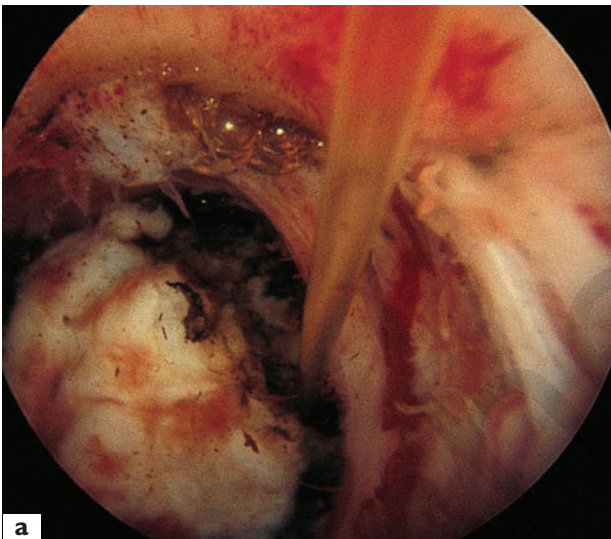


Figure 45.14 (a) and (b) Second-step hysteroscopic procedure. The residual myoma portion is easily separated from the surrounding myometrium and dissected off

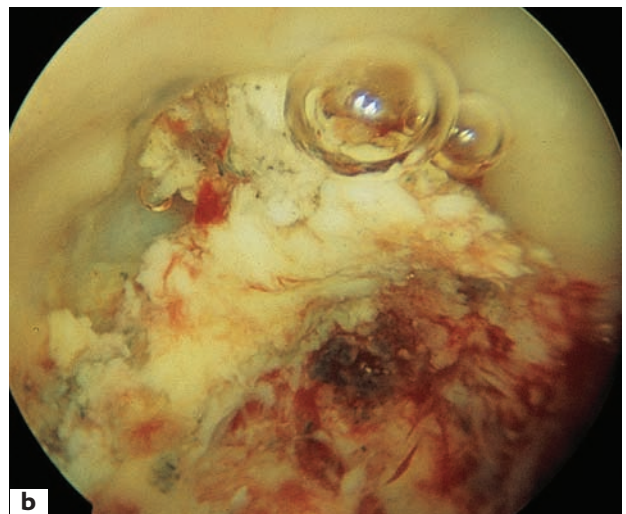
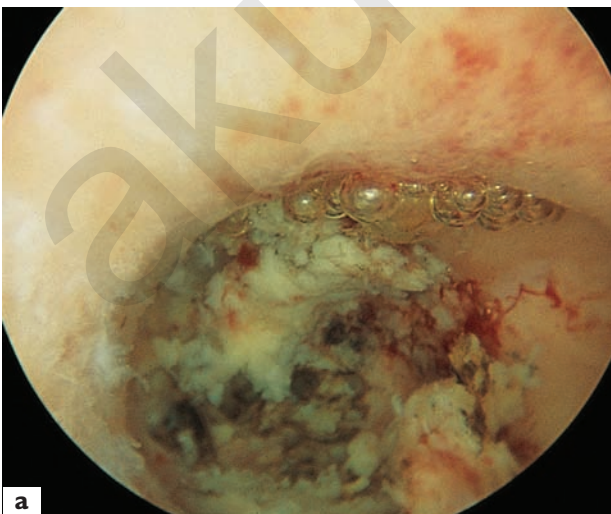


Figure 45.15 (a) and (b) Necrotic appearance of the residual myoma portion, 8 weeks after coagulation with the Nd:YAG laser

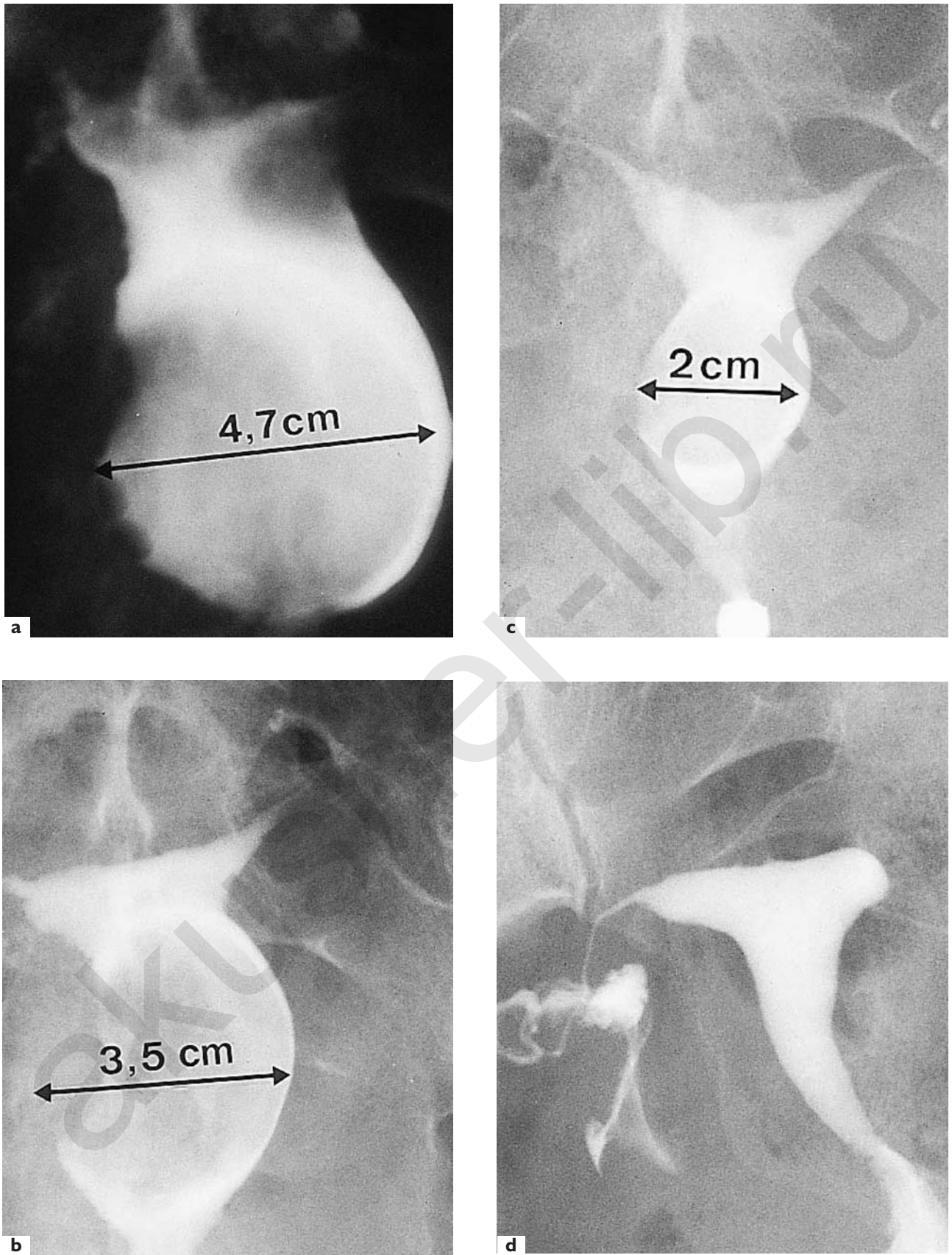


Figure 45.16 Hystero-graphy: (a) before gonadotropin-releasing hormone (GnRH) agonist therapy; (b) after GnRH agonist therapy; (c) 8 weeks after partial myomectomy and coagulation; the residual intramural portion was found protruding again in the uterine cavity; (d) 8 weeks after the second hysteroscopic myomectomy

Table 45.1 Surgical procedures and long-term results according to the site of myomas

	<i>Greater portion inside the uterine cavity</i>	<i>Greater portion located in the uterine wall</i>	<i>Multiple submucosal myomas (myomectomy and endometrial ablation)</i>
<i>Surgical procedures</i>			
Total number of patients	233	78	55
Successful	230	74	51
Failed	3*	4 [†]	4 [‡]
<i>1-year follow-up</i>			
Total number of patients	132	42	39
Recurrence of menorrhagia	1 (1%)	1 (2%)	8 (20%)
<i>2-year follow-up</i>			
Total number of patients	98	24	24
Recurrence of menorrhagia	2 (2%)	1 (4%)	6 (25%)

*Stromal tumor; [†]third-look hysteroscopy allowed removal of the myoma; [‡]myomectomy was not totally successful (in two cases, second-look laser hysteroscopy was successfully performed; in the other two cases, vaginal hysterectomy was proposed and successfully performed)

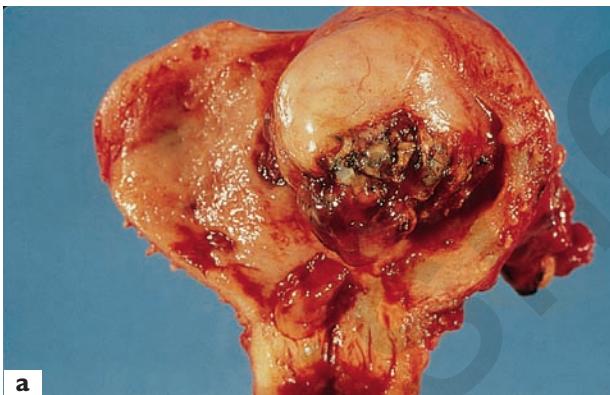
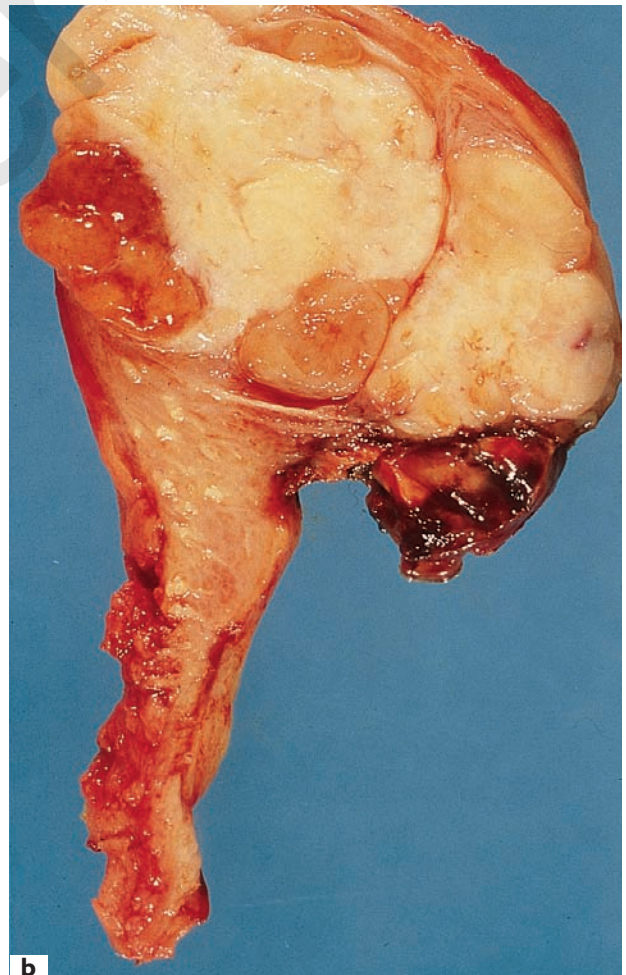


Figure 45.17 (a) and (b) Hysteroscopically, the intrauterine lesion appeared as benign myomas, but no plane of dissection could be found. Histology revealed a stromal tumor invading the myometrium



In patients with submucosal uterine fibroids, hysteroscopic myomectomy was carried out if the greater portion of the leiomyoma, as assessed by hystero-graphy, was inside the uterine cavity. Hormonal treatment for 8 weeks before hysteroscopic myomectomy was advised, since this produced significant uterine shrinkage.

Peroperative blood loss was minimal, possibly because of the decreased vascularity of the myometrium. This was demonstrated by a significant reduction in the uterine arterial blood flow (Doppler) after treatment with a GnRH agonist¹⁵.

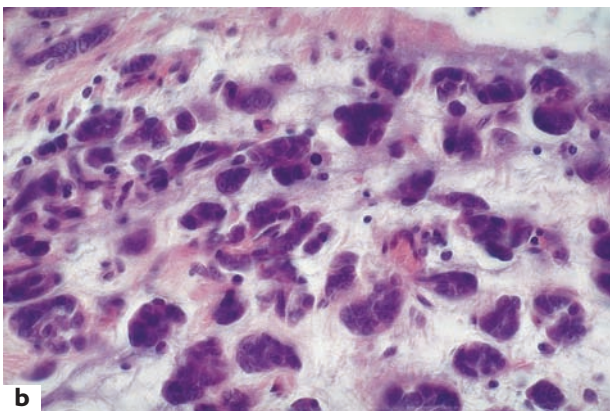
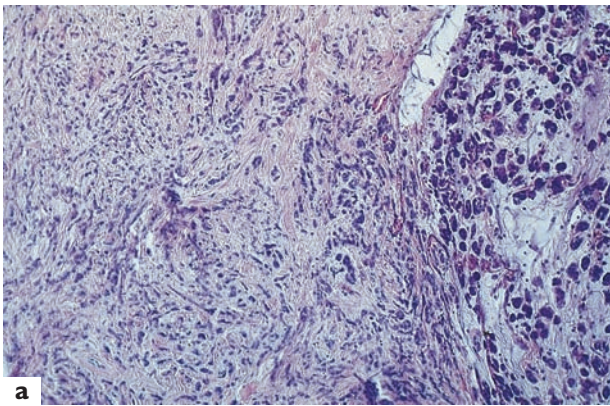


Figure 45.18 (a) Low-grade stromal sarcoma with areas of epithelial differentiation (on the right). In these areas, cells are considerably more atypical than those seen on the left, which resemble the stromal cells of proliferating endometrium; (b) areas of epithelial differentiation (high-power view)

For very large fibroids with the greater portion not inside the uterine cavity, myomectomy was carried out in two stages. During the first surgical procedure, the protruding portion was removed and the intramural portion was devascularized by introducing the laser fiber into the myoma, to a depth of 5–10 mm, depending on the depth of the remaining intramural portion (evaluated by echography). The pelvic structures were protected from injury because the distance between the top of the fiber and the external surface of the uterus was never < 1.5 cm. There was no risk of introducing the laser fiber as much as 1 cm into the remaining portion if the diameter of the fibroid was > 3–4 cm.

A very interesting finding was that this intramural portion of the myoma became submucosal and protruded inside the uterine cavity, possibly because of the GnRH agonist-induced uterine shrinkage. In all cases, the greater part of the remaining portion of the myoma was inside the uterine cavity, and myomectomy was easily performed by separating the myoma from the surrounding myometrium with the Nd:YAG laser.

CONCLUSION

Preoperative GnRH agonist treatment reduces tumor size and makes subsequent surgical treatment by hysteroscopy possible. In our series, even when the greater portion of the myoma was in the myometrium, a two-step hysteroscopic therapy combined with GnRH agonist therapy^{6,18} represented the ideal management of large submucous myomas, decreasing the need for laparotomy, which is often accompanied by increased operative blood loss and postoperative adhesion formation.

When numerous submucosal and intramural myomas were present, a higher risk of recurrence was observed than in patients with only one submucosal myoma⁸. Because of this high rate of recurrence, we prefer to perform a laparoscopic supracervical hysterectomy instead of the hysteroscopic procedure^{9,16}.

By preventing uterine bleeding, preoperative GnRH agonist therapy restores a normal hemoglobin concentration, and allows for the possibility of a later autologous transfusion⁶. The hormonal endometrial status is one of the factors affecting fluid absorption. Endometrial vascularization may account for liquid resorption, and this was reduced after preoperative GnRH agonist therapy. Less fluid was absorbed if the endometrium was atrophic, reducing the risk of fluid overload. This represents another major advantage of the combined medical and surgical approach to therapy.

The advantages of the preoperative use of a GnRH agonist are:

- Reduction of the myoma size
- Decreased risk of fluid overload
- Restoration of normal hemoglobin concentration
- Detection of a stromal tumor

Like Gallinat¹⁷, we believe that, although Nd:YAG laser treatment requires experience and a thorough knowledge of the technique, it nevertheless has the lowest complication rate, when compared with the resectoscope. Nd:YAG laser treatment must be considered the safest method in the hysteroscopic surgical treatment of large myomas.

REFERENCES

1. Hallez JP, Netter A, Cartier R. Methodical intra-uterine resection. *Am J Obstet Gynecol* 1987; 156: 10802–4
2. Loffer FD. Laser ablation of the endometrium. *Obstet Gynecol Clin North Am* 1988; 15: 77–89
3. Goldrath MH, Fuller T, Segal S. Laser photovaporization of endometrium for the treatment of menorrhagia. *Am J Obstet Gynecol* 1981; 140: 14–19
4. Goldrath MH. Hysteroscopic laser surgery. In Baggish MH, ed. *Basic and Advanced Laser Surgery*

- in Gynecology. Norwalk: Appleton-Century-Crofts, 1985: 357
5. Donnez J, Schrurs B, Gillerot S, et al. Treatment of uterine fibroids with implants of gonadotropin releasing hormone agonist: assessment by hystero-graphy. *Fertil Steril* 1989; 51: 947–50
 6. Donnez J, Gillerot S, Bourgonjon D, et al. Neodymium: YAG laser hysteroscopy in large submucous fibroids. *Fertil Steril* 1990; 54: 999–1003
 7. Neuwirth RS. Hysteroscopic management of symptomatic submucous fibroids. *Obstet Gynecol* 1983; 62: 509–11
 8. Donnez J. Nd:YAG laser hysteroscopic myomec-tomy. In Sutton C, Diamond M, eds. *Endoscopic Surgery for Gynecologists*. London: WB Saunders, 1993: 331–7
 9. Donnez J, Nisolle M. Hysteroscopic surgery. *Curr Opin Obstet Gynecol* 1992; 4: 439–46
 10. Healy DL, Fraser HM, Lawson SL. Shrinkage of a uterine fibroid after subcutaneous infusion of a LHRH agonist. *Br Med J* 1984; 209: 267–8
 11. Maheux R, Guilloateau C, Lemay A, et al. Luteinizing hormone-releasing hormone agonist and uterine leiomyoma: pilot study. *Am J Obstet Gynecol* 1985; 152: 1034
 12. Andreyko JL, Blumenfeld Z, Marschall LA, et al. Use of an agonistic analog of gonadotropin-releasing hormone (nafarelin) to treat leiomyomas: assessment by magnetic resonance imaging. *Am J Obstet Gynecol* 1988; 158: 903–10
 13. Friedman AJ, Barbieri RL, Doubilet PM, et al. A randomized, double-blind trial of gonadotropin releasing-hormone agonist (leuprolide) with or without medroxyprogesterone acetate in the treatment of leiomyomata uteri. *Fertil Steril* 1988; 49: 404–9
 14. Donnez J, Clerckx F, Gillerot S, et al. Traitement des fibromes utérins par implant d'agoniste de la GnRH: évaluation par hystérographie. *Contracept Fertil Sex* 1989; 17: 569–73
 15. Matta WHM, Stabile I, Shaw RS, et al. Doppler assessment of uterine blood flow changes in patients with fibroids receiving the gonadotropin-releasing hormone agonist Buserelin. *Fertil Steril* 1988; 49: 1083–5
 16. Donnez J, Nisolle M. Laparoscopic supracervical (subtotal) hysterectomy (LASH). *J Gynecol Surg* 1993; 9: 91–4
 17. Gallinat A. Hysteroscopic treatment of submucous fibroids using the Nd : YAG laser and modern elec-trical equipment. In Leuken RP, Gallinat A, eds. *Endoscopic Surgery in Gynecology*. Berlin: Demeter Verlag, 1993: 72–88
 18. Donnez J, Nisolle M. Nd : YAG laser hysteroscopic surgery: endometrial ablation, partial endometrial ablation and myomectomy. *Reprod Med Rev* 1993; 2: 63–71

akusher-lib.ru

Endometrial resection

B J van Herendael

INTRODUCTION

Sixty-four per cent of women are confronted with episodes of abnormal uterine bleeding (AUB)¹. Menorrhagia is a specific type of bleeding episode. Often women bleed so heavily that they find themselves at the wrong side of a vicious circle leading to a state of ferriprivaemia. Medication most often is not an acceptable long-term solution², neither is a hysterectomy. Although hysterectomy is often proposed as a 'hygienic' and definitive solution, there are numerous reports of morbidity³ and recently of sexual and psychological dysfunction and costs⁴. Although hysterectomy is still the most widespread solution for all types of AUB problems, it should be used only after thorough investigation and thorough explanation to the patient and her partner.

Local medical therapy (a progestin-loaded intrauterine contraceptive device) can only be successful if the uterine cavity is anatomically perfect and if the patient is disciplined enough to submit herself to checks at regular intervals.

Hysteroscopic endometrial resection is a conservative solution. The endometrial lining is resected to a layer just above the myometrium. An endothelial layer then replaces the endometrium. The consequence is that the blood flow is reduced dramatically in over 80% of patients. Hysteroscopic endometrial resection is in competition with other endometrial ablation techniques, such as laser endometrial ablation under hysteroscopic control, balloon endometrial ablation, hydroablation of the endometrium, ultrasound endometrial ablation, bipolar- and cryo-endometrial ablation and the latest diode laser endometrial ablation⁵.

The advantages of hysteroscopic electrical loop endometrial resection are two-fold. First, it is a technique under visual observation – an advantage it shares with rollerball electrical ablation, laser ablation and even hydroablation. The second, and main, advantage is the possibility of collecting samples for pathology. In the literature, we find reports of missed endometrial carcinomas picked up by the pathologist after examining the resected specimen⁶. The disadvantage of the technique is the high risk of complications, although these risks should not be exaggerated⁷. The mechanical complication of perforation is not what is meant here. Perforation is a hazard with all mechanical probes introduced into the uterine cavity, from simple Hegar dilators to very sophisticated instruments.

The most feared complication is the risk of circulatory overload with distension medium (transurethral resection of the prostate (TURP) syndrome). This risk is shared with hysteroscopic rollerball ablation and hysteroscopic laser endometrial ablation. This implies that hysteroscopic transcervical endometrial resection (TCER) requires more training than most techniques mentioned⁸.

INSTRUMENTS

A passive resectoscope is used⁹. The normal diameter is 26 F. A passive scope means that the active element, the loop, is retracted into the inner sleeve and has to be brought out by the operator before starting the resection and will retract towards the final lens of the scope when left.

All resections should be carried out with a through-flow instrument. Through flow means that there are two sleeves, an inner sleeve carrying the distension medium towards the uterine cavity and an outer sleeve for aspiration of the medium out of the cavity.

Electrical cutting current (undamped current) is the current of choice even for coagulation; here we hold the loop at a small distance over the bleeding vessel and create a spark to coagulate the vessel. The lower voltage of the cutting current is less likely to cause problems. Energy should be supplied if possible by a variable-output generator. The endometrial lining is not homogeneous, implying that different intensities are necessary to obtain an optimal result. The author uses 12 W for pure cutting and 80 W for coagulation.

Distension should be obtained with a pump mechanism that allows variable settings for both the inflow and the intracavity pressure. The maximum intracavity pressure is set between the systolic and diastolic blood pressures of the patient. In doing this, we avoid infusing the distension medium into the patient throughout the whole cardiac cycle. Too low a pressure would cause the blood to mix with the distension medium and obscure the view, and too high a pressure would cause a continuous flow of distension medium into the circulation of the patient. Aspiration into a collecting system allows us to have an idea of the amount of medium retrieved and, hence, be able to calculate the loss of distension medium. Classical endometrial resection is carried out in a non-ionic distension medium so as not to disperse the current. Glycine® 1% is the most commonly used distension medium among low-viscosity media,

mainly because of its low cost. We recommend use of the same distension medium as that used by urologists in the institution. The most common complication is fluid overload, the classical TURP syndrome, just as in urology.

TECHNIQUE

An endometrial resection should never be performed if the resection is not preceded by a diagnostic hysteroscopy with tissue sampling or, at least, a curettage.

It must be borne in mind by the hysteroscopic surgeon that this is a very conservative technique and that the technique should, therefore, only be performed in patients with no underlying uterine disease such as adenomyosis.

If an overt endometrial carcinoma is found, or even a carcinoma *in situ*, the patient should be treated as an oncology patient with major ablative surgery. If hyperplasia is found, recent reports suggest that there could be a place for conservative treatment. Further follow-up is, however, necessary before the treatment of hyperplasia by hysteroscopic resection of the endometrium can be considered as routine.

There is a question regarding pretreatment of the endometrium. In comparison with laser endometrial ablation, no special pretreatment is necessary, but TCER is easier and takes less operative time if the endometrium is between 3 and 5 mm in height. All classical pretreatments can be used or the resection can be planned in the early follicular phase, or an aspiration curettage with a 4–5-mm cannula can be performed to reduce the height.

Step one

The cervix is grasped with a vulsellum at the 11 o'clock position and is dilated up to Hegar 10 or 11, 33–35 F, corresponding to 11–12 mm. Dilatation up to this Hegar diameter is necessary to bring the scope easily into the uterine cavity and easily remove it.

Step two

The resectoscope is brought into the uterine cavity under direct vision.

Step three

The uterine cavity is inspected.

Step four

The loop is brought into contact with the mid-portion of the fundal area. Resection is begun by bringing the loop towards the lens of the scope. The loop should be embedded into the endometrium as far as necessary. The depth has to be judged by visual appreciation of the different linings of the uterine wall and should stop when the striated alignment of the myometrial musculature

becomes visible. The first furrow is the most important because this will set the depth for the whole of the resection.

The loop is brought into contact with the endometrium in the fundal area (Figure 46.1). Unipolar electricity, undamped, is activated. The first furrow is excised so that the endometrium is cut out to a depth just into the myometrium (Figure 46.2). If all the glandular buds are not excised in their totality a careful excision of 1 or 2 mm is performed over the first (Figure 46.3). This process is repeated until all the glandular buds are excised and the striated appearance of the layer above the myometrium can be seen (Figure 46.4).

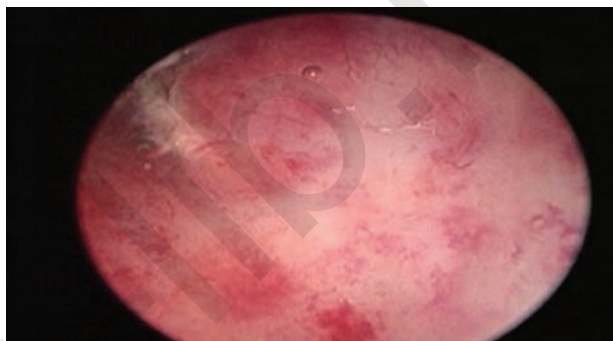


Figure 46.1 The loop is brought into contact with the endometrium in the fundal area

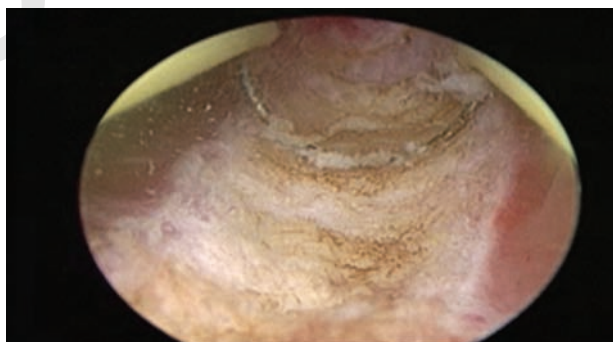


Figure 46.2 Excision of the first furrow

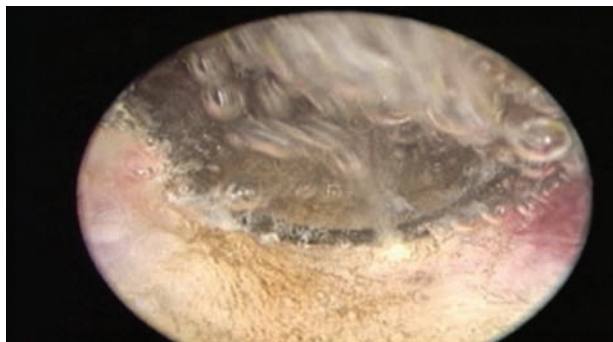


Figure 46.3 Excision of the glandular buds

Step five

The rest of the cavity is now treated. This can be performed in different sequences. Some surgeons proceed clockwise, others anticlockwise. I prefer to proceed first left and then right from the first furrow until I complete resection of the posterior part of the uterus. The loop is half embedded into and half out of the furrow so that the depth of the resection is easy to ascertain (Figure 46.5).

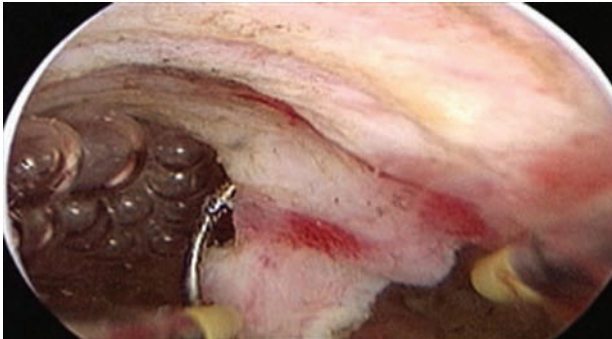

Figure 46.4 The process is repeated until the striated appearance of the layer above the myometrium is visible

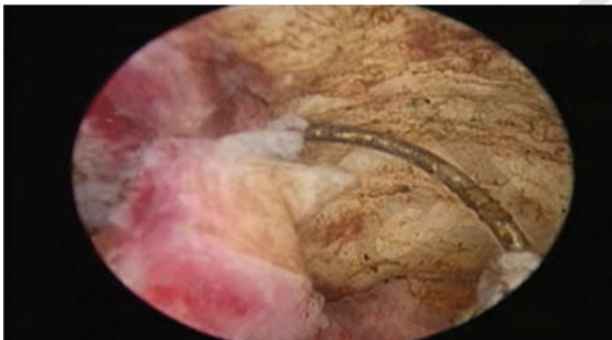


Figure 46.5 The loop is only half embedded in the endometrium so that the lowest part of the loop is at the level of the deepest passage of the previous furrow

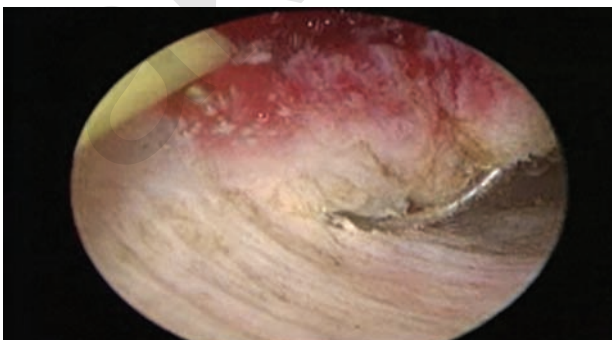


Figure 46.6 At the side walls, the loop is even less embedded so as to follow the curvature of the walls

Once the posterior side is completed, the lateral and anterior sides are tackled (Figure 46.6). The anterior side is always slightly more difficult, as bubbles caused by heating of the distension medium by the electrical current tend to collect in this area. It therefore becomes necessary to aspirate these bubbles at regular intervals (Figures 46.7 and 46.8). If necessary, the depth should be corrected until there are no glandular buds left (Figure 46.9). The resection is carried out to within 1 cm of the isthmus, a so-called

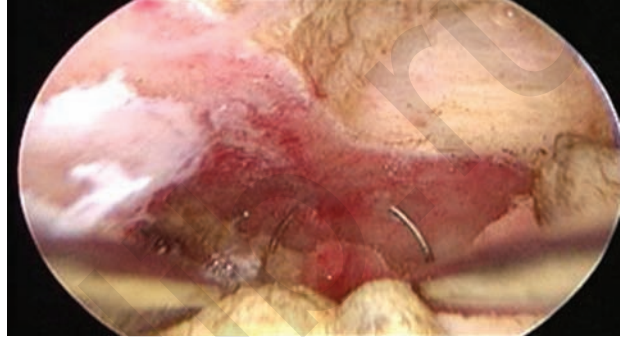


Figure 46.7 The anterior part is more difficult to treat as the tissue tends to fall towards the scope and bubbles generated by heating the distension medium make vision difficult. These bubbles must be aspirated

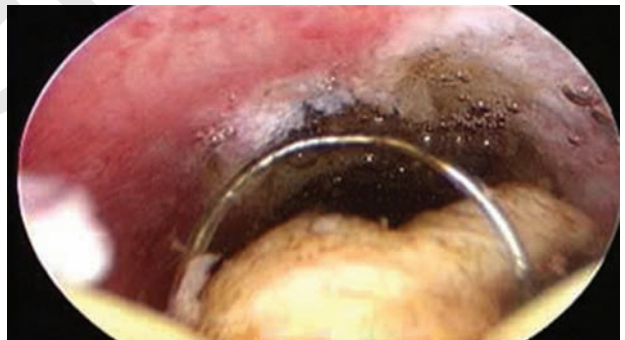


Figure 46.8 Example of the bubbles created by heating the distension medium

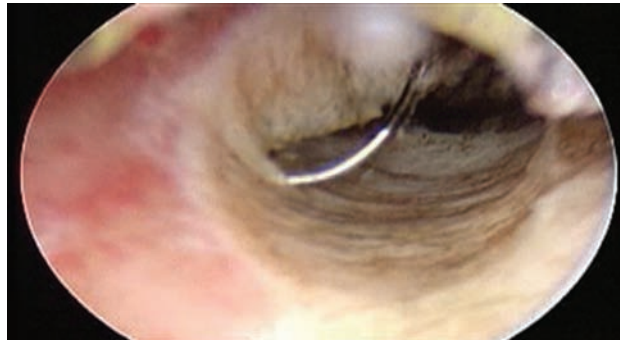


Figure 46.9 The circle is now completed and treatment of the fundal area can start

incomplete resection. A complete resection continues down to the cervical canal. The percentage of amenorrhea is higher with the latter technique.

Step six

The fundal and corneal areas are now treated (Figures 46.10–46.13). The fundal area can be treated with the loop by bringing the loop sideways over the fundal area.

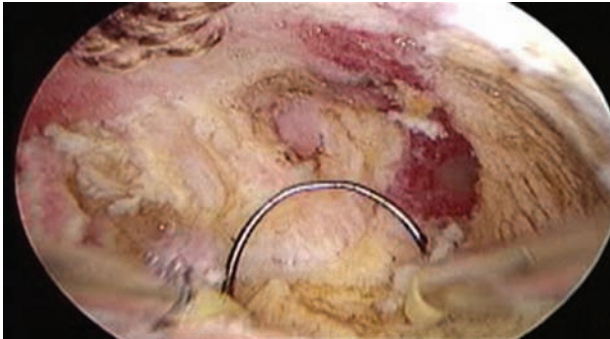


Figure 46.10 The tubal ostium, seen to the right in the middle of the picture with the dark red/crimson color scheme, is often difficult to treat with the classical resector loop

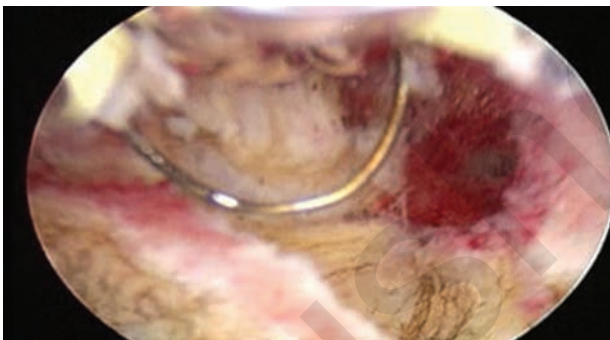


Figure 46.11 The combination of a deep-lying tubal ostium, a large resector loop and the bubbles makes it difficult to excise the osteal region precisely

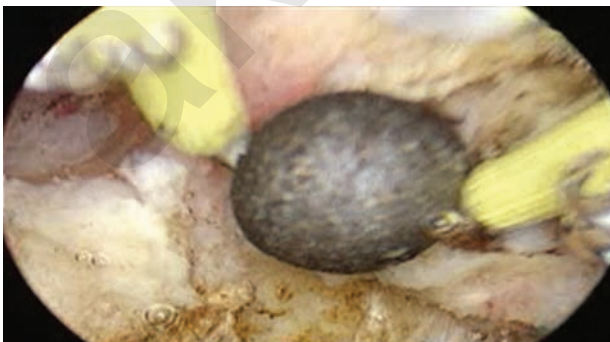

Figure 46.12 A small rollerball electrode can be useful in the treatment of these areas

The corneal areas can also be treated with the loop. If the loop is too large for the cornua, a small ball can be used to coagulate these areas.

Step seven

The fragments of tissue are grasped between the loop and the final lens of the resectoscope and brought out of the cavity (Figure 46.14).

Step eight

A last inspection of the uterine cavity is performed (Figure 46.15). If bleeding vessels are spotted, these are now coagulated. It can be useful to reduce the distension pressure in order to see the bleeding points (Figure 46.16).

Management of tissue fragments

If the uterus is large enough, the fragments of tissue should be ‘parked’ in the fundal area awaiting their removal at the end of the resection. If the uterus is small, resected fragments should be brought out whenever they interfere with good visibility.

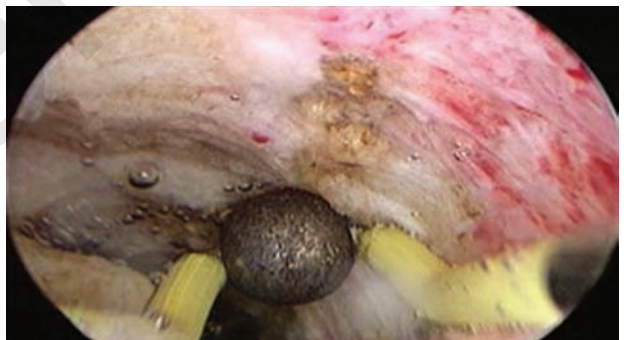


Figure 46.13 The rollerball electrode can also be used to treat the lower part of the resection in the cervix where deep resection is often dangerous as larger vessels can be opened inadvertently

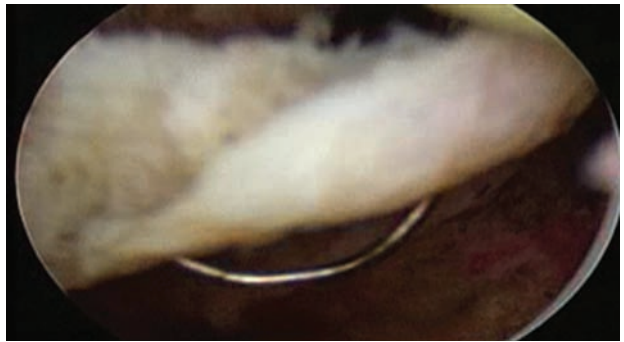


Figure 46.14 The fragments are grasped between the loop and the final lens and brought out of the uterine cavity

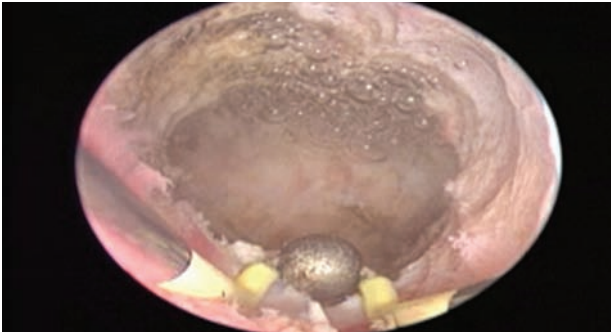


Figure 46.15 General view at the end of the resection

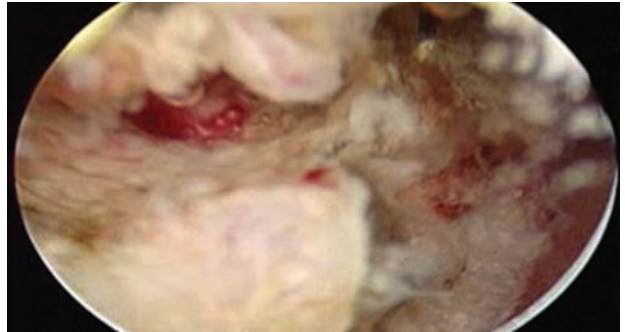

Figure 46.18 Note the glandular structure of the inside of the resected polyp

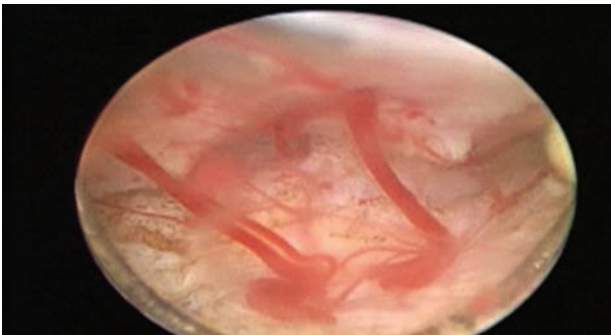


Figure 46.16 The pressure is reduced and the bleeding becomes visible so that the terminal part of the vessel can be coagulated

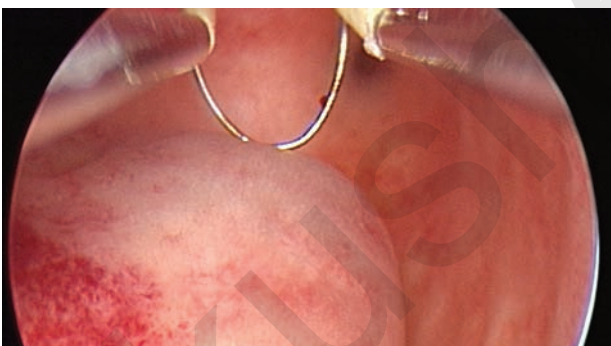


Figure 46.17 A polyp is removed at the same time as the endometrial resection

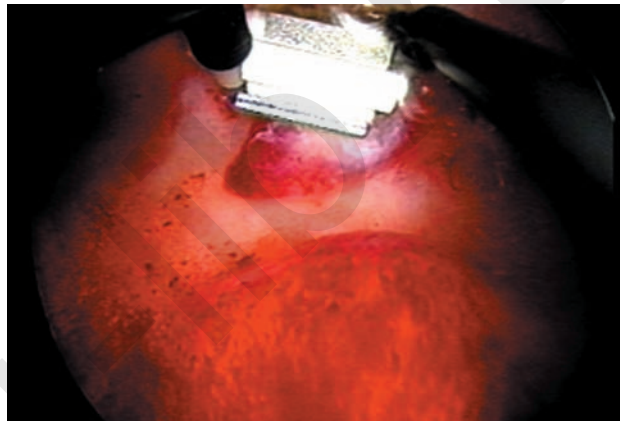


Figure 46.19 The electrode is brought in contact with the fundal area. Note that the visibility with normal saline is as good as with Glycine® when a through-flow resectoscope is used

CONCLUSIONS

Provided that the uterine cavity is of a reasonable size, the author suggests a resection of 10 cm. TCER is a well-documented technique that should be used as a first approach in patients with menorrhagia provided that there are no other pathological conditions in the uterine wall or the endometrium. Most common problems or failures are

caused by adenomyosis. This could be the reason why large uteri fare worse than their normal counterparts, as often there is the presence of adenomyosis alongside the myomas in these uteri.

If there are polyps in the uterine cavity, these should be treated during the same session (Figures 46.17 and 46.18). The outcome is the same as that for classical TCER.

If myomas are treated at the same time, the results seem slightly worse in the long-term follow-up. Our own long-term follow-up study (unpublished data) revealed that, after 5 years, 92% of the patients were still satisfied with the TCER and 96% would have the intervention again.

An alternative to unipolar high-frequency resection in Glycine distension medium is bipolar ablation in normal saline solution (Figures 46.19–46.21). It has to be said that fluid overload of the patient with normal saline has exactly the same consequences as overload with Glycine, except for the pharmacological effects of Glycine that do not

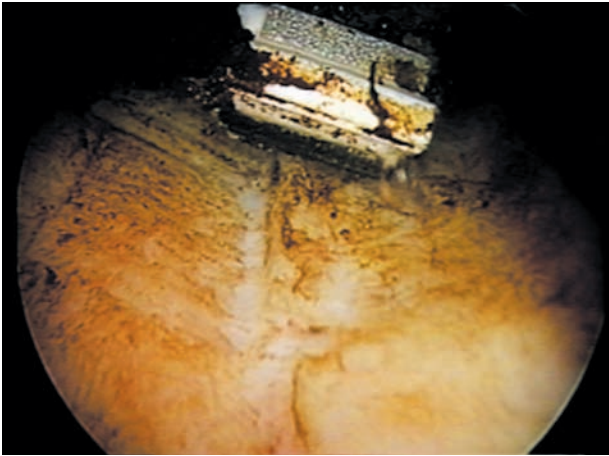


Figure 46.20 The action of the bipolar electrode is very powerful. The anatomical landmarks of the ablation are clearly visible. Note the different form of the electrode

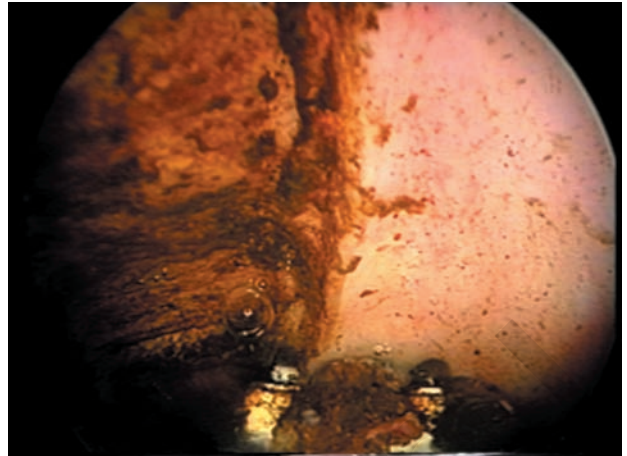


Figure 46.21 Both the posterior and the anterior wall must be treated. The bipolar electrodes are easier to manipulate than the classical resector loop

occur with normal saline. Ablation does not allow for pathological examination.

REFERENCES

1. Grainger DA, DeCherney AH. Hysteroscopic management of uterine bleeding. *Baillieres Clin Obstet Gynaecol* 1989; 3: 403–14
2. Wood C. Alternative treatment. *Baillieres Clin Obstet Gynaecol* 1995; 9: 373–97
3. Goldenberg M, Sivan E, Bider D, et al. Endometrial resection versus abdominal hysterectomy for menorrhagia. Correlated sample analysis. *J Reprod Med* 1996; 41: 333–6
4. Brumsted JR, Blackman JA, Badger GJ, et al. Hysteroscopy versus hysterectomy for the treatment of abnormal uterine bleeding: a comparison of cost. *Fertil Steril* 1996; 65: 310–16
5. Donnez J, Polet R, Mathieu P-E, et al. Nd : YAG laser ITT multifiber device (the Donnez device): endometrial ablation by interstitial hyperthermia. In Donnez J, Nisolle M, eds. *An Atlas of Laser Operative Laparoscopy and Hysteroscopy*. Carnforth, UK: The Parthenon Publishing Group, 1994: 353–9
6. Mencaglia L. Hysteroscopy and adenocarcinoma. *Obstet Gynecol Clin North Am* 1995; 22: 573–9
7. Bhattacharya S, Cameron IM, Mollison J, et al. Admission-discharge policies for hysteroscopic surgery; a randomised comparison of day case with in-patient admission. *Eur J Obstet Gynecol Reprod Biol* 1998; 78: 81–4
8. van Herendael BJ. Hazard and dangers of operative hysteroscopy. In Sutton C, Diamond M, eds. *Endoscopic Surgery for Gynaecologists*. London: WB Saunders, 1998: 118–25
9. van Herendael BJ. Instrumentation in hysteroscopy. *Obstet Gynecol Clin North Am* 1995; 22: 391–408

Global endometrial ablation

G A Vilos

Abnormal uterine bleeding (AUB) from benign causes affects approximately 20–25% of premenopausal women. The prevalence increases with age, and peaks during women's fifth decade just prior to the menopause¹. Traditionally, AUB has been treated medically, by dilatation and curettage (D&C) and/or hysterectomy. D&C has been widely used for the diagnosis and treatment of AUB; however, there are no randomized controlled clinical trials (RCTs) to demonstrate a sustained and prolonged therapeutic value. Hysterectomy has been the traditional and permanent treatment for AUB. However, the high hysterectomy rates and evaluation of risks and cost/benefit prompted the exploration of alternative therapies, one of which is endometrial ablation.

Hysteroscopic endometrial ablation or first-generation endometrial ablation technologies (FEATs) were introduced in the 1980s as an alternative to hysterectomy in women with AUB who failed medical management and/or D&C. Second-generation endometrial ablation technologies (SEATs), also called global endometrial ablation (GEA) technologies, were introduced in the 1990s as easier, possibly safer and equally effective alternatives to hysteroscopic endometrial ablation or FEATs².

Global endometrial ablation is defined as the automated destruction of the endometrium with an energy source without the use of operative hysteroscopy. The two exceptions to this rule include hydrothermablation (HTA), which can be performed under hysteroscopic observation, and microwave endometrial ablation (MEA), which is operator-dependent but performed without hysteroscopic visualization³. During the past decade several technologies have been introduced, some of which are extinct, but most remain available for clinical use, and others are still undergoing feasibility and/or comparative clinical trials. The technologies available for use are classified in Table 47.1.

All of these devices require minimal operator skills and no irrigant/distending solutions in the uterus, except for HTA which requires free circulating hot saline as the treating agent. All require thermal energy such as heat or cold to destroy the endometrium. Although all devices have produced good preliminary results, the long-term efficacy, complication rates and/or cost/benefit ratio, except for the hot liquid balloons, have not been established.

This chapter describes these devices as they appeared chronologically, and presents peer-reviewed publications and comparative randomized clinical trials with at least 12 months of follow-up. It is left up to the readers to assess the evidence and reach their own conclusions and

preferences. Criteria in choosing any of the devices should take into account: (1) maximum safety, (2) user-friendliness, (3) patient convenience, (4) analgesia/anesthesia requirements, (5) menstrual reduction rates, (6) durability and avoidance of further treatment and (7) costs of treatment compared with the first-generation ablation treatments and/or hysterectomy.

ENDOMETRIAL ABLATION

Endometrial ablation is the destruction or elimination of the endometrium by coagulation, freezing or resection, offered as an alternative to hysterectomy to those patients with AUB and benign pathology who are unable or unwilling to tolerate traditional therapies. Dysfunctional uterine bleeding (DUB) is defined as menstrual blood loss greater than 80 ml per cycle occurring in the absence of genital tract anatomic lesions or systemic diseases. DUB can be the result of both ovulatory and anovulatory anomalies. The consequences of AUB are excessive menstrual blood loss (menorrhagia, hypermenorrhea, polymenorrhea, menometrorrhagia), which frequently leads to iron-deficiency anemia. These signs and symptoms are often serious, embarrassing and debilitating conditions for many women, adversely affecting their quality of life. AUB together with uterine fibroids account for up to 75% of all hysterectomies performed worldwide^{1–5}.

Patient assessment

By intent, the aim of endometrial ablation is to destroy/eliminate the endometrium. Therefore, it is imperative to exclude premalignant and malignant

Table 47.1 Classification of second-generation endometrial ablation technologies (SEATs)

Hot liquid balloons
ThermaChoice® I, II and III
Cavaterm™ and Cavaterm™ <i>plus</i>
Thermablate™
Hydrothermablation (HTA)
Cryoablation (Her Option®)
Microwave endometrial ablation (MEA™)
Impedance-controlled ablation (NovaSure™)

endometrial lesions by endometrial biopsy and histological examination of intrauterine lesions such as myomas and polyps. Preoperative assessment of women should follow existing clinical practice guidelines and manufacturer's recommendations. Preoperative assessment may include all or some of the investigations listed under patient work-up.

Patient work-up

- A complete medical history
- Detailed physical and pelvic examination
- Papanicolaou smear within 12 months
- Endometrial sampling by office biopsy or D&C within 6 months
- Complete blood count, coagulation profile, thyroid function
- Pelvic imaging (sonography, magnetic resonance imaging (MRI), computed tomography (CT) scan)
- Hysteroscopy

Patient counseling

- Patients should be made aware that amenorrhea cannot be guaranteed. If patients wish or expect amenorrhea they should be advised against endometrial ablation and rather consider hysterectomy
- Although the menstrual reduction rates are reported to be between 85 and 95%, the amenorrhea rate is between 15 and 50%, depending on multiple factors such as the technology used, the experience of the surgeon and the presence of pathology such as myomas and/or adenomyosis
- It has been shown that the satisfaction rate following endometrial ablation is 80–90%
- Approximately 15–25% of women will require a second surgical procedure such as repeat endometrial ablation and/or hysterectomy. Repeat endometrial ablation is performed in approximately 2–15% of patients, and it may result in a higher complication rate such as uterine perforation and/or excessive bleeding, compared with the first ablation. Up to 20% of patients will have a subsequent hysterectomy for pain, abnormal bleeding or both. A higher prevalence of adenomyosis, approximately 50%, is usually found in hysterectomy specimens
- Endometrial ablation should not be offered to women who wish to preserve their fertility, or be used for contraception. Sterilization or other methods of birth control should be discussed.

Following endometrial ablation, intrauterine and ectopic pregnancies have been reported⁶

Indications for endometrial ablation

- Disabling uterine bleeding for disruption of life-style, convenience or unexplained bleeding on hormone replacement therapy (American College of Obstetricians and Gynecologists Technical Bulletin, February 1990⁷)
- Failed traditional therapies
- Contraindications to traditional therapies
- Poor surgical risk for hysterectomy
- To preserve the uterus

Relative contraindications

- Simple endometrial hyperplasia
- Dysmenorrhea
- Chronic pelvic pain
- Premenstrual dysphoric disorder
- Multiple or large uterine fibroids
- Enlarged uterus (more than 12 cm cavity length)
- Uterine prolapse

Absolute contraindications

- Genital tract malignancy (cervical, uterine, tubal, ovarian)
- Women wishing to preserve their fertility
- Women expecting amenorrhea as an outcome
- Acute pelvic inflammatory disease (PID)
- Intrauterine pregnancy

Preparation prior to ablation

A thin endometrium is easier to coagulate, freeze or resect, and may be associated with fewer intraoperative/postoperative complications and improved menstrual outcomes. Surgery may be more efficient and effective when performed in the immediate postmenstrual phase or following mechanical removal of the endometrium by sharp or suction curettage. Pharmacological agents such as oral contraceptives, progestins and danazol have been proved to be effective in thinning the endometrium, but one must bear in mind that progestins decidualize the endometrium, resulting in hypervascularity and stromal edema which might impede the energy used for ablation⁸. Gonadotropin-releasing hormone agonists (GnRH-a) have

been shown to be very effective in thinning the endometrium, and facilitate surgery by shortening operating time, reducing fluid absorption and improving menstrual outcome^{9–14}.

FIRST-GENERATION ENDOMETRIAL ABLATION TECHNOLOGIES

Photocoagulation of the endometrium

Laser photocoagulation or laser ablation (LA) of the endometrium to treat menorrhagia was first described by Dr Milton Goldrath of Detroit in 1981¹⁵. The patient is prepped and draped under appropriate anesthesia (usually general). The uterus is distended with a sterile liquid solution and the endometrium is photocoagulated with the Nd : YAG (neodymium : yttrium–aluminum–garnet) laser fiber by direct contact¹⁵ or by non-contact blanching of the endometrium¹⁶. It requires expensive equipment (Nd : YAG laser system and fibers), and it has been the least frequently used technique. Because it destroys the endometrium by direct contact or the blanching method, it is imperative to have a preoperative endometrial sample to exclude neoplasia. It has the lowest complication rate, including excessive bleeding, perforation, visceral burns and emergency interventions¹⁷.

Electrocoagulation of the endometrium

Electrocoagulation by the resectoscopic loop electrode and subsequently by the rollerball electrode (REA) were described in 1983¹⁸ and 1988¹⁹, respectively.

Transcervical resection of the endometrium

Transcervical resection of the endometrium (TCRE) was popularized in the late 1980s²⁰.

The patient is prepped and draped as for laser photocoagulation. The uterus is distended with an electrolyte-free sterile solution (glycine, sorbitol, dextrose, etc.), and the endometrium is coagulated or resected using an electrode connected to a high-frequency electro-surgical generator.

Clinical outcomes

The overall effect of endometrial ablation (Nd : YAG laser or high-frequency electrical energy referred to a radiofrequency, RF) is amenorrhea (15–50%), hypomenorrhea (30–50%) and no change in menses (8–10%)^{2,21}. Long-term results, using life-table analysis of up to 6.5 years, have shown high satisfaction rates of approximately 85%. Surgical retreatment rates are approximately up to 20% for hysterectomy and up to 10% for repeat endometrial ablation. Patients undergoing surgery after age 40 years appear to have a better outcome^{2,22}.

Complications of FEATs

Complications specific to hysteroscopic endometrial ablation include^{2,17,21–23}:

- Excessive (> 1000 ml) fluid absorption (0.4–1.5%)
- Hemorrhage (0.2–1.0%)
- Uterine perforation (0.8–1.5%)
- Visceral injury (0.1–0.3%)
- Infection and septicemia (0.4–1.0%)
- Recurrence of abnormal bleeding (8–10%)
- Death (0.2 per 1000)
- Unintended pregnancy (both ectopic and intra-uterine, estimated at 0.3%)
- Burns to the genital tract and viscera^{24–26}
- Laparotomy for visceral damage after uterine perforation and hysterectomy for uncontrolled bleeding

Although hysteroscopic endometrial ablation is effective and is associated with reduced morbidity, mortality, hospitalization and convalescence, compared with hysterectomy^{17,27}, it requires additional training and surgical expertise, excessive (non-) physiological solutions to distend the uterus and energy sources with their inherent hazards and complications^{24–26}. Therefore, its general use has been reluctantly accepted by the general obstetrician/gynecologist because many find the procedure and the energy sources intimidating and difficult to master.

SECOND-GENERATION ENDOMETRIAL ABLATION TECHNOLOGIES

SEATs, sometimes called global endometrial ablation (GEA), were introduced in the mid-1990s to overcome the above concerns and potential problems associated with the FEATs. These devices are described according to previous classification and in chronological order as they appeared in the gynecological field, and not in order of importance or the author's preference. An attempt is made to present all these devices in an unbiased manner, and describe their efficacy and safety only by the available peer-reviewed publications consisting of both grade A evidence (randomized controlled trials) and grade B evidence (well-conducted clinical cohort studies but not randomized). Reviews of these technologies have been published by Cooper and Erickson²⁷, Garry, in the Middlesbrough Consensus Document², and Vilos³.

Hot liquid balloons

The ThermaChoices

ThermaChoice® I The thermal balloon catheter (Gynecare, Ethicon, Somerville, NJ, USA) was designed by Dr Bob Neuwirth of New York, and it was described in 1994²⁸. Preliminary results in 18 patients were published in 1994²⁹, and the first pilot study of 30 patients was performed in June/July 1994 when the pressure and duration of treatment were established by Vilos *et al.*³⁰.

The ThermaChoice I system consists of a 16-cm long, 5-mm diameter catheter, with a latex balloon attached to its distal end, housing a heating element and two temperature sensors. The other end allows for inflation of the balloon and connects to a controller unit that monitors and controls preset intraballoon temperature, pressure and duration of treatment. The balloon catheter is first tested for leaks, and the system is primed by inflating it with 30 ml of 5% dextrose in water (5D/W) and deflating it to 200 mmHg negative pressure to remove any air. Subsequently, the balloon is inserted transcervically without hysteroscopic visualization. The balloon is inflated slowly to a pressure of 180 mmHg. The heater is then activated, and maintains evenly the intraballoon solution temperature at $87 \pm 5^\circ\text{C}$. An effective therapy has been determined to be 8 minutes.

The results from a prospective Canadian Clinical Trial³¹, an International Clinical Trial³² and a Food and Drug Administration (FDA)-approved United States study comparing the ThermaChoice I and rollerball^{33,34} are consistent. The efficacy of the ThermaChoice I is equivalent to that of rollerball hysteroscopic endometrial ablation, with an overall menstrual score reduction of 86% vs. 92% and patient satisfaction of 86% vs. 87% in the ThermaChoice I and rollerball groups, respectively.

Furthermore, the treatment time is significantly reduced (percentage less than 30 minutes) in the balloon group (71%) versus the rollerball group (29%), and the hysterectomy rates at 1 and 3 years of follow-up were 1% and 3% vs. 3% and 9%, respectively^{33,34}. At 5 years, there were 42 (16%) hysterectomies among the original 255 women (21 ThermaChoice, 21 rollerball), five repeat ablations (three ThermaChoice, two rollerball) and one D&C (rollerball). The satisfaction rate in the non-hysterectomy patients was 93% in the ThermaChoice and 100% in the rollerball group³⁵. Long-term (4–6 years) results from the original international cohort study ($n=256$, 72% respondents) indicated that the probability of avoiding hysterectomy was 85% of all women, and the probability of avoiding reablation was 88% of non-hysterectomized women. Overall, the probability of avoiding any surgery was 75%³⁶. The safety, efficacy and cost savings of the ThermaChoice I have also been reported by other investigators^{37–48}.

A significant number of selected patients can be treated without general anesthesia. Endometrial ablation by ThermaChoice is a blind procedure (not done under hysteroscopic visualization). Because of its high compliance, the balloon will not be pressurized if it is not contained within the uterine cavity. It can only be used when a normal uterine cavity is present, and it should not be used in the presence of intrauterine fibroids, polyps, adhesions or septa. However, a RCT demonstrated that the ThermaChoice balloon was as effective as rollerball coagulation in treating AUB in the presence of submucous myomas measuring 3 cm or less, with less than 50% of their diameter within the endometrial cavity⁴⁹.

ThermaChoice II The ThermaChoice II was introduced in 1998. The device is similar to ThermaChoice I except that the balloon is made of silicone and it contains an impeller to agitate the fluid (Figure 47.1). First it is tested for leaks and purged of any air, as for ThermaChoice I. The silicone balloon and the <5-mm diameter catheter are inserted into the uterus. The balloon is then filled with sterile 5D/W until the pressure reaches 180 mmHg. Once the pressure is confirmed to be stable by waiting for at least 30 seconds, the heater and the impeller are activated. The heating element and the impeller fan inside the balloon raise the temperature to 87°C (186°F) and evenly circulate the fluid for 8 minutes during the therapy cycle. The controller continuously monitors and displays intrauterine pressure, regulates fluid temperature and controls therapy time throughout the procedure. The heating element automatically deactivates if preset parameters are exceeded. When the controller signals that treatment is completed, the balloon is deflated manually and the catheter is withdrawn and discarded.

It has been demonstrated in extirpated human uteri that tissue necrosis was consistent to a depth of 4 mm of myometrium, except at the cornua, where necrosis extended for only 1 mm into the myometrium. Furthermore, the endomyometrial necrosis was more uniform and deeper throughout the uterine cavity, compared with ThermaChoice I.



Figure 47.1 The ThermaChoice® II hot water balloon system (Gynecare, Ethicon, Somerville, NJ, USA)

The effect of two preablation endometrial thinning modalities on the efficacy of the ThermaChoice II system has been evaluated. Qualified patients were randomized for a 3-minute suction curettage or 1 month of GnRH-a administration (Zoladex® 3.6 mg intramuscularly; AstraZeneca, Mississauga, Canada). Uterine bleeding was documented by menstrual diary scores at baseline, 3 months, 6 months and 1 year. One hundred and five patients with menorrhagia of benign etiology were randomized, and 102 patients were treated. Inclusion criteria required a patient's Higham menstrual score of >150, 1–2 months prior to treatment, and the preoperative mean baseline scores were 407 and 392 in the GnRH-a and suction curettage groups, respectively. No safety issues related to the device were noted. Silicone balloon material appears to perform similarly to the previous latex balloon design, as observed by postablation hysteroscopy. The postoperative Higham scores at 6 and 12 months consistently showed a reduction of menstrual blood loss up to 90%, with mean Higham scores of 25 vs. 32 in the GnRH-a and suction curettage groups, respectively. The overall success rate was 88% for goserelin (Zoladex) and 89% for curettage, while patient satisfaction was 90% and 95%, respectively⁵⁰.

Advantages of ThermaChoice II

- Catheter comparable to size of the Pipelle®
- Minimizes the need for cervical dilatation
- Allows treatment of latex-sensitive patients
- Provides more uniform distribution of heated liquid
- Provides more uniform and deeper necrosis of tissue
- Provides up to 90% reduction in menstrual bleeding
- Provides up to 95% patient satisfaction

ThermaChoice III The ThermaChoice III was introduced in 2004. The silicone balloon was modified to allow better expansion and coverage of the uterine cavity in an effort to increase the amenorrhea rate. No clinical results have been published to date.

The ThermaChoice balloon was the first global ablation technology introduced in the market, and its safety and long-term efficacy have been well established in over 300 000 procedures performed worldwide. The Food and Drug Administration Manufacturer and User Facility Device Experience (FDA MAUDE) database on ThermaChoice included 64 complications out of 150 000 procedures performed in the United States from December 1997 to May 2003. Adverse events included thermal bowel injury (five); other thermal burns (seven); required laparotomy (eight); and death (one)⁵¹.

The Cavaterm system

The Cavaterm™ hot liquid balloon system (Wallsten Medical, Morges, Switzerland) was described by Friberg *et al.* in 1996⁵². This device consists of a disposable silicone balloon catheter (outside diameter 8 mm) in which a heating element is integrated to a battery-operated controller (Figure 47.2). The balloon is filled with 1.5% glycine solution to a pressure of 200 mmHg (± 20). The liquid is vigorously circulated inside the balloon by pump oscillating pressure to ensure even heat transfer to the endomyometrium. The mean balloon temperature at the balloon surface is 75°C ($\pm 5^\circ\text{C}$), and the treatment is completed in 15 minutes^{52,53}. The Cavaterm system is based on the concept of a sustained high intraballoon pressure, resulting in a reduction of uterine blood flow, which in turn may enhance deeper penetration of the heat and improve clinical outcomes.

In three cohort studies with 50–117 patients the amenorrhea rate ranged from 22 to 68% after a follow-up of 3–60 months. The overall success rate ranged from 92 to 98%^{54–56}. A RCT of 82 women with menorrhagia compared transcervical hysteroscopic endometrial resection (TCRE) with the Cavaterm balloon. At 2 years of follow-up, the satisfaction rate was significantly higher in the Cavaterm-treated group (95 vs. 70%), while the reoperation rate was significantly higher in the TCRE group (15% vs. 6%)⁵⁷. A second RCT ($n=72$) compared the Cavaterm system with endometrial Nd:YAG laser ablation. All women were pretreated with a single dose of GnRH-a, 1 month prior to ablation. At 12 months, amenorrhea rates in the Cavaterm and laser ablation groups were 29% vs. 39%, with combined amenorrhea and hypomenorrhea rates of 73% vs. 69% and repeat surgery 15% vs. 12%, respectively⁵⁸. Another double-blind RCT compared the Cavaterm ($n=19$) with the NovaSure™ ($n=27$) device. At 12 months of follow-up, the amenorrhea, hypomenorrhea, eumenorrhea and menorrhagia rates

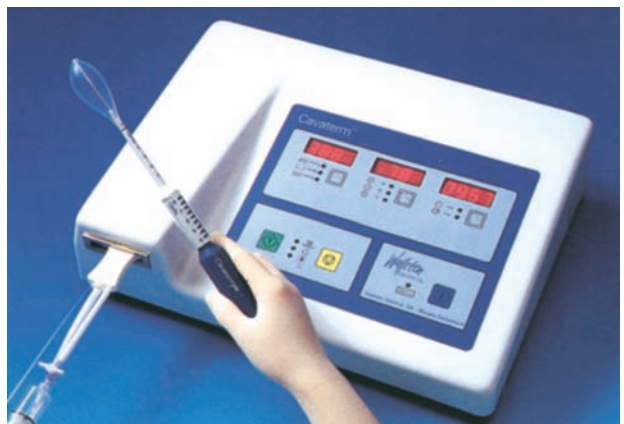

Figure 47.2 The Cavaterm™ hot glycine balloon (Wallsten Medical, Morges, Switzerland)

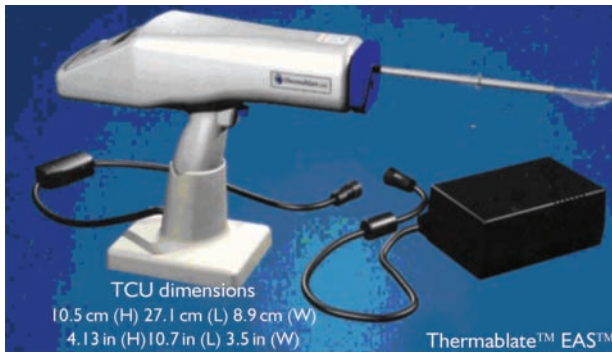


Figure 47.3 The Thermablate™ hot glycerine balloon system (MDMI Technologies, Richmond BC, Canada)

were 11% vs. 43%, 61% vs. 27%, 27% vs. 16% and 0% vs. 13% in the Cavaterm and NovaSure groups, respectively. The satisfaction rates were 83% and 92%, respectively⁵⁹.

Cavaterm Plus The Cavaterm *plus* system consists of an adjustable preformed silicone balloon of length 4–8 cm and a 6-mm diameter catheter. The self-regulating SoftHeat® element is powered by a low-voltage battery, and vigorous circulation of the intraballoon glycine solution maintains a uniform temperature of 78°C throughout the duration of the treatment.

The Cavaterm system is not available in the United States. According to Wallsten medical files, at least two bowel burns have been experienced with the Cavaterm balloon. In one case, the balloon was inserted into a false passage created by the dilator in a retroverted uterus. It was postulated that pharmacological pretreatment had resulted in thinning of the uterine wall, and its decreased vascularity eliminated the protective 'heat sink' effect of the uterine blood flow⁶⁰.

The Thermablate endometrial ablation system

This hot liquid balloon system was developed by Yackel and Elliot (MDMI Technologies, Richmond, BC, Canada), and was described in 2003⁶¹. The Thermablate is a hand-held device weighing approximately 830 g. It consists of a disposable cartridge–catheter–silicone balloon articulating to a treatment control unit (TCU) powered by a small electrical box (Figure 47.3). The entire system fits into a briefcase. Once switched on, the TCU preheats 28 ml of glycerine solution in approximately 8 minutes to 173°C ($\pm 5^\circ\text{C}$), and subsequently controls the treatment settings of time, pressure and temperature. The TCU remains in the treatment-ready mode for 35 minutes before it shuts down, but it can be restarted again. The procedure can be performed in an out-patient facility with minimal requirements for analgesia. After paracervical injection of local anesthetic, the cervix is dilated to 7 mm, the uterus is sounded and the 6-mm diameter insulated catheter with its preshaped balloon is inserted into the uterus.

In women treated with GnRH-a, or when cervical stenosis is known or suspected, the use of 400 µg oral, 400 µg vaginal misoprostol, given 9–12 hours prior to hysteroscopy, or *Laminaria* facilitate the procedure and result in fewer complications compared with placebo^{62,63}.

A suggested cocktail for local analgesia³:

- 10 ml lidocaine 1% with 1 : 200 000 epinephrine
- 10 ml bupivacaine 0.2%
- 50 ml (one ampule) sodium bicarbonate
- 1 ml (one ampule) atropine (0.5 mg)

giving 71 ml total solution; inject 5–10 ml at 4, 8 and 12 o'clock positions of the cervix.

If the treatment is not tolerated under local analgesia, conscious sedation can be achieved using the following cocktail of medications³:

- Fentanyl citrate 1 µg/kg intravenously (IV)
- Atropine 0.5–0.6 mg IV
- Midazolam 4 mg IV
- Antiemetic:
 - dimenhydrinate 50 mg IV
 - prochlorperazine 10 mg intramuscularly (IM) or IV

The treatment is initiated by finger trigger action on the TCU, and the hot liquid is forced from the cartridge through the catheter into the balloon by air pumped into the TCU heating chamber to a pressure of 180–200 mmHg. Treatment temperatures at the balloon surface reach approximately 100°C. Once the treatment cycle is initiated, there is an automatic 15-second balloon leak check followed by a series of pressurization and depressurization cycles during the 128 seconds of the treatment period. The treatment period was determined by phase I studies as necessary to coagulate 4–5 mm of endomyometrium.

Preliminary results in 16 women indicated amenorrhea (50%), hypomenorrhea (38%), eumenorrhea (6%) and failed treatment (6%)⁶¹. Treatment in Canada involving over 2000 patients indicated approximate amenorrhea, hypomenorrhea, eumenorrhea and failed treatment rates of 20%, 60%, 10% and 10%, respectively^{64–66}.

This latest hot liquid balloon is the simplest and most portable endometrial ablation device available. The 2-minute treatment time and small-diameter catheter allow utilization in an office setting under minimal analgesia. The Thermablate system is not available in the United States.

The HydroThermAblator

The HydroThermAblator (BEI Medical Systems, a Boston Scientific Company, Teterboro, NJ, USA) was conceived by the father of endometrial ablation, Dr Milton Goldrath of Detroit, and described in 1997⁶⁷. Externally heated 0.9% normal saline is infused and circulated directly into the



Figure 47.4 The HydroThermAblator hot free saline system (BEI Medical Systems, Teterboro, NJ, USA)

uterine cavity through the inflow channel of a continuous flow hysteroscope (Figure 47.4). The cervix is dilated to 8-mm. A 3-mm hysteroscope is introduced through a 7–8-mm disposable insulating sheath, allowing for an inflow and outflow channel, and the cavity is initially distended with room temperature saline for inspection. Subsequently, preheated saline (at 90°C) is infused under gravity at a pressure of approximately 50–55 mmHg for a 10-minute period under hysteroscopic observation. Additional time is required for a warm-up and a 1-minute cooling down period. The cervix must be sealed tightly to prevent leakage of the circulating hot saline into the vagina, and the controller automatically shuts off flow of the hot saline after 10 ml of unaccountable saline. This is the only device of all the global ablation techniques that allows direct observation during the treatment cycle, which is considered a major safety issue. Due to the low intrauterine pressure produced by gravity alone, no flow through patent Fallopian tubes has been detected at 50 mmHg. Histological studies of the effects of circulating hot saline on the uterus prior to hysterectomy have been reported^{68,69}.

In a RCT of 276 women with menorrhagia, 187 women were treated by hydrothermablation (HTA) and 89 by rollerball⁷⁰. All women were pretreated with

3.75 mg of leuprolide acetate, 3 weeks prior to ablation, and were evaluated at 12, 24 and 36 months. At 36 months, the amenorrhea, hypomenorrhea/eumenorrhea and patient satisfaction rates were 53%, 94% and 98% in the HTA group and 46%, 91% and 97% in the rollerball group, respectively⁷¹. Advantages of HTA over rollerball included reduced analgesia requirements and elimination of excessive fluid absorption, and requirement of minimal skills to perform the ablation.

It has been proposed that patients with intrauterine lesions or anatomic uterine malformation can be treated by the HTA system. At least two cohort studies have reported good results using HTA in women with menorrhagia and intracavitary pathology^{72,73}. However, the use of any SEAT to treat intracavitary lesions without histological diagnosis remains to be validated. Uterine sarcomas⁷⁴ and other atypical intrauterine lesions⁷⁵ have been identified incidentally by the routine use of resectoscopic endometrial ablation.

Disadvantages of the HTA system include cervical dilatation to 8 mm, the requirement for pretreatment, reduced portability, the need for hysteroscopic equipment and potential thermal burns. The FDA MAUDE database up to May 2003 included five complications in three patients: one thermal bowel injury, two other thermal injuries, one uterine perforation and one laparotomy⁵¹.

Microwave endometrial ablation

The use of microwave endometrial ablation (MEA™) (Microsulis, Waterlooville, Hampshire, UK) to treat women with menorrhagia was first described by Nick Sharp in 1995⁷⁶. The system consists of an 8-mm diameter reusable probe which is inserted into the uterus. Microwave power is generated by a magnetron, and passes along the cable to the probe at 30 W, generating energy of 1.5–9.3 kJ. The power is controlled via a foot-switch operated by the surgeon (Figure 47.5). The temperature achieved inside the uterus is monitored continuously by thermocouples on the exterior surface of the wave-guide. A computer displays the temperature graphically in real-time and generates a hard copy. The frequency of the microwaves is 9.2 GHz (9.2×10^9 Hz, compared with the electrosurgical generator's 0.5×10^6 Hz).

After appropriate analgesia/anesthesia (paracervical block, conscious sedation or general), the cervix is dilated to 9 mm and the microwave probe is inserted to touch the fundus. In a RCT, MEA under local anesthesia was acceptable to the majority of women referred for treatment. There was no recovery advantage from local anesthesia, and almost one in 10 women required conversion from local to general anesthesia during treatment because of discomfort⁷⁷. Once the probe is activated and the tip temperature reaches 95°C (within a few seconds), the probe is moved laterally to place the tip at the uterine cornua. The temperature reading will fall briefly and then rise. Once 95°C is again attained, the probe is moved to

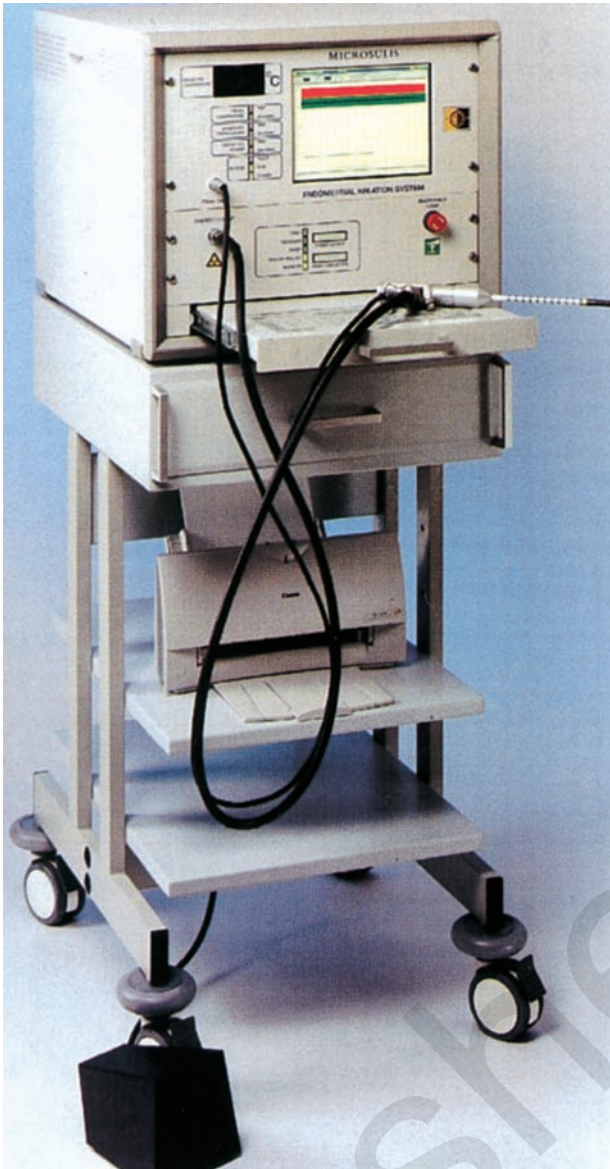


Figure 47.5 The microwave endometrial ablation (MEA™) system (Microsulis, Waterlooville, UK)

place the tip in the other cornual area to repeat the procedure. The probe is then gradually withdrawn while maintaining the probe temperature in the 80–95°C range to ensure even, complete endometrial destruction. The entire treatment is completed in 2–3 minutes. Prethinning of the endometrium is recommended.

Preliminary results after 6 months of treatment in 23 patients demonstrated: amenorrhea 57%, hypomenorrhea 26%, no improvement 12%. Three patients were retreated successfully. The overall results were 83% for single treatment and 96% after retreatment⁷⁶. A randomized comparative clinical trial (MEA, $n=129$) against transcervical resection (TCRE, $n=134$) reported that at 12 months, 89 (77%) women in the MEA group and 93 (75%) in the

resection group were totally or generally satisfied with their treatment⁷⁸. The menstrual pattern was similar in both groups, with a combined amenorrhea/hypomenorrhea rate of 89% in both groups and satisfaction rate of 90%. Repeat resection was performed in 1% and hysterectomy in 12–13% in both groups. The total operation time was 11 and 15 minutes in the MEA and TCRE groups, respectively⁷⁸. After 2 years of treatment, the satisfaction rates were 79% vs. 67% in the MEA and TCRE groups, respectively⁷⁹.

A multicenter RCT compared MEA ($n=215$) and rollerball endometrial ablation (REA, $n=107$). By intent-to-treat analysis, the success rate of MEA at 12 months (87.0%) did not differ significantly from that of REA (83.2%). Among evaluable patients, the success rate was also similar in the MEA (96.4%) and REA (92.7%) groups. The amenorrhea rate in evaluable patients was 61.3% vs. 91.0% and the satisfaction rate was 98.5% vs. 99% in the MEA and REA groups, respectively⁸⁰. At 3 years, the amenorrhea and satisfaction rates were 64% vs. 56% and 95% vs. 90% in the MEA and REA groups, respectively⁸¹. Success rates at 12 months in women with myomas and in those without myomas did not differ significantly between the MEA and REA groups. Among evaluable patients with myomas who underwent MEA, the success rate was 90.3%. These women attained an amenorrhea rate of 61.3%, compared with 38.5% of women with myomas treated by REA⁸⁰. Although all three RCTs included intracavitary polyps and myomas up to 2 cm in diameter, only the last RCT reported a subgroup analysis of patients with myomas⁸⁰.

Advantages of MEA include a short treatment time (3–4 minutes), high success rate and applicability in a larger uterus (up to 14 cm cavity length) with or without intracavitary polyps and myomas. Disadvantages include reduced portability, requirement for pretreatment to thin the endometrium, cervical dilatation to 9 mm, ultrasonic measurement of myometrial thickness and lack of a perforation detection mechanism.

Although the technique is of short duration and easy to master, it is a blind procedure, and the relative safety has not been established. In 1433 cases performed in 13 centers in the United Kingdom and Canada, one burn of the small bowel was encountered with the MEA (frequency 0.7/1000)⁸². An additional bowel injury was reported at the Middlesbrough Consensus Meeting in the UK². Furthermore, from November 2003 to March 2004, the FDA MAUDE database included three bowel burns and one case of peritonitis secondary to pyosalpinx, and no evidence of uterine perforation. One bowel burn occurred in the absence of obvious uterine perforation.

Cryoendometrial ablation

Cryosurgery of the endometrium using a probe to freeze the endometrium from –60°C to –100°C in six patients was first reported by Cahan and Brockunier in 1967⁸³.

Droegemueller *et al.* evaluated two types of cryoprobes using freon in 1970⁸⁴ (Frigitronics, Shelton, CT, USA). Ten of 16 patients with DUB developed amenorrhea during the 6–8-week interval between cryosurgery and a scheduled vaginal hysterectomy. In two patients, cryosurgery was accomplished under local anesthesia^{85,86}.

In two subsequent studies by Pittrof *et al.*, 18 patients underwent transcervical endometrial cryoablation using normal saline as a uterine distension medium^{87,88}. The principle of this technique was to distend the uterine cavity with 3–15 ml of normal saline and then to freeze it with a nitrous oxide iceball, forming a mould of the uterine cavity, with a specially designed cryosurgical probe. The probe appeared similar to a number 8 Hegar dilator. After 5 minutes, the ice was allowed to melt, and the same procedure was repeated with the probe pointing toward the other uterine cornua. Of the 12 patients followed up to 3 or more months, eight were completely satisfied with their results. There were no operative complications, and 13 patients were discharged the day after their operation^{87,88}.

Rutherford *et al.*, in a pilot study involving 15 patients followed for 22 months, reported that amenorrhea was achieved in 50%. New equipment was able to freeze the endometrium to -170°C ⁸⁹. The cervix was dilated to 8 mm, and the bladder was filled with 300–400 ml of warm saline to act as a heat sink. The uterine cavity was filled with up to 10 ml of a water-soluble lubricant. An 8 mm \times 27 cm conical-tip cryomedical freezing probe with a 4-cm freezing zone attached to a CMS 450 AccuProbe[®] system (Cryomedical Sciences, Rockville, MD, USA) was inserted to the uterine fundus. Once freezing of the uterine cavity was begun, iceball formation was monitored using a biplane 7.5-MHz transrectal transducer with an ultrasound scanner. Within 3–5 minutes after the probe

reached -170°C , the front of the iceball was seen to be at least 50% through the myometrium. At this point, freezing was discontinued and thawing begun⁸⁹. Fifteen patients underwent 16 procedures for DUB. Life-table calculations gave amenorrhea rates of 75.5% at 6 months and 50.3% at 22 months. One patient was retreated.

Her Option™ cryoablation This cryosurgical system (CryoGen, San Diego, CA, USA) is compressor driven and uses a new mixed gas coolant to generate temperatures of -90° to -100°C . The cryoprobe is inserted into the uterine cavity and saline is injected to bath the cryoprobe (Figure 47.6). Freezing–thawing of the intrauterine iceball is monitored with transabdominal ultrasound. Endometrial cryoablation in ten women undergoing hysterectomy resulted in 9–12-mm depth of endomyometrial necrosis as determined by tetrazolium staining and electron microscopy^{90–92}.

A multicenter RCT compared Her Option ($n=193$) with rollerball ($n=86$) in women with menorrhagia. Women treated by cryoablation received significantly less general anesthesia (46%) than those treated by rollerball (92%). At 12 months of follow-up, the amenorrhea and overall success rates were 28% and 77% in the Her Option group compared with 56% and 84% in the rollerball group, respectively⁹³. At 24 months, 77% of the cryoablation group reported that dysmenorrhea was non-existent or much improved, versus 81% of the rollerball group. Premenstrual symptoms were absent or mild in 64% of cryoablation and 79% of electrocoagulation patients. The satisfaction rates were 91% and 88% in the cryoablation and electrocoagulation groups, respectively. Of the cryoablation group, 7% proceeded to hysterectomy and 2.7% to repeat ablation, compared with 8.1% and 1.2% of the rollerball group, respectively⁹⁴.

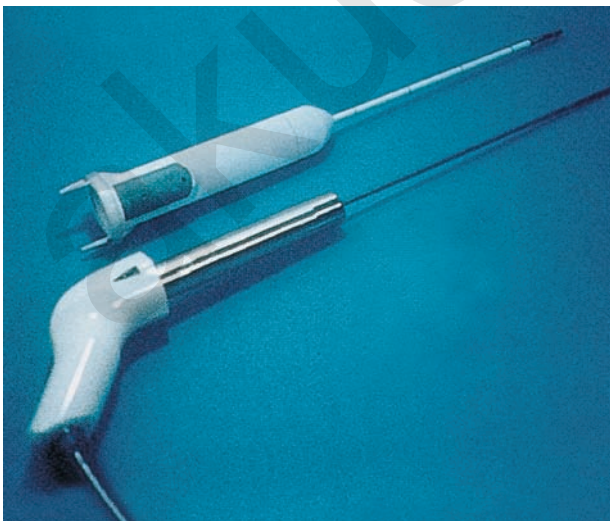


Figure 47.6 The Her Option™ cryoablation system (CryoGen, San Diego, CA, USA)




Figure 47.7 The NovaSure™ impedance-controlled electrocoagulation system (Novacept, Palo Alto, CA, USA)

The Her Option system requires a 6-mm cervical dilatation, and the duration of treatment is 10 minutes (first freeze 4 minutes, second freeze 6 minutes). Advantages of the system include portability, ease of performance, patient comfort and the use of ultrasound, which offers feedback and alleviates safety concerns. Disadvantages include the mandatory need for ultrasound and its required expertise, and endometrial prethinning. Up to May 2003, the FDA MAUDE database included five complications in five patients: one sepsis, one intensive-care unit admission, two uterine perforations and one uterine necrosis⁵¹.

Impedance-controlled endometrial electrocoagulation

The NovaSure™ system (Novacept, Palo Alto, CA, USA) consists of a single-use, three-dimensional bipolar ablation device and radiofrequency controller that enables controlled endometrial ablation in an average of 90 seconds (Figure 47.7). Endometrial prethinning of any kind (mechanical, pharmaceutical, timing) is not required. The patient can even be treated when actively bleeding. The NovaSure device consists of a conformable, bipolar, metalized, porous fabric mesh, mounted on an expandable frame. Integral to the hand-held device is the intrauterine measuring device to determine uterine cavity width (cornu-to-cornu distance). The unique geometry of the electrode controls and provides a shallower depth of myometrial desiccation in the cornual area and lower uterine segment, and a deeper ablation in the mid-body of the uterus. The NovaSure device can treat uteri with sounding lengths up to 12 cm, and an adjustable sheath accommodates and protects the cervix, thus reducing the possibility of burning the endocervical canal.

The NovaSure controller contains a constant-power output generator with a maximum power delivery of

180 W. Once the uterine cavity length is evaluated by sounding and the width is measured by the device, these values are entered into the controller, which automatically calculates the power output needed to assure an optimal confluent coagulation within the uterine cavity of a given size. The generator delivers 5.5 W/cm² power, and the total power delivered and duration of the procedure depend on the uterine cavity volume. Typical figures are 100 W of power over a 90-second treatment. The depth of ablation is controlled by continuous monitoring of tissue impedance (resistance) during the procedure. The ablation of the endometrial layer is a low-impedance process, due to a high level of conductive liquid present in the endometrial tissue. The endometrium is vaporized during the ablation and evacuated from the uterine cavity by suction. Once the myometrial layer is reached, tissue impedance (resistance) increases and quickly reaches 50 Ω (which is equivalent to the impedance of the ablated superficial myometrium), and the NovaSure system automatically terminates the ablation process. The ablation process is based not on temperature and time, but on specific, well-analyzed physical characteristics of the tissue.

The device is inserted transcervically into the uterine cavity; the sheath is retracted deploying a fan-shaped bipolar electrode, which conforms to the uterine cavity. Unlike the balloon concept of other devices, where pressure distends the uterine cavity, a vacuum is employed to assure good electrode–tissue contact. The vacuum pump is contained within the RF controller, and it is monitored and maintained within the uterine cavity throughout the procedure. Constant vacuum assures an intimate apposition between the electrode and the endomyometrium. Constant suction also removes blood, endometrium and vaporization by-products generated during the bipolar electrosurgical process.

A cavity integrity assessment system is an integral part of the NovaSure GEA system. It utilizes a hysteroflator-type technology. CO₂ is delivered into the uterine cavity at a safe flow rate and pressure. CO₂ pressure is monitored within the uterine cavity by the controller, sensing a maintained pressure over a known period of time. Once the proper pressure is maintained, confirming good uterine wall integrity, the controller proceeds with the ablation process in an automatic or semiautomatic mode.

Feasibility and effectiveness studies demonstrated that the NovaSure system required no endometrial prethinning⁹⁵. In a cohort study of 107 women with menorrhagia, the amenorrhea rate was 46% and 58% at 6 and 12 months, respectively⁹⁶. At 5 years of follow-up, 74% of evaluable women ($n=69$) reported amenorrhea, with 96% of patients reporting a reduction in bleeding to normal levels or less. Three patients (3/107) underwent hysterectomy and one patient (1/107) had a repeat ablation⁹⁷.

A multicenter RCT compared NovaSure ($n=175$) with TCRE combined with rollerball electrocoagulation ($n=90$). Treatment was performed at any time during the cycle, with no prethinning treatment in any group. One

year after treatment, 90% and 88%, respectively, reported normal bleeding or less, and 41% and 35%, respectively, experienced amenorrhea. Local and/or intravenous sedation was administered in 73% of NovaSure patients and 18% of rollerball patients. Intraoperative adverse events occurred less frequently with NovaSure (0.6%) than with the rollerball (6.7%). Postoperative adverse events occurred in 13% and 25.3% of patients, respectively⁹⁷.

The NovaSure device has also been compared in RCTs with the Cavaterm balloon for menorrhagia⁵⁹ and the ThermaChoice I for menorrhagia⁹⁹ and for immediate postoperative pain¹⁰⁰. Fifty-five women with menorrhagia were randomized (2:1) to NovaSure ($n=37$) and Cavaterm ($n=18$). At 12 months, the rate of amenorrhea was 43% vs. 11% and the satisfaction rate was 92% vs. 83% in the NovaSure and Cavaterm groups, respectively⁵⁹. The NovaSure device ($n=83$) has also been randomly compared with the ThermaChoice I ($n=43$). At 1 year, amenorrhea rates were 43% in the NovaSure group and 8% in the ThermaChoice group ($p<0.001$), while the satisfaction rate was 90% in the NovaSure group and 79% in the ThermaChoice I group ($p=0.003$)⁹⁹. Both methods, NovaSure and ThermaChoice, significantly improved health-related quality of life in the women, but there was no difference between the two groups¹⁰¹. In another RCT, the NovaSure system was also found to be associated with significantly lower intraoperative and postoperative pain than was the ThermaChoice I balloon¹⁰⁰.

Advantages of the NovaSure system include portability, ease of use, minimal analgesia requirements, short treatment and procedure time and minimal postoperative pain. Disadvantages include cervical dilatation to 9 mm and limitation of cavity size and shape. The FDA MAUDE database up to May 2003 included 11 complications in four patients treated with the NovaSure: two thermal bowel injuries, two endometritis, one sepsis, one intensive-care unit admission, two uterine perforations and three laparotomies⁵¹.

THIRD-GENERATION ENDOMETRIAL ABLATION TECHNOLOGIES

In 1869, Pantaleoni carried out the first hysteroscopy in a postmenopausal woman complaining of vaginal bleeding. He found a polyp and cauterized it with silver nitrate¹⁰². Since then, several chemical agents have been considered to destroy the endometrium in women with menorrhagia. The idea of injecting a gel or solution via a small-diameter catheter, to destroy the endometrium globally in an office setting, using no analgesia, is so attractive that several such agents are currently undergoing feasibility and safety evaluation.

Endometrial ablation with trichloroacetic acid

A recent publication described 90 women with menorrhagia treated with a 95% solution of trichloroacetic acid. Group one received an intrauterine instillation of trichloroacetic acid and group two received the same treatment after a single dose of a GnRH-a, 1 month before the procedure. After 12 months, the amenorrhea rates were 27% and 31% and the menstrual reduction rates to normal or less were 96% and 98%, respectively. No adverse events were reported¹⁰³. The findings of this study are very interesting and intriguing. However, further studies are indicated to validate the safety and efficacy of this treatment.

CONCLUSIONS

All SEATs are easier to use than the FEATs, and allow surgeons of varied hysteroscopic skills to treat a variety of women with menorrhagia. However, the ease of performance and simplicity of the device does not remove the need for adequate education and training.

Data on efficacy, durability and cost-effectiveness are accumulating rapidly. One study reviewed the clinical effectiveness and cost-effectiveness of two SEATs (MEA and thermal balloon endometrial ablation, TBEA) for AUB and compared them with the existing FEATs (TCRE, REA) and hysterectomy. The authors concluded that, overall, there were few significant differences between the outcomes of FEATs and SEATs including bleeding, satisfaction and quality of life measures and repeat surgery rates. Satisfaction with hysterectomy was initially higher, but there was no significant difference after 2 years. The economic model suggested that the SEATs were more cost-effective than the FEATs and hysterectomy¹⁰⁴.

Since the incidence of serious complications is low (approximately 1:1000), the overall safety will not be determined until several thousand procedures have been performed by each device. The estimated complication rates per 1000 procedures are 0.5 for the hot liquid balloons, 1 for HTA and cryoablation and 1.5 for NovaSure and MEA⁵¹. In choosing one of these devices, maximum safety should be the first criterion. An FDA MAUDE study from January 2003 to December 2004 reported 99 adverse events associated with hydrothermablation ($n=30$), NovaSure ($n=29$), ThermaChoice ($n=19$), MEA ($n=10$) and Her Option ($n=8$). A total of 34 were considered out of protocol: HTA ($n=12$), NovaSure ($n=12$), ThermaChoice ($n=4$), MEA ($n=6$) and Her Option ($n=0$)¹⁰⁵. Another FDA MAUDE study from January 1998 to April 2005 identified 186 injuries from all global ablation technologies. Primary injuries included: genital tract burns ($n=43$), bowel burns ($n=39$), uterine perforation ($n=33$), infection ($n=30$), uterine/cervical scarring ($n=19$), hemorrhage ($n=9$), ureteral burns ($n=1$), uterovaginal fistula ($n=1$) and other ($n=11$). Preoperative contraindications were present in 11 patients,

intraoperative protocol violations in 44 and technical errors in six. Cesarean-section scars were involved in four cases of thermal injury¹⁰⁶.

If safety and outcome measures are similar, the requirement for analgesia, the duration of treatment and associated costs may become of importance. All SEATs maximize patient convenience. A Cochrane review compared FEATs and SEATs. It concluded that the SEATs took less time to perform (11 minutes) and were more likely to be performed under local anesthesia (odds ratio 4.1, 95% confidence interval 1.1–15.0). The reduction in heavy bleeding did not differ significantly between any of the groups¹⁰⁷.

Since the endometrium is destroyed by all these devices, it is imperative that (pre-) malignant uterine disease be excluded.

Since all procedures are performed blindly (no hysteroscopic visualization), except hydrothermablation, it would be prudent to perform postdilatation hysteroscopy and immediately post-treatment hysteroscopy to ensure that only the intended endometrial cavity has been treated. False passages and partial or complete uterine perforations occur at a frequency of 0.8–1.5%, and may result in adjacent visceral injury.

Endometrial ablation was introduced as an alternative to hysterectomy to treat women with AUB of benign causes. Data from National Health Service hospitals in England from 1989 to 1996 indicated that rather than replacing hysterectomy in the treatment of AUB, endometrial ablation may have added an alternative operative technique¹⁰⁸. In the United States, the total hysterectomy rate decreased from 7.1 to 5.5 per 1000 women aged 15 or older from 1980 to 1999. However, endometrial ablation was not considered as one of the contributing factors to the decline^{109,110}. The hysterectomy rate in Canada was reduced by 33% from 1981 to 1996, with an additional decline of 19% from 1997 to 2003 (www.statcan.ca). The contribution of endometrial ablation to the decline of hysterectomy rates remains unclear, since the decline started before the introduction of endometrial ablation in the 1990s.

ACKNOWLEDGMENTS

I am indebted to Mrs Denise Dafoe for preparing this manuscript.

REFERENCES

1. Vilos GA, Lefebvre G, Graves G. Guidelines for the management of abnormal uterine bleeding. Society of Obstetricians and Gynecologists of Canada Clinical Practice Guideline No. 106. *J Obstet Gynecol Can* 2001; 23: 704–9

2. Garry R, for the Endometrial Ablation Group. Evidence and Techniques on Endometrial Ablation: A Consensus Meeting. Middlesbrough, UK. December 7–8, 2000. *Gynecol Endosc* 2002; 11: 5–17
3. Vilos GA. Hysteroscopic and nonhysteroscopic endometrial ablation [Review]. *Obstet Gynecol Clin North Am* 2004; 31: 687–704
4. Bachmann GA. Hysterectomy. A critical review. *J Reprod Med* 1990; 35: 839–62
5. Carlson KJ, Nichols DH, Schiff I. Indications for hysterectomy. *N Engl J Med* 1993; 83: 792–6
6. Vilos GA. Intrauterine pregnancy following rollerball endometrial ablation. *J Soc Obstet Gynecol Can* 1995; 17: 479–80
7. American College of Obstetricians and Gynecologists Technical Bulletin, February 1990
8. Brooks PG, Serden SP, Davos I. Hormonal inhibition of the endometrium for resectoscopic endometrial ablation. *Am J Obstet Gynecol* 1991; 164: 1601–8
9. Garry R, Khaur A, Mooney P, Stuart M. A comparison of goserelin and danazol as endometrial thinning agents prior to endometrial laser ablation. *Br J Obstet Gynaecol* 1996; 103: 339–44
10. Donnez J, Vilos GA, Gannon MJ, et al. Goserelin (Zoladex) plus endometrial ablation for dysfunctional uterine bleeding. A large randomized double-blind clinical trial. *Fertil Steril* 1997; 68: 29–36
11. Donnez J, Vilos GA, Gannon MJ, et al. Goserelin acetate (Zoladex) plus endometrial ablation for dysfunctional uterine bleeding (DUB): 3-year follow-up. *Fertil Steril* 2001; 75: 620–2
12. Vercellini P, Perino A, Consonni R, et al. Treatment with a gonadotrophin releasing hormone agonist before endometrial resection: a multicentre, randomised controlled trial. *Br J Obstet Gynaecol* 1996; 103: 562–8
13. Vercellini P, Perino A, Consonni R, et al. Does preoperative treatment with a gonadotropin-releasing hormone agonist improve the outcome of endometrial resection? *J Am Assoc Gynecol Laparosc* 1998; 5: 357–60
14. Sowter MC, Lethaby A, Singla AA. Pre-operative endometrial thinning agents before endometrial destruction for heavy menstrual bleeding. *Cochrane Database Syst Rev* 2002; (3): D001124
15. Goldrath MH, Fuller TA, Segal S. Laser photocoagulation of the endometrium for the treatment of menorrhagia. *Am J Obstet Gynecol* 1981; 140: 14–19
16. Loffer FD. Hysteroscopic endometrial ablation with the Nd : YAG laser using a nontouch technique. *Obstet Gynecol* 1987; 69: 679–82
17. Overton C, Hargreaves J, Maresh M. A national survey of the complications of endometrial destruction of menstrual disorders: the MISTLETOE study. *Br J Obstet Gynaecol* 1997; 104: 1351–9
18. DeCherney A, Polan ML. Hysteroscopic management of intrauterine lesions and intractable uterine bleeding. *Obstet Gynecol* 1983; 61: 392–6
19. Lin BL, Mipamoto M, Tomomatsu M, et al. The development of a new hysteroscopic resectoscope

- and its clinical application on transcervical resection (TCR) and endometrial ablation (EA). *Jpn J Gynecol Obstet Endosc* 1988; 4: 56–61
20. Perino A, Cittadini E, Colacurci N, et al. Endometrial ablation: principles and technique. *Acta Eur Fertil* 1990; 21: 313–17
 21. Farrell SA, Baskett TF. Endometrial ablation for dysfunctional uterine bleeding. *J Soc Obstet Gynecol Can* 1992; 14: 31–41
 22. Martyn P. Endometrial ablation: long-term outcome. *J Soc Obstet Gynecol Can* 2000; 22: 423–7
 23. Vilos GA, Pispidikis JT, Botz CK. Economic evaluation of hysteroscopic endometrial ablation versus vaginal hysterectomy for menorrhagia. *Obstet Gynecol* 1996; 88: 241–5
 24. Raders J, Vilos GA. Dispersive pad injuries associated with hysteroscopic surgery. *J Am Assoc Gynecol Laparosc* 1999; 6: 363–6
 25. Vilos GA, Brown S, Graham G, et al. Genital tract electrical burns during hysteroscopic endometrial ablation: report of 13 cases in United States and Canada. *J Am Assoc Gynecol Laparosc* 2000; 7: 141–7
 26. Vilos GA, McCulloch S, Borg P, et al. Intended and stray radiofrequency electrical currents during resectoscopic surgery. *J Am Assoc Gynecol Laparosc* 2000; 7: 55–63
 27. Cooper JM, Erickson ML. Global endometrial ablation technologies. *Obstet Gynecol Clin North Am* 2000; 27: 385–96
 28. Neuwirth RS, Duran M, Singer A, et al. The endometrial ablator: a new instrument. *Obstet Gynecol* 1994; 83: 792–6
 29. Singer A, Almanza R, Gutierrez A, et al. Preliminary clinical experience with a thermal balloon endometrial ablation method to treat menorrhagia. *Obstet Gynecol* 1994; 83: 732–4
 30. Vilos GA, Vilos EC, Pendley L. Endometrial ablation with a thermal balloon for the treatment of menorrhagia. *J Am Assoc Gynecol Laparosc* 1996; 3: 383–7
 31. Vilos GA, Fortin CA, Sanders B, et al. Clinical trial of the uterine thermal balloon for treatment of menorrhagia. *J Am Assoc Gynecol Laparosc* 1997; 4: 559–65
 32. Amso NN, Stabinsky SA, McFaul P, et al. Uterine thermal balloon therapy for the treatment of menorrhagia: the first 300 patients from a multicentre study. *Br J Obstet Gynaecol* 1998; 105: 517–23
 33. Meyer WR, Walsh BW, Grainger DA, et al. Thermal balloon and rollerball ablation to treat menorrhagia: a multicenter comparison. *Obstet Gynecol* 1998; 92: 98–103
 34. Grainger DA, Tjaden BL, Meyer WR, et al. Thermal balloon and rollerball ablation to treat menorrhagia: two-year results from a multicenter prospective randomized clinical trial. *J Am Assoc Gynecol Laparosc* 2000; 7: 175–9
 35. Loffer FD, Grainger D. Five-year follow-up of patients participating in a randomized trial of uterine balloon therapy versus rollerball ablation for treatment of menorrhagia. *J Am Assoc Gynecol Laparosc* 2002; 9: 429–35
 36. Amso NN, Fernandez H, Vilos GA, et al. Uterine endometrial thermal balloon therapy for the treatment of menorrhagia: long-term multicenter follow-up study. *Hum Reprod* 2003; 18: 1082–7
 37. Yackel DB. Menorrhagia treated by thermal balloon endometrial ablation. *J Soc Obstet Gynecol Can* 1999; 21: 1076–80
 38. Lissak A, Fruchter O, Mashlach S, et al. Immediate versus delayed treatment of perimenopausal bleeding due to benign causes by balloon thermal ablation. *J Am Assoc Gynecol Laparosc* 1999; 6: 145–50
 39. Aletebi FA, Vilos GA, Eskandar MA. Thermal balloon endometrial ablation to treat menorrhagia in high risk surgical candidates. *J Am Assoc Gynecol Laparosc* 1999; 6: 435–9
 40. Vilos GA, Aletebi FA, Eskandar MA. Endometrial thermal balloon ablation with a (ThermaChoice) system to treat menorrhagia: effect of intrauterine pressure and duration of treatment. *J Am Assoc Gynecol Laparosc* 2000; 7: 325–9
 41. Fernandez H, Capella S, Audibert F. Uterine thermal balloon therapy under local anesthesia for the treatment of menorrhagia. *Hum Reprod* 1997; 12: 2511–14
 42. Andersen LF, Meinert L, Rygaard C, et al. Thermal balloon endometrial ablation: safety aspects evaluated by serosal temperature, light microscopy and electron microscopy. *Eur J Obstet Gynecol Reprod Biol* 1998; 79: 63–8
 43. Shah AA, Stabinsky SA, Klusak T, et al. Measurement of serosal temperatures and depth of thermal injury generated by thermal balloon endometrial ablation in ex vivo and in vivo models. *Fertil Steril* 1998; 70: 692–7
 44. London R, Holzman M, Rubin D, Moffitt B. Payer cost savings with endometrial ablation therapy. *Am J Managed Care* 1999; 5: 889–97
 45. Vilos GA. Hot water balloon endometrial ablation. In *Proceedings of the International Symposium on Diagnostic and Operative Hysteroscopy*, February 25–27, Miami, Florida, 2000: 106–7
 46. Buckshee K, Barnerjee K, Bhatla H. Uterine balloon therapy to treat menorrhagia. *Int J Gynecol Obstet* 1998; 63: 139–43
 47. Luerti M, Garuti G. Endometrial ablation with the uterine balloon therapy system. A new therapeutic option for menorrhagia. *Ital J Gynecol Obstet* 1996; 8: 153–6
 48. Gervaise A, Fernandez H, Capella-Allouc S, et al. Thermal balloon ablation versus endometrial resection for the treatment of abnormal uterine bleeding. *Hum Reprod* 1999; 14: 2743–7
 49. Soysal ME, Soysal SK, Vicdan K. Thermal balloon ablation in myoma-induced menorrhagia under local anesthesia. *Gynecol Obstet Invest* 2001; 51: 128–33
 50. Vilos GA, Vilos EC. A randomized comparison of goserelin versus suction curettage prior to ThermaChoice II balloon ablation [Abstract]. *J Obstet Gynecol Can* 2002; 24: 656
 51. Gurtcheff SE, Sharp HT. Complications associated with global endometrial ablation: the ability of the

- MAUDE database. *Obstet Gynecol* 2003; 102: 1278–82
52. Friberg B, Wallsten H, Henriksson P, Persson BRR. A new, simple, safe and efficient device for the treatment of menorrhagia. *J Gynecol Tech* 1996; 2: 103–8
 53. Persson BRR, Friberg B, Olsrud J, et al. Numerical calculations of temperature distribution resulting from intracavitary heating of the uterus. *Gynecol Endosc* 1998; 7: 203–9
 54. Hawe JA, Phillips AG, Chien PE, et al. Cavaterm thermal balloon ablation for the treatment of menorrhagia. *Br J Obstet Gynaecol* 1999; 106: 1143–4
 55. Friberg B, Ahlgren M. Thermal balloon endometrial destruction: the outcome of treatment of 117 women followed up for a maximum period of 4 years. *Gynecol Endosc* 2000; 9: 389–95
 56. Mettler L. Long-term results in the treatment of menorrhagia and hypermenorrhea with a thermal balloon endometrial ablation technique. *J Soc Laparosc Surg* 2002; 6: 305–9
 57. Pellicano M, Guida M, Acunzo G, et al. Hysteroscopic transcervical endometrial resection versus thermal destruction for menorrhagia: a prospective randomized trial on satisfaction rate. *Am J Obstet Gynecol* 2002; 187: 545–50
 58. Howe J, Abbott J, Hunter D, et al. A randomized controlled trial comparing the Cavaterm endometrial ablation system with the Nd : YAG laser for the treatment of dysfunctional uterine bleeding. *Br J Obstet Gynaecol* 2003; 110: 350–7
 59. Abbott J, Howe J, Hunter D, et al. A double-blind randomized trial comparing the Cavaterm and the NovaSure endometrial ablation system for the treatment of dysfunctional uterine bleeding. *Fertil Steril* 2003; 80: 203–8
 60. Cavaterm system. Wallsten Medical, Kvisgaard, Denmark. Available at www.wallstenmedical.com
 61. Mangeshkar PS, Kopur A, Yackel D. Endometrial ablation with a new thermal balloon system. *J Am Assoc Gynecol Laparosc* 2003; 10: 27–32
 62. Thomas JA, Leyland N, Durand N, Windrich RC. The use of oral misoprostol as a cervical ripening agent in operative hysteroscopy: a double-blind, placebo-controlled trial. *Am J Obstet Gynecol* 2002; 186: 876–9
 63. Darwish AM, Ahmad AM, Mohammad AM. Cervical priming prior to operative hysteroscopy: a randomized comparison of laminaria versus misoprostol. *Hum Reprod* 2004; 19: 2391–4
 64. Vilos GA. Endometrial ablation with a new balloon system (Thermablate EAS) to treat menorrhagia in high-risk surgical candidates. *J Am Assoc Gynecol Laparosc* 2003; 10: S36
 65. Yackel D, Vilos GA. Thermablate EAS: a new endometrial ablation system. *Gynecol Surg* 2004; 1: 129–32
 66. Vilos GA, Abu-Rafea B, Haque A. Endometrial thermablation: a two minute balloon treatment. Presented at the 7th World Congress on Controversies in Obstetrics and Gynecology and Infertility, Athens, Greece, April, 2005
 67. Goldrath MH, Barrionuevo M, Husain M. Endometrial ablation with hysteroscopic instillation of hot saline solution. *J Am Assoc Gynecol Laparosc* 1997; 4: 235–40
 68. Richart RM, Botacini das Dores G, Nicolau SM, et al. Histologic studies of the effects of circulating hot saline on the uterus before hysterectomy. *J Am Assoc Gynecol Laparosc* 1999; 6: 269–73
 69. Bustos-Lopez HH, Baggish M, Valle RF, et al. Assessment of the safety of intrauterine instillation of heated saline for endometrial ablation. *Fertil Steril* 1998; 69: 155–60
 70. Corson SL. A multicentre evaluation of endometrial ablation by HydroThermAblator and rollerball for treatment of menorrhagia. *J Am Assoc Gynecol Laparosc* 2001; 8: 359–67
 71. Goldrath MH. Evaluation of HydroThermAblator and roller endometrial ablation for menorrhagia 3 years after treatment. *J Am Assoc Gynecol Laparosc* 2003; 10: 505–11
 72. Glasser MH, Zimmerman JD. The HydroThermAblator system for management of menorrhagia in women with submucous myomas: 12-to-20-month follow-up. *J Am Assoc Gynecol Laparosc* 2003; 10: 521–7
 73. Rosenbaum SP, Fried M, Munro MG. Endometrial hydrothermablation: a comparison of short-term clinical effectiveness in patients with normal endometrial cavities and those with intracavitary pathology. *J Am Assoc Gynecol Laparosc* 2005; 12: 144–9
 74. Vilos GA, Harding PG, Sugimoto A, et al. Hysteroscopic endomyometrial resection of three uterine sarcomas. *J Am Assoc Gynecol Laparosc* 2001; 8: 545–51
 75. Vilos GA, Ettler H. Atypical polypoid adenomyoma and hysteroscopic endometrial ablation. *J Obstet Gynecol Can* 2003; 25: 760–2
 76. Sharp NC, Cronin N, Feldberg I, et al. Microwave for menorrhagia: a new fast technique for endometrial ablation. *Lancet* 1995; 346: 1003–4
 77. Wallage S, Cooper KG, Graham WJ, Parkin DE. A randomized trial comparing local versus general anaesthesia for microwave endometrial ablation. *Br J Obstet Gynaecol* 2003; 110: 799–807
 78. Cooper KG, Bain C, Parkin D. Comparison of microwave endometrial ablation and transcervical resection of the endometrium for treatment of heavy menstrual loss: a randomized trial. *Lancet* 1999; 354: 1859–63
 79. Bain C, Cooper KG, Parkin DE. Microwave endometrial ablation versus endometrial resection: a randomized controlled trial. *Obstet Gynecol* 2002; 99: 983–7
 80. Cooper TM, Anderson TL, Fortin CA, et al. Microwave endometrial ablation vs. rollerball electroablation for menorrhagia: a multicenter randomized trial. *J Am Assoc Gynecol Laparosc* 2004; 11: 354–403
 81. Harris M, Anderson TL, Fortin C, et al. Microwave endometrial ablation: three year outcomes of a

- multicenter trial [Abstract]. *J Minim Invasive Gynecol* 2005; 12 (Suppl 1): 8
82. Downes E, Cooper K, O'Donovan P, Sharp N. Microwave endometrial ablation is a safe technique [Abstract]. *J Am Assoc Gynecol Laparosc* 2000; 7: S13
 83. Cahan WG, Brockunier A. Cryosurgery of the uterine cavity. *Am J Obstet Gynecol* 1967; 99: 138-53
 84. Droegemueller W, Greer BE, Makowski EL. Preliminary observations of cryoablation of the endometrium. *Am J Obstet Gynecol* 1970; 107: 958-61
 85. Droegemueller W, Greer B, Makowski E. Cryosurgery in patients with dysfunctional uterine bleeding. *Obstet Gynecol* 1971; 38: 256-8
 86. Droegemueller W, Makowski E, MacSalka R. Destruction of the endometrium by cryosurgery. *Am J Obstet Gynecol* 1971; 110: 467-9
 87. Pittrof R, Majid S, Murray A. Initial experience with transcervical cryoablation of the endometrium using saline as a uterine distension medium. *Minim Invasive Ther* 1993; 2: 69-73
 88. Pittrof R, Majid S, Murray A. Transcervical endometrial cryoablation (ECA) for menorrhagia. *Int J Gynecol Obstet* 1994; 47: 135-9
 89. Rutherford TJ, Zreik TG, Troiana RN, et al. Endometrial cryoablation, a minimally invasive procedure for abnormal uterine bleeding (pilot study). *J Am Assoc Gynecol Laparosc* 1998; 5: 23-8
 90. Dobak JD, Willems J, Howard R, et al. Endometrial cryoablation with ultrasound visualized in women undergoing hysterectomy. *J Am Assoc Gynecol Laparosc* 2000; 7: 89-93
 91. Dobak JD, Willems J. Extripated uterine endometrial cryoablation with ultrasound visualization. *J Am Assoc Gynecol Laparosc* 2000; 7: 95-101
 92. Dobak JD, Ryba E, Kovalcheck S. A new closed-loop cryosurgical device for endometrial ablation. *J Am Assoc Gynecol Laparosc* 2000; 7: 245-9
 93. Duleba AJ, Heppard MC, Soderstrom RM, Townsend DE. A randomized study comparing cryoablation and rollerball electroablation for treatment of dysfunctional uterine bleeding. *J Am Assoc Gynecol Laparosc* 2003; 10: 17-26
 94. Townsend DE, Duleba AJ, Wilkes MM. Durability of treatment effects after endometrial cryoablation versus rollerball electroablation for abnormal uterine bleeding: two-year results of a multicenter randomized trial. *Am J Obstet Gynecol* 2003; 188: 699-701
 95. Cooper J, Brill A, Fullop T. Is endometrial pre-treatment necessary in NovaSure 3-D endometrial ablation? *Gynecol Endosc* 2001; 10: 179-92
 96. Gallinat A, Nugent W. NovaSure impedance-controlled system for endometrial ablation. *J Am Assoc Gynecol Laparosc* 2002; 9: 279-85
 97. Rudowsky R, Gallinat A. NovaSure impedance controlled endometrial ablation system, long-term follow-up results in 107 patients [Abstract]. *J Minim Invasive Gynecol* 2005; 12 (Suppl 1): 76-7
 98. Cooper J, Gimpelson R, Laberge P, et al. A randomized multicentre trial of safety and efficacy of the NovaSure system in the treatment of menorrhagia. *J Am Assoc Gynecol Laparosc* 2002; 9: 418-28
 99. Bongers MY, Bourdrez P, Mol BW, et al. Randomized controlled trial of bipolar radiofrequency endometrial ablation and balloon endometrial ablation. *Br J Obstet Gynaecol* 2004; 111: 1095-102
 100. Laberge PY, Sabbah R, Fortin C, Gallinat A. Assessment and comparison of intraoperative and postoperative pain associated with NovaSure and ThermoChoice endometrial ablation systems. *J Am Assoc Gynecol Laparosc* 2003; 10: 223-32
 101. Bongers MY, Bourdrez P, Heintz PM, et al. Bipolar radiofrequency endometrial ablation compared with balloon endometrial ablation in dysfunctional uterine bleeding: impact on patients' health-related quality of life. *Fertil Steril* 2005; 83: 724-34
 102. Pantaleoni D. On endoscopic examination of the cavity of the womb. *Med Press Circ* 1969; 8: 26
 103. Kucuk M, Okman TK. Intrauterine instillation of trichloroacetic acid is effective for the treatment of dysfunctional uterine bleeding. *Fertil Steril* 2005; 83: 189-94
 104. Garside R, Stein K, Wyatt K, et al. The effectiveness and cost-effectiveness of microwave and thermal balloon endometrial ablation for heavy menstrual bleeding: a systematic review and economic modeling. *Health Technol Assess* 2004; 8: 1-155
 105. Della Badia C, Atogho A. Serious adverse events associated with the use of endometrial ablation devices [Abstract]. *J Minim Invasive Gynecol* 2005; 12 (Suppl 1): 15
 106. Sharp H, Jardine G. Global endometrial ablation in 196 patients and associated risk factors [Abstract]. *J Min Inv Gynecol* 2005; 12 (Suppl 1): 8-9
 107. Lethaby A, Hickey M, Garry R. Endometrial destruction techniques for heavy menstrual bleeding. *Cochrane Database Syst Rev* 2005; (4): CD001501
 108. Bridgman SA, Dunn KM. Has endometrial ablation replaced hysterectomy for the treatment of dysfunctional uterine bleeding? National figures. *Br J Obstet Gynaecol* 2000; 107: 531-4
 109. Lepine LA, Hillis SD, Marchbanks PA, et al. Hysterectomy Surveillance - United States, 1980-1993. *MMWR Morb Mortal Wkly Rep* 1997; 46: 1-15
 110. Keshavarz H, Hillis S, Kieke B, et al. Hysterectomy Surveillance - United States, 1994-1999. *MMWR Morb Mortal Wkly Rep* 2002; 51: 1-8

akusher-lib.ru

Tubal sterilization

B J van Herendael

INTRODUCTION

Prior to the introduction of laparoscopy, hysterectomy had been the main operation to stop fertility. The great majority of patients do not want to take medication throughout their fertile lives. Laparoscopy has changed this for the better as the technique can be performed under local anesthesia. However, there are many drawbacks associated with this technique, mainly technical, but also cost.

All of these laparoscopic techniques are valid, but some are more difficult to perform than others, and there is a substantial risk for patients with some of the techniques. The main drawback is the opening of the abdominal cavity. Even if the entry points are very small, the risk of entering large vessels, the aorta and the iliac vessels, both artery and vein, and the viscus are real and do not reflect the expertise of the operator.

Safer methods of definitive sterilization were sought. A first attempt by the World Health Organization to find a successful sterilization technique was the blind injection into the uterine cavity of caustic substances on a base of histoacrylates, or quinacrine¹. Although easy to apply, total occlusion occurred only in some 30% at a first attempt, too low a percentage to be applied in developing countries. Recanalization was a problem, even after long periods of time.

Since the advent of hysteroscopy, many hysteroscopic sterilization techniques have been tried (Table 48.1). Most

had to be abandoned due either to their unreliability or to their cost. Recently, major progress has been made.

In hysteroscopy², there were early experiments by Lindemann with unipolar coagulation of the intramural part of the tube. The main problem was recanalization, even after many years, in one case after 15 years, followed by pregnancy. The same applied to all other attempts to destroy the intramural part of the tube, even major destruction with the neodymium : yttrium–aluminum–garnet (ND : YAG) laser³. The intramural part of the tube seems to have an extraordinary capacity to regenerate itself. These techniques all required general anesthesia.

As destruction techniques from outside the tube seemed to fail, many systems were created to block the tube from within. We went in search of a method which could be used in an out-patient set-up, with, or even preferably without, anesthesia.

Most attempts to obstruct the tubal lumen completely have failed. Jan Brundin⁴, now the Medical Director of the Karolinska Institute in Sweden, developed a hygroscopic element, about 1.5 cm in length, with a memory of how far to swell once in contact with liquid. However, the P block was ejected in over 80% of cases.

The author has placed 20 P blocks, of which only four remained in place and not one patient had a bilateral occlusion (unpublished results).

Systems that remain in the lumen without occluding it, i.e. the silicone plugs of Erb, are successful but take too long to be positioned, on average 40 min, and are too costly⁵.

Therefore, we went in search of techniques that were easier to apply, that could be performed in less than 20 min, without local anesthesia. We had to develop small barrel scopes, less than 5 mm, with a working channel that accommodates 5 F instruments or a guiding wire.

The first of the fine systems, the Hamou plug, a nylon thread that anchored into the intramural area, was very effective⁶ but was not passed by the Food and Drug Administration and was, therefore, abandoned. The technique for insertion is shown in Figures 48.1–48.6.

The author has inserted 30 Hamou devices. Insertion was carried out in an office setting without any form of anesthesia, not even a local injection into the cervix. The Storz 'chorionoscope' (Storz, Tutlingen, Germany) was used according to Perino. The outer diameter of this hysteroscope is oval and is 3.8 mm. After 11 years of follow-up, we have had two pregnancies, both due to the fact that the device was not placed correctly into the tubal

Table 48.1 Sterilization techniques by laparoscopy and hysteroscopy

<i>Laparoscopy</i>	
Unipolar	Palmer technique
Bipolar	The Kleppinger bipolar forceps
Endotherm coagulation	Semms technique
Tubal occluding rings	The Yoon ring
Tubal occluding clips	The Hulka Clemens clip The Filshie clip
<i>Hysteroscopy</i>	
P block	J Brundin
Silicone plug	RA Erb
Hamou plug	J Hamou
STOP® device	Conceptus San Carlos, CA, USA




Figure 48.1 The original Hamou plug: a blue nylon device that was anchored into the intramural part of the tube. It had to be pushed in for at least five markers. The preformed arrow tip retained the plug in the intramural part of the tube

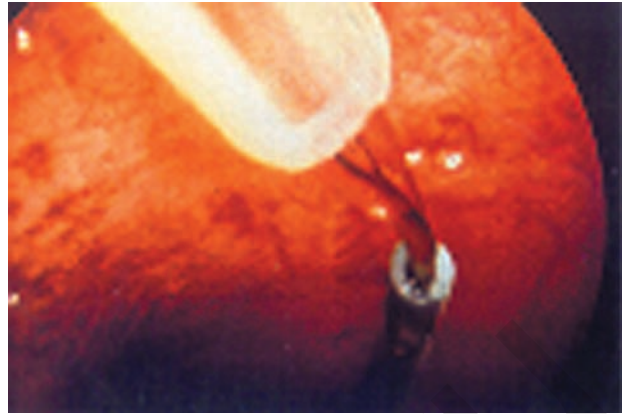


Figure 48.4 The guiding catheter is then withdrawn and the Hamou device is left in the tubal ostium, but a large part of it resides in the uterine cavity

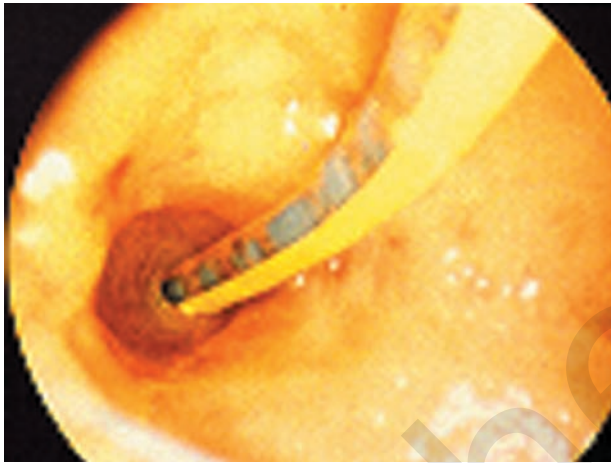


Figure 48.2 The guide catheter is seen at the tubal ostium, with the device inside




Figure 48.5 Correct placement of a Hamou device in the ostium of the tube

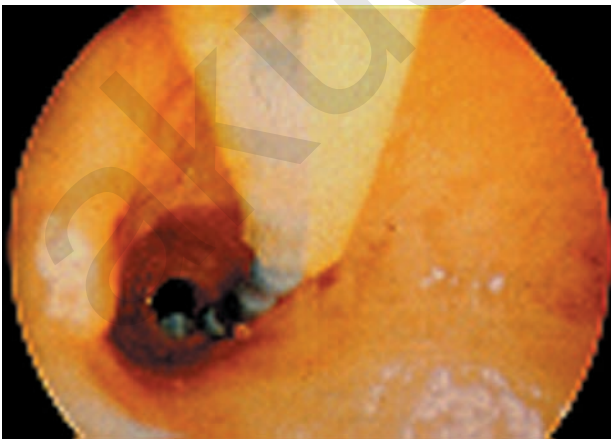


Figure 48.3 The device is now pushed about 2 cm into the intramural part of the tube by an occluding catheter within the first one, placed behind the device. The device is loaded into the guiding catheter from the front



Figure 48.6 As the thread is made of nylon, it is easily seen with classical vaginal ultrasound as a white element in the intramural space, where normally nothing catches the eye

ostium. The devices, however, collect calcium crystals on the stem, as do intrauterine contraceptive devices, because more than half of their actual length remains in the cavity. The weight of these crystals causes the devices to break. The critical period seems to be 9 years. Because the devices inflict wounds to the intramural tubal epithelium, there is permanent occlusion caused by the in-growth of fibroblasts into the adhesions. For this reason, this form of intratubal device cannot be advocated as a reversible method of sterilization.

More recently, the STOP® (Conceptus, San Carlos, CA, USA) system has appeared promising. Both the latter systems inflict small wounds on the tubal lumen so that a tissue reaction is engendered and its own cells, growing over the systems, obstruct the tubal lumen and occlude the tube permanently.

We use the Storz minihysteroscope (Storz), according to Bettocchi, and the Storz Endomat®, according to Hamou. The pump system is used with normal saline solution and the pressure does not exceed 50 mmHg when we work inside the uterus, thus avoiding cramping. The vaginoscopic technique, according to Bettocchi, is used. This means that we do not use a tenaculum to grasp the cervix. The pump is set to the maximal flow of 400 ml/min at a pressure of 100 mmHg, and the vagina is used as a first chamber. The cervix is localized and the scope is slipped into the cervical canal. The insertion technique is shown in Figures 48.7–48.13.

Because of the small part of the device protruding into the cavity, there is no interference with the endometrium and the menstrual pattern is not altered. The average insertion time is 9 min, if the intramural part of the tube is

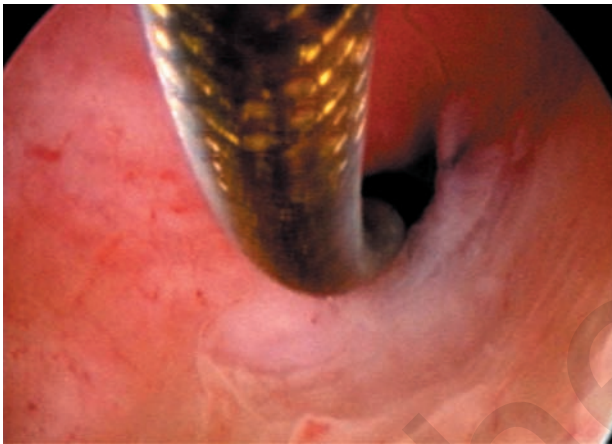


Figure 48.7 The STOP system: the guide wire carrying the device is inserted into the tubal ostium. Gentle pressure is used so as not to cause contractions

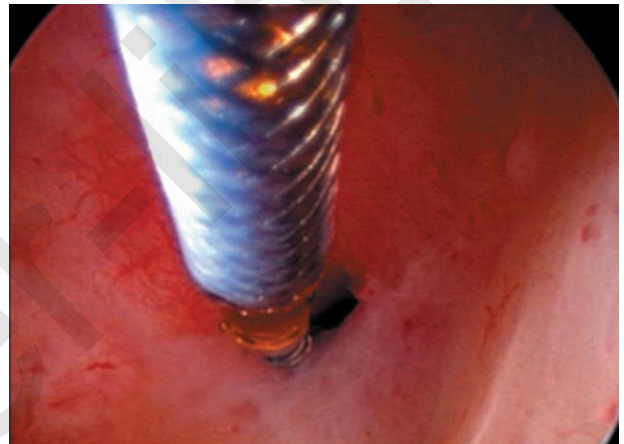


Figure 48.9 The STOP system: the outer catheter is removed until the wheel is blocked. At this time, the device is still not deployed and small adjustments can be made. Care is taken that the gold-colored indicator is approximately 1.5 cm from the tubal ostium

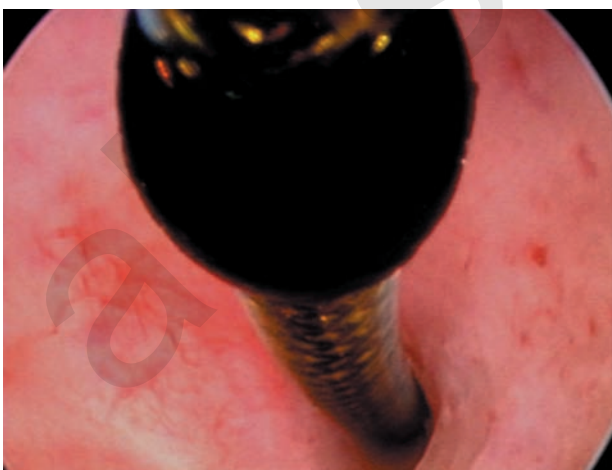


Figure 48.8 The STOP system: once the black 'stopper' is at the level of the tubal ostium, the wheel on the outside of the body is turned clockwise to deliver the device. The catheter is seen to come towards the end of the hysteroscope

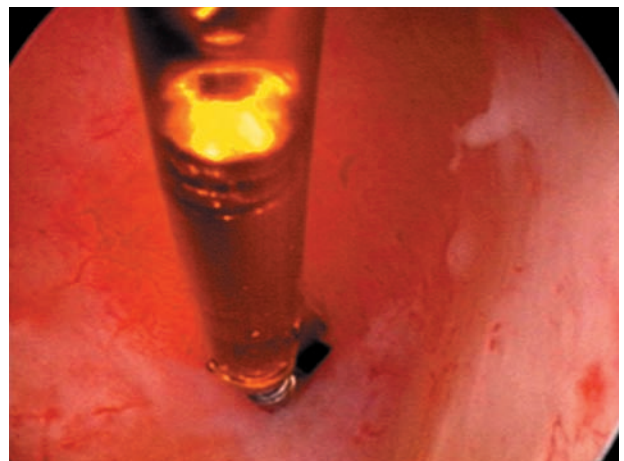


Figure 48.10 The STOP system: a closer view of the final stage before releasing the device so that it can be deployed in the intramural part of the tube

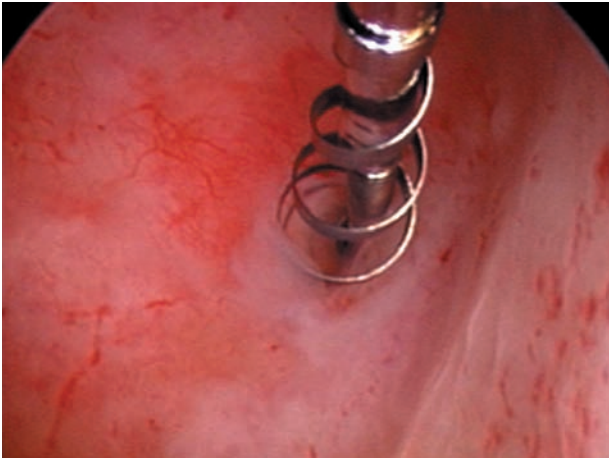


Figure 48.11 The STOP system: by turning the outside wheel counterclockwise, the device is now deployed so that it anchors itself in the intramural part of the tube

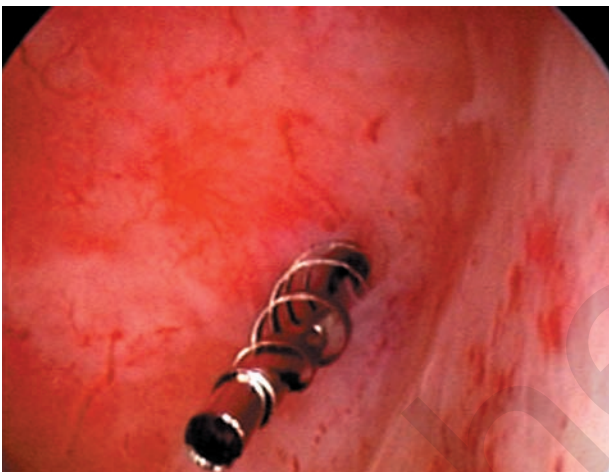

Figure 48.12 The STOP system: the device is now in place, the longer portion being left in the intramural part of the tube while the shorter part (approximately 1.5–2 cm) remains in the uterine cavity

patent and of normal anatomic configuration. Bilateral placement at first attempt is around 85%. A second attempt brings the bilateral placement up to 92%. Over 800 women with a follow-up of more than 5 years have shown only one pregnancy, due to device malfunction. The fibers on the device causes a tissue reaction, which produces permanent occlusion of the intramural part of the tube.

In conclusion, we can state that a new era has begun as far as definitive contraception is concerned. Hysteroscopic placement, using thin-barrelled hysteroscopes, of small

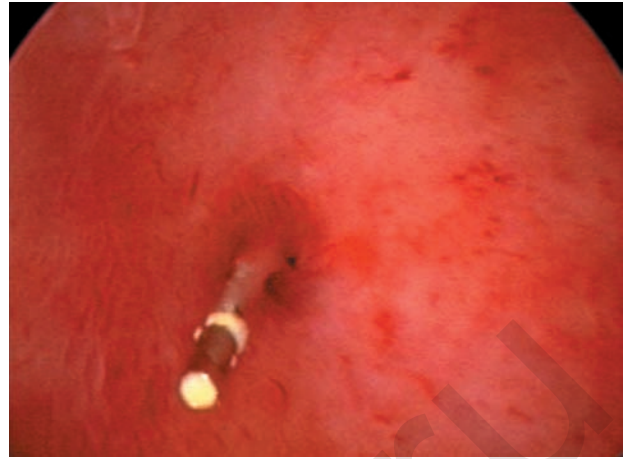


Figure 48.13 The STOP system: the right side of the same patient where a device had been installed exactly 1 month before. Because of an allergic reaction, the procedure had to be stopped at that time. Note the in-growths of the tissues at the tubal ostium and around the device blocking the intramural part of the tube

devices, causing occlusion of the intramural part of the tube, are the future of sterilization; the drawbacks are the difficulties of the hysteroscopic technique and the costs of the devices.

REFERENCES

1. Sokal DC, Zipper J, King T. Transcervical quinacrine sterilization: clinical experience. *Int J Gynecol Obstet* 1995; 51 (Suppl 1): S57–69
2. Sciarra JJ, Keith L. Hysteroscopic sterilization. *Obstet Gynecol Clin North Am* 1995; 22: 581–9
3. Donnez J, Malvaux V, Nisolle M, et al. Hysteroscopic sterilization. In Donnez J, Nisolle M, eds. *An Atlas of Laser Operative Laparoscopy and Hysteroscopy*. Carnforth, UK: Parthenon Publishing, 1994: 337–41
4. Brundin J. Hydrogel tubal blocking device: P-block. In Zatuchni GI, Shelton JD, Goldsmith A, eds. *Female Transcervical Sterilization*. Philadelphia: Harper & Row Publishers, 1983: 240
5. Ligt-Veneman NG, Tinga DJ, Kragt H, et al. The efficacy of intratubal silicone in the Ovabloc hysteroscopic method of sterilization. *Acta Obstet Gynecol Scand* 1999; 78: 824–5
6. Hamou J, Gasparri F, Scarselli GF, et al. Hysteroscopic reversible tubal sterilization. *Acta Eur Fertil* 1984; 15: 123

Complications of hysteroscopic surgery in gynecology

P Jadoul, J Donnez

INTRODUCTION

Hysteroscopic surgery has developed from a diagnostic tool into an effective surgical technique. It is now a standard investigational and therapeutic tool in gynecology, which, when implemented properly for the right indications in patients with no contraindications, has practically no complications. In retrospective studies, complication rates of 0.95–13.6% have been reported^{1–4}.

A members' survey of the American Association of Gynecologic Laparoscopists reported 17 298 operative hysteroscopies, with a complication rate of 3.8%¹. Pasini and Belloni³ reported 95 complications in a series of 697 operative hysteroscopies (13.6%), while Propst *et al.*³ encountered 25 complications in 925 procedures (2.7%).

A more recent study by Agostini *et al.*⁴ revealed a 3.5% complication rate (74/2116). In a prospective study conducted in The Netherlands in 1997, the complication rate among 2515 operative hysteroscopic procedures was just 0.95%⁵. Table 49.1 summarizes the published complication rates in prospective and retrospective studies. The wide variation is attributed to the varying experience of the gynecologists^{2,5} and the range of pathologies treated.

In Pasini and Belloni's series², complication rates decreased progressively due to more extensive training and experience of the surgeons.

Complication risks increase when hysteroscopy is performed for the treatment of intrauterine synechiae^{4,5}, intrauterine myomas^{2,3} and repeat endometrial resections¹⁵. Although complications are infrequent, their description helps us to understand their causes and thus take the necessary steps to avoid them. There are six groups of complications of operative hysteroscopy:

- Traumatic complications
- Hemorrhagic complications
- Distension medium complications
- Infection
- Thermal surgery damage
- Late complications

Less frequent complications, such as rupture of the tubes, rupture of the diaphragm leading to the patient's death, rupture of the uterine wall and trauma to pelvic vessels, have been reported.

Table 49.1 Reported complications of operative hysteroscopic procedures

Author(s)	Year	n	Perforation (%)	Bleeding (%)	Fluid (%)	Infection (%)	Urinary tract injury (%)	Bowel injury (%)
Magos <i>et al.</i> ⁶	1991	234	2.0	0.4	3.0			
Hill <i>et al.</i> ⁷	1992	850	0.8	0.8	0			
MISTLETOE study ⁸	1994	10 686	1.48	2.38				0.06
Pinion <i>et al.</i> ⁹	1994	105	1.0	6.0	11.0			
Scottish Hysteroscopy Audit Group ¹⁰	1995	978	1.1	3.6	6.0			
O'Connor and Magos ¹¹	1996	525	2.0	0.6	4.0			
O'Connor <i>et al.</i> ¹²	1997	116	3.0	0	3.0			
Nicoloso <i>et al.</i> ¹³	1997	2757	1.5	0.11	0.11			
Jansen <i>et al.</i> ⁵	2000	2515	1.3	0.16	0.2			
Propst <i>et al.</i> ³	2000	925	0.4		0.7	0.2		
Pasini and Belloni ²	2001	697	1.7	6.9	5.0			0.001
Ravi <i>et al.</i> ¹⁴	2001	70	8.6		0.01		0.01	
Agostini <i>et al.</i> ⁴	2003	2116	1.61	0.61	0.47	0.76		

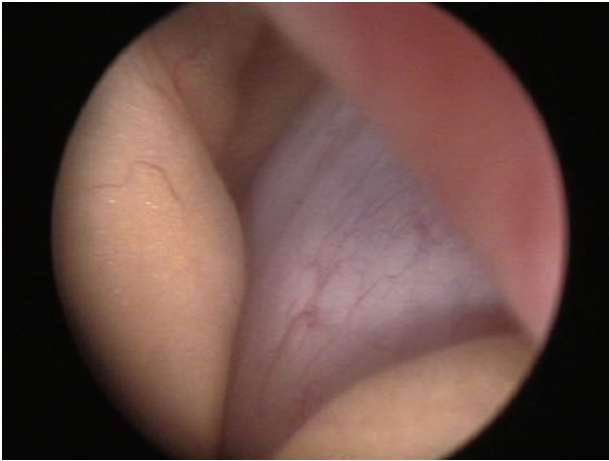


Figure 49.1 Visualization of the bowel through a uterine perforation

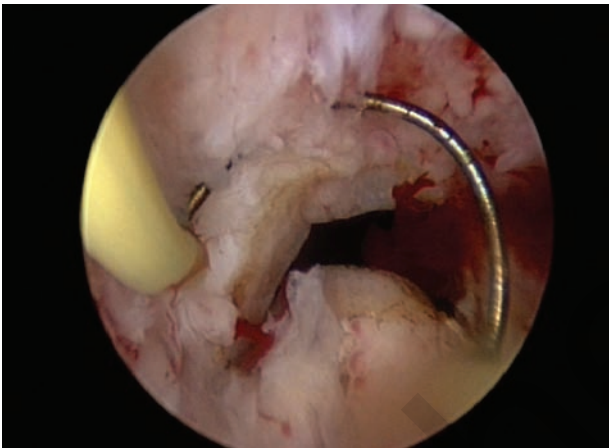


Figure 49.2 Perforation of the uterus with the resectoscope: hysteroscopic view

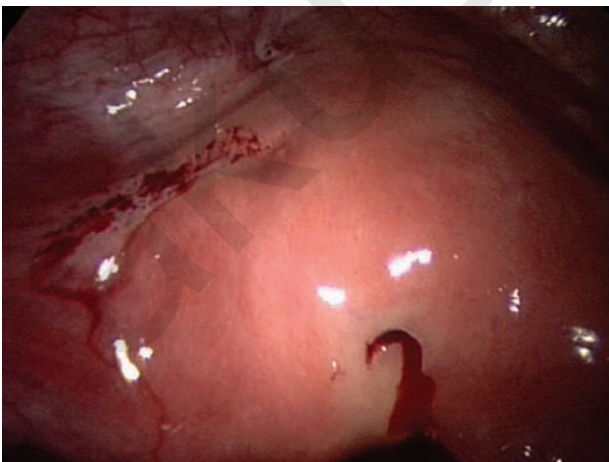


Figure 49.3 Perforation of the uterus with the resectoscope: laparoscopic view. Note the white aspect of the uterine serosa due to the thermal effect of the resectoscope

Our purpose is to describe the diagnosis, management and prevention of these complications.

TRAUMATIC COMPLICATIONS OF HYSTEROSCOPY

Traumatic complications of diagnostic hysteroscopy have been well documented. Hysteroscopic surgery, however, also involves some degree of blind manipulation. Dilating the cervix to accommodate wide-caliber operating instruments may cause cervical laceration and/or uterine perforation, with or without hemorrhage. The incidence of these complications has been estimated as 1–9%^{16,17}.

Diagnosis

Cervical laceration is diagnosed only if cervical bleeding occurs. Preoperative use of gonadotropin-releasing hormone (GnRH) analogs might render the cervix more resistant to dilatation.

Uterine perforation is suspected if the depth of passage of the sound or the dilator is greater than the apparent size of the uterus. Very rapid flow of liquid or very low distension pressure with CO₂ at the time of insertion of the hysteroscope should raise this suspicion.

Diagnosis is sometimes made by visualization of the bowel (Figure 49.1). Any hemorrhage before initiation of the surgical procedure is highly suggestive of traumatic damage.

Management

Cervical laceration is of little consequence, although sutures are occasionally required to prevent or stop cervical bleeding.

Uterine perforation does not usually need surgical repair. If perforation is diagnosed before the surgical procedure, surgery must be delayed and the patient observed for 24 hours. If perforation is diagnosed intraoperatively or after the surgical procedure, diagnostic laparoscopy is recommended to ensure that no thermal damage has been caused to adherent or adjacent structures, and that there is no unsuspected laceration of the large blood vessels (Figures 49.2 and 49.3).

Prevention

To prevent such complications, careful placement of the tenaculum and gentle dilatation of the cervix are recommended.

The hysteroscope must always be advanced under visual control, adapting the instrument axis to the direction of the cervical canal and the position of the uterus.

The use of *Laminaria* tents is favored by some hysteroscopists, but avoided by others, because of the

possible risk of overdilatation, resulting in a loss of distension medium and intrauterine pressure, and causing poor visualization. Some hysteroscopists prefer pharmacological dilatation with vaginal prostaglandins¹⁷. Their action causes softening of the cervical stroma leading to dilatation of the canal. This is enhanced by contraction of the myometrium induced by the drug.

HEMORRHAGIC COMPLICATIONS OF HYSTEROSCOPY

Intraoperative bleeding, other than that due to cervical laceration or uterine perforation, is usually the result of inadvertent or intentional trauma to the uterine wall. The reported rate of bleeding requiring surgery or uterine tamponade ranges from 0 to 22.4%^{18–21}. Hemorrhage can occur from false passages, with or without perforation, created either during dilatation or upon insertion of the hysteroscope. Bleeding can also occur after operative procedures, especially when the penetration of healthy myometrium is too deep. This can arise after using scissors or thermal energy (laser, resectoscope).

Diagnosis

Heavy and continuous vaginal bleeding during or after surgery must be investigated, to determine whether it is intrauterine or cervical bleeding. Management should be effected according to the origin of the hemorrhage.

Management

Intraoperatively, rapid bleeding can be controlled by coagulation, using either the tip of the laser fiber or the electrical loop. However, uncontrolled intraoperative or postoperative bleeding may sometimes require intrauterine tamponade. A Foley catheter is introduced into the uterine cavity and the balloon is inflated with 15 ml of liquid. After approximately 3 hours, half of the liquid is removed; if no bleeding recurs over the next hour, the catheter is removed and the patient is usually discharged. If active bleeding recurs, the balloon is reinflated and left in place overnight.

Prevention

Recommendations for avoiding trauma also apply to hemorrhagic complications. In addition, the entire surgical procedure must be carried out under strict visualization of the dissection plane. If large submucosal myomas or dense intrauterine synechiae are present, performing the procedure in two parts decreases the risk of such complications.

The use of intracervical vasopressin has been shown to reduce the risk of bleeding¹⁹, but this drug must be used with consideration of its systemic effects. Preoperative

medical therapy (GnRH agonists, danazol, progestins) has also been reported to decrease postoperative bleeding. Such therapy reduces the thickness and vascularity of the endometrium and shrinks myomas, and thus may be helpful in preventing this type of complication^{18,22,23}. A randomized double-blind study (the AZTEC (Adjunctive Zoladex for Thinning the Endometrium Comparison) study) proved that the use of GnRH agonists was helpful during endometrial ablation owing to the significant reduction in endometrial thickness²⁴.

DISTENSION MEDIUM COMPLICATIONS

Complications specifically related to distension media occur in 0.14–4% of procedures, and vary according to the medium used.

Carbon dioxide and air embolism

Venous gas embolism is the most feared complication when using CO₂ as a distension medium^{25–27}. This risk is low with the use of adequate hysteroflators. Most reports of fatal CO₂ embolism during operative hysteroscopy have been the result of using inadequate or faulty insufflators^{28,29}. Carbon dioxide is not advised for operative procedures due to the presence of bubbles that become apparent with bleeding, and also due to the risk of CO₂ embolism.

Air embolism has also been described. It can occur while using a fluid distension medium, and is provoked by repeated introduction and removal of the hysteroscope, the use of pressure pumps without air detectors^{30,31} and cervical trauma with subsequent dilacerated veins.

Diagnosis

Venous air embolism is marked by a sudden decrease in CO₂ pressure in the expired air. Clinical signs, such as decreased blood pressure, tachycardia, arrhythmia and increasing central venous pressure, come too late to be useful as warning signals. As soon as the end-tidal CO₂ drops in the expired air, insufflation must be stopped.

Management

The patient must be immediately ventilated with 100% oxygen³². If the patient is in the Trendelenburg position, this position must be maintained in order to prevent the passage of the air bubble into the pulmonary artery. If the patient is in normal decubitus, an anti-Trendelenburg position will keep the air bubble in the right atrium. A large catheter must be inserted into the right atrium through the internal jugular vein to aspirate the gas. Transesophageal ultrasound allows visualization of the gas embolism.

Prevention

The first rule of hysteroscopy with CO₂ is the use of adequate insufflators. The insufflation pressure must not exceed 100 mmHg. Faulty routes, especially submucosal passages, increase the risk of embolism. Cervical trauma with subsequent dilaceration of veins should be avoided to prevent air embolism. Repeated introduction of the hysteroscope must also be avoided, as must the use of CO₂ for cooling laser tips.

Fluid distension media

The ideal distending medium should be isotonic, non-hemolytic, non-conductive, non-toxic and rapidly eliminated from the body and must provide good visualization.

High-molecular-weight dextran The most feared complication of the use of dextran 70 (Hyskon®) is anaphylactic shock, although the incidence is rare at 1 in 10 000^{33,34}. So-called dextran-induced anaphylactic reaction (DIAR) is not predictable, and does not depend on the amount used³⁵. It can be prevented by performing an intravenous injection test with a small amount of 15% dextran, 2 minutes before using dextran 70. This distension medium also induces ascites and intravascular overload if a substantial volume is retained by the patient. Intravascular reabsorption of dextran has also been linked to non-cardiogenic pulmonary edema and to coagulation disorders³⁵⁻⁴¹.

Low-viscosity liquid complications These fluids (mainly sorbitol, glycine and dextrose in water) are primarily used during electrosurgical intrauterine procedures. When retained by the patient, they may cause hyponatremia and fluid overload.

Glycine solution has excellent optical and non-hemolytic properties during hysteroscopic surgery. Glycine is a non-essential amino acid which exists naturally in the body. Its normal plasma level is 120–155 µmol/l and it readily crosses the blood–brain barrier. Glycine functions as an inhibitory transmitter in the spinal cord and in the brainstem and retina. Its toxic effects on the central nervous system are also due to oxidative deamination in the liver and kidneys, and the formation of glyoxylic acid and ammonia⁴².

Glycine overload results in fluid overload (hypervolemia and hyponatremia) and in neurological symptoms. Glycine and its metabolites may be a cause of visual disturbances and encephalopathy, independent of changes in serum sodium levels and osmolarity.

In order to study the metabolism of glycine after endoscopic uterine surgery, serum concentrations of the amino acid and its metabolites were measured in seven patients with artificially induced menopause scheduled for neodymium : yttrium–aluminum–garnet (Nd:YAG) laser endoscopic procedures in our department⁴³. Fluid balance

was determined by a volumetric method (comparison of in- and outflow). The mean irrigant absorption was 1128±673 ml. A significant increase in glycine concentration during and after the procedure (up to 100 times the normal value) correlated with a rise in serum ammonia levels (Figure 49.4). Recovery was uneventful in all cases. Serum sodium levels and osmolarity remained normal during and after surgery, and there was no increased oxaluria.

Diagnosis

Manifestations of fluid overload and glycine intoxication are treacherous, and can occur at any time postoperatively. Patients present with bradycardia and hypertension followed by hypotension, nausea, vomiting, headache, visual disturbances, agitation, confusion and lethargy. Other important factors are a decrease in serum osmolarity and a rapid drop in the serum sodium level. If untreated, the result may be seizures, coma, cardiovascular collapse and death.

Management

Monitoring of intake and output of liquids during and after the procedure is mandatory to assess fluid balance. A discrepancy of 1000 ml requires the assessment of serum electrolytes to permit diagnosis. If a discrepancy of 1500 ml is noted during surgery, the procedure must be immediately stopped. If the serum sodium level is normal and the patient has no particular complaints, no further treatment is necessary. In the case of decreased sodium levels and hemodilution, the patient should observe fluid restrictions and intravenous diuretics (furosemide) should be administered. In the case of severe hyponatremia causing neurological symptoms, perfusion of hypertonic

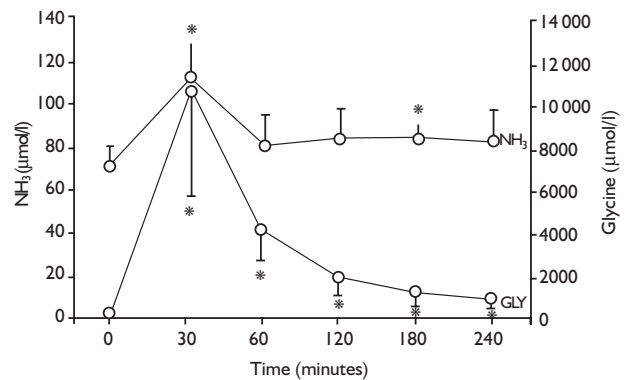


Figure 49.4 Concentrations of glycine and ammonia measured in the serum of seven patients with artificially induced menopause undergoing Nd:YAG laser endoscopic procedures

saline solution is required. If correction is too rapid, however, it may cause injury to the brain known as central pontine myelinolysis.

Prevention

During hysteroscopy with a liquid medium, monitoring of the inflow and outflow volumes is essential to prevent the retention of too much distension medium by the patient. An infusion pressure of more than 150 mmHg increases the risk of fluid absorption, but intravasation of the fluid often occurs through open uterine venous channels, or, in the presence of unrecognized perforation, with normal infusion pressure⁴⁴. If uterine perforation and/or a fluid balance discrepancy of over 1500 ml is detected, the procedure must be stopped.

INFECTIOUS COMPLICATIONS

Infection is rare, with an incidence of 0.25–1%^{19,45–50}.

Usually, infection follows prolonged operative procedures, especially when repeated insertion and removal of the hysteroscope through the cervical canal have been necessary. It occurs about 72 hours postoperatively and manifests itself with fever, vaginal discharge and pelvic pain. It can be treated successfully with broad-spectrum oral antibiotics. Hospitalization is rarely required. To prevent this complication, the use of prophylactic antibiotics is recommended.

Postoperative infection can be the cause of late complications, such as synechiae and infertility.

THERMAL ENERGY COMPLICATIONS

There is little information in the gynecological literature on the occurrence and management of injury to the viscera during hysteroscopy. Ravi *et al.*¹⁴ report one lesion to the bladder and ureter in 70 operative hysteroscopies, and Pasini and Belloni² one bowel injury after uterine perforation in a series of 697 operative hysteroscopies. The English MISTLETOE (Minimally Invasive Surgical Techniques – Laser, Endo-Thermal Or Endoresection) study of 10 686 endometrial resections from April 1993 to October 1994 reported a perforation rate of 0.64–2.47%, with 0.07% bowel injury⁸. Six visceral burns occurred, three with the loop associated with the rollerball and three with the loop alone. No visceral lesions were caused by the laser. Such injuries may be directly provoked by the electrical current or the thermal diffusion of energy. They often occur in the presence of uterine perforation. They can be induced by prolonged application of strong electrical or laser energy to the uterine wall, especially in the area of the tubal ostia.

Diagnosis

The diagnosis is missed intraoperatively in the majority of cases. Postoperative symptoms include fever, abdominal pain, leukocytosis and signs of peritonitis. Laparoscopy is helpful in suspect cases, but this may be insufficient to evaluate the bowel fully, and laparotomy is then required⁵¹.

Management

Guidelines described in Chapter 39 relating to vessel injuries and bowel burns during laparoscopy apply to such injuries.

Prevention

The success of prevention depends on respecting the technical conditions of surgical hysteroscopy. If uterine perforation occurs, the procedure must be delayed for the patient's safety. In addition, the energy source must always be activated with completely clear visualization of the tip of the laser fiber or the resectoscope loop.

LATE COMPLICATIONS

Besides the commonly encountered acute complications, a number of late complications, such as uterine perforation during a subsequent pregnancy, incomplete resection and undesired pregnancy and post-resection pain (hematometra and postablation tubal sterilization syndrome) warrant attention.

Uterine perforation during subsequent pregnancy

Operative hysteroscopy has an important role in the correction of Müllerian anomalies such as uterine septa, and in the improvement of fertility in the case of uterine synechiae or uterine hypoplasia in women exposed to diethylstilbestrol. In women undergoing hysteroscopic metroplasty, the uterus is weakened, and several cases of uterine rupture during subsequent pregnancy have been described^{52–59}. Some uterine ruptures even occurred after perforation during diagnostic hysteroscopy.

Undesired pregnancy

Endometrial ablation is not a method of contraception. Pregnancy rates of 0.2–1.6% have been described, but may be underreported^{60–62}. Placenta accreta, increta and percreta, placental abruption and postpartum hemorrhage have all been reported⁶³.

Hematometra and postablation tubal sterilization syndrome

The development of hematometra after operative hysteroscopy occurs infrequently, but the incidence is increased when the endocervix is resected. In reproductive-aged women or those utilizing cyclic hormone replacement therapy, cyclic or chronic lower pelvic pain may occur⁶⁴.

The diagnosis is made by ultrasonography.

In some cases, cervical dilatation may allow drainage of the hematometra. In most cases, hysterectomy is necessary to alleviate the pain.

Postablation tubal sterilization syndrome was first described by Townsend *et al.* in 1993⁶⁵. A patient with previous tubal ligation presented with lower quadrant pain following endometrial ablation. At laparoscopy, the left proximal Fallopian tube was hemorrhagic and swollen as in an ectopic pregnancy. Removal of the tube alleviated the discomfort. Over an 18-month period following this incident, six women presented with the same clinical and laparoscopic findings. Pain occurred between 6 and 10 months after endometrial ablation and at the time of an expected menstrual period. In a review by Bae *et al.*⁶⁶, six of 71 women with a history of endometrial ablation and tubal obstruction after ligation or salpingectomy developed postablation tubal sterilization syndrome.

The histopathology is that of persistent endometrium in the cornual area. Because the lower uterine segment is obliterated after endometrial ablation, menstrual blood passes out into the Fallopian tube and the proximal part of the tube fills with blood, causing distension and pain. Patients describe increasing pain, cyclic in the beginning, then continuous. Ultrasonography usually fails to reveal distended Fallopian tubes but may indicate hematometra in the cornual area.

The diagnosis is made by laparoscopy. Histopathology shows hematosalpinx and microscopic findings of salpingitis and myometritis.

Bilateral salpingectomy should be performed even if symptoms are unilateral, as recurrence of symptoms on the other side after unilateral salpingectomy has been reported. Hysterectomy might be necessary because of the possibility of deep myometritis and microabscesses of the myometrium⁶⁶.

To prevent postablation tubal sterilization syndrome, care should be taken to perform meticulous destruction of the uterine cornua at the time of endometrial ablation.

DISCUSSION

Operative hysteroscopy has provided new possibilities for the conservative treatment of gynecological pathologies. Although complications are not frequent, some serious problems do occur. Most of the complications described are induced by traumatic injuries. As the safety of the

procedure depends on the experience of the surgeon, the increasing number of gynecologists performing operative hysteroscopy will inevitably lead to an increase in the potential risk of complications. Understanding the risks inherent to the use of instruments and media selected will, however, minimize these risks and enhance the chances of good surgical results.

REFERENCES

1. Hulka JF, Peterson HB, Phillips JM, et al. Operative hysteroscopy. American Association of Gynecologic Laparoscopists 1991 membership survey. *J Reprod Med* 1993; 38: 572-3
2. Pasini A, Belloni C. Intraoperative complications of 697 consecutive operative hysteroscopies. *Minerva Ginecol* 2001; 53: 13-20
3. Propst AM, Liberman RF, Harlow BL, et al. Complications of hysteroscopic surgery: predicting patients at risk. *Obstet Gynecol* 2000; 96: 517-20
4. Agostini A, Bretelle F, Cravello L, et al. Complications of operative hysteroscopy. *Presse Med* 2003; 32: 826-9
5. Jansen FW, Vredevoogd CB, Van Ulzen K, et al. Complications of hysteroscopy: a prospective, multicenter study. *Obstet Gynecol* 2000; 96: 266-70
6. Magos AL, Baumann R, Lockwood GM, et al. Experience with the first 250 endometrial resections for menorrhagia. *Lancet* 1992; 337: 1074-8
7. Hill D, Maher P, Wood C, et al. Complications of operative hysteroscopy. *Gynaecol Endosc* 1992; 1: 185-9
8. Overton C, Hargreaves J, Maresh M. A national survey of the complications of endometrial destruction for menstrual disorders: the MISTLETOE study. *Br J Obstet Gynaecol* 1997; 104: 1351-9
9. Pinion SB, Parkin DE, Abramovich DR, et al. Randomised trial of hysterectomy, endometrial laser ablation and transcervical endometrial resection for dysfunctional uterine bleeding. *Br Med J* 1994; 309: 979-83
10. Scottish Hysteroscopy Audit Group. A Scottish audit of hysteroscopic surgery for menorrhagia: complications and follow-up. *Br J Obstet Gynaecol* 1995; 102: 249-54
11. O'Connor H, Magos A. Endometrial resection for the treatment of menorrhagia. *N Engl J Med* 1996; 335: 151-6
12. O'Connor H, Broadbent JAM, Magos AL, et al. Medical Research Council randomised trial of endometrial resection versus hysterectomy in management of menorrhagia. *Lancet* 1997; 349: 897-901
13. Nicoloso E, Carvello L, d'Ercole C, et al. Les complications de l'hystérocopie: enquête nationale prospective a propos de 2757 hystérocopies. *Rev Fr Gynecol Obstet* 1997; 92: 91-8
14. Ravi B, Schiavello H, Chandra P, et al. Safety and efficacy of hysteroscopic endomyometrial resection-

- ablation for menorrhagia. *J Reprod Med* 2001; 46: 1717–23
15. MacLean-Fraser E, Penava D, Vilos GA. Perioperative complication rate of primary and repeat hysteroscopic endometrial ablations. *J Am Assoc Gynecol Laparosc* 2002; 9: 175–7
 16. Castaing N, Darai E, Chuong T, et al. Mechanical and metabolic complications of hysteroscopic surgery: report of a retrospective study of 352 procedures. *Contracept Fertil Sex* 1999; 27: 210–15
 17. Preuththipan S, Herabutya Y. A randomized controlled trial of vaginal misoprostol for cervical priming before hysteroscopy. *Obstet Gynecol* 1999; 94: 427–30
 18. Brooks PG, Serden SP, Davos I. Hormonal inhibition of the endometrium for resectoscopic endometrial ablation. *Am J Obstet Gynecol* 1991; 164: 1601–6
 19. Brooks PG. Complications of operative hysteroscopy: how safe is it? *Clin Obstet Gynecol* 1992; 35: 256
 20. DeCherney AH, Diamond MD, Lavy G, et al. Endometrial ablation for intractable uterine bleeding: hysteroscopic resection. *Obstet Gynecol* 1987; 70: 668–70
 21. Donnez J, Gillerot S, Bourgonjon D, et al. Neodymium : YAG laser hysteroscopy in large submucous fibroids. *Fertil Steril* 1990; 54: 999–1003
 22. Donnez J, Schrurs B, Gillerot S, et al. Treatment of uterine fibroids with implants of gonadotropin-releasing hormone agonist: assessment by hystero-graphy. *Fertil Steril* 1989; 51: 947–50
 23. Donnez J, Vilos G, Gannon MJ, et al. Goserelin acetate (Zoladex) plus endometrial ablation for dysfunctional uterine bleeding: a large randomized, double-blind study. *Fertil Steril* 1997; 68: 29–36
 24. Donnez J, Vilos G, Gannon MJ, et al. AZTEC Study Group. Goserelin acetate (Zoladex) plus endometrial ablation for dysfunctional uterine bleeding: a 3-year follow-up evaluation. *Fertil Steril* 2001; 75: 620–2
 25. Corson SL, Brooks PG, Soderstrom RM. Gynecologic endoscopic gas embolism. *Fertil Steril* 1996; 65: 529–33
 26. Nishiyama T, Hanaoka K. Gas embolism during hysteroscopy. *Can J Anaesth* 1999; 46: 379–81
 27. Brandner P, Neis KJ, Ehmer C. The etiology, frequency and prevention of gas embolism during CO₂ hysteroscopy. *J Am Assoc Gynecol Laparosc* 1999; 6: 421–8
 28. Perry PM, Baughman VL. A complication of hysteroscopy: air embolism. *Anesthesiology* 1990; 73: 546–7
 29. Baggish MS, Daniell JF. Death caused by air embolism associated with neodymium : yttrium–aluminum–garnet laser surgery and artificial sapphire tips. *Am J Obstet Gynecol* 1989; 161: 877–8
 30. Nachum Z, Kol S, Adir Y, et al. Massive air embolus, possible cause of death after operative hysteroscopy using a 32% dextran 70 pump. *Fertil Steril* 1992; 58: 836–8
 31. Overton C, Wilson-Smith E, Hunt P, et al. Air embolism during endoscopic resection of the endometrium: recommendations for a change in practice. *Gynaecol Endosc* 1996; 5: 357
 32. Tur-Kaspa I. Hyperbaric oxygen therapy for air embolism complicating operative hysteroscopy. *Am J Obstet Gynecol* 1990; 163: 680–1
 33. Leake JF, Murphy AA, Zacur HA. Non-cardiogenic pulmonary oedema: a complication of operative hysteroscopy. *Obstet Gynecol* 1987; 48: 497–9
 34. McLucas B. Hyskon complications in hysteroscopic surgery. *Obstet Gynecol Surv* 1991; 46: 196–200
 35. Witz CA, Silverberg KM, Burns WN, et al. Complications associated with the absorption of hysteroscopic fluid media. *Fertil Steril* 1993; 60: 745–56
 36. Brandt RR, Dunn WF, Ory SJ. Dextran 70 embolization. Another cause of pulmonary hemorrhage, coagulopathy and rhabdomyolysis. *Chest* 1993; 104: 631–3
 37. Jedeikin R, Olsfanger D, Kessler J. Disseminated intravascular coagulopathy and adult respiratory distress syndrome: life-threatening complications of hysteroscopy. *Am J Obstet Gynecol* 1990; 162: 44–5
 38. Romero RM, Kreitzer JM, Gabrielson GV. Hyskon induced pulmonary hemorrhage. *J Clin Anaesth* 1995; 7: 323–5
 39. Vercellini P, Rossi R, Pagnoni B, et al. Hypervolemic pulmonary edema and severe coagulopathy after intrauterine dextran instillation. *Obstet Gynecol* 1992; 79: 838–9
 40. Morrison DM. Management of hysteroscopic surgery complications. *AORN J* 1999; 69: 194–7, 199–209, quiz 210, 213–15, 21
 41. Indman PD, Brooks PG, Cooper JM, et al. Complications of fluid overload from resectoscopic surgery. *J Am Assoc Gynecol Laparosc* 1998; 5: 63–7
 42. Van Herendael BJ. Hazards and dangers of operative hysteroscopy. In Sutton C, Diamond M, eds. *Endoscopic Surgery for Gynecologists*. London: WB Saunders Company, 1993: 641–8
 43. Van Boven M, Pendeville PE, Singelyn FJ. Glycine and its metabolites during and after intrauterine YAG laser surgery. *Br J Anaesth* 1993; 70 (Suppl 1): A87
 44. Vulgaropulos SP, Haley LC, Hulka JF. Intrauterine pressure and fluid absorption during continuous flow hysteroscopy. *Am J Obstet Gynecol* 1992; 167: 386–90
 45. Taylor PJ, Hamou JE. Hysteroscopy. *J Reprod Med* 1983; 28: 359–89
 46. Mergui JL, Raossanaly K, Salat-Baroux J. Place de l'hysteroscopie opératoire en 1990. *Lett Gynécol* 1990; 132: 21
 47. Rullo S, Boni T. Broad ligament abscess after operative hysteroscopy. *Clin Exp Obstet Gynecol* 1995; 22: 240–2
 48. Amin-Hanjani S, Good JM. Pyometra after endometrial resection and ablation. *Obstet Gynecol* 1995; 85: 893–4
 49. Jorgenson JC, Pelle J, Philipsen T. Fatal infection following transcervical fibroid resection. *Gynaecol Endosc* 1996; 5: 245

50. McCausland VM, Fields GA, McCausland AM, et al. Tuboovarian abscesses after operative hysteroscopy. *J Reprod Med* 1993; 38: 198–200
51. Sullivan B, Kenne P, Seibel M. Hysteroscopic resection of fibroid with thermal injury to sigmoid. *Obstet Gynecol* 1992; 80: 546–7
52. Creinin M, Chen M. Uterine defect in a twin pregnancy with a history of hysteroscopic fundal perforation. *Obstet Gynecol* 1992; 79: 879–80
53. Howe RS. Third-trimester uterine rupture following hysteroscopic uterine perforation. *Obstet Gynecol* 1993; 81: 827–9
54. Lobaugh ML, Bammel BM, Duke D, et al. Uterine rupture during pregnancy in a patient with a history of hysteroscopic metroplasty. *Obstet Gynecol* 1994; 83: 838–40
55. Yaron Y, Shenhav M, Jaffa AJ, et al. Uterine rupture at 33 weeks' gestation subsequent to hysteroscopic uterine perforation. *Am J Obstet Gynecol* 1994; 170: 786–7
56. Gabriele A, Zanetta G, Pasta F, et al. Uterine rupture after hysteroscopic metroplasty and labor induction. A case report. *J Reprod Med* 1999; 44: 642–4
57. Tannous W, Hamou J, Henry-Suchet J, et al. Uterine rupture during labor following surgical hysteroscopy. *Presse Med* 1996; 25: 159–61
58. Conturso R, Redaelli L, Pasini A, et al. Spontaneous uterine rupture with amniotic sac protrusion at 28 weeks subsequent to previous hysteroscopic metroplasty. *Eur J Obstet Gynecol Reprod Biol* 2003; 107: 98–100
59. Angell NF, Tan Domingo J, Siddiqi N. Uterine rupture at term after uncomplicated hysteroscopic metroplasty. *Obstet Gynecol* 2002; 100: 1098–9
60. Mints M, Radestad A, Rylander E. Follow up of hysteroscopic surgery for menorrhagia. *Acta Obstet Gynecol Scand* 1998; 77: 435–8
61. Baumann R, Owerdiek W, Reck C. Schwangerschaft nach Sterilisation und Endometriumablation. *Gebürtshilfe Frauenheilkd* 1994; 54: 246
62. Hill DJ, Mahrer P. Pregnancy following endometrial ablation. *Gynaecol Endosc* 1992; 1: 47
63. Rogerson L, Gannon B, O'Donovan P. Outcome of pregnancy following endometrial ablation. *J Gynecol Surg* 1997; 13: 155–60
64. Römer T, Campo R, Hücke J. Hämatometra nach hysteroskopischer Endometriumablation. *Zentralbl Gynäkol* 1995; 5: 278–80
65. Townsend DE, McCausland V, McCausland A, et al. Post-ablation tubal sterilization syndrome. *Obstet Gynecol* 1993; 82: 422–4
66. Bae IH, Pagedas AC, Perkins HE, et al. Postablation tubal sterilization syndrome. *J Am Assoc Gynecol Laparosc* 1996; 3: 435–8

Index

- abdominal cerclage 403
 - concerns in non-pregnant women 404
 - see also* laparoscopic abdominal cerclage
- abdominal wall 2
- abnormal uterine bleeding (AUB) *see* bleeding, uterine
- abortion 465
- accessory tube 120
- adenomyosis *see* endometriosis
- adhesiolysis 127–8, 151–3
- adhesions 123, 151–2
 - intratubal 146
 - intrauterine 464, 507–14
 - classification 507
 - diagnosis 507
 - etiopathogenesis 5–7
 - treatment 508–14
 - periadnexal 146–7
 - postoperative 208, 234–5
 - subovarian 32, 33
- adnexal torsion 211–15
 - etiology 212
 - treatment 212
 - follow-up 213–14
 - ischemic lesion management 211–13
 - postoperative fertility 214
- adnexectomy 264, 315
 - bilateral 315
 - unilateral 315
- Aesop™ laparoscope holder 413, 417
- air embolism 442, 555–6
- Allen–Masters syndrome 55
- ampulla 122, 142
 - dilatation 14
- ampullary folds 142
 - preservation of 144–6
- ampullary–ampullary anastomosis 188
- anastomosis *see* laparoscopic microsurgical tubal anastomosis
- anesthesia
 - fertiloscopy 117–18
 - prolapse treatment 278
- antibiotic therapy, prolapse treatment 281, 286
- appendix 120
- arcuate uterus 493
- arterial relationships 5–6
- Asherman's syndrome 464
- atraumatic forceps 18, 20
- biopsy
 - forceps 20
 - ovarian tissue 344–5
 - targeted hysteroscopic biopsies 477–9
- bipolar coagulation 268–70
- bipolar resectoscope 456
- bladder
 - Burch bladder neck suspension 286
 - catheter 278
 - endometriosis 85–91
 - diagnosis 85–6
 - histology 89
 - prevalence 85
 - surgical technique 86–9
 - symptoms 85, 86
 - injury 111, 430–1, 436–7
 - by secondary trocars 432
 - diagnosis 432, 436–7
 - management 432, 437
 - prevention 432, 437
 - mobilization 98
- bleeding, uterine 533
 - hysteroscopic evaluation 465–8
 - postmenopausal 462–3
 - see also* hemorrhage
- borderline ovarian tumors (BOT)
 - diagnosis 311–14
 - CA125 313–14
 - CT 312
 - laparoscopic staging 314
 - MRI 314
 - ultrasound 311–12
 - epidemiology 307
 - fertility preservation 317, 319
 - histology 308–10, 317–18
 - Brenner tumors 310
 - clear cell tumors 310
 - endometrioid tumors 310
 - mucinous BOT 309–10
 - peritoneal implants 310
 - serous BOT 308–9
 - molecular biology 310–11
 - prognosis 307–8
 - risk factors 308
 - risk of 206
 - surgical treatment 314–16
 - adjuvant treatment 316
 - HRT after 316

- borderline ovarian tumors (BOT) (*cont.*)
 results 318–19
 symptoms 311
bowel injury 111–12, 429–30
 diagnosis 430, 434
 during surgical procedures 432–6
 management 430, 434–5
 prevention 430, 435–6
 subocclusion due to umbilical incision suture 445
bowel preparation 278
bowel surgery 107–9
breast cancer patient monitoring 463
Brenner tumors 310
broad ligament 3
Burch bladder neck suspension 286
- CA125 369
 borderline ovarian tumor diagnosis 313–14
 ovarian cyst evaluation 195–7
cardiac surgery, fetal 399
Cavaterm™ system 537–8
 Cavaterm *Plus* 538
cerclage *see* abdominal cerclage
cervical atresia 502
cervical canal 471
 internal cervical os (ICO) 471, 472–3
cervical cancer 360–2, 375–87
 advanced-stage case management 385–6
 early-stage case management 384–5
 hysteroscopy 466–8
 laparoscopy-assisted hysterectomy 380–4
 Schauta operation 380
 Schauta–Amreich operation 380
 Schauta–Stoekel operation 380–4
 lymphadenectomy 360–2, 375–80
 aortic 378–80
 pelvic 375–8
 sentinel node assessment 386–7
cervical laceration 554
cervical pregnancy 166–7
cervical sacrofixation 289–96
 see also prolapse
cesarean section 219
 ectopic pregnancy in scar 167–9
 scar dehiscence 219–20
 repair 220–5
chemotherapy
 effects on ovarian function 350
 IVF and 343–4
chorioangioma, placental 399
ciliation index 146
clear cell tumors 310
clips 201
CO₂ gas insufflator 21–2
 smoke evacuation 28
 see also insufflation
CO₂ laser 23, 24, 25–6
coagulation
 bipolar 268–70
 electrocoagulation of the endometrium 535, 542–3
 endometriosis 40
 instruments 19
 photocoagulation of the endometrium 535
 placental anastomoses 395–6
colpotomy 289–93
complications 425–6
 diaphragmatic injury 444
 distension medium complications 442, 555–7
 due to synthetic materials 445
 gastrointestinal injury 111–12, 428–30, 432–6, 445
 hysteroscopic surgery 553–8
 incisional hernias 442–3
 infection 557
 injury during surgical procedures 432–45, 554–5, 556
 pneumothorax 444
 port-site metastases 443–4
 secondary trocar injury 431–2
 bladder 432
 epigastric vessels 431–2
 spleen injury 444–5
 subcutaneous emphysema 426
 urinary tract injury 430–1, 432, 436–41
 vascular injury 426–8, 441–2, 555
 see also specific procedures
computed tomography (CT)
 borderline ovarian tumor diagnosis 312
 ovarian cyst evaluation 197
cord occlusion in abnormal twin pregnancy 397
cornual pregnancy 159–64
 intramyometrial implantation 162–3
 methotrexate treatment 162
 surgical management 160–2
 triplet pregnancy 162
 see also ectopic pregnancy
corpus, uterine 471
corpus luteum 120
cryoendometrial ablation 540–2
cryopreservation
 embryo 315–16, 333, 343
 oocyte 334–5
 in vitro maturation 334–5
 mature oocyte 334
 see also ovarian tissue cryopreservation
culdoplasty
 McCall 102–4
 prolapse and 283
caldoscopy 133
caldotomy, circumferential 101
cumulus–oocyte complex (COC) 335
cystectomy, ovarian 45–7, 199–202, 315
 clips 201
 complications 207–8

- postoperative 208
 - spillage 207–8
- fibrin sealant 201–2
- indications for 198–9
- suturing 200–1
- versus laser vaporization 47–53
- see also* ovarian cysts
- cystoscopy 104, 286

- da Vinci™ robotic system 417, 418–20
- dextran 70 complications 556
- diaphragmatic hernia, congenital 399
- diaphragmatic injury 444
- diethylstilbestrol (DES) exposure 489–93
- digestive system 8–9
- distension medium 453, 473–4
 - complications 555–7
- Doppler ultrasound, ovarian cyst evaluation 195
- Douglas introducer 115–16, 119
- Douglasectomy 59–60
- drainage 272
- dye test 118, 121
- dysmenorrhea 55
 - see also* pain
- dyspareunia 55
 - see also* pain

- ectopic pregnancy 157
 - diagnosis 157–8
 - embryo transfer technique and 157
 - future fertility prognosis 176–7
 - ruptured ectopic pregnancy and 177
 - laparoscopic management 181–6
 - adjunctive therapy 184
 - conservative treatment 181–3
 - contraindications 183–4
 - indications for 184–5
 - postoperative work-up 184
 - results 185
 - salpingectomy 183
 - risk after bilateral salpingectomy 158
 - risk factors 157
 - specific sites 159–69
 - cervical pregnancy 166–7
 - cesarean section scar 167–9
 - cornual pregnancy 159–64
 - ovarian pregnancy 164–5
 - see also* heterotopic pregnancy; methotrexate (MTX)
- electrocoagulation of the endometrium 535
- embryo cryopreservation 315–16, 333, 343
- embryo transfer
 - ectopic pregnancy and 157
 - hydrosalpinx and 150–1
 - salpingectomy before 151
- embryoscopy 391
- emphysema, subcutaneous 426
- EndoAssist™ laparoscope holder 413

- endometrial ablation 533–44
 - complications 535
 - contraindications 534
 - first-generation technologies 535
 - indications for 534
 - patient assessment 533–4
 - patient counseling 534
 - preparation 534–5
 - second-generation technologies (SEATs) 535–43
 - classification 533
 - cryoendometrial ablation 540–2
 - hot liquid balloons 536–8
 - HydroThermAblator 538–9
 - impedance-controlled endometrial electrocoagulation 542–3
 - microwave endometrial ablation 539–40
 - third-generation technologies 543
 - trichloroacetic acid 543
- endometrial cancer 359, 369
 - hysteroscopy 466
 - laparoscopic hysterectomy 363
 - lymphadenectomy 359, 369
 - indications for 371–2
 - medical advice 369–70
 - rationale for 370
 - which nodes to remove 370
 - radiotherapy effectiveness 370–1
- endometrial resection 527–32
 - instruments 527–8
 - technique 528–30
- endometrioid tumors 310
- endometriomas 43–4
 - surgical treatment 44–53
 - indications for 44
 - risk of 47–53
 - transvaginal laparoscopy 136
 - see also* endometriosis
- endometriosis
 - bladder 85–91
 - diagnosis 85–6
 - histology 89
 - prevalence 85
 - surgical technique 86–9
 - symptoms 85, 86
 - laparoscopic hysterectomy 95, 104–9
 - bowel surgery 107–9
 - surgical technique 105–7
 - ovarian 43–53, 137
 - indications for surgery 44
 - laser vaporization 44–5, 47–53
 - ovarian cystectomy 45–53
 - pain in 55
 - peritoneal 31–40
 - black/bluish lesions 31
 - coagulation 40
 - diagnosis 31–7
 - excision 38–40

- endometriosis (*cont.*)
 laser vaporization 38
 non-visible endometriosis 34–7
 red lesions 31–2
 treatment modes 37–8
 white lesions 32
 rectovaginal 63–73
 diagnosis 65–6
 hormonal dependence 65
 recurrence 72–3
 surgical shaving 67–73
 retrocervical disease 63–4
 arguments for 64
 retroperitoneal disease 63–4
 arguments for 64
 classification of deep lesions 66–7
 transvaginal laparoscopy 136
 tubal surgery and 147
 ureteral 77–82
 left versus right 81–2
 prevalence 77, 81
 surgical treatment 78–80, 82
 symptoms and diagnosis 77–8
 uterine suspension 56–8
 endometritis 465, 507
 epigastric vessel perforation 431–2
 diagnosis 431
 management 431
 prevention 432
 epithelial ovarian tumors of low malignant potential *see*
 borderline ovarian tumors (BOT)
 ergonomics 409

 Fallopian tubes
 intratubal adhesions 146
 mucosal evaluation 146
 tubal disease 465
 wall fibrosis and thickness 146
 see also tubal occlusion; tubal surgery
 falloscopy 145
 fertility preservation 333, 355–7
 borderline ovarian tumors 317, 319
 ovarian transposition 352, 355
 see also cryopreservation
 fertility prognosis following treatment
 adnexal torsion 214
 hysteroscopic myomectomy 519
 laparoscopic myolysis 246–7
 laparoscopic myomectomy 235, 246–7
 methotrexate 177
 ovarian transposition 352
 salpingotomy 176–7
 see also fertility preservation
 fertiloscope 116
 introduction 118, 119
 fertiloscopy 115–30
 contraindications 128
 instrumentation 115–16
 operative procedure 119–28
 dye test 121
 hysteroscopy 125
 microsalpingoscopy 123–5
 operative fertiloscopy 125–8, 130
 pelvic exploration 119–21
 salpingoscopy 121–3
 results 128–9
 safety 130
 technique 116–19
 anesthesia 117–18
 hydroperitoneum 118–19
 introduction of fertiloscope 118, 119
 patient preparation 116–17
 use of operative channel 119
 fetal endoscopy 391–400
 complications 399
 contraindications 399
 diagnostic endoscopy 392–3
 techniques 391–2
 therapeutic endoscopy 393–9
 coagulation of placental anastomoses 395–6
 congenital diaphragmatic hernia 399
 cord occlusion in abnormal twin pregnancy 397
 fetal cardiac surgery 399
 myelomeningocele 399
 obstructive uropathies 397–8
 placental chorioangioma 399
 sacroccygeal teratoma 399
 septostomy 396–7
 twin-to-twin transfusion syndrome (TTTS) 393–7
 fetoscopy 391–2
 see also fetal endoscopy
 fibrin sealant 201–2
 fibroids *see* myomas
 fibrosis, tubal wall 146
 fimbria 119, 120
 fimbrioplasty 147
 FIPS laparoscope holder 413–14
 Foley catheter 286
 forceps
 atraumatic 18, 20
 biopsy 20
 bipolar 19
 grasping 18, 19
 foreign bodies, intrauterine 468
 funicular meso 3

 gamete intrafallopian transfer (GIFT) 465
 gastric perforation 428–9
 gastrointestinal injury 111–12, 428–30, 432–6, 445
 see also bowel injury; stomach injury
 genital ligament 5
 genitofemoral nerve 9
 global endometrial ablation (GEA) 533
 see also endometrial ablation

- glycine solution 556
- GnRH agonist therapy 273
 before endometrial ablation 534–5
 endometriosis 38, 45
 myomas 227–8, 246, 273, 515, 520–3
- grasping forceps 18, 19
- Hamou plug 549–51
- hematometra 558
- hemivagina 498–9
- hemoglobin catabolism 36–7
- hemorrhage 426–8, 441–2
 following hysteroscopy 555
 following laparoscopic hysterectomy 110
 following laparoscopic myomectomy 234, 246
 following lymphadenectomy 364–5
see also bleeding, uterine
- Her Option™ cryoablation 541–2
- hernias, incisional 442–3
- heterotopic pregnancy 158–9
 diagnosis 158
 incidence 158
 localization 158–9
 predisposing factors 158
 symptoms 158
 treatment 159
see also ectopic pregnancy
- hormone replacement therapy (HRT)
 hysterosonography and 462
 postoperative 316–17
- human chorionic gonadotropin (hCG)
 ectopic pregnancy diagnosis 157–8
 persistent trophoblast diagnosis 173
- hydatiform mole 467
- hydrosalpinx
 diagnosis 141
 IVF–embryo transfer and 150–1
 physiopathology 141, 142
see also tubal occlusion
- hydrothermablation (HTA) 533, 538–9
see also endometrial ablation
- HydroThermAblator 538–9
- hypermenorrhea 95–6
- hypogastric plexi 10
- hysterectomy 93, 263
 distension medium 453
 prolapse and 281, 282–3
see also laparoscopic hysterectomy
- hysterosalpingography 144
- hysterosalpingosonography 144–5
- hysteroscopic myomectomy 515–24
 equipment 515
 fertility and 519
 preoperative GnRH agonist therapy 515
 results 517–19
 techniques 516–17
 fibromatous uterus 517
 submucosal fibroids 516
- hysteroscopy 125, 126, 463–8, 471–2
 abnormal uterine bleeding evaluation 465–8
 complications 553–8
 distension media 555–7
 hemorrhagic 555
 late 557–8
 thermal energy 557
 traumatic 554–5
- infertility evaluation 463–5
 abortion 465
 endometritis 465
 GIFT 465
 intrauterine synechiae 464
 Müllerian anomalies 464
 sperm migration test 465
 submucous myomas 465
 tubal disease 465
 ZIFT 465
- instrumentation 453–6
 high-frequency generator 456
 resectoscopes 454, 456
 working elements 455
- internal cervical os as obstacle 472–3
- intrauterine foreign bodies 468
- myomectomy 515–24
- operative techniques 479–80
 bipolar surgery 479–80
 mechanical surgery 479
- targeted hysteroscopic biopsies 477–9
- uterine adhesion management 507–14
- uterine cavity distension 473–4
- uterine septum management 493–8
- vaginoscopic approach 472
- hysterosonography 457–63
 breast cancer patient monitoring 463
 contraindications 458
 HRT and 462
 indications for 458
 infertility and 461–2
 postmenopausal bleeding evaluation 462–3
 results 458–61
 technique 457–8
- iliac arteries 4, 5–6
- iliac veins 7
- ImagTrack laparoscope holder 414
- impedance-controlled endometrial electrocoagulation
 542–3
- in vitro* fertilization (IVF) 343–4
 chemotherapy and 343–4
 endometriomas and 44
 hydrosalpinx and 150–1
 hysterosonography 462
 stimulation protocols 344
- infection
 following hysteroscopy 557

- infection (*cont.*)
 following laparoscopic hysterectomy 110
- infertility
 as risk factor for borderline ovarian tumors 308
 hysteroscopic evaluation 463–5
 endometritis 465
 GIFT 465
 intrauterine synechiae 464
 Müllerian anomalies 464
 sperm migration test 465
 submucous myomas 465
 tubal disease 465
 ZIFT 465
 hysterosonography 461–2
 myomectomy for 239–40
 outcome 240
 uterine displacement and 55
 see also fertility prognosis following treatment;
 fertiloscopy
- innervation 9–11
- installation
 laparoscopic myomectomy 229
 prolapse treatment 278
 see also preoperative preparation
- insufflation 1–2
 CO₂ insufflators 21–2
 complications 442, 555–6
 smoke evacuation 28
 see also distension medium
- internal cervical os (ICO) 471
 as obstacle in hysteroscopy 472–3
- intestinal fixation 280
- intestinal injury *see* bowel injury
- intestinal probe 20, 21
- introducers 115–16
- irrigation–suction unit 22
- isthmic–ampullary anastomosis 188
- isthmic–isthmic anastomosis 188
- KCl, ectopic pregnancy management 159, 162
- laparoscope-holding systems 409–14
 active holders 413–14
 LapMan® project 409–12
 advantages 411
 indications in gynecological surgery 412
 solo surgery concept 412
 passive holders 412–13
- laparoscopic abdominal cerclage 404
 technique 404–5
- laparoscopic hysterectomy 93–112
 cervical cancer 380–4
 Schauta operation 380
 Schauta–Amreich operation 380
 Schauta–Stoeckel operation 380–4
 complications 109–12, 273, 274
 bladder injury 111
 bowel injury 111–12
 hemorrhage 110
 infection 110
 urinary tract complications 110–11
 definitions 94, 263
 endometrial cancer and 363
 endometriosis and 104–9
 bowel surgery 107–9
 surgical technique to remove endometriosis 105–7
 in benign diseases 263–75
 indications and contraindications 94–6, 263–4
 postoperative considerations 109
 preoperative GnRH agonist treatment 273
 prolapse and 281, 282–3
 techniques 264–6
 bipolar coagulation 268–70
 drainage 272
 ureter dissection 271
 uterine mobilizer 270–1
 vaginal closure 272
 see also laparoscopic subtotal hysterectomy (LASH);
 total laparoscopic hysterectomy (TLH)
- laparoscopic microsurgery 187
 digital enhancement 187
 instrumentation 187
 magnification 187
 needles 188
 prerequisites for surgery 188
 resolution 187
 sutures 188
 see also laparoscopic microsurgical tubal anastomosis;
 microsalpingoscopy
- laparoscopic microsurgical tubal anastomosis
 indications for 187
 surgical technique 189–92
 types of 188–9
 see also laparoscopic microsurgery
- laparoscopic myolysis 240–8
 fertility prognosis 246–7
 operative technique 242–5
- laparoscopic myomectomy 227–36, 240–8
 conversion rate 234
 efficiency 246–8
 fertility prognosis 235, 246–7
 indications for 228
 installation 229
 instrumentation 229
 obstetric scars 235
 operation time 234
 operative technique 229–32, 242
 enucleation 230
 hysterotomy suture 230–1
 incision of myometrium 230
 myoma extraction 231
 uterine artery occlusion 231–2

- postoperative adhesions 234–5
 postoperative course 234
 preoperative evaluation 227
 preoperative treatment 227–8
 safety 245–6
 hemorrhage risk 234
 second-look laparoscopy 232–4
 technical principles 228–9
see also myomectomy
- laparoscopic presacral neurectomy (LPSN) 61
- laparoscopic sacrocolpexy 289–302
 cervical/uterine sacrofixation 289–96
 complications 297–300
 vaginal vault sacrofixation 296–7
- laparoscopic subtotal hysterectomy (LASH) 251–61
 complications 258–60
 results 257
 surgical procedure 251–6
see also laparoscopic hysterectomy
- laparoscopic supracervical hysterectomy (LSH) 94
see also laparoscopic hysterectomy
- laparoscopic surgery
 fully integrated operating room 415
 human assistance 409
 instrument manipulation 414–15
 laparoscope holding systems 409–14
 active holders 413–14
 LapMan® project 409–12
 passive holders 412–13
 robotically assisted surgery 417–20
 initial experience 417–18
 preoperative planning 418
 surgical training 418
 technique 418–20
see also specific procedures
- laparoscopy-assisted hysterectomy *see* laparoscopic hysterectomy
- laparoscopy-assisted vaginal hysterectomy (LAVH) 93–4
 definition 94
see also laparoscopic hysterectomy
- LapMan® project 409–12
 advantages 411
 indications in gynecological surgery 412
 solo surgery concept 412
- laser photocoagulation of the endometrium 535
- laser treatment 22–7
 CO₂ laser 25–6
 endometriosis 38, 44–5, 47–53, 58–9
 versus ovarian cystectomy 47–53
 energy, power and power density 24–5
 LUNA (laser uterine nerve ablation) 11, 58–9
 Nd:YAG laser 27
 physical effects on tissue 23–4
 thermal effects 24
- lateral ligaments 5
- leiomyomas *see* myomas
- LUNA (laser uterine nerve ablation) 11, 58–9
- lymph nodes 12–13
- lymphadenectomy 12–14, 363–7
 cervical cancer 360–2, 375–80
 aortic lymphadenectomy 378–80
 pelvic lymphadenectomy 375–8
 complications 364–5
 endometrial cancer 359, 369–72
 indications for 371–2
 rationale 370
 which nodes to remove 370
 technique 363–4
 vaginal cancer 359–60
- McCall culdoplasty 102–4
- magnetic resonance imaging (MRI)
 borderline ovarian tumor diagnosis 314
 endometrial cancer evaluation 369
 ovarian cyst evaluation 197
- matrix metalloproteinases (MMPs) 37
- Mayer–Rokitansky–Küster–Hauser syndrome 484–9
- menorrhagia 527
- mesosalpinx 3
- metastases, port-site 443–4
- methotrexate (MTX) 162, 165, 166–7
 adjunctive therapy 184
 as first-line therapy 171–3
 failure of treatment 172–3
 follow-up 172
 injection at laparoscopy 172
 injection under ultrasonic guidance 171
 systemic treatment 172
 as second-line therapy 173–6
 future fertility prognosis 177
 mifepristone addition 176
 versus conservative surgical treatment 185
- microsalingoscopy 123–5
 results 129
- microsurgery *see* laparoscopic microsurgery
- microwave endometrial ablation (MEA) 533, 539–40
see also endometrial ablation
- mifepristone 176
- mobilization
 bladder 98
 uterine manipulator 270–1, 273, 279–80
- morcellation 101–2, 286
- morcellators 20–1
- mucous cysts of the cervix 477, 478
- Müllerian duct anomalies 464, 483–504
 classification 485
 development anomalies 484–93
 absence 484–9
 incomplete development 489–93
 embryology 483–4
 fusion anomalies 493–504
 lateral 493–501
 vertical 502–4

- myelomeningocele 399
myolysis *see* laparoscopic myolysis
myoma holder 20
myomas 465, 475, 476
 assisted reproduction and 239–40
 classification 516
 preoperative evaluation 227
 preoperative treatment 227–8, 273, 515
 recurrence after laparoscopic myomectomy 235, 248
 see also myomectomy
myomectomy 479–80
 efficiency 246–8
 for infertility 239–40
 outcome 240
 indications for 239
 safety 245–6
 see also hysteroscopic myomectomy; laparoscopic myomectomy
- Nd:YAG laser 23–4, 27
needle holders 20
needle placement 1–2
NovaSure™ electrocoagulation system 542–3
- obstructive uropathies, fetal 397–8
obturator artery 6
obturator nerve 10
‘one-stop fertility clinic’ 135–6
oocyte cryopreservation 334–5
 in vitro maturation 334–5
 mature oocyte 334
oophorectomy 202–6
operating laparoscope 27
ovarian artery 6
ovarian cancer 362–3
 see also borderline ovarian tumors (BOT)
ovarian cysts 195
 borderline tumor risk 206
 laparoscopic oophorectomy 202–6
 patient selection 208
 preoperative evaluation 195–8
 CA125 195–7
 CT 197–8
 MRI 197–8
 ultrasound 195
 see also cystectomy, ovarian
ovarian drilling 126–7, 136–8
 results 129
ovarian plexus 10
ovarian pregnancy 164–5
ovarian suspension *see* ovarian transposition
ovarian tissue cryopreservation 316, 344–7, 355–7
 fragments of cortical ovarian tissue 335–7
 freezing procedures 345, 346
 oncological indications 336–7
 ovarian biopsy sample 344–5
 primordial follicles 337
 isolation procedure 346–7
 reimplantation of ovarian tissue 323–30, 357
 thawing procedures 345, 346
 whole ovary 337–8, 345–6
ovarian transposition 350–2
 indications for 351–2
 ovarian function and fertility prognosis 352
 surgical technique 350, 355
ovarian tumors *see* borderline ovarian tumors (BOT);
 ovarian cancer
ovaries 119
 endometriosis 43–53, 137
 indications for surgery 44
 laser vaporization 44–5, 47–53
 ovarian cystectomy 45–53
 transvaginal laparoscopy 136
 radiotherapy effects on function 349–50
 chemotherapy and 350
 see also ovarian cancer; ovarian cysts; ovarian tissue cryopreservation
ovulation 119–20
- pain
 anatomic basis 10–11
 dysmenorrhea 55
 dyspareunia 55
 endometriosis and 55
 therapeutic applications 11–12
 uterine suspension 56
papilloma 135
paratubal cyst 120
paravaginal repair 285–6
parietal disinfection 278
patient preparation *see* preoperative preparation
pelvic congestion syndrome 56
pelvic pain *see* pain
pelvis
 cellular tissue 4–5
 lymph nodes 12–13
periadnexal adhesions 146–7
perineal pain *see* pain
peritoneal implants 310
peritoneal lavage 286
peritoneum 3–4
 rectal 8
persistent trophoblast
 diagnosis 173
 prevalence 174
 treatment 174–5
phimosis 121
phlebitis prevention 286
photocoagulation of the endometrium 535
placental anastomoses 395–6
placental chorioangioma 399
pneumoperitoneal needle placement 1–2
pneumothorax 444

- polycystic ovarian syndrome (PCOS) 127, 129
 polymalformative syndromes 393, 394
 polyps 125, 474–8
 removal 479
 port-site metastases 443–4
 postablation tubal sterilization syndrome 558
 postmenopausal bleeding evaluation 462–3
 pregnancy
 undesired 557
 uterine perforation 557
 see also ectopic pregnancy; fertility prognosis following
 treatment; fetal endoscopy
 preoperative preparation
 endometrial ablation 534–5
 fertiloscopy 116–17
 prolapse treatment 277–8
 robotically assisted surgery 418
 total laparoscopic hysterectomy 96
 see also installation
 prevesical neurectomy 61
 primordial follicle cryopreservation 337
 isolation technique 346–7
 probe
 intestinal 20, 21
 second-puncture 28
 third-puncture 28
 prolapse 277–87, 289–302
 operating field organization 279–80
 intestinal fixation 280
 manipulator positioning 279–80
 uterosacral ligament identification 280
 operating strategy 280–1
 operating technique 281–6
 anterior prosthesis fixation 284
 Burch bladder neck suspension 286
 cervical/uterine sacrofixation 289–96
 culdoplasty 283
 hysterectomy 282–3
 opening the space of Retzius 285
 paravaginal repair 285–6
 peritonealization 284, 285, 286
 posterior prosthesis fixation 283
 promontofixation 284–5
 promontory dissection 281–2
 rectovaginal space dissection 282
 vaginal vault 296–7
 patient preparation 277–8
 installation 278
 postoperative care 286–7
 preoperative assessment 277, 278–9
 trocar positioning 279
 urinary function evaluation 277
 promontofixation 284–5
 promontory dissection 281–2
 pseudomyxoma peritonei 316
 pudendal nerve 11
 surgical liberation 11–12
 pudendal plexus 9, 10
 radiotherapy
 effects on ovarian function 349–50
 endometrial cancer management 370–1
 ovarian transposition before 350–2
 indications for 351–2
 results 352
 surgical technique 350, 355
 rectal arteries 6
 rectal injury 433–4
 see also bowel injury
 rectal ligament 5
 rectovaginal adenomyosis 11, 63–73
 classification 66–7
 diagnosis 65–6
 hormonal dependence 65
 retrocervical and retroperitoneal disease 63–4
 shaving surgery 67–71
 complications 72
 recurrence 72–3
 see also endometriosis
 rectovaginal space dissection 282
 rectum 8–9
 resectoscope 454
 bipolar 456
 robotically assisted gynecological surgery 417–20
 initial experience 417–18
 preoperative planning 418
 surgical training 418
 technique 418–20
 sacral arteries 6
 sacral plexus 9
 sacrococcygeal teratoma 399
 sacrofixation
 cervical/uterine 289–96
 vaginal vault 296–7
 see also prolapse
 sagittal ligaments 5
 saline infusion sonohysterography (SIS) 457–8
 contraindications 458
 indications for 458
 see also hysterosonography
 salpingectomy 149
 before IVF–embryo transfer 151
 contraindications 183
 ectopic pregnancy risk and 158
 ectopic pregnancy treatment 159, 183
 results 185
 versus conservative surgical treatment 184–5
 salpingolysis 152, 153
 salpingoscopy 118, 121–3
 microsalpingoscopy 123–5
 results 129

- salpingostomy 147–8
 contraindications 184
- salpingotomy 181–3
 future fertility prognosis 176–7
 indications for 184–5
 versus medical treatment 185
 versus salpingectomy 184–5
 results 185
- scar dehiscence 219–20
 laparoscopic repair 220–5
- Schauta operation 380
- Schauta–Amreich operation 380
- Schauta–Stoekel operation 380–4
 laparoscopic step 381
 transvaginal step 381–4
- scissors 19
- second-puncture probe 28
- sentinel node assessment 386–7
- septate uterus *see* uterine septum
- septate vagina *see* vaginal septum
- septostomy 396–7
- shaving surgery, endometriosis 67–71
 complications 72
 recurrence 72–3
- smoke evacuation 28
- sonohysterography *see* hysterosonography
- space of Retzius opening 285
- sperm migration test 465
- spleen injury 444–5
- sterilization, tubal 549–52
 postablation tubal sterilization syndrome 558
- stomach injury 428–9
- STOP® system 551–2
- stress incontinence 14–15
- subcutaneous emphysema 426
- subovarian adhesions 32, 33
- suturing 200–1, 230–1
- synechiae, intrauterine 464
 see also adhesions
- synthetic material complications 445
- telescopes 17
- tension-free vaginal tape (TVT) 14, 15
- Thermablate endometrial ablation system 538
- ThermaChoice® thermal balloons 536–7
- thermal injuries 557
- third-puncture probes 28
- torus excision 59
- torus uterinus ablation 11
- total laparoscopic hysterectomy (TLH) 93–4
 definition 94
 technique 96–104
 bladder mobilization 98
 cervicovaginal attachment division 101
 cystoscopy 104
 exploration 97
 incisions 96
 morcellation 101–2
 preoperative preparation 96
 retroperitoneal dissection 97
 skin closure 104
 underwater examination 104
 upper uterine blood supply 98–9
 ureteral dissection 97–8
 uterine vessel ligation 99–101
 vaginal preparation 96
 vaginal vault closure and suspension 102–4
 see also laparoscopic hysterectomy
- transabdominal cervicoisthmic cerclage (TCC) 403
 see also abdominal cerclage
- transcervical endometrial resection (TCER) 527–32, 535
 instruments 527–8
 technique 528–30
- transobturator tape (TOT) 14, 15
- transvaginal laparoscopy 133–8
 evaluation 134–5
 instruments 133, 136
 ‘one-stop fertility clinic’ 135–6
 operative procedure 136–8
 endometriosis 136
 ovarian capsule drilling 136–8
 technique 133
- trichloroacetic acid, endometrial ablation 543
- trocars 17–18
 insertion 1–2
 ancillary placement 2–3
 laparoscopic microsurgery 188
 secondary trocar injury 431–2
- tubal anastomosis, types of 188
 see also laparoscopic microsurgical tubal anastomosis
- tubal occlusion 143, 147–9
 classification 143, 144
 scoring systems 144, 145
- tubal sterilization 549–52
- tubal surgery
 prognostic factors 143–7
 ampullary dilatation 144
 ampullary fold preservation 144–6
 ciliation index 146
 endometriosis 147
 fibrosis 146
 intratubal adhesions 146
 periadnexal adhesions 146–7
 tubal mucosa 146
 techniques 147–9
- tuberculosis
 genital 145
 uterine 478
- tubo–cornual anastomosis 188
- twin-to-twin transfusion syndrome (TTTS) 393–7

- ultrasonography
 - borderline ovarian tumor diagnosis 311–12
 - methotrexate injection guidance 171
 - ovarian cyst evaluation 195
 - see also* hysterosonography
- umbilical artery 5
- unicornuate uterus 489
 - with rudimentary horn 493
- ureter 7–8, 9
 - blood vessel relationships 6
 - dissection 271
 - endometriosis 77–82
 - diagnosis 78
 - left versus right 81–2
 - prevalence 77, 81
 - surgical treatment 78–80, 82
 - symptoms 77–8
 - injury 437–41
 - diagnosis 438
 - following subtotal laparoscopic hysterectomy 258–60
 - location 8
 - management 438–9
 - prevention 439–41
 - pelvic organ relationships 7
 - ureterolysis 78–9, 82
- urinary tract injury 111, 430–1, 432, 436–41
- uterine artery *see* uterine vessels
- uterine cavity
 - adhesions 464, 507–14
 - classification 507
 - diagnosis 507
 - etiopathogenesis 507
 - treatment 508–14
 - distension 453, 473–4
 - foreign bodies 468
 - hysteroscopic examination 474–7
- uterine introducer 115, 118
- uterine manipulator 270–1, 273, 279–80
 - laparoscopic microsurgery 188
 - positioning 279–80
- uterine perforation 554
 - during subsequent pregnancy 557
- uterine polyps 125
- uterine sacrofixation 289–96
 - see also* prolapse
- uterine septum 476, 478, 493–8
 - complete 497
 - partial 496–7
- uterine suspension 56–8
 - complications 57
 - indications for 56
 - operative technique 56–7
 - results 57–8
- uterine vessels 5–6
 - ligation 99–101
 - occlusion with laparoscopic myomectomy 231–2
- uterosacral ligaments 5
 - identification 280
- uterus didelphys 498
- uterus septus *see* uterine septum
- vagina
 - atresia 502
 - closure 272
 - disinfection 278
 - estrogen treatment 278
 - paravaginal repair 285–6
 - reconstruction 484–9
- vaginal cancer 359–60
- vaginal septum 498–9
 - transverse 502–4
 - with uterine septum 493
- vaginal vault prolapse 289
 - sacrofixation 296–7
- vascular injury 426–8, 441–2
 - diagnosis 427, 428, 441
 - epigastric vessel perforation 431–2
 - management 427, 428, 441–2
 - prevention 427–8
 - see also* hemorrhage
- venous air embolism 442, 555–6
- venous relationships 7
- Veress needle 116, 117
- vesical ligament 5
- vesicouterine ligaments 5
- visceral fascia 4, 5
- visceral ligaments 4–5
- Wolffian ducts 483–4
- zygote intrafallopian transfer (ZIFT) 465

Atlas of OPERATIVE LAPAROSCOPY AND HYSTEROSCOPY

Third Edition

This new edition of one of the modern classics of gynecological surgery provides an extensive and beautifully illustrated guide to laparoscopic and hysteroscopic techniques. The book has been extensively revised and updated since publication of the second edition in 2001. There are few texts that so adequately provide in-depth information on minimally invasive gynecologic surgery.

The coverage is comprehensive, including extensive sections on gynecological oncology and urogynecology. Basic principles are illustrated such as the operation aspects of instrumentation. Complications are highlighted with authoritative guidance on how to avoid and manage them.

The future of gynecological surgery will definitely be in the realm of minimally invasive endoscopic surgery. All gynecologists need to be knowledgeable on this important and ever-improving field. This beautiful, informative and thorough work of reference provides both practicing surgeon and trainee with an atlas, a textbook of gynecology and a surgical manual.

ABOUT THE EDITOR

Jacques Donnez MD PhD is Professor of Gynecology at the Catholic University of Louvain, Cliniques Universitaires St-Luc, Brussels, Belgium

informa
healthcare

www.informahealthcare.com

ISBN 0-415-38415-X



9 780415 384155