


THIRD EDITION

Cunningham and Gilstrap's

OPERATIVE OBSTETRICS



YEOMANS

HOFFMAN

GILSTRAP, III

CUNNINGHAM

**Mc
Graw
Hill**
Education

NOTICE

Medicine is an ever-changing science. As new research and clinical experience broaden our knowledge, changes in treatment and drug therapy are required. The authors and the publisher of this work have checked with sources believed to be reliable in their efforts to provide information that is complete and generally in accord with the standards accepted at the time of publication. However, in view of the possibility of human error or changes in medical sciences, neither the authors nor the publisher nor any other party who has been involved in the preparation or publication of this work warrants that the information contained herein is in every respect accurate or complete, and they disclaim all responsibility for any errors or omissions or for the results obtained from use of the information contained in this work. Readers are encouraged to confirm the information contained herein with other sources. For example and in particular, readers are advised to check the product information sheet included in the package of each drug they plan to administer to be certain that the information contained in this work is accurate and that changes have not been made in the recommended dose or in the contraindications for administration. This recommendation is of particular importance in connection with new or infrequently used drugs.

DEDICATION

THIRD EDITION

Cunningham and Gilstrap's
**OPERATIVE
OBSTETRICS**

EDWARD R. YEOMANS, MD

BARBARA L. HOFFMAN, MD

LARRY C. GILSTRAP III, MD

F. GARY CUNNINGHAM, MD



New York Chicago San Francisco Lisbon London Madrid Mexico City
Milan New Delhi San Juan Seoul Singapore Sydney Toronto

THIRD EDITION

Cunningham and Gilstrap's Operative Obstetrics, Third Edition

Copyright © 2017, 2002 by The McGraw-Hill Companies, Inc. All rights reserved. Printed in China. Except as permitted under the United States copyright Act of 1976, no part of this publication may be reproduced or distributed in any form or by any means, or stored in a data base or retrieval system, without the prior written permission of the publisher.

Copyright © 1995 Appleton & Lange

1 2 3 4 5 6 7 8 9 DSS 21 20 19 18 17

ISBN 978-0-07-184906-7

MHID 0-07-184906-8

This book was set in Adobe Garamond Pro by Aptara, Inc.

The editors were Andrew Moyer and Christie Naglieri.

The production supervisor was Richard Ruzicka.

The cover designer was Dreamit, Inc.

The index was prepared by Sandi Schroeder.

RR Donnelley was printer and binder.

This book is printed on acid-free paper.

Library of Congress Cataloging-in-Publication Data

Names: Gilstrap, Larry C., III, editor. | Cunningham, F. Gary, editor. |

Yeomans, Edward R., editor. | Hoffman, Barbara L., editor.

Title: Cunningham and Gilstrap's Operative Obstetrics / [edited by] Larry C. Gilstrap III, F. Gary

Cunningham, Edward R. Yeomans, Barbara L. Hoffman.

Other titles: Operative obstetrics (Gilstrap)

Description: 3rd edition. | New York : McGraw-Hill Education, Medical

Publishing Division, [2017] | Includes bibliographical references and index.

Identifiers: LCCN 2016016706 | ISBN 9780071849067 (hardcover : alk. paper) |

ISBN 0071849068 (hardcover : alk. paper)

Subjects: | MESH: Obstetric Surgical Procedures—methods | Pregnancy

Complications—surgery | Female Urogenital Diseases—surgery

Classification: LCC RG725 | NLM WQ 400 | DDC 618.8—dc23 LC record available at

<https://lccn.loc.gov/2016016706>

DEDICATION

Each day around the world, young doctors in residency training present to work with weighty goals. In this edition of *Cunningham and Gilstrap's Operative Obstetrics*, we acknowledge and celebrate their daily efforts to provide safe, compassionate, evidence-based care. As they strengthen their clinical foundation, their insightful questions sharpen *our* clinical skills. As mentors, we attempt to logically delineate the anatomy, physiology, and pathology of a given problem. Indeed, many of the nuances in this text find their origins in these discussions. Thus, we applaud all residents' academic curiosity and drive to improve their craft. In this role, they make us stronger physicians and better teachers, and we are grateful.

Edward R. Yeomans, MD
Barbara L. Hoffman, MD
Larry C. Gilstrap, III, MD
F. Gary Cunningham, MD

EDITORS

Edward R. Yeomans, MD

Professor and Chairman
Robert H. Messer, M.D. Endowed Chair
Department of Obstetrics and Gynecology
Texas Tech University Health Sciences Center

Barbara L. Hoffman, MD

Professor, Department of Obstetrics and Gynecology
University of Texas Southwestern Medical Center at Dallas
Parkland Health and Hospital System

Larry C. Gilstrap, III, MD

Executive Director, American Board of Obstetrics and
Gynecology

F. Gary Cunningham, MD

Beatrice & Miguel Elias Distinguished Chair in Obstetrics and
Gynecology
Professor, Department of Obstetrics and Gynecology
University of Texas Southwestern Medical Center at Dallas
Parkland Health and Hospital System

Artists

Lewis Calver, MS, CMI, FAMI

Associate Professor, Department of Obstetrics and Gynecology
University of Texas Southwestern Medical Center at Dallas

Marie Sena

Graduate, Biomedical Communications Graduate Program
University of Texas Southwestern Medical Center at Dallas

CONTRIBUTORS

April A. Bailey, MD

Assistant Professor, Department of Radiology
Assistant Professor, Department of Obstetrics and Gynecology
University of Texas Southwestern Medical Center at Dallas
Chapter 5: Perioperative Imaging

Sunil Balgobin, MD

Assistant Professor, Department of Obstetrics and Gynecology
University of Texas Southwestern Medical Center at Dallas
Chapter 28: Urologic and Gastrointestinal Injuries

Michael A. Belfort, MBBCH, DA (SA), MD (Cape Town), PhD, FRCSC, FRCOG

Ernst W. Bertner Chairman and Professor, Department
of Obstetrics and Gynecology
Professor, Department of Surgery
Professor, Department of Anesthesiology
Baylor College of Medicine
Obstetrician and Gynecologist-in-Chief
Texas Children's Hospital
Chapter 16: Fetal Therapy

Lubna Chohan, MD

Associate Professor, Department of Obstetrics
and Gynecology
Baylor College of Medicine
Chapter 14: Adnexal Masses

Marlene M. Corton, MD, MSCS

Director, Anatomical Education and Research
Professor, Department of Obstetrics and Gynecology
University of Texas Southwestern Medical Center at Dallas
Chapter 3: Anatomy

Geoffrey W. Cundiff, MD, FACOG, FACS, FRCSC

Dr Victor Gomel Professor of Obstetrics & Gynaecology
Professor & Head, Department of Obstetrics & Gynaecology
University of British Columbia
Chapter 4: Incisions and Closures

F. Gary Cunningham, MD

Beatrice & Miguel Elias Distinguished Chair in Obstetrics
and Gynecology
Professor, Department of Obstetrics and Gynecology
University of Texas Southwestern Medical Center at Dallas
Parkland Health and Hospital System
Chapter 1: Needles, Sutures, and Knots
Chapter 2: Surgical Instruments
Chapter 24: Shoulder Dystocia
Chapter 26: Peripartum Hysterectomy
Chapter 27: Placenta Previa and Morbidly Adherent Placenta
Chapter 30: Genital Tract Lacerations and Hematomas

Jimmy Espinoza, MD, MSc, FACOG

Associate Professor
Department of Obstetrics and Gynecology
Division of Maternal-Fetal Medicine
Baylor College of Medicine and Texas Children's Hospital
Chapter 13: Invasive Prenatal Diagnostic Procedures

Rajiv B. Gala, MD, FACOG

Residency Program Director
Vice-Chairman, Department of Obstetrics and Gynecology
Ochsner Clinic Foundation
Associate Professor of Obstetrics and Gynecology,
University of Queensland
Ochsner Clinical School
Chapter 8: Ectopic Pregnancy

Larry C. Gilstrap III, MD

Executive Director, American Board of Obstetrics and
Gynecology
Chapter 29: Management of Postpartum Hemorrhage

J. Seth Hawkins, MD

Assistant Professor, Department of Obstetrics and Gynecology
University of Texas Southwestern Medical Center at Dallas
Chapter 11: Lower Genital Tract Procedures

Joy L. Hawkins, MD

Professor, Department of Anesthesiology
Director of Obstetric Anesthesia
University of Colorado School of Medicine
Chapter 19: Anesthesia for the Pregnant Woman

Barbara L. Hoffman, MD

Professor, Department of Obstetrics and Gynecology
University of Texas Southwestern Medical Center at Dallas
Parkland Health and Hospital System
Chapter 2: Surgical Instruments

Clark T. Johnson, MD MPH

Assistant Professor, Division of Maternal Fetal Medicine
Department of Gynecology and Obstetrics
Johns Hopkins School of Medicine
Chapter 6: Clinical Simulation

Donna D. Johnson, MD

Lawrence L. Hester Professor
Chair, Department of Obstetrics and Gynecology
Medical University of South Carolina
Chapter 25: Cesarean Delivery

Kimberly Kenton, MD, MS

Professor, Obstetrics & Gynecology and Urology
 Chief, Female Pelvic Medicine & Reconstructive Surgery
 Northwestern University Feinberg School of Medicine
*Chapter 20: Episiotomy and Obstetric Anal Sphincter
 Lacerations*

Kimberly A. Kho, MD, MPH, MSCS

Director, Minimally Invasive Gynecologic Surgery Fellowship
 Associate Professor, Department of Obstetrics and
 Gynecology
 University of Texas Southwestern Medical Center at Dallas
Chapter 15: Diagnostic and Operative Laparoscopy

Stephanie N. Lin, MD

Visiting Instructor, Department of Obstetrics and Gynecology
 University of Utah
Chapter 7: Critical Illness in Pregnancy

Stephanie R. Martin, DO

Director, Southern Colorado Maternal Fetal Medicine
 Director, Maternal Fetal Medicine/Centura Southstate
 Visiting Associate Clinical Professor
 Department of Obstetrics and Gynecology
 University of Colorado School of Medicine
Chapter 7: Critical Illness in Pregnancy

Joan M. Mastrobattista, MD

Professor, Department of Obstetrics and Gynecology
 Division of Maternal-Fetal Medicine
 Baylor College of Medicine
 Ultrasound Clinic Chief, Texas Children's Hospital Pavilion
 for Women
Chapter 13: Invasive Prenatal Diagnostic Procedures

Hector Mendez-Figueroa, MD

Assistant Professor, Division of Maternal-Fetal Medicine
 Department of Obstetrics and Gynecology
 University of Texas Medical School at Houston
Chapter 17: Trauma in Pregnancy

Manju Monga, MD

Professor, Department of Obstetrics and Gynecology
 Vice Chair of Clinical Affairs, Obstetrics and Gynecology
 Baylor College of Medicine
Chapter 14: Adnexal Masses

Margaret Mueller, MD

Assistant Professor, Obstetrics & Gynecology
 Female Pelvic Medicine & Reconstructive Surgery
 Northwestern University Feinberg School of Medicine
*Chapter 20: Episiotomy and Obstetric Anal Sphincter
 Lacerations*

John Owen, MD, MSPH

Bruce A. Harris Jr. Endowed Professor of Obstetrics and
 Gynecology
 Maternal-Fetal Medicine
 Department of Obstetrics and Gynecology
 University of Alabama at Birmingham
Chapter 9: First- and Second-Trimester Pregnancy Termination

Anna M. Powell, MD

Clinical Instructor, Department of Obstetrics and Gynecology
 Medical University of South Carolina
Chapter 12: Treatment of Lower Genital Tract Infections

Susan M. Ramin, MD

Professor and Vice Chair of Education
 Henry and Emma Meyer Chair in Obstetrics and Gynecology
 Department of Obstetrics and Gynecology
 Baylor College of Medicine
Chapter 16: Fetal Therapy

Dwight J. Rouse, MD, MSPH

Professor, Department of Obstetrics & Gynecology
 Alpert Medical School
 Professor of Epidemiology
 School of Public Health
 Brown University
Chapter 17: Trauma in Pregnancy

Andrew J. Satin, MD

The Dorothy Edwards Professor of Gynecology and
 Obstetrics
 Professor and Director of Gynecology and Obstetrics
 Johns Hopkins School of Medicine
 Johns Hopkins Medicine
Chapter 6: Clinical Simulation

John O. Schorge, MD, FACOG, FACS

Chief of Gynecology and Gynecologic Oncology
 Associate Professor, Department of Obstetrics and
 Gynecology
 Massachusetts General Hospital–Harvard Medical School
Chapter 10: Gestational Trophoblastic Disease

Alireza A. Shamsirsaz, MD

Associate Professor
 Department of Obstetrics and Gynecology
 Baylor College of Medicine
 Associate, Department of Surgery
Chapter 16: Fetal Therapy

David E. Soper, MD

J. Marion Sims Professor, Department of Obstetrics and
 Gynecology
 Director, Division of Obstetric and Gynecologic Specialists
 Medical University of South Carolina
Chapter 12: Treatment of Lower Genital Tract Infections

Gretchen S. Stuart, MD, MPHTM

Associate Professor
 Director Division of Family Planning and Fellowship in Family
 Planning
 Department of Obstetrics and Gynecology
 University of North Carolina School of Medicine
Chapter 33: Puerperal Sterilization

Julia Timofeev, MD

Assistant Professor, Department of Gynecology and Obstetrics
 The Johns Hopkins University School of Medicine
Chapter 31: Uterine Inversion

Diane M. Twickler, MD

Dr. Fred Bonte Professorship in Radiology
 Professor, Department of Radiology and Department of
 Obstetrics and Gynecology
 University of Texas Southwestern Medical Center at Dallas
 Medical Director of Obstetrics and Gynecology
 Ultrasonography
 Parkland Health and Hospital System
Chapter 5: Perioperative Imaging

C. Edward Wells, MD

Professor, Department of Obstetrics and Gynecology
 University of Texas Southwestern Medical Center at Dallas
Chapter 18: Perioperative Considerations

Edward R. Yeomans, MD

Professor and Chairman
 Robert H. Messer, M.D. Endowed Chair
 Department of Obstetrics and Gynecology
 Texas Tech University Health Sciences Center
Chapter 21: Vaginal Breech Delivery
Chapter 22: Delivery of Twin Gestations
Chapter 23: Operative Vaginal Delivery

Kevin C. Worley, MD

Associate Professor, Department of Obstetrics and
 Gynecology
 Associate Residency Program Director
 University of Texas Southwestern Medical Center at Dallas
Chapter 32: Postoperative Complications

Christopher Zahn, MD

Vice President, Practice Activities: American College of
 Obstetricians and Gynecologists
 Professor, Department of Obstetrics and Gynecology
 Uniformed Services University of the Health Sciences
Chapter 31: Uterine Inversion

CONTENTS

Preface	xiii
---------------	------

SECTION 1

GENERAL CONSIDERATIONS

1. Needles, Sutures, and Knots.....	2	5. Perioperative Imaging	63
2. Surgical Instruments.....	15	6. Clinical Simulation.....	82
3. Anatomy	27	7. Critical Illness in Pregnancy	91
4. Incisions and Closures	49		

SECTION 2

ANTEPARTUM

8. Ectopic Pregnancy.....	112	14. Adnexal Masses.....	224
9. First- and Second-Trimester Pregnancy Termination	133	15. Diagnostic and Operative Laparoscopy.....	240
10. Gestational Trophoblastic Disease.....	156	16. Fetal Therapy.....	260
11. Lower Genital Tract Procedures	170	17. Trauma in Pregnancy	276
12. Treatment of Lower Genital Tract Infections.....	189	18. Perioperative Considerations.....	291
13. Invasive Prenatal Diagnostic Procedures	202	19. Anesthesia for the Pregnant Woman.....	307

SECTION 3

INTRAPARTUM

20. Episiotomy and Obstetric Anal Sphincter Lacerations.....	320	25. Cesarean Delivery.....	403
21. Vaginal Breech Delivery.....	335	26. Peripartum Hysterectomy.....	419
22. Delivery of Twin Gestations.....	350	27. Placenta Previa and Morbidly Adherent Placenta.....	435
23. Operative Vaginal Delivery.....	363	28. Urologic and Gastrointestinal Injuries.....	454
24. Shoulder Dystocia.....	389		

SECTION 4

POSTPARTUM

29. Management of Postpartum Hemorrhage.....	466	32. Postoperative Complications.....	503
30. Genital Tract Lacerations and Hematomas.....	482	33. Puerperal Sterilization.....	524
31. Uterine Inversion.....	493	Index.....	537

PREFACE

GENERAL CONSIDERATIONS

This edition of *Cunningham and Gilstrap's Operative Obstetrics* has been extensively and strategically reorganized for the busy practitioner. Once again, we emphasize the science-based underpinnings of clinical obstetrics. To accomplish these goals, the text has been updated with more than 3145 literature citations through 2016. Moreover, there are nearly 674 figures that include sonograms, magnetic resonance images, photographs, micrographs, and data graphs, most in vivid color. All of the original artwork was rendered by our own medical illustrators.

In this edition, as before, we continue to incorporate contemporaneous guidelines from professional and academic organizations such as the American College of Obstetricians and Gynecologists, the Society for Maternal–Fetal Medicine, and

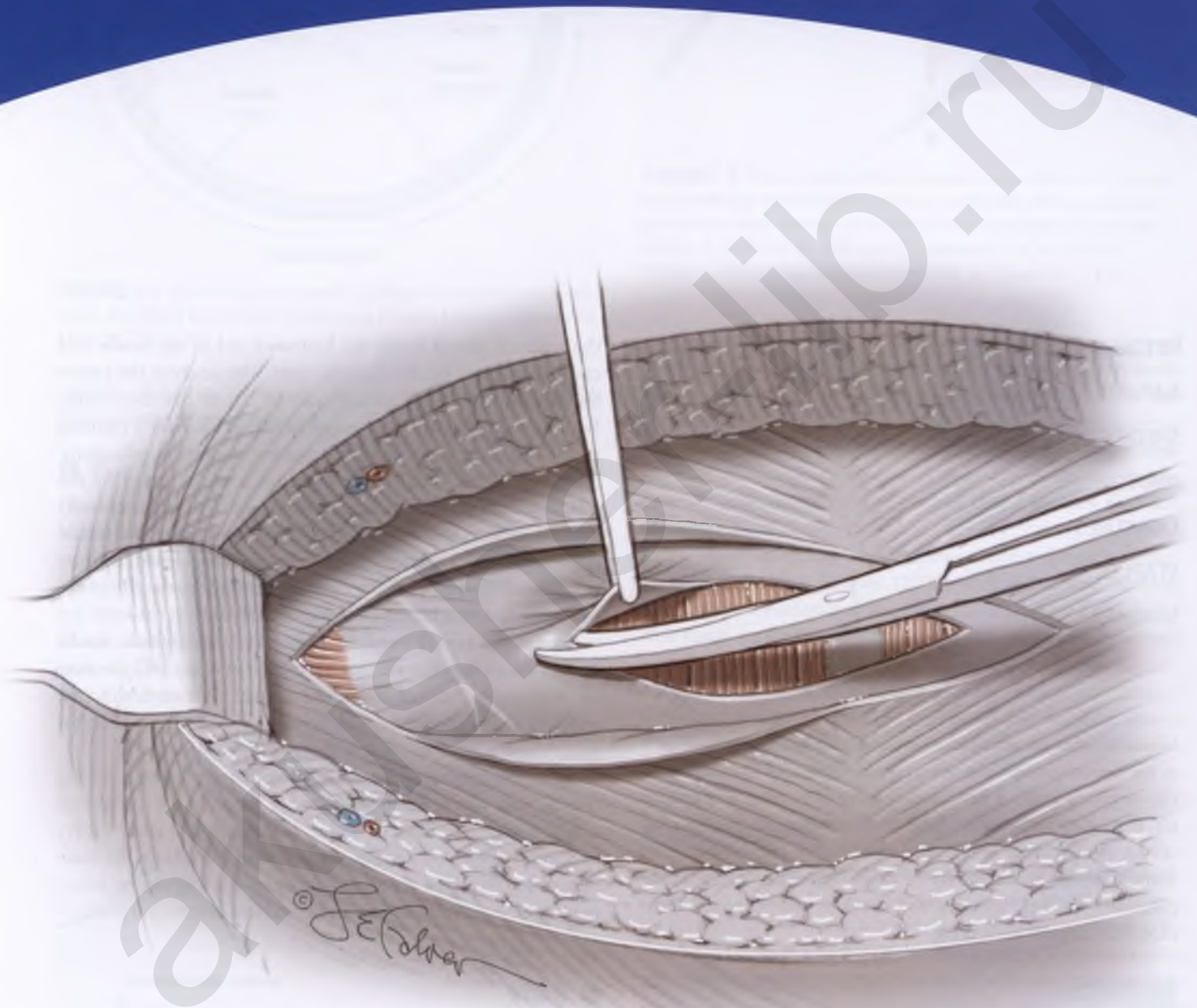
the Centers for Disease Control and Prevention, among others. Many of these data are distilled into newly constructed tables, in which information has been arranged in an easy read-and-use format. In addition, several diagnostic and management algorithms have been added to guide practitioners. While we strive to cite numerous sources to provide multiple evidence-based options for such management schemes, we also include clinical experiences drawn from large obstetrical services. In toto, the strength of each contributor has added to create the sum total of our academic endeavor.

Edward R. Yeomans
Barbara L. Hoffman
Larry C. Gilstrap, III
F. Gary Cunningham

akushner-lib

SECTION 1

GENERAL CONSIDERATIONS



The skin is the largest organ of the body and serves as a protective barrier against the external environment. It is composed of two main layers: the epidermis and the dermis. The epidermis is the outermost layer and is composed of several layers of cells, including the stratum corneum, stratum granulosum, stratum spinosum, and stratum basale. The dermis is the layer beneath the epidermis and is composed of connective tissue, blood vessels, and nerves. The skin also contains various structures such as hair, sweat glands, and sebaceous glands. Understanding the anatomy and physiology of the skin is essential for performing surgical procedures and for managing skin conditions.

The skin is a complex organ that plays a vital role in protecting the body from the environment. It is composed of two main layers: the epidermis and the dermis. The epidermis is the outermost layer and is composed of several layers of cells, including the stratum corneum, stratum granulosum, stratum spinosum, and stratum basale. The dermis is the layer beneath the epidermis and is composed of connective tissue, blood vessels, and nerves. The skin also contains various structures such as hair, sweat glands, and sebaceous glands. Understanding the anatomy and physiology of the skin is essential for performing surgical procedures and for managing skin conditions.

Needles, Sutures, and Knots

NEEDLES	2
SUTURES	4
SPECIFIC SUTURE TYPES	6
KNOTS	9
LIGATURES	12
STAPLES	13
SUMMARY	13

Mastering the use of needles, sutures, and instruments, as well as the technique of knot tying, is the technical foundation of the surgeon's craft. A bewildering array of needles and sutures are available. Some offer distinct advantages in specific situations, while others are simply competitive equivalents. This chapter describes the variety of available needles and sutures, guidelines for their selection and use, and principles and techniques of surgical knot tying.

NEEDLES

Characteristics of surgical needles include their attachment to the suture, the shape of the tip, the suture lever in tissue, and the curve of the needle. Surgical needles consist of three structural parts: the point or tip, the body, and the swage or eye. Their specific design depends on their intended surgical use and each variation has merits and disadvantages.

■ Swage

Three types of eye are commonly used in surgery: swaged, controlled release or "pop-off," and open. With a swaged needle,

the suture is placed inside the hollowed end of the needle and crimped in place by the manufacturer. This anchors the suture to the needle, and the suture must be cut to free the needle. Because of this security, a swaged needle is ideal for a running suture line and thus is often selected for obstetric applications. The swaged end is flattened to permit a secure grasp by the needle driver. Therefore, during suturing, the swage is ideally grasped rather than the rounder needle body to avoid lateral needle rotation. The diameter of the swaged needle end is larger than that of the rest of the needle and determines the size of the suture tract through tissue (Bennett, 1988).

Controlled-release needles differ from a swaged-on needle in that they allow the surgeon to release or "pop off" the needle with a sharp tug of the needle holder. This saves the time required to cut the suture with scissors. This design is used for interrupted sutures or for vascular pedicle ligation.

Last, the open-eyed needle is fashioned similar to a sewing needle, and suture must be threaded through the eye before use. Open-eyed needles offer the ability to pair a great variety of suture types and needles. Disadvantages include the time needed to thread the eye and its easy unthreading during suturing. Open-eyed needles are rarely used in obstetric surgery.

■ Body

In cross section, the needle body may be round or ovoid and is tapered gradually to the point. Ovoid needles may be flattened on top and bottom with rounded sides, or flattened on all four sides, producing a square or rectangular body. Some needle bodies also are ribbed longitudinally on the inner curvature to allow them to be securely grasped by the needle holder. For most obstetric surgery, the needle body is round and smooth.

The length of the needle body may be either straight or curved. Most curved needles have either a $\frac{1}{2}$ or $\frac{3}{8}$ circle configuration, although a $\frac{5}{8}$ -circle needle is sometimes used in vaginal surgery (Fig. 1-1). The $\frac{3}{8}$ -circle needle is most commonly

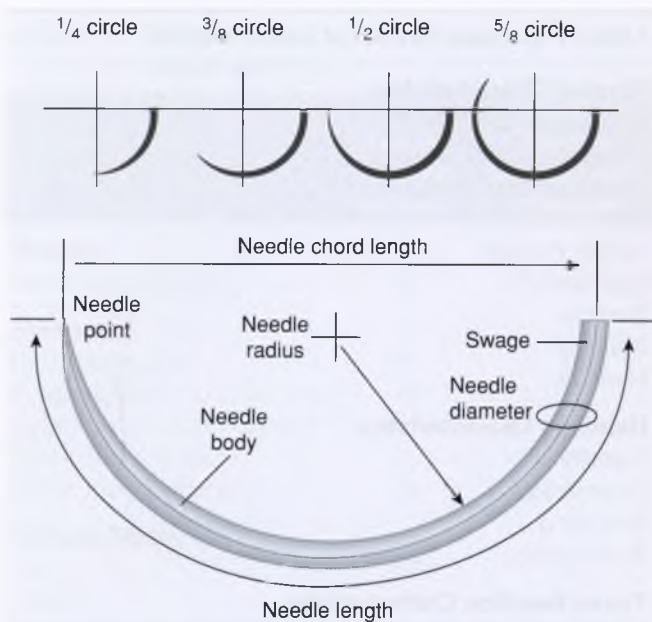


FIGURE 1-1 Curved surgical needle configurations and characteristics. (Modified from Dunn DL: *Wound Closure Manual*. Somerville, Ethicon, 2005.)

used in obstetrics. However, the $\frac{1}{2}$ - or $\frac{5}{8}$ -circle design aids maneuvering in small places.

■ Point

Needles are most commonly classified according to the cross section of their point (Fig. 1-2). Needle points may be tapered, cutting, reverse cutting, or blunt. As shown, cutting needles have three sharp edges and are more likely to pull through tissue than are tapered points. Tapered points are used for softer tissues such as uterus, vagina, and fascia (Fig. 1-3). The blunt point is used for very friable tissues, or occasionally for cannulating, and does not easily penetrate gloves.

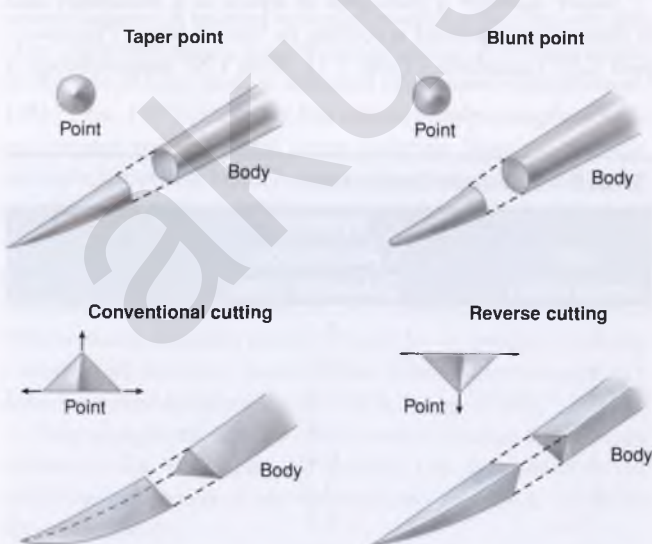


FIGURE 1-2 Configuration of various surgical needles. (Reproduced with permission from Balgobin S, Hamid CA, Hoffman BL: *Intraoperative considerations*. In Hoffman BL, Schorge JO, Bradshaw KD, et al (eds): *Williams Gynecology*, 3rd ed. New York, McGraw-Hill Education, 2016.)




FIGURE 1-3 Tissue cutting effects of taper needle (A), which pierces tissue with less trauma than a cutting needle (B). (Reproduced with permission from Hamid CA, Hoffman BL: *Intraoperative considerations*. In Hoffman BL, Schorge JO, Halvorson LM, et al (eds): *Williams Gynecology*, 2nd ed. New York, McGraw-Hill, 2012.)

Conventional-cutting needles have the cutting edge directed toward the wound edge. In contrast, the reverse-cutting needle has its flat surface toward the wound (see Fig. 1-2). For this reason, conventional-cutting needles have a greater tendency to pull through the edge when tightened. Although most commonly available cutting needles are of the reverse-cutting design, conventional-cutting needles may be useful for very fine skin suturing.

Needlestick injuries are a frequent concern during suturing. DeGirolamo and colleagues (2013) reviewed several methods to reduce the incidence of sharp surgical injuries and concluded that many maneuvers with sharp instruments can be replaced with less dangerous techniques. For example, there is moderate-quality evidence that double gloving reduces perforations (Mischke, 2014). Mornar and Perlow (2008) also have shown that blunt needles are suitable and likely decrease the incidence of needlestick injuries during episiotomy repair.

■ Technique

Curved needles are designed to be grasped and driven through tissue with a needle holder, also called a needle driver. The placement of the needle in the holder is dependent on the tissue to be sutured. In cases in which a thick tissue segment is traversed or in which little resistance is expected, the needle may be grasped $\frac{2}{3}$ or $\frac{3}{4}$ of the distance from point to eye (Fig. 1-4). One example is hysterotomy incision closure. If tougher tissue is anticipated, then the needle is more appropriately grasped in the middle or even slightly more toward the point. This aids needle passage yet helps avoid bending deformation of the needle. One example is sutures placed through the pubic periosteum.

Curved needles are never grasped with the hand. In a review of surgical glove perforation in obstetrics, Serrano and associates (1991) described a 13-percent rate of glove perforation. Most punctures occurred in the nondominant hand and suggested perforation due to grasping the needle. Such technique increases the risk of infection transmission to both patient and physician



FIGURE 1-4 Correct position of needle driver on curved needle. (Used with permission from U.S. Surgitech, Inc.)

(Dagleish, 1988). Longer, straight needles of the Keith type are sometimes used manually without a needle holder for mattress-type skin closures. These, too, are also likely to cause injury.

SUTURES

Some form of suture has been used for centuries either to approximate tissue or to ligate vessels. Wound suturing was described as early as 3500 BC in an Egyptian papyrus, and it was used by Galen, physician to the gladiators, to stop their bleeding (Snyder, 1976; Stone, 1988). Joseph Lister (1869), who pioneered the concept of antiseptis, made a major advance in suture material. His chromatization of gut suture in 1876 resulted in significant prolongation of suture tensile strength. In Lister’s day, the violin was often referred to as a “kit.” The most common source of gut material for suture was violin strings fashioned from sheep or ox intestines. Thus the term “kitgut” was introduced, and this later was modified to “catgut” (Stone, 1988).

Table 1-1 describes various characteristics of suture material. The ideal suture would cost little, tie easily and securely, possess superb tensile strength, stretch to accommodate wound edema, exhibit recoil to return to its initial length, and have no adverse effect on wound healing or infection rates (Yag-Howard, 2014). Unfortunately, no suture meets all of these requirements. Thus, compromises are made when selecting suture material, and both advantages and disadvantages are weighed.

Characteristics

Physical Characteristics

Several terms describe the physical characteristics of suture material. First of these, *physical configuration* refers to mono- or multifilamentous construction. Multifilamentous material ties more easily but has an increased tendency to harbor bacteria in its braiding (Balgobin, 2016; Bennett, 1988).

Capillarity refers to the ability of fluid to track along the suture. Namely, if one suture end is exposed to liquid, the ease

TABLE 1-1. Characteristics of Suture Material

Physical Characteristics

- Physical configuration
- Capillarity
- Fluid absorption ability
- Diameter (caliber)
- Tensile strength
- Knot strength
- Elasticity
- Plasticity
- Memory

Handling Characteristics

- Pliability
- Tissue drag
- Knot tying
- Knot slippage

Tissue Reaction Characteristics

- Inflammatory reaction
- Absorption
- Potential of infection
- Allergic reaction

Modified from Bennett, 1988.

with which fluid wicks to the opposite dry end defines its capillarity. In general, multifilament sutures have greater capillarity (Geiger, 2005). *Fluid absorption ability* is the capacity of suture to absorb fluid when immersed. Both of these characteristics increase the tendency to absorb and retain bacteria. For example, braided nylon, a material with high fluid-absorption capability and capillarity, absorbs three times as many bacteria as the corresponding monofilament suture (Bucknall, 1983).

Suture diameter is measured in tenths of a millimeter and is commonly expressed according to United States Pharmacopeia (USP) standards (Table 1-2). With USP nomenclature, a

TABLE 1-2. Suture Designation

USP Designation	Synthetic Absorbable Diameter (mm)
5	0.7
4	0.6
3	0.6
2	0.5
1	0.4
0	0.35
2-0	0.3
3-0	0.2
4-0	0.15
5-0	0.1

USP = United States Pharmacopeia.

TABLE 1-3. Physical Characteristics of Surgical Suture Materials

	Tensile Strength, kgf/mm ²	Effective Tensile Strength with 2 Throws
Metallic		
Steel, monofilament	163	163
Synthetic		
Polyglycolic acid	76	37
Polypropylene, monofilament	68	32
Polyethylene, monofilament	57	15
Nylon, monofilament	79	19
Nylon, multifilament	71	18
Natural Fibers		
Silk	55	6
Catgut	50	42

Data from Herrmann, 1971.

midpoint diameter size is designated as 0, and as suture diameter increases above this, arabic numbers are assigned. For example, no. 1 catgut is thicker than 0-gauge catgut. In contrast, as suture diameter decreases from this designated midpoint, 0s are added. By convention, an arabic number followed by a 0 also may be used to reflect the total number of 0s. For example, 3-0 suture may also be represented as 000. Therefore, 3-0 suture is greater in diameter than 4-0 (0000) suture. That said, specific tensile strength and diameter affect USP terminology, and thus, 4-0 catgut has a slightly larger diameter than 4-0 nylon.

Tensile strength is defined as the amount of weight necessary to break a suture divided by its cross-sectional area. In this respect, the breaking load will be quadrupled by a doubling of suture diameter. A knotted suture has roughly a third the strength of an unknotted suture, but the strength depends to some degree on the type of knot used, as discussed subsequently (Rodeheaver, 1981; Tera, 1977). Table 1-3 lists relative tensile strengths of various knotted and unknotted suture materials. Note the dramatic decline in strength of knotted versus unknotted suture for all except metallic sutures. Figure 1-5 depicts the relationship between suture diameter and tensile strength. Figure 1-6 depicts tensile strength over time following suture placement. The tensile strength also is affected by surgical technique. For example, a stray knot in a Prolene suture decreases tensile strength by 17 percent. Grasping a suture with forceps or needle holder lowers suture strength in a dose-dependent fashion (Abidin, 1989; Stamp, 1988).

Knot strength refers to the force needed to cause a given type of knot to slip, either partially or fully. It is dependent on the coefficient of friction of the material and its stretch capability (Bennett, 1988).

Elasticity refers to the tendency of the suture to return to its original shape after stretching. With high elasticity, a suture will be easily stretched by tissue swelling and will not cut into or through the tissue. *Plasticity* refers to the proneness of suture to retain its new shape after stretching. A highly plastic suture

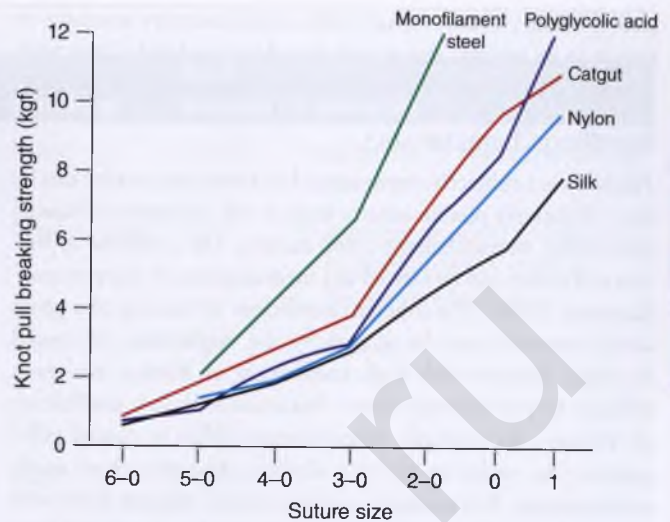


FIGURE 1-5 Knot pull breaking strength of various sizes of surgical sutures. (Redrawn and modified from Herrmann JB: Tensile strength and knot security of surgical suture materials. *Am Surg* 37(4):209, 1971.)

will retain its larger form even after tissue swelling subsides and thus may become loose.

In addition to elasticity, the tendency of suture material to cut through tissue is also directly related to tensile strength, inversely related to suture diameters, and dependent on tissue type. Of tissues, suture is least likely to cut through fascia, and in descending order, through muscle, peritoneum, and fat (Bennett, 1988; Tera, 1976). Moreover, the force required for suture to tear various tissue types changes during healing. From week 1 to week 2 following surgery, the likelihood that suture will cut through tissue is less than in the immediate postoperative period (Aberg, 1976).

Memory refers to the propensity of a material to return to its original shape after being deformed, for example, after being

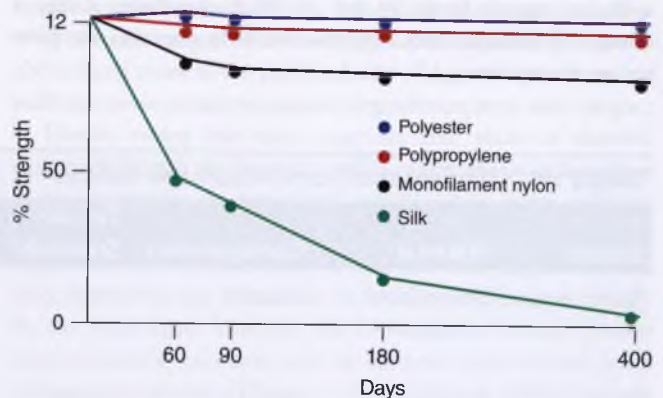


FIGURE 1-6 Nonabsorbable sutures and the percentage of strength remaining up to 400 days. Polyester (Ethibond and Mersilene) sutures and polypropylene (Prolene) sutures retained 100 percent of their original breaking strength after 400 days. Monofilament nylon (Ethilon) suture retained about 80 percent of its original breaking strength. Silk suture degrades and loses strength more rapidly. Usually less than 50 percent of its original strength remains at 2 months. Data are from size 2-0 and 4-0 gauge sutures implanted in rat subcutaneous sites. (Reproduced with permission from Salthouse TN: Biologic response to sutures, *Otolaryngol Head Neck Surg* 1980 Nov-Dec;88(6):658-664.)

tied (Bennett, 1988). Suture with a high memory attempts to return to its original shape, and thus does not hold a knot well. Nylon is an example of a suture with a high degree of memory.

Handling Characteristics

Pliability is a subjective term related to how easily suture can be bent. Relatively pliable sutures such as silk are easier to handle than stiffer, monofilament nylon sutures. The *coefficient of friction* of a suture can be viewed as a measurement of “slipperiness” (Bennett, 1988). The inherent coefficient of friction of a given suture material may be altered by the application of special coatings. Sutures with high coefficients of friction are more difficult to pull through tissue. Materials with low coefficients of friction—for example, monofilament nylon or coated polyglactin—are easier to set by a slipknot, but may more easily come undone. For example, a simple square surgeon knot with uncoated polyglycolic acid (Dexon) approaches maximum knot security, but the same knot tied with coated polyglactin 910 (Vicryl) is insecure (Trimbos, 1984).

Tissue Reaction

All suture material is foreign to the body and will elicit a tissue reaction directly proportionate to the amount of suture material present (Bennett, 1988). In this respect, the fewer sutures used, the better. Furthermore, the diameter of suture used under many circumstances is more closely linked to adhesion formation than the inherent reactivity of the material itself (Stone, 1988).

Three sequential histologic stages reflect the normal reaction of tissue to suture material (Madsen, 1953; Postlethwait, 1975). Stage I lasts from days 1 to 4 and consists of a leukocytic infiltrate of polymorphonuclear leukocytes, lymphocytes, and monocytes. During Stage II, from days 4 to 7, macrophages and fibroblasts arrive. Stage III begins after day 7 and consists primarily of a chronic inflammatory response and the appearance of additional fibrous tissue. Following this, findings diverge according to suture quality. With nonabsorbable suture, a fibrous capsule forms by day 28. With absorbable suture, a continued inflammatory response results in eventual complete suture absorption.

TABLE 1-4. Relative Tissue Reactivity to Sutures

Reaction	Nonabsorbable	Absorbable
Moderate	Silk, cotton	Catgut
Slight	Polyester (Dacron) Nylon (Ethilon) Polypropylene (Prolene)	Polydioxanone (PDS II) Polyglactin 910 (Vicryl) Polyglycolic acid (Dexon)
Minimal	Steel	

Table 1-4 ranks suture material according to tissue reactivity. Within this ranking, multifilamentous suture elicits greater tissue reaction than monofilamentous material and increases the risk of infection to a greater degree (Alexander, 1967; Sharp, 1982). Risk of infection is also heightened with braided suture material. Braiding can harbor bacteria in its interstices, where they are less susceptible to the cidal actions of leukocytes. Knots similarly provide interstices favorable to bacterial growth, which suggests that the number of knots placed should be minimized (Moy, 1992; Osterberg, 1983).

■ Specific Suture Types

Properties of absorbable and nonabsorbable sutures are detailed in Table 1-5 and Table 1-6. The terms *absorbable* and *nonabsorbable* are relative. Plain catgut, for example, which is an absorbable suture, may persist in tissue for many years (Postlethwait, 1975). And, with the exception of polyester (Dacron), polypropylene (Prolene), and stainless steel, all “nonabsorbable” sutures eventually degrade or are absorbed (Edlich, 1974; Nilsson, 1982). For these reasons, by convention, sutures that retain significant tensile strength beyond 60 days are commonly classified as “nonabsorbable” (Bennett, 1988; Moy, 1992).

Some sutures used for skin closure are impregnated with antibacterial compounds. Examples include the brands Vicryl Plus and Monocryl Plus. In a recent systematic review, Sajid and coworkers (2013) reported that antibacterial sutures significantly decreased the frequency of surgical site infections.

TABLE 1-5. Comparison of Some Absorbable Sutures

Suture	Material	Configuration	Tensile Strength	Handling	Knot Security	Absorption	Comments
Surgical gut	Sheep/beef intestine	Twisted	Poor	Fair	Poor	Unpredictable (12 weeks)	Chromic gut has less reaction, delayed absorption
Vicryl	Polyglactin	Braided	Good	Good	Fair	80 days	
Dexon	Polyglycolic acid	Braided	Good	Fair to good	Fair to good	90 days	Coated type handles better but has less knot security
PDS II	Polydioxanone	Monofilament	Good	Fair	Poor	180 days	
Monocryl	Poliglecaprone	Monofilament	Fair	Good	Good		
Biosyn	Glycomer	Monofilament	Good	Good	Good		

TABLE 1-6. Comparison of Some Nonabsorbable Sutures

Suture	Material	Configuration	Tensile Strength	Handling	Knot Security	Comments
Silk	Silkworm fibroin	Braided	Good	Good	Good	Predisposes to infection; may be coated
Nylon	Polyamide	Braided or monofilament	High	Poor to good	Fair	Braided predisposes to infection; monofilament or coating decreases handling
Prolene	Polypropylene	Monofilament	Fair to good	Poor	Poor	Cuts tissue
Novafil	Polybutester	Monofilament	High	Fair	Poor	
Mersilene Dacron	Polyethylene polyester	Braided	High	Good	Good	
Ethibond Ti-Cron Polydek Tevdek	Coated polyethylene	Braided	High	Poor to good	Poor to good	Handling and knot security vary with type of coating
Stainless steel	Steel	Monofilament, twisted, braided	High	Poor	Good	May kink; cuts through gloves
Silver wire	Silver	Monofilament	High	Fair	Good	More pliable than steel; used for dehiscence closure

The next sections describe commonly used suture material. It is readily apparent that each type has its own advantages and drawbacks. Perhaps with the exception of prospective studies of perineal repair, no clear and convincing data favor the superiority of any particular suture type for obstetric use.

Catgut

These sutures are made from the submucosa of sheep intestines or from the intestinal serosa of cattle. *Chromic catgut* is treated with salts of chromium, which strengthen the suture and delay its absorption. Catgut-based sutures are absorbed by lysosomal proteolytic enzymes. This process is relatively unpredictable and is accelerated by local infection, which reduces the duration of tensile strength (Stone, 1988). In contrast, synthetic absorbable sutures dissolve by hydrolysis in a more predictable manner. With catgut sutures, degradation and phagocytosis begin 12 hours after implantation and peak 3 days later. Tensile strength is minimal after 10 days, and absorption is complete within 2 to 3 weeks (Bennett, 1988; Postlethwait, 1975).

Plain catgut elicits a greater inflammatory response than chromic catgut. Catgut is slightly larger at each USP size than either polyglactin 910 (Vicryl) or polyglycolic acid (Dexon) (Stone, 1988). There is no evidence that catgut can induce an allergic response (Carroll, 1989).

Polyglycolic Acid (Dexon)

This is a high-molecular-weight linear-chain polymer of hydroxyacetic (glycolic) acid. Dexon S is uncoated polyglycolic acid that may be undyed beige or may be dyed green to enhance visibility in tissue. Dexon II is polyglycolic acid coated with

polycaprolate. It may be undyed beige or may be dyed green, violet, or bicolored to enhance identification. All synthetic absorbable sutures are nonantigenic and are degraded to carbon dioxide and water in a predictable manner by hydrolysis in the presence of tissue fluids (Salthouse, 1980; Williams, 1977). At 7 days following placement, this suture has lost one-third of its breaking strength, and it is completely absorbed in 90 to 120 days (Craig, 1975; Frazza, 1971). The prolonged retention of tensile strength would seem a theoretical advantage compared with chromic catgut. However, any actual superiority is probably related more to the predictability of degradation compared with the more erratic enzymatic degradation seen with catgut.

Dexon evokes less tissue reaction than plain or chromic catgut. Although its braided configuration makes it less than ideal for heavily contaminated surgical sites, some evidence supports a role. One study performed in guinea pigs suggests superiority of Dexon compared with chromic catgut to avoid infection following a bacterial inoculum (McGeehan, 1980). At the same time, however, the interstices in braided Dexon may potentiate infection, and its absorption is delayed in an infected environment (Foster, 1978; Williams, 1980). Because Dexon is braided, it is inappropriate for use as a transcutaneous skin closure material.

Polyglactin 910 (Vicryl)

This material is a copolymer of lactide and glycolide, which are cyclic compounds derived from lactic and glycolic acids. Like Dexon, Vicryl is braided. Its tensile strength is slightly less than that of Dexon, thus Vicryl is manufactured in slightly larger diameters than is Dexon at each USP-specified size

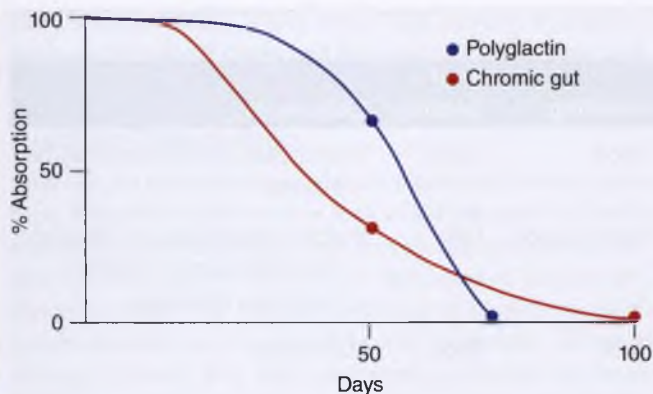


FIGURE 1-7 Percentage of absorption up to 100 days with polyglactin 910 (Vicryl) and chromic catgut sutures. Size 4-0 gauge sutures were implanted in a rat gluteal muscle, and absorption was calculated from cross-sectional area remaining. Absorption of surgical gut is seen by 14 days. With absorbable synthetic suture, some absorption is seen at about 35 days but is more rapid thereafter. (Reproduced with permission from Salthouse TN: Biologic response to sutures, *Otolaryngol Head Neck Surg* 1980 Nov-Dec;88(6):658–664.)

(Bennett, 1988; Stone, 1988). All currently manufactured Vicryl is coated and available in either white or purple. The inflammatory response to Vicryl is similar to that with Dexon. In rats and as shown in **Figure 1-7**, chromic catgut is absorbed at a faster rate than Vicryl. However, Vicryl is absorbed faster than Dexon. In two studies, 77 percent of Dexon remained after 63 days compared with 26 percent of Vicryl. Moreover, Vicryl was completely absorbed in 60 to 90 days compared with 90 to 120 days for Dexon (Conn, 1974; Craig, 1975). In rats, Vicryl does not contribute to the strength of abdominal wounds after 15 days (Nilsson, 1982).

For perineal repair, Mackrodt (1998) and Ketcham (1994) and their colleagues reported advantages of synthetic sutures compared with chromic suture. Kettle and coworkers (2010) performed a Cochrane database review and identified 18 controlled trials of perineal suturing following vaginal delivery. These investigators concluded that polyglycolic acid (Dexon) or polyglactin (Vicryl) sutures were superior to catgut derivatives because they produced significantly less pain, less need for analgesia, less late dyspareunia, and possibly less risk of dehiscence (Chap. 20, p. 325). A disadvantage for both Dexon and Vicryl are their relatively high tensile strength and low elasticity compared with chromic catgut. As a result, they tend to cut through tissue more readily.

Polydioxanone (PDS II)

This suture is a polymer made from paradioxanone and is manufactured as a monofilamentous suture. This contrasts with Dexon and Vicryl, which are multifilament. In one study, PDS II was completely absorbed in 180 days compared with 60 to 90 days for Vicryl and with 120 days for Dexon. PDS II also maintains 60 percent of breaking strength at 28 days compared with 5 percent or less for either Dexon or Vicryl (Ray, 1981). PDS II suture is capable of maintaining its integrity in tissue with bacterial infection (Schoetz, 1988). The principal disadvantage of PDS II suture is its stiffness, a result of monofilament construction, which makes it more difficult to tie.

Silk and Cotton

Silk fibroin is a natural protein produced during cocoon construction by the silkworm larva. It is braided and dyed black to create surgical silk. “Dermal silk” sutures are encased in protein to prevent epithelial ingrowth along the suture line, which would make removal more difficult (Bennett, 1988; Freeman, 1970). According to the UPS definition, silk is classified as nonabsorbable. This may stem from the fact that silk degradation is usually mediated by a foreign body response. That said, silk suture is absorbed after several months, and thus, silk suture is unsuitable for procedures requiring long-term stability. This delay may occasionally result in granuloma formation (Postlethwait, 1970; Salthouse, 1980).

The advantages of silk suture include easy handling, little knot slippage, and a minimal tendency to tear through tissues. But its potential to absorb fluid and bacterial is great, and thus it is poorly suited for use in an infected surgical field. Furthermore, quantitative investigations of knot strength suggest that compared with other materials, silk actually forms relatively weak knots (Tera, 1976).

Constructed of braided cotton fibers, cotton suture is rarely used in obstetric surgery. Unlike any other material, cotton is made stronger and the knot firmer by fluid absorption. Cotton is essentially identical to silk in its reactivity and infection-enhancing capacity (Hochberg, 1991).

Nylon

This synthetic polyamide polymer is manufactured as either a multi- or monofilament fiber. Its tensile strength is great, but nylon sutures are stiff, and they easily cut through thin tissue and require several well-placed knots to prevent untying. This material is selected primarily in cutaneous suturing and rarely used for internal hemostasis or wound approximation (Goulbourne, 1988). Nylon is eventually degraded and absorbed and has little remaining tensile strength after 6 months (Moloney, 1961). Birdwell and associates (1981) found that, in human studies, the strength of cutaneous wounds closed with buried nylon was comparable to that of those closed with Vicryl sutures. Trimbos and coworkers (1993) reported that compared with nylon, polybutester (Novafil) caused less hypertrophic scarring.

Polypropylene

These sutures are formed by propylene polymerization (Prolene) and are virtually identical to polyethylene sutures (Dermalene). The principal distinguishing feature of these sutures is an extremely small coefficient of friction, making them ideal for cervical cerclage or for cutaneous intradermal closure with later removal (Freeman, 1970; Homsy, 1968). This same feature, however, makes knots less secure. Polypropylene is also a very plastic suture, which stretches and deforms easily as the wound swells; thus, these sutures rarely cut through tissue (Bennett, 1988). Polypropylene is relatively noninflammatory (Salthouse, 1975).

Polyester

This synthetic suture material is a braided, multifilament, polymerized permanent suture and is manufactured in coated and uncoated forms. Mersilene is the most common uncoated

form used in obstetrics and commonly for cervical cerclage. Tevdek and Ethibond are examples of polyester sutures coated with Teflon and polybutylate, respectively, resulting in much smoother passage through tissues. Polyester sutures are second only to metal sutures in tensile strength (Herrmann, 1971). Polyester is truly nonabsorbable, and it retains its tensile strength indefinitely. Uncoated polyester suture evokes minimal inflammatory response (Hartko, 1982).

Stainless Steel

Stainless steel suture is available in either mono- or multifilamentous form but is rarely used today. Although it is inert and has excellent tensile strength and knot security, it is difficult to handle. Moreover, suture cuts through gloves easily, exposing the surgeon to blood-borne infectious diseases. It may be used in select cases of fascial closure in women with abdominal wall dehiscence or with extreme risk for infection and dehiscence.

KNOTS

Knot tying is the most important, but potentially the weakest, part of suture technique. In one older study, when the knots of a group of board-certified general surgeons were subjected to mechanical performance tests, it was determined that only 25 percent of the surgeons used appropriate knot construction (Thacker, 1977). A subsequent poll of a group of 25 gynecologists—"well known and selected on the grounds of their experience"—found that most were convinced they made square knots, even though the technique described resulted in slipknots (Trimbos, 1984). Batra and associates (1993) demonstrated that with minimal instruction, medical students consistently constructed stronger standard square knots than a cohort of practicing obstetrician/gynecologists using both monofilament and multifilament nylon sutures.

Faulty knot tying may be devastating and can lead to exsanguination or wound dehiscence. It is mandatory that the obstetrician thoroughly understand that certain knots are stronger than others, that different suture materials require different numbers of throws for knot security, and that these relationships are defined biomechanically (Edlich, 1991). Such knowledge provides the foundation for proper knot tying.

Terminology

There are three components in a suture tie: the loop, which affects hemostasis or wound approximation; the knot, which maintains loop security; and the ears, which ensure that the loop will not become untied because of knot slippage (Edlich, 1991).

An international code has been developed to describe surgical knots (Fig. 1-8). The number of wraps in a single throw is indicated by arabic numerals. Thus, the common single throw is 1, and the double or "surgeon's throw" is 2. The slip configuration is designated by the letter S. If successive throws are parallel, or square, the equals symbol (=) is used, whereas the multiplication sign (×) signifies a crossed or "granny" configuration. Thus, the common square knot is described as 1 = 1, a granny as 1 × 1, a square surgeon's knot as 2 = 2, and a simple slipknot as S = S.

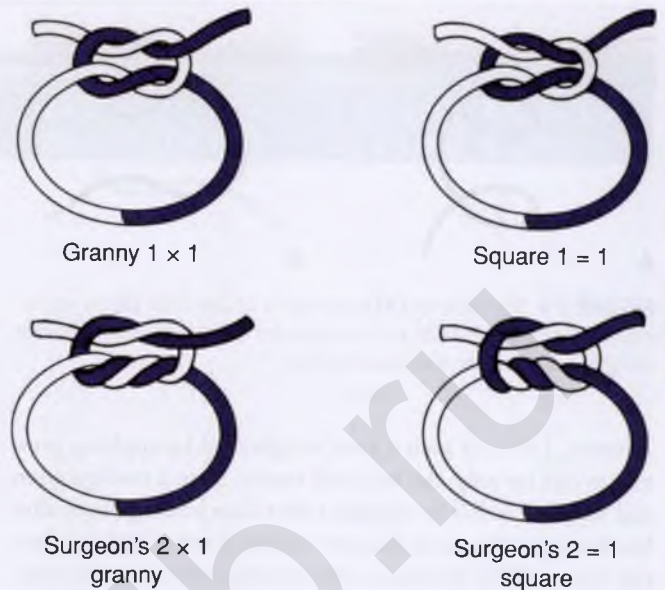


FIGURE 1-8 Various types of surgical knots. (Reproduced with permission from Balgobin S, Hamid CA, Hoffman BL: Intraoperative considerations. In Hoffman BL, Schorge JO, Bradshaw KD, et al (eds): Williams Gynecology, 3rd ed. New York, McGraw-Hill Education, 2016.)

Knot Slippage

There are several elements that influence slippage: the coefficient of friction of the chosen suture material, suture diameter and coating, moisture, knot configuration, and the final geometry of the finished knot. Additional factors are the human element and tying technique (Edlich, 1991). In particular, the coefficient of friction for any suture is linearly related to and determines the number of throws needed for knot security (Herrmann, 1971). The rate of knot slippage varies from 0 to 100 percent, depending on the knot type alone (Madsen, 1953; Thacker, 1975). For example, even in knots laid flat, the granny configuration always results in greater slippage than a square knot. An exception is the 2 = 2 and 2 × 2 configurations, which appear to be similar for most materials (Tera, 1976). Coated suture results in greater knot slippage than does the corresponding uncoated suture (Trimbos, 1984). Many types of suture also exhibit significant knot slacking in vivo, independent of inherent suture degradation. Notable exceptions to the principle are polyester sutures such as Ethibond (Tomita, 1992).

Each additional throw reduces knot slippage. After a certain number of throws—determined by the knot configuration and suture material—knot failure will occur by breakage, rather than slippage. At this point, additional throws only result in greater foreign-body inflammatory reaction and encourage infection (Brown, 1992).

Individual tying techniques also greatly influence knot slippage. Two particularly important aspects of technique are the force and the direction in which tension is applied as the knot is tightened. A sliding knot, also called a slipknot, may be constructed in either a square or granny configuration. Such knots are often helpful in obtaining close approximation of tissues during the initial stage of knot formation, especially when tying one-handed knots and deep-seated ligatures (Ivy, 2004;

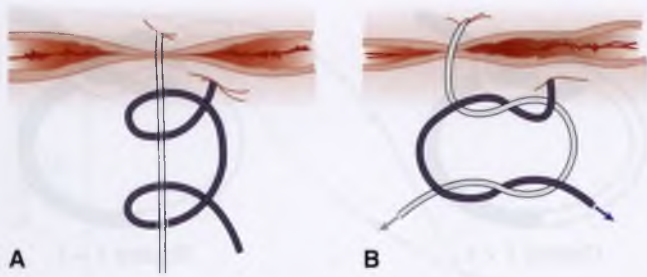


FIGURE 1-9 The slipknot (**A**) becomes a square knot (**B**) by applying equal tension to both ears in opposite directions and in a plane roughly horizontal to the tissue surface.

Zimmer, 1991). If such a knot is tightened by applying pressure to one ear only, the knot will remain in an S configuration and will tend to fail by slippage rather than breakage even after five throws. Also, monofilament sutures have a higher failure rate (Hurt, 2005). However, after the tissues have been approximated, the slipknot can be converted to a square or granny configuration by applying tension to both ears in opposite directions in a plane roughly horizontal to the tissue surface (Fig. 1-9). If the proper number of such throws is applied, as determined by the suture material, the knot will not fail by slippage. Babetty and associates (1998) found that tying sliding knots with an alternating and different pattern increased knot security.

Even if a slipknot is not squared during tightening, construction of the knot by alternating nonidentical (nonparallel) throws results in less failure by slippage than if identical throws are used. Constructing one-handed throws around alternate strands of suture—that is, alternating left- and right-handed tying—results in the strongest possible slipknot (Trimbos, 1984).

The amount of tension exerted by the surgeon on the ears of the knot also significantly alters the tendency for slippage. Ideally, tension equal to 80 percent of knot breakage strength should be applied to the ears of the suture (Edlich, 1991).

The length of the knot ears also influences slippage. Suture material with low coefficients of friction, such as nylon, is traditionally left with longer ears than material with higher frictional coefficients, such as chromic catgut. There is general agreement, however, that any knot requiring ears in excess of 3 mm is unsuitable for general use in surgery because longer ears predispose to infection (Thacker, 1975). Using appropriate technique, secure knots with ears 3 mm or less in length can be tied with any available suture material. Indeed, in most tensiometric studies of knot security, 2 mm is generally considered the maximal acceptable slippage (Tera, 1976).

■ Knot Breakage

The knot is generally the weakest part of any suture, and the force necessary to break a knotted suture is 20 to 90 percent lower than that required to break an untied suture (Tera, 1976; Thacker, 1975). The forces on a knotted suture are converted from straight-pull forces to shear forces by the configuration of the knot, thus causing the suture material to lose tensile strength (Edlich, 1991). Unlike suture strength, the relationship between knot strength and suture diameter becomes less important with finer-gauge sutures (Herrmann, 1971).

Knot efficiency is expressed as a percentage and describes the relationship between knotted and unknotted suture. It is defined as:

$$\text{Knot efficiency (\%)} = \frac{\text{tensile strength of knotted suture}}{\text{tensile strength of unknotted suture}}$$

Knot efficiency varies from 3 to 99 percent, depending on the type of knot and suture material. It is influenced only slightly by suture diameter (Tera, 1977; Trimbos, 1984). In vivo, the tissue in which the knot is embedded also influences knot strength. In general, knot security decreases over time in vivo, especially with absorbable sutures (Herrmann, 1971, 1973).

Even if identical suture material is used, knot efficiencies can vary from 5 to 55 percent depending on the knot type (Trimbos, 1984). For example, crossed or granny knots are less efficient—that is, they are actually weaker as opposed to more likely to fail by slippage—than are parallel or square configurations. This is true regardless of the suture material type used (Tera, 1977). Generally, more throws in a knot result in both less slippage and greater knot efficiency. However, because of the unique characteristics of individual suture material, beyond a certain point little additional strength is gained (Thacker, 1975).

Knot strength also is influenced by the rate at which force is applied to tighten the knot. Specifically, the breaking force of a knot is greater when gradual force is applied to the knot ears than when the tightening force is sudden. When monofilament nylon suture was used to tie a surgeon's square knot, for example, knot tightening at a rate of 500 mm/min resulted in a 32-percent reduction in knot strength compared with a tightening rate of 50 mm/min (Zimmer, 1991). All types and gauges of suture commonly available—with the exception of stainless steel—may be broken at the knot if suture is pulled too tightly and abruptly (Thacker, 1975).

Using a reproducible tensiometer technique, Tera and Aberg (1977) examined knot efficiency as it relates to type of suture material and type of knot. Table 1-7 lists some examples of absolute strengths of suture loops for various knots, suture materials, and suture dimensions. Table 1-8 lists chosen examples of knot efficiencies for various types of knots and sutures.

In general, square knots are stronger than their corresponding crossed configurations (Table 1-9). This difference is minimal, however, for the commonly used 1 = 1 = 1 or 1 × 1 × 1 knots with 0 to 3-0 chromic catgut. Knot strength for chromic gut is not significantly improved with additional throws. Interestingly, absolute knot strength with uncoated PDS sutures is not improved with four or more throws compared with a 1 = 1 = 1 configuration. Brown (1992) evaluated no. 1 suture materials and compared knot strength. He studied nylon, polypropylene, polydioxanone, polyglyconate, and polyglactin. After two throws, knot holding did not increase with any of these materials.

There are fewer comparable data for the newer, coated synthetic absorbable sutures. For materials with lower coefficients of friction, however, additional parallel throws with these materials would seem prudent. For monofilament nylon or silk in 0 to 3-0 gauges, significant additional strength is gained with a 2 = 2 = 2 or 1 × 1 × 1 knot compared with a 1 = 1 = 1 construction. 0-gauge Prolene demonstrated maximum knot

TABLE 1-7. Strength of Suture Loops in Kilopascals (kPa)

Suture Material Gauge/Diameter (mm)		Upper Value, Parallel Knots; Lower Value, Crossed Knots						
		1 = 1 1 × 1	2 = 1 2 × 1	1 = 2 1 × 2	2 = 2 2 × 2	1 = 1 = 1 1 × 1 × 1	2 = 2 = 2 2 × 2 × 2	1 = 1 = 1 = 1 1 × 1 × 1 × 1
Steel								
0	0.40	16.6	17.0	17.0	17.4	17.0	17.0	17.1
		16.4	15.0	16.6	17.4	16.6	17.0	17.6
000	0.25	6.8	7.2	7.2	7.2	7.0	7.0	7.2
		6.2	7.0	7.2	6.6	7.2	7.2	7.4
Chromic Catgut								
2	0.67	14.0	16.6	13.4	15.0	12.8	16.8	15.4
		11.8	14.4	11.4	16.4	13.8	17.0	14.2
0	0.47	7.6	8.2	8.2	6.8	7.6	7.4	8.6
		7.6	5.4	6.8	8.3	7.4	9.1	7.9
000	0.17	3.28	3.38	3.32	3.60	3.20	3.10	3.16
		3.36	3.96	3.0	3.96	3.14	4.12	3.0
Dexon								
2	0.53	17.4	17.8	18.0	18.4	17.6	18.2	18.6
		3.4	8.8	14.2	19.6	12.4	18.6	19.0
0	0.40	9.0	8.6	8.1	9.0	9.6	9.5	9.5
		1.8	1.0	7.0	8.2	8.9	9.2	8.8
000	0.26	2.78	3.94	3.64	3.66	4.08	3.60	3.52
		0.26	0.74	2.64	3.32	3.00	3.30	4.26
Mersilene								
2	0.53	13.0	14.4	10.6	15.2	14.0	15.4	14.4
		0.8	9.2	4.4	14.4	13.6	15.0	13.6
0	0.40	6.8	4.8	8.1	7.3	7.9	6.8	7.3
		1.9	5.2	7.4	8.6	7.3	8.6	7.8
Nylon								
2	0.52	1.6	1.8	3.6	3.2	5.8	11.4	7.8
		2.6	2.2	3.4	7.8	7.2	13.2	11.8
0	0.37	2.2	3.0	1.4	3.6	5.2	7.4	6.8
		1.4	4.8	0.8	6.8	4.0	8.0	6.4
000	0.25	0.56	0.74	2.54	1.60	2.68	3.48	3.58
		0.82	0.64	1.84	3.52	2.20	3.12	3.54
Silk								
0	0.39	2.0	2.3	2.9	3.2	5.0	6.4	6.4
		0.6	2.0	2.5	5.4	3.7	6.3	6.8
000	0.25	0.78	0.94	1.42	1.80	1.98	2.54	2.64
		0.50	1.36	1.24	2.22	1.66	2.34	2.22
Polyethylene								
0	0.40	1.6	1.3	2.4	2.1	4.4	6.6	6.0
		1.8	0.8	4.1	7.0	4.9	7.6	4.8
000	0.25	0.76	0.56	1.40	2.16	2.28	2.92	2.72
		0.60	0.42	1.44	3.26	1.46	3.46	2.54
Polyolefin								
0	0.40	3.2	3.5	7.2	6.9	7.5	8.0	7.4
		3.2	1.0	6.4	8.4	7.4	8.1	6.2
000	0.24	0.70	1.48	2.80	2.98	2.90	3.08	3.28
		1.52	0.64	2.46	3.28	2.96	3.46	3.36

Modified from Tera, 1977.

TABLE 1-8. Knot Strength in Percent of Tensile Strength of Unknotted Thread (Efficiency)

Suture Material; Unknotted Thread Tensile Strength (kPa)/ Diameter (mm)		Upper Value, Parallel Knots; Lower Value, Crossed Knots						Mean
		1 = 1 1 × 1	2 = 1 2 × 1	1 = 2 1 × 2	2 = 2 2 × 2	1 = 1 = 1 1 × 1 × 1	2 = 2 = 2 2 × 2 × 2	
Steel								
3.88	0.25	87	92	92	92	90	90	91
		79	90	92	85	92	92	88
Chromic Catgut								
2.76	0.31	59	61	60	65	58	61	61
		60	72	54	72	57	75	65
Dexon								
2.41	0.26	58	82	76	75	85	75	75
		5	15	55	69	62	68	46
Nylon								
2.32	0.25	12	16	55	34	58	75	42
		18	14	42	76	47	67	44
Silk								
1.88	0.25	21	25	38	48	53	63	41
		13	17	33	40	45	63	42
Polyethylene								
2.76	0.26	17	12	31	48	51	65	37
		13	9	23	32	32	47	29

strength with a 2 = 2 = 2 or 2 × 2 × 2 knot structure. Such configurations are superior even to a 1 = 1 = 1 = 1 = 1 construction. For Tevdek, five throws of any configuration have been recommended (Haxton, 1965).

It is interesting to note that with most materials tested, a 1 = 2 configuration is significantly stronger than a 2 = 1 knot construction (Tera, 1977). Furthermore, a 2 = 2 = 2 configuration is stable with all types of gauges of suture. This pattern is recommended if the specific suture characteristics are not known (Tera, 1976). In constructing a square knot, it is important to remember that such a knot cannot be constructed without crossing either the suture ends or the hands.

Annunziata and coworkers (1997) observed that knots used with a single suture and a suture loop—as in tying at the end of a running suture line—required more throws to achieve knot security. Wound security is, of course, also dependent on aspects

of surgical technique other than knot and suture strength. For example, tight fascial approximation results in a significantly weaker incision line than looser closure technique, presumably due to edema, ischemia, and poor healing (Stone, 1986).

LIGATURES

Securing tissue pedicles may be accomplished using various suturing techniques (Fig. 1-10). For smaller vascular pedicles, a single tie alone may be placed circumferentially beneath the clamp. However, tissues are often edematous in pregnancy, and pedicles shrink in size as edema subsides after delivery. Thus, single-suture ligation may also allow vessels to escape control. Accordingly, some prefer double ligation of larger vascular pedicles. Moreover, use of a transfixing suture for the second distal ligation improves hemostatic control for edema subsides.

With double ligation, the given pedicle receives two sutures, a free tie and then a transfixing stitch. First, a free tie is placed beneath the toe and heel of the tissue clamp, as in part A of Figure 1-10. This suture is tied. The second ligation is distal to the first and incorporates a stitch through the tissue pedicle. By anchoring the ligation to the pedicle, a surgeon decreases the risk of the suture slipping off the pedicle's end. Importantly, this second ligation is placed distal to the first to avert hematoma formation if a vessel is pierced during transfixion.

After traveling through the pedicle, the transfixing strands sweep forward to the clamp toe. These cross in front of the clamp toe, are directed around their respective side of the clamp, and are tied at the heel as the assistant removes the clamp.

TABLE 1-9. Recommended Knot Configurations for Commonly Used Obstetric Suture Material

Suture	Recommended Knot Configuration
Chromic catgut	1 = 1 = 1 or 1 × 1 × 1
Dexon, Vicryl	1 = 1 = 1 = 1 = 1
Monofilament silk	1 = 1 = 1 = 1
Monofilament nylon	1 = 1 = 1 = 1 = 1
Prolene	2 = 2 = 2 or 2 × 2 × 2
Tevdek	1 = 1 = 1 = 1 = 1 or 1 × 1 × 1 × 1 × 1
Other suture types	2 = 2 = 2

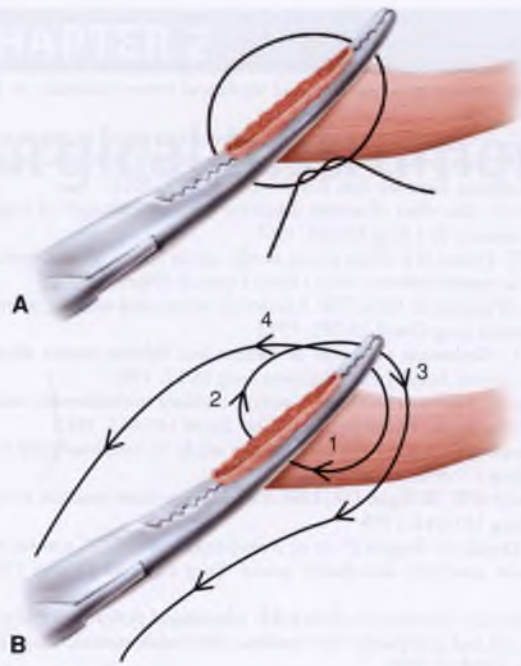


FIGURE 1-10 Double-ligation of a vascular pedicle. **A.** First, simple ligature encircles the pedicle below the clamp. Securing knots are tied at the clamp heel. **B.** With a transfixing stitch several variations are available. Here, the needle pierces the pedicle at the point labeled 1. This should be placed distal to the first ligature shown in part A. Once through the pedicle (point 2), the suture strands sweep to the clamp tip. After crossing at the tip (points 3 and 4), they are drawn back to the clamp heel. Strands are then tied beneath the heel.

In general, when clamped tissue pedicles are ligated, sutures may cut or tear through friable pedicles unless carefully secured. Thus, abrupt ligature cinching is avoided, but this is balanced against protracted cinching in which vessels can escape ligation and bleed.

STAPLES

Most stapling devices currently used for skin approximation are disposable. They are popular because of their speed and the excellent cosmetic appearance of the final incision. A device for placement of absorbable cuticular sutures is also available (Feese, 2013).

Staples are commonly used for skin closure following cesarean delivery. In a Cochrane Database review, Mackeen and associates (2012) reported similar outcomes when staples were compared with subcuticular skin closure. Since that time, however, randomized trials have indicated better results with subcuticular sutures. In two trials with more than 1100 women undergoing cesarean delivery, significantly better outcomes were achieved with subcuticular suture closure than with staples (Figuerola, 2013; Mackeen, 2014). Other trials showed greater patient satisfaction with the subcuticular closure (Aabakke, 2013).

When a stapler is used, the wound edges are everted by a second operator before the surgeon applies the staple. If the edges of a wound invert or if one edge rolls under the opposite side, a poorly formed, deep, noticeable scar will result. Additionally,

pressing too hard against the skin surface with the stapler is avoided to prevent placing the staple too deep and causing ischemia within the staple loop. When placed properly, the crossbar of the staple is elevated a few millimeters above the skin surface (Lammers, 2004). Staples are removed within 5 to 10 days to avoid leaving “track mark” scarring.

SUMMARY

From the foregoing discussion, the following principles may be drawn:

1. Cutting needles are infrequently needed in obstetrics because of their tendency to tear soft tissues like those in the uterus, vagina, hysterectomy pedicles, and fascia. One exception is a subcuticular skin closure. When cutting needles are used, those with a reverse cutting design may reduce the risk of tissue pull-through.
2. A curved needle ideally is not grasped by fingers.
3. Polyglactin 910 (Vicryl) or polyglycolic acid (Dexon) sutures have superior tensile strength compared with chromic catgut for the repair of vaginal lacerations and episiotomies.
4. Suture strength is reduced significantly by stray knots and by grasping the suture with any instrument.
5. With appropriate knot-tying technique, knot ears exceeding 3 mm in length are unnecessary regardless of suture type. Ears exceeding this length predispose to infection.
6. A square configuration is generally more secure than a cross (granny) knot. Either of these knots, however, is preferable to a slipknot, which is insecure after any number of throws.
7. If slipknots are necessary, as in tying one-handed knots in deep spaces, or in assisting in initial tissue approximation, they should be converted to square or granny configuration after placement. If conversion is not technically possible, tying slipknots over alternate threads is an acceptable substitute.
8. The appropriate knot configuration should be used for the suture material selected. In a properly tied knot, additional “insurance throws” do not contribute to knot security and may enhance infection.

REFERENCES

- Aabakke AJ, Krebs L, Pippert CB, et al: Subcuticular suture compared with staples for skin closure after cesarean delivery: a randomized controlled trial. *Obstet Gynecol* 122(4):878, 2013
- Aberg C: Change in strength of aponeurotic tissue enclosed in the suture during the initial healing period. An experimental investigation in rabbits. *Acta Chir Scand* 142:429, 1976
- Abidin MR, Towler MA, Thacker JG, et al: New atraumatic rounded-edge surgical needle holder jaws. *Am J Surg* 157:241, 1989
- Alexander JW, Kaplan JZ, Altemeier WA: Role of suture materials in the development of wound infection. *Ann Surg* 165:192, 1967
- Annunziata CC, Drake DB, Woods JA, et al: Technical considerations in knot construction. Part I. Continuous percutaneous and dermal suture closure. *J Emerg Med* 15:351, 1997
- Babety Z, Sümer A, Altintas S, et al: Changes in knot-holding capacity of sliding knots in vivo and tissue reaction. *Arch Surg* 133:727, 1998
- Balgobin S, Hamid CA, Hoffman BL: Intraoperative considerations. In Hoffman BL, Schorge JO, Bradshaw KD, et al (eds): *Williams Gynecology*, 3rd ed. New York, McGraw-Hill Education, 2016
- Batra EK, Taylor PT, Franz DA, et al: A portable tensiometer for assessing surgeon's knot tying technique. *Gynecol Oncol* 48:114, 1993
- Bennett RG: Selection of wound closure materials. *J Am Acad Dermatol* 68:742, 1988

- Birdwell DC, Gavelin GE, Kemsley FM, et al: "Staying power"—absorbable vs nonabsorbable. *Plast Reconstr Surg* 18:619, 1981
- Brown RP: Knotting technique and suture materials. *Br J Surg* 79:399, 1992
- Bucknall TE: Factors influencing wound complications: a clinical and experimental study. *Ann R Coll Surg* 65:71, 1983
- Carroll RE: Surgical catgut: the myth of allergy. *J Hand Surg* 14B:218, 1989
- Conn J Jr, Oyasu R, Welsh M, et al: Vicryl (polyglactin 910) synthetic absorbable sutures. *Am J Surg* 28:19, 1974
- Craig PH, Williams JA, Davis KW, et al: A biologic comparison of polyglactin 910 and polyglycolic acid synthetic absorbable sutures. *Surg Gynecol Obstet* 141:1, 1975
- Dalgleish AG, Malkovsky M: Surgical gloves as a mechanical barrier against human immunodeficiency virus. *Br J Surg* 75:171, 1988
- DeGirolamo KM, Courtemanche DJ, Hill WD, et al: Use of safety scalpels and other safety practices to reduce sharps injury in the operating room: what is the evidence? *Can J Surg* 56(4):263, 2013
- Dunn DL: *Wound Closure Manual*. Somerville, Ethicon, 2005
- Edlich RF: *USSC Surgical Knot Tying Manual*. Norwalk, United States Surgical Corporation, 1991
- Edlich RF, Panek PH, Rodeheaver GT, et al: Surgical sutures and infection: a biomaterial evaluation. *J Biomed Mater Res* 8:115, 1974
- Feese C, Johnson S, Hones E, et al: A randomized trial comparing metallic and absorbable staples for closure of Pfannenstiel incision for cesarean delivery. *Am J Obstet Gynecol* 209(6):556.e1, 2013
- Figueroa D, Jauk VC, Szychowski JM, et al: Surgical staples compared with subcuticular suture for skin closure after cesarean delivery: a randomized controlled trial. *Obstet Gynecol* 121(1):33, 2013
- Foster GE, Hardcastle JD: Polyglycolic acid as suture material. *Lancet* 1(8056):154, 1978
- Frazza EJ, Schmitt EE: A new absorbable suture. *J Biomed Mater Res* 5:43, 1971
- Freeman BS, Homsy CA, Fissette J, et al: An analysis of suture withdrawal stress. *Surg Gynecol Obstet* 131:441, 1970
- Geiger D, Debus ES, Ziegler UE, et al: Capillary activity of surgical sutures and suture-dependent bacterial transport: a qualitative study. *Surg Infect* 6:377, 2005
- Goulbourne IA, Nixon SJ, Naylor AR, et al: Comparison of polyglactin 910 and nylon in skin closure. *Br J Surg* 75:586, 1988
- Hamid CA, Hoffman BL: Intraoperative considerations. In Hoffman BL, Schorge JO, Halvorson LM, et al (eds): *Williams Gynecology*, 2nd ed. New York, McGraw-Hill, 2012
- Hartko WJ, Ghanekar G, Kemmann E: Suture materials currently used in obstetric-gynecologic surgery in the United States: a questionnaire survey. *Obstet Gynecol* 59:241, 1982
- Haxton H: The influence of suture materials and methods on the healing of abdominal wounds. *Br J Surg* 52:372, 1965
- Herrmann JB: Changes in tensile strength and knot security of surgical sutures in vivo. *Arch Surg* 106:797, 1973
- Herrmann JB: Tensile strength and knot security of surgical suture materials. *Am Surg* 37(4):209, 1971
- Hochberg J, Murray GF: Principles of operative surgery. In Sabiston DC Jr (ed), *Textbook of Surgery*, 14th ed. Philadelphia, WB Saunders, 1991
- Homsy CA, McDonald KE, Akers WW: Surgical suture—canine tissue interaction for six common suture types. *J Biomed Mater Res* 2:215, 1968
- Hurt J, Unger JB, Ivy JJ, et al: Tying a loop-to-strand suture: is it safe? *Am J Obstet Gynecol* 192:1094, 2005
- Ivy JJ, Unger JB, Hurt J, et al: The effect of number of throws on knot security with nonidentical sliding knots. *Am J Obstet Gynecol* 191:1618, 2004
- Ketcham KR, Pastorek JG II, Letellier RL: Episiotomy repair: chromic versus polyglycolic acid suture. *South Med J* 87:514, 1994
- Kettle C, Dowsell T, Ismail KM: Absorbable suture materials for primary repair of episiotomy and second degree tears. *Cochrane Database Syst Rev* 6:CD000006, 2010
- Lammers R, Trott A: Methods of wound closure. In Roberts J, Hedges J (eds): *Clinical Procedures in Emergency Medicine*. Philadelphia, WB Saunders, 2004, p 655
- Lister J: Observations on ligature of arteries on the antiseptic system. *Lancet* 6:289, 1869
- Mackeen AD, Berghella V, Larsen ML: Techniques and materials for skin closure in caesarean section. *Cochrane Database Syst Rev* 11:CD003577, 2012
- Mackeen AD, Fleisher J, Khalifeh A, et al: Patient satisfaction and cosmetic outcome in a randomized study of cesarean skin closure. *Obstet Gynecol* 123(Suppl 1):4S, 2014
- Mackrodt C, Gordon B, Fern E, et al: The Ipswich childbirth study: 2. A randomised comparison of polyglactin 910 with chromic catgut for postpartum perineal repair. *BJOG* 105:441, 1998
- Madsen ET: An experimental and clinical evaluation of surgical suture materials—I and II. *Surg Gynecol Obstet* 97:73, 1953
- McGeehan D, Hunt D, Chaudhuri A, et al: An experimental study of the relationship between synergistic wound sepsis and suture materials. *Br J Surg* 67:636, 1980
- Mischke C, Verbeek JH, Saarto A, et al: Gloves, extra gloves or special types of gloves for preventing percutaneous exposure injuries in healthcare personnel. *Cochrane Database Syst Rev* 7:3:CD009573, 2014
- Moloney GE: The effect of human tissues on the tensile strength of implanted nylon sutures. *Br J Surg* 48:528, 1961
- Mornar SJ, Perlow JH: Blunt suture needle use in laceration and episiotomy repair at vaginal delivery. *Am J Obstet Gynecol* 198:e14, 2008
- Moy RL, Waldman B, Hein DW: A review of sutures and suturing techniques. *J Dermatol Surg Oncol* 18:785, 1992
- Nilsson T: Mechanical properties of Prolene and Ethilon sutures after three weeks in vivo. *Scand J Plast Reconstr Surg* 16:11, 1982
- Osterberg B: Enclosure of bacteria within capillary multifilament sutures as protection against leukocytes. *Acta Chir Scand* 149:663, 1983
- Postlethwait RW: Long-term comparative study of nonabsorbable sutures. *Ann Surg* 171:892, 1970
- Postlethwait RW, Willigan DA, Ulin AW: Human tissue reaction to sutures. *Ann Surg* 181:144, 1975
- Ray JA, Doddi N, Regula D, et al: Polydioxanone (PDS), a novel monofilament synthetic absorbable suture. *Surg Gynecol Obstet* 153:497, 1981
- Rodeheaver GT, Thacker JG, Edlich RF: Mechanical performance of polyglycolic acid and polyglactin 910 synthetic absorbable sutures. *Surg Gynecol Obstet* 153:835, 1981
- Sajid MS, Craciunas L, Sains P, et al: Use of antibacterial sutures for skin closure in controlling surgical site infections: a systematic review of published randomized, controlled trials. *Gastroenterol Rep* 1(1):42, 2013
- Salthouse TN: Biologic response to sutures. *Otolaryngol Head Neck Surg* 88(6):658, 1980
- Salthouse TN, Matlaga BF: Significance of cellular enzyme activity at nonabsorbable suture implant sites: silk, polyester, and polypropylene. *J Surg Res* 19:127, 1975
- Schoetz DJ, Coller JA, Veidenheimer MC: Closure of abdominal wounds with polydioxanone. *Arch Surg* 213:72, 1988
- Serrano CW, Wright JW, Newton ER: Surgical glove perforation in obstetrics. *Obstet Gynecol* 191:77:525, 1991
- Sharp WV, Belden TA, King PH, et al: Suture resistance to infection. *Surgery* 92:61, 1982
- Snyder CC: On the history of the suture. *Plast Reconstr Surg* 58(4):401, 1976
- Stamp CV, McGregor W, Rodeheaver GT, et al: Surgical needle holder damage to sutures. *Am Surg* 54:300, 1988
- Stone IK: Suture materials. *Clin Obstet Gynecol* 31(3):712, 1988
- Stone IK, von Fraunhofer JA, Masterson BJ: The biomechanic effects of tight suture closure upon fascia. *Surg Gynecol Obstet* 163:448, 1986
- Tera H, Aberg C: Strength of knots in surgery in relation to type of knot, type of suture material, and dimension of suture thread. *Acta Chir Scand* 143:75, 1977
- Tera H, Aberg C: Tensile strengths of twelve types of knot employed in surgery, using different suture materials. *Acta Chir Scand* 142:1, 1976
- Thacker JG, Rodeheaver G, Kurtz L, et al: Mechanical performance of sutures in surgery. *Am J Surg* 133:713, 1977
- Thacker JG, Rodeheaver G, Moore JW, et al: Mechanical performance of surgical sutures. *Am J Surg* 130:374, 1975
- Tomita N, Tamai S, Shimaya M, et al: A study of elongation and knot slacking of various sutures. *Biomed Mater Eng* 2:71, 1992
- Trimbos JB: Security of various knots commonly used in surgical practice. *Obstet Gynecol* 64:274, 1984
- Trimbos JB, Smeets M, Verdel M, et al: Cosmetic result of lower midline laparotomy wounds: polybutester and nylon skin suture in a randomized clinical trial. *Obstet Gynecol* 82:390, 1993
- Williams DF: The effect of bacteria on absorbable sutures. *J Biomed Mater Res* 14:329, 1980
- Williams DF, Mort E: Enzyme-accelerated hydrolysis of polyglycolic acid. *J Bioeng* 1:231, 1977
- Yag-Howard C: Sutures, needles, and tissue adhesives: a review for dermatologic surgery. *Dermatol Surg* 40(Suppl 9):S3, 2014
- Zimmer CA, Thacker JG, Power DM, et al: Influence of knot configuration and tying technique on the mechanical performance of sutures. *J Emerg Med* 9:107, 1991

CHAPTER 2

Surgical Instruments

INSTRUMENTS	15
ELECTROSURGERY	22
SURGICAL DRAINS	24
VACUUM-ASSISTED WOUND CLOSURE	25

INSTRUMENTS

Surgical instruments are designed to extend the capability of a surgeon's hands and thus are crafted to retract, cut, grasp, and clear the operative field. Tissue types encountered in obstetric surgery vary, and accordingly, so too do the size, fineness, and strength of the tools chosen for a given procedure. Once an instrument is selected, traditional handling strives to maximize its efficiency.

■ Scalpel and Blades

Typical surgical blades used in obstetric surgery are pictured in [Figure 2-1](#) and include no. 10, 11, 15, and 20 blades. Blade anatomy includes the edge, sometimes referred to as the "belly." The unsharpened ridge that lies opposite to the edge is the spine. Last, the slot is the opening within the blade that allows it to be articulated and secured to the knife handle.

With surgical blades, function follows form, and larger blades are used for coarser tissues or larger incisions. For example, the no. 20 blade offers a long edge, which is ideal for quickly covering distance during initial skin incisions. The small no. 15 blade is selected for finer incisions. The acute angle and pointed tip of a no. 11 blade can easily incise tough-walled abscesses for drainage, such as those of the Bartholin gland duct.

When the scalpel is correctly held, the surgeon can direct blade movement. Two methods are shown in [Figure 2-2](#). If the scalpel is held like a pencil, this is termed the "pencil grip" or "precision grip." If the fingers are positioned to straddle the scalpel, this is termed the "power grip," "violin grip," or "bow grip." These grips maximize the use of the knife edge.

With the no. 10 and no. 20 blades, the scalpel is held at a 20- to 30-degree angle to the skin and is drawn firmly along the skin using the arm with minimal wrist and finger movement. This motion aids cutting with the full length of the scalpel edge and avoids burying the tip. In general, a surgeon cuts toward him- or herself and from nondominant to dominant sides. The initial incision should penetrate the dermis, maintaining the scalpel perpendicular to the surface to prevent beveling of the skin edge. During skin incision, firm and symmetrical traction on the lateral aspect of the incision keeps the incision straight and helps avoid multiple tracks and irregular skin edges.

The no. 15 and no. 11 blades, in contrast, are typically held using the pencil grip to make fine, precise incisions. With the no. 15 blade, the scalpel is held approximately 45 degrees to the skin surface. Fine knife dissection is best controlled using the fingers, and the heel of the hand can be stabilized on adjacent tissue. The no. 11 blade scalpel is ideal for stab incisions and is




FIGURE 2-1 Surgical blades commonly used in obstetric surgery.

held upright at nearly 90 degrees to the surface. Creating tension at the skin surface is important to reduce the amount of force required for penetration. Omission of this can result in uncontrolled penetration of underlying structures.

■ Scissors

These are commonly used to divide tissues, and modification in blade shape and size allows their use for various tissue textures (Fig. 2-3). For correct positioning, the thumb and fourth finger are placed within the instrument's rings, and the index finger is set against the crosspiece of the scissors for greater control. This "tripod" grip allows maximum shear, torque, and closing forces to be applied and provides superior stability and control. In general, surgeons cut away from themselves and from dominant to nondominant sides.

Of scissor types, the fine blades of Metzenbaum or iris scissors are used routinely to dissect or define natural tissue planes. As such, they may be employed to divide thin adhesions or incise peritoneum or vaginal epithelium. During dissection, traction on opposing poles of the tissue to be dissected typically simplifies the process. To begin, a small nick is often necessary to enter the correct tissue plane. The blades are closed and inserted between planes, while following the natural curves of tissues being dissected. The blades are opened, and then slightly closed and withdrawn (Fig. 2-4). After turning both wrist and blades 90 degrees, the surgeon reinserts the lower blade, and tissues are divided. When dissecting around a curve, the scissors should follow the natural curve of the structure. Dissection proceeds in the same plane to avoid burrowing into

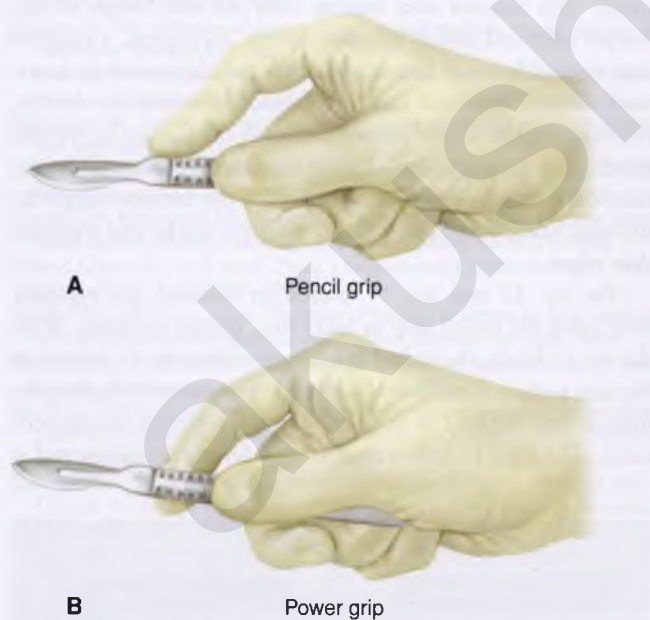


FIGURE 2-2 Scalpel grips. **A.** Scalpel is held as one would a pencil, and movement is directed by the thumb and index finger. **B.** Scalpel is held between the thumb and third finger. The end of the blade is forced up against the thenar muscles of the hand. (Reproduced with permission from Balgobin S, Hamid CA, Hoffman BL: Intraoperative considerations. In Hoffman BL, Schorge JO, Bradshaw KD, et al (eds): *Williams Gynecology*, 3rd ed. New York, McGraw-Hill Education, 2016.)

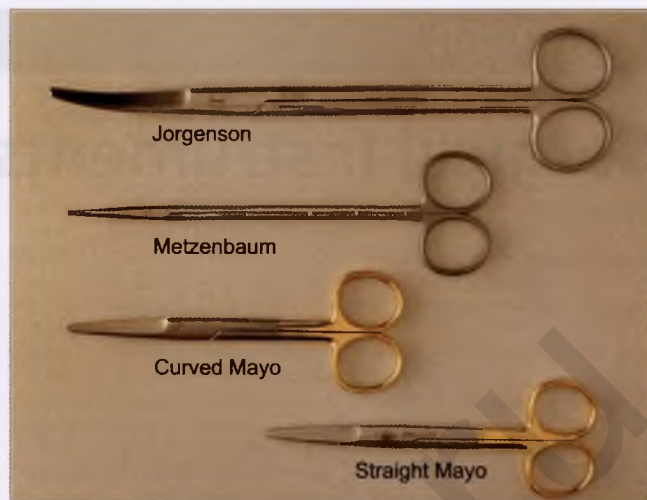


FIGURE 2-3 Scissors. (Scissors were provided by U.S. Surgitech, Inc.)

the structure or deviating away and toward unintended adjacent tissues.

Sturdier scissors such as curved Mayo scissors are used on denser tissue, such as anterior abdominal wall fascia. Similarly, Jorgenson scissors have thick blades and tips that are curved at a 90-degree angle. These are often used to separate the vagina and uterus during the final steps of hysterectomy. Straight Mayo scissors have blunt, flat blades. They are frequently used as suture-cutting scissors and should be reserved for this function. Use of tissue scissors for suture cutting can dull their blades and is ideally avoided.

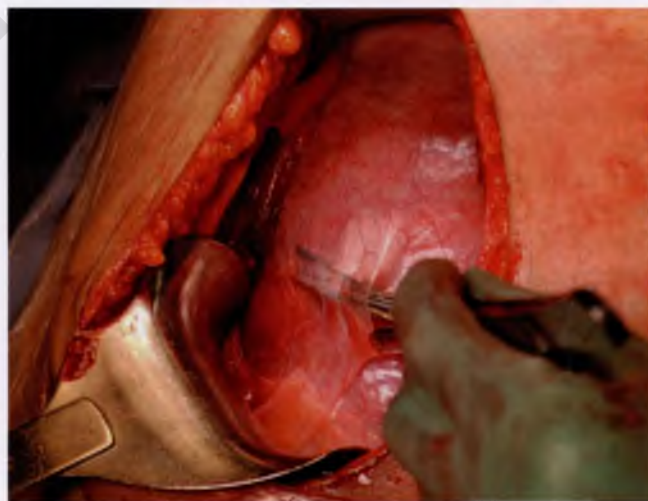

FIGURE 2-4 Plane dissection during repeat cesarean delivery. First, elevation of the peritoneum with forceps is followed by a shallow snip by Metzenbaum scissors. This permits entry into the dissection plane. During development of tissue planes, the closed scissor tips are placed at the border between two tissues, and forward pressure is applied to advance the tips. As shown here, scissors are then spread to expand the tissue plane. Next, scissor blades are slightly closed and retracted. Both blades and wrist are rotated 90 degrees. The lower blade is reinserted into the newly created tissue plane, and tissues are divided. (Used with permission from Dr. Sarah White.)

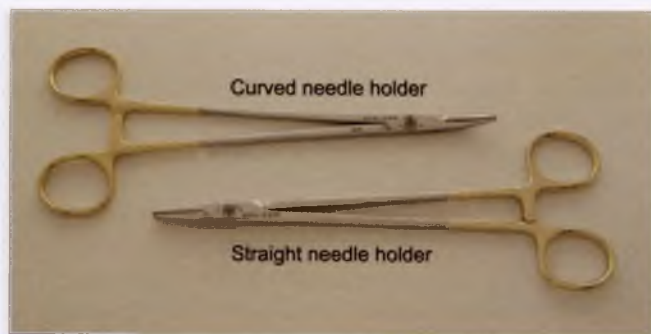


FIGURE 2-5 Needle drivers. (Scissors were provided by U.S. Surgitech, Inc.)

Clamps and scissors are not designed for ambidextrous use. The easy release of a clamp or use of standard right-handed scissors with the left hand therefore requires a different handgrip and technique than when these instruments are used with the right hand. The surgeon should strive to be facile in the use of these instruments with either hand using the appropriate grip and technique.

■ Needle Holders

Also called needle drivers, needle holders typically possess either straight or curved jaws (Fig. 2-5). Straight jaws are more frequently used. But curved jaws, such as those of the Heaney needle holder, aid needle placement in confined or angled areas. Needle holder anatomy also varies at the inner surface of each jaw. Surfaces typically contain either transverse serrations or cross hatching to help grip the needle securely. In most cases, the needle holder clasps a needle at a right angle and at a site approximately two-thirds from the needle tip, termed the swage. Unlike the cylindrical body of the needle, the swage is usually flattened, which improves the needle holder's grasp. If a curved holder is used, the needle is clasped similarly, and the inner curve of the holder faces the needle swage (Fig. 1-4, p. 4).

Traditionally, the needle holder is held with the thumb and fourth finger in the rings. The greatest advantage of this

grip is the precision afforded when directing needles. Also, the spring tension of the handles can be relieved from the lock in a controlled fashion, thereby releasing and regrasping the needle more precisely. Alternatively, with the "palmar grip," the needle holder is held between the ball of the thumb and the base of the remaining fingers. No fingers enter the instrument rings. This grip allows a simple rotating motion for driving curved needles through an arc. Its greatest advantage is the time saved during continuous suturing, as the needle can be released, regrasped, and redirected efficiently without replacing fingers in and out of the instrument rings. Disadvantageously, this grip has the potential to lack precision during needle release. When unlocking the needle driver, release of the spring lock should be smooth and gradual. This avoids an abrupt release, which may suddenly pop the handles apart with potential for awkwardness, loss of needle control, and tissue injury.

■ Tissue Forceps

Forceps function to hold tissue during cutting, to retract tissue for exposure, stabilize tissue during suturing, extract needles, grasp vessels for electro-surgical coagulation, pass ligatures around hemostats, and pack sponges. Forceps are held so that one blade functions as an extension of the thumb and the other as an extension of the opposing fingers. Alternate grips may appear awkward and limit the full range of wrist motion, leading to suboptimal instrument use.

Several types of forceps are used to handle tissues and to place sutures (Fig. 2-6). Heavy-toothed forceps, such as the Potts-Smith single-toothed forceps, Bonney forceps, and Ferris-Smith forceps, are used when a firm grasp is more important than gentle tissue handling. These tools are often used to hold fascia for abdominal wound closure. Light-toothed forceps, such as the single-toothed Adson, concentrate force on a tiny area and give more holding power with less tissue damage. These are used for more delicate work on moderately dense tissue such as skin.

Nontoothed forceps, also known as smooth forceps, exert their grip through serrations on the opposing tips. They are

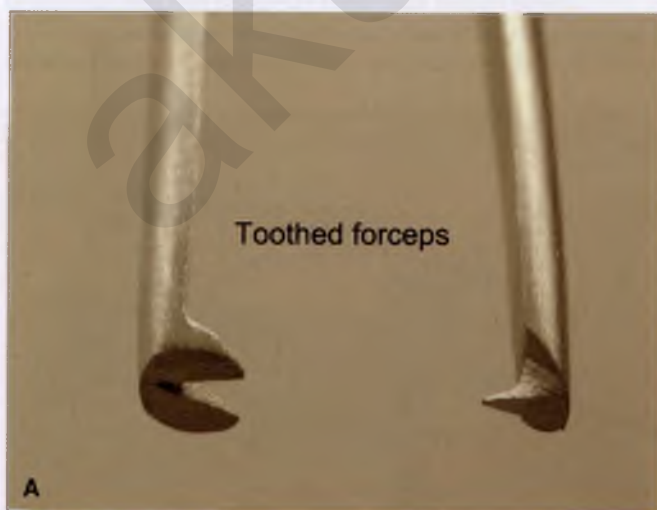

FIGURE 2-6 Tissue forceps. **A.** Tip of toothed forceps allows a firm tissue grasp. **B.** Smooth tissue forceps. (Forceps were provided by U.S. Surgitech, Inc.)

typically used for handling delicate tissue, such as peritoneum, and provide some holding power with minimal injury. DeBakey forceps are another type of smooth forceps, which were originally designed as vascular forceps but can be used for other delicate tissues. In contrast, the broader, shallow-grooved tips of Russian forceps and Singley forceps may be preferred if a broader or thicker area of tissue is manipulated. These are often used during hysterotomy closure during cesarean delivery.

■ Retractors

Abdominal Surgery

Clear visualization is essential during surgery, and retractors conform to body and organ angles to allow tissues to be pulled back from an operative field. In obstetrics, retractors may be grouped broadly as abdominal or vaginal and then as self-retaining or handheld.

Abdominal surgery in most cases requires active participation of an assistant surgeon around a confined incision. Thus, retractors that by themselves hold abdominal wall muscles apart, termed *self-retaining*, are often employed during laparotomy. Styles such as the Kirschner and O'Connor-O'Sullivan contain four broad, gently curved blades and retract in four directions. Blades pull the bladder caudally, the anterior abdominal wall muscles laterally, and the packed upper abdominal contents cephalad. The Balfour retractor retracts in three directions (Fig. 2-7). It can be made to retract in four with the addition of an upper arm attachment. Alternatively, ring-shaped retractors such as the Bookwalter and Denis Browne styles offer greater variability in the number and positioning of retractor blades. However, these usually require more time to assemble and place. With most of these styles, deep or shallow blades can be attached to the outer metal frame according to the abdominal cavity depth.

During self-retaining retractor positioning, attention is focused on blade depth to avoid femoral nerve compression injury. This nerve can be compressed anywhere along its course but is particularly susceptible within the body of the psoas muscle. In prevention, lateral retractor blades are selected and positioned such that only the rectus abdominis muscle and not the psoas muscle is retracted (Chen, 1995). The retractor blades are evaluated when placed, to confirm that they are not resting on the psoas muscle. For thin patients, folded laparotomy towels may be placed between the retractor rim and skin to elevate blades away from the psoas muscle.

In contrast to these reusable types, disposable self-retaining retractors consist of two equal-sized plastic rings connected by a cylindrical plastic sheath (Alexis and Mobius retractors). One ring collapses into a canoe shape that can be threaded through the incision and into the abdomen. Once inside the abdomen, it springs again to its circular form. The second ring remains exteriorized (Fig. 2-8). Between these rings, the plastic sheath spans the thickness of the abdominal wall. To hold the retractor in place, a surgeon everts the entire circumference of the exterior ring multiple times. This folding takes up slack in the sheath until the sheath is tight against the skin and subcutaneous layers. This yields 360-degree retraction, and disposable retractors come in variable sizes.

In addition to or in place of these self-retaining styles, a surgical assistant can use a handheld retractor. These instruments allow retraction in only one direction but can be placed and repositioned quickly (Fig. 2-9). The Richardson retractor has a sturdy, shallow right-angled blade that can hook around an incision for abdominal wall retraction. Alternatively, Deaver retractors have a gentle arching shape and conform easily to the curve of the anterior abdominal wall. Compared with Richardson retractors, they offer increased blade depth and are used commonly

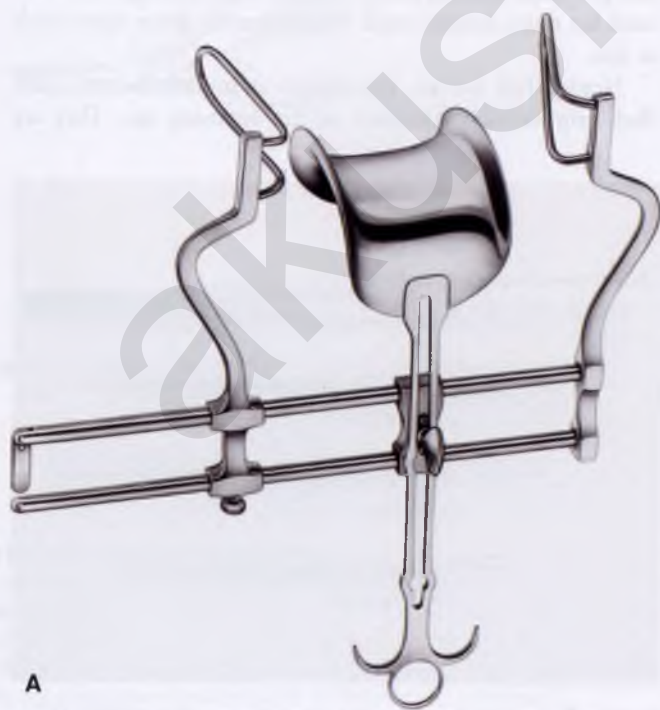

FIGURE 2-7 Self-retaining retractors. **A.** Balfour retractor. **B.** Bookwalter retractor.

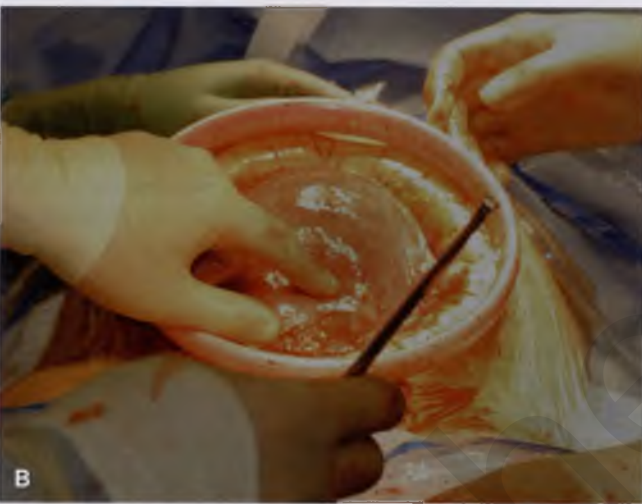
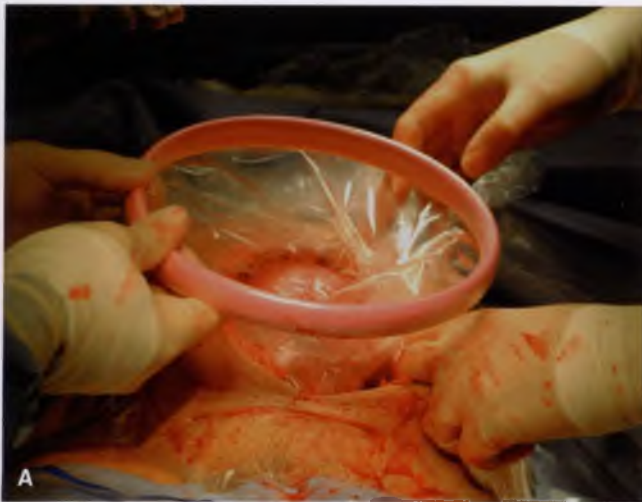
FIGURE 2-8 Disposable self-retaining retractor. **A.** The exterior ring is everted to fold the plastic sheath over the ring multiple times to take up slack in the sheath. **B.** This allows the sheath to conform tightly to the wound and provide retraction in 360 degrees.

to retract bowel, bladder, or anterior abdominal wall muscles. A Harrington retractor, also called a sweetheart retractor, has a broader tip that also effectively holds back packed bowel.

For laparoscopy or minilaparotomy incisions, the preceding retractors are too large, and those with smaller blades such as



FIGURE 2-9 Long, handheld abdominal retractors. (Retractors were provided by U.S. Surgitech, Inc.)




FIGURE 2-10 Short, handheld abdominal retractors. (Retractors were provided by U.S. Surgitech, Inc.)

the army-navy retractor or S-retractor are selected. S-retractors offer thinner, deeper blades, whereas the sturdier blades of the army-navy style allow stronger retraction (Fig. 2-10). Additionally, a metal Weitlaner or small-diameter disposable Alexis or Mobius self-retaining retractor may be used for minilaparotomy incisions.

In certain instances, such as vaginal cuff suturing or uterine artery ligation, a thin retractor blade, termed a malleable or ribbon retractor, may be required. Here, it serves as a metal wall to isolate actively sutured tissue from surrounding organs. This long, flexible metal strip can also be bent to conform to various body contours and can be used to retract. Narrow and wider sizes are available. A ribbon retractor can also be positioned to protect intestines from needle-stick injury during abdominal wall closure. This approach is especially useful in obese women or when anesthetic relaxation is not ideal. The retractor is placed over the intestines beneath the peritoneum and is left in place as a barrier while the fascia is closed. It is removed prior to final fascial stitches. Similarly, using a McNealy-Glassman viscera retainer—a “fish”—can help avoid needle-stick bowel perforation (Fig. 2-11). Prior to closing the final 2 to 3 cm of fascia, the surgeon pulls on the attached ring to remove the flexible retainer.

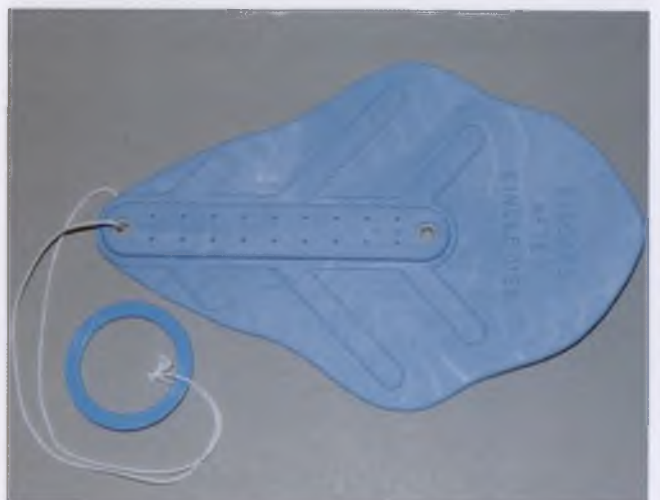

FIGURE 2-11 McNealy-Glassman viscera retainer. Also colloquially called a “fish.”

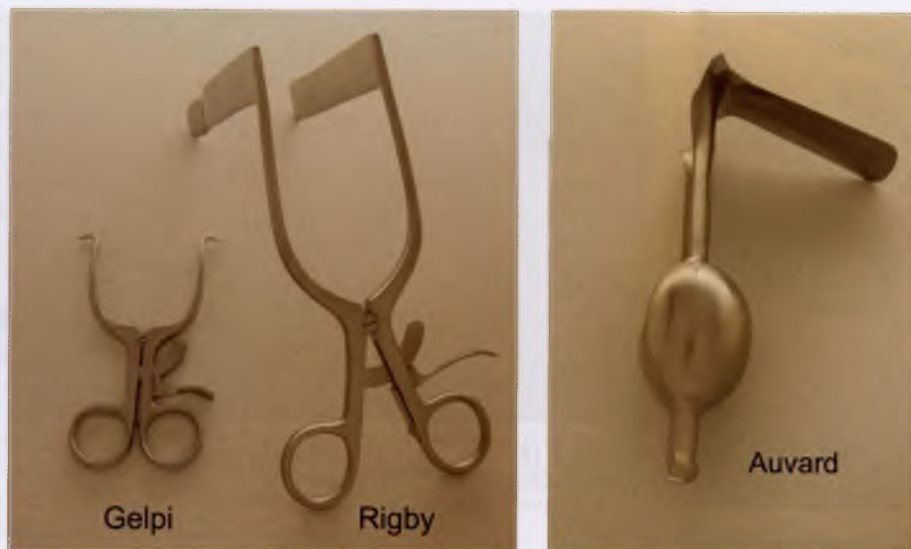


FIGURE 2-12 Vaginal self-retaining retractors. (Retractors were provided by U.S. Surgitech, Inc.)

Vaginal Surgery

To provide exposure for vaginal surgery, it is necessary to separate the vaginal walls, and several self-retaining retractors have been designed for this purpose (Fig. 2-12). The Gelpi retractor has two narrow teeth that are placed distally against opposing lateral vaginal walls and is most appropriate for perineal procedures. The Rigby retractor, with its longer blades, more effectively separates lateral vaginal walls, whereas a Graves speculum can be used to hold apart anterior and posterior walls. Finally, an Auvard weighted speculum contains a long, single blade and ballasted end, which uses gravity to pull the posterior vaginal wall downward.

The degree of retraction offered by vaginal self-retaining retractors at times may be limited. Therefore, handheld retractors used by an assistant are often required to augment or replace these instruments. Handheld retractors used in vaginal surgery include the Heaney right-angle retractor, a narrow Deaver retractor, and the Breisky-Navratil retractor (Fig. 2-13).

■ Tissue Clamps

Several types of tissue clamps are used for retraction during abdominal and vaginal operations. To manipulate the different textures encountered, these clamps are fashioned in various

shapes, sizes, and strengths. Importantly, some of these clamps are traumatic to tissue.

During vaginal procedures, the cervix often must be manipulated. Lahey thyroid clamps offer a secure grip, but their several sharp teeth can cause significant trauma. These are therefore less than ideal if the cervix is not removed at surgery. Alternatively, a single-toothed tenaculum can afford a firm grip but with less cervical injury (Fig. 2-14). As such, this tool is often employed during dilatation and curettage. Of less traumatic clamps, ring forceps, also called sponge forceps, can be used on the cervix and other dense tissues such as muscles. These forceps have large circular jaws with fine transverse grooves. Additionally, a folded gauze sponge can be placed between its jaws and used to absorb blood from the operative field or retract tissues.

For gentle elevation of fallopian tubes, the smooth, cupped jaws of a Babcock clamp are well suited. In contrast, the serrated teeth of the Allis and Allis-Adair clamps can provide a fine, firm grip on fascia or similar tissue (Fig. 2-15).

Tissue clamps can also occlude vascular and tissue pedicles during organ excision. Hemostat, tonsil, and Mixer right-angle clamps have small, slender jaws with fine inner transverse ridges to atraumatically grasp delicate tissue, especially vessels (Fig. 2-16). Heavier clamps are required to grasp and manipulate stiffer

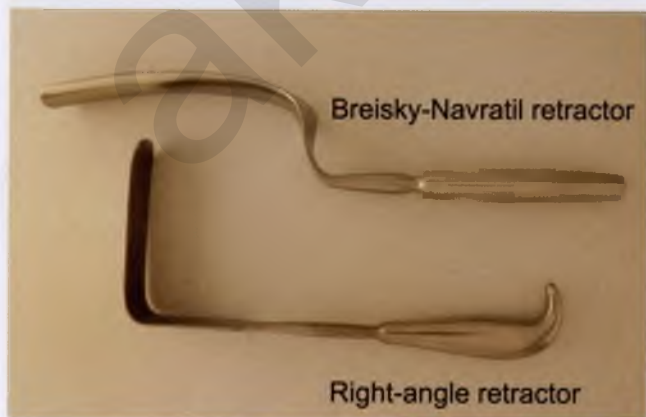


FIGURE 2-13 Vaginal handheld retractors. (Retractors were provided by U.S. Surgitech, Inc.)

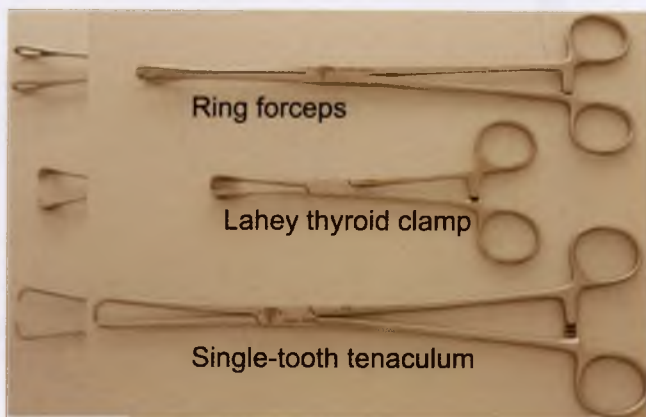


FIGURE 2-14 Clamps shown both open (left) and closed (right). (Clamps were provided by U.S. Surgitech, Inc.)

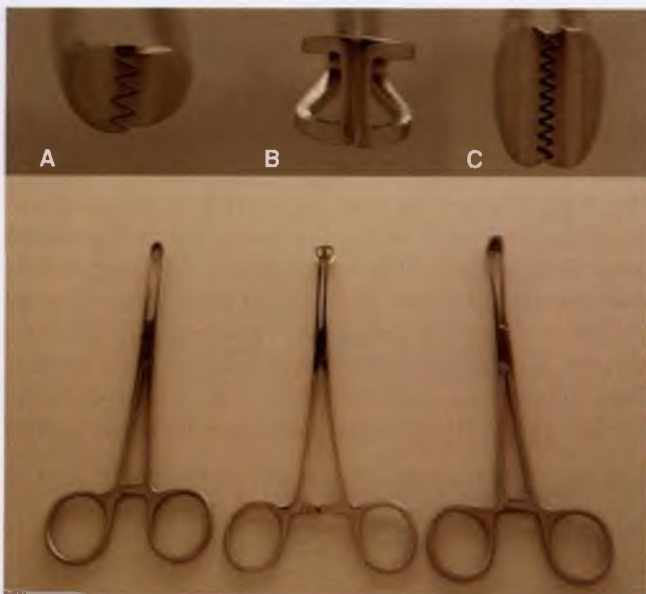


FIGURE 2-15 Tissue clamps. **A.** Allis. **B.** Babcock. **C.** Allis-Adair. (Reproduced with permission from Balgobin S, Hamid CA, Hoffman BL: Intraoperative considerations. In Hoffman BL, Schorge JO, Bradshaw KD, et al (eds): Williams Gynecology, 3rd ed. New York, McGraw-Hill Education, 2016. Clamps provided by U.S. Surgitech, Inc.)

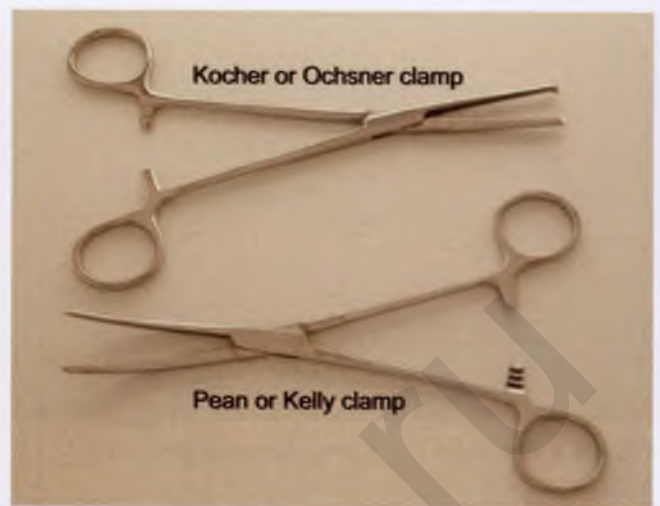


FIGURE 2-17 Tissue clamps. (Clamps were provided by U.S. Surgitech, Inc.)

tissues such as fascia. Examples include Pean or Kelly clamps and Kocher or Ochsner clamps (Fig. 2-17). These sturdy clamps have finely spaced transverse grooves along their inner jaws to minimize tissue slippage. They may be straight or curved to fit tissue contours. And, as with Kocher clamps, they may contain a set of interlocking teeth at the tip for additional grip security.

Ligaments that support the uterus and vagina are fibrous and vascular. Thus, a sturdy clamp that resists tissue slippage from its jaws is required during hysterectomy. Several clamps, including Heaney, Ballantine, Rogers, Zeppelin, and Masterson clamps, are effective (Fig. 2-18). The thick, durable

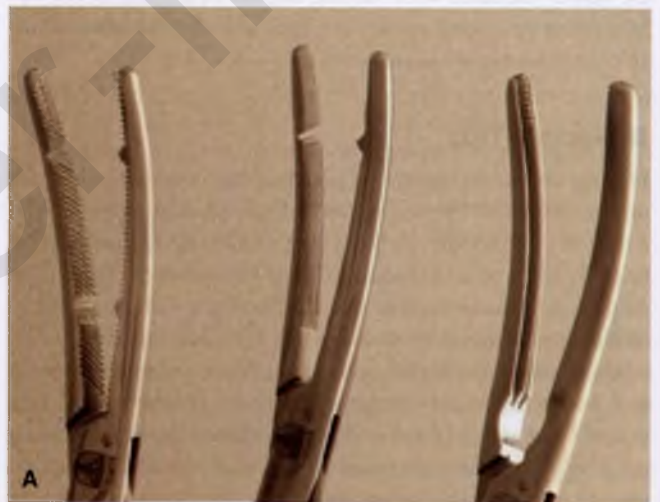

FIGURE 2-18 Heavy tissue clamps. **A.** From left to right: Heaney, Heaney-Ballantine, and Zeppelin clamp tips. **B.** Heaney clamps are constructed with a variety of curved tips. (Clamps were provided by U.S. Surgitech, Inc.)

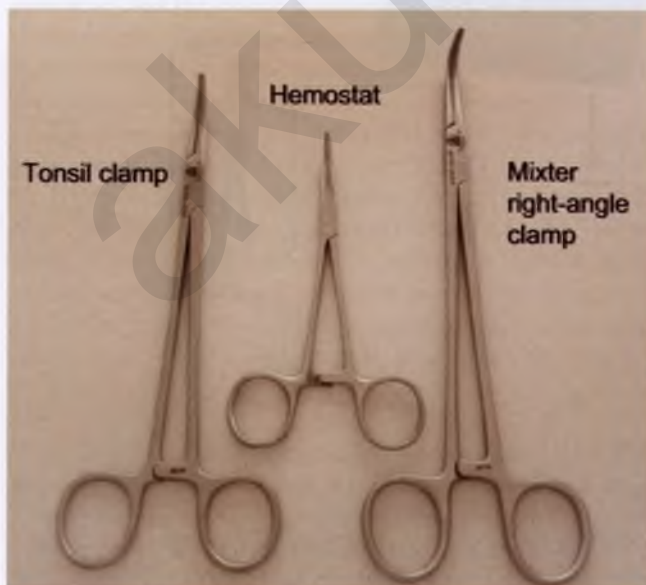

FIGURE 2-16 Vascular clamps. (Clamps were provided by U.S. Surgitech, Inc.)

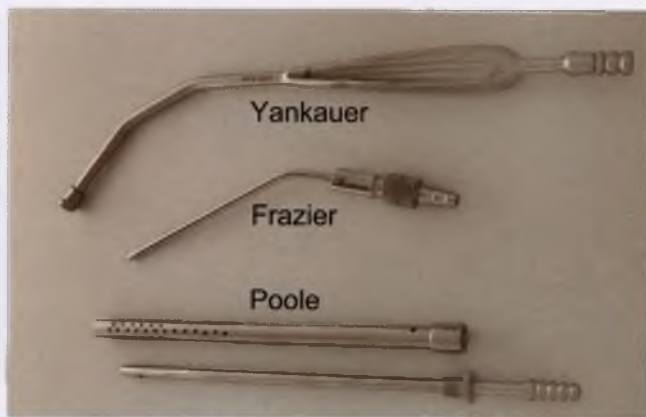


FIGURE 2-19 Suction tips. (Clamps were provided by U.S. Surgitech, Inc.)

jaws of these clamps carry deep, finely spaced grooves or serrations arranged either transversely or longitudinally for secure tissue grasping. Additionally, some contain a set of interlocking teeth at the tip or heel or both. Although this modification improves grip, it also may increase tissue trauma. These clamps are also constructed with varying degrees of angling at the tip. More acutely angled clamps are typically selected when available operating space is cramped.

■ Suction Tips

During obstetric surgery, suction may be needed to clear the operative field of blood, amniotic fluid, peritoneal fluids, and irrigants. Accordingly, the choice of suction tip typically is dictated by the type and amount of fluid encountered (Fig. 2-19). Adson and Frazier suction tips are fine bore and are useful in shallow or confined areas and when little bleeding is present. Alternatively, a Yankauer suction tip offers a midrange-sized tip and is used commonly in obstetric surgery. However, if a larger volume of fluid or blood is expected, then a Poole suction tip may be preferable. Its multiple pores allow continued suction even if some are obstructed with clot or tissue. In addition to removing large volumes of fluid quickly, the sieved sheath of the tip can be removed. The thinner-bore inner suction cannula can then be used for finer suctioning. Larger-bore Karman suction cannulas are used for evacuation of products of conception and are discussed in Chapter 9 (p. 137).

ELECTROSURGERY

Electrosurgery is one of the most commonly applied surgical tools and enables surgeons to coagulate vessels and incise tissues rapidly. Familiarity with the basic principles of electrosurgical methods can increase its effective use and minimize tissue injury. Semantically, *electrosurgery* differs from *electrocautery*, although the terms are often incorrectly interchanged. Electrosurgery directs the flow of current to the tissues themselves and produces localized tissue heating and destruction. As a result, electric current must pass through tissues to produce the desired effect (Amaral, 2005). By contrast, with electrocautery, electric current passes through a metal object, such as a wire loop, with internal resistance. Passage of the current through the resistance heats the loop, which then

may be used surgically. The flow of current is limited to the metal being heated, and no current enters the patient.

■ Monopolar Electrosurgery

Electric current is the flow of electrons through a circuit (Fig. 2-20). *Voltage* is the force that drives those charges around the circuit. *Impedance* is the obstacle that alternating current meets along the way. The electrosurgical circuit contains four main parts: the generator, the active electrode, the patient, and the return electrode. In monopolar electrosurgery, the return electrode in clinical use is the grounding pad. Current therefore flows: (1) from the generator, which is the source of voltage, (2) through the electrosurgical instrument tip to the patient,

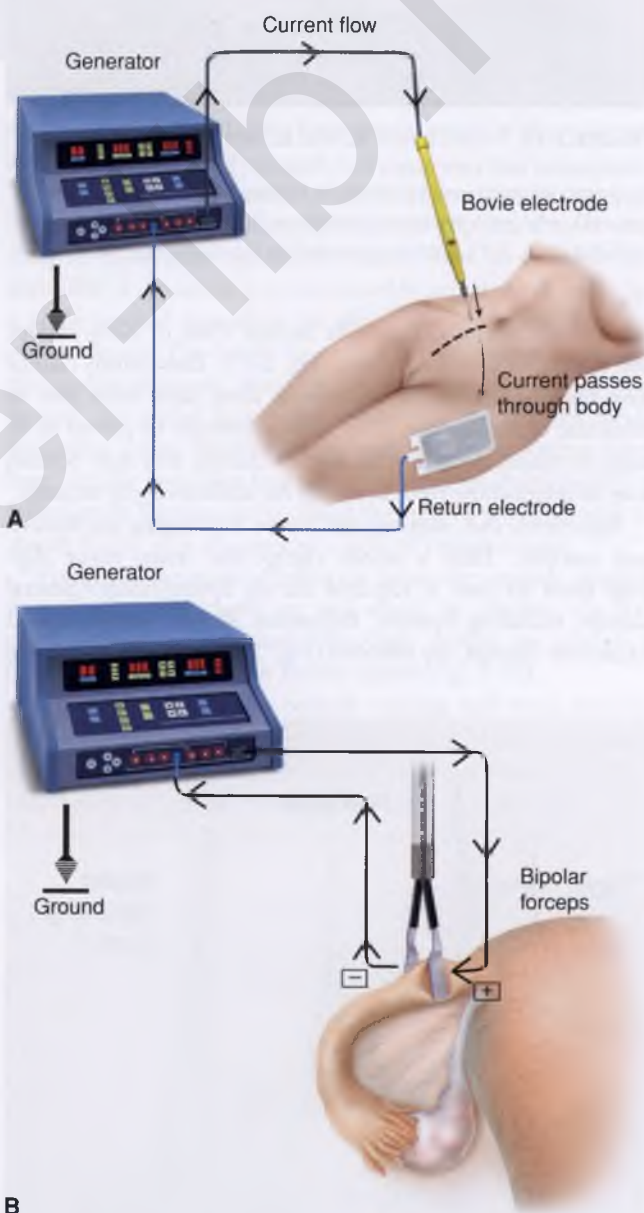

FIGURE 2-20 Circuits in electrosurgery. **A.** Monopolar electrosurgical circuit. **B.** Bipolar electrosurgical circuit. (Reproduced with permission from Balgobin S, Hamid CA, Hoffman BL: Intraoperative considerations. In Hoffman BL, Schorge JO, Bradshaw KD, et al (eds): *Williams Gynecology*, 3rd ed. New York, McGraw-Hill Education, 2016.)

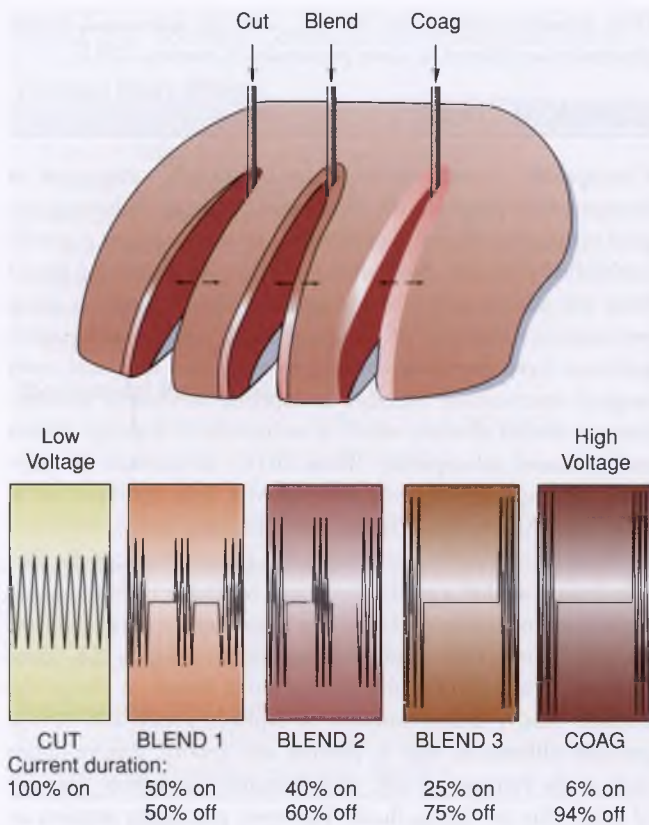


FIGURE 2-21 Tissue effects vary with cutting, blended, and coagulation currents. Lateral thermal damage with a pure coagulation current is increased compared with that from a pure cutting or blended current. The duration of applied energy varies between current types. (Reproduced with permission from Balgobin S, Hamid CA, Hoffman BL: Intraoperative considerations. In Hoffman BL, Schorge JO, Bradshaw KD, et al (eds): Williams Gynecology, 3rd ed. New York, McGraw-Hill Education, 2016.)

the source of impedance, and then (3) onto the grounding pad, where it is dispersed. Current leaves the pad to return to the generator, and the circuit is completed (Deatrick, 2015). In electrosurgery, tissue impedance converts electric current into thermal energy that causes tissue temperatures to rise. It is these thermal increases that create electrosurgery's tissue effects.

The current from a wall outlet that powers electrosurgical generators has a frequency of 60 Hz (in the United States) or 50 Hz (in other parts of the world). Extreme neuromuscular stimulation can result from this lower frequency, as with electrocution. However, at frequencies above 100 Hz, excitable membranes are not depolarized, and thus nerve and muscle responses are bypassed. For safe use during electrosurgery, modern surgical generators increase frequencies to greater than 200 Hz.

Tissue Effects

With electrosurgery, differing tissue effects are created by varying the manner in which current is produced and delivered. First, altering the current wave pattern can affect tissue temperatures. For example, the high-frequency continuous sinusoidal waveform produced with cutting current creates higher tissue temperatures than that with coagulation current (Fig. 2-21). Second, the extent to which current is spread over an area, also termed

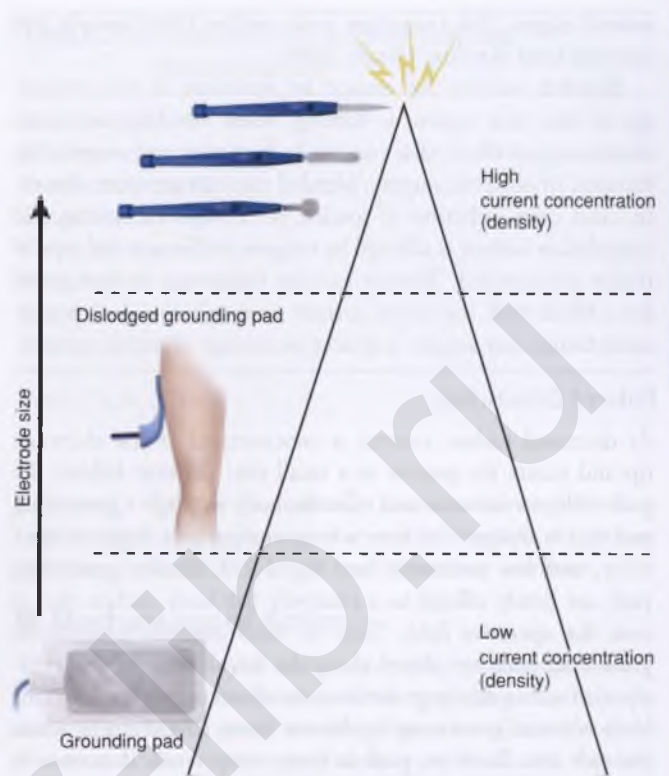


FIGURE 2-22 Current concentration and its effects. Thermal energy and risk for tissue injury diminish as current density decreases and electrode area increases. (Reproduced with permission from Balgobin S, Hamid CA, Hoffman BL: Intraoperative considerations. In Hoffman BL, Schorge JO, Bradshaw KD, et al (eds): Williams Gynecology, 3rd ed. New York, McGraw-Hill Education, 2016.)

current density, alters the rate of heat generation (Fig. 2-22). Thus, if current is concentrated onto a small area, such as a needle-tip electrode, greater tissue temperatures are generated than if delivered over a wider area, such as an electrosurgical blade or ball tip. In addition to current density, voltage can modify tissue effects. As voltage increases, the degree of thermal tissue damage similarly increases. And finally, the qualities and impedance of the tissues themselves affect energy transfer and heat dissipation. For example, water has low electrical impedance and liberates little heat, whereas skin with its greater impedance generates significantly higher tissue temperatures (Amaral, 2005).

Current

With electrosurgical cutting, a continuous sine wave of current is produced. The flow of high-frequency current typically is concentrated through an electrosurgical needle or blade and meets tissue impedance. Sparks are created between the tissue and electrode, intense heat is produced, cellular water vaporizes, and cells in the immediate area burst. Tissues are cut cleanly, and minimal coagulum is produced. As a result, few vessels are sealed, and minimal hemostasis accompanies electrosurgical cutting.

In contrast, coagulation current does not produce a constant waveform. Less heat is produced than with cutting current. However, tissue temperature still rises sufficiently to denature protein and disrupt normal cellular architecture. Cells are not vaporized instantly, and cellular debris remains associated with

wound edges. This coagulum seals smaller blood vessels and controls local bleeding (Singh, 2006).

Blended currents are created by variations in the percentage of time that current is flowing. Thus, blending can create electrosurgical effects that contain both cutting and coagulating features. In obstetric surgery, blended currents are often chosen. In most cases, selection of specific percentages of cutting and coagulation current is affected by surgeon preference and type of tissues encountered. Thinner vascular tissue may be best suited for a blend with less active current time, whereas denser avascular tissues may require a greater percentage of active current.

Patient Grounding

As discussed earlier, current is concentrated at the electrode tip and enters the patient at a small site. Current follows the path of least resistance and exits the body through a grounding pad that is designed to have a large surface area, high conductivity, and low resistance (see Fig. 2-22). Ideally, grounding pads are firmly affixed to a relatively flat body surface that is near the operative field. Thus, in most obstetric procedures, grounding pads are placed along the lateral upper thigh. Dissipation across this large surface area allows current to leave the body without generating significant tissue temperatures across the exit site. Even so, patient burns may result if current is concentrated through a return electrode. Clinically, this may occur if a grounding pad is partially dislodged. In this setting, the surface area is decreased, and exiting current concentration and tissue temperatures rise at the exit site. In addition, patient jewelry, metal candy-cane stirrups, or other surfaces with high conductivity and low resistance may serve as a return electrode. In such cases, patients may be burned by concentrated current exiting through these small contact sites.

■ Bipolar Electrosurgery

Bipolar differs from monopolar electrosurgery in that the tip of a bipolar device contains both an active electrode and a return electrode (see Fig. 2-20B). For this reason, a distant grounding return pad is not required. Coagulation current is concentrated on tissues grasped between the electrodes, and tissue must remain between them. If tissue slips from between the tips, then active and return electrodes contact to create a short circuit, and coagulation will not occur (Michelassi, 1997). Bipolar electrosurgery uses only coagulation current and lacks cutting capability. Thus, it is used infrequently for obstetric surgery.

■ Coexisting Electrical Devices

Patients with pacemakers, implantable cardioverter-defibrillators, or other electrical implants require special precautions. Stray electrosurgical current may be interpreted as an intracardiac signal by an implanted device and lead to pacing changes. In addition, myocardial electrical burns may result from conduction of current through the pacing electrode rather than through the grounding pad (Pinski, 2002). Accordingly, for women with these devices, preventative recommendations include pre- and postoperative cardiology consultation, continuous cardiac monitoring, and contingency plans for arrhythmias. During surgery, use of bipolar electrosurgical instruments or Harmonic scalpel is preferred. If monopolar tools are used,

then minimal settings are selected, and the active and return electrodes are placed in close proximity (Crossley, 2011).

SURGICAL DRAINS

Conceptually, wound drainage can be broadly categorized as therapeutic or prophylactic. Therapeutic drainage following surgical extirpation of an intraabdominal or pelvic abscess is a well-established principle. Such drains function by creating a fistula from the abscess cavity to the outside. Newer methods using percutaneous drainage of loculated fluids under radiographic guidance have decreased tissue damage, blood loss, and open surgical intervention. Another therapeutic method is vacuum-assisted wound closure, which is technically a drainage system and discussed subsequently (Kim, 2014). In contrast, prophylactic drainage remains controversial with little documentation of benefit (Alanis, 2010; Baier, 2010; Dahlke, 2013).

Fluid egress can be promoted either passively or actively. Passive drains establish a path of decreased resistance from the site to be drained to outside the body. The most popular passive devices are the Penrose drain and Malecot catheter (Fig. 2-23). These function as a wick to enable flow of fluid, blood, or pus to the outside. Passive drains function by capillary action and natural pressure differences, that is, posture and gravity. Passive drains such as the Penrose use soft, pliable material and allow drainage of either thin or viscous fluids. However, placement requires an exit large enough to avoid obstruction of the pliable rubber.

Active drains may be open or closed, and closed active drains are described as being low- or high-pressure systems. Active closed drains include Jackson-Pratt and Blake drains (see Fig. 2-23). Most of these direct flow into an attached receptacle, which allows the system to remain sealed. Silastic tubing minimizes damage that might be caused by more rigid evacuation tubes. Active closed drains allow collection of effluent, protect the skin from irritating discharges, and are less vulnerable to retrograde bacterial infection. Low pressure (100 to 150 mm Hg) can be attained with rechargeable canisters or bulbs, although such devices may occasionally allow retrograde passage of fluid

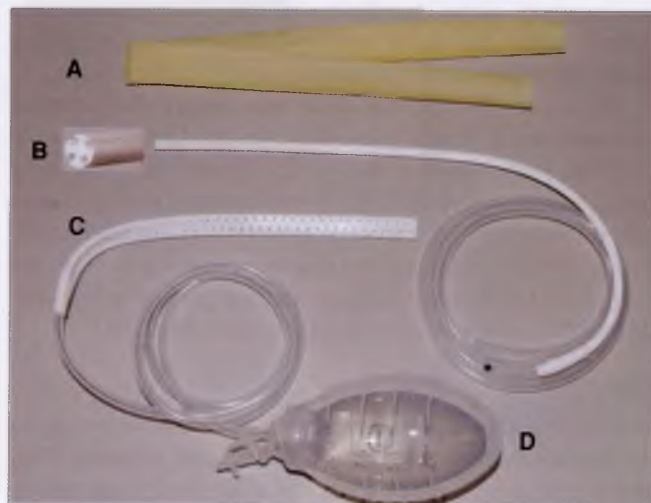


FIGURE 2-23 Surgical drains. **A.** Penrose drain. **B.** Blake drain. The inset shows the channels of this type. **C.** Jackson-Pratt drain. **D.** The latter two drains can be connected to a bulb-shaped suction evacuator. Calibrated volume markings on the bulb canister can aid output measurement. (Used with permission from Dr. Brian Casey.)

TABLE 2-1. Potential Complications of Surgical Drains**Foreign Body Effects**

Chemical and/or mechanical effects
 Erosion: hemorrhage, fistula, perforation
 Torsion: bowel obstruction
 Potentiation of infection
 Tissue irritation
 Bacterial adherence
 Retrograde bacterial migration
 Impaired suture-line healing

Mechanical Problems

Drain entrapment: sutures, kinking, tissue ingrowth
 Herniation of viscera through drain tracts
 Drain loss: migration, fragmentation
 Leakage due to incomplete drain tract formation

Physiologic Derangements

Pain
 Fluid and electrolyte loss
 Pneumoperitoneum, pneumothorax

Inadequate Drainage

Faulty positioning, kinking, or obstruction
 Poor drain or drainage method selection

with bacterial contamination at the time of recharging. A one-way valve may prevent this complication.

In contrast, active open drains—also called sump drains—are useful when large amounts of fluid must be removed from a relatively spacious body cavity. These are seldom indicated in obstetrics.

Mechanical drainage is not without the risks outlined in **Table 2-1** (Dougherty, 1992). Drains left in place more than 5 to 6 days ideally have surveillance cultures of the drain site obtained to check for superinfection. Prophylactic antibiotics may prevent infectious morbidity during short-term drain placement. Longer use of drains and antibiotics may lead to the development of bacterial infections. Drains with perforations also risk tissue ingrowth if left in place too long.

VACUUM-ASSISTED WOUND CLOSURE

Vacuum-assisted closure systems are designed to apply negative pressure to a foam-wound interface to promote wound healing. The technique is variably referred to as vacuum-assisted closure—VAC; topical negative pressure—TNP; and negative-pressure wound therapy—NPWT. Several systems are sold and are widely accepted despite meager evidence-based clinical efficacy (Hunter, 2007; Mouës, 2011; Schintler, 2012). One of the more popular is the V.A.C. Therapy system.

Although originally developed for chronic ulcer therapy, these methods can be placed in other open surgical wounds (**Table 2-2**). In obstetrics, disrupted and infected abdominal wounds are the major indication for vacuum-assisted closure. Another indication is to aid closure of perineal wounds resulting from paravaginal and perirectal hematomas and abscesses. These devices can also be selected for the “open surgical

TABLE 2-2. Indications for Vacuum-Assisted Wound Closure

Acute wounds
 Chronic wounds
 Traumatic wounds
 Subacute wounds
 Dehisced wounds
 Partial-thickness burns
 Ulcers—diabetic, venous
 Flaps and grafts

From Orgill, 2013.

abdomen,” which is occasionally encountered in obstetrics. Last, some use negative-pressure wound therapy to *prevent* infections in wounds closed to heal by primary intention.

■ Mechanisms of Action

The closed-system device uses an open-pore polyurethane foam that carries an antibacterial ionic-silver coating. Cutting the foam tailors it to a given wound’s dimension. Once placed in the wound, the foam is covered by a semioclusive dressing that incorporates the suction tubing (**Fig. 2-24**). Tubing is connected to a vacuum source that produces a negative pressure of 50 to 150 mm Hg. The tube is also connected to a reservoir and serves as a sump drain to remove edema fluid and exudates.

According to Orgill and Bayer (2013), there are likely four primary mechanisms of action for vacuum-assisted closure (**Fig. 2-25**). First, *macrodeformation* is achieved by the open-pore foam and suction, which draws wound edges together. Second, negative pressure at the foam-wound interface promotes cellular *microdeformation* and, in turn, cellular division. Removal of excess tissue edema is another mechanism. And last, the dressing provides an insulated, warm, and moist milieu. These mechanisms ostensibly result in robust granulation tissue

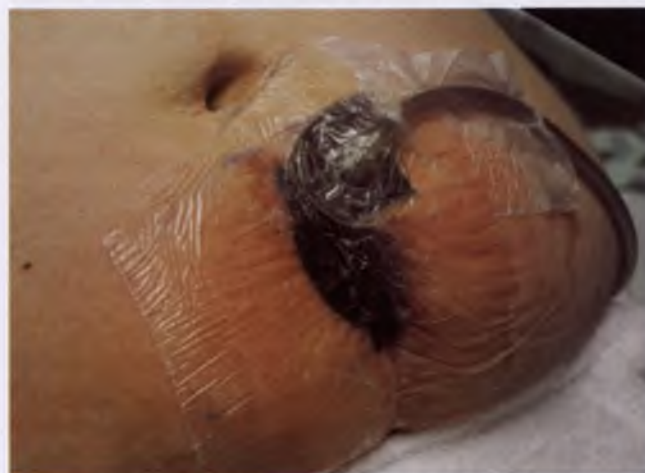

FIGURE 2-24 Vacuum-assisted wound closure applied to an abdominal wound. Black porous sponge can be cut and customized to fill wound dimensions. The suction tubing and disc lie over this sponge to draw out tissue fluid. A layer of plastic adhesive over this construction prevents loss of suction force. (Used with permission from Dr. Benjamin Kogutt.)

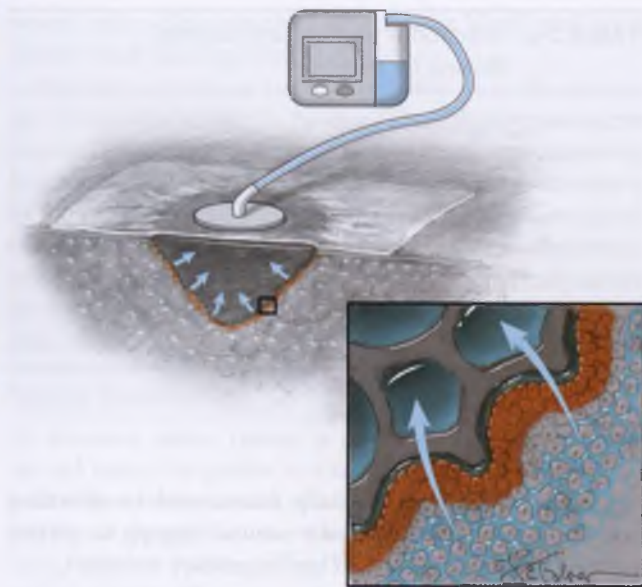


FIGURE 2-25 Theoretical effects of negative-pressure wound therapy include macro- and microdeformation, removal of tissue fluid, and creation of a warm, moist environment. As shown in the inset, tissue fluid is drawn from the healing wound. It filters through the porous sponge that fills the wound and is drawn out by suction tubing to an adjacent collection canister. As healing progresses, a layer of granulation tissue, shown in red, forms at the wound-sponge interface.

formation because of vascular endothelial growth factor (VEGF) upregulation. There is also cellular proliferation and modulation of inflammation.

■ Efficacy

Few randomized trials have compared vacuum-assisted wound closure with conventional wound care. Likewise, its cost effectiveness has not been thoroughly studied, although provider time is decreased substantially. That said, several systematic reviews have assessed evidence-based recommendations for these techniques. Mouës and colleagues (2011) concluded that the evidence supports this technology for chronic ulcer therapy of the lower extremities and for infected median sternotomy wounds. However, they were more circumspect regarding its use in disrupted abdominal wounds because of scant data. Hunter and associates (2007) cited studies showing that vacuum-assisted therapy stimulated increased microvessel density, improved blood flow, and decreased levels of matrix metalloproteinases and tumor necrosis factor- α . Other reviewers concluded that vacuum therapy was the most efficient method of temporary abdominal closure for patients with open abdomens (Bruhin, 2014; Quyn, 2012; Roberts, 2012).

■ Prophylactic Use

More recently, negative-pressure wound therapy has been modified for use in noninfected surgical wounds with surgically approximated skin edges. One such product is the Prevena Incision Management System. These various systems have been chosen for patients with high-risk abdominal wounds and in obese patients with otherwise clean incisions (Vargo, 2012; Webster, 2012). Lewis and coworkers (2014) performed a decision

analysis for use of prophylactic vacuum systems for closed abdominal wounds in women with gynecologic malignancies. They concluded that if such therapy decreased wound infections by a third, then the practice would likely be cost effective. The issue is currently unsettled, and in a Cochrane database review, Webster and associates (2012) urged performance of suitable high-quality trials because of the costs and current widespread use of prophylactic vacuum-assisted wound treatment.

REFERENCES

- Alanis MC, Villers MS, Law TL, et al: Complications of cesarean delivery in the massively obese parturient. *Am J Obstet Gynecol* 203(3):271.e1, 2010
- Amaral J: Electrosurgery and ultrasound for cutting and coagulating tissue in minimally invasive surgery. Soper N, Swanstrom L, Eubanks W (eds): *Mastery of Endoscopic and Laparoscopic Surgery*. Philadelphia, Lippincott Williams & Wilkins, 2005, p 67
- Baier PK, Glück NC, Baumgartner U, et al: Subcutaneous Redon drains do not reduce the incidence of surgical site infections after laparotomy. A randomized controlled trial on 200 patients. *Int J Colorectal Dis* 25(5):639, 2010
- Balgobin S, Hamid CA, Hoffman BL: Intraoperative considerations. In Hoffman BL, Schorge JO, Bradshaw KD, et al (eds): *Williams Gynecology*, 3rd ed. New York, McGraw-Hill Education, 2016
- Bruhin A, Ferreira F, Chariker M, et al: Systematic review and evidence based recommendations for the use of negative pressure wound therapy in the open abdomen. *Int J Surg* 12(10):1105, 2014
- Chen SS, Lin AT, Chen KK, et al: Femoral neuropathy after pelvic surgery. *Urology* 46(4):575, 1995
- Crossley GH, Poole JE, Rozner MA, et al: The Heart Rhythm Society (HRS)/American Society of Anesthesiologists (ASA) Expert Consensus Statement on the perioperative management of patients with implantable defibrillators, pacemakers and arrhythmia monitors: facilities and patient management. *Heart Rhythm* 8(7):1114, 2011
- Dahlke JD, Mendez-Figueroa H, Rouse DJ, et al: Evidence-based surgery for cesarean delivery: an updated systematic review. *Am J Obstet Gynecol* 209(4):294, 2013
- Deatrick KB, Doherty GM: Power sources in surgery. In Doherty GM (ed): *Current Surgical Diagnosis and Treatment*, 14th ed. New York, McGraw-Hill Education, 2015
- Dougherty SH, Simmons RL: The biology and practice of surgical drains. Parts 1 and 2. *Curr Probl Surg* 29(8):559, 1992
- Hunter JE, Teot L, Horch R, et al: Evidence-based medicine: vacuum-assisted closure in wound care management. *Int Wound J* 4(3):256, 2007
- Kim SI, Lim MC, Song YJ, et al: Application of a subcutaneous negative pressure drain without subcutaneous suture: impact on wound healing in gynecologic surgery. *Eur J Obstet Gynecol Reprod Biol* 173:94, 2014
- Lewis LS, Convery PA, Bolac CS, et al: Cost of care using prophylactic negative pressure wound vacuum on closed laparotomy incisions. *Gynecol Oncol* 132(3):684, 2014
- Michelassi F, Hurst R: Electrocautery, argon beam coagulation, cryotherapy, and other hemostatic and tissue ablative instruments. In Nyhus L, Baker R, Fischer J (eds): *Mastery of Surgery*. Boston, Little, Brown, and Company, 1997, p 234
- Mouës CM, Heule F, Hovius SE: A review of topical negative pressure therapy in wound healing: sufficient evidence? *Am J Surg* 201(4):544, 2011
- Orgill DP, Bayer LR: Negative pressure wound therapy: past, present and future. *Int Wound J* 10(Suppl 1):15, 2013
- Pinski SL, Trohman RG: Interference in implanted cardiac devices, part II. *Pacing Clin Electrophysiol* 25(10):1496, 2002
- Quyn AJ, Johnston C, Hall D, et al: The open abdomen and temporary abdominal closure systems—historical evolution and systematic review. *Colorectal Dis* 14(8):e429, 2012
- Roberts DJ, Zygun DA, Grendar J, et al: Negative-pressure wound therapy for critically ill adults with open abdominal wounds: a systematic review. *J Trauma Acute Care Surg* 73(3):629, 2012
- Schintler MV: Negative pressure therapy: theory and practice. *Diabetes Metab Res Rev* 28(Suppl 1):72, 2012
- Singh S, Maxwell D: Tools of the trade. *Best Pract Res Clin Obstet Gynaecol* 20(1):41, 2006
- Vargo D: Negative pressure wound therapy in the prevention of wound infection in high risk abdominal wound closures. *Am J Surg* 204(6):1021, 2012
- Webster J, Scuffham P, Stankiewicz M, et al: Negative pressure wound therapy for skin grafts and surgical wounds healing by primary intention. *Cochrane Database Syst Rev* 10:CD009261, 2014

CHAPTER 3

Anatomy

ANTERIOR ABDOMINAL WALL	27
VULVA	30
VAGINA AND HYMEN	33
PERINEUM	34
UTERUS	38
PELVIC LIGAMENTS	40
PELVIC VASCULATURE	40
PELVIC INNERVATION	42
ADNEXA	43
PELVIC URETER	44
THE BONY PELVIS	45

A thorough understanding of pelvic, perineal, and anterior abdominal wall anatomy is essential for obstetric practice and surgery. Although anatomic consistencies can be expected, marked variation may be encountered among women and in individual women as pregnancy advances. This is especially true for major blood vessels and genitourinary structures.

ANTERIOR ABDOMINAL WALL

The anterior abdominal wall plays several roles during pregnancy. It confines the abdominopelvic viscera; contributes

muscular action for respiration, elimination, and parturition; and stretches to accommodate the expanding uterus. For cesarean delivery, the anterior abdominal wall must be divided to gain surgical access to the internal reproductive organs. Thus, a comprehensive knowledge of its layered structure is required for safe and effective entry into the peritoneal cavity. The layers of the anterior abdominal wall include the skin and subcutaneous layer, which receive blood supply from the femoral artery, and the muscles and fascia, which are supplied by branches of the external iliac artery (Fig. 3-1).

■ Skin and Subcutaneous Layer

Langer lines correspond to the natural orientation of collagen fibers within the skin and are generally parallel to the orientation of the underlying muscle fibers. In the anterior abdominal wall, they are mostly arranged transversely. As a result, vertical skin incisions sustain greater lateral tension compared with low transverse incisions such as the Pfannenstiel, and thus generally develop wider scars.

The subcutaneous layer can be separated into a superficial, predominantly fatty layer known as Camper fascia, and a deeper, more fibrofatty layer known as Scarpa fascia. Camper fascia continues onto the perineum to provide fatty substance to the mons pubis and labia majora. Scarpa fascia continues inferiorly onto the perineum as Colles fascia, which is also known as the superficial perineal fascia (p. 31). Thus, blood or infection within the subcutaneous layer of the anterior abdominal wall can extend to the perineum, and vice versa.

Clinically, Scarpa fascia is better developed in the lower abdomen, and during surgery it can be best identified in the lateral portions of a low transverse incision. In contrast, this fascia is rarely recognized during midline vertical incisions and may be absent at the umbilicus (Martin, 1984).

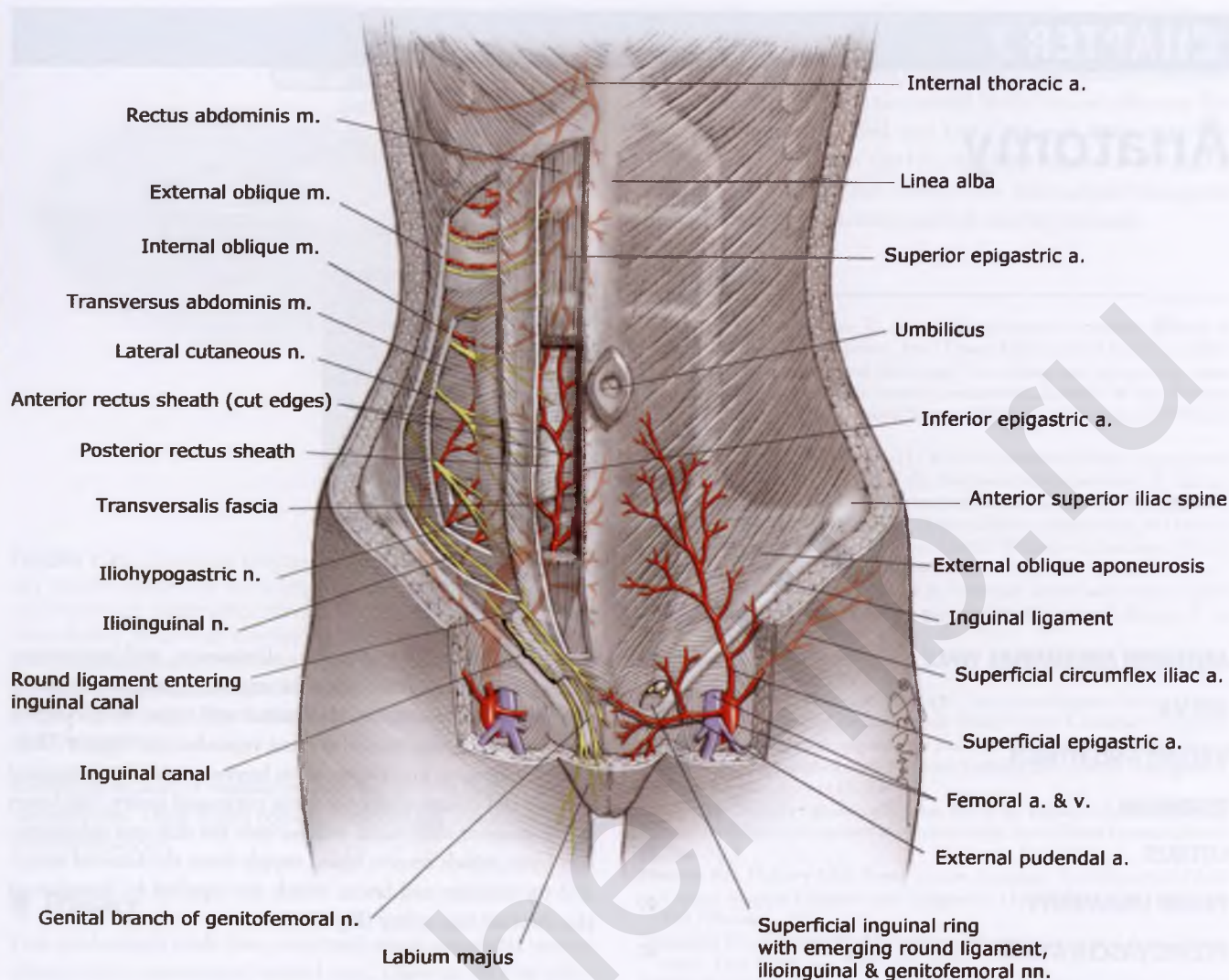


FIGURE 3-1 Anterior abdominal wall anatomy. (Reproduced with permission from Corton MM: *Anatomy*. In Hoffman BL, Schorge JO, Bradshaw KD, et al (eds): *Williams Gynecology*, 3rd ed. New York, McGraw-Hill Education, 2016.)

■ Muscles and Fascia

The anterior abdominal wall muscles consist of the midline rectus abdominis and pyramidalis muscles as well as the more lateral external and internal oblique and transversus abdominis muscles. These last three muscles, often called the flank muscles, contain a lateral muscular portion and a medial fibrous aponeurotic portion. The aponeuroses of these muscles contribute to the primary fascia of the anterior abdominal wall and form the important rectus sheath. In the midline, these aponeurotic layers fuse to create the linea alba, which extends from the xiphoid process to the symphysis pubis.

This anatomy is clinically relevant. First, surgically, because the aponeuroses of the internal oblique and transversus abdominis fuse in the lower abdomen, only two layers are identified laterally during low transverse incision creation. Also, in the lower abdomen, transition from muscle to aponeurosis for the internal oblique and transversus abdominis muscles takes place at a more medial site than that for the external oblique muscles. Accordingly, during low transverse incisions, muscle fibers of

the internal oblique muscle are often noted below the aponeurotic layer of the external oblique muscle.

The lowermost portion of the aponeurosis of the external oblique ends in a tendinous border known as the inguinal ligament. This ligament extends from the anterior superior iliac spine to the pubic tubercle. The superficial inguinal ring represents a narrow opening of the inguinal ligament near the pubic tubercle and serves as the exit site for the round ligament and one or two nerve branches. These are the inguinal branch of the ilioinguinal nerve and genital branch of the genitofemoral nerve (see Fig. 3-1).

Rectus Sheath

This is formed by the aponeuroses of the external and internal oblique and transversus abdominis muscles (Fig. 3-2). This sheath surrounds and holds the position of the rectus muscles. The composition of this sheath varies above and below the arcuate line, also known as the semicircular line of Douglas. This transverse line is a curved, tendinous boundary in the posterior

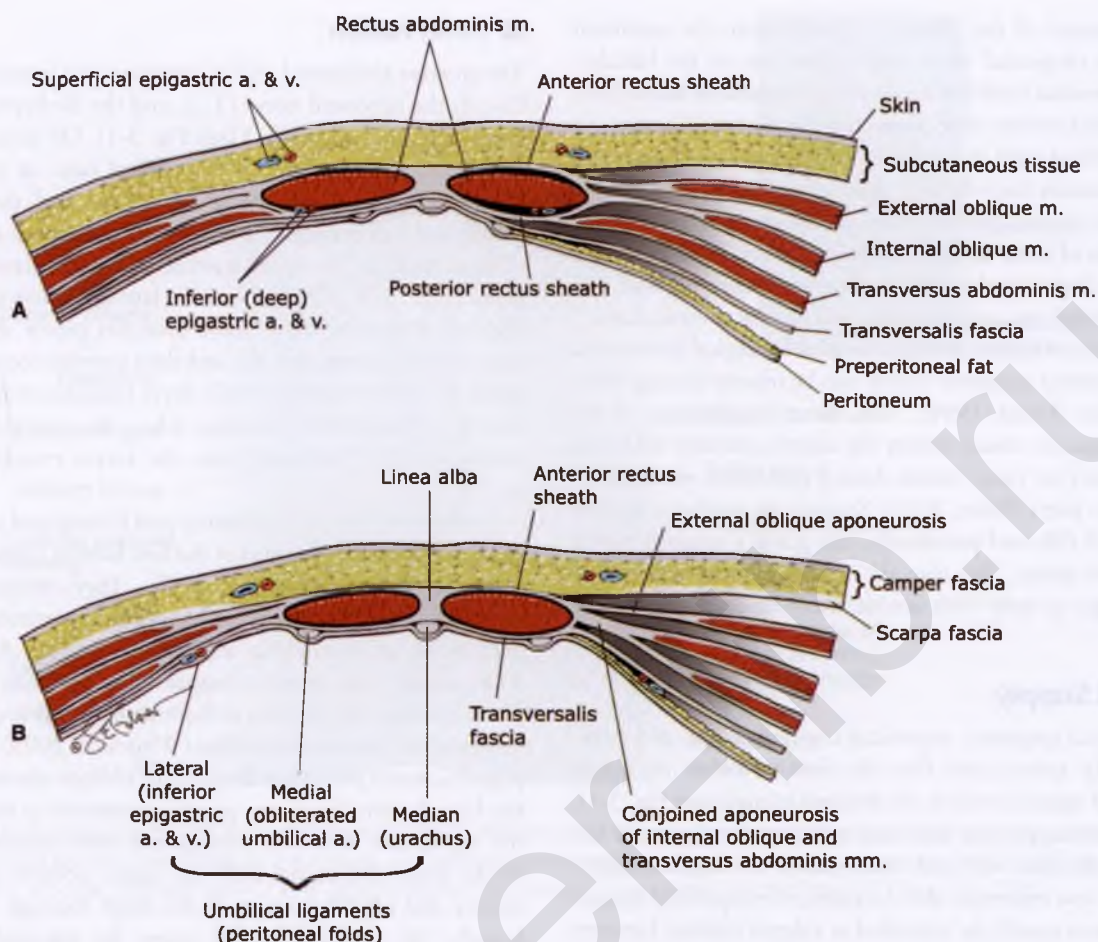


FIGURE 3-2 Transverse sections of the anterior abdominal wall above (A) and below (B) the arcuate line. (Reproduced with permission from Corton MM: Anatomy. In Hoffman BL, Schorge JO, Bradshaw KD, et al (eds): Williams Gynecology, 3rd ed. New York, McGraw-Hill Education, 2016.)

layer of the rectus sheath. It typically lies midway between the umbilicus and symphysis pubis. Cephalad to the arcuate line, the rectus sheath wraps both anterior and posterior to the rectus abdominis muscles. At this level, the anterior rectus sheath is formed by the aponeurosis of the external oblique and the split aponeurosis of the internal oblique muscle. The posterior rectus sheath is formed by the split aponeurosis of the internal oblique and aponeurosis of the transversus abdominis muscle. Caudad to the arcuate line, all aponeurotic layers pass anterior to the rectus abdominis muscles. Thus, in the lower abdomen, the posterior surfaces of the rectus muscles are in direct contact with the transversalis fascia. This transition of rectus sheath composition can be best appreciated during midline vertical abdominal incisions.

The paired small triangular pyramidalis muscles originate from the pubic bones, insert into the linea alba, and then lie ventral to the rectus abdominis muscles but beneath the anterior rectus sheath. This muscle may be absent in approximately 10 percent of women.

Similar to skin fibers, the flank muscles and rectus sheath fibers are oriented primarily transversely. Thus, suture lines placed in a vertical fascial incision must withstand more tension than those in a transverse incision. As a result, vertical fascial incisions are more prone to dehiscence and hernia formation.

Thus, during physical examination, an abnormally wide separation of the rectus muscles may suggest diastasis recti or hernia.

The transversalis fascia is the thin fibrous tissue layer that lies between the inner surface of the transversus abdominis muscle and the peritoneum. It serves as part of the general fascial layer that lines the entire abdominal cavity (Memon, 1999). Surgically, this layer is best recognized as the tissue that is bluntly or sharply dissected off the anterior surface of the bladder during entry into the abdominal cavity. Between the transversalis fascia and the peritoneum in the anterior abdominal wall lies a layer of extraperitoneal loose connective tissue often called preperitoneal fat.

■ Peritoneum

That portion of the peritoneum that lines the inner surface of the abdominal wall is termed *parietal peritoneum*. In the anterior abdominal wall, there are five elevations of parietal peritoneum that are raised by different structures (see Fig. 3-2). All five converge toward the umbilicus and are known as *umbilical ligaments*.

The single *median umbilical ligament* is formed by the urachus, an obliterated tube that extends from the apex of the bladder to the umbilicus. In fetal life, the urachus, which is a

fibrous remnant of the allantois, extends from the umbilical cord to the urogenital sinus, which gives rise to the bladder. The paired *medial umbilical ligaments* are formed by the obliterated umbilical arteries that connected the internal iliac arteries to the umbilical cord in fetal life. The paired *lateral umbilical ligaments* contain the inferior epigastric vessels.

Surgically, transection of a rare, patent urachus can result in extravasation of urine into the abdominal cavity. In addition, the differential diagnosis of a midline anterior abdominal wall cyst includes urachal cyst, urachal sinus, and urachal diverticulum.

The umbilical ligaments serve as valuable surgical landmarks. First, the inferior epigastric vessels can be injured during Maylard incisions (Hurd, 1994). Also, direct visualization of the inferior epigastric vessels within the lateral umbilical folds can prevent injury to these vessels during placement of accessory laparoscopic ports (Rahn, 2010). Second, the medial umbilical ligaments, if followed proximally, can guide a surgeon to the internal iliac artery. This may aid identification of the uterine artery's origin to assist with uterine artery ligation.

■ Blood Supply

The superficial epigastric, superficial circumflex iliac, and external pudendal arteries arise from the femoral artery just below the inguinal ligament within the femoral triangle (see Fig. 3-1). These vessels supply the skin and subcutaneous layers of the anterior abdominal wall and mons pubis. Of surgical importance, with low transverse skin incisions, the superficial epigastric vessels can usually be identified at a depth halfway between the skin and the anterior rectus sheath, just above Scarpa fascia, and several centimeters from the midline. During laparoscopic procedures, these vessels may be identified by transillumination in thin patients (Chap. 15, p. 254).

The inferior “deep” epigastric vessels and deep circumflex iliac vessels are branches of the external iliac vessels. They supply the muscles and fascia of the anterior abdominal wall. Of surgical relevance, the inferior epigastric vessels initially course lateral to, then posterior to the rectus abdominis muscles, which they supply. These vessels then pass ventral to the posterior rectus sheath, course between the sheath and the rectus muscles, and provide muscular branches. Near the umbilicus, these vessels anastomose with the superior epigastric artery and veins. The surgical importance of the inferior epigastric vessels is noted in the preceding section and in Chapter 4 (p. 53). Also, these vessels rarely may rupture following abdominal trauma leading to a rectus sheath hematoma (Tolcher, 2010).

On each side of the lower anterior abdominal wall, Hesselbach triangle is the region bounded laterally by the inferior epigastric vessels, inferiorly by the inguinal ligament, and medially by the lateral border of the rectus abdominis muscle. Hernias that protrude into the abdominal wall through Hesselbach triangle, and thus medial to the inferior epigastric vessels, are termed *direct inguinal hernias*. These are generally acquired. In contrast, *indirect inguinal hernias* enter the deep inguinal ring, which lies lateral to this triangle and thus lateral to the inferior epigastric vessels. Although infrequent, an indirect hernia may extend medially within the inguinal canal, exit through the superficial inguinal ring, and reach the ipsilateral labium majus.

■ Innervation

The anterior abdominal wall is innervated by intercostal nerves (T₇₋₁₁), the subcostal nerve (T₁₂), and the iliohypogastric and the ilioinguinal nerves (L₁) (see Fig. 3-1). Of these, the intercostal and subcostal nerves are ventral rami of the thoracic spinal nerves and run along the lateral and then anterior abdominal wall between the transversus abdominis and internal oblique muscles. This space is termed the transversus abdominis plane (Fig. 19-3, p. 314). Near the lateral borders of the rectus abdominis muscle, these nerve branches pierce the posterior rectus sheath, rectus muscle, and then anterior rectus sheath to reach the skin. Therefore, these nerve branches may be severed during a Pfannenstiel incision when the overlying anterior rectus sheath is separated from the rectus muscle (Fig. 4-5, p. 51).

In contrast, the iliohypogastric and ilioinguinal nerves originate from the ventral ramus of the first lumbar spinal nerve and often receive contributions from T₁₂. They emerge at a point lateral to the psoas muscle and course retroperitoneally. Their path continues ventrally in an inferomedial line. At a site 2 to 3 cm medial to the anterior superior iliac spine, the nerves then pierce through the internal oblique muscle and course superficial to it and toward the midline (Whiteside, 2003). The iliohypogastric nerve perforates the external oblique aponeurosis near the lateral rectus border to provide sensation to the skin over the suprapubic area. The ilioinguinal nerve supplies the skin of the lower abdominal wall and upper portion of the labia majora and medial portion of the thigh through its inguinal branch. The inguinal branch enters the inguinal canal and courses along the round ligament.

The ilioinguinal and iliohypogastric nerves can be severed during a low transverse incision or entrapped during closure. This is especially true if incisions extend beyond the lateral borders of the rectus muscle (Rahn, 2010). During laparoscopy, these nerves can also be injured by accessory trocar insertion through the lower abdominal wall. Preventively, these risks can be minimized if lateral trocars are placed superior to the anterior superior iliac spines and low transverse fascial incisions are not extended beyond the lateral borders of the rectus muscle. These nerves carry sensory information only, and injury leads to loss of sensation within the areas supplied. Rarely, chronic pain may develop.

The T₁₀ dermatome approximates the level of the umbilicus. Regional anesthesia for cesarean delivery or for puerperal sterilization ideally blocks T₁₀ through L₁ levels. In addition, a transversus abdominis plane (TAP) block can provide broad blockade to the nerves that traverse this plane (Chap. 19, p. 314). It may be placed following cesarean delivery to lessen analgesia requirements (Mishriky, 2012). There are also reports of rectus sheath block or ilioinguinal-iliohypogastric nerve block to decrease postoperative pain (Mei, 2011; Sviggum, 2012; Wolfson, 2012).

VULVA

The external female genitalia, collectively known as the *vulva* or *pudendum*, lie over the pubic bones and extend posteriorly

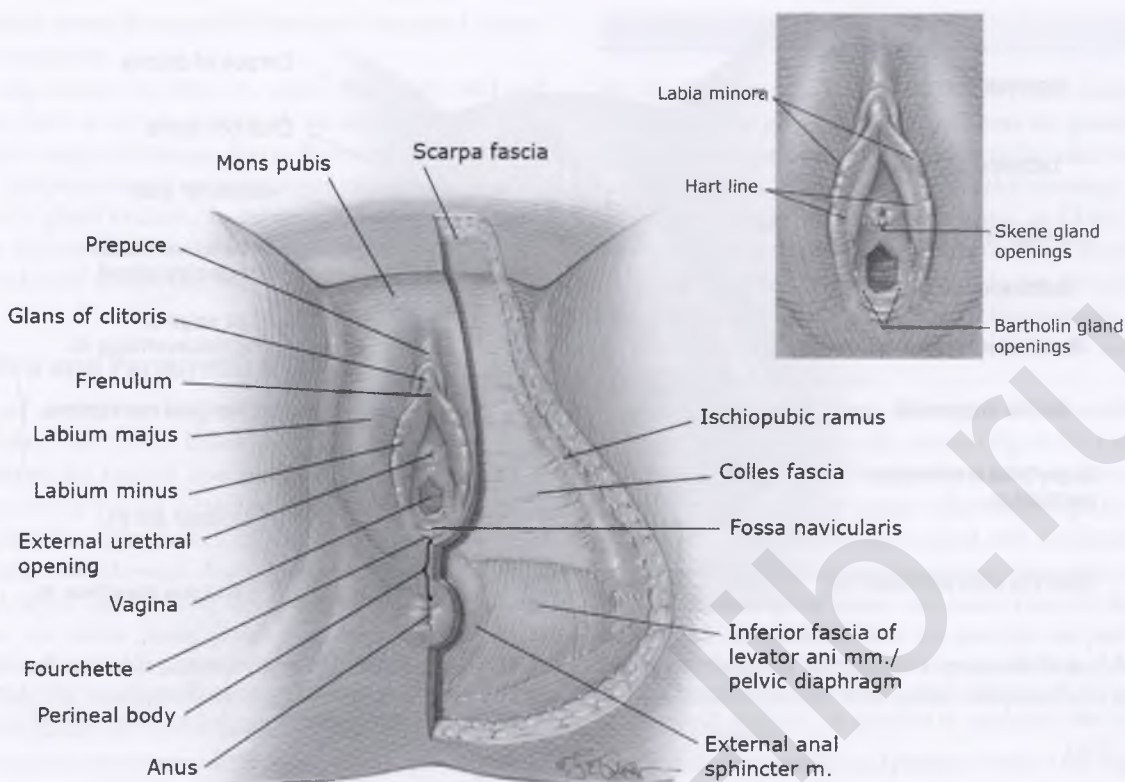


FIGURE 3-3 Vulvar structures (*left*) and subcutaneous layer of the anterior and posterior perineal triangles (*right*). Note the continuity of Colles and Scarpa fasciae. Inset: Vestibule boundaries and openings onto vestibule. (Reproduced with permission from Corton MM: Anatomy. In Hoffman BL, Schorge JO, Bradshaw KD, et al (eds): Williams Gynecology, 3rd ed. New York, McGraw-Hill Education, 2016.)

toward the perineal body. They include the mons pubis, labia majora and minora, clitoris, vestibule, vestibular bulbs, greater vestibular (Bartholin) glands, lesser vestibular glands, Skene and paraurethral glands, and the urethral and vaginal orifices (Fig. 3-3).

■ Mons Pubis and Labia

The mons pubis is the rounded fat pad that lies ventral to the pubic symphysis. The labia majora are two prominent folds that extend inferiorly from the mons pubis toward the perineal body. Embryologic homologues of the male scrotum, the labia majora are generally 7 to 8 cm in length, 2 to 3 cm in width, and 1 to 1.5 cm in thickness. The round ligaments and obliterated *processus vaginalis*, which is also termed the *canal of Nuck*, exit the inguinal canal and attach to the adipose tissue or skin of the labia majora. Posteriorly, the labia majora taper and merge into the area overlying the perineal body to form the posterior commissure.

Hair generally covers the skin of the mons pubis and labia majora. In addition, apocrine, eccrine, and sebaceous glands are abundant. The inner surface of the labia majora, however, lacks hair. Beneath the skin, the labia majora contain a dense connective-tissue layer, which is nearly void of muscular elements but is rich in elastic fibers and adipose tissue. This mass of fat provides bulk to the labia majora and is supplied with a rich venous plexus. During pregnancy, these veins commonly develop varicosities, especially in parous women, from the

increased venous pressure generated by the enlarging uterus. These varicosities appear as engorged tortuous veins or as small grapelike clusters, but are typically asymptomatic.

The subcutaneous layer of the mons and labia majora consists of a superficial fatty layer that is similar to and continuous with Camper fascia and a deeper membranous layer, which is Colles fascia.

The labia minora are two cutaneous folds that lie between the labia majora. In males, its homologue forms the ventral shaft of the penis. Anteriorly, each labium minus separates to form two folds that surround the glans of the clitoris. The prepuce or hood is the anterior fold that overlies the glans, and the frenulum is the fold that passes below the clitoris. Posteriorly, the labia minora end at the fourchette. The size of the labia minora varies greatly among individuals, with lengths from 2 to 10 cm and widths from 1 to 5 cm (Lloyd, 2005).

Structurally, the labia minora contain connective tissue with numerous vessels, elastin fibers, and scarce smooth muscle fibers. They are supplied with many nerve endings and are extremely sensitive (Ginger, 2011a). The epithelium of the labia minora varies with location. Thinly keratinized stratified squamous epithelium covers the outer surface of each labium. On the inner surface, the lateral portion is covered by this same epithelium up to a demarcating line—Hart line. Medial to Hart line, each labium is covered by squamous epithelium that is nonkeratinized. The labia minora lack hair follicles, eccrine glands, and apocrine glands. However, they contain many sebaceous glands (Wilkinson, 2011).

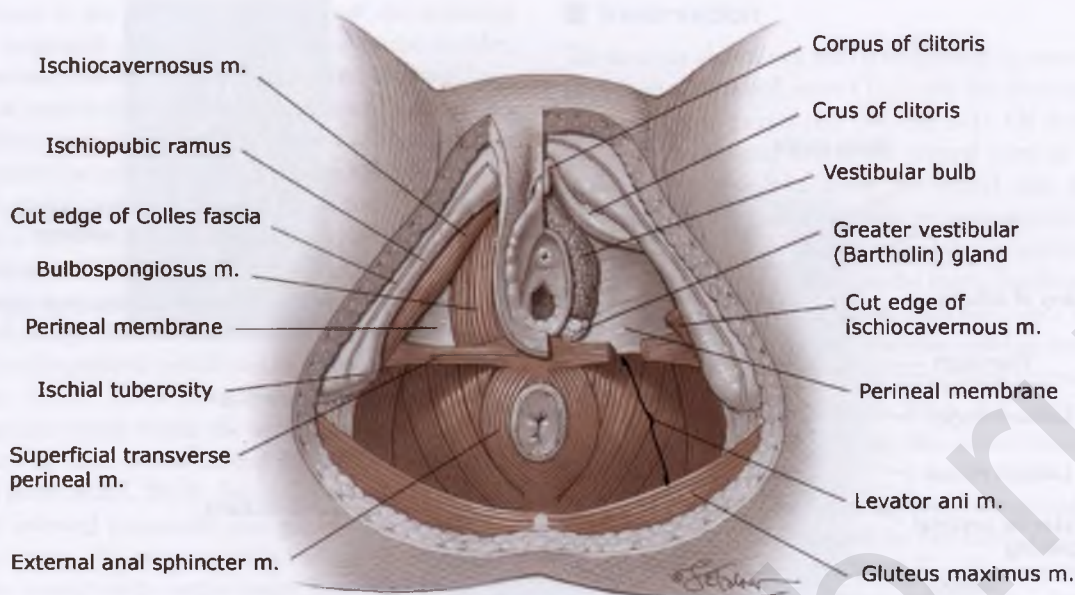


FIGURE 3-4 Superficial space of the anterior and posterior perineal triangles. On the image's left are the structures noted after removal of Colles fascia. On the image's right are the structures noted after removal of the superficial perineal muscles. (Reproduced with permission from Corton MM: *Anatomy*. In Hoffman BL, Schorge JO, Bradshaw KD, et al (eds): *Williams Gynecology*, 3rd ed. New York, McGraw-Hill Education, 2016.)

■ Clitoris

This is the principal female erogenous organ and is the erectile homologue of the penis. It is located beneath the prepuce, above the frenulum and urethra, and projects downward and inward toward the vaginal opening. The clitoris rarely exceeds 2 cm in length and is composed of a glans, a corpus or body, and two crura (Verkauf, 1992). The glans is usually less than 0.5 cm in diameter, is covered by stratified squamous epithelium, and is richly innervated. The clitoral body contains two corpora cavernosa. Extending from the clitoral body, each corpus cavernosum diverges laterally to form a long, narrow crus (Fig. 3-4). Each crus lies along the inferior surface of its respective ischiopubic ramus and deep to the ischiocavernosus muscle. The clitoral blood supply stems from branches of the internal pudendal artery. Specifically, the deep artery of the clitoris supplies the clitoral body, whereas the dorsal artery of the clitoris supplies the glans and prepuce (p. 36).

■ Vestibule

This is the functionally mature female structure derived from the embryonic urogenital sinus. In adult women, it is an almond-shaped area that is enclosed by Hart line laterally, the hymen medially, the clitoral frenulum anteriorly, and the fourchette posteriorly (see Fig. 3-3 inset). The vestibule is usually perforated by six openings: the urethra, the vagina, two Bartholin gland ducts, and the two ducts of the largest paraurethral glands—the Skene glands. It also contains the numerous openings of the lesser vestibular glands. The posterior portion of the vestibule between the fourchette and the vaginal opening is called the fossa navicularis. It is best observed in nulliparas.

The Hart line is clinically relevant when choosing incision sites for Bartholin gland drainage or marsupialization. That is,

in attempts to recreate near-normal gland duct anatomy following these procedures, incisions are ideally placed between the hymen and Hart line (Kaufman, 1994).

■ Vestibular Bulbs

These are homologues to the male penile bulb and corpus spongiosum. They are two elongated, approximately 3-cm long, richly vascular erectile masses that surround the vaginal orifice (see Fig. 3-4). Their posterior ends are in contact with the Bartholin glands. Their anterior ends are joined to one another and to the clitoris. Their deep surfaces are in direct contact with the perineal membrane. Their superficial surfaces are partially covered by the bulbospongiosus muscles, previously known as the bulbocavernosus muscles.

Clinically, the proximity of the Bartholin glands to the vestibular bulbs accounts for the significant bleeding often encountered with Bartholin gland excision. Following vulvar trauma, laceration of these bulbs or the clitoral crus may lead to sizable hematomas as discussed in Chapter 30 (p. 484).

■ Greater Vestibular (Bartholin) Glands

These major glands measure 0.5 to 1 cm in diameter. They are the homologues of the male bulbourethral or Cowper glands. On their respective side, each lies dorsal to the vascular vestibular bulb and deep to the inferior end of the bulbospongiosus muscle. The duct from each gland measures 1.5 to 2 cm long and opens distal to the hymeneal ring—one at 5 and the other at 7 o'clock on the vestibule.

The glands contain columnar cells that secrete clear or whitish mucus with lubricating properties. These glands are stimulated by sexual arousal. Contraction of the bulbospongiosus

VAGINA AND HYMEN

muscle, which covers the superficial surface of the gland, stimulates gland secretion.

Following trauma or infection, either duct may swell and obstruct to form a cyst or if infected, an abscess, which typically requires surgical drainage. This is illustrated in Chapter 12 (p. 193). Symptomatic or recurrent cysts may require marsupialization or gland excision. In contrast, the minor vestibular glands are shallow glands lined by simple mucin-secreting epithelium and open along Hart line.

■ Urethra and Paraurethral Glands

The external urethral opening or meatus lies in the midline of the vestibule, 1 to 1.5 cm below the pubic arch, and a short distance above the vaginal opening. The dorsal surface of the urethra lies on the ventral surface of the anterior vaginal wall.

The paraurethral glands are a collective arborization of small glands whose multiple small ducts open predominantly on the dorsal and lateral aspect along the entire urethral length. The two largest are called *Skene glands*, and their ducts typically lie distally and near the urethral meatus and open at the vestibule. Clinically, inflammation and duct obstruction of the paraurethral glands can lead to urethral diverticulum formation or a Skene gland cyst or abscess. A Skene gland cyst or abscess can generally be differentiated from a urethral diverticulum in that it deviates the external urethral opening to the contralateral side.

The distal portion of the vagina and hymen embryologically derive from the urogenital sinus, whereas the proximal vagina derives from the paramesonephric ducts. In adult women, the hymen is a thin border around the vaginal opening. It contains elastic and collagenous connective tissue, and both outer and inner surfaces are covered by nonkeratinized stratified squamous epithelium. Changes produced in the hymen by childbirth are usually readily recognizable. For example, over time, the hymen transforms into several nodules of various sizes, termed hymeneal caruncles.

Proximal to the hymen, the vagina is a musculomembranous tube that extends to the uterus (Fig. 3-5). Ventrally, the vagina is separated from the bladder and upper part of the urethra by loose connective tissue—the vesicovaginal space. The distal third of the urethra and vaginal wall are fused. Dorsally, between the mid vagina and the rectum, loose connective tissue forms the rectovaginal space. The lower third of the posterior vaginal wall is separated from the anus by the perineal body. The upper fourth of the vagina is separated from the rectum by the rectouterine pouch, also called the posterior cul-de-sac or pouch of Douglas.

Normally, the anterior and posterior walls of the vaginal lumen lie in contact, with only a slight space intervening at the lateral margins. Vaginal length varies considerably, but commonly, the anterior wall measures 6 to 8 cm, whereas the posterior vaginal

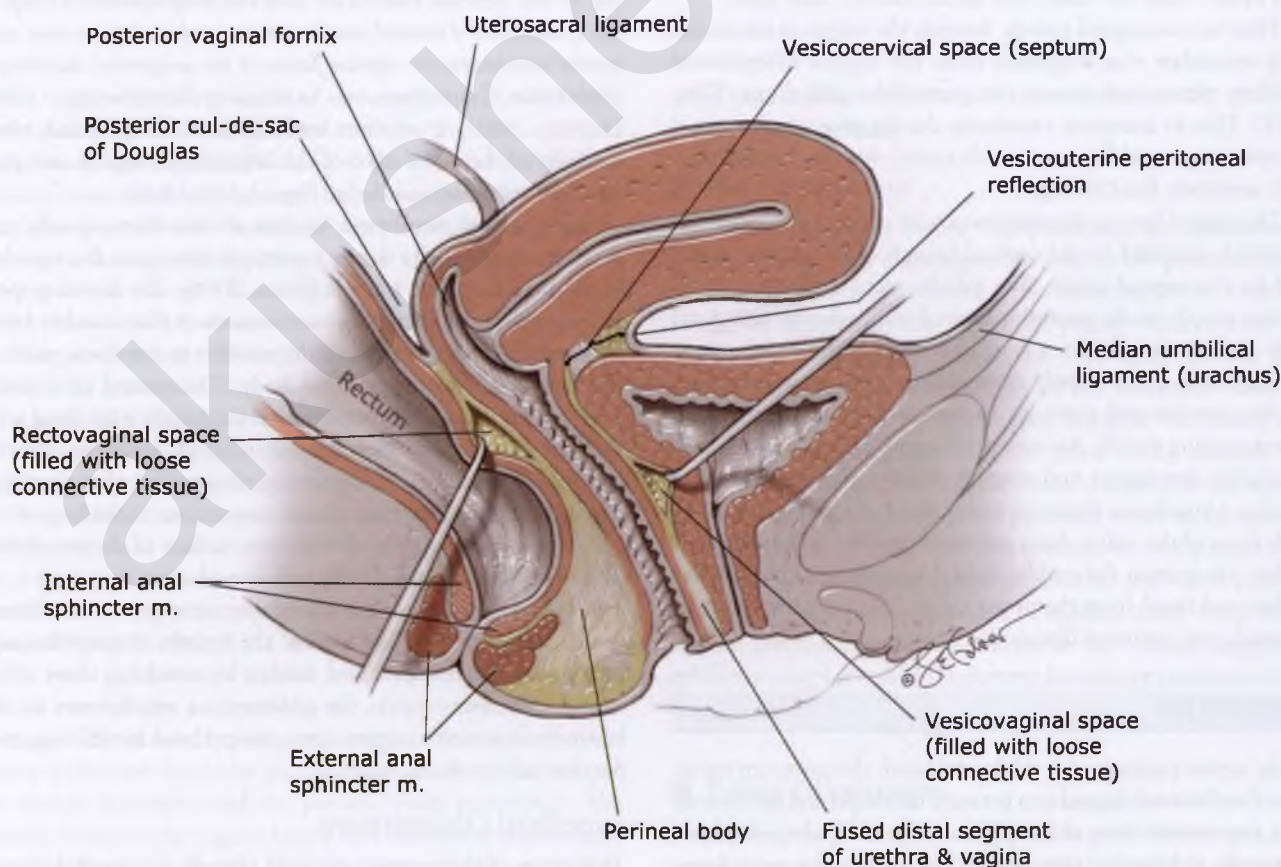


FIGURE 3-5 Surgical cleavage planes and vaginal wall layers. (Reproduced with permission from Corton MM: Anatomy. In Hoffman BL, Schorge JO, Bradshaw KD, et al (eds): Williams Gynecology, 3rd ed. New York, McGraw-Hill Education, 2016.)

wall is 7 to 10 cm. The upper end of the vaginal vault is subdivided by the cervix into anterior, posterior, and two lateral fornices. These are of considerable clinical importance because the internal pelvic organs usually can be palpated through the thin walls of these fornices. Moreover, the posterior fornix provides surgical access to the peritoneal cavity.

At the level of the hymen, the perineal membrane attaches to the lateral walls of the vagina and is believed to aid distal support. Just above this point, the pubovaginalis component of the levator ani muscles also attach to the lateral vaginal walls. The constant tone of these muscles keeps the distal vagina closed, especially prior to parturition. During vaginal birth, trauma to the levator ani muscles can lead to a wider vaginal introitus.

At the midportion of the vagina, its lateral walls are attached to the pelvis by visceral connective tissue. These lateral attachments blend into the investing fascia of the levator ani muscles.

The vaginal lining is composed of nonkeratinized stratified squamous epithelium and underlying lamina propria. In premenopausal women, this lining is arranged into numerous thin transverse ridges, known as rugae, which line the anterior and posterior vaginal walls along their length. Deep to this, there is a muscular layer, which contains smooth muscle, collagen, and elastin. Beneath this muscularis lies an adventitial layer consisting of collagen and elastin (Weber, 1997). Following epithelial birth trauma and healing, fragments of stratified epithelium are occasionally embedded beneath the vaginal surface. Similar to its native tissue, this buried epithelium continues to shed degenerated cells and keratin. As a result, firm epidermal inclusion cysts, which are filled with keratin debris, may form.

There are no vaginal glands. Instead, the vagina is lubricated by a transudate that originates from the vaginal subepithelial capillary plexus and crosses the permeable epithelium (Kim, 2011). Due to increased vascularity during pregnancy, vaginal secretions are notably increased. At times, this may be confused with amniotic fluid leakage.

The vagina has an abundant vascular supply. The proximal portion is supplied by the cervical branch of the uterine artery and by the vaginal artery. The middle rectal artery may contribute supply to the posterior vaginal wall, whereas the distal walls receive contributions from the internal pudendal artery. At each level, blood supply from each side forms anastomoses on the anterior and posterior vaginal walls with contralateral corresponding vessels. An extensive venous plexus immediately surrounds the vagina and roughly follows the course of the arteries. Lymphatics from the lower third of the vagina, along with those of the vulva, drain primarily into the inguinal lymph nodes. Those from the middle third drain into the internal iliac nodes, and those from the upper third drain into the external, internal, and common iliac nodes.

PERINEUM

In the supine position with thighs abducted, the perineum represents the diamond-shaped area between the thighs and has boundaries that mirror those of the pelvic outlet: the pubic symphysis anteriorly, ischiopubic rami and ischial tuberosities anterolaterally, sacrotuberous ligaments posterolaterally, and coccyx posteriorly. An arbitrary line joining the ischial tuberosities divides the

perineum into an anterior triangle, also called the urogenital triangle, and a posterior triangle, termed the anal triangle.

■ Perineal Body

Also called the central tendon of the perineum, the perineal body is a fibromuscular mass of tissue that lies between the distal part of the posterior vaginal wall and the anus, at the junction between the anal and urogenital triangles (see Figs. 3-3 and 3-5). The perineal body provides significant distal support for the vagina and anus and serves as the point of attachment for several structures in both the superficial and deep urogenital compartments (Shafik, 2007; Woodman, 2002). Superficially, the bulbospongiosus, superficial transverse perineal, and external anal sphincter muscles converge on the perineal body. More deeply, the perineal membrane, urethrovaginal sphincter muscles, portions of the pubococcygeus muscle, and internal anal sphincter muscle contribute (Corton, 2005; Larson, 2010). In the absence of prior trauma to the perineal body, its extent between the vagina and anus and its depth each measures approximately 3 to 4 cm. The perineal body is incised during an episiotomy and is torn with second-, third-, and fourth-degree lacerations (Chap. 20, p. 321).

■ Anterior (Urogenital) Triangle

The anterior perineal triangle can be further divided into a superficial and a deep compartment (pouch or space) by the perineal membrane. The superficial perineal space lies superficial to the perineal membrane and the deep space lies deep to the membrane. *Perineal membrane* has replaced the terms *urogenital diaphragm* or *inferior fascia of the urogenital diaphragm* (Federative Committee on Anatomical Terminology, 1998; Oelrich, 1983). It attaches laterally to the ischiopubic rami, medially to the distal third of the urethra and vagina, and posteriorly to the perineal body (Figs. 3-4 and 3-6).

The perineal membrane consists of two histologically and probably functionally distinct portions that span the opening of the anterior pelvic triangle (Stein, 2008). The dorsal or posterior portion is a dense fibrous tissue sheet that attaches laterally to the ischiopubic rami and medially to the distal third of the vagina and to the perineal body. The ventral or anterior portion of the perineal membrane is intimately associated with the compressor urethrae and urethrovaginal sphincter muscles (see Fig. 3-6 inset). The deep or superior surface of the perineal membrane appears to have direct connections to the levator ani muscles, and the superficial or inferior surface of the membrane fuses with the vestibular bulb and clitoral crus.

Clinically, the perineal membrane attaches to the lateral walls of the vagina at the level of the hymen. It provides support to the distal vagina and urethra by attaching these structures to the bony pelvis. In addition, its attachments to the levator ani muscles suggest that the perineal membrane may play an active role in support.

Superficial Compartment

This space of the anterior perineal triangle is bounded deeply by the perineal membrane and superficially by Colles fascia. This is an enclosed compartment except for the extension of

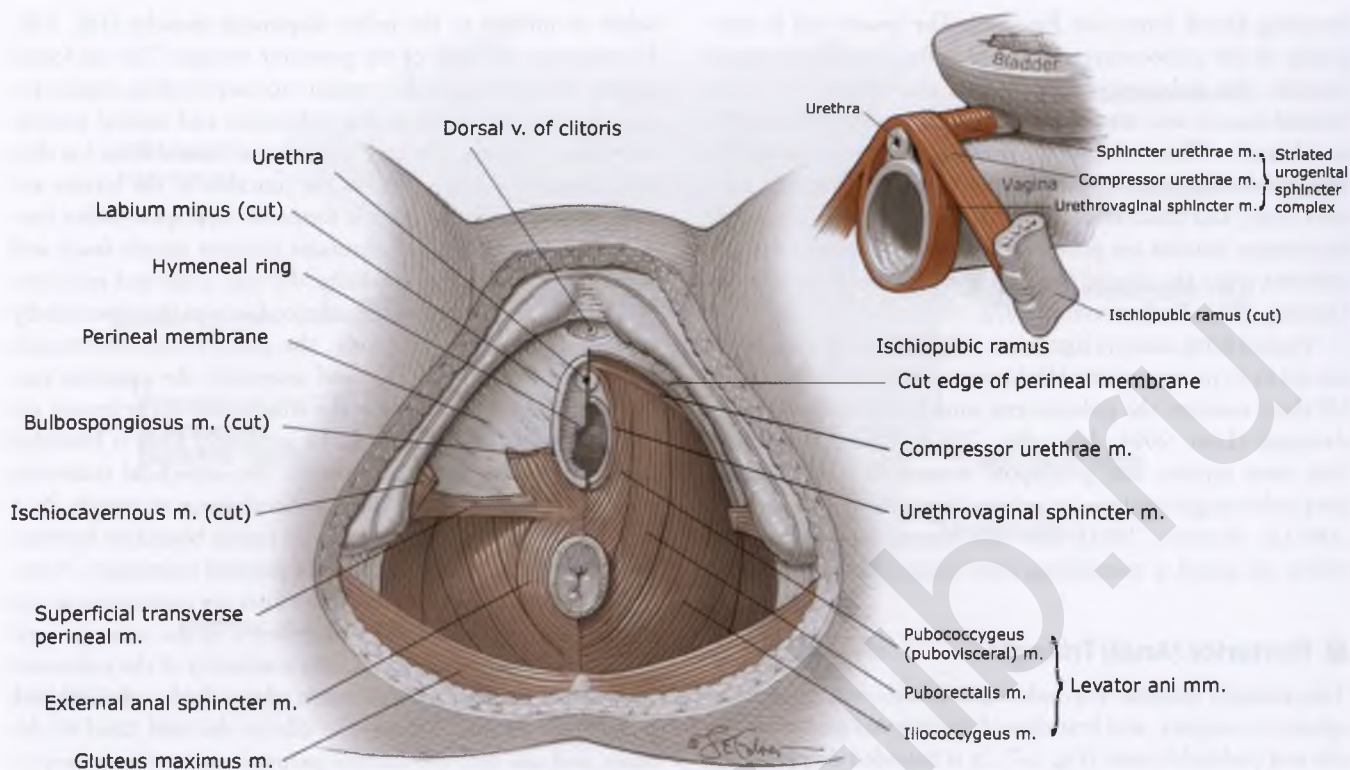


FIGURE 3-6 Deep space of the anterior perineal triangle. On the image's right lie structures noted after removal of the perineal membrane. Inset: Striated urogenital sphincter muscles. Also shown are all structures that attach to perineal body: bulbospongiosus, superficial transverse perineal, external anal sphincter, and puboperinealis muscles, perineal membrane, and urethrovaginal sphincter. (Reproduced with permission from Corton MM: Anatomy. In Hoffman BL, Schorge JO, Bradshaw KD, et al (eds): Williams Gynecology, 3rd ed. New York, McGraw-Hill Education, 2016.)

Colles fascia with Scarpa fascia of the anterior abdominal wall. Colles fascia has firm attachments to the ischiopubic rami and fascia lata of the thigh laterally and to the superficial transverse perineal muscles and the perineal membrane posteriorly. These attachments prevent the spread of most fluid, blood, or infection from the superficial perineal space to the thighs or posterior perineal triangle. However, in the mid-anterior region, Colles fascia has no attachments to the pubic bones and is therefore continuous with the anterior abdominal wall (Martin, 1984). This continuity may allow the spread of fluids between the superficial perineal space and the abdominal wall.

The superficial perineal compartment contains the Bartholin glands, vestibular bulbs, clitoral body and crura, branches of the pudendal vessels and nerve, and the ischiocavernosus, bulbospongiosus, and superficial transverse perineal muscles (see Fig. 3-4). Of these muscles, each ischiocavernosus muscle attaches on its respective side to the medial aspect of the ischial tuberosity posteriorly and the ischiopubic ramus laterally. Anteriorly, each attaches to a clitoral crus and may help maintain clitoral erection by compressing the crus to obstruct venous drainage. The bilateral bulbospongiosus muscles overlie the vestibular bulbs and Bartholin glands. They attach to the body of the clitoris anteriorly and the perineal body posteriorly. The muscles constrict the vaginal lumen and aid release of secretions from the Bartholin glands. They also may contribute to clitoral erection by compressing the deep dorsal vein of the clitoris. Last, the superficial transverse perineal muscles are narrow

strips that attach to the ischial tuberosities laterally and the perineal body medially.

Deep Compartment

This space, shown in Figure 3-6, previously and erroneously called the urogenital diaphragm, lies deep to the perineal membrane and extends up into the pelvis (Mirilas, 2004; Oelrich, 1983). In contrast to the superficial perineal space, which is primarily a closed compartment, the deep space extends into the anterior and posterior recesses of the ischioanal fossa. It is bounded superiorly by the inferior fascia of the levator ani muscles but is continuous with the pelvic cavity through the urogenital hiatus. It contains portions of the urethra and vagina and some branches of the internal pudendal artery and pudendal nerve. The deep compartment also contains the compressor urethrae and urethrovaginal sphincter muscles and distal portion of the sphincter urethrae muscle. Together, these latter three skeletal urethral muscles are known as the striated urogenital sphincter complex and are important for urinary continence (see Fig. 3-6 inset).

■ Pelvic Diaphragm

Found deep to the anterior and posterior perineal triangles, this broad muscular sling provides substantial support to the pelvic viscera. The pelvic diaphragm is made up of the levator ani and coccygeus muscle along with their superior and inferior

investing fascial layers (see Fig. 3-6). The levator ani is composed of the pubococcygeus, puborectalis, and iliococcygeus muscles. The pubococcygeus muscle is also termed the pubovisceral muscle and is subdivided based on points of insertion and function. These include the pubovaginalis, puboperinealis, and puboanalis muscles, which insert into the vaginal, perineal body, and anus, respectively (Kearney, 2004). The pelvic diaphragm muscles are primarily innervated by direct somatic efferents from the second through the fifth sacral nerve roots (Barber, 2002; Roshanravan, 2007).

Vaginal birth conveys significant risk for damage to the levator ani or to its innervation (DeLancey, 2003; Weidner, 2006). Of these muscles, the pubovisceral muscle is more commonly damaged (Lien, 2004; Margulies, 2007). Evidence supports that these injuries may predispose women to greater risk of later pelvic organ prolapse or urinary incontinence (DeLancey, 2007a,b; Rortveit, 2003). For this reason, current research efforts are aimed at minimizing these injuries.

■ Posterior (Anal) Triangle

This triangle contains the ischioanal fossae, anal canal, anal sphincter complex, and branches of the internal pudendal vessels and pudendal nerve (Fig. 3-7). It is bounded deeply by the fascia overlying the inferior surface of the levator ani muscles, and laterally by the fascia overlying the medial surface of the obturator internus muscles.

Ischioanal Fossa

Previously known as the ischiorectal fossa, this fat-filled wedge-shaped space is found on either side of the anal canal and

below or inferior to the pelvic diaphragm muscles (Fig. 3-8). It comprises the bulk of the posterior triangle. The fat found within this fossa provides support to surrounding organs yet allows rectal distention during defecation and vaginal stretching during delivery. On each side, the ischioanal fossa has skin as its superficial base, whereas the junction of the levator ani and obturator internus muscle forms its deep apex. Other borders include: laterally, the obturator internus muscle fascia and ischial tuberosity; inferomedially, the anal canal and sphincter complex; superomedially, the inferior fascia of the downwardly sloping levator ani; posteriorly, the gluteus maximus muscle and sacrotuberous ligament; and anteriorly, the posterior surface of the pubic bones below the attachment of the levator ani muscles. At a superficial level, the ischioanal fossa is bounded anteriorly by the posterior aspect of the superficial transverse perineal muscles and the deep perineal space or pouch. At a superior or deeper level, there is no fascial boundary between the fossa and the tissues deep to the perineal membrane. Posterior to the anus, the contents of the fossa are continuous across the midline except for the attachments of the external anal sphincter fibers to the coccyx. This continuity of the ischioanal fossa across perineal compartments allows fluid, infection, and malignancy to spread from one side of the anal canal to the other, and also into the anterior perineal compartment deep to the perineal membrane.

Anal Canal

This distal continuation of the rectum begins at the level of levator ani attachment to the rectum and ends at the anal skin. Along this 4- to 5-cm length, the mucosa consists of columnar epithelium in the uppermost portion, but at the dentate

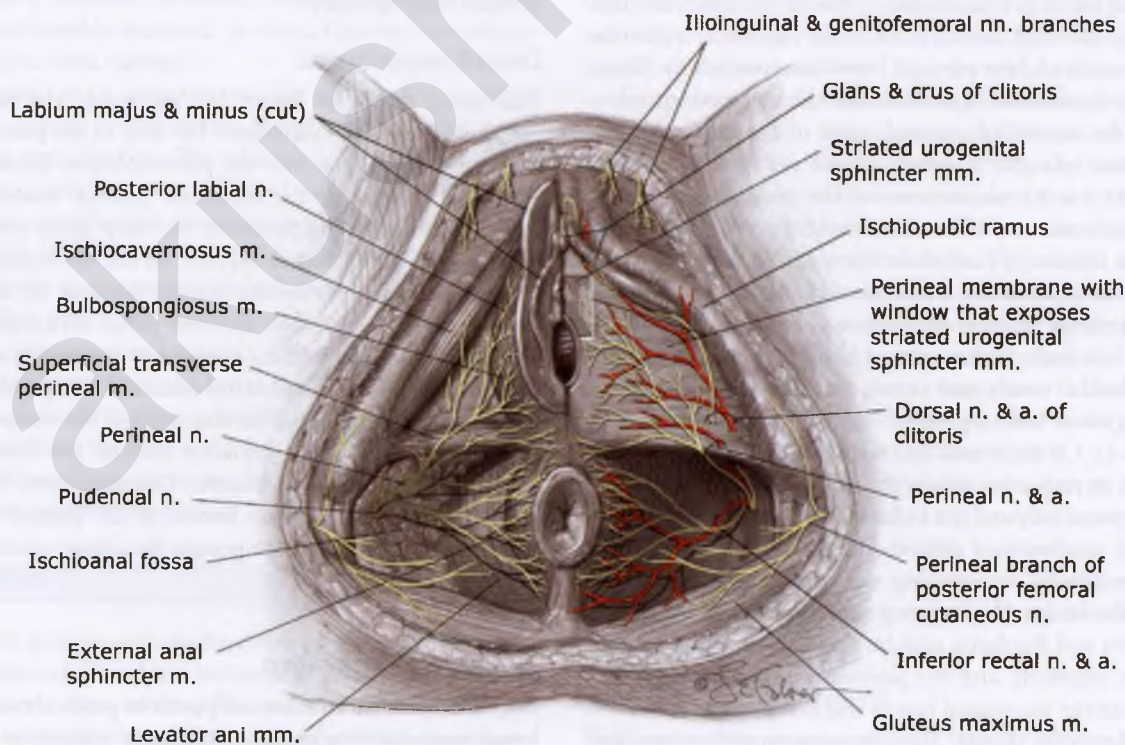


FIGURE 3-7 Anatomy of anterior and posterior perineal triangles and pudendal nerve and vessels. (Reproduced with permission from Corton MM: Anatomy. In Hoffman BL, Schorge JO, Bradshaw KD, et al (eds): Williams Gynecology, 3rd ed. New York, McGraw-Hill Education, 2016.)

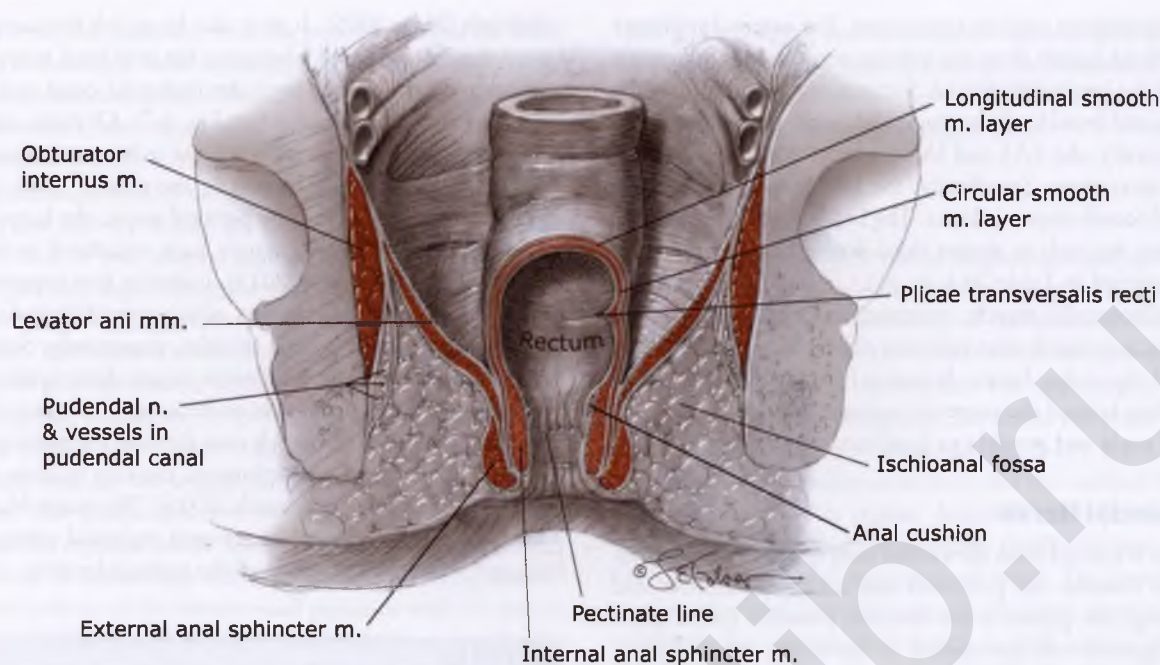


FIGURE 3-8 Ischioanal fossa and anal sphincter complex. (Modified with permission from Corton MM: *Anatomy*. In Hoffman BL, Schorge JO, Bradshaw KD, et al (eds): *Williams Gynecology*, 3rd ed. New York, McGraw-Hill Education, 2016.)

or pectinate line, simple stratified squamous epithelium begins and continues to the anal verge. Here, keratin and skin adnexa join the squamous epithelium.

The anal canal has several tissue layers. Inner layers include the anal mucosa, internal anal sphincter, and an intersphincteric space that contains the continuation of the rectal longitudinal smooth muscle layer. An outer layer consists of the puborectalis muscle at its cephalad extent and the external anal sphincter caudally.

Within the anal canal, three highly vascularized submucosal arteriovenous plexuses termed anal cushions aid complete closure of the canal and fecal continence when apposed. Increasing uterine size, excessive straining, and hard stool create increased pressure that ultimately leads to degeneration and subsequent laxity of the supportive connective-tissue base of this cushion. These cushions then protrude into and downward through the anal canal. This leads to venous engorgement within the cushions—now termed hemorrhoids. Venous stasis may result in inflammation, erosion of the epithelium, and bleeding.

External hemorrhoids are those that arise distal to the pectinate (dentate) line. They are covered by stratified squamous epithelium and receive sensory innervation from the inferior rectal nerve. Accordingly, pain and a palpable mass are typical complaints. Following resolution, a hemorrhoidal tag may remain and is composed of redundant anal skin and fibrotic tissue. In contrast, internal hemorrhoids are those that form above the dentate line and are covered by insensitive anorectal mucosa. These may prolapse or bleed but rarely become painful unless they undergo thrombosis or necrosis.

Anastomosis of the superior with the middle and inferior rectal veins represent important portal-systemic anastomoses. The inferior and middle rectal veins drain into the internal iliac vein (caval system) and hence to the right atrium. However,

the superior rectal vein drains into the inferior mesenteric vein, which is a component of the portal venous system. The veins that contribute to the portal system have no valves, and this may predispose to hemorrhoid formation.

Anal Sphincter Complex

This complex consists of two sphincters, the internal and external anal sphincter, and the puborectalis muscle. Both sphincters lie in proximity to the vagina, and one or both may be torn during vaginal delivery. The internal anal sphincter (IAS) is the distal continuation of the rectal circular smooth muscle layer (see Fig. 3-8). It is predominantly innervated by parasympathetic fibers, which pass through the pelvic splanchnic nerves (S2-S4). Along its length, this sphincter is supplied by the superior, middle, and inferior rectal arteries. The IAS contributes the bulk of the anal canal resting pressure, which significantly contributes to fecal continence, and relaxes prior to defecation. The IAS measures 3 to 4 cm in length, and at its distal margin, it overlaps the external sphincter for 1 to 2 cm (DeLancey, 1997; Rociu, 2000). The distal site at which this overlap ends is called the intersphincteric groove.

The external anal sphincter (EAS) is the striated muscle ring that surrounds the IAS. Anteriorly, it attaches to the perineal body and posteriorly, it connects to the coccyx via the anococcygeal ligament (see Fig. 3-7). The EAS maintains a constant resting contraction to aid continence, provides additional squeeze pressure when continence is threatened, yet relaxes for defecation. Although controversy persists, the EAS has traditionally been described as consisting of three parts: subcutaneous, superficial, and deep portions (Dalley, 1987). Many consider the deep portion to be continuous with the puborectalis muscle (Raizada, 2008). The more superficial fibers (subcutaneous portion) lie caudal to the internal sphincter and are separated from

the anal epithelium only by submucosa. The external sphincter receives blood supply from the inferior rectal artery, which is a branch of the internal pudendal. Somatic motor fibers from the inferior rectal branch of the pudendal nerve provide innervation. Clinically, the EAS and IAS are involved in higher-order obstetric lacerations. Specifically, the EAS is involved in both third- and fourth-degree injuries. The IAS is involved in fourth-degree tears but only in deeper third-degree lacerations, which are subclassified in Table 20-1 (p. 321).

The puborectalis muscle comprises the medial portion of the levator ani muscle that arises on either side from the inner surface of the pubic bones. It passes behind the rectum and forms a sling behind the anorectal junction, contributing to the anorectal angle and possibly to fecal continence.

■ Pudendal Nerve

This nerve is formed from the ventral rami of S2-4 spinal nerves. It courses between the piriformis and coccygeus muscles and exits through the greater sciatic foramen posterior to the sacrospinous ligament and just medial to the ischial spine (Barber, 2002; Maldonado, 2015). As such, when injecting local anesthetic for a pudendal nerve block, the ischial spine serves an identifiable landmark (Fig. 19-1, p. 309). The pudendal nerve then enters the perineum by passing through the lesser sciatic foramen to course along the medial surface of the obturator internus muscle. In this region, the nerve lies within the pudendal canal, also known as Alcock canal, which is formed by splitting of the obturator internus investing fascia (see Fig. 3-8) (Shafik, 1999). In general, the pudendal nerve is relatively fixed as it courses behind the sacrospinous ligament and within the pudendal canal. Accordingly, it may be at risk of stretch injury during downward displacement of the pelvic floor during

childbirth (Lien, 2005). It may also be at risk for compression injury during prolonged labor once the fetal head is engaged.

The pudendal nerve leaves the pudendal canal and divides into three terminal branches (see Fig. 3-7). Of these, the dorsal nerve of the clitoris runs between the ischiocavernosus muscle and perineal membrane to supply the clitoral glans (Ginger, 2011b; Montoya, 2011). The perineal nerve, the largest of the pudendal nerve branches, mainly runs superficial to the perineal membrane (Montoya, 2011). It divides into posterior labial branches and muscular branches, which serve the labial skin and the anterior perineal triangle muscles, respectively. Some muscular branches of the perineal nerve course deep to the perineal membrane and innervate parts of the urogenital sphincter complex. The inferior rectal branch runs through the ischioanal fossa to supply the external anal sphincter, the anal mucosa, and the perianal skin (Mahakkanukrauh, 2005). The major blood supply to the perineum is via the internal pudendal artery, and its branches mirror the divisions of the pudendal nerve.

UTERUS

The uterus, along with the proximal portion of the vagina and fallopian tubes, is embryologically derived from the paramesonephric ducts. The nonpregnant uterus is situated in the pelvic cavity between the bladder and the rectum. Almost the entire posterior wall of the uterus is covered by serosa, that is, visceral peritoneum (Fig. 3-9). The lower portion of this same peritoneum forms the anterior boundary of the posterior cul-de-sac—the rectouterine pouch or pouch of Douglas (see Fig. 3-5). On the anterior wall of the uterus, only the upper portion is covered by peritoneum. The peritoneum of the lower anterior wall reflects forward onto the bladder dome. With this arrangement, the lower anterior uterine

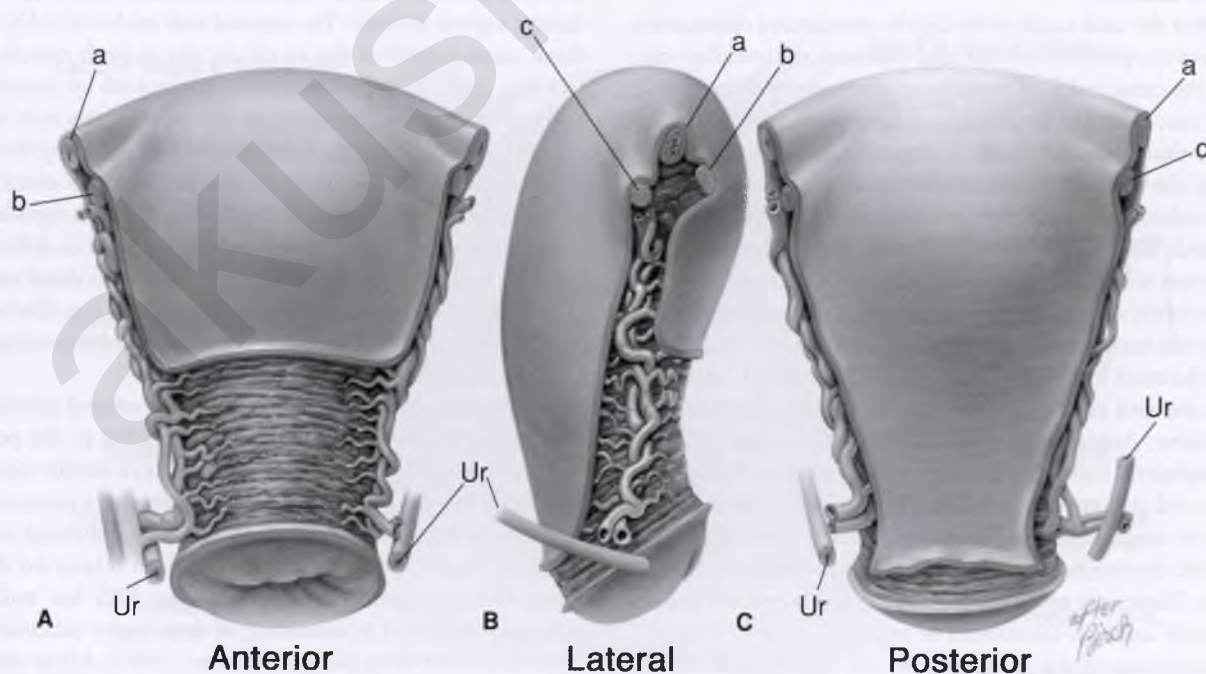


FIGURE 3-9 Anterior (A), right lateral (B), and posterior (C) views of the uterus of an adult woman. a = oviduct; b = round ligament; c = ovarian ligament; Ur = ureter. (Reproduced with permission from Cunningham FG, Leveno KJ, Bloom SL, et al (eds): *Anatomy*. In *Williams Obstetrics*, 24th ed. New York, McGraw-Hill Education, 2014.)

wall and cervix are separated from the posterior wall of the bladder by a well-defined loose connective tissue layer—the vesico-uterine/vesicocervical space. Clinically, during cesarean delivery, the peritoneum of the vesicouterine pouch is sharply incised, and the vesicouterine space is entered. Dissection caudally within this space separates the bladder off the lower uterine segment for hysterotomy and delivery (Chap. 26, p. 427).

The uterus is pear shaped and consists of two major but unequal parts: an upper triangular portion—the body or corpus, and a lower, cylindrical portion—the cervix, which projects into the vagina. The isthmus is the union site of these two. It is of special obstetric significance because it forms the lower uterine segment during pregnancy. At each superolateral margin of the body is a uterine cornu, from which a fallopian tube emerges. Also in this area are the origins of the round and uteroovarian ligaments. The fundus describes the convex upper uterine segment that lies cephalad to the level of fallopian tube insertion.

The bulk of the uterine body, but not the cervix, is muscle. The inner surfaces of the anterior and posterior walls lie almost in contact, and the cavity between these walls forms a mere slit. The nulligravid uterus measures 6 to 8 cm in length compared with 9 to 10 cm in multiparas. The nongravid uterus averages 60 g and typically weighs more in parous women (Langlois, 1970; Sheikhzadi, 2010). In nulligravidas, the fundus and cervix are approximately equal length, but in multiparas, the cervix is only a little more than a third of the total length.

Pregnancy stimulates remarkable uterine growth, which is initially due to muscle fiber hypertrophy. After 12 weeks' gestation, increasing uterine size is related to pressure exerted by the expanding conceptus. At term, the organ weighs nearly

1100 g. The uterine fundus becomes dome shaped. Moreover, the round ligaments appear to insert at the junction of the middle and upper thirds of the organ. The fallopian tubes elongate, but the ovaries grossly appear unchanged.

■ Cervix

The cervical portion of the uterus is cylindrical and open at each end by small apertures—the internal os and the external os. Proximally, the upper boundary of the cervix is the internal os, which corresponds to the level at which the anterior peritoneum is reflected onto the bladder. The upper segment of the cervix—the *portio supravaginalis*, lies above the point at which the vaginal walls attach to the cervix (Fig. 3-10). It is covered by peritoneum on its posterior surface, and the cardinal ligaments attach laterally in this region. Anteriorly, this portion of the cervix is separated from the overlying bladder by loose connective tissue within the vesicocervical space. The lower cervical portion protrudes into the vagina as the *portio vaginalis*. Before childbirth, the external cervical os is a small, regular oval opening. After labor, especially vaginal childbirth, the orifice is converted into a transverse slit that is divided such that there are the so-called anterior and posterior cervical lips. If torn deeply during labor or delivery, the cervix may heal in such a manner that it appears irregular, nodular, or stellate.

The portion of the cervix exterior to the external os is called the ectocervix and is lined predominantly by nonkeratinized stratified squamous epithelium. In contrast, the endocervical canal is covered by a single layer of mucin-secreting columnar epithelium, which creates deep cleftlike infoldings, which

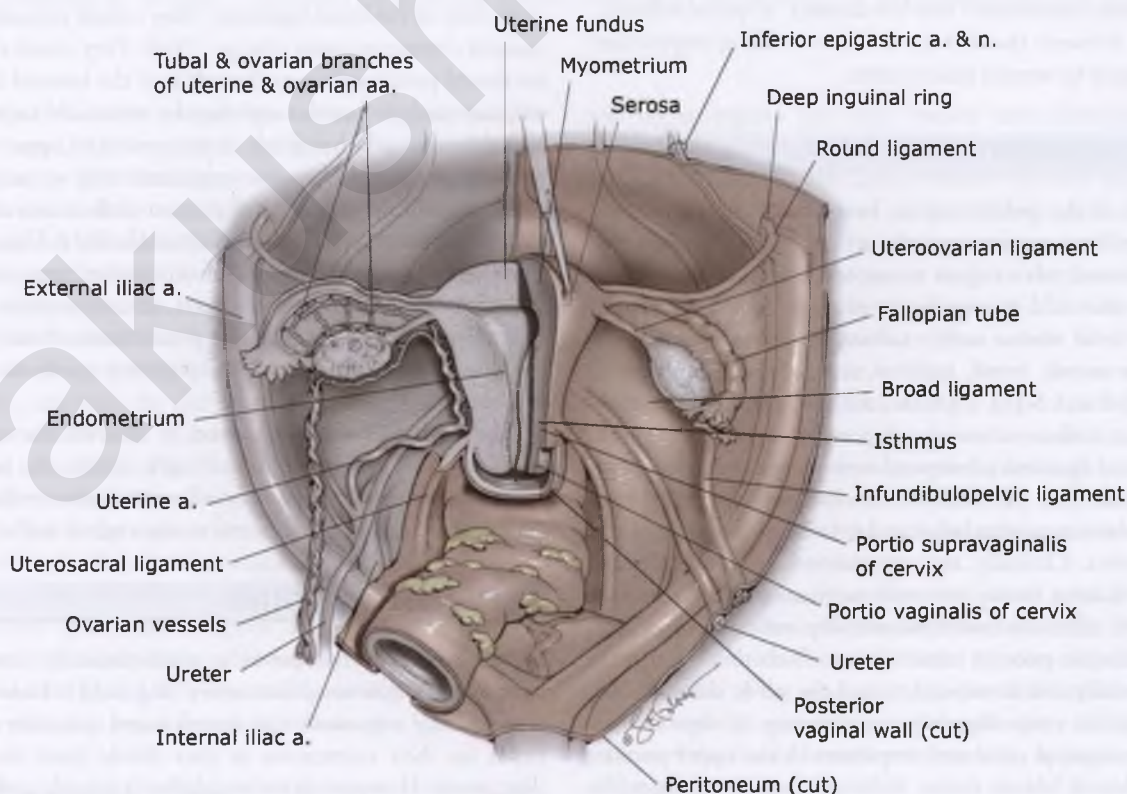


FIGURE 3-10 Uterus, adnexa, and associated anatomy. (Reproduced with permission from Corton MM: Anatomy. In Hoffman BL, Schorge JO, Bradshaw KD, et al (eds): Williams Gynecology, 3rd ed. New York, McGraw-Hill Education, 2016.)

are incorrectly often called “glands.” Commonly during pregnancy, the red, velvety endocervical epithelium moves out and onto the ectocervix in a physiologic process termed *eversion*.

The cervical stroma is composed mainly of collagen, elastin, and proteoglycans, but very little smooth muscle. Changes in the amount, composition, and orientation of these components lead to cervical ripening prior to labor onset. In early pregnancy, increased vascularity and edema within the cervix stroma beneath the epithelium leads to the ectocervical blue tint that is characteristic of *Chadwick sign* and the cervical softening that is termed *Goodell sign*. *Hegar sign* reflects uterine isthmic softening.

■ Myometrium and Endometrium

Most of the uterus is made up of myometrium, which is composed of smooth muscle bundles united by connective tissue containing many elastic fibers. Interlacing myometrial fibers surround myometrial vessels and contract to compress these. This anatomy is integral to hemostasis at the placental site after separation. Failure of the myometrium to contract leads to uterine atony, which is discussed in Chapter 29 (p. 469).

The number of myometrial muscle fibers varies by location (Schwalm, 1966). Levels progressively diminish caudally, and in the cervix, muscle composes only 10 percent of the tissue mass. During pregnancy, the upper myometrium undergoes marked hypertrophy, but there is no significant change in cervical muscle content.

The uterine cavity is lined with endometrium, which consists of an overlying epithelium, invaginating glands, and a supportive, vascular stroma. During pregnancy, the endometrium is hormonally transformed into the *decidua*. A special relationship exists between the decidua and the invading trophoblast and is integral to normal placentation.

PELVIC LIGAMENTS

Ligaments of the pelvis vary in composition and function. They range from connective tissue structures that support the bony pelvis and pelvic organs to smooth muscle and loose areolar tissue that add no significant support. Several ligaments extend from the uterine surface toward the pelvic sidewalls and include the round, broad, cardinal, and uterosacral ligaments (see Figs. 3-9 and 3-10). Of these, the cardinal and uterosacral ligaments contribute to uterine support.

The *round ligaments* correspond embryologically to the male gubernaculum testis (Acién, 2011). On each side, the round ligament originates somewhat below and anterior to the origin of the fallopian tubes. Clinically, this orientation can aid in fallopian tube identification during puerperal sterilization. This is important if pelvic adhesions limit tubal mobility and thus hinder fimbria visualization prior to tubal ligation. Each round ligament extends laterally and downward toward the pelvic sidewall. The round ligament enters the deep inguinal ring. It then courses within the inguinal canal and terminates in the upper portion of the ipsilateral labium majus. Although they do not contribute to uterine support, the round ligaments may help maintain uterine ante flexion. Sampson artery, most commonly a branch

of the uterine artery, runs just below this ligament and provides its blood supply. In nonpregnant women, the round ligament varies from 3 to 5 mm in diameter and is composed of smooth muscle bundles separated by fibrous tissue septa (Mahran, 1965). During pregnancy, these ligaments undergo considerable hypertrophy and increase appreciably in both length and diameter. Stretching of the round ligament as pregnancy advances may lead to pain or discomfort in the inguinal region.

Division of the round ligament is typically an initial step in hysterectomy. Its transection opens the broad ligament leaves and provides access to the pelvic sidewall retroperitoneum. This access allows direct visualization of the ureter and permits isolation of the uterine artery for safe ligation. This is discussed in detail in Chapter 26 (p. 424).

The *broad ligaments* are double layers of peritoneum that extend from the lateral walls of the uterus to the pelvic walls. With vertical sectioning through this ligament adjacent to the uterus, a triangular shape can be seen (see Fig. 3-9). The uterine vessels and ureter are found at its base. Each broad ligament consists of a fold of peritoneum termed the anterior and posterior leaves. This peritoneum drapes over structures extending from each uterine cornu. Peritoneum that overlies the fallopian tube is termed the *mesosalpinx*, that around the round ligament is the *mesoteres*, and that over the uteroovarian ligament is the *mesovarium*. Peritoneum that extends beneath the fimbriated end of the fallopian tube toward the pelvic wall forms the infundibulopelvic ligament or suspensory ligament of the ovary. This contains nerves and the ovarian vessels, and during pregnancy, these vessels, especially the venous plexuses, dramatically enlarge.

The *cardinal ligaments*—also called the transverse cervical or Mackenrodt ligaments—represent the thick tissue mass found at the base of the broad ligaments. They consist primarily of perivascular connective tissue (Range, 1964). They attach to the posterolateral pelvic walls near the origin of the internal iliac artery and surround the vessels supplying the uterus and vagina. Medially, this tissue attaches firmly to the cervix and upper vagina.

Each *uterosacral ligament* originates with a posterolateral attachment to the supravaginal portion of the cervix and inserts into the fascia over the sacrum (Ramanah, 2012; Umek, 2004). These ligaments are composed of connective tissue, small bundles of vessels and autonomic nerves, and some smooth muscle (Campbell, 1950). Covered by peritoneum, these ligaments form the lateral boundaries of the posterior cul-de-sac or pouch of Douglas.

The term *parametrium* is used to describe the connective tissue adjacent and lateral to the uterus within the broad ligament. Paracervical tissue is that adjacent to the cervix, whereas paracolpium is that tissue lateral to the vaginal walls.

PELVIC VASCULATURE

Blood supply to the pelvis is predominantly provided by branches of the internal iliac artery (Fig. 3-11). These branches are clinically organized into anterior and posterior divisions, based on their orientation as they divide from the internal iliac artery. However, great variability is found, and branches are highly variable between individuals. The anterior division branches provide substantial blood supply to the pelvic organs

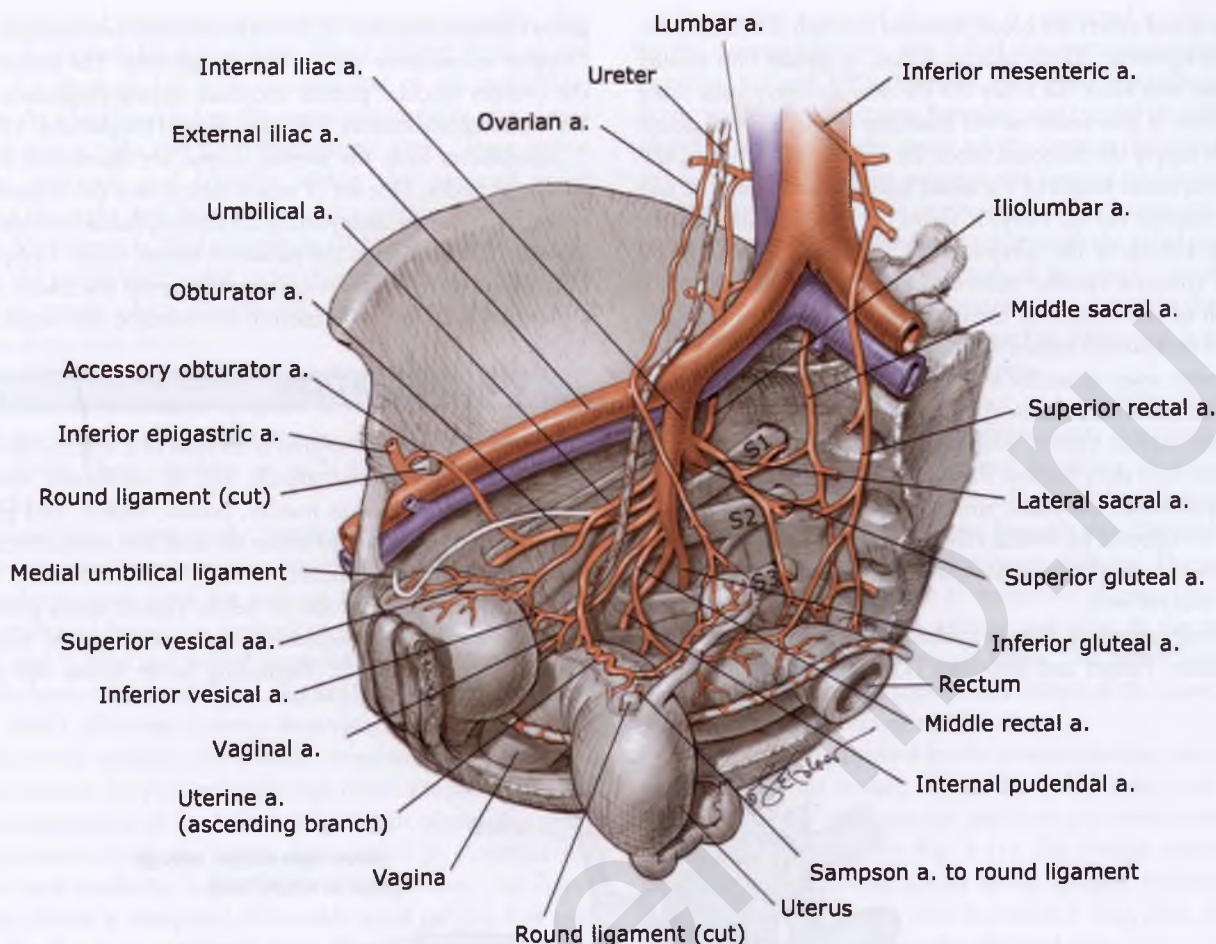


FIGURE 3-11 Pelvic arteries. In this image, the uterus and rectum are reflected to the left. (Reproduced with permission from Corton MM: Anatomy. In Hoffman BL, Schorge JO, Bradshaw KD, et al (eds): *Williams Gynecology*, 3rd ed. New York, McGraw-Hill Education, 2016.)

and perineum. Branches include the uterine, vaginal, middle rectal, obturator, inferior gluteal, and internal pudendal arteries, as well as the umbilical artery, whose patent part generally gives rise to one to three superior vesical arteries. The posterior division branches extend to the buttock, thigh, iliolumbar, and sacral regions and include the superior gluteal, lateral sacral, and iliolumbar arteries. For this reason, during internal iliac ligation, many advocate internal iliac ligation distal to the posterior division to avoid compromising blood flow to the areas supplied by this division, especially the gluteal muscles (Bleich, 2007).

The uterus derives its blood supply from both the ovarian and uterine arteries (see Fig. 3-10). The uterine artery, a main branch of the internal iliac artery, enters the base of the broad ligament to reach the upper cervix. In this path, the uterine artery crosses over the ureter approximately 1.5 to 2 cm lateral to the cervix. This proximity is of great surgical significance as the ureter may be injured or ligated during obstetric surgery. Ureters are particularly vulnerable when the uterine vessels are clamped and ligated at hysterectomy or when hemostatic sutures are placed to repair lateral extensions of a hysterotomy incision.

Once the uterine artery has reached the upper cervix, it generally divides into an ascending and a descending branch. The smaller cervicovaginal artery supplies blood to the lower cervix

and upper vagina. The main branch turns abruptly upward and extends as a highly convoluted vessel that traverses along the lateral margin of the uterus between the two leaves of the broad ligament. A branch of considerable size extends into the upper portion of the cervix, whereas numerous other branches penetrate the body of the uterus to form the arcuate arteries. These encircle the organ by coursing within the myometrium just beneath the serosal surface. These vessels from each side anastomose at the uterine midline. From the arcuate arteries, radial branches originate at right angles, traverse inward through the myometrium, enter the endometrium, and branch there to become basal arteries or coiled spiral arteries. The spiral arteries supply the functionalis layer of the endometrium. The basal arteries, also called the straight arteries, extend only into the basalis layer of the endometrium.

Just before the main uterine artery vessel reaches the fallopian tube, it divides into three terminal branches. The ovarian branch of the uterine artery forms an anastomosis with the terminal branch of the ovarian artery; the tubal branch makes its way through the mesosalpinx and supplies part of the fallopian tube; and the fundal branch penetrates the uppermost portion of the uterus.

In addition to the uterine artery, the uterus receives blood supply from the ovarian artery. This artery is a direct branch of

the aorta and enters the broad ligament through the infundibulopelvic ligament. At the ovarian hilum, it divides into smaller branches that enter the ovary. As the ovarian artery runs along the hilum, it also sends several branches through the mesosalpinx to supply the fallopian tubes. Its main stem, however, traverses the entire length of the broad ligament and makes its way to the uterine cornu. Here, it forms an anastomosis with the ovarian branch of the uterine artery. This dual uterine blood supply creates a vascular reserve to prevent uterine ischemia if ligation of the uterine or internal iliac artery is performed to control postpartum hemorrhage.

Uterine veins generally accompany their respective arteries, but great variability exists. As such, the arcuate veins unite to form the uterine vein(s), which empties into the internal iliac vein and then the common iliac vein. Some of the blood from the upper uterus, the ovary, and the upper part of the broad ligament is collected by several veins. Within the broad ligament, these veins form the large pampiniform plexus that terminates in the ovarian vein.

During pregnancy, there is marked hypertrophy of the uterine vasculature. Palmer and associates (1992) showed that uterine

artery diameter doubled by 20 weeks and that concomitant mean Doppler velocimetry was increased eightfold. The diameter of the ovarian vascular pedicle increases during pregnancy from 0.9 cm to approximately 2.6 cm at term (Hodgkinson, 1953).

Lymphatics from the uterine corpus are distributed to two groups of nodes. One set of vessels drains into the internal iliac nodes. The other set, after joining certain lymphatics from the ovarian region, terminates in the paraaortic lymph nodes. Lymphatics from the cervix terminate mainly in the internal iliac nodes, which are situated near the bifurcation of the common iliac vessels.

PELVIC INNERVATION

The peripheral nervous system is divided in a somatic division, which innervates skeletal muscle, and an autonomic division, which innervates smooth muscle, cardiac muscle, and glands. The autonomic portion is further divided into sympathetic and parasympathetic components.

Sympathetic innervation to pelvic viscera stems primarily from the superior hypogastric plexus, also termed the presacral nerve (Fig. 3-12). Beginning at or below the aortic

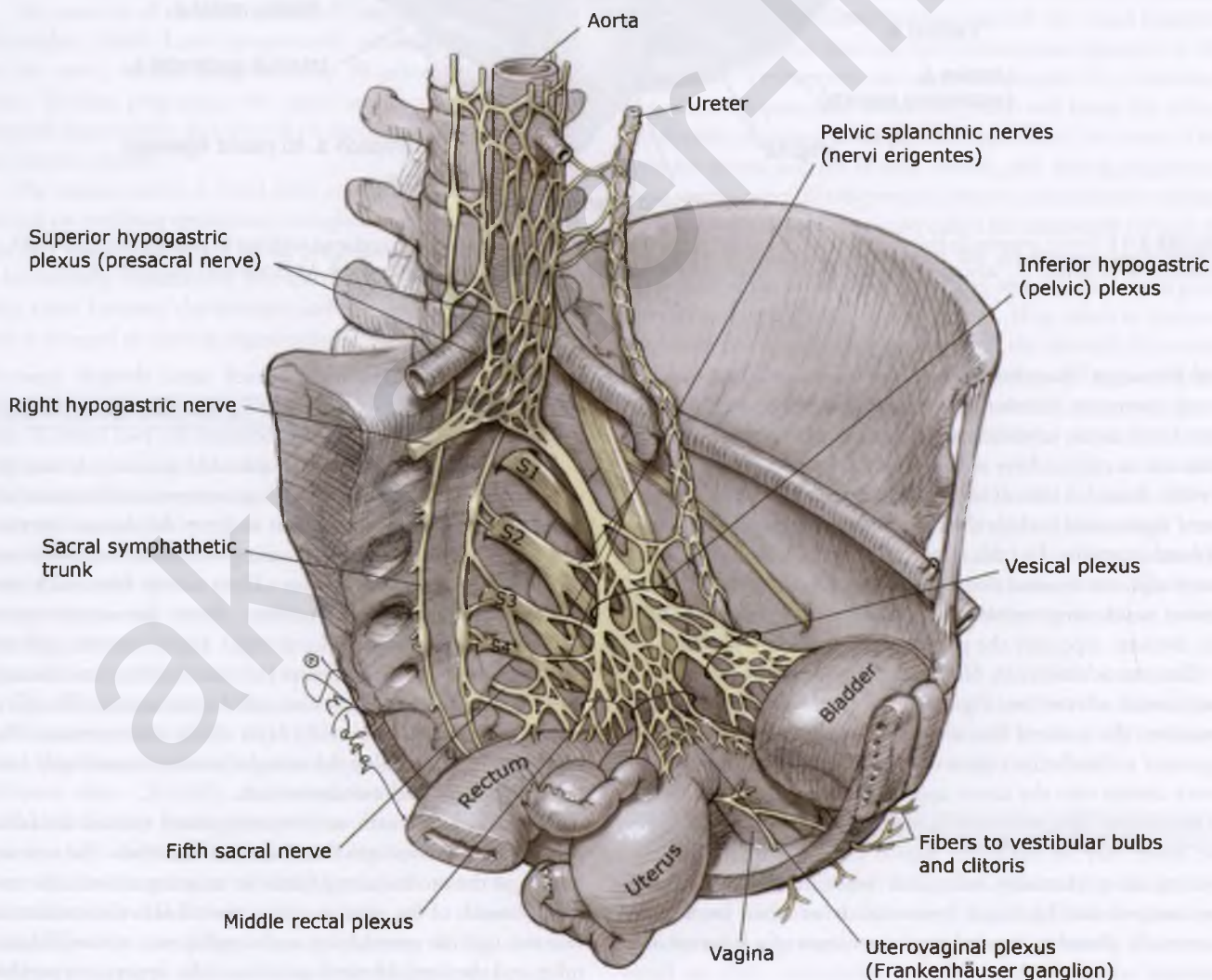


FIGURE 3-12 Pelvic autonomic nerves. Superior and inferior hypogastric plexuses. S1–S4 = first through fourth sacral nerves. (Reproduced with permission from Corton MM: Anatomy. In Hoffman BL, Schorge JO, Bradshaw KD, et al (eds): Williams Gynecology, 3rd ed. New York, McGraw-Hill Education, 2016.)

bifurcation and extending downward retroperitoneally, this plexus is formed by sympathetic fibers arising from spinal levels T₁₀ through L₂. It is an extension of the mesenteric plexus. At a level just below the sacral promontory, the plexus divides into a right and a left hypogastric nerve. These nerves course inferiorly and laterally within the presacral space toward the right and left border of the upper rectum (Açar, 2012; Moszkowicz, 2011; Ripperda, 2015). Sympathetic supply to the pelvic viscera also arises from the sacral sympathetic chain or trunk, which contributes to the inferior hypogastric plexus, described shortly.

In contrast, parasympathetic innervation to the pelvic viscera derives from neurons at spinal levels S₂ through S₄. Their axons exit as part of the anterior rami of the spinal nerves for those levels. These combine on each side to form the pelvic splanchnic nerves.

Connections between the hypogastric nerves (sympathetics), pelvic splanchnic nerves (parasympathetics), and the sacral sympathetic trunk form the inferior hypogastric plexus. This retroperitoneal branching network of intersecting nerves lies at the S₄ and S₅ level and several centimeters lateral to the rectum and the lower cervix and upper vagina (Ripperda, 2015; Spackman, 2007). The vesical plexus innervates the bladder and the middle rectal supplies the rectum, whereas the uterovaginal plexus reaches the proximal fallopian tubes, uterus, and upper vagina. Extensions of the inferior hypogastric plexus also reach the perineum along the vagina and urethra to innervate the clitoris and vestibular bulbs. Of these subplexuses, the uterovaginal plexus is composed of variably sized ganglia, but particularly of a large ganglionic plate that is situated on either side of the cervix, proximate to the uterosacral and cardinal ligaments (Ramanah, 2012).

Although the neuroanatomy of pelvic viscera is complex and not completely understood, most afferent sensory fibers from the uterus ascend through the inferior and superior hypogastric plexuses and hypogastric nerves and enter the spinal cord via T₁₀ through T₁₂ and L₁ spinal nerves. These transmit the painful stimuli of contractions to the central nervous system. The sensory nerves from the cervix and upper part of the birth canal pass through the pelvic splanchnic nerves to the second, third, and fourth sacral nerves. Those from the lower portion of the birth canal pass primarily through the pudendal nerve. Various neuraxial anesthetic blocks used in labor and delivery target this innervation (Chap. 19, p. 312).

ADNEXA

■ Ovaries

The ovaries are generally oval in shape and have a white glistening appearance. They vary in size, position, and appearance, depending on the age and the hormonal status of each woman. During childbearing years, they are generally 2.5 to 5 cm long, 1.5 to 3 cm thick, and 0.6 to 1.5 cm wide. Ovaries usually lie in the upper part of the pelvic cavity and rest in a slight depression on the lateral pelvic wall called the ovarian fossa. This fossa lies between the external and internal iliac vessels.

The medial aspect of the ovary is connected to the uterus by the ovarian ligament, also called the uteroovarian ligament (see Figs. 3-9 and 3-10). Laterally, each ovary is attached to the pelvic wall by the suspensory ligament, also termed the infundibulopelvic ligament of the ovary, which contains the ovarian vessels and nerves. The ovary proper is not covered by peritoneum. The uteroovarian ligament originates from the lateral and upper posterior portion of the uterus, just beneath the tubal insertion level, and extends to the medial pole of the ovary. Usually, this ligament is a few centimeters long and 3 to 4 mm in diameter. It is composed of muscle and connective tissue and is covered by peritoneum called the mesovarium.

The ovary consists of a cortex and medulla. In young women, the outermost portion of the cortex is smooth, has a dull white surface, and is designated the tunica albuginea. On its surface, there is a single layer of cuboidal epithelium, the germinal epithelium of Waldeyer. Beneath this epithelium, the cortex contains oocytes and developing follicles. The medulla is the central portion, which is composed of loose connective tissue. There are numerous arteries and veins in the medulla and a paucity of smooth muscle fibers. The hilum represents the depression along the mesovarian margin of the ovary where vessels and nerves enter or exit the ovary.

The ovaries are supplied by the ovarian arteries, which arise from the anterior surface of the abdominal aorta just below the origin of the renal arteries and from the ovarian branches of the uterine arteries (see Fig. 3-11). The ovarian veins follow the same retroperitoneal course as the arteries. However, the right ovarian vein drains into the inferior vena cava, and the left ovarian vein drains into the left renal vein.

Lymphatic drainage of the ovaries follows the ovarian vessels to the lower abdominal aorta. Here, lymphatic vessels drain into the paraaortic nodes.

Ovarian innervation is derived from the autonomic plexuses. The upper part of the ovarian plexus is formed from the renal and aortic plexuses, and the superior and inferior hypogastric plexuses contribute to the lower part. These plexuses consist of postganglionic sympathetic, parasympathetic, and visceral afferent fibers. Efferent sympathetic fibers within the ovarian plexus are derived from the 10th and 11th thoracic spinal segments and probably act to vasoconstrict. Sensory afferents follow the ovarian artery and enter at T₁₀ spinal cord level. Although the origin of the parasympathetic supply to the ovaries remains controversial, parasympathetic fibers are likely derived from both the vagus nerve and inferior hypogastric plexus. Parasympathetic fibers probably act to vasodilate (Stranding, 2008).

■ Fallopian Tubes

Also called uterine tubes, oviducts, or salpinges, these serpentine tubes extend 8 to 14 cm from the uterine cornua and are anatomically classified along their length as an interstitial portion, isthmus, ampulla, and infundibulum (Fig. 3-13). Most proximal, the interstitial portion is embodied within the uterine muscular wall. Next, the narrow 2- to 3-mm isthmus adjoins the uterus and widens gradually into the 5- to 8-mm, more lateral ampulla. Last, the infundibulum is the funnel-shaped fimbriated distal extremity of the tube, which opens into the abdominal cavity. The latter three extrauterine portions are

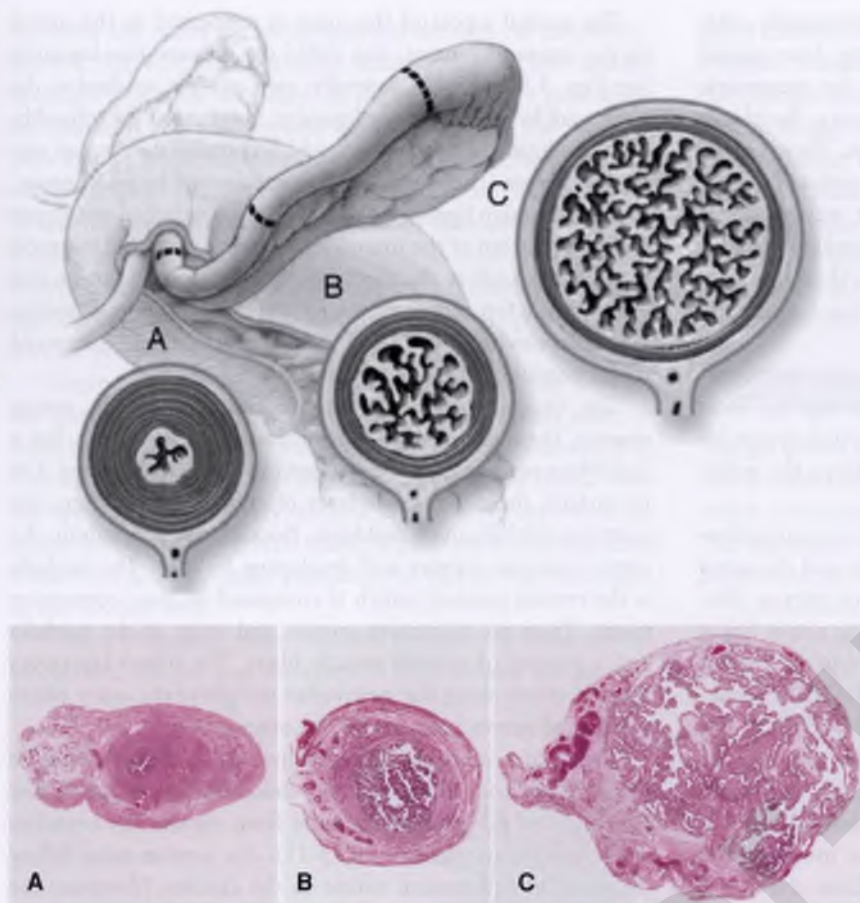

FIGURE 3-13 The fallopian tube of an adult woman with cross-sectioned illustrations of the gross structure in several portions: **(A)** isthmus, **(B)** ampulla, and **(C)** infundibulum. Below these are photographs of corresponding histologic sections. (Photographs used with permission from Dr. Kelley S. Carrick. Reproduced with permission from Cunningham FG, Leveno KJ, Bloom SL, et al (eds): *Anatomy*. In *Williams Obstetrics*, 24th ed. New York, McGraw-Hill Education, 2014.)

covered by the mesosalpinx at the superior margin of the broad ligament.

In cross section, the extrauterine fallopian tube contains a mesosalpinx, myosalpinx, and endosalpinx. The outer of these, the mesosalpinx, is a single-cell mesothelial layer functioning as visceral peritoneum. In the myosalpinx, smooth muscle is arranged in an inner circular and an outer longitudinal layer. In the distal tube, the two layers are less distinct and are replaced near the fimbriated extremity by sparse interlacing muscular fibers. The tubal musculature undergoes rhythmic contractions constantly, the rate of which varies with cyclical ovarian hormonal changes.

The tubal mucosa or endosalpinx is a single layer of columnar epithelium consisting of ciliated, secretory, and intercalary cells resting on a sparse lamina propria. It is in close contact with the underlying myosalpinx. The mucosa is arranged in longitudinal folds that become progressively more complex toward the fimbria. In the ampulla, the lumen is occupied almost completely by the arborescent mucosa. The current produced by the tubal cilia is such that the direction of flow is toward the uterine cavity. Tubal peristalsis created by cilia and muscular layer contraction is believed to be an important factor in ovum transport (Croxtatto, 2002).

The ovarian artery sends several branches through the mesosalpinx to supply the fallopian tubes (see Fig. 3-10). The venous plexus, lymphatic drainage, and nerve supply of the fallopian tubes follow a similar course to that of the ovaries.

PELVIC URETER

As the ureter enters the pelvis, it crosses over either the bifurcation of the common iliac artery or the proximal portion of the external iliac artery. In this area, it courses just medial to the ovarian vessels (see Fig. 3-10). The ureter is retroperitoneal and descends into the pelvis attached to the medial leaf of the broad ligament. Along this course, the ureter lies medial to the internal iliac branches and anterior and lateral to the uterosacral ligaments. The ureter then traverses through the cardinal ligament approximately 1 to 2 cm lateral to the cervix (see Fig. 3-9). Near the level of the uterine isthmus it courses below the uterine artery, giving rise to the saying “water under the bridge.” It then travels anteromedially toward the bladder base. In this path, it runs close to the upper third of the anterior vaginal wall (Rahn, 2007). Finally, the ureter enters the bladder and travels obliquely within the bladder wall for approximately 1.5 cm before opening at the ureteral orifice. Ureters may be injured at points along this path during obstetric surgeries. These injuries and their repair are described in Chapter 28 (p. 457).

The pelvic ureter receives blood supply from the vessels it passes: the common and internal iliac, uterine, and superior vesical vessels (see Fig. 3-11). As its course is medial to these vessels, blood supply reaches the ureter from a lateral-to-medial orientation. This relationship is important during surgical dissection to identify and isolate the ureter, also called ureterolysis. In contrast, the abdominal part of the ureter courses lateral to major vessels. Here, it receives most of its blood supply from medially located vessels. Vascular anastomoses on the connective tissue sheath enveloping the ureter form a longitudinal network of vessels. Avoiding dissection too close to this connective tissue sheath can reduce ureter devascularization during ureterolysis.

The ureter can significantly dilate during pregnancy. Schulman and Herlinger (1975) found it to be greater on the right side in nearly 85 percent of women. Theories for this unequal dilatation include cushioning provided to the left ureter by the sigmoid colon and greater compression of the right ureter by the dextrorotated uterus. In addition, the remarkable dilatation of the right ovarian vein complex, which passes obliquely over the ureter, may contribute. The ureters also elongate and often assume acute turns or angulations. At times, these may be misinterpreted in radiologic images as ureteral obstruction.

THE BONY PELVIS

■ Pelvic Bones

The pelvis is composed of four bones—the sacrum, coccyx, and two hip bones, termed the innominate bones. Each innominate bone is formed by the fusion of three bones—the ilium, ischium, and pubis, which fuse at the acetabulum, a cup-shaped structure that articulates with the femoral head (Fig. 3-14). The ilium articulates with the sacrum posteriorly at the sacroiliac joint. Anteriorly, the pelvic bones are joined together by the symphysis pubis, and this fibrocartilage is bounded and held by the superior and inferior pubic ligaments. The latter ligament is frequently designated the arcuate ligament of the pubis. As a group, these joints in general have a limited mobility, but this increases during pregnancy. Clinically, sacroiliac joint mobility is the likely reason that the McRoberts maneuver often is successful in releasing an obstructed shoulder in a case of shoulder dystocia (Chap. 24, p. 394).

The pelvis is conceptually divided into false and true components. The false pelvis lies above the *linea terminalis*, and the true pelvis is below this anatomic boundary (Fig. 3-15). The false pelvis is bounded posteriorly by the lumbar vertebra and laterally by the iliac fossa. Anteriorly, the false pelvis is bounded by the lower portion of the anterior abdominal wall.

The true pelvis is important in childbearing and extends to the pelvic floor muscles inferiorly. The *linea terminalis*, which is part of the pelvic brim, forms the superior boundary of the true pelvis and also of the pelvic inlet, described in the next section. The pelvic outlet, which represents the inferior margin of the true pelvis, has the same boundaries as the perineum (p. 34). The posterior boundary of the true pelvis is the anterior surface of the sacrum and coccyx, and the anterior boundary is formed by the dorsal surface of the pubic bones and ischiopubic rami and by the obturator membrane and obturator internus

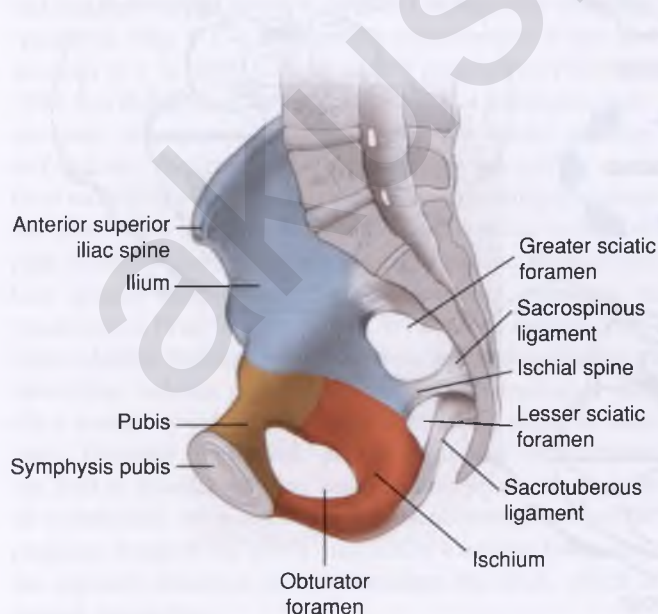


FIGURE 3-14 Sagittal view of the pelvic bones. (Reproduced with permission from Cunningham FG, Leveno KJ, Bloom SL, et al (eds): Anatomy. In Williams Obstetrics, 24th ed. New York, McGraw-Hill Education, 2014.)

muscles. The lateral boundaries are formed by the inner surface of the ischial spines and tuberosities and the sacrospinous notches and ligaments.

The ischial spines are clinically important bony prominences that project posteromedially from the medial surface of the ischium approximately at the level of the fifth sacral vertebra (S5). These are of great obstetric importance because the distance between them usually represents the shortest diameter of the true pelvis. They also serve as valuable landmarks in assessing the level to which the presenting part of the fetus has descended into the true pelvis. Last, as described earlier, these aid pudendal nerve block placement.

The sacrum forms the posterior wall of the true pelvis. Its upper anterior margin corresponds to the promontory. Normally, the sacrum has a marked vertical and a less pronounced horizontal concavity, which in abnormal pelvis may undergo important variations. The ala of the sacrum represents the winglike, triangular lateral projections on both sides of its upper surface.

■ Planes and Diameters of the Pelvis

The pelvis is described as having four arbitrary planes:

1. The plane of the pelvic inlet—the superior strait.
2. The plane of the pelvic outlet—the inferior strait.
3. The plane of the midpelvis—the least pelvic dimensions.
4. The plane of greatest pelvic dimension—posterior surface of the pubic bone at its midlength extending to the junction of the second and third vertebrae. This carries no obstetric significance for delivery.

Of these, the pelvic inlet is the superior boundary of the true pelvis (see Fig. 3-15). The inlet is bounded posteriorly by the promontory and alae of the sacrum, laterally by the *linea terminalis*, and anteriorly by the superior pubic rami and the symphysis pubis. During labor, fetal head engagement is defined as the point at which the greatest transverse diameter of the fetal skull—biparietal diameter—has passed through the pelvic inlet. Clinically, this is suggested when the lowest part of

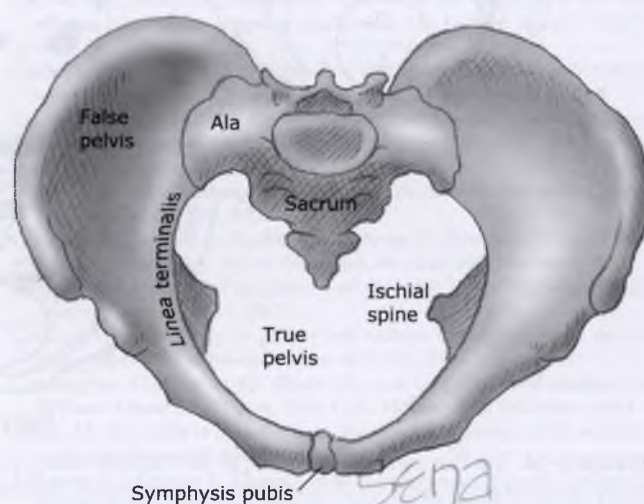


FIGURE 3-15 Adult female pelvis.

the fetal head reaches the level of the ischial spines, that is zero station, in the absence of significant scalp edema.

The *midpelvis* is measured at the level of the ischial spines, also called the midplane or plane of least pelvic dimensions. During labor, the degree of fetal head descent into the true pelvis may be described by station, and the midpelvis and ischial spines serve to mark zero station. The interspinous diameter is 10 cm or slightly greater, is usually the smallest pelvic diameter, and is particularly important in cases of obstructed labor. The anteroposterior diameter through the level of the ischial spines normally measures at least 11.5 cm.

The *pelvic outlet* consists of two approximately triangular areas whose boundaries mirror those of the perineal triangle described earlier (p. 34). They have a common base, which is a line drawn between the two ischial tuberosities. The apex of the posterior triangle is the tip of the sacrum (or coccyx), and the lateral boundaries are the sacrotuberous ligaments and the ischial tuberosities. The anterior triangle is formed by the descending inferior pubic rami. In women, these rami unite at an angle of 90 to 100 degrees to form a rounded arch under which the fetal head must pass. Obstetrically, three diameters of the pelvic outlet usually are described—the anteroposterior,

transverse, and posterior sagittal. Unless there is significant pelvic bony disease, the pelvic outlet seldom obstructs vaginal delivery.

■ Pelvic Shapes

The Caldwell-Moloy (1933, 1934) anatomic classification of the pelvis is based on shape, and its concepts aid an understanding of labor mechanisms. Specifically, the greatest transverse diameter of the inlet and its division into anterior and posterior segments are used to classify the pelvis as gynecoid, anthropoid, android, or platypelloid. The posterior segment determines the type of pelvis, whereas the anterior segment determines the tendency. These are both determined because many pelvises are not pure but are mixed types. For example, a gynecoid pelvis with an android tendency means that the posterior pelvis is gynecoid and the anterior pelvis is android shaped.

From viewing the four basic types in [Figure 3-16](#), the configuration of the gynecoid pelvis would intuitively seem suited for delivery of most fetuses. Indeed, Caldwell (1939) reported that the gynecoid pelvis was found in almost half of women.

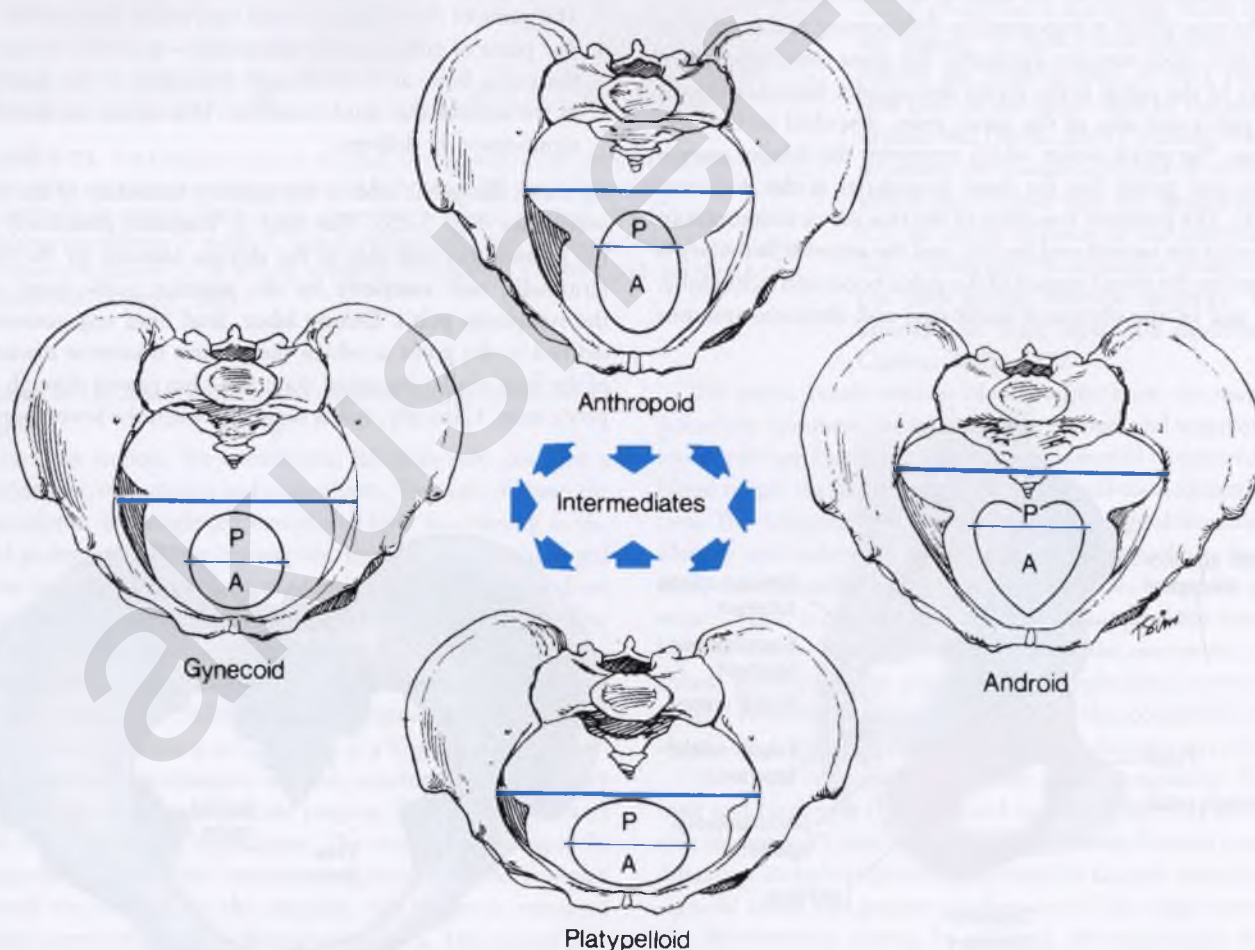


FIGURE 3-16 The four parent pelvic types of the Caldwell-Moloy classification. A line passing through the widest transverse diameter divides the inlets into posterior (P) and anterior (A) segments. (Reproduced with permission from Cunningham FG, Leveno KJ, Bloom SL, et al (eds): *Anatomy*. In *Williams Obstetrics*, 24th ed. New York, McGraw-Hill Education, 2014.)

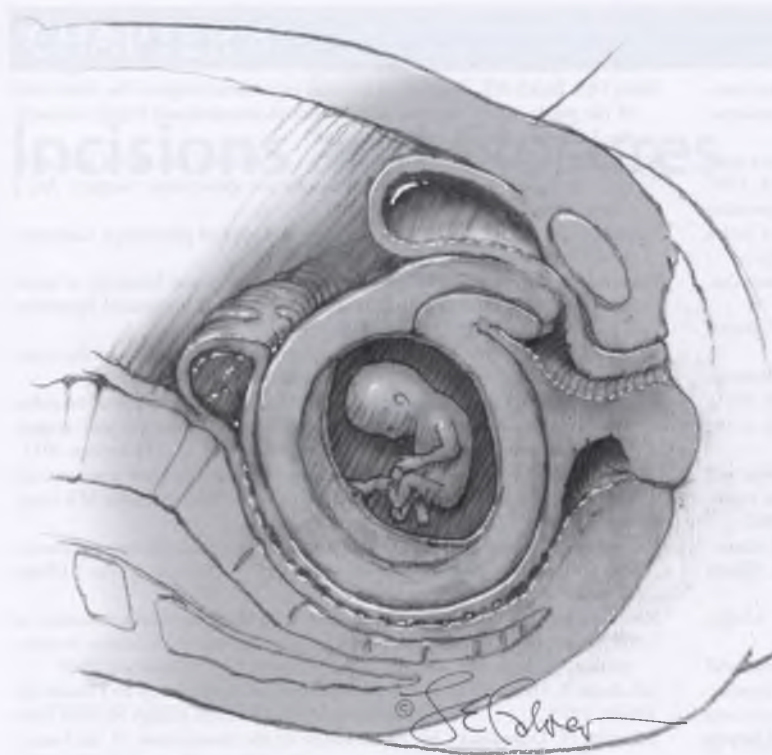


FIGURE 3-17 With uterine incarceration, the uterus is wedged between the sacral promontory and symphysis pubis. Resulting pressure against the urethra and rectum can cause urinary retention and constipation, respectively.

■ Uterine Incarceration

As the uterus enlarges during the first trimester, the fundus generally rises out of the true pelvis. In some pregnancies, however, a retroflexed or retroverted uterus fails to move upward and remains trapped between the sacral promontory and pubic symphysis (Fig. 3-17). This uterine incarceration is rare and develops in 1 in 3000 to 1 in 10,000 pregnancies (Gibbons, 1969; van Beekhuizen, 2003). Factors such as adhesions, endometriosis, leiomyomas—especially posterior fundal myomas, and anatomic abnormalities of the uterus may prevent the uterus from ascending out of the sacral hollow. Presenting symptoms are often vague and may include lower abdominal and pelvic pain, rectal pressure, and worsening constipation. Women may have urinary symptoms of dysuria, frequency, retention, or incontinence (Van Winter, 1991). With severe urinary symptoms, bladder drainage by intermittent self-catheterization or indwelling catheter may be necessary. Incarceration is usually a temporary state and resolves after 1 to 2 weeks in most cases. However, untreated, persistent uterine incarceration can lead to bladder rupture, renal failure, premature rupture of membranes, or miscarriage. Persistent entrapment of the pregnant uterus in the pelvis may lead to extensive lower uterine segment dilatation to accommodate the fetus, which is termed sacculatation.

Thus, early recognition of incarceration is important to allow pregnancy to proceed normally. Key findings during examination are severe anterior displacement of the cervix

behind the pubic symphysis, anterior angulation of vaginal axis, and a large mass that fills the posterior cul-de-sac. Sonography and magnetic-resonance imaging can be helpful adjuncts to pelvic examination when the diagnosis is suspected (Gottschalk, 2008; Grossenburg, 2011).

For uterine repositioning, the bladder is emptied, the woman is placed in the knee-chest position, and the uterus is gently pushed out of the pelvis. Often, this is best accomplished by digital pressure applied through the rectum. Conscious sedation, spinal analgesia, or general anesthesia may be necessary. Following repositioning, the catheter is left in place until bladder tone returns. Insertion of a soft pessary for a few weeks usually prevents reincarceration. Lettieri and colleagues (1994) described seven cases of uterine incarceration not amenable to these simple procedures. In two women, laparoscopy was used at 14 weeks to reposition the uterus using the round ligaments for traction. Alternatively, in two case series, colonoscopy was used to dislodge an incarcerated uterus (Dierickx, 2011; Seubert, 1999).

REFERENCES

- Açar HI, Kuzu MA: Important points for protection of the autonomic nerves during total mesorectal excision. *Dis Colon Rectum* 55(8):907, 2012
- Acien P, Sánchez del Campo F, Mayol MJ, et al: The female gubernaculum: role in the embryology and development of the genital tract and in the possible genesis of malformations. *Eur J Obstet Gynecol Reprod Biol* 159(2):426, 2011
- Barber MD, Bremer RE, Thor KB, et al: Innervation of the female levator ani muscles. *Am J Obstet Gynecol* 187:64, 2002
- Bleich AT, Rahn DD, Wieslander CK, et al: Posterior division of the internal iliac artery: anatomic variations and clinical applications. *Am J Obstet Gynecol* 197:658.e1, 2007
- Caldwell WE, Moloy HC: Anatomical variations in the female pelvis and their effect in labor with a suggested classification. *Am J Obstet Gynecol* 26:479, 1933
- Caldwell WE, Moloy HC, D'Esopo DA: Further studies on the pelvic architecture. *Am J Obstet Gynecol* 28:482, 1934
- Caldwell WE, Moloy HC, Swenson PC: The use of the roentgen ray in obstetrics, 1. Roentgen pelvimetry and cephalometry; technique of pelviroentgenography. *Am J Roentgenol* 41:305, 1939
- Campbell RM: The anatomy and histology of the sacrouterine ligaments. *Am J Obstet Gynecol* 59:1, 1950
- Corton MM: Anatomy. In Hoffman BL, Schorge JO, Bradshaw KD, et al (eds): *Williams Gynecology*, 3rd ed. New York, McGraw-Hill Education, 2016
- Corton MM: Anatomy of the pelvis: how the pelvis is built for support. *Clin Obstet Gynecol*, 48:611, 2005
- Croxatto HB: Physiology of gamete and embryo transport through the fallopian tube. *Reprod Biomed Online* 4(2):160, 2002
- Cunningham FG, Leveno KJ, Bloom SL, et al (eds): *Maternal anatomy*. In *Williams Obstetrics*, 24th ed. New York, McGraw-Hill Education, 2014
- Dalley AF: The riddle of the sphincters: the morphophysiology of the anorectal mechanism reviewed. *Am Surg* 53:298, 1987
- DeLancey JO, Kearney R, Chou Q, et al: The appearance of levator ani muscle abnormalities in magnetic resonance images after vaginal delivery. *Obstet Gynecol* 101:46, 2003

- DeLancey JO, Miller JM, Kearney R, et al: Vaginal birth and de novo stress incontinence: relative contributions of urethral dysfunction and mobility. *Obstet Gynecol* 110:354, 2007a
- DeLancey JO, Morgan DM, Fenner DE, et al: Comparison of levator ani muscle defects and function in women with and without pelvic organ prolapse. *Obstet Gynecol* 109:295, 2007b
- DeLancey JO, Toglia MR, Perucchini D: Internal and external anal sphincter anatomy as it relates to midline obstetric lacerations. *Obstet Gynecol* 90:924, 1997
- Dierickx I, Van Holsbeke C, Mesens T, et al: Colonoscopy-assisted reposition of the incarcerated uterus in mid-pregnancy: a report of four cases and a literature review. *Eur J Obstet Gynecol Reprod Biol* 158(2):153, 2011
- Federative Committee on Anatomical Terminology: *Terminologia Anatomica*. New York, Thieme Stuttgart, 1998
- Gibbons JM Jr, Paley WB: The incarcerated gravid uterus. *Obstet Gynecol* 33:842–845, 1969
- Ginger VA, Cold CJ, Yang CC: Structure and innervation of the labia minora: more than minor skin folds. *Female Pelvic Med Reconstr Surg* 17(4):180, 2011a
- Ginger VA, Cold CJ, Yang CC: Surgical anatomy of the dorsal nerve of the clitoris. *Neurourol Urodyn* 30(3):412, 2011b
- Gottschalk EM, Siedentopf JP, Schoenborn I, et al: Prenatal sonographic and MRI findings in a pregnancy complicated by uterine sacculation: case report and review of the literature. *Ultrasound Obstet Gynecol* 32:582, 2008
- Grossenburger NJ, Delaney AA, Berg TG: Treatment of a late second-trimester incarcerated uterus using ultrasound-guided manual reduction. *Obstet Gynecol* 118(2 Pt 2):436, 2011
- Hodgkinson CP: Physiology of the ovarian veins during pregnancy. *Obstet Gynecol* 1(1):26, 1953
- Hurd WW, Bud RO, DeLancey JO, et al: The location of abdominal wall blood vessels in relationship to abdominal landmarks apparent at laparoscopy. *Am J Obstet Gynecol* 171(3):642, 1994
- Kaufman RH: Cystic tumors. In Kaufman RH, Faro S (eds): *Benign Diseases of the Vulva and Vagina*. St Louis, Mosby, 1994
- Kim SO, Oh KJ, Lee HS, et al: Expression of aquaporin water channels in the vagina in premenopausal women. *J Sex Med* 8(7):1925, 2011
- Kearney R, Sawhney R, DeLancey JO: Levator ani muscle anatomy evaluated by origin-insertion pairs. *Obstet Gynecol* 104:168, 2004
- Langlois PL: The size of the normal uterus. *J Reprod Med* 4:220, 1970
- Larson KA, Yousif A, Lewicky-Gaup C, et al: Perineal body anatomy in living women: 3-dimensional analysis using thin-slice magnetic resonance imaging. *Am J Obstet Gynecol* 203(5):494.e15, 2010
- Lettieri L, Rodis JF, McLean DA, et al: Incarceration of the gravid uterus. *Obstet Gynecol Surv* 49:642, 1994
- Lien KC, Mooney B, DeLancey JO, et al: Levator ani muscle stretch induced by simulated vaginal birth. *Obstet Gynecol* 103:31, 2004
- Lien KC, Morgan DM, DeLancey JO, et al: Pudendal nerve stretch during vaginal birth: a 3D computer simulation. *Am J Obstet Gynecol* 192(5):1669, 2005
- Lloyd J, Crouch NS, Minto CL, et al: Female genital appearance: “normality” unfolds. *BJOG* 112(5):643, 2005
- Mahakkanukrauh P, Surin P, Vaidhayakarn P: Anatomical study of the pudendal nerve adjacent to the sacrospinous ligament. *Clin Anat* 18:200, 2005
- Mahran M: The microscopic anatomy of the round ligament. *J Obstet Gynaecol Br Commonw* 72:614, 1965
- Maldonado PA, Garcia AA, Chin K, et al: Anatomic variations of pudendal nerve within pelvis and pudendal canal: clinical applications. *Am J Obstet Gynecol* 213(5):727.e1, 2015
- Margulies RU, Huebner M, DeLancey JO: Origin and insertion points involved in levator ani muscle defects. *Am J Obstet Gynecol* 196:251.e1, 2007
- Martin BF: The formation of abdomino-perineal sacs by the fasciae of Scarpa and Colles, and their clinical significance. *J Anat* 138(Pt 4):603, 1984
- Mei W, Jin C, Feng L, et al: Bilateral ultrasound-guided transversus abdominis plane block combined with ilioinguinal-iliohypogastric nerve block for cesarean delivery anesthesia. *Anesth Analg* 113(1):134, 2011
- Memon MA, Quinn TH, Cahill DR: Transversalis fascia: historical aspects and its place in contemporary inguinal herniorrhaphy. *J Laparoendosc Adv Surg Tech A* 9:267, 1999
- Mirilas P, Skandalakis JE: Urogenital diaphragm: an erroneous concept casting its shadow over the sphincter urethrae and deep perineal space. *J Am Coll Surg* 198:279, 2004
- Mishriky BM, George RB, Habib AS: Transversus abdominis plane block for analgesia after Cesarean delivery: a systematic review and meta-analysis. *Can J Anaesth* 59(8):766, 2012
- Montoya TI, Calver L, Carrick KS, et al: Anatomic relationships of the pudendal nerve branches. *Am J Obstet Gynecol* 205(5):504.e1, 2011
- Moszkowicz D, Alsaid B, Bessede T, et al: Where does pelvic nerve injury occur during rectal surgery for cancer? *Colorectal Dis* 13(12):1326, 2011
- Oelrich T: The striated urogenital sphincter muscle in the female. *Anat Rec* 205:223, 1983
- Palmer SK, Zamudio S, Coffin C, et al: Quantitative estimation of human uterine artery blood flow and pelvic blood flow redistribution in pregnancy. *Obstet Gynecol* 80:1000, 1992
- Rahn DD, Bleich AT, Wai CY, et al: Anatomic relationships of the distal third of the pelvic ureter, trigone, and urethra in unembalmed female cadavers. *Am J Obstet Gynecol* 197:668.e1, 2007
- Rahn DD, Phelan JN, Roshanravan SM, et al: Anterior abdominal wall nerve and vessel anatomy: clinical implications for gynecologic surgery. *Am J Obstet Gynecol* 202(3):234.e1, 2010
- Raizada V, Mittal RK: Pelvic floor anatomy and applied physiology. *Gastroenterol Clin North Am* 37(3):493, 2008
- Ramanah R, Berger MB, Parratte BM, et al: Anatomy and histology of apical support: a literature review concerning cardinal and uterosacral ligaments. *Int Urogynecol J* 23(11):1483, 2012
- Range RL, Woodburne RT: The gross and microscopic anatomy of the transverse cervical ligaments. *Am J Obstet Gynecol* 90:460, 1964
- Ripperda CM, Jackson LA, Phelan JN, et al: Anatomic relationships of the pelvic autonomic nervous system in female cadavers: clinical applications to pelvic surgery. Oral presentation at AUGS Annual Scientific Meeting, 13–17 October, 2015
- Rociu E, Stoker J, Eijkemans MJ, et al: Normal anal sphincter anatomy and age- and sex-related variations at highspatial-resolution endoanal MR imaging. *Radiology* 217:395, 2000
- Rortveit G, Daltveit AK, Hannestad YS, et al: Vaginal delivery parameters and urinary incontinence: the Norwegian EPINCONT study. *Am J Obstet Gynecol* 189:1268, 2003
- Roshanravan SM, Wieslander CK, Schaffer JJ, et al: Neurovascular anatomy of the sacrospinous ligament region in female cadavers: implications in sacrospinous ligament fixation. *Am J Obstet Gynecol* 197(6):660.e1, 2007
- Schulman A, Herlinger H: Urinary tract dilatation in pregnancy. *Br J Radiol* 48:638, 1975
- Schwalm H, Dubrausky V: The structure of the musculature of the human uterus—muscles and connective tissue. *Am J Obstet Gynecol* 94:391, 1966
- Seubert DE, Puder KS, Goldmeier P, et al: Colonoscopic release of the incarcerated gravid uterus. *Obstet Gynecol* 94:792, 1999
- Shafik A, Doss SH: Pudendal canal: surgical anatomy and clinical implications. *Am Surg* 65:176, 1999
- Shafik A, Sibai OE, Shafik AA, et al: A novel concept for the surgical anatomy of the perineal body. *Dis Colon Rectum* 50(12):2120, 2007
- Sheikhzadai A, Sadr SS, Ghadyani MH, et al: Study of the normal internal organ weights in Tehran's population. *J Forensic Leg Med* 17(2):78, 2010
- Spackman R, Wrigley B, Roberts A, et al: The inferior hypogastric plexus: a different view. *J Obstet Gynaecol* 27(2):130, 2007
- Standring S (ed): *Female reproductive system*. In *Gray's Anatomy*, 40th ed. London, Elsevier, 2008
- Stein TA, DeLancey JO: Structure of the perineal membrane in females: gross and microscopic anatomy. *Obstet Gynecol* 111:686, 2008
- Sviggum HP, Niesen AD, Sites BD, et al: Trunk blocks 101: transversus abdominis plane, ilioinguinal-iliohypogastric, and rectus sheath blocks. *Int Anesthesiol Clin* 50(1):74, 2012
- Tolcher MC, Nitsche JF, Arendt KW, et al: Spontaneous rectus sheath hematoma pregnancy: case report and review of the literature. *Obstet Gynecol Surv* 65(8):517, 2010
- Umek WH, Morgan DM, Ashton-Miller JA, et al: Quantitative analysis of uterosacral ligament origin and insertion points by magnetic resonance imaging. *Obstet Gynecol* 103:447, 2004
- van Beekhuizen HJ, Bodewes HW, Tepe EM, et al: Role of magnetic resonance imaging in the diagnosis of incarceration of the gravid uterus. *Obstet Gynecol* 102(5 Pt 2):1134, 2003
- Van Winter JT, Ogburn PL Jr, Ney JA, et al: Uterine incarceration during the third trimester: a rare complication of pregnancy. *Mayo Clinic Proc* 66:608, 1991
- Verkauf BS, Von Thron J, O'Brien WF: Clitoral size in normal women. *Obstet Gynecol* 80(1):41, 1992
- Weber AM, Walters MD: Anterior vaginal prolapse: review of anatomy and techniques of surgical repair. *Obstet Gynecol* 89:311, 1997
- Weidner AC, Jamison MG, Branham V, et al: Neuropathic injury to the levator ani occurs in 1 in 4 primiparous women. *Am J Obstet Gynecol* 195:1851, 2006
- Whiteside JL, Barber MD, Walters MD, et al: Anatomy of ilioinguinal and iliohypogastric nerves in relation to trocar placement and low transverse incisions. *Am J Obstet Gynecol* 189:1574, 2003
- Wilkinson EJ, Massoll NA: Benign diseases of the vulva. In Kurman RJ, Ellenson LH, Ronnett BM (eds): *Blaustein's Pathology of the Female Genital Tract*, 6th ed. New York, Springer, 2011
- Wolfson A, Lee AJ, Wong RP, et al: Bilateral multi-injection iliohypogastric-ilioinguinal nerve block in conjunction with neuraxial morphine is superior to neuraxial morphine alone for postcesarean analgesia. *J Clin Anesth* 24(4):298, 2012
- Woodman PJ, Graney DO: Anatomy and physiology of the female perineal body with relevance to obstetrical injury and repair. *Clin Anat* 15:321, 2002

CHAPTER 4

Incisions and Closures

ANTERIOR ABDOMINAL WALL ANATOMY	49
ABDOMINAL INCISIONS	49
RETRACTORS	59
WOUND HEALING	59
SUMMARY	61

For the obstetric patient, several factors influence the surgeon's choice of abdominal incision and closure. Patient elements include the surgical indication, the urgency for operative intervention, and comorbid preoperative conditions. Specific to the wound, the presence of prior abdominal scars and circumstances affecting wound integrity also direct appropriate incision selection. Ideally, incisions are chosen to provide appropriately rapid entry, adequate exposure, and closure that will reduce the likelihood of infection or dehiscence.

ANTERIOR ABDOMINAL WALL ANATOMY

An intelligent choice of incision depends on a thorough understanding of abdominal wall anatomy. First, distribution of anterior abdominal wall vessels and nerves can affect postoperative healing and function. Knowledge of their location enables surgeons to minimize injury risk to these. Moreover, abdominal wall characteristics such as the direction of muscle contractility and the lines of skin and fascial tension may also alter wound healing and the resultant scar appearance and strength. Therefore, important anatomic parameters to consider include the overlying skin, subcutaneous tissue depth, abdominal wall vessels, and abdominal wall muscles and their fascial sheaths and

aponeuroses. Anterior wall anatomy is discussed and illustrated in Chapter 3 (p. 27).

ABDOMINAL INCISIONS

Incisions that are most useful for obstetric patients include the midline (vertical) incision and the Pfannenstiel, Maylard, Cherney, and supraumbilical (transverse) incisions (Fig. 4-1). Of these, transverse incisions follow Langer lines of skin tension. Thus, excellent cosmesis can usually be achieved with the Pfannenstiel, Maylard, Cherney, and transverse supraumbilical incisions. According to a study by Rees and Collier (1943), the force required to approximate the edges of a vertical incision in the lower abdomen is 30 times greater than that required to reapproximate a transverse incision. Additionally, decreased rates of fascial wound dehiscence and incisional hernia are noted. Specifically, proponents suggest that transverse incisions are as much as 30 times stronger than midline incisions. Mowat and Bonnar (1971), for example, observed that abdominal wound dehiscence after cesarean delivery was eight times more frequent with a vertical incision than with a transverse incision. Older literature also reported that wound evisceration was three to five times more common, and hernias developed two to three times more often when vertical incisions were used (Helmkamp, 1977; Thompson, 1949; Tollefson, 1954). That said, some studies indicate that this increased incidence of eviscerations with vertical incisions was secondary to inappropriate closures. Indeed, more recent studies show an advantage of midline vertical incisions compared with transverse incisions to avoid dehiscence, or note no difference (Farnell, 1986; Greenburg, 1979). Dehiscence and herniation aside, cosmesis is clearly better with transverse incisions.

■ Transverse Incisions

These incisions not only produce good cosmetic results but are also less painful. Additionally, when these incisions are placed in the lower abdomen, they interfere less with postoperative

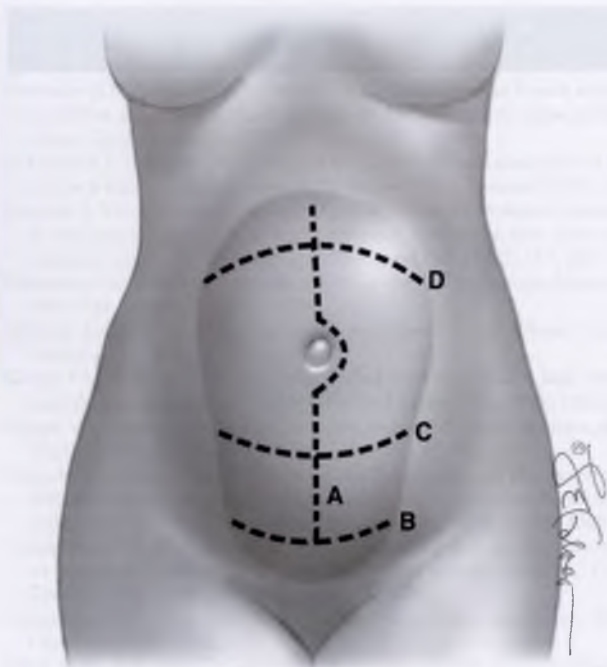


FIGURE 4-1 The most commonly used incisions are the midline vertical incision (A) and the Pfannenstiel (B). The Maylard incision (C) is a transverse incision between the umbilicus and the symphysis pubis. The supraumbilical incision, either transverse (D) or longitudinal, can be useful for obese women.

respiratory movement, thereby aiding easier recovery. Transverse incisions, however, do have certain disadvantages. Of primary importance, a transverse incision often offers less abdominal operating room than a low transverse incision. Others include: (1) the division of multiple layers of fascia and muscle can result in the formation of dead spaces; (2) there is comparatively more

bleeding; (3) these incisions are relatively more time consuming; and (4) transverse incisions may result in division of nerves, most notably the ilioinguinal and iliohypogastric nerves (Tollefson, 1954). These latter nerves pierce the fascial sheath of the internal oblique just medial to the anterior superior iliac spine and superior to the inguinal ligament. Coursing medially, they provide sensory innervation to the suprapubic area, mons pubis, and medial upper thigh (Fig. 4-2). Studies have demonstrated anatomic variation in the courses of these nerves (Rahn, 2010; Whiteside, 2003). This, combined with difficulty in visual identification, makes them vulnerable to disruption and entrapment even with a properly performed Pfannenstiel incision.

Pfannenstiel Incision

This is an excellent incision that offers adequate exposure for cesarean delivery and optimal cosmesis. As such, it is the preferred incision for nonobese women when the extra speed of delivery afforded by a vertical incision is not essential. With a Pfannenstiel incision, exposure of the pregnant uterus often is marginal, particularly in the obese woman. Also, the potential to lengthen the incision is limited. Moreover, extending the incision laterally is difficult, and the required dissection often leads to small-vessel injury. This may compromise hemostasis and necessitate a subfascial closed drainage system. Thus, the Pfannenstiel incision can be less than ideal if rapid entry, greater operating room, or upper abdominal access is critical. Examples include emergency cesarean delivery or reexploration of a patient with suspected hemorrhage or bowel injury.

To begin, the skin incision follows a semielliptical curve. Its lateral points are directed toward the anterior superior iliac spines. The midportion of the incision lies within the area of clipped pubic hair and approximately 1 to 2 cm above the symphysis pubis. Its length depends upon the amount of exposure

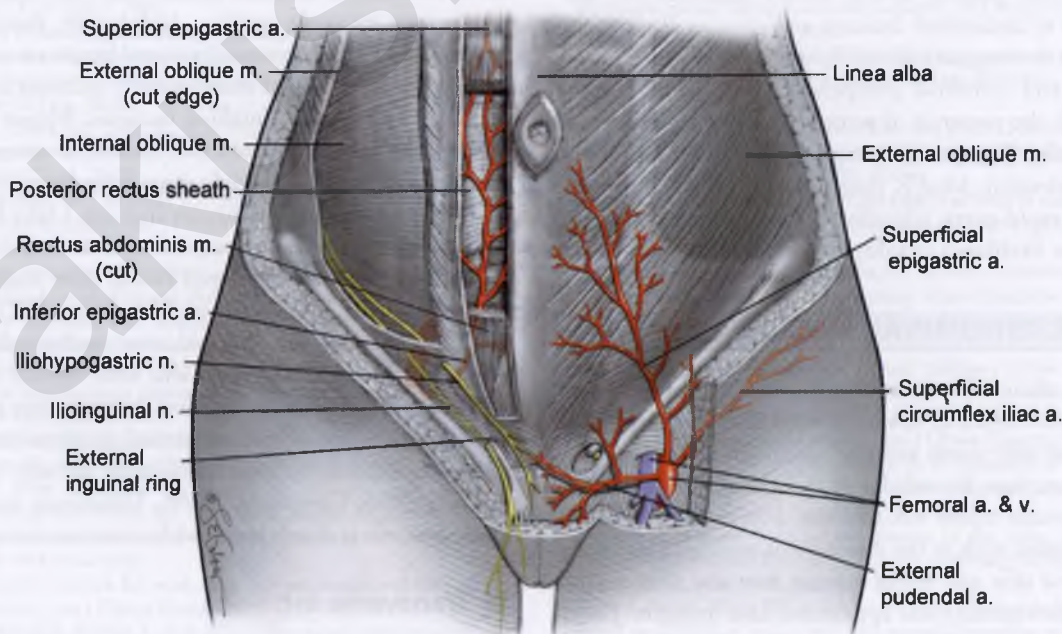


FIGURE 4-2 Anterior abdominal wall anatomy. Predominate vessels of the anterior abdominal wall are branches of the external iliac and femoral arteries. Innervation includes the ilioinguinal and iliohypogastric nerves.

required. The average incision begins and ends 2 or 3 cm below and medial to the anterior iliac crests. During skin incision, the scalpel blade is oriented perpendicular to the skin throughout. This avoids beveled skin edges, which degrade wound reapproximation and healing.

The adipose layer is also cut transversely. Bleeding can be minimized using an electrocautery blade to coagulate vessels of this layer, with special attention to the superficial epigastric artery. As shown in Figure 4-2, this artery runs longitudinally and can be found approximately 3 cm from the midline in this incision. Alternatively, blunt dissection of the adipose tissue with a retractor, from medial to lateral, moves the superficial epigastric arteries away from the dissection, which can decrease bleeding.

The anterior fascial sheath of the rectus abdominis muscles is exposed. It is then incised transversely in the midline sufficiently to expose the anterior surface of these muscles (Fig. 4-3). On each side, this dissection is carried laterally, using scissors or an electrocautery blade. Ideally, this lateral extension cuts each layer individually (Fig. 4-4). This permits identification and, ideally, avoidance of the iliohypogastric and ilioinguinal nerves as they run between these two fascial layers. Moreover, the fascia is elevated off the muscle to prevent muscle fiber transection or bleeding.

Next, the superior fascial edge is grasped with a Kocher clamp on either side of the midline. Traction is directed cephalad and slightly outward. Blunt dissection beneath the anterior fascia is then used to separate the fascia off the underlying rectus abdominis muscles (Fig. 4-5). The dissection begins just lateral to the linea alba and is carried laterally. During this separation of the anterior fascial sheath off




FIGURE 4-3 Pfannenstiel incision: the transverse incision is carried down to the rectus fascia, which is incised transversely in the midline to expose the rectus abdominis muscle. (Reproduced with permission from Hoffman BL, Corton MM: *Surgeries for benign gynecologic conditions*. In Hoffman BL, Schorge JO, Bradshaw KD, et al (eds): *Williams Gynecology*, 3rd ed. New York, McGraw-Hill Education, 2016.)

the rectus abdominis muscle bellies, methodical dissection ideally isolates small perforating vessels. These can be coagulated and then transected. The fascia separates easily from the bellies of the rectus muscle, but it may be densely adhered along the midline and require sharp dissection with curved Mayo scissors

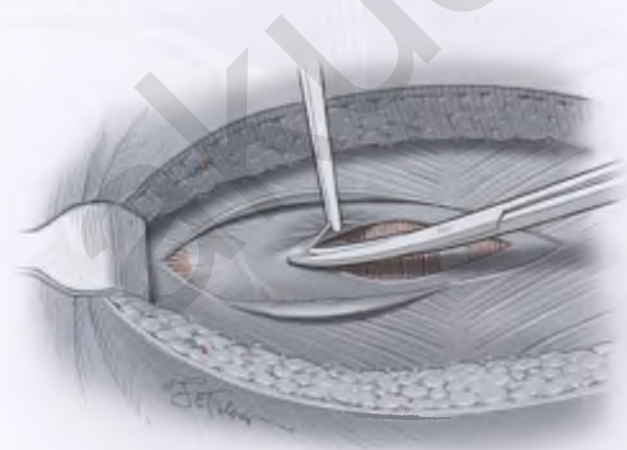


FIGURE 4-4 Pfannenstiel incision: scissors extend the fascial incision laterally and in two layers. Care is taken to avoid injuring the underlying rectus muscles. (Reproduced with permission from Hoffman BL, Corton MM: *Surgeries for benign gynecologic conditions*. In Hoffman BL, Schorge JO, Bradshaw KD, et al (eds): *Williams Gynecology*, 3rd ed. New York, McGraw-Hill Education, 2016.)

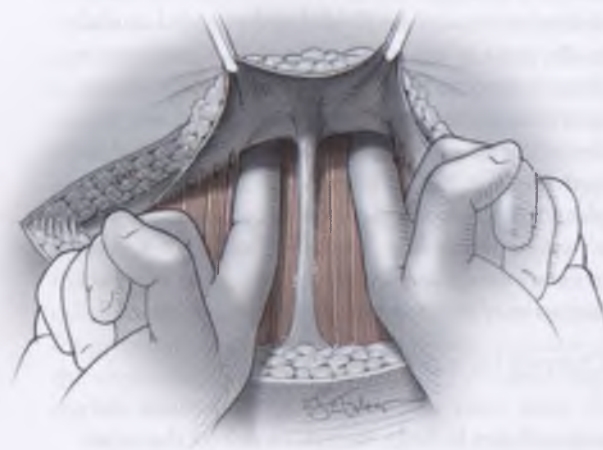

FIGURE 4-5 Pfannenstiel incision: the fascial edge is elevated and dissected away from the underlying rectus abdominis muscle. This dissection extends toward the umbilicus and the symphysis pubis. (Reproduced with permission from Hoffman BL, Corton MM: *Surgeries for benign gynecologic conditions*. In Hoffman BL, Schorge JO, Bradshaw KD, et al (eds): *Williams Gynecology*, 3rd ed. New York, McGraw-Hill Education, 2016.)

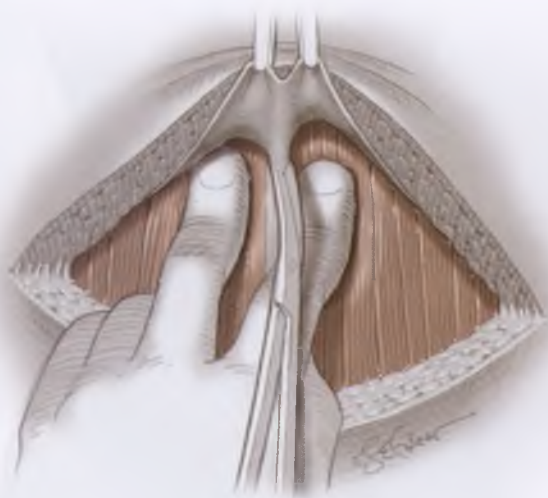


FIGURE 4-6 Pfannenstiel incision: in the midline, the anterior fascial sheath may be densely attached and require sharp dissection to separate fascia from muscle. (Reproduced with permission from Hoffman BL, Corton MM: *Surgeries for benign gynecologic conditions*. In Hoffman BL, Schorge JO, Bradshaw KD, et al (eds): *Williams Gynecology*, 3rd ed. New York, McGraw-Hill Education, 2016.)

(Fig. 4-6). Upon completion of this dissection, a semicircular area with a radius of 6 to 8 cm has been created. The area inferior to the initial fascial incision is then similarly separated.

Thereafter, the rectus abdominis muscles are bluntly parted from each other longitudinally in the midline. The pyramidalis muscle, located superficial to the rectus abdominis muscle, usually requires sharp division in the midline.

After separation of the rectus muscle bellies, the thin, filmy peritoneum is identified, grasped with two hemostats, elevated away from potential bowel and omentum, and sharply incised. Incision of the underlying peritoneum is made in a vertical fashion and extended cephalad to the extent that the rectus abdominis muscles are divided and extended caudad to the dome of the bladder (Fig. 4-7). Cystotomy is always a concern. Decompressing the bladder with an indwelling catheter and performing the inferior portion of this dissection in layers helps to prevent bladder laceration (Fig. 4-8). Following peritoneal entry, the planned operation is completed. For fascial closure, a running suture line is usually selected for a clean or clean-contaminated wound (Fig. 4-9). A complete discussion of closure technique is found on page 60.

Cherney Incision

In some cases a low transverse abdominal incision will not be large enough to deliver the infant safely or to obtain adequate exposure for hemostasis. The practice of “half transecting” the rectus abdominis muscles in this situation is discouraged for reasons explained later. Thus, under the noted circumstances, a Cherney incision may be preferred (Cherney, 1941). This incision divides the caudal tendons of both rectus abdominis muscle bellies

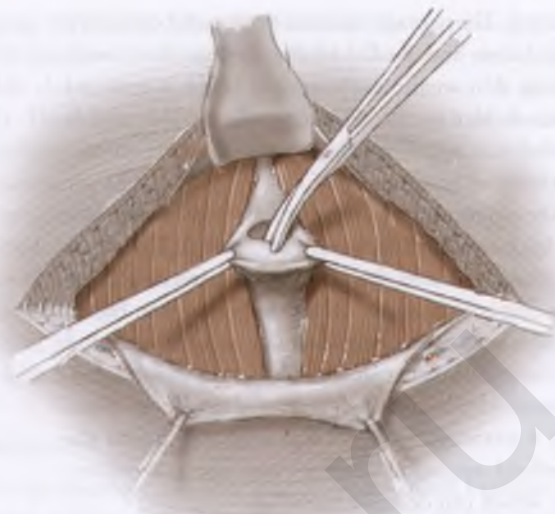


FIGURE 4-7 Peritoneal entry: the peritoneum is elevated and incised.

to provide additional operating space. The Cherney incision is approximately 25-percent longer than a midline vertical incision made from the umbilicus to the symphysis pubis. It also exposes the pelvic sidewall when needed, for example, for internal iliac artery ligation.

During tendon transection, the bladder is at risk for injury. Preventively, a surgeon can insert one finger between

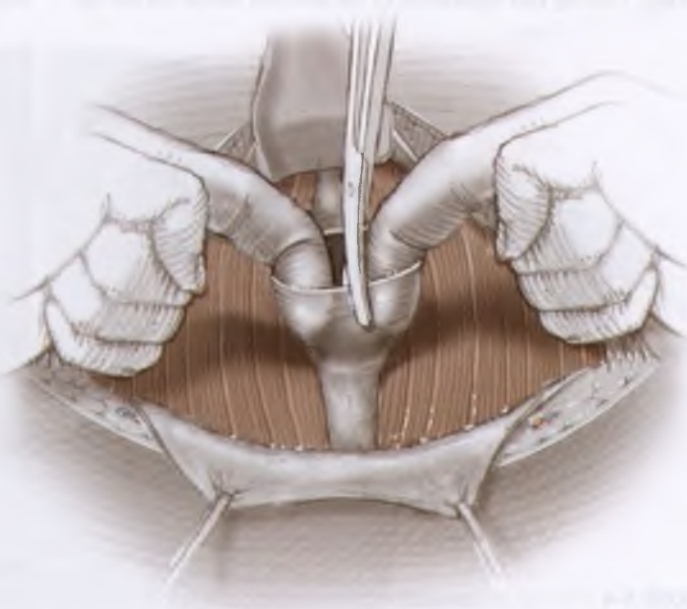


FIGURE 4-8 Peritoneal incision: the peritoneal incision is extended inferiorly, being careful to avoid cystotomy. To aid this, the caudal portion is incised in layers.

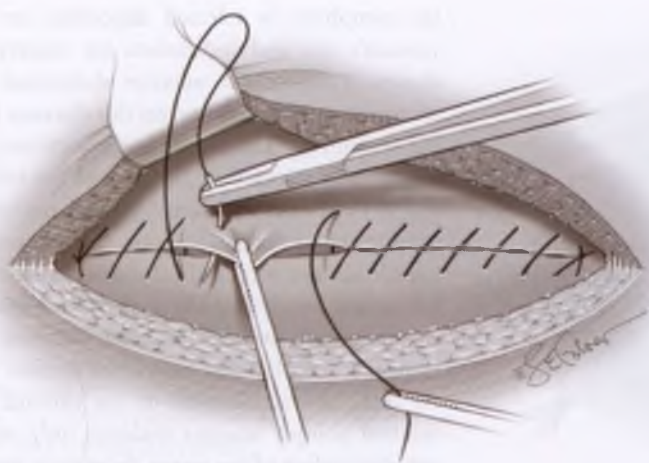


FIGURE 4-9 Fascial incision closure with a running suture line. Sutures are tied in the midline. (Reproduced with permission from Hoffman BL, Corton MM: *Surgeries for benign gynecologic conditions*. In Hoffman BL, Schorge JO, Bradshaw KD, et al (eds): *Williams Gynecology*, 3rd ed. New York, McGraw-Hill Education, 2016.)

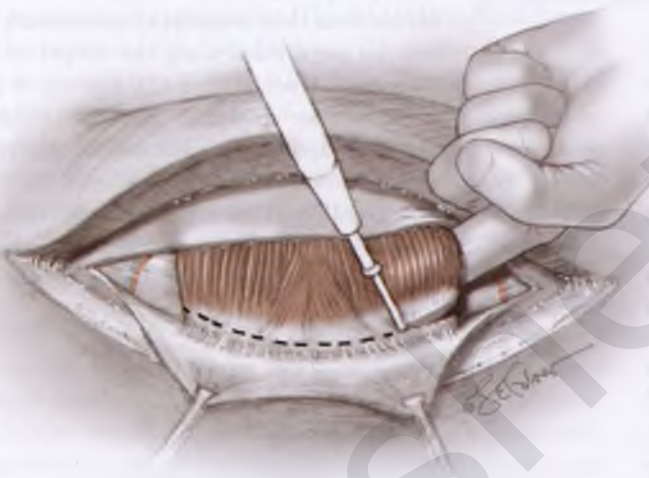


FIGURE 4-10 Cherney incision: attachments of the rectus abdominis muscle are isolated, and the tendons are cut near their insertion.

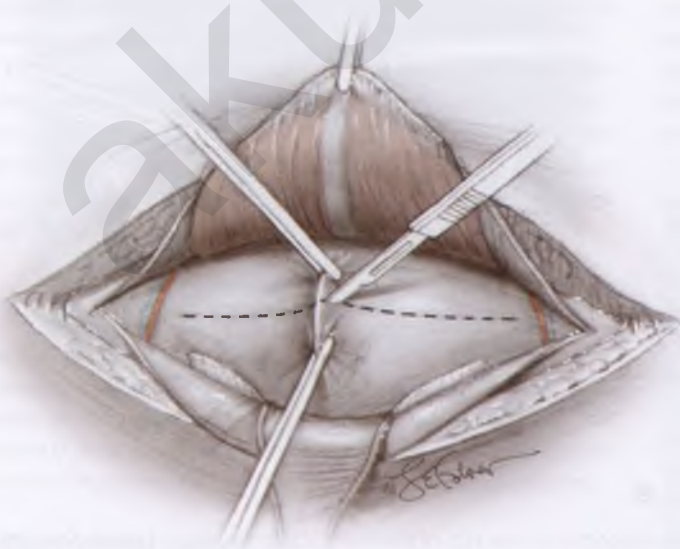


FIGURE 4-11 Cherney incision: the peritoneum is elevated and incised transversely.

the tendon and bladder and into the space of Retzius, which is the retropubic space. If the peritoneum is already incised, the space of Retzius can be developed by blunt dissection. Downward traction and pressure in the relatively bloodless midline beneath the rectus abdominis muscle can easily open the space of Retzius. At this level on the anterior abdominal wall, the inferior epigastric vessels are located laterally so injury can be avoided and their ligation is not required. The surgeon's finger is inserted into the space of Retzius and deep to the tendons (Fig. 4-10). The pyramidalis muscles and the tendinous distal rectus abdominis muscle are then sharply divided near their insertion into the pubis. Bleeding is negligible in this portion of the muscle.

The muscles are then reflected cephalad to reveal the peritoneum. The peritoneal incision can be extended laterally at a level approximately 2 cm cephalad to the bladder (Fig. 4-11).

For abdominal closure, the peritoneum is approximated separately with a fine-gauge chromic or polyglycolic acid suture in a running fashion. The need for drainage of the subfascial space is assessed individually, but in general, drains are avoided. The ends of the rectus tendons are reapproximated to the inferior portion of the rectus sheath with six to eight interrupted or horizontal mattress stitches using permanent suture (Fig. 4-12). The rectus tendons are not sutured directly to the symphysis pubis to avoid osteomyelitis. A running fascial closure can then be accomplished with no. 1 or no. 2 delayed-absorbable suture, as in the Pfannenstiel incision. Also, closure of the subcutaneous layer and skin is similar to that for the Pfannenstiel incision.

Maylard Incision

The true transverse muscle-cutting incision, the Maylard or Maylard-Bardenheuer incision, is a poor choice for cesarean delivery because of the greater operating time required. However, this incision affords excellent pelvic exposure and is used for radical pelvic surgery, including exenterations and removal of large adnexal masses (Maylard, 1907). For the obstetric patient, this incision can be used for exploratory laparotomy for postpartum bleeding, internal iliac artery ligation, or hysterectomy. It is an excellent choice for the woman treated by radical hysterectomy for cervical cancer in early pregnancy. Although it may be used for pregnant women with adnexal masses, exposure of the upper abdomen for possible surgical cancer staging is limited.

Importantly, some feel that a Pfannenstiel incision can be converted into a Maylard incision simply by incising the rectus abdominis muscles and avoiding the inferior epigastric vessels. As noted in the last section, this approach should not be pursued, as the dissection for a Pfannenstiel incision includes separation of the anterior fascial sheath from the underlying rectus abdominis muscle. The true Maylard incision does not

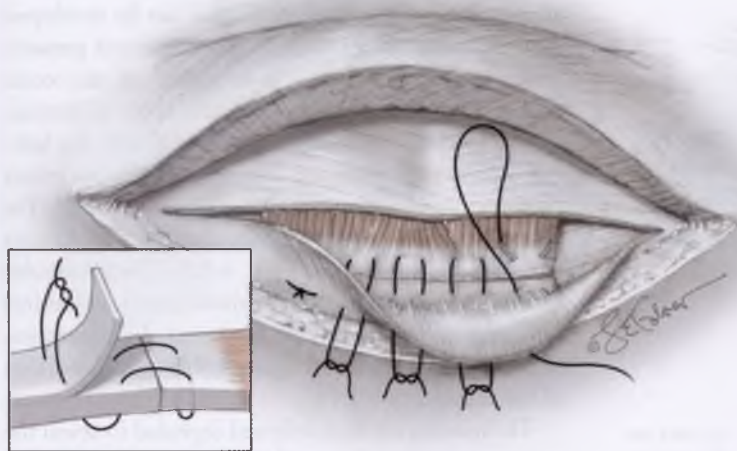


FIGURE 4-12 Cherney incision: before closing the fascia, the proximal portion of each tendon is reattached to its distal insertion using interrupted horizontal mattress stitches that also incorporate the lower rectus sheath fascia.

include this dissection. Consequently, final reapproximation of the fascial incision with a Maylard incision also brings the divided rectus muscle bellies in apposition. However, if the rectus muscles are transected after Pfannenstiel dissection, this muscle fiber apposition is compromised.

The Maylard incision begins with a transverse skin incision made 3 to 8 cm above the symphysis pubis. Distance from

the symphysis is selected depending on the woman's size and indications for surgery. As shown in Figure 4-2, anterior abdominal wall anatomy varies depending on this distance from the symphysis. Thus, with lower incisions, the pyramidalis muscles are noted, and the inferior epigastric arteries lie lateral to the rectus bellies. With more cephalad incisions, the pyramidalis muscle are not seen and inferior epigastric vessels course more medially and behind the rectus abdominis bellies. In either instance, this transverse incision lies below the arcuate line. As such, the aponeurosis of the external and internal oblique muscles coalesces only on the anterior surface of the rectus abdominis muscle.

After incising the skin and subcutaneous layer, a transverse fascial incision is made in the midline and carried well lateral to the borders of the rectus muscles. Next, blunt dissection separates the overlying rectus muscle bellies from their underlying peritoneum. The muscles are divided using the scalpel or electro-surgical blade (Fig. 4-13).

During or prior to this incision, the inferior epigastric vessels are identified lying on the posterior midportion of each muscle. The vessels are ligated with suture prior to further incision of the rectus muscles. This helps avoid vessel tearing, vessel retraction, and hematoma formation. In contrast, some surgeons advocate preserving these vessels, even when the rectus muscles are transected (Parson, 1968).

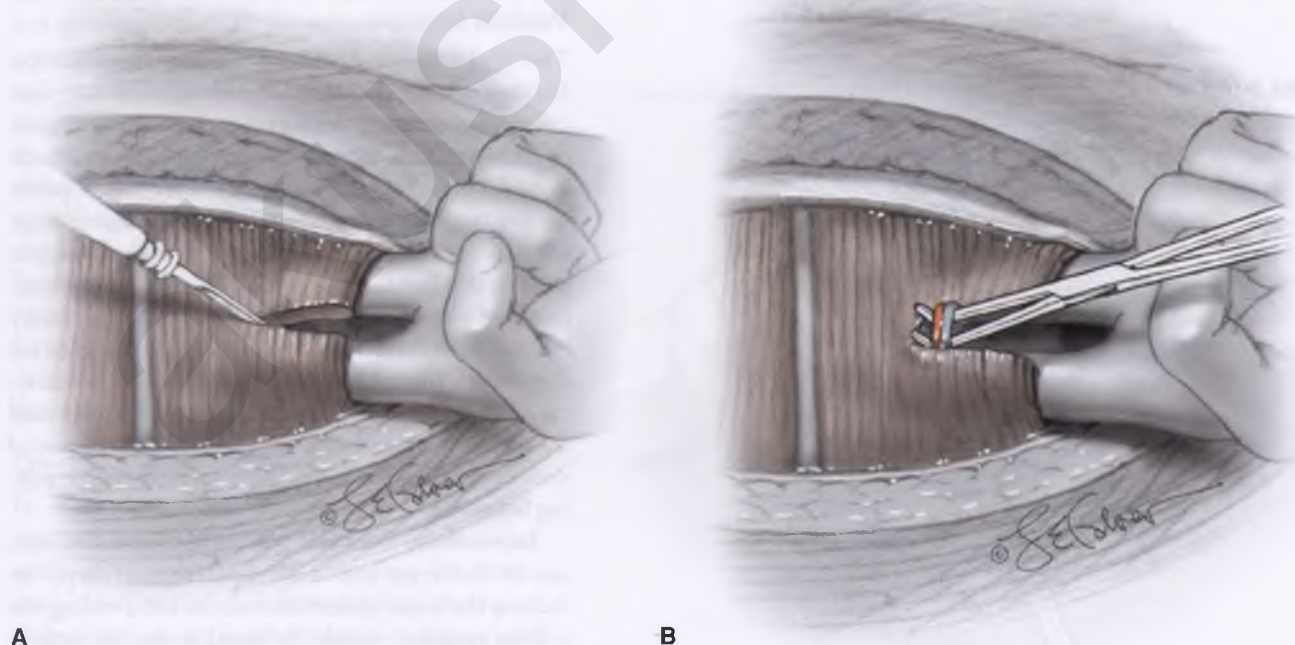


FIGURE 4-13 Maylard incision: a transverse incision is made in the midportion of the skin of the lower abdomen and is carried down to the fascia. The fascia is cut transversely, avoiding injury to the underlying rectus abdominis muscles. **A.** The bellies of the rectus abdominis muscles are then cut transversely, ideally with an electro-surgical blade, until the underlying inferior epigastric vessels are identified. **B.** The vessels are individually isolated, ligated, and then divided.




FIGURE 4-14 Maylard incision: following muscle division, the peritoneum can be cut transversely. The cut muscle ends are sutured to the fascial edge. This permits muscle fiber apposition once the fascia is closed.

For better reapproximation of the rectus muscles during closure, the underlying muscle is sutured to the overlying fascia prior to entering the peritoneum (Fig. 4-14). This affords better muscle apposition with fascial closure. The peritoneum is then incised transversely as with the Cherney incision (see Fig. 4-11).

At the procedure's end, fascial closure is similar to the technique for other transverse incisions. The muscles do not require approximation with individual sutures. In fact, sutures placed only through muscle can tear through the fibers during later muscle contraction. A subfascial drain may be considered if hemostasis is inadequate.

Supraumbilical Incision

This curving incision, shown in Figure 4-1, is made approximately 6 cm above the umbilicus and is centered in the midline. It is an excellent approach for the pregnant woman with a large uterus or an adnexal mass. In the latter instance, it can be extended to permit clear isolation of the infundibulopelvic ligament, which helps avoid ureteral injury (Gallup, 1993). A minimal staging operation for ovarian malignancy can be completed through this incision, which allows easy access to the omentum and hemidiaphragms.

The superior epigastric vessels are posterior to the midwidth of the rectus muscles in this area and are also richly anastomotic. Vessel ligation and ligation are necessary, and the muscles are then transected using an electro-surgical blade. The peritoneum is incised transversely and closed separately as for other large transverse incisions. A subfascial drain may be needed.

Vertical Incisions

When exploratory laparotomy is needed and the diagnosis is uncertain, a vertical incision is usually indicated. For instance, trauma in the pregnant woman is best managed by a vertical incision (Chap. 17, p. 284). In pregnant women, the two types of vertical incisions used are the paramedian and the midline.

Midline Vertical Incision

This incision provides rapid entry and is easy to perform. No important neurovascular structures traverse this incision, and

thus it is a relatively bloodless approach. Obstetric indications are numerous and are listed in Table 4-1.

In general, the lower midline incision is made from the symphysis pubis toward the umbilicus. As needed, it can be extended cephalad around the umbilicus. The incision is carried through the subcutaneous fat to the rectus fascia, which is incised (Fig. 4-15). Elevating the fascia with fingers or tissue clamps aids extension of this incision and helps prevent intraabdominal organ injury (Fig. 4-16).

At times, and especially during repeat laparotomy, the created fascia incision may lie lateral to the true abdominal midline. In such cases, only one rectus abdominis muscle belly is encountered. To reorient the incision, the plane between the fascia and muscle is dissected to identify the true midline between the two rectus muscle bellies (Fig. 4-17).

Because of the naturally occurring diastasis of the rectus muscles in pregnancy, there is often no need to separate the muscles, thus affording rapid access to the peritoneal cavity. The peritoneum is elevated and entered to avoid injury to intraperitoneal viscera (Fig. 4-18). This incision is extended cephalad. During this extension and above the arcuate line, the transverse fibers of the posterior rectus sheath may be seen and are incised with the peritoneum. As shown in Figure 4-19, the incision is then extended inferiorly toward the cephalad border of the bladder. To avoid cystotomy, the surgeons elevate the

TABLE 4-1. Possible Indications for Midline Incisions

Cesarean delivery for acute fetal distress or prolapsed cord
Hypovolemic shock
Prior midline incision
Suspicious ovarian tumor
Trauma
Bowel obstruction
Suspected perforated viscus
Preexisting midline incisional hernia
Obesity
Significant risks for cesarean hysterectomy
Radical cesarean hysterectomy

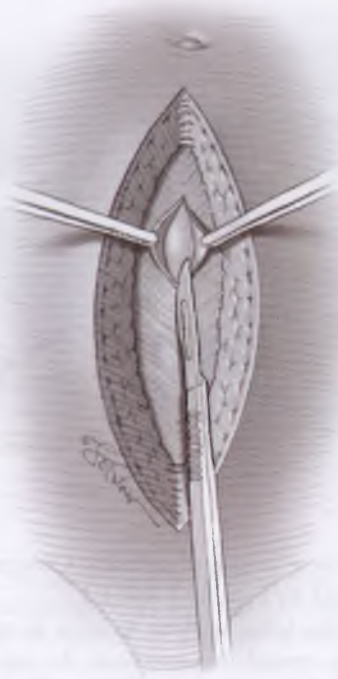

FIGURE 4-15 Midline vertical incision: a midline longitudinal incision is made from the symphysis pubis to the umbilicus. It is carried down to the fascia. The fascia is then incised longitudinally. (Reproduced with permission from Hoffman BL, Corton MM: *Surgeries for benign gynecologic conditions*. In Hoffman BL, Schorge JO, Bradshaw KD, et al (eds): *Williams Gynecology*, 3rd ed. New York, McGraw-Hill Education, 2016.)

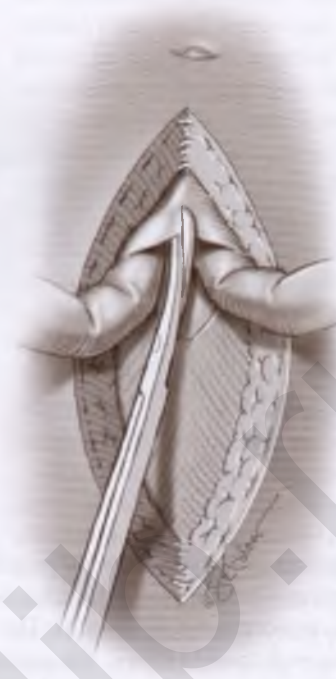

FIGURE 4-16 Midline vertical incision: the fascial incision is extended the full extent of the skin incision, while elevating it off the underlying tissue. (Reproduced with permission from Hoffman BL, Corton MM: *Surgeries for benign gynecologic conditions*. In Hoffman BL, Schorge JO, Bradshaw KD, et al (eds): *Williams Gynecology*, 3rd ed. New York, McGraw-Hill Education, 2016.)

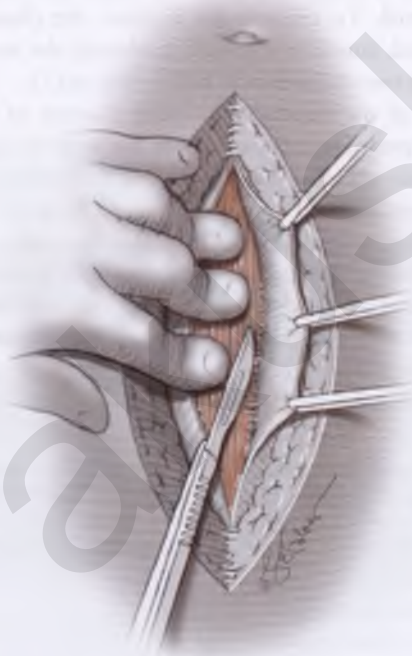


FIGURE 4-17 Midline vertical incision: at times, the created fascial incision lies lateral to the midline between the rectus abdominis bellies. In such cases, the fascial edge can be sharply dissected off the underlying rectus abdominis muscle until the true midline is identified. This is most often needed for repeat laparotomy. (Reproduced with permission from Hoffman BL, Corton MM: *Surgeries for benign gynecologic conditions*. In Hoffman BL, Schorge JO, Bradshaw KD, et al (eds): *Williams Gynecology*, 3rd ed. New York, McGraw-Hill Education, 2016.)

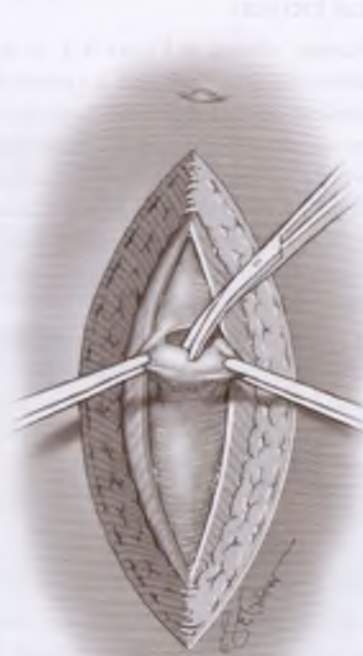

FIGURE 4-18 Midline vertical incision: the peritoneum is elevated and incised longitudinally to gain entry into the peritoneal cavity. (Figures 4-15 through 4-18: reproduced with permission from Hoffman BL, Corton MM: *Surgeries for benign gynecologic conditions*. In Hoffman BL, Schorge JO, Bradshaw KD, et al (eds): *Williams Gynecology*, 3rd ed. New York, McGraw-Hill Education, 2016.)

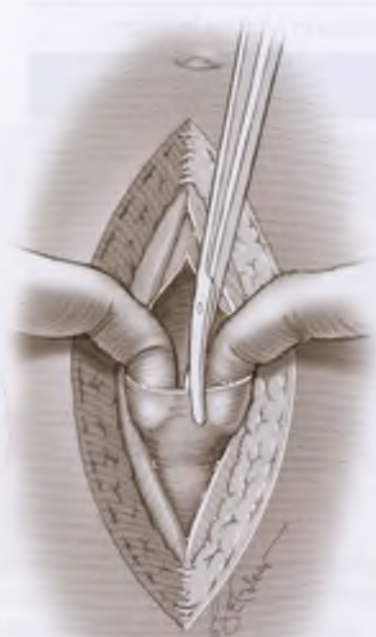

FIGURE 4-19 Midline vertical incision: the peritoneal incision is extended inferiorly by elevating the edges and incising it in layers to avoid injury to the bladder. (Reproduced with permission from Hoffman BL, Corton MM: *Surgeries for benign gynecologic conditions*. In Hoffman BL, Schorge JO, Bradshaw KD, et al (eds): *Williams Gynecology*, 3rd ed. New York, McGraw-Hill Education, 2016.)

peritoneal edges, and the incision is made in layers. Once the peritoneum is incised, the planned operation is completed. At the procedure's end, fascial closure is usually accomplished with a simple running suture line. Suturing begins at each pole of the incision and progresses to the incision's midpoint. No. 1 or no. 2 delayed-absorbable suture is suitable and incorporates the right and left edges of the linea alba. Once the midpoint is reached, sutures are tied together.

In patients at risk for dehiscence, mass closure with stitches that simultaneously incorporate the peritoneum, rectus sheath, and rectus muscle can be considered (Morrow, 1977; Shepherd,

1983; Wallace, 1980). Of these, the Smead-Jones closure places two bites on each side of the wound edge in a far-far, near-near arrangement (Fig. 4-20). This offers greater wound security because tension is distributed between two points. Moreover, stitches that are placed far from the wound require more force to pull through. With Smead-Jones closure, the far bites are placed 1.5 to 2 cm from the fascial edge, whereas near bites are placed 1 cm from the edge. Stitches are spaced approximately 1 cm apart along the incision length.

Alternatively, a single-layer, running, mass-closure technique can be selected. With this, stitches are placed similar to the Smead-Jones but only employ the far stitches (Fig. 4-21). As noted in Table 4-2, mass closure is effective and associated with cumulative dehiscence rates below 1 percent.

Paramedian Incision

This incision is used rarely in obstetrics. Proponents claim that it is stronger once healed than the midline incision. But Guillou and coworkers (1980) compared midline, medial paramedian, and lateral paramedian incisions in a prospective study and did not identify significant differences in rates of respiratory complication, wound infection, and dehiscence. They reported that the incidence of incisional hernias in patients with midline and medial paramedian incisions was the same, however, no hernias developed following lateral paramedian incisions. Relative disadvantages of the paramedian incision include greater rates of infection or intraoperative bleeding and longer operating time. There also can be nerve damage and atrophy of the rectus abdominis muscle. In addition, long paramedian incisions may increase postoperative pain with respiration.

■ Obesity

The technique demonstrated in Figure 4-22 is an ideal incision for massively obese pregnant women. It avoids cutting through the thick panniculus and the anaerobic moist environment of the subpannicular fold. In determining the site for the midline vertical skin incision, the surgeon identifies the crease beneath the panniculus. The incision begins on the skin at a level on the abdomen cephalad to this crease. As a result, the skin incision is periumbilical and extends cephalad around the umbilicus

FIGURE 4-20 Smead-Jones closure: in this far-far, near-near pattern, far stitches are placed 1.5 to 2 cm from the wound edge. Far stitches incorporate the anterior rectus sheath, rectus muscle, posterior rectus sheath, and peritoneum. Near stitches are placed 1 cm from the wound edge and incorporate only the anterior rectus sheath fascia. Along the incision length, stitches are spaced 1 cm apart.

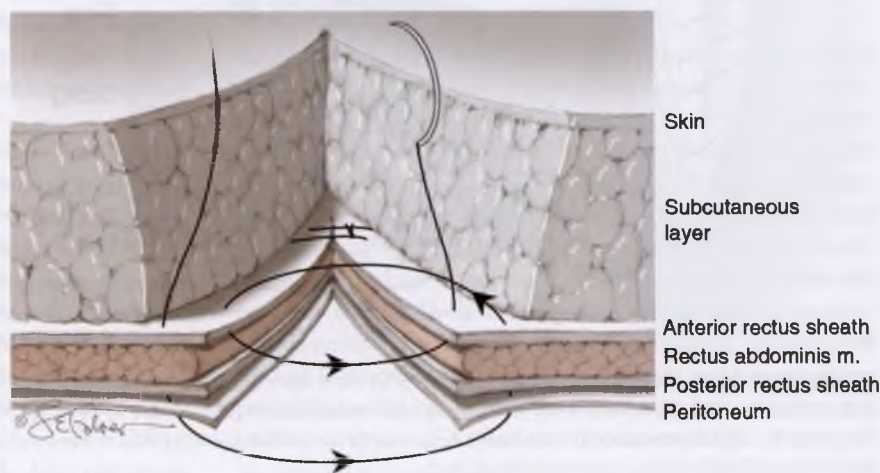


TABLE 4-2. Fascial Dehiscence after Closure with Running Sutures in Midline Incisions

Study	Number ^a	Suture ^b	Dehiscence Cases
Archie (1981)	120	No. 1 polypropylene	1
Murray (1978)	255	No. 1 polyglycolic acid	1
Shepherd (1983)	200	No. 2 polypropylene	0
Knight (1983)	419	No. 1 polypropylene	4
Gallup (1989)	210	No. 2 polypropylene	0
Total	1204		6 (0.5%)

^aNumber of cases.

^bProlene is a name brand for polypropylene suture, whereas Dexon is a name brand for polyglycolic acid suture.

as needed to afford sufficient delivery space. As shown in the figure, although higher on the abdomen, this incision provides access to the lower uterine segment.

At the procedure's end, the fascia is closed with a Smead-Jones or running mass closure. After irrigating the subcutaneous layer with normal saline, some choose to use a Jackson-Pratt drain that is placed superficial to the fascia. This drain is removed at 72 hours or after its output has fallen to less than 50 mL in 24 hours. There have been no randomized studies regarding the use of subcutaneous sutures versus subcutaneous drains in this population. Of obese women who had wound infections in a series reported by Morrow and colleagues (1977), none had subcutaneous drains.

A time-honored surgical principle is to eliminate dead space, although subcutaneous areas rarely contain adequate supportive tissues for approximation. If sutures are used, a running approximation using fine-gauge absorbable suture is performed. The relatively low wound infection rate in obese women in whom this technique was used supports this type of operative management (Gallup, 1989, 1990). The skin is closed with a suture stapler, and these staples are left in place for 7 to 14 days. Alternatively, the skin can be approximated with a subcuticular suture line.

The transverse supraumbilical incision is an alternative for obese pregnant women. This technique is most useful in women with a voluminous panniculus. Tixier and associates (2014)

describe a retrospective review of 18 patients with a mean body mass index of 47.7 kg/m² in whom this incision was used. The incision was subumbilical in 13 women (72 percent) and supraumbilical in the remainder. They reported excellent exposure of the lower uterine segment, and simple extraction of the neonate. Helmkamp and coworkers (1984) reported a wound infection rate of 25 percent in massively obese women in whom a periumbilical transverse incision was used. Because muscle cutting may be needed for this transverse incision, entry time can be lengthy and the resulting incision can be relatively bloody. If any transverse incision is chosen for obese women, it is ideally far removed from the subpannicular fold.

Prophylactic use of negative-pressure wound therapy (NPWT) has also been advocated as a technique to minimize surgical-site infection in obese women. Tuffaha and colleagues (2015) performed a cost utility analysis demonstrating theoretical cost effectiveness of NPWT compared with a standard, sterile skin dressing. Further studies are needed to confirm this. NPWT is discussed and illustrated in Chapter 2 (p. 25).

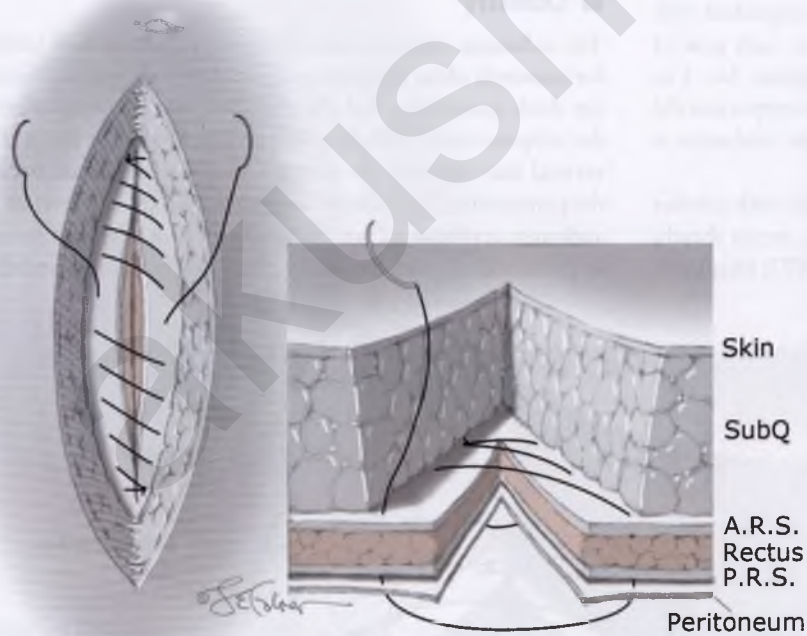


FIGURE 4-21 Mass closure: stitches are placed 1.5 to 2 cm from the wound edge (A) and incorporate the peritoneum, rectus muscle, and rectus sheath (B). Along the incision length, stitches are spaced 1 cm apart. A.R.S. = anterior rectus sheath; P.R.S. = posterior rectus sheath; SubQ = subcutaneous layer.

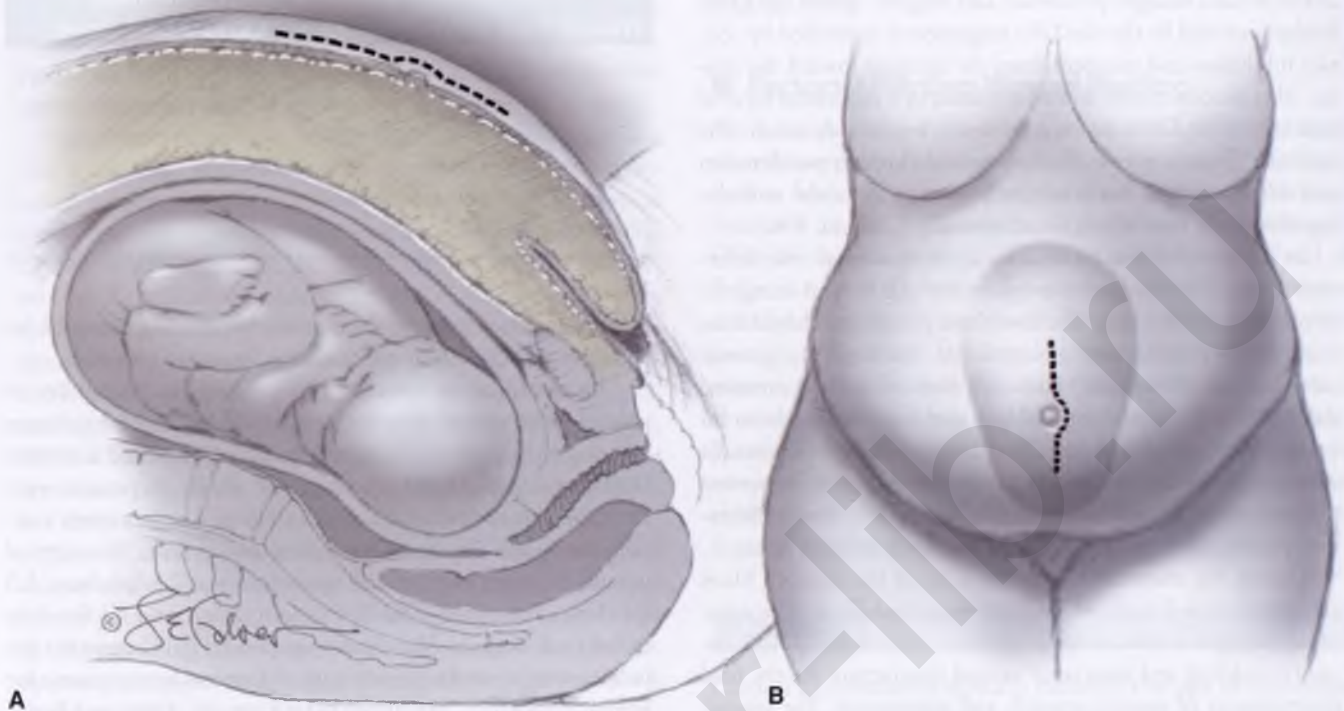


FIGURE 4-22 Incisions for obese parturients: the incision should avoid the overhanging panniculus. In these images, a periumbilical longitudinal incision is shown from sagittal (A) and coronal (B) views.

RETRACTORS

Incisions provide access to the surgical field, but surgery often depends on retractors to improve visualization. Handheld instruments are most commonly used in obstetric surgery, as they maximize viewing and are easily removed from the field during neonate delivery. Army-navy or small Richardson retractors are frequently chosen handheld instruments to hold back subcutaneous tissue while making an incision into the abdominal wall. To enhance viewing of the vesicouterine reflection of the peritoneum during bladder flap creation, a Balfour bladder blade is often selected to retract the inferior margin of the skin incision. Once the bladder flap is created, this retractor safely covers and pulls the bladder caudad while the hysterotomy incision is made. Other helpful handheld retractors include larger Richardson and Deaver retractors, which can retract the abdominal wall to allow access to the peritoneal cavity.

Several self-retaining retractors are selected for intraperitoneal surgery. Most have frames to which retracting arms are affixed. With the Balfour and O'Connor-O'Sullivan types, their frame rests atop the skin and arms retract laterally and cephalad/caudad. With the Omni and Bookwalter retractor types, their curved frame lies above the incision and is anchored to the operating table. Attached arms can then be positioned to retract laterally, cephalad/caudad, or at oblique angles.

All of these have the disadvantage of taking time to safely place and remove, which diminishes their usefulness for obstetric surgery that requires delivery. Moreover, their stiff frame

may hinder manipulation during newborn extraction. For these circumstances, one option is a disposable self-retaining retractor that uses two flexible rings attached to opposite ends of a plastic, cylindrical sheath. One ring is placed in the abdomen, the other lies outside the incision, and the intervening plastic sheath is pulled taut to retract the incision (Fig. 2-8, p. 19). Such disposable pliant retractors provide circumferential atraumatic retraction. In one study of 231 cesarean deliveries, the median insertion time was 18 seconds (Theodoridis, 2011).

WOUND HEALING

■ Physiology

Regardless of the mechanism of injury, wound healing includes four physiologic processes—*inflammation, migration, proliferation, and maturation*. The initial process of inflammation results in hemostasis through early vasoconstriction, platelet aggregation, and clot formation. The accumulation of cellular elements results in the release of histamine from mast cells, which increases vascular permeability and causes a subsequent vasodilation. The leakage of plasma and cellular elements is clinically noted as edema. These events permit margination, migration, and diapedesis of leukocytes. Due to chemotaxis, polymorphonuclear leukocytes that phagocytize bacteria and necrotic tissue predominate for the first 3 days. Subsequently, mononuclear leukocytes appear and transform into macrophages. In addition to continuing phagocytosis, they also attract fibroblasts, which

are essential to the later proliferation process of the wound (Lebovich, 1975).

The second phase of wound healing is migration. Basal cells at the wound margin proliferate and migrate across the fibrin bridge provided by the clot. The migration is controlled by contact inhibition and proceeds from the margins toward the center. This process results in the formation of a superficial layer of cells within 48 hours that is a barrier to bacterial invasion. The epithelial layer is eventually rejuvenated through proliferation and differentiation, but is relatively weak without the underlying fibroplasia that occurs simultaneously (Odland, 1968).

In the proliferation process, local mesenchymal cells differentiate into fibroblasts and migrate into the wound using the fibrin clot as scaffolding. The fibroblasts proliferate and produce mucopolysaccharides and glycoproteins that form the ground substance for fibroplasia. Within 4 days of wound creation, these cells begin producing collagen and continue to do so for up to 6 weeks. Collagen formation is responsible for the tensile strength of the wound and is ultimately the most important component of wound integrity (Howes, 1929). The proliferation process results in a disorganized array of collagen fibers.

During the maturation process, some of the collagen fibers are degraded and replaced by more organized fibers. The organized collagen fibrils undergo covalent cross-linking. This tissue remodeling and associated wound contracture are the final determinants of wound strength and appearance. The remodeling process may continue for years but never provides the original tensile strength of the native tissue.

Disruption can occur in any of these wound healing phases and depends on preexisting conditions. Importantly, the fibroblastic-proliferation phase from about day 5 through day 20 provides the most strength to the wound. Even so, by day 21, most wounds will have regained only 30 percent of their original tensile strength.

■ Wound Classification

Operative and traumatic wounds are classified according to the degree of bacterial contamination present at the time the wound is made or during the procedure. The four classifications include: (1) clean, (2) clean contaminated, (3) contaminated, and (4) dirty or infected wounds (Mangram, 1999).

A clean wound is an atraumatic, uninfected surgical incision made under aseptic conditions without entering the genitourinary, alimentary, respiratory, or oropharyngeal tract. A clean-contaminated wound refers to an atraumatic surgical incision that includes entry into the uninfected genitourinary, alimentary, respiratory, or oropharyngeal tract but without a break in aseptic technique. Many obstetric and gynecologic wounds are categorized as clean contaminated. A contaminated wound includes clean or clean-contaminated wounds compounded by major breaks in aseptic technique, by entry into an infected genitourinary tract, or by gross spillage from the alimentary tract. Fresh traumatic wounds are also in this group. Although a cesarean delivery performed in a laboring woman is best classified as a clean-contaminated wound, overt chorioamnionitis and further contamination with meconium-laden amniotic fluid increase the risk to the level of a contaminated wound. Last, dirty and

TABLE 4-3. Wound Classification and Associated Wound Infection

Wound Type	Infection Rate	Recommended Closure Technique
Clean	<5%	Primary approximation
Clean contaminated	10%	Primary approximation
Contaminated	15%	Surgeon discretion
Dirty and infected	30%	Delayed primary or secondary approximation

infected wounds refer to procedures for existing infection or abscesses and for heavily contaminated traumatic wounds.

This classification system helps predict the probability of postoperative wound infection and should influence the closure technique (Table 4-3). Using this system, Culver and associates (1991) reviewed 84,691 operations of which 58 percent were clean, 36 percent were clean contaminated, 4 percent were contaminated, and 2 percent were dirty or infected. The surgical wound infection rate per 100 operations was 2.1 for clean, 3.3 for clean contaminated, 6.4 for contaminated, and 7.1 for dirty or infected wounds. Mahdi and associates (2014) reported the incidence of wound infection with abdominal hysterectomy for benign gynecologic conditions to be 4 percent. Cruse and Foord (1980) found wound infection rates as high as 7.7 percent with clean-contaminated operations. As most operations performed in obstetrics and gynecology are clean contaminated, the surgical wound infection rate according to the literature ranges between 3.3 and 7.7 percent.

■ Wound Closure

Primary Closure

Incisions resulting in an excellent cosmetic scar are desired. To achieve this, most obstetric incisions are reapproximated by primary closure. Most data regarding laparotomy closure is derived from studies of cesarean delivery. Despite this, many conclusions regarding technique can be reasonably extrapolated to other surgeries requiring laparotomy in pregnancy.

At the procedure's end, closure of the visceral or parietal peritoneum is not required, and this practice is individualized. As each layer is closed, bleeding sites are located, clamped, and ligated or coagulated with an electrosurgical blade. The rectus abdominis muscles are allowed to fall into place. With significant diastasis, the rectus muscles may be approximated with one or two figure-of-eight sutures of 0-gauge chromic gut suture.

The overlying rectus fascia is closed by a continuous, non-locking technique with a delayed-absorbable suture. A delayed-absorbable monofilament suture material is recommended, and Chapter 1 (p. 4) contains a discussion of suture materials. In assessing the use of running versus interrupted suture in midline incisions, Fagniez and colleagues (1985) found no difference in the dehiscence rate in a randomized prospective trial of 3135 patients. Notably, however, a running suture line can typically be completed more quickly. Sutures are placed

approximately 1 cm apart and 1 to 1.5 cm from the fascial edge. Little additional security is attained beyond 1.5 cm (Campbell, 1989). Stitches ideally appose fascial edges and allow tissues to swell postoperatively without cutting through fascia or causing avascular necrosis. In patients with a higher risk for infection, there may be theoretical value to selection of a monofilament suture here rather than braided material.

The subcutaneous tissue usually need not be closed if it is less than 2 cm thick. With thicker layers, however, closure is recommended to minimize seroma and hematoma formation, which can lead to wound infection and/or disruption (Bohman, 1992; Chelmow, 2004; Dahlke, 2013; Naumann, 1995). However, two small randomized trials found that closing or not closing the subcutaneous layer did not affect either wound complications rates or cosmesis (Corbacioglu Esmer, 2014; Husslein, 2014). Routine addition of a subcutaneous drain does not prevent significant wound complications (Hellums, 2007; Ramsey, 2005). Drains may be used in the subfascial space if complete hemostasis is in doubt. These devices may be active or passive, and drain options are described in Chapter 2 (p. 24).

Skin is closed with a running subcuticular stitch using 4-0 delayed-absorbable suture or with staples. In comparison, final cosmetic results, patient pain, and infection rates appear similar. Skin suturing takes longer, but importantly wound separation rates are higher with staples (Basha, 2010; Figueroa, 2013; Mackeen, 2015; Tuuli, 2011).

Secondary Closure

However, there are occasional clinical situations when primary closure is not ideal for wound healing. These include contaminated and dirty infected wounds such as those with a ruptured appendix, intraabdominal abscess, or injury to bowel with fecal spill. In these cases, delayed primary closure may be preferable. Following fascial closure, a bridge consisting of rolls of gauze can be used to support loosely tied, interrupted 3-0 gauge monofilament polypropylene skin sutures (Menendez, 1985). These sutures usually are placed 2 cm apart using a mattress technique. Dressing sponges (4 × 8 in.) are laid in the wound deep to the sutures and are changed periodically following wound cleansing. In 5 to 7 days, the dressing gauze is removed, and the previously placed sutures are simply tied to approximate the skin edges. Steri-Strips may be used for further support.

If a wound infection develops anterior to the fascia and requires drainage, the wound is opened and traditionally is allowed to heal by secondary intention. In such cases, NWPT may be instituted to shorten healing time (Chap. 2, p. 25). Another alternative is early secondary closure, which also offers advantages over healing by secondary intention (Hermann, 1988; Walters, 1990). Dodson and colleagues (1992) have clearly shown that secondary closure can be performed under local anesthesia in a treatment-room setting.

For this, the infected wound is initially opened and debrided under local or general anesthesia. Saline-soaked gauze sponges are changed two times daily. Most wounds are ready for closure after 4 to 5 days of wound care. Ideally, they are free of necrotic tissue and appear beefy-red due to granulation tissue growth (Fig. 32-4, p. 510). After local anesthesia, no. 1 polypropylene interrupted sutures, placed 3 to 4 cm from the skin edge, are

used to reapproximate the wound and are reinforced with Steri-Strips. Still simpler is reapproximating the wound edges with an adhesive strip, which has been shown to be equally efficacious (Harris, 1996).

■ Factors Affecting Wound Healing

Any factor that inhibits the normal processes of healing can impair wound integrity. Examples include compromised vascularity such as from diabetes or prior irradiation or hindered metabolism such as with malnutrition, alcoholism, or chemotherapy. Infection impedes healing, and risks for infection are listed in Table 32-4 (p. 509). Among these are long operative times, excessive blood loss, use of open wound drains, smoking, poor glucose control, malignancy, and immunosuppression. Other risks in obstetric patients include prematurely ruptured membranes and chorioamnionitis. Obesity and older age are independent factors (Cruse, 1973, 1977; Dineen, 1961). Additional contributors to wound disruption in the absence of infection include poor suture choice, closure technique, excessive coughing, retching or vomiting, and distention from intestinal obstruction.

SUMMARY

Clinical circumstances typically influence the type of abdominal wall incision made. When speed is essential, the midline vertical incision is most advantageous. Excellent visualization of the intraabdominal structures can be obtained with a midline vertical, a Maylard, or a supraumbilical transverse incision. The best cosmetic result is achieved with the Pfannenstiel incision. In general, transverse incisions result in better healing and greater wound strength than vertical incisions. In patients at high risk for poor wound healing and dehiscence, a Smead-Jones or running mass closure is considered.

REFERENCES

- Archie JP, Feldman RW: Primary wound closure with permanent continuous running monofilament sutures. *Surg Gynecol Obstet* 153:721, 1981
- Basha SL, Rochon ML, Quiñones JN, et al: Randomized controlled trial of wound complication rates of subcuticular suture vs staples for skin closure at cesarean delivery. *Am J Obstet Gynecol* 203(3):285.e1, 2010
- Bohman VR, Gilstrap L, Leveno K, et al: Subcutaneous tissue: to close or not to close at cesarean section. *Am J Obstet Gynecol* 166:407, 1992
- Campbell JA, Temple WJ, Frank CB, et al: A biomechanical study of suture pullout in linea alba. *Surgery* 106:888, 1989
- Chelmow D, Rodriguez EJ, Sabatini MM: Suture closure of subcutaneous fat and wound disruption after cesarean delivery: a meta-analysis. *Obstet Gynecol* 103(5 Pt 1):974, 2004
- Cherney LS: A modified transverse incision for low abdominal operations. *Surg Gynecol Obstet* 72:92, 1941
- Corbacioglu Esmer A, Goksedef PC, Akca A, et al: Role of subcutaneous closure in preventing wound complications after cesarean delivery with Pfannenstiel incision: a randomized clinical trial. *J Obstet Gynaecol Res* 40(3):728, 2014
- Cruse P: Infection surveillance: identifying the problems and the high-risk patient. *South Med J* 70(Suppl 1):40, 1977
- Cruse PJ, Foord R: A five-year prospective study of 23,649 surgical wounds. *Arch Surg* 107:206, 1973
- Cruse PJ, Foord R: The epidemiology of wound infection. A 10-year prospective study of 62,939 wounds. *Surg Clin North Am* 60(1):27, 1980
- Culver DH, Horan TC, Gaynes RP, et al: Surgical wound infection rates by wound class, operative procedure, and patient risk index. National Nosocomial Infections Surveillance System. *Am J Med* 91(3B):152S, 1991

- Dahlke JD, Mendez-Figueroa H, Rouse DJ, et al: Evidence-based surgery for cesarean delivery: an updated systematic review. *Am J Obstet Gynecol* 209(4):294, 2013
- Dineen P: A critical study of 100 conservative wound infections. *Surg Gynecol Obstet* 113:91, 1961
- Dodson MK, Magann EF, Meeks GR: A randomized comparison of secondary closure and secondary intention with superficial wound dehiscence. *Obstet Gynecol* 80:321, 1992
- Fagniez P, Hay JM, Lacaine F, et al: Abdominal midline incision closure. A randomized prospective trial of 3135 patients, comparing continuous vs. interrupted polyglycolic acid sutures. *Arch Surg* 120:1351, 1985
- Farnell MB, Worthington-Self S, Mucha P Jr, et al: Closure of abdominal incisions with subcutaneous catheters. *Arch Surg* 126:641, 1986
- Figueroa D, Jauk VC, Szychowski JM, et al: Surgical staples compared with subcuticular suture for skin closure after cesarean delivery: a randomized controlled trial. *Obstet Gynecol* 121(1):33, 2013
- Gallup DG, King LA, Messing MJ, et al: Paraaortic lymph node sampling by means of an extraperitoneal approach with a supraumbilical transverse "sunrise" incision. *Am J Obstet Gynecol* 169(2 Pt 1):307, 1993
- Gallup DG, Nolan TE, Smith RP: Primary mass closure of midline incisions with a continuous polyglyconate monofilament absorbable suture. *Obstet Gynecol* 76:872, 1990
- Gallup DG, Talledo OE, King LA: Primary mass closure of midline incisions with a continuous running monofilament suture in gynecologic patients. *Obstet Gynecol* 73:67, 1989
- Greenburg G, Salk RP, Peskin GW: Wound dehiscence. Pathophysiology and prevention. *Arch Surg* 114:143, 1979
- Guillou PJ, Hall TJ, Donaldson DR, et al: Vertical abdominal incisions—a choice? *Br J Surg* 67:359, 1980
- Harris RL, Dodson MK: Surgical wound infection and management of extra-fascial wound disruption. *Postgrad Obstet Gynecol* 16:1, 1996
- Hellums EK, Lin MG, Ramsey PS: Prophylactic subcutaneous drainage for prevention of wound complications after cesarean delivery—a metaanalysis. *Am J Obstet Gynecol* 197(3):229, 2007
- Helmkamp BF: Abdominal wound dehiscence. *Am J Obstet Gynecol* 128:803, 1977
- Helmkamp BF, Krebs HB, Amstey MS: Correct use of surgical drains. *Contemp OB/GYN* 23:123, 1984
- Hermann GG, Pagi P, Christofferson I: Early secondary suture versus healing by second intention of incisional abscesses. *Surg Gynecol Obstet* 167:16, 1988
- Hoffman BL, Corton MM: Surgeries for benign gynecologic conditions. In Hoffman BL, Schorge JO, Bradshaw KD, et al (eds): *Williams Gynecology*, 3rd ed. New York, McGraw-Hill Education, 2016
- Howes EL, Sooy JW, Harvey SC: The healing of wounds as determined by their tensile strength. *JAMA* 92:242, 1929
- Husslein H, Gutsch M, Leipold H, et al: Suture closure versus non-closure of subcutaneous fat and cosmetic outcome after cesarean section: a randomized controlled trial. *PLoS One* 9(12):e114730, 2014
- Knight CD, Griffen FD: Abdominal wound closure with a continuous monofilament polypropylene suture. *Arch Surg* 118:1305, 1983
- Lebovich SJ, Ross R: The role of the macrophage in wound repair. *Am J Pathol* 78:71, 1975
- Mackeen AD, Schuster M, Berghella V: Suture versus staples for skin closure after cesarean: a metaanalysis. *Am J Obstet Gynecol* 212:621.e1, 2015
- Mahdi H, Goodrich S, Lockhart D, et al: Predictors of surgical site infection in women undergoing hysterectomy for benign gynecologic disease: a multicenter analysis using the national surgical quality improvement program data. *J Minim Invasive Gynecol* 21(5):901, 2014
- Mangram AJ, Horan TC, Pearson ML, et al: Guideline for Prevention of Surgical Site Infection, 1999. Centers for Disease Control and Prevention (CDC) Hospital Infection Control Practices Advisory Committee. *Am J Infect Control* 27(2):97, 1999
- Maylard AE: Direction of abdominal incision. *Br Med J* 2:895, 1907
- Menendez MA: The contaminated closure. In: O'Leary JP, Woltering EA (eds): *Techniques for Surgeons*. New York, John Wiley & Sons, 1985, p 36
- Morrow CP, Hernandez WL, Townsend DE, et al: Pelvic celiotomy in the obese patient. *Am J Obstet Gynecol* 127:335, 1977
- Mowat J, Bonnar J: Abdominal wound dehiscence after cesarean section. *Br Med J* 2:256, 1971
- Murray DH, Blaisdell FW: Use of synthetic absorbable sutures for abdominal and chest closures. *Arch Surg* 113:477, 1978
- Naumann RW, Hauth JC, Owen J, et al: Subcutaneous tissue approximation in relation to wound disruption after cesarean delivery in obese women. *Obstet Gynecol* 85:412, 1995
- Odland G, Ross R: Human wound repair. I. Epidermal regeneration. *J Cell Biol* 39:135, 1968
- Parson L, Ulfelder H: *Atlas of Pelvic Surgery*, 2nd ed. Philadelphia, Saunders, 1968, p 156
- Rahn DD, Phelan JN, Roshanravan SM, et al: Anterior abdominal wall nerve and vessel anatomy: clinical implications for gynecologic surgery. *Am J Obstet Gynecol* 202(3):234.e1, 2010
- Ramsey PS, White AM, Guinn DA, et al: Subcutaneous tissue reapproximation, alone or in combination with drain, in obese women undergoing cesarean delivery. *Obstet Gynecol* 105(5 Pt 1):967, 2005
- Rees VL, Collier FA: Anatomic and clinical study of the transverse abdominal incision. *Arch Surg* 47:137, 1943
- Shepherd JH, Cavanagh D, Riggs D, et al: Abdominal wound closure using a nonabsorbable single layer technique. *Obstet Gynecol* 61:248, 1983
- Theodoridis TD, Charzigeorgiou KN, Zepiridis L, et al: A prospective randomized study for evaluation of wound retractors in the prevention of incision site infections after cesarean section. *Clin Exp Obstet Gynecol* 38(1):57, 2011
- Thompson JB, Maclean KF, Collier FA: Role of the transverse abdominal incision and early ambulation in the reduction of postoperative complications. *Arch Surg* 59:1267, 1949
- Tixier H, Thouvenot S, Coulange L, et al: Cesarean section in morbidly obese women: supra or subumbilical transverse incision? *Acta Obstet Gynecol Scand* 88(9):1049, 2009
- Tollefson DG, Russell KP: The transverse incision in pelvic surgery. *Am J Obstet Gynecol* 68:410, 1954
- Tuffaha HW, Gillespie BM, Chaboyer W, et al: Cost-utility analysis of negative pressure wound therapy in high-risk cesarean section wounds. *J Surg Res* 195(2):612, 2015
- Tuuli MG, Rampersad RM, Carbone JF, et al: Staples compared with subcuticular suture for skin closure after cesarean delivery: a systematic review and meta-analysis. *Obstet Gynecol* 117:682, 2011
- Wallace D, Hernandez W, Schlaerth JB, et al: Prevention of abdominal wound disruption utilizing the Smead-Jones closure technique. *Obstet Gynecol* 56:226, 1980
- Walters MD, Dombroski RA, Davidson SA, et al: Reclosure of disrupted abdominal incisions. *Obstet Gynecol* 76:597, 1990
- Whiteside JL, Barber MD, Walters MD, et al: Anatomy of ilioinguinal and iliohypogastric nerves in relation to trocar placement and low transverse incisions. *Am J Obstet Gynecol* 189(6):1574, 2003

CHAPTER 5

Perioperative Imaging

IMAGING TECHNIQUES	63
SONOGRAPHY	63
IONIZING RADIATION	68
DIAGNOSTIC RADIATION	71
MAGNETIC RESONANCE IMAGING	74
DIAGNOSTIC IMAGING DURING PREGNANCY	79

IMAGING TECHNIQUES

Imaging modalities that are used as adjuncts for diagnosis and therapy during pregnancy include sonography, radiography, and magnetic resonance (MR) imaging. Given rapid changes in imaging technology, this chapter is not exhaustive but serves as a guide for imaging obstetric patients with perioperative needs. The focus is on safety, especially with regard to radiation exposure. Thus, detailed dosimetry is provided to help direct examination selection and patient counseling.

SONOGRAPHY

■ Safety

Of all the major advances in obstetrics, the development of sonography for study of both fetus and mother certainly is one of the greater achievements. The technique has become virtually indispensable in everyday practice (Figs. 5-1 through 5-3).

Diagnostic sonography uses sound wave transmission at certain frequencies. Recall that ultrasound is a form of nonionizing radiation that transmits energy. Studies involving prolonged

ultrasound exposure of animal fetuses suggest that it is possible to induce cellular alterations. For example, with at least 30 minutes of ultrasound exposure to embryonic mouse neurons, a statistically significant number of neurons were impeded from their expected migration (Ang, 2007). At this time, however, the American Institute of Ultrasound in Medicine (2010) and other organizations agree that these findings should not alter the use of ultrasound in pregnant women. Moreover, Naumburg and associates (2000) performed a case-control study of 578 children with leukemia compared with healthy controls. In each cohort, an equal number of the children had been exposed to ultrasound in utero, which implies that sonography did not induce the cancer.

Advances in technology have introduced Doppler-shift imaging coupled with gray-scale imaging to localize spectral waveforms and superimpose color mapping (Fig. 5-4). Higher energy intensities are used with this duplex Doppler imaging. Again, however, these should have no embryo or fetal effects if low-level pulses are used (Kossoff, 1997). Even so, at *very high* intensities of ultrasound, there is a *potential* for tissue damage from heat and cavitation (Callen, 2000). However, with the low-intensity range used during real-time imaging, no fetal risks have been demonstrated in more than 35 years of use (Maulik, 1997; Miller, 1998).

Ultrasound equipment must have a video display of acoustic output to safeguard against exceeding standards set by several organizations including the American College of Obstetricians and Gynecologists (2014). Acoustic outputs are displayed as an index. The *thermal index (TI)* is an estimate of temperature increases from acoustic output. If the index is below 1.0, then no potential risk is expected (Miller, 1998). Adverse effects reflected in thermal index changes have not been demonstrated with Doppler use in clinical applications (Maulik, 1997). The *mechanical index (MI)* is used to estimate the potential risk of cavitation from heat generated by real-time imaging. As long as sonographic contrast agents are not used, there is no hypothetical fetal risk of cavitation.

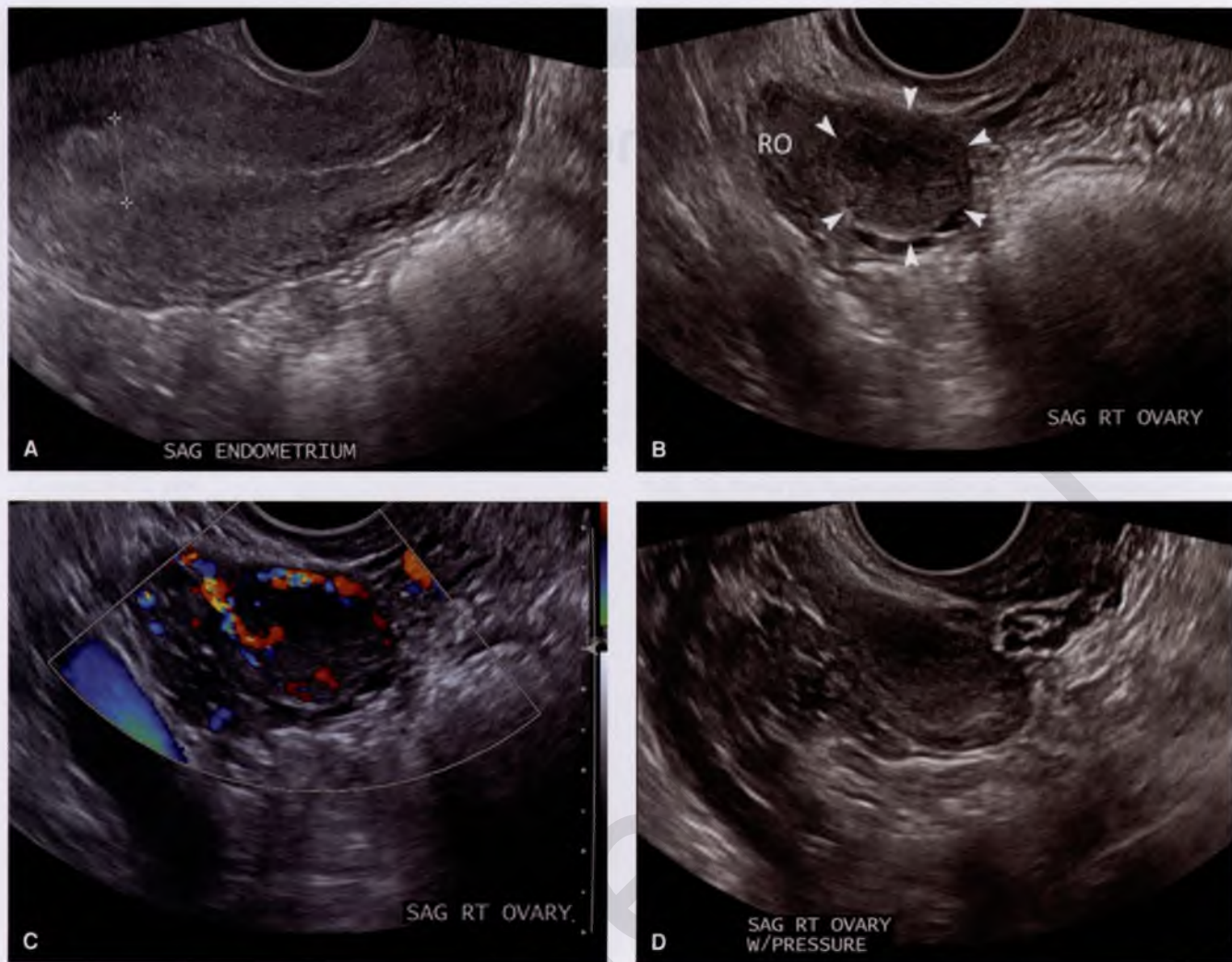


FIGURE 5-1 A 22-year-old gravida at 9 weeks' gestation. **A.** Transvaginal sonography in a sagittal view demonstrates mild inhomogeneity of the endometrium and no gestational sac. **B.** With evaluation of the adnexa, a normal appearing right ovary (RO) is noted and contains a corpus luteum cyst (*arrowheads*). **C.** With color Doppler imaging, characteristic peripheral vascularity, often called a "ring of fire," is seen. **D.** With gentle pressure from the transducer, the intraovarian position of the corpus luteum cyst is documented.

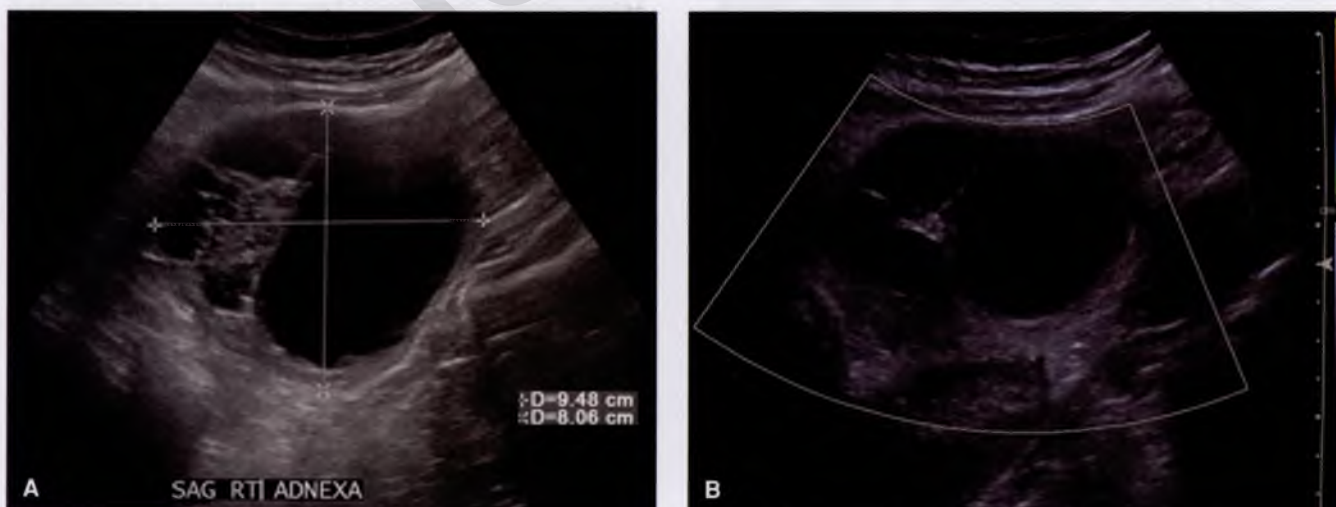


FIGURE 5-2 A 23-year-old gravida at 12 weeks' gestation complained of lower abdominal pain. **A.** Transabdominal sonography in a sagittal view shows an enlarged right ovary containing a multiseptate cyst (*calipers*). **B.** Color Doppler images demonstrate minimal vascularity within the right ovary. Importantly, absent vascular flow within an ovary is not necessary for the diagnosis of torsion. Given her compelling symptoms, diagnostic laparoscopy was performed, adnexal torsion was identified, and a right salpingo-oophorectomy was completed. Histologic evaluation revealed an ovarian serous cystadenoma.

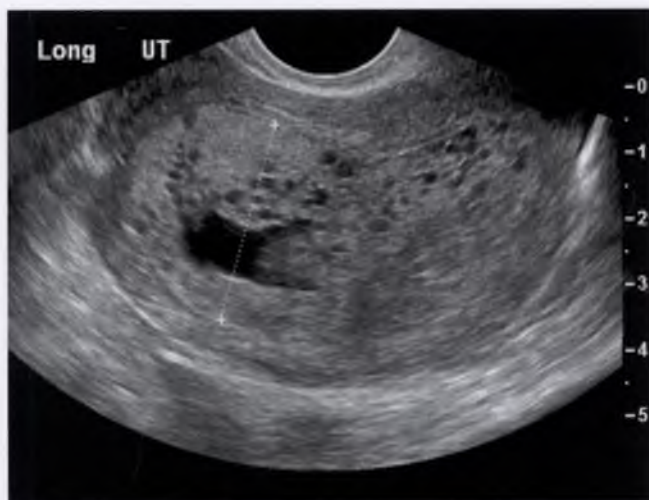
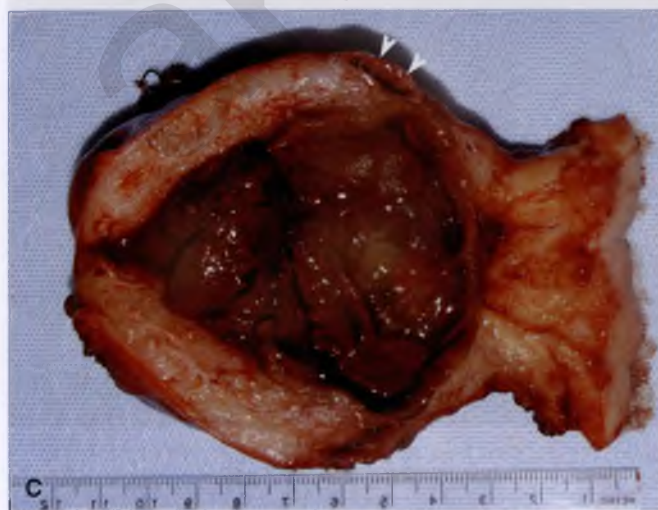
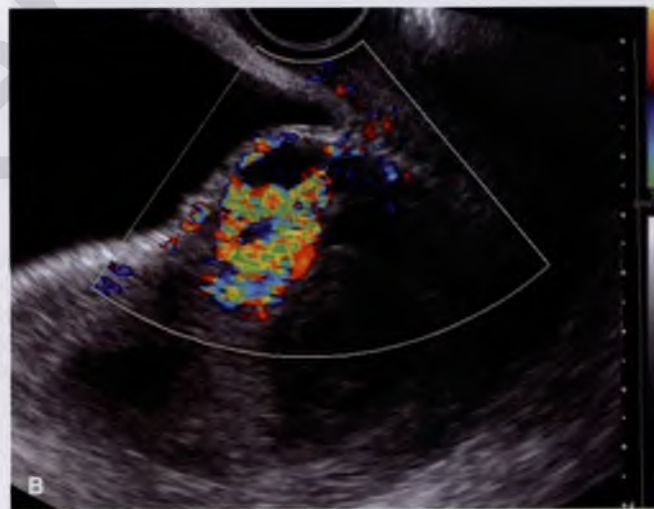
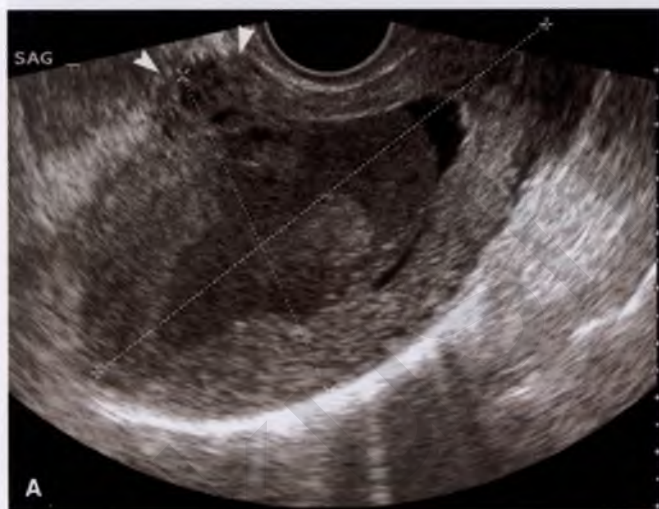

FIGURE 5-3 A 27-year-old gravida at 15 weeks' gestation complained of vaginal bleeding. This longitudinal image taken during transvaginal sonography shows cystic and solid heterogeneous tissue filling the endometrial cavity (*calipers*), and no fetal parts are identified. A complete hydatidiform mole was diagnosed histologically from a dilation and curettage specimen.



■ Maternal Evaluation

Ultrasound is often the initial tool in maternal evaluation given its lack of ionizing radiation, low cost, and widespread availability. In the chest, echocardiography is a sonographic tool used to assess cardiac hemodynamic function and to evaluate cardiac morphology and its adjacent structures such as the pericardium.

In the abdomen, common indications for solid organ evaluation include abdominal and flank pain (Figs. 5-5 and 5-6), jaundice, hematuria, organomegaly, or palpable mass. Abnormal blood test results, including elevated liver function tests and creatinine levels, may also be indications for abdominal ultrasound. Typically, a limited or right upper quadrant ultrasound includes the liver, gallbladder, common bile duct, pancreas, and right kidney (Fig. 5-7). A complete abdominal ultrasound also interrogates the spleen, left kidney, and upper-abdominal portions of the aorta and inferior vena cava. Ideally, a patient has fasted prior to sonographic evaluation of the abdomen to minimize bowel gas and for adequate gallbladder distention (American Institute of Ultrasound in Medicine, 2012). A renal ultrasound focuses on the kidneys, proximal collecting systems, and urinary bladder.

Outside the abdomen and pelvis, an obstetrician may select ultrasound to evaluate superficial structures, like the thyroid

FIGURE 5-4 A 37-year-old gravida with two prior cesarean deliveries complained of bleeding, and her pregnancy test was positive. **A.** Longitudinal transvaginal sonographic view of the uterus demonstrates heterogeneous tissue and blood clot filling the cavity and focal bulging (*arrowheads*) in the region of the cesarean scar. **B.** Further evaluation of the cesarean scar with color Doppler demonstrates significant vascularity with turbulent flow within the scar and adjacent myometrium. **C.** She had completed childbearing, and hysterectomy was planned. With specimen examination, a failed intrauterine pregnancy and clot filling the uterus were noted. Gross (*arrowheads*) and histologic analysis showed an arteriovenous malformation at the prior cesarean scar site.

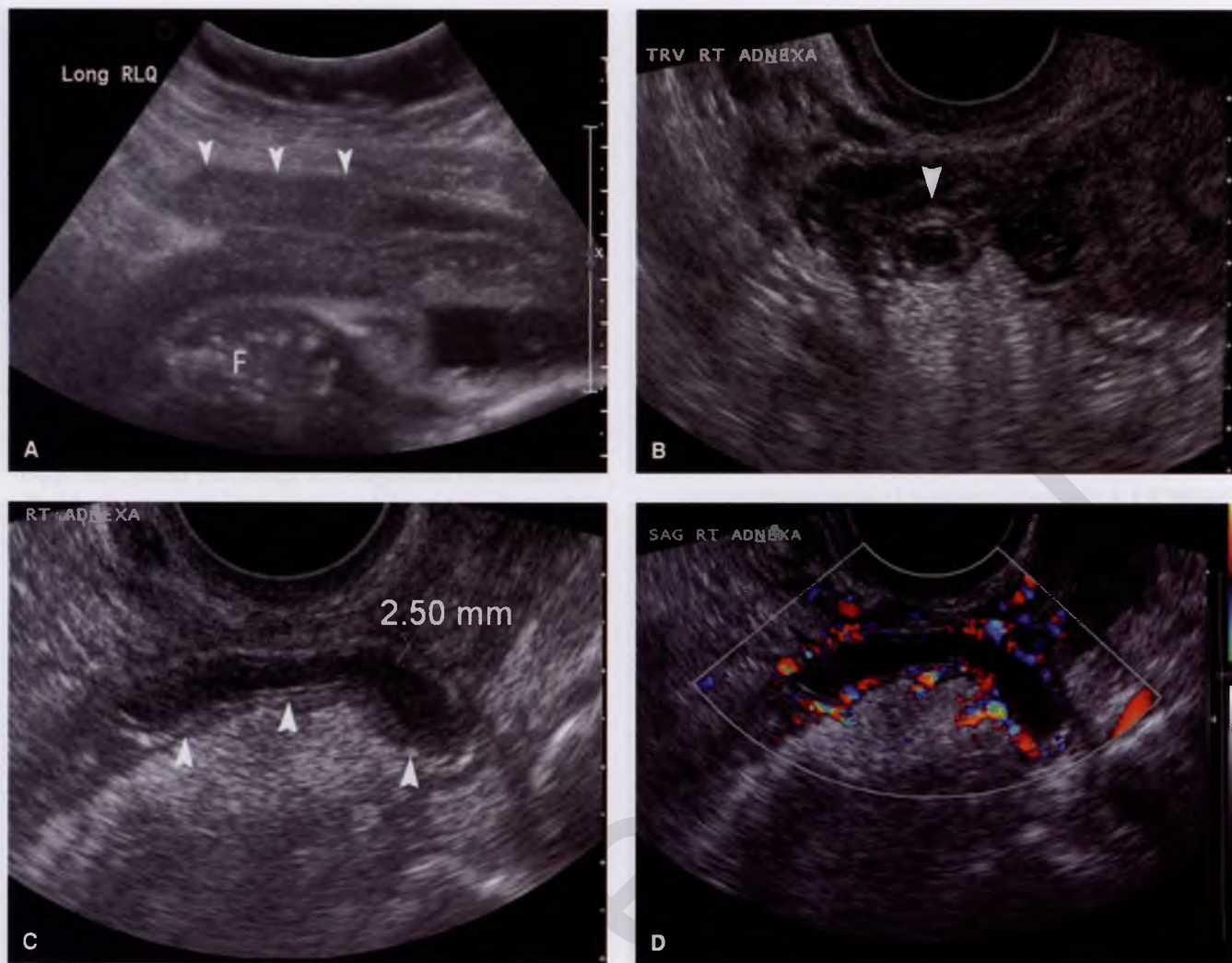


FIGURE 5-5 A 31-year-old gravida at 31 weeks' gestation complained of 6 days of right lower quadrant pain. **A.** A curvilinear sonography probe with lower frequency is used to evaluate deeper structures transabdominally. The relationship of the dilated appendix (*arrowheads*) to the uterus and fetus (*F*) is shown. In a different patient, gray-scale transverse (**B**) and longitudinal (**C**) images of the right adnexum demonstrate a dilated tubular structure (*arrowheads*). The cylinder appears blind-ending and exhibits a bowel signature, that is, alternating echogenic and hypoechoic layers in the wall. Findings suggest a dilated appendix. **D.** With color Doppler, the wall appeared hypervascular, further supporting the diagnosis of acute appendicitis.

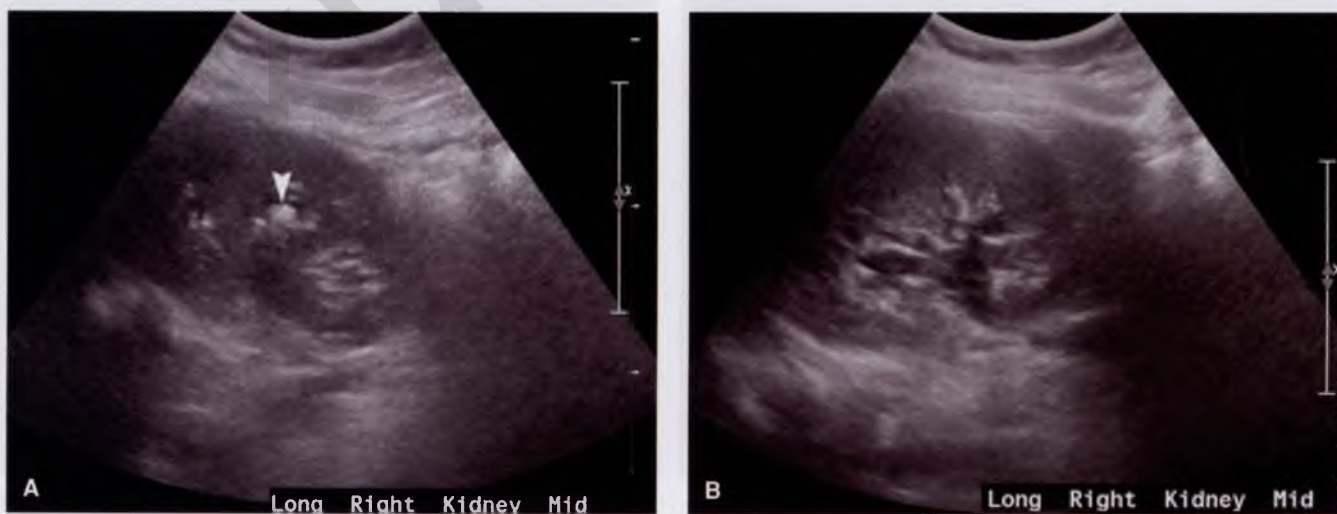


FIGURE 5-6 A 29-year-old gravida with a first-trimester pregnancy complains of right flank pain. **A.** Longitudinal gray-scale sonographic image of the right kidney shows an echogenic shadowing stone (*arrowhead*) in the collecting system. **B.** Anechoic dilated tubular structures are seen at the renal hilum.

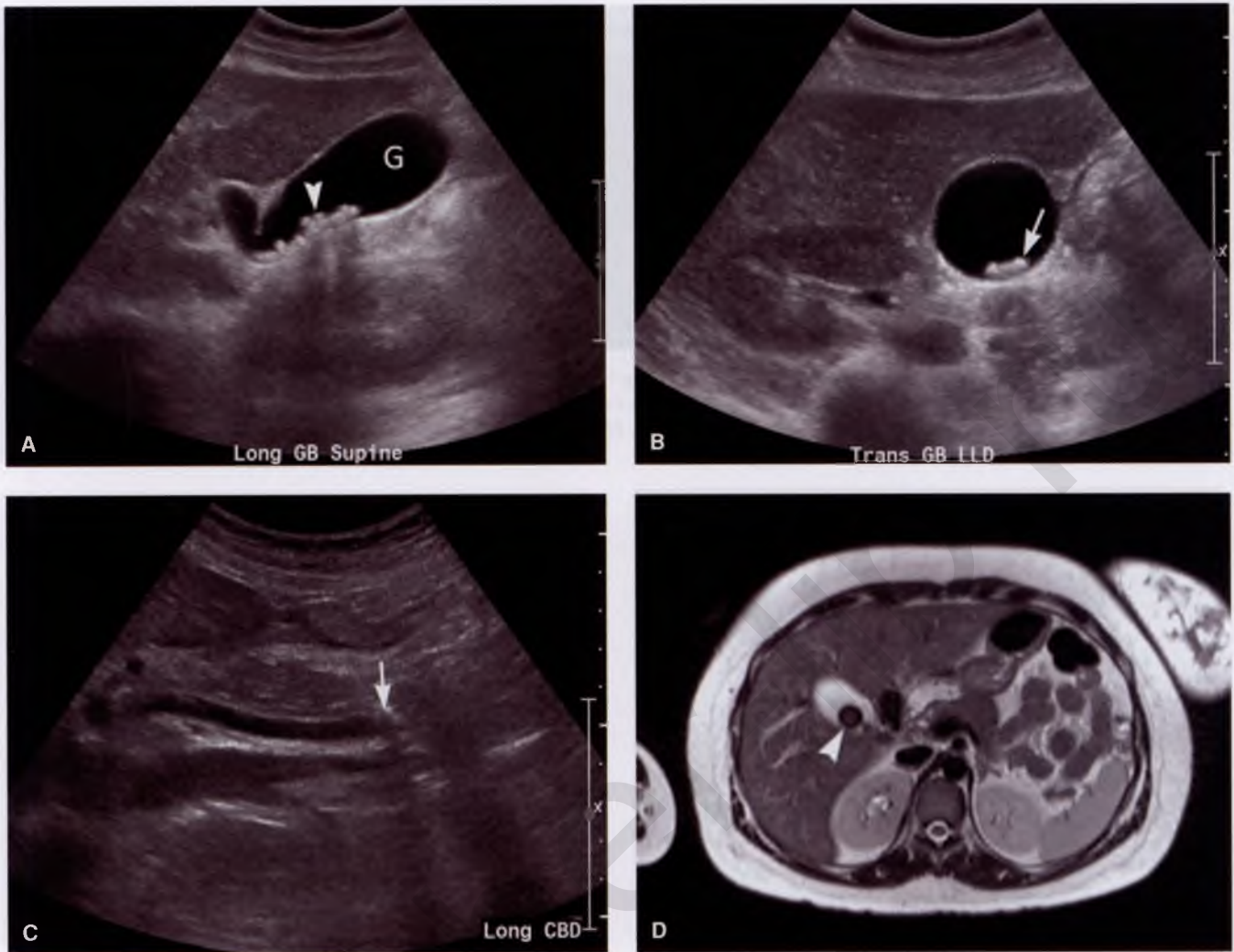


FIGURE 5-7 A 25-year-old primipara who is 14 days postpartum complains of right upper quadrant abdominal pain. **A.** Longitudinal gray-scale sonographic image of the gallbladder (G). There are multiple small shadowing stones (arrowhead). **B.** A transverse image shows a round, tense gallbladder and stones (arrow). **C.** Longitudinal image of the common bile duct demonstrates a prominent transverse diameter but also a shadowing stone (arrow) in the distal duct consistent with choledocholithiasis. **D.** Axial T2-weighted magnetic resonance image of the upper abdomen in a different third-trimester patient shows the focal signal loss of an incidentally detected gallstone (arrowhead).

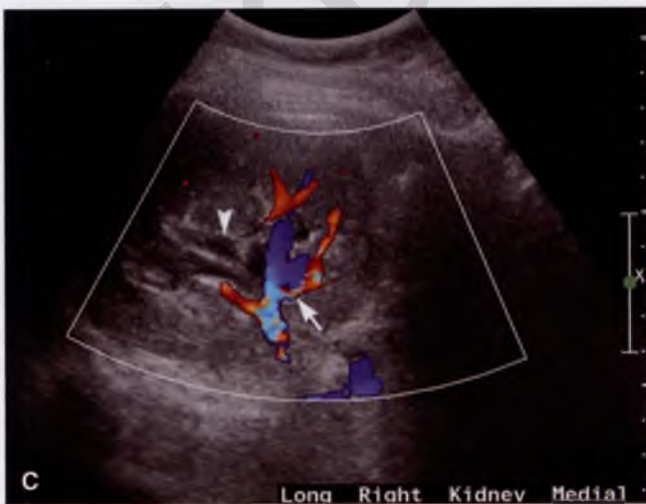

FIGURE 5-6 (Continued) **C.** Application of color Doppler shows a mildly dilated collecting system (arrowhead) in addition to hilar vessels (short arrow).

gland (Figs. 5-8 and 5-9) and breasts (Fig. 32-1B, p. 504). To detect deep-vein thrombosis (DVT), compression sonography, often combined with color Doppler sonography, is the initial test currently used (Fig. 32-13, p. 518). Vascular ultrasound incorporates spectral and color Doppler to assess solid organ and peripheral vasculature. However, with a pregnant uterus, structures normally visible for sonographic evaluation may become less so, such as the abdominal aorta, pancreas, and adnexa.

In the setting of trauma, a *FAST examination*—Focused Assessment with Sonography for Trauma—may be performed to look for pathologic pericardial or intraperitoneal free fluid acutely during resuscitation. Excessive abdominal fluid (blood) can be seen in the perihepatic space (Morison pouch); the perisplenic space; and the pelvis (anterior or posterior cul-de-sacs) (Fig. 17-10, p. 287). In the setting of pregnancy, ultrasound is less sensitive (61 percent) for intraabdominal injury than in nonpregnant individuals (71 percent). Nonetheless, it remains 94-percent specific for detecting injury in pregnancy with an accuracy of 92 percent (Richards, 2004).

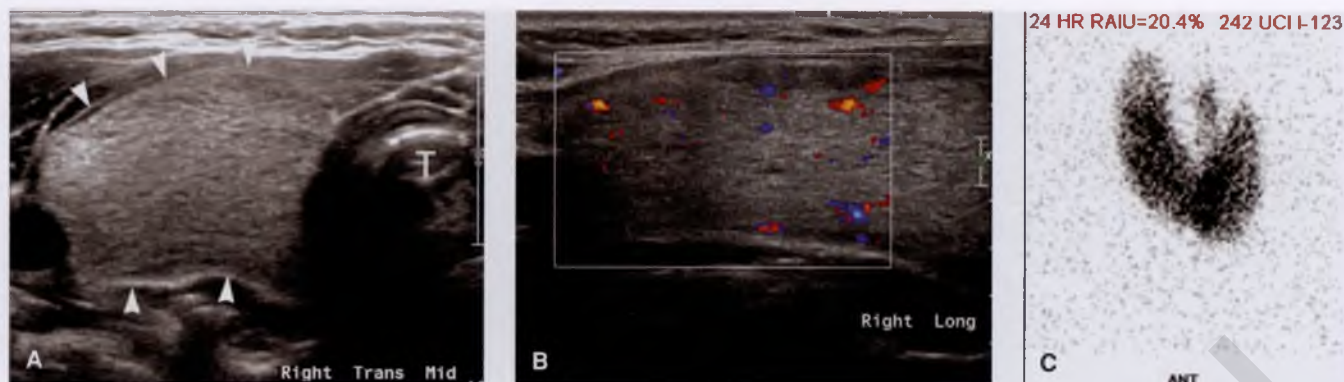


FIGURE 5-8 A 31-year-old gravida at 36 weeks' gestation is noted to have thyromegaly. **A.** Transverse sonographic images demonstrate a diffusely enlarged thyroid gland (*arrowheads*) with tiny cystic spaces throughout. T = trachea. **B.** Longitudinal image demonstrates normal vascularity with color Doppler, which suggests against thyroiditis. **C.** After delivery, a radioiodine uptake study demonstrated a normal uptake of 20.4 percent. Findings are consistent with a goiter.

The fetus and placenta are also evaluated sonographically with maternal trauma. Fetal biophysical assessment is done, and the placenta is examined for a retroplacental hematoma, that is, abruption (Fig. 5-10).

IONIZING RADIATION

Inevitably, some radiographic procedures are performed prior to recognition of early pregnancy, usually because of trauma or serious illness (Fig. 5-11). Fortunately, most diagnostic imaging procedures that use ionizing radiation are associated with minimal fetal risks. However, these procedures may lead to litigation if there is an adverse pregnancy outcome. In addition, perceptions related to medical procedures that are associated with radiation exposure may lead to a needless therapeutic abortion because of patient or physician anxiety.

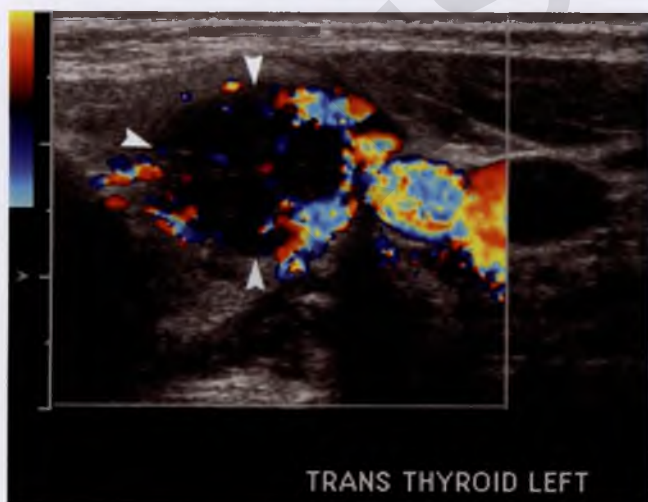


FIGURE 5-9 A 23-year-old gravida in the first trimester with a palpable left neck mass and history of multiple endocrine neoplasia type 2 (MEN2) syndrome. Transverse image of the left lobe of the thyroid demonstrates a solid hypoechoic mass (*arrowheads*) with internal vascularity on color Doppler evaluation. Histologic analysis following resection demonstrated medullary thyroid carcinoma.

In 2007, the American College of Radiology began to address the growing concern of radiation doses in medicine for all patients, whether pregnant or not. One stated goal was to limit radiation exposure in any given patient through safety practices and lifelong accumulated records of exposures (Amis, 2007). Recommendations of the College task force include additional considerations for special radiosensitive populations, such as children and pregnant and potentially pregnant women. It is also suggested that the College encourage radiology groups to record all ionizing radiation times and exposures, compare them with benchmarks, and evaluate outliers as part of ongoing quality assurance programs. Currently at our institution, special recommendations are made for pregnant women. Thus, radiation exposure is recorded in high-exposure areas such as computed tomography and fluoroscopy units, with quality assurance mechanisms in place to monitor findings.

The term *radiation* is poorly understood. Literally, it refers to transmission of energy. Thus, it is often applied not only to x-rays, but also to microwaves, ultrasound, diathermy, and radio waves. Of these, x-rays and gamma rays have short wavelengths with very high energy and are forms of *ionizing radiation*. The other four energy forms have rather long wavelengths and low energy (Brent, 1999b, 2009).

Ionizing radiation refers to waves or particles—*photons*—of significant energy that can change the structure of molecules such as those in DNA or that can create free radicals or ions capable of causing tissue damage (Hall, 1991; National Research Council, 1990). Methods of measuring the effects of x-rays are summarized in Table 5-1. The standard terms used are *exposure* (in air), *dose* (to tissue), and *relative effective dose* (to tissue). In the range of energies for diagnostic x-rays, the dose is now expressed in grays (Gy), and the relative effective dose is now expressed in sieverts (Sv). These can be used interchangeably. For consistency, all doses discussed subsequently are expressed in units of gray (1 Gy = 100 rad) or sievert (1 Sv = 100 rem). To convert, 1 Sv = 100 rem = 100 rad.

The biological effects of x-rays are caused by an electrochemical reaction that can cause tissue damage. According to Brent (1999a, 2009), x-rays and gamma radiation at high doses can create biological effects and reproductive risks in the fetus. Of

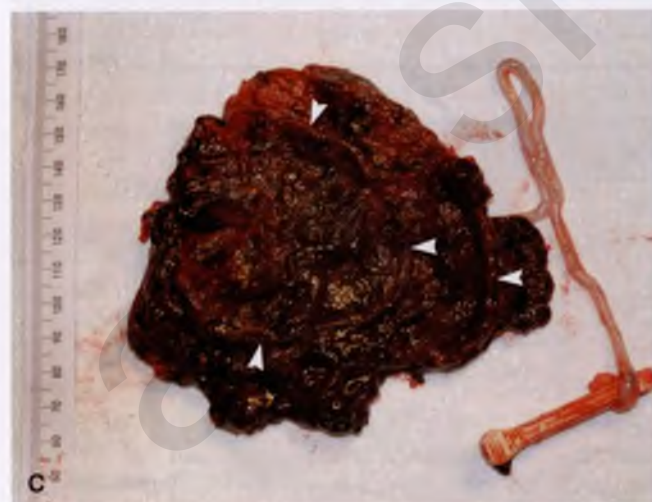
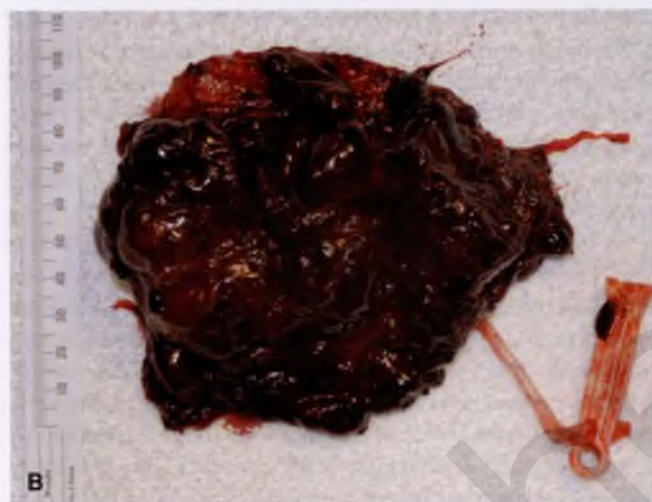
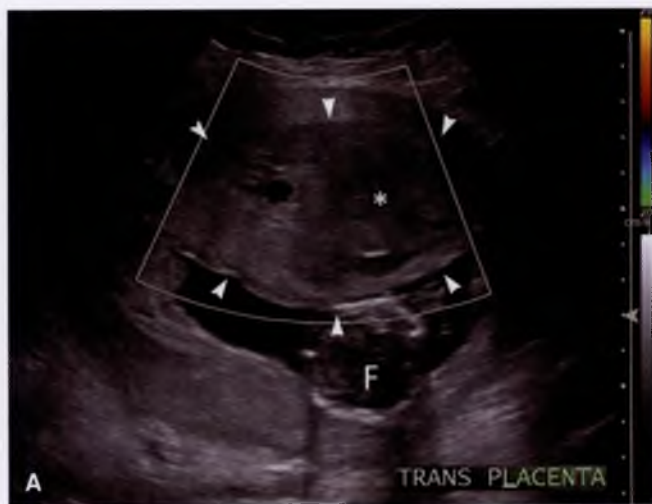FIGURE 5-10 A 17-week gestation with placental abruption. **A.** Transabdominal sonography demonstrates an intrauterine pregnancy (F) and a placenta measuring >5 cm (arrowheads). A focal, heterogeneous hypoechoic area was identified within the placenta (asterisk). No active vascular flow was identified within this area during color Doppler evaluation. Spontaneous labor and delivery ensued. **B.** Most of the placenta's basal plate was covered with clot. **C.** After clot is removed, the depression in the placenta made by the clot can be seen. Arrows mark the concentric crater rims of the depressions.

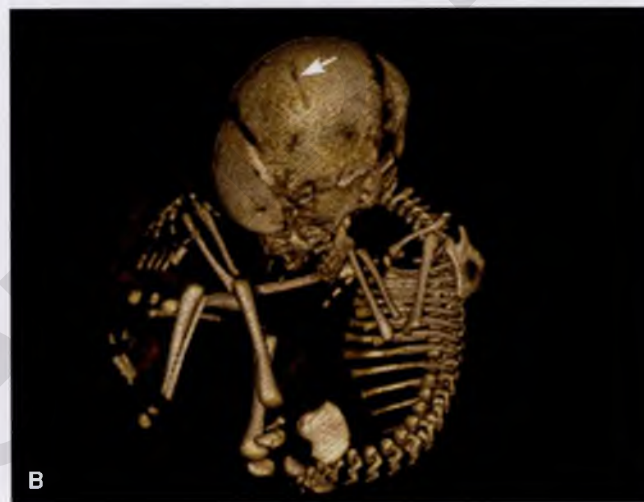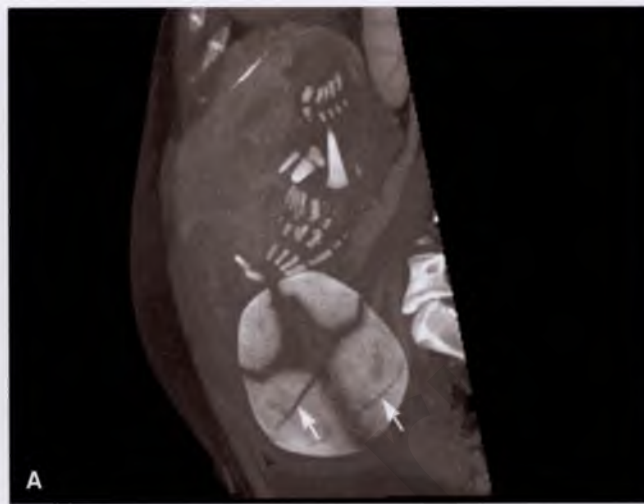


FIGURE 5-11 This gravida in her third trimester was involved in a high-speed motor vehicle accident (MVA). **A.** Maximum intensity projection image of the fetal skull acquired for maternal indications. The fetal skull fractures (arrows) are readily identified. **B.** 3-D reformatted computed tomography image in a bone algorithm demonstrates the fetal skeleton from data acquired during the maternal examination. Again, the arrow marks one fracture site. (Used with permission from Dr. Travis Browning.)

these actions, *deterministic effects* suggest that there is a threshold below which there is no risk of malformations, growth restriction, or abortions. This threshold is estimated to be less than 0.05 Gy (5 rad). That said, the true threshold for gross fetal malformations is more likely to be >0.2 Gy (20 rad), and the

TABLE 5-1. Measures of Ionizing Radiation

Exposure	The number of ions produced by x-rays per kg of air. Unit: roentgen (R)
Dose	The amount of energy deposited per kg of tissue. Modern unit: gray (Gy) (1 Gy = 100 rad). Traditional unit: rad
Relative effective dose	The amount of energy deposited per kg of tissue normalized for biological effectiveness. Modern unit: sievert (Sv) (1 Sv = 100 rem). Traditional unit: rem

lower estimation is used to provide a reasonable margin of safety (Brent, 2009). A second effect, radiation's *stochastic effect*, suggests that damage to a single cell may cause randomly determined probabilities of genetic diseases and carcinogenesis. In this theory, the cancer risk in radiated tissue is increased, even at very low doses.

An excellent review of ionizing radiation exposure during pregnancy was performed in exposed persons associated with the Fukushima nuclear plant disaster (Groen, 2012). This study reinforced the concept that high-level exposure is unlikely to occur with diagnostic procedures but that considerations should be made during pregnancy.

■ X-ray Dosimetry

According to Wagner (1997), when calculating the dose of ionizing radiation from medical imaging, several factors are considered: (1) type of study, (2) type and age of equipment, (3) distance of the target organ from the radiation source, (4) thickness of the body part penetrated, and (5) method or technique used for the study.

Estimates of the dose to the uterus and embryo for various commonly used radiographic examinations are summarized in Table 5-2. Studies of maternal body parts farthest from the uterus, such as the head, result in a very small dose of radiation scatter to the embryo or fetus. Notably, the size of the woman, radiographic technique, and equipment performance are variable factors. Thus, data in the table serve only as a guide. When calculation of the radiation dose for a specific individual is required, a medical physicist should be consulted. In his most recent review, Brent (2009) recommends consulting the Health Physics Society website at www.hps.org to view some examples of questions and

answers posed by patients exposed to radiation in the “ask the expert” section.

■ Deterministic Effects of Ionizing Radiation

As discussed, one potential harmful effect of radiation exposure is deterministic, which may result in abortion, growth restriction, congenital malformations, microcephaly, or mental retardation. These deterministic effects are threshold effects, and the level below which they are not induced is the *NOAEL*—the *no-adverse-effect level* (Brent, 2009).

The harmful deterministic effects of ionizing radiation have been extensively studied to identify cell damage that leads to embryo dysgenesis. These have been assessed in animal models. Human data stem from Japanese atomic bomb survivors and the Oxford Survey of Childhood Cancers (Sorahan, 1995). Additional sources have confirmed previous observations and provide more information. One is the 2003 International Commission on Radiological Protection (ICRP) publication of the biologic fetal effects from prenatal irradiation (Streffer, 2003). Another is the BEIR VII Phase 2 report of the National Research Council (2006) that discusses health risks from exposure to low levels of ionizing radiation.

Animal Studies

In the mouse model, the risk of lethality is highest during the preimplantation period, namely, up to 10 days postconception (Hall, 1991). This is likely due to blastomere destruction caused by chromosomal damage. The NOAEL for lethality is 0.15 to 0.2 Gy. In some mouse models, genomic instability can be induced at levels of 0.5 Gy (50 rad), which greatly exceeds levels from diagnostic studies (Streffer, 2003).

TABLE 5-2. Dose to the Uterus for Common Radiologic Procedures

Study	View	Dose ^a /View (mGy)	Films/Study ^b (No.)	Dose/Study (mGy)
Skull ^c	AP, PA Lat	<0.0001	4.1	<0.0005
Chest	AP, PA ^c , Lat ^d	<0.0001–0.0008	1.5	0.0002–0.0007
Mammogram ^d	CC, Lat	<0.0003–0.0005	4.0	0.0007–0.002
Lumbosacral spine ^e	AP, Lat	1.14–2.2	3.4	1.76–3.6
Abdomen ^e	AP		1.0	0.8–1.63
IVP ^e	3 views		5.5	6.9–14
Hip ^b (single)	AP	0.7–1.4	2.0	1–2
	Lat	0.18–0.51		

^aCalculated for x-ray beams with half-value layers ranging from 2 to 4 mm aluminum equivalent using the methodology of Rosenstein, 1988.

^bBased on data and methods reported by Laws, 1978.

^cEntrance exposure data from Conway, 1989.

^dEstimates based on compilation of above data.

^eBased on NEXT data reported in National Council on Radiation Protection and Measurements, 1989.

AP = anterior-posterior; CC = cranial-caudal; IVP = intravenous pyelogram; Lat = lateral; PA = posterior-anterior.

Modified from Cunningham, 2014.

During organogenesis in the mouse, high-dose radiation—1 Gy or 100 rad—is more likely to cause malformations and growth restriction and less likely to have lethal effects. Studies of brain development suggest that radiation affects neuronal development. Specifically, a “window of cortical sensitivity” is purported to exist in early and midfetal periods, and critical thresholds range from 0.1 to 0.3 Gy or 10 to 30 rad (Streffler, 2003).

Human Data

Adverse human effects of high-dose ionizing radiation are most often quoted from atomic bomb survivors from Hiroshima and Nagasaki (Greskovich, 2000; Otake, 1987). The International Commission on Radiological Protection confirmed initial studies showing that the increased risk of severe mental retardation was greatest between 8 and 15 weeks' gestation (Streffler, 2003). During this time, there may be a lower threshold dose of 0.3 Gy, that is, a range or “window of cortical sensitivity” similar to that in the mouse model discussed in the last section. The mean decrease in intelligence quotient (IQ) scores in humans exposed was 25 points per Gy. There appears to be a linear dose response, but it is not clear whether there is a threshold dose. Most estimates err on the conservative side by assuming a *linear no-threshold (LNT)* hypothesis. From their review, Strzelczyk and associates (2007) conclude that limitations of epidemiologic studies at exposures less than 0.1 Gy along with recent radiobiologic findings challenge the hypothesis that low-level radiation exposure causes adverse effects.

Finally, an increased risk of mental retardation in humans <8 weeks or >25 weeks' gestation, even with doses exceeding 0.5 Gy or 50 rad, has not been documented (Committee on Biological Effects, BEIR V, 1990; Streffer, 2003). There are reports that describe high-dose radiation given to treat women for malignancy, heavy menstrual bleeding, and uterine myomas. In one, Dekaban (1968) described 22 infants with microcephaly, mental retardation, or both, following exposure in the first half of pregnancy to an estimated 2.5 Gy or 250 rad. Malformations in other organs were not found unless they were accompanied by microcephaly, eye abnormalities, or growth restriction (Brent, 1999b).

The implications of these findings seem straightforward. From 8 to 15 weeks, the embryo is most susceptible to radiation-induced mental retardation. It has not been resolved whether there is a threshold dose at which abnormalities occur or if a no-threshold linear model is more accurate. The Committee on Biological Effects (1990) estimates the risk of severe mental retardation to be as low as 4 percent for 0.1 Gy (10 rad) and as high as 60 percent for 1.5 Gy (150 rad). But recall that these doses are 2 to 100 times higher than those from diagnostic radiation. Importantly, *cumulative doses from multiple procedures* may reach the harmful range, especially at 8 to 15 weeks' gestation. At 16 to 25 weeks, the risk is less. And again, there is no proven risk before 8 weeks or after 25 weeks.

Embryofetal risks from low-dose diagnostic radiation appear to be minimal. Current evidence suggests that there are no increased risks for malformations, growth restriction, or abortion from a radiation dose of <0.05 Gy (5 rad). Indeed, Brent (2009) concluded that gross congenital malformations would not be increased with exposure to less than 0.2 Gy (20 rad). And because diagnostic x-rays seldom exceed 0.1 Gy (10 rad),

Strzelczyk and associates (2007) concluded that these procedures are unlikely to cause deterministic effects.

■ Stochastic Effects of Ionizing Radiation

This refers to random, presumably unpredictable oncogenic or mutagenic effects of radiation exposure. These effects may link fetal diagnostic radiation exposure and an increased risk of childhood cancers or genetic diseases. According to Doll and Wakeford (1997) and the National Research Council (2006) BEIR VII Phase 2 report, excess cancers can result from in utero exposure to doses as low as 0.01 Sv or 1 rem. Stated another way by Hurwitz (2006), the estimated risk of childhood cancer following fetal exposure to 0.03 Gy or 3 rad doubles the background risk of 1 in 600 to that of 2 in 600.

In one report, in utero radiation exposure was determined for 10 solid cancers in adults aged 17 to 45 years. There was a dose-response relationship as previously noted at the 0.1 Sv or 10 rem threshold. Intriguingly, nine of 10 cancers were found in females (National Research Council, 2006). These likely are associated with a complex series of interactions between DNA and ionizing radiation. They also make it more problematic to predict cancer risk from low-dose radiation of less than 0.1 Sv or 10 rem. Importantly, below doses of 0.1 to 0.2 Sv, there is no convincing evidence of a carcinogenic effect (Brent, 2009; Preston, 2008; Strzelczyk, 2007).

■ Therapeutic Radiation

The Radiation Therapy Committee Task Group of the American Association of Physics in Medicine found that approximately 4000 pregnant women annually undergo cancer therapy in the United States (Stovall, 1995). Their recommendations are still in current use. The Task Group emphasizes careful individualization of radiotherapy for the pregnant woman. For example, in some cases, shielding the fetus and other safeguards can be taken (Fenig, 2001; Nuyttens, 2002). In other cases, the fetus will be exposed to dangerous doses of radiation, and a carefully designed plan must be improvised (Prado, 2000). One example is the model to estimate fetal dosage with maternal brain radiotherapy, and another is the model to calculate fetal dose with tangential breast irradiation developed by Mazonakis and coworkers (1999, 2003). The effects of radiotherapy on future fertility and pregnancy outcomes were reviewed by Wo and Viswanathan (2009).

■ Diagnostic Radiation

To estimate fetal risk, approximate x-ray dosimetry must be known. According to the American College of Radiology, no single diagnostic procedure results in a radiation dose significant enough to threaten embryofetal well-being (Hall, 1991).

Radiography

Dosimetry for standard radiographs is presented in Table 5-2. In pregnancy, the two-view chest radiograph is the most commonly used study. With this, fetal exposure is exceptionally small. With one abdominal radiograph, because the embryo or fetus is directly in the x-ray beam, the dose is higher—0.001 Gy or 0.1 rad (Fig. 5-12). The standard intravenous pyelogram may

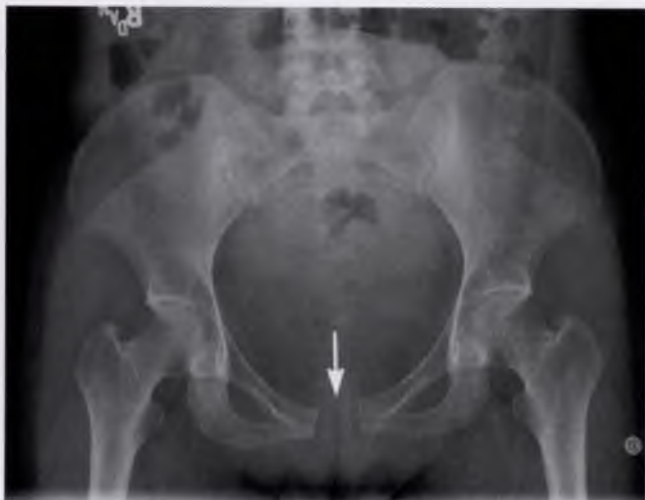

FIGURE 5-12 A 27-year-old primipara with persistent lower extremity pain with ambulation after spontaneous vaginal delivery. An AP pelvis radiograph obtained on postpartum day 2 demonstrates a widened symphysis pubis (arrow). The normal distance of the symphyseal joint is 0.4 to 0.5 cm, and symphyseal separation >1 cm is diagnostic for diastasis.

exceed 0.005 Gy or 0.5 rad because several abdominal films are taken during the examination. The one-shot pyelogram is useful when urolithiasis or other causes of obstruction are suspected but unproven by sonography. Most “trauma series,” such as radiographs of an extremity, skull, or rib series, deliver low doses because of the fetal distance from the target area. Fetal indications for radiographic studies are limited. Perhaps the most common is pelvimetry with a breech presentation.

Fluoroscopy and Angiography

Dosimetry calculations are much more difficult with these procedures because of difference for each case regarding the number of radiographs obtained, the total fluoroscopy time, and the length of time for which the fetus is in the radiation field (Figs. 5-13 and 5-14). As shown in Table 5-3, the range is variable. The Food and Drug Administration (FDA) limits the exposure rate for conventional fluoroscopy, such as those used for barium studies. But, special-purpose systems used in angiography have the potential for much higher exposure.

Endoscopy is the preferred method of gastrointestinal (GI) tract evaluation in pregnancy. Occasionally, an upper GI series or barium enema may be done before the woman realizes that she is pregnant. Most would likely be performed during the period of preimplantation or early organogenesis.

Angiography may occasionally be necessary for serious maternal disorders, especially for trauma. As previously discussed, the greater the distance of the x-ray beam from the embryo or fetus, the less the exposure and risk.

Computed Tomography

Most of these imaging studies are now performed by obtaining a spiral of 360-degree images that are postprocessed in multiple planes. Of these, the axial image remains the most commonly obtained. Multidetector CT (MDCT) imaging is now standard for common clinical indications. However, MDCT protocols may result in increased dosimetry compared with traditional CT imaging.

Several imaging parameters have an effect on exposure (Brenner, 2007). These include pitch, kilovoltage, tube current, collimation, number or thickness of slices, tube rotation, and total acquisition time. If a study is performed with and without

TABLE 5-3. Estimated X-Ray Doses to the Uterus/Embryo from Common Fluoroscopic Procedures

Procedure	Dose to Uterus (mGy)	Fluoroscopic Exposure Time (sec)	Cinegraphic Exposure Time (sec)
Cerebral angiography ^a	<0.1	—	—
Cardiac angiography ^{b,c}	0.65	223 (SD = 118)	49 (SD = 9)
Single-vessel PTCA ^{b,c}	0.60	1023 (SD = 952)	32 (SD = 7)
Double-vessel PTCA ^{b,c}	0.90	1186 (SD = 593)	49 (SD = 13)
Upper gastrointestinal series ^d	0.56	136	—
Barium swallow ^{b,e}	0.06	192	—
Barium enema ^{b,f,g}	20–40	289–311	—

^aWagner, 1997.

^bCalculations based on data of Gorson, 1984.

^cFinci, 1987.

^dSuleiman, 1991.

^eBased on female data from Rowley, 1987.

^fAssumes embryo in radiation field for entire examination.

^gBednarek, 1983.

PTCA = percutaneous transluminal coronary angioplasty; SD = standard deviation.

Modified from Cunningham, 2014.

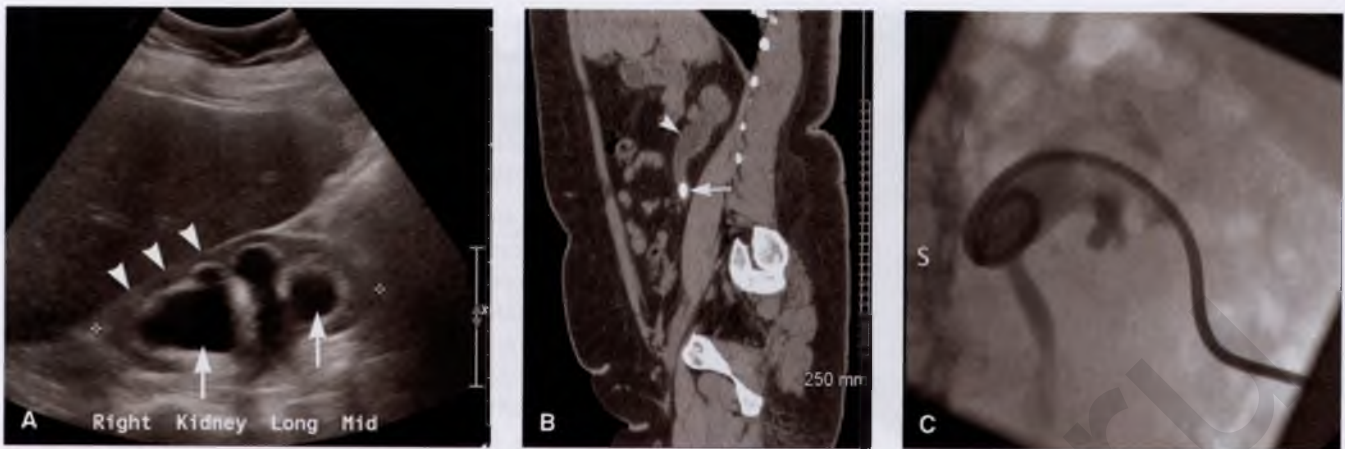


FIGURE 5-13 A 34-year-old gravida at 19 weeks' gestation with a history of nephrolithiasis. **A.** Sonographic image of the right upper quadrant demonstrates severe hydronephrosis (arrows) and thinned echogenic renal parenchyma (arrowheads). **B.** Sagittal computed tomography image shows an obstructing stone in the mid right ureter (arrow) and hydroureteronephrosis (arrowhead). **C.** Fluoroscopic image during percutaneous nephrostomy placement. The patient is positioned prone, and the spine (S) is on the left. Tight collimation is used to minimize radiation to adjacent structures.

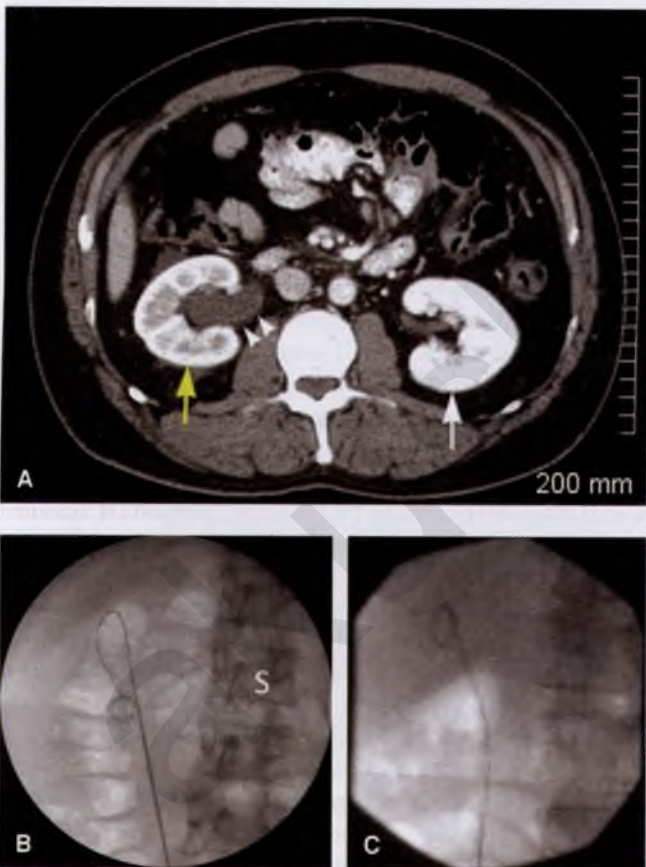


FIGURE 5-14 **A.** Axial contrast-enhanced computed tomography image demonstrates delayed enhancement of the right kidney (yellow arrow) compared with the left kidney (white arrow). This is due to obstruction with mild hydronephrosis noted on the right (arrowheads). **B.** Fluoroscopic images from retrograde nephroureteral stent placement with the patient supine. A flexible guide wire is advanced up the right ureter and into the proximal collecting system. S = spine. **C.** The pigtail catheter is advanced over the wire into good position; the wire is then removed, but the catheter remains.

contrast, the dose is essentially doubled because twice as many images are obtained. However, as a newer alternative, dual-energy scanners can create virtual non-contrast images instead. Fetal exposure is also dependent on factors such as maternal size and fetal size and position. And as with plain radiography, the closer the target area is to the fetus, the greater the dosimetry.

Hurwitz and colleagues (2006) employed a 16-channel MDCT to calculate fetal exposure at 0 and 3 months' gestation using a phantom model. Calculations were made for three commonly requested procedures in pregnant women (Table 5-4). Of these, the CT-angiography pulmonary embolism protocol has the same dosimetry exposure as the ventilation-perfusion (V/Q) lung scan discussed later. The appendicitis protocol, because of the pitch used, has the highest radiation exposure. However, it is useful clinically when dedicated MR imaging is not available. For imaging suspected urolithiasis, the MDCT scan protocol can be used if sonography is nondiagnostic. Using a similar protocol in 67 pregnant women with suspected appendicitis, Lazarus (2007) reported a sensitivity of 92 percent, a specificity of 99 percent, and a negative-predictive value of 99 percent. Here dosimetry is markedly decreased compared with appendiceal imaging because of a different pitch. Using a similar protocol, White (2007) identified urolithiasis in 13 of 20 women at an average of 26.5 weeks. Finally, abdominal CT should be performed if indicated in the pregnant woman with severe trauma.

TABLE 5-4. Estimated Radiation Dosimetry with 16-Channel Multidetector-Imaging Protocols

Protocol	Dosimetry (mGy)	
	Preimplantation	3 Months' Gestation
Pulmonary embolism	0.20–0.47	0.61–0.66
Renal stone	8–12	4–7
Appendix	15–17	20–40

Data from Hurwitz, 2006.

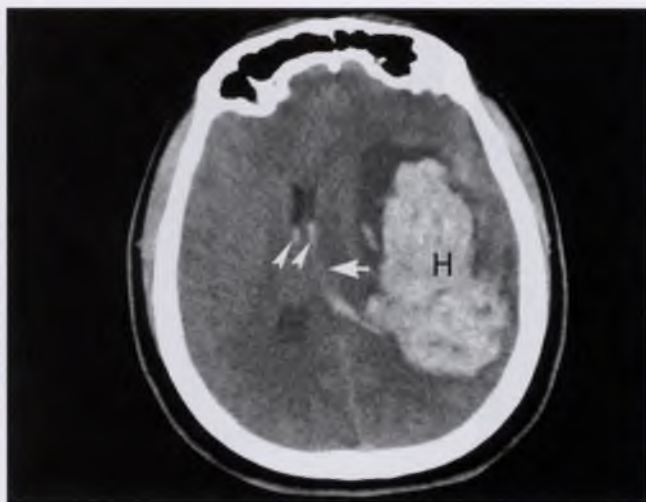


FIGURE 5-15 A 37-year-old gravida with intrapartum eclampsia at term. An image from a noncontrast computed tomography head study demonstrates a large frontoparietal temporal intraparenchymal hematoma (*H*) with intraventricular extension (*arrowheads*). The midline (*arrow*) is shifted to the right due to mass effect from the hematoma.

Cranial CT scanning is the most commonly requested study in pregnant women. Nonenhanced CT is often selected to detect acute hemorrhage within the epidural, subdural, or subarachnoid spaces (Fig. 5-15).

Pelvimetry is used by some before attempting breech vaginal delivery. The fetal dose approaches 0.015 Gy or 1.5 rad, but a low-exposure technique may reduce this to 0.0025 Gy or 0.25 rad (Moore, 1989).

Most experience with chest CT scanning comes from suspected pulmonary embolism. The most recent recommendations for its use in pregnancy are from the Prospective Investigation of Pulmonary Embolism Diagnosis (PIOPED—II) (Stein, 2007). Investigators found that pulmonary scintigraphy—the V/Q scan—was recommended for pregnant women by 70 percent of radiologists, and chest CT angiography was preferred by 30 percent. However, most agreed that MDCT angiography has greater accuracy with increasingly faster acquisition times. Availability of CT at all hours in most hospitals is another important consideration. Others have reported a higher use rate for CT angiography and emphasize that dosimetry is similar to that with V/Q scintigraphy (Brenner, 2007; Hurwitz, 2006; Matthews, 2006). Controversies on the topic continue, recognizing that fetal radiation doses are lower for CT angiography of the chest in comparison to V/Q scan, but maternal radiation doses with CT angiography of the chest are substantially higher (Revel, 2011; Winer-Muram, 2002). At Parkland Hospital, we use MDCT scanning initially for suspected pulmonary embolism.

Radiographic Contrast Agents

Intravenous contrast agents used with radiography and CT imaging are considered category B by the U.S. FDA (2008). The types of intravenous contrast employed for imaging today are iodinated and low osmolality, thus, they cross the placenta to the fetus. With water-soluble iodinated contrast, there has been no documented case of neonatal hypothyroidism or other

adverse effect reported after maternal injection for imaging (American College of Radiology, 2013). Oral contrast preparations, typically containing iodine or barium, have minimal systemic absorption and are unlikely to affect the fetus.

Nuclear Medicine Studies

These studies are performed by “tagging” a radioactive element to a carrier that can be injected, inhaled, or swallowed. For example, the radioisotope technetium-99m (^{99m}Tc) may be tagged to red blood cells, sulfur colloid, or pertechnetate. The method used to tag the agent determines fetal radiation exposure. The amount of placental transfer is obviously important, but so is renal clearance because of fetal proximity to the maternal bladder. Measurement of radioactive technetium is based on its decay, and the units used are the curie (Ci) or the becquerel (Bq). Dosimetry is usually expressed in millicuries (mCi). As shown in Table 5-1, the effective tissue dose is expressed in sievert units (Sv). As discussed previously, to convert: 1 Sv = 100 rem = 100 rad.

Depending on the physical and biochemical properties of a radioisotope, an average fetal exposure can be calculated (Wagner, 1997; Zanzonico, 2000). Commonly used radiopharmaceuticals and estimated absorbed fetal doses are given in Table 5-5. The radionuclide dose should be kept as low as possible (Adelstein, 1999). Exposures vary with gestational age and are greatest earlier in pregnancy for most radiopharmaceuticals. One exception is the later effect of iodine-131 on the fetal thyroid, discussed in a later paragraph (Wagner, 1997). Of resources, the International Commission on Radiological Protection (2001) has compiled dose coefficients for radionuclides. Stather and colleagues (2002) detailed the biokinetic and dosimetric models used by the Commission to estimate fetal radiation doses from maternal radionuclide exposure.

As discussed earlier, MDCT-angiography is being used preferentially for suspected pulmonary embolism during pregnancy. Previously, the preferred imaging modality was the V/Q scan. It can be used if CT angiography is nondiagnostic, although in some algorithms repeat CT angiography is still advocated over V/Q scan (Leung, 2011). During V/Q scanning, perfusion is measured with injected ^{99m}Tc macroaggregated albumin, and ventilation is measured with inhaled xenon-127 or xenon-133. Fetal radiation exposure with either is negligible (Chan, 2002; Mountford, 1997).

Thyroid scanning with iodine-123 or iodine-131 seldom is indicated in pregnancy. With trace doses used diagnostically, however, fetal risk is minimal. *Importantly, therapeutic radioiodine in doses to treat Graves disease or thyroid cancer may cause fetal thyroid ablation and cretinism.*

The sentinel lymphoscintigram uses ^{99m}Tc sulfur colloid to detect axillary lymph node metastases from breast cancer. This study is a commonly completed preoperatively in nonpregnant women (Newman, 2007; Spanheimer, 2009; Wang, 2007). As shown in Table 5-5, the calculated dose approximates 0.014 mSv or 1.4 mrad, which should not preclude its use during pregnancy.

MAGNETIC RESONANCE IMAGING

This technology has proven extremely useful for maternal and fetal imaging studies because it lacks ionizing radiation. Its advantages include high soft-tissue contrast, ability to characterize tissue,

TABLE 5-5. Radiopharmaceuticals Used in Nuclear Medicine Studies

Study	Estimated Activity Administered per Examination in Millicuries (mCi) ^a	Weeks Gestation ^b	Dose to Uterus/Embryo per Pharmaceutical (mSv) ^c
Brain	20 mCi ^{99m} Tc DTPA	<12	8.8
		12	7 ^c
Hepatobiliary	5 mCi ^{99m} Tc sulfur colloid	12	0.45
	5 mCi ^{99m} Tc HIDA		1.5
Bone	20 mCi ^{99m} Tc phosphate	<12	4.6
Pulmonary	3 mCi ^{99m} Tc-macroaggregated albumin	Any	0.45–0.57 (combined)
Ventilation	10 mCi ¹³³ Xe gas		
Renal	20 mCi ^{99m} Tc DTPA	<12	8.8
Abscess or tumor	3 mCi ⁶⁷ Ga citrate	<12	7.5
Cardiovascular	20 mCi ^{99m} Tc-labeled red blood cells	<12	5
		3 mCi ²¹⁰ Tl chloride	
		<12	11
		12	6.4
		24	5.2
		36	3
Thyroid	5 mCi ^{99m} TcO ₄	<8	2.4
	0.3 mCi ¹²³ I (whole body)	1.5–6	0.10
	0.1 mCi ¹³¹ I ^d		
	Whole body	2–6	0.15
	Whole body	7–9	0.88
	Whole body	12–13	1.6
	Whole body	20	3
	Thyroid-fetal	11	720
Thyroid-fetal	12–13	1300	
Thyroid-fetal	20	5900	
Sentinel Lymphoscintigram	5 mCi ^{99m} Tc sulfur colloid (1–3 mCi)		5

^aTo convert to mrem multiply × 100.

^bExposures are generally greater prior to 12 weeks compared with increasing gestational ages.

^cSome measurements account for placental transfer.

^dThe uptake and exposure of ¹³¹I increases with gestational age.

DTPA = diethylenetriaminepentaacetic acid; Ga = gallium; HIDA = hepatobiliary iminodiacetic acid; I = iodine; mCi = millicurie; mSv = millisievert; Tc = technetium; TcO₄ = pertechnetate; Tl = thallium.

Data from Adelstein, 1999; Schwartz, 2003; Stather, 2002; Wagner, 1997; Zanzonico, 2000, and their colleagues. Reproduced with permission from Twickler DM, Cunningham FG: General considerations and maternal evaluation. In Cunningham FG, Leveno KL, Bloom, et al (eds): Williams Obstetrics, 24th ed. New York, McGraw-Hill Education, 2014.

and acquisition of images in any plane. Of these, axial, sagittal, coronal planes are commonly depicted. With MR imaging, powerful magnets are used to temporarily alter the state of protons. The magnetic field strength is measured in tesla (T), and magnets used in clinical MR imaging are typically 1.5 to 3 T. The hydrogen proton is used for imaging because of its abundance, especially in water and fat. Radio waves are then used to deflect the magnetic vector. When the radiofrequency source is turned off, hydrogen protons return to their normal state. In doing so, they emit radio waves of different frequencies, which are received

by coils often wrapped around the body part of interest. The relative intensity of these signals is plotted on a gray scale. A series of pulse sequences in all planes can be obtained, and with applied gradients, the location of each received signal is used to create an image. Technological advances have significantly reduced scan times and improved image quality.

■ Safety

The most recent update of the Blue Ribbon Panel on MR safety of the American College of Radiology was summarized by Kanal

and associates (2007). The panel concluded that there are no reported harmful human effects from MR imaging, regardless of gestational age. Each request for MR imaging in a pregnant woman should be approved by the attending radiologist. Indicated imaging should be obtained if no other imaging studies can be performed, or if MR imaging would provide information that would otherwise require radiation exposure. Contraindications to MR imaging include internal cardiac pacemakers, neurostimulators, implanted defibrillators and infusion pumps, cochlear implants, shrapnel or other metal in biologically sensitive areas, some intracranial aneurysm clips, and any metallic foreign body in the eye. Of more than 51,000 nonpregnant patients scheduled for MR imaging, Dewey and coworkers (2007) found that only 0.4 percent had an absolute contraindication to the procedure.

Early studies of MR safety found no differences in blastocyst formation exposure of early murine embryos to MR imaging with 1.5 T (Chew, 2001). There is seldom a need or indication for clinical use of field strengths greater than 1.5 T. That said, a magnetic field strength up to 4 T has been reported to be safe in animals (Magin, 2000). Vadeyar and associates (2000) noted no demonstrable fetal heart rate pattern changes during MR imaging of pregnant women. Studies evaluating children exposed to MR in utero have shown no deleterious effects (Baker, 1994; Clements, 2000; Kok, 2004; Reeves, 2010).

■ Contrast Agents

Elemental *gadolinium chelates* are used to create paramagnetic contrast. These cross the placenta and are found in amniotic fluid. In doses approximately 10 times the human dose, a gadolinium-based contrast agent (GBCA) caused slight developmental delay in rabbit fetuses. De Santis and associates (2007) described 26 women given a gadolinium derivative in the first trimester without adverse fetal effects. According to Briggs and Freeman (2015) and the American College of Radiology (2007), routine use of gadolinium is not recommended unless there are overwhelming potential benefits. This recommendation stems from a possible

dissociation of the toxic gadolinium ion from its ligand in amniotic fluid and potential prolonged exposure of the fetus.

■ Maternal Indications

With maternal disorders unrelated to pregnancy, MR imaging technology has advantages compared with CT scanning because there is no ionizing radiation. In some cases, MR imaging may be comparable to CT, and in others, MR imaging is preferable. For example, maternal central nervous system abnormalities such as brain tumors or spinal trauma are more clearly seen with MR imaging. And MR imaging has provided valuable insights into the pathophysiology of eclampsia (Twickler, 2007; Zeeman, 2003, 2009). MR angiography can be done without intravascular contrast and provides imaging of the cerebral vasculature. It can also be used to calculate flow of the middle and posterior cerebral arteries (Zeeman, 2004a,b).

MR imaging is a superb technique to evaluate the abdomen and retroperitoneal space in a pregnant woman. It has been used in pregnancy for detection and localization of adrenal tumors, hepatic and renal masses, GI lesions, and pelvic abnormalities. In evaluating neoplasms of the chest, abdomen, and pelvis in pregnancy, MR imaging has particular value (Oto, 2007). It may be used to confirm pelvic and vena caval thrombosis—a common source of pulmonary embolism in pregnant women. As discussed in Chapter 32 (p. 513), CT and MR imaging are useful for evaluating puerperal infections, but MR imaging provides better visualization of the bladder flap area following cesarean delivery (Brown, 1999; Twickler, 1997).

MR imaging is now frequently used to evaluate right lower quadrant pain in pregnancy, specifically with suspected appendicitis (Pedrosa, 2007, 2009; Singh, 2007). Alternative etiologies of abdominal and pelvic pain in pregnancy, related and unrelated to the pregnant state, can also be identified on MR studies. These may include appendicitis and disorders of the GI tract, urinary tract, biliary tree, reproductive tract, and placenta (Figs. 5-16 through 5-19) (Furey, 2014).

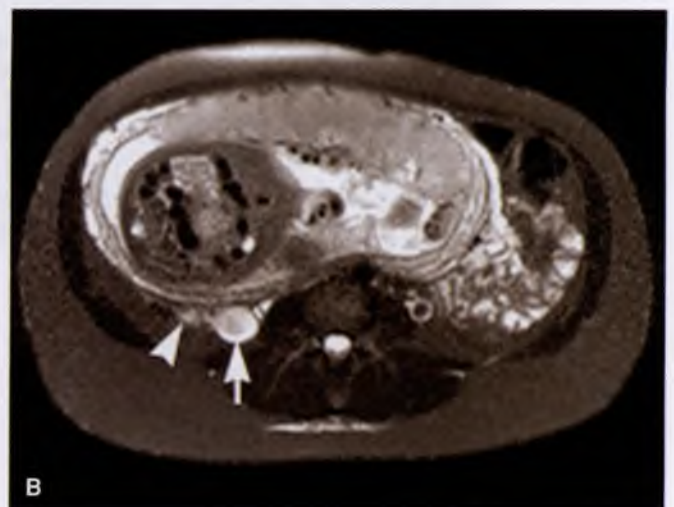
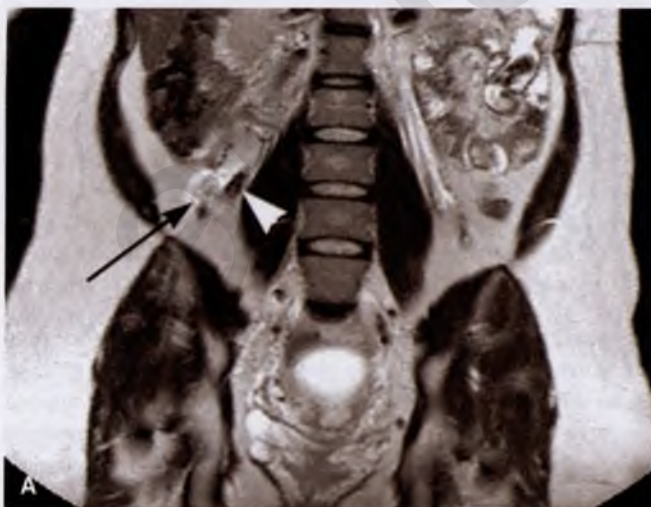

FIGURE 5-16 A 22-year-old gravida at 32 weeks' gestation describes 2 days of right-sided abdominal pain associated with nausea and dry heaves. **A.** Coronal T2-weighted magnetic resonance image demonstrates the appendix (*arrowhead*) with mild edema near the tip (*arrow*). **B.** Axial T2-weighted image with fat saturation again shows the mild edema (*arrowhead*). Note the enlarged right ovarian vein (*arrow*), which is not uncommon in pregnancy.

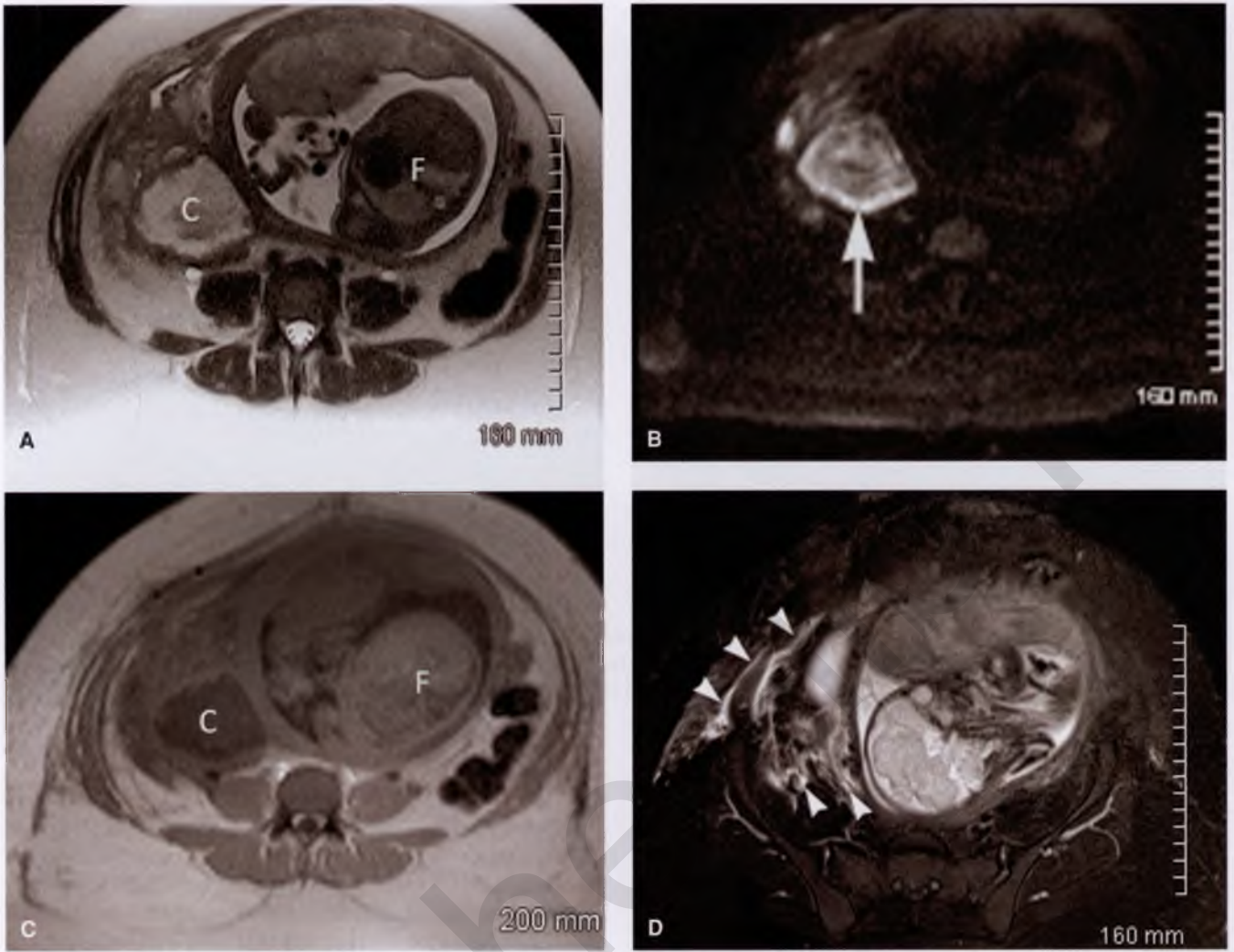


FIGURE 5-17 A 25-year-old gravida at 30 weeks' gestation is postoperative day 1 following appendectomy for perforated appendicitis. Axial T2- (A) and T1- (C) weighted images demonstrate a large collection (C) in the right lower quadrant. F = fetus. B. The collection contains viscous fluid as evidenced by the high signal (arrow) on diffusion weighted imaging. D. Axial T2-weighted image with fat saturation better demonstrates edema within the adjacent soft tissues (arrowheads). A large abscess was drained surgically.

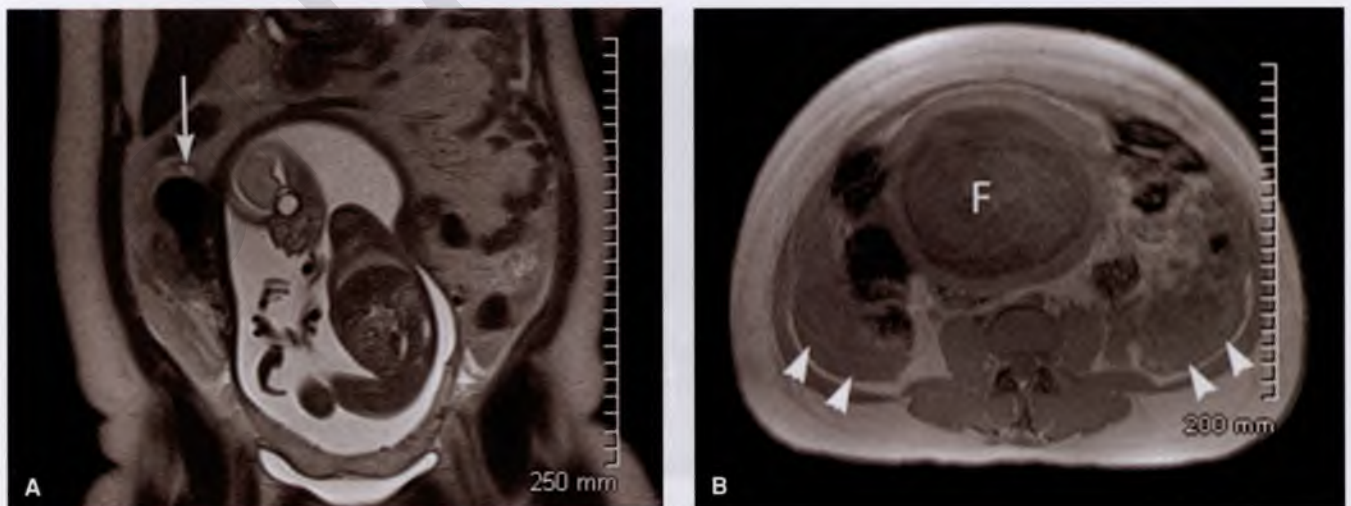


FIGURE 5-18 A 30-year-old gravida with abdominal pain and suspected appendicitis. A. Coronal T2-weighted image demonstrates a non-dilated but fluid-filled appendix (arrow). Mural thickening of the appendix and focal adjacent edema, which would suggest appendicitis, are absent. B. Axial T1-weighted image demonstrates a massive hemoperitoneum (arrowheads). During exploratory laparotomy, a bleeding placenta percreta was diagnosed and required subsequent cesarean hysterectomy. F = fetus.

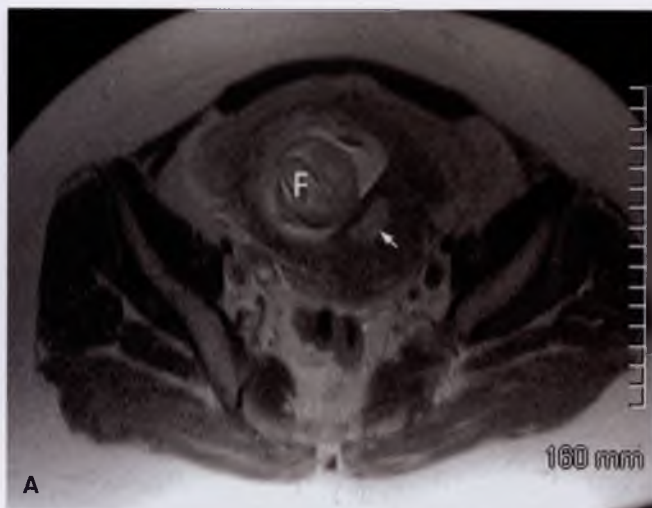
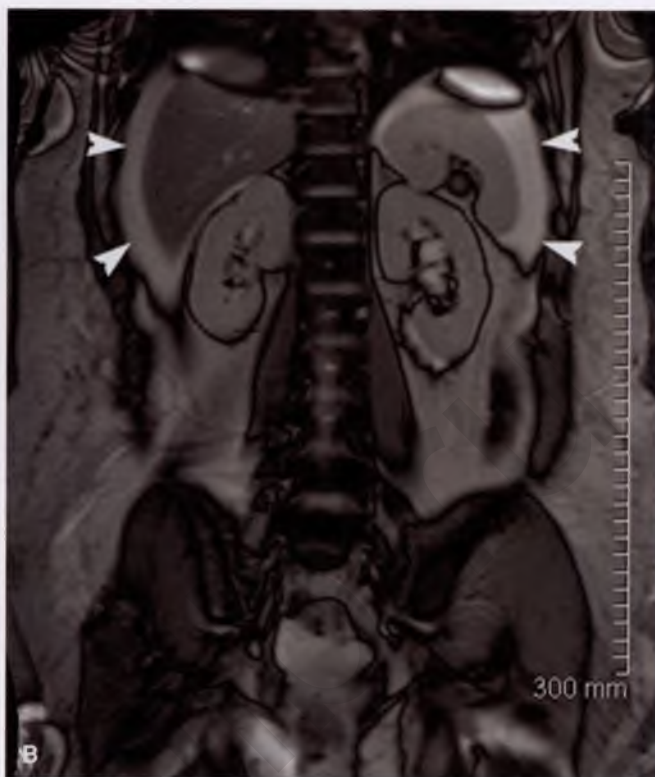

FIGURE 5-19 A 35-year-old gravida at 19 weeks' gestation with acute-onset abdominal pain, concerning for appendicitis. **A.** Axial T2-weighted image demonstrates the hyperintense decidualized endometrium (*arrow*) separate from the gestation (*F*). **B.** As emergent MR imaging in pregnancy often uses truncated sequences to save time, this balanced image from the localizer helps to quantify a volume of hemoperitoneum as large, given significant perihepatic and perisplenic fluid (*arrowheads*). An interstitial pregnancy was confirmed surgically.



■ Fetal Indications

Fetal MR imaging as a complement to sonography has been used with increasing frequency (De Wilde, 2005; Laifer-Narin, 2007; Sandrasegaran, 2006). According to Zaretsky and associates (2003a), almost all elements of the standard fetal anatomical survey can be evaluated using MR imaging. Bauer (2009), Reichel (2003), and Twickler (2002, 2003) and their colleagues have validated its use for fetal central nervous system anomalies

and biometry (Fig. 5-20). Caire and associates (2003) described MR strengths in evaluating fetal genitourinary anomalies. Hawkins and colleagues (2008) reported use of MR imaging in 21 fetuses with renal anomalies and oligohydramnios. Zaretsky and coworkers (2003b) reported that fetal weight estimation was more accurate using MR imaging than with sonography. The development of ultra-fast spin echo sequences used in MR has improved fetal imaging by being less affected by fetal movement.

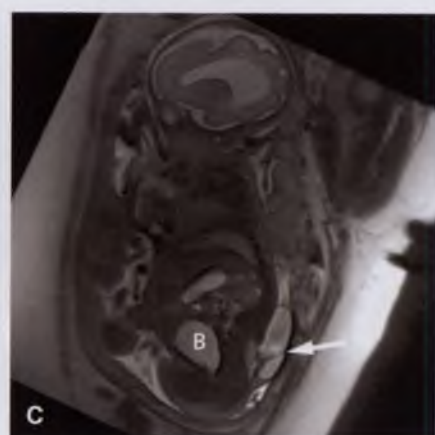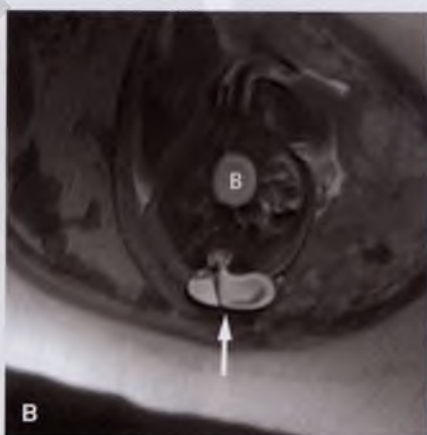

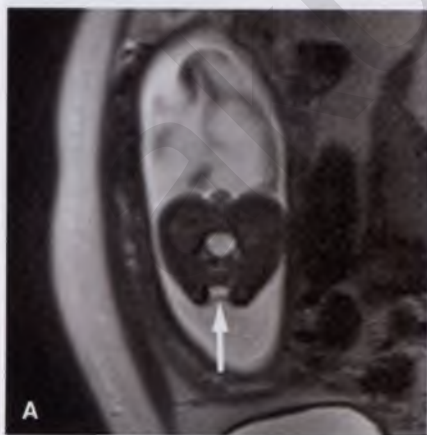
FIGURE 5-20 **A.** Axial Half Fourier Acquisition Single Shot Turbo Spin Echo (HASTE) image through the fetal pelvis demonstrates an open neural tube defect (*arrow*) at the level of the sacrum. In a different fetus, axial (**B**) and sagittal (**C**) HASTE images through the pelvis show a larger, bilobed myelomeningocele (*arrow*). B = fetal bladder.

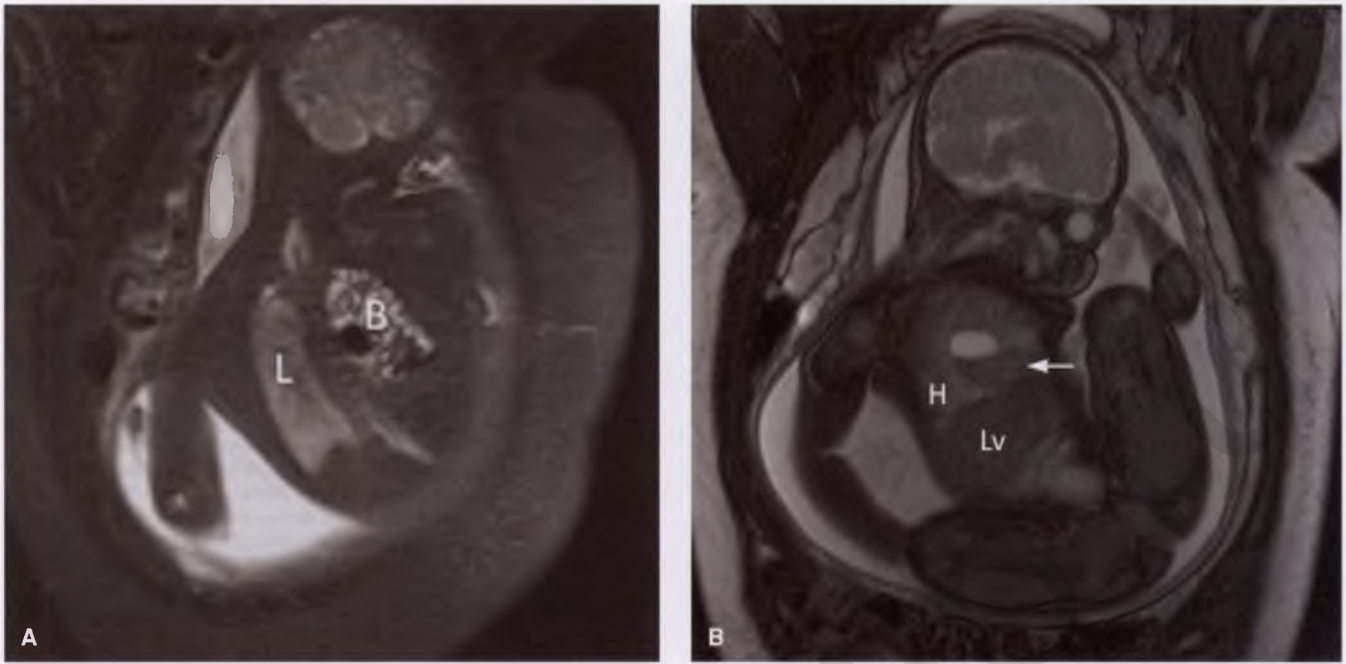


FIGURE 5-21 A 27-year-old gravida at 36 weeks' gestation with fetal left-sided congenital diaphragmatic hernia. **A.** T2-weighted fat-suppressed image demonstrates a portion of normal right lung (L) and the left chest filled with bowel (B). **B.** The balanced image demonstrates liver (Lv) below the diaphragm and up in the chest (arrow). The heart (H) is displaced to the right.

Levine (2001) reported that HASTE (Half-Fourier Acquisition Single Shot Turbo Spin Echo) sequences do not generate significant heat in the porcine uterus or fetus. The most common fetal indications for MR imaging are for evaluation of complex abnormalities of the central nervous system, chest, and genitourinary system (Fig. 5-21).

DIAGNOSTIC IMAGING DURING PREGNANCY

Suggested guidelines for imaging during pregnancy are shown in Table 5-6. The American College of Obstetricians and Gynecologists (2016) has reviewed the effects of radiographic imaging during pregnancy.

TABLE 5-6. Diagnostic Imaging During Pregnancy Recommendations

Sonography or magnetic resonance (MR) imaging are not causally linked with adverse fetal effects. If appropriate, these are considered in lieu of x-ray procedures in pregnancy.

Concern for possible fetal effects of ionizing radiation exposure should not proscribe needed diagnostic x-ray procedures for a pregnant woman.

Gravidas are counseled that x-ray exposure from a single diagnostic procedure does not result in harmful fetal effects. Specifically, fetal exposure to <5 rads is not linked to a greater rate of fetal anomalies or pregnancy loss.

Calculation of the radiation dose for a given woman by a medical physicist may be considered, especially if multiple studies are planned.

Intravenous contrast agents used with radiography and computed tomography are considered category B and unlikely to cause fetal harm. Gadolinium contrast for MR imaging is not recommended unless overwhelming potential benefits justifies potential fetal risk.

Radioactive isotopes of iodine are contraindicated for therapeutic use during pregnancy.

REFERENCES

- Adelstein SJ: Administered radionuclides in pregnancy. *Teratology* 59:236, 1999
- American College of Obstetricians and Gynecologists: Guidelines for diagnostic imaging during pregnancy. Committee Opinion No. 656, February 2016
- American College of Obstetricians and Gynecologists: Ultrasonography in pregnancy. Practice Bulletin No. 101, February 2009, Reaffirmed 2014
- American College of Radiology: ACR Manual on Contrast Media. Version 9, 2013
- American Institute of Ultrasound in Medicine: AIUM practice guideline for the performance of obstetric ultrasound examinations. *J Ultrasound Med* 29:157, 2010
- American Institute of Ultrasound in Medicine: AIUM practice guideline for the performance of an ultrasound examination of the abdomen and/or retroperitoneum. *J Ultrasound Med* 31:1301, 2012
- Amis ES, Butler PF, Applegate KE, et al: American College of Radiology white paper on radiation dose in medicine. *J Am Coll Radiol* 4(5): 272, 2007
- Ang ES, Gluncic V, Duque A, et al: Prenatal exposure to ultrasound waves impacts neuronal migration in mice. *Proc Natl Acad Sci USA* 103(34): 12903, 2006
- Baker PN, Johnson IR, Harvey PR, et al: A three-year follow-up of children imaged in utero with echo-planar magnetic resonance. *Am J Obstet Gynecol* 170(1):32, 1994
- Bauer S, Mirza F, Pri-Paz S, et al: Dandy-Walker malformations: a comparison of prenatal ultrasound and magnetic resonance imaging. Abstract No. 396 presented at the 29th annual meeting of the Society for Maternal-Fetal Medicine. 26-31 January 2009
- Bednarek DR, Rudin S, Wong, et al: Reduction of fluoroscopic exposure for the air-contrast barium enema. *Br J Radiol* 56:823, 1983
- Brenner DJ, Hall JH, Phil D: Computed tomography—an increasing source of radiation exposure. *N Engl J Med* 357:2277, 2007
- Brent RL: Developmental and reproductive risks of radiological procedures utilizing ionizing radiation during pregnancy. Proceedings No. 21 in Radiation Protection in Medicine: Contemporary Issues. Proceedings of the 35th annual meeting of the National Council on Radiation Protection and Measurements. Arlington, VA, 7-8 April 1999b
- Brent RL: Saving lives and changing family histories: appropriate counseling of pregnant women and men and women of reproductive age, concerning risk of diagnostic radiation exposure during and before pregnancy. *Am J Obstet Gynecol* 200(1):4, 2009
- Brent RL: Utilization of developmental basic science principles in the evaluation of reproductive risks from pre- and postconception environmental radiation exposures. *Teratology* 59:182, 1999a
- Briggs GG, Freeman RK: *Drugs in Pregnancy and Lactation*, 9th ed. Philadelphia, Wolters Kluwer, 2015
- Brown CE, Stettler RW, Twickler D, et al: Puerperal septic pelvic thrombophlebitis: incidence and response to heparin therapy. *Am J Obstet Gynecol* 181:143, 1999
- Caire JT, Ramus RM, Magee KP, et al: MRI of fetal genitourinary anomalies. *AJR Am J Roentgenol* 181:1381, 2003
- Callen PW: The obstetric ultrasound examination. In Callen PW (ed): *Ultrasonography in Obstetrics and Gynecology*, 4th ed. Philadelphia, WB Saunders, 2000
- Chan WS, Ray JG, Murray S, et al: Suspected pulmonary embolism in pregnancy. *Arch Intern Med* 152:1170, 2002
- Chew S, Ahmadi A, Goh PS, et al: The effects of 1.5T magnetic resonance imaging on early murine in-vitro embryo development. *J Magn Reson Imaging* 13:417, 2001
- Clements H, Duncan KR, Fielding K, et al: Infants exposed to MRI in utero have a normal paediatric assessment at 9 months of age. *Br J Radiol* 73(866):190, 2000
- Committee on Biological Effects of Ionizing Radiation, National Research Council: Other somatic and fetal effects. In BEIR V: *Effects of Exposure to Low Levels of Ionizing Radiation*. Washington, National Academy Press, 1990
- Conway BJ: Nationwide evaluation of x-ray trends: tabulation and graphical summary of surveys 1984 through 1987. Frankfort, Conference of Radiation Control Program Directors, 1989
- Cunningham FG, Leveno KJ, Bloom SL, et al (eds): *General considerations and maternal evaluation*. In *Williams Obstetrics*, 24th ed. New York, McGraw-Hill Education, 2014
- Dekaban AS: Abnormalities in children exposed to x-irradiation during various stages of gestation: tentative timetable of radiation injury to the human fetus. *J Nucl Med* 9:471, 1968
- De Santis M, Straface G, Cavaliere AF, et al: Gadolinium periconceptual exposure: pregnancy and neonatal outcome. *Acta Obstet Gynecol Scand* 86: 99, 2007
- De Wilde JP, Rivers AW, Price DL: A review of the current use of magnetic resonance imaging in pregnancy and safety implications for the fetus. *Prog Biophys Mol Biol* 87:335, 2005
- Dewey M, Schink T, Dewey CF: Frequency of referral of patients with safety-related contraindications to magnetic resonance imaging. *Eur J Radiol* March 22, 2007
- Doll R, Wakeford R: Risk of childhood cancer from fetal irradiation. *Br J Radiol* 70:130, 1997
- Fenig E, Mishaeli M, Kalish Y, et al: Pregnancy and radiation. *Cancer Treat Rev* 27:1, 2001
- Finci L, Meier B, Steffenino G, et al: Radiation exposure during diagnostic catheterization and single- and double-vessel percutaneous transluminal coronary angioplasty. *Am J Cardiol* 60:1401, 1987
- Food and Drug Administration: Content and format of labeling for human prescription drug and biological products: requirements for pregnancy and lactation labeling. *Fed Regist* 29:30831, 2008
- Furey EA, Bailey AA, Pedrosa I: Magnetic resonance imaging of acute abdominal and pelvic pain in pregnancy. *Top Magn Reson Imaging* 23(4):225, 2014
- Gorson RO, Lassen M, Rosenstein M: Patient dosimetry in diagnostic radiology. In Waggener RG, Kereiakes JG, Shalek R (eds): *Handbook of Medical Physics*, Vol II. Boca Raton, CRC Press, 1984
- Greskovich JF, Macklis RM: Radiation therapy in pregnancy: risk calculation and risk minimization. *Semin Oncol* 27:633, 2000
- Groen RS, Bae JY, Lim KJ: Fear of the unknown: ionizing radiation exposure during pregnancy. *Am J Obstet Gynecol* 206(6):456, 2012
- Hall EJ: Scientific view of low-level radiation risks. *RadioGraphics* 11:509, 1991
- Hawkins JS, Dashe JS, Twickler DM: Magnetic resonance imaging diagnosis of severe fetal renal anomalies. *Am J Obstet Gynecol* 198:328.e1, 2008
- Hurwitz LM, Yoshizumi T, Reiman RE, et al: Radiation dose to the fetus from body MDCT during early gestation. *Am J Roentgenol* 186:871, 2006
- International Commission on Radiological Protection: Doses to the embryo and fetus from intakes of radionuclides by the mother. *Ann ICRP* 31:19, 2001
- Kanal E, Barkovich AJ, Bell C, et al: ACR guidance document for safe MR practices: 2007. *AJR Am J Roentgenol* 188:1, 2007
- Kok RD, de Vries MM, Heerschap A, et al: Absence of harmful effects of magnetic resonance exposure at 1.5 T in utero during the third trimester of pregnancy: a follow-up study. *Magn Reson Imaging* 22(6):851, 2004
- Kossoff G: Contentious issues in safety of diagnostic ultrasound. *Ultrasound Obstet Gynecol* 10:151, 1997
- Laifer-Narin S, Budorick NE, Simpson LL, et al: Fetal magnetic resonance imaging: a review. *Curr Opin Obstet Gynecol* 19:151, 2007
- Laws PW, Rosenstein M: A somatic index for diagnostic radiology. *Health Phys* 35:629, 1978
- Lazarus E, Mayo-Smith WW, Mainiero MB, et al: CT in the evaluation of non-traumatic abdominal pain in pregnant women. *Radiology* 244:784, 2007
- Leung AN, Bull TM, Jaeschke R, et al: An official American Thoracic Society/Society of Thoracic Radiology clinical practice guideline: evaluation of suspected pulmonary embolism in pregnancy. *Am J Respir Crit Care Med* 184(10):1200, 2011
- Levine D, Zuo C, Faro CB, et al: Potential heating effect in the gravid uterus during MR HASTE imaging. *J Magn Reson Imaging* 13:856, 2001
- Magin RL, Lee JK, Klintsova A, et al: Biological effects of long-duration, high-field (4 T) MRI on growth and development in the mouse. *J Magn Reson Imaging* 12(1):140, 2000
- Matthews S: Imaging pulmonary embolism in pregnancy: what is the most appropriate imaging protocol? *Br J Radiol* 79(941):441, 2006
- Maulik D: Biosafety of diagnostic Doppler ultrasonography. In: *Doppler Ultrasonid in Obstetrics and Gynecology*. New York, Springer, 1997
- Mazonakis M, Damilakis J, Varveris H, et al: A method of estimating fetal dose during brain radiation therapy. *Int J Radiat Oncol Biol Phys* 44:455, 1999
- Mazonakis M, Varveris H, Damilakis J, et al: Radiation dose to conceptus resulting from tangential breast irradiation. *Int J Radiat Oncol Biol Phys* 55:386, 2003
- Miller MW, Brayman AA, Abramowicz JS: Obstetric ultrasonography: a biophysical consideration of patient safety—the “rules” have changed. *Am J Obstet Gynecol* 179:241, 1998
- Moore MM, Shearer DR: Fetal dose estimates for CT pelvimetry. *Radiology* 171(1):265, 1989
- Mountford PJ: Risk assessment of the nuclear medicine patient. *Br J Radiol* 100:671, 1997
- National Council on Radiation Protection and Measurements: Medical x-ray, electron beam and gamma-ray protection for energies up to 50 MeV. Report No. 102, Bethesda, 1989
- National Research Council: Health effects of exposure to low levels of ionizing radiation BEIR V. Committee on the Biological Effects of Ionizing

- Radiations. Board on Radiation Effects Research Commission on Life Sciences. National Academy Press, Washington, 1990
- National Research Council: Health risks from exposure to low levels of ionizing radiation BEIR VII Phase 2. Committee to assess health risks from exposure to low levels of ionizing radiation. Board on Radiation Effects Research Division on Earth and Life Studies. National Academies Press, Washington, 2006
- Naumburg E, Bellocco R, Cnattingius S, et al: Prenatal ultrasound examinations and risk of childhood leukaemia: case-control study. *BMJ* 320:282, 2000
- Newman EA, Newman LA: Lymphatic mapping techniques and sentinel lymph node biopsy in breast cancer. *Surg Clin North Am* 87:353, 2007
- Nuyttens JJ, Prado KL, Jenrette JM, et al: Fetal dose during radiotherapy: clinical implementation and review of the literature. *Cancer Radiother* 6:352, 2002
- Orake M, Yoshimaru H, Schull WJ: Severe mental retardation among the prenatally exposed survivors of the atomic bombing of Hiroshima and Nagasaki: a comparison of the old and new dosimetry systems. Radiation Effects Research Foundation, Technical Report No. 16-87, 1987
- Oto A, Ernst R, Jesse MK, et al: Magnetic resonance imaging of the chest, abdomen, and pelvis in the evaluation of pregnant patients with neoplasms. *Am J Perinatol* 24:243, 2007
- Pedrosa I, Laforanara M, Pandharipande PV, et al: Pregnant patients suspected of having acute appendicitis: effect of MR imaging on negative laparotomy rate and appendiceal perforation rate. *Radiology* 250(3):749, 2009
- Pedrosa I, Zeikus EA, Levine D, et al: MR imaging of acute right lower quadrant pain in pregnant and nonpregnant patients. *RadioGraphics* 27:721, 2007
- Prado KL, Nelson SJ, Nuyttens JJ, et al: Clinical implementation of the AAPM Task Group 36 recommendations on fetal dose from radiotherapy with photon beams: a head and neck irradiation case report. *J Appl Clin Med Phys* 1:1, 2000
- Preston DL, Cullings H, Suyama A, et al: Solid cancer incidence in atomic bomb survivors exposed in utero or as young children. *J Natl Cancer Inst* 100:428, 2008
- Reeves MJ, Brandreth M, Whitby EH, et al: Neonatal cochlear function: measurement after exposure to acoustic noise during in utero MR imaging. *Radiology* 257(3):802, 2010
- Reichel TF, Ramus RM, Caire JT, et al: Fetal central nervous system biometry on MR imaging. *AJR Am J Roentgenol* 180:1155, 2003
- Revel MP, Cohen S, Sanchez O, et al: Pulmonary embolism during pregnancy: diagnosis with lung scintigraphy or CT angiography? *Radiology* 258(2):590, 2011
- Richards JR, Ormsby EL, Romo MV, et al: Blunt abdominal injury in the pregnant patient: detection with US. *Radiology* 233(2):463, 2004
- Rosenstein M: Handbook of selected tissue doses for projections common in diagnostic radiology. Rockville, Department of Health and Human Services, Food and Drug Administration. DHHS Pub No. 89-8031, 1988
- Rowley KA, Hill SJ, Watkins RA, et al: An investigation into the levels of radiation exposure in diagnostic examinations involving fluoroscopy. *Br J Radiol* 60:167, 1987
- Sandrasegaran K, Lall CG, Aisen AA: Fetal magnetic resonance imaging. *Curr Opin Obstet Gynecol* 18:605, 2006
- Schwartz JL, Mozurkewich EL, Johnson TM: Current management of patients with melanoma who are pregnant, want to get pregnant, or do not want to get pregnant. *Cancer* 97:2130, 2003
- Singh A, Danrad R, Hahn PF, et al: MR imaging of the acute abdomen and pelvis: Acute appendicitis and beyond. *RadioGraphics* 27:1419, 2007
- Sorahan T, Lancashire RJ, Temperton DH, et al: Childhood cancer and paternal exposure to ionizing radiation: a second report from the Oxford Survey of Childhood Cancers. *Am J Ind Med* 28(1):71, 1995
- Spanheimer PM, Graham MM, Sugg SL, et al: Measurement of uterine radiation exposure from lymphoscintigraphy indicates safety of sentinel lymph node biopsy during pregnancy. *Ann Surg Oncol* 16(5):1143, 2009
- Stather JW, Phipps AW, Harrison JD, et al: Dose coefficients for the embryo and fetus following intakes of radionuclides by the mother. *J Radiol Prot* 22:1, 2002
- Stein, PD, Woodard PK, Weg JG, et al: Diagnostic pathways in acute pulmonary embolism: recommendations of the PLOPED II investigators. *Radiology* 242(1):15, 2007
- Stovall M, Blackwell CR, Cundiff J, et al: Fetal dose from radiotherapy with photon beams: report of AAPM Radiation Therapy Committee Task Group No. 36. *Med Phys* 22:63, 1995
- Streffer C, Shore R, Konermann G, et al: Biological effects after prenatal irradiation (embryo and fetus). A report of the International Commission on Radiological Protection. *Ann ICRP* 33(1-2):5, 2003
- Strzelczyk, J, Damlakis J, Marx MV, et al: Facts and controversies about radiation exposure, Part 2: Low-level exposures and cancer risk. *J Am Coll Radiol* 4:32, 2007
- Suleiman OH, Anderson J, Jones B, et al: Tissue doses in the upper gastrointestinal examination. *Radiology* 178:653, 1991
- Twickler DM, Cunningham FG: Central nervous system findings in preeclampsia and eclampsia. In Lyall F, Belfort M (eds): *Pre-eclampsia—Etiology, and Clinical Practice*. Cambridge, Cambridge University Press, 2007, p 424
- Twickler DM, Cunningham FG: General considerations and maternal evaluation. In Cunningham FG, Leveno KL, Bloom, et al (eds): *Williams Obstetrics*, 24th ed. New York, McGraw-Hill Education, 2014
- Twickler DM, Magee KP, Caire J, et al: Second-opinion magnetic resonance imaging for suspected fetal central nervous system abnormalities. *Am J Obstet Gynecol* 188:492, 2003
- Twickler DM, Reichel T, McIntire DD, et al: Fetal central nervous system ventricle and cisterna magna measurements by magnetic resonance imaging. *Am J Obstet Gynecol* 187:927, 2002
- Twickler DM, Setiawan AT, Evans R, et al: Imaging of puerperal septic thrombophlebitis: a prospective comparison of MR imaging, CT, and sonography. *AJR Am J Roentgenol* 169:1039, 1997
- Vaddey SH, Moore RJ, Strachan BK, et al: Effect of fetal magnetic resonance imaging on fetal heart rate patterns. *Am J Obstet Gynecol* 182:666, 2000
- Wagner LK, Lester RG, Saldana LR: *Exposure of the Pregnant Patient to Diagnostic Radiation*. Philadelphia, Medical Physics Publishing, 1997
- Wang L, Yu JM, Wang YS, et al: Preoperative lymphoscintigraphy predicts the successful identification but is not necessary in sentinel lymph nodes biopsy in breast cancer. *Ann Surg Oncol* 14(8):2215, 2007
- White WM, Zite NB, Gash J, et al: Low-dose computed tomography for the evaluation of flank pain in the pregnant population. *J Endourol* 21:1255, 2007
- Winer-Muram HT, Boone JM, Brown HL, et al: Pulmonary embolism in pregnant patients: fetal radiation dose with helical CT. *Radiology* 224(2):487, 2002
- Wo JY, Viswanathan AN: Impact of radiotherapy on fertility, pregnancy, and neonatal outcomes in female cancer patients. *Int J Radiat Oncol Biol Phys* 73(5):1304, 2009
- Zanzonico PB: Internal radionuclide radiation dosimetry: a review of basic concepts and recent developments. *J Nucl Med* 41:297, 2000
- Zaretsky M, McIntire D, Twickler DM: Feasibility of the fetal anatomic and maternal pelvic survey by magnetic resonance imaging at term. *Am J Obstet Gynecol* 189:997, 2003a
- Zaretsky M, Reichel TF, McIntire DD, et al: Comparison of magnetic resonance imaging to ultrasound in the estimation of birth weight at term. *Am J Obstet Gynecol* 189:1017, 2003b
- Zeeman GG, Cipolla MJ, Cunningham FG: Cerebrovascular (patho)physiology in preeclampsia. In Lindheimer MD, Roberts JM, Cunningham FG (eds): *Chesley's Hypertensive Disorders in Pregnancy*, 3rd ed. New York, Elsevier, 2009, p 229
- Zeeman GG, Fleckenstein JL, Twickler DM, et al: Cerebral infarction in eclampsia. *Am J Obstet Gynecol* 190:714, 2004a
- Zeeman G, Hatab M, Twickler D: Increased large vessel cerebral blood flow in severe preeclampsia by magnetic resonance evaluation. *Am J Obstet Gynecol* 191:2148, 2004b
- Zeeman GG, Hatab M, Twickler D: Maternal cerebral blood flow changes in pregnancy. *Am J Obstet Gynecol* 189:968, 2003

CHAPTER 6

Clinical Simulation

OBSTETRIC SIMULATION EVOLUTION	82
OBSTETRIC SIMULATION GOALS	82
SIMULATORS IN OBSTETRICS	83
OBSTETRIC SIMULATIONS	84
FUTURE ROLES FOR SIMULATION	89

Simulation is the imitation or representation of one act or system by another. According to the Society for Simulation in Healthcare (2015), simulation in medicine has four purposes to aid patient safety: (1) education, (2) assessment, (3) research, and (4) health system integration. During the past few years, simulation has been advanced as a technique to improve obstetric training and thus patient safety. Currently, many obstetric surgical techniques are decreasing in frequency, and this stems in large part from inadequate training due to declining procedure numbers. Thus, simulation poses a solution to this negative cycle by providing hands-on practice.

OBSTETRIC SIMULATION EVOLUTION

For decades, military and commercial aviation has used simulation not only to train pilots but to test them as well. In simulators, pilots are required to demonstrate their proficiency in basic skills and to practice for rare but critical events. Beginning in the 1990s, simulation in obstetric training was implemented, and evaluation has rapidly developed (Gardner, 2008). Thus, in addition to current training that includes didactic lectures and bedside teaching, simulation provides another learning format.

Initially, educational intentions drove simulation development in obstetrics. Since then, academics has been challenged by limitations that include work-hour restrictions, professional liability concerns, insurance payer pressures for shorter hospital stays, and teaching in front of an alert patient. These spurred medical schools to invest in simulation centers to provide a foundation for clinical teaching across specialties.

In obstetric residency training, profound challenges have arisen, and procedural experience has declined during the past two decades. The Accreditation Council for Graduate Medical Education Residency Review Committee (2015) has markedly restricted the tabulation of resident experience to all but four obstetric categories: (1) spontaneous vaginal delivery, (2) cesarean delivery, (3) operative vaginal delivery, (4) and sonographic examination. It is unclear whether this was done because broad national experience in the management of many conditions has become scarce or because the committee did not believe that procedures such as fourth-degree laceration repair, breech delivery, and twin delivery were important skills to master in residency. Importantly, of the four categories that are still reported to the Residency Review Committee, case log numbers have declined for nearly all categories in the past several years. For example, currently more than half of all graduating residents have performed fewer than 25 operative vaginal deliveries. Thus, simulation curriculums have been developed to supplement teaching of technical skills.

OBSTETRIC SIMULATION GOALS

Defining qualities of effective simulation-based education have been described in descending order of their importance: (1) providing feedback, (2) repetitive practice, (3) curriculum integration, (4) range of difficulty, (5) multiple learning strategies, (6) capture of clinical variation, (7) controlled environment, (8) individual learning, (9) defined outcomes, and (10) simulator validity (Issenberg, 2005). As the field fully integrates obstetric

TABLE 6-1. Simulator Types and Their General Qualities

Type	Cost	Pros	Cons	Examples
Bench models	Low	Cheap, portable	Limited activity	Knot tying, surgical skill stations
Model-based simulation	Low to high	Reproducible, modifiable fidelity	Wide variety, sometimes bulky	Laceration repair models, birth simulators
Faculty-driven simulation	Moderate	Personal interaction	Faculty oversight required, limited individual feedback	Mentored clinical scenarios
Computer-based simulation	Moderate to high	Easily reproducible, feedback	Lack physical interaction	Software exercises
Virtual reality simulation	High	Easily reproducible, feedback	Evolving technology/expense	Virtual reality sonography

Adapted from Gardner, 2008.

simulation into its training armamentarium, the ultimate goal is to make labor and delivery safer and minimize the burden of obstetric disease.

Simulation offers special opportunities to improve patient outcomes in rarely encountered circumstances. Thus, individual performance and team collaboration can be enhanced, and systems-based hurdles can be resolved before they affect the patient (American College of Obstetricians and Gynecologists, 2014). Such implementation has the potential to upgrade resident training. It also allows providers already in practice to update techniques or acquire new expertise. As a result, simulation can improve patient outcomes yet minimize patient risk during training.

Goals for simulator skill acquisition often differ widely. In addition to individual assessment, institutions can assess their teaching. For example, many learners within the same clinical scenario may make the same errors (Maslovitz, 2007). This awareness can help educators identify gaps in training or discrepancies in institutional guidelines (Andreatta, 2011). Another goal of simulation may be to improve a team dynamic or prepare for a specific clinical scenario (Auguste, 2011).

With the broad spectrum of learners in obstetrics, a simulation for one group may not be appropriate for a different group. Thus, when developing a simulation or a curriculum for a specific group, awareness of their baseline knowledge is paramount. Simply stated, know your learner and what you want them to learn.

SIMULATORS IN OBSTETRICS

Obstetric simulators vary from simple to complex, from individual to team focused, and from inexpensive to more costly. Simulators can be immersive, such as a virtual reality suite, or may involve actors or standardized patients. Hybrid simulators combine both sophisticated and crude components.

■ Simulator Types

Attempts to classify the different simulator subtypes are challenged by the rapid evolution of products, simulation techniques, and hybridization. In general, simulators can be described by

a set of groupings, but significant overlap is found between these groups (Table 6-1) (Gardner, 2008). The *fidelity* of a model summarizes several different factors. These include the physical realism of the simulation, the conceptual realism in relation to actual practice, and the ability to evoke willingness in the learner to invest time and effort in the experience offered (Gardner, 2008). These three factors typically define the success of a model. Simulators described as having high fidelity strive to closely reproduce an actual clinical environment. These tend to be technologically advanced, involve a combination of physical models and computer programs, and are expensive. Simulators described as having low fidelity, such as a pelvic manikin, tend to be inexpensive and less refined. Thus, with any simulation model, realism is balanced against cost.

The simulator and skill goal should also be aligned. For example, a simple model may provide the desired educational experience, and a more realistic or expensive model may not necessarily offer additional educational benefit. This tenet is summarized by the acronym, the ARRON (As Reasonably Realistic as Objectively Needed) rule. This guides a simulation organizer to match the educational goal to the available assets. These resources also include the time and preparation level of those undergoing the simulation (Macedonia, 2003).

■ Simulator Centers and Curricula

In 2008, the American College of Obstetricians and Gynecologists (2015) formed a Simulations Consortium to create simulation-based curricula to improve residency education and clinical competence. The consortium included members from free-standing simulation centers, most of which were affiliated with university-based medical schools and residency training programs. Centers help develop a culture of simulation and patient safety. Additionally, they can serve multiple medical specialties and promote interdisciplinary and multi-level training (Fig. 6-1). Advantageously, free-standing simulation centers allow institutions to consolidate costly simulation resources and provide technical support for the conduct of simulation training.

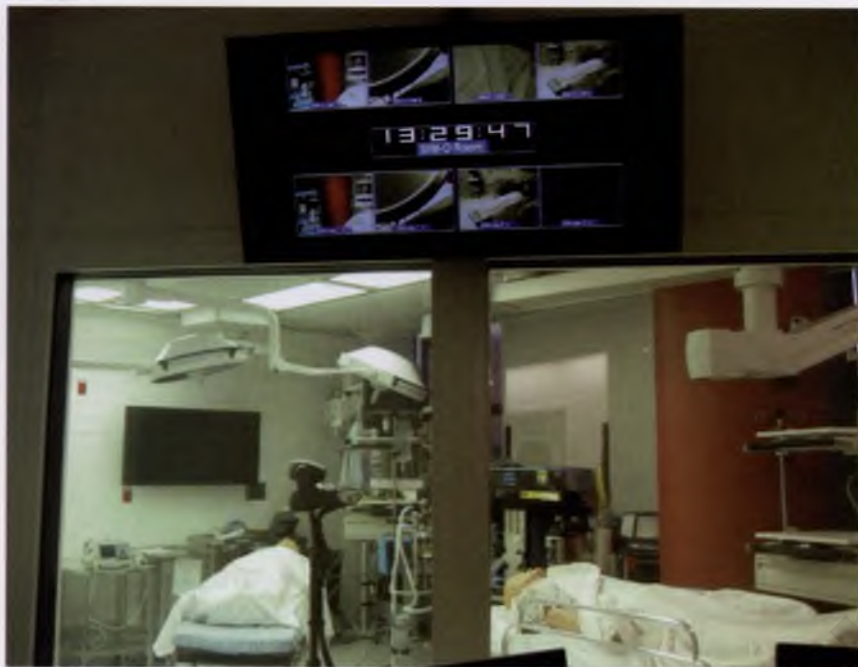

FIGURE 6-1 This simulation center has a viewing room and capability for video recording of an examination or surgery with simulated patients and accessories.

Both the College and the Society for Simulation in Healthcare (SSIH) have criteria for simulation centers and for the conduct of simulations. Efforts have been made to transition these centers out of classrooms and into more universally accessible locations. Simulation courses are promoted at national conferences, and development of mobile platforms allows transport of a mobile simulation center to hospitals that may not be affiliated with academic centers (Guise, 2013). The U.S. Department of Defense established one of the first mobile obstetric simulation programs (Deering, 2009).

From dedicated simulation centers to mobile simulation programs, broad efforts have sought to implement obstetric simulation training across a spectrum of settings to help train providers. The American College of Obstetricians and Gynecologists, the Royal College of Obstetricians and Gynaecologists, and the Society for Maternal-Fetal Medicine have established obstetric simulation courses for postgraduate medical education. The American Board of Obstetrics and Gynecology provides maintenance of certification (MOC) credit for these simulation courses.

OBSTETRIC SIMULATIONS

■ Medical Student Education

Vaginal delivery embodies a basic skill set that easily lends itself to simulation prior to clinical exposure. Skill acquisition builds confidence in the unseasoned provider and can later benefit a potentially apprehensive patient. Numerous birth simulators are available in the marketplace. Evidence suggests that cheaper models may not be inferior to more expensive versions (DeStephano, 2015). This is relevant, in that simulators costing a few hundred dollars can provide equal teaching experiences to those costing upwards of \$50,000.

Using a simulator, an educator can teach hand positioning, perineal support, fetal birth, placental delivery, uterine massage,

and correct carriage of the neonate (Fig. 6-2). Using a pelvic model may be as effective as using an obstetric mannequin to provide a positive learning experience for students. Such models also are a more mobile teaching tool that can be implemented even in an intrapartum suite immediately prior to delivery.

These simulators can augment a traditional lecture both by minimizing time in a seated classroom and by providing three-dimensional content to the learning experience. Evidence supports their role as an adjunct to traditional teaching methods (Scholz, 2012). Compared with traditional lecture, simulation curricula can lead to superior test scores and an improved sense of clinical confidence (Holmstrom, 2011). However, it is unclear whether a boost in confidence after simulation persists over time. Also, as a simulator supplement, use of actors as patients appears to improve not only skills and confidence but also patient communication (Siassakos, 2010).

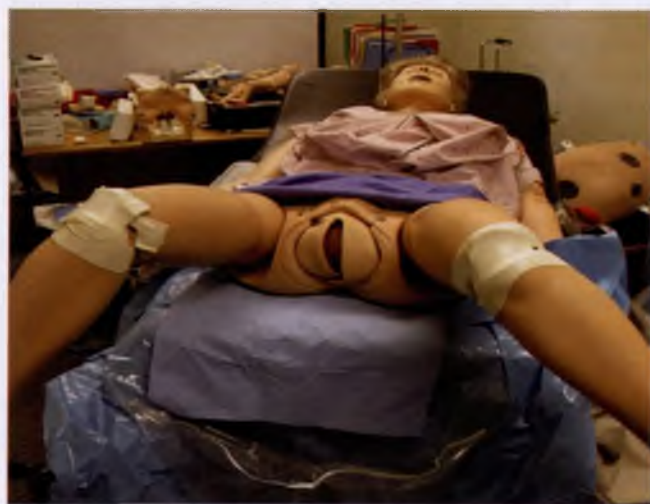

FIGURE 6-2 One high-fidelity simulation model for vaginal delivery.

Residency Preparation

For graduating students preparing to enter obstetric residency, simulation can bolster basic skills. The Association for Professors of Gynecology and Obstetrics (APGO) and the Council on Resident Education in Obstetrics and Gynecology (CREOG) have outlined obstetric skills that are desirable for residents to master prior to residency. Some include cervical examination, basic sonographic techniques, spontaneous vaginal delivery management, and first- or second-degree laceration repair. A foundation in surgical skills and knot tying is also encouraged. Last, accurate estimation of blood loss at time of delivery is another valuable topic (Straub, 2013). Ideally, these skills minimize situations in which learners find themselves not fully prepared.

For this goal, many institutions hold a “boot camp” for fourth-year students or new first-year residents. This can be accomplished expediently, and various topics can be presented in the few days prior to residency. However, institutions vary considerably in their offerings. Some schools may offer a robust session, whereas others provide nothing at all.

Intrapartum Simulation

During residency, obstetric simulation has perhaps its most robust application. The spectrum of skills to be acquired is wide and includes antepartum emergencies, intrapartum management, and postpartum complications (Table 6-2).

Specialization in maternal-fetal medicine similarly requires mastery of numerous obstetric skills in a short period of time. However, because some clinical events are rare, training without simulation may lead to significant skill gaps. Several complex scenarios can be modeled in simulation to provide training in critical care obstetric skills. Some examples include amniotic fluid embolism, diabetic ketoacidosis, myocardial infarction, cardiac arrest, and eclampsia (Birsner, 2013). Simulation of such advanced obstetric skills is still relatively novel compared with birth simulators and perineal laceration repair. These will likely evolve in coming years.

Simulation can be performed in a designated simulation room. Alternatively, simulations may be completed on the labor ward, and the term “in situ” is often used in the literature to describe these exercises. Understandably, performing sessions outside of a simulation lab and in real clinical wards has potential benefits.

TABLE 6-2. Topics for an Obstetric Simulation Curriculum

Eclampsia ^a
Breech delivery ^a
Shoulder dystocia ^a
Fourth-degree laceration repair
Postpartum hemorrhage: uterine atony

^aTopics for which specific formative simulations have been outlined.

Adapted from the American College of Obstetricians and Gynecologists, 2016.

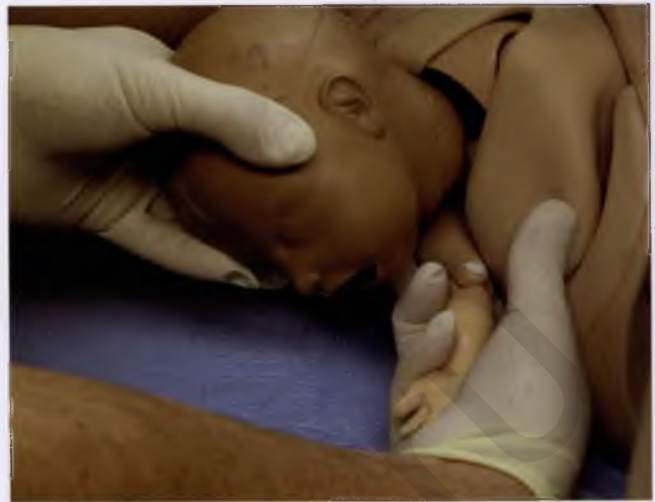

FIGURE 6-3 A simulation model for shoulder dystocia allows participants to practice relevant maneuvers.

Shoulder Dystocia

This complication is one of the most common topics of obstetric simulation. It is a feared intrapartum event that is frequently unanticipated, and shoulder dystocia training often integrates both the delivering provider and the supporting obstetric team. Such universal training is beneficial in that the person primarily managing a shoulder dystocia may not necessarily be an experienced accoucher. However, because multiple different maneuvers can resolve shoulder dystocia, simulation may permit even an experienced clinician to master a new maneuver. Simulation specifically can teach gaining access to the vagina to perform appropriate maneuvers (Fig. 6-3) (Crofts, 2008).

Of simulation options, using a simple empty potato chip cylinder can encourage vaginal examination that will permit the manipulation required to resolve a shoulder dystocia. Although a simple model provides a tool for shoulder dystocia maneuvers, high-fidelity simulations often offer greater feedback that might improve practice (Crofts, 2006). Specifically, some models measure the force applied to the fetal head and neck, and these help study behavior that may be associated with brachial plexus injury (Deering, 2011). Such objective feedback may identify occult causes of potential injury.

Outcome measures indicate that participants in shoulder dystocia simulation with a birth model are more likely to use correct maneuvers and perform sequential maneuvers more quickly during subsequent testing (Deering, 2004; Goffman, 2008). In addition, simulation improves communication during future events and helps both residents and attending physicians. Improvements in shoulder dystocia management are durable and persist even 1 year after an initial simulation (Crofts, 2008).

Operative Vaginal Delivery

In a time when the use of forceps appears to be declining, effective training remains important for indicated deliveries. The Royal College of Obstetricians and Gynaecologists has developed a specific Birth Simulation Training course—ROBuST

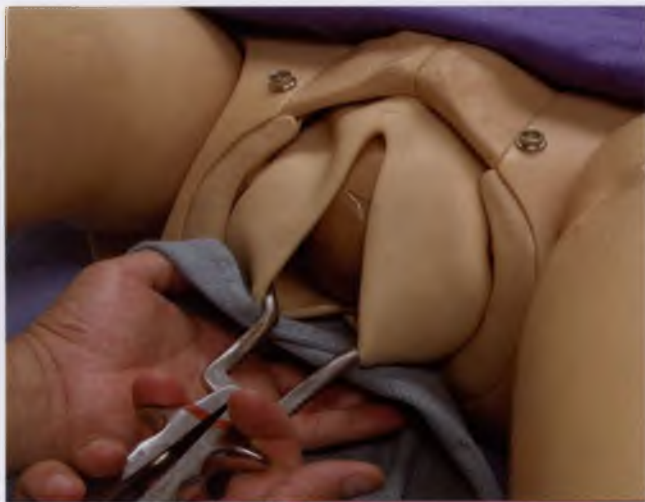

FIGURE 6-4 This simulation model provides a model for forceps application and traction.

Course—for operative vaginal delivery. Skills include manual rotation, vacuum-assisted delivery, and both classical and rotational forceps (Attilakos, 2014). This curriculum reviews not only technique but also appropriate clinical scenarios and potential risks.

Simulation with forceps can be performed using a birth model. Fetal head position can be assessed, and depending on the model, forceps blades can be directly applied (Macedonia, 2003). Various pelvic models provide a fetal vertex with anatomic sutures to ensure correct placement. Depending on the particular model, the degree and angle of applied force can be mimicked even if not perfectly replicated (Fig. 6-4). Given the decreasing actual number of forceps-assisted deliveries, simulation can play an important role in trainee comfort with this tool.

Simulated vacuum delivery has also been used to study applied force and demonstrates a relatively rapid learning curve (Eskander, 2012). As with simulation of forceps-assisted delivery, correct application can be practiced using a fetal vertex model with anatomically placed suture lines (Attilakos, 2014).

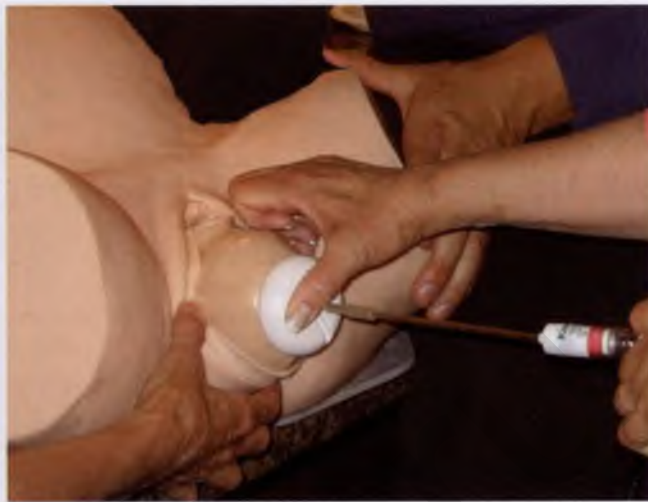

FIGURE 6-5 This simulation model provides a model for vacuum application and traction.

Specific teaching points review both the flexion point landmark for vacuum application and traction techniques to avoid cup detachment and unequal distributions of pressure on the fetal head (Fig. 6-5). High-fidelity devices can objectively measure applied force during simulation. One study of this simulation tool demonstrated a rapid acquisition of skills for vacuum application and pulling force (Eskander, 2012).

Vaginal Breech Delivery

This is well suited for simulation training, given its increasing rarity and potential for causing significant fetal harm with incorrect technique (Deering, 2006). In addition to breech delivery, some birth models can simulate complications such as head entrapment or nuchal arms and maternal complications such as postpartum hemorrhage. Simulation modeling readily replicates a spontaneous breech delivery—with or without an entrapped aftercoming head—as well as breech extraction (Fig. 6-6). Additionally, an adequate model can help instruct placement of Piper forceps on the aftercoming head. One small study showed that

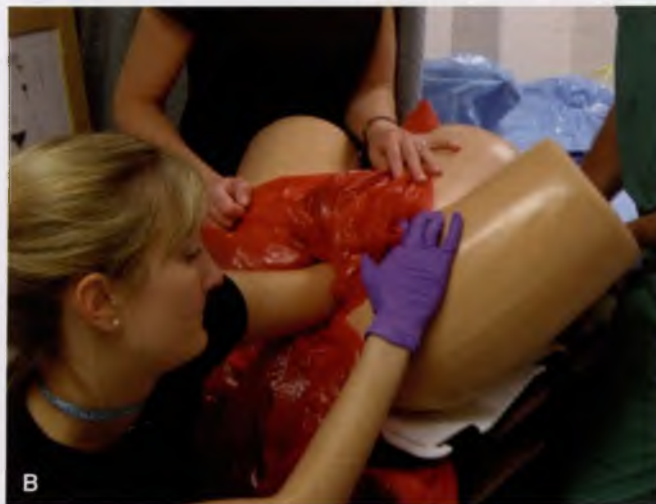
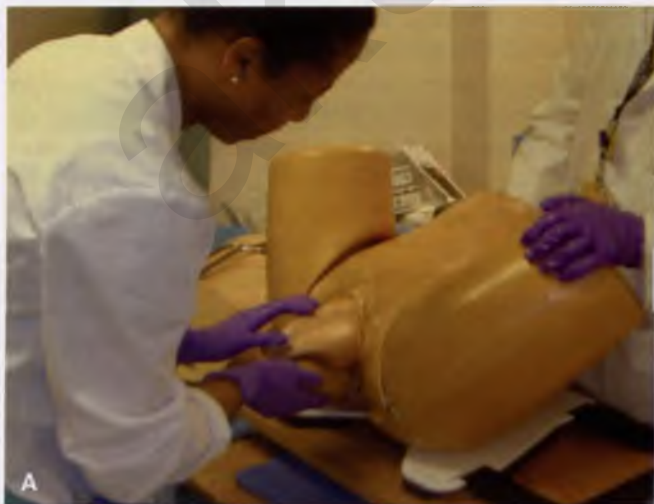
FIGURE 6-6 Breech delivery performed using a simulator allows modeling both spontaneous breech delivery (A) and breech extraction (B).

simulation training improved technique performance and safety during subsequent procedures (Deering, 2006).

Postpartum Hemorrhage

Postpartum hemorrhage is readily simulated using any of various birth models. Bleeding can be mimicked by a liquid substitute, other solid decoys, or even verbal cues that indicate hemorrhage. Uterotonics can be administered by verbal order or by injecting a mock agent through an intravenous line affixed to the mannequin. Models with varying fidelity can serve different audiences, depending on the goal of the exercise. Without simulation facilities on site, event organizers may frequently have to bring supplies or infrastructure. Yet, trainees benefit from performing these exercises in their native labor and delivery units (Guise, 2013).

Of evidence-based outcomes, a simulation program for incoming residents bolsters provider confidence and knowledge of obstetric hemorrhage management (Straub, 2013). In addition, hemorrhage simulation improves the accuracy of blood loss estimation (Maslovitz, 2008). With team-based simulations of postpartum hemorrhage, teamwork and management effectiveness appear to benefit (Fialkow, 2014; Merien, 2010). Outside of academic centers, simulation of postpartum hemorrhage can also improve health-system care and patient outcomes (Marshall, 2015).

Cesarean Delivery

Several commercially available simulation models emulate cesarean delivery (Fig. 6-7). Low-cost simulators can be easily created and focus on the elements that mimic clinical reality. Such simulators can be used to model the steps and surgical technique of uncomplicated or emergency cesarean delivery, even perimortem cesarean delivery (Sampson, 2013).

Intrapartum complications that require emergency cesarean delivery can be simulated to help identify system weakness and optimize management in these time-sensitive situations (Guise, 2013; Lipman, 2013). Team-based obstetric simulation improves team performance and surgeon technical skills in

these high-risk situations (Fransen, 2012; Merien, 2010). For example, Deering and Argani (personal communication, 2015) reported that Walter Reed Military Medical Center and Johns Hopkins Bayview Medical Center both reduced the decision-to-incision time for emergent cesarean deliveries after implementation of on-site team drills. This model of training can similarly be useful even in lower-resource settings (Walker, 2014). Establishing a scenario can be as simple as assembling various team members who might encounter specific obstetric complications and integrating all the different steps that must take place prior to “delivery.” With training and simulation, timing of cesarean delivery can be optimized in real-life clinical scenarios (Siassakos, 2009).

Of intrapartum emergencies, cord prolapse undeniably requires a quick and effective response to minimize poor fetal outcomes. In this instance, simulation often focuses more on team mobilization to effect patient care than on technical surgical skill. Of outcome measures, team-based drills performed in conjunction with annual training can decrease the time to cesarean delivery in cases of cord prolapse (Siassakos, 2009). Once training exercises are completed, subsequent performance drills can most effectively take place in situ and at random.

Of other intrapartum scenarios, second-stage cesarean delivery can be complicated and warrants practice to achieve atraumatic delivery (Attilakos, 2014). Specifically, simulation can teach destationing of the fetal head with a vaginal hand or reverse breech extraction. With the latter, a vertex-presenting fetus is delivered by breech extraction through the hysterotomy in an effort to avoid lower uterine segment laceration.

Perineal Laceration Repair

Vulvovaginal laceration repair can be readily modeled using animal tissue to teach and practice surgical technique. These models can effectively simulate all types of perineal lacerations and emphasize the specific anatomic structure for repair.

These models can also help demonstrate proficiency. One study using a beef tongue model of third-degree perineal

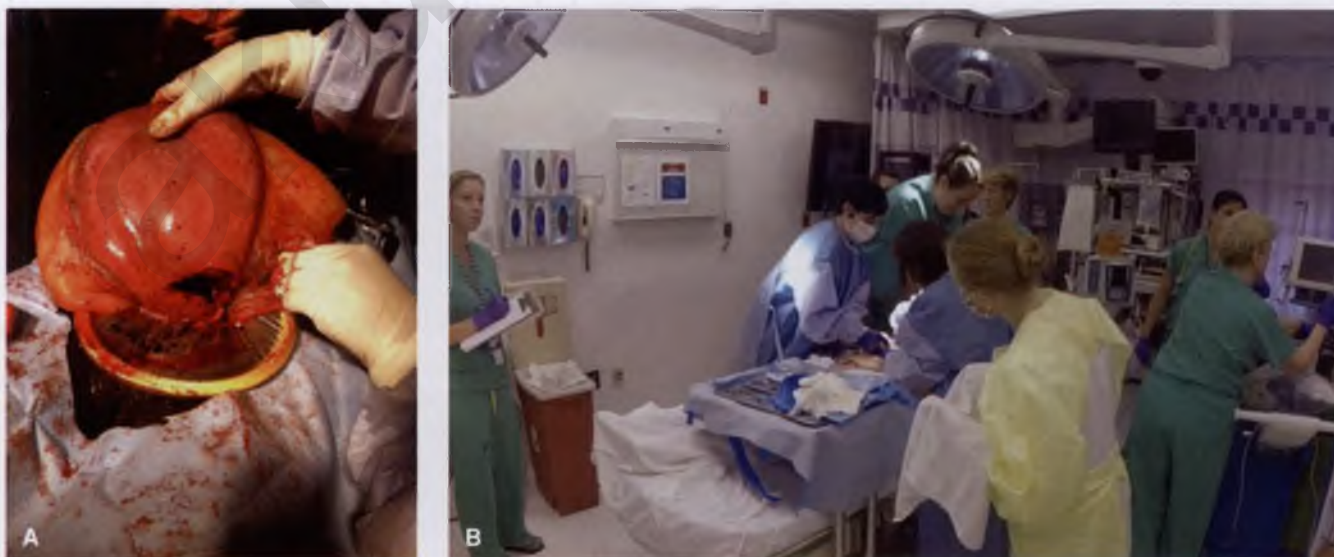

FIGURE 6-7 **A.** This cesarean delivery model focuses on individual cesarean delivery skills using a model to simulate the uterus and hysterotomy. **B.** Team-based simulation of a scenario implementing cesarean delivery.

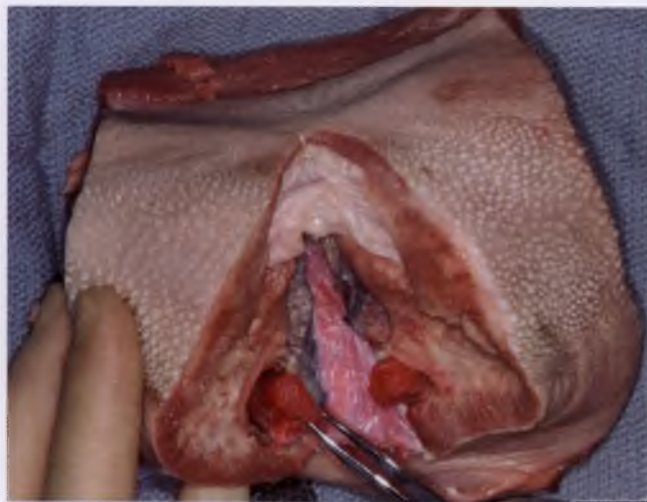

FIGURE 6-8 A beef tongue model in which separate cuts of meat represent the perineum and sphincter muscles allows simulated repair of a perineal laceration.

laceration showed that many residents are inadequately trained in this skill (Fig. 6-8) (Uppal, 2010). When coupled with a feedback mechanism, this model can also help with skill acquisition. Similar evaluation of a fourth-degree laceration repair model also confirmed it as a validated test for competency (Siddiqui, 2008). In these scenarios, simulation can serve to assess skills but also teach these fundamentals.

■ Critical Care Simulation

Concurrent with shorter hospital stays for uncomplicated obstetric patients, contemporary practice has seen a dramatic increase in the morbidity of hospitalized patients. Specifically, severe morbidity has doubled in the past decade, and this trend is anticipated to continue (Callaghan, 2012). Simulation can be tailored to minimize obstetric procedure complications. Namely, learners are introduced to technical procedures and high-risk situations in a nonthreatening learning environment (Birsner, 2013).

Simulations focused on critical care obstetric complications have been developed to train maternal-fetal medicine fellows, subspecialists, and critical care teams. Scenarios cover various topics such as cardiac arrest and eclampsia (Table 6-3) (Birsner,

2013). Such efforts may model obstetric care in a manner similar to basic or advanced cardiac life support training programs (Lipman, 2011). During simulation of one of these scenarios, organizers may choose to include another common skill set. For example, postpartum hemorrhage and amniotic fluid embolism management may be concurrently presented.

Of topics, simulation of cardiac arrest requires effective individual decision making but also effective and timely team mobilization and management. Similar to other types of code drills, obstetric cardiac codes can be effectively simulated, and these appear to improve timely intervention (Fisher, 2011). Simulation of a maternal code can effectively identify mistakes in management and help correct these (Lipman, 2010).

Perimortem cesarean delivery, that is, emergent cesarean delivery in the setting of cardiac arrest, can be lifesaving for the mother. For the fetus, the critical goal is to perform efficient perimortem cesarean delivery within 5 minutes after maternal arrest. Curricula to develop skills and management of perimortem cesarean delivery are associated with quicker response times in subsequent simulation and in clinical practice (Dijkman, 2010; Fisher, 2011).

Eclamptic seizure remains an important cause of maternal mortality despite aggressive prophylactic efforts. Simulation models can emulate a woman having a seizure or one suffering from magnesium toxicity. One study found that management scores of eclampsia were higher in a group provided simulation training compared with those given a lecture on this topic (Fisher, 2010). Given the necessity of timely management, simulation is particularly appropriate for these rare events.

■ Antepartum Simulation

Cerclage

Currently, only a few procedures lend themselves to antepartum simulation. Of these, cervical cerclage is well suited, and surgical steps for cerclage are illustrated in Chapter 11 (p. 172) (Macedonia, 2003). For this purpose, box trainer models have been described to simulate a cervix in the upper vagina (Nitsche, 2012). In the model, a series of pipes with foam insert are used to simulate a vagina. A cylindrical cut of beef with a hole drilled in its center simulates a cervix. The cervix is attached to the vagina, and the model is placed on a stand. Routine cerclage surgical instruments then assist cerclage suturing. This simulation has the benefit of being reasonably inexpensive. Additionally, simulation models can easily be modified to present more challenging clinical scenarios such as an incompetent cervix with prolapsed membranes (Fig. 6-9).

Obstetric Sonography Simulation

Sonographic simulators have advanced along with computer technology, and virtual reality scanners simulate obstetric scanning and biometry measurement. This technology has been validated as a tool to assess underlying sonographic skills (Burden, 2012).

Independent of virtual reality trainers, sonographic simulation is also possible using fetal pigs in formalin-sealed bags (Nitsche, 2013a). This model permits the practice of sonographically guided invasive fetal procedures. These include amniocentesis, periumbilical blood sampling, placental sampling, and bladder

TABLE 6-3. Possible Simulations for a High-Risk Obstetrics Curriculum

Eclampsia
Thyroid storm
Cardiac arrest
Sepsis syndrome
Pulmonary embolism
Myocardial infarction
Diabetic ketoacidosis
Intracranial hemorrhage
Amniotic fluid embolism
Emergency cesarean delivery
Hemorrhage/disseminated intravascular coagulopathy

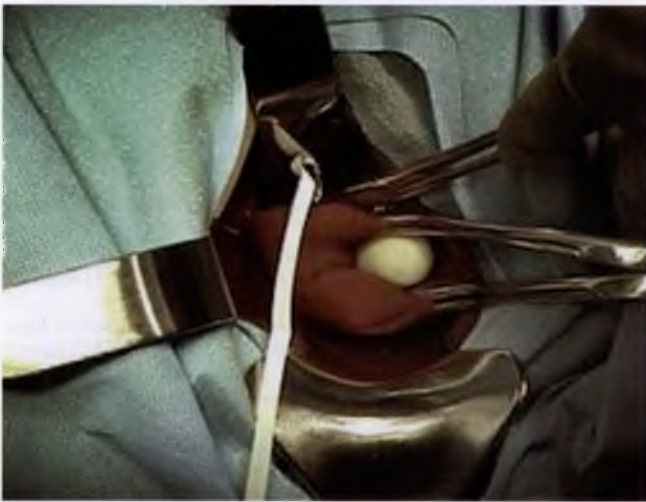

FIGURE 6-9 This cerclage simulator is made of a tubular canal to represent the vagina. Retractors aid visualization of simulated cervical stroma, which can be stitched.

stenting (Fig. 6-10) (Nitsche, 2013b). Despite their initial costs, these models are quite robust and, with adequate storage, can be maintained for prolonged and repeated use.

■ Other Scenarios for Obstetric Simulation

In obstetrics, other possible simulation topics include complications requiring anesthesia assistance, patient counseling, and planned multidisciplinary procedures. First, with high-risk obstetric care, some conditions are frequently co-managed with anesthesia providers. These clinicians have developed effective simulations for common obstetric anesthesia emergencies. Scenarios include epidural placement, blood loss estimation, and emergency intubation (Pratt, 2012). Given the integration of anesthesia providers into an obstetric team, their participation in team-based obstetric simulations can be synergistic.

Patient-doctor communication is paramount in medicine, and recent efforts have examined simulation training to hone these skills. Specifically, simulation of patient counseling for the woman with a periviable fetus can be used to identify biases in counseling (Tucker Edmonds, 2014). Although promising, there is currently little clear evidence regarding simulation in communication education (Karkowsky, 2013). That said, given the high stakes in these sensitive situations, which can involve multiple specialty teams, simulation may play a role in optimizing communication for patient-centered care.

As a final example, simulation is effective in rarely encountered scenarios that require a high degree of coordination and planning. Drills for a planned ex-utero intrapartum treatment (EXIT) procedure with anticipated immediate transfer to neonatal extracorporeal membrane oxygenation (ECMO) have been described (Chap. 16, p. 272) (Auguste, 2011). Such preparation can be employed for other similar types of scheduled procedures.

FUTURE ROLES FOR SIMULATION

With the propagation of obstetric simulation, evidence to support its use continues to accrue. Although not necessarily a panacea for challenges in obstetric training, simulation can serve as an important adjunct to traditional obstetric teaching. Moreover, the potential to provide cost-effective education and training of a global obstetric force has yet to be fully used. More models will no doubt be developed, while existing simulation modalities are further studied and enhanced.

Simulation is evolving not only as an educational tool, but as a way of assessing competency and clinical performance. In 2000, the American Board of Anesthesiology began to incorporate simulation courses as part of their MOC program. They subsequently required all residents to participate in simulated operating rooms and are scheduled to incorporate simulation into their primary certification examinations. In 2016, the American

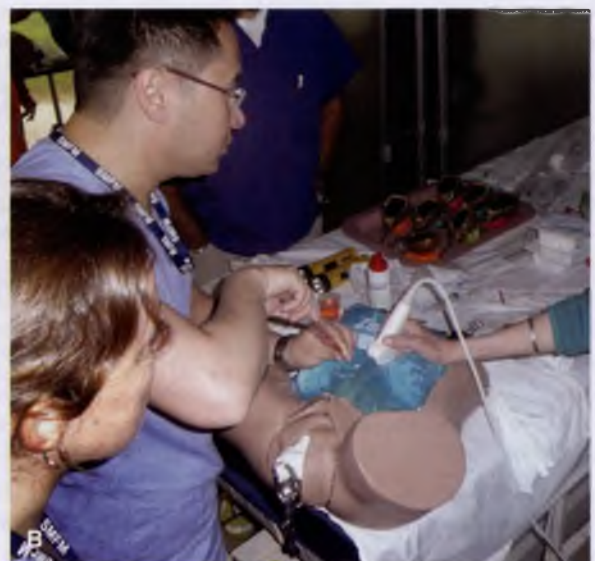
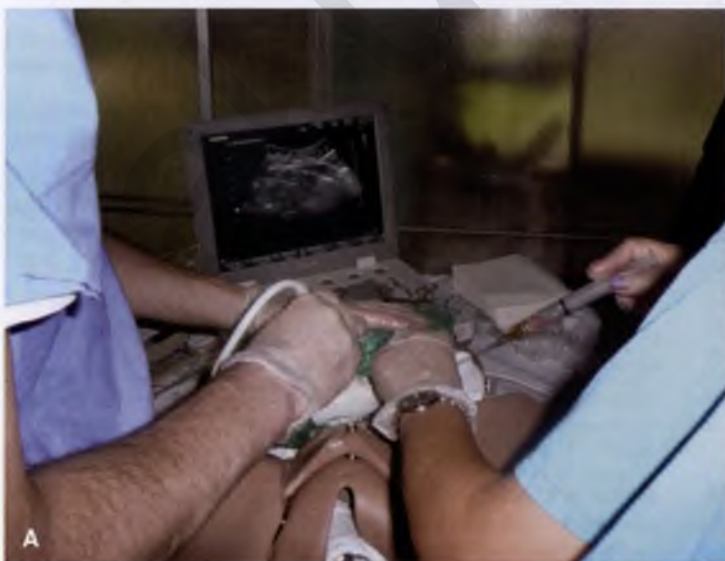
FIGURE 6-10 Sonography-guided procedure training. A container of echolucent gel is used to simulate an amniotic cavity for transabdominal chorionic villus sampling (A) or periumbilical blood sampling (B).

Board of Obstetrics and Gynecology allowed approved continuing medical education courses that are simulation based to be incorporated into their MOC program. In the future, obstetric simulations likely will be a part of the training and performance evaluation of future obstetricians.

REFERENCES

- Accreditation Council for Graduate Medical Education: Obstetrics and gynecology case logs: national data report 2013-2014. Available at: https://www.acgme.org/acgmeweb/Portals/0/OBGYN_National_Report_Program_Version.pdf. Accessed November 12, 2015
- American Board of Obstetrics and Gynecol 2016 bulletin for maintenance of certification for basic certification diplomates. 2016. Available at: <https://www.abog.org/bulletins/MOC2016.pdf>. Accessed July 10, 2016
- American College of Obstetricians and Gynecologists: Preparing for clinical emergencies in obstetrics and gynecology. Committee Opinion No. 590, March 2014
- American College of Obstetricians and Gynecologists: Simulations Working Group. Available at: <http://www.acog.org/About-ACOG/ACOG-Departments/Simulations-Consortium>. Accessed June 21, 2016
- Andreatta P, Frankel J, Boblick et al: Interdisciplinary team training identifies discrepancies in institutional policies and practices. *Am J Obstet Gynecol* 205(4):298, 2011
- Atilakos G, Draycott T, Gale A, et al (eds): *ROBuST: RCOG operative birth simulation training: course manual*. Cambridge, Cambridge University Press, 2014
- Auguste TC, Boswick JA, Loyd MK, et al: The simulation of an ex utero intrapartum procedure to extracorporeal membrane oxygenation. *J Pediatr Surg* 46(2):395, 2011
- Birsner ML, Satin AJ: Developing a program, a curriculum, a scenario. *Semin Perinatol* 37(3):175, 2013
- Burden C, Preshaw J, White P, et al: Validation of virtual reality simulation for obstetric ultrasonography: a prospective cross-sectional study. *Simul Healthc* 7(5):269, 2012
- Callaghan WM, Creanga AA, Kuklina EV: Severe maternal morbidity among delivery and postpartum hospitalizations in the United States. *Obstet Gynecol* 120(5):1029, 2012
- Crofts JF, Bartlett C, Ellis D, et al: Training for shoulder dystocia: a trial of simulation using low-fidelity and high-fidelity mannequins. *Obstet Gynecol* 108(6):1477, 2006
- Crofts JF, Fox R, Ellis D, et al: Observations from 450 shoulder dystocia simulations: lessons for skills training. *Obstet Gynecol* 112(4):906, 2008
- Deering S, Brown J, Hodor J, et al: Simulation training and resident performance of singleton vaginal breech delivery. *Obstet Gynecol* 107(1):86, 2006
- Deering S, Poggi S, Macedonia C, et al: Improving resident competency in the management of shoulder dystocia with simulation training. *Obstet Gynecol* 103(6):1224, 2004
- Deering S, Rosen MA, Salas E, et al: Building team and technical competency for obstetric emergencies: the mobile obstetric emergencies simulator (MOES) system. *Simul Healthc* 4(3):166, 2009
- Deering SH, Weeks L, Benedetti T: Evaluation of force applied during deliveries complicated by shoulder dystocia using simulation. *Am J Obstet Gynecol* 204(3):234e1, 2011
- DeStephano CC, Chou B, Patel S, et al: A randomized controlled trial of birth simulation for medical students. *Am J Obstet Gynecol* 213(1):91.e1, 2015
- Dijkman A, Huisman CM, Smit M, et al: Cardiac arrest in pregnancy: increasing use of perimortem cesarean section due to emergency skills training. *BJOG* 117(3):282, 2010
- Eskander R, Beall M, Ross MG: Vacuum-assisted vaginal delivery simulation—quantitation of subjective measures of traction and detachment forces. *J Matern Fetal Neonatal Med* 25(10):2039, 2012
- Fialkow MF, Adams CR, Carranza L, et al: In situ standardized patient-based simulation to train postpartum hemorrhage and team skills on a labor and delivery unit. *Simul Healthc* 9(1):65, 2014
- Fisher N, Bernstein PS, Satin A, et al: Resident training for eclampsia and magnesium toxicity management: simulation or traditional lecture? *Am J Obstet Gynecol* 203(4):379e1, 2010
- Fisher N, Eisen LA, Bayya JV, et al: Improved performance of maternal-fetal medicine staff after maternal cardiac arrest simulation-based training. *Am J Obstet Gynecol* 205(3):239e1, 2011
- Fransen AF, van de Ven J, Merien AE, et al: Effect of obstetric team training on team performance and medical technical skills: a randomised controlled trial. *BJOG* 119(11):1387, 2012
- Gardner R, Raemer DB: Simulation in obstetrics and gynecology. *Obstet Gynecol Clin North Am* 35(1):97, 2008
- Goffman D, Heo H, Pardanani S, et al: Improving shoulder dystocia management among resident and attending physicians using simulations. *Am J Obstet Gynecol* 199(3):294e1, 2008
- Guise JM, Mladenovic J: In situ simulation: identification of systems issues. *Semin Perinatol* 37(3):161, 2013
- Holmstrom SW, Downes K, Mayer JC, et al: Simulation training in an obstetric clerkship: a randomized controlled trial. *Obstet Gynecol* 118(3):649, 2011
- Issenberg SB, McGaghie WC, Petrusa ER, et al: Features and uses of high-fidelity medical simulations that lead to effective learning: a BEME systematic review. *Med Teach* 27(1):10, 2005
- Karkowsky CE, Chazotte C: Simulation: improving communication with patients. *Semin Perinatol* 37(3):157, 2013
- Lipman SS, Carvalho B, Cohen SE, et al: Response times for emergency cesarean delivery: use of simulation drills to assess and improve obstetric team performance. *J Perinatol* 33(4):259, 2013
- Lipman SS, Daniels KI, Arafah J, et al: The case for OBLS: a simulation-based obstetric life support program. *Semin Perinatol* 35(2):74, 2011
- Lipman SS, Daniels KI, Carvalho B, et al: Deficits in the provision of cardiopulmonary resuscitation during simulated obstetric crises. *Am J Obstet Gynecol* 203(2):179e1, 2010
- Macedonia CR, Gherman RB, Satin AJ: Simulation laboratories for training in obstetrics and gynecology. *Obstet Gynecol* 102(2):388, 2003
- Marshall NE, Vanderhoeven J, Eden KB, et al: Impact of simulation and team training on postpartum hemorrhage management in non-academic centers. *J Matern Fetal Neonatal Med* 28(5):495, 2015
- Maslovitz S, Barkai G, Lessing JB, et al: Improved accuracy of postpartum blood loss estimation as assessed by simulation. *Acta Obstet Gynecol Scand* 87(9):929, 2008
- Maslovitz S, Barkai G, Lessing JB, et al: Recurrent obstetric management mistakes identified by simulation. *Obstet Gynecol* 109(6):1295, 2007
- Merien AE, van de Ven J, Mol BW, et al: Multidisciplinary team training in a simulation setting for acute obstetric emergencies: a systematic review. *Obstet Gynecol* 115(5):1021, 2010
- Nitsche JF, Brost BC: A cervical cerclage task trainer for maternal-fetal medicine fellows and obstetrics/gynecology residents. *Simul Healthc* 7(5):321, 2012
- Nitsche JF, Brost BC: Obstetric ultrasound simulation. *Semin Perinatol* 37(3):199, 2013a
- Nitsche JF, Brost BC: The use of simulation in maternal-fetal medicine procedure training. *Semin Perinatol* 37(3):189, 2013b
- Pratt SD: Focused review: simulation in obstetric anesthesia. *Anesth Analg* 114(1):186, 2012
- Sampson CS, Renz NR, Wagner JC: An inexpensive and novel model for perimortem cesarean section. *Simul Healthc* 8(1):49, 2013
- Scholz C, Mann C, Kopp V, et al: High-fidelity simulation increases obstetric self-assurance and skills in undergraduate medical students. *J Perinat Med* 40(6):607, 2012
- Siassakos D, Draycott T, O'Brien K, et al: Exploratory randomized controlled trial of hybrid obstetric simulation training for undergraduate students. *Simul Healthc* 5(4):193, 2010
- Siassakos D, Hasafa Z, Sibanda T, et al: Retrospective cohort study of diagnosis-delivery interval with umbilical cord prolapse: the effect of team training. *BJOG* 116(8):1089, 2009
- Siddiqui NY, Stepp KJ, Lasch SJ, et al: Objective structured assessment of technical skills for repair of fourth-degree perineal lacerations. *Am J Obstet Gynecol* 199(6):676e1, 2008
- Society for Simulation in Healthcare: About simulation. Available at: <http://www.ssih.org/About-Simulation>. Accessed November 12, 2015
- Straub HL, Morgan G, Ochoa P, et al: Targeted obstetric hemorrhage programme improves incoming resident confidence and knowledge. *J Obstet Gynaecol* 33(8):798, 2013
- Tucker Edmonds B, McKenzie F, Fadel WF, et al: Using simulation to assess the influence of race and insurer on shared decision making in periviable counseling. *Simul Healthc* 9(6):353, 2014
- Uppal S, Harmanli O, Rowland J, et al: Resident competency in obstetric anal sphincter laceration repair. *Obstet Gynecol* 115(2 Pt 1):305, 2010
- Walker D, Cohen S, Fritz J, et al: Team training in obstetric and neonatal emergencies using highly realistic simulation in Mexico: impact on process indicators. *BMC Pregnancy Childbirth* 14(1):367, 2014

CHAPTER 7

Critical Illness in Pregnancy

MATERNAL MORTALITY	91
SEPSIS	92
RESPIRATORY FAILURE	95
HEMORRHAGE	97
CARDIAC DISEASE	99
HEMODYNAMIC MONITORING	102
CARDIAC ARREST	103
FETAL CONSIDERATIONS WITH MATERNAL CRITICAL ILLNESS	106

Critical illness in pregnancy is relatively rare. Current studies estimate the incidence of intensive care unit (ICU) admissions in pregnancy and the puerperium to range between 0.7 and 13.5 events per 1000 deliveries (Pollock, 2010). Most of these admissions are postpartum, and obstetric complications account for between 55 and 90 percent. The most common indications are hypertensive disorders of pregnancy, hemorrhage, and sepsis (Baskett, 2008; Chantry, 2008; Orsini, 2012; Pollock, 2010). Nonobstetric indications for ICU admission include maternal cardiovascular disease, pulmonary disease, cerebrovascular accidents, trauma, and anesthetic complications (Wanderer, 2013; Zwart, 2010).

This chapter provides an overview of the most commonly seen conditions in the critically ill pregnant and postpartum woman. Moreover, some less common disorders that an obstetrician would be expected to be familiar with will also be briefly presented.

MATERNAL MORTALITY

To understand maternal mortality rates, an understanding of the terms used to report maternal deaths is essential. The International Code of Diseases (ICD-10) and the World Health Organization (WHO) (2010) define *maternal death* as “the death of a woman while pregnant or within 42 days of termination of pregnancy, irrespective of the duration and site of the pregnancy, from any cause related to or aggravated by pregnancy or its management, but not from incidental or accidental causes.” A *pregnancy-related death* is defined as “the death of a woman while pregnant or within 1 year of termination of pregnancy irrespective of the duration or site of the pregnancy from complications of pregnancy, a chain of events initiated by pregnancy, or aggravation of an unrelated event or condition by the physiologic effects of pregnancy.” Of other terms, the *maternal mortality ratio (MMR)* is the number of maternal deaths per 100,000 live births. The *pregnancy-related mortality ratio* is defined as the number of pregnancy-related deaths per 100,000 live births.

Globally, maternal mortality rates have been decreasing by 1.3 percent per year since 1990 (Kassebaum, 2014). In 2013, the global MMR was 209 deaths per 100,000 live births. This number was lowest—12.1—in the developed world. The highest ratio was seen in Western sub-Saharan Africa, where the MMR was 468.9. Globally, obstetric causes such as hemorrhage, hypertension, and sepsis were responsible for 72 percent of maternal deaths. Other indirect causes such as human immunodeficiency virus (HIV) and other preexisting conditions were responsible for 28 percent (Say, 2014).

In the United States, the pregnancy-related mortality ratio in 2013 was 18.5 deaths per 100,000 live births (Kassebaum, 2014). Despite a significant decline in the maternal mortality rate during the 20th century, the pregnancy-related mortality ratio has climbed since 1987, when the ratio was 7.2 (Berg, 1996; Creanga, 2015). It is unclear if this is a true increase in

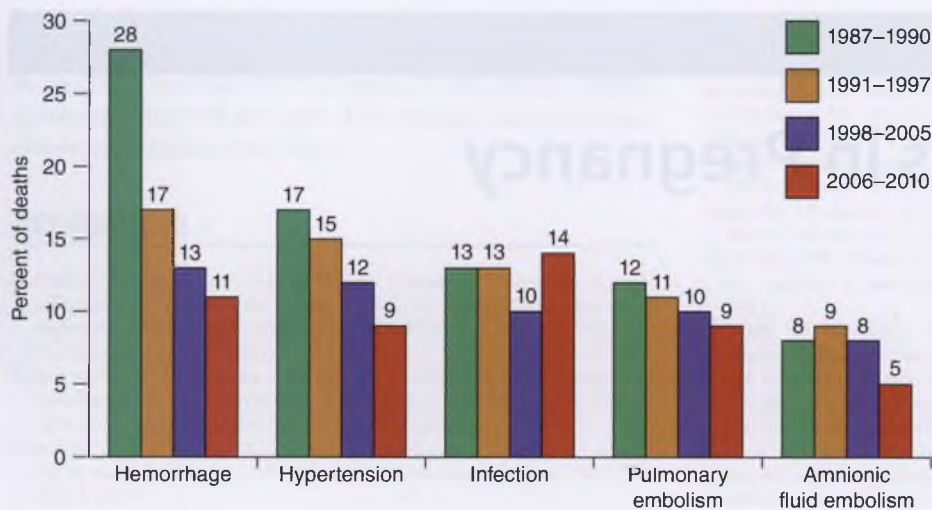


FIGURE 7-1 Cause-specific proportionate pregnancy-related mortality: United States 1987–2010. (Data from Creanga AA, Berg CJ, Syverson C, et al: Pregnancy-related mortality in the United States, 2006–2010. *Obstet Gynecol* 125(1):5, 2015.)

pregnancy-related mortality rates or whether this rise reflects improved ascertainment of cases. Examples include changes to death certificates and to insurance coding. Likely, it is from a combination of factors.

Unfortunately, a large racial disparity persists in pregnancy-related mortality rates in the United States. The pregnancy-related mortality ratio for black women is more than three times greater than that for white women—38.9 versus 12.0 deaths per 100,000 live births, respectively (Creanga, 2015).

Of specific etiologies, the leading causes of maternal mortality in 2010 were cardiovascular disease (14.6 percent), infection (13.6 percent), noncardiovascular medical conditions (12.7 percent), cardiomyopathy (11.8 percent), and hemorrhage (11.4 percent) (Creanga, 2015). As can be seen in [Figure 7-1](#), maternal mortality rates from hemorrhage and hypertensive disorders of pregnancy have significantly declined. In contrast, deaths from cardiovascular disease have steadily risen.

Several other parameters are noteworthy. First, pregnancy-related mortality ratios increase with increasing maternal age. Second, according to Creanga and colleagues (2015), most deaths occur on the day of delivery or pregnancy termination (16 percent), within 1 to 6 days (21 percent), or from 17 to 42 days (26 percent). Only 23 percent of deaths occurred antepartum and the remaining 14 percent after 42 days. Last, pregnancy-related deaths may complicate ectopic pregnancy, spontaneous abortion, or induced abortion. Between 2006 and 2010, approximately 6 percent of deaths were attributed to these failed pregnancies.

■ Maternal Mortality and Critical Illness

ICU admission rates appear to be similar between the developing world and the developed world. However, the maternal mortality rate associated with these admissions is significantly higher in the developing world—median 14 versus 3.4 percent (Pollock, 2010).

To predict survival, many different scoring systems have been created for individuals admitted to the ICU. These systems include the Acute Physiology and Chronic Health Evaluation (APACHE) and the Simplified Acute Physiology

Score (SAPS). These grading schemes were developed in non-pregnant ICU patients. Thus, they do not account for the physiologic changes of pregnancy or the self-limited nature of many obstetric complications such as preeclampsia. When the APACHE and SAPS scores are applied to a pregnant ICU population, the risk of mortality and the severity of illness are significantly overestimated (Gilbert, 2003; Stevens, 2006; Vasquez, 2007).

In critically ill pregnant women with severe sepsis or septic shock, other scoring classifications such as the Modified Early Warning Score (MEWS) and Systemic Inflammatory Response Syndrome (SIRS) criteria have been applied in an attempt to predict disease severity. However, the normal physiologic parameters of pregnancy overlap significantly with these scores, making them unreliable for predicting adverse events in a critically ill pregnant cohort (Bauer, 2014; Edwards, 2015). Thus, additional data are needed to accurately predict risk of ICU admission, disease severity, and mortality risk in the obstetric population.

Recently, a scoring system specific to critically ill gravidas has been proposed to predict illness severity. The Sepsis in Obstetrics Score (SOS), shown in [Table 7-1](#), collects data such as maternal temperature, pulse, and blood pressure to generate a score. Patients with a score ≥ 6 —out of a possible 28—have been reliably identified as being at high risk for ICU admission (Albright, 2014). Although promising, the SOS score requires future prospective validation.

SEPSIS

■ Epidemiology

Sepsis develops in approximately 1 of every 3500 hospitalizations for delivery in the United States. It is the leading cause of direct maternal deaths in the United Kingdom (Bauer, 2013; Cantwell, 2011). Unlike in the general population, infections in pregnant and postpartum women tend to be polymicrobial from organisms that compose the normal vaginal flora (Barton, 2012). Chorioamnionitis, endometritis, pneumonia, and pyelonephritis are the most frequent serious infections

TABLE 7-1. Sepsis in Obstetrics Scoring System

Variable	High Abnormal Range				Normal	Low Abnormal Range			
	+4	+3	+2	+1		+1	+2	+3	+4
Score	+4	+3	+2	+1	0	+1	+2	+3	+4
Temperature (°C)	>40.0	39–40.9		38.5–38.9	36–38.4	34–35.9	32–33.9	30–31.9	<30
SBP (mm Hg)					>90		70–90		<70
Heart rate (bpm)	>179	150–179	130–149	120–129	≤119				
Respiratory rate ^a	>49	35–49		25–34	12–24	10–11	6–9		≤5
Sp _o ₂ (%)					≥92	90–91		85–89	<85
WBC (per μL)	>39.9		25–39.9	17–24.9	5.7–16.9	3–5.6	1–2.9		<1
Immature neutrophils (%)			≥10		<10				
Lactic acid (mmol/L)			≥4		<4				

^aBreaths per minute.

bpm = beats per minute; SBP = systolic blood pressure; Sp_o₂ = peripheral capillary oxygen saturation; WBC = white blood cell count.

Data from Albright, 2014.

(Bauer, 2013). The most common organisms include *Escherichia coli*; group A and B streptococci; *Staphylococcus aureus*—both methicillin-sensitive and methicillin-resistant; *Streptococcus pneumoniae*; and various gram-negative rods (Acosta, 2014; Bauer, 2013; Knowles, 2015). Infections resulting from Group A β-hemolytic streptococcus and *E coli* are among those most commonly associated with maternal death (Acosta, 2014; Kramer, 2009; Mabie, 1997).

■ Definition

In 1992, the American College of Chest Physicians and the Society of Critical Care Medicine (ACCP-SCCM) introduced definitions for sepsis-related disorders. These have been generally adopted and used in practice by clinicians and investigators (Bone, 1992; Levy, 2003). SIRS describes an inflammatory response that may be due to several etiologies including infection, trauma, or burns.

The criteria for SIRS are shown in [Table 7-2](#). A woman meets criteria for sepsis if she has two or more SIRS criteria and a known or suspected infection. True sepsis is a continuum that progresses to severe sepsis with the development of organ dysfunction, hypoperfusion abnormality, or sepsis-induced hypotension. *Septic shock* is a subset of severe sepsis defined as sepsis-induced hypotension that persists despite adequate fluid resuscitation and that is accompanied by hypoperfusion abnormalities or by organ dysfunction. Hypoperfusion abnormalities

include, but are not limited to, lactic acidosis, oliguria, or an acutely altered mental status (Barton, 2012; Bone, 1992).

The Surviving Sepsis Campaign has established guidelines for sepsis management in nonpregnant patients. In 2012, updated guidelines for diagnosis and management of severe sepsis and septic shock for the general population were issued (Dellinger, 2013). These guidelines were formed by a consensus committee of 68 experts representing 30 international organizations. This chapter selectively addresses some of the important considerations in management of sepsis in pregnancy.

■ Diagnosis

Since the introduction of this definition of sepsis, the Surviving Sepsis Campaign has set forth extended specifications for the diagnosis of sepsis to improve diagnostic accuracy. [Table 7-3](#) shows these extended diagnostic measures. The Campaign has also set forth criteria for the diagnosis of severe sepsis, which are shown in [Table 7-4](#).

■ Management

The Surviving Sepsis Campaign has developed bundles to be performed within 3 and 6 hours of admission. These bundles focus on timely antibiotic administration and volume status reassessment. [Table 7-5](#) shows the 3-hour and 6-hour sepsis bundles.

TABLE 7-2. Criteria for Systemic Inflammatory Response Syndrome (SIRS)

Two or more of the following:

Body temperature >38°C or <36°C

Heart rate >90 beats per minute

Tachypnea, manifested by a respiratory rate >20 breaths/minute or by a PaCO₂ <32 mm Hg

Alteration in the WBC, such as a count >12,000/mm³, or a count <4000/mm³, or the presence of more than 10% immature neutrophils.

PaCO₂ = partial pressure of carbon dioxide in arterial blood; WBC = white blood cell count.

TABLE 7-3. Extended Criteria for Diagnosis of Sepsis**General variables**

Fever ($>38.3^{\circ}\text{C}$)
 Hypothermia (core temperature $<36^{\circ}\text{C}$)
 Heart rate $>90/\text{min}$ or more than two SD above the normal value for age
 Tachypnea
 Altered mental status
 Significant edema or positive fluid balance ($>20\text{ mL/kg}$ over 24 hr)
 Hyperglycemia (plasma glucose $>140\text{ mg/dL}$ or 7.7 mmol/L) in the absence of diabetes

Inflammatory variables

Leukocytosis (WBC count $>12,000/\mu\text{L}$)
 Leukopenia (WBC count $<4000/\mu\text{L}$)
 Normal WBC count with >10 percent immature forms
 Plasma C-reactive protein >2 SD above the normal value
 Plasma procalcitonin >2 SD above the normal value

Hemodynamic variables

Arterial hypotension (SBP $<90\text{ mm Hg}$, MAP $<70\text{ mm Hg}$, or an SBP decrease $>40\text{ mm Hg}$ in adults or <2 SD below normal for age)

Organ dysfunction variables

Arterial hypoxemia ($\text{PaO}_2/\text{FiO}_2 < 300$)
 Acute oliguria (urine output $<0.5\text{ mL/kg/hr}$ for at least 2 hr despite adequate fluid resuscitation)
 Creatinine increase $>0.5\text{ mg/dL}$ or $44.2\text{ }\mu\text{mol/L}$
 Coagulation abnormalities (INR >1.5 or aPTT $>60\text{ sec}$)
 Ileus (absent bowel sounds)
 Thrombocytopenia (platelet count $<100,000/\mu\text{L}$)
 Hyperbilirubinemia (plasma total bilirubin $>4\text{ mg/dL}$ or $70\text{ }\mu\text{mol/L}$)

Tissue perfusion variables

Hyperlactatemia ($>1\text{ mmol/L}$)
 Decreased capillary refill or mottling

aPTT = active partial thromboplastin time; INR = international normalized ratio; MAP = mean arterial pressure; $\text{PaO}_2/\text{FiO}_2$ = partial pressure oxygen in arterial blood/fraction of inspired oxygen; SBP = systolic blood pressure; SD = standard deviation; WBC = white blood cell count.

Fluid Resuscitation

This is an immediate concern with severe sepsis. Initial resuscitation begins with crystalloid in a volume of 30 mL/kg . Albumin is used for patients who require substantial amounts of crystalloids. Hetastarch is not recommended (Dellinger, 2015). Vasopressors are implemented for patients who fail to respond to volume resuscitation.

The goals of fluid resuscitation include the following: (1) central venous pressure of 8 to 12 mm Hg; (2) mean arterial pressure $>65\text{ mm Hg}$; (3) urine output of $>0.5\text{ mL/kg/hr}$; and (4) central venous oxygen saturation (Scvo_2) or

TABLE 7-4. Criteria for Severe Sepsis**Any of the following thought to be due to infection:**

Sepsis-induced hypotension
 Lactate above upper limits of laboratory normal
 Urine output $<0.5\text{ mL/kg/hr}$ for more than 2 hr despite adequate fluid resuscitation
 Acute lung injury with $\text{PaO}_2/\text{FiO}_2 < 250$ in the absence of pneumonia as infection source
 Acute lung injury with $\text{PaO}_2/\text{FiO}_2 < 200$ in the presence of pneumonia as infection source
 Creatinine $>2.0\text{ mg/dL}$ ($176.8\text{ }\mu\text{mol/L}$)
 Bilirubin $>2\text{ mg/dL}$ ($34.2\text{ }\mu\text{mol/L}$)
 Platelet count $<100,000/\mu\text{L}$
 Coagulopathy (international normalized ratio >1.5)

$\text{PaO}_2/\text{FiO}_2$ = partial pressure oxygen in arterial blood/fraction of inspired oxygen.
 From Dellinger, 2013.

TABLE 7-5. Three- and Six-hour Sepsis Bundles**Within 3 hr of presentation:**

Measure lactate level
 Obtain blood cultures prior to antibiotics
 Give broad-spectrum antibiotics
 Give 30 mL/kg fluid bolus of crystalloid for hypotension or lactate $\geq 4\text{ mmol/L}$

Within 6 hr of presentation:

If MAP $<65\text{ mm Hg}$ after initial fluid resuscitation:
 Vasopressors to maintain a MAP of $\geq 65\text{ mm Hg}$
 Reassess volume status and tissue perfusion
 If lactate elevated at 3 hr:
 Repeat lactate level
 If initial lactate $\geq 4\text{ mmol/L}$ reassess volume status and tissue perfusion.

After initial fluid resuscitation, focused examination:

Vital signs
 Cardiopulmonary status
 Capillary refill
 Pulse
 Skin findings

or

Two or more of the following:

Measure CVP
 Measure Scvo_2
 Bedside cardiovascular ultrasound
 Dynamic assessment of fluid responsiveness with passive leg raise or fluid challenge

CVP = central venous pressure; MAP = mean arterial pressure; Scvo_2 = central venous oxygen saturation.
 Adapted from Society of Critical Care Medicine, 2015.

mixed venous oxygen saturation (SvO_2) of 70 or 65 percent, respectively.

Antimicrobial Therapy

Intravenous antibiotic therapy is initiated promptly and within the first hour after recognition of septic shock and severe sepsis. In septic shock, each hour delay in administering effective antibiotics is associated with a 7.6-percent rise in the mortality rate (Dellinger, 2013; Kumar, 2006). Blood cultures and site-specific cultures are obtained before antimicrobial therapy is begun as long as doing so does not delay treatment longer than 45 minutes. The patient is prescribed a broad-spectrum antibiotic until agent selection can be refined once cultures are available (Barton, 2012; Pacheco, 2014). In pregnant women, the most likely bacteria are gram-negative rods and group A or group B streptococci. Therefore, antibiotic coverage should include formulations to treat these organisms.

Vasopressors

In the nonpregnant population, norepinephrine is recommended as the first-line agent in patients with septic shock not responsive to adequate fluid resuscitation (Barton, 2012; Dellinger, 2013). If norepinephrine and fluid therapy fail to correct hypotension, second-line vasopressors are used. Second-line agents include epinephrine and vasopressin.

RESPIRATORY FAILURE

Respiratory failure is a rare complication of pregnancy and develops in less than 0.1 percent of births (Chen, 2003). Causes of respiratory failure include pulmonary edema (cardiogenic and noncardiogenic), pneumonia, embolism (pulmonary, amniotic fluid, or venous air), asthma, and acute respiratory distress syndrome (ARDS). Pregnancy-specific causes include amniotic fluid embolism and pulmonary edema due to tocolytics or preeclampsia (Abdel-Razeq, 2011; Mighty, 2010).

Respiratory failure can be categorized as hypoxemic or as hypercapnic. In obstetric patients, hypoxemic respiratory failure is more frequently encountered. It develops when the arterial partial pressure of oxygen is low but the partial pressure of carbon dioxide is normal. This stems from an inability of the lungs to oxygenate blood. The most common cause is a ventilation-perfusion mismatch, which when taken to its most extreme manifestation is called a shunt. Ventilation-perfusion mismatch can develop if some portion of oxygenated blood from the heart does not communicate effectively with the alveoli. Shunts, on the other hand, occur when blood either bypasses the lungs—as

in Eisenmenger syndrome—or flows past alveoli that are not ventilated—as with atelectasis. Ventilation-perfusion mismatch often responds to oxygen therapy, whereas a shunt does not. Common causes of hypoxemic respiratory failure include pulmonary embolism, pulmonary edema, aspiration, pneumonia, ARDS, and pneumothorax.

In contrast, hypercapnic respiratory failure results from a failure of ventilation (CO_2 exchange) due to airflow obstruction, decreased respiratory drive, or respiratory muscle weakness. This can be seen in patients with severe asthma, drug overdose including magnesium sulfate, and neuromuscular disorders such as myasthenia gravis.

Physiologic Changes of Pregnancy

During pregnancy, several physiologic changes involve the respiratory system and can affect management of respiratory failure. First, an increase in the subcostal angle and elevation of the diaphragm leads to decreased chest compliance. Additionally, the rise in intraabdominal pressure and decrease in esophageal sphincter tone results in a greater risk of aspiration. Also, the normal decline in functional residual capacity promotes alveolar collapse, and the physiologic increase in minute ventilation creates a lower partial pressure of carbon dioxide (PCO_2). The net sum is respiratory alkalosis with a normal pH, low PCO_2 , and low HCO_3^- level. The PaO_2 tends to be higher than in a nonpregnant individual, but studies have found that this varies based on altitude (Hankins, 1996). Because the PCO_2 is lower in gravidas than in nonpregnant individuals, a “normal” PCO_2 can be a sign of inadequate ventilation and should not be considered reassuring (Mighty, 2010). [Table 7-6](#) compares arterial blood gas measurements in pregnant and nonpregnant women.

Acute Respiratory Distress Syndrome

This syndrome describes severe acute hypoxemic respiratory failure resulting from various pulmonary injuries. Importantly, in women with suspected ARDS, the diagnosis of cardiogenic pulmonary edema should first be excluded, as the treatment approach is very different. In 2012, the diagnostic specifications for ARDS were changed based on recommendations from a consensus conference. The primary conference objectives were to improve the reliability, validity, and feasibility of the ARDS diagnostic parameters. Known as the *Berlin criteria*, three mutually exclusive categories were created that classified ARDS as mild, moderate, or severe based on the degree of hypoxemia. They define ARDS as respiratory failure “within one week of a known clinical insult or new/worsening respiratory symptoms

TABLE 7-6. Normal Arterial Blood Gas Values in Pregnant and Nonpregnant Women

	pH	PCO_2 (mm Hg)	PO_2 (mm Hg)	HCO_3^- (mmol/L)	O_2 Saturation (%)
Pregnant	7.4–7.46	26–32	75–106	18–21	95–100
Nonpregnant	7.38–7.42	38–45	70–100	24–31	95–100

PCO_2 = partial pressure of carbon dioxide; PO_2 = partial pressure of oxygen.
Data from Dildy, 2004.

TABLE 7-7. The Berlin Definition of Acute Respiratory Distress Syndrome (ARDS)

Factor	Acute Respiratory Distress Syndrome		
Timing	Within 1 week of a known clinical insult or new/worsening respiratory symptoms		
Chest imaging ^a	Bilateral opacities—not fully explained by effusions, lobar/lung collapse, or nodules		
Origin of edema	Respiratory failure not fully explained by cardiac failure or fluid overload; need objective assessment (e.g., echocardiography) to exclude hydrostatic edema if no risk factor present		
	Mild	Moderate	Severe
Oxygenation ^b	200 < Pao ₂ /Fio ₂ ≤ 300 with PEEP or CPAP ≥ 5 cm H ₂ O	100 < Pao ₂ /Fio ₂ ≤ 200 with PEEP ≥ 5 cm H ₂ O	Pao ₂ /Fio ₂ ≤ 100 with PEEP ≥ 5 cm H ₂ O

^aChest radiography or computed tomography.

^bMay be delivered noninvasively with mild ARDS.

CPAP = continuous positive airway pressure; Pao₂/Fio₂ = partial pressure oxygen in arterial blood/fraction of inspired oxygen; PEEP = positive end-expiratory pressure.

with bilateral opacities not fully explained by effusions, lobar/lung collapse or nodules. The respiratory failure must not be fully explained by cardiac failure or fluid overload.” An echocardiogram is considered to exclude a cardiogenic cause if the source of ARDS is not clear (ARDS Definition Task Force, 2012; Ferguson, 2012; Mehta, 2015). Definitions of mild, moderate, and severe ARDS are shown in [Table 7-7](#).

■ Treatment

Antepartum or postpartum acute respiratory failure is ideally managed in conjunction with an intensive care expert and maternal-fetal medicine specialist. Treatment goals strive to restore ventilation and oxygenation. In a woman who is able to protect her airway and has only mild respiratory distress, supplemental oxygen may be the sole requirement. As shown in [Table 7-8](#), options for noninvasive oxygen supplementation include nasal cannula, various types of face masks, continuous positive airway pressure (CPAP), and noninvasive positive-pressure ventilation (NPPV). NPPV differs from CPAP in that it assists with ventilation as well as provides intermittent positive airway pressure (Gregoretti, 2015).

Intubation is indicated in those with hypercapnic or hypoxemic respiratory failure that does not respond adequately to supplemental oxygen, as well as in those who cannot protect

their airway. The indications are generally the same as those in nonpregnant individuals. Importantly, as noted earlier, normal PCO₂ values are lower in gravidas, and thus intubation is indicated at a lower PCO₂.

Tools and technique for intubation in the gravida are described in Chapter 19 (p. 311). Failed intubation occurs approximately eight times more often in a pregnant woman because of anatomic changes to the airway. Because of this, intubation is best performed by the most skilled person (Guntupalli, 2015). Moreover, those with potentially difficult intubations are ideally identified early. As discussed and illustrated in Chapter 18 (p. 293), preparations can be made to accommodate the woman with a challenging airway.

Mechanical Ventilation

Several different ventilator modes can be used for mechanical ventilation. These settings can be categorized as volume-limited modes, pressure-limited modes, or a combination of the two. In volume-limited modes, the tidal volume is preset, and the ventilator provides a predetermined tidal volume with each breath. In this mode, the airway pressures are allowed to vary, and this guarantees a minimum minute ventilation. As a reminder, minute ventilation = tidal volume × respiratory rate.

In pressure-limited modes, a preset positive-pressure level is given with each breath, and the tidal volume is allowed to vary. In pressure-targeted modes, the peak airway pressures are limited to reduce the risk for barotrauma. An example of a pressure-targeted mode is pressure support ventilation, which requires the patient to initiate spontaneous breaths. Another is pressure-control mode, in which a respiratory rate is preset (Grossbach, 2011).

In addition, the patient's ability to take spontaneous breaths can be accommodated. Listed here in order of increasing patient autonomy, modes are controlled mechanical ventilation (CMV), assist control (AC), and intermittent mandatory ventilation (IMV). All of these can be set as either volume limited or pressure limited. With CMV, the patient does not perform any of the work of breathing. Respiratory rate and tidal volume or peak airway pressure are set by the provider. With AC, a minimum respiratory rate is set, but the patient is able to

TABLE 7-8. Noninvasive Oxygen Delivery Systems

System	Oxygen Flow (liters/min)	Fio ₂
Nasal cannula	1–6	0.21–0.44
Simple face mask	5–10	0.3–0.6
Partial rebreather mask	8–12	0.4–0.7
Nonrebreather mask	10–15	0.6–0.8
Venturi mask	4–12	0.24–0.5

Fio₂ = fraction of inspired oxygen.

Data from Pruitt, 2003.

trigger additional ventilator-assisted breaths. Last, with IMV, a minimum respiratory rate is once again predetermined, and the patient is able to initiate additional breaths. However, unlike AC, these breaths are not assisted by the ventilator. Synchronized intermittent mechanical ventilation (SIMV) is a variation of IMV, and breaths are synchronized with patient effort (Grossbach, 2011).

Traditionally, the goal of mechanical ventilation has been to achieve a tidal volume of 10 to 15 mL/kg of ideal body weight. In 2000, the Acute Respiratory Distress Syndrome Network (ARDSNet) published the results of a randomized controlled trial in which patients were randomized to different tidal volume groups. In one cohort, a traditional tidal volume (12 mL/kg) with a peak pressure of 50 cm H₂O was compared against a low tidal volume (6 mL/kg) with a peak pressure of 30 cm H₂O. Mean peak pressures were 33 ± 8 cm of water in the traditional tidal volume group versus 25 ± 6 cm in the low tidal volume group. Of results, the low tidal volume group had a lower mortality rate—31 versus 40 percent—and more days off the ventilator in the first 28 hospital days—12 versus 10 days.

Extracorporeal Membrane Oxygenation

For women with severe ARDS refractory to mechanical ventilation, options are limited. Of these, extracorporeal membrane oxygenation (ECMO) in this population has shown some success. As an overview, ECMO functions by removing blood, adding O₂, and removing CO₂ before returning it to the circulation. For patients with ARDS, this is often accomplished by venovenous bypass, in which blood is removed from the inferior vena cava (IVC) and returned to the superior vena cava. For this, the patient must be fully anticoagulated. This method does not provide any hemodynamic support. In patients with cardiac failure, venoarterial bypass can be used. In this form of ECMO, blood is removed from the venous system, oxygenated, and then returned to the arterial system, bypassing the heart and lungs. This form of ECMO is associated with a much higher complication rate.

Several studies have found that referral to an ECMO center for patients with severe ARDS results in lower mortality rates and improved outcomes (Duarte, 2014). However, data on the use of ECMO in pregnancy are limited. In one series of 12 pregnant or postpartum women in Australia and New Zealand treated with ECMO during the H1N1 influenza outbreak, 66 percent of patients survived. Of the four deaths, three were from bleeding, which was intracranial, pulmonary, or generalized (Nair, 2011).

■ Amnionic Fluid Embolism

Amnionic fluid embolism is a rare but often catastrophic complication of pregnancy. Accurate data on prognosis after this event are difficult to determine due to the varying methods of case ascertainment. Maternal mortality rate estimates currently range from 20 to 60 percent (Clark, 2014). Between 2006 and 2010, amnionic fluid embolism was responsible for 5.3 percent of pregnancy-related deaths in the United States (Creanga, 2015).

Clinical characteristics include acute hypoxia, hypotension, and coagulopathy during labor, delivery, or within 30 minutes of delivery. Risk factors include induction of labor, cervical

laceration, placenta previa, placental abruption, advanced maternal age, and cesarean delivery (Ballinger, 2015; Clark, 2014; Knight, 2012).

The syndrome is a clinical diagnosis and assigned once other potential causes have been excluded. The presence of fetal squamous cells and debris in the pulmonary circulation is nonspecific and is not pathognomonic for amnionic fluid embolism. Studies of women with pulmonary artery catheters suggest that squamous cells may be a normal finding in the maternal pulmonary circulation (Clark, 1986; Lee, 1986).

The pathophysiology of amnionic fluid embolism is poorly understood. Current theories implicate an immunologic response to an unknown factor in amnionic fluid, fetal cells, or placental cells that enters the maternal circulation. The clinical response resembles the response observed with septic shock and anaphylactic shock, which supports a potential immunologic basis (Clark, 1995).

There is no definitive treatment, and management is supportive. Ventilatory support and oxygenation, volume resuscitation, vasopressor support, and correction of coagulopathy with transfusion of red cells and clotting factors remain the primary approach. If the woman remains undelivered, then perimortem cesarean delivery may be indicated if cardiac arrest occurs (p. 106).

HEMORRHAGE

Obstetric hemorrhage accounted for 11.4 percent of maternal deaths in the United States from 2006 to 2010 and is responsible for a significant portion of ICU admissions in obstetric patients (Creanga, 2015; Wanderer, 2013; Zwart, 2010). Importantly, as many as 90 percent of these deaths may be preventable (Berg, 2005). As described in Chapter 29 (p. 466), obstetric hemorrhage can be defined by several parameters. Three that are often used include blood loss >500 mL after a vaginal delivery and >1000 mL after cesarean delivery; need for blood transfusion; or >10 percent drop in hematocrit (American College of Obstetricians and Gynecologists, 2015b). Due to the physiologic changes of pregnancy, hemodynamic response to hemorrhage may be subtle until 25 to 30 percent of the circulating blood volume has been lost (~1500 to 1800 mL).

Chapter 29 describes surgical and medical management of obstetric hemorrhage. In this chapter, we focus on management of disseminated intravascular coagulopathy (DIC) and blood replacement strategies.

■ Disseminated Intravascular Coagulopathy

This form of consumptive coagulopathy is a relatively rare pregnancy complication, seen in women with placental abruption, amnionic fluid embolism, sepsis, and hemorrhage (Cunningham, 2015; Erez, 2015). DIC is a consumptive coagulopathy that results from exposure to a procoagulant such as tissue factor. When such procoagulants are released, they activate the clotting cascade, creating plugs or clots of platelets and fibrin. This activation depletes clotting factors and leads to bleeding. As the clots are degraded, the resulting fibrin-degradation products produce further damage and impair perfusion.

Clinically, patients with DIC demonstrate poor clotting. They may bleed spontaneously from puncture sites or surgical incisions and, if intubated, from the nose or mouth. Bleeding can originate intrapartum, from a normally dilated cervix or postpartum from the placenta site. Suspicion for DIC is confirmed by laboratory studies, which include a prolonged prothrombin time (PT) and partial thromboplastin time (PTT), an elevated international normalized ratio (INR), and diminished fibrinogen levels (Butwick, 2015; Erez, 2015).

■ Blood Replacement Strategies

Primary treatment for consumptive coagulopathy that is related to massive obstetric hemorrhage addresses the procoagulant source and blood component replacement. Historically, resuscitation of those with massive hemorrhage was initially performed using large volumes of crystalloid. Packed red blood cells, plasma, cryoprecipitate, and platelets were reserved for those with laboratory abnormalities (Pacheco, 2013). This approach fails to prevent dilutional coagulopathy and may lead to hypothermia and acidosis. Additionally, overuse of crystalloid may lead to increased bleeding due to dislodgement of fresh clots and increased hydrostatic pressure. In the nonobstetric literature, an approach using early replacement with blood products is reported to improve outcomes (Holcomb, 2008). During blood transfusion, it is emphasized that the use of additional components is not necessary until five or more units of blood have been administered.

■ 1:1:1 Blood Product Replacement

Transfusing with 1:1:1 blood product replacement regimen refers to administering components in a ratio of one unit of packed red blood cells (pRBCs) to one unit of fresh frozen plasma (FFP) and one unit of platelets. Even if laboratory values are normal, FFP and platelets are given to prevent coagulopathy from developing. This strategy was crafted from retrospective reviews of military and nonmilitary trauma patients, who showed improved outcomes with this approach (Borgman, 2007; Holcomb, 2008). A randomized controlled trial comparing 1:1:1 transfusion with 2:1:1 composition showed no difference in mortality rates at 24 hours or at 30 days between the two protocols. However, fewer deaths due to exsanguination at 24 hours were found in the 1:1:1 group (Holcomb, 2015). Despite the limited data for a 1:1:1 transfusion regimen, it serves as the basis for many massive transfusion protocols.

■ Massive Transfusion Protocol

These protocols improve outcomes in patients with massive hemorrhage. Their primary benefit centers on providing clinicians with rapid access to blood products and in signaling the severity of the situation to the entire care team. The Safe Motherhood Initiative of District II of the American College of Obstetricians and Gynecologists (2015c) recommends that a massive transfusion protocol be in place at all hospitals providing obstetric care. In addition, every institution should have a minimum of four units of O-negative pRBCs immediately available and the ability to obtain six more units of pRBCs and four units of FFP that are type specific. Platelets and additional products should be

obtainable in a timely manner. The Safe Motherhood Initiative massive transfusion protocol focuses on administering blood products in a 6:4:1 ratio—6 units of pRBCs, 4 units of FFP, and 1 apheresis platelet pack. Many other massive transfusion protocols exist as well (Cunningham, 2015).

Key components of any protocol should include rapid release of products from the blood bank and automatic performance of laboratory tests. When a woman has uncontrolled bleeding, a provider activates the massive transfusion protocol and sends blood specimens for type and crossmatch and for measurement of hemoglobin, platelet, PT, INR, PTT, and fibrinogen levels. Once the massive transfusion protocol has been initiated, two to four units of O-negative uncrossmatched blood can be administered while awaiting crossmatched blood. The blood bank then delivers a massive transfusion pack, usually in a plastic cooler container that remains at the bedside. Products are administered to the patient as necessary. Delivery of blood products continues until the protocol is deactivated.

If the laboratory tests are abnormal, then consideration is given for cryoprecipitate, tranexamic acid, prothrombin complex concentrate, or recombinant factor VIIa (rFVIIa). Cryoprecipitate consists primarily of fibrinogen and factor VIII. It has the same clotting factors as FFP but without the volume. Prothrombin complex concentrate contains factors II, IX, and X, and some preparations also contain factor VII. It is indicated for replacement of vitamin K-dependent clotting factors. Recombinant factor VIIa (Novoseven) is approved for use in hemophiliacs but has been used off-label in massive hemorrhage unresponsive to first-line therapies. It may increase risk of thromboembolic events. Tranexamic acid is an antifibrinolytic agent and is discussed later.

■ Viscoelastic Assays

Thromboelastography (TEG) and rotational thromboelastometry (ROTEM) are point-of-care tests that assess coagulation in whole blood and are designed to guide blood replacement therapy. These tests work by analyzing clot formation and breakdown in whole blood from a given patient. They provide information regarding time to clot formation, clot strength, and fibrinolysis. These can be performed at the bedside and more rapidly than traditional tests of clotting function. Currently, they are being used to guide blood product replacement in trauma, liver transplant, and cardiac surgery patients.

Studies of TEG and ROTEM techniques in gravidas have confirmed the hypercoagulable state of pregnancy and provide reference ranges for use in this population (Butwick, 2015; de Lange, 2014; Solomon, 2012). **Figure 7-2** shows examples in a normal gravida and in another with massive hemorrhage. Although these point-of-care tests appear promising, they also have several limitations. For example, they cannot be used to detect disorders of primary hemostasis (Solomon, 2012). Additionally, these tests cannot diagnose coagulopathies due to platelet dysfunction or antiplatelet drugs. Because they are point-of-care tests, they can be conducted by several different trained providers. However, there is the risk of misinterpretation when used by inadequately trained personnel. Further study is necessary to assess their use in managing obstetric hemorrhage.

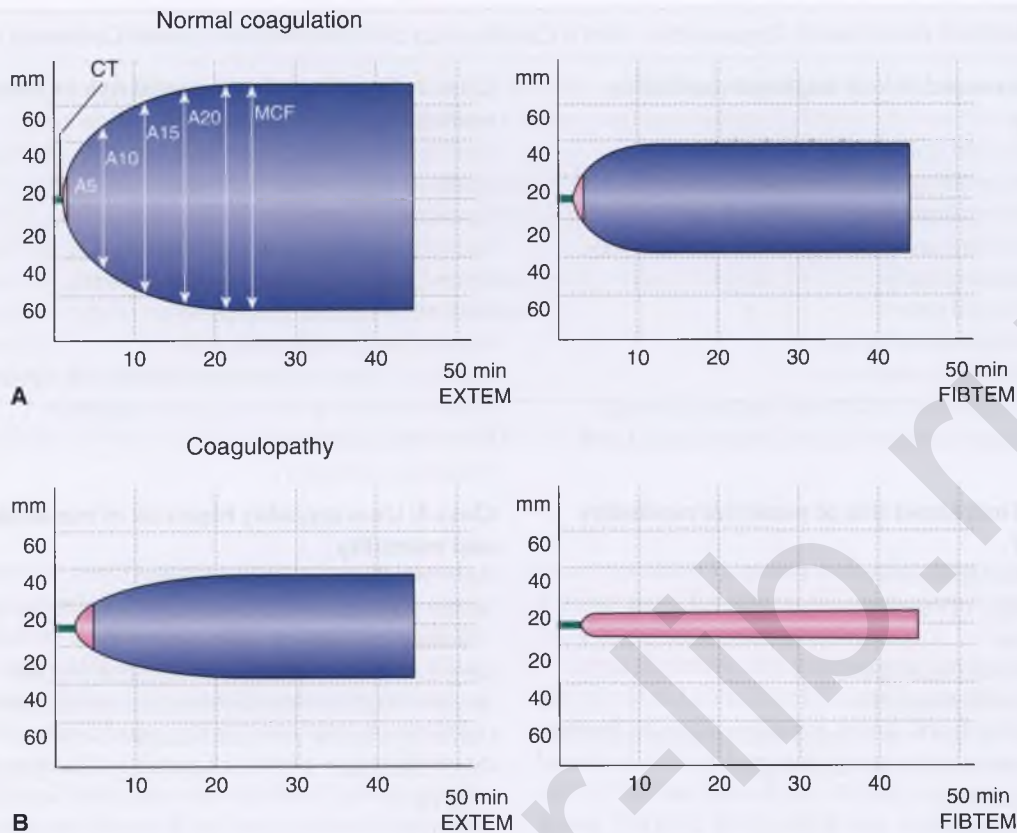


FIGURE 7-2 Thromboelastography (TEG) and rotational thromboelastography (ROTEM) coagulation profiles. **A.** Term normal pregnant woman shows enhanced coagulation with excellent clot quality. **B.** Woman with massive postpartum hemorrhage showing poor fibrin-clot quality. (Reproduced with permission from Solomon C, Collis RE, Collins PW: Haemostatic monitoring during postpartum haemorrhage and implications for management, *Br J Anaesth* 2012 Dec;109(6):851–863).

■ Tranexamic Acid

This is an antifibrinolytic drug that acts by preventing clot breakdown. Tranexamic acid (TXA) significantly reduces the risk of death in hemorrhaging trauma patients and decreases blood loss in women with menorrhagia (Roberts, 2012; Wellington, 2003). Very few studies have evaluated TXA use for postpartum hemorrhage. In these, it has been shown to reduce blood loss with postpartum hemorrhage, but safety concerns remain unaddressed (Ducloy-Bouthors, 2011). The World Maternal Antifibrinolytic trial (WOMAN trial) is a large randomized trial currently ongoing that is designed to answer these questions of safety and efficacy. In this trial, a 1-g dose of TXA is planned. The WHO (2012) recommends the use of TXA in postpartum hemorrhage due to atony when other uterotonic agents have failed.

CARDIAC DISEASE

■ Epidemiology

Cardiovascular disease and cardiomyopathy in the United States between 2006 and 2010 accounted for more than 25 percent of maternal deaths (Creanga, 2015). Approximately 1 to 4 percent of pregnancies are complicated by cardiac disease, and most cases stem from congenital heart defects (European Society of Gynecology, 2011). Notably, because of improved medical and surgical care of congenital heart disease,

more and more women are surviving to adulthood and are becoming pregnant.

During pregnancy, circulating blood volume increases 30 to 50 percent. In addition, systemic vascular resistance declines 20 percent and is accompanied by a 40-percent rise in cardiac output (Clark, 1989). This results in an elevated heart rate and diminished blood pressure. Labor and delivery further increases cardiac output. These changes are rapidly followed after delivery by an autotransfusion of blood and an increase in afterload. Understandably, these changes can result in acute or chronic cardiac decompensation in susceptible women.

Multiple scoring systems have been developed to predict which women are at greatest risk of cardiovascular events during pregnancy. Three are the modified WHO criteria, Cardiac Disease in Pregnancy—CARPREG, and Zwangerschap bij Aangeboren HARtAfwijking—ZAHARA (Drenthen, 2010; European Society of Gynecology, 2011; Siu, 2001; Thorne, 2006). **Table 7-9** outlines modified WHO classes and risk of maternal morbidity and mortality. Women in the modified WHO class III ideally receive preconception counseling and close surveillance by cardiologists and maternal-fetal medicine specialists. Women in the modified WHO Class IV group have an unacceptably high risk of severe morbidity or mortality and are counseled to avoid pregnancy or consider pregnancy termination if already pregnant (European Society of Gynecology, 2011; Thorne, 2006). The New York Heart Association functional classification is shown in **Table 7-10**.

TABLE 7-9. Modified World Health Organization (WHO) Classification of Risk in Pregnancy from Cardiovascular Disease**Class 1: No increased risk of maternal morbidity and mortality**

Uncomplicated, mild pulmonary stenosis
 Uncomplicated, small ventricular septal defect
 Uncomplicated, small patent ductus arteriosus
 Uncomplicated mitral valve prolapse with no more than trace mitral regurgitation
 Repaired atrial septal defect
 Repaired ventricular septal defect
 Repaired patent ductus arteriosus
 Repaired total anomalous pulmonary venous drainage
 Isolated ventricular extrasystoles and atrial ectopic beats

Class 2: Small increased risk of maternal morbidity and mortality

Unrepaired atrial septal defect
 Repaired tetralogy of Fallot
 Most arrhythmias
 Mild left ventricular impairment
 Hypertrophic cardiomyopathy
 Native or tissue valvular heart disease not considered WHO 4
 Marfan syndrome without aortic dilatation
 Heart transplantation
 Repaired coarctation

Class 3: Significantly increased risk of maternal morbidity and mortality

Mechanical valve
 Systemic right ventricle
 Post-Fontan operation
 Cyanotic heart disease
 Other complex congenital heart disease
 Mild left ventricular impairment
 Hypertrophic cardiomyopathy
 Native or tissue valvular heart disease not considered WHO 4
 Marfan syndrome without aortic dilatation
 Heart transplantation
 Repaired coarctation

Class 4: Unacceptably high risk of maternal morbidity and mortality

Pulmonary arterial hypertension
 Severe ventricular dysfunction (NYHA III-IV) or left ventricular ejection fraction <30%
 Severe left heart obstruction (e.g., coarctation)
 Severe mitral stenosis, severe symptomatic aortic stenosis
 Marfan syndrome with aorta dilated >45 mm
 Aortic dilatation >50 mm associated with bicuspid aortic valve

NYHA = New York Heart Association.

Data from European Society of Gynecology, 2011.

Management of Specific High-Risk Cardiac Diseases**Eisenmenger Syndrome**

This syndrome is associated with maternal mortality rates as high as 50 percent (Gleicher, 1979). It develops from excessive pulmonary blood flow caused by a chronic left-to-right shunt through intracardiac communications. Most commonly associated anomalies are unrepaired atrial septal defects, ventricular septal defects, or patent ductus arteriosus. This chronic overloading of the pulmonary circulation leads to elevation of pulmonary artery pressures. When these pressures exceed systemic pressures, the shunt direction reverses, and deoxygenated blood enters the systemic circulation and prevents pulmonary perfusion. This leads to a cycle of hypoxemia and worsening pulmonary hypertension.

During pregnancy, because of the normal decline in systemic vascular resistance, pulmonary artery pressures are closer

in value to systemic pressures. Therefore, the threshold for shunt reversal and hypoxemia is lowered. Any additional lowering of blood pressure, such as may occur with volume loss or vasodilation, places the woman at further risk for shunt reversal. Selective pulmonary artery vasodilators may be indicated (Warnes, 2008). Outcomes appear to be similar for vaginal or cesarean delivery (Gandhi, 2015).

In women with Eisenmenger syndrome, death most commonly occurs in the first week postpartum (Jones, 1965). Because of the high rate of maternal mortality, pregnancy is considered contraindicated. Pregnancy termination should be discussed with women who are already pregnant (European Society of Gynecology, 2011; Thorne, 2006).

Mitral Stenosis

This lesion most commonly follows as a complication of rheumatic heart disease. Severe stenosis is classified as a valve area

TABLE 7-10. New York Heart Association Functional Classification of Heart Disease

Class 1: Patients with cardiac disease and no functional limitation of physical activity.

Class 2: Patients with cardiac disease and slight limitation of physical activity. Ordinary physical activity results in fatigue, palpitations, or dyspnea.

Class 3: Patients with cardiac disease and marked limitation of physical activity. Asymptomatic at rest. Less than ordinary activity results in symptoms.

Class 4: Patients with cardiac disease and inability to perform physical activity without symptoms. Symptomatic at rest.

TABLE 7-11. Criteria for Severe Preeclampsia

Systolic blood pressure of 160 mm Hg or higher, or diastolic blood pressure of 110 mm Hg or higher on two occasions at least 4 hours apart while the woman is on bed rest (unless antihypertensive therapy is initiated before this time)
Thrombocytopenia—platelets less than 100,000/ μ L
Impaired liver function as indicated by abnormally elevated blood concentrations of liver enzymes (to twice normal concentrations), severe persistent right upper quadrant or epigastric pain unresponsive to medication and not accounted for by alternative diagnoses, or both
Progressive renal insufficiency—serum creatinine concentration greater than 1.1 mg/dL, or a doubling of the serum creatinine concentration in the absence of other renal disease
Pulmonary edema
New-onset cerebral or visual disturbances

Data from American College of Obstetricians and Gynecologists, 2013.

$<1 \text{ cm}^2$. Women with mitral stenosis are dependent on increased left atrial pressure to help blood pass through the stenotic opening. Decompensation in pregnancy often progresses due to the increased heart rate, which results in a shorter ventricular filling time. This decreased filling time leaves blood in the left atrium and leads to left atrial dilation, which is further worsened by the increased intravascular volume. As a result, supraventricular tachycardia and atrial fibrillation may develop. Cardiogenic pulmonary edema may also develop if the heart rate is not controlled so that the left atrium may adequately empty.

Mainstays of therapy include beta blockade for heart rate control and avoidance of fluid overload. Cesarean delivery is reserved for usual obstetric indications, and drugs such as terbutaline that cause maternal tachycardia are avoided. Forceps delivery to shorten second-stage labor may be considered in women with severe disease (Gandhi, 2015).

Aortic Stenosis

Isolated aortic stenosis most commonly results from a bicuspid aortic valve. Severe aortic stenosis is defined as valvular area $\leq 1.0 \text{ cm}^2$. Patients with this valvular lesion develop complications primarily from obstructed cardiac output. When challenged with increased circulating volume, gravidas may be unable to accommodate the intravascular load and subsequently develop cardiogenic pulmonary edema. Conversely, inadequate preload—from volume loss or vasodilation—may prevent adequate cardiac muscle perfusion. This leads to ischemia and risk for sudden death.

Intrapartum, cesarean delivery should be reserved for the usual obstetric indications. An assisted second stage should be considered. Postpartum, these patients are at increased risk of pulmonary edema due to the physiologic autotransfusion described earlier. Women with symptomatic aortic stenosis ideally undergo valvular correction prior to pregnancy (Gandhi, 2015).

Hypertensive Emergencies

Pregnancy-associated hypertensive disorders accounted for 9.4 percent of maternal deaths in the United States from 2006 to 2010, and these disorders affected between 5 and 10 percent of pregnancies (Creanga, 2015; Lo, 2013). The American College of Obstetricians and Gynecologists (2013) appointed a task

force to outline diagnoses and management of hypertension in pregnancy. The criteria for severe preeclampsia are listed in [Table 7-11](#).

Severe elevations of systolic blood pressure $\geq 160 \text{ mm Hg}$ or diastolic blood pressure $\geq 110 \text{ mm Hg}$ put the mother at risk of stroke. A recent investigation found that the risk of stroke from hypertensive disorders during pregnancy had increased (Leffert, 2015). The risk was 1.6 per 10,000 pregnancy hospitalizations during 2010 to 2011, which was a substantial increase from prior studies. They also found that in women with a hypertensive disorder during pregnancy, the risk of stroke is 5.2 times that of a woman without hypertension.

Accordingly, aggressive blood pressure control is instituted for values above these thresholds. During surveillance, a measurement is repeated several minutes later if an initial value is elevated. If blood pressure is persistently elevated in the severe range after 15 minutes of monitoring, then it should be aggressively managed as a hypertensive emergency. Treatment goals maintain blood pressure between 140 and 150 mm Hg systolic and between 90 and 100 mm Hg diastolic. This lowers the stroke risk yet allows adequate placental perfusion.

Of agents, intravenous labetalol or hydralazine, or oral short-acting nifedipine, are considered first-line therapy for hypertensive emergency in pregnant and postpartum women (American College of Obstetricians and Gynecologists, 2015a). Shown in [Table 7-12](#) are the dosing recommendations for management of acute hypertension recommended by the Joint National Committee 7. In women with refractory severe-range blood pressure not responsive to first-line medications, it may be necessary to initiate a continuous infusion (see [Table 7-12](#)). In practice, we seldom encounter the need for infusion. Notably, this should be done in conjunction with physicians who have experience using these medications. A sodium nitropruside drip can also be used for acute management of severe hypertension, but it should only be used when other methods fail. Notably, its antepartum use is limited to less than 4 hours as it can result in fetal cyanide poisoning.

Continuous fetal monitoring is recommended during treatment of a hypertensive emergency. Magnesium sulfate should not be given as an antihypertensive but should be given for seizure prophylaxis.

TABLE 7-12. Regimens of Treatment of Severe Pregnancy-Associated Hypertensive Disorders

Drug	Dosage	Adverse Effects
Intermittent		
Labetalol	20 mg IV bolus followed by 40 mg IV if needed after 10 min followed by 80 mg if BP still elevated in 10 min (max dose: 220 mg)	Bronchoconstriction
Hydralazine	5 mg IV bolus followed by 10 mg IV every 20–30 min if BP still elevated (max dose: 25 mg)	Hypotension, tachycardia, headache
Nifedipine	10 mg orally. If BP elevated, repeat every 20 min with up to 20 mg for 3 total doses	Headache
Infusion		
Labetalol	1–2 mg/min (max dose: 300 mg or 2.5 hr at 2 mg/min)	Bronchoconstriction
Nicardipine	5 mg/hr increased by 2.5 mg/hr every 5 to 15 min (max dose: 15 mg/hr)	Headache, flushing
Sodium nitroprusside	0.25 µg/kg/min to max dose 5 µg/kg/min (max dose: 4 hr at 5 µg/kg/min)	Fetal cyanide poisoning after 4 hr

BP = blood pressure; IV = intravenous; max = maximum.

From American College of Obstetricians and Gynecologists, 2015a; Chobanian, 2003; Lo, 2013.

HEMODYNAMIC MONITORING

The purpose of hemodynamic monitoring is to help guide therapy to maintain adequate tissue perfusion. Because tissue perfusion cannot be measured directly, indirect measures have been developed. These include both invasive and noninvasive techniques. Indications for invasive monitoring remain controversial, and more recent research focuses on noninvasive options.

■ Invasive Hemodynamic Monitoring

Arterial Line

An intraarterial catheter allows continuous measurement of blood pressure and can be used to determine stroke volume and cardiac output. The radial artery is the most common site of placement, but other sites are the brachial, femoral, or axillary artery. Common indications include the need for close blood pressure monitoring such as in those with shock or on vasopressor therapy, those with labile blood pressures, or those undergoing major surgery. Frequent blood gas determinations or continuous monitoring of cardiac output or stroke volume are other reasons. If an arterial line is used, measurement error can be a problem and requires a familiarity with the physical setup of the system. Complications with arterial lines are rare, but thrombosis, embolism, infection, and hematoma are potential risks (Scheer, 2002).

Central Venous Catheter

A central line provides access to large veins. Indications are cases in which peripheral vein catheters are inadequate, hemodynamic monitoring is required, or access is needed for vasopressors, chemotherapy, or parenteral nutrition. These agents can all cause venous inflammation when administered peripherally (Cheung, 2009). Although there are no absolute contraindications to central line placement, relative contraindications include vascular injury proximal to the access point and coagulopathy (Graham, 2007).

Central venous catheters are typically placed in the internal or external jugular vein, the subclavian vein, or the femoral vein. The right internal jugular vein is the preferred location during emergencies as it has the lowest associated risk of catheter malpositioning (Botha, 2006). Prior to infusion of drugs or parenteral nutrition, correct catheter tip placement should be confirmed by radiography, fluoroscopy, or echocardiography. The tip should lie in the lower superior vena cava just above the right atrium. The central venous pressure can be measured, and the central line can also be used to place a pulmonary artery catheter.

Central line-associated bloodstream infections (CLABSI) are a major source of complications from central line placement. These can be prevented in many cases through use of sterile technique and strict protocols for line placement and management (Liang, 2011; Miller, 2012). Other major complications include bleeding, arterial puncture, arrhythmia, venous thromboembolism, and pneumothorax (McGee, 2003).

Pulmonary Artery Catheter

This catheter is introduced through a central line, passes through the right atrium and right ventricle, and travels into the pulmonary vasculature. Here, it ends in a small-caliber pulmonary artery. Advantageously, a pulmonary artery catheter allows assessment of hemodynamic status in real time. With it, the central venous pressure, right-sided intracardiac pressures, pulmonary artery pressure, pulmonary capillary wedge pressure, pulmonary capillary occlusion pressure, cardiac output, and mixed venous oxyhemoglobin saturation can be measured. This permits calculation of additional physiologic parameters such as systemic vascular resistance or pulmonary vascular resistance.

Historically, pulmonary artery catheterization was the mainstay of invasive hemodynamic monitoring in critically ill patients. With time, however, its use has fallen out of favor following data from multiple studies that failed to show survival benefit from routine use (Connors, 1996; Richard, 2003; Sandham, 2003; Shah, 2005).

■ Noninvasive and Minimally Invasive Monitoring

Echocardiography

Transthoracic (TTE), transesophageal (TEE), and subcostal echocardiography can be used to monitor the hemodynamic status of critically ill patients. TTE and subcostal echocardiography have the advantage of being performed in an awake and alert patient. The woman must be sedated for TEE studies.

TEE provides the highest quality images. Thus, it allows accurate measurement of heart chamber size and determination of right and left ventricular function and aortic, mitral, and tricuspid valve function. The IVC and the aorta can also be evaluated. Of parameters, it can measure ejection fraction, estimated stroke volume, and pulmonary artery pressures to calculate cardiac output. Left ventricular end diastolic area (LVEDA) can also be determined and used to predict fluid responsiveness (Michard, 2002).

TTE can provide information similar to that from TEE, but image quality is poorer. Fortunately, the normal physiologic changes in pregnancy aid visualization of cardiac anatomy with TTE.

Subcostal echocardiography can be used to determine collapsibility of the IVC, whose diameter has been shown to correlate directly with central venous pressure. A collapsed vena cava indicates fluid depletion, whereas a distended IVC is indicative of high right atrial pressures (Stawicki, 2014). Echocardiography is especially helpful in evaluating patients with congenital cardiac disease.

Bioimpedance/Bioreactance

Bioimpedance- and bioactance-based systems are two noninvasive options for monitoring cardiac output and other hemodynamic variables such as stroke volume and cardiac index in critically ill patients. Of the two, a bioimpedance system measures the change in electrical current that is artificially applied to the thorax. The change is created by blood flow, and the current is passed between electrodes placed on a patient's chest. Specifically, bioimpedance detects electrical resistance induced by blood flow. In the thorax, fluid levels change as the left ventricle contracts and blood flows into the thoracic aorta. This creates a corresponding change in resistance within the thorax because the fluid level in the aorta rises. Bioimpedance measures the amplitude of this voltage change across the thorax for its calculations (Jakovljevic, 2014). The system is easy to use but is sensitive to patient movement and electrode placement. Moreover, current data are lacking regarding its ability to improve patient outcomes.

In contrast, bioactance measures relative phase shifts of an oscillating current that travels across the chest. The underlying scientific phenomenon is that the higher the cardiac stroke volume, the more significant these phase shifts become. This system has more flexibility in terms of sensor location and can be used in the setting of other monitors. Although validation studies in nonpregnant patients show promise, minimal data are available for pregnant women.

■ Determining Fluid Responsiveness

Circulatory insufficiency is a common clinical problem faced by critically ill patients. In these individuals, detecting volume

depletion and predicting response to fluid therapy is important. If cardiac output improves following volume expansion, the patient is deemed to be preload responsive. However, in a non-preload-responsive patient, volume expansion may exacerbate pulmonary edema, precipitate respiratory failure, prolong mechanical ventilation times, and contribute to the development of intraabdominal hypertension (Thiel, 2009).

■ Indications for Hemodynamic Monitoring

Current guidelines for invasive hemodynamic monitoring during pregnancy are lacking. Thus, trends in monitoring in obstetric critically ill patients parallel those in nonpregnant patients. Some indications for hemodynamic monitoring include:

- Shock: septic, hypovolemic, cardiogenic, unexplained—refractory to initial resuscitation
- Sepsis or pregnancy-associated hypertension with persistent oliguria
- Adult respiratory distress syndrome
- Cardiac disease: aortic or mitral stenosis, ischemic heart disease, or New York Heart Association class III or IV heart disease in labor
- Amniotic fluid embolism

Decisions to institute hemodynamic monitoring are individualized and made in conjunction with maternal-fetal medicine and critical care specialists.

CARDIAC ARREST

■ Epidemiology and Causes

Cardiac arrest occurs in approximately 1 in 12,000 hospitalizations for delivery each year. Surprisingly, almost 60 percent of those patients who experienced a cardiac arrest during their hospitalization for delivery survived and were ultimately discharged from the hospital. The most common causes of cardiac arrest in descending order are hemorrhage, heart failure, amniotic fluid embolism, sepsis, anesthesia complications, aspiration pneumonitis, venous thromboembolism, and eclampsia (Mhyre, 2014). The American Heart Association has developed the mnemonic BEAU-CHOPS to help providers remember the most common causes of cardiac arrest in pregnant women (Table 7-13).

Although this mnemonic addresses the most common etiologies of cardiac arrest in pregnant women, the other reversible reasons for arrest should also be remembered. These are commonly referred to as the H's and T's and are shown in Table 7-14.

■ Cardiac Arrest Management

Cardiac arrest in a pregnant woman presents several unique challenges that are not present in other populations. The best chance for fetal survival is through survival of the mother or through timely delivery after the arrest. In addition, the physiologic changes of pregnancy complicate resuscitation efforts. One effect is compression of the IVC by the gravid uterus, which retards venous return. Others are decreased functional residual capacity, increased oxygen consumption, increased aspiration risk, and difficult airway management due to changes in airway anatomy.

TABLE 7-13. BEAU-CHOPS Mnemonic for Causes of Cardiac Arrest in Pregnancy

B leeding/DIC
E mbolism—coronary/pulmonary/amnionic fluid
A nesthesia complications
U terine atony
C ardiac disease—myocardial infarction/ischemic/aortic dissection/cardiomyopathy/congenital
H ypertension/preeclampsia/eclampsia
O ther—standard differential per ACLS guidelines (Table 7-14)
P lacenta previa/placental abruption
S epsis

ACLS = advanced cardiac life support; DIC = disseminated intravascular coagulopathy.

Data from Vanden Hoek, 2010.

TABLE 7-14. Reversible Causes of Cardiac Arrest: The H's and T's

H's
Hypovolemia
Hypoxia
Hydrogen ion (acidosis)
Hyperkalemia
Hypokalemia
Hypothermia
T's
Toxins
Tamponade (cardiac)
Tension pneumothorax
Thrombosis—coronary and pulmonary

Data from Neumar, 2010.

In 2010, the American Heart Association updated its recommendations for basic (BLS) and advanced cardiac life support (ACLS) (Berg, 2010; Neumar, 2010). In 2014, the Society for Obstetric Anesthesia and Perinatology published a complementary consensus statement regarding cardiac arrest management in pregnancy (Lipman, 2014). These guidelines place more emphasis on chest compressions than respirations and recommend several modifications for pregnant women. These changes include a slightly higher hand placement on the sternum during chest compressions to account for the upward displacement of the diaphragm. Also, intravenous access should be obtained above the level of the diaphragm because the gravid uterus can obstruct venous return from the lower extremities. This poor return can impair cardiac output, uterine perfusion, and drug delivery (Lipman, 2014; Vanden Hoek, 2010). To alleviate some venous compression by the gravid uterus, left uterine displacement is encouraged. They further recommend perimortem cesarean delivery to be performed after 4 min if spontaneous circulation fails to return. Fetal monitoring is not indicated during maternal cardiac arrest as maternal status will guide resuscitative efforts. **Figure 7-3** summarizes the American Heart Association algorithm for maternal cardiac arrest. Specific suggestions for managing maternal cardiac arrest are described in the subsequent sections.

Call for Help

Ideally, an obstetric code response team has been developed that is familiar with resuscitation of the gravida. The response team should

also involve a neonatal resuscitation team. Normal components of cardiac arrest response include beginning chest compressions and obtaining a code cart, backboard, automated external defibrillator (AED) or defibrillator. In addition, preliminary

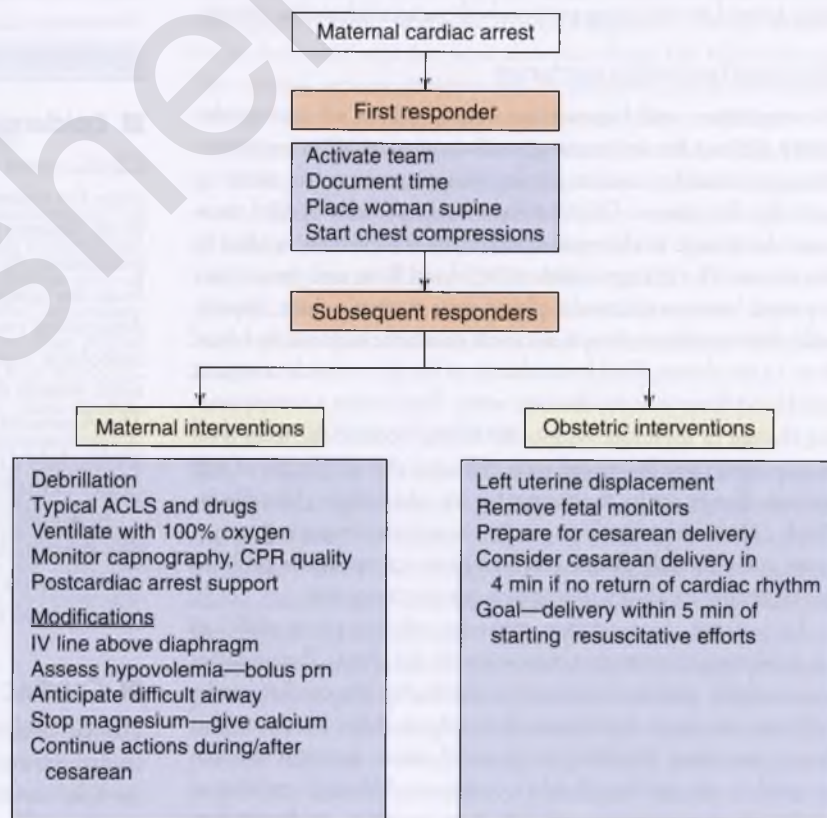


FIGURE 7-3 American Heart Association algorithm for cardiac arrest management. ACLS = advanced cardiac life support; CPR = cardiopulmonary resuscitation; IV = intravenous; prn = as needed. (Data from Vanden Hoek TL, Morrison LJ, Shuster M, et al: Part 12: cardiac arrest in special situations: 2010 American Heart Association Guidelines for Cardiopulmonary Resuscitation and Emergency Cardiovascular Care, *Circulation* 2010 Nov 2;122(18 Suppl 3):S829–S861.)

preparations begin immediately for perimortem cesarean delivery (Lipman, 2014).

Chest Compressions

Guidelines place special emphasis on the importance of chest compressions. These should be hard and rapid with a rate of 100 compressions per minute. Importantly, the sternum is ideally compressed 5 cm or 2 inches with each compression and allowed to fully recoil. In an obviously pregnant woman, hands are placed 2 to 3 cm farther cephalad to adjust for the upward displacement of the diaphragm. If the patient is not intubated, chest compressions are performed at a rate of 30 compressions per 2 breaths. With an intubated woman, they are performed continuously. The provider performing chest compressions is rotated every 2 min or every 5 cycles because provider fatigue lessens the quality of resuscitation. The efficacy of chest compressions is increased if the patient is on a firm surface, thus a backboard is placed as soon as possible.

Left Uterine Displacement

In a woman whose uterus reaches the level of the umbilicus or higher—20 weeks with a singleton gestation—left uterine displacement is preferred to relieve aortocaval compression. Ideally, the provider stands at the mother's left side and uses two hands to pull the uterus leftward and ventrally (toward the ceiling). It is important to elevate the uterus because downward pressure can worsen aortocaval compression. **Figure 7-4** illustrates proper technique for left uterine displacement. If it is not possible for the provider to stand on the left side, the uterus can

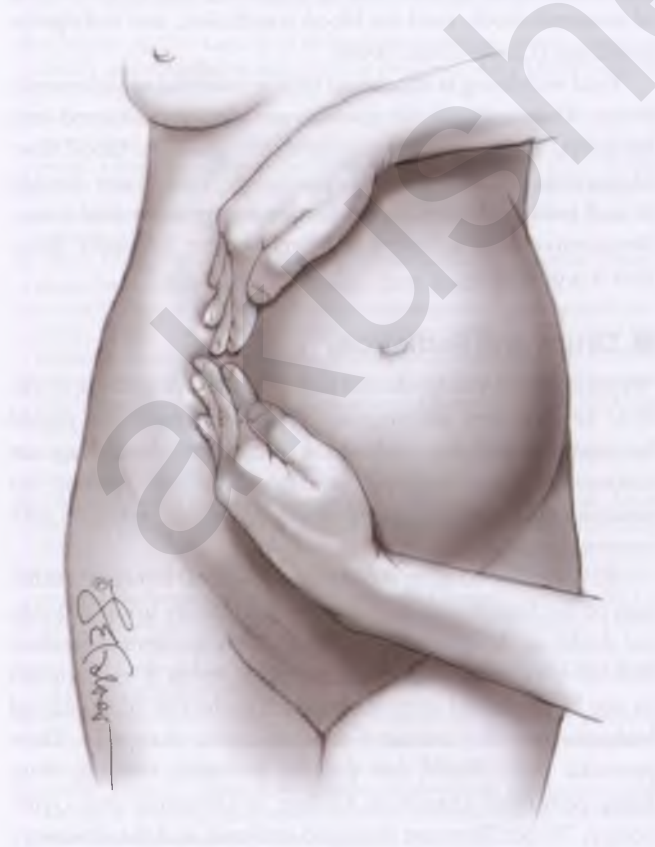

FIGURE 7-4 Left lateral displacement of the uterus. The operator preferentially stands at the mother's left side.

instead be pushed to left and elevated by a clinician standing on the mother's right side.

Another option is placing the patient's body in a left lateral tilt of 30 degrees. Specific boards have been developed to place the woman in this position, but these may not be available in a timely fashion. Additionally, simulations have demonstrated decreased resuscitation efficacy of 20 percent when the patient was placed in left lateral tilt (Rees, 1988).

Intravenous Access

Because of aortocaval compression by the gravid uterus, intravenous access should be obtained above the level of the diaphragm. Drugs given below the level of the diaphragm may have delayed onset or may never reach the systemic circulation. Central venous access is recommended in women in whom peripheral access cannot be obtained or if large volumes of fluids or blood products are anticipated. Intraosseous access can also be considered (Lipman, 2014; Vanden Hoek, 2010).

Chest Compression Efficacy

In the intubated patient, efficacy of chest compressions can be assessed using continuous capnography. Continuous capnography measures the partial pressure of exhaled carbon dioxide and is an indirect measure of cardiac output. End-tidal carbon dioxide levels above 10 mm Hg suggest adequate chest compressions. Additionally, rising end-tidal carbon dioxide levels can predict return of spontaneous circulation (Lipman, 2014).

Airway/Breathing

Airway management is essential in a pregnant patient with cardiac arrest, and intubation is accomplished expediently to minimize aspiration risks. Due to physiologic changes in airway anatomy during pregnancy, intubation is significantly more challenging. Only experienced providers should attempt intubation as repeated trauma to the airway from failed attempts can make subsequent attempts more difficult. Moreover, because of decreased functional residual capacity, increased oxygen consumption, and increased intrapulmonary shunting, pregnant women develop hypoxemia much more quickly than nonpregnant women. Maneuvers such as the jaw thrust and head tilt chin lift are used to open the airway as necessary, and oral suctioning removes excess secretions (Lipman, 2014).

If an advanced airway is not in place, two breaths should be administered after every 30 chest compressions. Once an advanced airway is in place, breaths are administered at a rate of 10 breaths per minute. The American Heart Association guidelines recommend a 500- to 700-mL tidal volume delivered over 1 second (Vanden Hoek, 2010).

Defibrillation/Drugs

Defibrillation is performed as soon as indicated. The American Heart Association sets a goal of delivering a shock in cases of a shockable rhythm within 3 minutes of collapse. For a cardiac arrest occurring on an obstetric unit, the Society for Obstetric Anesthesia and Perinatology (SOAP) recommends that an AED be used or a defibrillator in AED mode due to lack of provider familiarity with rhythm analysis. Defibrillation energy requirements do not change for a pregnant woman, and it is

safe for the fetus. If possible, fetal monitors are removed to avoid burning the mother. Additionally, rhythm checks should not delay chest compressions by more than 5 seconds (Lipman, 2014; Vanden Hoek, 2010).

Current ACLS guidelines recommend administering the identical drug dosages and timing regardless of pregnancy. Also, because the life of the fetus depends on saving the life of the mother, none of the drugs in the guidelines are considered contraindicated.

■ Perimortem Cesarean Delivery

The American Heart Association recommends that plans should be made for an emergency cesarean delivery as soon as cardiac arrest is identified in a pregnant woman with a 20-week-size or larger uterus. This is done regardless of viability, as the enlarged uterus can impair resuscitation efforts. Multiple case reports and case series describe return of spontaneous circulation immediately after performing a perimortem cesarean delivery without evidence of worsened maternal status (Einav, 2012).

The “4 Minute Rule”

Irreversible fetal anoxic brain injury is thought to develop as soon as 4 to 5 minutes after cardiac arrest. Additionally, analyses of case reports and case series show improved neonatal survival rates and neurologic outcome if cesarean delivery is performed within 5 minutes of maternal cardiac arrest (Katz, 2005, 2012). This, combined with the return of spontaneous circulation described after perimortem cesarean delivery, prompted the American Heart Association and Society of Perinatal Anesthesiologists to recommend that perimortem cesarean delivery be initiated 4 minutes after cardiac arrest with delivery of the fetus by 5 minutes (Lipman, 2014; Vanden Hoek, 2010). Unfortunately, most perimortem cesarean sections fall outside of this window (Jeejeebhoy, 2011; Katz, 2005). In certain circumstances, it is advisable to perform perimortem cesarean delivery immediately rather than waiting for 4 minutes of resuscitative efforts (Katz, 2012; Vanden Hoek, 2010). Examples are women with a nonsurvivable injury or cases in which resuscitative efforts appear futile. And, because apparently healthy neonates have been delivered after prolonged cardiac arrest, perimortem cesarean delivery should still be considered even after prolonged resuscitation (Einav, 2012).

Logistics of Perimortem Cesarean Delivery

The operation should be performed at the mother’s location. Simulations have shown that transfer to the operating room results in delays in delivery and decreased quality of resuscitation (Lipman, 2011, 2013). The only necessary items for performing a perimortem cesarean delivery are gloves, a scalpel, and clamps for the umbilical cord. Delivery should not be delayed to cleanse the abdomen. A vertical laparotomy incision has been advocated for perimortem cesarean delivery. However, many providers are much more comfortable performing an emergency cesarean delivery through a Pfannenstiel incision. Some institutions develop their own perimortem cesarean delivery kit that contains all of the necessary items in a centralized location. Suggested items to include are scalpels, surgical gloves, gowns, masks, laparotomy sponges, Pean clamps, Mayo

scissors, retractors, cord clamps, needle driver, suitable suture, and items for the neonate such as resuscitation supplies (Hui, 2011; Jeejeebhoy, 2014; Lipman, 2014).

During surgery, bleeding is minimal because of poor or absent maternal circulation. If spontaneous circulation returns, the abdomen can be packed and the patient transported to an operating room for hysterotomy and laparotomy closure.

■ Institutional Preparation

Because maternal cardiac arrest is rare, few people have extensive experience in managing this event. It is infrequently covered during routine ACLS certification courses. Accordingly, multidisciplinary team training simulations are recommended to improve interdepartmental communication and to identify local barriers to optimal care (Hui, 2011; Lipman, 2014). In addition, items needed for a perimortem cesarean delivery may not be immediately available in an emergency. Thus, development of a specific perimortem cesarean delivery kit that can be transported by the code team to an obstetric code may help decrease delays.

FETAL CONSIDERATIONS WITH MATERNAL CRITICAL ILLNESS

In critically ill pregnant women, spontaneous abortion, fetal demise, and other adverse neonatal outcomes often occur. Perinatal mortality rates reach up to 20 percent (Aoyama, 2014). Critically ill obstetric patients hospitalized for a nonobstetric indication are at greatest risk of pregnancy loss in the setting of maternal shock, need for blood transfusion, and early gestational age (Cartin-Ceba, 2008).

Fetal well-being is dependent on the maternal cardiovascular status. Thus, critically ill gravidas are ideally positioned in a left lateral tilt to optimally improve uteroplacental blood flow. Hypoxemia is avoided, as is hypotension. Vasopressor therapy is used judiciously so as not to further compromise fetal status. Betamethasone is indicated if delivery before 34 weeks’ gestation is a possibility.

■ Drugs and Radiation

Women should not be denied access to lifesaving drugs in the ICU because they are pregnant. That said, providers should be cognizant that the fetal effects of many of these drugs are unknown. When multiple equally efficacious options for treatment are available, providers ideally balance fetal risks with maternal benefit.

All necessary imaging should be performed. However, radiation to the fetus is minimized when possible by using abdominal shielding. Additionally, radiologic tests are limited to those that are necessary. While x-ray exposure up to 5 rads appears to not be associated with teratogenicity, the risk of childhood leukemia may be increased at levels lower than this. These potential risks should not prevent necessary imaging from being performed (American College of Obstetrics and Gynecology, 2016). These are discussed in detail, and the dosimetry measures of various radiographic procedures are presented in Chapter 5 (p. 68).

■ Fetal Monitoring

There are currently no guidelines regarding fetal monitoring in the critically ill obstetric patient. The monitoring type and intervals are selected on a case-by-case basis in conjunction with a maternal-fetal medicine specialist. Prior to viability, fetal surveillance in excess of intermittent confirmation of fetal heart rate is not indicated. In general, assessment of fetal status should not be performed unless providers are able and willing to act on the information that it provides. If delivery is not an option, then monitoring is avoided or minimized.

■ Decision for Delivery

The decision to deliver a fetus in a critically ill gravida is best made in concert with a maternal-fetal medicine specialist. In some cases, iatrogenic preterm delivery is indicated to improve maternal condition, such as in severe sepsis due to chorioamnionitis. In general, attempts to stabilize the mother should occur prior to delivery. In other situations, the cause of critical illness may be reversible and delivery of a preterm fetus can be postponed.

REFERENCES

- Abdel-Razeq SS: Obstetric emergencies: respiratory distress. *Contemp OB/GYN*, November 1, 2011
- Acosta CD, Kurinczuk JJ, Lucas DN, et al: Severe maternal sepsis in the UK, 2011–2012: a national case-control study. *PLoS Med* 11(7):e1001672, 2014
- Acute Respiratory Distress Syndrome Network: Ventilation with lower tidal volumes as compared with traditional tidal volumes for acute lung injury and the acute respiratory distress syndrome. *N Engl J Med* 342(18):1301, 2000
- Albright CM, Ali TN, Lopes V, et al: The sepsis in obstetrics score: a model to identify risk of morbidity from sepsis in pregnancy. *Am J Obstet Gynecol* 211(1):e31, 2014
- American College of Obstetricians and Gynecologists: Emergent therapy for acute-onset, severe hypertension during pregnancy and the postpartum period. Committee Opinion No. 623, *Obstet Gynecol* 125(2):521, 2015a
- American College of Obstetricians and Gynecologists: Guidelines for diagnostic imaging during pregnancy and lactation. Committee Opinion No. 656, February 2016
- American College of Obstetricians and Gynecologists: Postpartum hemorrhage. Practice Bulletin No. 76, October 2006, Reaffirmed 2015b
- American College of Obstetricians and Gynecologists: Safe motherhood initiative. 2015c. Available at: <http://www.acog.org/About-ACOG/ACOG-Districts/District-II/Safe-Motherhood-Initiative>. Accessed February 10, 2016
- American College of Obstetricians and Gynecologists, Task Force on Hypertension in Pregnancy: hypertension in pregnancy. *Obstet Gynecol* 122(5):1122, 2013
- Aoyama K, Seaward PG, Lapinsky SE: Fetal outcome in the critically ill pregnant woman. *Crit Care* 18(3):307, 2014
- ARDS Definition Task Force, Ranieri VM, Rubenfeld GD, et al: Acute respiratory distress syndrome: the Berlin Definition. *JAMA* 307(23):2526, 2012
- Ballinger KJ, Chu Lam MT, Hon HH, et al: Amniotic fluid embolism: despite progress, challenges remain. *Curr Opin Obstet Gynecol* 27(6):398, 2015
- Barton JR, Sibai BM: Severe sepsis and septic shock in pregnancy. *Obstet Gynecol* 120(3):689, 2012
- Baskett TF: Epidemiology of obstetric critical care. *Best Pract Res Clin Obstet Gynaecol* 22(5):763, 2008
- Bauer ME, Bateman BT, Bauer ST, et al: Maternal sepsis mortality and morbidity during hospitalization for delivery: temporal trends and independent associations for severe sepsis. *Anesth Analg* 117(4):944, 2013
- Bauer ME, Bauer ST, Rajala B, et al: Maternal physiologic parameters in relationship to systemic inflammatory response syndrome criteria: a systematic review and meta-analysis. *Obstet Gynecol* 124(3):535, 2014
- Berg C, Atrash H, Koonin L, et al: Pregnancy-related mortality in the United States 1987–1990. *Obstet Gynecol* 88(2):161, 1996
- Berg CI, Harper MA, Atkinson SM, et al: Preventability of pregnancy-related deaths: results of a state-wide review. *Obstet Gynecol* 106(6):1228, 2005
- Berg RA, Hemphill R, Abella BS, et al: Part 5: adult basic life support: 2010 American Heart Association Guidelines for Cardiopulmonary Resuscitation and Emergency Cardiovascular Care *Circulation* 122(18 Suppl 3):S685, 2010
- Bone RC, Balk RA, Cerra FB, et al: Definitions for sepsis and organ failure and guidelines for the use of innovative therapies in sepsis. The ACCP/SCCM Consensus Conference Committee, American College of Chest Physicians/Society of Critical Care Medicine. *Chest* 101(6):1644, 1992
- Borgman MA, Spinella PC, Perkins JG, et al: The ratio of blood products transfused affects mortality in patients receiving massive transfusions at a combat support hospital. *J Trauma* 63(4):805, 2007
- Botha R, van Schoor AN, Boon JM, et al: Anatomical considerations of the anterior approach for central venous catheter placement. *Clin Anat* 19(2):101, 2006
- Butwick AJ, Goodnough LT: Transfusion and coagulation management in major obstetric hemorrhage. *Curr Opin Anaesthesiol* 28(3):275, 2015
- Cantwell R, Clutton-Brock T, Cooper G, et al: Saving mothers' lives: reviewing maternal deaths to make motherhood safer: 2006–2008. *BJOG* 118:1, 2011
- Cartin-Ceba R, Gajic O, Iyer VN, et al: Fetal outcomes of critically ill pregnant women admitted to the intensive care unit for nonobstetric causes. *Crit Care Med* 36(10):2746, 2008
- Chantry AA, Deneux-Tharaux C, Bonnet MP, et al: Pregnancy-related ICU admissions in France: trends in rate and severity, 2006–2009. *Crit Care Med* 43(1):78, 2008
- Chen CY, Chen CP, Wang KG, et al: Factors implicated in the outcome of pregnancies complicated by acute respiratory failure. *J Reprod Med* 48(8):641, 2003
- Cheung E, Baerlocher MO, Asch M, et al: Venous access: a practical review for 2009. *Can Fam Physician* 55(5):494, 2009
- Chobanian AV, Bakris GL, Black HR, et al: Seventh Report of the Joint National Committee on Prevention, Detection, Evaluation, and Treatment of High Blood Pressure. *Hypertension* 42(6):1206, 2003
- Clark SL: Amniotic fluid embolism. *Obstet Gynecol* 123(2 Pt 1):337, 2014
- Clark SL, Cotton DB, Lee W, et al: Central hemodynamic assessment of normal term pregnancy. *Am J Obstet Gynecol* 161(6 Pt 1):1439, 1989
- Clark SL, Hankins GD, Dudley DA, et al: Amniotic fluid embolism: analysis of the national registry. *Am J Obstet Gynecol* 172:1158, 1995
- Clark SL, Pavlova Z, Greenspoon J, et al: Squamous cells in the maternal pulmonary circulation. *Am J Obstet Gynecol* 154(1):104, 1986
- Connors AF Jr, Speroff T, Dawson NV, et al: The effectiveness of right heart catheterization in the initial care of critically ill patients. *JAMA* 276(11):889, 1996
- Creanga AA, Berg CJ, Syverson C, et al: Pregnancy-related mortality in the United States, 2006–2010. *Obstet Gynecol* 125(1):5, 2015
- Cunningham FG, Nelson DB: Disseminated intravascular coagulation syndromes in obstetrics. *Obstet Gynecol* 126(5):999, 2015
- de Lange NM, van Rheenen-Flach LE, Lance MD, et al: Peri-partum reference ranges for ROTEM(R) thromboelastometry. *Br J Anaesth* 112(5):852, 2014
- Dellinger RP: The Surviving Sepsis Campaign: where have we been and where are we going? *Cleve Clin J Med* 82(4):237, 2015
- Dellinger RP, Levy MM, Rhodes A, et al: Surviving Sepsis Campaign: international guidelines for management of severe sepsis and septic shock. *Crit Care Med* 41(2):580, 2013
- Dildy GA III: Fetal pulse oximetry: a critical appraisal. *Best Pract Res Clin Obstet Gynaecol* 18(3):477, 2004
- Drenthen W, Boersma E, Balci A, et al: Predictors of pregnancy complications in women with congenital heart disease. *Eur Heart J* 31(17):2124, 2010
- Duarte AG: ARDS in pregnancy. *Clin Obstet Gynecol* 57(4):862, 2014
- Ducloy-Bouthors AS, Jude B, Duhamel A, et al: High-dose tranexamic acid reduces blood loss in postpartum haemorrhage. *Crit Care* 15(2):R117, 2011
- Edwards SE, Grobman WA, Lappen JR, et al: Modified obstetric early warning scoring systems (MOEWS): validating the diagnostic performance for severe sepsis in women with chorioamnionitis. *Am J Obstet Gynecol* 212(4):536.e1, 2015
- Einav S, Kaufman N, Sela HY: Maternal cardiac arrest and perimortem caesarean delivery: evidence or expert-based? *Resuscitation* 83(10):1191, 2012
- Erez O, Mastrolia SA, Thachil J: Disseminated intravascular coagulation in pregnancy: insights in pathophysiology, diagnosis and management. *Am J Obstet Gynecol* 213(4):452, 2015
- European Society of Gynecology (ESG), Association for European Paediatric Cardiology (AEPIC), German Society for Gender Medicine, et al: ESC guidelines on the management of cardiovascular diseases during pregnancy: the Task Force on the Management of Cardiovascular Diseases during Pregnancy of the European Society of Cardiology (ESC). *Eur Heart J* 32(24):3147, 2011

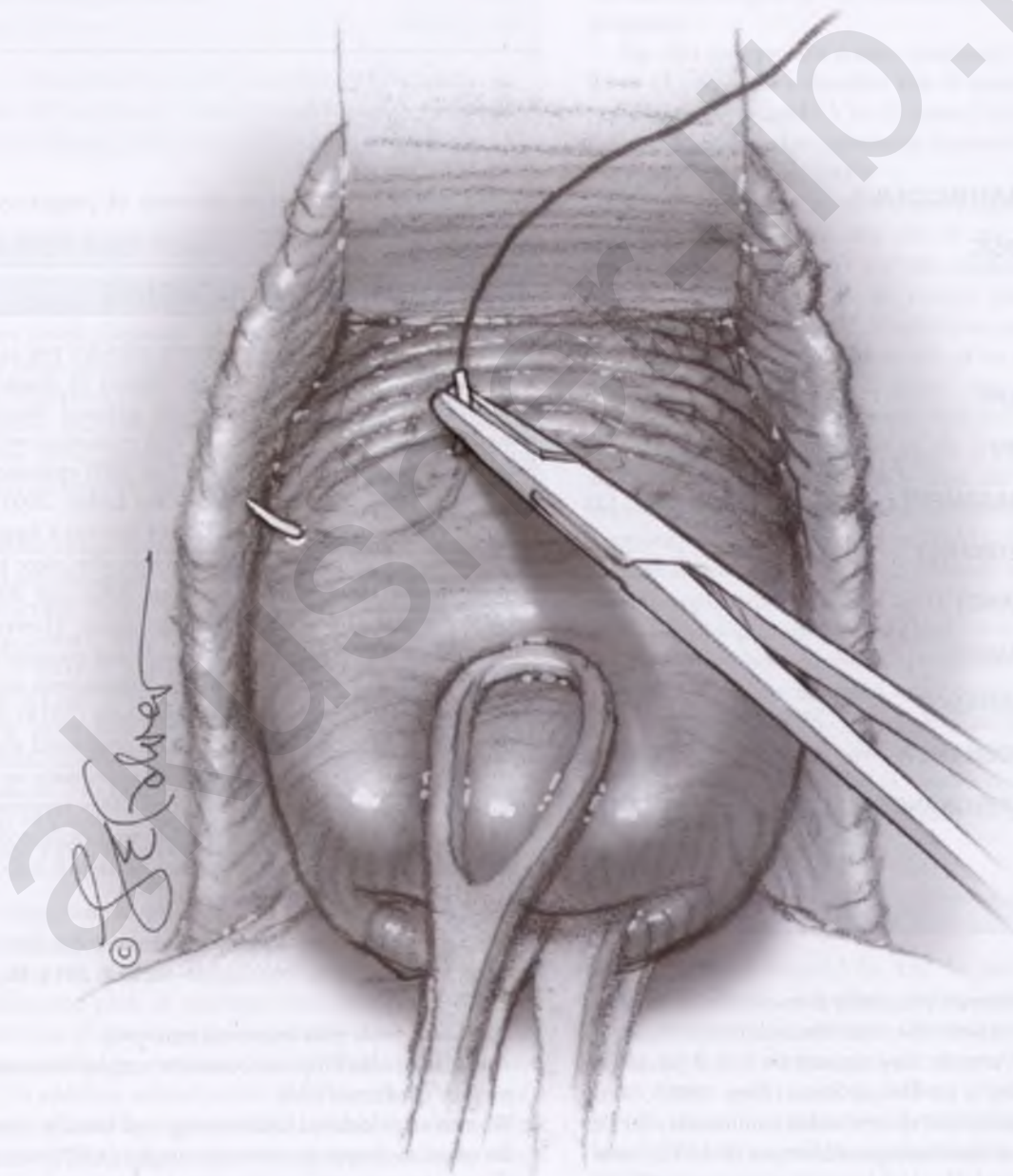
- Ferguson ND, Fan E, Camporota L, et al: The Berlin definition of ARDS: an expanded rationale, justification, and supplementary material. *Intensive Care Med* 38(10):1573, 2013
- Gandhi M, Martin SR: Cardiac disease in pregnancy. *Obstet Gynecol Clin North Am* 42(2):315, 2015
- Gilbert T: Obstetric admissions to the intensive care unit: outcomes and severity of illness. *Obstet Gynecol* 102(5 Pt 1): 897, 2003
- Gleicher N, Midwall J, Hochberger D, et al: Eisenmenger's syndrome and pregnancy. *Obstet Gynecol Surv* 34(10):721, 1979
- Graham AS, Ozment C, Tegtmeyer K, et al: Videos in clinical medicine. Central venous catheterization. *N Engl J Med* 356(21):e21, 2007
- Gregoret C, Pisani L, Cortegiani A, et al: Noninvasive ventilation in critically ill patients. *Crit Care Clin* 31(3): 435, 2015
- Grossbach I, Chlan L, Tracy MF: Overview of mechanical ventilatory support and management of patient- and ventilator-related responses. *Crit Care Nurse* 31(3):30, 2011
- Guntupalli KK, Karnad DR, Bandi V, et al: Critical illness in pregnancy part II: common medical conditions complicating pregnancy and puerperium. *Chest* 148(5):1333, 2015
- Hankins GD, Clark SL, Harvey CJ, et al: Third-trimester arterial blood gas and acid base values in normal pregnancy at moderate altitude. *Obstet Gynecol* 88(3):347, 1996
- Holcomb JB, Tilley BC, Baraniuk S, et al: Transfusion of plasma, platelets, and red blood cells in a 1:1:1 vs a 1:1:2 ratio and mortality in patients with severe trauma: the PROPPR randomized clinical trial. *JAMA* 313(5):471, 2015
- Holcomb JB, Wade CE, Michalek JE, et al: Increased plasma and platelet to red blood cell ratios improves outcome in 466 massively transfused civilian trauma patients. *Ann Surg* 248(3):447, 2008
- Hui D, Morrison LJ, Windrim R, et al: The American Heart Association 2010 guidelines for the management of cardiac arrest in pregnancy consensus recommendations on implementation strategies. *J Obstet Gynaecol Can* 33(8):858, 2011
- Jakovljevic DG, Trenell MI, MacGowan GA: Bioimpedance and bioactance methods for monitoring cardiac output. *Best Pract Res Clin Anaesthesiol* 28(4):381, 2014
- Jeejeebhoy F, Windrim R: Management of cardiac arrest in pregnancy. *Best Pract Res Clin Obstet Gynaecol* 28(4):607, 2014
- Jeejeebhoy FM, Zelop CM, Windrim R, et al: Management of cardiac arrest in pregnancy: a systematic review. *Resuscitation* 82(7):801, 2011
- Jones AM, Howitt G: Eisenmenger syndrome in pregnancy. *Br Med J* 1(5451): 1627, 1965
- Kassebaum NJ, Bertozzi-Villa A, Coggeshall MS, et al: Global, regional and national levels and causes of maternal mortality during 1990–2013: a systematic analysis for the Global Burden of Disease Study 2013. *Lancet* 384(9947): 980, 2014
- Katz V, Balderston K, DeFreest M: Perimortem cesarean delivery: were our assumptions correct? *Am J Obstet Gynecol* 192(6):1916, 2005
- Katz VL: Perimortem cesarean delivery: its role in maternal mortality. *Semin Perinatol* 36(1):68, 2012
- Knight M, Berg C, Brocklehurst P, et al: Amniotic fluid embolism incidence, risk factors and outcomes: a review and recommendations. *BMC Pregnancy Childbirth* 12:7, 2012
- Knowles SJ, O'Sullivan NP, Meenan AM, et al: Maternal sepsis incidence, aetiology and outcome for mother and fetus: a prospective study. *BJOG* 122(5):663, 2015
- Kramer HM, Schutte JM, Zwart JJ, et al: Maternal mortality and severe morbidity from sepsis in the Netherlands. *Acta Obstet Gynecol Scand* 88(6):647, 2009
- Kumar A, Roberts D, Wood KE, et al: Duration of hypotension before initiation of effective antimicrobial therapy is the critical determinant of survival in human septic shock. *Crit Care Med* 34(6):1589, 2006
- Lee W, Ginsburg KA, Cotton DB, et al: Squamous and trophoblastic cells in the maternal pulmonary circulation identified by invasive hemodynamic monitoring during the peripartum period. *Am J Obstet Gynecol* 155(5):999, 1986
- Leffert LR, Clancy CR, Bateman BT, et al: Hypertensive disorders and pregnancy-related stroke: frequency, trends, risk factors, and outcomes. *Obstet Gynecol* 125(1):124, 2015
- Levy MM, Fink MP, Marshall JC, et al: 2001 SCCM/ESICM/ACCP/ATS/SIS International Sepsis Definitions Conference. *Crit Care Med* 31(4):1250, 2003
- Liang SY, Marschall J: Update on emerging infections: news from the Centers for Disease Control and Prevention. Vital signs: central line-associated blood stream infections—United States, 2001, 2008, and 2009. *Ann Emerg Med* 58(5):447, 2011
- Lipman S, Cohen S, Einav S, et al: The Society for Obstetric Anesthesia and Perinatology consensus statement on the management of cardiac arrest in pregnancy. *Anesth Analg* 118(5):1003, 2014
- Lipman S, Daniels K, Cohen SE, et al: Labor room setting compared with the operating room for simulated perimortem cesarean delivery: a randomized controlled trial. *Obstet Gynecol* 118(5):1090, 2011
- Lipman SS, Wong JY, Arafah J, et al: Transport decreases the quality of cardiopulmonary resuscitation during simulated maternal cardiac arrest. *Anesth Analg* 116(1):162, 2013
- Lo JO, Mission JF, Caughey AB: Hypertensive disease of pregnancy and maternal mortality. *Curr Opin Obstet Gynecol* 25(2):124, 2013
- Mabie WC, Barton JR, Sibai B: Septic shock in pregnancy. *Obstet Gynecol* 90(4 pt 1):553, 1997
- McGee DC, Gould MK: Preventing complications of central venous catheterization. *N Engl J Med* 348(12):1123, 2003
- Mehta N, Chen K, Hardy E, et al: Respiratory disease in pregnancy. *Best Pract Res Clin Obstet Gynaecol* 29(5):598, 2015
- Mhyre JM, Tsen LC, Einav S, et al: Cardiac arrest during hospitalization for delivery in the United States, 1998–2011. *Anesthesiology* 120(4):810, 2014
- Michard F, Teboul JL: Predicting fluid responsiveness in ICU patients: a critical analysis of the evidence. *Chest* 121(6): 2000, 2002
- Mighty HE: Acute respiratory failure in pregnancy. *Clin Obstet Gynecol* 53(2): 360, 2010
- Miller SE, Maragakis LL: Central line-associated bloodstream infection prevention. *Curr Opin Infect Dis* 25(4):412, 2012
- Nair P, Davies AR, Beca J, et al: Extracorporeal membrane oxygenation for severe ARDS in pregnant and postpartum women during the 2009 H1N1 pandemic. *Intensive Care Med* 37(4):648, 2011
- Neumar RW, Otto CW, Link MS, et al: Part 8: adult advanced cardiovascular life support: 2010 American Heart Association Guidelines for Cardiopulmonary Resuscitation and Emergency Cardiovascular Care. *Circulation* 122(18 Suppl 3):S729, 2010
- Orsini J, Butala A, Diaz L, et al: Clinical profile of obstetric patients admitted to the medical-surgical intensive care unit (MSICU) of an inner-city hospital in New York. *J Clin Med Res* 4(5):314, 2012
- Pacheco LD, Saade GR, Costantine MM, et al: The role of massive transfusion protocols in obstetrics. *Am J Perinatol* 30(1):1, 2013
- Pacheco LD, Saade GR, Hankins GD: Severe sepsis during pregnancy. *Clin Obstet Gynecol* 57(4):827, 2014
- Pollock W, Rose L, Dennis CL: Pregnant and postpartum admissions to the intensive care unit: a systematic review. *Intensive Care Med* 36(9):1465, 2010
- Pruitt WC, Jacobs M: Breathing lessons: basics of oxygen therapy. *Nursing* 33(10):43, 2003
- Rees GA, Willis BA: Resuscitation in late pregnancy. *Anaesthesia* 43(5):347, 1988
- Richard C, Warszawski J, Anguel N, et al: Early use of the pulmonary artery catheter and outcomes in patients with shock and acute respiratory distress syndrome: a randomized controlled trial. *JAMA* 290(20):2713, 2003
- Roberts I, Shakur H, Ker K, et al: Antifibrinolytic drugs for acute traumatic injury. *Cochrane Database Syst Rev* 12:CD004896, 2012
- Sandham JD, Hull RD, Brant RF, et al: A randomized, controlled trial of the use of pulmonary-artery catheters in high-risk surgical patients. *N Engl J Med* 348(1):5, 2003
- Say L, Chou D, Gemmill A, et al: Global Causes of Maternal Death: a WHO systematic analysis. *Lancet Global Health* 2:e323, 2014
- Scheer B, Perel A, Pfeiffer UJ: Clinical review: complications and risk factors of peripheral arterial catheters used for haemodynamic monitoring in anaesthesia and intensive care medicine. *Crit Care* 6(3):199, 2002
- Shah MR, Hasselblad V, Stevenson LW, et al: Impact of the pulmonary artery catheter in critically ill patients: meta-analysis of randomized clinical trials. *JAMA* 294(13):1664, 2005
- Siu SC, Sermer M, Colman JM, et al: Prospective multicenter study of pregnancy outcomes in women with heart disease. *Circulation* 104(5):515, 2001
- Society of Critical Care Medicine: Surviving sepsis campaign: updated bundles in response to new evidence. 2015. Available at: http://www.survivingsepsis.org/sitecollectiondocuments/ssc_bundle.pdf. Accessed February 12, 2016
- Solomon C, Collis RE, Collins PW: Haemostatic monitoring during postpartum haemorrhage and implications for management. *Br J Anaesth* 109(6): 851, 2012
- Stawicki SP, Adkins EJ, Eiferman DS, et al: Prospective evaluation of intravascular volume status in critically ill patients: does inferior vena cava collapsibility correlate with central venous pressure? *J Trauma Acute Care Surg* 76(4):956, 2014
- Stevens TA, Carroll MA, Promecene PA, et al: Utility of Acute Physiology, Age, and Chronic Health Evaluation (APACHE III) score in maternal admissions to the intensive care unit. *Am J Obstet Gynecol* 194(5):e13, 2006
- Thiel SW, Kollef MH, Isakow W: Non-invasive stroke volume measurement and passive leg raising predict volume responsiveness in medical ICU patients: an observational cohort study. *Crit Care* 13(4):R111, 2009

- Thorne S, MacGregor A, Nelson-Piercy C: Risks of contraception and pregnancy in heart disease. *Heart* 92(10):1520, 2006
- Vanden Hoek TL, Morrison LJ, Shuster M, et al: Part 12: cardiac arrest in special situations: 2010 American Heart Association Guidelines for Cardiopulmonary Resuscitation and Emergency Cardiovascular Care. *Circulation* 122(18 Suppl 3): S829, 2010
- Vasquez DN, Estenssoro E, Canales HS, et al: Clinical characteristics and outcomes of obstetric patients requiring ICU admission. *Chest* 131(3):718, 2007
- Wanderer JP, Leffert LR, Mhyre JM, et al: Epidemiology of obstetric-related ICU admissions in Maryland: 1999–2008. *Crit Care Med* 41(8):1844, 2013
- Warnes CA, Williams RG, Bashore TM, et al: ACC/AHA 2008 Guidelines for the Management of Adults with Congenital Heart Disease: a report of the American College of Cardiology/American Heart Association Task Force on Practice Guidelines (Writing Committee to Develop Guidelines on the Management of Adults With Congenital Heart Disease). *Circulation* 118(23):e714, 2008
- Wellington K, Wagstaff AJ: Tranexamic acid: a review of its use in the management of menorrhagia. *Drugs* 63(13):1417, 2003
- World Health Organization: International statistical classification of diseases and related health problems—10th revision, edition 2010. Geneva, World Health Organization, 2010
- World Health Organization: WHO recommendations for the prevention and treatment of postpartum haemorrhage. Geneva, World Health Organization, 2012
- Zwart JJ, Dupuis JR, Richters A, et al: Obstetric intensive care unit admission: a 2-year nationwide population-based cohort study. *Intensive Care Med* 36(2):256, 2010

akusher-lib.ru

SECTION 2

ANTEPARTUM



Ectopic Pregnancy

EPIDEMIOLOGY AND INCIDENCE	112
ETIOLOGY AND RISK	113
ANATOMY	113
DIAGNOSIS	114
SURGICAL THERAPY	118
MEDICAL THERAPY	121
EXPECTANT MANAGEMENT	123
INTERSTITIAL PREGNANCY	123
OVARIAN PREGNANCY	126
CERVICAL PREGNANCY	126
ABDOMINAL PREGNANCY	127
HETEROTOPIC PREGNANCY	128
CESAREAN SCAR PREGNANCY	128

An ectopic or extrauterine pregnancy is one in which the blastocyst implants anywhere other than the endometrial lining of the uterine cavity. As such, they account for 1 to 2 percent of reported pregnancies in the United States (Zane, 2002). With the advent of a sensitive and specific radioimmunoassay for the β -subunit of human chorionic gonadotropin (β -hCG), combined with high-resolution transvaginal sonography (TVS), the initial presentation of a woman with an ectopic pregnancy is seldom as life threatening as in the past. Nevertheless, ectopic pregnancies remain an important cause of morbidity

and mortality in the first trimester of pregnancy in the United States.

EPIDEMIOLOGY AND INCIDENCE

Reported ectopic pregnancy incidence rates are not as reliable as in the past. The dramatic improvements in diagnosis and outpatient treatment protocols render national hospital discharge statistics invalid. That said, one evaluation within the Kaiser Permanente system from 1997 to 2000 estimated a rate of 20.7 per 1000 pregnancies (Van Den Eeden, 2005). More recently, Hoover and colleagues (2010) queried a large claims database for women aged 15 to 44 years who were privately insured in the United States between 2002 and 2007 and calculated a rate of 6.4 per 1000 pregnancies. However, this reduction in ectopic pregnancy rate might not accurately reflect cases occurring in higher-risk, lower-socioeconomic, uninsured populations. Namely, Stulberg and associates (2014) reviewed 2004 to 2008 Medicaid claims data and confirmed that black women were 46 percent more likely to experience an ectopic pregnancy compared with white women. They reported a rate of 14.0 per 1000 pregnancies in the 14 states evaluated.

In modern gynecologic practice, several factors help explain the incidence of ectopic pregnancies:

1. Greater prevalence of sexually transmitted diseases, specifically chlamydial infections (Ljubin-Sternak, 2014; Rajkhowa, 2000)
2. Diagnostic tools with improved sensitivity
3. Tubal factor infertility and corrective surgery to restore tubal patency (Ankum, 1996)
4. Women with delayed childbearing and their accompanied use of assisted reproductive technologies (ART), which carry increased ectopic pregnancy risks (Li, 2014a)
5. Increased intrauterine device (IUD) use and tubal sterilization, which predispose to ectopic pregnancy with method failure (Heinemann, 2015; Mol, 1995).

TABLE 8-1. Risk Factors for Ectopic Pregnancy

Factor	Odds Ratio (95% CI)
Prior ectopic pregnancy	12.5 (7.5, 20.9)
Prior tubal surgery	4.0 (2.6, 6.1)
Smoking >20 cigarettes per day	3.5 (1.4, 8.6)
Prior STD with confirmed PID by laparoscopy and/or positive test for <i>Chlamydia trachomatis</i>	3.4 (2.4, 5.0)
Three or more prior spontaneous miscarriages	3.0 (1.3, 6.9)
Age \geq 40 years	2.9 (1.4, 6.1)
Prior medical or surgical abortion	2.8 (1.1, 7.2)
Infertility >1 year	2.6 (1.6, 4.2)
Lifetime sexual partners >5	1.6 (1.2, 2.1)
Previous IUD use	1.3 (1.0, 1.8)

IUD = intrauterine device; PID = pelvic inflammatory disease; STD = sexually transmitted disease.

Data from Bouyer, 2003; Buster, 1999.

ETIOLOGY AND RISK

An appreciation of risk factors for ectopic pregnancy may lead to a more timely diagnosis. As summarized in [Table 8-1](#), documented tubal pathology, surgery to restore tubal patency, and tubal sterilization carry the highest risks for fallopian tube obstruction and subsequent ectopic pregnancy. A woman with two prior ectopic pregnancies has a 10- to 16-fold increased chance for another (Barnhart, 2006; Skjeldestad, 1998).

Of other risks, recurrent chlamydial infection causes intraluminal inflammation and subsequent fibrin deposition with tubal scarring (Hillis, 1997). Moreover, despite subsequent negative culture results, chlamydial antigens can persist to trigger a delayed hypersensitivity reaction with continued scarring (Toth, 2000). In contrast to endotoxin-producing *Neisseria gonorrhoeae*, which causes rapid, virulent pelvic inflammation, chlamydial inflammatory response is chronic and peaks at 7 to 14 days. This chronic inflammation can lead to arrest of the descending embryo while providing a proimplantation signal for embryos within the fallopian tube (Shaw, 2010).

Smoking, which may be a surrogate marker for sexually transmitted infections, also increases the risk of ectopic pregnancy. This risk is three- to fourfold in women who consume more than one pack of cigarettes daily (Saraiya, 1998). The increased rate of ectopic pregnancy among smokers undergoing ART was verified in a metaanalysis by Waylen and associates (2009). In addition, animal studies show that the fallopian tube is directly affected by cigarette smoke. Smoking alters oocyte cumulus complex pick-up and embryo transport by its effects on ciliary function and smooth muscle contraction (Shaw, 2010; Talbot, 2005). Also, oviductal transport of embryos is mediated in part by the cannabinoid receptor (CB1), which is influenced by endocannabinoid signaling. Chronic exposure to

nicotine can affect endocannabinoid levels and lead to fallopian tube dysfunction (Horne, 2008).

ART for sub- or infertile couples is another risk. It has an associated 0.8-percent incidence of ectopic pregnancy per transfer and 2.2-percent per clinical pregnancy (Coste, 2000). Interestingly, recent series are finding significant reductions in ectopic pregnancy rates associated with in vitro fertilization (IVF) if frozen-thawed embryos are used instead of those derived from fresh cycles (2.22 versus 4.62 percent) (Fang, 2015; Huang, 2014). In women undergoing IVF, the main risk factors for ectopic pregnancy are tubal factor infertility and hydrosalpinges (Strandell, 1999; Van Voorhis, 2006). Moreover, “atypical” implantation is more common following ART. These include interstitial, abdominal, cervical, ovarian, or heterotopic pregnancies. A heterotopic pregnancy is an intrauterine pregnancy (IUP) coexistent with an extrauterine pregnancy.

Age also increases the ectopic pregnancy rate. Women aged 35 to 44 years have a threefold risk of ectopic pregnancy compared with those aged 15 to 25 years (Goldner, 1993). These have been attributed to age-related hormonal changes that alter tubal function (Coste, 2000).

When considering a contraceptive’s role in ectopic pregnancy, the absolute risk (the risk of any women experiencing an ectopic pregnancy) and the conditional risk (the risk a given pregnancy will be an ectopic pregnancy) are both weighed. Most contraceptives effectively prevent pregnancies and thereby lower the absolute risk of an ectopic pregnancy. However, if pregnancy does occur, some methods increase the conditions that favor ectopic implantation. For example, the contraceptive failure rates of the levonorgestrel-releasing intrauterine system (LNG-IUS) and the copper IUD are extremely low and have an adjusted hazard ratio for ectopic pregnancy of 0.26 (Heinemann, 2015). However, the IUD mechanisms of action are more effective in preventing intrauterine implantation. Thus, if an IUD fails, a higher proportion of resulting pregnancies are likely to be ectopic (Furlong, 2002). Of other methods, progestin-only contraceptive pills have a slightly increased rate because of their effects to diminish tubal motility. Tubal sterilization can be followed by an ectopic pregnancy and is also discussed in [Chapter 33](#) (p. 527). This risk is doubled in women younger than 30 years at the time of sterilization, partially because of age-related fecundity.

ANATOMY

As described in [Chapter 3](#) (p. 43), the fallopian tube contains interstitial, isthmic, ampullary, and infundibular portions. Of these, the interstitial portion is the most proximal, and muscle of the tubal wall merges with the myometrium. This segment has a lumen with a simple, stellate cross-section ([Fig. 3-13](#), p. 44). The isthmic portion of the fallopian tube has a narrow lumen with a thick wall. It is approximately 2 cm in length and has few longitudinal mucosal folds. The ampulla has thin walls and makes up most of the fallopian tube. It contains primary, secondary, and tertiary longitudinal mucosal folds throughout, and these folds favor ovum fertilization. Logically, this is where

ectopic pregnancies typically implant. The infundibulum is the distal, trumpet-shaped end lined by fimbriae and connected to the ovary.

Lack of a submucosal layer within the fallopian tube provides easy access for the fertilized ovum to burrow through the epithelium and allow implantation within the muscular wall. Moreover, absent resistance allows early trophoblast penetration. As the rapidly proliferating trophoblast erodes the muscularis layer, maternal blood pours into the spaces within the trophoblastic or adjacent tissue.

With this pattern of invasion, the anatomic location of a tubal pregnancy may predict the extent of damage. Senterman and coworkers (1988) studied histologic samples from 84 isthmic and ampullary pregnancies and reported that half of the ampullary pregnancies were intraluminal, and the muscularis was preserved in 85 percent of these. Conversely, isthmic gestations were found both intra- and extraluminally with greater disruption of the tubal wall.

Nearly 95 percent of ectopic pregnancies implant in the fallopian tube (Bouyer, 2002). Other uncommon sites are individually described later in the chapter. Bilateral simultaneous ectopic pregnancies are rare, and their estimated prevalence is 1 of every 200,000 pregnancies (al-Awwad, 1999).

DIAGNOSIS

■ Symptoms

Many women with a small, unruptured ectopic pregnancy have unremarkable clinical findings. In these instances, early diagnosis of ectopic pregnancy is aided by a high index of suspicion.

Classic symptoms of ectopic pregnancy are amenorrhea followed by vaginal bleeding and abdominal pain on the affected side. Other pregnancy discomforts such as breast tenderness, nausea, and urinary frequency may accompany more ominous findings. Of these, shoulder pain worsened by inspiration can be caused by phrenic nerve irritation from subdiaphragmatic blood. Vasomotor disturbances such as vertigo and syncope may reflect hemorrhagic hypovolemia.

However, no constellation of symptoms secures the diagnosis with reliability (Dart, 1999). Thus, every sexually active reproductive-aged woman who has abdominal pain or vaginal bleeding should be screened for pregnancy. The diagnosis is considered strongly in those with risk factors.

Rarely, ectopic pregnancies have been the source of abdominal pain in women who previously underwent hysterectomy (Fylstra, 2009). Presumably, postoperative fistulous connections allow sperm to access an ovulated ovum. Possibilities include a nonobliterated cervical stump after supracervical hysterectomy, fistula following vaginal cuff infection, or prolapsed fallopian tube.

■ Physical Findings

Although some women have orthostatic findings, normal vital signs are unreliable to exclude a ruptured ectopic pregnancy. Birkhahn and associates (2003) employed the shock index to evaluate the possibility of ruptured ectopic pregnancy. This index reflects heart rate divided by systolic blood pressure

($HR \div SBP$) and is used to evaluate trauma patients for hypovolemic or septic shock. The normal range lies between 0.5 and 0.7 for nonpregnant patients. A shock index >0.85 and a systolic blood pressure <110 mm Hg are highly suggestive of a potentially life-threatening gynecologic emergency, such as a ruptured ectopic pregnancy (Polena, 2015).

Abdominal and pelvic findings are notoriously scarce in many women before tubal rupture. With rupture, however, nearly three fourths will have marked tenderness during both abdominal and pelvic examination. Pain is aggravated with cervical manipulation, which most likely reflects posterior cul-de-sac peritoneal irritation from blood. A pelvic mass, including fullness posterolateral to the uterus, can be palpated in approximately 20 percent of women. Initially, an ectopic pregnancy may feel soft and elastic, whereas extensive hemorrhage produces a firmer consistency. Many times, discomfort precludes palpation of the mass, and limiting examinations may help avert iatrogenic rupture.

■ Laboratory Findings

Serial serum β -hCG measurements and TVS are the most valuable diagnostic aids to confirm clinical suspicions of an ectopic pregnancy (Fig. 8-1). Human chorionic gonadotropin is a glycoprotein produced by syncytiotrophoblast and can be detected in serum as early as 8 days after the luteinizing hormone surge. In normal pregnancies, serum β -hCG levels rise in a log-linear fashion until 60 or 80 days after the last menses, at which time values plateau at approximately 100,000 IU/L. Given the variability between assays of 5 to 10 percent, interpretation of serial values is more reliable when performed by the same laboratory. With a robust uterine pregnancy, serum β -hCG levels should increase at least 53 to 66 percent every 48 hours (Barnhart, 2004; Kadar, 1982). In hemodynamically stable women, adding a third serum β -hCG level on day 4 or 7 could correct the diagnosis of a pregnancy of unknown location in an additional 7 to 13 percent of patients (Zee, 2014). This additional time and data may better ascertain the location and viability of the pregnancy. However, the value of this added data point should be weighed against the increased chance of ectopic pregnancy rupture in the interim. Nevertheless, inadequately rising serum β -hCG levels indicate only a dying pregnancy, not its location.

Frequently, women present with an unsure last menstrual period, and an educated guess of gestational age is made. In these cases, correlation between the serum β -hCG concentration and TVS findings becomes especially important, as discussed in the next section.

As an adjunctive test, determination of a serum progesterone concentration is used by some when serum β -hCG determinations and sonographic findings are inconclusive (Carson, 1993; Stovall, 1992). Serum progesterone concentrations vary minimally between 5 and 10 weeks' gestation, thus a single value is sufficient. Mol and colleagues (1998) performed a metaanalysis of 22 studies to assess the accuracy of a single serum progesterone level to differentiate ectopic from uterine pregnancy. They found that results were most accurate when approached from the viewpoint of *healthy versus dying pregnancy*. With serum progesterone




FIGURE 8-1 Algorithm of ectopic pregnancy evaluation. ^aAbnormal IUPs may be treated by D & C, medical regimens, or expectant management. ^bExpectant management may be appropriate in a small select group of women with very low β -hCG levels that are dropping. β -hCG = β -human chorionic gonadotropin; D & C = dilatation and curettage; IUP = intrauterine pregnancy; TVS = transvaginal sonography.

levels <5 ng/mL, a dying pregnancy was detected with near perfect specificity and with a sensitivity of 60 percent. Conversely, values >20 ng/mL had a sensitivity of 95 percent with specificity approximating 40 percent to identify a healthy pregnancy. Ultimately, serum progesterone levels can be used to buttress a clinical impression, but they alone cannot reliably differentiate between an ectopic and uterine pregnancy (Guha, 2014).

■ Sonography

High-resolution sonography has revolutionized the clinical management of women with a suspected ectopic pregnancy. However, routine sonography without a clinical suspicion of ectopic pregnancy does not improve diagnostic and triage efficiency. With TVS, a gestational sac is usually visible between $4\frac{1}{2}$ and 5 weeks after the last menstrual period, the yolk sac appears between 5 and 6 weeks after the last menstrual period, and a fetal pole with cardiac activity is first detected at $5\frac{1}{2}$ to 6 weeks after the last menstrual period. With transabdominal sonography, these structures are visualized slightly later. The sonographic diagnosis of ectopic pregnancy rests on visualization of an adnexal mass separate from the ovary (Fig. 8-2).

When the last menstrual period is unknown, serum β -hCG testing is used to define expected sonographic findings. Each institution must define a β -hCG discriminatory value, that is, the lower limit at which an examiner can reliably visualize pregnancy. At most institutions, this value is a concentration between 1500 and 2000 IU/L. Accurate IUP diagnosis by TVS is three times more likely if the initial β -hCG level is above this value. A fetal pole is usually recognized when the serum β -hCG concentration has reached 5000 IU/L, and embryonic cardiac activity is usually recognized when the serum β -hCG level has reached 17,000 IU/L. Technical challenges include coexisting leiomyomas, adenomyosis, or intrauterine devices, which can visually hinder the ability to accurately diagnose an intrauterine gestation. Moreover, multifetal gestations may have sufficient trophoblast to produce β -hCG levels above the discriminatory value when they have not yet reached structural development to be seen sonographically (Gurel, 2007; Ko, 2014).

In addition to these exceptional cases, the absence of a uterine pregnancy when β -hCG levels are above the discriminatory value may suggest an abnormal pregnancy that is an ectopic, an incomplete abortion, or a resolving completed abortion. For example, despite total passage of products of conception with complete abortion, β -hCG testing may still be positive while original circulating β -hCG is metabolized and cleared. Conversely, sonographic findings obtained when β -hCG values lie below the discriminatory value are not diagnostic in nearly two thirds of cases (Barnhart, 1999).

In an attempt to unify the language used with sonographic diagnosis of early pregnancies, a consensus statement was published. The following five categories were agreed upon for diagnosis based upon sonographic findings: (1) definitive ectopic pregnancy (extrauterine gestational sac with yolk sac and/or embryo, with or without cardiac activity), (2) probable ectopic pregnancy (inhomogeneous adnexal mass or extrauterine saclike structure), (3) pregnancy of unknown location (PUL) (no signs of either an ectopic pregnancy or IUP), (4) probable

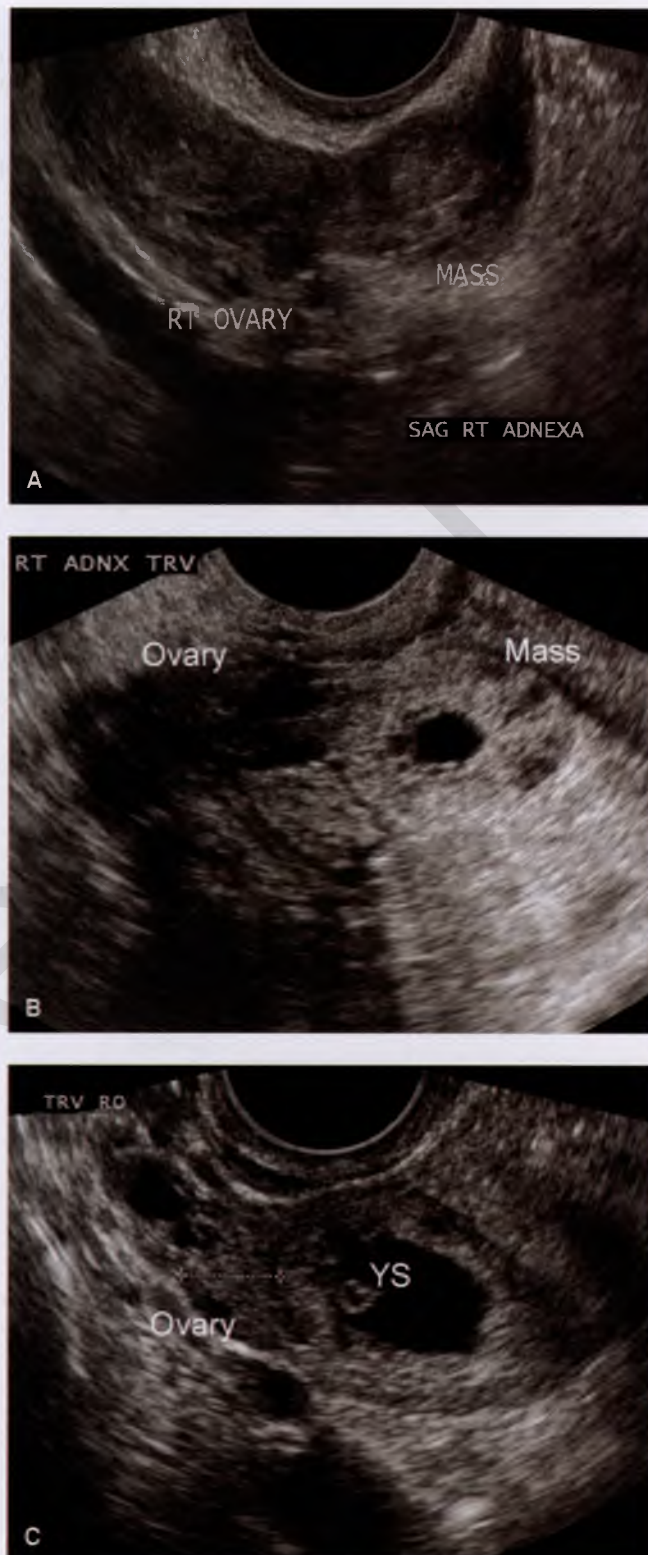

FIGURE 8-2 Transvaginal sonographic findings with various ectopic pregnancies. For sonographic diagnosis, an ectopic mass should be seen in the adnexa separate from the ovary and may be seen: (A) as an inhomogeneous adnexal mass, (B) as an empty extrauterine sac with a hyperechoic ring, or (C) as a yolk sac (YS) and/or fetal pole with or without cardiac activity within an extrauterine sac. Calipers mark the ovary.

IUP (intrauterine echogenic saclike structure), and (5) definite IUP (intrauterine gestational sac with yolk sac and/or embryo, with or without cardiac activity) (Barnhart, 2011).

Systematic sonographic evaluation is critical to establish the correct diagnosis. Most begin with the endometrial cavity. In pregnancies conceived spontaneously, identification of a uterine pregnancy effectively excludes the possibility of an ectopic implantation. When ART is employed, however, careful examination of the tube and ovary is performed even with an intrauterine pregnancy because heterotopic pregnancy rates may be as high as 1 per 100 (Tal, 1996).

An intracavitary fluid collection caused by partial breakdown of the decidua can create a *pseudogestational sac*, or *pseudosac*. This small, anechoic collection lies typically in the midline of the uterine cavity. In contrast, a normal gestational sac is eccentrically located (Dashefsky, 1988). Another intracavitary finding is a trilaminar endometrial pattern, which represents two adjacent edematous proliferative-phase endometrial layers (Lavie, 1996). For the diagnosis of ectopic pregnancy, this finding's specificity is 94 percent but with a sensitivity of only 38 percent (Hammond, 2005). Endometrial stripe thickness has not been well correlated with ectopic pregnancies. However, Moschos and Twickler (2008b) determined that in women with a PUL at presentation, no normal IUPs had a stripe thickness <8 mm.

The fallopian tubes and ovaries are also inspected. Visualization of an extrauterine yolk sac or embryo clearly confirms a tubal pregnancy, although such findings are present in only 15 to 30 percent of cases (Paul, 2000). In some cases, a halo or tubal ring surrounded by a thin hypoechoic area caused by subserosal edema can be seen. According to Burry and associates (1993), this has a positive predictive value of 92 percent and a sensitivity of 95 percent. Brown and coworkers (1994) conducted a metaanalysis of 10 studies to ascertain the best transvaginal sonographic criteria to diagnose ectopic pregnancy. They reported that the finding of any adnexal mass, other than a simple ovarian cyst, was the most accurate, with a sensitivity of 84 percent, specificity of 99 percent, positive predictive value of 96 percent, and negative predictive value of 95 percent. However, not all adnexal masses represent an ectopic pregnancy, and integration of sonographic findings with other clinical information is necessary.

Differentiation of an ectopic pregnancy from a corpus luteum cyst can be challenging. However, Swire and coworkers (2004) observed that the corpus luteum wall is less echogenic compared with both the halo and the endometrium. They found that a spongelike, lacelike, or reticular pattern seen within the cyst is classic for hemorrhage (Fig. 14-4, p. 228). Moreover, a corpus luteum is found within the parenchyma of an ovary, whereas an asymmetric ovary should raise suspicion of an ectopic pregnancy (Gurel, 2007). With transvaginal color Doppler imaging, placental blood flow within the periphery of the complex adnexal mass—the *ring of fire*—can be seen (Fig. 8-3). Although this finding can aid ectopic pregnancy diagnosis, it also can be seen with a corpus luteum of pregnancy (Pellerito, 1992). Finally, to help characterize a suspicious mass, an examiner can gently palpate an adnexum that is placed between the vaginal probe and the examiner's abdominal hand during real-time scanning. A mass that moves separately from the ovary suggests a tubal pregnancy, whereas a

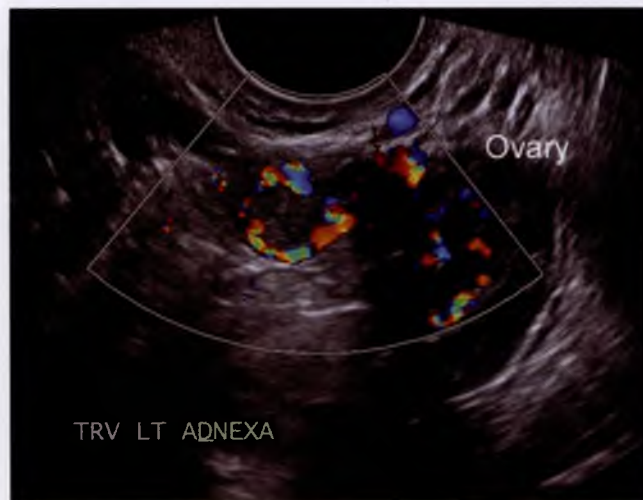

FIGURE 8-3 Color Doppler transvaginal sonography of an ectopic pregnancy. The “ring of fire” reflects increased blood flow within the fallopian tube wall and around the periphery of the pregnancy.

mass that moves synchronously more likely represents a corpus luteum cyst (Levine, 2007).

During sonographic evaluation of the pelvis, a small amount of free fluid, as little as 10 mL, is commonly present in the posterior cul-de-sac (Khalifé, 1998). Free fluid that contains low-level echoes or echogenic debris is consistent with hemoperitoneum with clot. If free fluid is seen extending to the fundus of the uterus, it is considered to be moderate in amount. Once identified, moderate free fluid should prompt further evaluation of the paracolic gutters and Morison pouch in the right upper quadrant to assess the fluid's extent (Fig. 17-10, p. 287). Blood in the paracolic gutters and Morison pouch indicates significant hemorrhage. Specifically, free fluid in Morison pouch typically is not seen until a hemoperitoneum reaches 400 to 700 mL (Branney, 1995; Rodgerson, 2001). Detection of peritoneal fluid in conjunction with an adnexal mass is highly predictive of ectopic pregnancy (Nyberg, 1991).

Despite technologic advances, the absence of suggestive findings does not exclude an ectopic pregnancy. In addition, TVS has not decreased the prevalence of tubal rupture or need for transfusions at the time of surgery (Atri, 2003). However, sonography has decreased the need for diagnostic laparoscopy or curettage or both to establish the diagnosis of ectopic pregnancy.

■ Endometrial Sampling

Several endometrial changes accompany ectopic pregnancy, and all lack coexistent trophoblast. Decidual reaction is found in 42 percent of samples, secretory endometrium in 22 percent, and proliferative endometrium in 12 percent (Lopez, 1994). Many recommend that the absence of trophoblastic tissue be confirmed by curettage before methotrexate (MTX) treatment is given (Barnhart, 2002; Chung, 2011; Shaunik, 2011). Investigators found that the presumptive diagnosis of ectopic pregnancy is inaccurate in nearly 40 percent of cases without histologic exclusion of a spontaneous pregnancy loss. Nevertheless, the need for and method of endometrial sampling must carefully be weighed against the limited maternal risks of MTX.

Endometrial biopsy with a Pipelle catheter was studied as an alternative to curettage and found inferior. The sensitivity of obtaining chorionic villi ranged from 30 to 63 percent (Barnhart, 2003b; Ries, 2000). By comparison, frozen section of curettage fragments to identify products of conception is accurate in more than 90 percent of cases (Barak, 2005; Li, 2014b; Spandorfer, 1996).

OUTCOMES

Without intervention, an ectopic tubal pregnancy can lead to tubal abortion, to tubal rupture, or to spontaneous resolution. *Tubal abortion* is the expulsion of products through the fimbrial end of the fallopian tube. This tissue can then either regress or reimplant in the abdominal cavity. With reimplantation, bleeding or pain necessitating surgical intervention is a common complication. *Tubal rupture* is usually associated with significant intraabdominal hemorrhage. With *spontaneous resolution*, small ectopic pregnancies die and are resorbed without adverse patient effects.

Reductions in morbidity and mortality rates are directly related to the early diagnosis of ectopic pregnancies prior to rupture and catastrophic hemorrhage. Early diagnosis also may allow for conservative therapeutic approaches, preserved reproductive capacity, and reduced overall treatment costs.

SURGICAL THERAPY

■ Laparotomy versus Laparoscopy

An ectopic pregnancy can be surgically removed via either of these routes. At least three prospective studies have compared laparotomy with laparoscopic surgery for this indication (Lundorff, 1991; Murphy, 1992; Vermesh, 1989). Their findings are summarized as follows:

1. Overall, tubal patency determined at second-look laparoscopy did not differ between these routes. However, higher rates of ipsilateral adhesions were found in the laparotomy group.
2. Each method was followed by a similar number of subsequent uterine pregnancies.
3. Subsequent ectopic pregnancies were less frequent in women treated laparoscopically, although this difference in rate was not significant.
4. Laparoscopy resulted in shorter operative times, less blood loss, fewer analgesic requirements, and shorter hospital stays.
5. Laparoscopic surgery was significantly less successful in resolving a tubal pregnancy. However, this was balanced by the just-mentioned benefits of laparoscopy.
6. The costs for laparoscopy were significantly lower than for laparotomy, although some argue that costs are similar when cases converted to laparotomy are considered (Fouk, 1996).

Thus, with modern instrumentation and improved laparoscopic skills, most pelvic surgeons now select minimally invasive surgery (MIS) to treat ectopic pregnancies in suitable candidates. A general discussion of laparoscopy in pregnancy is found in Chapter 15 (p. 240). Even for a clinically stable patient with hemoperitoneum, ruptured ectopic pregnancies

may be treated via MIS (Sagiv, 2001). Among experienced surgeons, shorter operating times and expedited hemorrhage control were both advantages of laparoscopic intervention for ruptured ectopic pregnancies (Cohen, 2013). Although an unstable patient was previously considered a contraindication to laparoscopic surgery, many skilled surgeons feel they can safely and quickly enter the abdomen laparoscopically. That said, the lowered venous return and cardiac output associated with the pneumoperitoneum of laparoscopy must be factored into the decision to select MIS for hypovolemic patients.

Laparotomy offers a potential advantage to laparoscopy if salpingostomy is planned. A metaanalysis using data from two trials concluded that compared with laparotomic salpingostomy, laparoscopic salpingostomy leads to one case of persistent trophoblastic disease for every 12 women undergoing a laparoscopic approach (Mol, 2008). However, residual tissue responds well to MTX, and this is weighed against the risks of laparotomy.

■ Conservative versus Radical Surgery

Two multicenter, randomized controlled trials have been completed to date to guide the choice between conservative surgery—laparoscopic salpingostomy, and definitive treatment—laparoscopic salpingectomy. The European Surgery in Ectopic Pregnancy (ESEP) study randomized women with a healthy contralateral fallopian tube to salpingectomy ($n = 231$) or salpingostomy ($n = 215$). After surgery, the cumulative rates of ongoing pregnancy by natural conception did not differ significantly between groups (56 versus 61 percent, respectively) (Mol, 2014). In the DEMETER trial, patients with “active ectopic pregnancies” were randomly assigned to either salpingectomy or salpingostomy. Similar to the ESEP study, the subsequent 2-year rate for achieving an IUP did not differ between groups (64 versus 70 percent, respectively) (Fernandez, 2013).

Salpingectomy, performed for ectopic pregnancy, either by laparotomy or laparoscopy, should resolve ectopic pregnancy 100 percent of the time, because the fallopian tube containing the ectopic implantation is completely removed. One hazard of conservative surgery and medical therapy for ectopic pregnancy is the possibility of residual trophoblastic tissue in the tube continuing to proliferate, causing symptoms, and even resulting in tubal rupture. To summarize the literature, this risk of incomplete removal of the trophoblastic tissue from the tube is 2 to 11 percent with laparotomy and 5 to 20 percent with laparoscopy. A prophylactic postoperative dose of MTX to prevent persistent trophoblasts would need to be given to 10 women to prevent one case (Mol, 2008). Therefore, close observation with serial measurement of β -hCG levels is the preferred option.

■ Salpingectomy

If the contralateral fallopian tube appears normal, then salpingectomy is a reasonable treatment option that avoids the 5- to 8-percent complication rate caused by persistent or recurrent ipsilateral ectopic pregnancies (Rulin, 1995).

Many laparoscopic techniques have been described to perform salpingectomy, and two options are presented here. First, following abdominal entry, the affected fallopian tube is identified, and atraumatic forceps grasp, elevate, and extend the tube.

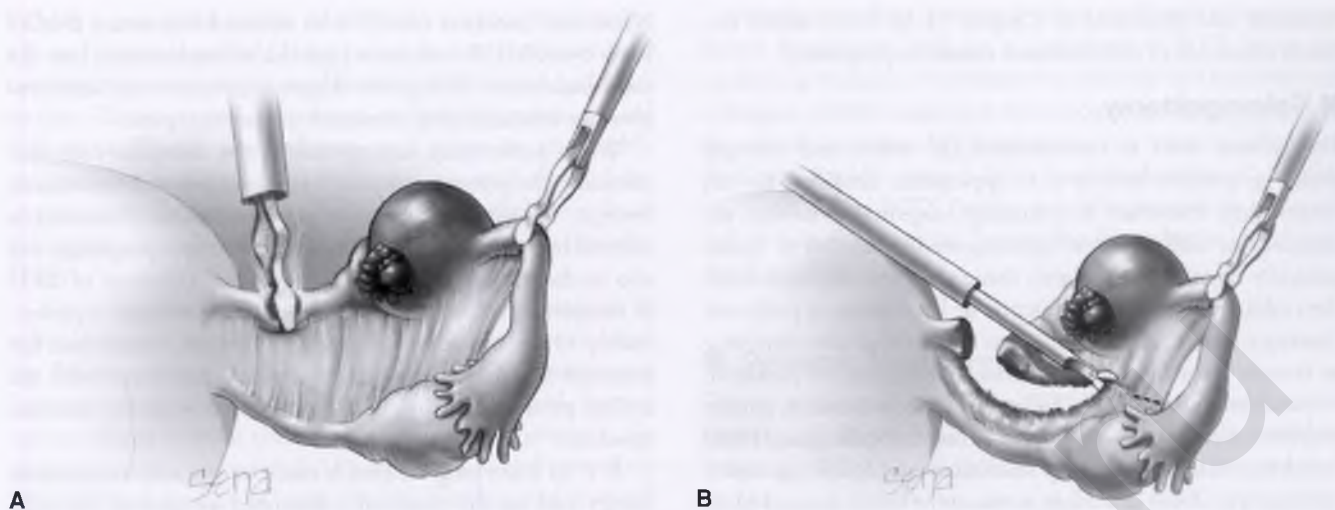


FIGURE 8-4 Technique for salpingectomy. **A.** Bipolar tool coagulates the proximal fallopian tube to achieve hemostasis prior to transection. **B.** Once vessels within a segment of the mesosalpinx are rendered hemostatic, laparoscopic scissors cut through that portion. This process is repeated serially along the entire mesosalpinx length. (Reproduced with permission from Thompson MJ, Kho KA: Minimally invasive surgery. In Hoffman BL, Schorge JO, Bradshaw KD, et al: Williams Gynecology, 3rd ed. New York, McGraw-Hill Education, 2016.)

The most proximal portion of the fallopian tube is desiccated and transected using the surgeon's preference of energy source. The mesosalpinx under the fallopian tube is sequentially coagulated and transected until the fallopian tube is freed (Fig. 8-4).

As a second option, the vascular supply to the fallopian tube within the mesosalpinx can instead be suture ligated. Figure 8-5 shows an endoscopic suture loop encircling the involved fallopian tube segment. Absorbable and delayed-absorbable suture loops are available, and either is suitable for ligation. Two or three suture loops are sequentially placed, and the tube distal to these ligatures is then cut free with scissors. The most proximal portion of the affected fallopian tube is desiccated to help prevent ipsilateral recurrence. Lim and associates (2007)

compared electrocautery of the tube and mesosalpinx during laparoscopic salpingectomy with laparoscopic suture-loop (Endoloop) ligation. Endoloop use was associated with significantly shorter operating times (48 versus 61 minutes) and lower postoperative pain scores.

Following excision, most tubal ectopic pregnancies are small and pliant. Thus, they can be held firmly by grasping forceps and drawn up into one of the accessory site cannulas. The laparoscopic cannula, grasping forceps, and ectopic tissue can then be removed together. Larger tubal ectopic pregnancies may be placed in an endoscopic sac to prevent fragmentation as they are removed through the laparoscopic port site. Alternatively, larger ectopic pregnancies can be morcellated with scissors within an enclosed bag. Tissue removal techniques are also

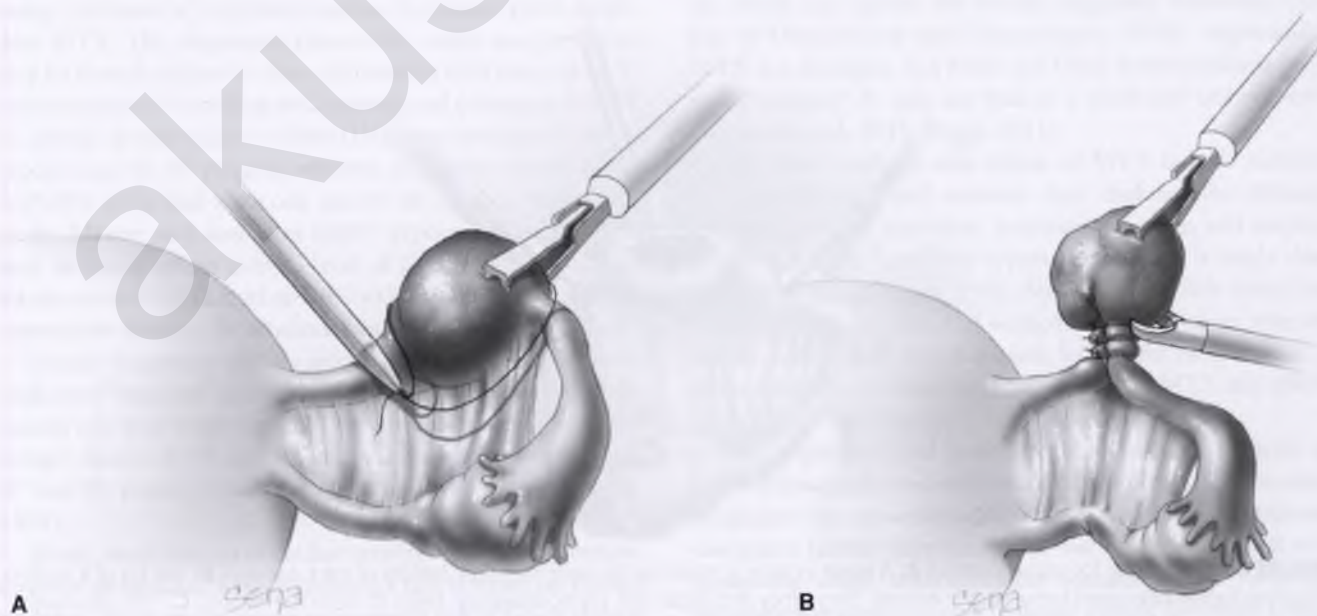

FIGURE 8-5 A. Endoscopic loop ligation. **B.** Looped portion of tube excised. (Reproduced with permission from Thompson MJ, Kho KA: Minimally invasive surgery. In Hoffman BL, Schorge JO, Bradshaw KD, et al: Williams Gynecology, 3rd ed. New York, McGraw-Hill Education, 2016.)

presented and illustrated in Chapter 14 (p. 234), which discusses treatment of other adnexal masses in pregnancy.

■ Salpingostomy

The woman who is hemodynamically stable and strongly desires to preserve fertility is an appropriate candidate for salpingostomy. However, if a treating surgeon has neither the laparoscopic skills nor the instrumentation needed to atraumatically remove trophoblastic tissue via linear salpingostomy, then salpingectomy by laparoscopy or laparotomy is preferred. Leaving a scarred, charred fallopian tube behind after removing an ectopic pregnancy does not preserve reproductive potential.

In addition, serum β -hCG levels may be a factor in patient selection. A retrospective study by Milad and colleagues (1998) found that ectopic-pregnancy resolution rates following salpingostomy were lower in women in whom the initial serum β -hCG level was >8000 IU/L. Supportive evidence for this comes from

Natale and associates (2003), who reported that serum β -hCG levels >6000 IU/L indicate a high risk of implantation into the tubal muscularis. This greater degree of invasion may leave trophoblast behind during extraction of the conceptus.

When performing salpingostomy, the fallopian tube surrounding the ectopic complex is first grasped with atraumatic forceps. To aid hemostasis, dilute vasopressin (Pitressin) is injected into the mesosalpinx beneath the ectopic pregnancy and also in the serosal layer overlying the mass. Dilutions of 20 U of vasopressin in 30 to 100 mL of saline are suitable. Approximately 10 mL of solution is typically sufficient. Vasopressin has potential systemic vasoconstrictive effects. Aspiration with the syringe prior to and during injection helps avoid intravascular injection.

A 1- to 2-cm long incision is made on the anti-mesosalpinx border and on the maximally distended portion of the tube that holds the pregnancy (Fig. 8-6). Suitable tools for incision

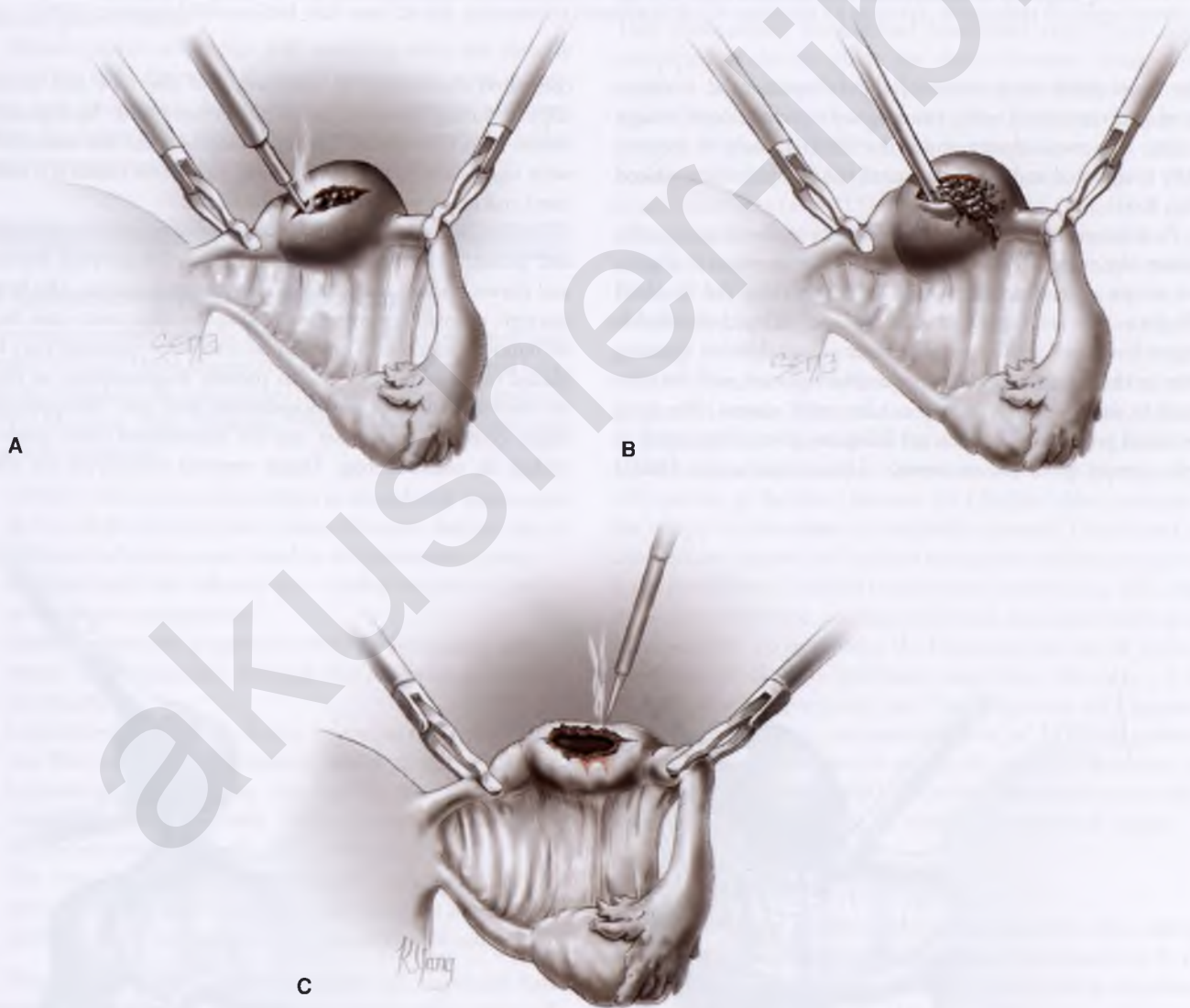


FIGURE 8-6 Technique for salpingostomy. **A.** A linear incision is made on the antimesenteric border of the tubal wall. **B.** The tip of a suction-irrigating tool is insinuated between the ectopic pregnancy and tubal wall. Hydrodissection helps to detach the mass. **C.** The salpingostomy site is made hemostatic. The ostomy site later closes by secondary intention without stitches. (Reproduced with permission from Thompson MJ, Kho KA: Minimally invasive surgery. In Hoffman BL, Schorge JO, Bradshaw KD, et al: Williams Gynecology, 3rd ed. New York, McGraw-Hill Education, 2016.)

include a monopolar needle tip electrode, scissors, bipolar needle, or Harmonic scalpel. The products of conception are then carefully removed using a combination of blunt and hydrodissection. Electrosurgical coagulation of bleeding points can aid hemostasis. Finally, the abdomen and pelvis are thoroughly irrigated and suctioned free of all tubal placental tissue. Subsequent intraabdominal implantation of trophoblastic tissue can explain some cases of persistent serum β -hCG levels (Bucella, 2009).

A novel approach to the conservative surgical treatment of a distal fallopian tube ectopic pregnancy involves a device called the fallopian tube stripping forceps (FTSF). The laparoscopic instrument has two clamp plates that, when closed, form a narrow ellipse to milk the fallopian tube free of products. In their observational trial with 102 women, Liu and coworkers (2014) found the rates of intraoperative bleeding and of recurrent ectopic pregnancy to be lower in the stripping-forceps group compared with a group undergoing salpingostomy. The rates of persistent ectopic pregnancy or subsequent spontaneous IUP did not differ. This method awaits additional investigation.

MEDICAL THERAPY

Medical treatment of ectopic pregnancy with MTX is preferred by most, if feasible. The best candidate for medical therapy is a woman who is asymptomatic and motivated and who has resources to be compliant with surveillance. Absolute contraindications for medical therapy with MTX include hemodynamic instability, active pulmonary or peptic ulcer disease, breastfeeding, moderate to severe anemia or thrombocytopenia, immunosuppression, and contraindications to MTX itself (American College of Obstetricians and Gynecologists, 2014; American Society for Reproductive Medicine, 2013). With medical therapy, there are some classic predictors of success.

First, the initial serum β -hCG level is the single best prognostic indicator of treatment success in women given single-dose MTX. The prognostic value of the other two predictors may be directly related to their relationship with serum β -hCG concentrations. According to Lipscomb and colleagues (1999), an initial serum value <5000 IU/L was associated with a success rate of 92 percent, whereas an initial concentration $>15,000$ IU/L had a success rate of 68 percent. In another study, Menon and associates (2007) reported that compared with an initial serum β -hCG level of 2000 to 4999 IU/L, an initial serum β -hCG level of 5000 to 9999 IU/L is nearly four times more likely to be associated with MTX therapy failure.

Ectopic pregnancy size is a second predictor, and many early trials used “large size” as an exclusion criterion. In one study, the success rate with single-dose MTX was 93 percent in cases with ectopic masses <3.5 cm, whereas success rates were between 87 and 90 percent when the mass was >3.5 cm (Lipscomb, 1998).

Third, identification of cardiac activity is a relative contraindication to medical therapy, although this is based on limited evidence. Most studies report an increased risk of failure if there is cardiac activity, however, a success rate of 87 percent has been reported (Lipscomb, 1998).

Investigators have evaluated other predictors of treatment failure. Extrauterine yolk sac as a predictor of MTX failure has conflicting evidence. A retrospective analysis by Lipscomb and colleagues (2009) found that this sonographic finding added to the risk of single-dose MTX failure but was not an independent predictor. Rapidly rising β -hCG levels both before (>50 percent) and during MTX therapy may also portend an increased risk of failure (American Society for Reproductive Medicine, 2013; Dudley, 2004).

Systemic Methotrexate

This is a folic acid antagonist that competitively inhibits the binding of dihydrofolic acid to the enzyme dihydrofolate reductase. This leads to reduced amounts of purines and thymidylate and thereby an arrest of DNA, RNA, and protein synthesis. It inhibits rapidly proliferating tissue, such as bone marrow, buccal and intestinal mucosa, malignant cells, and trophoblastic tissue. Indications for use in gynecology are cancer chemotherapy and early pregnancy termination.

The drug can be given orally, intravenously, or intramuscularly (IM) or can be directly injected into the ectopic pregnancy sac. Currently, parenteral MTX administration is used most commonly for this indication.

Prior to MTX therapy, a complete blood count, serum creatinine and β -hCG levels, liver function tests, and blood type and Rh status are obtained (American Society for Reproductive Medicine, 2013). Moreover, all except blood typing are repeated prior to additional doses (Lipscomb, 2007). With administration, women are counseled to avoid the following until treatment is completed: folic acid-containing supplements, which can competitively reduce MTX binding to dihydrofolate reductase; nonsteroidal antiinflammatory drugs, which reduce renal blood flow and delay drug excretion; alcohol, which can predispose to concurrent hepatic enzyme elevation; sunlight, which can provoke MTX-related dermatitis; and sexual activity, which can rupture the ectopic pregnancy (American College of Obstetricians and Gynecologists, 2014). Importantly, MTX is a teratogen, is a Food and Drug Administration pregnancy category X, and can lead to a profound embryopathy (Nurmohamed, 2011; Poggi, 2011).

The most common side effects of MTX include stomatitis, conjunctivitis, and transient liver dysfunction, although myelosuppression, mucositis, pulmonary damage, and anaphylactoid reactions have been reported with even a single dose of 50 to 100 mg (Isaacs, 1996; Straka, 2004). Side effects are seen in as many as a third of women treated, however, they are usually self-limited. In some cases, leucovorin (folinic acid) is given following treatment to blunt or reverse MTX side effects (Table 8-2). Such therapy is termed *leucovorin rescue*.

The single-dose and multidose MTX protocols shown in Table 8-2 are associated with overall resolution rates for ectopic pregnancy that approximate 90 percent. To date, Alleyassin and coworkers (2006) have completed the only randomized trial comparing single- and multidose administrations. Although the study was underpowered to detect a small difference in success rates, they did observe that 89 percent in the single-dose group and 93 percent in the multidose group were successfully

TABLE 8-2. Medical Treatment Protocols for Ectopic Pregnancy

	Single Dose	Multidose
Dosing	One dose; repeat if necessary	Up to four doses of both drugs until serum β -hCG declines by 15%
Medication Dosage		
Methotrexate	50 mg/m ² BSA (day 1)	1 mg/kg, days 1, 3, 5, and 7
Leucovorin	NA	0.1 mg/kg days 2, 4, 6, and 8
Serum β-hCG level	Days 1 (baseline), 4, and 7	Days 1 (baseline), 3, 5, and 7
Indication for additional dose	If serum β -hCG level does not decline by 15% from day 4 to day 7 Less than 15% decline during weekly surveillance	If serum β -hCG level declines <15%, give additional dose; repeat serum β -hCG in 48 hours and compare with previous value; maximum four doses
Surveillance	Once 15% decline achieved, then weekly serum β -hCG levels until undetectable	
Methotrexate Contraindications		
Sensitivity to MTX	Intrauterine pregnancy	Peptic ulcer disease
Tubal rupture	Hepatic, renal, or hematologic dysfunction	Immunodeficiency
Breastfeeding	Active pulmonary disease	

BSA = body surface area; β -hCG = β -human chorionic gonadotropin; MTX = methotrexate; NA = not applicable.

treated. When analyzed from the standpoint of treatment failure, single-dose therapy had a 50-percent higher failure rate compared with multidose therapy (6 versus 4 of 54 patients). Lipscomb and colleagues (2005) reviewed their institutional experience with MTX therapy in 643 consecutively treated patients. They found no significant differences in treatment duration, serum β -hCG levels, or success rates between the multi- and single-dose protocols—95 and 90 percent, respectively. Barnhart and associates (2003a) performed a metaanalysis of 26 studies that included 1327 women treated with MTX for ectopic pregnancy. Single-dose therapy was more commonly used because of simplicity. It was less expensive, was easily accepted because of less intensive posttherapy monitoring, and did not require leucovorin rescue (Alexander, 1996). The major limitation was that multidose treatment had a fivefold greater chance of success than single-dose therapy. Failures included women with tubal rupture, massive intraabdominal hemorrhage, and need for urgent surgery and blood transfusions. Ultimately, most women received between one and four doses of MTX. Interestingly, the initial serum β -hCG value was not a valid indicator of how many doses of MTX a patient would need for a successful outcome (Nowak-Markwitz, 2009). In the absence of adequately powered randomized trials comparing single- with multidose therapy, we use single-dose MTX.

Single-Dose Methotrexate

Intramuscular MTX given as a single dose has been the most widely used medical treatment of ectopic pregnancy. Various doses have been studied, and the most popular is a calculated dose of 50 mg/m² based on body surface area (BSA) (Stovall, 1993). In the small-randomized trial by Hajenius and colleagues (2000), treatment with 25 mg/m² was as effective as treatment with 50 mg/m². BSA can be determined using

various Internet-based BSA calculators, such as: <http://www.globalrph.com/bsa2.htm>.

Close monitoring is imperative. A serum β -hCG level is determined prior to MTX administration and is repeated on days 4 and 7 following injection. Levels usually continue to rise until day 4. The day 4 and 7 serum values are then compared. If a decline of 15 percent or more is seen, then weekly serum β -hCG levels are drawn until they measure <5 IU/L. A decline less than 15 percent is seen in approximately 20 percent of treated women. In such cases, a second 50-mg/m² dose is given, and the protocol is restarted. Approximate time to resolution for all women averages 36 days, but in some, treatment requires 109 days (Lipscomb, 1998).

Multidose Methotrexate

The most common regimen for this is seen in Table 8-2. It consists of up to four doses of parenteral MTX, followed by adjunctive doses of leucovorin given 24 hours later. Serial serum β -hCG concentrations are obtained. If a 15-percent decline from the previous value is not attained—for example, days 1 to 3—an additional MTX/leucovorin dose is given, and the serum β -hCG level is repeated 2 days later. A maximum of four doses are given, and weekly serum β -hCG level surveillance continues until values are undetectable.

A hybrid “two-dose” protocol has been proposed in an effort to balance the efficacy and convenience of the two most commonly used protocols (Barnhart, 2007). The regimen involves administering 50 mg/m² of intramuscular MTX on days 0 and 4 without leucovorin rescue. Although the protocol is still considered experimental, no safety concerns were noted in the 101 patients treated, and the success rate approached 87 percent. A recent comparison of the single-dose and “two-dose” MTX protocols found equivalent success rates (87 versus 90, respectively) with a trend toward

increased need for repeated doses in the single-dose cohort (Gungorduk, 2011).

■ Surveillance

During the first few days following MTX administration, up to half of women experience abdominal pain that can be controlled with mild analgesics. This *separation pain* presumably results from tubal distention caused by tubal abortion or hematoma formation or both (Stovall, 1993). In some cases, inpatient observation with serial hematocrit determinations and gentle abdominal examinations help assess the need for surgical intervention.

In all cases of conservative treatment, β -hCG levels should be followed until a nonpregnant level is reached to ensure complete resolution of the ectopic pregnancy. However, a declining β -hCG level does not eliminate the possibility of tubal rupture. Heard and associates (1998) reported an academic emergency department experience with 11 ruptured ectopic pregnancies previously treated with MTX. They found that seven of the cases of rupture occurred with declining levels of β -hCG. Rupture of an ectopic gestation can occur with a β -hCG level as low as 10 IU/L.

Posttherapy monitoring assesses treatment success and screens for signs of persistent or progressing ectopic pregnancy. Most medical management protocols have well-defined surveillance schedules. In the absence of symptoms, bimanual examinations are limited to avoid the theoretical risk of manual tubal rupture. Importantly, sonographic monitoring of ectopic mass dimensions can be misleading after serum β -hCG levels have declined to <15 IU/L. Brown and colleagues (1991) described persistent masses to be resolving hematomas rather than persistent trophoblastic tissue. For this reason, posttherapy sonography is reserved for suspected complications such as tubal rupture. Most recommend contraception for 3 to 6 months after successful medical therapy with MTX, as this drug may persist in human tissues for up to 8 months after a single dose (Warkany, 1978).

If the woman is D negative and her partner has a blood group that is either D positive or unknown, then 300 μ g of anti-D immune globulin should be given to prevent anti-D isoimmunization. In women not planning for a proximate pregnancy, contraceptive counseling is provided.

■ Medical versus Surgical Therapy

Several randomized trials have compared MTX treatment with laparoscopic surgery. One multicenter trial compared a multidosed MTX protocol with laparoscopic salpingostomy and found no differences for tubal preservation and primary treatment success (Hajenius, 1997). However, in this same study group, health-related quality-of-life factors such as pain, posttherapy depression, and decreased perception of health were significantly worsened after systemic MTX compared with laparoscopic salpingostomy (Nieuwkerk, 1998).

When single-dose MTX is compared with surgical intervention, results are conflicting. In two separate studies, single-dose MTX was overall less successful in resolving pregnancy than was laparoscopic salpingostomy, although tubal patency

and subsequent IUP rates were similar between both groups (Fernandez, 1998; Sowter, 2001). Women treated with MTX had significantly better physical functioning immediately following therapy, but psychologic functioning measures did not differ. Krag Moeller and associates (2009) reported the results from their prospective randomized trial that had a median surveillance of 8.6 years during which future pregnancy rates were evaluated. Ectopic-resolution success rates were not significantly different between those managed surgically and those treated with MTX. Moreover, cumulative spontaneous IUP rates were not significantly different between the MTX group (73 percent) and the surgical group (62 percent).

Based on these studies, we conclude that women who are hemodynamically stable and in whom there is a small tubal diameter, no fetal cardiac activity, and serum β -hCG concentrations <5000 IU/L have similar outcomes with medical or surgical management. Despite lower success rates with medical therapy for women with larger tubal size, higher serum β -hCG levels, and fetal cardiac activity, medical management can be offered to the motivated woman who understands the risks of emergency surgery in the event of treatment failure.

EXPECTANT MANAGEMENT

In selected women, some choose close observation in anticipation that the ectopic pregnancy will be spontaneously resorbed. Intuitively, it is difficult to accurately predict which women will have an uncomplicated course with such management. Although an initial serum β -hCG concentration has been shown to best predict outcome, the range varies widely. For example, initial values <200 IU/L predict successful spontaneous resolution in 88 to 96 percent of attempts, whereas values >2000 IU/L had success rates of only 20 to 25 percent (Elson, 2004; Trio, 1995). Even with declining values, when the initial β -hCG level exceeded 2000 IU/L, the success rate was only 7 percent (Shalev, 1995). Interestingly, in this study, ipsilateral tubal patency and 1-year fertility rates did not differ with either success or failure of expectant management.

Close monitoring is warranted because the risk of tubal rupture persists despite low and declining serum β -hCG levels. An argument could be made that the minimal side effects of MTX make it preferable to a potentially prolonged surveillance and patient anxiety.

INTERSTITIAL PREGNANCY

This form of ectopic pregnancy implants in the proximal tubal segment that lies within the muscular uterine wall. Swelling lateral to the insertion of the round ligament is the characteristic anatomic finding (Fig. 8-7). Incorrectly, these are sometimes called cornual pregnancies, but this term correctly describes conceptions that develop in the horns of uteri with müllerian anomalies (Lau, 1999; Moawad, 2010). In the past, rupture of interstitial pregnancies usually took place following 8 to 16 weeks of amenorrhea because of the greater distensibility of the myometrium covering the interstitial segment of fallopian tube. Risk factors are similar to others discussed, although

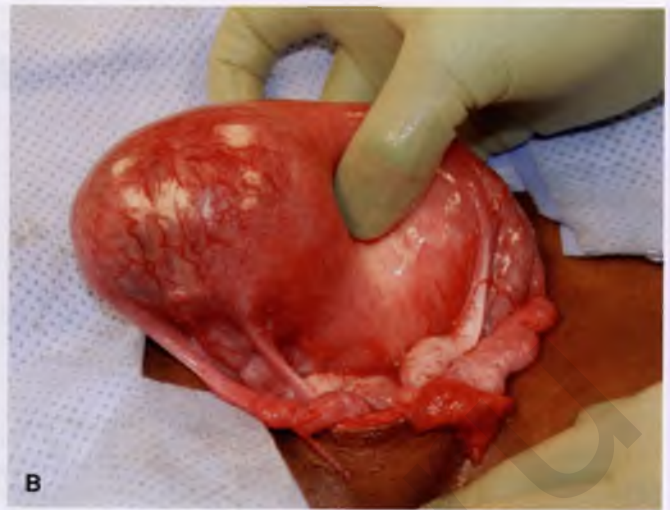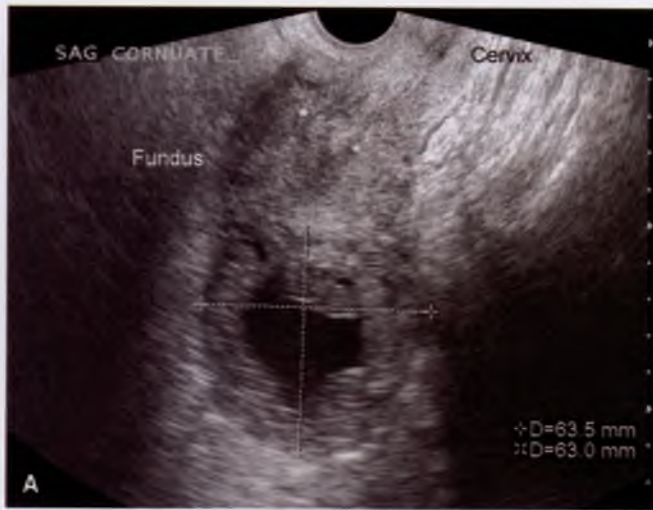


FIGURE 8-7 Interstitial pregnancy. **A.** Transvaginal sonogram, parasagittal view shows an empty uterine cavity (*white asterisks*) and a mass superior and lateral to the uterine fundus (*calipers*). An embryo lies within the gestational sac. **B.** Same interstitial pregnancy prior to resection.

previous ipsilateral salpingectomy is a specific risk factor for interstitial pregnancy (Lau, 1999). Because of the proximity of these pregnancies to the uterine and ovarian arteries, there is a risk of severe hemorrhage, which is associated with mortality rates as high as 2.5 percent (Tulandi, 2004).

Although small case reports describe successful treatment with MTX, interstitial ectopic pregnancies usually are diagnosed late and require surgical resection. With cornuectomy, the pregnancy, its surrounding myometrium, and the ipsilateral fallopian tube are excised en bloc. The fallopian tube is removed to avoid future ectopic pregnancy in this tube (Fig. 8-8). Attempts should always be made to preserve the ovary.

Next, infiltration of the adjacent myometrium with dilute vasopressin and/or ligation of both ascending uterine arteries can assist with minimizing surgical blood loss. The cornual serosa surrounding the pregnancy is then incised with an electro-surgical blade (Fig. 8-9). The incision is angled inward as it is deepened in a V-shaped manner. Once the pregnancy is excised, hemostasis can be achieved with electro-surgical blade coagulation or with interrupted sutures.

Last, the myometrial bed is closed in a multilayer fashion using absorbable or delayed-absorbable suture in an interrupted or continuous running fashion (Fig. 8-10). Chromic suture is an option and has a lower tendency to cut through the congested myometrium. However, the degree of wound tension required to reapproximate the contracted myometrium may require greater tensile strength, which can be provided by a delayed-absorbable suture. One choice is polyglactin 910 (Vicryl).

In cases with rupture and brisk bleeding, another approach to cornuectomy may be needed. First, two clamps may have quickly been placed across the base of the cornu to immediately control hemorrhage. Following salpingectomy, the cornual myometrium above these clamps is sharply removed. The myometrium within each clamp is then suture ligated with a transfixing stitch. When needed, additional interrupted sutures that approximate the myometrium can assist with hemostasis.

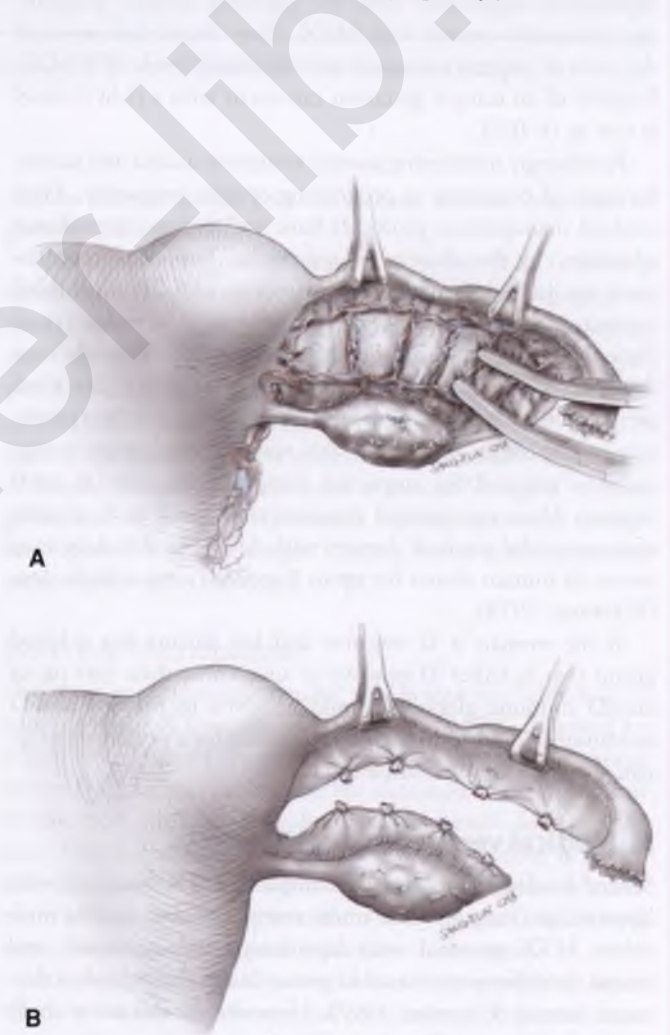


FIGURE 8-8 Technique for cornuectomy. **A.** Salpingectomy is completed first. Clamps are placed distally across the mesosalpinx and the intervening tissue is sharply transected. **B.** This process continues serially and medially until the entire mesosalpinx is transected. (Reproduced with permission from Hoffman BL, Corton MM: *Surgeries for benign gynecologic conditions*. In Hoffman BL, Schorge JO, Bradshaw KD, et al: *Williams Gynecology*, 3rd ed. New York, McGraw-Hill Education, 2016.)

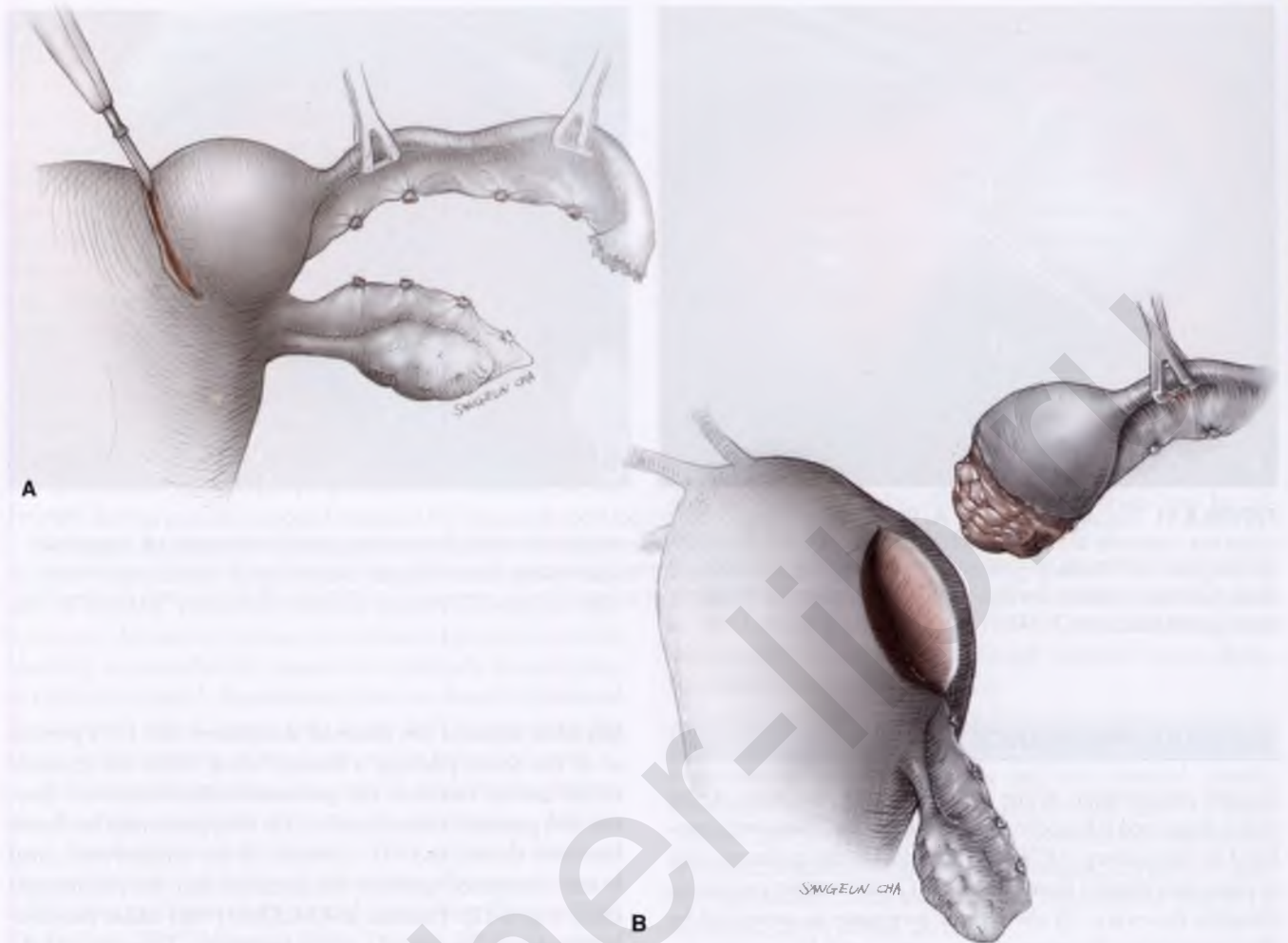


FIGURE 8-9 A. The uterine serosa surrounding the ectopic mass is incised. **B.** This incision continues deeply at a slight inward angle to create a wedge-shaped myometrial defect.

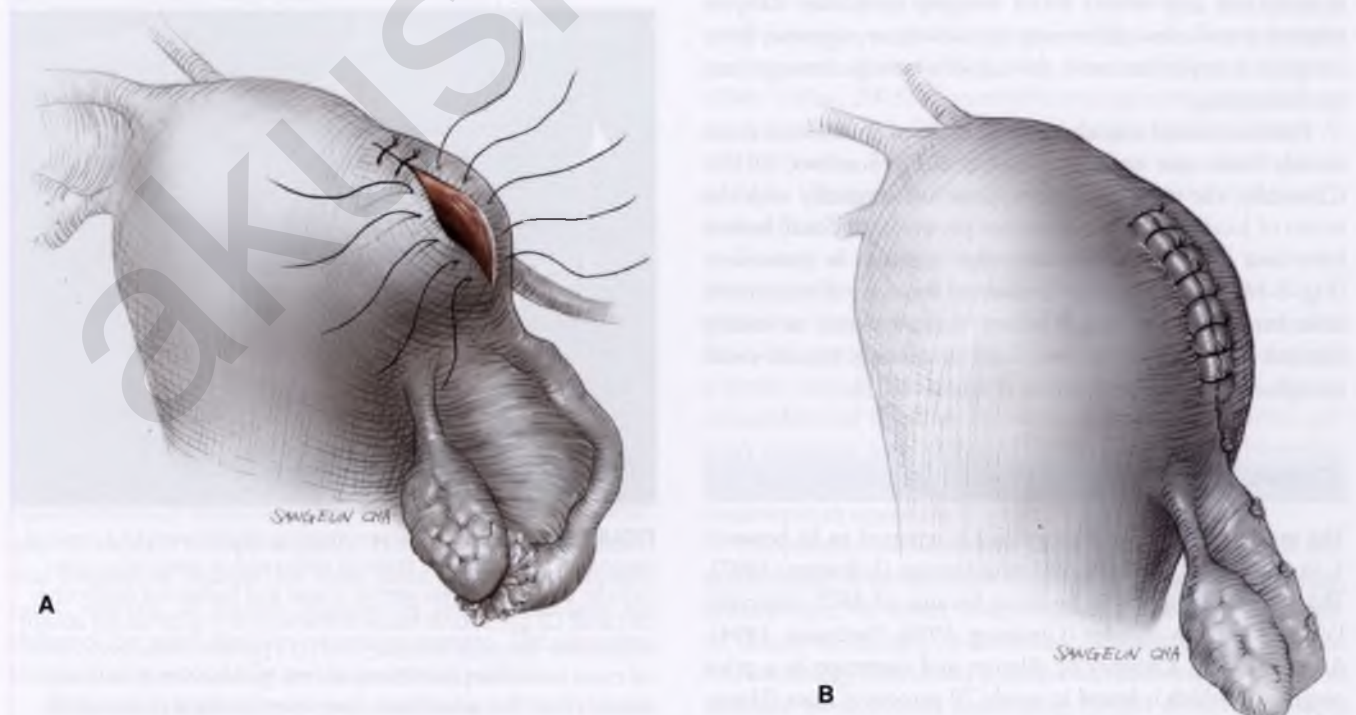


FIGURE 8-10 A. The myometrium is then closed in layers with a running or interrupted suture line. **B.** Last, the uterine serosa is closed in a running subserosal or interrupted suture line.

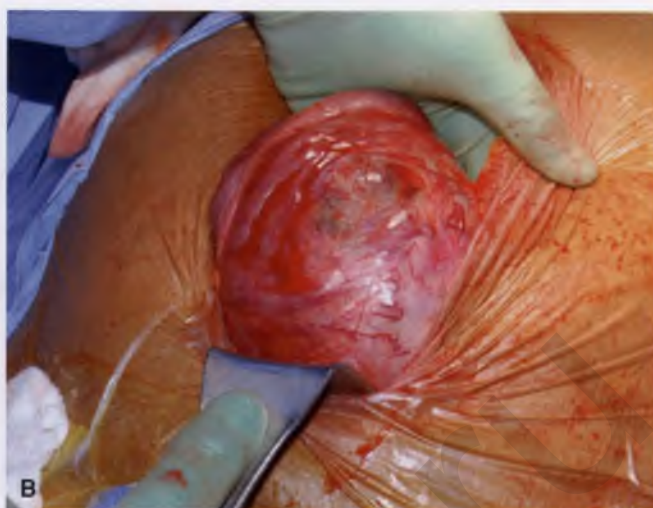
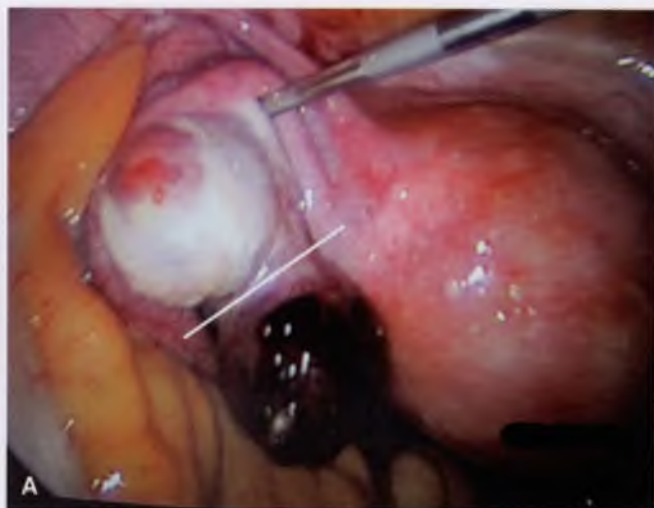
FIGURE 8-11 Ovarian pregnancies. **A.** The ectopic pregnancy bulges out from the ovary. The ipsilateral fallopian tube was normal. The white line marks the line of resection during laparoscopy. (Used with permission from Drs. Alyson Garcia and David Rogers.) **B.** Large ovarian pregnancy at 13 weeks' gestation removed by oophorectomy during laparotomy. (Used with permission from Dr. Kyler Elwell. Reproduced with permission from Cunningham FG, Leveno KJ, Bloom SL, et al (eds): Ectopic pregnancy. In Williams Obstetrics, 24th ed. New York, McGraw-Hill Education, 2014.)

OVARIAN PREGNANCY

Ectopic implantation of the fertilized egg in the ovary is rare and is diagnosed if four clinical criteria are met. These were outlined by Spiegelberg (1878) and include: (1) the ipsilateral tube is intact and distinct from the ovary; (2) the ectopic pregnancy occupies the ovary; (3) the ectopic pregnancy is connected by the uteroovarian ligament to the uterus; and (4) ovarian tissue can be demonstrated histologically in the placental tissue. A more recent increased incidence in ovarian pregnancy likely is artifactual and reflects better imaging modalities. Despite improved resolution, differentiating an ovarian pregnancy from a ruptured corpus luteum in the face of a hemoperitoneum can be challenging.

Evidence-based management of these pregnancies accrues mainly from case reports (Hassan, 2012; Scutiero, 2012). Classically, the mass is usually approached surgically with the intent of local resection and ovarian preservation. Small lesions have been managed by ovarian wedge resection or cystectomy (Fig. 8-11). Oophorectomy is reserved for cases of uncontrollable hemorrhage or larger lesions. Last, systemic or locally injected methotrexate has been used successfully to treat small unruptured ovarian pregnancies (Pagidas, 2013).

CERVICAL PREGNANCY

The incidence of cervical pregnancy is reported to be between 1 in 8600 and 1 in 12,400 pregnancies (Ushakov, 1997). The incidence appears to be rising because of ART, especially IVF and embryo transfer (Ginsburg, 1994; Pattinson, 1994). Another risk is a history of dilation and curettage in a prior pregnancy, which is found in nearly 70 percent of cases (Hung, 1996; Pisarska, 1999). Four diagnostic criteria are necessary for cervical pregnancy confirmation: (1) cervical glands are

identified opposite the placental attachment site, (2) a portion of or the entire placenta is located below either the entrance of the uterine vessels or the peritoneal reflection on the anterior and posterior uterine surface, (3) fetal parts must be absent from the uterus, and (4) a portion of the endocervical canal is seen interposed between the gestation and the endometrial canal (Fig. 8-12). Paalman and McElin (1959) added the clinical diagnostic features of cervical pregnancy. These are: (1) the internal cervical os must be closed; (2) products of conception

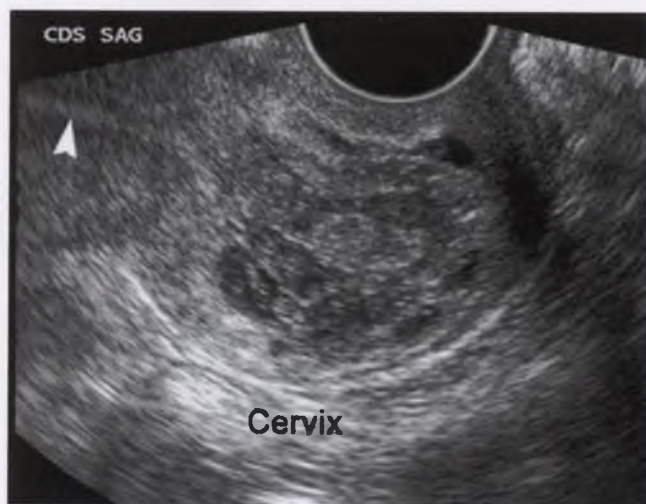

FIGURE 8-12 Transvaginal sonography, sagittal view of a cervical pregnancy. Sonographic findings with cervical pregnancy may include: (1) an hourglass uterine shape and ballooned endocervical canal; (2) gestational tissue at the level of the cervix; (3) absent intrauterine gestational tissue; and (4) a portion of the endocervical canal seen interposed between the gestation and the endometrial canal. The arrowhead marks the thin distal endometrial stripe. (Used with permission from Drs. Diane Twickler and Elysia Moschos.)

must be completely confined within and firmly attached to the endocervix; (3) uterine bleeding occurs in the absence of significant cramping; and (4) a soft, enlarged cervix equal to or larger than the uterine fundus is palpable.

Profuse hemorrhage can complicate the treatment of cervical pregnancies, and therefore a surgeon should have the capacity to use adjuvant options such as uterine artery embolization when initiating medical or surgical therapy. Kung and coworkers (1997) reviewed the use of MTX for the treatment of cervical pregnancies less than 12 weeks and found a 91-percent success rate for uterine preservation. Rather than systemic MTX, locally injected MTX was used more frequently in cases with ongoing cardiac activity. In fetuses with cardiac motion, local MTX may be complemented by adjunctive fetal potassium chloride (KCl) injection. At our institution, most unruptured cervical ectopic pregnancies are managed in this fashion.

Although conservative management is feasible for many women with cervical pregnancies, surgical intervention may also be selected. Procedures include suction curettage or hysterectomy. Moreover, in those with advanced gestations or with bleeding uncontrolled by conservative methods, hysterectomy is typically required. Importantly, patients should understand the increased risk of urinary tract injury with hysterectomy due to the close proximity of the ureters to the ballooned cervix.

With surgical evacuation of a cervical pregnancy by dilation and curettage, preventive steps may be advantageous. Authors have described preemptive ligation of the cervical branches of the uterine artery, intracervical vasopressin, and even the use of a Shirodkar cerclage to help control hemorrhage (Davis, 2008; De La Vega, 2007; Mesogitis 2005; Trojano, 2009). In cases of postprocedural hemorrhage, tamponade of the cervical implantation site using a Foley balloon can be considered prior to definitive treatment with hysterectomy (Fylstra, 2001).

ABDOMINAL PREGNANCY

Primary abdominal pregnancies are defined as conceptions that develop within the peritoneal cavity but are not tubal, ovarian, or intraligamentous pregnancies. Studdiford (1942) initially defined four criteria for primary abdominal pregnancy classification: (1) normal fallopian tubes and ovaries, (2) no evidence of uteroperitoneal fistula, (3) pregnancy related solely to the peritoneal surface, and (4) no evidence of secondary implantation following initial primary tubal nidation. Accounting for these criteria, a few theories have been postulated. Paternoster (1999) proposed that retrograde menstruation may reverse the course of the fertilized ovum in cases of delayed ovulation. Dmowski (2002) suggested that akin to uterine cancer, embryos could potentially travel along the lymphatic channels to subsequently implant retroperitoneally. However, *secondary abdominal pregnancies* account for most cases. With these, initially tubal, ovarian, or uterine pregnancies are released into the abdomen by tubal abortion or uterine rupture. The conceptus then implants secondarily on the peritoneal surface.

Abdominal pregnancies are rare, composing only 0.9 percent of ectopic pregnancies (Atrash, 1987). However, because of their associated complications, they confer a maternal mortality

rate that is nearly 8 times greater than that with tubal ectopic pregnancies. The most prominent complication is bleeding, which can be severe for several reasons. First, abdominal pregnancies in general reach a larger size before clinical identification or rupture. Thus, a bigger placenta, greater number of vessels, and wider vessel caliber all contribute to significant hemorrhage. Second, the placenta implants on surfaces that lack the contractility of uterine myometrium. Thus, placenta separation can lead to torrential and persistent bleeding, similar to that seen with profound uterine atony.

■ Diagnosis

As noted, a missed diagnosis is the main factor that contributes to the high associated maternal mortality rate. Abdominal pain is the most frequent symptom, but a pathognomonic pattern does not exist. Clinically, abnormal fetal positions may be palpated, or the cervix is displaced (Zeck, 2007).

Routine β -hCG testing to confirm pregnancy and earlier sonographic examination have helped reduce mortality rates in the United States (Atrash, 1987). Other laboratory tests are typically uninformative, although maternal serum alpha-fetoprotein levels may be elevated.

Sonographic clues include a fetus seen separate from the uterus or eccentrically positioned within the pelvis; lack of myometrium between the fetus and the maternal anterior abdominal wall or bladder; and extrauterine placental tissue (Sherer, 2007). Oligohydramnios is common but nonspecific. If needed, magnetic resonance (MR) imaging can provide superior information concerning placental implantation (Fig. 8-13) (Bertrand, 2009; Mittal, 2012).

■ Management

An abdominal pregnancy can be life-threatening, and management depends on gestational age at diagnosis. Some describe waiting until fetal viability with close surveillance (Gomez, 2008; Varma, 2003). Conservative management, however, carries a maternal risk for sudden and dangerous hemorrhage. At our institution, we counsel for intervention once the diagnosis is made. Certainly, before 24 weeks, conservative treatment is seldom justified.

Because of its rarity, only case reports and small case series provide evidence-based guidance. Poole and colleagues (2012) performed a systematic review of abdominal ectopic pregnancies with gestational ages of 20 weeks or less. They observed primary surgical intervention in 88 percent of cases due to intraabdominal bleeding. However, in cases found earlier, primary treatment with KCl or MTX can be employed. Nevertheless, nearly half of the medically treated women subsequently underwent an operation.

Preoperative considerations include the availability of surgeons skilled in retroperitoneal surgery and managing vascular, urinary tract, or bowel complications. Moreover, the hospital should be capable of delivering sufficient blood products. Anesthesiology staff ideally prepares for massive transfusion and intensive intraoperative monitoring. Similar to cervical ectopic pregnancy, adjunctive embolization procedures by an interventional radiologist may prove helpful.

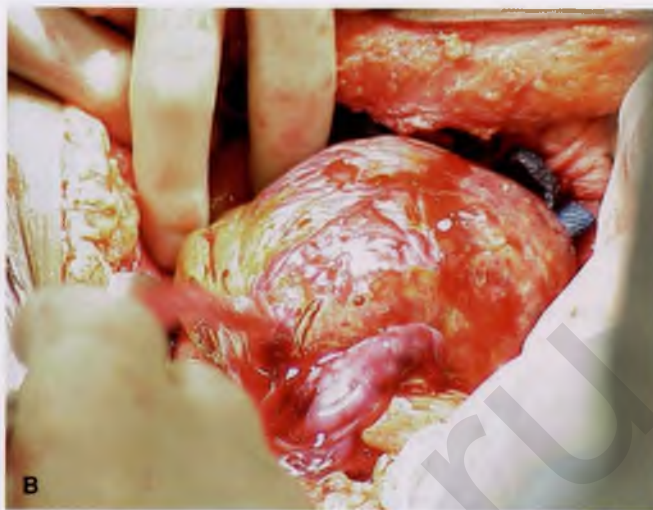
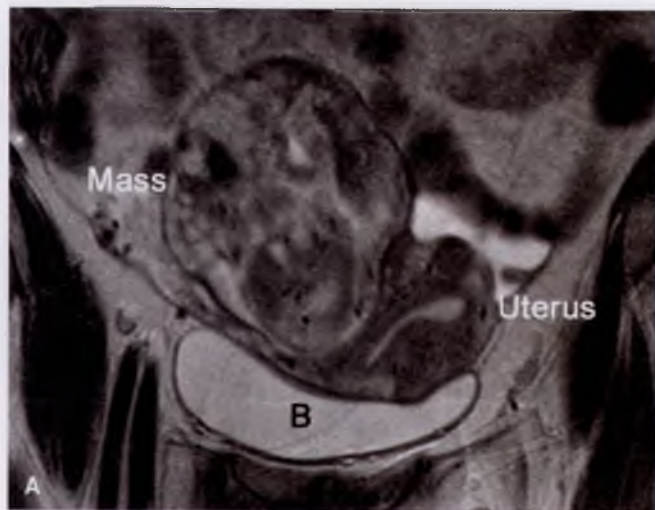


FIGURE 8-13 Abdominal pregnancy. **A.** Magnetic resonance image delineates the borders of this 18-week gestation. The uterus is small and deviated to the patient's left **B.** The conceptus was covered by a veil of omentum at the time of laparotomy. (Reproduced with permission from Hnat MD, Roberts S: Case report: a markedly elevated MSAFP. (update) in Cunningham FG, Leveno KL, Bloom SL, et al (eds), Williams Obstetrics, 22nd ed., New York, McGraw-Hill, 2008. Online. accessmedicine.com.)

With advanced abdominal pregnancies >20 weeks' gestation, surgery is primary treatment. The principal surgical objective is delivery of the fetus only and retention of the placenta. Following fetal delivery, the placental implantation site is carefully assessed, and unnecessary exploration that might provoke hemorrhage is avoided. Importantly, anatomy is commonly distorted and surrounding areas are extremely vascular. Placenta removal may precipitate massive hemorrhage as the normal hemostatic mechanism of myometrial contraction is absent. However, if the implantation site is already briskly bleeding, then en bloc resection is performed. The blood supply to the placenta should be ligated or occluded prior to tissue removal. In many ways, surgical management is similar to that for placenta percreta, which is detailed in Chapter 27 (p. 446).

Optimal postoperative placental management remains controversial (Roberts, 2005). Ideally, and usually depending on its size, placental function rapidly declines, and the placenta is resorbed. Notably, placental resorption may take years (Roberts, 2005; Valenzano, 2003). During postsurgical surveillance, serial sonography can be helpful, and disappearance of intraplacental Doppler flow may predict involution (Bajo, 1996). Serial serum β -hCG titers have limited utility and are not predictive of placental mass absorption. MTX has been used to accelerate the destruction of the retained placental tissue. However, this produces a large volume of necrotic tissue (Costa, 1991). This nidus almost uniformly creates in an intraabdominal infection that result in abscesses, sepsis, and thromboembolic phenomena (Rahman, 1982).

HETEROTOPIC PREGNANCY

A uterine pregnancy in conjunction with an extrauterine pregnancy is termed a heterotopic pregnancy. In the past, incidence estimates were computed to be 1 in 30,000 pregnancies, figuring incidences of dizygotic twinning and ectopic pregnancy of 1 percent each. In pregnancies that result

from ART, the rate of heterotopic pregnancies approximates 0.09 percent (Perkins, 2015). Proposed mechanisms include hydrostatic forces delivering the embryo into the cornual or tubal area, the tip of the catheter directing transfer toward the tubal ostia, or reflux of uterine secretions leading to retrograde tubal implantation.

Laparoscopic removal of the extrauterine pregnancy is the treatment of choice once discovered. Local or systemic MTX is contraindicated with a desired IUP due to teratogenicity risks. However, success has been reported using local KCl alone injected into the extrauterine sac.

CESAREAN SCAR PREGNANCY

This develops from implantation within the scar of a prior cesarean delivery through a microscopic tract in the myometrium. As such, it carries significant risks of serious maternal morbidity and mortality from massive hemorrhage. Fortunately, cesarean scar pregnancy (CSP) is uncommon, and reviews cite an incidence that approximates 1 in 2000 pregnancies (Sadeghi, 2010). These microscopic tracts can also stem from other prior uterine surgery—curettage, myomectomy, operative hysteroscopy—and perhaps from manual removal of the placenta (Ash, 2007). Differentiating between a cervicoisthmic pregnancy and a CSP can be difficult, and several investigators have described sonographic findings (Jurkovic, 2003; Moschos, 2008a). According to Godin (1997), four sonographic criteria satisfy the diagnosis: (1) an empty uterine cavity, (2) an empty cervical canal, (3) a gestational sac in the anterior part of the uterine isthmus, and (4) absence of healthy myometrium between the bladder and gestational sac (Fig. 8-14).

Despite a rising incidence of CSPs, there is no clear consensus on the optimal treatment modality. Of choices, a recent literature review by Cheung and coworkers (2015) reported success rates of 74 to 89 percent with local MTX infiltration. In contrast, Wang and associates (2014) reviewed their experi-

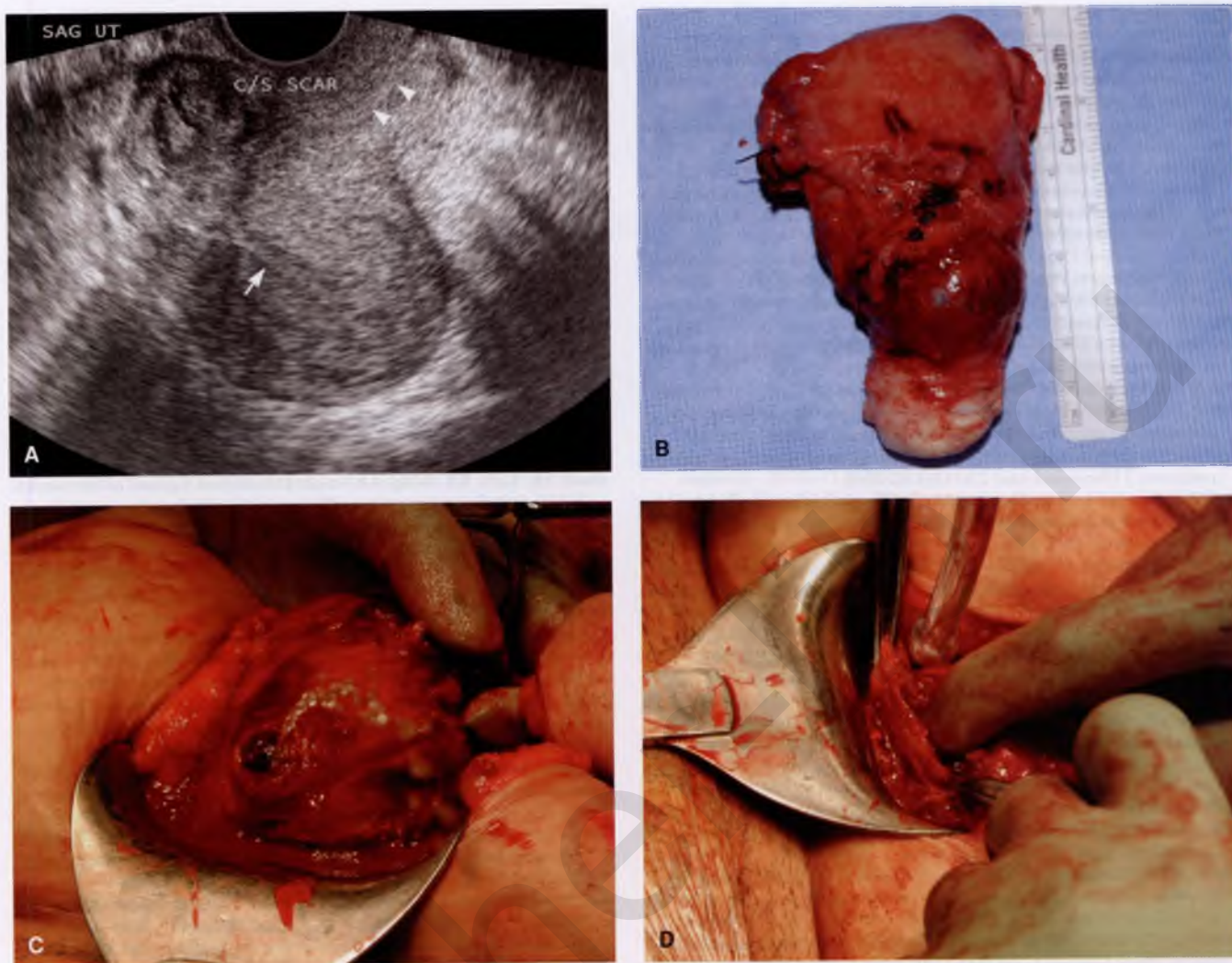


FIGURE 8-14 Cesarean scar pregnancy. **A.** Transvaginal sonogram of a uterus with a cesarean scar pregnancy (CSP) in a sagittal plane. An empty uterine cavity is identified by a bright hyperechoic endometrial stripe (*white arrow*). An empty cervical canal is similarly identified (*arrowheads*). **B.** In a different patient, a hysterectomy specimen contains a CSP. (Used with permission from Dr. Sunil Balgobin.) **C & D.** A stream of amniotic fluid follows rupture of a CSP's gestation sac during uterine elevation at laparotomy. In part D, the pregnancy has been excised, and the surgeon's index finger is inserted into the hysterotomy. Clamps mark the incision's lateral margins prior to layered closure of the myometrial defect. (Used with permission from Dr. C. Edward Wells.)

ence with hysteroscopic and laparoscopic resection of CSP and found quicker normalization of β -hCG levels and fewer complications with laparoscopy. Last, for women with no future fertility desires or with acute hemoperitoneum from rupture, hysterectomy may be performed. We have employed all three of these approaches and have tailored selection to individual patient circumstances (see Fig. 8-14).

SUMMARY

High-resolution transvaginal sonography and reliable biochemical markers of gestational pathology have made possible the early diagnosis of ectopic pregnancy. Despite this, a clinician must maintain a high index of suspicion in any reproductive-aged woman complaining of abdominal pain and/or vaginal bleeding. Early diagnosis allows for the use of medical or conservative surgical options, reduces the inci-

dence of rupture, and reduces overall maternal morbidity and mortality rates.

Laparoscopic salpingostomy or salpingectomy can be used in most cases of tubal ectopic pregnancy. Exceptions that would merit laparotomy can include significant pelvic adhesions that are suspected preoperatively or encountered at surgery, severe patient hypovolemia, a facility without suitable equipment, a surgeon with insufficient skills, or a patient with contraindications to laparoscopy in general. In contrast, medical therapy, including MTX, has a more selective application and can be safely used in those patients meeting pretreatment criteria, including compliance with postinjection surveillance.

Close posttreatment surveillance is necessary to ensure complete resolution of the ectopic pregnancy. Patients are counseled on the significantly increased risk of an ectopic pregnancy in subsequent pregnancies. Seeking care early will help ensure quick detection should this problem arise again.

REFERENCES

- al-Awwad MM, al Daham N, Escet JS: Spontaneous unruptured bilateral ectopic pregnancy: conservative tubal surgery. *Obstet Gynecol Surv* 54(9):543, 1999
- Alexander JM, Rouse DJ, Varner E, et al: Treatment of the small unruptured ectopic pregnancy: a cost analysis of methotrexate versus laparoscopy. *Obstet Gynecol* 88(1):123, 1996
- Alleyassin A, Khademi A, Aghahosseini M, et al: Comparison of success rates in the medical management of ectopic pregnancy with single-dose and multiple-dose administration of methotrexate: a prospective, randomized clinical trial. *Fertil Steril* 85(6):1661, 2006
- American College of Obstetricians and Gynecologists: Medical management of ectopic pregnancy. Practice Bulletin No. 94, June 2008, Reaffirmed 2014
- American Society for Reproductive Medicine: Medical treatment of ectopic pregnancy: a committee opinion. *Fertil Steril* 100(3):638, 2013
- Ankum WM, Mol BW, Van der Veen, F, et al: Risk factors for ectopic pregnancy: a meta-analysis. *Fertil Steril* 65(6):1093, 1996
- Ash A, Smith A, Maxwell D: Caesarean scar pregnancy. *BJOG* 114(3):253, 2007
- Atrash HK, Friede A, Hogue CJ: Abdominal pregnancy in the United States: frequency and maternal mortality. *Obstet Gynecol* 1987; 69: 333, 1987
- Atri M: Ectopic pregnancy versus corpus luteum cyst revisited: best Doppler predictors. *J Ultrasound Med* 22(11):1181, 2003
- Bajo JM, Garcia-Frutos A, Huertas MA: Sonographic followup of a placenta left in situ after delivery of the fetus in an abdominal pregnancy. *Ultrasound Obstet Gynecol* 7:285, 1996
- Barak SM, Oettinger A, Perri H, et al: Frozen section examination of endometrial curettings in the diagnosis of ectopic pregnancy. *Acta Obstet Gynecol Scand* 84(1):43, 2005
- Barnhart K, Hummel AC, Sammel MD, et al: Use of "2-dose" regimen of methotrexate to treat ectopic pregnancy. *Fertil Steril* 87(2):250, 2007
- Barnhart K, Sammel MD, Chung K, et al: Decline of serum human chorionic gonadotropin and spontaneous complete abortion: defining the normal curve. *Obstet Gynecol* 104(5 Pt 1):975, 2004
- Barnhart K, van Mello NM, Bourne T, et al: Pregnancy of unknown location: a consensus statement of nomenclature, definitions, and outcome. *Fertil Steril* 95(3):857, 2011
- Barnhart KT, Gosman G, Ashby R, et al: The medical management of ectopic pregnancy: a meta-analysis comparing "single dose" and "multidose" regimens. *Obstet Gynecol* 101(4):778, 2003a
- Barnhart KT, Gracia CR, Reindl B, et al: Usefulness of Pipelle endometrial biopsy in the diagnosis of women at risk for ectopic pregnancy. *Am J Obstet Gynecol* 188(4):906, 2003b
- Barnhart KT, Katz I, Hummel A, et al: Presumed diagnosis of ectopic pregnancy. *Obstet Gynecol* 100(3):505, 2002
- Barnhart KT, Sammel MD, Gracia CR, et al: Risk factors for ectopic pregnancy in women with symptomatic first-trimester pregnancies. *Fertil Steril* 86(1):36, 2006
- Barnhart KT, Simhan H, Kamelle SA: Diagnostic accuracy of ultrasound above and below the beta-hCG discriminatory zone. *Obstet Gynecol* 94(4):583, 1999
- Bertrand G, Le Ray C, Simard-Émond L, et al: Imaging in the management of abdominal pregnancy: a case report and review of the literature. *J Obstet Gynaecol Can* 31(1):57, 2009
- Birkhahn RH, Gaeta TJ, Van Deusen SK, et al: The ability of traditional vital signs and shock index to identify ruptured ectopic pregnancy. *Am J Obstet Gynecol* 189(5):1293, 2003
- Bouyer J, Coste J, Fernandez H, et al: Sites of ectopic pregnancy: a 10 year population-based study of 1800 cases. *Hum Reprod* 17(12):3224, 2002
- Bouyer J, Coste J, Shojaei T, et al: Risk factors for ectopic pregnancy: a comprehensive analysis based on a large case-control, population-based study in France. *Am J Epidemiol* 157(3):18, 2003
- Branney SW, Wolfe RE, Moore EE, et al: Quantitative sensitivity of ultrasound in detecting free intraperitoneal fluid. *J Trauma* 39(2):375, 1995
- Brown DL, Doubilet PM: Transvaginal sonography for diagnosing ectopic pregnancy: positivity criteria and performance characteristics. *J Ultrasound Med* 13(4):259, 1994
- Brown DL, Felker RE, Stovall TG, et al: Serial endovaginal sonography of ectopic pregnancies treated with methotrexate. *Obstet Gynecol* 77(3):406, 1991
- Bucella D, Buxant F, Anaf V, et al: Omental trophoblastic implants after surgical management of ectopic pregnancy. *Arch Gynecol Obstet* 280(1):115, 2009
- Burry KA, Thurmond AS, Suby-Long TD, et al: Transvaginal ultrasonographic findings in surgically verified ectopic pregnancy. *Am J Obstet Gynecol* 168(6 Pt 1):1796, 1993
- Buster JE, Pisarska MD: Medical management of ectopic pregnancy. *Clin Obstet Gynecol* 42(1):23, 1999
- Carson SA, Buster JE: Ectopic pregnancy. *N Engl J Med* 329(16):1174, 1993
- Cheung VY: Local methotrexate injection as the first-line treatment for cesarean scar pregnancy: review of the literature. *J Minim Invasive Gynecol* 22(5):753, 2015
- Chung K, Chandavarkar U, Opper N, et al: Reevaluating the role of dilation and curettage in the diagnosis of pregnancy of unknown location. *Fertil Steril* 96(3):659, 2011
- Cohen A, Almog B, Sarel A, et al: Laparoscopy versus laparotomy in the management of ectopic pregnancy with massive hemoperitoneum. *Int J Gynaecol Obstet* 123(2):139, 2013
- Coste J, Fernandez H, Joye N, et al: Role of chromosome abnormalities in ectopic pregnancy. *Fertil Steril* 74(6):1259, 2000
- Costa SD, Presley J, Bastert G: Advanced abdominal pregnancy. *Obstet Gynecol Surv* 46:515, 1991
- Cunningham FG, Leveno KJ, Bloom SL, et al (eds): Ectopic pregnancy. In *Williams Obstetrics*, 24th ed. New York, McGraw-Hill Education, 2014
- Dart RG, Kaplan B, Varaklis K: Predictive value of history and physical examination in patients with suspected ectopic pregnancy. *Ann Emerg Med* 33(3):283, 1999
- Dashefsky SM, Lyons EA, Levi CS, et al: Suspected ectopic pregnancy: endovaginal and transvesical US. *Radiology* 169(1):181, 1988
- Davis LB, Lathi RB, Milki AA, et al: Transvaginal ligation of the cervical branches of the uterine artery and injection of vasopressin in a cervical pregnancy as an initial step to controlling hemorrhage: a case report. *J Reprod Med* 53(5):365, 2008
- De La Vega GA, Avery C, Nemiroff R, et al: Treatment of early cervical pregnancy with cerclage, carboprost, curettage, and balloon tamponade. *Obstet Gynecol* 109(2 Pt 2):505, 2007
- Dmowski WP, Rana N, Ding J, et al: Retroperitoneal subpancreatic ectopic pregnancy following in vitro fertilization in a patient with previous bilateral salpingectomy: how did it get there? *J Assist Reprod Genet* 19:90, 2002.
- Dudley PS, Heard MJ, Sangi-Haghpeykar H, et al: Characterizing ectopic pregnancies that rupture despite treatment with methotrexate. *Fertil Steril* 82(5):1374, 2004
- Elson J, Taylor A, Banerjee S, et al: Expectant management of tubal ectopic pregnancy: prediction of successful outcome using decision tree analysis. *Ultrasound Obstet Gynecol* 23(6):552, 2004
- Fang C, Huang R, Wei LN, et al: Frozen-thawed day 5 blastocyst transfer is associated with a lower risk of ectopic pregnancy than day 3 transfer and fresh transfer. *Fertil Steril* 103(3):655.e.3, 2015
- Fernandez H, Capmas P, Lucot JP, et al: Fertility after ectopic pregnancy: the DEMETER randomized trial. *Hum Reprod* 28(5):1247, 2013
- Fernandez H, Yves Vincent SC, Pauthier S, et al: Randomized trial of conservative laparoscopic treatment and methotrexate administration in ectopic pregnancy and subsequent fertility. *Human Reprod* 13(11):3239, 1998
- Foull RA, Steiger RM: Operative management of ectopic pregnancy: a cost analysis. *Am J Obstet Gynecol* 175(1):90, 1996
- Furlong LA: Ectopic pregnancy risk when contraception fails. A review. *J Reprod Med* 47(11):881, 2002
- Fylstra DL: Ectopic pregnancy after hysterectomy: a review and insight into etiology and prevention. *Fertil Steril* 94(2):431, 2009
- Fylstra DL, Coffey MD: Treatment of cervical pregnancy with cerclage, curettage and balloon tamponade. A report of three cases. *J Reprod Med* 46(1):71, 2001
- Ginsburg ES, Frates MC, Rein MS, et al: Early diagnosis and treatment of cervical pregnancy in an in vitro fertilization program. *Fertil Steril* 61(5):966, 1994
- Godin PA, Bassil S, Donnez J: An ectopic pregnancy developing in a previous caesarian section scar. *Fertil Steril* 67(2):398, 1997
- Goldner TE, Lawson HW, Xia Z, et al: Surveillance for ectopic pregnancy—United States, 1970-1989. *MMWR* 42(6):73, 1993
- Gomez E, Vergara L, Weber C, et al: Successful expectant management of an abdominal pregnancy diagnosed at 14 weeks. *J Matern Fetal Neonatal Med* 21(12):917, 2008
- Guha S, Ayim F, Ludlow J, et al: Triaging pregnancies of unknown location: the performance of protocols based on single serum progesterone or repeated serum hCG levels. *Hum Reprod* 29(5):938, 2014
- Gungorduk K, Ascioglu O, Yildirim G, et al: Comparison of single-dose and two-dose methotrexate protocols for the treatment of unruptured ectopic pregnancy. *J Obstet Gynaecol* 31(4):330, 2011
- Gurel S, Sarikaya B, Gurel K, et al: Role of sonography in the diagnosis of ectopic pregnancy. *J Clin Ultrasound* 35(9):509, 2007
- Hajenius PJ, Engelsbel S, Mol BW, et al: Randomised trial of systemic methotrexate versus laparoscopic salpingostomy in tubal pregnancy. *Lancet* 350(9080):774, 1997
- Hajenius PJ, Mol BW, Bossuyt PM, et al: Interventions for tubal ectopic pregnancy. *Cochrane Database Syst Rev* 2:CD000324, 2000

- Hammoud AO, Hammoud I, Bujold E, et al: The role of sonographic endometrial patterns and endometrial thickness in the differential diagnosis of ectopic pregnancy. *Am J Obstet Gynecol* 192(5):1370, 2005
- Hassan S, Arora R, Bhatia K: Primary ovarian pregnancy: case report and review of literature. *BMJ Case Rep* Nov 21, 2012
- Heard K, Kendall J, Abbott J: Rupture of ectopic pregnancy after medical therapy with methotrexate: a case series. *J Emerg Med* 16(6):857, 1998
- Heinemann K, Reed S, Moehner S, et al: Comparative contraceptive effectiveness of levonorgestrel-releasing and copper intrauterine devices: the European Active Surveillance Study for Intrauterine Devices. *Contraception* 91(4):280, 2015
- Hillis SD, Owens LM, Marchbanks PA, et al: Recurrent chlamydial infections increase the risks of hospitalization for ectopic pregnancy and pelvic inflammatory disease. *Am J Obstet Gynecol* 176(1 Pt 1):103, 1997
- Hnat MD, Roberts S: Case report: a markedly elevated MSAFP (Update). In Cunningham FG, Leveno KL, Bloom SL, et al (eds), *Williams Obstetrics*, 22nd ed, New York, McGraw-Hill, 2008. Online. accessmedicine.com. Available at: <http://accessmedicine.mhmedical.com/updatesContent.aspx?bookId=535§ionId=41704749&jumpsectionID=0>
- Hoffman BL, Corton MM: Surgeries for benign gynecologic conditions. In Hoffman BL, Schorge JO, Bradshaw KD, et al: *Williams Gynecology*, 3rd ed. New York, McGraw-Hill Education, 2016
- Hoover KW, Tao G, Kent CK: Trends in the diagnosis and treatment of ectopic pregnancy in the United States. *Obstet Gynecol* 115(3):495, 2010
- Horne AW, Phillips JA 3rd, Kane N, et al: CB1 expression is attenuated in Fallopian tube and decidua of women with ectopic pregnancy. *PLoS One* 3(12):e3969, 2008
- Huang B, Hu D, Qian K, et al: Is frozen embryo transfer cycle associated with a significantly lower incidence of ectopic pregnancy? An analysis of more than 30,000 cycles. *Fertil Steril* 102(5):1345, 2014
- Hung TH, Jeng CJ, Yang YC, et al: Treatment of cervical pregnancy with methotrexate. *Int J Gynaecol Obstet* 53(3):243, 1996
- Isaacs JD Jr, McGehee RP, Cowan BD: Life-threatening neutropenia following methotrexate treatment of ectopic pregnancy: a report of two cases. *Obstet Gynecol* 88(4 Pt 2):694, 1996
- Jurkovic D, Hillaby K, Woelfer B, et al: First-trimester diagnosis and management of pregnancies implanted into the lower uterine segment cesarean section scar. *Ultrasound Obstet Gynecol* 21(3):220, 2003
- Kadar N, DeCherney AH, Romero R: Receiver operating characteristic (ROC) curve analysis of the relative efficacy of single and serial chorionic gonadotropin determinations in the early diagnosis of ectopic pregnancy. *Fertil Steril* 37(4):542, 1982
- Khalife S, Falcone T, Hemmings R, et al: Diagnostic accuracy of transvaginal ultrasound in detecting free pelvic fluid. *J Reprod Med* 43(9):795, 1998
- Ko JK, Cheung VY: Time to revisit the human chorionic gonadotropin discriminatory level in the management of pregnancy of unknown location. *J Ultrasound Med* 33(3):465, 2014
- Krag Moeller LB, Moeller C, Thomsen SG, et al: Success and spontaneous pregnancy rates following systemic methotrexate versus laparoscopic surgery for tubal pregnancies: a randomized trial. *Acta Obstet Gynecol Scand* 88(12):1331, 2009
- Kung FT, Chang SY, Tsai YC, et al: Subsequent reproduction and obstetric outcome after methotrexate treatment of cervical pregnancy: a review of original literature and international collaborative follow-up. *Hum Reprod* 12(3):591, 1997
- Lau S, Tulandi T: Conservative medical and surgical management of interstitial ectopic pregnancy. *Fertil Steril* 72(2):207, 1999
- Lavie O, Boldes R, Neuman M, et al: Ultrasonographic "endometrial three-layer" pattern: a unique finding in ectopic pregnancy. *J Clin Ultrasound* 24(4):179, 1996
- Levine D: Ectopic pregnancy. *Radiology* 245(2):385, 2007
- Li C, Meng CX, Zhao WH, et al: Risk factors for ectopic pregnancy in women with planned pregnancy: a case-control study. *Eur J Obstet Gynecol Reprod Biol* 181:176, 2014a
- Li Y, Yang Y, He QZ, et al: Frozen section of uterine curetting in excluding the possibility of ectopic pregnancy—a clinicopathologic study of 715 cases. *Clin Exp Obstet Gynecol* 41(4):419, 2014b
- Lim YH, Ng SP, Ng PH, et al: Laparoscopic salpingectomy in tubal pregnancy: prospective randomized trial using Endloop versus electrocautery. *J Obstet Gynaecol Res* 33(6):855, 2007
- Lipscomb GH: Medical therapy for ectopic pregnancy. *Semin Reprod Med* 25(2):93, 2007
- Lipscomb GH, Bran D, McCord ML, et al: Analysis of three hundred fifteen ectopic pregnancies treated with single-dose methotrexate. *Am J Obstet Gynecol* 178(6):1354, 1998
- Lipscomb GH, Givens VM, Meyer NL, et al: Comparison of multidose and single-dose methotrexate protocols for the treatment of ectopic pregnancy. *Am J Obstet Gynecol* 192(6):1844; discussion 1847, 2005
- Lipscomb GH, Gomez IG, Givens VM, et al: Yolk sac on transvaginal ultrasound as a prognostic indicator in the treatment of ectopic pregnancy with single-dose methotrexate. *Am J Obstet Gynecol* 200(3):338.e331, 2009
- Lipscomb GH, McCord ML, Stovall TG, et al: Predictors of success of methotrexate treatment in women with tubal ectopic pregnancies. *N Engl J Med* 341(26):1974, 1999
- Liu L, Zhang G, Zhou W, et al: Fallopian tube stripping forceps: a novel instrumental design for distal tubal pregnancy laparoscopy. *Eur J Obstet Gynecol Reprod Biol* 183:109, 2014
- Ljubin-Sternak S, Mestrovic T: Chlamydia trachomatis and genital mycoplasmas: pathogens with an impact on human reproductive health. *J Pathog* 2014:183167, 2014
- Lopez HB, Micheelsen U, Berendtsen H, et al: Ectopic pregnancy and its associated endometrial changes. *Gynecol Obstet Invest* 38(2):104, 1994
- Lundorff P, Thorburn J, Hahlin M, et al: Laparoscopic surgery in ectopic pregnancy. A randomized trial versus laparotomy. *Acta Obstet Gynecol Scand* 70(4-5):343, 1991
- Menon S, Collins J, Barnhart KT: Establishing a human chorionic gonadotropin cutoff to guide methotrexate treatment of ectopic pregnancy: a systematic review. *Fertil Steril* 87(3):481, 2007
- Mesogitis S, Pilalis A, Daskalakis G, et al: Management of early viable cervical pregnancy. *BJOG* 112(4):409, 2005
- Milad MP, Klein E, Kazer RR: Preoperative serum hCG level and intraoperative failure of laparoscopic linear salpingostomy for ectopic pregnancy. *Obstet Gynecol* 92(3):373, 1998
- Mittal SK, Singh N, Verma AK, et al: Fetal MRI in the pre-operative diagnosis and assessment of secondary abdominal pregnancy: a rare sequela of a previous caesarean section. *Diagn Interv Radiol* 18(5):496, 2012
- Moawad NS, Mahajan ST, Moniz MH, et al: Current diagnosis and treatment of interstitial pregnancy. *Am J Obstet Gynecol* 202(1):15, 2010
- Mol BW, Ankum WM, Bossuyt PM, et al: Contraception and the risk of ectopic pregnancy: a meta-analysis. *Contraception* 52(6):337, 1995
- Mol BW, Lijmer JG, Ankum WM, et al: The accuracy of single serum progesterone measurement in the diagnosis of ectopic pregnancy: a meta-analysis. *Hum Reprod* 13(11):3220, 1998
- Mol F, Mol BW, Ankum WM, et al: Current evidence on surgery, systemic methotrexate and expectant management in the treatment of tubal ectopic pregnancy: a systematic review and meta-analysis. *Hum Reprod Update* 14(4):309, 2008
- Mol F, van Mello NM, Strandell A, et al: Salpingotomy versus salpingectomy in women with tubal pregnancy (ESEP study): an open-label, multicentre, randomised controlled trial. *Lancet* 383(9927):1483, 2014
- Moschos E, Hoffman BL: Clinical pearl: cervical ectopic pregnancy (Update). In Cunningham FG, Leveno KL, Bloom SL, et al (eds), *Williams Obstetrics*, 22nd ed., New York, McGraw-Hill, 2007. Online. accessmedicine.com. Available at: <http://accessmedicine.mhmedical.com/ViewLarge.aspx?figid=41704608>
- Moschos E, Sreenarasimhaiah S, Twickler DM: First-trimester diagnosis of cesarean scar ectopic pregnancy. *J Clin Ultrasound* 36(8):504, 2008a
- Moschos E, Twickler DM: Endometrial thickness predicts intrauterine pregnancy in patients with pregnancy of unknown location. *Ultrasound Obstet Gynecol* 32(7):929, 2008b
- Murphy AA, Nager CW, Wujek JJ, et al: Operative laparoscopy versus laparotomy for the management of ectopic pregnancy: a prospective trial. *Fertil Steril* 57(6):1180, 1992
- Natale A, Candiani M, Merlo D, et al: Human chorionic gonadotropin level as a predictor of trophoblastic infiltration into the tubal wall in ectopic pregnancy: a blinded study. *Fertil Steril* 79(4):981, 2003
- Nieuwkerk PT, Hajenius PJ, Ankum WM, et al: Systemic methotrexate therapy versus laparoscopic salpingostomy in patients with tubal pregnancy. Part I. Impact on patients' health-related quality of life. *Fertil Steril* 70(3):511, 1998
- Nowak-Markwitz E, Michalak M, Olejnik M, et al: Cutoff value of human chorionic gonadotropin in relation to the number of methotrexate cycles in the successful treatment of ectopic pregnancy. *Fertil Steril* 92(4):1203, 2009
- Nurmohamed L, Moretti ME, Schechter T, et al: Outcome following high-dose methotrexate in pregnancies misdiagnosed as ectopic. *Am J Obstet Gynecol* 205(6):533.e531, 2011
- Nyberg DA, Hughes MP, Mack LA, et al: Extrauterine findings of ectopic pregnancy of transvaginal US: importance of echogenic fluid. *Radiology* 178(3):823, 1991
- Paalman RJ, McElin TW: Cervical pregnancy: review of the literature and presentation of cases. *Am J Obstet Gynecol* 77(6):1261, 1959
- Pagidas K, Frishman GN: Nonsurgical management of primary ovarian pregnancy with transvaginal ultrasound-guided local administration of methotrexate. *J Minim Invasive Gynecol* 20(2):252, 2013
- Paternoster DM, Santarossa C: Primary abdominal pregnancy. A case report. *Minerva Ginecol* 51:251, 1999

- Pattinson HA, Dunphy BC, Wood S, et al: Cervical pregnancy following in vitro fertilization: evacuation after uterine artery embolization with subsequent successful intrauterine pregnancy. *Aust N Z J Obstet Gynaecol* 34(4):492, 1994
- Paul M, Schaff E, Nichols M: The roles of clinical assessment, human chorionic gonadotropin assays, and ultrasonography in medical abortion practice. *Am J Obstet Gynecol* 183(2 Suppl):S34, 2000
- Pellerito JS, Taylor KJ, Quedens-Case C, et al: Ectopic pregnancy: evaluation with endovaginal color flow imaging. *Radiology* 183(2):407, 1992
- Perkins KM, Boulet SL, Kissin DM, et al: Risk of ectopic pregnancy associated with assisted reproductive technology in the United States, 2001-2011. *Obstet Gynecol* 125(1):70, 2015
- Pisarska MD, Carson SA: Incidence and risk factors for ectopic pregnancy. *Clin Obstet Gynecol* 42(1):2, 1999
- Poggi SH, Ghidini A: Importance of timing of gestational exposure to methotrexate for its teratogenic effects when used in setting of misdiagnosis of ectopic pregnancy. *Fertil Steril* 96(3):669, 2011
- Polena V, Huchon C, Varas Ramos C, et al: Non-invasive tools for the diagnosis of potentially life-threatening gynaecological emergencies: a systematic review. *PLoS One* 10(2):e0114189, 2015
- Poole A, Haas D, Magann EF: Early abdominal ectopic pregnancies: a systematic review of the literature. *Gynecol Obstet Invest* 74(4):249, 2012
- Rahman MS, Al-Suleiman SA, Rahman J, et al: Advanced abdominal pregnancy—observations in 10 cases. *Obstet Gynecol* 59:366, 1982
- Rajkhowa M, Glass MR, Rutherford AJ, et al: Trends in the incidence of ectopic pregnancy in England and Wales from 1966 to 1996. *BJOG* 107(3):369, 2000
- Ries A, Singson P, Bidus M, et al: Use of the endometrial Pipelle in the diagnosis of early abnormal gestations. *Fertil Steril* 74(3):593, 2000
- Roberts RV, Dickinson JE, Leung Y, et al: Advanced abdominal pregnancy: still an occurrence in modern medicine. *Aust N Z J Obstet Gynaecol* 45(6):518, 2005
- Rodgerson JD, Heegaard WG, Plummer D, et al: Emergency department right upper quadrant ultrasound is associated with a reduced time to diagnosis and treatment of ruptured ectopic pregnancies. *Acad Emerg Med* 8(4):331, 2001
- Rulin MC: Is salpingostomy the surgical treatment of choice for unruptured tubal pregnancy? *Obstet Gynecol* 86(6):1010, 1995
- Sadeghi H, Rutherford T, Rackow BW, et al: Cesarean scar ectopic pregnancy: case series and review of the literature. *Am J Perinatol* 27(2):111, 2010
- Sagiv R, Debby A, Sadan O, et al: Laparoscopic surgery for extrauterine pregnancy in hemodynamically unstable patients. *J Am Assoc Gynecol Laparosc* 8(4):529, 2001
- Saraiya M, Berg CJ, Kendrick JS, et al: Cigarette smoking as a risk factor for ectopic pregnancy. *Am J Obstet Gynecol* 178(3):493, 1998
- Scutiero G, Di Gioia P, Spada A, et al: Primary ovarian pregnancy and its management. *JLS* 16(3):492, 2012
- Senterman M, Jibodh R, Tulandi T: Histopathologic study of ampullary and isthmic tubal ectopic pregnancy. *Am J Obstet Gynecol* 159(4):939, 1988
- Shalev E, Peleg D, Tsabari A, et al: Spontaneous resolution of ectopic tubal pregnancy: natural history. *Fertil Steril* 63(1):15, 1995
- Shaunik A, Kulp J, Appleby DH, et al: Utility of dilation and curettage in the diagnosis of pregnancy of unknown location. *Am J Obstet Gynecol* 204(2):130.e131, 2011
- Shaw JL, Dey SK, Critchley HO, et al: Current knowledge of the aetiology of human tubal ectopic pregnancy. *Hum Reprod Update* 16(4):432, 2010
- Sherer DM, Dalloul M, Gorelick C, et al: Unusual maternal vasculature in the placental periphery leading to the diagnosis of abdominal pregnancy at 25 weeks' gestation. *J Clin Ultrasound* 35(5):268, 2007
- Skjeldestad FE, Hadgu AM, Eriksson N: Epidemiology of repeat ectopic pregnancy: a population-based prospective cohort study. *Obstet Gynecol* 91(1):129, 1998
- Sowter MC, Farquhar CM, Petrie KJ, et al: A randomised trial comparing single dose systemic methotrexate and laparoscopic surgery for the treatment of unruptured tubal pregnancy. *BJOG* 108(2):192, 2001
- Spandorfer SD, Menzin AW, Barnhart KT, et al: Efficacy of frozen-section evaluation of uterine curettings in the diagnosis of ectopic pregnancy. *Am J Obstet Gynecol* 175(3 Pt 1):603, 1996
- Spiegelberg O: Zur Casuistik der Ovarialschwangerschaft. *Arch Gynak* 13:73, 1878
- Stovall TG, Ling FW: Single-dose methotrexate: an expanded clinical trial. *Am J Obstet Gynecol* 168(6 Pt 1):1759, 1993
- Stovall TG, Ling FW, Andersen RN, et al: Improved sensitivity and specificity of a single measurement of serum progesterone over serial quantitative beta-human chorionic gonadotrophin in screening for ectopic pregnancy. *Hum Reprod* 7(5):723, 1992
- Straka M, Zeringue E, Goldman M: A rare drug reaction to methotrexate after treatment for ectopic pregnancy. *Obstet Gynecol* 103(5 Pt 2):1047, 2004
- Strandell A, Thorburn J, Hamberger L: Risk factors for ectopic pregnancy in assisted reproduction. *Fertil Steril* 71(2):282, 1999
- Studdiford W: Primary peritoneal pregnancy. *Am J Obstet Gynecol* 44:487, 1942
- Stulberg DB, Cain LR, Dahlquist I, et al: Ectopic pregnancy rates and racial disparities in the Medicaid population, 2004-2008. *Fertil Steril* 102(6):1671, 2014
- Swire MN, Castro-Aragon I, Levine D: Various sonographic appearances of the hemorrhagic corpus luteum cyst. *Ultrasound Q* 20(2):45, 2004
- Tal J, Haddad S, Gordon N, et al: Heterotopic pregnancy after ovulation induction and assisted reproductive technologies: a literature review from 1971 to 1993. *Fertil Steril* 66(1):1, 1996
- Talbot P, Riveles K: Smoking and reproduction: the oviduct as a target of cigarette smoke. *Reprod Biol Endocrinol* 3:52, 2005
- Thompson MJ, Kho KA: Minimally invasive surgery. In Hoffman BL, Schorge JO, Bradshaw KD, et al: *Williams Gynecology*, 3rd ed. New York, McGraw-Hill Education, 2016
- Toth M, Patton DL, Campbell LA, et al: Detection of chlamydial antigenic material in ovarian, prostatic, ectopic pregnancy and semen samples of culture-negative subjects. *Am J Reprod Immunol* 43(4):218, 2000
- Trio D, Strobelt N, Picciolo C, et al: Prognostic factors for successful expectant management of ectopic pregnancy. *Fertil Steril* 63(3):469, 1995
- Trojano G, Colafiglio G, Saliani N, et al: Successful management of a cervical twin pregnancy: neoadjuvant systemic methotrexate and prophylactic high cervical cerclage before curettage. *Fertil Steril* 91(3):935.e17, 2009
- Tulandi T, Al-Jaroudi D: Interstitial pregnancy: results generated from the Society of Reproductive Surgeons Registry. *Obstet Gynecol* 103(1):47, 2004
- Ushakov FB, Elchalal U, Aceman PJ, et al: Cervical pregnancy: past and future. *Obstet Gynecol Surv* 52(1):45, 1997
- Valenzano M, Nicoletti L, Odicino F, et al: Five-year follow-up of placental involution after abdominal pregnancy. *J Clin Ultrasound* 31(1):39, 2003
- Van Den Eeden SK, Shan J, Bruce C, et al: Ectopic pregnancy rate and treatment utilization in a large managed care organization. *Obstet Gynecol* 105(5 Pt 1):1052, 2005
- Van Voorhis BJ: Outcomes from assisted reproductive technology. *Obstet Gynecol* 107(1):183, 2006
- Varma R, Mascarenhas L, James D: Successful outcome of advanced abdominal pregnancy with exclusive omental insertion. *Ultrasound Obstet Gynecol* 12:192, 2003
- Vermesh M, Silva PD, Rosen GF, et al: Management of unruptured ectopic gestation by linear salpingostomy: a prospective, randomized clinical trial of laparoscopy versus laparotomy. *Obstet Gynecol* 73(3 Pt 1):400, 1989
- Wang G, Liu X, Bi F, et al: Evaluation of the efficacy of laparoscopic resection for the management of exogenous cesarean scar pregnancy. *Fertil Steril* 101(5):1501, 2014
- Warkany J: Aminopterin and methotrexate: folic acid deficiency. *Teratology* 17(3):353, 1978
- Waylen AL, Metwally M, Jones GL, et al: Effects of cigarette smoking upon clinical outcomes of assisted reproduction: a meta-analysis. *Hum Reprod Update* 15(1):31, 2009
- Zane SB, Kieke BA Jr, Kendrick JS, et al: Surveillance in a time of changing health care practices: estimating ectopic pregnancy incidence in the United States. *Matern Child Health J* 6(4):227, 2002
- Zeck W, Kelters I, Winter R, et al: Lessons learned from four advanced abdominal pregnancies at an East African Health Center. *J Perinat Med* 35(4):278, 2007
- Zee J, Sammel MD, Chung K, et al: Ectopic pregnancy prediction in women with a pregnancy of unknown location: data beyond 48 h are necessary. *Hum Reprod* 29(3):441, 2014

CHAPTER 9

First- and Second-Trimester Pregnancy Termination

EPIDEMIOLOGY OF INDUCED ABORTION	133
ABORTION INDICATIONS	134
PATIENT EVALUATION	135
SURGICAL METHODS	136
PREABORTION CERVICAL RIPENING	141
MEDICAL ABORTION	144
ABORTION COMPLICATIONS	148
LONG-TERM ABORTION RISKS	151

Although surgical methods of abortion have changed little in the past 50 years, the expanding interest in pharmacologic agents has both increased reproductive options and broadened the range of possible complications. Even with optimum use of medical-based protocols, the need for surgery to complete a failed procedure or to manage complications requires a thorough knowledge of operative technique.

EPIDEMIOLOGY OF INDUCED ABORTION

The Centers for Disease Control and Prevention (CDC) define induced abortion as a procedure to terminate a suspected or known intrauterine pregnancy and to produce a nonviable fetus at any gestational age (Koonin, 1999). In 2008, approximately 50 percent of more than 6.5 million pregnancies in the United States were unintended, defined as either mistimed or unwanted. Of these, 40 percent—excluding spontaneous losses—ended in legal abortion (Finer, 2014). The national rate

of unintended pregnancies has fallen, which is perhaps due to more effective contraception. Still, approximately 20 percent of sexually active, reproductive-aged women in the United States who do not use effective contraception account for more than 40 percent of unintended pregnancies (Gold, 2009). Thus, most of these conceptions, and therefore induced abortions, are preventable.

Beginning in 1969, the number and selected characteristics of women who underwent legal abortions were monitored on an annual basis by the CDC. Since 1990, when the number of legal abortions in the United States peaked at 1.43 million, the absolute number has declined. In 2002, the total was 854,122, and by 2011, this had fallen to 730,322 (Pazol, 2014). At the same time, estimates world-wide exceed 40 million (Sedgh, 2007). Data are also collected regarding patient demographics and include age, race, marital status, state of residency, and gestational age. In addition, the recorded method—curettage, medical, instillation, and other—is gathered.

Despite this, many of the associated demographic and abortion-method data are not reported. The CDC depends on cooperation between abortion providers and the state agencies to supply statistics. Thus, their summary data are likely underestimated, although data trends should be reliable. Indeed, the CDC reports that for 2011, their totals are approximately 70 percent of estimates recorded by the Guttmacher Institute. This privately funded agency also collects and publishes analyses of abortion data obtained through periodic direct contact with identified abortion providers (Jones, 2014). This implies that in 2011, approximately 1.04 million legal abortions were performed in the United States.

Notable trends include declines in proportions of adolescent pregnancies and increased proportions of parous women and women of color selecting abortion (Jones, 2009). Poor women were identified as having the greatest absolute increase in the abortion rate between 2000 and 2008. Overall, an estimated 30 percent of women aged 15 to

44 years in 2008 will have had an abortion by age 45 (Jones, 2011a).

The CDC also computes the *abortion rate*, which is the number of abortions per 1000 women of reproductive age. In contrast, the *abortion ratio* is the number of abortions per 1000 live births. The abortion rate is a crude estimate of the population incidence of undesired pregnancies, whereas the ratio better approximates the proportion of conceptions that are undesired. Since 2002, in the United States, both the abortion rate and ratio have been declining. In 2011, the abortion ratio was approximately 219 per 1000 live births, whereas the rate was approximately 13.9 per 1000 reproductive-aged women (Pazol, 2014).

The observed declines in the reported abortion number, rate, and ratio is not easily explained and likely involves multiple contributing, interrelated factors (Jones, 2009). Possibilities include more effective contraception use, changing attitudes toward abortion, decreasing availability of providers, and increasing legal and economic barriers. Still unclear is whether legal abortion should be viewed as a reportable event such as births and fetal deaths or as a health-related issue akin to other procedures.

In spite of these and other limitations, accurate abortion statistics help estimate abortion practices. Groups with higher abortion rates can be targeted for improved health-care services and effective contraception for the prevention of unintended pregnancies. Preventable causes of abortion-associated morbidity and mortality may also be identified and addressed.

ABORTION MORTALITY

The availability of safe, legal procedures is the most important preventable factor affecting abortion-related deaths (Cates, 1976; Grimes, 1979). Maternal death from legal abortion is rare, and rates since 1978 are less than 1 death per 100,000 reported legal abortions (Pazol, 2014). In 2010, the last year for which CDC data are currently available, 10 deaths related to legal abortion were recorded. Other reports confirm that the incidence of maternal death and other complications increases with advancing gestational age (Diedrich, 2009). From data of the Abortion Mortality Surveillance System, the maternal mortality rate between 1988 and 1997 for procedures performed at ≤ 8 weeks' gestation was 0.1 deaths per 100,000 abortions. In the second trimester, the relative risk for mortality increased substantially with a 14-fold increase at 13 to 15 weeks, a 29-fold increase at 16 to 20 weeks, and a 77-fold increased risk at ≥ 21 weeks' gestation (Bartlett, 2004). Causes of abortion-related death can be classified as direct, which include hemorrhage, infection, embolic (thrombotic, amniotic fluid, or air), and anesthetic-related. Indirect deaths stem mainly from cardiac and cerebral vascular events. Of deaths, 80 percent were due to direct causes, of which hemorrhage and infection accounted for approximately half of cases. Anesthetic and embolic complications each accounted for approximately 15 percent.

Approximately 70 percent of legal abortions are performed by first-trimester suction dilatation and curettage (D & C). The epidemiology of abortion morbidity and mortality principally reflects complications related to this procedure (Pazol, 2014). A

continuing pregnancy has an associated death rate of 8 to 9 per 100,000 live births. A legal abortion is markedly safer than this, and a recent estimate was only 0.6 deaths per 100,000 abortions (Raymond, 2012). As gestational age advances and abortion methods change to dilatation and evacuation (D & E) or medical induction, the observed death rate increases and approaches baseline pregnancy-associated mortality rates. Second-trimester procedures generally require greater levels of anesthesia, which may explain a portion of the observed increase.

ABORTION INDICATIONS

Although induced abortion is usually the result of an unintended pregnancy, numerous social, economic, and personal pressures influence the decision (Torres, 1988). Other concerns include the effects of pregnancy on a woman's health or issues related to fetal well-being. Some women with chronic medical diseases choose pregnancy termination only after learning that continuing the pregnancy poses significant health risks. That said, the effects of pregnancy on preexisting medical disease are highly variable, and in most conditions, they form a continuum of risk based in large part on the disease type and current severity. The point at which the risks to a patient's health (or life) become unacceptable is often obscure, and risks can only be estimated. Moreover, accepted guidelines for recommending pregnancy termination do not currently exist. Nevertheless, for most chronic medical conditions, there are sufficient data to inform clinical decisions based on the likelihood and magnitude of pregnancy-associated risks. The importance of accurate preconceptional counseling cannot be overemphasized.

To assess fetal well-being, prenatal diagnosis is increasingly elected, and significant structural and genetic conditions affect at least 3 to 5 percent of all births. As a result, an increasing number of women are faced with the decision of abortion based on neonatal health concerns. In some cases a presumed "lethal" condition is found, although the use of this term has been appropriately disparaged. Instead, a physiologic appraisal and counseling are preferred (Wilkinson, 2012). For fetal conditions not associated with neonatal survival, induced abortion merely changes the outcome timing. However, nonlethal conditions are more common and are generally associated with wide variations in clinical outcome. Rarely can diagnosis accurately depict the postnatal course. Thus, patients must usually make decisions based on incomplete information. Moreover, prenatal diagnosis is often not completed until the second trimester, a time when pregnancy terminations incur more risk and expense and become less available.

LEGAL ABORTION SERVICES

■ Provider Numbers

Based on a 1996 survey of abortion providers, the Guttmacher Institute reported that 32 percent of reproductive-aged women in the United States lived in the 86 percent of counties that had no recognized provider (Henshaw, 1998). In total, 70 percent of abortions were performed in outpatient specialty clinics compared with only 7 percent in hospitals. These findings

confirm that, since abortion legalization in the United States in 1973, hospital-based services have mostly been replaced by outpatient centers. These centers can provide a broader and more cost-effective range of reproductive health services than can either hospitals or physician offices. Regrettably, this evolution has fostered the marginalization of abortion providers and decreased accessibility to hospital-based residency training. Because abortion is an emotionally charged issue, it has attained significant political and legal status, which threatens to transcend its medical aspects.

Between 1982 and 2000, the number of abortion providers in the United States had steadily declined. However, provider numbers through 2011 have become relatively stable, which may be attributable to an increase in clinicians who perform medical instead of surgical procedures. In 2008, approximately 1800 providers were reported by the Guttmacher Institute (Jones, 2011b). Reasons for the decline include perceived social stigma, economic reimbursement, decreased training opportunities, and even personal fears (American College of Obstetricians and Gynecologists, 2014c). These pressures have created a paradox in which most obstetrician-gynecologists favor access to legal abortion, but most are unwilling to perform them.

Attempts at reversing the trends in provider attrition have met obstacles. The American College of Obstetricians and Gynecologists (2014d) has long been a supporter of legal abortion prior to fetal viability, and the Accreditation Council for Graduate Medical Education has mandated since 1996 that residency curricula include induced abortion. That said, specific training in surgical methods, especially second-trimester D & E, may be lacking (American College of Obstetricians and Gynecologists, 2014a; Eastwood, 2006). Clearly abortion training in residency improves many skills needed for practice, including first-trimester sonography, management of incomplete and missed abortions or fetal death, and provision of effective analgesia.

■ Limitations to Access

In 1990, the National Abortion Federation and the American College of Obstetricians and Gynecologists sponsored a symposium on abortion provision (Grimes, 1992). This group identified many disincentives to abortion access, most of which had no simple solutions. Increasingly, federal and state legislatures have sought to limit legal abortion on many levels. The most widely imposed restriction is economic. Most states have emulated the federal restriction on abortion reimbursement by prohibiting public funding. Women with federally funded medical care are usually not covered for abortion services unless they are performed for serious maternal health concerns. Other common restrictions involve parental involvement in the abortion decision, mandatory counseling with state-imposed content, waiting periods, and the requirement to be given the opportunity to view sonographic images.

Much of the current state legislative activity seeks to emphasize the potential restrictions permitted by *Roe v. Wade* for post-viable pregnancies, originally described as third-trimester cases. Presumably, the 1973 court recognized that third-trimester abortions might reasonably be restricted because of legitimate concerns for neonatal survival, but acknowledged that a

procedure performed for the life or health of the mother could not be banned.

Other legislation has focused on procedural restrictions such as those associated with *partial birth abortions*, also known as intact dilatation and extraction (D & X) (Epner, 1998). *Partial birth abortion* is a lay term that is not recognized by the College or other medical authorities. According to a policy statement by the American College of Obstetricians and Gynecologists (1997), intact D & X contains these four elements: (1) deliberate cervical dilatation, (2) conversion of the fetus to a footling breech, (3) breech extraction of the body (but not the cranium), and (4) evacuation of the intracranial contents to aid the delivery of a dead but otherwise intact fetus.

However, because all of the included steps are part of established obstetric techniques, they must be performed in the precise sequence to meet criteria for an intact D & X. The criminalization of poorly defined abortion methods has harmful ramifications for abortion providers and carries penalties that far exceed commonly encountered civil liabilities (Kassirer, 1997). The American College of Obstetricians and Gynecologists (1997) has acknowledged that intact D & X may be the best or most appropriate procedure in a particular circumstance and that the decision should be left to the patient and her doctor.

In 2003, a law banning partial birth abortion was signed and subsequently upheld by the Supreme Court in 2007 (*Gonzales v. Carhart*). In response, the American College of Obstetricians and Gynecologists condemned the ruling. States responded by passing laws restricting this procedure, and as of this writing, 32 have passed laws banning it. Although some have been enjoined by state courts, others permit an exception for the mother's life. Because of the indefinite nature of these legal proceedings, periodic surveillance of local policies is essential.

Thus, much of the contemporary debate involves the definition of "viability," an imprecise term that lacks evidence-based definitions. More recent court rulings have wrestled with legal definitions of viability. Although imperfect, gestational age and fetal weight estimation are still the most accurate predictors of neonatal survival. Because the capacity for neonatal survival spans a biologic continuum of probability across gestation and is greatly influenced by the presence and severity of fetal anomalies and the level of neonatal care provided, it is unlikely that a single gestational age threshold could ever be universally accepted. Nevertheless, recent expert opinion now suggests that viability may be reasonably assumed as early as 23 weeks' gestation (Raju, 2014).

PATIENT EVALUATION

Patient evaluation should include a history, physical examination, appropriate laboratory studies, and counseling. Beyond establishing that the decision is voluntary, counseling must include informed consent. At a minimum, the patient should know the diagnosis, purpose of the procedure, risks and possible complications, alternative treatments, and the likelihood of successful treatment (American College of Obstetricians and Gynecologists, 2012).

Counseling requires a nonjudgmental, informed, and objective attitude. Using open-ended questions, clinicians encourage

the woman to express her own feelings and the feelings of those close to her regarding her decision, in the context of her current life situation and her plans for future childbearing and contraception. Providing accurate information can alleviate common fears regarding abortion and later reproductive health. In some cases, women experience guilt from various underlying beliefs and perceptions. These feelings should be normalized, even if they cannot be completely dispelled (Adler, 1992). Legal restrictions, particularly those imposed on adolescents, may further heighten the psychological discomfort, and counselors may effectively mediate the process of parental notification, when applicable. Pain management and postprocedure contraception is also discussed.

■ History and Physical Examination

The complete history focuses on the timing and reliability of the last normal menstrual period, because accurate gestational age determination is crucial to selecting the correct method. Other important historical elements for preoperative care are listed in Chapter 18 (p. 291). Women with conditions severe enough to warrant a medically indicated pregnancy termination may require additional evaluation to optimize their status. Although stable and well-controlled chronic medical conditions can be managed in outpatient centers, indications for inpatient procedures are numerous and require appreciable judgment (Guiahi, 2012). Women with known bleeding disorders or who are receiving anticoagulation represent a particularly high-risk group. In these women, termination using an abortifacient is avoided because the timing of the passage of conception products and the amount of associated hemorrhage are unpredictable.

Physical examination ideally obtains vital signs and weight and assesses cardiopulmonary findings. A sterile speculum is inserted to seek cervical pathology that might increase surgical complications. These include active cervicitis, deformities, and past trauma. Bimanual pelvic examination should ascertain uterine size, detect other pelvic pathology, and determine the position of the uterus with respect to the cervix. The latter helps direct the insertion angle of cervical dilators and curettes. Women with suspected pelvic pathology or a discrepancy between the menstrual date and uterine size should undergo sonography. Imaging can be used to exclude multifetal gestations, uterine anomalies, or ectopic pregnancies. Maternal obesity or other obstacles to a complete pelvic examination should also prompt sonographic imaging. If an embryonic or fetal demise is found, this may remove sources of guilt and anxiety and may enhance third-party reimbursement. Although routine use of sonography has been questioned, it is widely performed (Kulier, 2011a; O'Connell, 2009). In women with prior cesarean deliveries, sonography localizes the placental implantation site to exclude abnormal placentation, which increases bleeding risks. Some cases, such as cesarean scar ectopic pregnancy, require special care at facilities equipped to manage their potentially significant complications (Chap. 8, p. 128).

■ Laboratory Testing

Few laboratory studies beyond a reliable urine or serum pregnancy test are required in healthy, young women. At minimum,

hematocrit, Rh status, indirect Coombs, and urinalysis are obtained. Cultures of the cervix are appropriate if active cervicitis is suspected, and routine testing of women younger than 25 years has been recommended by the Centers for Disease Control and Prevention (2015). Rh immunoglobulin is indicated for an Rh-negative woman, unless she is already isoimmunized or the paternal Rh-negative status is confirmed. Testing for human immunodeficiency virus is also considered (Gupta, 1998).

METHODS OVERVIEW

Methods of first- and second-trimester abortion are either primary surgical or medical. Surgical methods generally require mechanical cervical dilatation sufficient to pass the necessary instruments. Pharmacologic cervical “ripening,” that is, softening, may serve as a useful adjunct.

Primary medical regimens combine the effects of pharmacologic or mechanical cervical ripening and the stimulation of uterine activity. Pharmacologic regimens are favored in the first trimester. In later gestations, a separate phase of cervical ripening may be desirable and can employ both mechanical and pharmacologic methods. However, two phases increase procedural time.

SURGICAL METHODS

■ First-Trimester Dilatation and Curettage

In the early first-trimester, vacuum aspiration is by far the most common abortion method. For pregnancies ≤ 7 weeks' gestation, small flexible cannulas (4 to 6 mm) may be selected. Often, cervical dilatation is not required at this early stage. This procedure has been termed menstrual extraction or menstrual regulation. It has been performed after a missed menses but without biochemical or sonographic confirmation of a pregnancy. Required instruments include a speculum, tenaculum, 50-mL manual vacuum syringe, and appropriate cannulas (Fig. 9-1). Although preoperative sedation is not usually

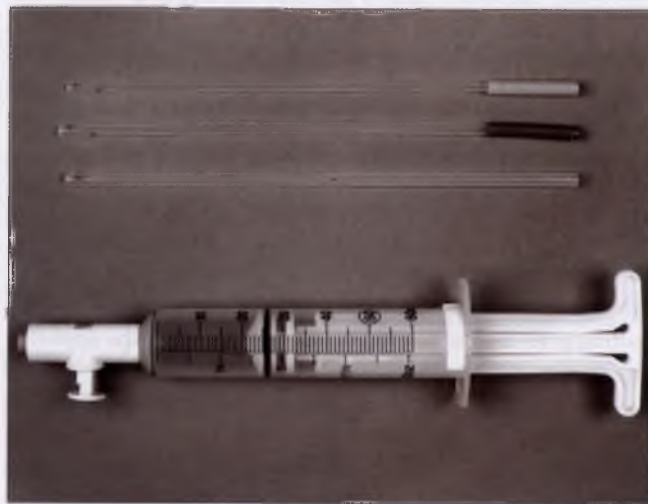

FIGURE 9-1 Karman cannulas and self-locking syringe with pinch valve used for early abortion.

necessary, preoperative administration of a nonsteroidal antiinflammatory drug (NSAID) may help reduce pain.

After the patient is placed in dorsal lithotomy position, a speculum is inserted. The cervix is visualized and cleaned with povidone-iodine or chlorhexidine gluconate solution or simply irrigated with saline (Achilles, 2011). In parous women, a small flexible catheter will usually pass without much discomfort. In nulliparas, a paracervical block, described below, may be needed to reduce pain. Injection of a local anesthetic at the site of tenaculum placement may also be considered.

After the catheter reaches the uterine fundus, the vacuum syringe is primed, and the catheter is slowly rotated and withdrawn. *Confirmation of tissue consistent with products of conception is crucial to all surgical abortions.* Failure to obtain such tissue should prompt transvaginal sonography and a measurement of a quantitative human chorionic gonadotropin (hCG) level to exclude a possible ectopic gestation (Edwards, 1997). The optimal suction cannula for early curettage is unclear. Flexible cannulas have two ports and smaller diameters, which may cause them to clog more easily. A 7-mm rigid cannula may permit intact extraction of the gestational sac, which aids postoperative confirmation.

For women who present early in pregnancy, this method appears to be safe and as effective as procedures performed later in the first trimester. The lower gestational age threshold for this method has not been established. If attention to detail and appropriate follow-up is implemented, there may not be an absolute lower limit.

For gestations aged ≥ 8 weeks, curettage usually requires some cervical dilatation, especially in nulliparas. This is performed intraoperatively with tapered dilators such as Hank dilators or Deniston (Pratt design) autoclavable dilators (Fig. 9-2). Preoperative osmotic dilators or, alternatively, prostaglandins administered via oral, buccal, or vaginal routes are also options and are discussed on page 141. Required cannulas have a larger diameter (Fig. 9-3).

Intravenous (IV) access is considered whenever a paracervical block is placed because of risks for anesthetic agent toxicity and for vagal reactions. Access may also be used to provide light conscious sedation. Common agents include midazolam (Versed) and fentanyl (Sublimaze). Nitrous oxide in concentrations of up to 50 percent is another option. Conscious sedation is defined as a minimally depressed level of consciousness that still permits a woman to maintain her airway and to



FIGURE 9-3 Plastic Karman cannulas of various sizes for performing suction curettage. Inset. Each cannula tip has a large, fluted opening. (Reproduced with permission from Hoffman BL, Corton MM: *Surgeries for benign gynecologic conditions*. In Hoffman BL, Schorge JI, Bradshaw KD, et al: *Williams Gynecology*, 3rd ed. New York, McGraw-Hill Education, 2016.)

appropriately respond to both physical and verbal stimulation. That said, agents and dosages that provide light conscious sedation in one patient may lead to much deeper levels, even to respiratory compromise, in others.

In practice, conscious sedation forms a continuum. Three levels are recognized—minimal, moderate, and deep sedation—categorized by responsiveness, spontaneous ventilation, cardiovascular function, and airway control. Patients with underlying medical problems are more likely to experience unanticipated effects. Accurate and continuous monitoring of the patient's level of consciousness is the single most important aspect of safe conscious sedation. Moderate or deep sedation is ideally avoided and may unexpectedly precipitate the need for intubation. Thus, incremental dosing is preferred to a single-dose-fits-all approach. For these reasons, facilities providing conscious sedation should have equipment, medications, and personnel on hand to assist the primary operator if needed. Guidelines for the administration of conscious sedation are available from the American Society of Anesthesiologists (2002).

During the procedure, initial steps mirror those described for earlier gestations. Previously placed osmotic dilators can be removed at this time. After the paracervical block has set, a single-tooth tenaculum is applied for countertraction. This also straightens the endocervical canal and helps avert uterine perforation. The tenaculum may be oriented horizontally and incorporate tissue on the anterior ectocervix. Some prefer a vertical orientation, with the posterior tooth inside the external os. The tenaculum may also be placed on the posterior cervical lip in analogous fashion, and in cases of significant retroflexion, it provides superior traction forces for straightening the canal. In these cases, the curved dilators and curettes are also inserted with a posterior trajectory to match canal and cavity topology.

With paracervical blockade, pain transmitted through sensory and parasympathetic fibers in Frankenhäuser plexus is blocked. These fibers innervate the cervix and upper vagina and enter the uterus at the level of the internal os. With countertraction applied by the tenaculum, an operator injects 4 to 5 mL of anesthetic to a depth of about 1.5 cm into the cervical stroma and at the level of the cervicovaginal junction. Injections are at 4 and 8 o'clock positions and near the insertion sites of the uterosacral



FIGURE 9-2 Hanks dilators. (Reproduced with permission from Hoffman BL, Corton MM: *Surgeries for benign gynecologic conditions*. In Hoffman BL, Schorge JI, Bradshaw KD, et al: *Williams Gynecology*, 3rd ed. New York, McGraw-Hill Education, 2016.)

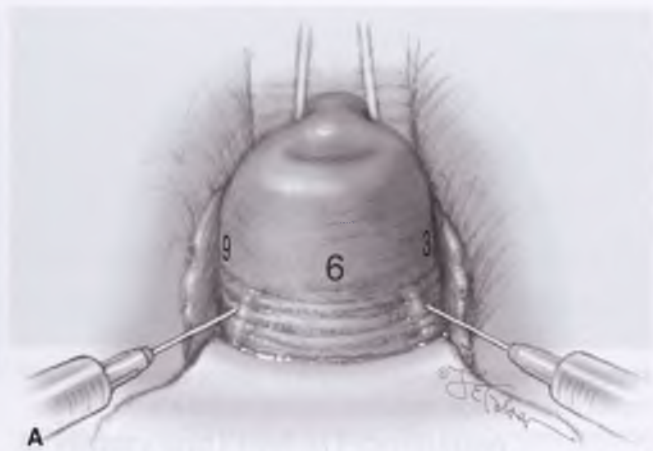


FIGURE 9-4 Paracervical blockade. **A.** One technique injects anesthetic at the 4 and 8 o'clock positions and near the insertion sites of the uterosacral ligaments. Upward traction on the cervix aids landmark visualization. **B.** The needle on the left shows the injection site from part A, but in a coronal view. The needle on the right depicts another blockade method in which local anesthetic is injected deep into the cervix. This is performed at 3, 5, 7, and 9 o'clock positions on the ectocervix.

ligaments (Fig. 9-4). As another method, injection to a depth of about 3 cm directly into the cervix may be more effective. This is completed at the 3, 5, 7, and 9 o'clock positions to deliver a total of 16 to 20 mL. However, significantly greater resistance is expected at the greater depth (Cetin, 1997; Wiebe, 1992).

Intravascular injection is avoided by careful needle aspiration. Either 1-percent lidocaine or 1- to 2-percent chlorprocaine may be selected. Chlorprocaine, an ester, has a faster onset of action and is safer after inadvertent intravascular injection. Some practitioners add 3 to 4 mL of 8.4-percent sodium bicarbonate to 30 mL of lidocaine to reduce acidity and injection discomfort.

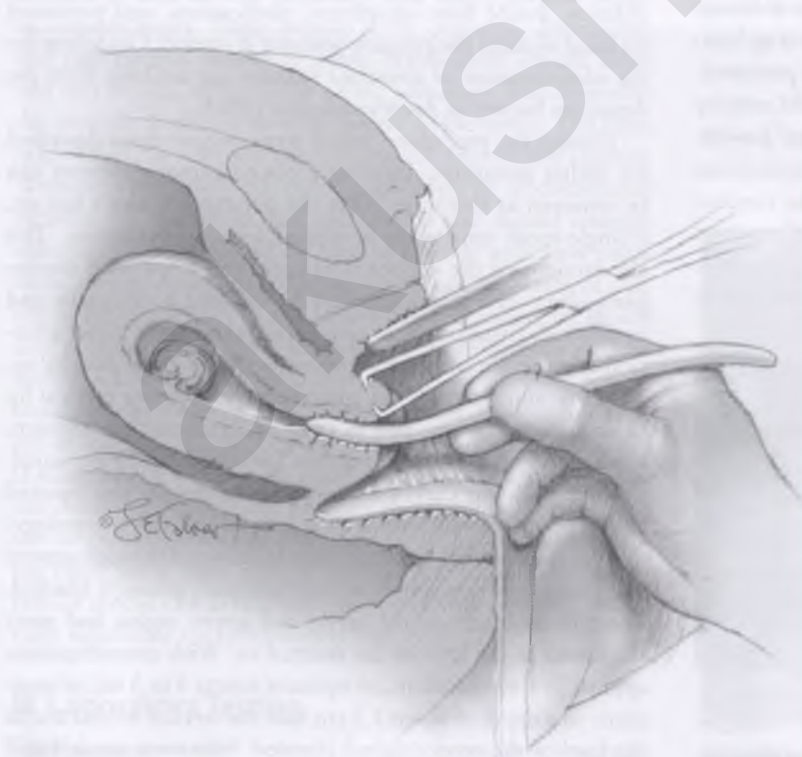
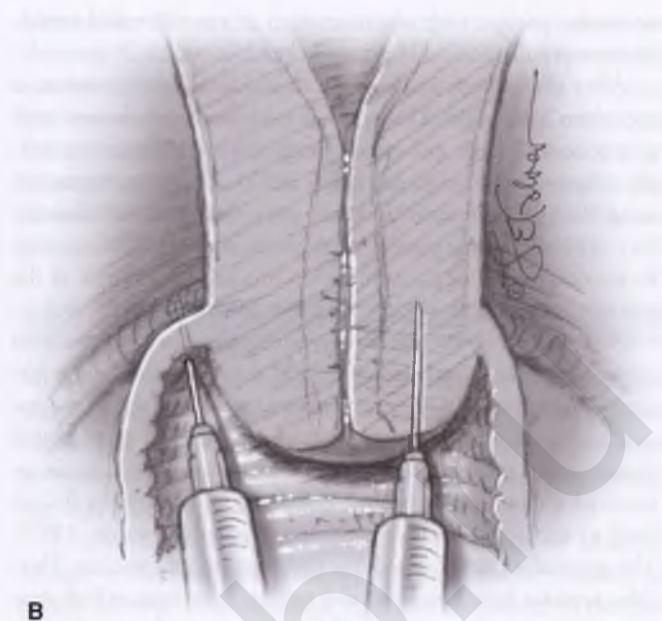


FIGURE 9-5 Dilatation of the cervix with a dilator. Note that the fourth and fifth fingers rest against the perineum and buttocks and lateral to the introitus. This maneuver provides a measure of safety from exerting excessive pressure on the cervix, a potential cause of uterine perforation.



B

This may also hasten onset of the block. Addition of vasopressin (Pitressin)—10 units to 30 to 50 mL of the local anesthetic—decreases blood loss and eases cervical dilatation (Phillips, 1997; Schulz, 1985). A standard vial of Pitressin contains 20 units.

Progressive dilatation of the cervix is performed with a set of tapered, curved dilators with the operator's hand stabilized on the perineum (Fig. 9-5). Dilators with a gentle taper (e.g., Hank or Pratt types) may be easier to use than Hegar dilators. Hank dilators also have a raised band on the shank, which provides a visual clue to prevent overinsertion. Dilators are sized in consecutive numbers, which represent either their *circumference* in

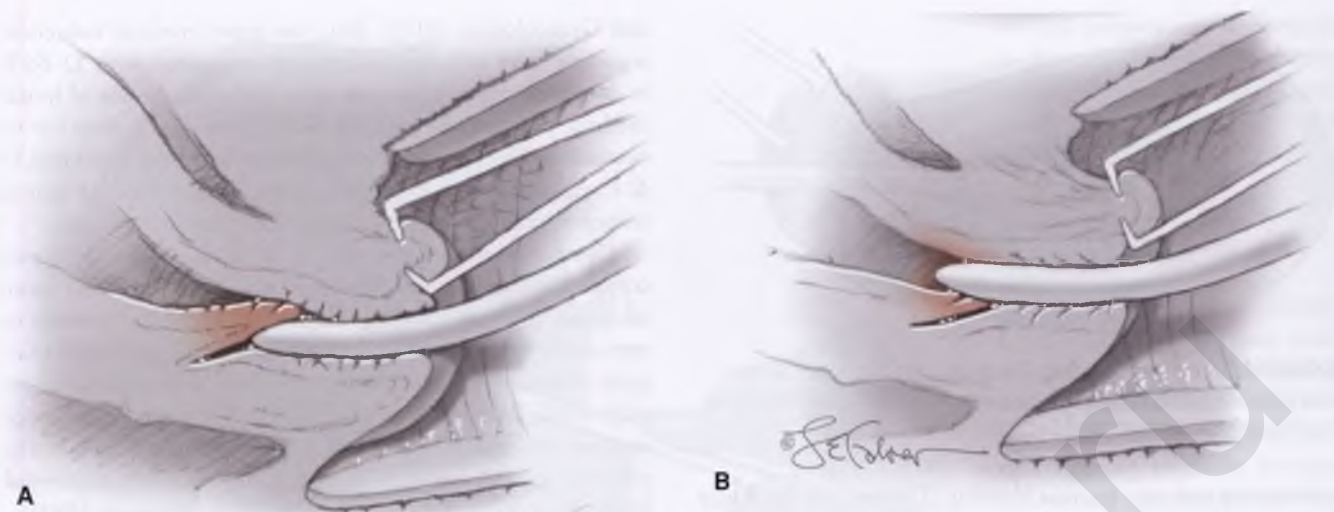


FIGURE 9-6 **A.** Creation of a false track on the posterior aspect of the endocervical canal due to inadequate straightening of the canal, misdirection of the dilator, and use of excessive force. This may eventuate in complete perforation if not recognized. **B.** To correct this problem, increased traction force straightens the canal, and the dilator is redirected along the endocervical canal.

mm (Hank or Pratt types) or their *diameter* in mm (Denniston or Hegar types). In general, the cervix is dilated to an opening size slightly larger than the chosen cannula, because as the abortion proceeds, physiologic narrowing of the canal ensues. An important aspect of curettage is the tactile assessment of insertion force and the location of the uterine fundus, which marks the anatomic boundary for instrument passage. Constriction at the internal os interferes with this feedback. Thus, a second dilatation and larger dilators are used as needed, or the curettage may be finished with a smaller cannula.

Creation of a false tract such as that shown in [Figure 9-6](#) is a complication of dilatation, especially if small-gauge dilators are initially required. It may result in uterine perforation. At least in a training institution, the adjunctive use of intraoperative sonography is instructive and potentially protective. It provides important visual feedback as to the optimal path for the dilators

and curette. Sonography also reinforces desirable tactile feedback to guide insertion forces and to halt insertion past the uterine fundus. Sonography also helps to identify the location of fetal parts during D & E as later described. It can confirm an empty cavity or identify the reaccumulation of blood. In sum, lower rates of uterine perforation and fewer repeat procedures for retained products have been reported with intraoperative sonography use (Acharya, 2004; Darney, 1989).

If a rigid cannula is chosen, its diameter in millimeters should be equal to (or 1 mm less) than the gestational age in weeks. Both curved and straight rigid cannulas are available, and the choice is primarily based on operator preference and canal shape (see [Fig. 9-3](#)). If flexible cannulas are preferred, a 5-mm Karman cannula may be used up to 7 weeks' gestation; a 6-mm up to 10 weeks' gestation; a 7-mm at 11 weeks' gestation; and an 8-mm at 12 weeks' gestation.

After adequate dilatation is confirmed, the cannula is inserted into the uterine cavity as shown in [Figure 9-7](#). Next, 50 to 60 mm Hg suction is applied. After the appropriate vacuum level is attained, the abortion proceeds by slowly rotating and withdrawing the cannula ([Fig. 9-8](#)). *Because of the risk of perforation with rigid cannulas, these are not inserted with suction applied.* With flexible cannulas, a slow, gentle in-and-out motion may be applied, taking care to rotate the cannula only on the outward movement lest the tip be avulsed. Excessive bleeding after catheter withdrawal is treated with a second aspiration. At times, the catheter may become clogged, and this may require catheter removal. Alternatively, rapid application and removal of the suction by the sliding suction control on the handle, while keeping the cannula stationary, can also be effective. After suctioning is finished, some recommend routine sharp curettage to confirm complete tissue removal. This, however, is probably

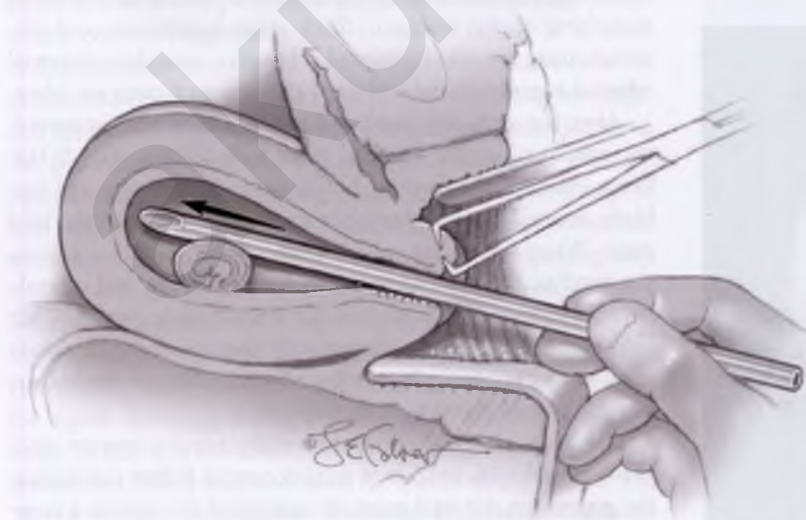


FIGURE 9-7 The vacuum curette is introduced through the dilated endocervical canal and to the uterine fundus. This is done prior to attaching the curette to the vacuum aspirator handle and tubing.

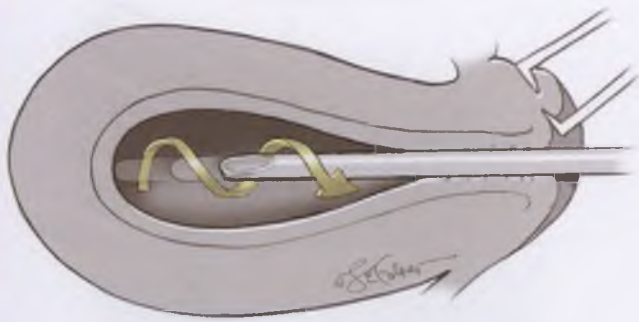


FIGURE 9-8 Uterine aspiration. The products of conception are evacuated by rotary motion of the cannula, while slowly withdrawing the cannula with applied suction.

unnecessary and may increase bleeding (Darney, 1987b). Once only scant bleeding is noted, instruments are withdrawn. A bimanual examination is repeated to document a firm, involuting uterus.

Tissue that has accumulated in the gauze-lined suction canister can be resuspended in saline and examined (Fig. 9-9). Continuing pregnancy is reported in 0.1 to 0.3 percent of cases after first-trimester D & C (Binkin, 1984). The risk increases with declining gestational age. In some cases, a multifetal gestation may be the underlying cause. At gestational ages less than 9 weeks, portions of the gestational sac and trophoblastic tissue are identified. Beyond this time, fetal parts can also be identified. If the expected tissue is not recognized, then ectopic pregnancy, molar gestation, or failed abortion is suspected, and the patient is evaluated accordingly (Edwards, 1997). Use of prophylactic antibiotics is indicated for all suction abortions, as described on page 149 (Low, 2012; Sawaya, 1996).

■ Second-Trimester Dilatation and Evacuation

In the midtrimester, D & E is by far the most commonly reported abortion method (American College of Obstetricians

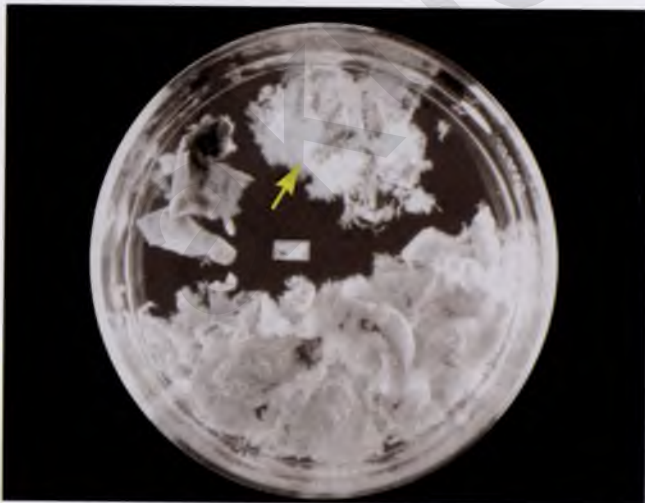


FIGURE 9-9 Tissue aspirate from an 8-week pregnancy. The arrow indicates the thin, transparent gestational sac and the frond-like projections of the surrounding chorionic villi. The remaining tissue is decidua.

and Gynecologists, 2015). But, the newer medical induction regimens have not been adequately compared with D & E in contemporary randomized trials. Thus, the choice of initial method, especially beyond 16 weeks' gestation, is best left to operator or institutional preference. It is well established that D & E, especially when performed in the latter part of the second trimester, requires special training, skills, and instruments.

Compared with curettage, D & E is technically more complex for several reasons. These include the need for more advanced cervical dilatation, the use of special instruments to remove the fetal parts, and the requirement for additional analgesia. A paracervical block alone is unlikely to provide sufficient pain relief. Thus, IV access followed by conscious sedation or regional analgesia is strongly considered. As mentioned in the previous section, vasopressin, as a component of paracervical blockade, reduces intraoperative blood loss (Peterson, 1983).

In most cases, and in essentially all cases beyond 16 weeks' gestation, preoperative osmotic dilators or other forms of cervical ripening are necessary. Without preliminary cervical preparation, sufficient dilatation to a diameter ≥ 2 cm is unlikely without using excessive force with the dilator. Adequate dilatation is required to pass the grasping forceps through the internal os and to remove all the fetal parts. Prior to starting the evacuation, sufficient cervical dilatation must be confirmed. If cervical dilatation is inadequate, additional osmotic dilators can be placed and the procedure delayed for at least 4 to 6 hours or rescheduled for the next day (Hern, 1994). Care is taken to leave the membranes intact during osmotic dilation. If the chorioamnion is inadvertently ruptured, the osmotic dilators are still placed but removed within 12 hours. The procedure is then completed.

Once dilatation is deemed adequate, the cervix is grasped with a tenaculum, and a cannula is passed into the uterine cavity to rupture the membranes and evacuate as much amniotic fluid as possible by applied suction. The cannula is always advanced fully into the uterine cavity before suction is applied. Up to 15 weeks' gestation, a 14-mm cannula will usually suffice, whereas gestations ≥ 16 weeks require a 16-mm size. During suctioning of the amniotic fluid, some membranes and placental tissue are often removed. However, complete placental removal is generally delayed until after the fetal parts are taken.

After the amniotic fluid and cannula have been removed, the operator extracts the fetal parts with forceps (Fig. 9-10). Once inserted, the forceps should be opened widely and one blade inserted along the anterior uterine wall to grasp the fetal parts. When fetal parts are felt between the blades on closing the handles, these are removed with a firm grasp and a gentle twisting motion. The calvarium is the most likely part to be left behind. If it cannot be grasped with forceps, some clinicians administer oxytocin, which may induce its descent toward the internal os and thereby aid its retrieval.

Complete placental removal generally requires one or more passes with the 14- to 16-mm suction curette. Before concluding the procedure, the fetal parts are assembled to confirm a complete abortion. Similarly, the quantity of placental tissue is visually assessed. If fetal parts remain in the uterus, gentle probing with a small, sharp curette may locate and retrieve them. Conversely, they may be identified with sonography and then removed.

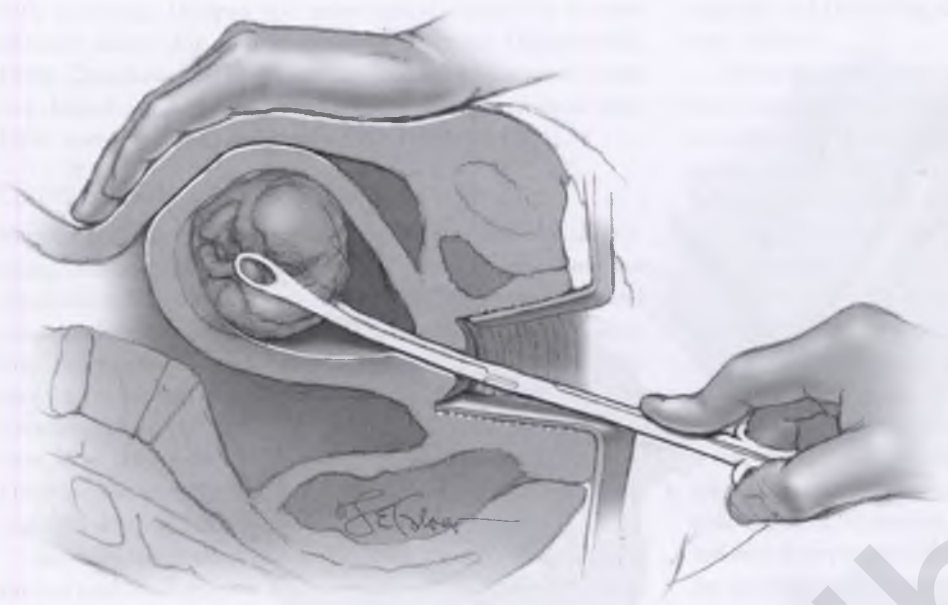


FIGURE 9-10 Proper use of extracting forceps during D & E. External manipulation of the uterus may aid the operator in locating and grasping fetal parts if intraoperative sonography is not used.

■ Hysterotomy and Hysterectomy

Except in unusual circumstances, hysterotomy is infrequently used for abortion. Prior placement of an abdominal cerclage with plans for continued cerclage retention or a large obstructing myoma may be legitimate indications for hysterotomy. In some cases, a spontaneous hysterotomy may occur with uterine rupture during midtrimester labor induction (p. 150). Possible indications for concurrent abortion/hysterectomy include some cases of cervical cancer, uncontrollable hemorrhage from abnormal placentation, and septic abortion.

PREABORTION CERVICAL RIPENING

Many first-trimester procedures are performed following preoperative cervical preparation. One Cochrane review of 51 trials of first-trimester surgical abortion included comparisons of 24 different cervical preparations (Kapp, 2010). These investigators concluded that a separate cervical ripening phase decreased the procedure length and the need for mechanical dilation. Agents included mifepristone, osmotic dilators, and any of four different prostaglandins. More recent placebo-controlled trials have confirmed the efficacy of preoperative ripening with misoprostol in the first trimester, albeit at the risk of more maternal symptoms. Of these, Meirik and colleagues (2012) showed that a single 400- μ g oral dose of misoprostol was associated with lower rates of incomplete abortion and the need for repeat curettage. Using a similar dose administered vaginally, Mittal and associates (2011) observed decreased procedural time, blood loss, and need for mechanical dilation. The World Health Organization Technical and Policy Guidance on Safe Abortion and the Royal College of Obstetricians and Gynecologists recommend cervical preparation for procedures beyond 9 weeks' gestation for nulliparas and for all women beyond 10 weeks (Lalithkumar, 2007). In the second trimester,

cervical preparation is essential to prevent cervical and uterine injury. Various mechanical and pharmacologic methods are listed in Table 9-1.

■ Osmotic Dilators

Laminaria Tents

Laminaria species, specifically *L. japonica* and *L. digitata*, were one of the earliest cervical ripening devices. Made from desiccated seaweed stalks, laminaria induce cervical ripening primarily through mechanical distention of the endocervical canal. Secondary mechanisms are the release of endogenous prostaglandins and possibly disruption of weak collagen cross-linkages (Ye, 1982). After preparation of the cervix with an antiseptic solution, one or more laminaria tents are coated with sterile lubricating jelly. They are inserted into the cervical canal so that their proximal tip lies just past the internal os (Fig. 9-11). The tents expand most rapidly in the first 4 to 6 hours but reach maximum size at 24 hours. They attain a final diameter four times greater than their original (Wheeler, 1983). Placement of several smaller tents, rather than one large tent, may result in improved dilatation. This may also ease their later removal, as a single, large tent can form a dumbbell shape in the

TABLE 9-1. Cervical Ripening Methods Prior to Induced Abortion

Mechanical	
Osmotic dilators	
Laminaria	
Dilapan-S	
Lamicel ^a	
Catheters	
Foley \pm extraamniotic saline infusion	
Metreurynter	
Pharmacologic	
Prostanoids	
PGE ₁ (misoprostol, gemeprost ^a)	
PGE ₂ (dinoprostone, metenoprost ^a)	
PGF _{2α} (carboprost, native PGF _{2α} ^a)	
Antiprogestin	
Mifepristone	
Nitric oxide donor	
Nitroglycerine (glyceryl trinitrate gel)	
Aromatase inhibitor	
Letrozole	

^aNot currently available in the United States.

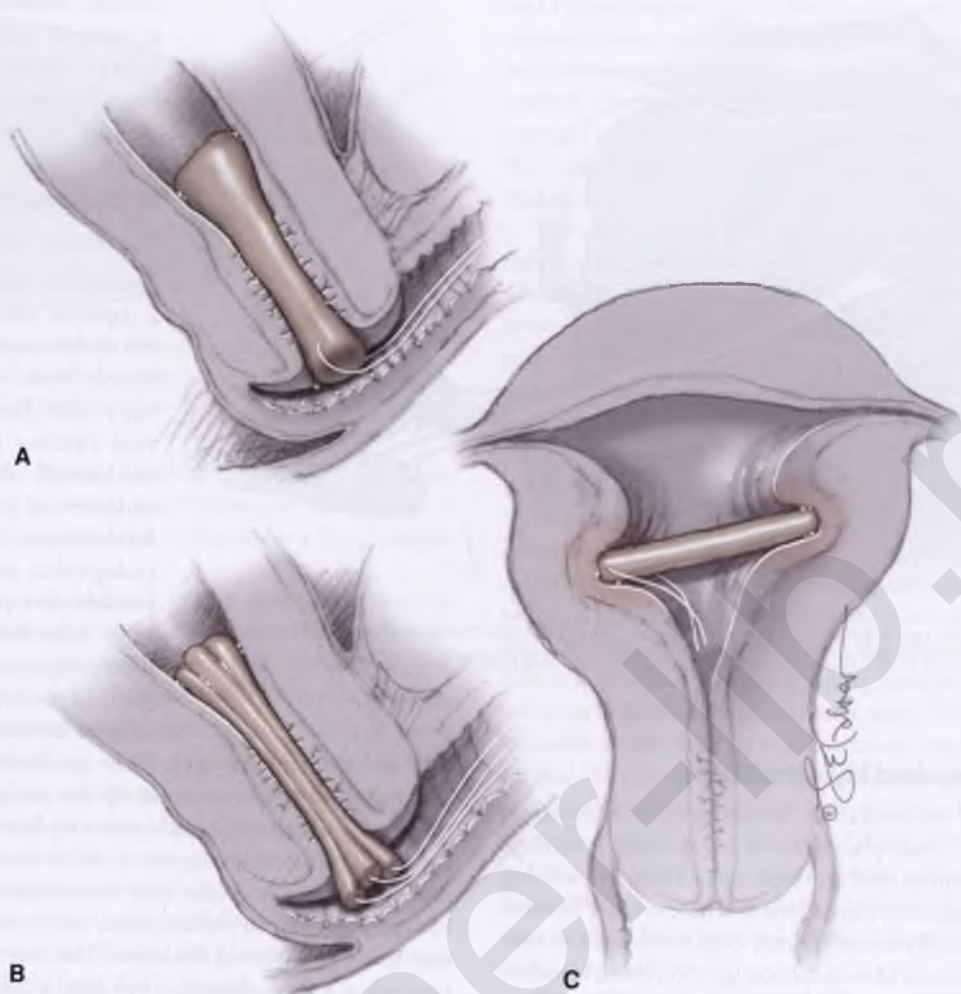


FIGURE 9-11 Insertion of laminaria prior to suction curettage. **A.** Swollen single, large laminaria. **B.** Placement of multiple, small laminaria. **C.** Misplaced or dislodged laminaria in the uterine cavity.

canal and lead to a more difficult and painful tent extraction. The clinician ideally places as many tents as will fit without causing patient discomfort. Gentle placement of several gauze sponges at the external os helps to prevent spontaneous expulsion. If placed too far into the endocervical canal, laminaria can become dislodged superiorly and become intrauterine. For this reason, the numbers of sponges and laminaria inserted are carefully tabulated and recorded in the chart. Laminaria, once placed, do not preclude the patient from ambulating, voiding, or stooling.

For midtrimester medical induction, laminaria are effective and significantly reduce the induction-to-delivery interval (Atlas, 1998; Stubblefield, 1975). In general, the value of laminaria increases with longer insertion-to-induction intervals, and the laminaria are ideally inserted the day prior to the procedure. Serial laminaria applications significantly increase cervical dilatation compared with a single application (Hern, 1994; Stubblefield, 1982). Indeed, repetitive laminaria application over several days can produce cervical dilatation of approximately 4 cm. This may create enough dilatation to preclude the need for additional forced dilatation in the operating room during D & E or further hasten labor in cases where labor induction is selected. For the latter, use of a vaginal prostaglandin and a single laminaria application prior to or concurrent with the uterotonic agent is gener-

ally sufficient. In sum, the need for shorter inductions must be weighed against the delay and patient inconvenience associated with 2 to 3 days of cervical preparation.

Disadvantages associated with laminaria include the skill for correct placement, the need for a separate patient encounter, delay in obtaining maximum effect, and patient discomfort associated with placement. Other less-desirable features include an inability to mold or shape the tents to conform to a curved canal and a lack of precise manufactured specifications. There is also a potential for incomplete sterility because ethylene oxide sterilization does not completely eradicate viable spores that may be found in the interstices of the seaweed stem. These concerns have prompted the development of alternative synthetic osmotic dilators.

Dilapan-S

This hygroscopic cervical dilator is composed of a polymer hydrogel and is available in two diameters—3 and 4 mm. In 1995, the original Dilapan was removed from the U.S. market because of concerns over device fragmentation. It was reintroduced as Dilapan-S following Food and Drug Administration (FDA) approval of a new device design. After 4 to 6 hours, the 3-mm size can expand to reach 10 mm in diameter, whereas the 4-mm size can attain a nearly 13-mm diameter. Compared

with laminaria, Dilapan acts more quickly, and it is a more effective dilator for second-trimester abortions (Blumenthal, 1988; Chambers, 2011). In contrast, similar efficacy was noted in a clinical comparison of laminaria and Dilapan in more than 1000 women prior to outpatient D & E (Hern, 1994).

Catheter Dilators

Various balloon-catheter devices are effective for cervical ripening, although they are not widely used. *Metreurynters* are intrauterine balloons that are inflated with a sterile solution and connected to traction, resulting in mechanical cervical dilatation. Foley catheters with a 30-mL balloon are more commonly used in the United States. Catheters likely exert their effect by stretching the cervix and lower uterine segment, which stimulates local release of endogenous mediators (Manabe, 1983). Double-balloon catheters have been developed that exert bidirectional dilating forces at the internal and external os.

Extra-amniotic saline infusion (EASI) is another efficient adjunct to both midtrimester and term labor inductions (Sherman, 1996). Using aseptic technique, a lubricated 26-French (8.7-mm diameter) Foley catheter with a 30- to 50-mL balloon is grasped with ring forceps and inserted through the internal cervical os using some countertraction if needed. Following insertion, the catheter balloon is inflated in the lower uterine segment. For the tightly closed, nulliparous cervix, a smaller diameter catheter, that is, an 18F size (6-mm diameter) may be preferred. Normal saline is infused through the catheter lumen at a nominal rate of 30 to 60 mL/hr. In contrast to metreurynter use, traction is not applied. The proposed mechanism of action is both mechanical pressure and disruption of the choriodecidual interface, which releases endogenous prostaglandins (Keirse, 1983). Use of EASI alone can induce midtrimester abortion. However, the time from catheter placement to delivery averages 30 to 35 hours (Blum, 1980). In a randomized clinical trial, Hogg and Owen (2001) compared laminaria and EASI in women undergoing midtrimester termination with high-dose oxytocin and low-dose vaginal PGE₂. No significant differences between the two groups with regard to labor duration (mean = 17 hours) or induction success at 24 hours were observed.

For midtrimester pregnancy labor induction, EASI offers low cost, reversibility, lack of systemic side effects, more efficient placement, and less patient discomfort. Compared with laminaria, EASI does not appear to increase the risk of obstetric infection (Hogg, 2001).

■ Pharmacologic Cervical Ripening

Prostaglandins

These endogenous lipid-soluble hormones have a broad spectrum of physiologic effects. Although commonly used for labor induction, prostaglandins are also used for cervical ripening. These compounds induce enzymatic changes that promote collagen breakdown and collagen fiber rearrangement and thereby cervical softening and dilatation (Ramsey, 1996). Although various prostaglandin formulations can be administered by vaginal, intracervical, extraovular, intraamniotic, intravenous, intramuscular (IM), and oral routes, most regimens studied have included

vaginal, oral (including sublingual and buccal), and intraamniotic delivery.

These pharmacologic alternatives to osmotic dilators for cervical ripening prior to surgical abortion procedures have been investigated. As mentioned previously, a separate cervical ripening phase is not mandatory prior to first-trimester D & C, but may have some clinical advantages. There are theoretic advantages to avoiding forced cervical dilatation, particularly in nulliparas.

Lawrie and colleagues (1996) provided a 400- μ g oral dose of misoprostol given 12 hours prior to vacuum aspiration to one group and compared this with an 800- μ g vaginal dose of misoprostol given 2 to 4 hours preoperatively to another group. These researchers measured the insertion force required to attain 9 mm of dilatation. Although neither regimen was superior in this regard, oral administration induced abortion prior to the clinic visit in two of 30 women, and one additional patient was admitted with heavy vaginal bleeding. Both groups experienced a similar incidence of prostaglandin-induced side effects—20 percent had nausea or vomiting. Women in the oral group also experienced more abdominal pain and preoperative bleeding. Based on two prospective randomized trials, Singh and associates (1998, 1999) concluded that vaginal misoprostol 400 μ g given 3 hours prior to D & C dilated the cervix to the desired 8 mm in 92 percent of nulliparas. Abdominal pain occurred in 13 percent of their study population, and vaginal bleeding was observed in 17 percent. Other similar trials have demonstrated shorter operating times and less blood loss in women pretreated with misoprostol compared with placebo (Scheepers, 1999). Although first-trimester cervical ripening with misoprostol appears to have advantages that are both objective—shorter operating time—and surrogate—less forced dilatation, the incidence of maternal side effects detracts from its clinical utility.

Prostaglandins similarly induce cervical ripening prior to or concurrent with midtrimester abortion. Low dosages of prostaglandins—PGE₁, PGE₂, and PGF_{2 α} analogues—are effective for this. Comparisons between prostaglandins and osmotic dilators have yielded mixed results with regard to cervical ripening prior to midtrimester labor induction (Atlas, 1998; Christensen, 1983; Darney, 1987a; Killick, 1985; Lauersen, 1982). Medical methods have the advantages of being less invasive and of posing less potential for cervical trauma. The amount of cervical dilatation achieved with low-dose vaginal and IM prostaglandins is proportional to the posttreatment interval. In a study by Christensen and coworkers (1983), cervical dilatation was measured by the size of the largest Hegar dilator that could be inserted through the cervical canal without resistance. At 3 hours posttreatment, the cervix was dilated 7 to 8 mm; at 6 hours, 8 to 9 mm; and at 12 hours, 9 to 10 mm. Although prostaglandins are useful for cervical ripening, their efficacy is dose dependent. Higher doses may cause undesirable side effects, such as uterine contractions and bleeding.

Hormone Modulators

Mifepristone (Mifeprex) is an FDA-approved derivative of the synthetic progestin norethindrone and is available as 200-mg tablets in the United States. It is a progesterone-receptor antagonist and competitively inhibits endometrial progesterone receptors to incite

TABLE 9-2. Medical Abortion: Research Dimensions

Agents, alone or in combination: mifepristone, misoprostol, gemeprost, methotrexate
Dosage and dosing interval for each medication
Route of prostaglandin administration: oral, buccal, sublingual, vaginal, rectal
Use of repeat prostaglandin dosing regimens
Definition of medical "failure" requiring D & C
Recommended follow-up protocols: timing, adjunctive sonography/ β -hCG confirmation
Gestational age limit: ≤ 49 days versus > 49 days
Influence of patient history such as parity
Side-effect profiles
Patient satisfaction and willingness to use again

hCG = human chorionic gonadotropin; D & C = dilatation and curettage.

decidual necrosis and endometrial sloughing. It also stimulates myometrial prostaglandin production, increases myometrial sensitivity to prostaglandins, and upregulates myometrial gap junctions (Swahn, 1988). Thus, like prostaglandins, mifepristone has a wide range of reproductive effects, which include cervical ripening.

Concomitant use of mifepristone and prostaglandins is also effective for second-trimester pregnancy interruption (Jannet, 1996; UK Multicenter Group, 1997). Randomized clinical trials of midtrimester labor induction have evaluated preinduction treatment with oral mifepristone and compared it with preinduction cervical ripening with osmotic dilators or with low-dose prostaglandins. Oral mifepristone significantly shortened induction-to-delivery intervals and provided superior induction success rates (Ho, 1995; Rodger, 1990). Mifepristone is also effective as a cervical ripening/dilating agent given 30 to 48 hours prior to first-trimester D & C (Cohn, 1991; Lefebvre, 1990). As with misoprostol, higher dosages were associated with increased abdominal pain and bleeding.

MEDICAL ABORTION

■ First Trimester

Since the commercial release of mifepristone, the worldwide use of medical regimens as an alternative to surgical D & C has increased markedly. Typical regimens use a combination of oral mifepristone followed by a prostaglandin—generally misoprostol, 400 to 800 μ g. Mifepristone is approved by the FDA as a component of first-trimester medical abortion regimens at a dose of 600 mg and at a gestational age not to exceed 49 days. However, mifepristone can only be prescribed by certified providers, is relatively expensive, and is not legally available in all countries. Accordingly, single-agent misoprostol regimens and the use of methotrexate and as a mifepristone substitute have been investigated.

Overall first-trimester medical abortion success rates range from 90 to 95 percent. Very low rates of serious complications are observed in controlled clinical settings with good access to emergency services and high rates of follow-up. Whether these rates can be achieved in a more general clinical setting has been questioned. Nevertheless, these success rates, alone or in aggregate, are lower than rates reported for first-trimester D & C, which exceed 99 percent (Hakim-Elahi, 1990). Because

the goal of medical regimens is to cause the biologic equivalent of a miscarriage, the clinical course closely mimics the natural event, albeit with variable and unpredictable timing and duration. Abdominal pain, vaginal bleeding, nausea, vomiting, and diarrhea are anticipated side effects from prostaglandins and from the passage of the conception products.

In search of the "optimal" medical abortion, investigators have researched numerous aspects of the process (Table 9-2). This creates nearly endless combinations of different components and therefore significant confusion. A Cochrane review by Kulier and coworkers (2011b) evaluated 58 trials that used a primary outcome of "failure to achieve complete abortion." Included studies varied by compared agents, drug dosages, routes of administration, and timing of administration. Secondary outcomes were rates of surgical evacuation and ongoing pregnancy, prolonged time to complete abortion, days of bleeding, pain, use of additional uterotonic agents, gastrointestinal side effects, and patient dissatisfaction. Including selected secondary outcomes for each primary comparison, more than 60 forest plots were produced! The authors' conclusions are summarized in Table 9-3.

Presently, the most widely accepted regimen is mifepristone 600 mg (or alternatively, 200 mg) orally on day 1 in clinic. This is followed in 48 hours by misoprostol 400 μ g (or alternatively 800 μ g at 49 to 63 days' gestation), administered by a vaginal, buccal, or sublingual route. The misoprostol may be given in clinic or taken by the patient at home, which avoids an additional visit. If mifepristone is not available and methotrexate is contraindicated, then vaginal misoprostol alone may be used. Typically, an 800- μ g misoprostol dose is given every 3 to 24 hours for a maximum of three doses. Misoprostol-only regimens are associated with significantly higher continuing pregnancy rates (approaching 10 percent) compared with the rates for approved-combination regimens (≤ 1 percent).

Usually, a follow-up office visit is scheduled for 2 weeks, at which time the patient is assessed for abortion completion. This evaluation is based on only clinical features, and use of clinical history alone appears to be satisfactory (Rossi, 2004). Of adjunctive tools, transvaginal sonography would be expected to show an absent gestational sac, whereas a quantitative serum β -hCG level should demonstrate a predicted fall. If the clinical evaluation does not confirm completion, and sonography shows a gestational sac, surgery is usually recommended.

TABLE 9-3. Summary of a Cochrane Review of Methods for First-Trimester Medical Abortion

Mifepristone plus misoprostol, the most common combination regimen, is safe and effective
Combination regimens are more effective than single-agent protocols
Lowering the mifepristone dose from 600 mg to 200 mg does not decrease efficacy if combined with a misoprostol dose of at least 400 µg
Vaginal misoprostol is superior to oral (including buccal and sublingual): higher efficacy and lower side effects
Use of the combination regimen at ≥9 weeks is associated with at least a doubling of the failure rate compared with use at ≤7 weeks
The combination of methotrexate and a prostaglandin is associated with success rates >90 percent
The most common serious complication is the need for blood transfusion and approximates 0.2%
The ability to generalize of these results to some settings may be limited because of the controlled research protocols

Data from Kulier, 2011b.

An important limitation of these regimens is the gestational age ceiling, above which efficacy declines and complications increase. Most major trials have excluded pregnancies beyond 9 weeks (63 days). In a large trial, which used a 600-mg oral dose of mifepristone and an oral 800-µg dose of misoprostol, the success rate for ages ≤49 days was 92 percent. This rate declined to 83 percent for ages between 50 and 56 days and to 77 percent for ages between 57 and 63 days (Spitz, 1998). This decline in efficacy may be unique to regimens that use oral misoprostol instead of vaginal misoprostol or gemeprost (El-Refaey, 1995). Nevertheless, these protocols require precise gestational age criteria and the availability of vaginal sonography (Spitz, 1998).

The definition of abortion success also varies among trials, which may account for some of the observed variance and makes direct comparisons difficult. Implicit in these definitions is the recognition that first-trimester medical abortion success represents a continuum. It ranges from complete expulsion of conception products within 4 hours of prostaglandin administration to a continuing pregnancy that is recognized several weeks later and surgically removed. The most rational research-based definition of failure is the subsequent use of curettage to complete the procedure due to clinically significant hemorrhage, retained products, continuing pregnancy, or patient request (Spitz, 1998). The decision to perform curettage is based, in part, on clinical judgment and on a reasonable but arbitrary time limit, such as 14 days. It is unlikely that success rates with current regimens can be further improved.

As an alternative to mifepristone, methotrexate 50 mg/m² is administered orally or more commonly by IM injection. This is followed 3 to 7 days later by an 800-µg vaginal dose of misoprostol. As with mifepristone-based regimens, vaginal administration of the misoprostol is more effective than the oral route. Comparative trials have also shown superiority of a 7-day interval compared with a 3-day methotrexate-misoprostol interval. The 3-day interval led to a sevenfold higher failure rate (Crenin, 1995). One trial randomly assigned 1042 women with gestations ≤49 days to receive IM methotrexate 50 mg/m² plus an 800-µg vaginal dose of misoprostol or to receive a 600-mg oral dose of mifepristone and a 400-µg oral dose of misoprostol (Wiebe, 2002). Significantly more women in the mifepristone group had completed the abortion by day 8—91 percent versus 75 percent. However, the number of surgical interventions

by 2 weeks was similar—3.6 percent versus 4.0 percent. Side effects were similarly common in both groups (>50 percent). Clinically significant complications occurred in only 4.4 percent of the methotrexate group and 3.6 percent of the mifepristone patients. One advantage of methotrexate compared with mifepristone is that it may effectively treat the rare ectopic pregnancy.

Compared with outpatient D & C, medical abortions are cumbersome, more expensive, and logistically demanding. More clinic visits are required, and the staff must be thoroughly familiar with the side effects and typical course for expulsion of conception products. Importantly, the need for immediate access to surgical facilities must be appreciated, although only 2 to 4 percent of women develop an indication for surgical intervention (Spitz, 1998).

■ Second Trimester

Complete, dysmorphic assessment of an aborted fetus is assisted by an intact conceptus, and this is a relative contraindication to D & E. Several methods of second-trimester medical abortion are listed in Table 9-4. Vaginal and IM prostaglandins and IV oxytocin are effective agents. Rarely used in contemporary practice to induce midtrimester abortion, various compounds that include hypertonic saline, hyperosmotic

TABLE 9-4. Medical Induction of Midtrimester Abortion

Prostanoids: PGE₁, PGE₂, PGF_{2α}

Vaginal

Intrauterine: extraovular^a, intraamniotic

Intramuscular

Oral, buccal, sublingual

Oxytocin

High-dose intravenous regimens

Instillation Procedures

Hypertonic saline

Hyperosmolar urea

Ethacridine lactate

^aExtraovular describes the potential space between the uterine decidua and chorion.

urea, and prostaglandins can be instilled into the uterine cavity, through intraamniotic or extraovular routes. *Extraovular* refers to the potential space between the uterine decidua and chorion. Concomitant use of cervical ripening optimizes induction efficacy.

Prostaglandin E₂

Several prostaglandins are commonly used for midtrimester medical abortion. Two commercially available PGE₂ analogues are dinoprostone (Prostin) and meteneprost. Of these, only Prostin is FDA approved as an abortifacient in the midtrimester and up to 28 weeks' gestation. The recommended dosing regimen of Prostin for second-trimester termination is 20 mg vaginally every 3 to 4 hours with a maximal exposure of 24 hours. The suppositories are inserted high into the posterior fornix. In 123 women who underwent a midtrimester abortion with osmotic dilator preparation followed by vaginal PGE₂, 20 mg every 4 hours, the mean induction-to-delivery interval was 13 hours. This did not include the 17 percent who had a failed induction at 24 hours and received an alternate regimen (Owen, 1992, 1996).

Higher rates of induction success with this vaginal PGE₂ regimen have been reported. Rakhshani and Grimes (1988) observed a 90-percent success rate at 24 hours in 94 women who received Prostin, 20 mg every 3 hours, but did not receive osmotic dilator pretreatment. The mean delivery interval was 14 hours. Lauersen and associates (1975) observed a mean abortion interval of 12 hours using Prostin, 20 mg every 2 hours, and only 1 of 70 women was not delivered by 24 hours. PGE₂ is costly and not thermally stable, so that improper storage and handling may render it inactive. Thus, if a patient has poor biologic response to vaginal PGE₂, one should consider using a different lot number.

Reasonable options for PGE₂ failures include D & E, changing to a different induction agent such as concentrated oxytocin, or delaying the induction for several days (Lauersen, 1975; Owen, 1992). If delay is possible, sequential application of osmotic dilators in the interval is considered.

Common side effects from PGE₂ include nausea, emesis, fever, diarrhea, and headache. Hypotension may occur, but it is uncommon. The addition of an antipyretic such as acetaminophen to this regimen is useful. Even with prophylaxis, these symptoms develop in 40 to 60 percent of patients (Lauersen, 1975; Owen, 1992, 1996).

Prostaglandin F_{2α}

In this country, native PGF_{2α} has been replaced by a long-acting methylated form, which is carboprost tromethamine (Hemabate). It is the only other commercially available prostaglandin and is FDA-approved and marketed as a midtrimester abortifacient for 13- to 20-week gestations. The recommended dosing regimen of carboprost for midtrimester abortion is 250 μg, administered by IM injection every 1.5 to 3.5 hours with maximum exposure of 12 mg or 48 hours. An initial test dose of 100 μg may be given to confirm patient tolerance before the full 250-μg dose. Women who fail to respond to the initial dose may receive a 500-μg dose.

Common side effects associated with carboprost include vomiting and diarrhea (66 percent), fever (12 percent), flushing

(7 percent), and hypertension (4 percent). In a randomized trial of PGF_{2α} administered by continuous IV infusion, prophylactic treatment with prochlorperazine (Compazine) and diphenoxylate hydrochloride with atropine (Lomotil) significantly reduced side effects and did not affect treatment efficacy (Fahmy, 1981). Bronchoconstriction can occur in susceptible patients, and carboprost is used with caution in patients with asthma.

Intramuscular carboprost is effective and results in induction-to-delivery intervals of 11 to 21 hours (Borgida, 1995; Bygdeman, 1988). Clinical trials comparing IM carboprost to vaginal PGE₂ have demonstrated that PGE₂ is superior to carboprost with regard to induction success at 24 hours and induction-to-delivery interval (Borgida 1995; Bygdeman, 1988). Although effective for midtrimester abortion, the frequent IM administration and high rate of gastrointestinal side effects, even in premedicated patients, make this alternative less desirable than the standard vaginal PGE₂ regimen.

Outside of the United States, intraamniotic 15-methyl-PGF_{2α} (2.5 mg) has also been studied as a midtrimester abortifacient and compared with intraamniotic native PGF_{2α} (World Health Organization, 1977). It was found to be superior to both vaginal PGE₂ and vaginal misoprostol (Ferguson, 1993; Perry, 1998). Intraamniotic administration compared with the IM route appears to have similar efficacy but fewer maternal side effects.

Prostaglandin E₁

Series E₁ prostaglandins are potent uterotonic agents with tolerable side-effect profiles. Two PGE₁ preparations have been evaluated for midtrimester labor induction. Of these, misoprostol (Cytotec) is available in this country, but gemeprost (Cervagem) is not currently available. Both compounds are highly effective for midtrimester labor induction. Induction-to-delivery intervals range from 15 to 17 hours with gemeprost alone and from 13 to 35 hours for misoprostol alone (Scheepers, 1999). The wide efficacy range observed for misoprostol is likely due to variations among dosing regimens, which vary from 100 μg every 12 hours to 400 μg every 3 hours. Oral versus vaginal administration also accounts for a portion of the observed variance. For example, the oral route is inferior because of increased maternal side effects (Ho, 1997).

Gemeprost dosing regimens are more uniform—generally 1 mg is placed vaginally every 3 to 6 hours. Unlike misoprostol, various gemeprost dosing regimens are similar with respect to labor duration and midtrimester induction success rates (Dickinson, 1998; Thong, 1992). Misoprostol has a significant cost advantage compared with gemeprost, and unlike gemeprost, misoprostol is thermally stable.

“High-dose” misoprostol regimens that administer 400 μg every 3 hours result in shorter labors, higher induction success rates, and lower retained placenta rates compared with a “low-dose” regimen of 100 μg given every 12 hours. This increased efficacy is associated with more side effects, primarily emesis (20 percent), diarrhea (22 percent), and temperature elevations (28 percent) (Herabutya, 1998). These side effects, however, develop less frequently than with either PGE₂ or PGF_{2α}. Side effects of gemeprost and their incidences resemble those with misoprostol. Emesis is noted in 14 to 23 percent, and diarrhea

TABLE 9-5. Concentrated Oxytocin Protocol for Midtrimester Pregnancy Termination

Cycle 1: 50 units oxytocin in 500 mL normal saline IV over 3 hours (278 mU/min) followed by a 1-hour diuresis
Cycle 2: 100 units oxytocin in 500 mL normal saline IV over 3 hours (556 mU/min) followed by a 1-hour diuresis
Cycle 3: 150 units oxytocin in 500 mL normal saline IV over 3 hours (833 mU/min) followed by a 1-hour diuresis
Cycle 4: 200 units oxytocin in 500 mL normal saline IV over 3 hours (1111 mU/min) followed by a 1-hour diuresis
Cycle 5: 250 units oxytocin in 500 mL normal saline IV over 3 hours (1389 mU/min) followed by a 1-hour diuresis
Cycle 6: 300 units oxytocin in 500 mL normal saline IV over 3 hours (1667 mU/min) followed by a 1-hour diuresis

in 20 to 26 percent (Cameron, 1987). Overall, misoprostol appears to be preferable to gemeprost.

Oxytocin

Although widely used for labor induction in the third trimester, these dilute solutions of oxytocin are generally ineffective in the midtrimester. In contrast, concentrated oxytocin regimens are effective for midtrimester pregnancy termination (Owen, 1999; Ramin, 2000; Winkler, 1991; Yapar, 1996). One regimen is shown in [Table 9-5](#). For pregnancies up to 24 weeks' gestation, concentrated oxytocin, alone or with the addition of low-dose vaginal PGE₂ (10 mg every 6 hours), has been compared with the standard PGE₂ vaginal regimen (Owen, 1992, 1996). Concentrated oxytocin is associated with fewer maternal side effects than vaginal PGE₂ regimens and has similar efficacy.

The addition of low-dose vaginal PGE₂ to the concentrated oxytocin infusion likely stimulates cervical ripening beyond that achieved with concurrent osmotic dilator placement and appears to increase the proportion of women delivered by 24 hours (Owen, 1996, 1999). A comparison of vaginal misoprostol (200 µg every 12 hours) versus concentrated oxytocin plus low-dose vaginal PGE₂ demonstrated that a relatively low dose of vaginal misoprostol was inferior with regard to rates of 24-hour induction success, retained placenta, and incidence of live birth (Owen, 1999). Conversely, a higher-dose misoprostol regimen, consisting of an initial dose of 600 µg, followed by 400 µg every 4 hours for a total 24-hour dose of 2600 µg, was associated with a shorter induction time and fewer cases of retained placenta compared with the concentrated oxytocin/PGE₂ regimen described above (Ramsey, 2004).

It is important to emphasize that this standardized concentrated oxytocin regimen uses isotonic normal saline as the diluent, limits total fluid intake to 3000 mL in 24 hours, and allows scheduled periods of diuresis between each cycle. Note

that the volume of crystalloid diluent can be decreased from a nominal 500 mL per cycle to as few as 50 to 100 mL if clinically indicated, as long as each cycle is administered during 180 minutes. If delivery is considered to be imminent at the end of cycle 6, then cycle 6 may be repeated.

Whalley and Pritchard (1963) observed that high doses of oxytocin given for prolonged periods in hypotonic solutions may lead to symptomatic hyponatremia. In a randomized trial of concentrated oxytocin, Owen and associates (1992) found similar pre- and postinduction serum sodium levels using a defined concentrated oxytocin protocol similar to that shown in [Table 9-5](#).

Intrauterine Instillation of Nonprostanoid Agents

Three non-prostanoids have been administered via intrauterine instillation for midtrimester abortion but are now largely of historic interest. Of these, hypertonic saline is gravity-instilled as 150 to 250 mL of a 20-percent saline solution into the uterine cavity through an 18-gauge spinal needle. Intraamniotic needle placement must be confirmed to prevent unintentional intravenous, intraperitoneal, or intramyometrial injection. Fetal death usually occurs within a few hours of instillation. Hypertonic saline is contraindicated in patients with active pelvic infection, fetal death, or unstable medical conditions such as cardiopulmonary disease or renal insufficiency. Hypertonic saline instillation is associated with a mean instillation-to-abortion interval of 22 to 25 hours, depending on the concurrent dosage of oxytocin (Kerenyi, 1973). It can be used without an additional uterotonic (oxytocin). A combined approach may increase the incidence of water intoxication and disseminated intravascular coagulopathy (Berger, 1975). Hypofibrinogenemia develops in approximately 0.3 percent of cases (Kerenyi, 1973). Hyponatremia is rare and has only been associated with saline-instillation abortions.

Hyperosmolar urea is effective and is also fetocidal. Typically, a 30- to 40-percent solution, that is, 60 to 80 g in 200 mL of normal saline, is instilled. Unintentional systemic administration is not associated with the same severe complications as seen with hypertonic saline. Although hyperosmotic urea may be somewhat safer than saline, instillation-to-delivery intervals are generally longer and range from 36 to 48 hours.

Ethacridine lactate is an acridine dye that appears to be a safe and effective alternative to hyperosmotic agents and is still used in developing countries. When administered as a 0.1-percent solution into the extraovular space (250 to 300 mL) through a transcervical catheter, instillation-to-delivery intervals range from 25 to 40 hours (Bhathena, 1990). Intraamniotic administration results in comparable instillation-to-delivery intervals (Gardo, 1990). Concomitant use of oxytocin reduces induction-to-delivery intervals to 15 to 20 hours (Yapar, 1996).

Second-Trimester Medical versus Surgical Abortion

Second-trimester abortions account for approximately 10 percent of procedures in the United States but for a disproportionate share of abortion-associated morbidity. Thus, an understanding of the comparative efficacy and complications

associated with medical versus surgical terminations is essential. A Cochrane review by Lohr and coworkers (2008) compared these methods based on an analysis of only two available trials from 1980 ($n = 100$) and 2004 ($n = 18$). One trial compared D & E with intraamniotic PGF_{2α} (Grimes, 1980). The other compared D & E against a 200-mg oral dose of mifepristone followed by a single, vaginal 800-μg dose of misoprostol and then oral misoprostol, 400 μg every 3 hours. In both trials, the D & E group received laminaria 1 to 2 days prior to surgery (Grimes, 2004). With such small samples, the confidence intervals for uncommon complications were wide and included unity. However, a composite of adverse events favored D & E. Surgery was also associated with less pain and hospital time, as most of the medical group spent at least one inpatient night compared with <5 percent of the D & E group. Of note, more than half of the medical group in the misoprostol trial required curettage for retained placenta. In comparison with other studies, this was much higher than a reported rate of 8 percent with mifepristone plus misoprostol or 2 percent with misoprostol plus EASI (Ashok, 2004; Ramsey, 2004).

A randomized trial by Kelly and associates (2010) compared medical and surgical terminations at 13 to 20 weeks' gestation with a primary outcome of "distress" measured by the impact-of-events scale and also acceptability. At the 2-week follow-up, patients favored surgery, reporting significantly lower intrusion subscores and higher general health scores. One hundred percent of respondents were willing to have a repeat surgical termination compared with only half of the medical group. The medical group also reported significantly more pain and bleeding.

In cases of suspected abnormal placentation as with prior cesarean delivery and placenta previa, D & E is preferable to medical regimens. That said, special preparations are made to manage hemorrhage and include the availability of blood components, interventional radiology, and facilities to perform hysterectomy.

In summary, when choosing medical labor induction versus surgery in the midtrimester, numerous aspects should be considered including effectiveness, cost, safety, side effects, associated comorbidities, patient preference, indication, and provider availability. For most of these aspects, D & E is clearly favored, but the biggest obstacle may be provider availability.

ABORTION COMPLICATIONS

Serious complications including infection, hemorrhage, and need for additional unplanned surgical procedures occur at a rate that approximates 0.7 per 1000 first-trimester abortions (Hakim-Elahi, 1990). Including later procedures, an observed rate was 7 events per 1000 cases (Grimes, 1979). Many complications are preventable, but some still occur despite competent technique. Therefore, providers ideally are able to recognize complications, avoid them to the degree possible, and understand that optimal management may require additional specialized facilities and consultation. Because most legal abortions are currently performed using surgical methods, a standard conceptual triad of bleeding, infection, and tissue injury is

applicable. Medical pregnancy terminations may impose additional risks, as do anesthetic complications.

■ Surgical Injury

During surgical evacuation, the cervix, uterine corpus, or adjacent abdominal organs may be damaged. First, cervical trauma may follow forceful dilatation or misdirected dilators, and these can lead to a false tract, perforation, vessel injury, or cervicovaginal fistula. Trauma from the grasping tenaculum is also possible. Vessel injury occurs most commonly at the internal os in the 3 or 9 o'clock position. Consequent bleeding may require laparotomy because the ascending branch of the uterine artery will bleed into the broad ligament above the levator ani plane, which can cause severe pain. At laparotomy, the vessel can be identified and ligated, usually without the need for hysterectomy. Conversely, if the descending branch of the uterine artery is injured, the cardinal ligaments and levator ani muscle usually prevent intraabdominal bleeding, and the blood loss is mostly external. Sutures placed at 3 and 9 o'clock at the cervicovaginal junction may control the hemorrhage, but knowledge of the ureteral course is necessary to prevent ureteral ligation. If these sutures are unsuccessful, however, management may require hysterectomy unless the bladder and ureter can be mobilized and the vessel ligated. Another option is vessel embolization by arteriography, which is increasingly employed (Chap. 29, p. 478). In another scenario, transient vessel spasm with delayed hemorrhage, shock, and death may occur several hours after the injury.

A uterine sound, dilator, or curette may perforate the uterus, so preoperative knowledge of uterine size and position is crucial. If obesity or other factors interfere with bimanual examination, then sonography is indicated. In a series of 67,175 curettage abortions, of which 86 percent were performed at gestational ages less than 12 weeks, risk factors for perforation included operator inexperience, multiparity, and advanced gestational age. Preventively, use of osmotic dilators appeared to decrease the incidence of perforation (Grimes, 1984). Also, traction on the tenaculum grasping the cervix effectively straightens the canal and aids instrument passage. As the abortion proceeds, the uterine size decreases and instrument insertion must be adjusted accordingly. Simple perforations may be unrecognized, and thus the true incidence of this complication may be underestimated. The reported incidence is 0.09 to 0.9 events per 1000 abortions. Concurrent laparoscopy confirms a significantly higher rate of 20 events per 1000 cases (Grimes, 1984; Hakim-Elahi, 1990; Kaali, 1989).

Serious morbidity associated with uterine perforation is uncommon because the most likely site is the midline of the fundus. This myometrium is not highly vascular, and the contractile smooth muscle is an efficient hemostatic mechanism. Simple perforations without applied suction are generally managed with observation.

With a suspected high-risk perforation, particularly those associated with D & E, management is more involved. If readily available, sonography may be useful to identify blood in the cul-de-sac. Laparoscopy is used to confirm the injury site, exclude significant hemorrhage, and inspect adjacent viscera for damage. Perforations that are not bleeding and not associated

with other organ injury may be managed conservatively, observing for hemodynamic instability or peritoneal signs (Kaali, 1989). Uterine perforation is not a contraindication to completing the curettage under laparoscopic guidance. Conversely, the procedure may be delayed until the patient's condition is stable.

More seriously, suction curettage may injure the omentum, bowel, fallopian tube, bladder, or ureter. Bowel and omentum may become entrapped in the suction catheter or forceps and be delivered through the os. Because bowel injuries can be fatal, the extent of the injury must be well characterized to plan the most appropriate repair. Normal findings at laparoscopy can be falsely reassuring, and sequential exploration or "running" of the bowel by an experienced surgeon is preferable. Unfortunately, unrecognized bowel injuries may require several days to become clinically manifest, and most patients develop symptoms within 72 hours (Soderstrom, 1993). The extent of the bowel injury will determine the repair. A small serosal injury can be oversewn and followed by irrigation. Full-thickness injuries may require resection and reanastomosis. Prophylactic antibiotics are generally given for these cases.

Bladder injuries are also considered whenever the uterus is perforated. Laparoscopy can generally exclude significant injury to the dome, which can be repaired in layers followed by extended catheter drainage (Fig. 28-1, p. 456). Catheter placement can also demonstrate gross hematuria suggesting the possibility of a trigone injury. In these cases, urologic consultation and ureteral stenting are generally required. Bowel and lower urinary tract injuries and their management are discussed further in Chapter 28.

■ Hemorrhage

Blood loss during a first-trimester suction D & C averages less than 100 to 150 mL and increases with advancing gestational age. There are no widely accepted criteria to define a pathologic abortion-associated hemorrhage. Thus, transfusion may be an appropriate indirect measure of excessive blood loss. A rate of 0.6 cases of transfusion per 1000 first-trimester D & C procedures contrasts with 1.9 cases per 1000 D & E procedures and with 9.6 cases per 1000 saline and PGF_{2α} instillations (Grimes, 1979).

More commonly, hemorrhage with later abortions is caused by uterine atony, and blood loss increases with general anesthetic (Grimes, 1979). Atony is diagnosed by palpating an enlarged, boggy corpus. It is effectively treated with bimanual massage and uterotonic agents such as methylergonovine (Methergine), 0.2 mg IM, or carboprost tromethamine (Hemabate), 250 µg IM. When these measures fail, retained products should be suspected and may be visualized with ultrasound. Treatment is repeat curettage. If atony persists, invasive procedures can often be avoided by placing a Foley catheter within the uterine cavity and inflating its balloon with 30 to 80 mL of sterile saline to act as a tamponade. A Bakri balloon similarly filled with up to 500 mL of saline may be used for more advanced gestations (Fig. 29-6, p. 473).

Placenta accreta may cause profuse hemorrhage, requiring hysterectomy or uterine artery embolization (Peterson,

1983; Steinauer, 2008). Rarely, hematometra—"postabortion syndrome"—may develop in the first few hours after the procedure. Clinically, these women have severe lower abdominal pain, cramping, and even vagal symptoms. There is little or no external bleeding as the uterine cavity becomes distended with trapped blood and clot. Palpation reveals an enlarged, tense, tender, and globular uterus. Treatment involves repeat aspiration of the clot and administration of a uterotonic agent to prevent recurrence.

Retained products are an important source of abortion morbidity and may result in either bleeding or infection. The rate of immediate and delayed repeat aspiration is reported to be <1 percent (Hakim-Elahi, 1990). Bleeding may be immediate or delayed. Clinically, the uterus is often enlarged and tender, even in the absence of other signs and symptoms of infection. Management is repeat curettage. Preoperative sonography may be useful to estimate uterine size and amount of remaining products. If remote from the original procedure, a second course of antibiotics is considered.

Obstetric hemorrhage from any cause can lead to shock and coagulopathy. The latter may accelerate bleeding and hinder management. Fluid and blood component replacement through large-bore peripheral IV lines is lifesaving. Hemorrhage management is further outlined in Chapter 29.

■ Infection

Uterine infection with extension into other pelvic and abdominal organs may lead to sepsis and death. Retained products are an important predisposing factor, as are genital colonization with *Neisseria gonorrhoeae*, *Chlamydia trachomatis*, and some clostridial species (Burkman, 1976; Moller, 1982). If active cervicitis is suspected, Gram stain and appropriate cultures help guide antibiotic therapy prior to abortion. Women with endometritis generally present with fever, abdominal pain, and bleeding. Physical examination will confirm uterine tenderness and exclude abscess. For uncomplicated metritis, ceftriaxone 250 mg IM and 10 days of doxycycline 100 mg orally twice a day will cover the most common causative pathogens—group B streptococcus, *Bacteroides* species, *N gonorrhoeae*, *Escherichia coli*, and *Staphylococcus aureus* (Burkman, 1977).

Preventively, the use of antibiotics at the time of surgical abortion is well studied. A metaanalysis of 12 randomized studies performed between 1981 and 1993 confirmed an overall risk reduction of 0.58 (Sawaya, 1996). Significant risk reductions were found in all subgroups, including "low-risk" women. In one large trial, doxycycline, 100 mg orally given 1 hour before and 200 mg orally after the procedure, was associated with a relative risk of 0.12 for postoperative infection (Levallois, 1988). The best prophylactic regimen is less certain, and numerous agents are effective.

A Cochrane review by Low and coworkers (2012) included 19 trials of prophylactic antibiotics in women undergoing first-trimester surgical or medical abortion. The authors did not stratify outcome efficacy by medical versus surgical approach. They reported that, compared with placebo, postabortal infection rates declined by 41 percent when an antibiotic was given. They were not able to determine which antibiotic(s) or

which strategy (treat-all versus screen-and-treat) was optimal. The American College of Obstetricians and Gynecologists (2016) suggests a treat-all regimen of doxycycline, 100 mg orally before the procedure and 200 mg postabortion. An alternative is metronidazole, 500 mg orally twice daily for 5 days. In cases of complete spontaneous abortion, antibiotics are unnecessary. However, women with incomplete abortions requiring curettage should receive prophylaxis.

■ Septic Abortion

An abortion associated with infection and complicated by fever, metritis, and parametritis is considered a septic abortion (Stubblefield, 1994). Although such serious infections may complicate legal abortion, the term has become almost synonymous with clandestine procedures. Clearly, the legalization of abortion in this country has nearly eliminated deaths from illegal abortion (Jewett, 1973). Indeed, abortion wards containing 20 to 30 infected women, many at risk for death, have become only a distant memory.

Patient delays in seeking treatment and delayed recognition by the medical system are the largest contributing factors to maternal mortality in cases of septic abortion. As pelvic infection spreads, it provokes multiple, sometimes irreversible processes. These include pelvic abscess, septic pelvic thrombophlebitis, disseminated intravascular coagulopathy, renal failure, and septic shock (Stubblefield, 1994).

Management of septic abortion begins with a high index of suspicion. Classic pelvic findings are fundal and parametrial tenderness, uterine enlargement, and fever in a woman who likely still has a positive urine or serum β -hCG test result. In cases of septic abortion, retained products of conception must be evacuated once the patient is hemodynamically stable and preferably after she has received at least one dose of parenteral broad-spectrum antibiotics (Table 32-2, p. 507). In the first trimester, suction D & C is appropriate. In the second trimester, either D & E or medical induction methods may be used. Appropriate cultures can be obtained from cervical specimens, blood, or products of conception. A Gram stain of the cervicovaginal secretions can also be informative. Coverage for suspected clostridial infection is broad spectrum and listed in Table 12-1 (p. 192).

Laparotomy is indicated if bowel injury with peritonitis is a concern. Clostridial myonecrosis may be suspected by Gram stain or by air in the myometrium, parametrium, or under the diaphragm on a radiograph. This is an indication for abdominal hysterectomy and oophorectomy, granted reasonably stable vital signs. In women with an otherwise uncomplicated pelvic abscess, computed tomography (CT)-directed percutaneous aspiration may be attempted. In other cases, exploratory laparotomy and abscess drainage may be necessary. A Clinical Expert Series on this topic was recently published (Eschenbach, 2015).

■ Physiologic and Pharmacologic Complications

Vasovagal symptoms can result from cervical manipulation during paracervical blockade injections, from forced dilatation, or from postoperative hematometra. Bradycardia may lead to hypotension and syncope that will generally abate without

therapy in several minutes. Atropine, 0.5 mg, may be given IV to treat the bradycardia if symptoms persist or recur.

Allergic reactions and drug reactions may complicate any medical encounter. Toxic reactions can follow intravascular injection of local amide anesthetics and are signaled by tinnitus and sensations of taste and odor. These can lead to seizures and cardiovascular collapse and are discussed in Chapter 19. Preventatively, careful aspiration prior to the administration of paracervical blockade and limitation of total doses to less than 200 mg of lidocaine should prevent toxicity (Hakim-Elahi, 1990).

Uterine rupture has been reported in women undergoing midtrimester labor induction. Although the precise incidence is unknown, a retrospective review of 606 women at a single center who received vaginal PGE₁, intraamniotic PGF_{2 α} , oxytocin, or oxytocin plus vaginal PGE₂ revealed an incidence of uterine rupture of 0.6 percent (Chapman, 1996). As expected, the rate was significantly higher in women with a prior cesarean delivery—3.8 percent versus 0.2 percent. In three cases, the uterine rupture was repaired. However, the fourth required hysterectomy. Other risk factors identified included gestational age >21 weeks and prolonged induction. Women who do not deliver after 24 hours of uterotonic agents should be evaluated with sonography and clinical examination, particularly if they have had prior uterine surgery. With rupture, a sonogram may confirm an extrauterine fetus and an involuting uterus. In contrast, the safety of D & E in patients with a scarred uterus is comparable to those with no prior surgery (Schneider, 1994).

Following to the reports of uterine rupture in women with prior cesarean delivery undergoing third-trimester misoprostol labor induction, many clinicians became reluctant to use PGE₁ for midtrimester medical abortion in women with prior cesarean delivery. From a systematic review of 16 studies of midtrimester misoprostol abortion, Goyal (2009) reported an absolute uterine rupture rate of 0.28 percent in women with prior cesarean delivery versus 0.04 percent in those with an unscarred uterus. An important source of variance was the uncontrolled use of cervical preparation and misoprostol dosing. That said, qualitative assessment of these regimens suggested that vaginal or oral misoprostol, 400 μ g every 6 hours, was the most commonly prescribed dosage. Essentially all midtrimester labor induction agents have been associated with uterine rupture in both scarred and unscarred uteri. Although a cesarean scar significantly increases the *relative* risk, the absolute risk is still low and must be weighed against a D & E or hysterotomy. When D & E provision is unavailable, accepting the small risk is clearly preferable to routine hysterotomy.

Retained placenta—“incomplete abortion”—is a complication of midtrimester labor inductions, and 3 to 15 percent of cases require curettage. Although the optimal duration and management of the third stage has not been determined, our practice is to allow up to 3 hours for spontaneous placental delivery with concurrent administration of cycle 1 of concentrated oxytocin shown in Table 9-5. If the placenta does not spontaneously deliver, we attempt manual removal. If this is unsuccessful or if hemorrhage complicates the extended third stage, then curettage is indicated (Owen, 1996). Routine curettage is unnecessary and associated with a significant increase in the incidence of postoperative intrauterine adhesions (Lurie, 1991).

The overall incidence of thromboembolism, air embolism, and amniotic fluid embolism associated with abortion is unknown but very small. Nevertheless, pulmonary embolism with air, amniotic fluid, or thrombosis accounted for 21 percent of abortion-related maternal deaths between 1972 and 1975 (Lawson, 1990).

Anomalous fetuses have occurred in women who have a continuing pregnancy following a failed first-trimester medical abortion using misoprostol. Although the absolute risk appears to be relatively low—10 percent or less (Schüler, 1999; Sitruk-Ware, 1998; Vauzelle, 2013), several patterns of fetal anomalies have been reported, including Möbius syndrome, which is congenital facial paralysis, frontal/temporal skull defects, and limb deficiencies (Fonseca, 1991; Gonzalez, 1993; Pastuszak, 1991). Other reported associations include ventral wall defects, arthrogryposis, and Poland syndrome. Methotrexate is a folate antagonist associated with a well-recognized profound embryopathy that includes intrauterine growth restriction and cardiac, craniofacial, and skeletal abnormalities (Nurmohamed, 2011). Arthrogryposis, a condition of multiple, congenital joint contractures, may follow a failed D & C procedure and is presumed secondary to vascular compromise or chronic amniotic fluid leakage (Hall, 1996).

Live birth is an undesirable and tragic consequence of medical pregnancy terminations in the second trimester with ethical, medical, and legal implications. Although hypertonic saline or urea instillation procedures are almost always fetocidal and live birth rates are less than 2 per 1000 procedure, these methods have largely been replaced (Grimes, 1979). Prostaglandins and oxytocin stimulate labor, do not directly cause intrapartum demise, and are associated with chances for a live birth with advancing gestations. Vaginal prostaglandins have been associated with live birth rates from 4 to 50 percent (Owen, 1996, 1999). Use of concentrated oxytocin appears to be associated with lower live birth rates than vaginal PGE₁. However, this has not been adequately tested in a prospective clinical trial. Because of concern among patients, physicians, and hospitals regarding the consequences of live birth in this clinical setting, intracardiac injection of potassium chloride or intraamniotic/intracardiac digoxin prior to labor induction may be considered (American College of Obstetricians and Gynecologists, 2015). This technique requires special skills, may have maternal side effects, is illegal in some states, and is considered unacceptable by some patients. It is not recommended as an adjunct to D & E, and only limited data support that it speeds midtrimester medical abortion time (Borgatta, 2011; Diedrich, 2010; Jackson, 2001).

Ideally each institution should establish a protocol for the management of live birth. The protocol must be written by members from both the obstetric and neonatal teams and reviewed by legal staff to ensure compliance with state and federal laws. Patients should be apprised of the risks and consequences of live birth and should accept the protocol in advance. The protocol may address medical and ethical concerns based on estimated gestational age and fetal weight, birth weight, and the severity of fetal anomalies. Hospice care for a predetermined maximum interval—for example, 1 hour—may be recommended as an alternative to immediate resuscitation and critical care.

LONG-TERM ABORTION RISKS

Because induced abortion is such a common procedure, its potential effects on women's health and reproductive potential have been widely investigated. Increases in the risk of long-term morbidity could have significant public health implications. Conversely, misconceptions regarding long-term abortion risks may unnecessarily increase a patient's anxiety and belie the principles of informed consent. Most investigators have, for pragmatic and ethical reasons, used retrospective case-control or cohort study designs. These study designs suffer from several methodologic limitations that include choice of biologically appropriate comparison groups and failure to include possible confounding factors, especially preexisting conditions or number of previous abortions (Hill, 1965; Hogue, 1982; Steinberg, 2012). Importantly, an association does not prove a cause-effect relationship, and small relative risks such as 2 to 3 or odds ratios such as 3 to 4, even if statistically significant due to large sample sizes, lack credibility and are likely to be explained by unmeasured or omitted confounders (Grimes, 2012).

Table 9-6 summarizes published relationships between induced abortion and later adverse events. Note that most available data reflect the risks associated with one prior first-trimester curettage or medical abortion, and the risks from this are negligible. However, the effects of multiple induced abortions or of second-trimester D & E or labor induction have not been as thoroughly investigated but may increase some risks.

The most consistently identified association is between induced abortion and an increased likelihood of preterm birth in a subsequent pregnancy. The risk is primarily for spontaneous and not for indicated preterm birth. Although this association has not been confirmed by all investigators, several more recent reports have confirmed earlier findings of a clear dose-response effect. Plausible postulates to explain this association include cervical injury from (repeated) forced dilation, which may cause cervical lacerations or simply weaken tissue integrity. Epidemiologic data support controlled cervical ripening and dilatation with osmotic dilators prior to second-trimester curettage procedures (Grimes, 1984; Stubblefield, 1984).

Of particular note are studies that assess possible mental health effects of induced abortion. These reports have generally considered axes of mood, anxiety, impulse control, substance abuse, eating disorders, and suicidal ideation (Steinberg, 2014). Some investigators have reported an association between abortion and subsequent mental health problems, especially substance use and anxiety. A metaanalysis by Coleman and associates (2011) suggested a significant effect of induced abortion on mental health. However, Steinberg and associates (2012) judged their conclusion to be invalid because of methodologic errors. Clearly, some women do experience feelings of regret, sadness, or guilt. Women at risk for these feelings include those whose pregnancies were wanted, who lack social support, or who have conflicted feelings about their decision. Ideally, these risk factors can be identified in counseling and effectively addressed to diminish the effect of negative emotions.

TABLE 9-6. Effects of Legal Abortion on Subsequent Pregnancy Outcomes and Maternal Health

Maternal Health Concern	Effect	References
Secondary infertility	No increased risk	Atlas, 1998; Atrash, 1990 ^a ; Hogue, 1982 ^a ; Stubblefield, 1984
Spontaneous abortion	D & C: no increased risk D & E: may increase risk Multiple abortions: may increase risk Medical safer than D & C	Atrash, 1990 ^a ; Parrazzini, 1998 Hogue, 1982 ^a Infante-Rivard, 1996 Gan, 2008 ^a
Preterm birth/low birthweight	First trimester: no increased risk First trimester: medical versus D & C risks similar D & E: may increase risk Dose-response: risk proportional to number Increased risk with 1, 2, or 3 abortions	Chen, 2004; Hogue, 1982 ^a ; Lao, 1998; Raatikainen, 2006 Virk, 2007 Atrash, 1990 ^a Ancel, 2004; Klemetti, 2012; Linn, 1983; Thom, 1992 Zhou, 1999
Ectopic pregnancy	Multiple induced abortions: may increase risk No increased risk	Atrash, 1990 ^a ; Skjeldestad, 1997; Tharaux-Deneuve, 1998 Atrash, 1997; Holt, 1989
Intrapartum infection	No increased risk Some increased risk	Muhlemann, 1996 Krohn, 1998
Placenta previa	No increased risk ≥3 induced abortions: may increase risk Slightly increased risk	Atrash, 1990 ^a ; Hogue, 1982 ^a Thom, 1992 Taylor, 1993
Cervical insufficiency	No reliable data	
Breast cancer	No increased risk	Bartholomew, 1998 ^a ; Beral, 2004; Harris, 1989; Ilic, 2013; Melbye, 1997; Michels, 1996; Palmer, 1997; Reeves, 2006
	Some increased risk	Brind, 1996; Daling, 1996; Newcomb, 1996
Ovarian cancer	Multiple induced abortions are protective No increased risk	Negri, 1991, 1992 Chen, 1996
Mental health risks	Conflicting data ^b	Adler, 1992; Bellieni, 2013 ^a ; Boonstra, 2006; Coleman, 2011 ^a ; Cogle, 2005; Fergusson, 2013 ^a ; Munk-Olsen, 2011; Steinberg, 2011, 2014
Congenital malformations	No increased risk	Hogue, 1982 ^a ; Lu, 2011

^aReview article.^bSee text for more details.

REFERENCES

- Acharya G, Morgan H, Paramanatham L, et al: A randomized controlled trial comparing surgical termination of pregnancy with and without continuous ultrasound guidance. *Eur J Obstet Gynecol Reprod Biol* 114:69, 2004
- Achilles SL, Reeves MF, Society of Family Planning: Prevention of infection after induced abortion. *Contraception* 83:295, 2011
- Adler N, David H, Major B, et al: Psychosocial factors in abortion: a review. *Am Psychol* 47:1194, 1992
- American College of Obstetricians and Gynecologists: Abortion training and education. Committee Opinion No. 612, November 2014a
- American College of Obstetricians and Gynecologists: Antibiotic prophylaxis for gynecologic procedures. Practice Bulletin No. 104, May 2009, Reaffirmed 2016
- American College of Obstetricians and Gynecologists: Increasing access to abortion. Committee Opinion No. 613, November 2014c
- American College of Obstetricians and Gynecologists: Informed consent. Committee Opinion No. 439, August 2009, Reaffirmed 2012
- American College of Obstetricians and Gynecologists: Policy on abortion. Intact D & X statement, January 1997. Available at: <http://www.physiciansforreproductiverights.org/wp-content/uploads/2013/03/ACOG-abortion-policy.pdf>. Accessed September 1, 2015
- American College of Obstetricians and Gynecologists: Policy on abortion. Revised and approved, November 2014d. Available at: <http://www.acog.org/-/media/Statements-of-Policy/Public/sop069.pdf?dmc=1&ts=20150901T1354327415>. Accessed September 1, 2015
- American College of Obstetricians and Gynecologists: Second-trimester abortion. Practice Bulletin No. 135, June 2013, Reaffirmed 2015
- American Society of Anesthesiologists Task Force on Sedation and Analgesia by Non-Anesthesiologists: Practice guidelines for sedation and analgesia by non-anesthesiologists. *Anesthesiology* 96:1004, 2002
- Ancel PY, Lelong N, Papiernik E, et al: History of induced abortion as a risk factor for preterm birth in European countries: results of the EUROPOP survey. *Hum Reprod* 19:734, 2004
- Ashok PW, Templeton A, Wagaarachchi PT, et al: Midtrimester medical termination of pregnancy: a review of 1002 consecutive cases. *Contraception* 69:51, 2004
- Atlas RO, Lemus J, Reed J, et al: Second trimester abortion using prostaglandin E₂ suppositories with or without intracervical laminaria japonica: a randomized study. *Obstet Gynecol* 92:398, 1998

- Atrash HK, Hogue CJ: The effect of pregnancy termination on future reproduction. *Baillieres Clin Obstet Gynaecol* 4:391, 1990
- Atrash HK, Strauss LR, Kendrick JS, et al: The relation between induced abortion and ectopic pregnancy. *Obstet Gynecol* 89:512, 1997
- Bartholomew LL, Grimes DA: The alleged association between induced abortion and risk of breast cancer: biology or bias? *Obstet Gynecol Survey* 53:708, 1998
- Bartlett LA, Berg CJ, Shulman HB, et al: Risk factors for legal induced abortion-related mortality in the United States. *Obstet Gynecol* 103:729, 2004
- Belliemi CV, Buonocore G: Abortion and subsequent mental health: review of the literature. *Psychiatry Clin Neurosci* 67:301, 2013
- Beral V, Bull D, Doll R, et al: Breast cancer and abortion: collaborative reanalysis of data from 53 epidemiological studies, including 83,000 women with breast cancer from 16 countries. *Lancet* 363:1007, 2004
- Berger GS, Edelman DA, Kerenyi TD: Oxytocin administration, instillation-to-abortion time, and morbidity associated with saline instillation. *Am J Obstet Gynecol* 121:941, 1975
- Bhathena RK, Sheriar NK, Walvekar VR, et al: Second-trimester pregnancy termination using extra-amniotic ethacridine lactate. *BJOG* 97:1026, 1990
- Binkin NJ, Lang PR, Rhodenhiser EP, et al: Abortion surveillance, 1981. *MMWR CDC Surveill Summ* 33(3):1SS, 1984
- Blum M: Experience with the induction of second-trimester abortion by extra-amniotic physiological saline infusion. Report of 127 cases. *Eur J Obstet Gynecol Reprod Biol* 10:183, 1980
- Blumenthal PD: Prospective comparison of Dilapan and laminaria for pretreatment of the cervix in second-trimester induction abortion. *Obstet Gynecol* 72:243, 1988
- Boonstra HD, Gold RB, Richards CL: Abortion and women's health: a turning point for America. New York, Guttmacher Institute, 2006
- Borgatta L, Kapp N, Society of Family Planning: Clinical guidelines. Labor induction abortion in the second trimester. *Contraception* 84:4, 2011
- Borgida AF, Rodis JF, Hanlon W, et al: Second-trimester abortion by intramuscular 15-methyl-prostaglandin F₂α or intravaginal prostaglandin E₂ suppositories: a randomized trial. *Obstet Gynecol* 85:697, 1995
- Brind J, Chinchilli VM, Severs WB, et al: Induced abortion as an independent risk factor for breast cancer: a comprehensive review and meta-analysis. *J Epidemiol Community Health* 50:481, 1996
- Burkman RT, Atienza MF, King TM: Culture and treatment results in endometritis following elective abortion. *Am J Obstet Gynecol* 197:128:556, 1977
- Burkman RT, Tonascia JA, Atienza MF, et al: Untreated endocervical gonorrhea and endometritis following elective abortion. *Am J Obstet Gynecol* 126:648, 1976
- Bygdeman M: Termination of second trimester pregnancy with laminaria and intramuscular 15-methyl PGF₂α or 16-phenoxy-omega-17,18,10,20-tetranor PGE₂ methylsulfonylamide. A randomized multicenter study. *Int J Gynecol Obstet* 26:129, 1988
- Cameron IT, Michie AF, Baird DT: Prostaglandin-induced pregnancy termination: further studies of gemeprost (16,16-dimethyl-trans-Delta 2PGE₁ methylester) vaginal pessaries in the early second trimester. *Prostaglandins* 34:111, 1987
- Cates W Jr, Rochat RW: Illegal abortions in the United States: 1972-1974. *Fam Plann Perspect* 8:86, 1976
- Centers for Disease Control and Prevention: Sexually transmitted diseases treatment guidelines, 2015. *MMWR* 64(3):1, 2015
- Cetin A, Cetin M: Effect of deep injections of local anesthetics and basal dilatation of cervix in management of pain during legal abortions. *Contraception* 56:85, 1997
- Chambers DG, Willcourt RJ, Laver AR, et al: Comparison of Dilapan-S and laminaria for cervical priming before surgical pregnancy termination at 17-22 weeks' gestation. *Int J Womens Health* 3:347, 2011
- Chapman SH, Crispens M, Owen J, et al: Complications of midtrimester pregnancy termination: the effect of prior cesarean delivery. *Am J Obstet Gynecol* 175:889, 1996
- Chen A, Yuan W, Meirik O, et al: Mifepristone-induced early abortion and outcome of subsequent wanted pregnancy. *Am J Epidemiol* 160:110, 2004
- Chen M, Cook LS, Daling JR, et al: Incomplete pregnancies and risk of ovarian cancer (Washington, United States). *Cancer Causes Control* 7:415, 1996
- Christensen NJ, Bygdeman M, Green K: Comparison of different prostaglandin analogues and laminaria for preoperative dilatation of the cervix in late first trimester abortion. *Contraception* 27:51, 1983
- Cohn N, Stewart P: Pretreatment of the primigravid uterine cervix with mifepristone 30 hours prior to termination of pregnancy: a double-blind study. *BJOG* 98:778, 1991
- Coleman PK: Abortion and mental health: quantitative synthesis and analysis of research published 1995-2009. *Br J Psychiatry* 199:180, 2011
- Cogle JR, Reardon DC, Coleman PK: Generalized anxiety following unintended pregnancies resolved through childbirth and abortion: a cohort study of the 1995 National Survey of Family Growth. *J Anxiety Disord* 19:137, 2005
- Crenin MD, Vittinghoff E, Galbraith S, et al: A randomized trial comparing misoprostol three and seven days after methotrexate for early abortion. *Am J Obstet Gynecol* 173:1784, 1995
- Daling JR, Brinton LA, Voigt LF, et al: Risk of breast cancer among white women following induced abortion. *Am J Obstet Epidemiol* 144:373, 1996
- Darney PD, Dorward K: Cervical dilation before first-trimester elective abortion: a controlled comparison of metenprost, laminaria, and hypan. *Obstet Gynecol* 70:397, 1987a
- Darney PD, Landy U, Macpherson S, et al: Abortion training in U.S. obstetrics and gynecology residency programs. *Fam Plann Perspect* 19:4, 1987b
- Darney PD, Sweet RL: Routine intraoperative ultrasonography for second trimester abortion reduces incidence of uterine perforation. *J Ultrasound Med* 8:71, 1989
- Dickinson JE, Godfrey M, Evans SF: Efficacy of intravaginal misoprostol in second-trimester pregnancy termination: a randomized controlled trial. *J Matern-Fetal Med* 7:115, 1998
- Diedrich J, Drey E, Society of Family Planning: Induction of fetal demise before abortion. *Contraception* 81:462, 2010
- Diedrich J, Steinauer J: Complications of surgical abortion. *Clin Obstet Gynecol* 52:205, 2009
- Eastwood KL, Kacmar JE, Steinauer J: Abortion training in the United States obstetrics and gynecology residency programs. *Obstet Gynecol* 108:303, 2006
- Edwards J, Carson SA: New technologies permit safe abortion at less than six weeks' gestation and provide timely detection of ectopic gestation. *Am J Obstet Gynecol* 176:1101, 1997
- El-Refacy, Templeton A: Induction of abortion in the second trimester by a combination of misoprostol and mifepristone: a randomized comparison between two misoprostol regimens. *Hum Reprod* 10:475, 1995
- Epner JE, Jonas HS, Seckinger DL: Late-term abortion. *JAMA* 280:724, 1998
- Eschenbach DA: Treating spontaneous and induced septic abortions. *Obstet Gynecol* 125:1042, 2015
- Fahmy K: Prophylaxis against prostaglandin-induced gastrointestinal side effects. *Int J Gynaecol Obstet* 19:487, 1981
- Ferguson JE, Burkett BJ, Pinkerton JV, et al: Intra-amniotic 15(2)-methyl prostaglandin F_{2α} and termination of middle and late second-trimester pregnancy for genetic indications: a contemporary approach. *Am J Obstet Gynecol* 169:332, 1993
- Fergusson DM, Horwood LJ, Boden JM: Does abortion reduce the mental health risks of unwanted or unintended pregnancy? A re-appraisal of the evidence. *Aust N Z J Psychiatry* 47:819, 2013
- Finer LB, Zolna MR: Shifts in intended and unintended pregnancies in the United States, 2001-2008. *Am J Public Health* 104:S43, 2014
- Fonseca W: Misoprostol and congenital malformations. *Lancet* 338:56, 1991
- Gan C, Zou Y, Wu S, et al: The influence of medical abortion compared with surgical abortion on subsequent pregnancy outcome. *Int J Gynaecol Obstet* 101:231, 2008
- Gardo S, Nagy M: Induction of second trimester abortion by intra-amniotic instillation of Rivanol (ethacridine) combined with oxytocin infusion. *Arch Gynecol Obstet* 247:39, 1990
- Gold RB, Sonfield A, Richards CL, et al: Next steps for America's family planning program: leveraging the potential of Medicaid and Title X in an evolving health care system. New York, Guttmacher Institute, 2009
- Gonzalez CH, Vargas FR, Perez AB, et al: Limb deficiency with or without Möbius sequence in seven Brazilian children associated with misoprostol use in the first trimester of pregnancy. *Am J Med Genet* 47:59, 1993
- Goyal V: Uterine rupture in second-trimester misoprostol-induced abortion after cesarean delivery. *Obstet Gynecol* 113:1117, 2009
- Grimes DA: Clinicians who provide abortions: the thinning ranks. *Obstet Gynecol* 80:719, 1992
- Grimes DA, Cates W: Complications from legally induced abortion: a review. *Obstet Gynecol Survey* 34:177, 1979
- Grimes DA, Hulka JF, McCutchen ME: Midtrimester abortion by dilatation and evacuation versus intra-amniotic instillation of prostaglandin F_{2α}: a randomized clinical trial. *Am J Obstet Gynecol* 137:785, 1980
- Grimes DA, Schultz KF: False alarms in pseudo-epidemics, the limitations of observational epidemiology. *Obstet Gynecol* 120:920, 2012
- Grimes DA, Schulz KF, Cates W Jr: Prevention of perforation during curettage abortion. *JAMA* 251:2108, 1984
- Grimes DA, Smith SM, Witham AD: Mifepristone and misoprostol versus dilation and evacuation for midtrimester abortion: a pilot randomised controlled trial. *BJOG* 111:148, 2004
- Guiahi M, Davis A, Society of Family Planning: First-trimester abortion in women with medical conditions. *Contraception* 86:622, 2012
- Gupta S: Early non-surgical abortion—give women the choice. *Hum Reprod* 13:2379, 1998
- Hakim-Elahi E, Tovell HM, Burnhill MS: Complications of first-trimester abortion: a report of 170,000 cases. *Obstet Gynecol* 76:129, 1990

- Hall JG: Arthrogyposis associated with unsuccessful attempts at termination of pregnancy. *Am J Med Genet* 63:293, 1996
- Harris BM, Eklund G, Meirik O, et al: Risk of cancer of the breast after legal abortion during first trimester: a Swedish register study. *BMJ* 299:1430, 1989
- Henshaw S: Abortion incidence and services in the United States, 1995-1996. *Fam Plann Perspect* 30:263, 1998
- Herabutya Y, Prasertsawat PO: Second trimester abortion using intravaginal misoprostol. *Intl J Gynecol Obstet* 60:161, 1998
- Hern WM: Laminaria versus Dilapan osmotic cervical dilators for outpatient dilation and evacuation abortion: randomized cohort comparison of 1001 patients. *Am J Obstet Gynecol* 171:1324, 1994
- Hill AB: The environment and disease: association or causation? *Proc R Soc Med* 58:295, 1965
- Ho PC, Ngai SW, Liu KL, et al: Vaginal misoprostol compared with oral misoprostol in termination of second-trimester pregnancy. *Obstet Gynecol* 90:7335, 1997
- Ho PC, Tsant SS, Ma HK: Reducing the induction to abortion interval in termination of second trimester pregnancies: a comparison of mifepristone with laminaria tent. *BJOG* 102:648, 1995
- Hoffman BL, Corton MM: Surgeries for benign gynecologic conditions. In Hoffman BL, Schorge JI, Bradshaw KD, et al: *Williams Gynecology*, 3rd ed. New York, McGraw-Hill Education, 2016
- Hogg B, Owen J: Laminaria versus extraamniotic saline infusion (EASI) for cervical ripening and mid-trimester labor induction. *Am J Obstet Gynecol* 184:1145, 2001
- Hogue CJR, Cates W Jr, Tietze C: The effects of induced abortion on subsequent reproduction. *Epidemiol Rev* 4:66, 1982
- Holt VL, Daling JR, Voigt LF, et al: Induced abortion and the risk of subsequent ectopic pregnancy. *Am J Public Health* 79:1234, 1989
- Ilic M, Vlainjac H, Marinkovic J, et al: Abortion and breast cancer: case-control study. *Tumori* 99:452, 2013
- Infante-Rivard C, Gauthier R: Induced abortion as a risk factor for subsequent fetal loss. *Epidemiology* 7:540, 1996
- Jackson RA, Teplin VL, Drey EA, et al: Digoxin to facilitate late second-trimester abortion: a randomized, masked, placebo-controlled trial. *Obstet Gynecol* 97:471, 2001
- Jannet D, Afak N, Abankwa A, et al: Termination of 2nd and 3rd trimester pregnancies with mifepristone and misoprostol. *Eur J Obstet Gynecol Reprod Biology* 70:159, 1996
- Jewett JF: Septic induced abortion. *N Engl J Med* 289:748, 1973
- Jones RK, Jerman J: Abortion incidence and service availability in the United States, 2011. *Perspect Sex Reprod Health* 46:3, 2014
- Jones RK, Kavanaugh ML: Changes in abortion rates between 2000 and 2008 and lifetime incidence of abortion. *Obstet Gynecol* 117:1358, 2011a
- Jones RK, Kooistra K: Abortion incidence and access to services in the United States, 2008. *Perspect Sex Reprod Health* 43:41, 2011b
- Jones RK, Kost K, Singh S, et al: Trends in abortion in the United States. *Clin Obstet Gynecol* 52:119, 2009
- Kaali SG, Szigetvari IA, Bartfai GS: The frequency and management of uterine perforations during first-trimester abortions. *Am J Obstet Gynecol* 161:406, 1989
- Kapp N, Lohr PA, Ngo TD, et al: Cervical preparation for first trimester surgical abortion. *Cochrane Database Syst Rev* 2:CD007207, 2010
- Kassirer JP: Practicing medicine without a license—the new intrusions by Congress. *N Engl J Med* 336:1747, 1997
- Keirse MJ, Thiery M, Parewijck W, et al: Chronic stimulation of uterine prostaglandin synthesis during cervical ripening before the onset of labor. *Prostaglandins* 25:671, 1983
- Kelly T, Suddes J, Howel D, et al: Comparing medical versus surgical termination of pregnancy at 12-20 weeks of gestation: a randomized controlled trial. *BJOG* 117:1512, 2010
- Kerenyi TD, Mandelman N, Sherman DH: Five thousand consecutive saline inductions. *Am J Obstet Gynecol* 116:593, 1973
- Killick SR, Williams CA, Elstein M: A comparison of prostaglandin E₂ pessaries and laminaria tents for ripening the cervix before termination of pregnancy. *BJOG* 92:518, 1985
- Klemetti R, Gissler M, Niinimäki M, et al: Birth outcomes after induced abortion: a nationwide register-based study of first births in Finland. *Hum Reprod* 27:3315, 2012
- Koonin LM, Strauss LT, Chrisman CE, et al: Abortion surveillance—United States, 1996. *MMWR* 48:1, 1999
- Krohn MA, Germain M, Muhlemann K, et al: Prior pregnancy outcome and the risk of intra-amniotic infection in the following pregnancy. *Am J Obstet Gynecol* 178:381, 1998
- Kulier R, Kapp N: Comprehensive analysis of the use of pre-procedure ultrasound for first- and second-trimester abortion. *Contraception* 83:30, 2011a
- Kulier R, Kapp N, Gülmezoglu AM, et al: Medical methods for first trimester abortion. *Cochrane Database Syst Rev* 11:CD002855, 2011b
- Lalitkumar S, Bygdeman M, Gemzell-Danielsson K: Mid-trimester induced abortion: a review. *Hum Reprod Update* 13:37, 2007
- Lao T, Ho LF: Induced abortion is not a cause of subsequent preterm delivery in teenage pregnancies. *Hum Reprod* 13:7588, 1998
- Lauersen NH, Den T, Iliescu C, et al: Cervical priming prior to dilatation and evacuation: a comparison of methods. *Am J Obstet Gynecol* 144:890, 1982
- Lauersen NH, Secher NJ, Wilson KH: Mid-trimester abortion induced by intravaginal administration of prostaglandin E₂ suppositories. *Am J Obstet Gynecol* 122:947, 1975
- Lawrie A, Penney G, Templeton A: A randomized comparison of oral and vaginal misoprostol for cervical priming before suction termination of pregnancy. *BJOG* 103:1117, 1996
- Lawson HW, Atrash JK, Franks AL: Fatal pulmonary embolism during legal induced abortion in the United States from 1972 to 1985. *Am J Obstet Gynecol* 162:986, 1990
- Lefebvre Y, Proulx LO, Elie R, et al: The effects of RU-38486 on cervical ripening. *Am J Obstet Gynecol* 162:61, 1990
- Levallois P, Rioux JE: Prophylactic antibiotics for suction curettage abortion: results of a clinical controlled trial. *Am J Obstet Gynecol* 158:100, 1988
- Linn S, Schoenbaum SC, Monson RR, et al: The relationship between induced abortion and outcome of subsequent pregnancies. *Am J Obstet Gynecol* 146:136, 1983
- Lohr PA, Hayes JL, Gemzell-Danielsson K: Surgical versus medical methods for second trimester induced abortion. *Cochrane Database Syst Rev* 1:CD006714, 2008
- Low N, Mueller M, Van Vliet HA, et al: Perioperative antibiotics to prevent infection after first-trimester abortion. *Cochrane Database Syst Rev* 3:CD005217, 2012
- Lu QB, Wang ZP, Gao LJ, et al: Previous abortion and the risk of neural tube defects: a case-control study. *J Reprod Med* 56:431, 2011
- Lurie S, Appelman Z, Katz Z: Curettage after midtrimester termination of pregnancy: is it necessary? *J Reprod Med* 36:786, 1991
- Manabe Y, Okazaki T, Takahashi A: Prostaglandins E and F in amniotic fluid during stretch-induced cervical softening and labor at term. *Gynecol Obstet Invest* 15:343, 1983
- Meirik O, My Huong NT, Piaggio G, et al: Complications of first-trimester abortion by vacuum aspiration after cervical preparation with and without misoprostol: a multicentre randomised trial. *Lancet* 379:1817, 2012
- Melbye M, Wohlfahrt J, Olsen JH, et al: Induced abortion and the risk of breast cancer. *N Engl J Med* 336:81, 1997
- Michels KB, Willett WC: Does induced or spontaneous abortion affect the risk of breast cancer? *Epidemiology* 7:521, 1996
- Mital S, Sehgal R, Aggarwal S, et al: Cervical priming with misoprostol before manual vacuum aspiration versus electric vacuum aspiration for first-trimester surgical abortion. *Int J Gynaecol Obstet* 112:34, 2011
- Moller BR, Ahrons S, Laurin J, et al: Pelvic infection after elective abortion associated with *Chlamydia trachomatis*. *Obstet Gynecol* 59:210, 1982
- Muhlemann K, Germain M, Krohn M: Does an abortion increase the risk of intrapartum infection in the following pregnancy? *Epidemiology* 7:194, 1996
- Munk-Olsen T, Laursen TM, Pedersen CB, et al: Induced first-trimester abortion and risk of mental disorder. *N Engl J Med* 364:332, 2011
- Negri E, Franceschi S, La Vecchia C, et al: Incomplete pregnancies and ovarian cancer risk. *Gynecol Oncol* 47:234, 1992
- Negri E, Franceschi S, Tzonou A, et al: Pooled analysis of 3 European case-control studies: I. Reproductive factors and risk of epithelial ovarian cancer. *Int J Cancer* 49:50, 1991
- Newcomb PA, Storer BE, Longnecker MP, et al: Pregnancy termination in relation to risk of breast cancer. *JAMA* 275:283, 1996
- Nurmohamed L, Moretti ME, Schechter T, et al: Outcome following high-dose methotrexate in pregnancies misdiagnosed as ectopic. *Am J Obstet Gynecol* 205(6):533.e1, 2011
- O'Connell K, Jones HE, Simon M, et al: First-trimester surgical abortion practices: a survey of National Abortion Federation members. *Contraception* 79:385, 2009
- Owen J, Hautz JC: Concentrated oxytocin plus low-dose prostaglandin E₂ compared with prostaglandin E₂ vaginal suppositories for second-trimester pregnancy termination. *Obstet Gynecol* 88:110, 1996
- Owen J, Hautz JC: Vaginal misoprostol vs. concentrated oxytocin plus low-dose prostaglandin E₂ for second-trimester pregnancy termination. *J Matern-Fetal Med* 8:48, 1999
- Owen J, Hautz JC, Winkler CL, et al: Midtrimester pregnancy termination: a randomized trial of prostaglandin E₂ versus concentrated oxytocin. *Am J Obstet Gynecol* 167:1112, 1992
- Palmer JR, Rosenberg L, Rao RS, et al: Induced and spontaneous abortion in relation to risk of breast cancer (United States). *Cancer Causes Control* 8:841, 1997

- Parrazzini F, Chatenoud L, Tozzi L, et al: Induced abortion in the first trimester of pregnancy and risk of miscarriage. *BJOG* 105:418, 1998
- Pastuszak AL, Schuler L, Speck-Martins CE, et al: Use of misoprostol during pregnancy and Möbius' syndrome in infants. *N Engl J Med* 338:1881, 1998
- Pazol K, Creanga AA, Burley KD, et al: Abortion surveillance—United States, 2011. *MMWR Surveill Summ* 63:1, 2014
- Perry KG, Roberts WE, Martin RW, et al: Comparison of intra-amniotic 15S-15-methyl PGF₂alpha and intravaginal prostaglandin E₂ for second-trimester uterine evacuation. *J Perinatal* 18:24, 1998
- Peterson WF, Berry FN, Grade MR, et al: Second-trimester abortion by dilatation and evacuation: an analysis of 11,747 cases. *Obstet Gynecol* 62:185, 1983
- Phillips DR, Nathanson HG, Milim SJ, et al: The effect of dilute vasopressin solution on the force needed for cervical dilatation: a randomized controlled trial. *Obstet Gynecol* 89:507, 1997
- Raatikainen K, Heiskanen N, Heinonen S: Induced abortion: not an independent risk factor for pregnancy outcome, but a challenge for health counseling. *Ann Epidemiol* 16:587, 2006
- Raju TN, Mercer BM, Burchfield DJ, et al: Perivable birth: executive summary of a joint workshop by the Eunice Kennedy Shriver National Institute of Child Health and Human Development, Society for Maternal-Fetal Medicine, American Academy of Pediatrics, and American College of Obstetricians and Gynecologists. *Obstet Gynecol* 123:1083, 2014
- Rakhshani R, Grimes DA: Prostaglandin E₂ suppositories as a second-trimester abortifacient. *J Reprod Med* 33:817, 1988
- Ramin KD, Ogburn PL Jr, Danilenko-Dixon D, et al: High-dose misoprostol for mid-gestation pregnancy interruption. *Am J Obstet Gynecol* 182:S137, 2000
- Ramsey PS, Ramin KD: Misoprostol, a prostaglandin E₁ analog, for prelabor ripening of the unfavorable uterine cervix. *Fetal Mat Med Rev* 8:217, 1996
- Ramsey PS, Savage K, Lincoln T, et al: Vaginal misoprostol versus concentrated oxytocin and vaginal PGE₂ for second-trimester labor induction. *Obstet Gynecol* 104:138, 2004
- Raymond EG, Grimes DA: The comparative safety of legal induced abortion and childbirth in the United States. *Obstet Gynecol* 119:215, 2012
- Reeves GK, Kan SW, Key T, et al: Breast cancer risk in relation to abortion: results from the EPIC study. *Int J Cancer* 119:1741, 2006
- Rodger MW, Baird DT: Pretreatment with mifepristone (RU486) reduces interval between prostaglandin administration and expulsion in second trimester abortion. *BJOG* 1990; 97:41, 1990
- Rossi B, Creinin MD, Meyn LA: Ability of the clinician and patient to predict the outcome of mifepristone and misoprostol medical abortion. *Contraception* 70:313, 2004
- Sawaya GF, Grady D, Kerlikowske K, et al: Antibiotics at the time of induced abortion: the case for universal prophylaxis based on a meta-analysis. *Obstet Gynecol* 87:884, 1996
- Scheepers HC, van Erp EJ, van Bergh AS: Use of misoprostol in first and second trimester abortion: a review. *Obstet Gynecol Surv* 54:592, 1999
- Schneider D, Bukovsky I, Caspi E: Safety of midtrimester pregnancy termination by laminaria and evacuation in patients with previous cesarean section. *Am J Obstet Gynecol* 171:554, 1994
- Schüler L, Pastuszak A, Sanseverino TV, et al: Pregnancy outcome after exposure to misoprostol in Brazil: a prospective, controlled study. *Reprod Toxicol* 13:147, 1999
- Schulz KF, Grimes DA, Christensen DD: Vasopressin reduces blood loss from second-trimester dilatation and evacuation abortion. *Lancet* 2:353, 1985
- Sedgh G, Henshaw SK, Singh S, et al: Legal abortion worldwide: incidence and recent trends. *Int Fam Plan Perspect* 33:106, 2007
- Sherman DJ, Frenkel E, Tovbin J, et al: Ripening of the unfavorable cervix with extraamniotic catheter balloon: clinical experience and review. *Obstet Gynecol Surv* 51:621, 1996
- Singh K, Fong YF, Prasad RN, et al: Randomized trial to determine optimal dose of vaginal misoprostol for pre-abortion cervical priming. *Obstet Gynecol* 92:795, 1998
- Singh K, Fong YF, Prasad RN, et al: Vaginal misoprostol for pre-abortion cervical priming: is there an optimal evacuation time interval? *BJOG* 106:266, 1999
- Sitruk-Ware R, Davey A, Sakiz E: Fetal malformation and failed medical termination of pregnancy. *Lancet* 352:323, 1998
- Skjeldstad FE, Gargiullo PM, Kendrick JS: Multiple induced abortions as risk factor for ectopic pregnancy. *Acta Obstet Gynecol Scand* 76:691, 1997
- Soderstrom RM: Bowel injury litigation after laparoscopy. *J Am Assoc Gynecol Laparosc* 1:74, 1993
- Spitz IM, Bardin CW, Benton L, et al: Early pregnancy termination with mifepristone and misoprostol in the United States. *N Engl J Med* 338:1241, 1998
- Steinauer JE, Diedrich JT, Wilson MW, et al: Uterine artery embolization in postabortion hemorrhage. *Obstet Gynecol* 111:881, 2008
- Steinberg JR, Finer LB: Examining the association of abortion history and current mental health: a reanalysis of the National Comorbidity Survey using a common-risk-factors model. *Soc Sci Med* 72:72, 2011
- Steinberg JR, McCulloch CE, Adler NE: Abortion and mental health: findings from the National Comorbidity Survey-Replication. *Obstet Gynecol* 123:263, 2014
- Steinberg JR, Trussell J, Hall KS, et al: Fatal flaws in recent meta-analysis on abortion and mental health. *Contraception* 86:430, 2012
- Stubblefield PG, Altman AM, Goldstein SP: Randomized trial of one versus two days of laminaria treatment prior to late midtrimester abortion by uterine evacuation: a pilot study. *Am J Obstet Gynecol* 143:481, 1982
- Stubblefield PG, Grimes DA: Septic abortion. *Curr Concepts* 331:5, 1994
- Stubblefield PG, Monson R, Schoenbaum SC, et al: Fertility after induced abortion: a prospective follow-up study. *Obstet Gynecol* 63:186, 1984
- Stubblefield PG, Naftolin F, Frigoletto F, et al: Laminaria augmentation of intra-amniotic PGF₂alpha for midtrimester pregnancy termination. *Prostaglandins* 10:413, 1975
- Swahn ML, Bygdeman M: The effect of the antiprogesterin RU 486 on uterine contractility and sensitivity to prostaglandin and oxytocin. *BJOG* 95:126, 1988
- Taylor VM, Kramer MD, Vaughan TL, et al: Placenta previa in relation to induced and spontaneous abortion: a population-based study. *Obstet Gynecol* 82:88, 1993
- Tharaux-Deneux C, Bouyer J, Job-Spirai N, et al: Risk of ectopic pregnancy and previous induced abortion. *Am J Public Health* 88:401, 1998
- Thom DH, Nelson LM, Vaughan TL: Spontaneous abortion and subsequent adverse birth outcomes. *Am J Obstet Gynecol* 166:111, 1992
- Thong KJ, Baird DT: A study of gemeprost alone, Dilapan or mifepristone in combination with gemeprost for the termination of second trimester pregnancy. *Contraception* 46:11, 1992
- Torres A, Forrest JD: Why do women have abortions? *Fam Plann Perspect* 20:169, 1988
- UK Multicenter Study Group: Oral mifepristone 600 mg and vaginal gemeprost for mid-trimester induction of abortion. *Contraception* 56:361, 1997
- Vauzelle C, Beghin D, Cournot MP, et al: Birth defects after exposure to misoprostol in the first trimester of pregnancy: prospective follow-up study. *Reprod Toxicol* 36:98, 2013
- Virk J, Zhang J, Olsen J: Medical abortion and the risk of subsequent adverse pregnancy outcomes. *N Engl J Med* 357:648, 2007
- Whalley PJ, Pritchard JA: Oxytocin and water intoxication. *JAMA* 186:601, 1963
- Wheeler RG, Scheider K: Properties and safety of cervical dilators. *Am J Obstet Gynecol* 146:597, 1983
- Wiebe ER: Comparison of the efficacy of different local anesthetics and techniques of local anesthesia in therapeutic abortions. *Am J Obstet Gynecol* 167:131, 1992
- Wiebe ER, Dunn S, Guilbert E, et al: Comparison of abortions induced by methotrexate or mifepristone followed by misoprostol. *Obstet Gynecol* 99:813, 2002
- Wilkinson DJ, Thiele P, Watkins A, et al: Fatally flawed? A review and ethical analysis of lethal congenital malformations. *BJOG* 119:1302, 2012
- Winkler CL, Gray SE, Hauth JC, et al: Mid-second trimester labor induction concentrated oxytocin compared with prostaglandin E₂ vaginal suppositories. *Obstet Gynecol* 77:297, 1991
- World Health Organization (WHO) Task Force on the Use of Prostaglandins for the Regulation of Fertility: Prostaglandins and abortion. *Am J Obstet Gynecol* 129:601, 1977
- Yapar EG, Enoz S, Urkurtur M, et al: Second trimester pregnancy termination including fetal death: comparison of five different methods. *Gynecol Reprod Biol* 69:97, 1996
- Ye BL, Yamamoto K, Tyson JE: Functional and biochemical aspects of laminaria use in first-trimester pregnancy termination. *Am J Obstet Gynecol* 142:36, 1982
- Zhou W, Sorensen HT, Olsen J: Induced abortion and subsequent pregnancy duration. *Obstet Gynecol* 94:948, 1999

Gestational Trophoblastic Disease

EPIDEMIOLOGY AND RISK FACTORS	156
HYDATIDIFORM MOLE (MOLAR PREGNANCY)	157
TREATMENT OF MOLAR PREGNANCY	159
GESTATIONAL TROPHOBLASTIC NEOPLASIA	161
STAGING	163
TREATMENT	165

Gestational trophoblastic disease (GTD) refers to a spectrum of interrelated but histologically distinct tumors originating from the placenta (Table 10-1). These diseases are characterized by a reliable tumor marker, the β -subunit of human chorionic gonadotropin (β -hCG), and have varying tendencies toward local invasion and metastasis.

Gestational trophoblastic neoplasia (GTN) refers to a subset of GTD that develops malignant sequelae. These tumors require formal staging and typically respond very favorably to chemotherapy. GTN develops most commonly after a molar pregnancy, yet it may follow any gestation—including a normal term delivery. The prognosis is excellent with rare exceptions, and patients are routinely cured even in the presence of widespread disease. Moreover, fertility can be preserved in virtually all cases. The likelihood of a successful subsequent pregnancy outcome is equally bright (Vargas, 2014; Williams, 2014; Wong, 2014). Accordingly, although gestational trophoblastic disease is uncommon, it is so intimately related to pregnancy that clinicians practicing obstetrics should be familiar with its presentation, diagnosis, and management.

EPIDEMIOLOGY AND RISK FACTORS

The incidence of gestational trophoblastic disease has remained fairly constant at approximately 1 to 2 per 1000 deliveries

in North America and Europe (Drake, 2006; Loukovaara, 2005; Lybol, 2011). A similar frequency has been observed in South Africa and Turkey (Cakmak, 2014; Moodley, 2003). Although historically higher incidence rates have been reported in parts of Asia, this may have largely reflected discrepancies between population-based and hospital-based data collection (Kim, 2004). Improved socioeconomic conditions and dietary changes may also be partly responsible. That said, Hispanics and Native Americans living in the United States reportedly do have an increased incidence, as do certain population groups living in Southeast Asia (Drake, 2006; Smith, 2003; Tham, 2003). In at least one study, GTN was found to be more aggressive in Asian women (Maesta, 2015).

Of other risk factors, the upper and lower extremes of maternal age have classically been associated with a higher risk of developing GTD (Altman, 2008; Loukovaara, 2005). This association is much greater for complete moles, whereas the risk of partial molar pregnancy varies relatively little with age. Moreover, compared with the risk of those with maternal age of 15 years or younger, the degree of risk is much greater for

TABLE 10-1. Modified WHO Classification of GTD

Molar Pregnancies

Hydatidiform mole

Complete

Partial

Invasive mole

Trophoblastic Tumors

Choriocarcinoma

Placental site trophoblastic tumor

Epithelioid trophoblastic tumor

GTD = gestational trophoblastic disease; WHO = World Health Organization.

Modified from Kurman, 2014.

TABLE 10-2. Features of Hydatidiform Moles

Feature	Complete Mole	Partial Mole
Karyotype	46,XX or 46,XY	69,XXX or 69,XXY
Pathology		
Fetus/embryo	Absent	Present
Villous edema	Diffuse	Focal
Trophoblastic proliferation	Can be marked	Focal and minimal
p57Kip2 immunostaining	Negative	Positive
Clinical presentation		
Typical diagnosis	Molar gestation	Missed abortion
Postmolar malignant sequelae	15%	4–6%

women 45 years (1 percent) or older (17 percent at age 50) (Savage, 2010; Sebire, 2002a). One explanation may relate to ova from older women having higher rates of abnormal fertilization. Similarly, older paternal age has also been associated with elevated risk (La Vecchia, 1984; Parazzini, 1986).

Prior unsuccessful pregnancies also increase the risk of GTD. For example, previous spontaneous abortion at least doubles the risk of molar pregnancy (Parazzini, 1991). More significant, a personal history of GTD increases the risk of developing a molar gestation in a subsequent pregnancy by at least 10-fold. The frequency in a subsequent conception is approximately 1 percent, and most cases mirror the same type of mole (Garrett, 2008; Sebire, 2003). Furthermore, following two episodes of molar pregnancy, 23 percent of later conceptions result in another molar gestation (Berkowitz, 1998). For this reason, women with a prior history of GTD should undergo early first-trimester sonographic examination in subsequent pregnancies. Familial hydatidiform moles, however, are rare (Fallahian, 2003).

Oral contraceptive pill use is weakly associated with an increased risk of GTD in some case-control studies. Although use may roughly double the risk, which is dependent on the duration, the overall impact is slight and could be explained by confounding factors other than causality (Palmer, 1999; Parazzini, 2002). Moreover, women who used oral contraceptive pills during the cycle in which they became pregnant had a higher risk in some but not all studies (Costa, 2006; Palmer, 1999).

Certain other epidemiologic characteristics also appear to differ markedly between complete and partial moles. For example, vitamin A deficiency and low dietary intake of carotene are associated with an increased risk of only complete moles (Berkowitz, 1985, 1995; Parazzini, 1988). Partial moles have been linked to higher educational levels, smoking, irregular menstrual cycles, and obstetric histories in which only male infants are among the prior live births (Berkowitz, 1995; Parazzini, 1986).

HYDATIDIFORM MOLE (MOLAR PREGNANCY)

Hydatidiform moles are categorized as either *complete hydatidiform moles* or *partial hydatidiform moles* (Table 10-2). These are abnormal pregnancies characterized histologically by aberrant changes within the placenta. Classically, the chorionic villi in these placentas show trophoblastic proliferation and edema of the villous stroma. This proliferation leads to the abnormally high β -hCG levels frequently found. Chromosomal abnormali-

ties play an integral role in development of these tumors and also in differentiating between partial and complete types (Lage, 1992).

Complete Hydatidiform Mole

Classically, complete molar pregnancies are distinguished from partial moles by stark differences in their karyotype, histologic appearance, and clinical presentation. First, complete moles typically have a diploid karyotype, and 85 to 90 percent of cases are 46,XX (Fig. 10-1). The chromosomes, however, in these

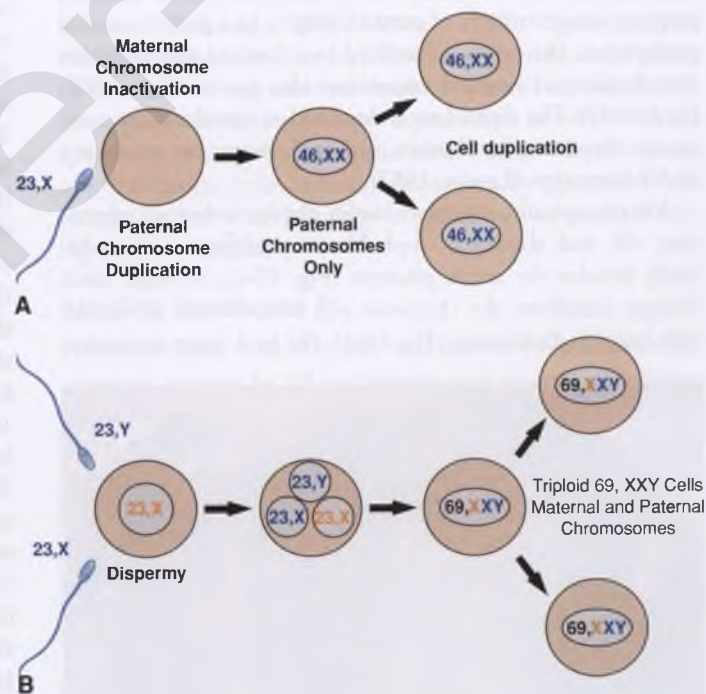


FIGURE 10-1 **A.** A 46,XX complete mole may be formed if a 23,X-bearing haploid sperm penetrates a 23,X-containing haploid egg whose genes have become “inactive.” Paternal chromosomes then duplicate to create a 46,XX diploid chromosomal complement solely of paternal origin. Alternatively, this same type of inactivated egg can be fertilized independently by two sperm, either 23,X- or 23,Y-bearing, to create a 46,XX or 46,XY chromosomal complement, again of paternal origin only. **B.** Partial moles may be formed if two sperm, either 23,X- or 23,Y-bearing, both fertilize a 23,X-containing haploid egg, whose genes have not been inactivated. The resulting fertilized egg is triploid. Alternatively, a similar haploid egg may be fertilized by an unreduced diploid 46,XY sperm. (Reproduced with permission from Schorge JO: Gestational trophoblastic disease. In Hoffman BL, Schorge JO, Bradshaw KD, et al: Williams Gynecology, 3rd ed. New York, McGraw-Hill Education, 2016.)

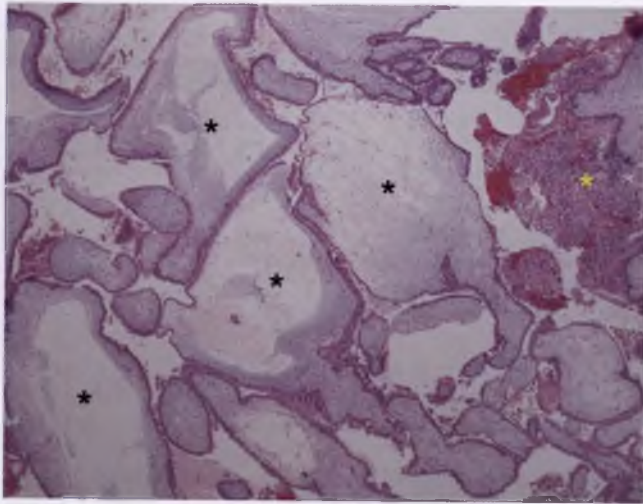


FIGURE 10-2 Complete moles are characterized by diffuse placental villous edema, which produces villous enlargement and cystern formation in some villi (black asterisks). This striking villous enlargement is the etiology of the vesicle-like villous morphology noted grossly in complete moles (see Fig. 10-3). Complete moles also typically show trophoblastic proliferation (yellow asterisk), which may be focal or widespread. This leads to the excessive levels of beta human chorionic gonadotropin (β -hCG) often seen with molar pregnancy. (Used with permission from Dr. Erika Fong.)

pregnancies are entirely of paternal origin. In a process termed *androgenesis*, the ovum is fertilized by a haploid sperm, which then duplicates its own chromosomes after meiosis (Fan, 2002; Kajii, 1977). The diploid set is described as *diandric*. Less commonly, dispermic fertilization of a single ovum can produce a 46,XY karyotype (Lawler, 1987).

Microscopically, complete moles display enlarged, edematous villi and abnormal trophoblastic proliferation that diffusely involve the entire placenta (Fig. 10-2). Grossly, these changes transform the chorionic villi into clusters of vesicles with variable dimensions (Fig. 10-3). No fetal tissue or amnion

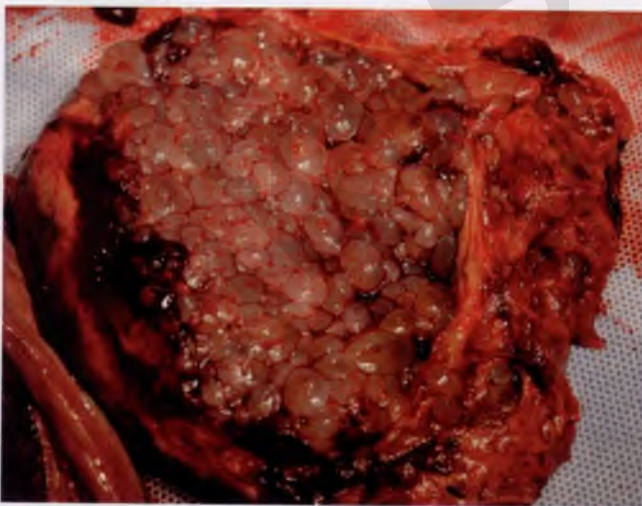


FIGURE 10-3 Complete hydatidiform mole with grapelike fluid-filled clusters formed by swollen chorionic villi. (Used with permission from Dr. Sasha Andrews. Reproduced with permission from Schorge JO: Gestational trophoblastic disease. In Hoffman BL, Schorge JO, Bradshaw KD, et al: Williams Gynecology, 3rd ed. New York, McGraw-Hill Education, 2016.)

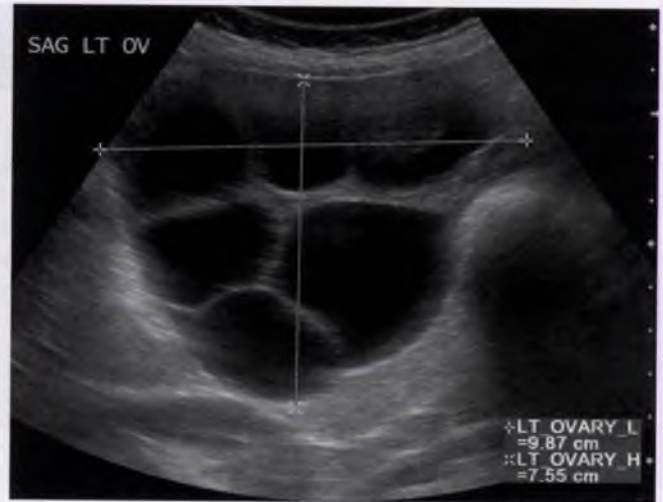

FIGURE 10-4 Transvaginal sonogram of multiple theca-lutein cysts within one ovary of a woman with a complete molar pregnancy. Bilateral, multiple simple cysts are characteristic findings.

is produced. As a result, this mass of placental tissue completely fills the endometrial cavity.

The classic presentation of a complete mole has changed over the past few decades. Previously, common signs were heavy vaginal bleeding, significant anemia, and uterine sizes well in excess of that predicted for their gestational age. Hyperemesis gravidarum and preeclampsia developed in approximately one quarter of women (Montz, 1988; Soto-Wright, 1995). Theca-lutein cysts arise from prolonged exposure to luteinizing hormone (LH) or β -hCG and range in size from 3 to 20 cm (Fig. 10-4). When theca-lutein cysts are present, and especially if bilateral, the risk of postmolar GTN is increased.

Today, many of these signs and symptoms are no longer seen (Mangili, 2008). As a result of β -hCG testing and sonography, the mean gestational age at evacuation of a complete mole currently is earlier and approximates 9 weeks. This compares with 12 weeks in the 1990s, and 16 to 17 weeks in the 1960s and 1970s (Drake, 2006; Soto-Wright, 1995; Sun, 2015). A large proportion of patients are asymptomatic at diagnosis (Joneborg, 2014). For the remainder, vaginal bleeding remains the most common presenting symptom, and β -hCG levels are often much higher than expected. One quarter of women have uterine size noticeably greater than dates, but the incidence of anemia is less than 10 percent. Hyperemesis gravidarum, preeclampsia, and symptomatic theca-lutein cysts are rarely observed (Lazarus, 1999; Mosher, 1998; Soto-Wright, 1995). Currently, these sequelae typically develop chiefly in patients without early prenatal care who present with a more advanced gestational age and markedly elevated serum β -hCG levels. Plasma thyroxine levels are often increased in women with complete moles, but clinical hyperthyroidism is infrequent. In these circumstances, serum free thyroxine levels are elevated as a consequence of the thyrotropin-like effect of β -hCG (Hershman, 2004).

■ Partial Hydatidiform Mole

These moles vary from complete hydatidiform moles by having a triploid karyotype, coexisting fetus, and less-pronounced

clinical features. Partial moles have a triploid karyotype (69,XXX, 69,XXY, or less commonly 69,XYY) that is composed of one maternal and two paternal haploid sets of chromosomes (see Fig. 10-1) (Lawler, 1991). The coexisting fetus present with a partial mole is nonviable and typically has multiple malformations with abnormal growth (Jauniaux, 1999). The degree and extent of trophoblastic proliferation and villous edema is decreased compared with that of complete moles. Moreover, most partial moles contain fetal tissue and amnion, in addition to placental tissues.

Patients with partial moles typically present with signs and symptoms of an incomplete or missed abortion unless sonographic features suggesting placental abnormalities are detected beforehand. Many women will have vaginal bleeding, but because trophoblastic proliferation is slight and only focal, uterine enlargement in excess of gestational age is uncommon. Similarly, preeclampsia, theca-lutein cysts, hyperthyroidism, or other dramatic clinical features are rare (Stefos, 2002). Preevacuation β -hCG levels are typically much lower than those for complete moles and often do not exceed 100,000 mIU/mL. For this reason, partial moles are often not identified, or even suspected, until after a histologic review of a curettage specimen.

■ Diagnosis

Clinical Assessment

An important characteristic of complete molar pregnancy, less so for partial moles, is its tendency to produce β -hCG well in excess of that expected for the gestational age (Sasaki, 2003). Robust proliferation of trophoblasts in complete moles results in dramatically elevated β -hCG levels. When combined with transvaginal sonography, serum β -hCG measurement is so suggestive of the diagnosis that most complete moles are now diagnosed before 10 weeks' gestation and prior to patient symptoms (Sun, 2015).

Although β -hCG levels are helpful, the diagnosis of complete molar pregnancy is more frequently confirmed sonographically because of the easily identifiable diffuse, swollen, and enlarged chorionic villi. Typically, complete moles show a complex intrauterine mass composed of multiple small echogenic spaces. Fetal tissues and amniotic sac are absent (Fig. 10-5) (Benson, 2000). In contrast, sonographic features of a partial molar pregnancy tend to be much more subtle, showing a thickened, hydropic placenta with concomitant fetus (Zhou, 2005).

Despite the utility of these tools, there are diagnostic limitations. Lazarus and colleagues (1999) reported that β -hCG levels in early molar pregnancies may not always be elevated in the first trimester. These same investigators also found that sonography could lead to a false-negative diagnosis if performed at very early gestational ages and before the chorionic villi have attained their characteristic vesicular pattern. Specifically, only 20 to 30 percent of patients may have sonographic evidence to indicate a partial mole (Johns, 2005; Lindholm, 1999; Sebire, 2001). Consequently, the preoperative diagnosis in very early gestations can be difficult and may not be entirely clear until after a comprehensive histologic review of the abortal specimen. In unclear cases with a live fetus and a desired pregnancy, fetal karyotyping to identify a triploid fetal chromosomal pattern can clarify the diagnosis and management.

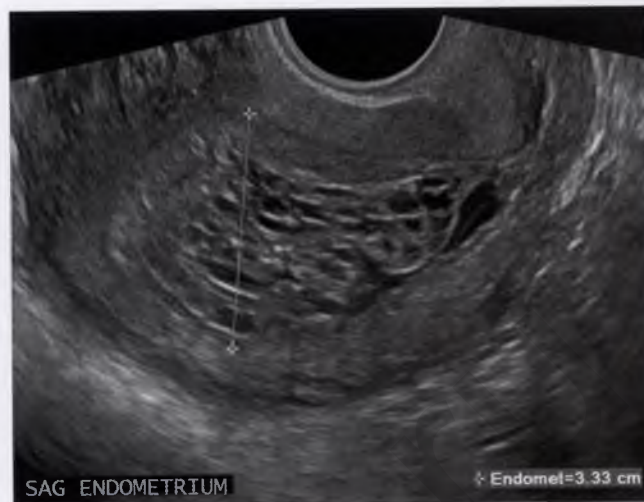


FIGURE 10-5 Transverse sonogram of a uterus with a complete hydatidiform mole. The classic “snowstorm” appearance is created by the multiple placental vesicles. The mole, marked by calipers, completely fills this uterine cavity.

Histopathology

In early pregnancy, it may also be histologically difficult to distinguish among complete moles, partial moles, and hydropic abortuses (Fukunaga, 2005; Mosher, 1998). Hydropic abortuses are pregnancies that were formed by the traditional union of one haploid egg and one haploid sperm but have failed. Their placentas display *hydropic degeneration*, in which villi are edematous and swollen, and thus mimic some villous features of hydatidiform moles. Most moles are readily identifiable histologically, but when histology is not definitive, ancillary testing may be required.

Ancillary Techniques

Histopathologic evaluation can be enhanced by immunohistochemical staining for p57 expression and by molecular genotyping. p57KIP2 is a nuclear protein whose gene is paternally imprinted and maternally expressed. This means that the gene product is produced only in tissues containing a maternal allele. Because complete moles contain only paternal genes, the p57KIP2 protein is absent in complete moles, and tissues do not pick up this stain (Merchant, 2005). In contrast, this nuclear protein is strongly expressed in normal placentas, in spontaneous pregnancy losses with hydropic degeneration, and in partial hydatidiform moles (Castrillon, 2001). Accordingly, immunostaining for p57KIP2 is an effective means to isolate complete mole from the diagnostic list.

For distinction of a partial mole from a nonmolar hydropic abortus, both of which express p57, molecular genotyping can be used. Molecular genotyping determines the parental source of polymorphic alleles. Thereby, it can distinguish among a diploid-diantric genome (complete mole), a triploid diantric-monogynic genome (partial mole), or biparental diploidy (nonmolar abortus).

■ Treatment of Molar Pregnancy

Suction curettage is the preferred method of evacuation regardless of uterine size or type of molar pregnancy in patients

who wish to remain fertile (American College of Obstetricians and Gynecologists, 2016; Tidy, 2000). Preoperative evaluation attempts to identify known potential complications such as preeclampsia, hyperthyroidism, anemia, and electrolyte depletion from hyperemesis (Lurain, 2010). Because molar tissue can infrequently be deported to the lung parenchyma, most recommend a preoperative chest radiograph. Gravidas should not be given prostanoids to ripen the cervix, since these drugs can induce uterine contractions and might increase the risk of trophoblastic embolization to the pulmonary vasculature (Seckl, 2010).

Because of the tremendous vascularity of these placentas, blood products should be available prior to the evacuation of larger moles, and adequate infusion lines established. At the beginning of the evacuation, the cervix is dilated to admit a 10- to 12-mm plastic suction curette. The technique mirrors that for other failed pregnancies, which is illustrated in Chapter 9 (p. 136). As aspiration of molar tissues ensues, intravenous oxytocin is given to help minimize bleeding. At our institution, 20 units of synthetic oxytocin are mixed with 1 L of crystalloid and infused at rates to achieve uterine contraction. In some cases, intraoperative sonography may be indicated to help reduce the risk of uterine perforation and assist in confirming complete evacuation. After suction evacuation, a thorough, gentle curettage is performed. If bleeding continues despite uterine evacuation and oxytocin infusion, other uterotonic agents, such as those described in Chapter 29 (p. 470), are given. In rare cases, pelvic arterial embolization or hysterectomy may be necessary (Tse, 2007).

It is invariable that some degree of trophoblastic deportation into the pelvic venous system takes place during molar evacuation (Hankins, 1987). With large molar pregnancies, the volume of tissue may be sufficient to produce clinically apparent respiratory insufficiency, pulmonary edema, or even embolism. In our earlier experiences with very large moles, these and their chest radiograph manifestations clear rapidly without specific treatment and do not cause persistent disease. However, fatalities have been described (Delmis, 2000).

Methods other than suction curettage may be considered for select cases. Hysterectomy with ovarian preservation may be preferable for women who have completed childbearing. Of women aged 40 and older, approximately a third will subsequently develop GTN, and hysterectomy markedly reduces this likelihood (Hanna, 2010). Theca-lutein ovarian cysts, if present, do not require intervention since they will regress after molar evacuation. In extreme cases, these may be aspirated, but oophorectomy is not performed except when torsion leads to extensive ovarian infarction (Mungan, 1996).

Following curettage, because of the possibility of partial mole and its attendant fetal tissue, Rh immune globulin should be given to nonsensitized Rh D-negative women. Rh immune globulin, however, may be withheld if the diagnosis of complete mole is absolute (Fung Kee, 2003).

■ Postmolar Surveillance

With hydatidiform moles, no pathologic or clinical features at presentation consistently predict which patients will ultimately develop subsequent GTN. Because of the trophoblastic

proliferation that characterizes these neoplasms, serial serum β -hCG levels following evacuation can be used to effectively monitor patients for GTN development. Therefore, postmolar surveillance with serial quantitative serum β -hCG levels is standard. Titers are monitored following uterine evacuation at least every 1 to 2 weeks until they become undetectable.

After achieving undetectable β -hCG levels, monthly levels are drawn during 6 months of surveillance (Sebire, 2007). However, poor compliance with prolonged monitoring has been reported—especially among indigent women and certain ethnic groups in the United States (Allen, 2003; Massad, 2000). A single blood sample demonstrating an undetectable level of β -hCG following molar evacuation is sufficient to exclude the possibility of progression to GTN in more than 99 percent of patients (Braga, 2016). Thus, after appropriate counseling, some women may elect to be discharged from routine surveillance once an undetectable value is achieved (Lavie, 2005; Wolfberg, 2004). One of the benefits of this strategy is that shortened surveillance could enable women to attempt a subsequent pregnancy sooner. However, GTN may still rarely develop after a β -hCG level has normalized, and this should be communicated to the patient (Kerkmeijer, 2007; Sebire, 2007).

Conception during the monitoring period elevates serum β -hCG levels and can hinder detection of postmolar progression to GTN (Allen, 2003). But other than complicating the monitoring schedule, these pregnancies fortunately are otherwise uneventful (Tuncer, 1999). To prevent difficulties with interpretation, women are encouraged to use effective contraception until achieving a β -hCG titer less than 5 mIU/mL or below the threshold of the individual assay. Oral contraceptive pills or injectable medroxyprogesterone acetate are preferred to less-effective barrier contraception (Braga, 2015; Costa, 2006; Massad, 2000). In contrast, intrauterine devices are not inserted until the β -hCG level is undetectable because of the risk of uterine perforation if an invasive mole is present.

■ Prophylactic Chemotherapy

The purpose of administering chemotherapy at the time of molar evacuation is mainly to prevent GTN development in high-risk patients who are unlikely to be compliant or for whom β -hCG surveillance is not available. In clinical practice, the correct classification of high-risk complete moles, however, is extremely difficult, as there is no universally accepted combination of risk factors that accurately predict GTN development. Regardless of how a high-risk complete mole is defined, few women will ultimately be assigned to this group. Due to the risks of increased drug resistance, delayed treatment of GTN, and toxic side effects with fatalities reported, this practice cannot currently be recommended (American College of Obstetricians and Gynecologists, 2016; Fu, 2012). As a result, prophylactic chemotherapy is generally only used in those countries with limited resources to reliably monitor patients after evacuation (Uberti, 2009).

■ Ectopic Molar Pregnancy

The true incidence of ectopic gestational trophoblastic disease approximates 1.5 per 1 million births (Gillespie, 2004).

More than 90 percent of suspected cases will actually reflect an overdiagnosis of florid extravillous trophoblastic proliferation in the fallopian tube (Burton, 2001; Sebire, 2005b). As with any ectopic pregnancy, initial management usually involves surgical removal of the conceptus and histopathologic evaluation.

■ Coexistent Fetus

Rarely, a twin pregnancy consists of a hydatidiform mole and a coexisting normal fetus. The estimated incidence is 1 per 20,000 to 100,000 pregnancies (Fig. 10-6). In those with continuing pregnancy, survival of the normal fetus is variable and dependent on complications that commonly develop from the molar component. The most worrisome is preeclampsia or hemorrhage, which frequently necessitate preterm delivery.

Sebire and associates (2002b) described the outcome of 77 twin pregnancies, each composed of a complete mole and a healthy cotwin. Of this group, 24 women chose to have an elective termination, and 53 continued their pregnancies. Twenty-three gestations spontaneously aborted at less than 24 weeks, two were terminated due to severe preeclampsia, and 28 pregnancies lasted at least 24 weeks—resulting in 20 live births. The authors demonstrated that coexisting complete moles and healthy cotwin pregnancies have a high risk of spontaneous abortion, but approximately 40 percent result in live births. The risk of progression to GTN was 16 percent in first-trimester terminations and not significantly higher (21 percent)

in women who continued their pregnancies. Because the risk of malignancy is unchanged with advancement of gestational age, pregnancy continuation may be allowed, provided that severe maternal complications are controlled and fetal growth is normal. Fetal karyotyping to confirm a normal fetal chromosomal pattern is also recommended (Marcorelles, 2005; Matsui, 2000).

GESTATIONAL TROPHOBLASTIC NEOPLASIA

This term primarily encompasses pathologic entities that are characterized by aggressive invasion of the endometrium and myometrium by trophoblastic cells. Histologic categories include common tumors such as the invasive mole and gestational choriocarcinoma, as well as the rare placental-site trophoblastic tumor and epithelioid trophoblastic tumor. Although these histologic types have been characterized and described, in most cases of GTN, no tissue is available for pathologic study. Most cases of GTN are diagnosed based on elevated β -hCG levels and managed clinically.

GTN typically develops with or follows some form of pregnancy, but occasionally the antecedent gestation cannot be confirmed with certainty. Rarely, GTN develops after a live birth, miscarriage, or termination. The overwhelming majority of cases follow a hydatidiform mole. GTN develops after evacuation in 15 to 20 percent of complete moles (Golfier, 2007; Wolfberg, 2004). Despite the trend toward diagnosis at earlier gestational ages, this incidence has not decreased (Sun, 2015). Of those women who develop GTN, three quarters have locally invasive molar disease, and the remaining one quarter develops metastases. In contrast, GTN develops in only 4 to 6 percent of partial moles following evacuation (Feltmate, 2006; Lavié, 2005). Most are locally invasive, and metastatic choriocarcinoma is rare (Cheung, 2004; Seckl, 2000).

■ Histologic Classification

Invasive Mole

This is a common manifestation of GTN characterized by whole chorionic villi that accompany excessive trophoblastic overgrowth and invasion. These tissues penetrate deep into the myometrium, sometimes to involve the peritoneum, adjacent parametrium, or vaginal vault (Fig. 10-7). Such moles are locally invasive, but generally lack the pronounced tendency to develop widespread metastases typical of choriocarcinoma. Invasive moles originate almost exclusively from complete or partial molar gestations (Sebire, 2005a).

Gestational Choriocarcinoma

This extremely malignant tumor is composed of sheets of anaplastic cytotrophoblast cells and syncytiotrophoblast with prominent hemorrhage, necrosis, and vascular invasion (see Fig. 10-7). Unlike molar disease, however, formed chorionic

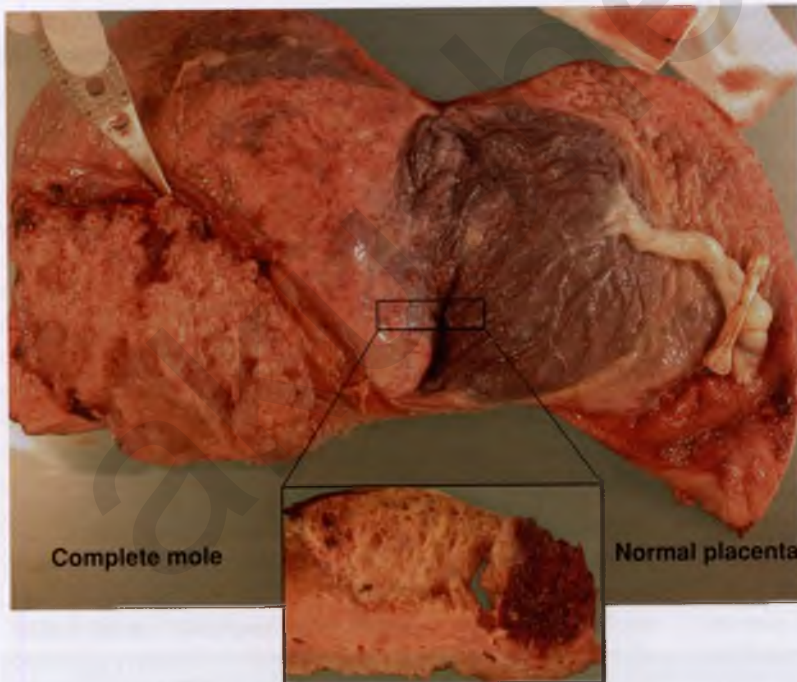


FIGURE 10-6 Placentas from a twin pregnancy composed of one normal twin and one complete mole. The complete mole (left) shows the characteristic vesicular structure. The placenta of the normal cotwin (right) appears grossly normal. Inset: A transverse section through the border between these two is shown. (Used with permission from Drs. April Bleich and Brian Levenson. Reproduced with permission from Schorge JO: Gestational trophoblastic disease. In Hoffman BL, Schorge JO, Bradshaw KD, et al: Williams Gynecology, 3rd ed. New York, McGraw-Hill Education, 2016.)

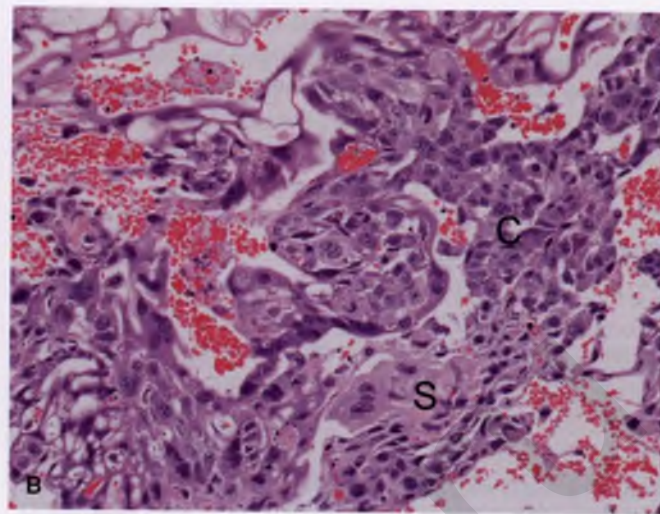
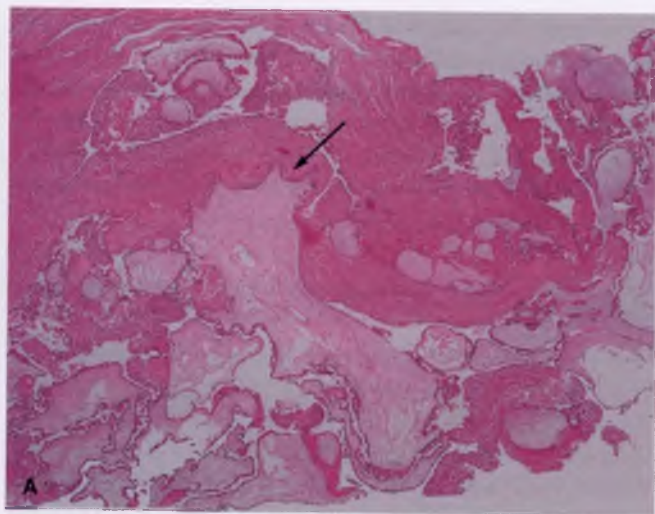


FIGURE 10-7 A. An invasive mole contains whole villi that invade locally. The arrow marks one villus invading deeply into the adjacent myometrium. (Used with permission from Dr. Ona Faye-Peterson. Reproduced with permission from Schorge JO: Gestational trophoblastic disease. In Hoffman BL, Schorge JO, Bradshaw KD, et al: Williams Gynecology, 3rd ed. New York, McGraw-Hill Education, 2016.) **B.** Choriocarcinoma is a biphasic tumor characterized by cytotrophoblast (C), intimately admixed with multinucleate syncytiotrophoblast (S). Choriocarcinoma is a vascular tumor, typically with prominent hemorrhage, as evidenced by the abundant blood in the background. (Used with permission from Dr. Kelley Carrick.)

villi are characteristically absent. Gestational choriocarcinomas initially invade the endometrium and myometrium but tend to develop early blood-borne systemic metastases.

Although most cases develop following evacuation of a molar pregnancy, these tumors may rarely follow a nonmolar pregnancy. Of nonmolar antecedents, two thirds are term pregnancies, and one third are spontaneous abortions or pregnancy terminations. Occasionally, unanticipated choriocarcinoma is detected in an otherwise normal-appearing placenta at delivery. More commonly, however, the diagnosis of choriocarcinoma is delayed for months due to subtle signs and symptoms of disease. Most patients present with metrorrhagia, and high β -hCG levels are detected (Lok, 2006). For this reason, abnormal bleeding for more than 6 weeks following any pregnancy is evaluated with β -hCG testing to exclude a new pregnancy or GTN. Less frequently, the diagnosis is made in an asymptomatic woman by an incidental positive pregnancy test (Diver, 2013).

Notably, primary “nongestational” choriocarcinoma ovarian germ cell tumors, although rare, have an identical histologic appearance. This ovarian cancer is in part distinguished by the absence of a preceding pregnancy event (Lee, 2009).

In part because of the typical delay to diagnosis, choriocarcinomas that follow term pregnancies have a significantly higher mortality rate than GTN following nonmolar abortions. Death rates range between 10 to 15 percent (Diver, 2013; Lok, 2006; Rodabaugh, 1998; Tidy, 1995). More than half of patients presenting with brain metastases or placental site trophoblastic tumors have a preceding term gestation (Feltmate, 2001; Newlands, 2002). The frequency of these high-risk features also helps to explain the poorer prognosis for choriocarcinoma following a term pregnancy.

Placental-Site Trophoblastic Tumor

This tumor consists predominantly of intermediate trophoblasts at the placental site and is a rare variant of GTN with

unique disease behavior. Placental-site trophoblastic tumors can follow any type of pregnancy, but develop most commonly following a term gestation (Papadopoulos, 2002). Typically, patients have irregular bleeding months or years after the antecedent pregnancy (Feltmate, 2001). Placental-site trophoblastic tumors tend to infiltrate only within the uterus, disseminate late in their course, and produce low levels of β -hCG (van Trommel, 2013). When this tumor does spread, the pattern mirrors that of gestational choriocarcinoma, with metastases often to the lungs, liver, or vagina (Baergen, 2006).

Hysterectomy is the primary treatment for nonmetastatic placental site trophoblastic tumor. This is due to its relative insensitivity to chemotherapy (Papadopoulos, 2002).

Metastatic placental-site trophoblastic tumor has a much poorer prognosis than its postmolar GTN counterpart. As a result, aggressive combination chemotherapy is indicated. Radiation may also have a role in some situations. The overall 10-year survival is 70 percent, but patients with metastases have a much poorer prognosis (Hyman, 2013; Schmid, 2009).

Epithelioid Trophoblastic Tumor

This rare trophoblastic tumor is distinct from gestational choriocarcinoma and placental-site trophoblastic tumor. The preceding pregnancy event may be remote, or in some cases, a prior gestation cannot be confirmed (Palmer, 2008). Epithelioid trophoblastic tumor develops from neoplastic transformation of chorionic-type intermediate trophoblast. Grossly, epithelioid trophoblastic tumor grows in a nodular fashion rather than the infiltrative pattern of placental-site trophoblastic tumor (Shih, 1998). Hysterectomy is the primary method of treatment due to presumed chemoresistance and because the diagnosis is usually confirmed in advance by endometrial biopsy. More than one third of patients will present with metastatic disease that has demonstrable chemoresistance to multiagent therapy and carries a poor prognosis (Davis, 2015; Palmer, 2008).

TABLE 10-3. FIGO Criteria for Gestational Trophoblastic Neoplasia Diagnosis

β-hCG level plateau persists in four measurements during a period of 3 weeks or longer (days 1, 7, 14, and 21)
β-hCG level rise in 3 weekly consecutive measurements or longer, over a period of 2 weeks or more (days 1, 7, and 14)
β-hCG level remains elevated for 6 months or more
Histologic diagnosis of choriocarcinoma

β-hCG = beta human chorionic gonadotropin; FIGO = International Federation of Gynecology and Obstetrics.
Data from FIGO Oncology Committee, 2002.

■ Diagnosis

Most GTN cases are clinically diagnosed, using β-hCG evidence (Table 10-3). Tissue is infrequently available for pathologic diagnosis, unless a diagnosis of placental-site trophoblastic tumor or a nongestational ovarian tumor is being considered. As a result, most centers in the United States diagnose GTN on the basis of rising β-hCG values or a persistent plateau of β-hCG values for at least 3 weeks. Unfortunately, uniformity is lacking in the definition of a persistent plateau. Additionally, the diagnostic criteria are less stringent in the United States than in Europe, partly because of concern that some patients may be lost to follow-up if stricter criteria are used.

When serologic criteria are met for GTN, a new intrauterine pregnancy should be excluded using β-hCG levels correlated with sonographic findings. This is especially true if there has been a long delay in monitoring of serial β-hCG levels or non-compliance with contraception or both.

■ Assessment

Patients diagnosed with GTN undergo thorough assessment to determine the extent of disease before contemplating treatment. The initial evaluation may be limited to pelvic examination, chest radiograph, and pelvic sonography or abdominopelvic computed tomography (CT) scanning. Most commonly, metastatic disease is detected in the lungs. Although approximately 40 percent of patients will have micrometastases not otherwise visible with chest radiography, chest CT is not necessarily required because these small lesions do not affect outcome (Darby, 2009). However, pulmonary lesions evident on chest radiograph should at least prompt CT of the chest and magnetic resonance (MR) imaging of the brain. Fortunately, central nervous system involvement is rare in the absence of neurologic symptoms or signs (Price, 2010). Positron emission

tomography (PET) may occasionally be useful in the evaluation of occult choriocarcinoma or relapse from previously treated GTN when conventional imaging is equivocal or fails to identify metastatic disease (Dhillon, 2006; Numnum, 2005).

■ Staging

GTN is anatomically staged based on a system adopted by the International Federation of Gynecology and Obstetrics (FIGO) (Table 10-4). Patients at low risk for therapeutic failure are distinguished from those at high risk using the modified prognostic scoring system of the World Health Organization (WHO) (Table 10-5). Approximately 95 percent of patients will have a WHO score of 0 to 6 and be considered to have low-risk disease (Sita-Lumsden, 2012). The remainder will have a score >7 and be assigned to the high-risk GTN group. For the most accurate description of these patients, the Roman numeral corresponding to FIGO stage is separated by a colon from the sum of all the actual risk factor scores, for example, stage II:4 or stage IV:9 (FIGO Committee on Gynecologic Oncology, 2009; Petru, 2009). This scoring best reflects disease behavior (Ngan, 2004). Women with high-risk scores are more likely to have tumors that are resistant to single-agent chemotherapy. They are therefore treated initially with combination chemotherapy. Although patients with stage I disease infrequently have a high-risk score, those with stage IV disease invariably have a high-risk score. Women diagnosed with FIGO stage I, II, or III GTN have a survival rate approaching 100 percent (Lurain, 2010).

Nonmetastatic Disease

Invasive moles arising from complete molar gestations make up most nonmetastatic GTN cases. Placental-site trophoblastic tumors and epithelioid trophoblastic tumors are other rarer causes of nonmetastatic GTN. Locally invasive trophoblastic tumors may perforate through the myometrium and lead to

TABLE 10-4. FIGO Anatomic Staging

Stage	Characteristics
I	Disease confined to the uterus
II	GTN extends outside of the uterus but is limited to the genital structures (adnexa, vagina, broad ligament)
III	GTN extends to the lungs, with or without known genital tract involvement
IV	All other metastatic sites

FIGO = International Federation of Gynecology and Obstetrics; GTN = gestational trophoblastic neoplasia.
From FIGO Committee on Gynecologic, 2009.

TABLE 10-5. Modified WHO Prognostic Scoring System as Adapted by FIGO

Scores	0	1	2	4
Age (yr)	<40	≥40	—	—
Antecedent pregnancy	Mole	Abortion	Term	—
Interval months from index pregnancy	<4	4–6	7–12	>12
Pretreatment serum β-hCG (mIU/mL)	<10 ³	10 ³ –<10 ⁴	10 ⁴ –<10 ⁵	≥10 ⁵
Largest tumor size (including uterus)	<3 cm	3–4 cm	≥5 cm	—
Site of metastases	—	Spleen, kidney	GI	Liver, brain
Number of metastases	—	1–4	5–8	>8
Previous failed chemotherapy drugs	—	—	1	≥2

Low risk = WHO score of 0 to 6; high risk = WHO score of ≥7

β-hCG = beta human chorionic gonadotropin; FIGO = International Federation of Gynecology and Obstetrics; GI = gastrointestinal; WHO = World Health Organization.

From FIGO Committee on Gynecologic, 2009.

intraperitoneal bleeding (Mackenzie, 1993). Alternatively, vaginal hemorrhage can follow tumor erosion into uterine vessels, or necrotic tumor may involve the uterine wall and serve as a nidus for infection. Fortunately, the prognosis is excellent for all types of nonmetastatic disease despite these possible manifestations.

Metastatic Disease

Choriocarcinomas originating from complete molar gestations compose most cases of metastatic GTN. Of complete moles, 3 to 4 percent develop metastatic choriocarcinoma after evacuation. The incidence following any other type of molar or nonmolar gestation is rare. With its propensity for distant spread, choriocarcinoma should be suspected in any reproductive-aged woman with metastatic disease from an unknown primary (Tidy, 1995). In such cases, a common presentation is chest imaging that shows numerous pulmonary masses. Biopsies may be difficult to interpret in this setting, but measurement of β-hCG level is warranted and may be confirmatory. As a basic rule, whenever choriocarcinoma is diagnosed histologically, chemotherapy is indicated.

Many affected patients are largely asymptomatic, but metastatic GTN is highly vascular and prone to severe hemorrhage either spontaneously or during attempts at biopsy. The most common sites of spread are the lungs (80 percent), vagina (30 percent), pelvis (20 percent), liver (10 percent), and brain (10 percent) (Fig. 10-8). Patients with pulmonary metastases typically have asymptomatic lesions identified on routine chest radiograph and infrequently present with cough, dyspnea, hemoptysis, pleuritic chest pain, or signs of pulmonary hypertension (Seckl, 1991). Hepatic or cerebral involvement is encountered almost exclusively in patients who have had an antecedent nonmolar pregnancy and a protracted delay in tumor diagnosis (Newlands, 2002; Savage, 2015). These women may present with associated hemorrhagic events. Virtually all patients with hepatic or cerebral metastases have concurrent pulmonary or vaginal involvement or both. Menorrhagia is a common presenting symptom of isolated vaginal metastases. Great caution is used in attempting excision of any metastatic disease site due

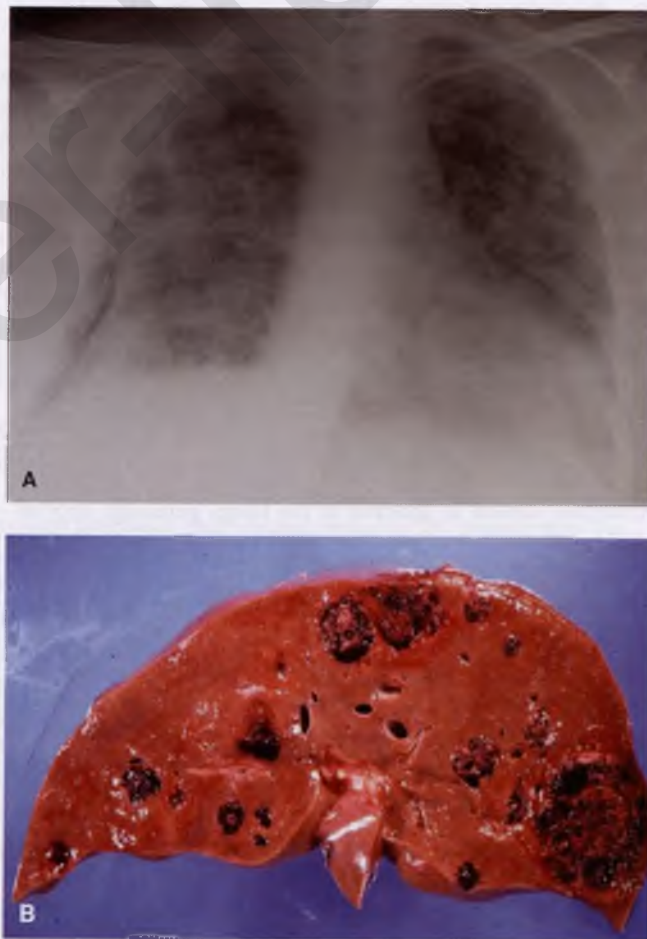


FIGURE 10-8 Common sites of gestational trophoblastic neoplasia metastasis. **A.** Chest radiograph demonstrates widespread metastatic lesions. **B.** Autopsy specimen shows multiple hemorrhagic hepatic metastases. (Used with permission from Dr. Michael G. Connor. Reproduced with permission from Cunningham FG, Leveno KJ, Bloom SL, et al (eds): *Gestational trophoblastic disease*. In *Williams Obstetrics*, 24th ed. New York, McGraw-Hill Education, 2014.)

to the risk of profuse hemorrhage. Thus, this practice is almost uniformly avoided except in extenuating circumstances.

■ Treatment

Surgery

Most patients diagnosed with postmolar GTN have persistent tumor confined to the endometrial cavity and are treated primarily with chemotherapeutic agents. Repeat dilatation and curettage is generally avoided to prevent morbidity and mortality caused by uterine perforation, hemorrhage, infection, intrauterine adhesions, and anesthetic complications (American College of Obstetricians and Gynecologists, 2016). Accordingly, second evacuations are not typically performed in the United States unless patients have persistent uterine bleeding and substantial amounts of retained molar tissue. Repeat uterine curettage is a more standard part of the management of postmolar GTN in Europe. This practice significantly reduces both the number of patients needing any further treatment and the number of courses in those who do require chemotherapy (Pezeshki, 2004; van Trommel, 2005). A second evacuation followed by continued surveillance, however, is a less attractive option, even for poorly compliant patients, than single-agent chemotherapy (Allen, 2003; Massad, 2000).

Hysterectomy may play several roles in the treatment of GTN. First, it may be performed to primarily treat placental-site trophoblastic tumors, epithelioid trophoblastic tumors, or other types of chemotherapy-resistant disease. Fortunately declining in incidence, severe uncontrollable vaginal or intraabdominal bleeding may necessitate hysterectomy as an emergency procedure (Chao, 2002; Clark, 2010). Because of these more extreme indications, most women undergoing hysterectomy have elevated pretreatment risk scores, unusual pathology, and higher mortality rates (Pisal, 2002). Finally, adjuvant hysterectomy decreases the total dose of chemotherapy needed to achieve clinical remission in low-risk GTN. Patients with disease apparently confined to the uterus who do not desire future fertility should be counseled regarding this option (Suzuka, 2001). However, the risk of GTN persistence after hysterectomy remains approximately 3 to 5 percent, and these patients should be monitored postoperatively (American College of Obstetricians and Gynecologists, 2016).

Residual lung metastases may persist in 10 to 20 percent of patients achieving clinical remission of GTN after completion of chemotherapy. These patients do not appear to have an increased risk of relapse compared with those having normal chest radiographs or CT scans. Thus, thoracotomy is not usually necessary unless remission cannot otherwise be achieved (Powles, 2006).

Chemotherapy for Low-Risk GTN

Methotrexate. Most patients with hydatidiform mole who develop GTN are at low risk of chemotherapy resistance (score 0-6) (Seckl, 2010). Single-agent methotrexate is the most common treatment, and complete response rates range from 67 to 81 percent for the two most common intramuscular methotrexate regimens described in the next paragraph. Despite being classified as low risk, the highest cure rates occur in patients

with the lowest WHO scores of 0 to 1, and decrease proportionally for those with scores of 5 to 6 (Sita-Lumsden, 2012). As a result of efficacy rates in the low 30 percent range, patients with a WHO score of 6 should at least be considered for primary combination chemotherapy (Taylor, 2013). Overall, 19 to 33 percent of women develop methotrexate resistance and are switched to other agents, described subsequently.

With methotrexate, the Gynecologic Oncology Group (GOG) conducted a prospective cohort dose-escalation study (protocol #79) of weekly administration that established a maximum dose of 50 mg/m² with minimal toxicity (Homesley, 1988, 1990). This regimen is continued weekly until β -hCG levels are undetectable, and then two or three additional weekly doses are given (Lybol, 2012). Lower doses, such as 40 mg/m², or even 30 mg/m², may have similar efficacy.

Alternatively, Charing Cross Hospital and University of Sheffield investigators currently use an 8-day alternating regimen of 50 mg IM methotrexate on treatment days 1, 3, 5, and 7, and oral leucovorin, 7.5 to 15 mg taken orally on days 2, 4, 6, and 8. Treatment is repeated every 2 weeks (Taylor, 2013). Leucovorin is folic acid, has activity that is equivalent to folic acid, and is given to help blunt some of methotrexate's toxicity.

Methotrexate is a folic acid antagonist that inhibits DNA synthesis. Mild stomatitis is the most common side effect, but other serosal symptoms, especially pleurisy, develop in up to one quarter of patients treated with low-dose methotrexate. Pericarditis, peritonitis, and pneumonitis are infrequent (Sharma, 1999). Compared with that from weekly administration, toxicity develops more often from the more intense 8-day regimens despite routine leucovorin "rescue" (Gleeson, 1993).

Dactinomycin. Due to toxicity concerns, dactinomycin is less commonly used for the primary treatment of low-risk disease but appears to have superior efficacy as a single agent (Alazzam, 2012; Yarandi, 2008). Since survival rates are so high, methotrexate is usually tried first because most clinicians consider it to be the least toxic therapy.

Patients who do not respond to an initial single-agent chemotherapeutic regimen fail to have persistently dropping β -hCG levels. These women should have their score recalculated using the modified WHO prognostic scoring system. Most women will still be considered low-risk and may be switched to a single-agent second-line therapy. Methotrexate-resistant GTN often responds to dactinomycin (Chapman-Davis, 2012; Chen, 2004). The GOG demonstrated a 74-percent success rate in a phase II trial (protocol #176) of pulse dactinomycin as salvage treatment in 38 patients with methotrexate-resistant GTN (Covens, 2006). Etoposide is less commonly used in this setting but is also effective (Mangili, 1996). Patients initially treated with pulse dactinomycin who develop resistant GTN may still be successfully treated with the 5-day course of dactinomycin (Kohorn, 2002). Alternatively, single-agent methotrexate or etoposide is often effective in these cases (Matsui, 2005).

Chemotherapy for High-Risk GTN

Approximately 5 percent of GTN patients present with high-risk disease. Such patients are highly likely to develop drug resistance to single-agent chemotherapy (Seckl, 2010). Etoposide,

methotrexate, and dactinomycin (actinomycin D) alternating with cyclophosphamide and vincristine (Oncovin) (EMA/CO) chemotherapy is a well-tolerated and highly effective regimen for high-risk GTN. It is considered the preferred treatment in most circumstances. Bower and coworkers (1997) at Charing Cross Hospital reported a 78-percent complete remission rate in 272 consecutive women. Similar complete response rates are reported by others (Escobar, 2003; Lu, 2008). Response rates are comparable whether patients are treated primarily or after failure of single-agent methotrexate and/or dactinomycin.

Patients with high-risk disease have an overall survival rate of 86 to 92 percent, although approximately one quarter become refractory to or relapse from EMA/CO (Bower, 1997; Escobar, 2003; Lu, 2008; Lurain, 2010). Secondary treatment usually involves platinum-based chemotherapy combined with possible surgical excision of resistant disease (Alazzam, 2012). Newlands and colleagues (2000) at Charing Cross Hospital reported an 88-percent survival rate among 34 patients by replacing the cyclophosphamide and vincristine component with etoposide and cisplatin (Platinol) (EMA/EP). In patients resistant to EMA/CO, paclitaxel (Taxol) and alternating platinum and etoposide (TP/TE) has also demonstrated comparable efficacy to EMA/EP and appears less toxic (Patel, 2010; Wang, 2008). Bleomycin, etoposide, and cisplatin (BEP) is another potentially effective regimen (Lurain, 2005; Patel, 2010).

High-risk patients with a large disease burden are at risk for early death due to tumor-lysis related hemorrhage and clinical deterioration despite standard combination therapy (Bolze, 2015). In these selected cases, rather than proceeding directly with EMA/CO, a lower-dose etoposide and cisplatin combination used as an induction regimen appears to reduce the mortality risk 10-fold (Alifrangis, 2013).

Brain Metastases

Fortunately, the incidence of brain metastases in postmolar GTN is extremely low overall, but those with nonmolar choriocarcinoma have a 20-percent risk (Savage, 2015). Patients with cerebral metastases may present with seizures, headaches, or hemiparesis (Newlands, 2002). Occasionally, they are moribund on arrival after not recognizing the significance of their symptoms or following an extended delay in diagnosis. In such extenuating circumstances, emergency craniotomy may be indicated to stabilize the patient (Savage, 2015). In experienced centers, virtually all GTN-related deaths occur in stage IV patients with WHO risk scores of 12 or more (Neubauer, 2015). Fortunately, the cure rate for those with brain metastases is high if neurologic deterioration does not occur within the first couple of weeks after diagnosis. The sequence of aggressive multimodality therapy is controversial, but may include chemotherapy, surgery, and radiation (American College of Obstetricians and Gynecologists, 2016).

Posttreatment Surveillance

Monitoring of patients with low-risk GTN consists of weekly β -hCG measurements until the level is undetectable for 3 consecutive weeks. This is followed by monthly titers until the level is undetectable for 12 months. Patients with high-risk disease are followed for 24 months due to the greater risk of late

relapse. Patients are encouraged to use effective contraception, as outlined earlier, during the entire surveillance period.

Subsequent Pregnancy Outcome

Although patients may expect a normal reproductive outcome after achieving remission from GTN, some evidence suggests that adverse maternal outcomes and spontaneous abortion occur more frequently among those who conceive within 6 months of chemotherapy completion (Braga, 2009). Women having a pregnancy affected by a histologically confirmed complete or partial mole may be counseled that the risk of a repeat mole in a subsequent pregnancy approximates 1 percent (Garrett, 2008). Most will be of the same type of mole as the preceding pregnancy (Sebire, 2003). Women who become pregnant within 12 months after chemotherapy for GTN can be reassured of a likely favorable outcome, although the safest option is still to delay pregnancy for a full year (Williams, 2014). Pregnancy after combination EMA/CO chemotherapy for GTN also has a high probability of success and favorable outcome (Lok, 2003). All major cytotoxic treatments except methotrexate increase the risk of early menopause (Savage, 2015).

Phantom β -hCG

Occasionally, persistent mild elevations of serum β -hCG are detected that lead physicians to erroneously treat patients with cytotoxic chemotherapy or hysterectomy or both, when in reality no true β -hCG or trophoblastic disease is present (Cole, 1998; Rotmensch, 2000). This “phantom” β -hCG reading results from heterophilic antibodies in the serum that interfere with the β -hCG immunoassay and cause a false-positive result (American College of Obstetricians and Gynecologists, 2016).

Several methods can clarify the diagnosis. First, a urine pregnancy test can be performed. With phantom β -hCG, the heterophilic antibodies are not filtered or renally excreted. Thus, the urine test will show true and negative results for β -hCG. Importantly, to conclusively exclude trophoblastic disease by this method, the index β -hCG level obtained from the serum must be significantly higher than the detection threshold of the urine test. A second method performs serial dilutions of the serum sample, which should result in a similar proportional decline in the β -hCG level if β -hCG is truly present. However, phantom β -hCG measurements will be unchanged by dilution. As a third method, if phantom β -hCG is suspected, some specialized laboratories can admix additives to block the heterophilic antibodies. Last, a different β -hCG assay using an alternative method may accurately demonstrate the absence of true β -hCG (Cole, 1998; Rotmensch, 2000).

Quiescent Gestational Trophoblastic Disease

Patients with persistent mild elevations (usually in the range of 50 mIU/mL or less) of true β -hCG may have a dormant premalignant condition if no tumor is identified by physical examination or imaging studies (Khanlian, 2003). In this instance, phantom β -hCG should also be conclusively excluded as a possibility. The low β -hCG titers may persist for months or years before disappearing. Chemotherapy and surgery usually have

no effect. Hormonal contraception may be helpful in lowering titers to an undetectable level, but patients should be closely monitored since metastatic GTN may eventually develop (Khanlian, 2003; Kohorn, 2002; Palmieri, 2007).

REFERENCES

- Alazzam M, Tidy J, Hancock BW, et al: First-line chemotherapy in low risk gestational trophoblastic neoplasia. *Cochrane Database Syst Rev* 7:CD007102, 2012
- Alifrangis C, Agarwal R, Short D, et al: EMA/CO for high-risk gestational trophoblastic neoplasia: good outcomes with induction low-dose etoposide-cisplatin and genetic analysis. *J Clin Oncol* 31(2):280, 2013
- Allen JE, King MR, Farrar DF, et al: Postmolar surveillance at a trophoblastic disease center that serves indigent women. *Am J Obstet Gynecol* 188:1151, 2003
- Altman AD, Bentley B, Murray S, et al: Maternal age-related rates of gestational trophoblastic disease. *Obstet Gynecol* 112:244, 2008
- American College of Obstetricians and Gynecologists: Diagnosis and treatment of gestational trophoblastic disease. Practice Bulletin No. 53, June 2004, Reaffirmed 2016
- Baergen RN, Rutgers JL, Young RH, et al: Placental site trophoblastic tumor: a study of 55 cases and review of the literature emphasizing factors of prognostic significance. *Gynecol Oncol* 100:511, 2006
- Benson CB, Genest DR, Bernstein MR, et al: Sonographic appearance of first trimester complete hydatidiform moles. *Ultrasound Obstet Gynecol* 16:188, 2000
- Berkowitz RS, Bernstein MR, Harlow BL, et al: Case-control study of risk factors for partial molar pregnancy. *Am J Obstet Gynecol* 173:788, 1995
- Berkowitz RS, Cramer DW, Bernstein MR, et al: Risk factors for complete molar pregnancy from a case-control study. *Am J Obstet Gynecol* 152:1016, 1985
- Berkowitz RS, Im SS, Bernstein MR, et al: Gestational trophoblastic disease: subsequent pregnancy outcome, including repeat molar pregnancy. *J Reprod Med* 43:81, 1998
- Bolze PA, Riedl C, Massardier J, et al: Mortality of gestational trophoblastic neoplasia with a FIGO score of 13 and higher. *Am J Obstet Gynecol* 214(3):390.e1, 2015
- Bower M, Newlands ES, Holden L, et al: EMA/CO for high-risk gestational trophoblastic tumors: results from a cohort of 272 patients. *J Clin Oncol* 15:2636, 1997
- Braga A, Maesta I, Matos M, et al: Gestational trophoblastic neoplasia after spontaneous human chorionic gonadotropin normalization following molar pregnancy evacuation. *Gynecol Oncol* 139(2):283, 2015
- Braga A, Maesta I, Michelin OC, et al: Maternal and perinatal outcomes of first pregnancy after chemotherapy for gestational trophoblastic neoplasia in Brazilian women. *Gynecol Oncol* 112:568, 2009
- Braga A, Maesta I, Short D, et al: Hormonal contraceptive use before hCG remission does not increase the risk of gestational trophoblastic neoplasia following complete hydatidiform mole: a historical database review. *BJOG* 123(8):1330, 2016
- Burton JL, Lidbury EA, Gillespie AM, et al: Overdiagnosis of hydatidiform mole in early tubal ectopic pregnancy. *Histopathology* 38:409, 2001
- Cakmak B, Toprak M, Nacar MC, et al: Incidence of gestational trophoblastic disease in Tokat province, Turkey. *J Turk Ger Gynecol Assoc* 15(1):22, 2014
- Castrillon DH, Sun D, Weremowicz S, et al: Discrimination of complete hydatidiform mole from its mimics by immunohistochemistry of the paternally imprinted gene product p57KIP2. *Am J Surg Pathol* 25:1225, 2001
- Chao A, Lin CT, Chang TC, et al: Choriocarcinoma with diffuse intra-abdominal abscess and disseminated intravascular coagulation: a case report. *J Reprod Med* 47:689, 2002
- Chapman-Davis E, Hoekstra AV, Rademaker AW, et al: Treatment of non-metastatic and metastatic low-risk gestational trophoblastic neoplasia: factors associated with resistance to single-agent methotrexate chemotherapy. *Gynecol Oncol* 125(3):572, 2012
- Chen LM, Lengyel ER, Bethan PC: Single-agent pulse dactinomycin has only modest activity for methotrexate-resistant gestational trophoblastic neoplasia. *Gynecol Oncol* 94:204, 2004
- Cheung AN, Khoo US, Lai CY, et al: Metastatic trophoblastic disease after an initial diagnosis of partial hydatidiform mole: genotyping and chromosome in situ hybridization analysis. *Cancer* 100:1411, 2004
- Clark RM, Nevadunsky NS, Ghosh S, et al: The evolving role of hysterectomy in gestational trophoblastic neoplasia at the New England Trophoblastic Disease Center. *J Reprod Med* 5:194, 2010
- Cole LA: Phantom hCG and phantom choriocarcinoma. *Gynecol Oncol* 71:325, 1998
- Costa HL, Doyle P: Influence of oral contraceptives in the development of post-molar trophoblastic neoplasia—a systematic review. *Gynecol Oncol* 100:579, 2006
- Covens A, Filiaci VL, Burger RA, et al: Phase II trial of pulse dactinomycin as salvage therapy for failed low-risk gestational trophoblastic neoplasia: a Gynecologic Oncology Group study. *Cancer* 107(6):1280, 2006
- Cunningham FG, Leveno KJ, Bloom SL, et al (eds): Gestational trophoblastic disease. In *Williams Obstetrics*, 24th ed. New York, McGraw-Hill Education, 2014
- Darby S, Jolley I, Pennington S: Does chest CT matter in the staging of GTN? *Gynecol Oncol* 112:155, 2009
- Davis MR, Howitt BE, Quade BJ, et al: Epithelioid trophoblastic tumor: a single institution case series at the New England Trophoblastic Disease Center. *Gynecol Oncol* 137(3):456, 2015
- Delmis J, Pfeifer D, Ivanisevic M, et al: Sudden death from trophoblastic embolism in pregnancy. *Eur J Obstet Gynecol Reprod Biol* 92:225, 2000
- Dhillon T, Palmieri C, Sebire NJ, et al: Value of whole body ¹⁸F-DG-PET to identify the active site of gestational trophoblastic neoplasia. *J Reprod Med* 51:979, 2006
- Diver E, May T, Vargas R, et al: Changes in clinical presentation of post-term choriocarcinoma at the New England Trophoblastic Disease Center in recent years. *Gynecol Oncol* 130(3):483, 2013
- Drake RD, Rao GG, McIntire DD, et al: Gestational trophoblastic disease among Hispanic women: a 21-year hospital-based study. *Gynecol Oncol* 103(1):81, 2006
- Escobar PF, Lurain JR, Singh DK, et al: Treatment of high-risk gestational trophoblastic neoplasia with etoposide, methotrexate, actinomycin D, cyclophosphamide, and vincristine chemotherapy. *Gynecol Oncol* 91:552, 2003
- Fallahian M: Familial gestational trophoblastic disease. *Placenta* 24:797, 2003
- Fan JB, Surti U, Tailon-Miller P, et al: Paternal origins of complete hydatidiform moles proven by whole genome single-nucleotide polymorphism haplotyping. *Genomics* 79:58, 2002
- Feltmate CM, Genest DR, Wise L, et al: Placental site trophoblastic tumor: a 17-year experience at the New England Trophoblastic Disease Center. *Gynecol Oncol* 82:415, 2001
- Feltmate CM, Growdon WB, Wolfberg AJ, et al: Clinical characteristics of persistent gestational trophoblastic neoplasia after partial hydatidiform molar pregnancy. *J Reprod Med* 51:902, 2006
- FIGO Committee on Gynecologic Oncology: Current FIGO staging for cancer of the vagina, fallopian tube, ovary, and gestational trophoblastic neoplasia. *Int J Gynaecol Obstet* 105:3, 2009
- FIGO Oncology Committee: FIGO staging for gestational trophoblastic neoplasia 2000. *Int J Gynaecol Obstet* 77:285, 2002
- Fu J, Fang F, Xie L, et al: Prophylactic chemotherapy for hydatidiform mole to prevent gestational trophoblastic neoplasia. *Cochrane Database Syst Rev* 10:CD007289, 2012
- Fukunaga M, Katabuchi H, Nagasaka T, et al: Interobserver and intraobserver variability in the diagnosis of hydatidiform mole. *Am J Surg Pathol* 29:942, 2005
- Fung Kee FK, Eason E, Crane J, et al: Prevention of Rh alloimmunization. *J Obstet Gynaecol Can* 25:765, 2003
- Garrett LA, Garner EI, Feltmate CM, et al: Subsequent pregnancy outcomes in patients with molar pregnancy and persistent gestational trophoblastic neoplasia. *J Reprod Med* 53(7):481, 2008
- Gillespie AM, Lidbury EA, Tidy JA, et al: The clinical presentation, treatment, and outcome of patients diagnosed with possible ectopic molar gestation. *Int J Gynecol Cancer* 14:366, 2004
- Gleeson NC, Finan MA, Fiorica JV, et al: Nonmetastatic gestational trophoblastic disease: weekly methotrexate compared with 8-day methotrexate-folinic acid. *Eur J Gynaecol Oncol* 14:461, 1993
- Golfer F, Raudrant D, Frappart L, et al: First epidemiological data from the French Trophoblastic Disease Reference Center. *Am J Obstet Gynecol* 196:172.e1, 2007
- Hankins GD, Wendel GD, Snyder RR, et al: Trophoblastic embolization during molar evacuation: central hemodynamic observations. *Obstet Gynecol* 63:368, 1987
- Hanna RK, Soper JT: The role of surgery and radiation therapy in the management of gestational trophoblastic disease. *Oncologist* 15(6):593, 2010
- Hershman JM: Physiologic and pathological aspects of the effect of human chorionic gonadotropin on the thyroid. *Best Pract Res Clin Endocrinol Metab* 18:249, 2004
- Homesley HD, Blessing JA, Rettenmaier M, et al: Weekly intramuscular methotrexate for nonmetastatic gestational trophoblastic disease. *Obstet Gynecol* 72:413, 1988
- Homesley HD, Blessing JA, Schlaerth J, et al: Rapid escalation of weekly intramuscular methotrexate for nonmetastatic gestational trophoblastic disease: a Gynecologic Oncology Group study. *Gynecol Oncol* 39:305, 1990

- Hyman DM, Bakios L, Gualtiere G, et al: Placental site trophoblastic tumor: analysis of presentation, treatment, and outcome. *Gynecol Oncol* 129(1):58, 2013
- Jauniaux E: Partial moles: from postnatal to prenatal diagnosis. *Placenta* 20: 379, 1999
- Johns J, Greenwold N, Buckley S, et al: A prospective study of ultrasound screening for molar pregnancies in missed miscarriages. *Ultrasound Obstet Gynecol* 25:493, 2005
- Joneborg U, Eloranta S, Johansson AL, et al: Hydatidiform mole and subsequent pregnancy outcome: a population-based cohort study. *Am J Obstet Gynecol* 211(6):681.e1, 2014
- Kajii T, Ohama K: Androgenetic origin of hydatidiform mole. *Nature* 268: 633, 1977
- Kerkmeijer LG, Wielsma S, Massuger LF, et al: Recurrent gestational trophoblastic disease after hCG normalization following hydatidiform mole in The Netherlands. *Gynecol Oncol* 106:142, 2007
- Khanlian SA, Smith HO, Cole LA: Persistent low levels of human chorionic gonadotropin: a premalignant gestational trophoblastic disease. *Am J Obstet Gynecol* 188:1254, 2003
- Kim SJ, Lee C, Kwon SY, et al: Studying changes in the incidence, diagnosis and management of GTD: the South Korean model. *J Reprod Med* 49:643, 2004
- Kohorn EI: Persistent low-level "real" human chorionic gonadotropin: a clinical challenge and a therapeutic dilemma. *Gynecol Oncol* 85:315, 2002
- Kurman RJ, Carcangiu ML, Herrington CS, et al (eds): WHO Classification of Tumours of Female Reproductive Organs, 4th ed. Lyon, International Agency for Research on Cancer, 2014
- Lage JM, Mark SD, Roberts DJ, et al: A flow cytometric study of 137 fresh hydropic placentas: correlation between types of hydatidiform moles and nuclear DNA ploidy. *Obstet Gynecol* 79:403, 1992
- La Vecchia C, Parazzini F, Decarli A, et al: Age of parents and risk of gestational trophoblastic disease. *J Natl Cancer Inst* 73:639, 1984
- Lavie I, Rao GG, Castrillon DH, et al: Duration of human chorionic gonadotropin surveillance for partial hydatidiform moles. *Am J Obstet Gynecol* 192:1362, 2005
- Lawler SD, Fisher RA: Genetic studies in hydatidiform mole with clinical correlations. *Placenta* 8:77, 1987
- Lawler SD, Fisher RA, Dent J: A prospective genetic study of complete and partial hydatidiform moles. *Am J Obstet Gynecol* 164:1270, 1991
- Lazarus E, Hulka C, Siewert B, et al: Sonographic appearance of early complete molar pregnancies. *J Ultrasound Med* 18:589, 1999
- Lee KH, Lee IH, Kim BG, et al: Clinicopathologic characteristics of malignant germ cell tumors in the ovaries of Korean women: a Korean Gynecologic Oncology Group Study. *Int J Gynecol Cancer* 19:84, 2009
- Lindholm H, Flam F: The diagnosis of molar pregnancy by sonography and gross morphology. *Acta Obstet Gynecol Scand* 78:6, 1999
- Lok CA, Ansink AC, Grootfaam D, et al: Treatment and prognosis of post term choriocarcinoma in The Netherlands. *Gynecol Oncol* 103:698, 2006
- Lok CA, van der Houwen C, ten Kate-Booij MJ, et al: Pregnancy after EMA/CO for gestational trophoblastic disease: a report from The Netherlands. *BJOG* 110:560, 2003
- Loukovaara M, Pukkala E, Lehtovirta P, et al: Epidemiology of hydatidiform mole in Finland, 1975 to 2001. *Eur J Gynaecol Oncol* 26:207, 2005
- Lu WG, Ye F, Shen YM, et al: EMA-CO chemotherapy for high-risk gestational trophoblastic neoplasia: a clinical analysis of 54 patients. *Int J Gynecol Cancer* 18:357, 2008
- Lurain JR, Nejad B: Secondary chemotherapy for high-risk gestational trophoblastic neoplasia. *Gynecol Oncol* 97:618, 2005
- Lurain JR, Singh DK, Schink JC: Management of metastatic high-risk gestational trophoblastic neoplasia: FIGO stage II-IV: risk factor score > or = 7. *J Reprod Med* 55:199, 2010
- Lybol C, Thomas CM, Bulten J, et al: Increase in the incidence of gestational trophoblastic disease in The Netherlands. *Gynecol Oncol* 121(2):334, 2011
- Mackenzie F, Mathers A, Kennedy J: Invasive hydatidiform mole presenting as an acute primary haemoperitoneum. *BJOG* 100:953, 1993
- Maesta I, Berkowitz RS, Goldstein DP, et al: Relationship between race and clinical characteristics, extent of disease, and response to chemotherapy in patients with low-risk gestational trophoblastic neoplasia. *Gynecol Oncol* 138(1):50, 2015
- Mangili G, Garavaglia E, Cavoretto P, et al: Clinical presentation of hydatidiform mole in northern Italy: has it changed in the last 20 years? *Am J Obstet Gynecol* 2008 198(3):302.e1, 2008
- Mangili G, Garavaglia E, Frigerio L, et al: Management of low-risk gestational trophoblastic tumors with etoposide (VP16) in patients resistant to methotrexate. *Gynecol Oncol* 61:218, 1996
- Marcorettes P, Audrezer MP, Le Bris MJ, et al: Diagnosis and outcome of complete hydatidiform mole coexisting with a live twin fetus. *Eur J Obstet Gynecol Reprod Biol* 118:21, 2005
- Massad LS, Abu-Rustum NR, Lee SS, et al: Poor compliance with postmolar surveillance and treatment protocols by indigent women. *Obstet Gynecol* 96: 940, 2000
- Matsui H, Sekiya S, Hando T, et al: Hydatidiform mole coexistent with a twin live fetus: a national collaborative study in Japan. *Hum Reprod* 15:608, 2000
- Matsui H, Suzuka K, Yamazawa K, et al: Relapse rate of patients with low-risk gestational trophoblastic tumor initially treated with single-agent chemotherapy. *Gynecol Oncol* 96:616, 2005
- Merchant SH, Amin MB, Viswanatha DS, et al: p57KIP2 immunohistochemistry in early molar pregnancies: emphasis on its complementary role in the differential diagnosis of hydropic abortuses. *Hum Pathol* 36:180, 2005
- Montz FJ, Schlaerth JB, Morrow CP: The natural history of theca lutein cysts. *Obstet Gynecol* 72:247, 1988
- Moodley M, Tunkyi K, Moodley J: Gestational trophoblastic syndrome: an audit of 112 patients. A South African experience. *Int J Gynecol Cancer* 13:234, 2003
- Mosher R, Goldstein DP, Berkowitz R, et al: Complete hydatidiform mole: comparison of clinicopathologic features, current and past. *J Reprod Med* 43:21, 1998
- Mungan T, Kuscü E, Dabakoglu T, et al: Hydatidiform mole: clinical analysis of 310 patients. *Int J Gynaecol Obstet* 52:233, 1996
- Neubauer NL, Strohl AE, Schink JC, et al: Fatal gestational trophoblastic neoplasia: an analysis of treatment failures at the Brewer Trophoblastic Disease Center from 1979-2012 compared to 1962-1978. *Gynecol Oncol* 138:339, 2015
- Newlands ES, Holden L, Seckl MJ, et al: Management of brain metastases in patients with high-risk gestational trophoblastic tumors. *J Reprod Med* 47:465, 2002
- Newlands ES, Mulholland PJ, Holden L, et al: Etoposide and cisplatin/etoposide, methotrexate, and actinomycin D (EMA) chemotherapy for patients with high-risk gestational trophoblastic tumors refractory to EMA/cyclophosphamide and vincristine chemotherapy and patients presenting with metastatic placental site trophoblastic tumors. *J Clin Oncol* 18:854, 2000
- Ngan HY: The practicability of FIGO 2000 staging for gestational trophoblastic neoplasia. *Int J Gynecol Cancer* 14:202, 2004
- Numnum TM, Leath CA III, Straughn JM Jr, et al: Occult choriocarcinoma discovered by positron emission tomography/computed tomography imaging following a successful pregnancy. *Gynecol Oncol* 97:713, 2005
- Palmer JE, Macdonald M, Wells M, et al: Epithelioid trophoblastic tumor: a review of the literature. *J Reprod Med* 53:465, 2008
- Palmer JR, Driscoll SG, Rosenberg L, et al: Oral contraceptive use and risk of gestational trophoblastic tumors. *J Natl Cancer Inst* 91:635, 1999
- Palmieri C, Dhillon T, Fisher RA, et al: Management and outcome of healthy women with a persistently elevated beta-hCG. *Gynecol Oncol* 106:35, 2007
- Papadopoulos AJ, Foskett M, Seckl MJ, et al: Twenty-five years' clinical experience with placental site trophoblastic tumors. *J Reprod Med* 47:460, 2002
- Parazzini F, Cipriani S, Mangili G, et al: Oral contraceptives and risk of gestational trophoblastic disease. *Contraception* 65:425, 2002
- Parazzini F, La Vecchia C, Mangili G, et al: Dietary factors and risk of trophoblastic disease. *Am J Obstet Gynecol* 158:93, 1988
- Parazzini F, La Vecchia C, Pampallona S: Parental age and risk of complete and partial hydatidiform mole. *BJOG* 93:582, 1986
- Parazzini F, Mangili G, La Vecchia C, et al: Risk factors for gestational trophoblastic disease: a separate analysis of complete and partial hydatidiform moles. *Obstet Gynecol* 78:1039, 1991
- Patel SM, Desai A: Management of drug resistant gestational trophoblastic neoplasia. *J Reprod Med* 55:296, 2010
- Petru E, Luck JH, Stuart G, et al: Gynecologic Cancer Intergroup (GCIg) proposals for changes of the current FIGO staging system. *Eur J Obstet Gynecol Reprod Biol* 143:69, 2009
- Pezeshki M, Hancock BW, Silcocks P, et al: The role of repeat uterine evacuation in the management of persistent gestational trophoblastic disease. *Gynecol Oncol* 95:423, 2004
- Pisal N, North C, Tidy J, et al: Role of hysterectomy in management of gestational trophoblastic disease. *Gynecol Oncol* 87:190, 2002
- Powles T, Savage P, Short D, et al: Residual lung lesions after completion of chemotherapy for gestational trophoblastic neoplasia: should we operate? *Br J Cancer* 94:51, 2006
- Price JM, Hancock BW, Tidy J, et al: Screening for central nervous system disease in metastatic gestational trophoblastic neoplasia. *J Reprod Med* 55:301, 2010
- Rodabaugh KJ, Bernstein MR, Goldstein DP, et al: Natural history of postterm choriocarcinoma. *J Reprod Med* 43:75, 1998
- Rotmensch S, Cole LA: False diagnosis and needless therapy of presumed malignant disease in women with false-positive human chorionic gonadotropin concentrations. *Lancet* 355:712, 2000
- Sasaki S: Clinical presentation and management of molar pregnancy. *Best Pract Res Clin Obstet Gynaecol* 17:885, 2003

- Savage P, Kelpanides I, Tuthill M, et al: Brain metastases in gestational trophoblastic neoplasia: an update on incidence, management and outcome. *Gynecol Oncol* 137(1):73, 2015
- Savage P, Williams J, Wong SL, et al: The demographics of molar pregnancies in England and Wales from 2000-2009. *J Reprod Med* 5:341, 2010
- Schmid P, Nagai Y, Agarwal R, et al: Prognostic markers and long-term outcome of placental-site trophoblastic tumors: a retrospective observational study. *Lancet* 374:48, 2009
- Schorge JO: Gestational trophoblastic disease. In Hoffman BL, Schorge JO, Bradshaw KD, et al: *Williams Gynecology*, 3rd ed. New York, McGraw-Hill Education, 2016
- Sebire NJ, Fisher RA, Foscett M, et al: Risk of recurrent hydatidiform mole and subsequent pregnancy outcome following complete or partial hydatidiform molar pregnancy. *BJOG* 110:22, 2003
- Sebire NJ, Foscett M, Fisher RA, et al: Persistent gestational trophoblastic disease is rarely, if ever, derived from nonmolar first-trimester miscarriage. *Med Hypoth* 64:689, 2005a
- Sebire NJ, Foscett M, Fisher RA, et al: Risk of partial and complete hydatidiform molar pregnancy in relation to maternal age. *BJOG* 109:99, 2002a
- Sebire NJ, Foscett M, Paradinas FJ, et al: Outcome of twin pregnancies with complete hydatidiform mole and healthy cotwin. *Lancet* 359:2165, 2002b
- Sebire NJ, Foscett M, Short D, et al: Shortened duration of human chorionic gonadotrophin surveillance following complete or partial hydatidiform mole: evidence for revised protocol of a UK regional trophoblastic disease unit. *BJOG* 114:760, 2007
- Sebire NJ, Lindsay I, Fisher RA, et al: Overdiagnosis of complete and partial hydatidiform mole in tubal ectopic pregnancies. *Int J Gynecol Pathol* 24:260, 2005b
- Sebire NJ, Rees H, Paradinas F, et al: The diagnostic implications of routine ultrasound examination in histologically confirmed early molar pregnancies. *Ultrasound Obstet Gynecol* 18:662, 2001
- Seckl MJ, Fisher RA, Salerno G, et al: Choriocarcinoma and partial hydatidiform moles. *Lancet* 356:36, 2000
- Seckl MJ, Rustin GJS, Newlands ES, et al: Pulmonary embolism, pulmonary hypertension, and choriocarcinoma. *Lancet* 338:1313, 1991
- Seckl MJ, Sebire NJ, Berkowitz RS: Gestational trophoblastic disease. *Lancet* 376:717, 2010
- Sharma S, Jagdev S, Coleman RE, et al: Serosal complications of single-agent low-dose methotrexate used in gestational trophoblastic diseases: first reported case of methotrexate-induced peritonitis. *Br J Cancer* 81:1037, 1999
- Shih IM, Kurman RJ: Epithelioid trophoblastic tumor: a neoplasm distinct from choriocarcinoma and placental site trophoblastic tumor simulating carcinoma. *Am J Surg Pathol* 22:1393, 1998
- Sita-Lumsden A, Short D, Lindsay I, et al: Treatment outcomes for 618 women with gestational trophoblastic tumours following a molar pregnancy at the Charing Cross Hospital, 2000-2009. *Br J Cancer* 107(11):1810, 2012
- Smith HO, Hilgers RD, Bedrick EJ, et al: Ethnic differences at risk for gestational trophoblastic disease in New Mexico: a 25-year population-based study. *Am J Obstet Gynecol* 188:357, 2003
- Soto-Wright V, Bernstein M, Goldstein DP, et al: The changing clinical presentation of complete molar pregnancy. *Obstet Gynecol* 86:775, 1995
- Stefos T, Plachouras N, Mari G, et al: A case of partial mole and atypical type I triploidy associated with severe HELLP syndrome at 18 weeks' gestation. *Ultrasound Obstet Gynecol* 20:403, 2002
- Sun SY, Melamed A, Goldstein DP, et al: Changing presentation of complete hydatidiform mole at the New England Trophoblastic Disease Center over the past three decades: does early diagnosis alter risk for gestational trophoblastic neoplasia? *Gynecol Oncol* 138:46, 2015
- Suzuka K, Matsui H, Iitsuka Y, et al: Adjuvant hysterectomy in low-risk gestational trophoblastic disease. *Obstet Gynecol* 97:431, 2001
- Taylor F, Grew T, Everard J, et al: The outcome of patients with low risk gestational trophoblastic neoplasia treated with single agent intramuscular methotrexate and oral folinic acid. *Eur J Cancer* 49(15):3184, 2013
- Tham BW, Everard JE, Tidy JA, et al: Gestational trophoblastic disease in the Asian population of northern England and North Wales. *BJOG* 110:555, 2003
- Tidy JA, Gillespie AM, Bright N, et al: Gestational trophoblastic disease: a study of mode of evacuation and subsequent need for treatment with chemotherapy. *Gynecol Oncol* 78:309, 2000
- Tidy JA, Rustin GJ, Newlands ES, et al: Presentation and management of choriocarcinoma after nonmolar pregnancy. *BJOG* 102:715, 1995
- Tse KY, Chan KK, Tam KF: 20-year experience of managing profuse bleeding in gestational trophoblastic disease. *J Reprod Med* (5):397, 2007
- Tuncer ZS, Bernstein MR, Goldstein DP, et al: Outcome of pregnancies occurring within 1 year of hydatidiform mole. *Obstet Gynecol* 94:588, 1999
- Uberri EMH, Fajardo MDC, da Cunha AGV, et al: Prevention of postmolar gestational trophoblastic neoplasia using prophylactic single bolus dose of actinomycin D in high-risk hydatidiform mole: a simple, effective, secure and low-cost approach without adverse effects on compliance to general follow-up or subsequent treatment. *Gynecol Oncol* 114:299, 2009
- van Trommel NE, Lok CA, Bulten H, et al: Long-term outcome of placental site trophoblastic tumor in The Netherlands. *J Reprod Med* 58(5-6):224, 2013
- van Trommel NE, Massuger LF, Verheijen RH, et al: The curative effect of a second curettage in persistent trophoblastic disease: a retrospective cohort survey. *Gynecol Oncol* 99:6, 2005
- Vargas R, Barroilhet LM, Esselen K, et al: Subsequent pregnancy outcomes after complete and partial molar pregnancy, recurrent molar pregnancy, and gestational trophoblastic neoplasia: an update from the New England Trophoblastic Disease Center. *J Reprod Med* 59(5-6):188, 2014
- Wang J, Short D, Sebire NJ, et al: Salvage chemotherapy of relapsed or high-risk gestational trophoblastic neoplasia (GTN) with paclitaxel/cisplatin alternating with paclitaxel/etoposide (TP/TE). *Ann Oncol* 19:1578, 2008
- Williams J, Short D, Dayal L, et al: Effect of early pregnancy following chemotherapy on disease relapse and fetal outcome in women treated for gestational trophoblastic neoplasia. *J Reprod Med* 59(5-6):248, 2014
- Wolfberg AJ, Feltmate C, Goldstein DP, et al: Low risk of relapse after achieving undetectable hCG levels in women with complete molar pregnancy. *Obstet Gynecol* 104:551, 2004
- Wong JM, Liu D, Lurain JR: Reproductive outcomes after multiagent chemotherapy for high-risk gestational trophoblastic neoplasia. *J Reprod Med* 59(5-6):204, 2014
- Yarandi F, Eftekhari Z, Shojaei H, et al: Pulse methotrexate versus pulse actinomycin D in the treatment of low-risk gestational trophoblastic neoplasia. *Int J Gynaecol Obstet* 103:33, 2008
- Zhou Q, Lei XY, Xie Q, et al: Sonographic and Doppler imaging in the diagnosis and treatment of gestational trophoblastic disease: a 12-year experience. *J Ultrasound Med* 24:15, 2005

CHAPTER 11

Lower Genital Tract Procedures

CERVICAL INSUFFICIENCY.....	170
CERCLAGE TECHNIQUES.....	172
CERCLAGE EFFICACY.....	177
DÜHRSSENS INCISIONS.....	181
FEMALE GENITAL MUTILATION AT LABOR AND DELIVERY.....	182
VAGINAL SEPTUM.....	182
CERVICAL BIOPSY.....	182
CERVICAL POLYPECTOMY.....	184

During pregnancy, several conditions may necessitate operative procedures on the vulva, vagina, or cervix. Of surgeries, cervical cerclage is one of the more common. Other procedures are used during delivery and include Dührssens incisions, division of a vaginal septum, and release of female genital mutilation scarring. A brief review of procedures relevant to cervical dysplasia and cervical polyps concludes the chapter.

CERVICAL INSUFFICIENCY

The primary function of the cervix during pregnancy is to keep the uterus and its contents sequestered until controlled cervical dilatation and delivery ensues at term. Failure of this function may result in preterm birth. Thus, to reinforce an insufficient cervix, cerclage procedures are often performed.

When the cervix fails because of an intrinsic weakness during the midtrimester, it has been historically referred to as

cervical incompetence. Today, the term *cervical insufficiency* is preferred to avoid negative connotations. The intrinsic cervical defect classically results in painless dilatation of the cervix with pregnancy loss during the midtrimester. Easterday and Reid (1959) described this process: “The cervix in these patients usually dilates without discomfort, over a period of days or possibly weeks, to the point where the membranes are plainly visible on speculum examination. Unless this is recognized early, the membranes will rupture, and the pregnancy will terminate prematurely.” However, overreliance on this classic history may impede the diagnosis of cervical insufficiency. In fact, early symptoms frequently develop and include urinary frequency and urgency, lower abdominal pressure, or watery discharge (Toaff, 1974). After rupture of membranes, this process may become overtly painful due to contractions, further distention of the cervix, and passage of the uterine contents. Such devastating early losses often recur in subsequent pregnancies, and this supports the concept of intrinsic cervical deficiency.

■ Congenital Etiologies

Intrinsic Genetic and Biochemical Deficiencies

The etiology of this cervical deficiency has been debated and may stem from either congenital or acquired defects. Given that 25 percent of women with a history of cervical insufficiency have a first-degree relative with the condition, a genetic factor seems very plausible (Warren, 2009). As putative elements, extracellular matrix components and several genes have been studied in affected women. Notably, women with prior cervical insufficiency do not have intrinsically low collagen levels within the extracellular matrix, nor do they appear to have an inferior quality of collagen or an excessive number of smooth muscle cells (Oxlund, 2010). Although polymorphisms in certain genes associated with inflammation and collagen metabolism have been identified in women with cervical

insufficiency, their role in intrinsic cervical deficiency remains unclear (Warren, 2009).

During pregnancy, the biochemistry and structure of the cervix undergo important changes. These alterations include significantly decreased stromal stiffness, greater water content, increased sulfated glycosaminoglycan content, increased collagen solubility, and decreased collagen organization (Myers, 2008, 2009). These changes occur early, typically within the first 4 to 6 weeks of pregnancy.

In preparation for labor, further changes develop in the cervix, and these may differ in women with preterm labor. With cervical ripening in both term and preterm cervixes, there is increased transition from high-molecular weight glycosaminoglycans to low-molecular weight hyaluronan. Endocervical levels of hyaluronan at the time of ultrasound-indicated cerclage performed between 15 and 25 weeks are higher in women who delivered preterm as opposed to those delivering at term (Eglinton, 2011). In preterm cervixes, this transition to lower-molecular-weight hyaluronan is associated with increased *Has2* (hyaluronan synthase) gene activity. This contrasts with term cervixes, in which *Has1* dominates (Akgul, 2012).

Diethylstilbestrol Exposure In Utero

Since 1978, numerous cases of cervical insufficiency associated with in utero diethylstilbestrol (DES) exposure have been reported (Goldstein, 1978; Mangan, 1982; Sandberg, 1981; Singer, 1978). Jefferies and colleagues (1984) studied 367 women with complete records regarding DES exposure. They noted that anomalies were strongly tied to gestational week at first dose and total dose. In addition to cervical abnormalities, uterine malformations are also common among women with DES exposure in utero. However, outcomes are not improved by cervical cerclage placement in women with DES exposure in utero (Kaufman, 1984). The Food and Drug Administration made pregnancy a contraindication to use of DES in 1971, and greatly restricted its use as a postcoital contraceptive in 1975. Despite this, DES use continued in several countries, and thus providers should remain vigilant for DES-exposed patients.

Uterine Malformations

Among women with uterine malformations, cervical length has been reported to be shorter. For example, Crane and coworkers (2012) reported that cervical length was significantly shorter in women with bicornuate (3.46 cm) or unicornuate (2.20 cm) uteri compared with low-risk controls (4.32 cm). Women with a uterine malformation were more likely to deliver preterm. Namely, 14 percent delivered before 35 weeks, and 27 percent delivered before 37 weeks compared with 3.3 percent of controls. However, the cause of the increased preterm birth rate is unclear. Distention of a malformed uterus or an intrinsic cervical deficiency associated with uterine malformations has been implicated.

Given this increased risk of preterm birth, a handful of studies have sought to determine the utility of cerclage among women with uterine malformations. In one retrospective study, 30 of 88 women with a prior second-trimester loss had müllerian anomalies of the upper genital tract (Ayers, 1988). These included 12 arcuate, 10 septate, and eight bicornuate uteri. Of these 30 women, 24 (80 percent) had cervical shortening

seen sonographically and underwent cerclage. The remaining six women did not receive a cerclage. Good outcomes were reported in both cohorts. Moreover, among the total population of 88 women, 68 of the 70 women who underwent cerclage delivered after 35 weeks, and of those 18 who did not have cerclage, 95 percent delivered after 35 weeks.

Of specific müllerian defects, Yassaee and Mostafae (2011) reported outcomes in 40 women with bicornuate and arcuate uteri. Women who had a bicornuate uterus and who underwent cerclage had higher term delivery rates than those with a bicornuate uterus and no cerclage—76 percent versus 27 percent, respectively. In contrast, such rates were not significantly different among women with an arcuate uterus and with or without a cerclage. In light of the heterogeneity of uterine malformations and the scant data regarding cerclage in affected women, it remains unclear whether this surgery improves outcomes for women with uterine anomalies in general.

■ Surgically Induced Defects

Conization

For decades, published data have been conflicted with respect to rates of second-trimester losses and preterm birth among women who have undergone cervical conization. Recent literature indicates that this controversy continues. For example, Fischer and coworkers (2010) compared 85 women with a history of cold-knife conization or loop electrosurgical excision procedure (LEEP) and 85 matched controls. Although the average cervical length of women with a history of either procedure was shorter than that of controls—3.3 versus 3.9 cm—the fraction of women with cervical lengths <2.5 cm did not significantly differ between the groups. No woman with a cervical length <2.5 cm delivered prior to 34 weeks, and there were no second-trimester losses consistent with cervical insufficiency. In contrast, Armarnik and associates (2011) analyzed 53 cases of conization—mostly LEEP—among 104,670 deliveries. They found a significantly increased risk of preterm birth before <34 weeks' gestation among the women who had this surgery.

When limited to only include LEEP, controversy exists with respect to the subsequent preterm birth risk. Heinonen and colleagues (2013) found that LEEP—especially repeat procedures—increased the risk of preterm birth. The interval between procedures did not affect this risk. Other studies suggest that short intervals may adversely affect outcomes (Ciavattini, 2015; Conner, 2013). In a study of 241,701 women who were delivered of singleton pregnancies at Parkland Hospital, 511 women had previously undergone LEEP and another 842 had undergone LEEP after the index pregnancy (Werner, 2010). In this group of treated gravidas, the risk of preterm birth was not increased compared with that of the general obstetric population.

Given the lack of agreement as to whether conization increases preterm birth risk, it is no surprise that cerclage has not been shown to benefit such women, and it may cause harm. Zeisler and associates (1997) compared 30 women with prior conization who underwent cerclage with 39 control women who did not receive cerclage. They reported no significant difference in the preterm birth rates (23 and 21 percent, respectively). However, women who underwent cerclage were twice

as likely to be hospitalized for preterm labor—67 percent versus 33 percent, respectively. These authors recommended that prophylactic cerclage should be used more sparingly in women with a history of conization. We agree.

Pregnancy Termination

Several recent studies indicate that pregnancy termination confers a small but statistically significant risk of cervical incompetence and preterm birth. Scholten and coworkers (2013) studied a perinatal database encompassing women with singleton pregnancies that reached at least 20 weeks. Within this database, 16,000 women (1.2 percent) had undergone pregnancy termination, and 90 to 95 percent of these cases involved a surgical method of evacuation. Among this subgroup of women, rates of cervical incompetence treated by cerclage were significantly higher, with an adjusted OR of 1.11. In their review of 37 studies, Shah and associates (2009) found that a single induced pregnancy termination confers a small increased risk for low birthweight and preterm birth but not delivery of a small-for-gestational-age neonate. More than one induced pregnancy termination further increases the risk of low birthweight. Finally, Kilpatrick and colleagues (2006) reported that prior termination before <20 weeks' gestation was associated with previable ruptured membranes and cervical dilatation. Despite this apparently increased risk of preterm birth among women with a prior pregnancy termination, no study has shown a benefit from cerclage. Similar to women with previous conization, expectant management is reasonable for women with a prior pregnancy termination.

CERCLAGE TECHNIQUES

The main surgery for cervical insufficiency involves placement of a cerclage. The timing of this procedure results in three categories of cerclage: ultrasound-indicated, prophylactic (history-indicated), or rescue cerclage. In many cases, these overlap.

Of these, an ultrasound-indicated cerclage is currently favored for women who have a prior loss suggesting cervical insufficiency and who develop cervical shortening during sonographic surveillance. Prophylactic cerclage is generally restricted to women with histories strongly suggesting cervical insufficiency. At our institution, we generally offer a prophylactic cerclage to women who have had a prior cerclage and to women with a history of at least one midtrimester loss that appears attributable to cervical insufficiency. Last, the concept of rescue cerclage, alternatively termed an emergency cerclage, is not well defined. The term is generally used when the cervix is dilated and membranes are visible or prolapsing during the mid-second trimester. Importantly, inevitable abortion or preterm labor is excluded in such cases prior to cerclage placement. If not, the force of uterine contents against cerclage stitches during contractions can ultimately tear the cervix and lead to significant cervical trauma and bleeding.

With the exception of some prophylactic procedures, most cerclages are placed transvaginally. Generally speaking, a transvaginal cerclage is not placed until the second trimester. This is because 15 to 20 percent of pregnancies will abort spontaneously and render a cerclage unnecessary and potentially dangerous from lacerations just described. Prior to cerclage placement, most

practitioners sonographically document fetal cardiac activity and exclude obvious severe or lethal fetal anomalies. In particular, many women undergo first-trimester screening with serum analytes, nuchal translucency, and/or free fetal DNA evaluation.

■ Contraindications

Most authorities do not recommend cerclage after 24 weeks, given the risks for prematurely ruptured membranes and pregnancy loss. At Parkland Hospital, cerclage procedures are generally not done once putative fetal viability is reached after 23 to 24 weeks. Cerclage is not performed in women with a suspected indication for delivery, such as preeclampsia or chorioamnionitis. Preterm labor, active bleeding, or ruptured membranes are other contraindications. Evidence best supports the use of cerclage in singleton pregnancies, and at Parkland Hospital, we currently do not place a cerclage in women with a multifetal gestation. The American College of Obstetricians and Gynecologists (2014) does not recommend the use of cerclage in twin pregnancies.

■ Cerclage Techniques

Several techniques for transvaginal cervical cerclage have been described, including the Lash procedure (1950), Shirodkar cerclage (1955), McDonald cerclage (1957), and the Wurm procedure (Hefner, 1951). In 1965, Benson and Durfee described the transabdominal cerclage, although laparoscopic or robotic placement is increasingly used now. Today, the most commonly used transvaginal procedures are variations of the Shirodkar and McDonald cerclages. Neither appears more effective than the other (Odibo, 2007).

For transvaginal cerclage, no studies guide selection of optimal suture material. In a secondary analysis of a randomized trial evaluating McDonald versus no cerclage, 84 women received polyester braided suture, 46 women received polyester braided tape (Mersilene), and eight women received monofilament suture (Berghella, 2012; Owen, 2009). The women with monofilament suture were excluded from analysis due to the small number. Outcomes did not differ according to suture material.

Shirodkar Technique

In his original manuscript, Dr. Vithal Naresh Shirodkar (1955) described a technique using fascia lata. This has subsequently been replaced by polyester braided surgical tape such as Mersilene. The surgical technique remains similar today and is typically performed as outlined in the subsequent steps.

Regional analgesia is suitable and preferred. The woman is then placed in the standard dorsal lithotomy position, typically using candy-cane stirrups. The vagina and perineum are surgically prepared, drapes are positioned, and the bladder is drained. Some authors do not use antiseptic solution on the exposed amnionic membranes because of the irritative effect and instead use warm saline solution (Pelosi, 1990). That said, no evidence indicates that either method yields superior outcomes.

To begin, a weighted Auvard speculum is placed along the posterior vaginal wall, and the cervix is grasped with DeLee ovum or ring forceps anteriorly, posteriorly, and laterally. Right-angle retractors held by an assistant are used to ensure additional exposure. With traction on the ring forceps, the

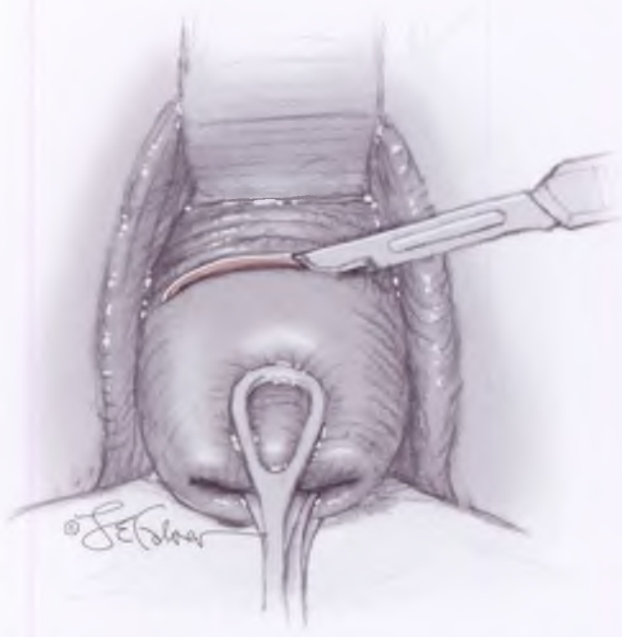


FIGURE 11-1 Modified Shirodkar cerclage. After pulling down with DeLee forceps, a transverse incision is made at the intersection of the smooth epithelium of the portio vaginalis and the rugose epithelium overlying the bladder.

intersection of the cardinal ligament at the lateral aspect of the cervix is palpated and serves to approximate the level of the internal os.

The cervix is then pulled down and a transverse incision is made near the reflection of the bladder (Fig. 11-1). The bladder

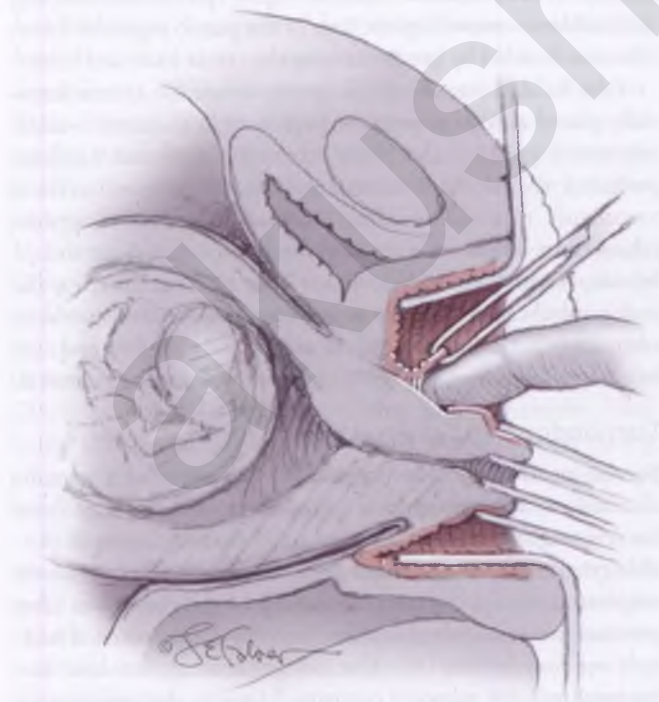


FIGURE 11-3 An Allis clamp attached to the vaginal epithelium is elevated to provide exposure and countertraction to aid dissection. Sharp dissection may occasionally be required, particularly when there has been prior surgery. A similar procedure is performed posteriorly.

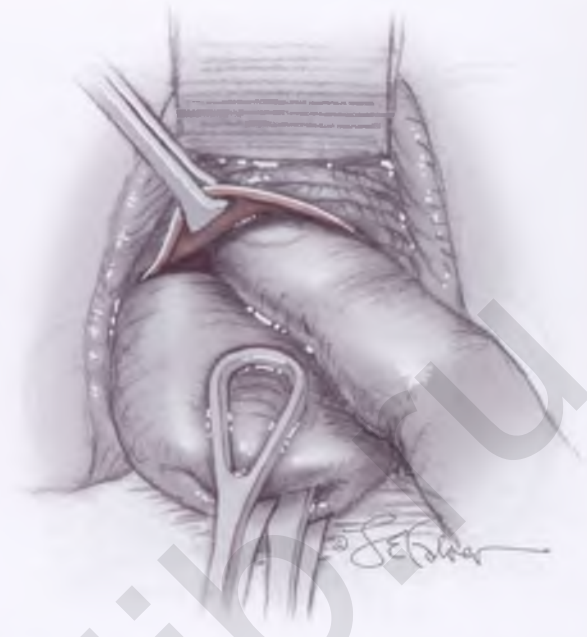


FIGURE 11-2 Beneath the incised vaginal epithelium, the surgeon's finger is used to mobilize the bladder bluntly cephalad to the level of the internal os, near where the vesicouterine peritoneal fold is encountered.

can then be mobilized cephalad. This is often completed with blunt dissection to the level of the internal os and near where the vesicouterine peritoneal fold is encountered (Figs. 11-2 and 11-3). The cervix is then pulled upward, and a transverse incision is made through the vaginal epithelium across the posterior aspect of the cervix. Similar mobilization to the level of the internal os can then be performed posteriorly.

Allis clamps are placed bilaterally at the sides of the cervix and within the dissected span of cervix (Fig. 11-4). The Allis

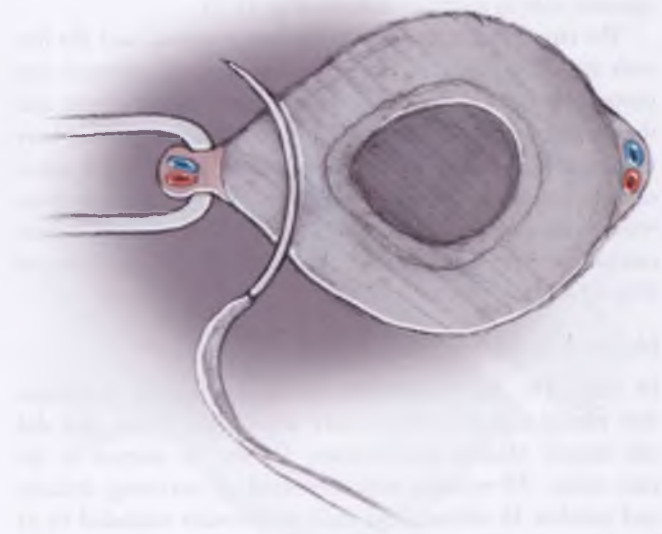


FIGURE 11-4 Allis clamps are applied bilaterally at the sides prior to passing the needles of the Mersilene tape just under the tip of the clamp. Importantly, these clamps are intended to “bunch” the paracervical vessels within the clamp and pull them laterally prior to needle placement.

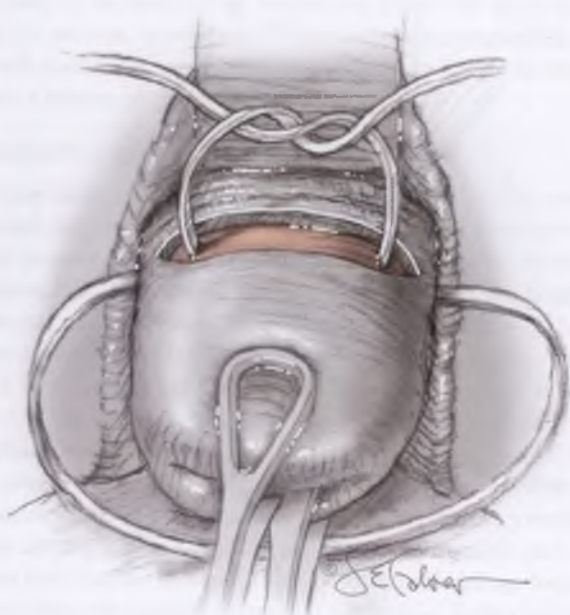


FIGURE 11-5 The 5-mm Mersilene tape is lubricated with sterile gel lubricant and advanced from posterior to anterior on the right and left sides. Care is taken to not pass the needles too deeply and to ensure that the tape lies flat and without twists.

clamps are closed with the objective of bunching the paracervical vessels within the clamp and pulling them laterally. This allows the needle and suture to pass under the clamp tip while avoiding paracervical vessel puncture (Rust, 1967). A 5-mm Mersilene tape that is armed on each end with a needle is lubricated with sterile gel lubricant. One needle is then advanced from posterior to anterior on one side (Harger, 1980). Importantly, passing the needle too deep risks membrane rupture. The tape ideally lies flat and without twists across the posterior aspect of the cervix. The other needle is then advanced on the opposite side in a similar fashion (Fig. 11-5).

The tape is tied anteriorly to aid later removal, and the free ends are left exposed. As originally described, the anterior and posterior incisions were closed with chromic catgut suture, and the patient was anticipated to deliver by cesarean. To aid later tape removal, the previous edition of this book did not advocate closure of the incisions unless there was bleeding. For those who prefer to close the incisions, a tail of the cerclage suture can be left to protrude through the incision to aid later removal (Fig. 11-6) (Curet, 1980).

McDonald Technique

In 1957, Dr. Ian McDonald described a simpler technique that placed a purse-string suture around the cervix and did not require bladder mobilization. Of the 70 women in his case series, 33 women were delivered of surviving infants, and another 16 women had their pregnancies extended by at least 4 weeks. The surgical procedure used today is similar to McDonald's original description, but a nonabsorbable suture is typically used. Options include a no. 1 or 2 monofilament nylon or polypropylene suture, a polyester braided suture, or Mersilene tape.

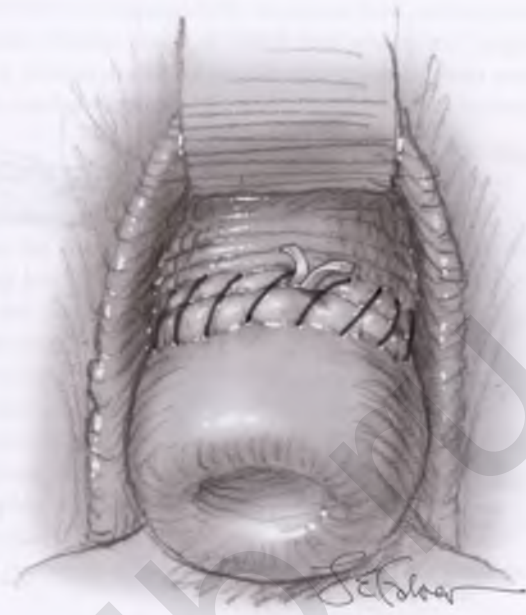

FIGURE 11-6 The Mersilene tape is then tied anteriorly with the cut free ends left exposed to ease later removal. The vaginal epithelium may be closed, as in this figure, with a running suture line.

As with the Shirodkar cerclage, spinal analgesia is recommended by most. The woman is placed in standard dorsal lithotomy position and prepared as described in the previous section. The cervix is grasped with DeLee ovum or ring forceps, and the cervicovesical junction is identified. One marker of this junction is the transition from the rugose epithelium overlying the bladder to smooth epithelium of the portio vaginalis. Identification is aided by gently moving the cervix back and forth.

Four to six bites of a purse-string suture are circumferentially placed as high as possible, beginning at the cervicovesical junction (Figs. 11-7 and 11-8). At the 3 o'clock and 9 o'clock positions, the needle is maneuvered under the lateral cervical vasculature to avoid bleeding. McDonald cautioned against taking bites that are too shallow posteriorly, and these should be deep enough to include the stroma without entering the endocervical canal. The knot is tied anteriorly, typically without completely occluding the endocervical canal. The free ends are left long enough to more easily identify them for later removal.

Transabdominal Cervicoisthmic Cerclage

Benson and Durfee (1965) described placement of a transabdominal cerclage for women who are not suitable candidates for transvaginal cerclage. One of the following serves as possible criterion: "(1) an obvious congenitally short or extensively amputated cervix; (2) marked scarring of the cervix—as after previous unsuccessful cervical cerclage; (3) deeply notched multiple cervical defects; (4) unhealed, penetrating, forniceal lacerations; and (5) subacute cervicitis." Due to the significantly increased risk of bleeding and complications associated with transabdominal cerclage, Rand and Norwitz (2003) recommend that the transabdominal approach be reserved for selected patients. Examples include women with failed transvaginal

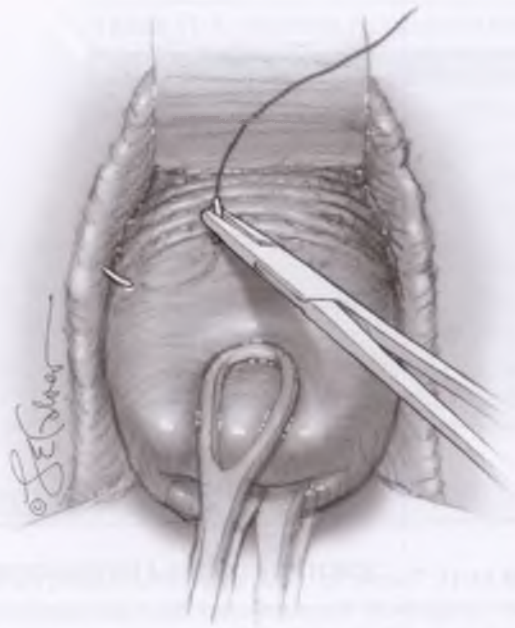

FIGURE 11-7 McDonald cerclage. The cervix is grasped with DeLee ovum forceps, and the cervicovesical junction is identified at the intersection of the smooth epithelium of the portio vaginalis and the rugose epithelium overlying the urinary bladder. A non-absorbable suture with attached needle is used to begin a purse-string suture at the 12 o'clock position.

cerclages or those in whom a transvaginal cerclage is technically impossible to perform because of extreme cervical shortening, scarring, or laceration. The recommendations of Rust and Roberts (2005) are similar.

Placement of a cervicoisthmic cerclage was originally described using laparotomy, but several reports additionally detail laparoscopic or robotically assisted cervicoisthmic cerclages (Foster, 2013; Menderes, 2015; Moore, 2012; Riiskjaer, 2012; Tulandi, 2014). Although transvaginally placed cervicoisthmic cerclages have been described, these are essentially modifications of the Shirodkar technique that seek higher placement (Golfier, 2001; Katz, 2005).

Transabdominal cerclage placement becomes increasingly difficult with an enlarging uterus. Therefore, women ideally undergo cerclage before pregnancy or at 11 to 14 weeks' gestation, but after initial screening for aneuploidy and obvious malformation is completed (Rand, 2003). Tulandi and colleagues (2014) evaluated 16 studies involving 678 pregnancies. They found that results of placement before pregnancy and during pregnancy were similar, whether performed laparoscopically or by laparotomy. Placement before conception is more practical.

Following induction of general anesthesia, the patient is positioned supine, the abdomen and vagina are surgically prepared, and a Foley catheter is inserted. A Pfannenstiel incision provides suitable access. After entry into the abdomen, the vesicouterine peritoneal reflection is incised, and the vesicouterine space is entered. The loose connective tissue in this space is easily disrupted bluntly or sharply to permit caudal mobilization of the bladder (Fig. 11-9). The bladder is moved to expose the uterine isthmus.

The uterine artery is identified bilaterally, and this is aided by gentle upward traction of the uterine fundus. Invaluable

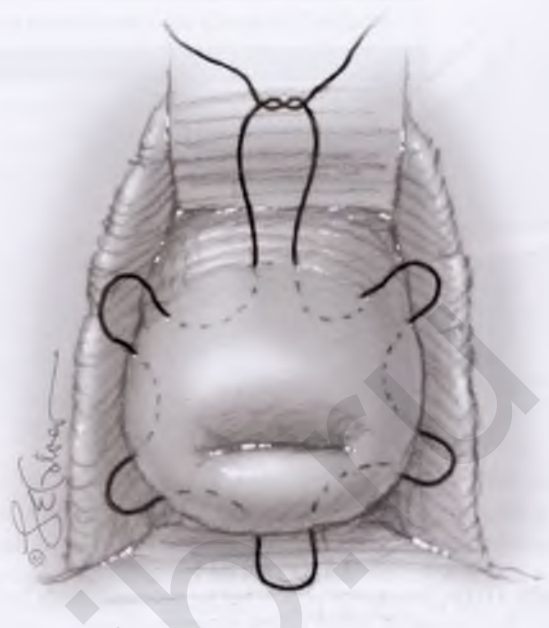

FIGURE 11-8 The needle is maneuvered under the lateral cervical vasculature at the 9 o'clock position to avoid bleeding. One to 2 bites are taken posteriorly and deep enough to purchase adequate cervical stroma without traversing the endocervical canal. This is repeated at the 3 o'clock position. The knot is tied anteriorly with multiple (typically eight) throws when using nonabsorbable suture. The free ends are left long enough to aid their later identification during cerclage removal.

comments by Benson and Durfee (1965) describe the uterine vessels and a potential "free space" that lies between these vessels and the lateral aspect of the uterine isthmus at the level of the internal os. They encourage careful dissection to define this space, while avoiding the ureter, which lies posterolateral

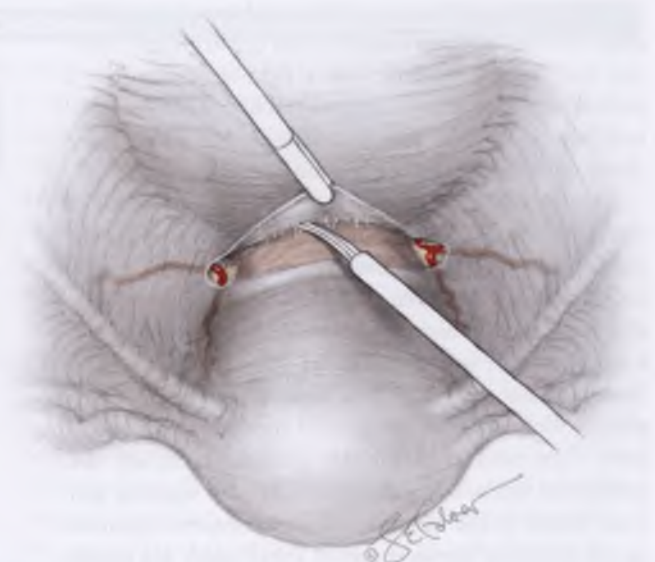


FIGURE 11-9 Transabdominal cervicoisthmic cerclage. Following incision of the vesicouterine peritoneal reflection, sharp dissection proceeds caudally within the vesicouterine space. This allows the bladder to be mobilized caudally to the level of the uterine isthmus.

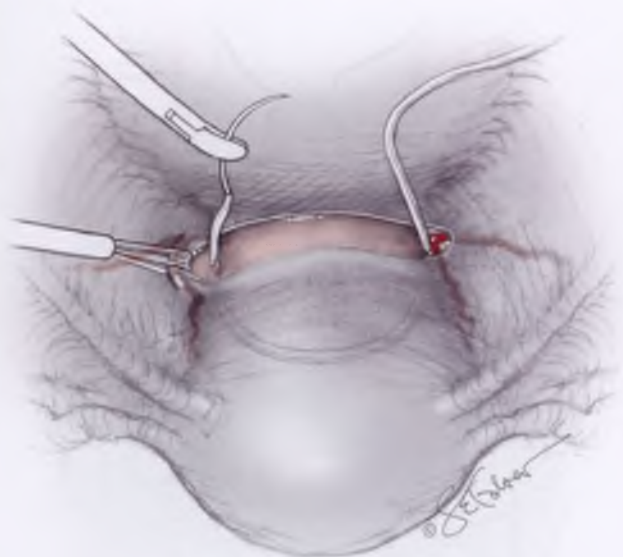


FIGURE 11-10 The uterine vessels will be prominent near the level of the internal os, which is typically approximately 1 cm superior to the insertion of the uterosacral ligaments. In the area of the internal os, a window is made in free space medial to the vessels. This avoids vessel compression by the tightened cerclage. Care is also taken to avoid the ureter, which is lateral and posterior.

(Fig. 11-10). Subsequently, the broad ligament's posterior leaf is punctured in an avascular area on each side of the uterus. This allows the Mersilene tape to be threaded through the broad ligament and the avascular space at a level just above the cervicoisthmic junction. Passing the tape medially to the uterine vessels avoids their occlusion when the cerclage is tied.

The Mersilene strand is then passed around the isthmus and tied. Suture may be passed anterior to posterior, and the knot tied behind the uterus (Herron, 1988). Alternatively, suture ends may be threaded so that they are knotted at the front of the uterus.

With their modification, Debbs and associates (2007) grasp the uterine vessels laterally at the cervicoisthmic junction and create a window with a right-angle clamp at a point 1 cm superior to the uterosacral ligaments. An assistant then passes the 5-mm Mersilene tape on a long Kelly clamp to the open right-angle clamp.

These needleless approaches can minimize the risk of vessel puncture and hemorrhage, particularly during laparoscopic approaches (Menderes, 2015). Alternatively, for laparoscopy, Mersilene tape attached to blunt needles that have been straightened, to enable passage through a trocar, can be used (see Fig. 11-10) (Tusheva, 2012). These authors described their laparoscopic approach to placing the cerclage at the level of the internal os as follows: "The landmarks for this placement include the uterosacral ligaments; a distance of 1.5 cm superior and 1 cm lateral to the insertion of the uterosacral ligament on the posterior uterus is a good initial guide for needle placement. The needles are then cut off and removed, and the Mersilene suture is then tied tightly around the cervix with six knots using intracorporeal knot tying." The bladder flap is typically replaced over the cerclage with

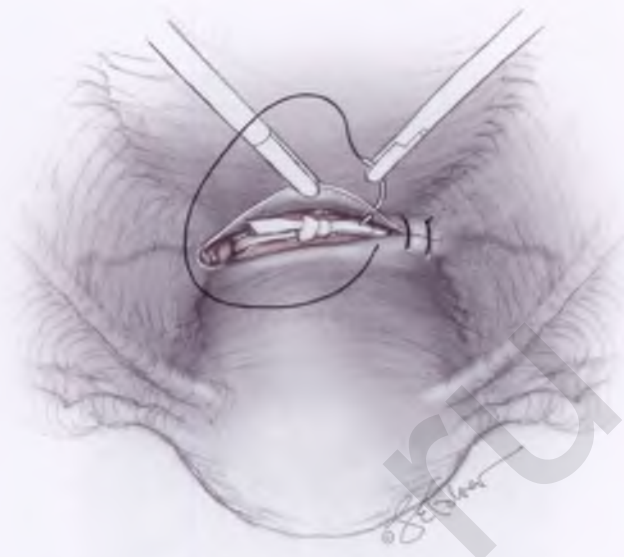


FIGURE 11-11 There is no consensus whether passing the suture anterior to posterior or vice versa is superior. In this case, the knot is tied anteriorly, and the vesicouterine peritoneum is closed with absorbable suture in a running fashion.

absorbable suture for both open and laparoscopic approaches (Fig. 11-11).

Emergency/Rescue Cerclage

The chief difficulty that distinguishes the emergent or rescue cerclage from those described previously is that the cervix has begun to dilate and efface, and typically the membranes are exposed. Frequently, the membranes are protruding from an open cervix, and numerous techniques for reducing the membranes have been described (Table 11-1). Of these, use of a moist swab or sponge stick is shown in Figure 11-12.

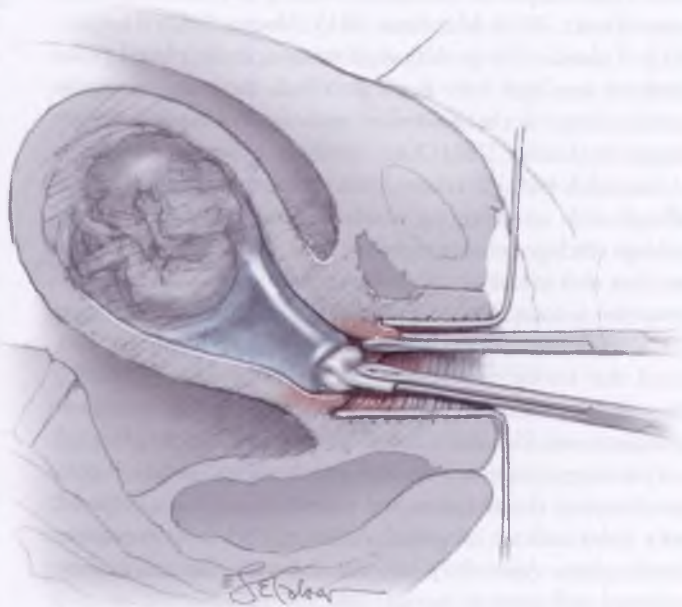


FIGURE 11-12 At times, the membranes may be exposed or prolapsed, creating interference and the potential for their inadvertent rupture. Traction with DeLee ovum forceps on the cervix combined with gentle elevation of a moistened sponge swab can push the membranes cephalad. Several other techniques to reduce exposed membranes are listed in Table 11-1.

TABLE 11-1. Methods Proposed to Reduce Protruding Membranes for Cervical Cerclage

Method	Investigator
Traction on cervical edges	Daskalakis, 2006; Yip, 1998
Moist swab to reduce	Olatunbosun, 1981; Daskalakis, 2006
General anesthesia	MacDougall, 1991; Olatunbosun, 1981; Yip, 1998
Multiple cervical stay sutures	Olatunbosun, 1981
Overfilling the bladder	Scheerer, 1989
Amnioreduction	Locatelli, 1999; MacDougall, 1991
Foley catheter	MacDougall, 1991; Yip, 1998
Inflated balloon	Tsatsaris, 2001
Steep Trendelenburg position	MacDougall, 1991; Olatunbosun, 1981; Tsatsaris, 2001; Yip, 1998
Knee-chest position	Ogawa, 1999

CERCLAGE EFFICACY

■ Transvaginal Cerclage Efficacy

Several randomized trials have evaluated transvaginal cerclage efficacy. Three of the earliest focused on placement of a prophylactic cerclage based on obstetric history. These are summarized in [Table 11-2](#).

More recent randomized trials have studied sonographic screening of cervical length to guide cerclage placement. As shown in [Table 11-3](#), screened cohorts were diverse and included women at low risk for pregnancy complication and women at risk for preterm birth. Of six prospective trials that investigated primarily singleton pregnancies, the results have been mixed. Four studies reported no benefit, and two showed more favorable outcomes.

The trial by Owen and colleagues (2009) focused specifically on at-risk women, that is, those with prior deliveries before 34 weeks who were screened for cervical shortening. It is one

of the largest randomized trials on the topic and thus forms the basis of current recommendations regarding screening for cervical insufficiency and intervention. Given that transvaginal sonographic screening of cervical length was used in this study to identify cerclage candidates, and in light of the reported secondary outcomes, such screening is now recommended by both the American College of Obstetricians and Gynecologists (2014) and the Society for Maternal-Fetal Medicine (2015) beginning at 16 weeks' gestation for at-risk women.

This surveillance typically begins at 2-week intervals between transvaginal ultrasound assessments. The surveillance is changed to weekly if the cervical length shortens to measure less than 30 mm but longer than 25 mm. If the cervix shortens to measure less than 25 mm before 24 weeks in a woman with a prior spontaneous preterm birth that occurred before 34 weeks, then most authorities recommend that a cerclage be offered.

These criteria broaden the eligibility for cerclage from those meeting the strict definition of cervical insufficiency to women with a history of spontaneous preterm birth before 34 weeks

TABLE 11-2. Randomized Controlled Trials of Cerclage Based on Obstetric History

Study	n	Obstetric History	Outcomes
Rush, 1984	194	History of 2 to 4 pregnancies that ended spontaneously before 37 weeks, with at least 1 pregnancy that ended spontaneously between 14 and 36 weeks	No significant differences for rates of preterm birth before 37 weeks, low birthweight, neonatal mortality or morbidity. Cerclage patients had significantly longer hospitalizations. 18 of 96 women with cerclage and 12 of 98 women without cerclage had ruptured membranes ($p = NS$)
Lazar, 1984	506	Complex multifactor scoring chart: women with a moderate risk of preterm birth (scores ≥ 9 but < 20) were eligible	No significant differences in the rates of preterm birth or perinatal deaths. Women with cerclage were twofold more likely to be hospitalized ($p < .001$)
MRC/RCOG, 1993	1292	Women were eligible if their obstetricians were uncertain whether to advise them to have a cerclage based on prior history	Fewer deliveries before 33 weeks (13 vs 17%, $p = .03$) and fewer very-low-birthweight neonates (10 vs 13%, $p = .05$) in the cerclage group, but the overall preterm birth rates were not significantly different (26 vs 31%, $p = .07$). Rates of miscarriage, stillbirth, and neonatal death did not differ. Hospital admission and tocolysis was more common in the cerclage group, among which there was a twofold increased risk of puerperal fever ($p = .03$)

MRC/RCOG = Medical Research Council/Royal College of Obstetricians and Gynaecologists Working Party on Cervical Cerclage; n = number of study patients; NS = not significant.

TABLE 11-3. Randomized Controlled Trials of Cerclage Using a Screening-Based Approach

Study	n	Cervix Characteristics	Outcomes
Rust, 2000	61	Sonographic screening between 16 and 24 weeks for prolapse of the membranes for >25% of the total cervical length or a distal cervical length <2.5 cm	No significant differences at initial exam with respect to internal os dilatation, depth of membrane prolapse, or distal cervical length. No differences in preterm birth rates before 37, 34, or 28 weeks. No differences in neonatal morbidity or death rates
Althuisius, 2001	35	Cervical length <25 mm before 27 weeks; randomized to cerclage and bed rest or bed rest alone	0 of 19 randomized to cerclage delivered before 34 weeks compared with 7 of 16 (44%) without cerclage ($p = .002$). No significant differences in neonatal survival rates, but compound neonatal morbidity was 5% for cerclage vs 50% for no cerclage ($p = .005$)
Berghella, 2004	61	Asymptomatic with a cervical length <25 mm or more than 25% funneling. Enrolled women were either those at high risk of preterm birth due to history and surveilled sonographically or were low-risk women with cervical changes found incidentally	No significant difference for the primary outcomes of preterm birth <35 weeks (45% for cerclage group vs 47% for no cerclage group). A subgroup analysis of singleton pregnancies with a prior history of preterm birth <35 weeks and a short cervix also did not show significant differences
To, 2004	253	47,123 women were screened and 470 women with a cervical length of ≤ 15 mm identified; 253 consented to participate	No significant difference in rates of preterm birth before 33 weeks or rates of perinatal or maternal morbidity
Simcox, 2009	248	Randomized to either cerclage based on history alone or cerclage for a cervical length <20 mm	No significant differences in the mean gestational age at delivery, delivery before 34 weeks, or delivery between 24 and 34 weeks. No significant differences with respect to neonatal outcomes. More interventions were performed among women randomized to sonographically indicated cerclage
Owen, 2009	302	1014 women with a prior spontaneous preterm birth before 34 weeks were screened for a short cervix <25 mm. Women with acute cervical insufficiency, defined as a dilatation of 2 cm with membranes visible, were ineligible	Primary outcome was delivery before 35 weeks: no significant difference (32% in cerclage group vs 42% in the no cerclage group, $p = .09$). Secondary outcomes: preterm birth before 24 weeks (6% in cerclage vs 14% in no cerclage group, $p = .03$), preterm birth before 37 weeks (45% in the cerclage vs 60% in the no cerclage group, $p = .01$), perinatal death (9% in the cerclage group vs 15% in the no cerclage group, $p = .046$). In a logistic regression model, a cervical length of <15 mm was associated with fewer preterm births <35 weeks for cerclage (OR 0.23, $p = .006$)

n = number of study patients; OR = odds ratio.

who are found to have a short cervix (<25 mm) before 24 weeks. Based on these data by Owen and coworkers (2009), ACOG (2014) opines that screening for a short cervix and cerclage placement in such women may reduce the preterm birth rate. Further, ACOG recommends a screening-based approach, as it might prevent unnecessary procedures in more than half of women with a prior preterm birth who do not have cervical shortening in a subsequent pregnancy. This benefit does not extend to women with only a short cervix before 24 weeks and no history of spontaneous preterm birth. For such women, progesterone-based therapy is currently recommended (American College of Obstetricians and Gynecologists, 2014).

With respect to a history-indicated cerclage, ACOG (2014) states that such a cerclage is appropriate when there is a history of at least one second-trimester loss related to painless cervical dilatation without labor or placental abruption, or when there is a history of prior cerclage for such an indication. Recommendations of the Society for Maternal-Fetal Medicine (2015) are generally consistent with those of ACOG. One caveat is that for cerclage based on history alone, only a history of three or more preterm births or second-trimester losses has been associated with benefit.

At Parkland Hospital, we offer cerclage to women with a history of at least one prior second-trimester loss consistent with cervical insufficiency. Women are not routinely screened for a

TABLE 11-4. Varying Criteria Used for Studies Describing Rescue or Emergent Cerclages for a Dilated Cervix

Study	n	Gestational Age (weeks) at Cerclage	Description of Cervix
Olatunbosun, 1981	12	Mean 21.4 (range 16–28)	Cervical effacement $\geq 50\%$, cervical dilatation ≥ 4 cm, herniation of intact membranes through open cervix
Scheerer, 1989	4	Range 21–23	Dilated 3–5 cm, with membranes prolapsed 3–7 cm through the external os into the vagina
MacDougall, 1991	19	Range 16–28	Dilated 3–10 cm
Yip, 1998	19	Range 16–30	Dilated at least 1 cm (mean 2.5 cm, range 1–6 cm) with herniated membranes
Kurup, 1999	35	Mean 22.3 \pm 0.4	Emergent: pelvic pressure, clear vaginal discharge, cervix ≥ 2 cm, absence of regular uterine contractions, absence or presence of membranes at or beyond the external os
	15	Mean 20.8 \pm 0.6	Urgent: “beaking” of amniotic fluid at the internal os identified sonographically
Mays, 2000	18	NS	Cervix dilated at least 2 cm and 50% effaced; membranes visible at the external os

n = number of study patients; NS = not stated.

short cervix. However, women with a history of preterm birth who are incidentally noted to have a short cervix (<25 mm) are considered for cerclage.

■ Transabdominal Cervicoisthmic Cerclage Efficacy

There are no randomized trials of transabdominal cerclage. Davis and associates (2000) retrospectively compared 40 cases of transabdominal cerclage with 24 cases of transvaginal prophylactic cerclage. Preterm prematurely ruptured membranes occurred less often among women with a transabdominal cerclage (8 versus 29 percent). In addition, preterm births before 33 and 35 weeks' gestation were fewer among women who received transabdominal cerclage—10 versus 38 percent and 18 versus 42 percent, respectively. Consistent with this, the gestational age at delivery was later among women with transabdominal cerclage—mean 36.3 versus 32.8 weeks.

Lotgering and colleagues (2006) also reported benefits for transabdominal cerclage in their study of 101 women. Before placement of a transabdominal cerclage, 76 percent of the women had prior deliveries before 32 weeks, and the neonatal survival rate was 28 percent. After cerclage placement, the rates were 7 and 94 percent, respectively. These authors reported that blood loss at the time of transabdominal cerclage was at least 500 mL in three women. Membranes ruptured in two cases. All women ultimately underwent cesarean delivery. In this study, women were eligible for transabdominal cerclage if they had a “classic” history of cervical insufficiency, with at least two successive pregnancy losses in the second or early third trimester, and a cervix that precluded placement of a transvaginal cerclage because it was very short, scarred, or partially absent. For women meeting such criteria, consideration of a transabdominal cerclage seems reasonable.

■ Rescue or Emergency Cerclage Efficacy

There is no agreed-upon definition of what constitutes a rescue cerclage. Thus, the literature varies particularly with respect to

degree of cervical dilation, although in most cases some degree of membrane visibility or prolapse is present (Table 11-4). The wide-ranging criteria for defining an emergency or rescue cerclage parallel the variable success rates reported.

Recent reports emphasize the risks of these procedures, particularly when the cervix is more dilated. Predictors of poor outcomes after emergency cerclage include prolapsed membranes, infection, cerclage placed after 22 weeks' gestation, a cervix dilated more than 3 cm, or symptoms such as low-back pain, pelvic pressure, mild cramping, or bloody or mucous discharge (Namouz, 2013). One large case series reported outcomes for 110 women treated with emergency cerclage (Fortner, 2012). They compared women with cervical dilation measuring 2 cm or more with women with cervical dilation less than 2 cm. Gestational age at cerclage placement did not vary between the two groups. However, women with the greater cervical dilation delivered at an earlier gestational age—27 versus 36 weeks. Nelson and colleagues (2014) found that subsequent chorioamnionitis complicated nearly half of emergent cerclage cases. Of note, in a study of maternal morbidity and mortality from sepsis, rescue cerclage was a risk factor (Bauer, 2013).

For women facing a poor pregnancy prognosis due to cervical dilation and prolapsing membranes in midgestation, it seems reasonable to offer emergency or rescue cerclage with appropriate counseling. However, it is unclear if such interventions truly confer a benefit or merely increase the risk of membrane rupture and infection.

■ Amniocentesis before Cerclage

Diagnostic amniocentesis prior to cerclage was hoped to identify markers of occult, early amnionitis to further aid cerclage candidate selection. Mays and associates (2000) retrospectively described the outcomes of 18 women dilated at least 2 cm with membranes visible at the external os who underwent rescue cerclage. They reported better outcomes among the women with culture-negative amniocentesis results prior to cerclage

placement. However, improved outcomes were not reported by Airoldi and coworkers (2009), who performed amniocentesis between 15 and 25^{6/7} weeks in 122 women with a 1- to 4-cm dilated cervix. The rate of preterm birth before 28 weeks in women who underwent preoperative amniocentesis was higher than those who did not have amniocentesis (58 versus 34 percent). However, after multivariate logistic regression, amniocentesis was not an independent contributor to preterm birth before 28 weeks.

Many different markers of infection within amniotic fluid have been studied and include concentrations of various cytokines, glucose levels, leukocyte count, and culture. Most investigations have compared these markers with the results of culture, but some studies have paired these with placental histology or delivery within 24 hours (Edwards, 2001; Greig, 1994; Odibo, 1999). None of these markers is superior. Of cytokines, no commercially available assay has proven any one to be a reliable marker of intraamniotic infection.

Glucose studies are also inherently problematic, given that there is no agreed-upon threshold for what constitutes an abnormally low level. Reported levels range from 5 to 25 mg/dL (Dildy, 1994; Edwards, 2001; Greig, 1994; Kiltz, 1991). Sensitivities, specificities, positive-predictive values, and negative-predictive values vary widely. The difficulty of choosing any particular threshold is confounded by the great variance in normal amniotic-fluid glucose values, which are influenced by glucose intolerance, blood glucose levels, amniotic-fluid volume, and gestational age (Dashe, 2000; Oliveira, 2002; Spellacy, 1973; Weiss, 1985; Weissman, 2003).

In sum, no randomized trial has demonstrated that a management decision based on amniocentesis using a marker associated with intraamniotic infection leads to improved outcomes. Accordingly, amniocentesis to detect infection prior to cerclage is not recommended.

■ Indomethacin or Antibiotics

Indomethacin is one nonsteroidal antiinflammatory drug (NSAID) that inhibits transformation of arachidonic acid into prostaglandins. Some prostaglandins promote uterine contractility and cervical ripening. Thus, investigators have evaluated indomethacin in women undergoing cerclage to complement surgical effects. Berghella and colleagues (2009) investigated the effect of indomethacin for 222 singleton pregnancies with a dilated cervix of at least 1 cm between 14 and 25^{6/7} weeks. Indomethacin was administered in a third of cases, but this did not improve pregnancy outcomes whether cerclage was placed or not. In contrast, Miller and associates (2014) reported a possible benefit of indomethacin. Fifty-three women with preterm cervical dilatation between 16 and 24 weeks were randomly assigned to no intervention or to oral indomethacin 50 mg every 8 hours for three doses plus antibiotics (cefazolin or clindamycin). Three women were lost to follow-up. Of evaluable pregnancies allocated the nonintervention arm, only 63 percent were prolonged by at least 28 days compared with 92 percent in the intervention arm. Despite this, gestational age at delivery and neonatal outcomes did not differ significantly. At this time, the utility of indomethacin and antibiotics at the time of cerclage placement remains uncertain.

■ Cervical Occlusion

A multicenter randomized trial of cervical cerclage with and without cervical occlusion was halted early due to slow recruitment and a futility analysis showing no benefit (Brix, 2013). For cervical occlusion, the circumferential suture is tightened until the cervical canal is closed. There were two trials to the study, and in both the prophylactic trial (197 women) and the therapeutic trial (87 women), there were arms for cervical occlusion and no cervical occlusion. From data accrued before both trials were halted, cervical occlusion had no effect on gestational age at delivery or time spent in the neonatal intensive care unit.

■ Additional Stitch Placement

Funai and coworkers (1999) reported that cerclage increases the measurable cervical length. Since then, a more proximally placed stitch or a greater length of functional cervix inferior to the suture correlates with improved cerclage success (Althuisius, 2002; Scheib, 2009). In recognition of this, a second suture placed more cephalad to the first has been attempted (Giraldo-Isaza, 2013; Park, 2012; Pergialiotis, 2015; Woensdregt, 2008). However, the bulk of studies have not yielded improved outcomes. Based on a metaanalysis, Berghella and associates (2013) recommended placement of a single suture as cephalad as possible.

■ Cerclage Complications

Risks for complications depend on the cerclage type. Other factors include the diameter of initial cervical dilatation and the surface area of membranes that are exposed or protruding through the cervix. Logically, membrane rupture is a risk and can occur either during the procedure or sometime thereafter. Chorioamnionitis may follow membrane rupture but may also develop after a cerclage without overt evidence of rupture. As noted earlier, rescue cerclage is an independent risk factor for severe sepsis.

Other potential complications include suture displacement and cervical lacerations. One can envision how a cerclage might fail due to displacement of the suture, either immediately while trying to close the cervix prior to tying the knot or after completion of surgery. This tearing of the suture through the cervix, leading to cervical laceration, might be more likely to occur after shallow bites in a markedly thinned or attenuated cervix, or if the cervix undergoes further softening during labor. Depending on the extent of the tear, this can lead to obvious cervical laceration, and potentially further cervical dilatation. Aarnoudse and Huisjes (1979) reported that suture displacement complicated 7 of 52 cases (14 percent). Harger (1980) reported obvious cervical laceration at delivery in 14 percent of women with McDonald cerclages and 11 percent of women with Shirodkar cerclages. This compared with lacerations in only 2.2 percent of the 55,688 women without cerclage. More recent, large studies indicate that cerclage is associated with cervical laceration at delivery (Landy, 2011; Melamed, 2009; Parikh, 2007).

In addition, damage to the genitourinary system can include bladder and ureteral injuries and fistula. Bladder injuries are rare but include delayed complications from retained misplaced suture (Ruan, 2011). More seriously, injury to the ureter and urinary tract fistulas have been reported after cerclage.

These include ureterovaginal fistula after a McDonald cerclage, vesicocervical fistula after a Shirodkar cerclage, cervicovaginal fistula after a transvaginal cerclage, and vesicovaginal fistula (Berchuck, 1984; Grotegut, 2010; Madueke-Laveaux, 2013; McKay, 2003; Ng, 2015; Wall, 2007). Prior cerclage is one risk factor for genitourinary fistula (Massengill, 2012).

Occasionally, there is severe hemorrhage, particularly with abdominal cerclage. During this procedure, Herron and Parer (1988) reported blood loss as the most common complication. Three of eight women were transfused after a procedure-related puncture of the uterine artery.

For women who manifest cervical change after placement of a cerclage, repeat cerclage has been attempted. In one study, 26 women with a McDonald cerclage were subsequently surveilled sonographically for cervical change (Fox, 1998). Twelve had further cervical change and underwent repeat cerclage, with delivery delayed by an average 7 weeks. Apart from this study, however, few data indicate that reoperation confers a benefit.

■ Cerclage Removal after Membrane Rupture

During the past few decades, some retrospective studies have suggested harm, particularly due to infection and sepsis, with cerclage retention after membrane rupture (D Laskin, 2012; Ludmir, 1994). However, others have suggested no significant differences in risk (Kominiarek, 2006; McElrath, 2000, 2002). In one randomized trial, Galyean and colleagues (2014) evaluated cerclage removal versus retention in women with ruptured membranes. Unfortunately, the trial was halted early due to the results of a futility analysis and after randomization of only 56 subjects. In the 24 women who were randomized to cerclage retention and the 32 to removal, the primary study outcome, which was prolonging pregnancy by 1 week, did not differ significantly. The chorioamnionitis rate with retention was higher—42 percent versus 25 percent, respectively, although this difference was not significant. Moreover, there were no significant differences with respect to rates of composite neonatal morbidity—56 percent versus 50 percent; perinatal death—16 percent versus 12 percent; or gestational age at delivery—198 versus 200 days, respectively.

In sum, the question of whether to remove a cerclage or leave it in place after premature rupture of membranes remains unresolved. It seems reasonable to discuss options with the patient, including potential risks of infection, without mandating a particular strategy. The American College of Obstetricians and Gynecologists (2014) states that either action is reasonable in this setting. That said, signs of chorioamnionitis should prompt delivery.

■ Cerclage Removal and Labor

If labor ensues, cerclage removal is indicated to avoid cervical laceration and uterine rupture (Chibber, 2010; Fox, 2009; Peters, 1979). For women with a prior cesarean considering transabdominal cerclage, Martin and colleagues (2013) estimated the overall risk of subsequent scar disruption to be 2 percent. In their series of 51 pregnancies, the sole case of uterine rupture was associated with a unicornuate uterus and preterm labor at 31 weeks' gestation.

For uncomplicated pregnancies without labor, a cerclage is generally removed at approximately 37 weeks' gestation. This attempts to balance the risk of preterm birth and the risks of labor with a cerclage in place. Removal prior to labor onset is generally easier to accomplish and more controlled than removal during labor. For women scheduled to undergo repeat cesarean delivery, cerclage removal is sometimes deferred until the time of regional analgesia and delivery. However, again, the risk of labor ensuing before delivery must be considered.

During removal, particularly with a Shirodkar cerclage or a cerclage using braided suture or tape, analgesia may be required to ensure patient comfort and sufficient visualization (Caspi, 1990). Transvaginally placed cerclages are generally removed even after cesarean delivery to avoid rare complications of a persistent foreign body, such as delayed vaginal erosion (Hawkins, 2014). Conversely, it is reasonable to leave a transabdominal cerclage in place until completion of childbearing.

DÜHRSSENS INCISIONS

Rarely, precipitous delivery of a preterm fetus may result in entrapment of the aftercoming head if the cervix is not fully dilated (Fig. 11-13). In such a circumstance, Dührssen incisions of the cervix may be lifesaving for the fetus. However, these incisions have long been recognized as dangerous and potentially life-threatening to the mother, particularly from hemorrhage. DeLee (1913) stressed that the incisions are safe only after complete effacement of the cervix. He further cited several deaths from hemorrhage and extension into the broad

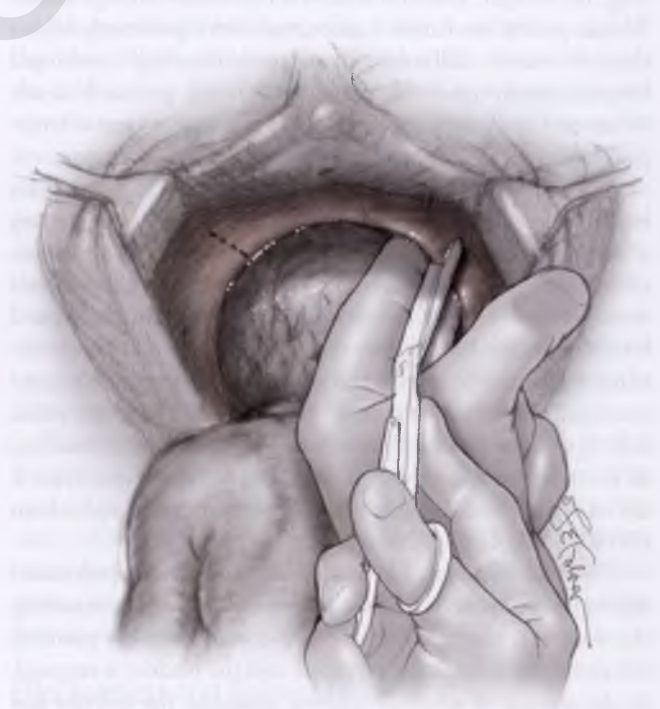


FIGURE 11-13 Dührssen incision being cut at 2 o'clock, which is followed by a second incision at 10 o'clock. Infrequently, an additional incision is required at 6 o'clock. The incisions are so placed to minimize bleeding from the laterally located cervical branches of the uterine artery. After delivery, the incisions are repaired with absorbable suture using in a running, locking stitch.

ligaments and even into the peritoneal cavity. Given the comparative safety and availability of cesarean delivery today, the sole justification for the use of Dührssens incisions is entrapment of the aftercoming head of a preterm neonate.

For placement of cervical incisions, vaginal sidewall retractors may aid viewing, but exposure may not be possible. Therefore, the provider typically places one or two fingers inside the cervix to protect the fetal neck and head. Large blunt-tipped scissors such as bandage scissors are introduced along the obstetrician's fingers, and the cervix is cut at the 2 o'clock position. This may then be repeated at the 10 o'clock and 6 o'clock positions if needed to allow delivery. After delivery, the incisions are inspected to exclude supravaginal extension. The incisions are closed with absorbable suture in a running, locking fashion (Fig. 30-2, p. 484).

FEMALE GENITAL MUTILATION AT LABOR AND DELIVERY

Female genital mutilation is injury and disfigurement of the external genitalia primarily for cultural reasons. Although it is increasingly performed by medical providers rather than by traditional practitioners, the procedures are never medically indicated and can only result in injury (World Health Organization, 2014). Potential harms include immediate risks of infection and bleeding and chronic risks of recurrent urinary tract infections, perineal cyst formation, and infertility. Obstetric risks are numerous and are detailed in a large study of 28,393 women delivering at 28 centers in Burkina Faso, Ghana, Kenya, Nigeria, Senegal, and the Sudan (WHO Study Group, 2006). Female genital mutilation is associated with significantly higher rates of cesarean delivery, postpartum hemorrhage, prolonged hospitalization, newborn resuscitation, and perinatal death. Wuest and coworkers (2009) documented higher rates of emergency cesarean delivery and third-degree vaginal laceration.

The increased risks of difficult and traumatic delivery are related to the degree of disfigurement, which is described using a classification system. Type 1 are procedures resulting in partial or complete clitoridectomy—only rarely is the prepuce alone removed; type 2 are excisional procedures of clitoris and labia minora, and sometimes the labia majora; type 3 are infibulation procedures intended to narrow or obliterate the vaginal opening, often involving excision of part or all of the vulva; and type 4 are all other procedures. The procedures resulting in more severe disfigurement, particularly type 2 and type 3, are associated with increased rates of peripartum complications (WHO Study Group, 2006).

To avoid traumatic obstetric tears, defibulation procedures during labor have been described (Rouzi, 2001). After counseling, the woman is placed in the standard dorsal lithotomy position, the perineum is surgically prepared, and the bladder is emptied. In the absence of adequate regional analgesia, the anterior scar tissue is injected with 1-percent lidocaine. The index and middle fingers of the nondominant hand are insinuated between the anterior scar and the crowning head. The anterior scar is thereby isolated and cut in its midline with scissors in the other hand (Fig. 11-14). After delivery, sutures are placed only if necessary for hemostasis, and a Foley catheter is kept in place for 24 hours.

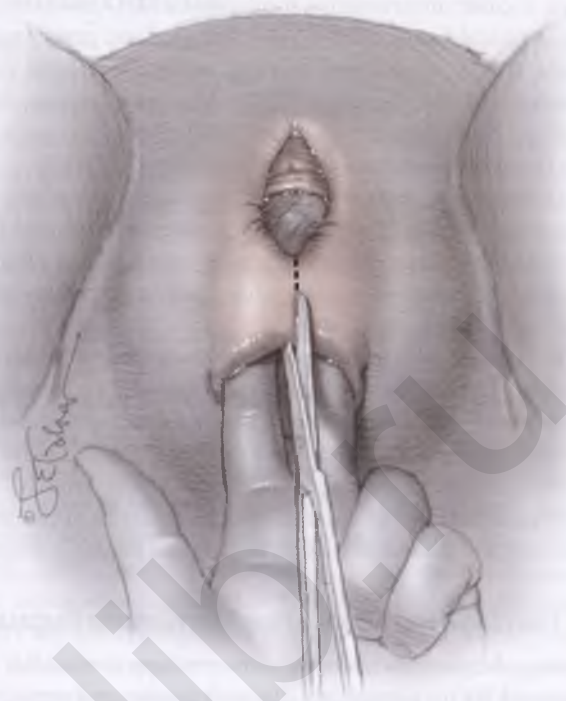


FIGURE 11-14 Defibulation during labor. After ensuring adequate pain control with either regional anesthesia or by injecting the anterior scar with 1-percent lidocaine, the index and middle fingers of the nondominant hand are insinuated between the anterior scar and crowning fetal head. The anterior scar is then cut midline with Mayo scissors during a contraction.

Retrospectively reported outcomes of 388 women who underwent defibulation were not significantly different from those of the 388 chosen controls (Rouzi, 2012). No randomized intervention trials for pregnant women presenting with genital mutilation were in a Cochrane Database Systematic Review (Balogun, 2013).

VAGINAL SEPTUM

Occasionally, a woman with a longitudinal septum may present in labor. By waiting until the second stage of labor, this septum can frequently be found to be markedly attenuated by the downward pressure of the fetal head against it (Fig. 11-15). The septum can then be isolated by fingers insinuated between it and the fetal head. After ensuring adequate analgesia, the septum is transected with scissors. Notably, transection of the superior attachment should avoid urethral injury. Depending on the thickness of the septum, some may choose to clamp the septum prior to transection. The cut ends are ligated with absorbable suture (de França Neto, 2014). With a thick pedicle, a transfixing stitch may be prudent.

CERVICAL BIOPSY

During pregnancy, the goal of colposcopic-directed cervical biopsy is identification or exclusion of invasive cancer. The American Society for Colposcopy and Cervical Pathology (ASCCP) recommends colposcopy for women with positive cervical

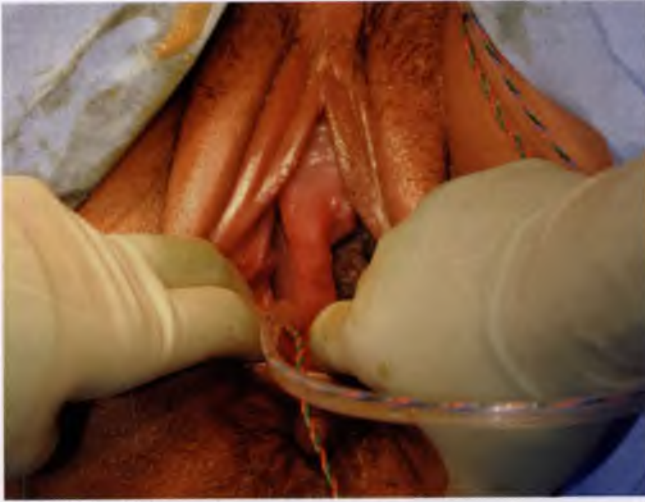

FIGURE 11-15 This primigravida without prior prenatal care presented at term in active labor. Between the clinician's fingers, a distal longitudinal vaginal septum is seen. Labor was allowed to progress normally, and once the cervix was completely dilated, effective pushing aided fetal descent. Seen here, the thick cordlike septum extends across the vaginal opening. The fetal head is seen on the patient's left. Additionally, a fetal scalp electrode (*green and red braid*) and an intrauterine pressure catheter (*plastic tubing*) are seen. (Reproduced with permission from Ha TK, Hoffman BL: Clinical pearl: longitudinal vaginal septum (update). In Cunningham FG, Leveno KL, Bloom SL, et al (eds), *Williams Obstetrics*, 24th ed, New York, McGraw-Hill Education, 2014. Online. accessmedicine.com.)

screening results (Saslow, 2012). Interpretation of these results depends on the woman's age, cytologic findings, and human papillomavirus (HPV) testing results. Indications for colposcopy per ASCCP guidelines were published by Massad and coworkers (2013). These recommendations are periodically updated, and therefore review of the latest ASCCP guidelines for screening and management of cervical pathology in pregnancy is encouraged.

At colposcopy, suspicious-appearing lesions are typically sampled with Tischler biopsy forceps. In pregnancy, immediate diagnostic excisional procedures are recommended only if invasive cancer is suspected.

■ Cervical Biopsy

A cervical biopsy is performed with sharp, small biopsy forceps, such as Tischler forceps. The technique for cervical biopsy mirrors that for the nonpregnant patient. However, given the tendency of the cervix to bleed in pregnancy, large cotton swabs, ferric subsulfate solution (Monsel paste), silver nitrate sticks, and suture material should be readily available. Kohan and associates (1980) reported the morbidity of colposcopically directed cervical biopsies during pregnancy to be "negligible." At Parkland Hospital, rare cases of heavy bleeding encountered after cervical biopsy have been handled with application of Monsel paste, vaginal packing with gauze, and overnight observation.

■ Diagnostic Excisional Procedures

These include both cold-knife cone biopsy and LEEP. According to the ASCCP, both procedures are acceptable when invasion is suspected during pregnancy and can be performed

during all three trimesters. Procedures are often avoided during the last 4 to 6 weeks due to concerns for inciting bleeding, preterm membrane rupture, or preterm labor.

The following is a general technique for performing a diagnostic excisional procedure by either cold-knife or LEEP conization. After adequate regional anesthesia is achieved, the patient is placed in the standard dorsal lithotomy position, and a leftward lateral tilt is used for women in the second or third trimester. The perineum and distal vagina are surgically prepared. Vigorous cervical scrubbing is avoided to permit accurate histologic evaluation of the excised specimen. A weighted Auvard speculum is placed along the posterior vaginal wall, Lugol iodine solution is briefly poured into the proximal vault to stain the portio vaginalis, and then excess stain is atraumatically suctioned.

For initial exposure and manipulation, a single-tooth tenaculum is placed on the anterior lip of the cervix. Hemostatic sutures using no. 1 absorbable suture in a figure-of-eight fashion are placed at the 3 and 9 o'clock positions without removing the needles. These sutures ligate the descending cervical branch of the uterine artery found on each side of the cervix and also aid exposure and manipulation. Depending on the degree of cervical manipulation anticipated, the single-tooth tenaculum can be removed or remain. Sabol and colleagues (1971) described diluting 3 units of vasopressin (Pitressin) in 10 mL of saline and circumferentially injecting into the cervical stroma an amount sufficient to cause cervical blanching. This resulted in less blood loss without complications compared with saline injection alone. Vasopressin is a potent vasoconstrictor, and aspiration prior to injection avoids intravascular injection. Moreover, injection should be communicated to anesthesia staff.

The excisional procedure using either a scalpel or a LEEP electrode follows. If a sound is placed within the os to guide the cold-knife conization, insertion depth is shallow to avoid membrane rupture. For nearly 50 years, a shallow biopsy has been favored during conization. Berman and Disaia (1989) recommended a coin, rather than cone, biopsy during pregnancy (Fig. 11-16). The intent is to avoid removal of cervical stroma that might lead to loss of cervical integrity. Importantly, this must be individualized, as a coin biopsy may be insufficient when adenocarcinoma in situ is suspected. This lesion may be multifocal and discontinuous within the endocervical canal. After specimen removal, it is labeled with a suture at the 12-o'clock position for review by the pathologist.

Electrocoagulation is used to ensure hemostasis. For further reassurance, the hemostatic sutures at 3 and 9 o'clock have been used to encircle the cervix with two bites anteriorly and posteriorly, although there is little evidence to support this practice. Sturmdorf sutures have also been used to cover the bare cervical stroma with mucosa and aid hemostasis, although there are few data to support this.

Effectiveness and Risks of Diagnostic Excisional Procedures

No trials have compared LEEP and cold-knife conization during pregnancy. Most studies are relatively small, retrospective case series that focus on only one modality.

With respect to LEEP in pregnancy, Schaefer and associates (2012) retrospectively reported a low complication rate among

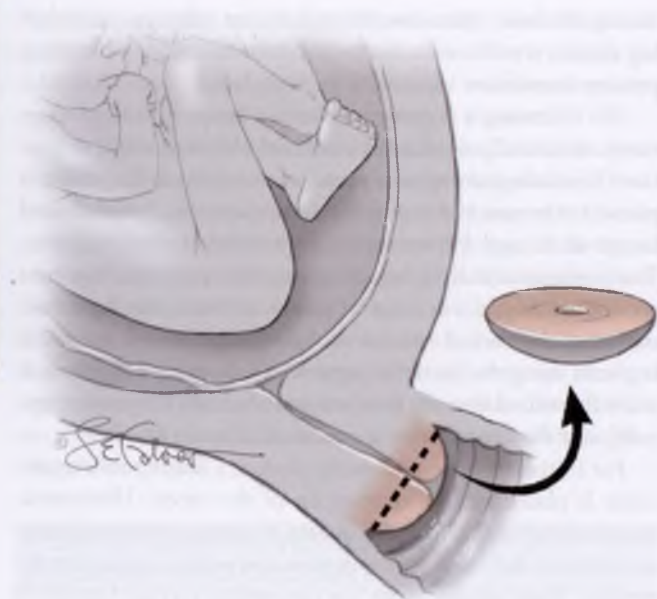


FIGURE 11-16 “Coin biopsy” of the cervix. A modified conization to avoid removal of cervical stroma is occasionally performed. This shallow modification may not be appropriate when endocervical disease or adenocarcinoma in situ is suspected.

27 treated women, but the rate of positive margins was high—56 percent. Kärrberg and colleagues (2013) noted a similarly low complication rate for colposcopically directed cervical biopsy and LEEP conization in pregnancy. Of their cases, dysplastic lesions persisted in 55 percent, regressed in 33 percent, and progressed in 12 percent. There was no serious postoperative bleeding, and cervical biopsy and LEEP conization were concluded to be safe. In another study of 20 women with LEEP conization in pregnancy, Robinson and coworkers (1997) reported more concerning complications, particularly when the procedure is performed in the third trimester. They also cited high rates of positive or uninterpretable margins. The authors reported complications including three preterm births and two women who required blood transfusion after the procedure. They concluded that LEEP during pregnancy did not consistently result in a diagnostic specimen, and residual disease rates were high.

Reports of cold-knife cone biopsy in pregnancy are generally older, but similar concerns for bleeding and incomplete excision remain. Hannigan and colleagues (1982) reported significant hemorrhage that measured at least 500 mL in 10 of 82 women (12 percent), prompted transfusion in 2 patients, merited readmission for bleeding in 3 patients, and required two additional surgeries in 1 patient. Estimated blood loss was significantly greater during the third trimester. Excluding the 14 who had a spontaneous abortion, elective termination, or who were lost to follow-up, there were 68 remaining women. Of these, 65 were delivered of live neonates, of which 12 percent were preterm. Positive margins were seen in 47 of 82 women (57 percent). Of these 47 women, 40 had a hysterectomy during the first postpartum year, and 68 percent were found to have residual disease. Similarly, high rates of bleeding and persistent disease were reported by Boutselis (1972), who reported an overall complication rate for conization of 21

percent, the most common of which was bleeding. The risk of residual tumor increased with gestational age at procedure and was as high as 75 percent in the third trimester.

Thus, for women with suspected invasive cervical carcinoma in pregnancy, either cold-knife conization or LEEP is a reasonable option. Potential risks include significant bleeding and possibly preterm birth, which must be weighed against the risks of not performing the procedure when cancer is suspected. The risk of residual disease requires that follow-up be ensured.

CERVICAL POLYPECTOMY

Polyps and pedunculated or prolapsed leiomyomas originating from the cervix or distal lower uterine segment can be a source of antepartum bleeding. Large lesions may occasionally cause symptomatic protrusion from the vagina. The stalk base may be visible with examination, but frequently the origin is endocervical. Dysplasia arising within endocervical polyps is rare and more often found among women with a prior abnormal cytologic result or in a polyp larger than 20 mm in diameter (Long, 2013). Tokunaka and associates (2014) reported outcomes of women who underwent cervical polypectomy during the first and second trimesters. Ominously, half the lesions thought to be cervical polyps were identified histologically as decidual polyps, which arise from the uterine endometrium. Following removal of either a decidual or an endocervical polyp, women with decidual polyps had higher risks of spontaneous abortion (12 versus 0 percent) and preterm birth (34 versus 5 percent).

Straub and associates (2010) reviewed the literature on cervical and prolapsed submucosal leiomyomas complicating pregnancy. Reported complications include hemorrhage, rupture of membranes, preterm labor, and hysterectomy.

Little published information guides removal of polyps or pedunculated myomas in pregnancy, and expectant management is preferred by most given the risk of bleeding (Robertson, 2005). When features on a large lesion are suspicious for cancer, biopsy in a manner similar to cervical biopsy, discussed on page 183 is reasonable. For symptomatic lesions, removal is sometimes considered. Importantly, however, the risk of bleeding (and the ability to stop such bleeding) is judiciously weighed against any imputed benefit of removal. For a pedunculated lesion with a relatively thin stalk, grabbing the end of the polyp with a ring forceps and twisting it on its base has been performed to effect hemostatic removal (Demirci, 2007). Alternatively, the Endoloop Ligature (Ethicon) using polydioxanone monofilament absorbable suture can be guided to the base of the pedicle (Fig. 11-17). The scored end of the plastic tube is snapped and pulled to tighten the loop and secure the knot. A second Endoloop ligature may be considered for additional reassurance, prior to removal with surgical scissors. This use of the Endoloop ligature should be performed in the operating room in case complications arise.

CONCLUSION

Prophylactic cerclage may be offered to women with a history of at least one midtrimester loss with features suggestive of cervical insufficiency and to women with a prior cerclage.

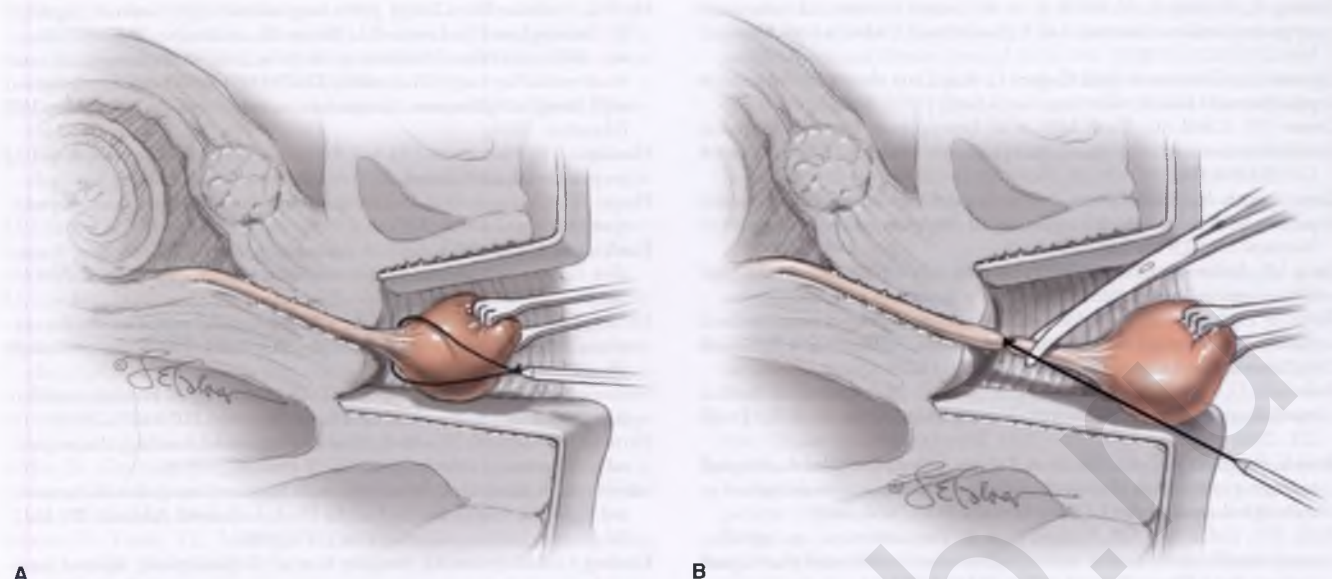


FIGURE 11-17 Endoloop ligation of a large pedunculated mass. **A.** The preformed ligature of polydioxanone monofilament delayed-absorbable suture is first guided to the base of the pedicle. **B.** The scored end of the plastic tube is snapped and pulled to tighten the loop and secure the knot. Placement of a second loop ligature can be considered for additional reassurance, prior to removing the lesion with scissors.

However, many women with a history suggestive of cervical insufficiency can be followed sonographically, with placement of an ultrasound-indicated cerclage if the cervical length is less than 25 mm. Cerclage is typically not performed after fetal viability and thus generally not later than 24 weeks. Rescue or emergent cerclage is poorly defined in the literature, but typically is considered when there is midtrimester cervical dilatation with prolapsing or exposed membranes. Abdominal cervicoisthmic cerclage is an option when there is a history of failed transvaginal cerclage and/or little to no functional cervix on which to perform cervical cerclage.

Dührssen incisions are indicated only for entrapment of the aftercoming head of the precipitously delivered preterm breech neonate. For women with a history of genital mutilation, particularly the more severe forms, defibulation during labor can be considered to aid controlled vaginal delivery. For women in labor who have a vaginal septum, its attenuation during the second stage of labor can assist with transection and ligation of the cut ends. Cervical conization carries significant risks in pregnancy and is generally indicated only for suspected invasive cervical disease. For women with pedunculated cervical lesions that are symptomatic or have features suspicious for malignancy, removal can be considered, but carries risks for the pregnancy.

REFERENCES

- Aarnoudse JG, Huisjes HJ: Complications of cerclage. *Acta Obstet Gynecol Scand* 58(3):255, 1979
- Airoldi J, Pereira L, Cotter A, et al: Amniocentesis prior to physical exam-indicated cerclage in women with midtrimester cervical dilation: results from the expectant management compared to Physical Exam-indicated Cerclage international cohort study. *Am J Perinatol* 26(1):63, 2009
- Akgul Y, Holt R, Mummert M, et al: Dynamic changes in cervical glycosaminoglycan composition during normal pregnancy and preterm birth. *Endocrinology* 153(7):3493, 2012
- Althuisius S, Dekker G, Hummel P, et al: Cervical Incompetence Prevention Randomized Cerclage Trial (CIPRACT): effect of therapeutic cerclage with bed rest vs. bed rest only on cervical length. *Ultrasound Obstet Gynecol* 20(2):163, 2002
- Althuisius SM, Dekker GA, Hummel P, et al: Final results of the Cervical Incompetence Prevention Randomized Cerclage Trial (CIPRACT): therapeutic cerclage with bed rest versus bed rest alone. *Am J Obstet Gynecol* 185(5):1106, 2001
- American College of Obstetricians and Gynecologists: Cerclage for the management of cervical insufficiency. Practice Bulletin No. 142, February 2014
- Armarnik S, Sheiner E, Piura B, et al: Obstetric outcome following cervical conization. *Arch Gynecol Obstet* 283(4):765, 2011
- Ayers JW, DeGroot RM, Compton AA, et al: Sonographic evaluation of cervical length in pregnancy: diagnosis and management of preterm cervical effacement in patients at risk for premature delivery. *Obstet Gynecol* 71(6 Pt 1):939, 1988
- Balogun OO, Hirayama F, Wariki WM, et al: Interventions for improving outcomes for pregnant women who have experienced genital cutting. *Cochrane Database Syst Rev* 2:CD009872, 2013
- Bauer ME, Bateman BT, Bauer ST, et al: Maternal sepsis mortality and morbidity during hospitalization for delivery: temporal trends and independent associations for severe sepsis. *Anesth Analg* 117(4):944, 2013
- Benson RC, Durfee RB: Transabdominal cervico uterine cerclage during pregnancy for the treatment of cervical incompetence. *Obstet Gynecol* 25:145, 1965
- Berchuck A, Sokol RJ: Cervicovaginal fistula formation: a new complication of Shirodkar cerclage. *Am J Perinatol* 1(3):263, 1984
- Berghella V, Ludmir J, Simonazzi G, et al: Transvaginal cervical cerclage: evidence for perioperative management strategies. *Am J Obstet Gynecol* 209(3):181, 2013
- Berghella V, Odibo AO, Tolosa JE: Cerclage for prevention of preterm birth in women with a short cervix found on transvaginal ultrasound examination: a randomized trial. *Am J Obstet Gynecol* 191(4):1311, 2004
- Berghella V, Prasertcharoensuk W, Cotter A, et al: Does indomethacin prevent preterm birth in women with cervical dilatation in the second trimester? *Am J Perinatol* 26(1):13, 2009
- Berghella V, Szychowski JM, Owen J, et al: Suture type and ultrasound-indicated cerclage efficacy. *J Matern Fetal Neonatal Med* 25(11):2287, 2012
- Berman ML, DiSaia PJ: Malignancy and pregnancy. In Creasy RK, Resnick R (eds): *Maternal-Fetal Medicine: Principles and Practice*, 2nd ed. Philadelphia, Saunders, 1989
- Boutselis JG: Intraepithelial carcinoma of the cervix associated with pregnancy. *Obstet Gynecol* 40(5):657, 1972
- Brix N, Secher NJ, McCormack CD, et al: Randomised trial of cervical cerclage, with and without occlusion, for the prevention of preterm birth in women suspected for cervical insufficiency. *BJOG* 120(5):613, 2013
- Caspi E, Schneider DF, Mor Z, et al: Cervical internal os cerclage: description of a new technique and comparison with Shirodkar operation. *Am J Perinatol* 7(4):347, 1990

- Chibber R, El-Saleh E, Al Fadhli R, et al: Uterine rupture and subsequent pregnancy outcome—how safe is it? A 25-year study. *J Matern Fetal Neonatal Med* 23(5):421, 2010
- Ciavattini A, Clemente N, Delli Carpini G, et al: Loop electrosurgical excision procedure and risk of miscarriage. *Fertil Steril* 103(4):1043, 2015
- Conner SN, Cahill AG, Tuuli MG, et al: Interval from loop electrosurgical excision procedure to pregnancy and pregnancy outcomes. *Obstet Gynecol* 122(6):1154, 2013
- Crane J, Scott H, Stewart A, et al: Transvaginal ultrasonography to predict preterm birth in women with bicornuate or didelphus uterus. *J Matern Fetal Neonatal Med* 25(10):1960, 2012
- Curet LB, Koller W, Olson RW: Temporary submucosal cervical cerclage. *Obstet Gynecol* 55(3):392, 1980
- Dashe JS, Nathan L, McIntire DD, et al: Correlation between amniotic fluid glucose concentration and amniotic fluid volume in pregnancy complicated by diabetes. *Am J Obstet Gynecol* 182(4):901, 2000
- Daskalakis G, Papantoniou N, Mesogitis S, et al: Management of cervical insufficiency and bulging fetal membranes. *Obstet Gynecol* 107(2 Pt 1): 221, 2006
- Davis G, Berghella V, Talucci M, et al: Patients with a prior failed transvaginal cerclage: a comparison of obstetric outcomes with either transabdominal or transvaginal cerclage. *Am J Obstet Gynecol* 183(4):836, 2000
- Debbs RH, DeLa Vega GA, Pearson S, et al: Transabdominal cerclage after comprehensive evaluation of women with previous unsuccessful transvaginal cerclage. *Am J Obstet Gynecol* 197(3):317.e1, 2007
- de França Neto AH, Nobrega BV, Clementino Filho J, et al: Intrapartum diagnosis and treatment of longitudinal vaginal septum. *Case Rep Obstet Gynecol* 2014:108973, 2014
- DeLee JB: *The Principles and Practice of Obstetrics*. Philadelphia, WB Saunders, 1913
- Demirci F, Somunkiran A, Safak AA, et al: Vaginal removal of a prolapsed pedunculated submucosal myoma during pregnancy. *Adv Ther* 24(4):903, 2007
- Dildy GA, Pearlman MD, Smith LG, et al: Amniotic fluid glucose concentration: a marker for infection in preterm labor and preterm premature rupture of membranes. *Infect Dis Obstet Gynecol* 1(4):166, 1994
- D Laskin M, Yinon Y, Whittle WL: Preterm premature rupture of membranes in the presence of cerclage: is the risk for intra-uterine infection and adverse neonatal outcome increased? *J Matern Fetal Neonatal Med* 25(4):424, 2012
- Easterday CL, Reid DE: The incompetent cervix in repetitive abortion and premature labor. *N Engl J Med* 260(14):687, 1959
- Edwards RK, Clark P, Locksmith Gregory J, et al: Performance characteristics of putative tests for subclinical chorioamnionitis. *Infect Dis Obstet Gynecol* 9(4):209, 2001
- Eglinton GS, Herway C, Skupski DW, et al: Endocervical hyaluronan and ultrasound-indicated cerclage. *Ultrasound Obstet Gynecol* 37(2):214, 2011
- Fischer RL, Sveinbjornsson G, Hansen C: Cervical sonography in pregnant women with a prior cone biopsy or loop electrosurgical excision procedure. *Ultrasound Obstet Gynecol* 36(5):613, 2010
- Fortner KB, Fitzpatrick CB, Grotegug CA, et al: Cervical dilation as a predictor of pregnancy outcome following emergency cerclage. *J Matern Fetal Neonatal Med* 25(10):1884, 2012
- Foster TL, Addleman RN, Moore ES, et al: Robotic-assisted prophylactic transabdominal cervical cerclage in singleton pregnancies. *J Obstet Gynaecol* 33(8):821, 2013
- Fox NS, Rebarber A, Bender S, et al: Labor outcomes after Shirodkar cerclage. *J Reprod Med* 54(6):361, 2009
- Fox R, Holmes R, James M, et al: Serial transvaginal ultrasonography following McDonald cerclage and repeat suture insertion. *Aust N Z J Obstet Gynaecol* 38(1):27, 1998
- Funai EF, Paidas MJ, Rebarber A, et al: Change in cervical length after prophylactic cerclage. *Obstet Gynecol* 94(1):117, 1999
- Galysan A, Garite TJ, Maurel K, et al: Removal versus retention of cerclage in preterm premature rupture of membranes: a randomized controlled trial. *Am J Obstet Gynecol* 211(4):399.e1, 2014
- Giraldo-Isaza MA, Fried GP, Hegarty SE, et al: Comparison of 2 stitches vs 1 stitch for transvaginal cervical cerclage for preterm birth prevention. *Am J Obstet Gynecol* 208(3):209.e1, 2013
- Goldstein DP: Incompetent cervix in offspring exposed to diethylstilbestrol in utero. *Obstet Gynecol* 52(1 Suppl):73S, 1978
- Golfier F, Bessai K, Paparel P, et al: Transvaginal cervicoisthmic cerclage as an alternative to the transabdominal technique. *Eur J Obstet Gynecol Reprod Biol* 100(1):16, 2001
- Greig PC, Ernest JM, Teot L: Low amniotic fluid glucose levels are a specific but not a sensitive marker for subclinical intrauterine infections in patients in preterm labor with intact membranes. *Am J Obstet Gynecol* 171(2):365, 1994
- Grotegug CA, Moore NL, Reddick KL, et al: Cervicovaginal fistula presenting during miscarriage. *Ultrasound Obstet Gynecol* 36(1):112, 2010
- Ha TK, Hoffman BL: Clinical pearl: longitudinal vaginal septum. (update). In Cunningham FG, Leveno KL, Bloom SL, et al (eds), *Williams Obstetrics*, 24th ed. Online. Available at: <http://accessmedicine.mhmedical.com/MultimediaPlayer.aspx?MultimediaID=7918799&SearchTerm=longitudinal%20vaginal%20septum>. accessmedicine.com. New York, McGraw-Hill Education, 2014
- Hannigan EV, Whitehouse HH 3rd, Atkinson WD, et al: Cone biopsy during pregnancy. *Obstet Gynecol* 60(4):450, 1982
- Harger JH: Comparison of success and morbidity in cervical cerclage procedures. *Obstet Gynecol* 56(5):543, 1980
- Hawkins E, Nimaroff M: Vaginal erosion of an abdominal cerclage 7 years after laparoscopic placement. *Obstet Gynecol* 123(2 Pt 2 Suppl 2):420, 2014
- Hefner JD, Patow WE, Ludwig JM Jr: A new surgical procedure for the correction of the incompetent cervix during pregnancy. The Wurm procedure. *Obstet Gynecol* 18:616, 1961
- Heinonen A, Gissler M, Riska A, et al: Loop electrosurgical excision procedure and the risk for preterm delivery. *Obstet Gynecol* 121(5):1063, 2013
- Herron MA, Parer JT: Transabdominal cerclage for fetal wastage due to cervical incompetence. *Obstet Gynecol* 71(6 Pt 1):865, 1988
- Jefferies JA, Robboy SJ, O'Brien PC, et al: Structural anomalies of the cervix and vagina in women enrolled in the Diethylstilbestrol Adenosis (DESAD) Project. *Am J Obstet Gynecol* 148(1):59, 1984
- Kärberg C, Brännström M, Strander B, et al: Colposcopically directed cervical biopsy during pregnancy; minor surgical and obstetrical complications and high rates of persistence and regression. *Acta Obstet Gynecol Scand* 92(6):692, 2013
- Katz M, Abrahams C: Transvaginal placement of cervicoisthmic cerclage: report on pregnancy outcome. *Am J Obstet Gynecol* 192(6):1989, 2005
- Kaufman RH, Noller K, Adam E, et al: Upper genital tract abnormalities and pregnancy outcome in diethylstilbestrol-exposed progeny. *Am J Obstet Gynecol* 148(7):973, 1984
- Kilpatrick SJ, Patil R, Connell J, et al: Risk factors for previable premature rupture of membranes or advanced cervical dilatation: a case control study. *Am J Obstet Gynecol* 194(4):1168, 2006
- Kiltz RJ, Burke MS, Porreco RP: Amniotic fluid glucose concentration as a marker for intra-amniotic infection. *Obstet Gynecol* 78(4):619, 1991
- Kohan S, Beckman EM, Bigelow B, et al: The role of colposcopy in the management of cervical intraepithelial neoplasia during pregnancy and postpartum. *J Reprod Med* 25(5):279, 1980
- Kominiarek MA, Kemp A: Perinatal outcome in preterm premature rupture of membranes at < or = 32 weeks with retained cerclage. *J Reprod Med* 51(7):533, 2006
- Kurup M, Goldkrand JW: Cervical incompetence: elective, emergent, or urgent cerclage. *Am J Obstet Gynecol* 181(2):240, 1999
- Landy HJ, Laughon SK, Bailit JL, et al: Characteristics associated with severe perineal and cervical lacerations during vaginal delivery. *Obstet Gynecol* 117(3):627, 2011
- Lash AF, Lash SR: Habitual abortion; the incompetent internal os of the cervix. *Am J Obstet Gynecol* 59(1):68, 1950
- Lazar P, Gueguen S, Dreyfus J, et al: Multicentred controlled trial of cervical cerclage in women at moderate risk of preterm delivery. *BJOG* 91(8):731, 1984
- Locatelli A, Vergani P, Bellini P, et al: Amnioreduction in emergency cerclage with prolapsed membranes: comparison of two methods for reducing the membranes. *Am J Perinatol* 16(2):73, 1999
- Long ME, Dwarica DS, Kastner TM, et al: Comparison of dysplastic and benign endocervical polyps. *J Low Genit Tract Dis* 17(2):142, 2013
- Lotgering FK, Gaugler-Senden IP, Lotgering SF, et al: Outcome after transabdominal cervicoisthmic cerclage. *Obstet Gynecol* 107(4):779, 2006
- Ludmir J, Bader T, Chen L, et al: Poor perinatal outcome associated with retained cerclage in patients with premature rupture of membranes. *Obstet Gynecol* 84(5):823, 1994
- MacDougall J, Siddle N: Emergency cervical cerclage. *BJOG* 98(12):1234, 1991
- Maduke-Laveaux OS, Platte R, Poplawsky D: Unique complication of a Shirodkar cerclage: remote formation of a vesicocervical fistula in a patient with the history of cervical cerclage placement: a case report and literature review. *Female Pelvic Med Reconstr Surg* 19(5):306, 2013
- Mangan CE, Borow L, Burtmett-Rubin MM, et al: Pregnancy outcome in 98 women exposed to diethylstilbestrol in utero, their mothers, and unexposed siblings. *Obstet Gynecol* 59(3):315, 1982
- Martin JM, Moore ES, Foster TL, et al: Transabdominal cerclage placement in patients with prior uterine incisions: risk of scar disruption. *J Obstet Gynaecol* 33(7):682, 2013
- Massad LS, Einstein MH, Huh WK, et al: 2012 updated consensus guidelines for the management of abnormal cervical cancer screening tests and cancer precursors. *J Low Genit Tract Dis* 17(5 Suppl 1):S1, 2013

- Massengill JC, Baker TM, Von Pechmann WS, et al: Commonalities of cerclage-related genitourinary fistulas. *Female Pelvic Med Reconstr Surg* 18(6):362, 2012
- Mays JK, Figueroa R, Shah J, et al: Amniocentesis for selection before rescue cerclage. *Obstet Gynecol* 95(5):652, 2000
- McDonald IA: Suture of the cervix for inevitable miscarriage. *J Obstet Gynaecol Br Emp* 64(3):346, 1957
- McElrath TF, Norwitz ER, Lieberman ES, et al: Management of cervical cerclage and preterm premature rupture of the membranes: should the stitch be removed? *Am J Obstet Gynecol* 183(4):840, 2000
- McElrath TF, Norwitz ER, Lieberman ES, et al: Perinatal outcome after preterm premature rupture of membranes with in situ cervical cerclage. *Am J Obstet Gynecol* 187(5):1147, 2002
- McKay HA, Hanlon K: Vesicovaginal fistula after cervical cerclage: repair by transurethral suture cystorrhaphy. *J Urol* 169(3):1086, 2003
- Melamed N, Ben-Haroush A, Chen R, et al: Intrapartum cervical lacerations: characteristics, risk factors, and effects on subsequent pregnancies. *Am J Obstet Gynecol* 200(4):388.e1, 2009
- Menderes G, Clark LE, Azodi M: Needleless laparoscopic abdominal cerclage placement. *J Minim Invasive Gynecol* 22(3):321, 2015
- Miller ES, Grobman WA, Fonseca L, et al: Indomethacin and antibiotics in examination-indicated cerclage: a randomized controlled trial. *Obstet Gynecol* 123(6):1311, 2014
- Moore ES, Foster TL, McHugh K, et al: Robotic-assisted transabdominal cerclage (RoboTAC) in the non-pregnant patient. *J Obstet Gynaecol* 32(7):643, 2012
- MRC/RCOG Working Party on Cervical Cerclage: Final report of the Medical Research Council/Royal College of Obstetricians and Gynaecologists multicentre randomised trial of cervical cerclage. *BJOG* 100(6):516, 1993
- Myers K, Socrate S, Tzeranis D, et al: Changes in the biochemical constituents and morphologic appearance of the human cervical stroma during pregnancy. *Eur J Obstet Gynecol Reprod Biol* 144 Suppl 1:S82, 2009
- Myers KM, Paskaleva AP, House M, et al: Mechanical and biochemical properties of human cervical tissue. *Acta Biomater* 4(1):104, 2008
- Namouz S, Porat S, Okun N, et al: Emergency cerclage: literature review. *Obstet Gynecol Surv* 68(5):379, 2013
- Nelson L, Dola T, Tran T, et al: Pregnancy outcomes following placement of elective, urgent and emergent cerclage. *J Matern Fetal Neonatal Med* 22(3):269, 2009
- Ng KL, Kale AS, Gosavi AT: Ureterovaginal fistula after insertion of a McDonald suture: case report and review of published reports. *J Obstet Gynaecol Res* 41(7):1129, 2015
- Odibo AO, Berghella V, To MS, et al: Shirodkar versus McDonald cerclage for the prevention of preterm birth in women with short cervical length. *Am J Perinatol* 24(1):55, 2007
- Odibo AO, Rodis JF, Sanders MM, et al: Relationship of amniotic fluid markers of intra-amniotic infection with histopathology in cases of preterm labor with intact membranes. *J Perinatol* 19(6 Pt 1):407, 1999
- Ogawa M, Sanada H, Tsuda A, et al: Modified cervical cerclage in pregnant women with advanced bulging membranes: knee-chest positioning. *Acta Obstet Gynecol Scand* 78(9):779, 1999
- Olatunbosun OA, Dyck F: Cervical cerclage operation for a dilated cervix. *Obstet Gynecol* 57(2):166, 1981
- Oliveira FR, Barros EG, Magalhães JA: Biochemical profile of amniotic fluid for the assessment of fetal and renal development. *Braz J Med Biol Res* 35(2):215, 2002
- Owen J, Hankins G, Iams JD, et al: Multicenter randomized trial of cerclage for preterm birth prevention in high-risk women with shortened midtrimester cervical length. *Am J Obstet Gynecol* 201(4):375.e1, 2009
- Oxlund BS, Ørtoft G, Brüel A, et al: Cervical collagen and biomechanical strength in non-pregnant women with a history of cervical insufficiency. *Reprod Biol Endocrinol* 8:92, 2010
- Parikh R, Brotzman S, Anasti JN: Cervical lacerations: some surprising facts. *Am J Obstet Gynecol* 196(5):e17, 2007
- Park JM, Tuuli MG, Wong M, et al: Cervical cerclage: one stitch or two? *Am J Perinatol* 29(6):477, 2012
- Pelosi MA: A new technique for reduction of prolapsed fetal membranes for emergency cervical cerclage. *Obstet Gynecol* 75(1):143, 1990
- Pergialiotis V, Vlachos DG, Prodromidou A, et al: Double versus single cervical cerclage for the prevention of preterm births. *J Matern Fetal Neonatal Med* 28(4):379, 2015
- Peters WA 3rd, Thiagarajah S, Harbert GM Jr: Cervical cerclage: twenty years' experience. *South Med J* 72(8):933, 1979
- Rand L, Norwitz ER: Current controversies in cervical cerclage. *Semin Perinatol* 27(1):73, 2003
- Riiskjaer M, Petersen OB, Ulldbjerg N, et al: Feasibility and clinical effects of laparoscopic abdominal cerclage: an observational study. *Acta Obstet Gynecol Scand* 91(11):1314, 2012
- Robertson M, Scott P, Ellwood DA, et al: Endocervical polyp in pregnancy: gray scale and color Doppler images and essential considerations in pregnancy. *Ultrasound Obstet Gynecol* 26(5):583, 2005
- Robinson WR, Webb S, Tirpack J, et al: Management of cervical intraepithelial neoplasia during pregnancy with LOOP excision. *Gynecol Oncol* 64(1):153, 1997
- Rouzi AA, Aljhadali EA, Amarín ZO, et al: The use of intrapartum defibulation in women with female genital mutilation. *BJOG* 108(9):949, 2001
- Rouzi AA, Al-Sibiani SA, Al-Mansouri NM, et al: Defibulation during vaginal delivery for women with type III female genital mutilation. *Obstet Gynecol* 120(1):98, 2012
- Ruan JM, Adams SR, Carpinito G, et al: Bladder calculus presenting as recurrent urinary tract infections: a late complication of cervical cerclage placement: a case report. *J Reprod Med* 56(3-4):172, 2011
- Rush RW, Isaacs S, McPherson K, et al: A randomized controlled trial of cervical cerclage in women at high risk of spontaneous preterm delivery. *BJOG* 91(8):724, 1984
- Rust JA Jr, Botte JM: Curved Allis (tongue) forceps technic in Shirodkar operation. *Obstet Gynecol* 30(3):438, 1967
- Rust OA, Atlas RO, Jones KJ, et al: A randomized trial of cerclage versus no cerclage among patients with ultrasonographically detected second-trimester preterm dilatation of the internal os. *Am J Obstet Gynecol* 183(4):830, 2000
- Rust OA, Roberts WE: Does cerclage prevent preterm birth? *Obstet Gynecol Clin North Am* 32(3):441, 2005
- Sabol ED, Gibson JL, Bowes WA: Vasopressin injection in cervical conization. A double-blinded study. *Obstet Gynecol* 37(4):596, 1971
- Sandberg EC, Riffle NL, Higdon JV, et al: Pregnancy outcome in women exposed to diethylstilbestrol in utero. *Am J Obstet Gynecol* 140(2):194, 1981
- Saslow D, Solomon D, Lawson HW, et al: American Cancer Society, American Society for Colposcopy and Cervical Pathology, and American Society for Clinical Pathology screening guidelines for the prevention and early detection of cervical cancer. *Am J Clin Pathol* 137(4):516, 2012
- Schaefer K, Peters D, Aulmann S, et al: Value and feasibility of LLETZ procedures for pregnant women with suspected high-grade squamous intraepithelial lesions and microinvasive cervical cancer. *Int J Gynaecol Obstet* 118(2):141, 2012
- Scheerer LJ, Lam F, Bartolucci L, et al: A new technique for reduction of prolapsed fetal membranes for emergency cervical cerclage. *Obstet Gynecol* 74(3 Pt 1):408, 1989
- Scheib S, Visintine JF, Miroshnichenko G, et al: Is cerclage height associated with the incidence of preterm birth in women with an ultrasound-indicated cerclage? *Am J Obstet Gynecol* 200(5):e12, 2009
- Scholten BL, Page-Christiaens GC, Franx A, et al: The influence of pregnancy termination on the outcome of subsequent pregnancies: a retrospective cohort study. *BMJ Open* 3(5):e002803, 2013
- Shah PS, Zao J: Induced termination of pregnancy and low birthweight and preterm birth: a systematic review and meta-analyses. *BJOG* 116(11):1425, 2009
- Shirodkar VN: A new method of operative treatment of habitual abortions in the first trimester of pregnancy. *The Antiseptic* 52:299, 1955
- Simcox R, Seed PT, Bennett P, et al: A randomized controlled trial of cervical scanning vs history to determine cerclage in women at high risk of preterm birth (CIRCLE trial). *Am J Obstet Gynecol* 200(6):623.e1, 2009
- Singer MS, Hochman M: Incompetent cervix in a hormone-exposed offspring. *Obstet Gynecol* 51(5):625, 1978
- Society of Maternal-Fetal Medicine: Cervical cerclage for the woman with prior adverse pregnancy outcome. Reaffirmed 2015. Available at: <https://www.smfm.org/publications/98-cervical-cerclage-for-the-woman-with-prior-adverse-pregnancy-outcome>. Accessed July 18, 2015
- Spellacy WN, Bui WC, Bradley B, et al: Maternal, fetal and amniotic fluid levels of glucose, insulin and growth hormone. *Obstet Gynecol* 41(3):323, 1973
- Straub HL, Chohan L, Kilpatrick CC: Cervical and prolapsed submucosal leiomyomas complicating pregnancy. *Obstet Gynecol Surv* 65(9):583, 2010
- To MS, Alfirevic Z, Heath VC, et al: Cervical cerclage for prevention of preterm delivery in women with short cervix: randomised controlled trial. *Lancet* 363(9424):1849, 2004
- Toaff R, Toaff ME: Diagnosis of impending late abortion. *Obstet Gynecol* 43(5):756, 1974
- Tokunaka M, Hasegawa J, Oba T, et al: Decidual polyps are associated with preterm delivery in cases of attempted uterine cervical polypectomy during the first and second trimester. *J Matern Fetal Neonatal Med* 28(9):1061, 2014
- Tsatsaris V, Senat MV, Gervaise A, et al: Balloon replacement of fetal membranes to facilitate emergency cervical cerclage. *Obstet Gynecol* 98(2):243, 2001
- Tulandi T, Alghanaim N, Hakeem G, et al: Pre and post-conceptional abdominal cerclage by laparoscopy or laparotomy. *J Minim Invasive Gynecol* 21(6):987, 2014

- Tusheva OA, Cohen SL, McElrath TF, et al: Laparoscopic placement of cervical cerclage. *Rev Obstet Gynecol* 5(3-4):e158, 2012
- Wall LL, Khan F, Adams S: Vesicovaginal fistula formation after cervical cerclage mimicking premature rupture of membranes. *Obstet Gynecol* 109(2 Pt2):493, 2007
- Warren JE, Silver RM: Genetics of the cervix in relation to preterm birth. *Semin Perinatol* 33(5):308, 2009
- Weiss PA, Hofmann H, Winter R, et al: Amniotic fluid glucose values in normal and abnormal pregnancies. *Obstet Gynecol* 65(3):333, 1985
- Weissman A, Lowenstein L, Drugan A, et al: Effect of the 100-g oral glucose tolerance test on fetal acid-base balance. *Prenat Diagn* 23(4):281, 2003
- Werner CL, Lo JY, Heffernan T, et al: Loop electrosurgical excision procedure and risk of preterm birth. *Obstet Gynecol* 115(3):605, 2010
- WHO study group on female genital mutilation and obstetric outcome, Banks E, Meirik O, et al: Female genital mutilation and obstetric outcome: WHO collaborative prospective study in six African countries. *Lancet* 367(9525):1835, 2006
- World Health Organization: Female genital mutilation. Fact Sheet No. 241. Updated February 2014. Available at: <http://www.who.int/mediacentre/factsheets/fs241/en/>. Accessed July 18, 2015
- Woensdregt K, Norwitz ER, Cackovic M, et al: Effect of 2 stitches vs 1 stitch on the prevention of preterm birth in women with singleton pregnancies who undergo cervical cerclage. *Am J Obstet Gynecol* 198(4):396.e1, 2008
- Wuest S, Raio L, Wyssmueller D, et al: Effects of female genital mutilation on birth outcomes in Switzerland. *BJOG* 116(9):1204, 2009
- Yassae F, Mostafae L: The role of cervical cerclage in pregnancy outcome in women with uterine anomaly. *J Reprod Infertil* 12(4):277, 2011
- Yip SK, Fung HY, Fung TY: Emergency cervical cerclage: a study between duration of cerclage in situ with gestation at cerclage, herniation of forewater, and cervical dilatation at presentation. *Eur J Obstet Gynecol Reprod Biol* 78(1):63, 1998
- Zeisler H, Joura EA, Bancher-Todesca D, et al: Prophylactic cerclage in pregnancy. Effect in women with a history of conization. *J Reprod Med* 42(7):390, 1997

CHAPTER 12

Treatment of Lower Genital Tract Infections

VULVAR ABSCESS	189
BARTHOLIN GLAND DUCT ABSCESS	192
ANOGENITAL CONDYLOMA ACUMINATA	194
VAGINAL FLORA	196
BACTERIAL VAGINOSIS	196
SEXUALLY TRANSMITTED DISEASES	197
PELVIC INFLAMMATORY DISEASE	199
VULVOVAGINAL CANDIDIASIS	199

In pregnancy, bacterial and viral lower genital tract infections are common and generally managed medically. Sexually transmitted diseases (STDs) such as gonorrhea, trichomoniasis, and chlamydial infection are treated with antibiotic regimens according to guidelines outlined by the Centers for Disease Control and Prevention (CDC) (Workowski, 2015). Vulvovaginal candidiasis and bacterial vaginosis can also cause symptomatic vaginal discharge during pregnancy. Treatment recommendations for all these are briefly reviewed and interwoven within the specific topics of this chapter.

In contrast, surgical treatment is generally reserved for vulvovaginal abscesses or for condylomata causing marked obstruction. Otherwise, surgery has little role in treating chronic viral or bacterial infections during pregnancy.

The clinical presentation of vulvovaginal infections is probably minimally affected by pregnancy. Host factors such as diabetes mellitus or human immunodeficiency virus (HIV) are evaluated prior to management decisions. Importantly,

immunosuppression from HIV and acquired immunodeficiency syndrome (AIDS) may mask clinical and laboratory signs of local infection and bacteremia due to impaired inflammatory response (Berger, 1994).

VULVAR ABSCESS

These usually involve the labia majora, and vulvar abscesses occasionally complicate pregnancy. Acute infections can stem from pyogenic folliculitis, and common risks include local trauma from shaving, obesity, or diabetes mellitus. Chronic or recurrent vulvar abscesses may develop in women with furunculosis, carbuncles, hidradenitis suppurativa, methicillin-resistant *Staphylococcus aureus* (MRSA) colonization, or less often, with Crohn disease.

Small abscesses may be painful but can often be initially managed conservatively with hot compresses and sitz baths. Most superficial infections will become fluctuant, expand, and then drain spontaneously. After spontaneous emptying, persistent erythema or pain may reflect a surrounding cellulitis. Also, a deeper-seated abscess with a thick wall may not reach the skin surface to drain. Thus, differentiation between cellulitis with marked induration and abscess can be difficult. If the clinical picture is unclear, needle aspiration of the affected area can help distinguish between the two. Additionally, in rare cases with unconventional findings, sonography, if readily available, of the swelling can be considered (Blaivas, 2011).

The involved pathogenic bacteria generally are usual skin flora (staphylococcal and streptococcal species) but may also be composed of a mixed aerobic and anaerobic flora. In complicated infections, culture collection prior to antibiotic initiation may be helpful for later antibiotic regimen adjustment.

■ Incision and Drainage

Mature, superficial vulvar abscesses are best treated with simple incision and drainage (I & D) (Fig. 12-1). Surgical consent is

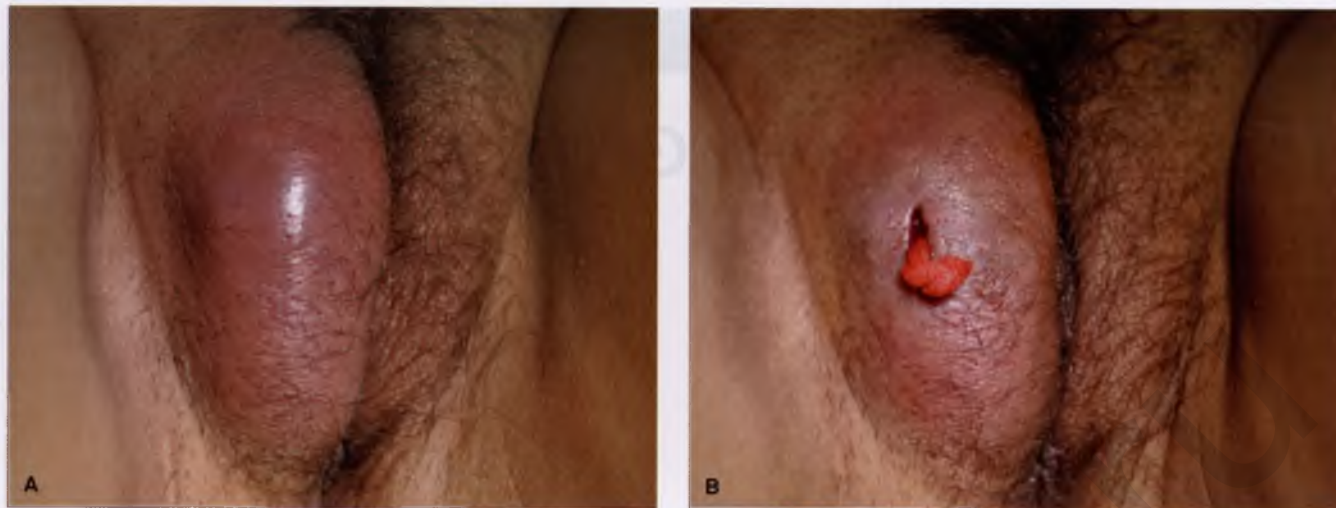


FIGURE 12-1 Right vulvar abscess. **A.** Before drainage. **B.** Iodoform gauze packing in place.

obtained from the patient, and specific risks include bleeding, recurrent abscess, worsening infection, and scar formation or chronic pain at the incision site.

To begin, the skin overlying the planned I & D site is cleaned with a chlorhexidine or betadine solution. In office settings, a local anesthetic such as 1-percent lidocaine is injected along the planned incision. With a no. 11 scalpel blade oriented perpendicular to the skin surface, a vertical incision, which follows natural Langer cleavage lines, is created. The length is typically dictated by abscess size and the need for wound packing. Specifically, small cavities typically will not require gauze or iodoform packing, but local hydrotherapy may assist healing. Thus, a 0.5- to 1-cm incision may suffice. For larger abscesses, a 1- to 2-cm length is often needed.

Following initial I & D, desired aerobic cultures are obtained. Gentle abscess compression, as tolerated by the patient, aids evacuation. For abscesses larger than 3 cm, a cotton-tip swab can be swept within the cavity to disrupt loculated pockets of pus. Importantly, an abscess may overlie the vascular vestibular bulb, which is shown in Fig. 3-4 (p. 32). In these cases, probing should be gentle to avoid puncture of the posterior abscess wall and laceration of these veins.

Clinicians will often add broad-spectrum oral antimicrobial treatment. In populations with greater risks for MRSA, oral clindamycin may be preferred (Thurman, 2008). However, antibiotics are generally not necessary in the absence of cellulitis or isolation of specific pathogens. If provided, oral antibiotics are suitable for smaller abscesses with mild cellulitis. However, for substantial associated cellulitis or fever, admission for administration is reasonable. Bacterial culture is more strongly recommended in the setting of recurrent or refractory abscesses. Treatment is then guided by antibiotic susceptibility, although most infections are caused by organisms found in skin flora.

Hospitalization for surgical drainage is considered in cases with a large or deep abscess, significant surrounding cellulitis, or suspicion for systemic infection. With a larger abscess, I & D in the operating room may afford adequate patient anesthesia for sufficient disruption of intracavitary loculations and for wound packing.

Following evacuation, packing large cavities with gauze ribbon or placing a passive drain such as a Penrose drain can sustain drainage as infection resolves. Packing is usually changed each day, and premedication with suitable analgesia is typically needed. This may be oral or intravenous sedation depending on wound size and patient tolerance. Most women are ready for discharge after 1 to 2 days, but cases complicated by immunosuppression may require longer stays to manage comorbid conditions.

■ Necrotizing Infection

Necrotizing vulvar infection may present as a cellulitis, fasciitis, or myositis and is a serious polymicrobial process characterized by rapid progression. This is a surgical emergency, and its associated mortality rate ranges between 12 and 60 percent (Horowitz, 2011). Predisposing factors for necrotizing fasciitis include diabetes mellitus most commonly, but prior radiation is also a risk. Clostridial species are classically implicated in this infection. Group A *Streptococcus* is another important bacteria involved in necrotizing infections that can develop in healthy individuals in any age group (Wong, 2003).

Clinical systemic features include fever and tachycardia, which can evolve to sepsis. Locally, superficial vascular thrombosis develops and gives skin its characteristically dusky appearance (Fig. 12-2). Tissue edema imparts a doughy texture, and a foul odor may be noted. Tissue crepitus or cutaneous bulla formation is frequently caused by toxin production and proliferation of *Clostridium* species with local gas formation.

Early and aggressive surgical exploration is the key step in managing necrotizing infections. In obvious cases, no imaging is needed, and patients are prepared for surgical debridement. However, tissue destruction is usually far more extensive than is evident by surface examination. Thus, in less-clear cases, the diagnosis may be clarified by identifying gas in affected tissues by radiography or computed tomography if these can be quickly obtained. Otherwise, prompt surgical exploration is preferred, as antibiotic therapy without debridement is associated with high mortality rates that can approach 100 percent (Anaya, 2007).

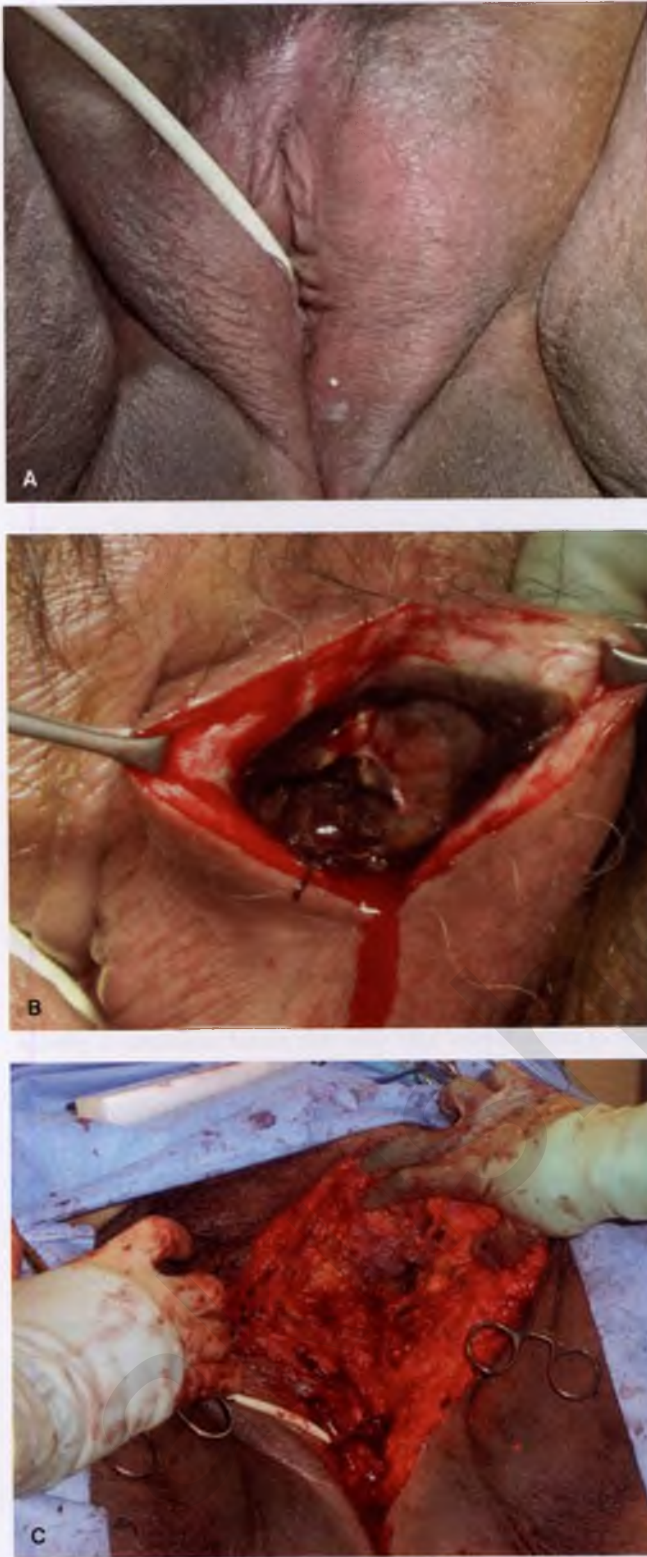


FIGURE 12-2 Vulvar necrotizing fasciitis. **A.** Preoperative photograph shows deceptively minimal erythema, and no fluctuance was appreciated. **B.** With incision, necrotic tissue and thin watery discharge are noted. **C.** Extensive debridement was required to reach well-vascularized tissue. (Used with permission from Dr. David Miller.)

During debridement, due to poor tissue vascularity, there is little or no bleeding but instead usually a thin, gray transudate. As shown in Figure 12-2, necrotic tissue resection continues until healthy viable tissue is reached at the dissection boundaries. In severe cases, dissection may extend cephalad to the lower anterior abdominal wall, laterally onto the proximal inner thigh, or caudally toward the buttock. Such resection can be disfiguring and may require later reconstructive tissue flaps.

Following excision of necrotic tissues, the wound is packed with moist gauze and covered with a dressing. Wet-to-dry dressing changes are ideally completed twice daily, and additional focal wound debridement is often needed. Debridement is completed at the bedside or in the operating room depending on patient tolerance and the burden of necrotic tissue.

Empiric antibiotic treatment includes antimicrobial activity against gram-positive, gram-negative, and anaerobic organisms, particularly group A *Streptococcus* and clostridial species. Necrotizing skin and soft-tissue infections may be mono- or polymicrobial, but initial empiric antibiotic therapy should be broad until further culture information can guide therapy. The 2014 Infectious Disease Society of America (IDSA) guidelines recommend broad empiric antibiotic treatment. Acceptable regimens may include: (1) an agent against MRSA (vancomycin, daptomycin, or linezolid) plus piperacillin-tazobactam, (2) an MRSA agent plus a carbapenem, or (3) an MRSA agent plus ceftriaxone and metronidazole (Anaya, 2007; Stevens, 2014). If toxin-elaborating strains of streptococcus are identified as the causative agent, the IDSA recommends penicillin plus clindamycin (Stevens, 2014). Further therapy can be tailored based on Gram stain and on culture and sensitivity results, once available (Table 12-1). Of note, clinicians should be cognizant of the emergence of carbapenemases and betalactamases that may lead to resistance, particularly in gram-negative infections (Vasoo, 2015).

■ Hidradenitis Suppurativa

This chronic pustular disease of apocrine sweat glands can involve axillary, perianal, and genital areas. It often presents as recurrent abscesses with superficial draining sinus tracts. The pathogenesis of hidradenitis suppurativa remains unclear. In histologic studies, sebaceous gland atrophy is followed by early lymphocytic inflammation and hyperkeratosis of the pilosebaceous unit. This leads to subsequent hair-follicle destruction and granuloma formation (Jemec, 2012; Yazdanyar, 2011). Scarring and sinus tracts form during the healing process.

During pregnancy, few indications prompt definitive surgical therapy for chronic hidradenitis suppurativa. That said, lesions may become secondarily infected with staphylococcal, nonhemolytic streptococcal, *Escherichia coli*, and *Proteus* species, as well as anaerobes. Additional testing with biopsies and bacterial cultures may be indicated in atypical or refractory cases (Jemec, 2012).

Hidradenitis suppurativa can be difficult to treat, especially when lesions are chronic and extensive. This, in part, stems from the often multiple, deep-seated sites of secondary infection, which antibiotics may not easily penetrate. In general, antibiotics are first-line therapy. With mild superficial lesions, topical 1-percent clindamycin solution applied twice daily is thought to prevent secondary bacterial infections and improve inflammation (Clemmensen, 1983). Oral clindamycin, 300 mg twice daily,

TABLE 12-1. Antibiotic Regimens for Necrotizing Fasciitis

Infection Type	Antimicrobials ^a	Bacterial Coverage
Mixed	Vancomycin (C)	MRSA
	or	
	Daptomycin (B)	
	or	
	Linezolid (C)	
	PLUS	
Streptococcal	Piperacillin-tazobactam (B)	Gram positive Gram negative Anaerobes Group A <i>Streptococcus</i> <i>Clostridium</i> spp
	or	
	Ertapenem (B)	
	or	
	Imipenem (C)	
	or	
<i>Staphylococcus aureus</i>	Meropenem (B)	Gram positive Gram negative Anaerobes Group A <i>Streptococcus</i> <i>Clostridium</i> spp
	Penicillin (B)	
	PLUS	
	Clindamycin (B)	
	Nafcillin (B)	
	or	
Oxacillin (B)		
or		
Cefazolin (B)		
PLUS		
Clindamycin (B)		

^aFood and Drug Administration pregnancy category is listed in parentheses.

MRSA = methicillin-resistant *Staphylococcus aureus*.

Data from Stevens, 2014.

may better manage deep-seated lesions (Alhusayen, 2012). As needed, Gram stain and culture can guide antibiotic therapy.

Of other options, in reproductive-aged women, isotretinoin and antiandrogen therapy are used cautiously and require reliable birth control. However, in pregnancy, these two options are avoided because of potential adverse fetal effects (Shirazi, 2015). Extensive surgical management or “unroofing” procedures should be postponed until after delivery.

BARTHOLIN GLAND DUCT ABSCESS

■ Pathogenesis

Cysts and abscess formation are the most common disorders of the Bartholin gland ducts, affecting 2 to 3 percent of women. However, few data are available regarding the specific epidemiology of Bartholin gland duct infection in pregnancy. In one study of 219 women with Bartholin gland duct abscesses, 5.5 percent were pregnant at the time of diagnosis (Kessous, 2013). Affected women may often have prior or concomitant STDs, especially gonorrhea or chlamydial infection. Recurrent abscess may result from a scarred Bartholin gland duct damaged during prior infection. Causative organisms are those of the normal vaginal flora. Thus, potential organisms include gram-negative

and gram-positive anaerobic rods, *E coli*, and staphylococcal or streptococcal species (Kessous, 2013; Tanaka, 2005).

Clinical presentation of a Bartholin gland duct infection is usually an abscess. Ductal infection (bartholinitis) without abscess is unusual. Abscesses are generally unilocular and several centimeters in diameter (Fig. 12-3). Similar to other vulvar

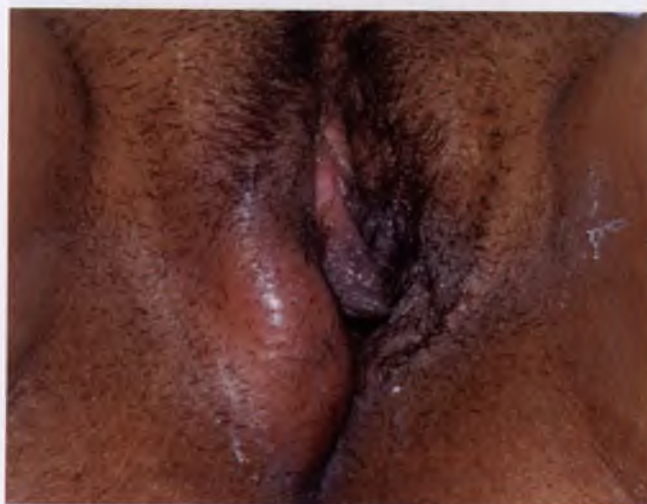

FIGURE 12-3 Right Bartholin gland duct abscess.

abscesses, surrounding erythema, induration, and tenderness may obscure the actual abscess size. Rarely, bacteremia, septic shock, and a toxic-shock-like syndrome can also complicate Bartholin gland duct infections (Honig, 1991; Lopez-Zeno, 1990; Shearin, 1989; Sherer, 2009). Moreover, careful examination for necrotizing fasciitis should precede decisions on the optimal treatment, especially in immunocompromised women. Decisions concerning appropriate therapy depend on underlying immune status and infection severity.

In general, immunocompetent women with early, mild infection or a small abscess can be treated with a broad-spectrum oral antibiotic, analgesics, and local heat by packs or sitz baths. The hope is that warmth will open the obstructed ostium to permit spontaneous evacuation. With such local therapy, abscesses often drain within 1 to 2 days. In abscess management, abscess excision is not indicated. Thus, if the abscess is large and fluctuant, then surgical drainage is appropriate.

■ Surgical Drainage

Several surgical techniques for Bartholin gland duct abscess include I & D, marsupialization, and catheter drainage. None of these has undergone randomized, prospective evaluation in sufficiently large trials to show differences in outcome. With surgical treatment for Bartholin gland duct abscesses, there are four main goals. First, the infected duct abscess must be adequately emptied. Second, infection complications such as cellulitis or infrequently necrotizing fasciitis and sepsis are identified or prevented. Third, the gland should be preserved, so that it may continue its secretory function. Last, recurrences should be prevented by creation of a new gland duct ostium to replace the function of the presumed damaged or occluded duct. The new opening is actually a cutaneous fistula that may take several weeks to fully epithelialize. Patency of this tract allows continued gland secretion without cyst or recurrent abscess formation.

During patient consenting, several potential complications are discussed. First, following I & D, the Bartholin gland duct can become obstructed again. This is not uncommon, and patients are informed of the possible need to repeat the procedure. Dyspareunia is an infrequent long-term sequela. Rarely, bleeding from vestibular bulb laceration or sepsis may occur. Also rare, chorioamnionitis and sternoclavicular septic arthritis after drainage of a Bartholin gland duct abscess in a pregnant woman has been reported (Kelly, 2014).

Word Catheter Placement

The simplest I & D technique involves creating a 1-cm-long vertical stab wound with a no. 11 or 15 scalpel blade into the abscess cavity (Fig. 12-4). The incision is placed just outside and parallel to the hymen at 5 or 7 o'clock (depending on the side involved). This position mimics the normal anatomy of the gland opening. If the abscess has drained spontaneously, the opening can be extended as needed to improve evacuation. Wound cultures may be obtained at this time. At our institution, we typically obtain pus samples for aerobic culture and for nucleic acid amplification testing (NAAT) for *Neisseria gonorrhoeae* and *Chlamydia trachomatis*.

Following drainage, the cavity is explored with a small cotton-tip swab to open potential pus loculations. Probing is gentle to avoid perforation through the duct wall and into the nearby and highly vascular vestibular bulb.

The tip of a self-retaining Word catheter is inserted into the cavity. This flexible latex device has a 10F stem, measures 5 cm long, and has a balloon tip. Once the tip is seated within the cavity, 2 to 5 mL of water or saline is injected into the catheter hub and travels to fill the balloon (Word, 1964). Insufflation with fluid is preferred to air, as the latter is associated with premature balloon deflation. The bulb is inflated sufficiently to prevent spontaneous catheter expulsion through the incision opening. Once in place, the catheter permits pus to drain out around it. The Word catheter stem also serves as the template around which the new fistulous tract forms. The hub end of the

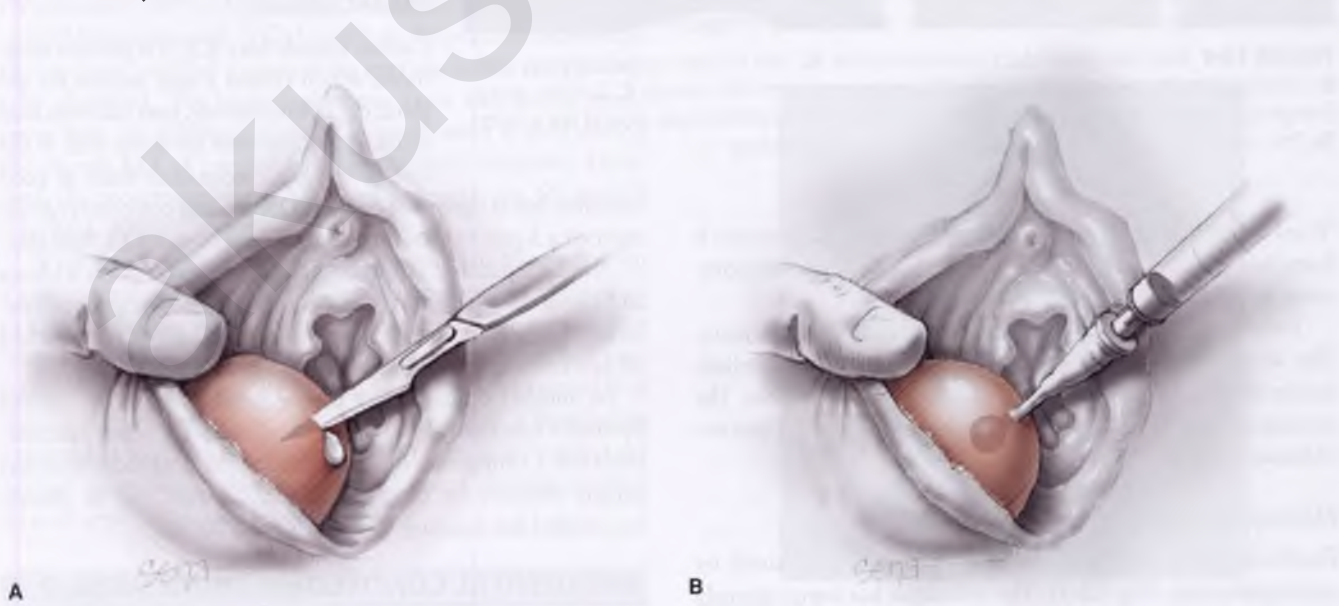


FIGURE 12-4 Bartholin gland duct incision and drainage (A) followed by Word catheter insertion and balloon insufflation (B). (Reproduced with permission from Hoffman BL, Corton MM: Surgeries for benign gynecologic conditions. In Hoffman BL, Schorge JO, Bradshaw KD, et al: Williams Gynecology, 3rd ed. New York, McGraw-Hill Education, 2016.)

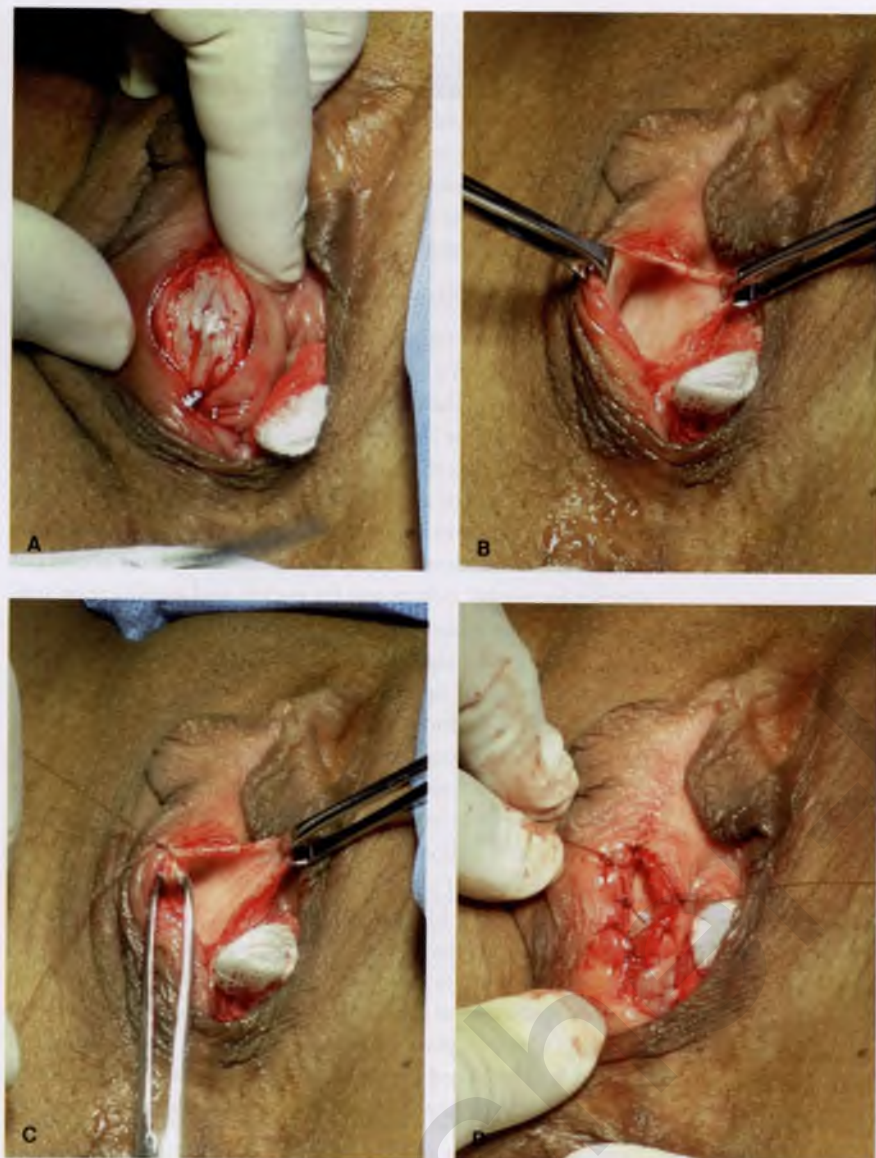

FIGURE 12-5 Bartholin gland duct marsupialization. **A.** Skin incision reveals abscess wall. **B.** Following cavity drainage, the cyst walls are grasped with Allis clamps. **C.** Sutures using fine-gauge absorbable or delayed-absorbable are placed circumferentially around the incision. **D.** This completed opening will narrow markedly during healing.

Word catheter is then tucked inside the vagina. This prevents it from being dislodged by traction during normal perineal movement and improves catheter comfort.

Following I & D, sitz baths can aid healing and ease pain. The Word catheter may be removed after sufficient epithelialization of the new fistula is complete, usually 2 to 4 weeks. The recurrence rate for this technique ranges from 2 to 25 percent (Marzano, 2004).

Marsupialization

Bartholin gland duct abscesses also can be safely drained by marsupialization (Fig. 12-5). The technique has been variously described, but in sum, the abscess is opened, the abscess lining at this incision is isolated, and the lining is tacked to the vestibular skin around the incision using fine absorbable suture. The procedure may require general or regional anesthesia but

can be accomplished with local infiltration or pudendal block. Large abscesses usually require greater degrees of anesthesia.

To begin, a vertical or elliptical incision is made using a scalpel with a no. 15 blade. Importantly, an ostium of sufficient diameter is created to compensate for wound narrowing, as the healed fistula has an appreciably smaller caliber. An incision measuring 1 to 2 cm is usually adequate (Mayeaux, 2013). The cut is made across the skin overlying the cyst bulge and is placed just outside and parallel to the hymen at 5 or 7 o'clock (depending on the side involved). This position mimics normal anatomy of the gland duct ostium.

A second superimposed vertical incision then opens the underlying cyst wall, and pus under pressure spills out. Pus may be cultured. Allis clamps are then placed on the superior, inferior, right, and left lateral cyst wall edges around the incision and fanned out. The cavity is explored with a small cotton-tip swab to open potential fluid loculations. Again, gentle probing avoids duct wall perforation and vestibular bulb laceration. The edges of the cyst wall are sutured to adjacent skin edges with interrupted sutures using 2-0 or 3-0 gauge absorbable or delayed-absorbable suture.

The abscess cavity can be packed loosely with quarter-inch plain gauze, which may be removed after 24 hours. However, this is not mandatory. Healing is usually completed by 10 days, and recurrence is rare.

Other Options

Carbon dioxide laser (CO₂) is another treatment, which creates a new ostium for the gland duct. Alternatively, laser has been used to incise and vaporize the inner wall of the cyst cavity. Both techniques result in good

outcomes but at significant cost. Di Donato and coworkers (2013) reported a 3-year relapse-free rate of 88 percent with CO₂ laser use.

Needle aspiration of infected Bartholin gland ducts without additional therapy appears to have the highest recurrence rate. In one study of 98 patients, the associated failure rate reached 38 percent within 6 months (Wechter, 2009).

As another option, silver nitrate application to the incised Bartholin cyst cavity was evaluated in one prospective randomized trial. Compared with marsupialization, this technique was equally effective for managing Bartholin duct cyst or abscess but yielded less scarring (Ozdegirmenci, 2008).

ANOGENITAL CONDYLOMA ACUMINATA

■ Pathogenesis

Human papillomavirus (HPV) infection during pregnancy can present as a latent, subclinical, or clinical anogenital infection

that poses little risk to pregnancy outcome. With clinical infection, HPV types 6 or 11 are often involved, are “low-risk” oncogenic types, and produce anogenital warts. In contrast, infection with higher-risk HPV types is frequently associated with cervical intraepithelial neoplasia (CIN). High-risk oncogenic types include 16, 18, 31, 33, and 35 (Castellsagué, 2008).

Anogenital warts, also termed condylomata acuminata, are thought to enlarge or proliferate in pregnancy. However, few studies have compared incidences in pregnant and nonpregnant patients (Oriel, 1971). In populations with lower HPV prevalence, incidence of condyloma may be lower in pregnant than nonpregnant patients (Yuk, 2014). Accelerated viral replication with advancing pregnancy has been hypothesized to explain the growth of perineal lesions and increased detection of HPV DNA from the cervicovaginal lavage in pregnant women (Fife, 1999; Rando, 1989).

■ Medical Treatment

HPV management for any woman begins with careful visual examination, sometimes aided by colposcopy of the entire lower genital tract. External genital warts are generally easily identified, and neither biopsy nor HPV DNA typing for confirmation is necessary in most cases.

Condylomata acuminata rarely complicate vaginal delivery. Lesions commonly improve or regress rapidly following delivery. Consequently, condylomata acuminata may be managed expectantly in gravidas. If instituted, therapy aims to minimize treatment toxicity to the mother and fetus and debulk symptomatic genital warts.

In pregnancy, treatment options are limited, and podophyllin, podophyllotoxin, interferon, and 5-fluorouracil (5-FU) are contraindicated. Moreover, data are scarce to support the safety of topical imiquimod or sinecatechins in pregnancy. Accordingly, these therapies are also generally not recommended (Workowski, 2015). Application of bichloroacetic acid (BCA) or trichloroacetic acid (TCA) in 80- to 90-percent solutions is the preferred medical treatment for gravidas as it is not systemically absorbed. The highest clearance rates and lowest recurrence rates are achieved when TCA application is used during the second half of pregnancy or in the third trimester. However, the recurrence rate is high and approximates 63 percent (Garland, 2009).

With TCA or BCA application, a small dab of solution on a cotton-swab tip is applied only to the warts and allowed to dry. In response, a white “frosting” develops on the wart surface within minutes. This treatment can be repeated weekly if necessary. If an excess amount of acid is applied, the treated area should be powdered with talc, baking soda, or a liquid-soap preparation to remove unreacted acid. Preventively, coating the normal surrounding skin with a thin layer of petrolatum prior to acid application may be protective.

■ Surgical Treatment

Of surgical options, all are considered safe in pregnancy and would typically be performed during the second trimester. Cryotherapy destroys warts by cryoinduced cytolysis using liquid nitrogen applied directly to the wart. Treatment generally

does not require anesthesia and is associated with minimal scarring. Success rates range from 60 to 100 percent, but warts recur in 38 to 73 percent of pregnant and nonpregnant women (Garland, 2009).

Excision of warts at their base can be accomplished with a scalpel to remove the affected tissue, but this requires local anesthesia. Recurrence rates range from 19 to 29 percent.

Laser ablation heats or vaporizes tissue. Special equipment and training are required, as depth and extent of vaporization is carefully controlled to avoid collateral destruction of underlying tissue. Associated procedural risks are pain, bleeding, collateral and underlying skin damage, and postoperative scarring. Thus, greater degrees of analgesia are typically required, and regional or general anesthesia may be needed for bulky lesions. Cure rates range from 60 to 100 percent, and warts recur in up to 80 percent of cases (Beutner, 1999).

■ Preventive Steps

Vertical transmission of virus to the neonate is rare but can lead to juvenile-onset respiratory papillomatosis. This most often involves HPV types 6 and 11. One large retrospective study found a vertical transmission rate of 7 cases per 1000 women with anogenital warts (Silverberg, 2003). That said, data are limited to draw definitive conclusions regarding the protective effect of cesarean delivery (Workowski, 2015). Cesarean delivery is not recommended to prevent vertical transmission. Cesarean delivery may be indicated if vulvar or vaginal warts are obstructing the birth canal or pose a risk of significant avulsion and hemorrhage during vaginal delivery (Fig. 12-6).

Prevention of most condylomata is possible by vaccination with a quadrivalent vaccine (Gardasil) that covers HPV types 6, 11, 16, 18 or with a bivalent vaccine (Cervarix) that addresses HPV types 16 and 18. In 2014, the Food and Drug Administration (FDA) also approved a 9-valent HPV-strain vaccine (Gardasil-9) for use in females aged 9 to 26 years and males aged 9 to 15. This new vaccine targets five additional HPV

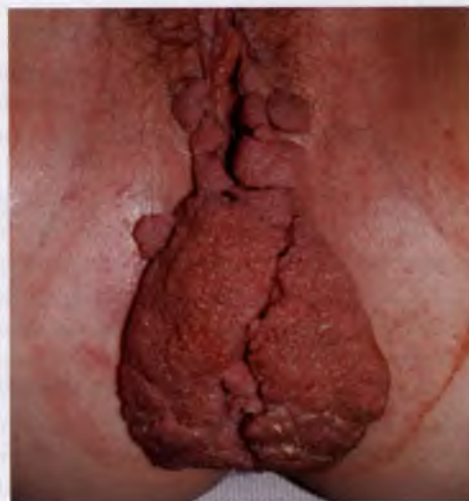

FIGURE 12-6 Extreme growth of condyloma acuminata surrounds the anus and covers the perineum and distal labia. This patient underwent cesarean delivery due to concerns for tissue tearing and bleeding with vaginal delivery. This photograph was taken 8 weeks postpartum prior to surgical excision.

types (31, 33, 45, 52, 58) and generates an antibody response to HPV 6, 11, 16, and 18 that is noninferior to that generated by the quadrivalent vaccine (Joura, 2015).

Vaccination incorporates three intramuscular doses. A first dose is followed by a second injection in 1 or 2 months and then by a final dose given 6 months after the first. This HPV immunization is not currently recommended during pregnancy. That said, data from a pregnancy registry have suggested no fetal or neonatal harm if pregnancy occurs shortly after immunization (Centers for Disease Control and Prevention, 2011). If a woman is found to be pregnant after starting the vaccination series, the remaining doses are delayed until after delivery. Women who are breastfeeding may be vaccinated.

VAGINAL FLORA

A broad range of bacteria make up the normal vaginal flora. Although their full function is unknown, this population does provide a first-line defense by impeding overgrowth of virulent exogenous bacteria. During a woman's reproductive years, the dominant vaginal bacteria are traditionally thought to be lactobacilli. These are gram-positive facultative anaerobic or microaerophilic rod-shaped bacteria. In the research setting, understanding emerging variations of vaginal flora can help distinguish normal from abnormal secretions and explain greater susceptibility to specific infection.

To categorize vaginal flora, culture and culture-independent techniques have helped identify five major and two singleton vaginal bacterial communities in asymptomatic, nonpregnant, reproductive-aged women (Ravel, 2011). Identified ethnic differences may be explained in part by differences in human practices and by host genetics. Of these bacterial communities, 73 percent are dominated by one or more *Lactobacillus* species that constituted >50 percent of all obtained sequences using polymerase chain reaction (PCR). The two vaginal communities without *Lactobacillus* dominance show greater vaginal microbiome variability and higher Nugent scores, described later. Notably, these two communities are associated with increased risk of STD acquisition that can include HIV. These are also linked with adverse pregnancy outcomes such as preterm birth, postabortal sepsis, early and late miscarriage, recurrent abortion, histologic chorioamnionitis, and postpartum endometritis (Lamont, 2011a,b).

The effect of pregnancy on vaginal flora is not clearly understood. A few studies have investigated vaginal microbiome composition or its stability in pregnancy using culture-independent techniques either at single time points or longitudinally. Microbiome shifts may account for the physiologic changes in pregnancy that can affect a woman's risk for STD acquisition or other vulvovaginitis. In one small study of 30 women, pregnancy was associated with less variability in the vaginal microbiome (Romero, 2014). Anderson and associates (2013) followed a cohort of women at low risk for gestational complications during their pregnancy and immediately postpartum. Goals were to investigate changes in vaginal flora and changes in cervicovaginal immune cell composition. *Lactobacillus* populations declined in the third trimester compared with those of nonpregnant controls (71 versus 100 percent). These populations

diminished further in the puerperium (18 percent). In this study, the third trimester was also associated with a lower colonization by *E coli* compared with the nonpregnant state. Few local and systemic immune cell changes were noted during pregnancy, but levels of proinflammatory cytokine interleukin 1 β and C-reactive protein were substantially different between pregnant and nonpregnant women. *Ureaplasma urealyticum* was isolated from 60 percent of the pregnant women in this study. As such, this may play a role as a normal commensal organism. Despite these interesting bench-top findings, correlation between these data and clinical pregnancy outcomes are unclear.

BACTERIAL VAGINOSIS

This is the most common cause of vaginal discharge among reproductive-aged women worldwide. Bacterial vaginosis (BV) represents a pathogenic shift of the vaginal flora with a polymicrobial overgrowth of facultative and anaerobic organisms. The normal flora is replaced by a broad range of primarily anaerobic bacteria including *Gardnerella vaginalis*, *Atopobium vaginae*, and *Mobiluncus* species, among others.

Of pregnant women, 10 to 30 percent fulfill criteria for BV, and approximately 50 percent of these women are asymptomatic. Accurately diagnosing BV is critical because vaginitis is frequently treated empirically, often leading to delay of appropriate therapy. Diagnosis can be made using clinical criteria. Amsel criteria include: (1) presence of a thin, gray vaginal discharge, (2) release of a fishy odor following application of 10-percent potassium hydroxide (KOH) to a slide preparation of the discharge ("whiff" test), (3) clue cells that comprise >20 percent of a saline preparation's squamous cell population, and (4) vaginal pH >4.7. Another criteria set, the Nugent score, involves microscopic examination of a gram-stained vaginal discharge smear. Scores are calculated by assessing bacterial staining and morphology. By comparison, Amsel criteria are more specific, whereas the Nugent score is more sensitive. Amsel criteria are used more often by the practicing clinician, whereas both the Nugent and Amsel scores may be used for clinical research. One analysis of classic BV diagnostic criteria in 310 patients revealed that the single most reliable indicator of BV was the presence of clue cells on wet mount examination of vaginal secretions. With this, a sensitivity of 98 percent, specificity of 94 percent, positive predictive value of 90 percent, and negative predictive value of 99 percent was found (Thomason, 1990).

BV is not transmitted vertically but is a significant risk factor for acquisition of other infections, including HIV (Farquhar, 2010). It is also linked with adverse pregnancy outcomes such as preterm delivery, clinical and histologic chorioamnionitis, postpartum endometritis, and postcesarean infections (Duff, 2014). The CDC notes that insufficient evidence supports screening for BV in asymptomatic pregnant women to prevent preterm birth (Workowski, 2015). This pertains to women at high or low risk for preterm delivery.

To relieve symptoms in a woman who complains of a fishy-smelling discharge, treatment is recommended. In pregnancy, one option is oral metronidazole administered as a 500-mg dose twice daily for 7 days. Metronidazole is considered an FDA pregnancy category B drug. Alternatives include vaginal

TABLE 12-2. Common Infections and Preferred Treatment in Pregnancy

Infection	Drug ^a	Dosage
Vulvovaginal candidiasis	Recommended	
	Clotrimazole 1% cream	1 app vaginally for 7 days
	2% cream	1 app vaginally for 3 days
	Alternative	
	Fluconazole	150 mg orally once
Bacterial vaginosis	Recommended	
	Metronidazole	500 mg orally twice daily for 7 days
	Metronidazole gel 0.75%	5 g (1 applicator) vaginally daily for 5 days
	Clindamycin cream 2%	5 g (1 applicator) vaginally daily for 7 days
	Alternative	
	Clindamycin	300 mg orally twice daily for 7 days
	Clindamycin ovules	100 mg vaginally daily for 3 days
Gonorrhea	Recommended	
	Ceftriaxone	250 mg IM once
	PLUS	
	Azithromycin	1 g orally once
	Alternative	
	Cefixime	400 mg orally once
	PLUS	
	Azithromycin	1 g orally once
Chlamydial	Recommended	
	Azithromycin	1 g orally once
	Alternative	
	Erythromycin base	500 mg orally four times daily for 7 days
Trichomoniasis	Recommended	
	Metronidazole	2 g orally once or 500 mg orally twice daily for 7 days

^aAll agents are Food and Drug Administration pregnancy category B except for fluconazole (category C).

IM = intramuscular; MRSA = methicillin-resistant *Staphylococcus aureus*.

metronidazole gel and oral or vaginal clindamycin cream (Table 12-2). These agents are preferable to tinidazole, which has only limited data regarding its use and safety in pregnancy (Briggs, 2015). Treatment of recognized BV is also considered prior to planned operative obstetric procedures to reduce risks of postoperative endometritis (Watts, 1990).

Clinical resolution usually follows shortly after treatment cessation. However, recurrence rates are high and range from 30 to 50 percent within 2 to 3 months of treatment (Verstraelen, 2009). Practitioners often find the treatment of repeat episodes of BV problematic, and few data guide optimal treatment. Selecting a different option from Table 12-2 can be used for a recurrence. Retreatment with the same initial regimen is also acceptable for treating persistent or recurrent BV after a first episode (Workowski, 2015).

In women with recurrent BV, a vaginal biofilm community may form and contain several organisms that create a field difficult to penetrate with antibiotics. Namely, *G vaginalis* can create a biofilm that adheres to vaginal epithelium. Further work illustrates this bacterium may be just the initial species whose

presence aids growth of other species normally associated with BV. The biofilm may contain *G vaginalis*, *A vaginae*, and *Bacteroides*, *Corynebacterium*, *Prevotella*, *Ruminococcus*, and *Streptococcus* species, among others (Swidsinski, 2005; Verstraelen, 2013).

SEXUALLY TRANSMITTED DISEASES

These infections are common in reproductive-aged women and can pose some risk to the perinate. Among potential complications, preterm birth and neonatal infection are prominent.

■ Gonorrhea

The number of annually reported cases has steadily declined since implementation of a national gonorrhea control program in the United States in the 1970s. In 2014, the rate of reported gonorrhea was 101 cases per 100,000 women (Centers for Disease Control and Prevention, 2015).

N gonorrhoeae is a gram-negative diplococcus that primarily infects nonciliated, columnar, or cuboidal epithelium of the endocervix, urethra, rectum, or pharynx. Gonococci are

obligate human pathogens that cannot survive outside the human host. The incubation period for *N gonorrhoeae* is 3 to 5 days, and male-to-female transmission is approximately 50 to 90 percent with a single exposure (Hooper, 1989).

Gonorrhea has been associated with an increased risk for adverse pregnancy outcomes including septic abortion, spontaneous preterm birth, prematurely ruptured membranes, chorioamnionitis, stillbirth, small-for-gestational-age neonate, postpartum infection, and increased risk of maternal HIV acquisition. Thus, prompt treatment is recommended (Alger, 1988; Johnson, 2011; Liu, 2013). Vertical transmission to the neonate can occur in 30 to 47 percent of cases if cervical infection is present at the time of vaginal delivery. Rare cases have also been reported with cesarean delivery in the setting of ruptured membranes (Diener, 1981; Strand, 1979).

Up to 80 percent of infected women are asymptomatic. Clinically manifestations vary and include mucopurulent vaginal discharge and cervical friability. Dysuria can also be present. Frequently, nonpregnant women with gonorrhea will not seek medical attention until signs or symptoms of upper tract infection are present, but these ascending infections are less common in pregnancy.

Currently, performing NAAT of an endocervix or vaginal sample obtained with a Dacron swab is preferred for diagnosis. A first-catch urine sample is acceptable but may detect up to 10-percent fewer infections (Papp, 2014). NAAT has replaced culture in most laboratories. It has a sensitivity >90 percent and a specificity >99 percent (Knox, 2002; Masek, 2009; Papp, 2014). Although it is a more expensive option than culture or Gram stain, results are rapid and accurate. NAATs using PCR to amplify specific *N gonorrhoeae* target sequences will detect both live and dead organisms. Thus, a test-of-cure sample is ideally not collected sooner than 3 weeks following treatment to avoid unnecessary retreatment. Additionally, false-positive results may occur in low-prevalence populations. However, the CDC no longer recommends routine additional testing following a positive NAAT result during screening unless otherwise indicated by the specific NAAT product insert (Papp, 2014).

If antibiotic resistance is suspected, a culture is instead collected to perform antibiotic susceptibility testing. Over time, *N gonorrhoeae* has acquired resistance to fluoroquinolones, penicillins, and tetracyclines, and antibiotic resistance is a legitimate concern for gonococcal infections. Accordingly, dual therapy is recommended to prevent antibiotic resistance. For gravidas, current CDC guidelines recommend intramuscular ceftriaxone 250 mg plus oral azithromycin 1 or 2 g both as a single dose (see Table 12-2) (Workowski, 2015). In the setting of severe IgE-mediated penicillin allergy, an infectious disease specialist should be consulted.

Preventively, all pregnant women living in a high-seroprevalence area are screened for gonorrhea at their first prenatal visit. Women younger than 25 years have the highest infection risk. Other risk factors include new or multiple sexual partners, prior STD, partner with an STD, and exchanging sex for drugs or money (Workowski, 2015). If a woman is treated for gonorrhea during pregnancy, she is additionally tested for other STDs that include syphilis, trichomoniasis, and HIV, hepatitis

B, and chlamydial infection. Testing is repeated within 3 to 6 months, preferably in the third trimester of pregnancy.

■ Chlamydial Infection

Urogenital *C trachomatis* is the most common sexually transmitted infection in the United States. Infections with *C trachomatis* encompass cervicitis, urethritis, and conjunctivitis in both neonates and sexually active adolescents. In 2014, the rate of reported chlamydial infections was 456 cases per 100,000 women (Centers for Disease Control and Prevention, 2015).

Chlamydia trachomatis is an obligate intracellular pathogen that targets squamocolumnar cells of the endocervix and upper genital tract, conjunctiva, urethra, and rectum. The incubation period depends on the infection type, but generally lasts 7 to 21 days. The risk of chlamydia acquisition after a single episode of intercourse is unknown but thought to be lower than with gonorrhea. It is readily transmissible during vaginal, anal, or oral sex and during vaginal delivery.

Women with untreated chlamydial infection are thought to carry greater risks for preterm premature rupture of membranes, preterm birth, a low-birth-weight neonate, and a decreased perinatal survival rate compared with treated women or uninfected controls (Ryan, 1990). Universal screening in pregnancy is not recommended, but women younger than 25 years in high-prevalence areas should be tested at the first perinatal visit. Risk factors and clinical findings for chlamydial infection are similar to those for gonorrhea. Diagnosis is best made using NAAT from a provider- or patient-collected endocervical or vaginal swab or from a first-catch urine sample (Papp, 2014).

Treatment is azithromycin, 1 g orally once. Alternative treatments include erythromycin and amoxicillin. Treatment failure is infrequent. Thus, most posttreatment infections result from reinfection from a sexual partner who was incompletely treated or from initiation of sexual activity with a new partner. Partner treatment is recommended for all STDs, and test of cure should be documented during pregnancy. Concurrent screening for gonorrhea, trichomoniasis, syphilis, and HIV and hepatitis B infection is performed.

■ Trichomoniasis

Infection caused by the protozoan *Trichomonas vaginalis* is often subclinical. This organism can persist in the female urogenital tract for long periods, but up to one third of asymptomatic women will develop symptoms within 6 months (Heine, 1993). With symptoms, complaints can range from scant vaginal discharge with pruritus to heavy, yellow-green, frothy vaginal secretions. Dysuria is another potential symptom. *Trichomonas vaginalis* is a common pathogen associated with increased risk of maternal HIV acquisition and transmission and risk of upper genital tract infection (Miller, 2011). Data from a nationally representative cohort study between 2001 and 2004 demonstrated that 3 percent of reproductive-aged women in the United States are infected (Satterwhite, 2013).

Some studies have linked trichomoniasis with preterm birth, however, treatment does not decrease this risk (Gulmezoglu, 2011; Wendel, 2007). Thus, screening of asymptomatic women is not recommended during pregnancy. Rare cases of neonatal

pneumonia, sepsis, and vaginal trichomoniasis from maternal infection have been reported (Szarka, 2002; Trintis, 2010).

For symptomatic women, there are no official guidelines for *T vaginalis* testing. Diagnosis can be made by direct visualization of motile trichomonads during saline microscopy. However, this approach provides typically only 60- to 70-percent sensitivity. Culture is considered the most accurate laboratory test but requires 5 days for results (Nye, 2009). Also, vaginal specimens may be evaluated with point-of-care, FDA-approved tests that include the OSOM *Trichomonas* Rapid Test (Genzyme Diagnostics) and the Affirm VP III (BD Diagnostic Systems). These offer sensitivities of 64 to 98 percent and specificities of 99 to 100 percent (Andrea, 2011; Hobbs, 2013; Huppert, 2007). Of these, the OSOM *Trichomonas* Rapid Test is a dipstick assay using monoclonal antibodies specific to trichomonad antigens and can be read within 10 minutes. Another option, the Aptima *Trichomonas vaginalis* assay (Hologic) is a NAAT that has a sensitivity near 100 percent (Andrea, 2011; Huppert, 2007; Nye, 2009). It requires formal laboratory processing and thus results are not immediate. However, it is the authors' preference to use such NAAT methods, because of their high sensitivity and specificity.

Preferred treatment is oral metronidazole, 2 g in a single dose. This agent is preferable to tinidazole, which has only limited data regarding its use and safety in pregnancy (Briggs, 2015). Topical metronidazole is ineffective for treatment of vaginal trichomoniasis. Metronidazole-resistant trichomoniasis develops in 5 percent of women. Resistance in pregnancy is rare, and one case report described successful treatment with high-dose tinidazole (Subramanian, 2011).

PELVIC INFLAMMATORY DISEASE

This spectrum of upper genital tract infections is presumed to result from ascending lower genital tract infection. Gonorrhea was previously the most common cause until the introduction of penicillin. Currently, chlamydial infection accounts for one third of cases. Pelvic inflammatory disease (PID) is infrequent during pregnancy, is typically limited to the first trimester, and is an indication for hospitalization. Parenteral antibiotics most suitable for pregnancy are clindamycin 900 mg every 8 hours plus gentamicin 3 to 5 mg/kg in a single daily dose. Tubo-ovarian abscess (TOA) is a rare complication of PID during pregnancy. Cases following in vitro fertilization and embryo transfer have been reported (Matsunaga, 2003). Also infrequently, a chronic asymptomatic TOA may be incidentally discovered at cesarean delivery (Erdem, 2002).

VULVOVAGINAL CANDIDIASIS

Yeast is typically a commensal component of normal vaginal flora. However, certain predisposing factors such as diabetes mellitus, pregnancy, antibiotic or corticosteroid use, and immunosuppression may result in episodic infection. *Candida albicans* is overwhelmingly the most common species, although recurrent vulvovaginal candidiasis (VVC) can also occur with non-*albicans* species including *Candida glabrata*. Yeast infection is a frequent cause of vaginitis in nonpregnant women. Moreover, the incidence is thought to rise in pregnancy and is

associated with more frequent recurrences and reduced therapeutic response. Symptomatic VVC affects at least 15 percent of gravidas (Sobel, 2007). Of inciting reasons, high hormone levels in pregnancy lead to increased vaginal glycogen concentrations, which provide a carbon source for yeast. Estrogen also enhances adherence of yeast to vaginal epithelial cells.

VVC can be diagnosed with the addition of 10-percent KOH to a saline microscopy slide to aid visualization of budding yeast or hyphae. Such KOH preparation has a sensitivity that approximates 50 percent. Thus, obtaining a yeast culture is reasonable if the diagnosis is unclear and if symptoms of itching, burning, abnormal vaginal discharge suggest this infection. Vaginal pH is typically normal (pH <4.5), and whiff test results are generally negative. To date, PCR testing for *Candida* species is not FDA-approved, thus yeast culture remains the gold standard for diagnosis (Workowski, 2015).

VVC may be treated with either oral or topical agents. Topical agents are preferred in pregnancy because oral azoles are FDA pregnancy category C. Over-the-counter CDC-recommended intravaginal agents include: 1- to 2-percent clotrimazole cream, 2- to 4-percent miconazole cream, miconazole 100 mg or 200 mg vaginal suppositories, or 6.5-percent tioconazole ointment. Butoconazole or terconazole of variable strength given as a cream or vaginal suppository is also available by prescription (Workowski, 2015).

In 5 to 10 percent of women with recurrent VVC, defined as more than four episodes per year, maintenance oral fluconazole administered as 150 mg weekly for 6 months may be considered. This regimen has not been studied in pregnancy.

Although common in pregnancy, candidiasis poses little risk to mother or fetus. One study evaluated the eradication of asymptomatic *Candida* in pregnancy to reduce preterm birth rates. There were no statistically significant differences in outcomes between treatment groups (Roberts, 2011). Congenital candidiasis is rare and manifests as cutaneous vesiculopustular eruptions or pneumonia (Wang, 2008). It can manifest early in neonatal life and is thought to result from ascending infection (Duff, 2014; Filippidi, 2014).

REFERENCES

- Alger LS, Lovchik JC, Hebel JR, et al: The association of *Chlamydia trachomatis*, *Neisseria gonorrhoeae*, and group B streptococci with preterm rupture of the membranes and pregnancy outcome. *Am J Obstet Gynecol* 159:397, 1988
- Alhusayen R, Shear NH: Pharmacologic interventions for hidradenitis suppurativa: what does the evidence say? *Am J Clin Dermatol* 13(5):283, 2012
- Anaya DA, Dellinger EP: Necrotizing soft-tissue infection: diagnosis and management. *Clin Infect Dis* 44:705, 2007
- Anderson BL, Mendez-Figueroa H, Dahlke JD, et al: Pregnancy-induced changes in immune protection of the genital tract: defining normal. *Am J Obstet Gynecol* 208(4):321.e1, 2013
- Andrea SB, Chapin KC: Comparison of Aptima *Trichomonas vaginalis* transcription-mediated amplification assay and BD affirm VP III for detection of *T vaginalis* in symptomatic women: performance parameters and epidemiological implications. *J Clin Microbiol* 49:866, 2011
- Berger BJ, Hussain F, Roistacher K: Bacterial infections in HIV-infected patients. *Infect Dis Clin North Am* 8:449, 1994
- Beutner KR, Wiley DJ, Douglas JM, et al: Genital warts and their treatment. *Clin Infect Dis* 28 Suppl 1:S37, 1999
- Blaivas M, Adhikari S: Unexpected findings on point-of-care superficial ultrasound imaging before incision and drainage. *J Ultrasound Med* 30(10):142, 2011

- Briggs GG, Freeman RK: *Drugs in Pregnancy and Lactation*, 10th ed. Philadelphia, Lippincott Williams & Wilkins, 2015
- Castellsagué X: Natural history and epidemiology of HPV infection and cervical cancer. *Gynecol Oncol* 110(3 Suppl 2):S4, 2008
- Centers for Disease Control and Prevention: FDA licensure of bivalent human papillomavirus vaccine (HPV2, Cervarix) for use in females and updated HPV vaccination recommendations from the Advisory Committee on Immunization Practices (ACIP). *MMWR* 59(20):629, 2011
- Centers for Disease Control and Prevention: Sexually transmitted disease surveillance 2014. Atlanta, U.S. Department of Health and Human Services, 2015
- Clemmensen OJ: Topical treatment of hidradenitis suppurativa with clindamycin. *Int J Dermatol* 22:325, 1983
- Di Donato V, Bellati F, Casorelli A, et al. CO₂ laser treatment for Bartholin gland abscess: ultrasound evaluation of risk recurrence. *J Minim Invasive Gynecol* 20:346, 2013
- Diener B: Cesarean section complicated by gonococcal ophthalmia neonatorum. *J Fam Pract* 13(5):739, 1981
- Duff P: Maternal and fetal infections. In Creasy RK, Resnik R, Iams JD, et al (eds): *Creasy and Resnik's Maternal Fetal Medicine: Principles and Practice*. 7th ed. Philadelphia, Saunders, 2014
- Erdem M, Arslan M, Yazici G, et al: Incidental tubo-ovarian abscess at abdominal delivery: a case report. *J Matern Fetal Neonatal Med* 12(4):279, 2002
- Farquhar C, Mbori-Ngacha D, Overbaugh J, et al: Illness during pregnancy and bacterial vaginosis are associated with in-utero HIV-1 transmission. *AIDS* 24:153, 2010
- Fife KH, Katz BP, Brizendine EJ, et al: Cervical human papillomavirus deoxyribonucleic acid persists throughout pregnancy and decreases in the postpartum period. *Am J Obstet Gynecol* 180:1110, 1999
- Filippidi A, Galanakis E, Maraki S, et al: The effect of maternal flora on *Candida* colonisation in the neonate. *Mycoses* 57:43, 2014
- Food and Drug Administration: FDA approves Gardasil 9 for prevention of certain cancers caused by five additional types of HPV. 2014. Available at: <http://www.fda.gov/NewsEvents/Newsroom/PressAnnouncements/ucm426485.htm>. Accessed July 9, 2015
- Garland SM, Steben M, Sings HL, et al: Natural history of genital warts: analysis of the placebo arm of 2 randomized phase III trials of a quadrivalent human papillomavirus (types 6, 11, 16, and 18) vaccine. *J Infect Dis* 199:805, 2009
- Gulmezoglu AM, Azhar M: Interventions for trichomoniasis in pregnancy. *Cochrane Database Syst Rev* 5:CD000220, 2011
- Heine P, McGregor JA: *Trichomonas vaginalis*: a reemerging pathogen. *Clin Obstet Gynecol* 36:137, 1993
- Hobbs MM, Sena AC: Modern diagnosis of *Trichomonas vaginalis* infection. *Sex Transm Infect* 89(6):434, 2013
- Honig J: Septic shock complicating drainage of a Bartholin gland abscess. *Obstet Gynecol* 77(3):490, 1991
- Hooper R: Cohort study of venereal disease: the risk of gonorrhea transmission from infected women to men. *Am J Epidemiol* 108:136, 1989.
- Horowitz IR, Buscema J, Majmudar B: Surgical conditions of the vulva. In Rock JA, Jones HW 3rd (eds): *Te Linde's Operative Gynecology*, 10th ed. Philadelphia, Lippincott Williams, & Wilkins, 2011, p 480
- Huppert JS, Mortensen JE, Reed JL, et al: Rapid antigen testing compares favorably with transcription-mediated amplification assay for the detection of *Trichomonas vaginalis* in young women. *Clin Infect Dis* 45(2):194, 2007
- Jemec GB: Hidradenitis suppurativa. *N Engl J Med* 366:158, 2012
- Johnson HL, Ghanem KG, Zenilman JM, et al: Sexually transmitted infections and adverse pregnancy outcomes among women attending inner city public sexually transmitted diseases clinics. *Sex Transm Dis* 38(3):167, 2011
- Joura EA, Guiliano AR, Iverson OE, et al: A 9-valent HPV vaccine against infection and intraepithelial neoplasia in women. *N Engl J Med* 372:711, 2015
- Kelly JC, Jia X, Vindenes T, et al: Chorioamnionitis and sternoclavicular septic arthritis after drainage of Bartholin gland abscess. *Obstet Gynecol* 124(2 Pt 2 Suppl 1):436, 2014
- Kessous R, Aricha-Tamir B, Shezaf B, et al: Clinical and microbiological characteristics of Bartholin gland abscesses. *Obstet Gynecol* 122(4):794, 2013
- Knox J, Tabrizi SN, Miller P, et al: Evaluation of self-collected samples in contrast to practitioner-collected samples for detection of *Chlamydia trachomatis*, *Neisseria gonorrhoeae*, and *Trichomonas vaginalis* by polymerase chain reaction among women living in remote areas. *Sex Transm Dis* 29:647, 2002
- Lamont RF, Nhan-Chang CL, Sobel JD, et al: Treatment of abnormal vaginal flora in early pregnancy with clindamycin for the prevention of spontaneous preterm birth: a systematic review and metaanalysis. *Am J Obstet Gynecol* 205:177, 2011a
- Lamont RF, Sobel JD, Akins RA, et al: The vaginal microbiome: new information about genital tract flora using molecular based techniques. *BJOG* 118:533, 2011b
- Liu B, Roberts C, Clarke M, et al: Chlamydia and gonorrhea infections and the risk of adverse obstetric outcomes: a retrospective cohort study. *Sex Transm Infect* 89(8):672, 2013
- Lopez-Zeno J, Ross E, O'Grady J: Septic shock complicating drainage of a Bartholin gland abscess. *Obstet Gynecol* 76(5 Pt 2):915, 1990
- Marzano DA, Haefner HK: The Bartholin gland cyst: past, present, and future. *J Low Genit Tract Dis* 8:195, 2004
- Masek BJ, Arora N, Quinn N, et al: Performance of three nucleic acid amplification tests for detection of *Chlamydia trachomatis* and *Neisseria gonorrhoeae* by use of self-collected vaginal swabs obtained via an Internet-based screening program. *J Clin Microbiol* 47:1663, 2009
- Matsunaga Y, Fukushima K, Nozaki M, et al: A case of pregnancy complicated by the development of a tubo-ovarian abscess following in vitro fertilization and embryo transfer. *Am J Perinatol* 20(6):277, 2003
- Mayeaux EJ, Cooper D: Vulvar procedures: biopsy, Bartholin abscess treatment, and condyloma treatment. *Obstet Gynecol Clin North Am* 40:759, 2013
- Miller MR, Nyirjesy P: Refractory trichomoniasis in HIV-positive and HIV-negative subjects. *Curr Infect Dis Rep* 13(6):595, 2011
- Nye MB, Schwebke JR, Body BA: Comparison of APTIMA *Trichomonas vaginalis* transcription-mediated amplification to wet mount microscopy, culture, and polymerase chain reaction for diagnosis of trichomoniasis in men and women. *Am J Obstet Gynecol* 200(2):188.e1, 2009
- Oriel JD: Natural history of genital warts. *Br J Vener Dis* 76(1):S21, 1971
- Ozdegirmenci O, Kayikcioglu F, Haberal A: Prospective randomized study of marsupialization versus silver nitrate application in the management of Bartholin gland cysts and abscesses. *J Minim Invasive Gynecol* 16:149, 2009
- Papp JR, Schachter J, Gaydos CA, et al: Recommendations for the laboratory-based detection of *Chlamydia trachomatis* and *Neisseria gonorrhoeae*—2014. *MMWR* 63(2):1, 2014
- Rando RF, Lindheim S, Hasty L, et al: Increased frequency of detection of human papillomavirus deoxyribonucleic acid in exfoliated cervical cells during pregnancy. *Am J Obstet Gynecol* 161:50, 1989
- Ravel J, Gajer P, Abdo Z, et al: Vaginal microbiome of reproductive-age women. *Proc Natl Acad Sci U S A* 108(suppl 1):4680, 2011
- Roberts CL, Rickard K, Kotsiou G, et al: Treatment of asymptomatic vaginal candidiasis in pregnancy to prevent preterm birth: an open-label pilot randomized controlled trial. *BMC Pregnancy Childbirth* 11:18, 2011
- Romero R, Hassan SS, Gajer P, et al: The composition and stability of the vaginal microbiota of normal pregnant women is different from that of non-pregnant women. *Microbiome* 2(1):4, 2014
- Ryan GM, Abdella TN, McNeely SG, et al: *Chlamydia trachomatis* infection in pregnancy and effect of treatment on outcome. *Am J Obstet Gynecol* 162:34, 1990
- Satterwhite CL, Tortrone E, Meites E, et al: Sexually transmitted infections among US women and men: prevalence and incidence estimates, 2008. *Sex Transm Dis* 40(3):187, 2013
- Shearin R, Boehlke J, Karanth S: Toxic shock-like syndrome associated with Bartholin's gland abscess: case report. *Am J Obstet Gynecol* 160(5 Pt 1):1073, 1989
- Sherer DM, Dalloul M, Salameh G, et al: Methicillin-resistant *Staphylococcus aureus* bacteremia and chorioamnionitis after recurrent marsupialization of a Bartholin abscess. *Obstet Gynecol* 114:471, 2009
- Shirazi M, Abbariki E, Pirjani R, et al: Congenital microtia in a neonate due to maternal isotretinoin exposure 1 month before pregnancy: case report. *J Obstet Gynaecol Res* 41(6):975, 2015
- Silverberg MJ, Thorsen P, Lindeberg H, et al: Condyloma in pregnancy is strongly predictive of juvenile-onset recurrent respiratory papillomatosis. *Obstet Gynecol* 101:645, 2003
- Sobel JD: Vulvovaginal candidosis. *Lancet* 369(9577):1961, 2007
- Stevens DL, Bisno AL, Chambers HF, et al: Practice guidelines for the diagnosis and management of skin and soft tissue infections: 2014 update by the Infectious Diseases Society of America. *Clin Infect Dis* 59(2):147, 2014
- Strand CL, Arango VA: Gonococcal ophthalmia neonatorum after delivery by cesarean section: report of a case. *Sex Transm Dis* 6(2):77, 1979
- Subramanian C, Sobel JD: A case of high-level metronidazole-resistant trichomoniasis in pregnancy successfully treated. *J Low Genit Tract Dis* 15(3):248, 2011
- Swidsinski A, Mendling W, Loening-Baucke V, et al: Adherent biofilms in bacterial vaginosis. *Obstet Gynecol* 106:1013, 2005
- Szarka K, Temesvari P, Kerekes A, et al: Neonatal pneumonia caused by *Trichomonas vaginalis*. *Acta Microbiol Immunol Hung* 49(1):15, 2002

- Tanaka K, Mikamo H, Ninomiya M, et al: Microbiology of Bartholin's gland abscess in Japan. *J Clin Microbiol* 43(8):4258, 2005
- Thomason JL, Gelbart SM, Anderson RJ, et al: Statistical evaluation of diagnostic criteria for bacterial vaginosis. *Am J Obstet Gynecol* 162:155, 1990
- Thurman AR, Satterfield TM, Soper DE: Methicillin-resistant *Staphylococcus aureus* as a common cause of vulvar abscesses. *Obstet Gynecol* 112:538, 2008
- Trintis J, Epie N, Boss R, et al: Neonatal *Trichomonas vaginalis* infection: a case report and review of literature. *Int J STD AIDS* 21:606, 2010
- Vasoo S, Barreto JN, Tosh PK: Emerging issues in gram-negative bacterial resistance: an update for the practicing clinician. *Mayo Clin Proc* 90(3):395, 2015
- Verstraelen H, Swidsinski A: The biofilm in bacterial vaginosis: implications for epidemiology, diagnosis and treatment. *Curr Opin Infect Dis* 26(1):86, 2013
- Verstraelen H, Verhelst R: Bacterial vaginosis: an update on diagnosis and treatment. *Expert Rev Anti Infect Ther* 7:1109, 2009
- Wang SM, Hsu CH, Chang JH: Congenital candidiasis. *Pediatr Neonatol* 49:94, 2008
- Watts DH, Krohn MA, Hillier SL, et al: Bacterial vaginosis as a risk factor for post-cesarean endometritis. *Obstet Gynecol* 75:52, 1990
- Wechter ME, Wu JM, Marzano D, et al: Management of Bartholin duct cysts and abscesses: a systematic review. *Obstet Gynecol Surv* 64:395, 2009.
- Wendel KA, Workowski KA: Trichomoniasis: challenges to appropriate management. *Clin Infect Dis* 44:S123, 2007
- Wong CH, Chang HC, Pasupathy S, et al: Necrotizing fasciitis: clinical presentation, microbiology, and determinants of mortality. *J Bone Joint Surg Am* 85-A(8):1454, 2003
- Word B: New instrument for office treatment of cyst and abscess of Bartholin's gland. *JAMA* 190:777, 1964
- Workowski K, Bolan G: Sexually Transmitted Diseases Treatment Guidelines, 2015. *MMWR* 64(3):1, 2015
- Yazdanyar S, Jemec GB: Hidradenitis suppurativa: a review of cause and treatment. *Curr Opin Infect Dis* 24:118, 2011
- Yuk JS, Hong JH, Yi KW, et al: Comparing the prevalence of condylomata acuminata between pregnant women and nonpregnant controls in South Korea. *Sex Transm Dis* 41(5):292, 2014.

CHAPTER 13

Invasive Prenatal Diagnostic Procedures

PREPROCEDURAL STEPS	202
AMNIOCENTESIS	203
CHORIONIC VILLUS SAMPLING	212
FETAL BLOOD SAMPLING	217
OTHER INVASIVE DIAGNOSTIC PROCEDURES	220
SUMMARY	220

Invasive prenatal diagnosis allows vital details to be obtained regarding the fetus that can include genetic, biochemical, or physiologic data. This chapter describes amniocentesis, chorionic villus sampling (CVS), and fetal blood sampling (FBS), which are the most frequently used invasive techniques to obtain this information. Most perinatal centers have the technical expertise to perform all of these procedures and to select the best method for each clinical scenario. However, certain conditions meriting specialized techniques may require referral to a fetal center.

To complement diagnostic imaging and invasive fetal procedures, perinatal centers must provide detailed genetic counseling. With this, available clinical options are described, their risks are explained, and their consequences are communicated in a nondirective, supportive way.

PREPROCEDURAL STEPS

■ Invasive Prenatal Testing Counseling

Myriad tests for *prenatal screening* are available to the practicing obstetrician. The American College of Obstetricians and

Gynecologists (2016b) recommends that all pregnant women regardless of age be offered aneuploidy screening before 20 weeks' gestation. *Diagnostic testing* is then offered to women whose screening test results are positive. In that same publication, the College also endorsed that all pregnant women, regardless of age, should be counseled regarding the option of invasive or diagnostic fetal testing after a thorough explanation of the differences between screening and diagnostic tests.

Invasive prenatal tests yield diagnostic results but have the potential for procedure-related complications. Therefore, pre-test counseling by the obstetrician or maternal-fetal medicine (MFM) specialist or by a genetic counselor or medical geneticist is recommended. Elements of counseling are listed in [Table 13-1](#).

Prior to the procedure, the patient is ideally instructed regarding suggested postprocedural activity restrictions. Further, a description of how complications will be evaluated is recommended.

■ Time Out

Prior to any invasive test, several procedural steps are recommended. Needed specimen containers are assembled and are pre-labeled to reduce errors. Laboratory requisitions are similarly pre-marked to reflect the procedure and type of specimen.

A "time out" is suggested, given the risk of pregnancy complications including fetal loss. Elements that are reviewed and confirmed include correct patient identity and medical record number, the planned procedure, tests to be performed from the samples, potential intraprocedural complications, correct specimen labeling, and pertinent maternal laboratory results. The latter may include maternal blood type, Rh status, and positive results from hepatitis B, hepatitis C, or human immunodeficiency (HIV) testing. Following amniocentesis, CVS, and FBS, all rhesus-negative women (without alloimmunization to D) should receive prophylactic administration of Rh(D) immune globulin.

TABLE 13-1. Elements of Counseling before Invasive Prenatal Testing

Indication for the test
Risks/potential complications of procedure
Alternative therapies or natural history of condition if expectant management elected
Specific test(s) ordered
Diagnostic accuracy and test limitations
Gestational age range for which an invasive test can be safely performed
Waiting interval before a final result is expected
Postprocedural activity limitations

AMNIOCENTESIS

Table 13-2 lists some of the common indications for genetic amniocentesis. The most frequent reason is identification of genetic defects. Other less often used purposes are evaluation of fetal anemia or pulmonary maturity and a search for infection.

■ Evaluation for Fetal Genetic Abnormalities

In the United States, most providers offer prenatal genetic analysis of a fetal sample to all women who will be 35 years or older at their expected date of delivery. This approach is based on the increased risk of aneuploidy seen with advancing maternal age. Selection of this age as the threshold for offering invasive testing is arbitrary. It was chosen more than 30 years ago as a pragmatic balance between the available laboratory resources, the relatively limited information regarding the safety of the emerging technology of amniocentesis, and the fetal genetic risks. As seen in Table 13-3, this threshold still seems a reasonable balance between the 1:200 risk of a chromosomal abnormality and the known risks of the amniocentesis procedure (Hook, 1981, 1983). Presently, approximately 7.5 percent of pregnant women will be of advanced maternal

age, and approximately 30 percent of Down syndrome births will occur in this population. Because most Down syndrome births occur in women younger than 35 years, maternal age alone is an inefficient screening criterion. As stated above, the American College of Obstetricians and Gynecologists (2016a) endorses offering diagnostic testing to all women regardless of age. Thus, appropriate risk/benefit counseling is indicated prior to testing.

Following Analyte Screening

As a surrogate for amniocenteses, less-invasive screening tests that measure maternal serum analytes have been developed. These are often selected by gravidas at lower risk for genetic defects. Both first- and second-trimester screening algorithms yield a risk assessment for Down syndrome. For results that show an elevated aneuploidy risk, more invasive prenatal testing is then typically offered.

TABLE 13-2. Some Indications for Amniocentesis

Timing	Indication
2nd trimester (15–17 wks)	Obtain cells for karyotype
	Diagnose certain metabolic disorders
	Assay amniotic fluid AFP level ^a
Late 2nd/early 3rd trimester	Determine alloimmunization severity ^b
	Diagnose intraamniotic infection/ inflammation
	Insert dye to diagnose ruptured membranes
	Confirm fetal lung maturity ^c
	Amnioreduction in singleton or multifetal gestation
Therapeutic	Treatment of hydramnios
	Fluid removal prior to cerclage placement

TABLE 13-3. Relationship between Maternal Age and the Estimated Rate of Chromosomal Abnormalities^a

Age	Risk of Liveborn Down Syndrome	Risk of Liveborn Chromosomal Abnormality
20	1/1667	1/526
25	1/1250	1/476
30	1/952	1/385
35	1/385	1/202
36	1/295	1/162
37	1/227	1/129
38	1/175	1/102
39	1/137	1/82
40	1/106	1/65
41	1/82	1/51
42	1/64	1/40
43	1/50	1/32
44	1/38	1/25
45	1/30	1/20
46	1/23	1/16
47	1/18	1/13
48	1/14	1/10
49	1/11	1/7

^aTo assist neural-tube defect detection.

^bNow rarely used.

^cDeclining use for this purpose.

AFP = alpha-fetoprotein.

^aAges are at the expected time of delivery.

Data from Hook, 1981, 1983

TABLE 13-4. Aneuploidy Risk Associated with Selected Major Fetal Anomalies

Abnormality	Birth Prevalence	Aneuploidy Risk (%)	Common Aneuploidies ^a
Cystic hygroma	1/5000	50–70	45X, 21, 18, 13, triploidy
Nonimmune hydrops	1/1500–4000	10–20	21, 18, 13, 45X, triploidy
Ventriculomegaly	1/1000–2000	5–25	13, 18, 21, triploidy
Holoprosencephaly	1/10,000–15,000	30–40	13, 18, 22, triploidy
Dandy Walker malformation	1/12,000	40	18, 13, 21, triploidy
Cleft lip/palate	1/1000	5–15	18, 13
Cardiac defects	5–8/1000	10–30	21, 18, 13, 45X, 22q11.2 microdeletion
Diaphragmatic hernia	1/3000–4000	5–15	18, 13, 21
Esophageal atresia	1/4000	10	18, 21
Duodenal atresia	1/10,000	30	21
Gastroschisis	1/2000–4000	No increase	
Omphalocele	1/4000	30–50	18, 13, 21, triploidy
Clubfoot	1/1000	5–30	18, 13

^aNumbers indicate autosomal trisomies except where indicated, for example, 45,X indicates Turner syndrome.

Reproduced with permission from Cunningham FG, Leveno K, Bloom S, et al (eds): *Genetics*. In *Williams Obstetrics*, 24th ed. McGraw-Hill, 2014. Data from Best, 2012; Canfield, 2006; Colvin, 2005; Cragan, 2009; Dolk, 2010; Ecker, 2000; Gallot, 2007; Long, 2006; Orioli, 2010; Pedersen, 2012; Sharma, 2011; Solomon, 2010; Walker, 2001.

The first-trimester combined screen measures both nuchal translucency thickness and maternal serum analyte concentrations. Specific analytes are free β -human chorionic gonadotropin (hCG) and pregnancy-associated plasma protein A (PAPP-A). This combined screening approach has an 85-percent detection rate for Down syndrome and a 5-percent false-positive or screen-positive rate.

For second-trimester screening, the quadruple-marker test or “quad test” is the most often used serum screening test for aneuploidy. With this, the four measured maternal serum analytes are maternal serum alpha-fetoprotein (MSAFP), hCG, unconjugated estriol, and inhibin A. The quad test yields an 81-percent detection rate for Down syndrome with a 5-percent screen-positive rate (Dugoff, 2010). An abnormal screening test is defined as one in which the combined age and biochemical risk for Down syndrome exceeds the second-trimester risk of a 35-year-old woman, which is 1 affected neonate per 270 live births (1:270).

Following Structural Anomaly Identification

As described in the last section, several approaches for first- and second-trimester aneuploidy screening have been developed with the goal of offering a minimally invasive test with a high detection but low screen-positive rate.

In addition to these, technologic advancements in sonographic scanning now permit fetal structural anomalies to be found at an early gestational age. And, this is often the finding that prompts genetic amniocentesis or CVS. Specifically, [Table 13-4](#) lists many major structural defects that have a high association with fetal aneuploidy. In addition, soft sonography markers can add predictive power. For example, nuchal thickening, hyperechoic bowel, short humerus or femur length, echogenic intracardiac focus, choroid plexus cysts, and pyel ectasis increase the likelihood of aneuploidy (Nyberg, 1993, 2001; Rotmensch, 1997; Smith-Bindman 2001).

Genetic Amniocentesis

For any of the indications above, genetic amniocentesis removes amniotic fluid and amniocytes for biochemical or DNA studies. Molecular abnormalities responsible for many disorders are being identified at a rapid rate, and thus any list is quickly rendered outdated. However, the more common genetic conditions for which DNA-based prenatal diagnosis is indicated are shown in [Table 13-5](#). Many of these conditions are rare, and their diagnosis is so complex that consultation with a genetics unit is encouraged prior to performing an invasive test.

As an adjunct to standard karyotyping, chromosomal microarray (CMA) is a newer technique to detect chromosomal abnormalities (microdeletions and duplications) that are not diagnosable by traditional karyotyping.

Neural-Tube Detection

The screening test for open spina bifida is a second-trimester measurement of MSAFP levels. In the past, amniocentesis was considered a good screening test. However, it currently has been supplanted by sonography because of the advances in image quality. In many centers, sonographic diagnosis of spina bifida has been greatly enhanced by the recognition of associated abnormalities of the skull and brain. These include ventriculomegaly, microcephaly, concave deformity of the frontal bones (lemon sign), and obliteration of the cisterna magna, which leads to an abnormal anterior curvature of the cerebellar hemispheres (banana sign) (Nicolaidis, 1986a; UK Collaborative Study, 1979).

Patients at increased risk for a neural-tube defect include those with an elevated MSAFP level during screening or those with a previously affected child. These gravidas should be referred to centers experienced in high-resolution fetal sonography. If sonographic examination demonstrates a normal fetal spine, cranium, and cerebellum, the chance of an undetected open spinal abnormality is low. Amniocentesis can be reserved

TABLE 13-5. Common Conditions for Which Molecular Prenatal Diagnosis Is Available

Disorder	Mode of Inheritance	Prenatal Diagnosis
α_1 -Antitrypsin deficiency	AR	Determine PiZZ allele. Not all homozygotes have liver involvement; preprocedural genetic counseling critical
α -Thalassemia	AR	α -Hemoglobin gene
Adult polycystic kidney	AD	<i>PKD1</i> and <i>PKD2</i> gene mutation. In large families, linkage is possible in >90%. Gene mutation identifiable in 50% of PKD1 and 75% of PKD2
β -Thalassemia	AR	β -Hemoglobin gene mutation
Congenital adrenal hyperplasia	AR	<i>CYP21A2</i> gene mutations/deletions. Nine common mutations/deletions detect 90 to 95% of carriers. Sequencing available
Cystic fibrosis	AR	<i>CFTR</i> gene mutation
Duchenne/Becker muscular dystrophy	XLR	Dystrophin gene mutation
Fragile X syndrome	XLR	CGG repeat number
Hemoglobinopathy (SS, SC)	AR	β -Chain gene mutation
Hemophilia A	XLR	Factor VIII gene inversion 45%, other gene mutations 45% (not available in all labs), linkage analysis in appropriate families
Huntington disease	AD	CAG repeat length (PGD and noninforming PND possible to avoid disclosing presymptomatic parents' disease status)
Marfan syndrome	AD	Fibrillin (<i>FBN-1</i>) gene mutation. Linkage in large families. Approximately 70% have mutation identified
Myotonic dystrophy	AD	CTG expansion in the <i>DMPK</i> gene
Neurofibromatosis type 1	AD	<i>NF1</i> gene mutation identifiable in >95% of cases but requires sequencing. Linkage in appropriate families
Phenylketonuria	AR	4 to 15 common mutations, 40% to 50% detection. Further mutation analysis >99% detection
Retinoblastoma	AD	Mutation in both copies of the gene <i>RB1</i>
Spinal muscular atrophy	AR/AD	
Tay-Sachs disease	AR	Enzyme absence; gene mutation

AD = autosomal dominant; AR = autosomal recessive; PGD = preimplantation genetic diagnosis; PND = prenatal diagnosis; XLR = X-linked recessive.

Modified from Wapner, 2014.

for patients with fetuses possessing suspicious sonography findings or with large MSAFP elevations despite a normal sonographic scan. Also, it is suitable for at-risk women in whom the ability to visualize fetal anatomy is inadequate. Importantly, in women without access to sonographic services, MSAFP level testing may still play a limited role to identify those at increased risk for a fetal open neural-tube defect.

■ Evaluation of Fetal Conditions

Infection

In addition to genetic information, access to amniotic fluid can provide vital data regarding several conditions affecting the fetus. Of these, preterm birth is a leading cause of perinatal morbidity, mortality, and long-term adverse outcomes. An association between intrauterine infection/inflammation, preterm labor, and chronic sequelae has been demonstrated (Yoon, 2000). Because of this, amniocentesis for women with preterm labor or prior to rescue cerclage placement may be considered in some cases. Testing for subclinical infection/

inflammation evaluates a Gram stain, amniotic fluid glucose level, and white blood cell count. In patients with more overt clinical findings of intraamniotic infection, amniocentesis may play a role because the results of the amniotic fluid culture can change antimicrobial selection. More recently, the advent of commercially available point-of-care testing of amniotic fluid provides reliable identification of intraamniotic inflammation at the bedside (Chaemsathong, 2016; Nien, 2006). This may lead to an increased use of diagnostic amniocentesis in women with suspected preterm labor.

Fetal Lung Maturity

Because of the availability of sonography for early pregnancy dating, assessment of amniotic fluid for fetal lung maturity is infrequently needed. However, in indicated cases, contemporary methods use fluorescence polarization and lamellar body counts to assess fluid (Neerhof, 2001). Although previously used for this indication, lecithin/sphingomyelin ratio and phosphatidylglycerol level methods are less commonly selected (Gluck, 1974; Hallman, 1976).

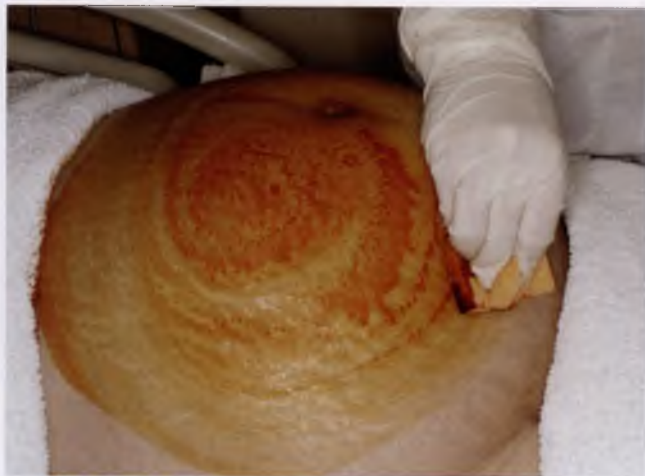


FIGURE 13-1 Abdominal preparation with povidone-iodine solution prior to amniocentesis. (Reproduced with permission from Fleischer AC, Toy EC, Lee W, et al (eds): *Amniocentesis*. In *Sonography in Obstetrics & Gynecology: Principles and Practice*, 7th ed. New York, McGraw-Hill, 2011)

Anemia and Metabolic Disorders

Fetal hemolytic disease severity and need for fetal blood transfusion or early delivery were previously determined from amniocentesis. Fluid was then interpreted using spectrophotometric estimation of amniotic fluid bilirubin levels (Liley, 1961). This evaluation is less accurate in the midtrimester, and direct measurement of the fetal hemoglobin concentration by FBS was instead previously used in suspected cases (Nicolaidis, 1986b, 1988).

However, in contemporary practice, sonographic estimation of peak systolic blood flow velocity through the fetal brain's middle cerebral artery yields diagnostic information regarding the degree of fetal anemia. This noninvasive assessment is now a validated and widely used modality (Moise, 2012). Thus, cases requiring amniocentesis, which is more invasive, are rapidly declining in number (Mari, 2000).

Many abnormalities of lipid, mucopolysaccharide, amino acid, and carbohydrate metabolism are amenable to prenatal diagnosis from the study of cultured amniotic fluid cells. However, the earlier diagnosis and the substantially larger amount of tissue obtained by CVS make it the preferred method of diagnosing this group of disorders.

Genetic Amniocentesis Technique

Preprocedural Steps

Genetic amniocentesis is commonly performed in the midtrimester between 15 and 18 weeks' gestation. At this gestational age, the amount of fluid is adequate (approximately 150 mL), the ratio of viable to nonviable amniocytes is greatest, and in most cases, the amnion has fused with the chorion. This last attribute more easily permits successful cavity entry and thereby reduces the risk for premature rupture of membranes.

Prior to the procedure, a sonographic examination is performed to determine fetal number, confirm gestational age, assure fetal viability, document fetal anatomy, and locate the placenta and placental cord insertion.

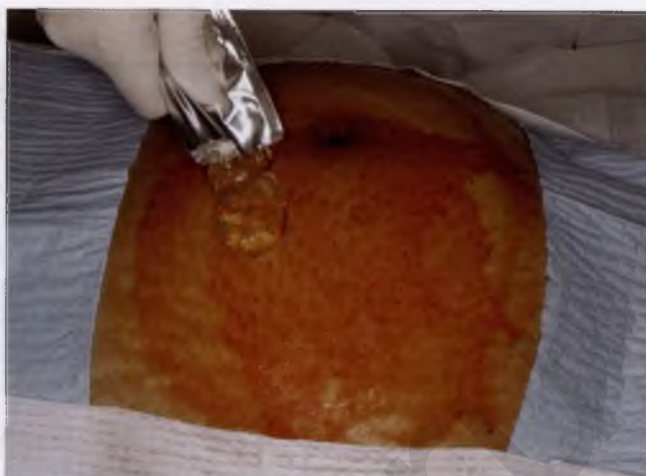

FIGURE 13-2 Coupling gel is then placed to aid sonographic guidance. (Reproduced with permission from Fleischer AC, Toy EC, Lee W, et al (eds): *Amniocentesis*. In *Sonography in Obstetrics & Gynecology: Principles and Practice*, 7th ed. New York, McGraw-Hill, 2011.)

The maternal abdomen is cleansed with an antiseptic solution (povidone-iodine or chlorhexidine) (Figs. 13-1 and 13-2). Antibiotic prophylaxis prior to amniocentesis is not recommended based on evidence. One trial evaluated the fetal loss rate within the 22nd week of pregnancy in untreated women versus those who received prophylactic agents. Compared with untreated women, those who received antibiotics had a lower loss rate, but the difference did not reach statistical significance (Gramellini, 2007).

Needle Insertion Technique

Usually, 20- or 22-gauge spinal needles in differing lengths are assembled, and the needle should be sufficiently long to reach the target pocket (Fig. 13-3). Selection accounts for placental location, maternal abdominal wall thickness, and possible uterine contraction in response to needle insertion, which temporarily widens the myometrial wall. Local anesthesia is generally not

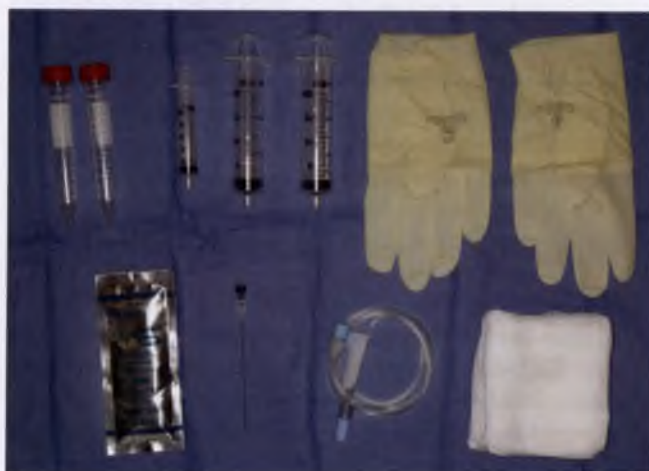

FIGURE 13-3 Equipment tray for amniocentesis. (Reproduced with permission from Fleischer AC, Toy EC, Lee W, et al (eds): *Amniocentesis*. In *Sonography in Obstetrics & Gynecology: Principles and Practice*, 7th ed. New York, McGraw-Hill, 2011.)

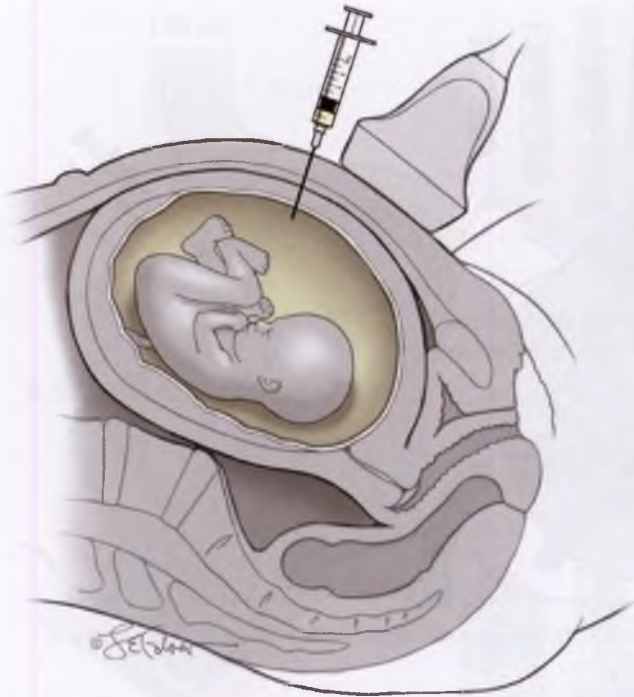


FIGURE 13-4 With amniocentesis, sonographic guidance helps avoid fetal and placental puncture.

necessary and does not diminish discomfort caused by uterine penetration.

Under direct sonographic guidance, the needle is introduced with a quick thrust into a pocket of amniotic fluid that is free of fetal parts and umbilical cord (Fig. 13-4). Once the target pocket is reached, the first 2 mL of aspirated amniotic fluid is discarded to prevent maternal cell contamination. Subsequently, 20 to 30 mL of amniotic fluid is withdrawn into a sterile syringe. This fluid is then transferred into sterile tubes and sent for testing. Fetal heart rate is documented before and after the procedure.

Complication Prevention

Although blind insertion of the sampling needle was the standard in years past, current practice employs continuous sonographic guidance. Visualization should be maintained throughout the procedure to avoid inadvertent fetal puncture and to identify uterine wall contractions, which occasionally will retract the needle tip back into the myometrium (Jeanty, 1990; Lenke, 1985). Direct real-time sonographic guidance allows easier manipulation of the needle if a uterine contraction or fetal movement is encountered (Fig. 13-5).

Operators are cautioned to avoid needle insertion through the maternal bowel to prevent contaminating the uterine cavity. Transplacental passage is also avoided when possible. But if unavoidable, the thinnest portion should be traversed. In these instances, color Doppler is helpful to identify and avoid umbilical vessels at the sampling site. Moreover, the placental cord insertion site contains the largest vessels, and a location away from this area is desirable.

If the initial effort to obtain fluid is unsuccessful, a second attempt in another location can be performed after reevaluation

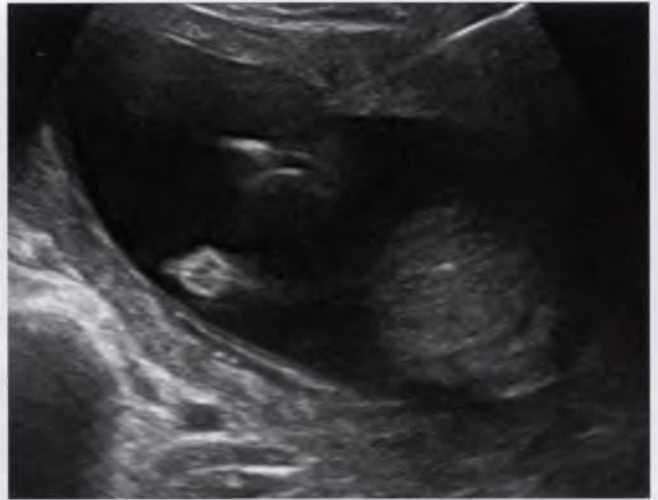


FIGURE 13-5 Sonogram during amniocentesis shows the linear and highly reflective needle in the upper right portion of the image. The tip has entered the amniotic sac.

of fetal and placental positions. Amniotic membrane tenting and the development of needle-induced uterine wall contractions are the most frequent cause of initial failure. If the amnion is not yet fused to the chorion at the initial evaluation for amniocentesis, the procedure is best postponed for a few days to a week to improve the success rate of obtaining fluid on the first attempt. Although studies have demonstrated that the fetal loss rate increases with the number of needle insertions, it does not rise with the number of separate procedures. With experienced operators, return visits are rarely needed.

Postprocedural Activity

Bed rest is not required after genetic amniocentesis, but the woman should be instructed to avoid heavy lifting and vigorous exercise for 24 hours. Complications after most procedures are uncommon, but women are cautioned regarding potential warning signs. These include fever, fluid leakage, bleeding, or regular contractions. Management of these complications is found on page 210.

■ Amniocentesis in Multifetal Gestations

In multifetal pregnancy, amniotic fluid from each sac must be sampled individually to provide accurate data for each fetus. Suitable methods employ a multineedle method or a single needle approach. The *multineedle technique* involves puncture of the first sac and withdrawal of amniotic fluid. Before the needle is removed from the sac, a dilute dye is injected. A new needle insertion then punctures the second twin's sac (Elias, 1980; Filkins, 1984; Vink, 2012). Retrieval of clear fluid from the second puncture confirms that the first sac was not resampled (Fig. 13-6). If blue-tinged fluid is retrieved, the needle is removed. Another attempt at sampling the second sac is then made.

Of marker dyes, methylene blue is contraindicated because of associated skin staining, small bowel atresia in some studies, and methemoglobinemia risks (Nicolini, 1990a; Van der Pol, 1992). Indigo carmine use has been reviewed in large series by both Cragan (1993) and Pruggmayer (1992) and their colleagues. No

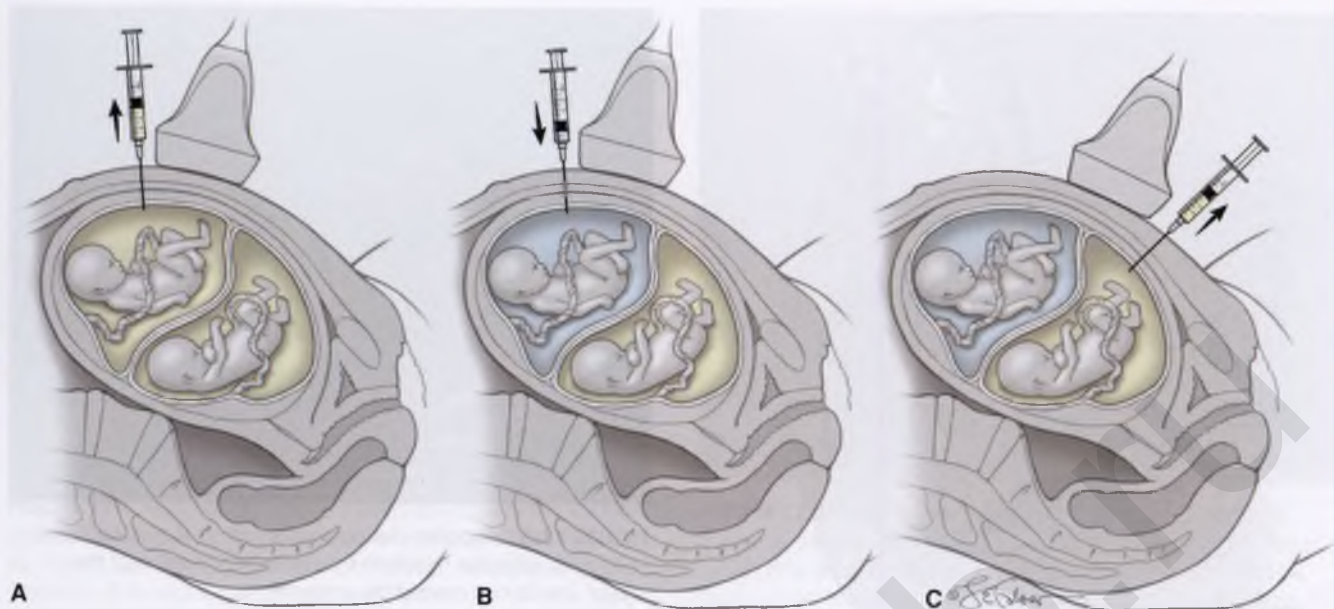


FIGURE 13-6 One method of performing amniocentesis in twins. **A.** Amniotic fluid is aspirated from the first sac. **B.** Indigo carmine is injected into the first sac. **C.** Clear fluid is aspirated from the second sac.

increased risk for small-bowel atresia, or any other congenital anomaly, has been found. However, because of theoretic risks posed by an intraamniotic dye, instillation-free techniques have evolved (Jeanty, 1990; Sebire, 1996). This is especially true given the current national shortage of indigo carmine.

Of the instillation-free options, some operators prefer a *single-insertion technique*. With sonographic guidance, the site of needle insertion is determined by the position of the dividing membrane, and the proximal sac is sampled first (Jeanty, 1990; Vink, 2012). After entry into the first sac and aspiration of amniotic fluid, the needle is advanced through the dividing membrane into the second sac. To avoid contamination of the second sample with fluid from the first, the first 2 mL of fluid from the second sample is discarded. This method may cause iatrogenic rupture of the dividing membrane with creation of a monoamniotic sac and its attendant risk of cord entanglement (Megory, 1991). This complication appears to occur almost exclusively in monochorionic gestations.

Bahado-Singh and associates (1992) described a technique of twin amniocentesis that entails identifying the separating membranes using a curvilinear or linear sonographic transducer. The first needle is inserted, fluid retrieved, and the needle left in place. A second needle is inserted on the other side of the membrane and into the second sac. Visualization of the two needle tips on opposite sides of the membrane confirms sampling from each sac.

■ Laboratory Considerations

Cell Growth Methods

Cells within the amniotic fluid are shed from numerous fetal sources, including the lower urinary tract, skin, respiratory tract, gastrointestinal tract, and amnion. After fluid retrieval, cells are placed into tissue culture, either in flasks or on coverslips. After

3 to 7 days of growth, sufficient mitoses are present for staining and karyotype analysis. Cells grown in flasks are harvested and analyzed together by specialized techniques. Cells grown on coverslips are analyzed in situ as individual colonies. Amniocyte culture is reliable, and cells fail to grow in <1 percent of cases.

Chromosomal Microarray

This newer technique identifies microdeletions and duplications that are not detectable by traditional karyotyping and is used in some cases (Fig. 13-7). In fetuses with structural anomalies identified by sonography, CMA can increase the detection rate of chromosomal anomalies by 6 percent compared with conventional karyotyping. Further, the detection rate of chromosomal anomalies rises by 1.7 percent in women whose indication for testing was advanced maternal age or positive screening results (Wapner, 2012). CMA does not identify balanced translocations and triploidies and thus is best used to complement karyotyping. At our center, we employ karyotyping and CMA when fetal structural anomalies are found.

As another option, whole-exome sequencing has the potential to isolate chromosomal anomalies not identifiable by either conventional karyotyping or CMA. However, at the moment, whole-exome sequencing is too expensive to be implemented in routine clinical practice.

Chromosomal Mosaicism

Two or more cell lines with different karyotypes in a single person are found in approximately 0.1 to 0.3 percent of cases. This chromosomal mosaicism most often results from postzygotic nondisjunction (Hsu, 1984). It can also result from meiotic errors that lead to trisomic rescue. Both are described more fully on page 216. Notably, the observation of multiple cell lines in a prenatal sample does not necessarily mean that the fetus is mosaic, because such results are confirmed in the fetus

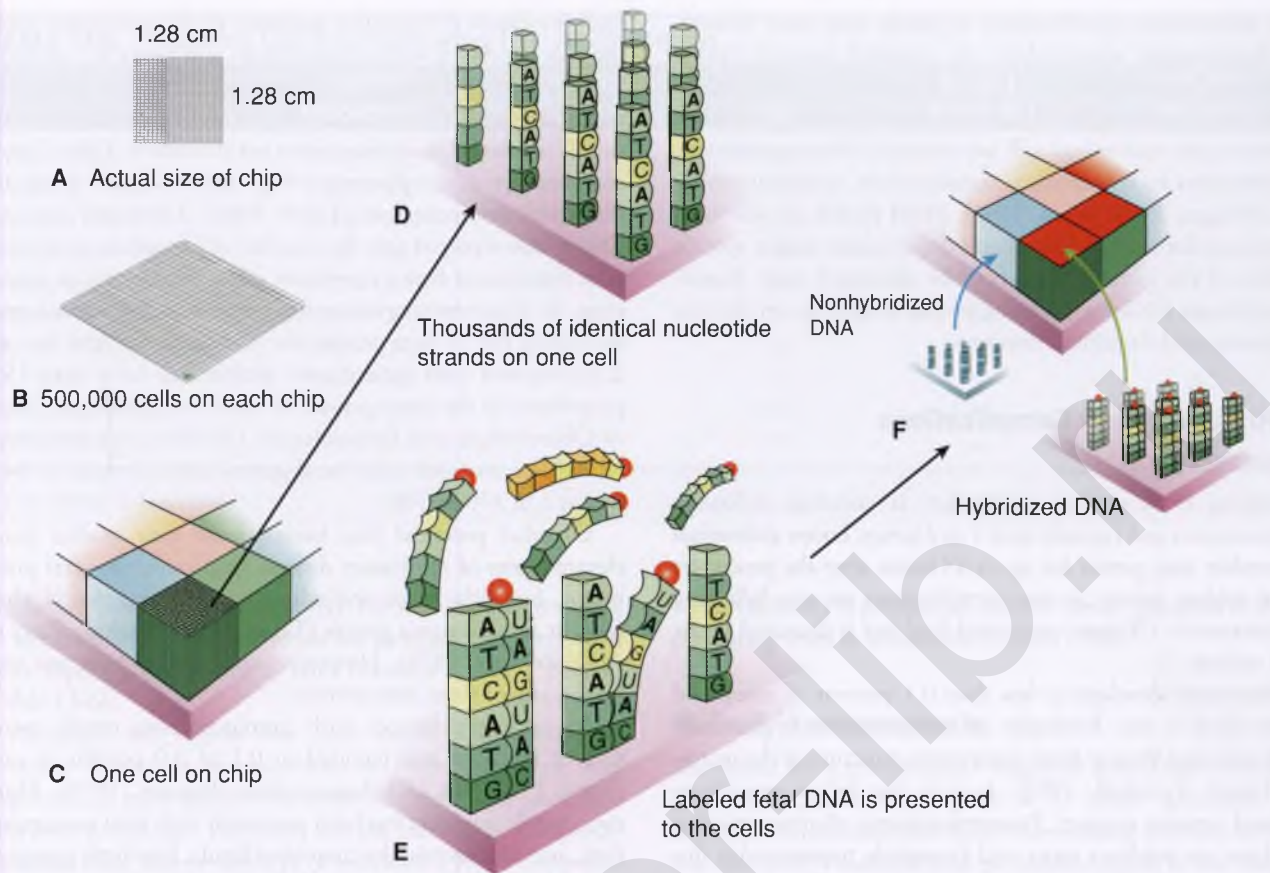


FIGURE 13-7 Chromosomal microarray analysis. **A.** Actual microarray chip size. **B.** Each chip contains thousands of cells (squares). **C & D.** Each cell contains thousands of identical oligonucleotides on its surface, and each cell is unique in its nucleotide content. **E.** During genetic analysis, a mixture containing tagged fetal DNA is presented to the chip. Complementary DNA sequences bind. **F.** If a laser is shined on the chip, DNA sequences that have bound will glow. This identifies a matching sequence. (Reproduced with permission from Doody KJ: Treatment of the infertile couple. In Hoffman BL, Schorge JO, Schaffer JL, et al (eds): Williams Gynecology, 2nd ed. New York, McGraw-Hill, 2012.)

in only 70 percent of cases (Bui, 1984). One common explanation is pseudomosaicism, in which an abnormality is evident in only one of several flasks or confined to a single colony (Hsu, 1984). In this case, the abnormal cells arise *in vitro*, are not present in the fetus, and are not clinically important. True mosaicism exists when the same abnormality is present on more than one coverslip colony or in more than one cell culture flask.

Once confirmed as true, the question of whether amniotic fluid mosaicism also involves the fetus may be resolved by karyotyping fetal lymphocytes obtained by FBS (Gosden, 1988). However, this approach may not be valid in all cases. Namely, the mosaic cell line may involve other fetal tissues and have clinical implications, but be excluded from the fetal hematopoietic compartment and not be present in a fetal blood sample (Johnson, 1997). Alternatively, some mosaic results, for example, trisomy 20, occur in the amniotic fluid relatively frequently but are rarely confirmed in the fetus (Johnson, 1997).

Further evaluation of amniotic fluid mosaic results should also include detailed sonographic scanning to assess fetal growth and exclude structural anomalies. If both sonography and fetal blood sampling results are normal, the parents can be reassured that in most cases major chromosomal abnormalities involving the fetus have been excluded (Gosden, 1988).

Genetic counseling is helpful in explaining such technical details to the patient, but parents should be reminded that a small chance of fetal involvement still exists. Because of the complexity of interpreting mosaic amniotic fluid results, consultation with the cytogenetics laboratory and a clinical geneticist is recommended.

Fluorescence In Situ Hybridization

Fluorescence in situ hybridization (FISH) permits determination of the number and location of specific DNA sequences. FISH probes are short, fluorescent-labeled DNA sequences that are hybridized to a known location on a specific chromosome. Interphase cells are then evaluated by counting the number of discrete fluorescent signals from each probe. A normal diploid cell queried with a probe for the centromere of chromosome 18 would have two signals, while a trisomy 18 cell would have three signals.

Interphase FISH is beneficial in cases in which rapid results are crucial to subsequent obstetric management. One example is a case of advanced gestational age, in which the decision to intervene for fetal indications would be affected by results. Speed derives from the facts that amniotic fluid does not require culture and that FISH can detect aneuploidies caused by monosomies, some trisomies, certain trisomies associated

with robertsonian translocations, triploidy, and other numerical chromosomal abnormalities. In standard practice, probes involving chromosomes 13, 18, 21, X, and Y are used as these are the commonest causes of aneuploidy in liveborn neonates. However, this technology will not routinely detect cytogenetic abnormalities such as mosaics, translocations, or rare aneuploidies (Klinger, 1992; Ward, 1993). FISH probes are also used to evaluate for microdeletions and duplications within specific regions of the genome known to be associated with disease. Examples are DiGeorge/velocardiofacial syndrome, cri-du-chat syndrome, and Angelman disease.

■ Amniocentesis Complications

Maternal Effects

Cramping from uterine contraction is common following amniocentesis and typically lasts 1 to 2 hours. Lower abdominal discomfort may persist for up to 48 hours after the procedure but is seldom severe. Serious complications are rare following amniocentesis. Of these, associated fetal loss is discussed in the next section.

Amnionitis develops in less than 0.1 percent of cases, and septic shock is rare. Etiologies are contamination of amniotic fluid with skin flora or from inadvertent puncture of the maternal bowel (Turnbull, 1983). It may also follow procedure-induced amnion rupture. Postamniocentesis chorioamnionitis can have an insidious onset and frequently presents with flu-like symptoms with few early localizing signs. This can evolve into a serious maternal systemic infection unless early aggressive treatment is undertaken. Therefore, a high index of suspicion is necessary.

Treatment is similar to that for other serious obstetric infections. Intravenous broad-spectrum antibiotics are continued until the woman is afebrile for more than 24 hours. At this point, antibiotics may be discontinued.

Another complication, *rhesus alloimmunization*, develops in approximately 1 percent of Rh-negative women undergoing amniocentesis. As noted on page 202, prophylactic administration of anti-D immunoglobulin following the procedure can help avoid this problem (Golbus, 1979; Hill, 1980; Tabor, 1986).

Amniotic fluid leakage or *vaginal bleeding* is noted by 2 to 3 percent of women after amniocentesis and is usually self-limited. Unlike spontaneous second-trimester amnion rupture, fluid leakage following amniocentesis usually resolves after a few days of modified activities and pelvic rest. Successful pregnancy outcome after such an event is common (Kishida, 1994). Occasionally, leakage of amniotic fluid will persist throughout pregnancy, but if the amniotic fluid volume remains adequate, a good outcome may be anticipated (NICHD Amniocentesis Registry, 1976; Simpson, 1981).

Fetal Complications after Amniocentesis

The safety and accuracy of midtrimester amniocentesis has been documented in numerous studies. Contemporary studies report total postprocedural loss rates up to 28 weeks that range from 1 to 2 percent (Canadian Early and Mid-Trimester Amniocentesis Trial [CEMAT] Group, 1998). Concurrent

high-resolution sonographic guidance of the procedure lowers the risk associated with amniocentesis and raises the probability of obtaining a sample. Of other associations, a greater risk of loss is found if 19-gauge or larger needles are used or if the needle is inserted more than twice per procedure. Other factors are puncture of the placenta, a high index MSAFP level, and discolored amniotic fluid (Tabor, 1986). Tabor and associates (2009) also reported that the number of procedures performed by a department had a significant effect on the risk of miscarriage. In departments performing fewer than 500 amniocenteses during the 11-year period, the odds ratio for fetal loss was 2.2 compared with departments performing more than 1500 procedures in the same period. In sum, the American College of Obstetricians and Gynecologists (2016a) cite a procedure-related loss rate after traditional genetic amniocentesis to be as low as 1 in 370 to 900.

Of other potential fetal harms, some early studies found elevated rates of respiratory distress syndrome, neonatal pneumonia, hip dislocation, and talipes equinovarus, that is, clubfoot, in amniocentesis groups (Tabor, 1986; Working Party on Amniocentesis, 1978). However, other studies have not confirmed any of these associations.

In early experiences with amniocentesis, needle puncture of the fetus was reported in 0.1 to 3.0 percent of cases (Karp, 1977; NICHD Amniocentesis Registry, 1978). Moreover, needle puncture has been associated with fetal exsanguination, intestinal atresia, ileocutaneous fistula, fetal limb gangrene, uniocular blindness, porencephalic cysts, patellar tendon disruption, skin dimples, and peripheral nerve damage (Broome, 1976; Epley, 1979; Karp, 1977; Lamb, 1975; Merin, 1980; Rickwood, 1977; Swift, 1979; Therkelsen, 1981; Young, 1977; Youroukos, 1980). Continuous use of sonography to guide the needle minimizes risk of fetal puncture. In experienced centers, this is a rare complication.

No long-term adverse effects have been demonstrated in children undergoing amniocentesis. Baird and coworkers (1994) compared 1296 liveborn children whose mothers had a midtrimester amniocentesis with unsampled controls. With the exception of hemolytic disease due to alloimmunization, the offspring of women who had amniocentesis were no more likely than controls to have a disability during childhood and adolescence.

Women interested in genetic amniocentesis known to be infected with hepatitis B, hepatitis C, or HIV need additional counseling regarding the risk of vertical transmission. With chronic hepatitis B, genetic amniocentesis does not appear to increase the risk of neonatal infection with hepatitis B. These neonates generally receive the hepatitis B vaccine and immunoprophylaxis (HBIG) after delivery. Women with HIV who are not taking highly active antiretroviral therapy (HAART) and women with high viral loads of hepatitis C are counseled on noninvasive screening methods. This is because data on the risk of vertical transmission, especially if the procedure is transplacental, are limited.

Complications in Multifetal Gestations

Numerous studies have evaluated the risks of second-trimester amniocentesis in twins. Compared with singletons, in

TABLE 13-6. Pregnancy Outcomes Following Twin Amniocentesis

	Years of Procedures	Continuous Guidance	No.	Loss to 20 wk (%)	Loss to 28 wk (%)
Pijpers, 1988	1980–1985	N	83	1.2	4.8
Anderson, 1991	1969–1990	N	330	—	3.6
Antsaklis, 1991	1978–1988	N	53	0.0	1.9
Pruggmayer, 1991	1982–1989	Y	98	6.1	8.1
Pruggmayer, 1992	1981–1990	Y	529	2.3	3.7
Wapner, 1993	1984–1990	Y	73	1.4	2.9
Ghidini, 1993	1987–1992	Y	101	0.0	3.0
Ko, 1998	1986–1997	Y	128	—	4.5
Yukobowich, 2001	1990–1997	Y	476	2.7	—
Cahill, 2009	1990–2006	Y	311	—	3.2 ^a

^aLoss before 24 weeks.

which loss rates are approximately 1.0 to 1.7 percent before 28 weeks, the loss rates for twins are somewhat higher. Most series report postprocedural rates between 2 and 5 percent (Table 13-6).

Although the higher loss rates could demonstrate an increased danger of amniocentesis in twins compared with singletons, it more likely reflects the inherent risks associated with twin gestations. This helps put the increase in postprocedural loss rates into perspective (Pretorius, 1993; Prompelan, 1989). Further support comes from Ghidini and colleagues (1993), who analyzed 101 twins undergoing amniocentesis and compared them with similar unsampled twins recruited in the second trimester. Each group had a loss rate of 2 percent to 25 weeks' gestation. The total fetal loss rate in the sampled group was 3.5 percent compared with 3.2 percent in the unsampled group.

Thus, evidence is reassuring, and in most cases, loss does not appear to be related to the procedure. Agarwal and Alfirevic (2012), in their systematic review of pregnancy loss after CVS and genetic amniocentesis in twin gestations, found it impossible to adequately assess the excess risk following invasive procedures in twins without randomized studies. They concluded that currently available data show similar overall pregnancy loss rates for both amniocentesis and CVS and noted the excess risk to be approximately 1 percent above the background risk. Vink and colleagues (2012) gave a similar risk of amniocentesis-related loss in their review of prenatal diagnosis in twins. Presently, the best estimate of procedure-induced loss from a second-trimester amniocentesis performed in an experienced center approximates 1 percent.

Patients with twins must also be counseled regarding the risk of finding a karyotypically abnormal child. Because there are two fetuses, risk is approximately twice that following a singleton procedure (Rodis, 1990). Amniocentesis in twins does raise some challenging questions. Families need to consider the possibility of a test finding that one twin is normal and the other has an abnormality. Selective termination of the affected fetus is an option. However, it is associated with a postprocedural loss rate of 5 to 10 percent (Evans, 1999). Moreover, selective termination is associated with an increased risk of preterm

birth, especially if performed after 20 weeks' gestation or if the presenting fetus is terminated (Lynch, 1996).

■ Early Amniocentesis

The desire for a first-trimester diagnosis stimulated interest in performing amniocentesis prior to 15 weeks' gestation. The technique varies somewhat from conventional amniocentesis in that less fluid is available and incomplete fusion of the amnion and chorion is common before 14 weeks' gestation (Canadian Early and Mid-Trimester Amniocentesis Trial [CEMAT] Group, 1998). Therefore, tenting of the free-floating membranes may hamper fluid aspiration. Penetration can usually be completed by a sharp thrust of the needle, but this fails in approximately 2 to 3 percent of cases.

Although initial experience with early amniocentesis was reassuring, subsequent studies raised serious concerns regarding its safety (Assel, 1992; Hanson, 1992; Henry, 1992; Penso, 1990). When performed before 13 weeks' gestation, rates are increased for cell culture failure, membrane rupture, and pregnancy loss compared with rates following later procedures (CEMAT Group, 1998; Nicolaides, 1994; Sundberg, 1997).

Another important concern is that in 1 to 2 percent of cases, severe fetal talipes equinovarus developed. This rate is tenfold higher than the expected rate of 1 defect per 1000 births. These clubfoot anomalies are most likely secondary to procedure-induced fluid leakage because the incidence of talipes is 15 percent following this leakage. For these reasons, amniocentesis should be delayed until at least week 15 of pregnancy (American College of Obstetricians and Gynecologists, 2016a).

■ Technique in Advanced Gestations

Amniocentesis for fetal lung maturity or for spectral analysis to measure bilirubin concentration has become infrequent in contemporary obstetric practice. When amniocentesis is necessary, sonographic guidance is recommended. These procedures may be complicated by bleeding or membrane rupture, and management is best individualized.

CHORIONIC VILLUS SAMPLING

The major drawback of conventional second-trimester genetic amniocentesis is the later availability of karyotype results. This, in turn, poses the medical risks and emotional burden associated with second-trimester pregnancy termination for those electing this. Because of these concerns, CVS is now offered in most referral centers. This method samples the placental villi rather than amniotic fluid. Villi can be reached by a transcervical or a transabdominal approach. Approach selection is dictated by provider experience and the clinical variables discussed in subsequent sections.

CVS is the most successful technique to date for moving prenatal diagnosis into the first trimester. However, the recent introduction of cell-free fetal DNA testing of maternal blood may influence the number of CVS procedures performed at referring centers. That said, at the present time, fetal DNA testing is considered a screening rather than diagnostic test.

In addition to genetic information, most biochemical diagnoses that can be made from amniotic fluid or cultured amniocytes can usually be made from chorionic villi (Poenaru, 1987). In many cases, the results are available more rapidly and efficiently when villi are used. This is because sufficient enzyme is present in the sample to allow direct analysis rather than products of tissue culture being required. However, for certain rare biochemical diagnoses, villi are not a suitable or reliable source (Gray, 1995). To ensure that appropriate testing is possible, the laboratory should be consulted prior to sampling.

■ Procedure-Related Anatomy

Between 9 and 12 weeks' gestation, the developing pregnancy does not yet fill the uterine cavity (Fig. 13-8). The sac is surrounded by the leathery chorionic membranes within which are both the amniotic cavity and the extraembryonic coelom. The amniotic cavity contains the embryo and is enclosed by the thin amniotic membrane. The extraembryonic coelom is located between the amniotic and chorionic membranes and contains a mucoid-like substance. This space is compressed and disappears as the amniotic sac grows toward the chorion and the two membranes fuse.

Prior to 9 weeks' gestation, chorionic villi cover the entire outer surface of the gestational sac. As growth continues, the developing sac begins to fill the uterine cavity, and most villi regress to form the chorion laeve. Remaining villi at the implantation site rapidly proliferate to create the chorion frondosum, which forms the future placenta. Between 9 and 12 weeks' gestation, these villi float freely within the blood of the intervillous space and are only loosely anchored to the underlying decidua basalis. As a reminder, the decidua is the entire maternal endometrium that has been hormonally primed for pregnancy implantation.

■ CVS Timing

Conventionally, CVS is performed between 11 and 14 weeks' gestation. Most spontaneous pregnancy losses would have occurred by 11 weeks. Thus, by postponing CVS until 11 weeks, fewer CVS procedures may be needed. In addition, CVS before 10 weeks' gestation is associated with an increased risk for fetal

limb defects, discussed on page 215. CVS can also be offered later between 14 and 15 weeks' gestation. At this time, it may offer advantages compared with early amniocentesis. Remember that before 15 weeks, amniocentesis carries an increased risk of limb abnormalities and of miscarriage compared with CVS or compared with later midtrimester amniocentesis (Tabor, 2010).

■ Comparison of Transcervical and Transabdominal CVS

The transabdominal and transcervical approaches to chorionic villus sampling are equally safe (Brambati, 1991a; Jackson, 1992). In most cases, operator or patient choice determines the sampling route. However, in 3 to 5 percent of cases, one approach is clearly preferred. Thus, operators ideally are skilled in both. For example, transcervical CVS is technically easier than transabdominal CVS when the placenta is posterior. However, a fundal placenta is more simply approached by transabdominal CVS. Severe antelexion or retroflexion of the uterus can preclude transvaginal CVS despite uterine manipulation. Bowel in the sampling path should exclude transabdominal CVS, whereas necrotic cervical polyps or an active herpetic lesion should prompt transabdominal sampling.

For the patient, transcervical CVS is more comfortable and in general is associated with less *fetomaternal bleeding* (Smidt-Jensen, 1994). Vaginal bleeding is more common following transcervical CVS, whereas cramping occurs more frequently with the transabdominal procedure. There are no differences in birthweight, gestational age at delivery, or congenital malformations between the two.

Of specimens, more chorionic tissue is obtained by the transcervical method. However, the proportion of cases in which less than 10 mg is obtained is similar in both groups. The sampling success rate at the first attempt is higher with transabdominal than transvaginal CVS methods (Smidt-Jensen, 1992). In addition, transcervical CVS is associated with more multiple insertions than the transabdominal route.

Prior to CVS, sonography examination immediately before the procedure confirms fetal cardiac activity, appropriate growth, placental location, and preferred route. Findings that may increase procedural difficulty include uterine leiomyomas or contractions. In multifetal pregnancies, the number of fetuses and their chorionicity are documented.

■ Transcervical Technique

To begin, the position of the uterus and cervix are viewed sonographically, and a catheter path is mentally mapped. If the uterus is anteverted, additional filling of the bladder can be used to straighten the uterine position. Most procedures require a moderately filled bladder. However, an overfilled bladder lifts the uterus out of the pelvis, which lengthens the sampling path and can diminish the uterine flexibility required for catheter manipulation. Occasionally, a uterine contraction may interfere with catheter passage. Delaying the procedure until the contraction abates is suggested.

Once uterine condition and location are favorable, the patient is placed in the dorsal lithotomy position, and the vulva and vagina are prepared with povidone-iodine solution or other

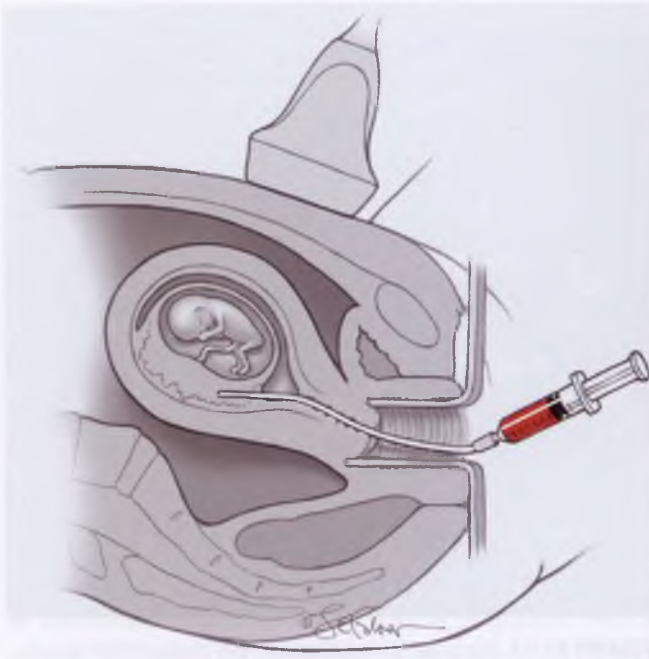


FIGURE 13-8 Technique for transcervical chorionic villus sampling.

antiseptic agent. A speculum is inserted, and the cervix is similarly prepared. The distal 3 to 5 cm of the sampling catheter is molded into a slight curve. The catheter is then gently passed under sonographic guidance through the cervix until a loss of resistance is felt at the internal os. The operator waits until the sonographer visualizes the catheter tip. The catheter is then advanced parallel to the chorionic membranes through the placenta to its distal edge (Figs. 13-8 and 13-9). The stylet is removed, and a 20-mL syringe containing nutrient medium is attached. Negative pressure is applied by means of the syringe, and the catheter is removed slowly. Cramping is common during initial catheter insertion, and patients are so warned. A vasovagal response from catheter passage is rare but may occur.

The average sample from a transcervical aspiration contains 15 to 30 mg of villous material. If sufficient villi are not retrieved with the initial pass, a second insertion can be made with minimal effect on pregnancy loss rate.

The villi identified in the syringe are carefully and aseptically transferred for confirmatory inspection and dissection under a microscope. Identification of the appropriate tissue is mandatory to minimize decidual contamination, which will add superfluous maternal genetic material. An on-site dissecting microscope can help to rapidly assess sample adequacy and the quality of the specimen obtained, and can differentiate the chorionic villi from clots or decidua.

■ Transabdominal Technique

A transabdominal CVS is a preferred approach if the placenta is anterior. The maternal abdomen is prepared with povidone-iodine solution or other aseptic agent. A small 25-gauge needle is used to administer local anesthetic into the skin over the planned insertion site. The needle is then angled using sonographic guidance to determine the best orientation for the needle in

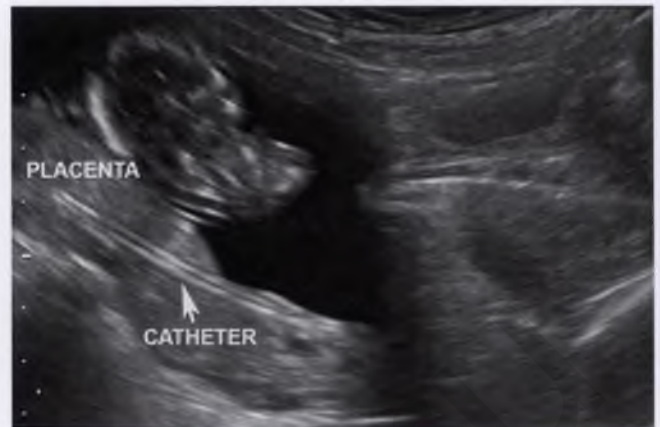


FIGURE 13-9 Sonogram of transcervical chorionic villus sampling demonstrates the catheter, which is easily seen as the bright white line in the posterior placenta.

the maternal abdomen. Next, continuous sonography is used to direct an 18-, 19- or 20-gauge spinal needle into the long axis of the placenta (Figs. 13-10 and 13-11). After removal of the stylet, villi are aspirated into a 20-mL syringe containing tissue culture media. Because the needle is somewhat smaller than the cervical sampling catheter, three or four in-and-out passes of the needle tip through the body of the placenta are required to retrieve villi.

Unlike transcervical CVS, the transabdominal procedure can be performed throughout pregnancy. Therefore, it constitutes an alternative to amniocentesis or FBS for karyotyping, if needed later in pregnancy. If oligohydramnios is present, transabdominal CVS may be the only approach available to determine fetal karyotype.

■ CVS in Multifetal Gestations

Twin and higher-order multifetal gestations have been sampled successfully using CVS (Brambati, 1991b; Pergament, 1992; Wapner, 1993). Each distinct placental site must be identified and sampled individually. No dye marker is available to assure retrieval from a given gestation. Accordingly, if the provider suspects that two separate samples have not been obtained, amniocentesis should then be offered if the fetal genders are concordant (Brambati, 1991b). However, in experienced centers, this is rarely required if the needle is sonographically guided and placed meticulously.

Another potential difficulty is possible cross-contamination of samples when both placentas lie on the same uterine wall. In these cases, sampling the lower placenta transcervically and the upper one transabdominally minimizes the chance of contamination. When a biochemical diagnosis is required, the potential for misinterpretation is even greater because a small amount of normal tissue could significantly alter the test result. These cases should only be sampled in experienced centers.

A detailed drawing of the location of each placenta and fetus is made at the time of the procedure. Each specimen jar is carefully labeled to reflect this placental location. In the case of one abnormal result, this diagram will permit later identification of the affected fetus.

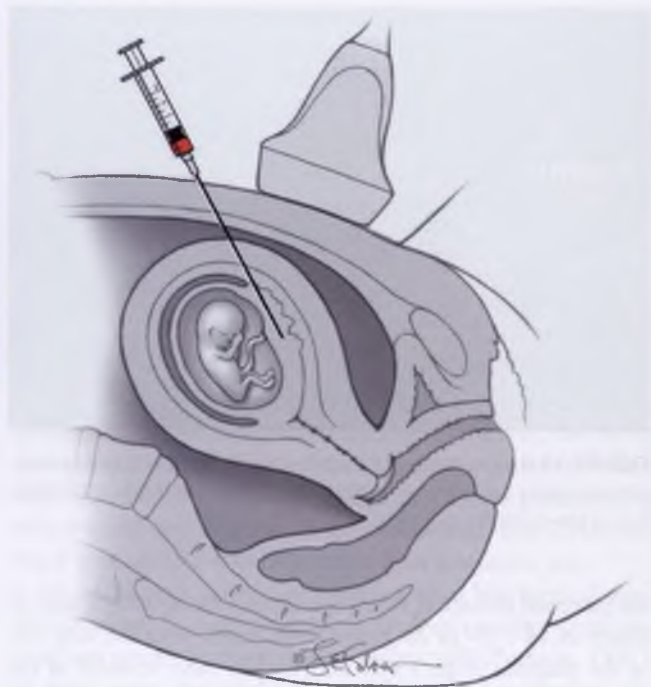


FIGURE 13-10 Transabdominal chorionic villus sampling. Note that the needle is inserted parallel to the chorionic plate.

■ Postprocedure Recommendations

After an adequate sample is obtained, the patient may be discharged home. Women are counseled to avoid strenuous activity and sexual intercourse for 24 hours after CVS. Symptoms that warrant contact with a provider include heavy bleeding, moderate to severe abdominal pain, fever, chills, or unusual vaginal discharge. Vaginal spotting is not unusual following CVS, but heavy vaginal bleeding merits investigation.

■ CVS Complications

Pregnancy Loss

The advantage of earlier diagnosis must be weighed against any possible increased risk of fetal loss attributable to CVS. In experienced individuals and centers, CVS procedure-related loss rates may be the same as those for amniocentesis (American College of Obstetricians and Gynecologists, 2016a). Early data evaluating CVS safety come primarily from

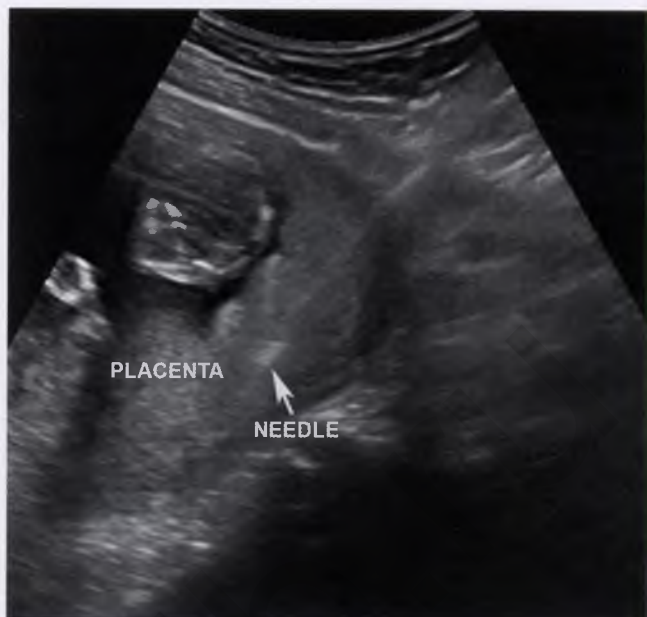

FIGURE 13-11 Sonogram of transabdominal chorionic villus sampling demonstrating the needle, which is easily seen as the bright white line in the posterior placenta.

three collaborative reports that compared CVS and amniocentesis (Table 13-7). In these, all patients were enrolled in the first trimester to account for potential differences in the background loss rates in the two different sampling windows. In two of these studies, the fetal loss rates approximated 7 percent and were statistically similar between groups. No significant differences were noted in the incidence of preterm birth or low birthweight. Maternal complications were equally uncommon in each group.

Notably, repeated catheter insertions were associated with pregnancy loss. Cases requiring three or more passes had a 10.8-percent spontaneous abortion rate compared with 2.9 percent in cases that required only one pass (Rhoads, 1989).

Operator experience also plays a role. For example, in the third study of Table 13-7, the higher loss rate was attributed to operator inexperience. These results demonstrate the relatively prolonged learning curve for CVS before safety is maximized. The threshold number of cases for proficiency may approach 400 (Saura, 1994). In a more recent study, Tabor and colleagues (2009) examined 31,355 singleton gestations of gravidas who

TABLE 13-7. Total Pregnancy Loss Rates of Chorionic Villus Sampling (CVS) and Amniocentesis (AC) from Three Trials

Study	Eligible or Attempted (n)		Total Loss Rate (%)		CVS Excess Loss Rate (%)
	CVS	AC	CVS	AC	
Canadian Collaborative CVS/Amniocentesis Clinical Trial Group (1989)	1191	1200	7.6	7.0	0.6
U.S. Collaborative Study (Rhoads, 1989)	2235	651	7.2	5.7	0.8 ^a
Medical Research Council (1991)	1609	1592	13.6	9.0	4.6

^aCorrected for difference in maternal age and gestational age.

underwent CVS between 1996 and 2006. The authors reported a 1.9-percent miscarriage rate before 24 weeks' gestation. Again, in departments performing 500 to 1000 and 1001 to 1500 procedures, the miscarriage risk was 40 percent greater compared with that from centers performing more than 1500 procedures. The authors concluded that pregnancy loss after amniocentesis and CVS were 1.4 percent and 1.9 percent, respectively. This difference was thought to be due to the difference in gestational age at the time of the procedures.

Investigators in another study of 1001 CVS procedures evaluated whether other operator-related factors affect method-associated loss and complication rates (Lim, 2014). Operator factors included MFM trainee participation, number of procedures performed yearly, and operator use of one or both CVS techniques. CVS approach was selected according to operator preference. A procedure-related complication was defined as preterm premature rupture of membranes, intrauterine post-procedural hematoma, or persistent vaginal bleeding for at least 7 days after CVS. Procedure-related losses were defined as unintentional losses within 28 days in pregnancies with a normal CVS result, no identified fetal anomalies, and no pre-existing pregnancy complications.

Of study results, trainee participation did not correlate with increased rates of procedure-related complications or losses. Operators who performed both transabdominal and transcervical CVS had lower overall procedure-related losses (1.3 percent) and total complications rates (2.6 percent) than operators who performed only transcervical CVS (4.4 and 7.1 percent, respectively). If operators performed 10 or fewer CVS cases per year, the procedure-related losses and total complication rates were 6.9 and 9.2 percent, respectively. This is significantly more than rates (1.5 and 3.0 percent, respectively) if >10 procedures are performed yearly. The authors concluded that CVS appears to be safer in the hands of operators with a greater volume of cases and in those who can provide both CVS approaches.

Other Complications

After transabdominal CVS, vaginal bleeding or spotting is relatively infrequent and is noted in ≤ 1 percent of cases. Of women sampled transcervically, most centers report postprocedural bleeding in 7 to 10 percent. With the transcervical route, minimal spotting is a more frequent event and may develop in one third of women (Rhoads, 1989). On occasion, a small subchorionic hematoma is seen following sampling but usually resolves spontaneously within a few weeks. This finding is rarely associated with an adverse outcome (Brambati, 1987b). Hematomas may occur after the catheter is passed too deeply into the underlying vascular decidua basalis. Because passage into the decidua gives a "gritty" sensation, careful attention to the feel of the catheter can minimize this complication. Operators ideally also avoid sampling near or within large placental "lakes," which will also lead to bleeding (Liu, 1991). Sonographically, lakes are prominent intervillous spaces within the placenta that appear anechoic. With brief application of color Doppler, these areas usually light up with color.

One concern with transcervical CVS is the transvaginal passage of an instrument that would introduce vaginal flora into the uterus and increase the infection risk. Although cultures of

catheter tips have isolated bacteria in 30 percent of transcervical CVS cases, the incidence of chorioamnionitis is low (Brambati, 1985, 1987a; Garden, 1985). Moreover, rates following either the transcervical or transabdominal procedure are equal. Infection following transabdominal CVS may originate from inadvertent bowel puncture by the sampling needle (Brambati, 1991a).

Early in the development of transcervical CVS, two life-threatening pelvic infections were reported (Barela, 1986; Blakemore, 1985). In the United States Collaborative Trial, infection was suspected as a possible etiology of pregnancy loss in only 0.3 percent of cases (Rhoads, 1989). A practice of using a new sterile catheter for each insertion was subsequently universally adopted, and no additional serious infections have been reported.

Acute rupture of membranes is rare in experienced centers (Rhoads, 1989). Fluid leakage with resulting oligohydramnios can develop days to weeks after the procedure (Cheng, 1991; Hogge, 1986). In most cases, this is unrelated to the procedure, but occasionally may be secondary to a procedure-induced hematoma.

An acute rise in MSAFP levels after CVS is consistently reported and implies a detectable degree of *fetomaternal bleeding* (Blakemore, 1986; Brambati, 1986; Shulman, 1990b). The MSAFP level elevation is not related to the technique used to retrieve villi but seems to depend on the quantity of tissue aspirated (Shulman, 1990b). Levels return to normal ranges by 16 to 18 weeks' gestation and thus allow MSAFP screening to proceed according to usual prenatal protocols.

All Rh-negative, nonsensitized women undergoing CVS should receive rhesus immune globulin following the procedure. Exacerbation of Rh alloimmunization following CVS has been described. Therefore, existing Rh sensitization is a contraindication to the procedure (Moise, 1990).

Fetal Abnormality after CVS

No report on CVS would be complete without discussing its possible association with limb reduction defects (LRDs). Firth and coworkers (1991) reported five fetuses affected with severe limb abnormalities from 289 pregnancies sampled between gestations aged 56 and 66 days. Four of the five fetuses had the unusual oromandibular-limb hypogenesis syndrome, which occurs in the general population at a rate of 1 case per 175,000 births. A second group described 14 more cases that ranged from mild to severe defects. Only two of the cases coincided with sampling performed after 9.5 weeks (Burton, 1993).

In response, the World Health Organization (WHO) Registry for CVS called for reports regarding LRD following CVS (WHO/PAHO Consultation on CVS, 1999). Data from 216,381 procedures are now in the WHO CVS Registry. To analyze a possible temporal relationship between CVS and LRD, a subset of 106,383 cases were stratified by the week at which the procedure was performed. The incidences of LRD were 11.7, 4.9, 3.8, 3.4, and 2.3 cases per 10,000 CVS procedures in weeks 8, 9, 10, 11, and >12, respectively. Only the rate at week 8 exceeded the background risk for LRD. The WHO concluded that CVS was not associated with LRD if performed after 8 completed weeks of pregnancy (Froster, 1996). The American College of Obstetricians and Gynecologists (2016a) cites performing procedures after 10 week's gestation.

Present data appear to confirm that performing CVS in the standard gestational window of 10 to 13 completed weeks does not increase the risk of LRD. At our center, we prefer to perform CVS between 11 and 14 weeks' gestation. Sampling prior to 10 weeks is not recommended, except in very unusual circumstances, such as when a patient's religious beliefs may preclude pregnancy termination beyond a specific gestational age. These patients, however, must be informed that the incidence of severe LRD could be as high as 1 to 2 percent.

■ CVS Cytogenetic Result Accuracy

Early in CVS development, incorrect results were described (Cheung, 1987; Martin, 1986a). In unclear cases, additional testing was needed to define the clinical significance of mosaic or other ambiguous findings and to compensate for laboratory failure and maternal cell contamination (Ledbetter, 1990; Mikkelsen, 1987).

In contrast, today, genetic evaluation of chorionic villi provides a high degree of success and accuracy, particularly in the diagnosis of common trisomies. Continued experience has almost eliminated maternal cell contamination as a source of clinical errors. In addition, we now have a better understanding of the pathogenesis of confined placental mosaicism. The latter finding in a CVS sample is currently less likely to lead to an incorrect diagnosis. Moreover, this finding provides the clinician with information predictive of pregnancy outcome and can serve as a clue to the presence of uniparental disomy. Therefore, an understanding of villous morphology and CVS laboratory techniques is required for correct clinical interpretation.

Chorionic villi have three major components: (1) an outer layer of hormonally active and invasive syncytiotrophoblast; (2) a middle layer of cytotrophoblasts from which the syncytiotrophoblast is derived; and (3) an inner mesodermal core containing blood capillaries for oxygen and nutrient exchange. After collection, the villi are cleaned of any adhered decidua and then exposed to trypsin to digest and separate the cytotrophoblasts from the underlying mesodermal core of the villus. The cytotrophoblasts have a high mitotic index, and many spontaneous mitoses are available for immediate chromosomal analysis.

With processing, the liquid suspension containing the cytotrophoblasts either is dropped immediately onto a slide for analysis or may undergo a short incubation (Gregson, 1983; Simoni, 1983). This *direct preparation* can give preliminary results within 2 to 3 hours. However, most laboratories now instead use an overnight incubation to improve karyotype quality. With this, test findings are reported within 2 to 4 days. This direct method has the advantage of providing a rapid result and minimizing decidual and maternal cell contamination. Disadvantageously, this preparation is labor intensive, adds cost, and is not routinely available in some laboratories.

As a second step, the mesodermal villous cores are placed in tissue culture and within 1 week are harvested for chromosomal analysis (Chang, 1982). This *tissue culture* method seeks karyotypic discrepancies between the cytotrophoblast and the actual fetal state. Ideally, both the direct and culture methods are used because they each evaluate slightly different tissue sources. Abnormalities in either may have clinical implications.

Maternal Cell Contamination

Chorionic villus samples typically contain a mixture of placental villi and maternally derived decidua. Although specimens are thoroughly washed and inspected under a microscope following collection, some maternal cells may remain and grow in the culture. As a result, two cell lines, one fetal and the other maternal, may be identified. In other cases, the maternal cell line may completely overgrow the culture. This can lead to diagnostic errors including incorrect sex determination and potentially to false-negative diagnoses. However, there are no published reports of the latter (Boehm, 1993; Ledbetter, 1992; Williams, 1987).

Of the preparation techniques, the direct method, described in the last section, is generally thought to prevent maternal cell contamination. In contrast, the tissue culture method has a contamination rate that varies from 1.8 to 4 percent (Gregson, 1983; Ledbetter, 1992). Interestingly, for reasons still unclear, maternal cell contamination occurs more frequently in specimens retrieved by the transcervical route (Ledbetter, 1992).

Contamination of samples with significant amounts of maternal decidual tissue is almost always due to small sample size, which makes selection of appropriate tissue difficult. As experience with CVS accrues, securing adequate quantities of villi improves, and contamination is less of a problem. Moreover, choosing only whole, clearly villous material and discarding any atypical fragments, small pieces, or fragments with adherent decidua will avoid confusion (Elles, 1983). Therefore, if the initial CVS aspirate volume is small, a second pass is performed rather than risk inaccurate results. When proper care is taken and good cooperation and communication exist between the sampler and the laboratory, even small amounts of contaminating maternal tissue can be avoided.

Confined Placental Mosaicism

The second major source of potential diagnostic error associated with CVS is mosaicism confined to the placenta. Although the fetus and placenta have a common origin, tissue from CVS will not always reflect fetal genotype (Karkut, 1985; Ledbetter, 1990). Discrepancies between the cytogenetics of the placenta and fetus occur because the cells contributing to the chorionic villi become separate and distinct from those forming the embryo in early development. Specifically, at approximately the 32- to 64-cell stage, only 3 to 4 cells become compartmentalized into the inner cell mass to form the embryo, while the remaining cells become precursors of extraembryonic tissues.

Mosaicism can then occur through two possible mechanisms (Wolstenholme, 1996). By a first method, an initial meiotic error in one of the gametes can lead to a trisomic conceptus, which normally would spontaneously abort. However, if one of the early aneuploid precursor cells loses one of the chromosomes contributing to the trisomic set during subsequent mitotic divisions, the embryo can be "rescued" by reduction of a portion of its cells to disomy. This will create a mosaic morula in which the percentage of normal cells depends on the timing of the rescue during cell division. More abnormal cells will be present when corrective rescue is delayed to the second or a subsequent cell division. Because most cells in the morula proceed to the trophoblast cell lineage (processed by

the direct preparation method), it is highly probable that the lineage identified during sampling will continue to contain a significant number of trisomic cells. In contrast, because few cells are incorporated into the inner cell mass, involvement of the fetus with the abnormal lineage will depend on the chance distribution of the aneuploid progenitor cells. Involvement of the mesenchymal core of the villus, which also evolves from the inner cell mass, is similarly dependent on this random cell distribution. If the fetal cell lineage has been rescued, then confined placental mosaicism is found. With this, the trophoblast and perhaps the extraembryonic mesoderm will have aneuploid cells, but the fetus will be euploid.

A second mechanism can also explain mosaicism. Namely, mitotic, postzygotic errors produce abnormal cells whose distribution and percentage in the morula or blastocyst depend on the timing of nondisjunction. If mitotic errors occur early in morular development, they may segregate to the inner cell mass. Here, they have the same potential to produce an affected fetus as do meiotic errors.

Some Clinical Effects of Mosaicism. Of mosaic methods, meiotic rescue can lead to *uniparental disomy (UPD)*. With this, the original trisomic cell contains two chromosomes from one parent and one chromosome from the other parent. Following rescue, there is a theoretic 1 in 3 chance that the resulting pair of chromosomes came from the same parent, that is, uniparental disomy. UPD may have clinical consequences if the chromosomes involved carry imprinted genes in which expression is based on the parent of origin. For example, Prader-Willi syndrome may result from uniparental, maternal disomy for chromosome 15. Therefore, a CVS diagnosis of confined placental mosaicism for trisomy 15 may be the initial clue that UPD could be present and could lead to an affected child (Cassidy, 1992; Purvis-Smith, 1992). Because of this, all cases in which CVS reveals trisomy 15 confined to the placenta (either complete or mosaic) should be evaluated for UPD by subsequent amniotic fluid analysis. In addition to chromosome 15, chromosomes 7, 11, 14, and 22 are believed to be imprinted. Thus, confined placental mosaicism involving these chromosomes may require additional evaluation for UPD (Ledbetter, 1995).

A growing body of evidence indicates that confined placental mosaicism (unassociated with UPD) can alter placental function and lead to fetal growth failure or perinatal death (Goldberg, 1990; Johnson, 1990; Kalousek, 1987, 1991; Wapner, 1992; Wolstenholme, 1996; Worton, 1984). The exact mechanism by which abnormal cells within the placenta prompt these outcomes is unknown. However, the effect may be limited to specific chromosomes. For example, confined placental mosaicism of chromosome 16 leads to severe intrauterine growth restriction (IUGR), prematurity, or perinatal death. Less than 30 percent of pregnancies result in normal, appropriate-for-gestational-age, full-term neonates (Benn, 1998; Breed, 1991; Kalousek, 1993; Phillips, 1996; Post, 1992).

In most cases, if the mosaic results are confined to the placenta, fetal development will be normal. However, mosaic cell lines that also involve the fetus can have significant phenotypic consequences.

Management of Mosaicism. Mosaicism is found in approximately 1 percent of all CVS samples but is confirmed in the fetus in only 10 to 40 percent of these cases (Breed, 1991; Ledbetter, 1992; Mikkelsen, 1987; Vejerslev, 1989). The probability of fetal involvement appears to be related to the tissue source in which the aneuploid cells were detected and the specific chromosome involved (Ledbetter, 1995). Compared with the direct preparation method, mesenchymal core culture results are more likely to reflect a true fetal mosaicism. In either case, CVS mosaic results require clarification using amniocentesis or FBS to determine their clinical significance.

Of the two, amniocentesis is frequently performed to elucidate the extent of fetal involvement. When mosaicism is found only from the direct preparation method, amniocentesis appears to correlate perfectly with fetal genotype (Phillips, 1996). However, when a mosaicism is observed in the tissue culture method, amniocentesis may yield false-positive or false-negative results. In these instances, amniocentesis will predict the true fetal karyotype in approximately 94 percent of cases (Phillips, 1996). Most importantly, these discrepancies may involve common autosomal trisomies.

The following clinical recommendations may be used to assist in evaluation of CVS mosaicism. Analysis of CVS samples should, if possible, include both direct preparation and tissue culture methods. Although the direct preparation is less likely to be representative of the fetus, it minimizes the likelihood of maternal cell contamination, and if culture fails, a nonmosaic normal direct preparation result can be considered conclusive (Bartels, 1989; Martin, 1986b). If mosaicism is found from either tissue culture or direct preparation methods, amniocentesis should be offered. Our recommendation is that a decision to terminate a pregnancy not be based entirely on a CVS mosaic result. For CVS mosaicism involving sex chromosome abnormalities, polyploidy, marker chromosomes, structural rearrangements, and uncommon trisomies, the patient can be reassured if amniocentesis results are euploid and if a detailed sonographic examination is normal. However, no guarantees should be made and, as described earlier, in certain cases, testing for UPD will be indicated.

If common trisomies 21, 18, and 13 are involved, amniocentesis is offered. However, the patient must be advised of the possibility of a false-negative result. Subsequent testing may include detailed sonography, FBS, or fetal skin biopsy. At present, the predictive accuracy of these additional tests is uncertain.

FETAL BLOOD SAMPLING

In 1983, Daffos and coworkers described passing a spinal needle through the maternal abdomen and into the umbilical cord while guided by sonography to obtain fetal blood. This technique is now variously described as percutaneous umbilical blood sampling (PUBS), fetal blood sampling, cordocentesis, or funipuncture.

Alternatively, fetal vasculature can be accessed by needle insertion into the fetal anterior abdominal wall. The hepatic vein is the most accessible and safest intrafetal location (Nicolini, 1990b).

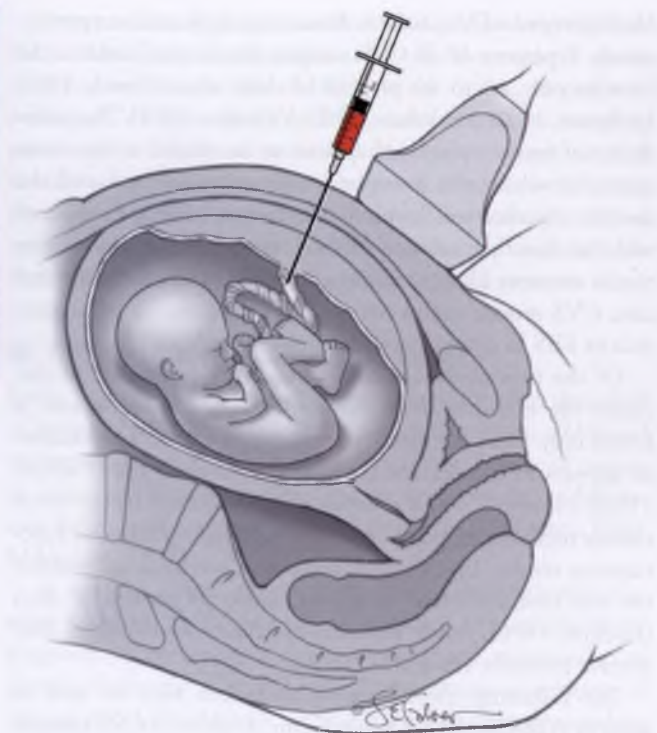


FIGURE 13-12 Fetal blood sampling with sonographically guided insertion of the needle into the umbilical vein. This technique permits access to fetal blood from an anterior placenta.

■ FBS Preparation

At least 24 hours prior to FBS, we typically administer glucocorticoids to mothers with a fetus between 23 and 34 weeks' gestation to accelerate fetal lung maturity. A sonographic examination is performed to confirm fetal viability and determine fetal position and placental location.

At our institution, FBS is performed in the operating room when the gestational age is ≥ 23 weeks. It is important to obtain intravenous access in the mother prior to the procedure to provide rapid administration of analgesics and fluids if needed. This is also important in the event of complications necessitating emergent cesarean delivery. Local anesthesia is optional for diagnostic FBS. However, it is recommended with intrauterine transfusions to help with maternal discomfort associated with prolonged needle insertion. We also frequently use maternal sedation.

■ FBS Technique

Vessels in the cord or fetal abdomen can be accessed generally using a "free-hand" technique, in which no needle guide is used. If the cord is chosen, it is most reliably entered at the placental insertion site, where it is anchored (Figs. 13-12 through 13-14). Entering into a free-floating loop of cord can be more difficult. Color Doppler imaging can significantly enhance visualization of the cord and is especially useful when oligohydramnios is present. Needles designed to optimize sonographic visualization are also available.

Before the procedure, priming the 22-gauge needle with sodium citrate solution or heparin helps prevent clot formation. After the needle has punctured the fetal vessel, a sample of blood

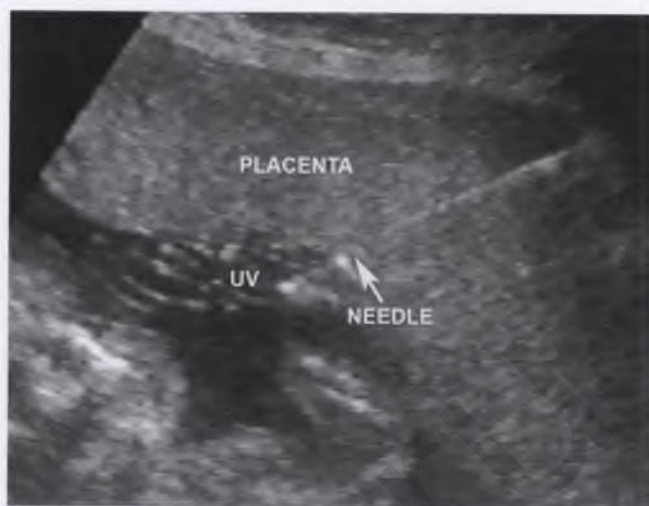

FIGURE 13-13 Sonogram during fetal blood sampling demonstrates transplacental needle passage into the umbilical vein (UV) at the cord-placenta interface.

is aspirated. This allows verification that the blood is fetal. The most definitive means to establish this compares the mean corpuscular volume (MCV) of the aspirated red blood cells (RBCs) to that in a sample of maternal blood. Although dependent on gestational age, fetal RBCs are larger than those in the adult. This comparison is easily performed on small aliquots of blood by a standard laboratory instrument like a Coulter counter. Alternatively, one can inject a small amount of sterile saline. If the needle indeed lies in the umbilical vein, microbubbles

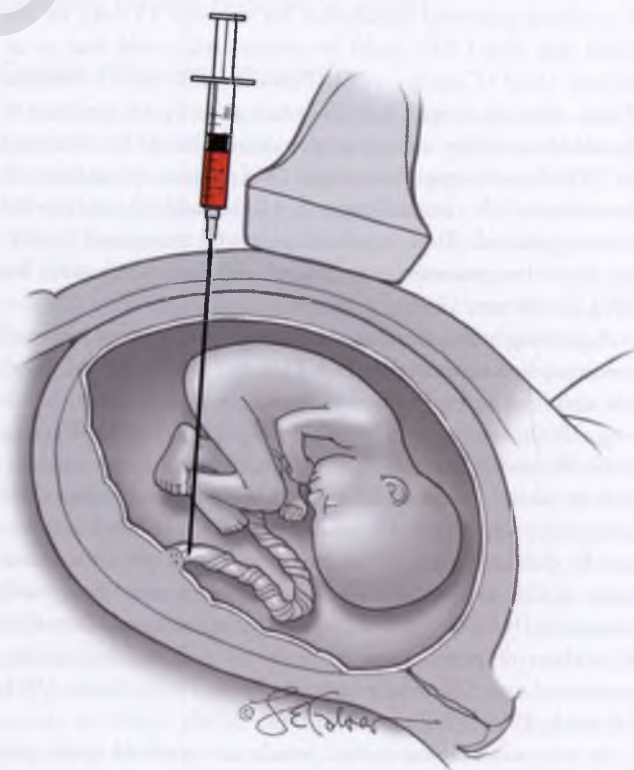


FIGURE 13-14 Fetal blood sampling with sonographically guided insertion of the needle into the umbilical vein. This technique allows access to fetal blood from a posterior placenta.

created by the injection will be seen moving toward the fetus. Once correct needle placement is confirmed, suitable blood sample collection or blood transfusion can be completed.

■ Success Rates and Safety

Fetal loss after FBS is approximately 2-percent higher than the background risk for a given fetus (Daffos, 1985; Shulman, 1990a). Because many of the fetuses requiring FBS have severe congenital malformations, the background loss rate is higher than that of the generally lower-risk population undergoing CVS or amniocentesis.

The North American FBS Registry collects data from 16 centers in the United States and Canada. Information is available on 7462 diagnostic procedures performed on 6023 patients (Ludomirsky, 1993). Fetal loss is defined as intrauterine fetal death within 14 days of the procedure. The calculated fetal loss rates are 1.1 percent per procedure and 1.3 percent per patient. In this registry, 84 pregnancies were considered lost as a direct consequence of FBS. Fetal loss was attributable to chorioamnionitis, membrane rupture, puncture site bleeding, severe bradycardia, and thrombosis. The range of losses for participating centers varied from 1 to 6.7 percent, which reflects operator experience and perhaps differences in patient selection. Notably, these figures are subjective, relying on the operator's impression that a fetal loss was directly related to the procedure itself and not to the underlying fetal condition that necessitated the procedure. Because many of these fetuses were compromised at the time of FBS, in utero death following the procedure might have been unrelated. Patients may be counseled that FBS sampling has an overall fetal loss rate that approximates 1 percent for fetuses without structural abnormalities (Society for Maternal-Fetal Medicine, 2013).

The intrahepatic vein is a suitable alternative site of sampling or transfusion when access is difficult or impossible at the placental cord insertion site. Nicolini and coworkers (1990b) have described their experience with 214 FBS procedures performed from the fetal hepatic vein. They report success rates of 91 and 90 percent for diagnostic and therapeutic procedures, respectively. Fetal loss rates were comparable to those for FBS procedures performed at the placental cord insertion site.

■ FBS Indications

Approximately two thirds of diagnostic FBS procedures reported to the FBS Registry mentioned earlier were performed either to determine a rapid karyotype or to evaluate hematologic status in pregnancies at risk for RBC alloimmunization (Ludomirsky, 1993). One third of the procedures were performed to exclude fetal infection or to evaluate nonimmune hydrops, fetal acid-base status, twin-twin transfusion syndrome, or fetal platelet count. Many of these indications are no longer relevant because of safer alternatives for rapid chromosomal analysis such as FISH of amniocytes or CVS. Also, many of the hematologic and other diagnoses that previously required fetal blood can now be performed by molecular analysis on more easily obtained fetal samples. FBS is used mainly in cases of mosaic results from CVS or amniocentesis and in cases of fetal anemia or infection.

Most cases of mosaicism found in CVS samples can be effectively excluded by amniocentesis (p. 208). However, there are reports of true fetal mosaicism, including trisomy 21, in which the chorionic villus culture revealed two cell lines and the amniotic fluid culture was entirely normal, yet true mosaicism was demonstrated in fetal blood (Ledbetter, 1990).

DNA Analysis

Most inherited hematologic disorders can now be diagnosed by the study of fetal DNA obtained from amniocytes or chorionic villi. Therefore, the antenatal detection of most congenital coagulopathies, hemoglobinopathies, white blood cell disorders, and immune disorders does not usually require direct analysis of fetal blood specimens. In some of these cases, family studies are uninformative, and FBS is necessary for diagnosis. However, this is now the exception rather than the rule.

Fetal Anemia

Assessment of fetal anemia in cases of RBC alloimmunization is most accurate with direct measurement of fetal blood. However, as described on page 206, contemporary assessment of fetal anemia begins with Doppler interrogation of the fetal middle cerebral artery (Mari, 2005, 2015). In cases of suspected severe fetal anemia, FBS is recommended as it is the most accurate and reliable way to determine the fetal hemoglobin level and the optimal timing of a transfusion.

FBS for determination of fetal anemia in RBC alloimmunization was the second most common reason for FBS, accounting for 23 percent of all cases reported to the FBS Registry, described earlier (Ludomirsky, 1993).

Fetal Thrombocytopenia

Women with *immune thrombocytopenic purpura (ITP)* have up to a 15-percent chance of delivering a neonate with a low platelet count. However, the risk of significant neonatal bleeding, specifically intracranial hemorrhage, is slight (Burrows, 1993). Nevertheless, some reports advocate delivery by cesarean if the fetal platelet count is $<50,000/\mu\text{L}$ to avoid the trauma that may result from labor. However, no data show that cesarean delivery offers significant advantage compared with vaginal delivery (Garmel, 1995).

Alloimmune thrombocytopenia is the platelet equivalent of Rh disease. In this disorder, the mother makes antibodies to antigens on the fetal platelets, and the transplacental passage of these antibodies results in fetal thrombocytopenia. This disorder is associated with a greater depression of the fetal platelet count than is found in ITP. Unlike ITP, intracranial hemorrhage may occur in utero long before the onset of labor. Because severe thrombocytopenia and intracranial hemorrhage have been documented as early as 20 weeks' gestation in this disorder, prolonged antenatal therapy is necessary to protect the fetus against spontaneous bleeding. Platelets have a short life span of only 5 to 7 days. Thus, repeated in utero transfusions are required if this therapeutic option is chosen. Most fetuses with alloimmune thrombocytopenia will respond to intravenous immunoglobulin (IVIG) at a dose of 1 g/kg administered intravenously once weekly to the mother (Bussel, 1988; Lynch, 1992).

FBS is still a valuable tool in alloimmune thrombocytopenia management. Namely, FBS is performed after IVIG treatment initiation to determine its effectiveness and the need for “rescue” maternal corticosteroid treatment. It also may be helpful in choosing the delivery route. Because alloimmune thrombocytopenia may lead to severely depressed fetal platelet counts, FBS for this indication should be performed in centers with personnel, equipment, and laboratory services familiar with this disease and its manifestations. A count should be determined before the sampling needle is withdrawn. A concentrate of washed maternal platelets should be available, and if the fetal platelet count is found to be $<40,000$ to $<50,000/\mu\text{L}$, a transfusion of maternal platelet concentrate can be given.

Infectious Disease Diagnosis

Evaluation for fetal infection was the third most frequent indication (8 percent) for FBS in the registry. The need for this modality has been markedly reduced by the availability of polymerase chain reaction (PCR). PCR analysis is now highly reliable in detecting infections caused by bacteria and by protozoa in amniotic fluid (Alanen, 1998). It is also both highly sensitive and specific for the detection of fetal viral infections and affords a diagnosis in a few hours (Van den Veyver, 1998). Amniocentesis and molecular techniques are safer options compared with FBS for the confirmation of fetal infection.

Fetal Physiologic Status

Because cord pH at the time of delivery is a well-accepted indicator of neonatal status, FBS for blood gas assessment was hoped to accurately predict fetal condition. Theoretically, FBS could provide data when more conventional forms of fetal assessment (non-stress testing, biophysical profile) were either equivocal or conflicting. However, small studies to assess this have found conflicting results as to the benefits of FBS for this indication in IUGR fetuses (Nicolaidis, 1989; Nicolini, 1990c).

Notably, appreciable fetal acidosis and hypoxia are found only when the umbilical artery Doppler waveform and the fetal heart rate pattern are abnormal (Nicolini, 1990c; Pardi, 1993). Doppler velocimetry of the umbilical artery seems to be a much more powerful predictor than FBS of the compromised IUGR fetus. Furthermore, the incidence of fetal distress, necessitating emergent cesarean delivery, is higher when FBS is performed in IUGR fetuses (Ludomirsky, 1993). Because of this, amniocentesis is the preferred technique when determination of fetal karyotype is indicated in the evaluation of the growth-restricted fetus.

Fetal Therapy

The greatest success achieved with in utero intravascular therapy to date has been the treatment of fetal anemia or thrombocytopenia, just described. In addition, several fetal conditions have been treated through administration of therapeutic agents into the fetal circulation when therapy to the mother is unsuccessful. One example is the treatment of fetal arrhythmias with various antiarrhythmic agents (Dumesic, 1982). Maternally administered digoxin is not always effective in treating supraventricular tachycardia in hydropic fetuses because transplacental passage of the drug is suboptimal due to fetal congestive heart failure (Weiner, 1988).

Of other therapies, animal data suggest that in utero stem cell transplantation is feasible early in fetal life, but the chances of rejection increase as pregnancy progresses (Crombleholme, 1991). Chimeras have been successfully created in utero in sheep and maintained after birth (Flake, 1986). In humans, antenatal stem cell transplantation has been reported in only a few cases. Access to the fetal circulation allows the potential for this type of therapeutic strategy to be attempted during fetal life.

OTHER INVASIVE DIAGNOSTIC PROCEDURES

Infrequently, analysis of other fetal tissues may be required. Fetal skin biopsies are performed to diagnose genetic skin disorders when molecular testing is not available. It can also be helpful in the evaluation of fetal mosaicism for chromosomes (such as 22) that are known not to manifest in fetal blood (Berghele, 1998). Fetal muscle biopsy for dystrophin analysis can help diagnose muscular dystrophy in a male fetus if DNA testing is not informative (Evans, 1995).

Aspiration and analysis of fetal urine is imperative in the evaluation of fetal renal function before vesicoamniotic shunt placement, illustrated in Chapter 16 (p. 263) (Johnson, 1994). Each of these procedures is performed under sonographic guidance. Because they are rarely required, their use is usually confined to a few regional referral centers.

SUMMARY

Midtrimester amniocentesis created the field of invasive prenatal diagnosis and has become the standard to which all other methods are compared. Earlier prenatal diagnostic methods have increasing appeal for many patients. The most studied of these methods is CVS. Both transcervical and transabdominal techniques are comparably effective. Thus, individual operator experience and placental location usually determine the approach chosen. Experience from randomized controlled studies has all but eliminated the performance of early amniocentesis.

Indications for FBS have dramatically declined because of advances in molecular and cytogenetic techniques, which allow for diagnosis from amniotic fluid and chorionic villi. It is now rarely chosen for determining fetal karyotype. FBS is, however, the most direct method of evaluating the severity of Rh sensitization, and it is the preferred method in severe cases. FBS is used more for fetal therapy than for karyotyping. Helping guide the patient to select the most appropriate diagnostic procedure for each indication is a crucial role for the obstetrician and genetic counselor.

REFERENCES

- Agarwal K, Alfirevic Z: Pregnancy loss after chorionic villus sampling and genetic amniocentesis in twin pregnancies: a systematic review. *Ultrasound Obstet Gynecol* 40(2):128, 2012
- Alanen A: Polymerase chain reaction in the detection of microbes in amniotic fluid. *Ann Med* 30:288, 1998
- American College of Obstetricians and Gynecologists: Invasive prenatal diagnostic testing for genetic disorders. *Practice Bulletin No. 162*, May 2016a
- American College of Obstetricians and Gynecologists: Screening for fetal aneuploidy. *Practice Bulletin No. 163*, May 2016b

- Anderson RL, Goldberg JD, Golbus MS: Prenatal diagnosis in multiple gestation: 20 years' experience with amniocentesis. *Prenat Diagn* 11(4):263, 1991
- Antsaklis A, Gougoulakis A, Mesogitis S, et al: Invasive techniques for fetal diagnosis in multiple pregnancy. *Int J Gynaecol Obstet* 34(4):309, 1991
- Assel BG, Lewis SM, Dickerman LH, et al: Single-operator comparison of early and mid-second trimester amniocentesis. *Obstet Gynecol* 79(6):940, 1992
- Bahado-Singh R, Schmitt R, Hobbins JC: New technique for genetic amniocentesis in twins. *Obstet Gynecol* 79(2):304, 1992
- Baird PA, Yee IM, Sadovnick AD: Population-based study of long-term outcomes after amniocentesis. *Lancet* 344:1134, 1994
- Barela AI, Kleinman GE, Golditch IM, et al: Septic shock with renal failure after chorionic villus sampling. *Am J Obstet Gynecol* 154(5):1100, 1986
- Bartels I, Hansmann I, Holland U, et al: Down syndrome at birth not detected by first trimester chorionic villus sampling. *Am J Med Genet* 34(4):606, 1989
- Benn P: Trisomy 16 and trisomy 16 mosaicism: a review. *Am J Med Genet* 79(2):121, 1998
- Berghella V, Wapner RJ, Yang-Feng T, et al: Prenatal confirmation of true fetal trisomy 22 mosaicism by fetal skin biopsy following normal fetal blood sampling. *Prenat Diagn* 18(4):384, 1998
- Best KE, Tennant PW, Addor MC, et al: Epidemiology of small intestinal atresia in Europe: a register-based study. *Arch Dis Child Fetal Neonatal Ed* 97(5):F353, 2012
- Blakemore KJ, Baumgarten A, Schoenfeld-Dimaio M, et al: Rise in maternal serum alpha-fetoprotein concentration after chorionic villus sampling and the possibility of isoimmunization. *Am J Obstet Gynecol* 155(5):988, 1986
- Blakemore KJ, Mahoney MJ, Hobbins JC: Infection and chorionic villus sampling. *Lancet* 2:339, 1985
- Boehm FH, Salyer SL, Dev VG, et al: Chorionic villus sampling: quality control—a continuous improvement model. *Am J Obstet Gynecol* 168(6 Pt 1):1766, 1993
- Brambati B, Guercilena S, Bonacchi I, et al: Feto-maternal transfusion after chorionic villus sampling: clinical implications. *Hum Reprod* 1(1):37, 1986
- Brambati B, Matarrelli M, Varotto F: Septic complications after chorionic villus sampling. *Lancet* 1(8543):1212, 1987a
- Brambati B, Oldrini A, Ferrazzi E, et al: Chorionic villus sampling: an analysis of the obstetric experience of 1000 cases. *Prenat Diagn* 7(3):157, 1987b
- Brambati B, Terzian E, Tognoni G: Randomized clinical trial of transabdominal versus transcervical chorionic villus sampling methods. *Prenat Diagn* 11(5):285, 1991a
- Brambati B, Tului L, Lanzani A, et al: First-trimester genetic diagnosis in multiple pregnancy: principles and potential pitfalls. *Prenat Diagn* 11(10):767, 1991b
- Brambati B, Varotto F: Infection and chorionic villus sampling. *Lancet* 2(8455):609, 1985
- Breed AS, Mantingh A, Vosters R, et al: Follow-up and pregnancy outcome after a diagnosis of mosaicism in CVS. *Prenat Diagn* 11(8):577, 1991
- Broome DL, Wilson MG, Weiss B, et al: Needle puncture of fetus: a complication of second-trimester amniocentesis. *Am J Obstet Gynecol* 126(2):247, 1976
- Bui TH, Iselius L, Lindsten J: European collaborative study on prenatal diagnosis: mosaicism, pseudomosaicism and single abnormal cells in amniotic fluid cell cultures. *Prenat Diagn* 4:145, 1984
- Burrows RF, Kelton JG: Pregnancy in patients with idiopathic thrombocytopenic purpura: assessing the risks for the infant at delivery. *Obstet Gynecol Surv* 48(12):781, 1993
- Burton BK, Schultz CJ, Berried L: Spectrum of limb disruption defects associated with chorionic villus sampling. *Pediatrics* 91(5):989, 1993
- Bussel J, Berkowitz RL, McFarland JG, et al: Antenatal treatment of neonatal alloimmune thrombocytopenia. *N Engl J Med* 319(21):1374, 1988
- Cahill AG, Macones GA, Stamilio DM, et al: Pregnancy loss rate after mid-trimester amniocentesis in twin pregnancies. *Am J Obstet Gynecol* 200(3):257.e1, 2009
- Canadian Collaborative CVS/Amniocentesis Clinical Trial Group: Multicentre randomized clinical trial of chorionic villus sampling and amniocentesis. *Lancet* 1(8628):1, 1989
- Canadian Early and Mid-Trimester Amniocentesis Trial (CEMAT) Group: Randomised trial to assess safety and fetal outcome of early and midtrimester amniocentesis. *Lancet* 351(9098):242, 1998
- Canfield MA, Honein MA, Yuskiv N, et al: National estimates and race/ethnic-specific variation of selected birth defects in the United States, 1999–2001. *Birth Defects Res A Clin Mol Teratol* 76(11):747, 2006
- Cassidy SB, Lai LW, Erickson RP, et al: Trisomy 15 with loss of the paternal 15 as a cause of Prader-Willi syndrome due to maternal disomy. *Am J Hum Genet* 51(4):701, 1992
- Chaemsithong P, Romero R, Korzeniewski SJ, et al: A point of care test for interleukin-6 in amniotic fluid in preterm prelabor rupture of membranes: a step toward the early treatment of acute intra-amniotic inflammation/infection. *J Matern Fetal Neonatal Med* 29(3):360, 2016
- Chang HC, Jones OW, Masui H: Human amniotic fluid cells grown in a hormone-supplemented medium: suitability for prenatal diagnosis. *Proc Natl Acad Sci U S A* 79(15):4795, 1982
- Cheng EY, Luthy DA, Hickok DE, et al: Transcervical chorionic villus sampling and midtrimester oligohydramnios. *Am J Obstet Gynecol* 165(4 Pt 1):1063, 1991
- Cheung SW, Crane JP, Beaver HA, et al: Chromosome mosaicism and maternal cell contamination in chorionic villi. *Prenat Diagn* 7(8):535, 1987
- Colvin J, Bower C, Dickinson JE, et al: Outcomes of congenital diaphragmatic hernia: a population-based study in Western Australia. *Pediatrics* 116(3):e356, 2005
- Cragan JD, Gilboa SM: Including prenatal diagnoses in birth defects monitoring: experience of the Metropolitan Atlanta Congenital Defects Program. *Birth Defects Res (Part A)* 85(1):20, 2009
- Cragan JD, Martin ML, Khoury MJ, et al: Dye use during amniocentesis and birth defects. *Lancet* 340(8856):1352, 1993
- Crombleholme TM, Langer JC, Harrison MR, et al: Transplantation of fetal cells. *Am J Obstet Gynecol* 164(1 Pt 1):218, 1991
- Cunningham FG, Leveno K, Bloom S, et al (eds): *Genetics*. In *Williams Obstetrics*, 24th ed. New York, McGraw-Hill, 2014, p 278
- Daffos F, Capella-Pavlovsky M, Forestier F: Fetal blood sampling during pregnancy with use of a needle guided by ultrasound: a study of 606 consecutive cases. *Am J Obstet Gynecol* 153(6):655, 1985
- Dolk H, Loane M, Garne E: The prevalence of congenital anomalies in Europe. *Adv Exp Med Biol* 686:349, 2010
- Doody KJ: Treatment of the infertile couple. In Hoffman BL, Schorge JO, Schaffer JI, et al (eds): *Williams Gynecology*, 2nd ed. New York, McGraw-Hill, 2012
- Dugoff L, Society for Maternal-Fetal Medicine: First- and second-trimester maternal serum markers for aneuploidy and adverse pregnancy outcomes. *Obstet Gynecol* 115(5):1052, 2010
- Dumesic DA, Silverman NH, Tobias S, et al: Transplacental cardioversion of fetal supraventricular tachycardia with procainamide. *N Engl J Med* 307(18):1128, 1982
- Ecker JL, Shipp TD, Bromley B, et al: The sonographic diagnosis of Dandy-Walker and Dandy-Walker variant: associated findings and outcomes. *Prenat Diagn* 20(3):328, 2000
- Elias S, Gerbie AB, Simpson JL, et al: Genetic amniocentesis in twin gestations. *Am J Obstet Gynecol* 138(2):169, 1980
- Elles RG, Williamson R, Niazi D, et al: Absence of maternal contamination of chorionic villi used for fetal gene analysis. *N Engl J Med* 308(24):1433, 1983
- Epley SL, Hanson JW, Cruikshank DP: Fetal injury with midtrimester diagnostic amniocentesis. *Obstet Gynecol* 53(1):77, 1979
- Evans MI, Goldberg JD, Horenstein J, et al: Selective termination for structural, chromosomal, and mendelian anomalies: international experience. *Am J Obstet Gynecol* 181(4):893, 1999
- Evans MI, Krivchenia EL, Johnson MP, et al: In utero fetal muscle biopsy alters diagnosis and carrier risks in Duchenne and Becker muscular dystrophy. *Fetal Diagn Ther* 10(2):71, 1995
- Filkins K, Russo J: Genetic amniocentesis in multiple gestations. *Prenat Diagn* 4(3):223, 1984
- Firth HV, Boyd PA, Chamberlain P, et al: Severe limb abnormalities after chorionic villus sampling at 56–66 days gestation. *Lancet* 337(8744):762, 1991
- Flake AW, Harrison MR, Adzick NS, et al: Transplantation of fetal hematopoietic stem cells in utero: the creation of hematopoietic chimeras. *Science* 233(4765):776, 1986
- Fleischer AC, Toy EC, Lee W, et al (eds): *Amniocentesis*. In *Sonography in Obstetrics & Gynecology: Principles and Practice*, 7th ed. New York, McGraw-Hill, 2011, p 735
- Froster UG, Jackson L: Limb defects and chorionic villus sampling: results from an international registry, 1992–1994. *Lancet* 347(9000):489, 1996
- Gallot D, Boda C, Ughetto S, et al: Prenatal detection and outcome of congenital diaphragmatic hernia: a French registry-based study. *Ultrasound Obstet Gynecol* 29(3):276, 2007
- Garden AS, Reid G, Benzie RJ: Chorionic villus sampling. *Lancet* 1:1270, 1985
- Garmel SH, Craig SD, Morin LM, et al: The role of percutaneous umbilical blood sampling in the management of immune thrombocytopenic purpura. *Prenat Diagn* 15(5):439, 1995
- Ghidini A, Lynch L, Hicks C, et al: The risk of second-trimester amniocentesis in twin gestations: a case control study. *Am J Obstet Gynecol* 169:1013, 1993
- Gluck L, Kulovich MV, Borer RC, et al: The interpretation and significance of the lecithin/sphingomyelin ratio in amniotic fluid. *Am J Obstet Gynecol* 120(1):142, 1974
- Golbus MS, Loughman WD, Epstein CJ, et al: Prenatal genetic diagnosis in 3000 amniocenteses. *N Engl J Med* 300(4):157, 1979
- Goldberg JD, Porter AE, Golbus MS: Current assessment of fetal losses as a direct consequence of chorionic villus sampling. *Am J Med Genet* 35(2):174, 1990

- Gosden C, Nicolaidis KH, Rodeck CH: Fetal blood sampling in investigation of chromosome mosaicism in amniotic fluid cell culture. *Lancet* 1(8586): 613, 1988
- Gramellini D, Fieni S, Casilla G, et al: Mid-trimester amniocentesis and antibiotic prophylaxis. *Prenat Diagn* 27(10):956, 2007
- Gray RG, Green A, Cole T, et al: A misdiagnosis of x-linked adrenoleukodystrophy in cultured chorionic villus cells by the measurement of very-long-chain fatty acids. *Prenat Diagn* 15(5):486, 1995
- Gregson NM, Seabright N: Handling of chorionic villi for direct chromosome studies. *Lancet* 2(8365-66):1491, 1983
- Hallman M, Kulovich M, Kirkpatrick E, et al: Phosphatidylinositol and phosphatidylglycerol in amniotic fluid: indices of lung maturity. *Am J Obstet Gynecol* 125(5):613, 1976
- Hanson FW, Tennant FR, Hune S, et al: Early amniocentesis: outcome, risks, and technical problems at 12.8 weeks. *Am J Obstet Gynecol* 166(6 Pt 1): 1707, 1992
- Henry GP, Miller WA: Early amniocentesis. *J Reprod Med* 37(5):396, 1992
- Hill LM, Platt LD, Kellogg B: Rh-sensitization after genetic amniocentesis. *Obstet Gynecol* 56(4):459, 1980
- Hogge WA, Schonberg SA, Golbus MS: Chorionic villus sampling: experience of the first 1000 cases. *Am J Obstet Gynecol* 154(6):1249, 1986
- Hook EB: Rates of chromosome abnormalities at different maternal ages. *Obstet Gynecol* 58(3):282, 1981
- Hook EB, Cross PK, Schreinemachers DM: Chromosomal abnormality rates at amniocentesis and in liveborn infants. *JAMA* 249(15):2034, 1983
- Hsu LY, Perlis TE: United States survey on chromosome mosaicism and pseudomosaicism in prenatal diagnosis. *Prenat Diagn* 4 Spec No:97, 1984
- Jackson LG, Zachary JM, Fowler SE, et al: A randomized comparison of transcervical and transabdominal chorionic villus sampling. *N Engl J Med* 327(9):594, 1992
- Jeanry P, Shah D, Roussis P: Single-needle insertion in twin amniocentesis. *J Ultrasound Med* 9(9):511, 1990
- Johnson A, Wapner RJ: Mosaicism: implications for postnatal outcome. *Curr Opin Obstet Gynecol* 9(2):126, 1997
- Johnson A, Wapner RJ, Davis GH, et al: Mosaicism in chorionic villus sampling: an association with poor perinatal outcome. *Obstet Gynecol* 75(4):573, 1990
- Johnson MP, Bukowdki TP, Reitleman C, et al: In utero surgical treatment of fetal obstructive uropathy: a new comprehensive approach to identify appropriate candidates for vesicoamniotic shunt therapy. *Am J Obstet Gynecol* 170(6):1770, 1994
- Kalousek DK, Dill FJ, Pantzar T, et al: Confined chorionic mosaicism in prenatal diagnosis. *Hum Genet* 77(2):163, 1987
- Kalousek DK, Howard-Peebles PN, Olson SB, et al: Confirmation of CVS mosaicism in term placentae and high frequency of intrauterine growth retardation association with confined placental mosaicism. *Prenat Diagn* 11(10):743, 1991
- Kalousek DK, Langlois S, Barrett I, et al: Uniparental disomy for chromosome 16 in humans. *Am J Hum Genet* 52(1):8, 1993
- Karkut I, Zakrzewski S, Sperling K: Mixed karyotypes obtained by chorionic villi analysis: mosaicism and maternal contamination. In: Fraccaro M, Simoni G, Brambati B (eds), *First Trimester Fetal Diagnosis*. Heidelberg, Springer, 1985, p 144
- Karp, LE, Hayden PW: Fetal puncture during midtrimester amniocentesis. *Obstet Gynecol* 49(1):115, 1977
- Kishida T, Yamada H, Sagawa T, et al: Spontaneous reseat of high-leak PROM following genetic amniocentesis. *Int J Gynaecol Obstet* 47(1):55, 1994
- Klinger K, Landes G, Shook D, et al: Rapid detection of chromosome aneuploidies in uncultured amniocytes by using fluorescence in situ hybridization (FISH). *Am J Hum Genet* 51(1):55, 1992
- Ko T, Tseng L, Hwa H: Second-trimester genetic amniocentesis in twin pregnancy. *Int J Gynecol Obstet* 61:285, 1998
- Lamb MP: Gangrene of a fetal limb due to amniocentesis. *BJOG* 82(10):829, 1975
- Ledbetter DH, Engel E: Uniparental disomy in humans: development of an imprinting map and its implications for prenatal diagnosis. *Hum Mol Genet Spec No* 4:1757, 1995
- Ledbetter DH, Martin AO, Verlinsky Y, et al: Cytogenetic results of chorionic villus sampling: high success rate and diagnostic accuracy in the United States collaborative study. *Am J Obstet Gynecol* 162(2):495, 1990
- Ledbetter DH, Zachary JM, Simpson JL, et al: Cytogenetic results from the US collaborative study on CVS. *Prenat Diagn* 12(5):317, 1992
- Lenke RR, Cyr DR, Mack LA: Midtrimester genetic amniocentesis with simultaneous ultrasound guidance. *J Clin Ultrasound* 13(5):371, 1985
- Liley AW: Liquor amnii analysis in the management of the pregnancy complicated by rhesus isoimmunization. *Am J Obstet Gynecol* 82:1359, 1961
- Lim K, Omidakhsh N, Hutcheon J, et al: CVS loss and complication rates: operator dependent factors. *Am J Obstet Gynecol* 210(1):S84, 2014
- Liu DT, Agbaje R, Preston C, et al: Intraplacental sonolucent spaces: incidences and relevance to chorionic villus sampling. *Prenat Diagn* 11(10): 805, 1991
- Long A, Moran P, Robson S: Outcome of fetal cerebral posterior fossa anomalies. *Prenat Diagn* 26(8):707, 2006
- Ludomirsky A: Intrauterine fetal blood sampling—a multicenter registry: evaluation of 7462 procedures between 1987–1991. *Am J Obstet Gynecol* 168:318, 1993
- Lynch L, Berkowitz RL, Stone J, et al: Preterm delivery after selective termination in twin pregnancies. *Obstet Gynecol* 87(3): 366, 1996
- Lynch L, Bussel JB, McFarland JG, et al: Antenatal treatment of alloimmune thrombocytopenia. *Obstet Gynecol* 80(1):67, 1992
- Mari G: Middle cerebral artery peak systolic velocity: is it the standard of care for the diagnosis of fetal anemia? *J Ultrasound Med* 24(5):697, 2005
- Mari G, Deter RL, Carpenter RL, et al: Noninvasive diagnosis by Doppler ultrasonography of fetal anemia due to maternal red-cell alloimmunization. *N Engl J Med* 342(1):9, 2000
- Mari G, Norton ME, Stone J, et al: Society for Maternal-Fetal Medicine (SMFM) Clinical Guideline #8: The fetus at risk for anemia—diagnosis and management. *Am J Obstet Gynecol* 212(6):697, 2015
- Martin AO, Elias S, Rosinsky B, et al: False-negative findings on chorionic villus sampling. *Lancet* 2(16):391, 1986a
- Martin AO, Simpson JL, Rosinsky BJ, et al: Chorionic villus sampling in continuing pregnancies. II: cytogenetic reliability. *Am J Obstet Gynecol* 154(6):1653, 1986b
- Medical Research Council: Medical Research Council European trial of chorion villus sampling. MRC working party on the evaluation of chorion villus sampling. *Lancet* 337(8756):1491, 1991
- Megory E, Weiner E, Shalev E, et al: Pseudomonoamniotic twins with cord entanglement following genetic funipuncture. *Obstet Gynecol* 78(5 Pt 2): 915, 1991
- Merin M, Beyth Y: Unioocular congenital blindness as a complication of mid-trimester amniocentesis. *Am J Ophthalmol* 89(2):299, 1980
- Mikkelsen M, Ayme S: Chromosomal findings in chorionic villi. In: Vogel F, Sperling K (eds): *Human Genetics*. Heidelberg, Springer, 1987
- Moise KJ, Argoti PS: Management and prevention of red cell alloimmunization in pregnancy. A systematic review. *Obstet Gynecol* 120(5):1132, 2012
- Moise KJ, Carpenter RJ: Increased severity of fetal hemolytic disease with known Rhesus alloimmunization after first trimester transcervical chorionic villus biopsy. *Fetal Diagn Ther* 5(2):76, 1990
- Neerhof MG, Haney EI, Silver RK, et al: Lamellar body counts compared with traditional phospholipid analysis as an assay for evaluating fetal lung maturity. *Obstet Gynecol* 97(2):305, 2001
- NICHD Amniocentesis Registry: Midtrimester amniocentesis for prenatal diagnosis: safety and accuracy. *JAMA* 236(13):1471, 1976
- NICHD Amniocentesis Registry: The safety and accuracy of mid-trimester amniocentesis. DHEW Publication No. (NIH) 78–190. Washington, Department of Health, Education and Welfare, 1978
- Nicolaides K, Brizot Mde L, Patel F, et al: Comparison of chorionic villus sampling and amniocentesis for fetal karyotyping at 10–13 weeks' gestation. *Lancet* 344(8920):435, 1994
- Nicolaides KH, Campbell S, Gabbe SG, et al: Ultrasound screening for spina bifida: cranial and cerebellar signs. *Lancet* 2(8498):72, 1986a
- Nicolaides KH, Economides DL, Soothill PW: Blood gases, pH, and lactate in appropriate- and small-for-gestational-age fetuses. *Am J Obstet Gynecol* 161(4):996, 1989
- Nicolaides KH, Rodeck CH, Mibashan RS, et al: Have Liley charts outlived their usefulness? *Am J Obstet Gynecol* 155(1):90, 1986b
- Nicolaides KH, Soothill PW, Clewell WH, et al: Fetal haemoglobin measurement in the assessment of red cell isoimmunization. *Lancet* 1(8594):1073, 1988
- Nicolini U, Monni G: Intestinal obstruction in babies exposed in utero to methylene blue. *Lancet* 336(8725):1258, 1990a
- Nicolini U, Nicolaides P, Fisk NM, et al: Fetal blood sampling from the intrahepatic vein: analysis of safety and clinical experience with 214 procedures. *Obstet Gynecol* 76(1):47, 1990b
- Nicolini U, Nicolaides P, Fisk NM, et al: Limited role of fetal blood sampling in prediction of outcome in intrauterine growth retardation. *Lancet* 336(8718):768, 1990c
- Nien JK, Yoon BH, Espinoza J, et al: A rapid MMP-8 bedside test for the detection of intra-amniotic inflammation identifies patients at risk for imminent preterm delivery. *Am J Obstet Gynecol* 195(4):1025, 2006
- Nyberg DA, Resta RG, Luthy DA, et al: Humerus and femur length shortening in the detection of Down syndrome. *Am J Obstet Gynecol* 168(2):534, 1993

- Nyberg DA, Souter VL, El-Bastawissi A, et al: Isolated sonographic markers for detection of fetal Down syndrome in the second trimester of pregnancy. *J Ultrasound Med* 20(10):1053, 2001
- Orioli IM, Catilla EE: Epidemiology of holoprosencephaly: prevalence and risk factors. *Am J Med Genet Part C Semin Med Genet* 154C:13, 2010
- Pardi G, Cetin I, Marconi AM, et al: Diagnostic value of blood sampling in fetuses with growth retardation. *N Engl J Med* 328(10):692, 1993
- Pedersen RN, Calzolari E, Husby S, et al: Oesophageal atresia: prevalence, prenatal diagnosis, and associated anomalies in 23 European regions. *Arch Dis Child* 97(3):227, 2012
- Penso CA, Sandstrom MM, Garber MF, et al: Early amniocentesis: report of 407 cases with neonatal follow-up. *Obstet Gynecol* 76(6):1032, 1990
- Pergament E, Schulman JD, Copeland K, et al: The risk and efficacy of chorionic villus sampling in multiple gestations. *Prenat Diagn* 12(5):377, 1992
- Phillips OP, Tharapel AT, Lerner JL, et al: Risk of fetal mosaicism when placental mosaicism is diagnosed by chorionic villus sampling. *Am J Obstet Gynecol* 174(3):850, 1996
- Pijpers L, Jahoda MG, Vosters RP, et al: Genetic amniocentesis in twin pregnancies. *BJOG* 95(4):323, 1988
- Poenu L: First trimester prenatal diagnosis of metabolic diseases: a survey in countries from the European community. *Prenat Diagn* 7(5):333, 1987
- Post JG, Nijhuis JG: Trisomy 16 confined to the placenta. *Prenat Diagn* 12(12):1001, 1992
- Pretorius DH, Budorick NE, Scioscia AL, et al: Twin pregnancies in the second trimester in an α -fetoprotein screening program: sonographic evaluation and outcome. *AJR Am J Roentgenol* 161(5):1001, 1993
- Prompelt HJ, Madiam H, Schillinger H: Prognose von sonographisch fröh diagnostizierter Zwillingschwangerschafter. *Geburtshilfe Frauenheilkd* 49:715, 1989
- Pruggmayer M, Baumann P, Schütte H, et al: Incidence of abortion after genetic amniocentesis in twin pregnancies. *Prenat Diagn* 11(8):63, 1991
- Pruggmayer MR, Jahoda MG, Van der Pol JG: Genetic amniocentesis in twin pregnancies: results of a multicenter study of 529 cases. *Ultrasound Obstet Gynecol* 2(1):6, 1992
- Purvis-Smith SG, Saville T, Manass S, et al: Uniparental disomy 15 resulting from "correction" of an initial trisomy 15. *Am J Hum Genet* 50(6):1348, 1992
- Rhoads GG, Jackson LG, Schlesselman SE, et al: The safety and efficacy of chorionic villus sampling for early prenatal diagnosis of cytogenetic abnormalities. *N Engl J Med* 320(10):609, 1989
- Rickwood AM: A case of ileal atresia and ileocolic fistula caused by amniocentesis. *J Pediatr* 91(2):312, 1977
- Rodis JF, Egan JF, Craffey A, et al: Calculated risk of chromosomal abnormalities in twin gestations. *Obstet Gynecol* 76: 1037, 1990
- Rotmensch S, Liberati M, Bronshteyn M, et al: Prenatal sonographic findings in 187 fetuses with Down syndrome. *Prenat Diagn* 17(11):1001, 1997
- Saura R, Gauthier B, Taine L, et al: Operator experiences and fetal loss rate in transabdominal CVS. *Prenat Diagn* 14(1):70, 1994
- Sebire MJ, Noble PL, Odibo A, et al: Single uterine entry for genetic amniocentesis in twin pregnancies. *Lancet* 7(1):26, 1996
- Sharma R, Stone S, Alzouebi A, et al: Perinatal outcome of prenatally diagnosed congenital talipes equinovarus. *Prenat Diagn* 31(2):142, 2011
- Shulman LP, Elias S: Percutaneous umbilical blood sampling, fetal skin sampling, and fetal liver biopsy. *Semin Perinatol* 14(6):456, 1990a
- Shulman LP, Meyers CM, Simpson JL, et al: Fetomaternal transfusion depends on amount of chorionic villi aspirated but not on method of chorionic villus sampling. *Am J Obstet Gynecol* 162(5):1185, 1990b
- Simoni G, Brambati B, Danesino C, et al: Efficient direct chromosome analyses and enzyme determinations from chorionic villi samples in the first trimester of pregnancy. *Hum Genet* 63(4):349, 1983
- Simpson JL, Socol ML, Aladjem S, et al: Normal fetal growth despite persistent amniotic fluid leakage after genetic amniocentesis. *Prenat Diagn* 1(4):277, 1981
- Smidt-Jensen S, Permin M, Philip J, et al: Randomised comparison of amniocentesis and transabdominal and transcervical chorionic villus sampling. *Lancet* 340(8830):1237, 1992
- Smidt-Jensen S, Philip J, Zachary JM, et al: Implications of maternal serum alpha-fetoprotein elevation caused by transabdominal and transcervical CVS. *Prenat Diagn* 14(1):35, 1994
- Smith-Bindman R, Hosmer W, Feldstein VA, et al: Second-trimester ultrasound to detect fetuses with Down syndrome: a meta-analysis. *JAMA* 285(8):1044, 2001
- Society for Maternal-Fetal Medicine (SMFM), Berry SM, Stone J, et al: Fetal blood sampling. *Am J Obstet Gynecol* 209(3):170, 2013
- Solomon BD, Rosenbaum KN, Meck JM, et al: Holoprosencephaly due to numeric chromosome abnormalities. *Am J Med Genet C Semin Med Genet* 154C:146, 2010
- Sundberg K, Bang J, Smidt-Jensen S, et al: Randomized study of risk of fetal loss related to early amniocentesis versus chorionic villus sampling. *Lancet* 350(9079):697, 1997
- Swift PG, Driscoll IB, Vowles KD: Neonatal small bowel obstruction associated with amniocentesis. *BMJ* 1(6165):720, 1979
- Tabor A, Alfirevic Z: Update on procedure-related risks for prenatal diagnosis techniques. *Fetal Diagn Ther* 27(1):1, 2010
- Tabor A, Philip J, Madsen M, et al: Randomized controlled trial of genetic amniocentesis in 4606 low-risk women. *Lancet* 1:1287, 1986
- Tabor A, Vestergaard CH, Lidgaard Ø: Fetal loss rate after chorionic villus sampling and amniocentesis: an 11-year national registry study. *Ultrasound Obstet Gynecol* 34(1):19, 2009
- Therkelsen AJ, Rehder H: Intestinal atresia caused by second trimester amniocentesis: case report. *BJOG* 88:559, 1981
- Turnbull AC, MacKenzie IZ: Second-trimester amniocentesis and termination of pregnancy. *Br Med Bull* 39(4):315, 1983
- UK Collaborative Study on Alpha-Fetoprotein in Relation to Neural Tube Defects: Amniotic fluid alpha-fetoprotein measurements in antenatal diagnosis of anencephaly and open spina bifida in early pregnancy. *Lancet* 2:652, 1979
- Van den Veyver IB, Ni J, Bowles N, et al: Detection of intrauterine viral infection using the polymerase chain reaction. *Mol Genet Metab* 63(2):85, 1998
- van der Pol JG, Wolf H, Boer K, et al: Jejunal atresia related to the use of methylene blue in genetic amniocentesis in twins. *BJOG* 99(2):141, 1992
- Vejslev LO, Mikkelsen M: The European collaborative study on mosaicism in chorionic villus sampling: data from 1986 to 1987. *Prenat Diagn* 9(8):575, 1989
- Vink J, Wapner R, D'Alton ME: Prenatal diagnosis in twin gestations. *Semin Perinatol* 36(3):169, 2012
- Walker SJ, Ball RH, Babcock CJ, et al: Prevalence of aneuploidy and additional anatomic abnormalities in fetuses and neonates with cleft lip with or without cleft palate. A population-based study in Utah. *J Ultrasound Med* 20(11):1175, 2001
- Wapner RJ: Prenatal diagnosis of congenital disorders. In Creasy, Resnik, Iams, et al (eds): *Creasy and Resnik's Maternal-Fetal Medicine: Principles and Practice*, 7th ed. Philadelphia, Saunders, 2014
- Wapner RJ, Johnson A, Davis G: Prenatal diagnosis in twin gestations: a comparison between second trimester amniocentesis and first trimester chorionic villus sampling. *Obstet Gynecol* 82:49, 1993
- Wapner RJ, Martin CL, Levy B, et al: Chromosomal microarray versus karyotyping for prenatal diagnosis. *N Engl J Med* 367(23):2175, 2012
- Wapner RJ, Simpson JL, Golbus MS, et al: Chorionic mosaicism: association with fetal loss but not with adverse perinatal outcome. *Prenat Diagn* 12(5):347, 1992
- Ward BE, Gersen SL, Carelli MP, et al: Rapid prenatal diagnosis of chromosomal aneuploidies by fluorescence in situ hybridization: clinical experience with 4,500 specimens. *Am J Hum Genet* 52:854, 1993
- Weiner CP, Thompson MI: Direct treatment of fetal supraventricular tachycardia after failed transplacental therapy. *Am J Obstet Gynecol* 158:570, 1988
- WHO/PAHO: Evaluation of chorionic villus sampling safety: WHO/PAHO consultation on CVS. *Prenat Diagn* 19(2):97, 1999
- Williams J III, Madearis AL, Chun WH, et al: Maternal cell contamination in cultured chorionic villi: comparison of chromosome Q-polymorphisms derived from villi, fetal skin, and maternal lymphocytes. *Prenat Diagn* 7(5):315, 1987
- Wolstenholme J: Confined placental mosaicism for trisomies 2, 3, 7, 8, 9, 16, and 22: their incidence, likely origins, and mechanisms for cell lineage compartmentalization. *Prenat Diagn* 16(6):511, 1996
- Working Party on Amniocentesis: An assessment of hazards of amniocentesis. *BJOG* 85 Suppl 2:1, 1978
- Worton RG, Stern R: A Canadian collaborative study of mosaicism in amniotic fluid cell cultures. *Prenat Diagn* 4 Spec No:131, 1984
- Yoon BH, Romero R, Park JS, et al: Fetal exposure to an intraamniotic inflammation and the development of cerebral palsy at the age of three years. *Am J Obstet Gynecol* 182:675, 2000
- Young PE, Matson MR, Jones OW: Fetal exsanguination and other vascular injuries from mid-trimester genetic amniocentesis. *Am J Obstet Gynecol* 129:21, 1977
- Youroukos S, Papadelis F, Matsaniotis N: Porencephalic cysts after amniocentesis. *Arch Dis Child* 55(10):814, 1980
- Yukobowich E, Anteby E, Cohen S, et al: Risk of fetal loss in twin pregnancies undergoing second trimester amniocentesis. *Obstet Gynecol* 98(2):213, 2001

CHAPTER 14

Adnexal Masses

INCIDENCE	224
DIFFERENTIAL DIAGNOSIS	224
COMPLICATIONS	225
DIAGNOSTIC TOOLS	227
MANAGEMENT	230
SUMMARY	238

Pelvic masses during pregnancy have historically posed diagnostic and therapeutic dilemmas for the obstetrician. Maternal mortality rates with surgery were prohibitive through the early 20th century. For example, among 720 pregnant women with surgically treated adnexal masses reviewed by McKerron (1906), the maternal mortality rate was 21 percent, and the fetal mortality rate was 50 percent.

These high mortality rates with surgical treatment led to further decades during which expectant management was selected. However, conservative care was also associated with excessive mortality rates. Patton (1906) reported a 26-percent maternal death rate with expectant care. Another early study of adnexal masses in pregnancy summarized the many complications with conservative management. These included torsion (33 percent), cyst rupture (5 percent), suppuration (14 percent), and significant dystocia leading to cesarean delivery (16 percent) (Spencer, 1920). Caverly (1931) reported a 30-percent spontaneous abortion rate in cases expectantly managed.

From these experiences, treatment evolved to that of expectant observation until the second trimester, after which time, any mass that persisted was excised surgically. This

regimen gained popular acceptance not only because of the high maternal complication rate if the mass remained, but also because of the 2- to 8-percent risk of ovarian malignancy. Following the introduction of modern anesthetic techniques, antibiotics, and blood banking, maternal and fetal morbidity and mortality rates declined. Yet, despite these improvements, management of adnexal masses during pregnancy is still challenging.

INCIDENCE

The reported incidence of adnexal masses that are discovered during pregnancy varies considerably. Prior to the introduction of sonography, Grimes and colleagues (1954) reported an incidence of 1.2 percent of pregnancies from their private practice. As expected, with the advent of sonographic examination of nearly all pregnancies, the reported incidence is appreciably higher and ranges from 5 to 25 percent in the first trimester (Condous, 2004; Yazbek, 2007). In the second trimester, in a study of more than 24,000 women, an incidence of 4.9 percent was reported (Goh, 2013). The proportion of adnexal masses in pregnancy that are malignant is also variably reported and ranges from 2 to 8 percent. Most of these are tumors of low malignant potential (Leiserowitz, 2006; Ngu, 2014).

DIFFERENTIAL DIAGNOSIS

The differential diagnosis of an adnexal mass in pregnancy depends on the stage of pregnancy at the time of diagnosis and the sonographic appearance of the mass (Table 14-1). Many women during a routine, first-trimester sonographic examination will have an incidental finding of a small, cystic adnexal mass measuring less than 3 cm. These typically represent functional corpus luteum cysts. In approximately 5 percent of scans, such simple sonographic masses will measure 3 cm or greater (Glanc, 2007; Yazbek, 2007). Most of these larger cysts are also

TABLE 14-1. Differential Diagnosis of Adnexal Masses During Pregnancy

Uterine	Fallopian Tube
Pedunculated leiomyoma	Ectopic pregnancy
Leiomyosarcoma	Hydrosalpinx
Müllerian rudimentary horn	Paratubal cyst
	Primary fallopian tube neoplasm
Ovarian	Urologic Origin
Functional cyst	Pelvic kidney
Follicular cyst	Urinoma
Corpus luteum cyst	
Theca-lutein cyst	Gastrointestinal Origin
OHSS	Appendicular abscess
Endometrioma	Diverticular abscess
Mature cystic teratoma	Rectosigmoid stool
Mucinous cystadenoma	Primary GI neoplasm
Serous cystadenoma	
Other benign ovarian neoplasm	Other
Paraovarian cyst	Peritoneal inclusion cyst
Ectopic pregnancy	Abdominal pregnancy
Tuboovarian complex	Benign inflammatory node
Primary ovarian malignancy	
Metastatic neoplasm	

GI = gastrointestinal; OHSS = ovarian hyperstimulation syndrome.

functional, and only 0.7 to 1.7 percent persist beyond the first trimester (Condous, 2004; Yazbek, 2007). Simple cysts that persist into the second trimester are less likely to be functional cysts, and etiologies include ovarian cystadenomas, hydrosalpinx, paraovarian or paratubal cysts, endometriomas, or theca-lutein cysts.

Of complex adnexal masses, the most common etiology in pregnancy is benign mature cystic teratoma, colloquially called a dermoid cyst (Yacobozzi, 2012). Other complex masses may be endometriomas; benign cystadenomas, especially mucinous cystadenomas; or malignant tumors. Solid masses are less frequent but may represent ectopic pregnancy, pedunculated leiomyomas, or ovarian fibromas. Malignant adnexal masses can be simple but more often appear complex or solid.

There are also nonneoplastic adnexal masses to consider. For example, a chronic tuboovarian complex or an ectopic pregnancy may appear as a complex mass, even if an intrauterine pregnancy is also seen. Although simultaneous intrauterine and ectopic pregnancies are rare, a clinician should consider the possibility, particularly in a woman who has undergone assisted reproductive technology (ART) treatments. Of 553,577 pregnancies reported to the National ART Surveillance System for the decade 2001 to 2011, Perkins and associates (2015) found the heterotopic pregnancy rate approximated 0.09 percent in pregnancies resulting from ART. Bello and colleagues (1986) reported the incidence of combined ectopic and intrauterine pregnancies as 1 in 3899 to 15,000 pregnancies.

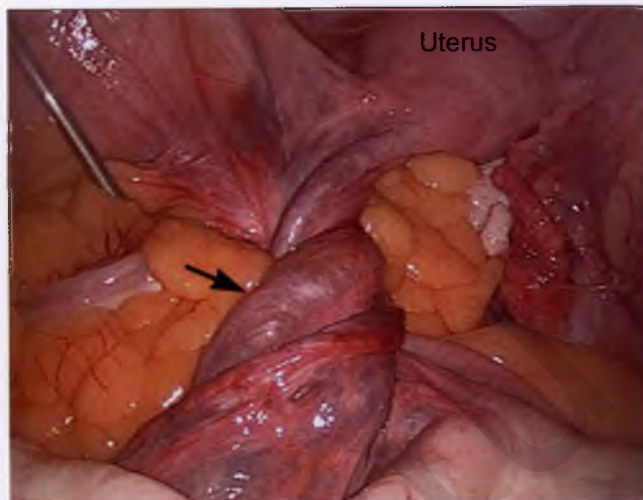


FIGURE 14-1 Adnexal torsion. This laparoscopic photograph shows torsion of a 30-cm ovarian cyst. The arrow points to the twisted proximal fallopian tube and uteroovarian ligament.

COMPLICATIONS

■ Torsion

Incidence and Etiology

A major problem with adnexal masses in pregnancy is torsion of adnexal components. Most often, the ovary and fallopian tube rotate as a single entity (Figs. 14-1 and 14-2). Infrequently, an ovary may alone turn about its mesovarium, and rarely a fallopian tube twists alone about the mesosalpinx. The reported incidence of adnexal torsion during pregnancy is 1 to 5 cases per 10,000 spontaneous pregnancies. It may be as high as 16 percent in pregnancies conceived using ART and complicated by ovarian hyperstimulation (Mashiach, 1990). This increased rate may be explained by the greater tendency during ART treatment to develop large, multicystic ovaries that result from the artificial hormonal stimulation.

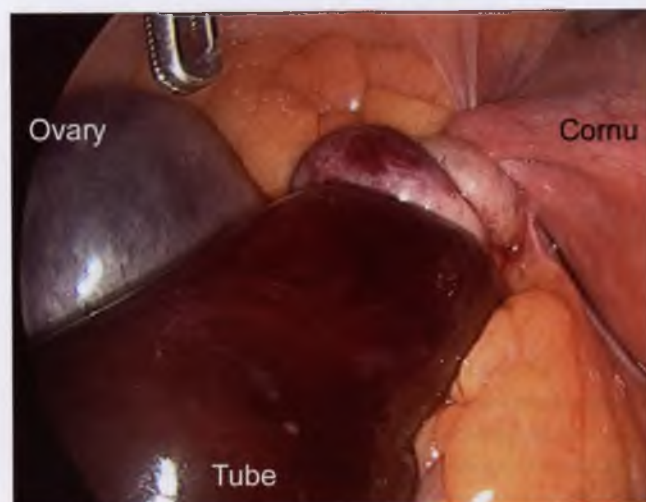


FIGURE 14-2 Adnexal torsion. This laparoscopic photograph shows torsion of a 12-cm mature cystic teratoma that led to ovarian necrosis and hemorrhagic distention of the adjacent fallopian tube.

In general, factors associated with a higher rate of torsion include masses that are 6 to 10 cm in diameter and a gestational age of 10 to 17 weeks. Indeed, 37 percent of torsion cases present between 15 and 16 weeks' gestation. Mechanistically, displacement of the adnexa by the rapidly growing uterus is one explanation for this timing (Koo, 2011; Yen, 2009). Of 33 pregnant women with adnexal torsion in one study, three presented with symptoms 3 weeks postpartum, suggesting that torsion may also be associated with uterine involution (Yen, 2009).

Adnexa receive blood supply from adnexal branches of both the uterine and ovarian vessels. Of these, torsion usually involves the uterine branches, which travel with and then twist with the uteroovarian ligament and proximal fallopian tube. During torsion, low-pressure veins draining an adnexum are compressed early by the twisting pedicle, but high-pressure arteries initially resist compression. As a result of this continued inflow but arrested egress of blood, the adnexum becomes congested and edematous but does not infarct. Because of this, cases of early torsion can often be conservatively managed at the time of surgery. With continued stromal swelling, however, arteries can become compressed, leading to infarction and necrosis that necessitate adnexectomy. Grossly, twisted adnexa are enlarged and often appear hemorrhagic.

Diagnosis

Symptoms may include acute-onset pain that is constant or intermittent, nausea and vomiting, and signs of peritoneal irritation (Hasson, 2010). The pain usually is localized to the involved side, with radiation to the flank, groin, or thigh. Low-grade fever suggests adnexal necrosis.

Sonography plays an essential role, and specific findings have been described. First, multiple follicles rimming an enlarged ovary reflect ovarian congestion and edema described in the last section. The twisted pedicle may appear as a bull's-eye target, whirlpool, or snail shell, that is, a rounded hyperechoic structure with multiple, inner, concentric hypoechoic rings. In affected women, transvaginal color Doppler sonography (TV-CDS) may show disruption of normal adnexal blood flow. In some cases, however, incomplete or intermittent torsion may variably display both venous and arterial flow using TV-CDS. Thus, disruption of vascular flow, when present, is highly suggestive of torsion. But torsion cannot be excluded on the basis of a normal Doppler study alone, especially with clinically suggestive signs and symptoms. Computed tomography (CT) or magnetic resonance (MR) imaging is usually not required. These may be helpful in complicated cases or in those with ambiguous clinical presentation, such as that seen with incomplete or chronic torsion.

Treatment

Salvage of the involved adnexa, resection of any associated cyst or tumor, and possible oophoropexy are treatment goals. However, adnexal necrosis or rupture with hemorrhage may mandate adnexal removal.

Torsion may be evaluated by laparoscopy or laparotomy. Previously, to avoid possible thrombus release and subsequent embolism, adnexal untwisting was eschewed, and adnexectomy

was the standard. However, evidence does not support this. McGovern and coworkers (1999) reviewed nearly 1000 cases of torsion and found that pulmonary embolism was rare and occurred in only 0.2 percent. Notably, these cases of embolism were associated with adnexal excision, and none were linked to untwisting of the pedicle. In a study of 94 women with adnexal torsion, Zweizig and associates (1993) reported no increased morbidity in women undergoing untwisting of the adnexum compared with those undergoing adnexectomy.

For these reasons, detorsion of the adnexum is generally recommended. Within minutes following untwisting, congestion is relieved, and ovarian volume and cyanosis typically diminish. For many, absence of these changes may prompt adnexal removal. A persistently engorged, black-blue ovary with foci of hemorrhage, however, is not pathognomonic for necrosis, and the ovary may still recover. In one study of 102 cases of ovarian torsion in nonpregnant women, patients underwent detorsion without oophorectomy, regardless of ischemic appearance of the adnexa. Surgery included detorsion alone (35 percent), ovarian cyst aspiration (33 percent), cystectomy (30 percent), and oophoropexy for repeat torsion (1 percent). No cases were complicated by thromboembolism postoperatively. Postoperative sonography done 8 to 10 weeks later showed ovaries with normal size and normal follicular development in more than 90 percent of patients. Almost 14 percent of the entire cohort underwent subsequent surgery for unrelated issues, and all but one patient had normal-appearing adnexa. Six women later underwent in vitro fertilization (IVF) with oocytes retrieved from the previously ischemic ovaries, and all were fertilized (Oelsner, 2003). Despite these encouraging findings, if conservative management of a dusky adnexum is elected, vigilance for fever, leukocytosis, and peritoneal signs is required to exclude later postoperative adnexal necrosis. For the gravida, this potential complication may make conservative management of the necrotic-appearing adnexum less advantageous.

Following detorsion, there is no consensus as to the management of the reperfused adnexum. Ovarian cysts or masses are ideally excised to prevent repeat torsion and to exclude cancer in suspect masses. Cystectomy in a hemorrhagic, edematous ovary, however, may technically be difficult. Surgical steps of cystectomy and adnexectomy are illustrated on page 232. Importantly, a preserved adnexum can twist again at a later time, and this is especially true for adnexa with long utero-ovarian ligaments. To minimize this risk, one intraoperative technique suitable for pregnancy can be considered. With it, a running stitch is placed through the length of the ligament and then tied to create an accordion-like shortening of the ligament.

■ Malignancy

Incidence and Etiology

Ovarian malignancy is certainly one of the worst complications of an adnexal mass. The incidence of ovarian malignancy during pregnancy ranges from 1 in 20,000 to 1 in 50,000 births (Palmer, 2009; Smith, 2003). Among women with adnexal masses in pregnancy, the reported rate of cancer varies between 2 and 8 percent (Leiserowitz, 2006; Ngu, 2014). Masses greater than 10 to 15 cm in diameter are associated with a higher rate of

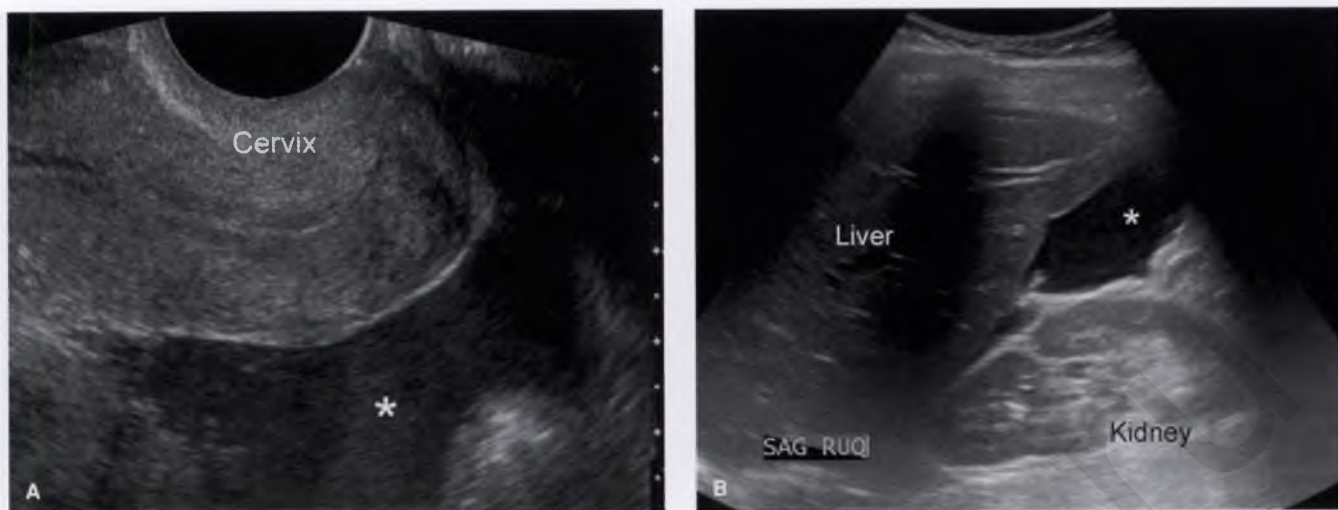


FIGURE 14-3 Hemoperitoneum. **A.** In this transvaginal sonographic sagittal view of the cervix and cul-de-sac, low-level echoes in the posterior cul-de-sac are marked by the asterisk and reflect hemoperitoneum. **B.** With significant hemorrhage, blood may reach Morison pouch. In this right-upper-quadrant sonogram, the anechoic area (*) adjacent to the liver edge and kidney represents blood from a ruptured hemorrhagic cyst.

malignancy (Koo, 2011; Yen, 2009). In one study, an increase in mass diameter greater than 0.35 cm/wk was associated with a higher malignancy rate (8.3 percent) compared with the cancer rate (0.88 percent) in slower growing tumors (Yen, 2009).

In a study of more than 4.8 million obstetric patients in California, 9375 were diagnosed with an adnexal mass. Of these, 87 women had ovarian cancer, and another 115 gravidas had low-malignant-potential tumors. More than 80 percent of cases were International Federation of Gynecology and Obstetrics (FIGO) stage I, and the overall mortality rate due to ovarian cancer was 4.7 percent. The authors attributed the low mortality rate to a higher rate of germ cell tumors—39 percent, younger patients—30 years, and early-stage disease compared with nonpregnant women in the California cancer registry database (Leiserowitz, 2006).

Diagnosis

Commonly, pelvic pain, constipation, and back pain may be earlier signs of ovarian cancer. Unfortunately, these often mirror pregnancy symptoms and can delay diagnosis. Moreover, many ovarian masses are asymptomatic and only detected during routine prenatal sonographic examination.

Sonography is the preferred initial evaluation if an adnexal mass is suspected. The typical imaged appearance of ovarian cancer varies but is usually complex. Peritoneal implants with more advanced-stage tumors are rarely detected sonographically. In cases with more complicated anatomy, MR imaging may add supplemental information. With suspected cancer, tumor markers are obtained as outlined on page 230.

Management

If malignancy is strongly suspected, preoperative consultation with a gynecologic oncologist is prudent. During surgery for a highly suspicious adnexal mass, pelvic washings are obtained for cytologic analysis once the abdomen is entered. If frozen-section histopathologic analysis of the mass verifies malignancy, cancer staging begins with careful inspection of all accessible

peritoneal and visceral surfaces (Giuntoli, 2006; Yazigi, 1988). Biopsies are taken from the diaphragmatic surface and peritoneum; omentectomy is done; and pelvic and infrarenal para-aortic lymph nodes are sampled. Depending on uterine size, some of these components, especially lymphadenectomy, may not be technically feasible. If there is advanced disease, bilateral adnexectomy and omentectomy will decrease most tumor burden. In early pregnancy, hysterectomy and aggressive surgical debulking procedures may be elected.

■ Cyst Rupture or Obstructed Labor

Rupture of an adnexal cyst is uncommon and is reported to occur in <1 percent of cases (Naqvi, 2015). Symptoms are similar to those with torsion and may include acute abdominal pain associated with peritoneal signs. If the cyst is hemorrhagic, there may be associated hypotension due to hemoperitoneum. Again, sonography can aid diagnosis. Hemoperitoneum is seen as anechoic or complex fluid in the cul-de-sac. With advancing volumes, fluid extends up the paracolic gutters to Morison pouch (Fig. 14-3).

Large adnexal masses located in the anterior or posterior cul-de-sacs can potentially obstruct labor. In these cases, they act similarly to a leiomyoma in the lower uterine segment (Goh, 2013).

DIAGNOSTIC TOOLS

■ Sonography

Several diagnostic modalities have been evaluated to help differentiate between benign and malignant adnexal masses and to predict the likelihood of emergent surgical intervention during pregnancy. These include sonography and Doppler interrogation, CT, and MR imaging, as well as the use of serum tumor markers.

With sonography, several investigators have assessed characteristics of adnexal masses during pregnancy to predict malignancy (Bromley, 1997; Chiang, 2004; Yacobozzi, 2012;

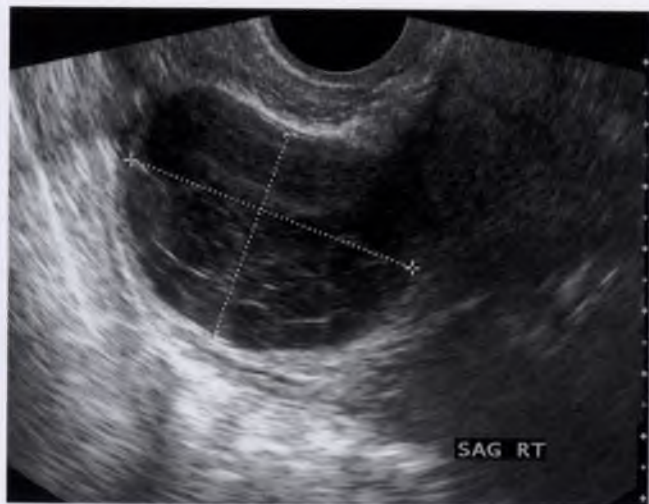


FIGURE 14-4 Hemorrhagic ovarian cyst. These cysts have varying sonographic appearances, and the reticular pattern seen in this transvaginal image is common.

Zanetta, 2003). Simple cysts usually have thin walls and are anechoic. If there is acute or chronic hemorrhage, then the cyst may be echogenic or show a reticular pattern (Fig. 14-4). A large fluid-filled or multilocular cyst that persists in the second trimester is more likely to be a serous or mucinous cystadenoma than a functional cyst (Fig. 14-5). These tumors sometimes have thin septations.

Complex adnexal masses that are encountered during pregnancy vary sonographically. Those most commonly seen are benign mature cystic teratomas, which are bilateral in approximately 10 percent of cases. Their characteristic sonographic appearance includes hyperechoic mural nodules, acoustic

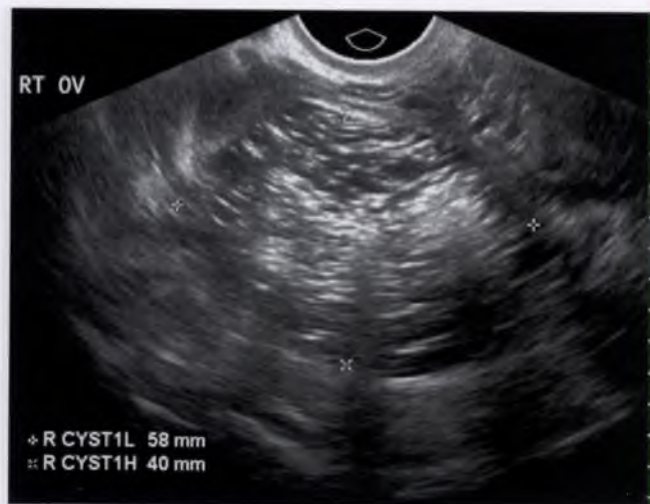


FIGURE 14-6 Mature cystic teratoma. In this transvaginal sonogram, multiple thin, echogenic bands are created by hair in the cyst cavity. A fat-fluid level is also evident. (Used with permission from Dr. Timothy P. Canavan, Magee Women's Hospital, University of Pittsburgh.)

shadowing, and a fat-fluid interface (Fig. 14-6). Additionally, hyperechoic lines or dots represent hair oriented lengthwise or on end, respectively. Endometriomas are seen in 3 to 10 percent of pregnant women (Fig. 14-7). These tumors are characterized by diffuse homogenous low-level internal echoes, and septations may be present. In some cases, their appearance mimics a hemorrhagic cyst.

Solid tumors are less common. Leiomyomas are the most common solid adnexal masses in pregnancy. As shown in Figure 14-8, they appear similar to an ovarian fibroma, that is, hypoechoic, heterogeneous, and solid with acoustic shadowing.

Theca-lutein cysts are typically bilateral and associated with increased human chorionic gonadotropin (hCG) production, which is often seen with multifetal gestation or gestational trophoblastic disease. Their characteristic appearance includes enlarged ovaries with multiple anechoic cysts (Fig. 14-9). These cysts usually resolve spontaneously after delivery as hCG levels dissipate.

Some sonographic characteristics raise the likelihood of malignancy in adnexal masses. Worrisome findings include large diameter, thick or multiple septa, thick or irregular inner walls, mural papillary growths, and mixing of cystic and solid components. With TV-CDS, intracystic blood flow adds concern. Ascites, while also a worrisome sonographic feature,

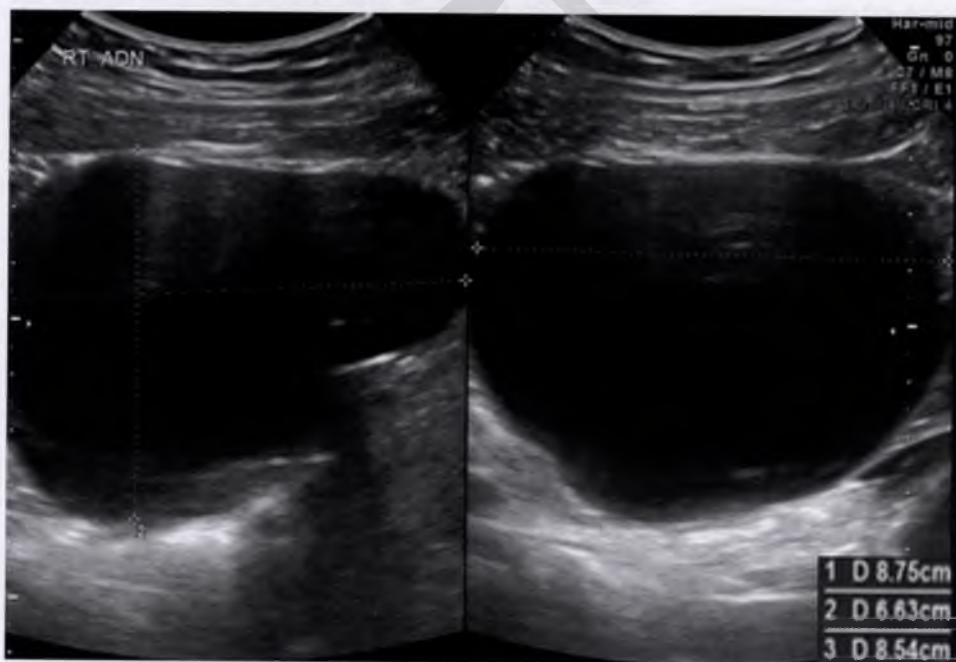


FIGURE 14-5 Ovarian cystadenoma. As seen in this transabdominal sonogram, a large, thin-walled, fluid-filled cyst is typical of this neoplasm. (Used with permission from Dr. Joan M. Mastrobattista, Baylor College of Medicine.)

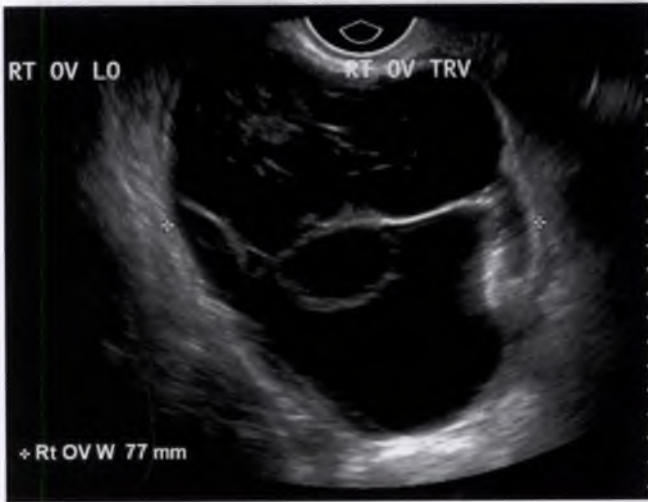


FIGURE 14-7 Ovarian endometrioma. This transvaginal sonogram displays characteristic diffuse, homogenous low-level internal echoes and thin septations. (Used with permission from Dr. Timothy P. Canavan, Magee Women's Hospital, University of Pittsburgh.)

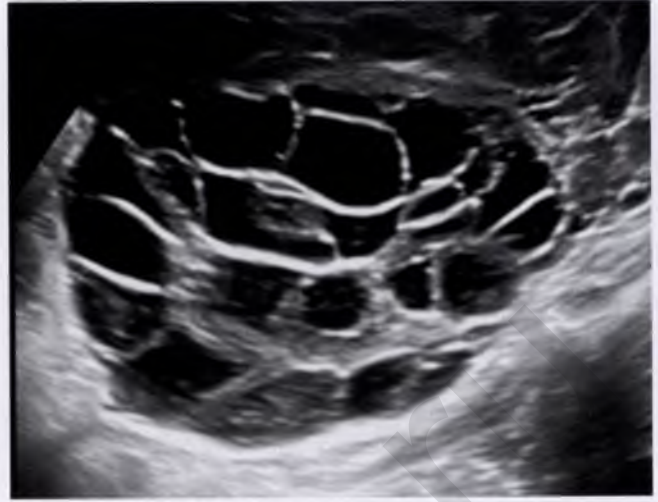


FIGURE 14-9 Theca lutein cysts. This transvaginal sonogram shows multiple small theca lutein cysts contained within the ovary. Both ovaries are typically affected. (Used with permission from Dr. Janice L. B. Byrne, University of Utah School of Medicine.)

is rarely seen in pregnancy. Although malignancy is unlikely in the absence of these features, it can never be excluded (Whitecar, 1999).

■ Doppler Interrogation

As just noted, Doppler interrogation can be used in nonpregnant women to complement two-dimensional (2-D) gray-scale imaging to aid discrimination between benign and malignant adnexal masses. Some characteristics that suggest malignancy include very high color content seen during Doppler evaluation. With spectral pulsed-wave Doppler analysis, a low resistance

index (≤ 0.42) and low pulsatility index (≤ 1.0) are indicative (Abbas, 2014; Timmerman, 2010). Scoring models that have incorporated Doppler provide great accuracy for detecting malignancy, with 93-percent sensitivity and 92-percent specificity (Abbas, 2014). These results, however, have not been replicated during pregnancy. Wheeler and Fleischer (1997) used sonography and color Doppler to evaluate 34 pregnant women with complex adnexal masses in the second trimester. The positive-predictive value of a low (< 1.0) pulsatility index was only 42 percent. This was due to the considerable overlap in blood flow patterns between benign and malignant masses.

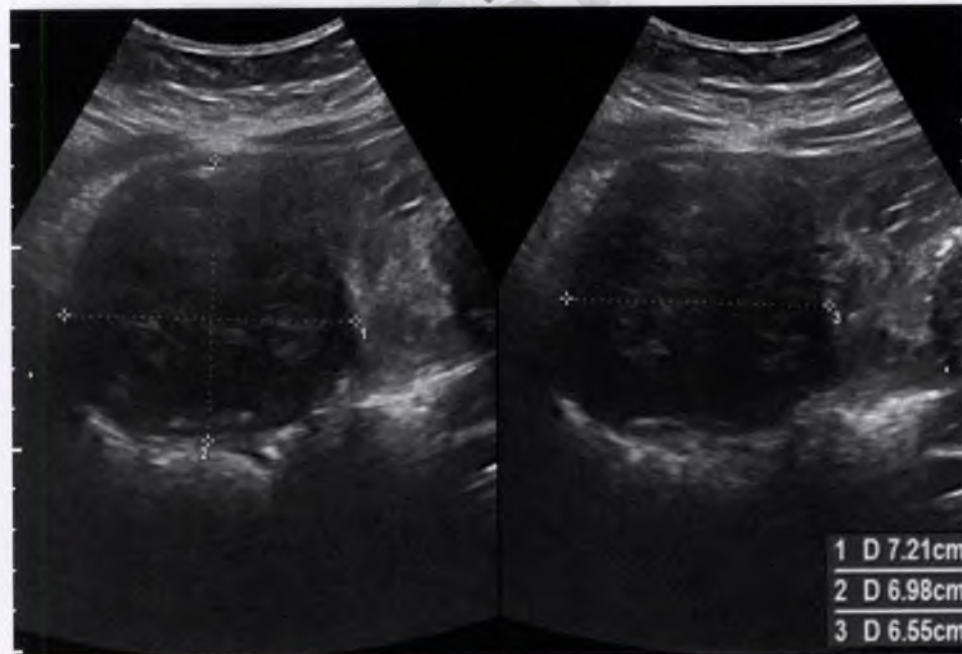


FIGURE 14-8 Leiomyoma. This transabdominal sonogram shows a right lateral subserous myoma. This well-defined, hypoechoic structure could be mistaken for an adnexal mass. (Used with permission from Dr. Joan M. Mastrobattista, Baylor College of Medicine.)

■ Magnetic Resonance Imaging

Due to its superior resolution between soft-tissue densities, this modality may be superior at defining a mass as extraovarian in origin (American College of Obstetricians and Gynecologists, 2015a). Thus, it may provide improved tissue characterization for sonographically indeterminate adnexal masses. For example, a pedunculated uterine myoma can be distinguished from an ovarian fibroma. Also, its wide field of view may allow MR imaging to better characterize large masses that are incompletely viewed by sonography.

The role of MR imaging as an adjunct in diagnostic evaluation of adnexal masses in pregnancy was reviewed by Glanc and associates (2008). As discussed in Chapter 5 (p. 74), MR imaging without

contrast is considered safe in pregnancy. However, the safety of gadolinium-based MR imaging contrast agents has not been determined.

■ Computed Tomography

Although this modality involves exposure of the fetus to radiation, CT allows rapid evaluation of tumor masses in women who are clinically unstable. Compared with sonography, it also may offer better resolution in identifying nonobstetric causes of abdominal pain (Hoover, 2011). As indicated, the disadvantage is that CT imaging of the abdomen and pelvis results in fetal x-ray exposure of 10 to 50 mGy (Chap. 5, p. 73). For these latter reasons, CT imaging is less commonly used to evaluate adnexal masses during pregnancy (Goldberg-Stein, 2012).

■ Tumor Markers

The most common serum tumor marker used to evaluate an adnexal mass in a nonpregnant woman is cancer antigen 125 (CA125). In nongravid women, serum CA125 levels measuring greater than 65 U/mL predicted ovarian malignancy with a sensitivity of 91 percent (Malkasian, 1988; Patsner, 1989). Serum CA125 levels are elevated in 50 percent of early-stage and 80 percent of advanced-stage epithelial ovarian cancers (Horowitz, 2011). That said, CA125 is also elevated in other disease states that include endometriosis, peritonitis, salpingitis, leiomyoma, tuberculosis, and certain metastatic nongynecologic and gynecologic cancers.

Unfortunately, CA125 is not specific in pregnant women. Increased serum levels (>35 U/mL) have been found in both the first and second trimesters in women with uncomplicated pregnancies (Seki, 1986; Touitou, 1989). It has been suggested that after the first trimester, a markedly elevated serum CA125 level (1000 to 10,000 U/mL) should raise suspicion of malignancy (Goh, 2014).

Other tumor markers such as β -hCG, lactate dehydrogenase (LDH), and maternal serum α -fetoprotein (MSAFP) similarly have limited value during pregnancy because their levels rise physiologically (Sarandokou, 2007). An exception to this is that markedly elevated MSAFP levels are often seen with germ cell tumors such as yolk sac tumors, embryonal tumors, or mixed germ cell tumors. Specifically, MSAFP levels >9.0 multiples of the median should prompt further evaluation by sonography (Horowitz, 2011). OVA1 is a biomarker blood test that measures five analytes, one of which is CA125. However, ranges for OVA1 results have not been defined for pregnancy, and thus this test is not recommended.

MANAGEMENT

Management of an adnexal mass in pregnancy depends on factors that include gestational age at discovery, mass diameter, sonographic characteristics that might indicate malignancy, and whether or not there are complaints. With symptoms, most agree that surgical excision is indicated. However, for asymptomatic masses that do not appear malignant, either expectant management or surgical removal may be considered. In pregnancy, surgical treatment of adnexal masses includes

cystectomy or oophorectomy that is accomplished either by laparoscopy or laparotomy.

Importantly, if the corpus luteum is removed before 10 weeks' gestation, progestational support is recommended until 10 weeks' gestation to maintain the pregnancy. Suitable regimens include: (1) micronized progesterone (Prometrium) 200 or 300 mg orally once daily; (2) 8-percent progesterone vaginal gel (Crinone) one premeasured applicator vaginally daily plus micronized progesterone 100 or 200 mg orally once daily; or (3) intramuscular 17-hydroxyprogesterone caproate (Delalutin), 150 mg. For the last, if between 8 and 10 weeks, then only one injection is required immediately after surgery. If the corpus luteum is excised between 6 and 8 weeks, then two additional doses should be given 1 and 2 weeks after the first.

■ Emergent Surgical Treatment

As noted, major complications of adnexal masses include malignancy and emergent situations such as labor obstruction, torsion, or tumor rupture (Naqvi, 2015). When an emergent complication is suspected, surgery should not be delayed because of pregnancy. In a study by Lee and colleagues (2004), surgical management for ovarian tumors was described in 36 women who underwent emergent surgery for torsion—61 percent in the first trimester, 14 percent in the second, and 25 percent in the last trimester. Outcomes in these women were compared with those of 53 women who underwent elective surgery for an adnexal mass in the first or second trimester. The incidence of preterm birth before 37 weeks was significantly higher in women who underwent emergent surgery compared with those who had elective surgery—22 versus 4 percent, respectively.

■ Asymptomatic Masses

Expectant Management

As noted, with an asymptomatic adnexal mass, surgery or observation may be appropriate. Thus, maternal-fetal risks of surgery are balanced against risks for malignancy and for mass-related complications that may develop as pregnancy progresses.

It is reasonable to observe many asymptomatic adnexal masses that are not suspicious for malignancy (Naqvi, 2015). Condous and coworkers (2004) studied 161 women who were identified as having an adnexal mass during the first trimester with a mean ovarian cyst diameter of 4.8 cm and a range of 1.2 to 11.5 cm. Of these, 71 percent resolved spontaneously. The true rate of resolution may be inaccurate due to situations that prompt surgical removal. For larger cysts that are asymptomatic, the greater potential risk for torsion or rupture should be considered.

Surgical Management

If an adnexal mass poses a risk for malignancy or future complications or if signs suggest torsion or hemodynamic instability due to rupture, then surgical intervention is indicated (Naqvi, 2015). According to the American College of Obstetricians and Gynecologists (2015b), indicated surgery should not be postponed regardless of trimester. That said, the College recommends that when possible, elective surgery is ideally postponed until after delivery and nonurgent surgery is preferably done in

the second trimester. The rationale for delaying nonemergent surgery to the second trimester is twofold. First, fetal organogenesis is complete and possible teratogenic effects are mitigated. Second, spontaneous abortions are less common than earlier in pregnancy (O'Rourke, 2006).

Preoperative Preparation. In general, during patient consenting for adnexal surgery, the discussion includes the risk for oophorectomy. This may be needed for malignancy or for extensive bleeding from ovarian cyst rupture or iatrogenic injury. Also, a variable degree of ovarian reserve is lost with either ovarian cystectomy or oophorectomy.

Many patients undergoing cystectomy for ovarian pathology have associated pain. In most cases, cystectomy will be curative, however, in other instances pain may persist despite cyst excision. Thus, patients are counseled that cystectomy may not relieve chronic pain in all cases.

Adnexal surgery is typically a clean surgical case, and antibiotics are typically not required preoperatively. Surgery during pregnancy dictates venous thromboembolism prophylaxis, and options are discussed in Chapter 18 (p. 297).

Laparotomy versus Laparoscopy. With surgical management, adnexal masses may be removed via laparotomy or laparoscopy. One of the largest studies reviewing surgery in pregnancy spanned 20 years and contained more than 2 million deliveries (Reedy, 1997). Pregnancy outcomes were reviewed in women who underwent nonobstetric surgery between 4 and 20 weeks' gestation. Of these women, 2181 underwent laparoscopic surgery and 1522 underwent laparotomy. Perinatal outcomes reviewed included birthweight, gestational age, fetal growth restriction, congenital malformations, and perinatal mortality. These investigators reported no differences between these five outcomes for women undergoing laparoscopy versus laparotomy. For any woman undergoing surgery, however, the risks for a low-birthweight newborn (<2500 g), preterm delivery (prior to 37 weeks' gestation), or fetal growth restriction were increased. Importantly, these investigators could not reliably attribute these adverse perinatal outcomes to anesthesia, to the underlying disease process, or to surgery itself.

Another study of 5405 nonobstetric operations during pregnancy showed similar findings (Mazze, 1989). These investigators reported an increased risk of low-birthweight infants (<2500 g) due to fetal growth restriction and to preterm delivery (<37 weeks' gestation). Although 42 percent of these procedures were performed in the first trimester—and thus during organogenesis—congenital malformation rates were not increased.

During the past few decades, the use of laparoscopy in pregnancy has increased. Advantages include faster recovery and return to daily activities, decreased postoperative pain and narcotic use, earlier return of bowel function, shorter hospital stay, decreased wound infection rates, and earlier ambulation (Al-Fozan, 2002).

Previously, pregnancy was thought to be a contraindication to laparoscopy, but this perception has changed as more data have accrued. Potential concerns include the risk of preterm labor and fetal loss, fetal hypoxia, and decreased uterine blood flow from the increased intraperitoneal pressure caused

by pneumoperitoneum. That said, pregnancy loss and preterm labor are thought to be related more to the underlying pathology and not the surgical procedure per se (Al-Fozan, 2002).

Large studies of laparoscopic adnexal surgery in pregnancy are scarce. Of those reported in the literature, the overall maternal and fetal outcomes are favorable. In a retrospective review of 48 laparoscopies for adnexal masses in pregnancy, surgery was performed between 6 and 33 weeks' gestation for symptomatic pelvis masses, torsion, cyst rupture, or persistent or suspicious ovarian masses (Mathevet, 2003). Abdominal entry was either by Veress needle placement in the left upper quadrant or by an open Hasson technique, both described in Chapter 15 (p. 248). The mean gestational age at birth was 39 weeks, and the range was 36 to 41 weeks. One fetus died 4 days after laparoscopic ovarian cystectomy at 17 weeks' gestation.

Another study of 67 laparoscopies for adnexal masses at 12 to 25 weeks' gestation showed similar outcomes (Yuen, 2004). Entry was by the open technique, and the median cyst diameter was 6 cm, with a range of 4 to 15 cm. There were no intraoperative or postoperative complications, and the median gestation at delivery was 39 weeks. One patient had a pregnancy loss 6 weeks after laparoscopic cystectomy performed at 16 weeks' gestation for a 5-cm mature cystic teratoma. During the case, intraoperative cyst contents were not spilled. She later presented at 22 weeks' gestation with ruptured membranes and delivered a stillborn fetus.

Although the Society of American Gastrointestinal Endoscopic Surgeons (SAGES) guidelines indicate that laparoscopy can be safely performed in any trimester, it seems reasonable to consider the constraints posed by increasing uterine size, especially in the last trimester (Pearl, 2011). Indeed, most reports of laparoscopy in the third trimester are small case series. In one series, successful fetal outcomes were reported in 10 women who underwent laparoscopic surgery between 28 and 34 weeks' gestation (Upadhyay, 2007). These cases included laparoscopic appendectomy, cholecystectomy, and adnexal surgery. Nine of these women were delivered at term. In the remaining case, preterm delivery followed laparoscopic appendectomy for a perforated appendix with purulent peritonitis. In all 10 cases, the Veress needle was used for abdominal entry. Another series reviewed 92 women who underwent either appendectomy or cholecystectomy—61 laparoscopies and 31 laparotomies (Affleck, 1999). Fifteen of these women had laparoscopy in the third trimester. In this series, there were no fetal losses, uterine injuries, or spontaneous abortions in the laparoscopic group. Outcomes between the laparotomy and laparoscopy groups did not differ. There was a slightly higher rate of preterm delivery (<37 weeks) in both the laparotomy and laparoscopy groups compared with women not undergoing surgery.

Surgical route is also dictated by clinical factors. Namely, large cysts may obstruct laparoscopic instrument mobility and may not fit into endoscopic sacs for contained removal. For medium-sized cysts, laparotomy incisions can usually be minimized. Minilaparotomy typically offers shorter operative times, lower rates of cyst rupture, and greater cost savings compared with laparoscopy. However, this approach can limit a surgeon's ability to lyse adhesions and inspect peritoneal surfaces for signs of ovarian malignancy.

Women with large cysts or significant pelvic adhesive disease are usually managed by laparotomy, depending on gestational age. With a greater potential for malignancy, a midline vertical incision provides a surgical field large enough for oophorectomy or cyst enucleation without tumor rupture and for surgical staging in the upper abdomen if malignancy is found. In those with a low risk of malignancy and a moderately sized cyst, laparotomy through a low transverse incision may be appropriate and offer the advantages of this incision (Chap. 4, p. 49).

Cystectomy versus Adnexectomy. Ovarian cysts presumed to be benign or to have a lower concern for malignancy may be enucleated, or the whole ovary may be removed. Of these two, cystectomy offers the advantage of ovarian preservation, but at the risk of cyst rupture and content spill. With ovarian cancer, such spill and subsequent malignant seeding can worsen patient prognosis. Thus, the decision for one surgical technique in preference to the other is influenced by lesion size and intraoperative findings. For example, smaller lesions generally require only cystectomy with preservation of reproductive function. Larger lesions may necessitate oophorectomy because of increased risks of cyst rupture during enucleation and difficulty in reconstructing ovarian anatomy following large cyst removal. Also, risk of malignancy is greater in these bigger cysts (Okugawa, 2001). Clinical findings of an unexpected malignancy at the time of surgery will dictate further actions described on page 227.

Cystectomy via Laparotomy. To gain abdominal entry, a low-transverse or midline vertical laparotomy incision is created as illustrated in Chapter 4 (p. 50). As described earlier, if cancer is a greater concern, pelvic washings are collected prior to ovarian manipulation. A self-retaining retractor is placed within the incision, the pelvis is explored, and the bowel and omentum are packed from the operating field. The ovary is brought into view, and moist laparotomy sponges are placed in the cul-de-sac and beneath the ovary. This helps to minimize contamination of the pelvis if the cyst ruptures during excision.

To begin, the ovary is held between the surgeon's thumb and opposing fingers. The ovarian capsule that overlies the dome of the cyst is then cut with either scalpel or electrocautery needle tip. This incision is ideally placed on the antimesenteric surface of the ovary to minimize dissection into vessels at the ovarian hilum. The incision is deepened to reach the cyst wall without entering and rupturing the cyst (Fig. 14-10).

The surgeon positions Allis clamps on the incised edges of the ovarian capsule and gently pulls these in a direction away from the cyst wall (Fig. 14-11). Concurrently, the surgeon places fingers on the cyst near the grasped ovarian capsule and stretches the cyst in the direction opposite the Allis clamps. Such traction and countertraction across the cleavage plane aids dissection. Because the surface of the cyst wall is often smooth and slippery, the surgeon may place an opened gauze sponge between fingers and the cyst wall to afford a better grip (Fig. 14-12). Blunt dissection then proceeds to develop the cleavage plane between the cyst wall and the remaining ovarian stroma. For this, pressure from a fingertip, knife handle, or opening and closing scissor blades can be used. Sharp dissection with Metzenbaum scissor tips can also be used and is often

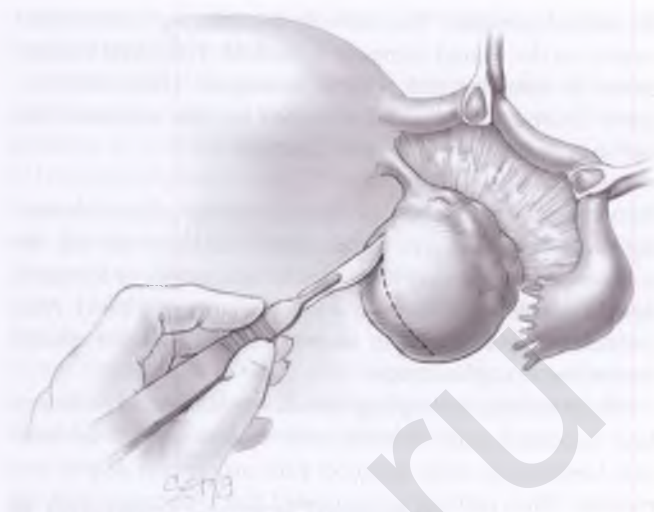


FIGURE 14-10 Cystectomy via laparotomy. To begin, an incision is made into the ovarian capsule. (Reproduced with permission from Hoffman BL, Corton MM: *Surgeries for benign gynecologic conditions*. In Hoffman BL, Schorge JO, Bradshaw KD, et al (eds): *Williams Gynecology*, 3rd ed. New York, McGraw-Hill Education, 2016.)

alternated in tandem with blunt separation. If adhesions obliterate the cleavage plane, sharp dissection is preferred.

As dissection approaches completion, the highly vascular ovarian hilum is reached. If possible, a hemostat or Kelly clamp is placed across the small remaining tissue bridge between the cyst and normal ovary. The clamp is positioned closer to the ovary to allow space for scissors to cut the tissue pedicle and free the cyst without rupture. The pedicle is ligated with a fine absorbable suture. The ovarian bed is then examined, and bleeding points are coagulated or suture ligated.

The ovarian bed is then closed in layers using 3-0 or 4-0 gauge delayed-absorbable suture. These sutures reapproximate the ovarian tissue that previously surrounded the cyst on both sides (Fig. 14-13). The ovarian incision is closed with a running subcuticular stitch (similar to a subcuticular stitch) using 4-0 or 5-0 gauge delayed-absorbable suture.

Laparotomy sponges are removed from the cul-de-sac, and the pelvis is copiously irrigated. Irrigation assumes an even greater importance with ovarian cyst rupture. For example, spill from a mature cystic teratoma (dermoid cyst), if neglected, may induce a chemical peritonitis. Depending on the surgeon's preference and the patient's anatomy, an adhesion barrier may be placed around the ovary prior to laparotomy closure to lower adhesion formation. However, no substantial evidence documents that the use of such barriers improves fertility, decreases pain, or prevents bowel obstruction (American Society for Reproductive Medicine, 2013).

Laparoscopic Cystectomy. Initial intraoperative steps for laparoscopy are described in Chapter 15 (p. 248). Upon entry, exploration is completed and washings are secured as needed. Although the basic steps of incision and dissection are completed during laparoscopic ovarian cyst removal, there are distinct differences.

To begin, a blunt probe is placed under the uteroovarian ligament and posterior ovarian surface to elevate the ovary. An

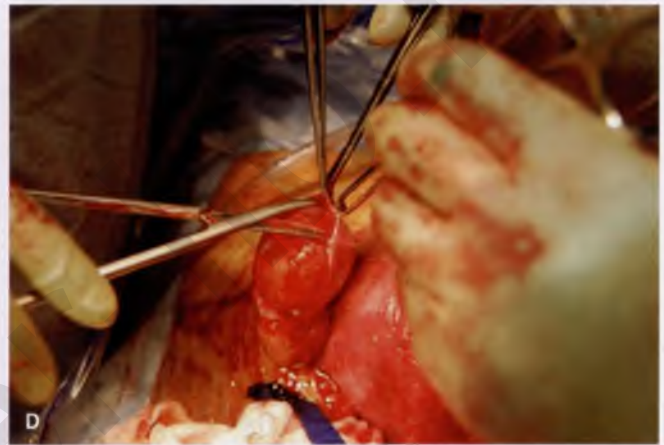
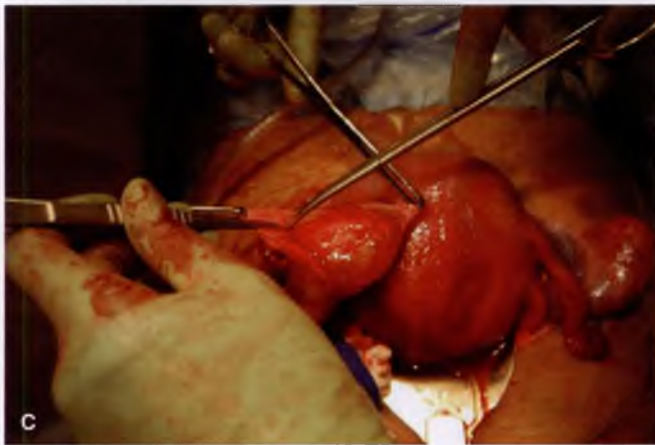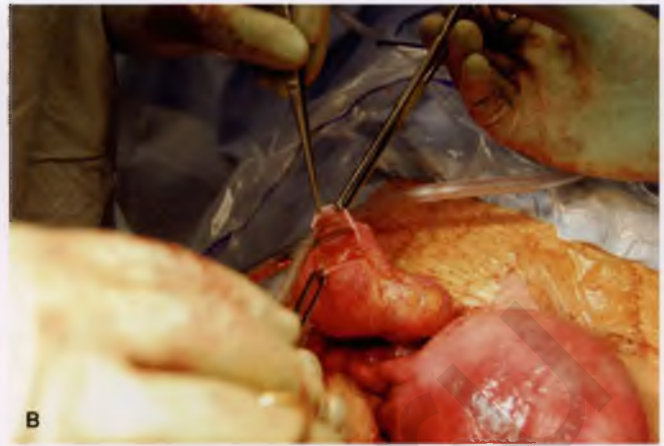
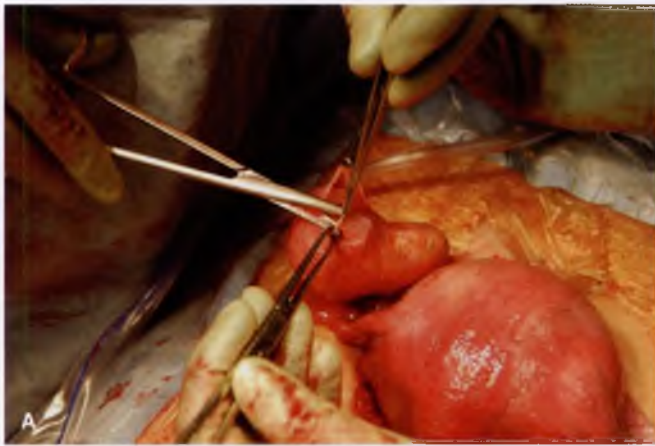


FIGURE 14-11 A plane is then developed between the overlying ovarian capsule and the underlying cyst (A-D). During dissection, gentle traction on the tissue to be dissected typically simplifies the process. Once the correct tissue plane is entered, scissor blades are closed and inserted between planes, while following the natural curves of tissues being dissected. The blades are opened, and then slightly closed and withdrawn. Dissection proceeds in the same plane to avoid burrowing into the cyst and rupturing it.

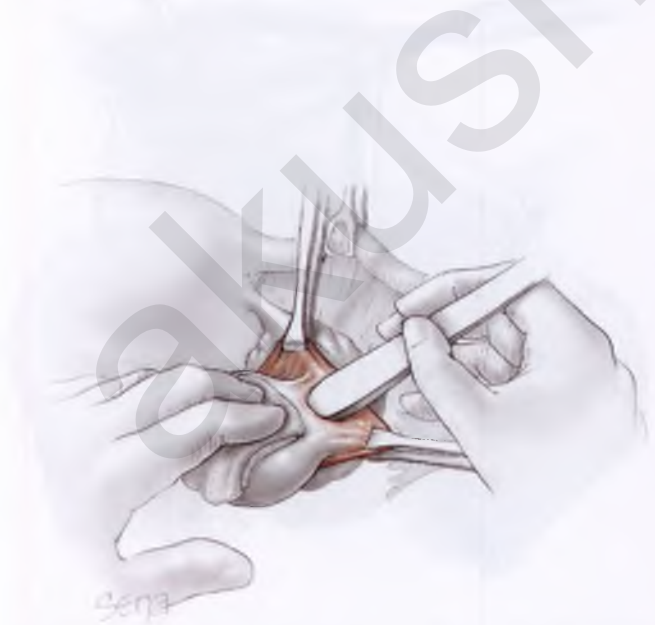


FIGURE 14-12 Blunt dissection can similarly develop this space. Ideally, the entire cyst is removed intact. (Reproduced with permission from Hoffman BL, Corton MM: Surgeries for benign gynecologic conditions. In Hoffman BL, Schorge JO, Bradshaw KD, et al (eds): Williams Gynecology, 3rd ed. New York, McGraw-Hill Education, 2016.)

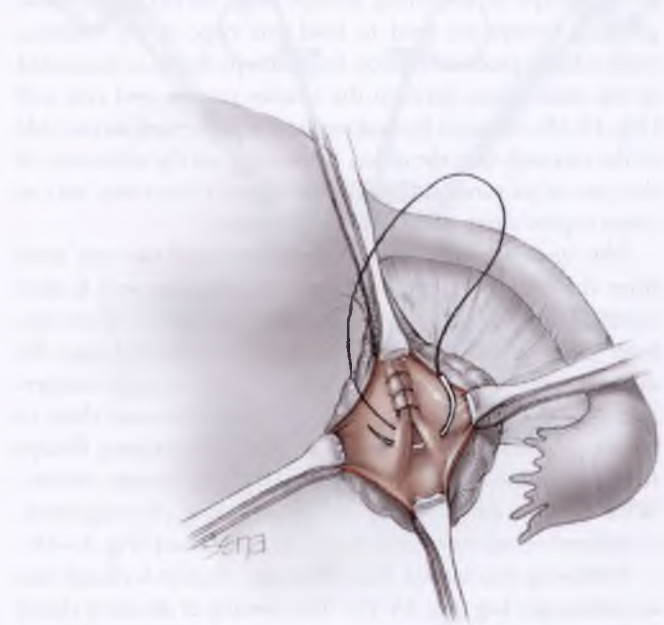


FIGURE 14-13 The remaining ovarian capsule can be closed with suture. (Reproduced with permission from Hoffman BL, Corton MM: Surgeries for benign gynecologic conditions. In Hoffman BL, Schorge JO, Bradshaw KD, et al (eds): Williams Gynecology, 3rd ed. New York, McGraw-Hill Education, 2016.)

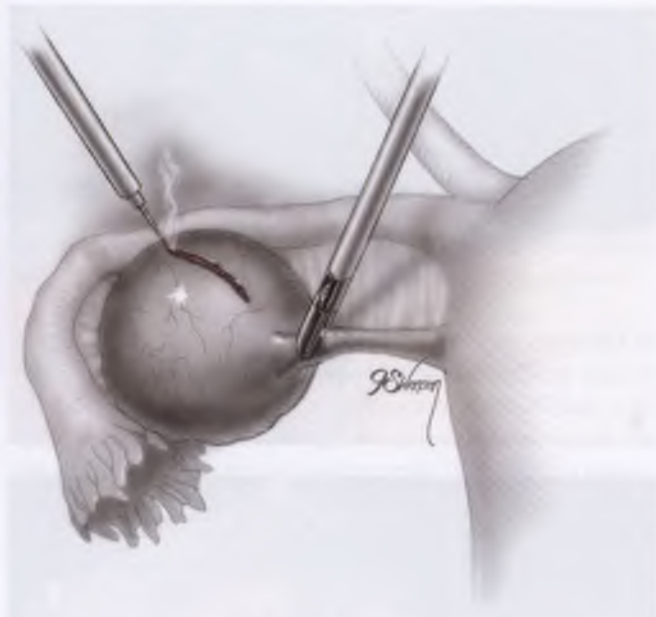


FIGURE 14-14 Laparoscopic cystectomy. To begin, the ovarian capsule is incised. (Reproduced with permission from Thompson M, Kho K: Minimally invasive surgery. In Hoffman BL, Schorge JO, Bradshaw KD, et al (eds): Williams Gynecology, 3rd ed. New York, McGraw-Hill Education, 2016.)

atraumatic grasping forceps then steadies the ovary. One may consider placing an open endoscopic bag beneath the ovary to catch any cyst spill. A monopolar needle tip electrode set at a cutting voltage or harmonic scalpel is used to incise the ovarian capsule that overlies the cyst (Fig. 14-14).

A space between the ovary and cyst wall is then created using blunt forceps or dissecting scissors (Fig. 14-15). Atraumatic grasping forceps are used to hold one edge of the incision, while a blunt probe or suction-irrigation probe tip is insinuated in the tissue plane between the ovarian capsule and cyst wall (Fig. 14-16). Blunt or hydrodissection is performed on one side of the cyst and then the other. Depending on the adherence of the cyst to its surrounding ovarian tissue, cystectomy may at times require sharp dissection with scissors.

Not uncommonly during the dissection of the cyst away from the ovary, the cyst may rupture. The cyst wall is then removed using a “stripping” technique (Fig. 14-17). With this, both the cyst wall and cyst capsule can be grasped near the dissection plane by atraumatic forceps. Traction and counter-traction can separate filmy connective tissue between these to advance the dissection plane. As a result, the grasping forceps strip the cyst wall away from the underlying ovarian stroma. With the cyst enucleated, points of bleeding are coagulated, or isolated vessels may be grasped and coagulated (Fig. 14-18).

Following enucleation from the ovary, the cyst is placed into an endoscopic bag (Fig. 14-19). The opening of the sac is closed and brought up to the anterior abdominal wall. Depending on its size, the cyst and endoscopic bag may be removed in toto through one of the accessory cannulas.

Alternatively, with larger cysts, the cannula is removed, and the entire pursed opening of the bag is drawn up through the trocar incision and fanned out onto the skin surface. The open

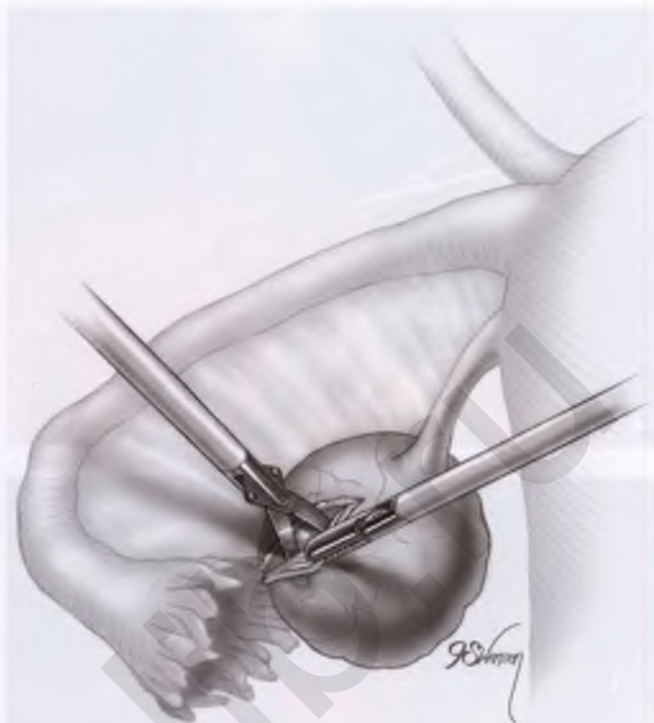


FIGURE 14-15 The ovarian capsule is grasped with forceps and the underlying cyst is dissected away sharply. (Reproduced with permission from Thompson M, Kho K: Minimally invasive surgery. In Hoffman BL, Schorge JO, Bradshaw KD, et al (eds): Williams Gynecology, 3rd ed. New York, McGraw-Hill Education, 2016.)

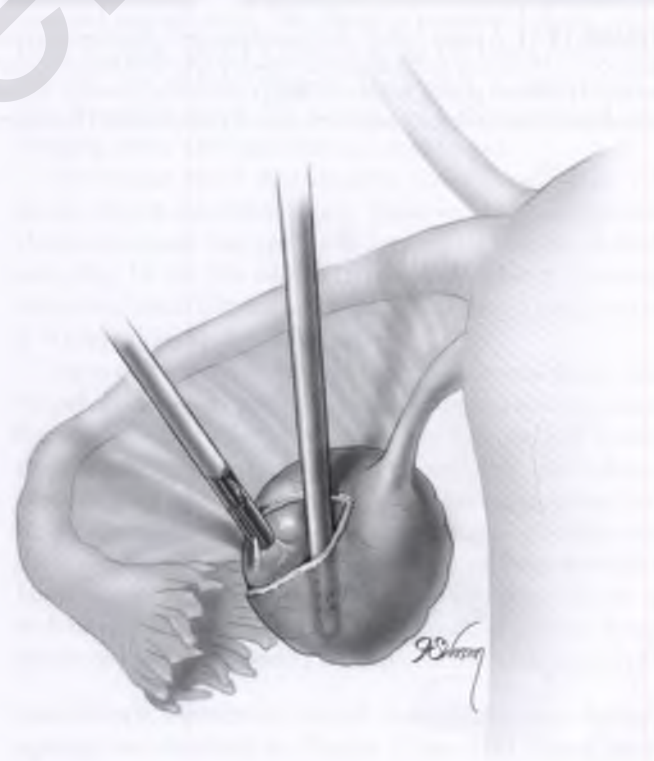


FIGURE 14-16 Blunt dissection can similarly develop this space between the capsule and cyst. Ideally, the cyst is removed intact. (Reproduced with permission from Thompson M, Kho K: Minimally invasive surgery. In Hoffman BL, Schorge JO, Bradshaw KD, et al (eds): Williams Gynecology, 3rd ed. New York, McGraw-Hill Education, 2016.)

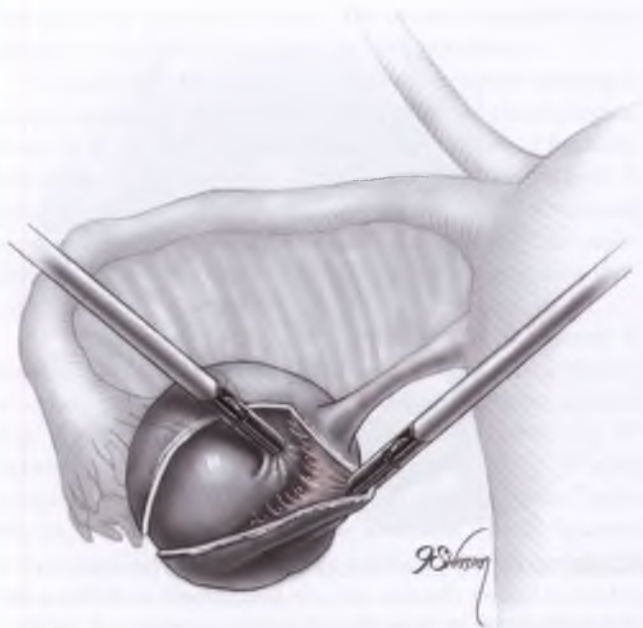


FIGURE 14-17 With cyst rupture, traction and countertraction can be used to strip the cyst wall from the surrounding ovarian stroma. (Reproduced with permission from Thompson M, Kho K: Minimally invasive surgery. In Hoffman BL, Schorge JO, Bradshaw KD, et al (eds): Williams Gynecology, 3rd ed. New York, McGraw-Hill Education, 2016.)

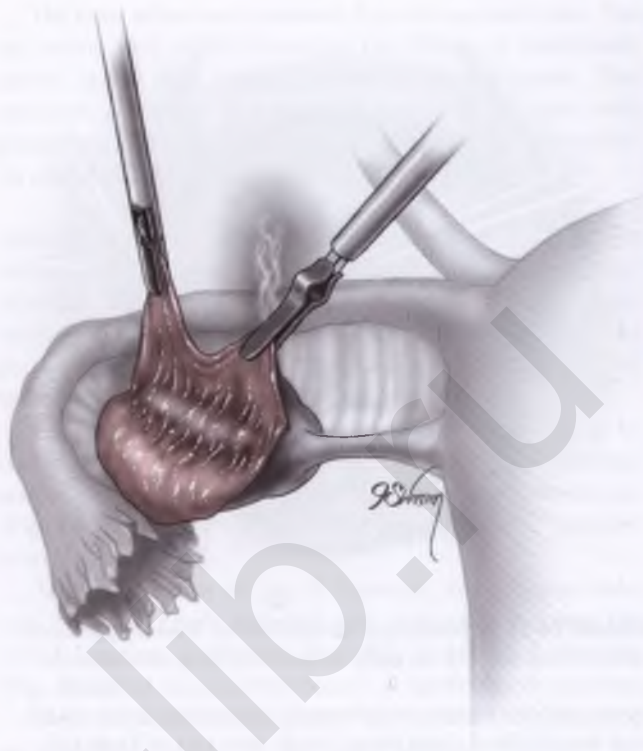

FIGURE 14-18 The remaining ovary is made hemostatic with electrocoagulation. (Reproduced with permission from Thompson M, Kho K: Minimally invasive surgery. In Hoffman BL, Schorge JO, Bradshaw KD, et al (eds): Williams Gynecology, 3rd ed. New York, McGraw-Hill Education, 2016.)

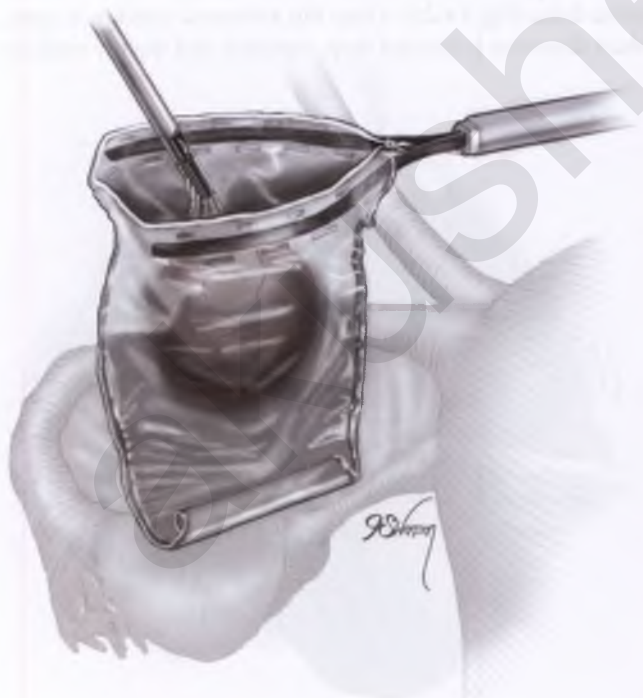

FIGURE 14-19 The cyst is placed in an endoscopic bag for removal. (Reproduced with permission from Thompson M, Kho K: Minimally invasive surgery. In Hoffman BL, Schorge JO, Bradshaw KD, et al (eds): Williams Gynecology, 3rd ed. New York, McGraw-Hill Education, 2016.)

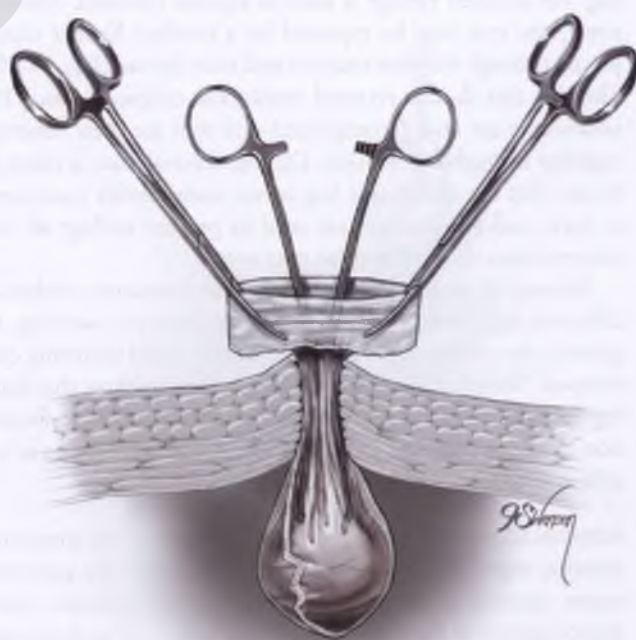


FIGURE 14-20 For large cysts, a toothed clamp punctures and decompresses the cyst. Liquid contents are then suctioned out of the bag prior to bag removal. (Reproduced with permission from Thompson M, Kho K: Minimally invasive surgery. In Hoffman BL, Schorge JO, Bradshaw KD, et al (eds): Williams Gynecology, 3rd ed. New York, McGraw-Hill Education, 2016.)

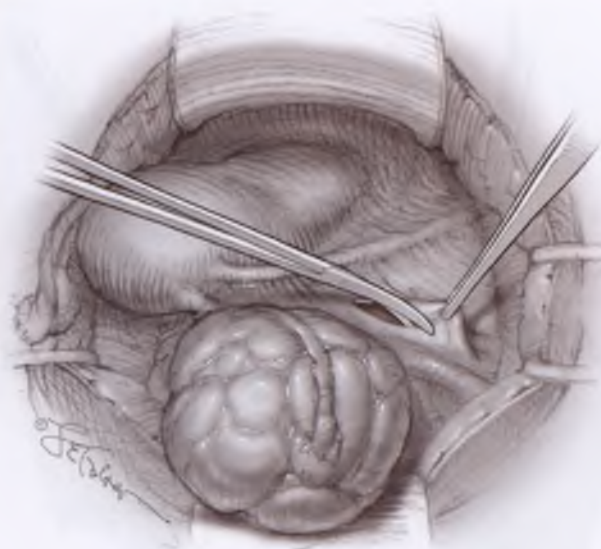


FIGURE 14-21 Adnexectomy via laparotomy. The retroperitoneal space is opened, and the ureter is identified. (Reproduced with permission from Hoffman BL, Corton MM: *Surgeries for benign gynecologic conditions*. In Hoffman BL, Schorge JO, Bradshaw KD, et al (eds): *Williams Gynecology*, 3rd ed. New York, McGraw-Hill Education, 2016.)

edges of the bag are pulled upward to lift and press the cyst up against the incision. A needle tip is then directed into the incision and pierces the cyst contained within the endoscopic bag. An attached syringe is used to aspirate contents. Alternatively, the cyst may be ruptured by a toothed Kocher clamp placed through the skin incision and into the sac (Fig. 14-20). Thereby, cyst fluid is retained within the endoscopic sac. The endoscopic sac and decompressed cyst wall are then removed together through the incision. During removal, care is taken to ensure that the endoscopic bag is not inadvertently punctured or torn, and all measures are used to prevent spillage of cyst contents into the abdomen or port site.

Because of increased risk of adhesion formation, technical difficulty, and time associated with laparoscopic suturing, in general, the ovarian capsule is not sutured closed following cyst removal. Several studies in gynecologic patients show that leaving the capsule open does not lead to increased adhesion formation (Marana, 1991; Wiskind, 1990). Again, application of an adhesion barrier may be considered.

Adnexectomy via Laparotomy. For removal of the adnexum, essential steps include preventive identification of the ipsilateral ureter, ligation of the infundibulopelvic (IP) ligament, combined ligation of the proximal fallopian tube and uteroovarian ligament, and transection of the intervening mesovarium and mesosalpinx. After abdominal entry, washings are collected as indicated, the pelvis is explored, and the adnexum is lifted and inspected.

Prior to clamping the IP ligament, the ureter is identified. In many instances, the ureter is seen beneath the posterior pelvic sidewall peritoneum. Here, it can often be identified as it enters the pelvis and crosses over the common iliac artery bifurcation

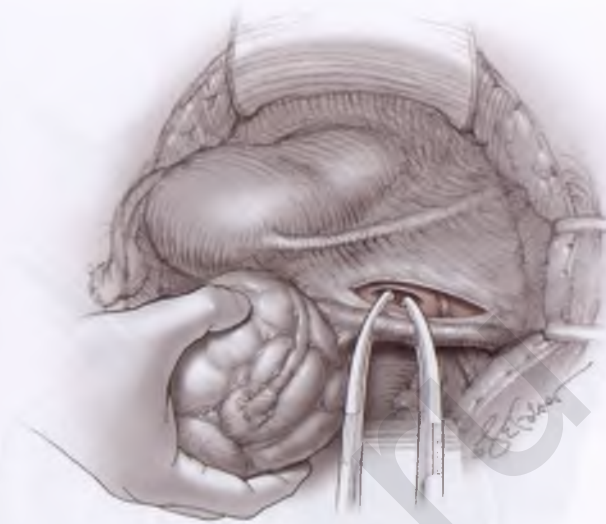


FIGURE 14-22 The infundibulopelvic ligament is clamped, cut, and suture ligated. (Reproduced with permission from Hoffman BL, Corton MM: *Surgeries for benign gynecologic conditions*. In Hoffman BL, Schorge JO, Bradshaw KD, et al (eds): *Williams Gynecology*, 3rd ed. New York, McGraw-Hill Education, 2016.)

just medial to the ovarian vessels (Fig. 3-10, p. 39). At times, a gravid uterus will obstruct these views, and retroperitoneal isolation of the ureter is required. For this, the peritoneum within the area bounded by the round ligament, the IP ligament, and the external iliac vessels is tented with tissue forceps and incised. This first peritoneal incision is extended cephalad toward the pelvic brim (Fig. 14-21). Once this peritoneal window is open, blunt dissection is directed deep, cephalad, and slightly medially

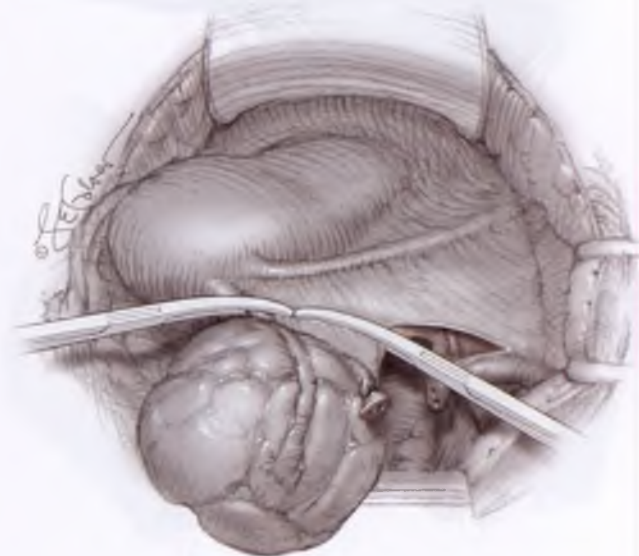


FIGURE 14-23 The uteroovarian ligament and fallopian tube are clamped, cut, and suture ligated. The remaining mesosalpinx and mesovarium are included in another clamp. (Reproduced with permission from Hoffman BL, Corton MM: *Surgeries for benign gynecologic conditions*. In Hoffman BL, Schorge JO, Bradshaw KD, et al (eds): *Williams Gynecology*, 3rd ed. New York, McGraw-Hill Education, 2016.)

through loose connective tissue. The ureter is typically found attached to the medial leaf of the incised peritoneum.

To isolate the IP ligament, a second peritoneal opening is sharply created with Metzenbaum scissors or electro-surgical blade. It is made in the posterior leaf of the broad ligament below the IP ligament but above the ureter. This incision is extended medially and toward the uterus. While remaining parallel to the IP ligament, it is also extended lateral and cephalad toward the pelvic brim. Ideally, the ureter is in view during this entire incision.

As a result of both peritoneal incisions, the IP ligament is isolated. This vascular ligament is then clamped with a Heaney or other sturdy clamp, and the clamp curve faces upward (Fig. 14-22). A single Kelly clamp is placed across the IP ligament at a distance medial to the Heaney clamp. During completion of adnexectomy, this medial clamp prevents “back-bleeding” and is removed with the specimen. The IP ligament is transected between the Heaney and Kelly clamps, and the IP tissue pedicle is then ligated.

With the adnexum elevated, a Heaney or similar clamp is placed across both the uteroovarian ligament and fallopian tube. It also incorporates some of the mesosalpinx and mesovarium. The clamp’s curve faces the ovary. Next, another clamp enters laterally and is directed medially to close around the remaining mesosalpinx and mesovarium beneath the ovary. Again, the clamp curve faces the ovary. Ideally, the tips of both clamps touch beneath the adnexum (Fig. 14-23). Tissue above the clamps is cut with curved Mayo scissors to free the adnexum.

The freed adnexum is removed from the operative site. Tissue within each of the remaining two clamps is individually suture ligated with 0-gauge delayed-absorbable suture. This specimen is sent to pathology for evaluation. In cases with greater concern for cancer, intraoperative frozen-section analysis can be requested.

Laparoscopic Adnexectomy. After abdominal entry, exploration, and collection of pelvic washings as indicated, the adnexum is lifted from the pelvis and inspected. As with open adnexal excision, the ureter’s course is identified. If needed, the peritoneum lateral to the ureter is incised, and retroperitoneal isolation of the ureter is completed.

Ligation of the ovarian vessels within the IP ligament can be completed with electro-surgical coagulating devices, Harmonic scalpel, or endoscopic stapler depending on surgeon preference (Fig. 14-24). Once these vessels are occluded, the IP ligament is severed proximally.

After transection of the IP ligament, the fallopian tube and ovary are gently elevated with atraumatic forceps. The broad ligament is incised, and this is extended medially (Fig. 14-25).

Next, the uteroovarian ligament and proximal fallopian tube are identified posterior to the round ligament. Similar to the IP, these may be coagulated or stapled (Fig. 14-26). Distal to this occlusion, the uteroovarian ligament and fallopian tube are transected, and the adnexum is freed. As with cystectomy, endoscopic bags are available for tissue removal.



FIGURE 14-24 Laparoscopic adnexectomy. The peritoneum is incised lateral to the ovarian vessels to access the retroperitoneal space. Blunt dissection is then performed to identify the ureter on the medial leaf of the broad ligament. (Reproduced with permission from Thompson M, Kho K: Minimally invasive surgery. In Hoffman BL, Schorge JO, Bradshaw KD, et al (eds): Williams Gynecology, 3rd ed. New York, McGraw-Hill Education, 2016.)

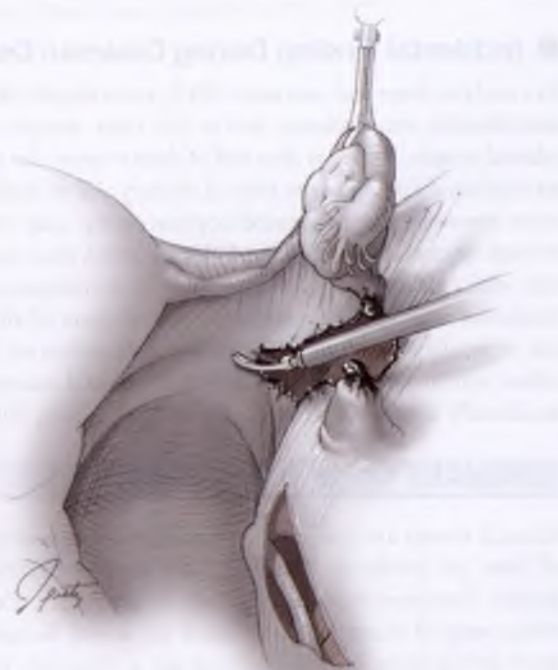

FIGURE 14-25 The infundibulopelvic ligament is transected by a vessel sealing device or by electrocoagulation followed by sharp division. (Reproduced with permission from Thompson M, Kho K: Minimally invasive surgery. In Hoffman BL, Schorge JO, Bradshaw KD, et al (eds): Williams Gynecology, 3rd ed. New York, McGraw-Hill Education, 2016.)

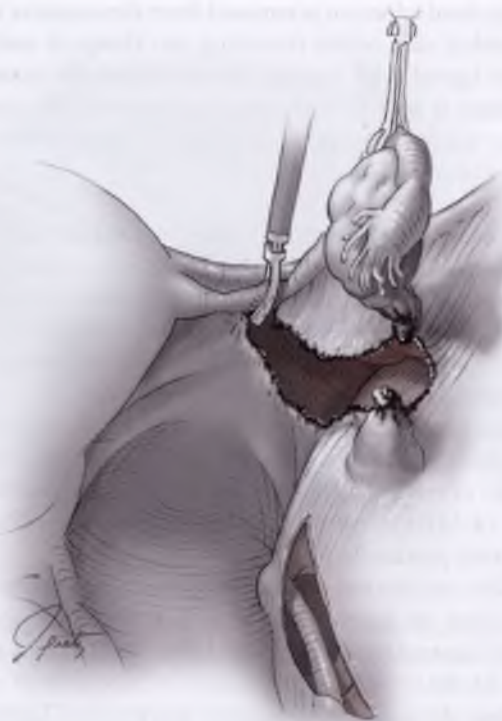


FIGURE 14-26 The uteroovarian ligament and fallopian tube are similarly transected. The adnexum is placed in a bag, removed through the trocar incision, and morcellated in the bag (if necessary). (Reproduced with permission from Thompson M, Kho K: Minimally invasive surgery. In Hoffman BL, Schorge JO, Bradshaw KD, et al (eds): *Williams Gynecology*, 3rd ed. New York, McGraw-Hill Education, 2016.)

■ Incidental Finding During Cesarean Delivery

In a study by Baser and associates (2013), more than 46,000 cesarean deliveries were reviewed, and in 151 cases, women also had adnexal surgery. For more than half of these women, the mass was an incidental finding at the time of delivery. All of these masses were removed. Five warranted oophorectomy, and 146 were excised by cystectomy. Final pathology showed three malignancies, with a mean size of 10.6 cm. Two of these malignancies were incidental findings. The authors support excision of all masses, but especially if larger than 5 cm. Although studies are limited, others similarly recommend removal of adnexal masses found incidentally at cesarean delivery (Dede, 2007; Ulker, 2010).

SUMMARY

Adnexal masses are commonly found during pregnancy. Many of these are incidental findings at the time of routine sonographic examination, especially early in pregnancy. Expectant versus surgical management is based on several factors. Foremost among these is the gestational age at discovery, the mass size, and its sonographic characteristics that may be cystic, solid, or complex. In many women, a mass found early in pregnancy will regress as pregnancy progresses. Surgical excision is mandatory with a symptomatic mass or with one that has characteristics suggestive of malignancy. In most cases, laparoscopic cystectomy is the preferred surgical method when feasible.

REFERENCES

- Abbas AM, Zahran KM, Nasr A, et al: A new scoring model for characterization of adnexal masses based on two-dimensional gray-scale and colour Doppler sonographic features. *Facts Views Vis Obgyn* 6(2):68, 2014
- Affleck DG, Handrahan DL, Egger MJ, et al: The laparoscopic management of appendicitis and cholelithiasis during pregnancy. *Am J Surg* 178(6):523, 1999
- Al-Fozan H, Tulandi T: Safety and risks of laparoscopy in pregnancy. *Curr Opin Obstet Gynecol* 14(4):375, 2002
- American College of Obstetricians and Gynecologists: Management of adnexal masses. Practice Bulletin No. 83, July 2007, Reaffirmed 2015a
- American College of Obstetricians and Gynecologists: Nonobstetric surgery during pregnancy. Committee Opinion No. 474, February 2011, Reaffirmed 2015b
- American Society for Reproductive Medicine: Pathogenesis, consequences, and control of peritoneal adhesions in gynecologic surgery: a committee opinion. *Fertil Steril* 99(6):1550, 2013
- Baser E, Erkilinc S, Esin S, et al: Adnexal masses encountered during cesarean delivery. *Int J Gynaecol Obstet* 123(2):124, 2013
- Bello G, Schonholz D, Mosipur J, et al: Combined pregnancy: the Mount Sinai experience. *Obstet Gynecol Surv* 41:603, 1986
- Bromley B, Benacerraf B: Adnexal masses during pregnancy: accuracy of sonographic diagnosis and outcome. *J Ultrasound Med* 16:447, 1997
- Caverly CE: Ovarian cysts complicating pregnancy. *Am J Obstet Gynecol* 21:566, 1931
- Chiang G, Levine D: Imaging of adnexal masses in pregnancy. *J Ultrasound Med* 23:805, 2004
- Condous G, Khalid A, Okaro E, et al: Should we be examining the ovaries in pregnancy? Prevalence and natural history of adnexal pathology detected at first trimester sonography. *Ultrasound Obstet Gynecol* 24:62, 2004
- Dede M, Yenen MC, Yilmaz A, et al: Treatment of incidental adnexal masses at cesarean section: a retrospective study. *Int J Gynecol Cancer* 17(2): 339, 2007
- Giuntoli RL II, Vang RS, Bristow RE: Evaluation and management of adnexal masses during pregnancy. *Clin Obstet Gynecol* 49(3):492, 2006
- Glanc P, Brofman N, Salem S, et al: The prevalence of incidental simple ovarian cysts > or = 3 cm detected by transvaginal sonography in early pregnancy. *J Obstet Gynaecol Can* 6:502, 2007
- Glanc P, Salem S, Farine D: Adnexal masses in the pregnant patient. A diagnostic and management challenge. *Ultrasound Q* 24:225, 2008
- Goh W, Bohrer J, Zalud I: Management of the adnexal mass in pregnancy. *Curr Opin Obstet Gynecol* 26:49, 2014
- Goh WA, Rincon M, Bohrer J, et al: Persistent ovarian masses and pregnancy outcomes. *J Matern Fetal Neonatal Med* 26:11, 2013
- Goldberg-Stein SA, Liu B, Hahn PF, et al: Radiation dose management: Part 2, estimating fetal radiation risk from CT during pregnancy. *AJR Am J Roentgenol* 198(4):W352, 2012
- Grimes WH, Bartholomew RA, Calvin ED, et al: Ovarian cysts complicating pregnancy. *Am J Obstet Gynecol* 68:594, 1954
- Hasson J, Tsafir Z, Azem F, et al: Comparison of adnexal torsion between pregnant and nonpregnant women. *Am J Obstet Gynecol* 202:536e1, 2010
- Hoffman BL, Corton MM: Surgeries for benign gynecologic conditions. In Hoffman BL, Schorge JO, Bradshaw KD, et al (eds): *Williams Gynecology*, 3rd ed. New York, McGraw-Hill Education, 2016.
- Hoover K, Jenkins TR: Evaluation and management of adnexal mass in pregnancy. *Am J Obstet Gynecol* 205:97, 2011
- Horowitz NS: Management of adnexal mass in pregnancy. *Clin Obstet Gynecol* 54:519, 2011
- Koo YJ, Kim TJ, Lee JE, et al: Risk of torsion and malignancy by adnexal mass size in pregnant women. *Acta Obstet Gynecol Scand* 90:358, 2011
- Lee G, Hur S, Shin J, et al: Elective vs. conservative management of ovarian tumors in pregnancy. *Int J Gynaecol Obstet* 85:250, 2004
- Leiserowitz GS, Xing G, Cress R, et al: Adnexal masses in pregnancy: how often are they malignant? *Gynecol Oncol* 101:315, 2006
- Malkasian GD, Knapp RC, Lavin PT, et al: Preoperative evaluation of serum CA125 levels in premenopausal and postmenopausal patients with pelvic masses. *Am J Obstet Gynecol* 159:341, 1988
- Marana R, Luciano AA, Muzii L, et al: Reproductive outcome after ovarian surgery: suturing versus nonsuturing of the ovarian cortex. *J Gynecol Surg* 7:155, 1991
- Mashiach S, Bider D, Moran O, et al: Adnexal torsion of hyperstimulated ovaries in pregnancies after gonadotropin therapy. *Fertil Steril* 53(1):76, 1990
- Mathevet P, Nessah K, Dargent D, et al: Laparoscopic management of adnexal masses in pregnancy: a case series. *Eur J Obstet Gynecol Reprod Biol* 108(2):217, 2003

- Mazze R, Kallen B: Reproductive outcome after anesthesia and operation during pregnancy: a Registry study of 5405 cases. *Am J Obstet Gynecol* 161:1178, 1989
- McGovern PG, Noah R, Koenigsberg R, et al: Adnexal torsion and pulmonary embolism: case report and review of the literature. *Obstet Gynecol Surv* 54(9):601, 1999
- McKerron RG: *Pregnancy, Labor, and Childbirth with Ovarian Tumors*. New York, Redman, 1906
- Naqvi M, Kaimal A: Adnexal masses in pregnancy. *Clin Obstet Gynecol* 58:93, 2015
- Ngu SF, Cheung VY, Pun TC: Surgical management of adnexal masses in pregnancy. *JLS* 18:71, 2014
- Oelsner G, Cohen SB, Soriano D, et al: Minimal surgery for the twisted ischaemic adnexa can preserve ovarian function. *Hum Reprod* 18(12):2599, 2003
- Okugawa K, Hirakawa T, Fukushima K, et al: Relationship between age, histological type, and size of ovarian tumors. *Int J Gynaecol Obstet* 74(1):45, 2001
- O'Rourke N, Kodali BS: Laparoscopic surgery during pregnancy. *Curr Opin Anaesthesiol* 19(3):254, 2006
- Palmer J, Vatish M, Tidy J: Epithelial ovarian cancer in pregnancy: a review of the literature. *BJOG* 116:480, 2009
- Patsner B: Promise and pitfalls of CA-125 in gynecology. *Am J Gynecol Health* 3:13, 1989
- Patton CL: Adnexal tumors in pregnancy. *Surg Gynecol Obstet* 3:413, 1906
- Pearl J, Price R, Richardson W, et al: Guidelines for diagnosis, treatment, and use of laparoscopy for surgical problems during pregnancy. *Surg Endosc* 25(11):3479, 2011
- Perkins KM, Boulet SL, Kissin DM, et al: Risk of ectopic pregnancy associated with assisted reproductive technology in the United States, 2001–2011. *Obstet Gynecol* 125(1):70, 2015
- Reedy MB, Kallen B, Kuehl TJ: Laparoscopy during pregnancy: a study of five fetal outcome parameters with use of the Swedish Health Registry. *Am J Obstet Gynecol* 177(3):673, 1997
- Sarandokou A, Protonatariou E, Rizos D: Tumor markers in biological fluids associated with pregnancy. *Crit Rev Clin Lab Sci* 109:221, 2007
- Seki K, Kikuchi Y, Uesato T, et al: Increased serum CA 125 levels during the first trimester of pregnancy. *Acta Obstet Gynecol Scand* 65:583, 1986
- Smith LH, Danielsen B, Allen ME, et al: Cancer associated with obstetric delivery: results of linkage with the California cancer registry. *Am J Obstet Gynecol* 189:1128, 2003
- Spencer HR: The Lettsomian Lectures on tumours complicating pregnancy, labour, and the puerperium: delivered before the Medical Society of London. *BMJ* 1(3086):246, 1920
- Thompson M, Kho K: Minimally invasive surgery. In Hoffman BL, Schorge JO, Bradshaw KD, et al (eds): *Williams Gynecology*, 3rd ed. New York, McGraw-Hill Education, 2016.
- Timmerman D, Ameye L, Fischerova D, et al: Simple ultrasound rules to distinguish between benign and malignant adnexal masses before surgery: prospective validation by IOTA group. *BMJ* 341:c6839, 2010
- Touitou Y, Bogdan A, Darbois Y: CA 125 (ovarian cancer associated antigen) in cancer and pregnancy. *Anticancer Res* 9:1805, 1989
- Ulker V, Gedikbasi A, Numanoglu C, et al: Incidental adnexal masses at cesarean section and review of the literature. *J Obstet Gynaecol Res* 36(3):502, 2010
- Upadhyay A, Stanten S, Kazantsev G, et al: Laparoscopic management of a nonobstetric emergency in the third trimester of pregnancy. *Surg Endosc* 21(8):1344, 2007
- Wheeler TC, Fleischer AC: Complex adnexal mass in pregnancy: predictive value of color Doppler sonography. *J Ultrasound Med* 16:425, 1997
- Whitecar P, Turner S, Higby K: Adnexal masses in pregnancy: a review of 130 cases undergoing surgical management. *Am J Obstet Gynecol* 181:19, 1999
- Wiskind AK, Toledo AA, Dudley AG, et al: Adhesion formation after ovarian wound repair in New Zealand White rabbits: a comparison of ovarian microsurgical closure with ovarian non-closure. *Am J Obstet Gynecol* 163:1674, 1990
- Yacobozzi M, Nguyen D, Rakita D: Adnexal masses in pregnancy. *Semin Ultrasound CT MRI* 33:55, 2012
- Yazbek J, Salim R, Woelfer B, et al: The value of ultrasound visualization of the ovaries during the routine 11–14 weeks nuchal translucency scan. *Eur J Obstet Gynecol* 132:154, 2007
- Yazigi R, Sandstad J, Munoz AK: Primary staging in ovarian tumors of low malignant potential. *Gynecol Oncol* 31:402, 1988
- Yen CF, Lin SL, Murk W, et al: Risk analysis of torsion and malignancy for adnexal masses during pregnancy. *Fertil Steril* 91:1895, 2009
- Yuen PM, Ng PS, Leung PL, et al: Outcome in laparoscopic management of persistent adnexal mass during the second trimester of pregnancy. *Surg Endosc* 18(9):1354, 2004
- Zanetta G, Mariani E, Lissoni A, et al: A prospective study of the role of ultrasound in the management of adnexal masses in pregnancy. *BJOG* 110:578, 2003
- Zweizig S, Perron J, Grubb D, et al: Conservative management of adnexal torsion. *Am J Obstet Gynecol* 168(6 Pt 1):1791, 1993

CHAPTER 15

Diagnostic and Operative Laparoscopy

CONSIDERATIONS	240
ADVANTAGES	242
INDICATIONS	242
RESTRICTIONS	243
PATIENT PREPARATION	246
EQUIPMENT	247
INTRAOPERATIVE STEPS	248
SPECIFIC PROCEDURES	255
POSTOPERATIVE MANAGEMENT	256
COMPLICATIONS	256
SUMMARY	257

The first laparoscopies in pregnancy were performed in the early 1990s. Since then, laparoscopy has been widely adopted as an alternative to laparotomy for the diagnosis and treatment of surgical conditions arising in pregnancy. Accordingly, surgeons should be aware of the distinct physiologic changes during gestation that may require technique modification. With these adjustments, gravidas can benefit from advantages of laparoscopy similar to those experienced by nonpregnant patients.

CONSIDERATIONS

Laparoscopy was previously considered contraindicated during pregnancy because of concerns regarding its cardiopulmonary

impairment and potential trauma to the fetus and gravid uterus. However, surgeons knowledgeable of these consequences can often minimize or avoid their effect.

■ Cardiopulmonary Effects

Laparoscopy produces distinct cardiovascular and pulmonary changes, which may be particularly important for a gravida. These include: (1) absorption of carbon dioxide (CO₂) across the peritoneum and into circulation, (2) increased intraabdominal pressure generated by the pneumoperitoneum, and (3) Trendelenburg positioning (Table 15-1). These changes may be exacerbated in pregnancy due to maternal physiologic changes and the gravid uterus.

First, laparoscopy requires abdominal wall elevation, and this is usually achieved by instilling gas into the abdominal cavity. In most cases, CO₂ is selected to create this pneumoperitoneum and offers the advantages of low combustibility and rapid absorption. However, absorption of this gas across the peritoneum and into blood can lead to systemic CO₂ accumulation and hypercarbia. In turn, hypercarbia produces sympathetic stimulation that raises systemic and pulmonary vascular resistance and increases blood pressure. Moreover, if hypercarbia is not cleared by compensatory ventilation, acidemia develops. From this, direct myocardial contractility depression and decreased cardiac output can follow (Ho, 1995; Reynolds, 2003; Sharma, 1996). Hypercarbia can also lead to tachycardia and arrhythmia. Fortunately, the effects of CO₂ are typically compensated by controlled ventilation by anesthesia staff.

Second, insufflation of any gas elevates intraabdominal pressure. Pneumoperitoneum pressures above 10 mm Hg have consistently led to a 25- to 35-percent reduction in cardiac output regardless of patient positioning (Johannsen, 1989; Torrielli, 1990). This decline is attributable to pressure-mediated pooling of blood in the lower extremities, consequent decreased venous return, and a compensatory increase in systemic vascular resistance. Diminished venous return and cardiac output can lower uteroplacental perfusion, which may have fetal effects.

TABLE 15-1. Physiologic Effects of CO₂ Insufflation of the Peritoneal Cavity

System	Effects ^a	Mechanisms	Possible Maternal-Fetal Effects
Respiratory	Pco ₂ increases, pH decreases	CO ₂ absorption	Hypercarbia, acidosis
Cardiovascular	Increased—heart rate; systemic vascular resistance; pulmonary, central venous, and mean arterial pressures	Hypercarbia and increased intraabdominal pressure	Uteroplacental hypoperfusion—possible fetal hypoxia, acidosis, and hypoperfusion ^b
	Decreased—cardiac output	Decreased venous return	
Blood Flow	Decreased splanchnic flow with hypoperfusion of liver, kidneys, and gastrointestinal organs	Increased intraabdominal pressure	As above
	Decreased venous return from lower extremities	Increased intraabdominal pressure	As above
	Increased cerebral blood flow	Hypercarbia possibly from shunting due to splanchnic tamponade	Increased CSF pressure ^b

^aEffects intensified when insufflation pressure >20 mm Hg in baboons (Reedy, 1995).

^bData primarily from animal studies.

CO₂ = carbon dioxide; CSF = cerebrospinal fluid; Pco₂ = partial pressure of CO₂.

Reproduced with permission from Cunningham FG, Leveno KL, Bloom SL, et al (eds): General considerations and maternal evaluation. In Williams Obstetrics, 24th ed. New York, McGraw-Hill Education, 2014. Data from O'Rourke, 2006; Reynolds, 2003.

In pregnancy, this can be partially compensated by using low insufflation pressures and a maternal left-lateral tilt (p. 248). Of other concerns, a distention pressure of 20 mm Hg reduces renal blood flow, glomerular filtration rate, mesenteric arterial flow, and intestinal mucosal blood flow (Diebel, 1992; Richards, 1983). These hemodynamic changes may hold more significance for those with impaired cardiac function, anemia, or hypovolemia. This may be particularly relevant for acute indications associated with significant bleeding.

Last, the diaphragm is displaced upward by intraabdominal pressure from the pneumoperitoneum. This is accentuated by organs also being pushed cephalad against the diaphragm by the gravid uterus and by Trendelenburg positioning. Moreover, insufflation pressures stiffen the diaphragm and chest wall. Together, these alterations lead to higher required airway pressures to achieve adequate mechanical ventilation. Also, as the diaphragm moves up, lung volume and functional residual capacity are diminished, which in turn reduces the reserve volume for oxygenation. Remember that in pregnancy, functional residual capacity also normally declines. Lower lung volume also favors a tendency for the lung to collapse and to develop atelectasis. This can create ventilation and perfusion mismatching and an increased alveolar-arterial oxygen gradient. Together, all of these factors favor poorer oxygenation.

Despite these physiologic changes, absolute contraindications to pneumoperitoneum are few. These include increased intracranial pressure, acute angle glaucoma, and retinal detachment.

Gasless Laparoscopy

Some of the physiologic limitations of laparoscopy can be mitigated in part by laparoscopic surgery performed without

pneumoperitoneum, that is, gasless laparoscopy. With this technique, the abdominal wall is mechanically elevated by fan-blade-like wings. These blades are fanned out once inside the abdomen, are applied against the inner anterior abdominal peritoneum, and are elevated by a mechanical lift. Although infrequently used, gasless laparoscopy may have benefits for the gravida. It eliminates concerns regarding CO₂ exposure and pressure-related vascular changes and permits the use of regional anesthesia for pelvic procedures (Pelosi, 1997a). Moreover, because intraperitoneal gas retention is not required during surgery, instruments may be inserted without cannulas. This results in smaller abdominal wall incisions.

Of drawbacks, gasless laparoscopy often provides only limited exposure in morbidly obese women. Also, without the pressure created by a pneumoperitoneum, venous oozing at surgical sites may be increased. Last, because this approach is not widely used, necessary equipment is frequently not available. Overall, the reported use of gasless laparoscopy in pregnancy is limited (Sesti, 2013).

■ Laparoscopic Trauma

In pregnancy, possible iatrogenic uterine trauma is a concern, and this restricts use of some laparoscopic entry and uterine manipulation techniques. During laparoscopic entry, the uterus may be inadvertently punctured or lacerated, particularly when ports are not placed sufficiently cephalad. Perforation of the gravid uterus can result in miscarriage or premature rupture of membranes, although healthy live pregnancies have been reported (Joumblat, 2012; Kho, 2009). To safely gain abdominal entry, suitable techniques are described on page 248.

In late pregnancy, the enlarged uterus may obscure viewing of the pelvic sidewalls and limit exposure in the pelvis and lower

abdomen. A large uterus may also hinder needed instrument mobility. In nonpregnant women, traditional intrauterine manipulators are used to overcome these constraints. However, these enter the uterine cavity and thus are contraindicated for pregnancy. Alternative methods are offered on page 254.

ADVANTAGES

Intraoperatively, laparoscopy provides the surgeon with a panoramic view of the pelvis and upper abdomen to evaluate intraabdominal pathology. Technical advantages include optical magnification, enhanced illumination, and improved viewing of deep structures. In addition, the smaller size of laparoscopic instrumentation and the magnified view aid delicate and precise dissection.

Postoperatively, laparoscopy offers several advantages that stem mainly from the smaller abdominal wall incisions. Compared with laparotomy, these benefits include shorter hospital stays, lower postoperative ileus rates, fewer wound complications, and faster activity resumption (Nieboer, 2009; Pearl, 2011). Diminished postoperative pain also reduces narcotic demands. Less narcotic depression and smaller incisions improve postoperative pulmonary function. For obese patients, who traditionally have demonstrated a high frequency of wound complications, the prospect of avoiding laparotomy carries proven benefit. In addition to these immediate benefits, randomized, prospective animal and human studies show decreased adhesion formation with laparoscopic surgery (Luciano, 1989; Lundorff, 1991).

INDICATIONS

■ Appendicitis

In experienced hands, laparoscopy can be used to concomitantly diagnose and treat many acute abdominal conditions. In two large institutional reviews, the frequency of intraabdominal surgery in pregnancy for nonobstetric indications approximated 0.2 percent (Allen, 1989; Kort, 1993). In these studies, the most frequent indications were appendicitis, adnexal mass, and cholecystitis.

Of these, acute appendicitis complicated 1 in every 500 to 2000 pregnancies and is the most common indication for laparoscopy in gravidas (Andersen, 1999; Burke, 2015; Mourad, 2000). In studies of nonpregnant women, several randomized trials show lower rates of wound infections, less postoperative pain, and shorter hospital stay with minimally invasive surgery (MIS) compared with laparotomy. Despite these advantages, laparoscopic appendectomy is associated with a higher rate of intraabdominal abscess, longer operative times, and greater hospital charges (Sauerland, 2010). However, in cases in which the diagnosis is less clear but appendicitis is suspected, laparoscopy offers an opportunity to view the entire abdominal cavity for alternative pathology. This compares with the limited view through a typical minilaparotomy incision. This benefit may be especially true if the appendix appears grossly normal.

Notably, the risk of miscarriage may be increased with laparoscopy. One metaanalysis of 11 studies of laparoscopic appendectomy in pregnancy demonstrated an increased relative risk

(1.91) for miscarriage following MIS compared with laparotomy to remove the appendix (Wilasrusmee, 2012). Operative times, wound infection rates, preterm delivery rates, ultimate birthweights, and Apgar scores did not differ between the surgery routes. Most procedures were performed in the second trimester, although the range of gestational ages was broad. Notably, this study was criticized for not controlling for confounders such as patient age, fetal gestational age, and complications of appendicitis. Authors of a more recent systematic review indicate that the level of evidence is not strong enough to demonstrate a preferred approach to appendectomy. They concede that laparoscopy may be associated with a higher risk of miscarriage (Walker, 2014).

■ Cholecystitis

Gallstones often develop in pregnancy because of the increased cholesterol saturation of bile and decreased gallbladder motility, which leads to stasis. Acute cholecystitis secondary to stones is also common and is the second most frequent indication for nonobstetric surgery during pregnancy.

Currently, the decision to proceed with surgical treatment of acute cholecystitis is based on the same criteria used for nonpregnant women. In the past, most favored medical therapy. However, the recurrence rate during the same pregnancy is high, and affected women ultimately require cholecystectomy for persistent symptoms. Moreover, if cholecystitis recurs later in gestation, preterm labor is more likely and cholecystectomy is technically more difficult. Date and coworkers (2008) reviewed the literature and found no increased risk of preterm birth or fetal demise for operative compared with conservative management. There was, however, a significantly higher rate of fetal death from gallstone pancreatitis when women were managed conservatively. Thus, most surgeons advocate cholecystectomy upon initial admission for acute cholecystitis due to the high risk of recurrence with conservative management and the overall safety of the procedure.

There should be no reluctance to perform cholecystectomy via laparoscopy for a gravida. This is supported by a large body of evidence regarding the safety and efficacy of laparoscopic cholecystectomy in pregnancy and during any trimester (Eichenberg, 1996; Geburz, 1997; Tarraza, 1997). In an analysis of a large surgical database, laparoscopic cholecystectomy resulted in shorter operative times and lengths of stay and fewer minor complications compared with laparotomy (Cox, 2016). Furthermore, another large database analysis demonstrates that surgeons with high surgical volumes have significantly fewer maternal and fetal complications compared with low-volume surgeons (Kuy, 2009). In sum, the Society of American Gastrointestinal and Endoscopic Surgeons (SAGES) endorses laparoscopy as the preferred route for cholecystectomy in pregnant patients in any trimester (Pearl, 2011).

■ Adnexal Torsion

One source of acute pain in pregnancy is torsion of the fallopian tube and ovary. In gravidas, the adnexa may twist with greater frequency. Suggested reasons include the increased laxity of the supportive tissues of the ovaries and fallopian tubes, increased

ovarian volume attributable to the corpus luteum, and uterine growth, which can elevate the adnexa from the pelvis.

As discussed and illustrated in Chapter 14 (p. 225), laparoscopy is effective in both the diagnosis and treatment of torsion. For laparoscopy and laparotomy, several series document the safety and efficacy of detorsion and intraoperative observation for reperfusion. This is then followed by cystectomy, adnexectomy, or no further treatment. The decision to retain or excise the affected adnexum are based on the presence of infarction or suspected ovarian pathology (Bider, 1991; Mage, 1989; Morice, 1997). Importantly, if the corpus luteum is excised in the first 10 weeks of pregnancy, exogenous progesterone should be supplemented, and regimens are outlined in Chapter 18 (p. 303) (Csapo, 1973).

■ Adnexal Masses

These are discovered in approximately 1 to 2 percent of all pregnancies (Leiserowitz, 2006). Most masses are diagnosed during routine first-trimester sonographic examination. Most are benign simple cysts, which resolve by the second trimester. However, indications for surgery during pregnancy include malignant-appearing features seen with imaging or acute symptoms. Acute findings may include intraabdominal bleeding from cyst rupture or pain from torsion or from mass effect. A full discussion of adnexal mass management is provided in Chapter 14 (p. 230). In cases requiring surgery, numerous case reports and series attest to the feasibility and effectiveness of laparoscopic treatment of adnexal masses in pregnancy (Koo, 2012; Parker, 1996; Pelosi, 1997a; Soriano, 1999).

■ Heterotopic Pregnancy

From Duverney's first report in 1708 through the early 1970s, the spontaneous occurrence of combined intrauterine and tubal gestation had an incidence of 1 in 30,000 pregnancies. With the advent of assisted reproductive technology (ART), treated patients carry a heterotopic gestation risk of 0.09 percent (Perkins, 2015). With early intervention, up to 70 percent of intrauterine gestations have been salvaged (Rojansky, 1996).

Patients may present with pain, and sonography demonstrates an intrauterine pregnancy (IUP) concurrent with a complex adnexal mass or free fluid in the pelvis. Such rupture at presentation is not infrequent, particularly because misdiagnosis is common. In these cases, timely surgical management is critical to avoid hemorrhagic shock.

Ideally, heterotopic gestations are diagnosed early and prior to tubal pregnancy rupture. In such cases, conservative medical treatment of the ectopic pregnancy, however, is not an option. This is because of methotrexate's teratogenicity to the IUP.

With surgical treatment of the ectopic tubal pregnancy, goals include hemodynamic support of the patient, removal of all ectopic trophoblastic tissue, repair or excision of the damaged tube, and preservation of fertility and of the IUP in those so desiring. For most women, laparoscopic salpingectomy may be preferred as it is definitive and diminishes the risk of reoperation. This may be especially the case because monitoring for persistent trophoblastic tissue is indeterminate due to human

chorionic gonadotropin contributions from the IUP. The surgical steps for laparoscopic salpingectomy are found in Chapter 8 (p. 118). Notably, for women with ruptured ectopic pregnancies who are hemodynamically unstable or in those with contraindications to laparoscopy, laparotomy offers fast entry into the abdomen for control of bleeding.

■ Transabdominal Cervicoisthmic Cerclage

As described in Chapter 11 (p. 174), permanent transabdominal cerclage may be placed for women who are not suitable candidates for transvaginal cerclage. Such patients may have an amputated or scarred cervix or have undergone a prior transvaginal cerclage operation that failed to maintain the pregnancy. Transabdominal cerclage can be placed laparoscopically and ideally before conception. During pregnancy, placement becomes increasingly difficult as the uterus grows. Therefore, cerclage is best placed before pregnancy or at 11 to 14 weeks' gestation. This gestational age allows for the higher miscarriage rates seen earlier in the first trimester. It also permits initial screening for aneuploidy and obvious malformation (Rand, 2003).

■ Fetal Surgery

As discussed in Chapter 16 (p. 260), a growing body of research demonstrates promising outcomes using intrauterine endoscopy for specific fetal conditions. Termed *fetoscopy*, indications for the surgical treatment of severe anomalies continues to grow (Peiro, 2009). More common procedures include endoscopic ablation of aberrant vessels in twin-twin transfusion syndrome, with vasa previa, or in twin reversed arterial perfusion (TRAP) sequence. Another indication is endoscopic release of strangulating amnion strands in amniotic band syndrome. Of reconstructive surgeries, some centers are completing antenatal spina bifida closures laparoscopically. Yet, despite the intuitive fetal benefits of fetoscopic surgery, preterm labor and preterm rupture of membranes remain persistent risks (Danzer, 2003; Sala, 2014).

RESTRICTIONS

■ General Considerations

Limits to laparoscopic surgery can stem from characteristics of the given pathology, from surgeon skill or facility barriers, or from maternal comorbidities. Of pathology considerations, prolonged operations are avoided to minimize the exposure of both mother and fetus to anesthesia and pneumoperitoneum. Specifically, large masses or dense adhesions may obscure viewing, hinder access, increase collateral organ injury risks, and lengthen surgeries. In addition, large solid masses or cysts suspicious for cancer may be difficult to extirpate intact without significantly enlarging initial laparoscopy incisions. Diagnostic laparoscopy also may reveal a condition best approached by laparotomy. One example is unsuspected malignancy that requires surgical staging.

Of facility limitations, appropriate laparoscopic tools may not be available. Moreover, unforeseen equipment malfunction or surgical complications can develop that warrant conversion

to laparotomy. In certain situations, a multidisciplinary team of anesthesiologists, obstetricians, pediatricians, and nursing staff may be needed to optimize maternal and fetal outcomes. If these requisites are not available, then the benefits of laparoscopy are weighed against those provided by laparotomy.

■ Maternal Comorbidities

Uterine Size

Maternal characteristics can often limit or complicate laparoscopic surgery. Of these, uterine size may pose a prominent obstacle by restricting visualization and limiting access and organ manipulation. Moreover, a large uterus can aggravate some of the cardiopulmonary changes described on page 240.

Obesity

In the past, obesity was considered a relative contraindication for laparoscopy. However, in more recent studies, healthy obese women experienced less pain, quicker recovery, and fewer postoperative complications, such as wound infections and postoperative ileus, after laparoscopy compared with laparotomy (Eltabbakh, 1999; Scribner, 2002). That said, some outcomes may be adversely affected in obese women undergoing laparoscopy compared with normal-weight patients. Of these, higher conversion rates to laparotomy, longer operating times, and longer hospitalizations have been noted (Chopin, 2009; Heinberg, 2004; Thomas, 2006). However, this has not been found by all investigators, and overall outcomes may be superior to laparotomy (Camanni, 2010; O'Hanlan, 2003; Shah, 2015).

Certain operative parameters are altered in obese women undergoing laparoscopy. First, adequate ventilation may be difficult. In general, obese patients display reduced lung compliance that is proportional to their body mass index. Moreover, abdominal wall adiposity lowers abdominal wall compliance, which in turn elevates the pneumoperitoneum pressure required for adequate surgical space. Also, fatter omentum and mesenteric fat add to the bulk forced against the diaphragm in Trendelenburg position. As a result, increases in inspiratory resistance and decreased pulmonary compliance should be anticipated.

To assess a patient's tolerance of these physiologic changes, a "tilt test" can be performed prior to initiation of the procedure. Following induction of general anesthesia, the patient is slowly placed into steep Trendelenburg, and cardiopulmonary parameters are briefly observed. Testing the patient's tolerance of this position may help anticipate difficulties with airway and cardiopulmonary management, even prior to abdominal insufflation.

With morbid obesity, another surgical challenge is the anatomic distortion of the abdominal wall. In obese patients, the umbilicus remains the thinnest portion of the anterior abdominal wall and allows optimal access to the abdomen. But in these patients, anatomic landmarks can be displaced caudally and may hinder normal laparoscopic access. For this reason, the position of the umbilicus relative to underlying structures is assessed, and accommodation for deviation is made to ensure safe laparoscopic entry (Hurd, 1991; Pelosi, 1998). In addition, an open technique for laparoscopic access may be considered in cases with advanced gestational age. Access at a subxiphoid site or in the left or right upper quadrants can also be employed.

Obese patients have a higher risk of postoperative hernia development at former port sites. This rate may be higher in cases in which extensive traction is placed on the ports. Preventively, fascial closure of port sites is considered and strongly recommended in sites measuring 10 mm or greater.

Prior Abdominopelvic Surgery

Previous abdominal or pelvic surgery is a well-known risk factor for intraperitoneal adhesions. During abdominal entry with laparoscopy, adhesive disease increases the risk of visceral and vascular injury. Adhesions are also associated with higher conversion rates to laparotomy because tedious adhesiolysis may be completed by some surgeons more safely and expeditiously with open surgical dissection. Thus, careful questioning regarding prior perioperative infection, hematoma, or extensive adhesiolysis can provide meaningful information before a planned procedure. Similarly, a history of endometriosis, pelvic inflammatory disease, or radiation treatment may predispose to adhesions.

During preoperative physical examination, a surgeon notes the location of previous surgical scars. In addition, abdominal wall hernias, hernia repairs, and reparative mesh are identified and avoided during trocar insertion. If concerns for abdominal adhesive disease arise, plans for entry at a site other than the umbilicus are considered to avoid organ injury.

■ Surgery Timing

Urgently indicated surgery should proceed regardless of fetal gestational age (Table 15-2). Purely elective surgery should be delayed until after pregnancy. If surgery in pregnancy can be timed, intraabdominal surgery is optimally completed early in the second trimester. Postponing surgery to the second trimester avoids exposure to potential teratogens during organogenesis, preterm contractions, and the higher incidence of spontaneous abortion normally seen during the first trimester. Moreover, many women undergo first-trimester screening with serum analytes, nuchal translucency, and/or free fetal-DNA evaluation to identify fetal anomalies. Early second-trimester surgery also lowers the risk for preterm labor, which is seen more commonly with late second- or third-trimester surgery. Finally, operative field exposure is not yet compromised by encroachment of the gravid uterus into the mid- and upper abdomen (Fig. 15-1).

■ Fetal Considerations

Anesthetic Risk

The intraabdominal process requiring surgery often represents a real risk to the well-being of the patient and her fetus. In early studies, however, general anesthesia used for operations in the first trimester was implicated in subsequent spontaneous abortion. Notably, these investigations failed to control for the effects of the intraabdominal process itself or for its severity (Knill-Jones, 1975). Subsequently, no strong evidence supports higher miscarriage rates in women exposed to anesthetics (Cohen-Kerem, 2005). Furthermore, in their literature review, the American College of Obstetricians and Gynecologists (2015) states that no currently used anesthetic agents are teratogenic when used in standard dosages at any gestational age.

TABLE 15-2. Some Guidelines for the Performance of Laparoscopic Surgery in Pregnancy**Preoperative Considerations**

Surgical approach	Laparoscopic treatment of acute abdominal processes has the same indications in pregnant and nonpregnant patients
Pregnancy trimester	Laparoscopy can be safely performed during any trimester of pregnancy, but if able, ideally in 2nd trimester

Intraoperative Care

Patient positioning	Gravidas are placed in the left lateral recumbent position to minimize compression of the vena cava and the aorta
Initial port placement	Initial access can be safely accomplished with open (Hasson), Veress needle, or optical trocar technique if the location is adjusted according to fundal height, prior incisions, and surgeon experience
Insufflation pressure	CO ₂ insufflation of 10–15 mm Hg can be safely used for laparoscopy in pregnancy. Intraabdominal pressure is maintained at the minimum level sufficient to allow adequate visualization
CO ₂ monitoring	Intraoperative CO ₂ monitoring by capnography is used during laparoscopy in pregnancy
VTE prophylaxis	Intraoperative and postoperative pneumatic compression devices and early postoperative ambulation are recommended for deep-vein thrombosis prophylaxis in pregnancy

Perioperative Care

Fetal heart monitoring	Fetal heart rate is monitored pre- and postoperatively in the setting of urgent abdominal surgery during pregnancy
Obstetric consultation	Obstetric consultation can be obtained pre- and/or postoperatively based on the acuity of the patient's disease, gestational age, and consultant availability. For viable pregnancies, obstetric consultation includes discussion of what fetal indications would prompt intraoperative delivery
Tocolytics	Tocolytics are not used prophylactically but may be considered perioperatively, in coordination with obstetric consultation, when signs of preterm labor are present

CO₂ = carbon dioxide; VTE = venous thromboembolism.

Data from Pearl, 2011.

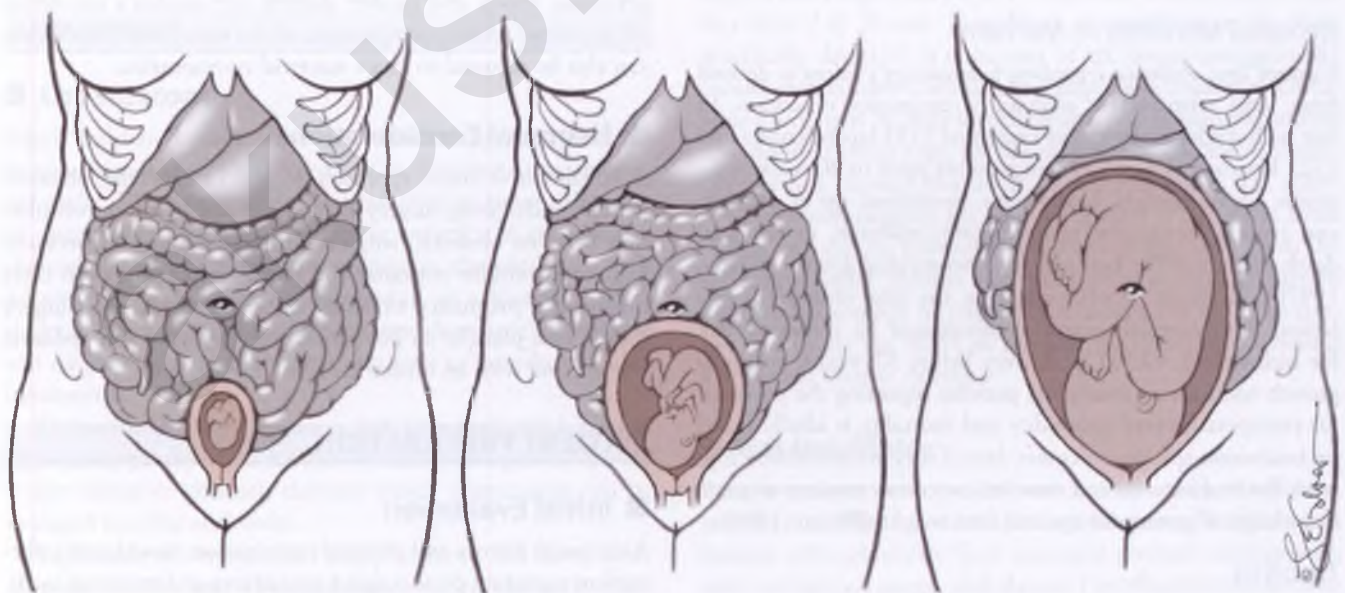


FIGURE 15-1 With increasing gestational age and uterine growth, intraabdominal organs are moved cephalad. Importantly, uterine growth must be considered for safe laparoscopic trocar placement. Changing anatomy will also alter the clinical presentation of many conditions. One example is appendicitis.

Fetal Physiologic or Teratogenic Risks

The immediate and delayed fetal effects of the CO₂ pneumoperitoneum continue to be a concern. Particular worries include diminished uterine blood flow due to pelvic vascular compression, changes in maternal hemodynamics, and transperitoneal CO₂ absorption. However, in pregnant baboons, no changes in Doppler blood flow to the fetus are found with pneumoperitoneum pressures of 20 mm Hg (Reedy, 1995). In one study of gravid ewes, an intraabdominal pressure of 20 mm Hg led to diminished maternal placental blood flow but no change in fetal lamb placental perfusion, fetal organ blood flow, blood pH, or blood gas values (Barnard, 1995). In another study, pregnant ewes were insufflated to a pneumoperitoneum pressure of 15 mm Hg. The fetal lamb had transient hypotension and tachycardia. These changes were minimized by inducing maternal respiratory alkalosis via hyperventilation (Hunter, 1995). All these data should be kept in context. Namely, pneumoperitoneum pressures of 20 mm Hg, especially in smaller animals, may not reflect actual changes that develop during most laparoscopies in humans.

In humans, insufflation pressures are generally maintained at 12 to 15 mm Hg or at the minimum pressure required for adequate viewing and instrument manipulation. Prospective randomized studies are lacking, and thus our understanding of the relative risks and benefits of laparoscopy during pregnancy are limited to case series, retrospective analyses of registry data, and a few metaanalyses. This growing body of literature regarding CO₂ pneumoperitoneum in pregnancy does not reflect a teratogenic or otherwise detrimental effect of CO₂ on human newborns. Further, investigators that followed a small cohort of children to up to age 8 years found no evidence of growth or developmental delays (Rizzo, 2003). As a pneumoperitoneum alternative, gasless laparoscopy avoids these concerns and is described on page 241.

Neonatal Morbidity or Mortality

Current best evidence regarding laparoscopy's safety is derived from large retrospective analyses of pregnancy outcomes. In one such study, investigators examined 2181 laparoscopies and 1522 laparotomies in pregnant patients prior to 20 weeks' gestation. Encouragingly, birthweight, gestational age at delivery, and rates of congenital malformation, stillbirth, or neonatal death did not differ between the two surgical groups (Reedy, 1997b). However, in comparison to the total obstetric population, both surgical groups demonstrated an increased risk for birthweight <2500 g, delivery before 37 weeks, and fetal growth restriction. Counseling patients regarding the potential for perioperative fetal morbidity and mortality is ideally based on institution-specific outcomes data, if they are available. Prognosis for fetal survival and neonatal outcomes requires accurate knowledge of gestational age and fetal weight (Phelan, 1990).

Tocolysis

In gravidas undergoing laparoscopy, no data from randomized studies currently support the routine use of prophylactic tocolysis for the prevention of preterm labor. Additionally, routine prophylactic-dose glucocorticoids are not recommended to hasten fetal lung maturity. However, these may be considered

and used as indicated in response to preterm labor that may complicate laparoscopic surgery. In such circumstances, rare contraindications to their use would be sepsis or active systemic infection.

Fetal Monitoring

Fetal heart rate should be identified and documented before and after surgery. In a pregnancy that has not yet reached a viable age, this may be performed using a handheld Doppler device. In even earlier pregnancies, targeted bedside sonography may be needed to document the heartbeat. For fetuses that have attained a viable age, both fetal heart rate and uterine activity are electronically monitored preoperatively and postoperatively. For intraoperative fetal monitoring, the American College of Obstetricians and Gynecologists (2015) states that this should be individualized. It may aid "maternal positioning and cardiorespiratory management, and may influence the decision to deliver the fetus."

In general, intraoperative fetal monitoring may be considered if the fetus is a viable age and if the woman has consented to emergency cesarean delivery. Moreover, an obstetrician must be available and willing to intervene for fetal indications, and the index surgery must permit safe emergency delivery. If fetal monitoring is implemented during surgery, a Doppler device or sonographic transducer can be placed directly against the patient's anterior abdominal wall. Alternatively, a transvaginal transducer may be placed. This method avoids encroachment on the surgical field.

In response to general anesthesia, fetal heart rate pattern typically shows reduced variability. The fetal heart rate baseline also may be lower but still lies within normal range. If changes suggest jeopardized fetal well-being, then uteroplacental perfusion can be augmented. Steps include releasing the pneumoperitoneum to diminish intraabdominal pressure against perfusing vessels and further shifting the mother's left-lateral tilt to relieve uterine compression of the vena cava. Ventilation can also be adjusted to favor maternal normocarbida.

Neonatal Considerations

A collaborative team approach to the care of the obstetric patient undergoing surgery is essential and involves consultation between obstetric, surgical, anesthesiology, and neonatal teams to optimize maternal and newborn outcomes. In cases involving a pregnancy that has reached a viable age, surgery should take place in an institution with neonatal and pediatric services and with an obstetric team.

PATIENT PREPARATION

Initial Evaluation

A thorough history and physical examination should seek information regarding prior surgical procedures and maternal medical complications such as cardiac disease, pulmonary disorders, obesity, and diabetes mellitus. Pertinent laboratory testing is done, and results are compared with values anticipated during pregnancy. Preoperative sonographic assessment for fetal viability, gestational age, and lethal anomalies is prudent. In

pregnancies of viable age, sonography also adds information regarding fetal position and placental location should delivery be indicated. Gentle cervical examination provides baseline status of dilatation and effacement. This is especially valuable if postoperative contractions ensue. Vaginal bleeding, if present, mandates a thorough evaluation for its source, including placental localization to exclude placenta previa or abruption.

■ Consenting

During the consenting process for laparoscopy, a surgeon reviews goals and risks of the specific procedure. Laparoscopy itself is typically associated with few complications. Of these, organ injury caused by puncture or by electrosurgical tools is the most common major complication and is discussed on page 256. Patients are also counseled regarding a possible need to complete the operation via laparotomy. Reasons for conversion include failure to gain abdominal access, organ injury during entry, or extensive adhesions.

■ Thromboprophylaxis

External pneumatic compression stockings are routinely applied to the lower extremities to reduce venous pooling and to augment return venous flow. However, no randomized trials address unfractionated or low-molecular-weight heparin use or placement of intermittent pneumatic compression devices in pregnancy to prevent venous thromboembolism. SAGES recommends placement of pneumatic compression devices around the lower extremities (Pearl, 2011). In general, the American College of Chest Physicians recommends pharmacologic thromboprophylaxis in laparoscopic procedures anticipated to last longer than 45 minutes but mechanical thromboprophylaxis for shorter cases (Guyatt, 2012).

EQUIPMENT

■ Laparoscope

Rigid, rod-lens laparoscopes have traditionally been used for diagnostic and operative procedures to illuminate the abdominal cavity. These laparoscopes are classified as either diagnostic or operative based on the absence or presence of an operative channel. Diagnostic laparoscopes range in diameter from 2 to 12 mm and possess either a 0-degree or an angled lens. Most surgeons use a 5- to 10-mm laparoscope diagnostic laparoscope and employ separate abdominal port sites to introduce needed instruments.

Operative laparoscopes are a less frequently used option. These are typically 10 to 12 mm in caliber and possess a 3- to 5-mm operative channel, through which instruments can be threaded into the abdomen.

Laparoscopes vary in their angle of view. The most common are 0-, 30-, and 45-degree laparoscopes, and each offers a different view of the peritoneal cavity. A 0-degree endoscope offers a forward view and is preferred by most surgeons. In contrast, angled-view endoscopes provide a lateral and larger field of view. These are useful during cases with more complicated pathology that may obstruct a traditional forward view.

More recently, flexible-tip laparoscopes with articulating, bendable tips have been employed and are frequently selected for single-port surgical procedures. These laparoscopes contain a camera chip at their distal tip. This allows the laparoscope to bend around structures and provide angled views that range from 0 to 120 degrees. Such flexible laparoscopes or rigid angled-view laparoscopes, in particular, may aid visualization during laparoscopies in pregnant women. Namely, if a gravid uterus fills much of the pelvis and the ability to manipulate it is limited, then these alternative viewing angles can permit better inspection around the uterus.

Laparoscopic lighting originates from a light source, travels through a light cable, and finally is transmitted through the laparoscope. Currently, a cold light source is used and provides a more intense beam. The term “cold light” describes the dissipation of heat along the length of the cable. Cold light sources use halogen, xenon, or halide. Despite heat dissipation, the light source still creates a hot tip at the laparoscope’s distal end. Thus, prolonged exposure of the tip to surgical drapes, patient skin, or internal organs is avoided. Thermal injuries have resulted from such exposure. Fiberoptic cables that attach to the laparoscope deliver the light. Significant heat capable of igniting drapes and producing burns is released at the distal end of the cable. Thus, the “off” or “standby” settings are used when the light cable is not attached to the laparoscope.

■ Trocars

Trocars provide access to the abdominal cavity. They contain: (1) a cannula or sleeve, which is tubular and allows access to the abdominal cavity; (2) a seal, which is located in the cannula and prevents air from escaping from the pneumoperitoneum; and (3) an obturator designed to help penetrate into the abdominal cavity. Disposable and reusable trocars are available in differing lengths that range from 60 to 150 mm and with diameters that vary from 2 to 20 mm. In addition, *reposable* trocars are those specifically designed to reuse part of the trocar, and generally consist of a reusable cannula but a disposable obturator. Obturator tip designs include bladed, blunt, and radially expanding tips. Another trocar type, the *optical trocar*, allows for concomitant viewing through the trocar during abdominal wall entry. A balloon surrounding the cannula shaft is a feature of some trocars and can be inflated to prevent dislodgement from the abdominal wall. Cannulas with this fixation mechanism may be ideal for laparoscopy in pregnancy. Namely, the ability to control and secure the depth of the cannula sleeve could prevent inadvertent uterine damage.

■ Gas Insufflator

Pneumoperitoneum is created and maintained by insufflation systems that deliver gas to the abdominal cavity. Well-designed systems offer adjustable flow rates and pressure settings with easily recognized gauges and alarms. For effective maintenance of abdominal wall elevation that replaces gas lost through leakage and suction, a gas flow rate of at least 10 L/min is required. Pressures are set at the lowest pressure required to visualize the abdominal cavity and safely perform the procedure, generally <15 mm Hg.

■ Surgical Instruments

Laparoscopic scissors and graspers are available in numerous designs. They are classified by caliber (typically 3, 5, or 10 mm) and by length (33 cm is standard, 45 cm is bariatric length). Common features include the ability to perform uni-polar or bipolar electrosurgery and a mechanism for rotation of the instrument shaft. Suction-irrigation instruments with the capacity to deliver fluid in a pressurized stream are useful for isolating bleeding vessels and fragmenting blood clots for subsequent suction removal.

INTRAOPERATIVE STEPS

■ Bladder and Stomach Decompression

Preparation differs little from that commonly employed for laparotomy. Nasogastric or orogastric decompression of the stomach reduces the risk for its injury and lowers the risk for pulmonary aspiration of gastric contents. This is especially important in pregnancy, in which gastroesophageal sphincter tone is lessened and aspiration risks are thereby increased. The bladder is emptied transurethrally, usually by an indwelling Foley catheter.

■ Patient Positioning

Aortocaval compression by the pregnant uterus warrants positioning the patient in a left-lateral tilt similar to that used during cesarean delivery. This position is implemented for gestations that are 16 weeks or older to maximize hemodynamic parameters (Kinsella, 1994). Positional changes during surgery, including movement into Trendelenburg position, should be gradual to minimize potential adverse effects.

Following anesthesia induction, a patient is placed in low dorsal lithotomy position with the legs in booted support stirrups. This provides access to the vagina for sonographic fetal assessment or for manual displacement of the uterus. If uterine manipulation is needed, the buttocks are placed slightly past the edge of the table.

To aid proper leg positioning, the stirrup brackets, which holster the stirrups, are attached to the table at the level of the patient hips. To prevent femoral nerve injury, the hips are positioned without sharp flexion or marked abduction or external hip rotation. The knees are not flexed more than 90 degrees.

The common peroneal nerve, now termed the common fibular nerve, originates above the popliteal fossa and crosses the lateral head of the fibula before it descends down the lateral calf. At the lateral fibular head, this nerve is at risk for compression against leg stirrups. Therefore, patient positioning that avoids pressure at this point or the addition of cushioned padding is warranted.

To avert slipping when in steep Trendelenburg position and to minimize lower back pressure, a patient can be placed directly on an antiskid material such as egg-crate or gel pad. With these, patient skin directly contacts the padding (Klauschie, 2010; Lamvu, 2004).

Patient arms are tucked to the side in military position. This allows improved patient access and prevents upper extremity hyperextension, which can result in brachial plexus injury. The

arms may be tucked using an extended draw sheet, which is placed under the gel pad. This relationship limits arm slippage, which can generate pressure against the brachial plexus. Even in obese patients, the use of antiskid material and arm tucking is useful in preventing slippage for long periods in steep Trendelenburg position (Klauschie, 2010). The arms are padded to avert compression of the ulnar and median nerves. Fingertips are facing the thighs, well-padded, and positioned away from the moving foot of the bed to prevent unintentional amputation. During arm positioning, finger oxygen monitors and intravenous access should not be dislodged.

Shoulder braces are padded brackets that are placed on the cephalic side of the operating room bed and arch around to the patient's acromion. Their goal is to brace the shoulder and prevent the head from slipping off the bed when in Trendelenburg position. If shoulder braces are required, we recommend tucking the arms in addition to using well-padded braces. However, due to the risk of nerve injury, the use of shoulder braces in general should be limited. Specifically, brachial plexus injury complicates 0.16 percent of gynecologic laparoscopic procedures. When shoulder braces are used, compression over the acromion may apply pressure that stretches the plexus. Moreover, lateral compression by braces may compress the humerus against the plexus. Both predispose to brachial plexus injury (Romanowski, 1993).

■ Laparoscopic Entry

This remains the most hazardous portion of any laparoscopic procedure. Nearly half of all intraoperative injuries occur with this step (Bhoynul, 2001; Chandler, 2001). Moreover, potential injury to the gravid uterus makes this a critical step that requires thoughtful planning. Unintentional puncture of the uterus and membranes during transumbilical placement of the Veress needle and cannulas has been reported (Kho, 2009; Reedy, 1997a).

The open Hasson technique is advocated by many because downward puncture is not required. But, other methods of entry can be used to gain access during pregnancy. This includes establishing a pneumoperitoneum with a Veress needle followed by port placement. In general, it is advisable to use the technique most comfortable and most successful for the surgeon. Regardless of method, keys to entry are: (1) appropriate anatomic planning of the entry site to provide adequate distance from the uterus and (2) controlled entry to avoid trauma to the uterus or other vital structures.

For larger uteri, subxiphoid or left upper quadrant sites are preferred locations. In an advanced gestation in the third trimester, sonographic guidance may also help locate and map a free, safe space for primary trocar placement. Moreover, the uterus can be gently manipulated laterally away from the site of entry through an exaggerated lateral tilt of the bed or gentle manual traction.

Hasson Open Entry Technique

The best site for abdominal entry will vary with gestational age. In general, planned laparoscopic entry at a point 6 to 8 cm cephalad to the level of the fundus is advised to optimize visualization of the pelvis. Thus for the early first trimester,

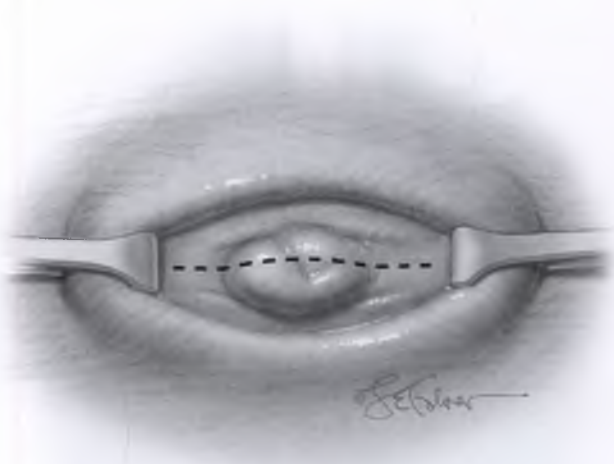


FIGURE 15-2 The umbilical skin incision may be made vertically or transversely, as shown here. Some surgeons prefer an infraumbilical transverse incision.

entry at the umbilicus offers its typical advantages. Namely, the punctum is the site at which the anterior abdominal wall is typically thinnest.

To lower puncture injury rates with closed entry methods, an open entry technique was described by Hasson (1971, 1974). For this, a 1- to 2-cm transverse skin incision is made while applying tension to its lateral borders (Fig. 15-2). Some surgeons prefer to make this incision at the lower edge of the umbilicus. In either case, skin edges are retracted laterally, and the subcutaneous layer is divided to expose the linea alba (Fig. 15-3). A “roll” of this fascia is grasped and elevated upward with two Allis clamps (Fig. 15-4). This roll should include only the fascia

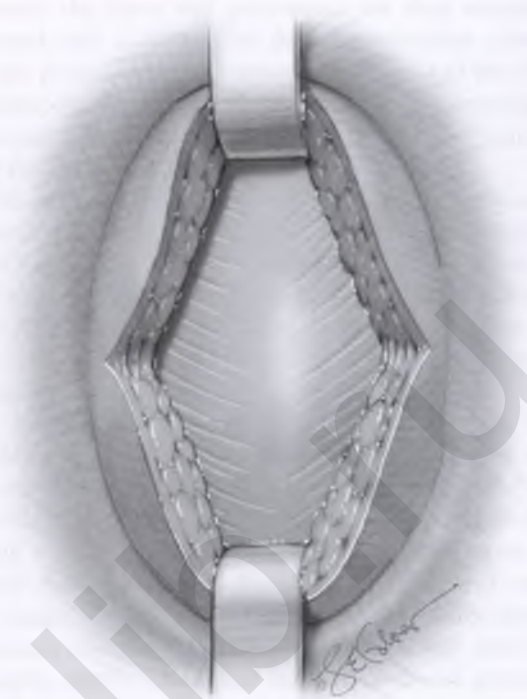

FIGURE 15-3 Attenuated fascia is identified.

but be substantial enough to include the full thickness of the linea alba. This step helps to minimize bowel laceration during fascial incision (Fig. 15-5). A 0.5- to 1-cm incision with scalpel or scissors then transects the fascial roll (Fig. 15-6). This fascial incision may be bluntly stretched to accommodate the Hasson trocar (Fig. 15-7). The Allis clamps are repositioned, one on each free fascial edge. The parietal peritoneum is grasped with two hemostats and is sharply incised (Fig. 15-8). In other instances,

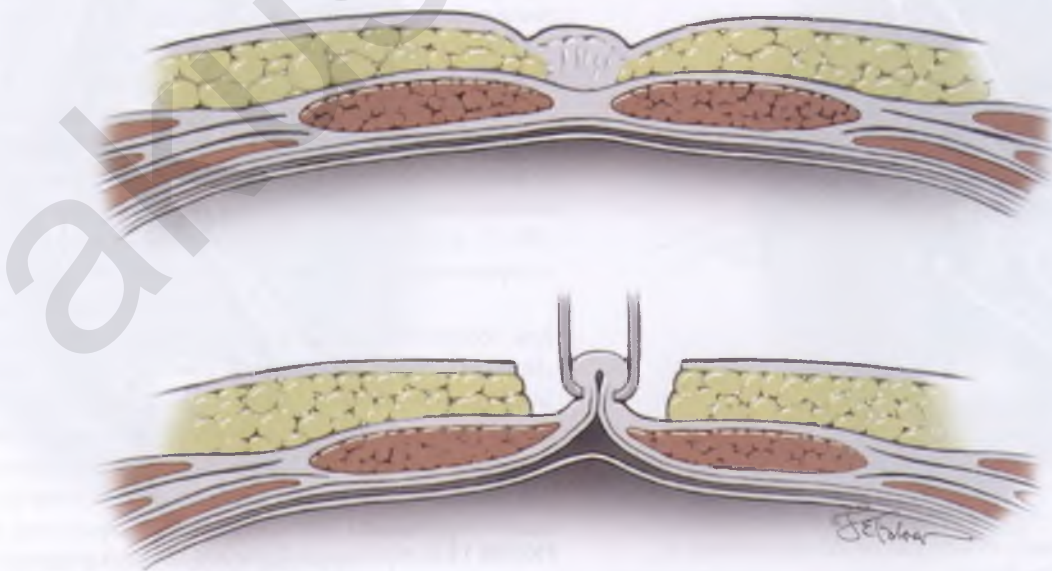


FIGURE 15-4 Shown in this cross-sectional view of the anterior abdominal wall, a substantial grasp of the fascia creates a roll of tissue. This in combination with elevation of the fascia helps to minimize the risk for bowel laceration during abdominal entry.

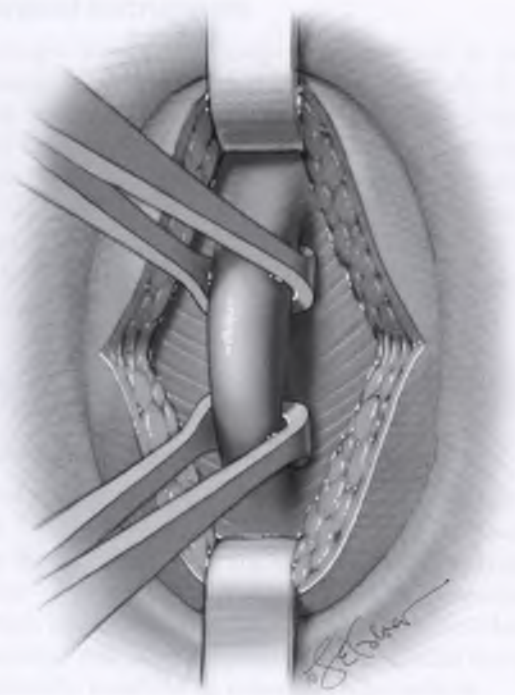


FIGURE 15-5 Fascia is grasped by two Allis clamps and elevated away from viscera beneath.

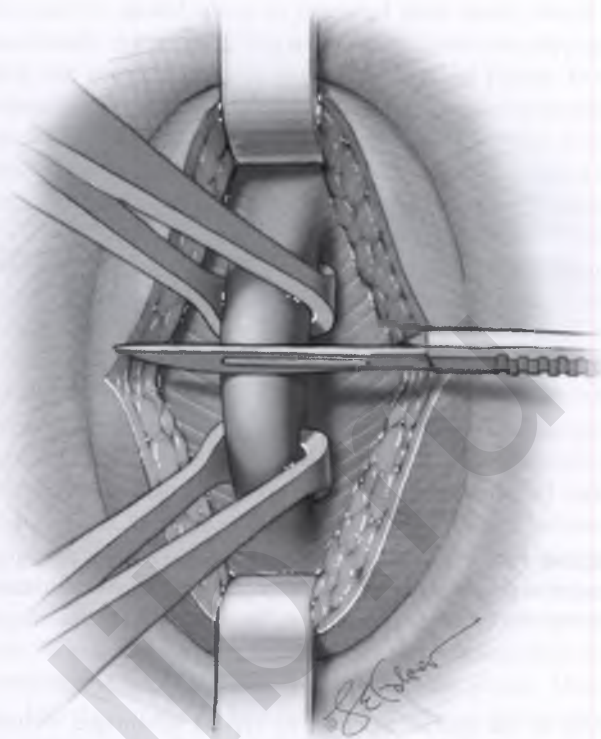


FIGURE 15-6 The Allis clamps are elevated as the fascia is sharply incised.

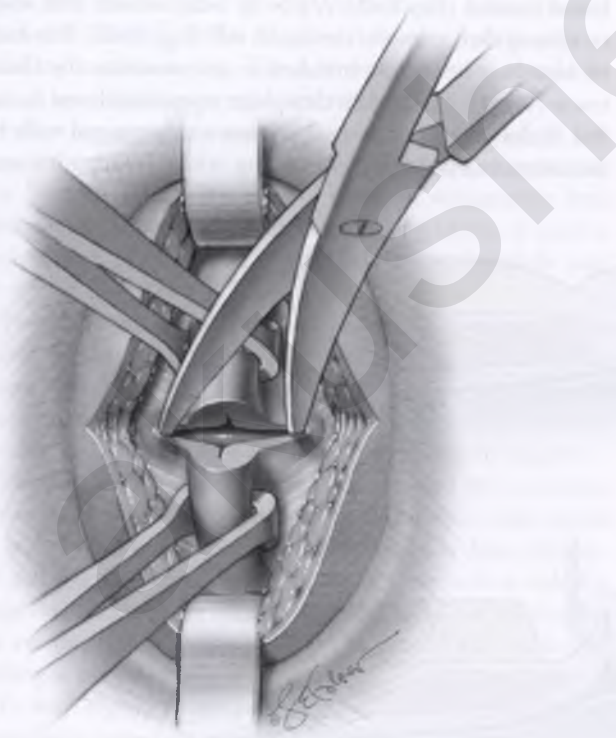


FIGURE 15-7 The fascial incision can be bluntly stretched, as shown here, or may be sharply incised laterally to open the incision sufficiently to accept the Hasson trocar. Overextending the incision is avoided to prevent gas escape once the cannula is seated and a pneumoperitoneum is created.

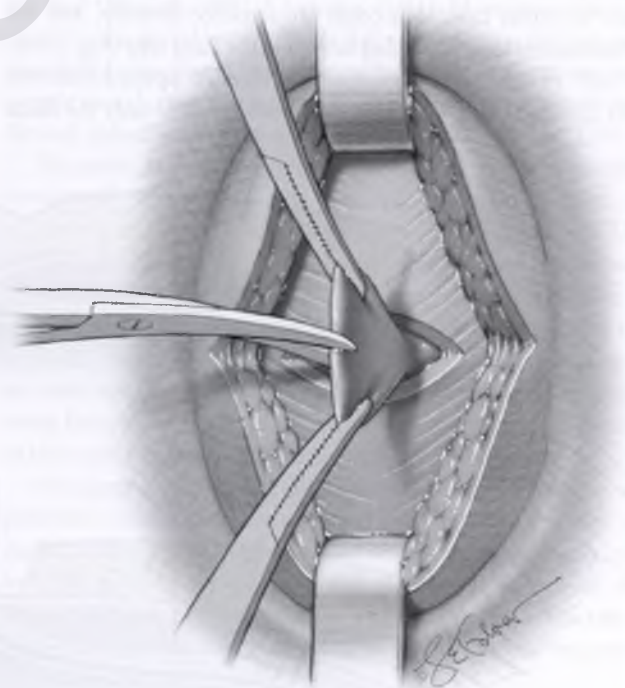


FIGURE 15-8 At times, the fascia and peritoneum are incised simultaneously. If not, the peritoneum is grasped with two hemostats and sharply incised.

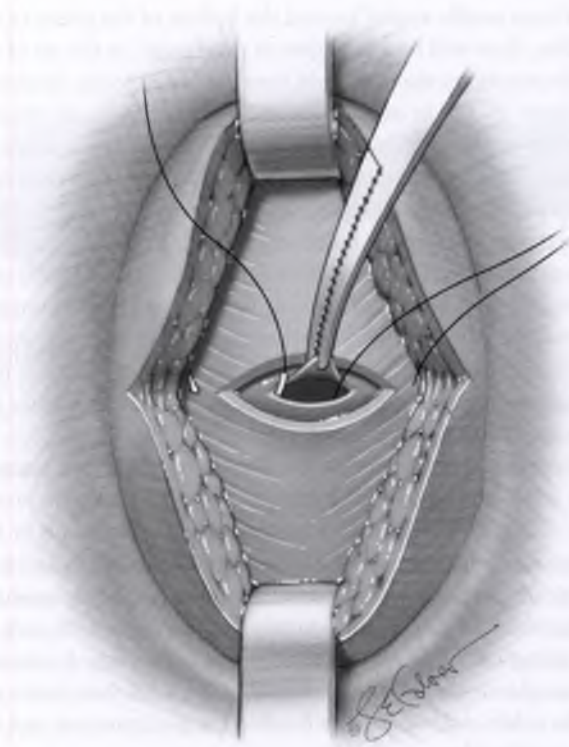


FIGURE 15-9 One stitch is placed through the peritoneum and fascia on either side of the incision. These are not tied but are instead wrapped around the suture holders found on each side of the Hasson trocar.

the peritoneum may be incised incidentally and concurrently during the fascial incision.

Following peritoneal entry, the end of an S-retractor is then placed into the abdomen. A second retractor is similarly placed. The abdominal portion of the S-retractor elevates the abdominal wall and shields the underlying organs as a stitch of 0-gauge delayed-absorbable suture is placed through the peritoneum and fascia on each side of the fascial opening (Fig. 15-9). This suture is not tied until the end of the case when the fascia will be reapproximated.

The distal tip of the Hasson trocar plus its blunt-ended inner obturator are inserted into the incision. The fascial tag sutures are pulled firmly upward and threaded into the suture holders found on either side of the cannula's proximal end (Fig. 15-10). The blunt obturator is removed. This allows the laparoscope to be threaded through the cannula.

Despite its advantages, this technique is not foolproof, and organ injury, mainly bowel, has been described (Magrina, 2002). Typically, this method of entry takes longer than closed entry, and the pneumoperitoneum can be difficult to maintain in some cases due to air escape around the cannula. To counter this, care to avoid an incision that is larger than the cannula can minimize pneumoperitoneum loss. Also, Hasson-type trocars that also contain a fixation device may help.

Veress Needle Entry

The goal of this closed technique is to first create a pneumoperitoneum with a 14-gauge Veress needle. Once a pneumoperitoneum

is created, the fascia and peritoneum are then secondarily punctured with a trocar. The pneumoperitoneum serves to tense the peritoneum and increases the distance of the viscera and retroperitoneal structures from the trocar entering the abdominal wall. These steps ideally help lower the puncture injury risk during trocar insertion.

With all the closed methods, a skin incision appropriate to the trocar size is created. This is usually at the umbilicus if the uterine fundus is an adequate distance from this point—usually 8 to 9 cm. The incision can be either horizontal or vertical, is placed centrally within the umbilicus, and can be made with a no. 11 or 15 blade. Skin hooks or Allis clamps can aid in everting the umbilicus.

To begin, a Veress needle tip travels through the fascia and peritoneum and into the intraabdominal cavity to allow abdominal cavity insufflation with CO₂. During both Veress and trocar placement, many surgeons recommend abdominal wall elevation, either manually or with instruments such as towel clips (Fig. 15-11). A study using computed tomography images revealed that up to 8 cm can be added between the incision and retroperitoneum by elevation with towel clips (Shamiyeh, 2009). Abdominal wall elevation also provides a controlled countertension to the downward thrust of the Veress needle and subsequent trocar during insertion.

The Veress needle has a spring-loaded obturator. Thus, as the device contacts the fascia, the obturator is pushed back, and the needle pierces the fascia and peritoneum. As soon as the tip enters the abdominal cavity, the obturator springs forward to prevent the needle from injuring abdominal viscera.

Prior to insertion, the Veress needle is checked for patency by flushing saline through the needle and then withdrawing the fluid. The spring mechanism is also confirmed to function appropriately. The patient and operating table are flat, and the anterior abdominal wall is elevated. The Veress needle is inserted

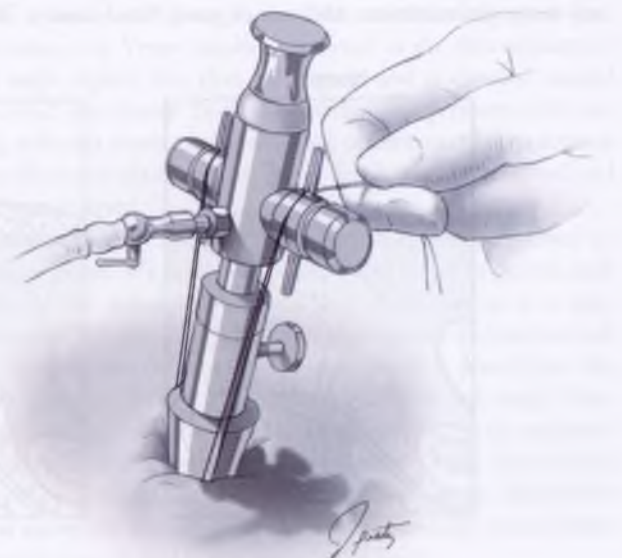


FIGURE 15-10 Once the Hasson trocar is placed, the fascial sutures are wrapped through the trocar's suture holders.

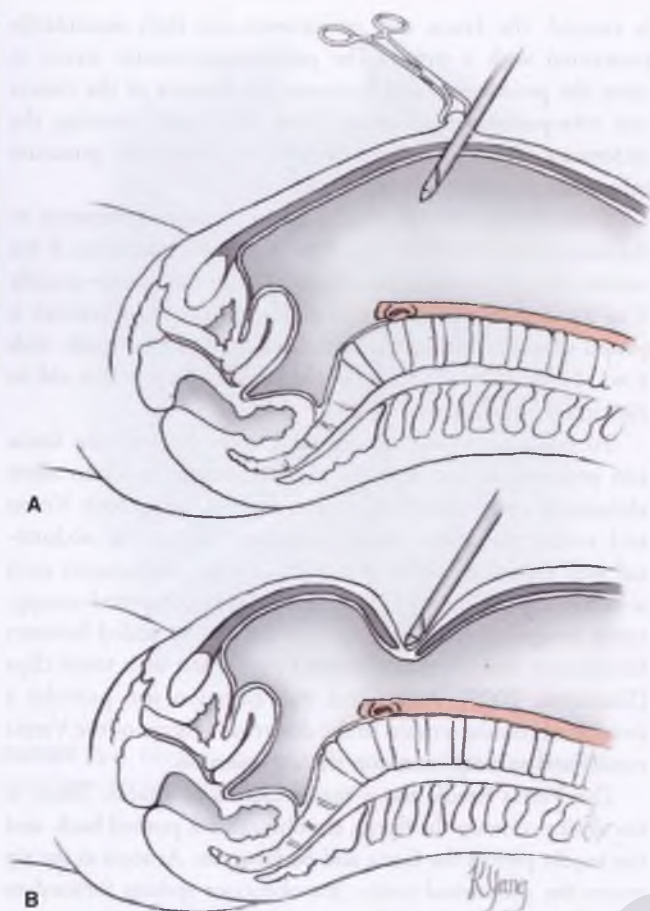


FIGURE 15-11 **A.** Abdominal wall elevation with hand or towel clips creates a buffer space for a trocar to enter the abdomen yet avoid major vessel injury. **B.** Without anterior abdominal wall elevation.

at a 45- to 90-degree angle, depending on patient habitus and abdominal wall thickness. In patients with a normal body mass index, angling the needle at a 45-degree angle permits abdominal entry yet minimizes the risk of great vessel injury. With

the Veress needle angled toward the hollow of the pelvis in the midline, there will be a sensation of two “pops” as the tip of the needle penetrates the fascia and then the peritoneum. As shown in **Figure 15-12**, in overweight and obese individuals, smaller insertion angles are needed to successfully enter the abdomen.

Entry failures with this method usually stem from Veress needle tip placement into the preperitoneal space (**Fig. 15-13**). Flow of gas through the needle insufflates the preperitoneal space. This gaseous dissection of the peritoneum away from the anterior abdominal wall hinders the trocar in piercing the peritoneum. Instead, the trocar further stretches and pushes the peritoneum internally. Fortunately, this problem can often be overcome by a second attempt with the Veress needle at an alternative entry site or by switching to another entry technique (**Fig. 15-14**).

Preperitoneal insertion of the Veress needle is not uncommon and can lead to abandonment of the laparoscopic procedure. Thus, confirmation of correct needle placement in the peritoneal cavity is essential. For confirmation, a 10-mL syringe containing 5 mL of saline is attached to the hub of the inserted Veress needle. With aspiration, air bubbles should be seen in the syringe. If blood or bowel contents are aspirated, concern for vascular or visceral injury should be high. In these cases, the needle is left in place to help localize the puncture site and act as a vascular plug.

After aspiration and confirmation of bubbles, saline is easily injected with no resistance. The surgeon should be unable to reaspirate this saline, which has dispersed into the abdominal cavity. Similarly, a hanging drop test can be used. With this, a few drops of saline are placed on the external open end of the Veress needle. If the needle tip is correctly inserted, the fluid drops disappear into the lower pressure of the abdominal cavity. If the fluid fails to drop and incorrect entry is suspected, the needle is withdrawn and checked for patency. Moving the Veress needle from side to side is avoided at this stage. Such movement can create rents in the omentum or injure bowel.

Once correct placement is confirmed by these methods, the CO₂ insufflation tubing can be attached to the needle. A

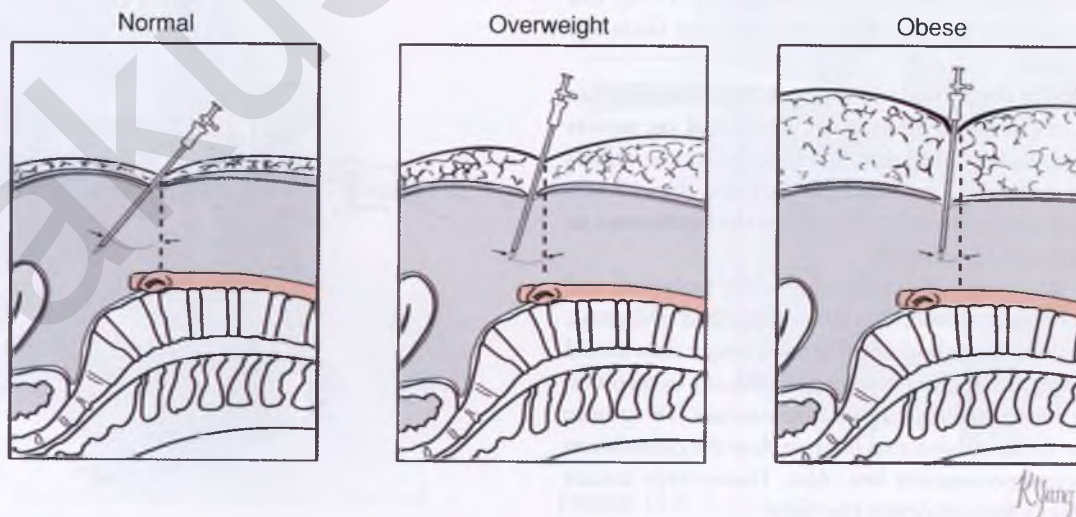


FIGURE 15-12 The appropriate angle needed for the Veress needle to enter the abdomen without injury to the aorta varies with the degree of body fat. (Reproduced with permission from Kho KA, Thompson MJ: Fundamentals of minimally invasive surgery. In Hoffman BL, Schorge JO, Bradshaw KD, et al: Williams Gynecology, 3rd ed. New York, McGraw-Hill Education, 2016.)

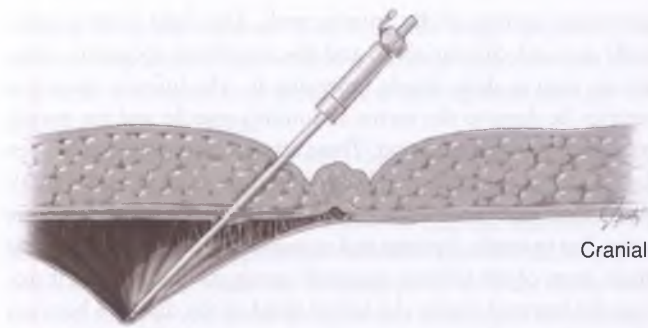


FIGURE 15-13 Veress needle tenting the peritoneal layer is seen in this sagittal view of the anterior abdominal wall. (Reproduced with permission from Kho KA, Thompson MJ: Fundamentals of minimally invasive surgery. In Hoffman BL, Schorge JO, Bradshaw KD, et al: Williams Gynecology, 3rd ed. New York, McGraw-Hill Education, 2016.)

low-volume flow of CO₂ is selected, and initial intraabdominal pressure recordings should measure <8 mm Hg while the abdominal wall is manually lifted. If the pressure is higher than this threshold, the needle is immediately removed. The initial pressure is the most sensitive measurement of correct intraperitoneal Veress needle placement (Vilos, 2007). With the needle correctly inserted, pressure and gas flow may be increased. Simultaneously, the electronic insufflator parameters are closely monitored ensure a steady increase in the pressure and continued flow. If the intraperitoneal pressure rises rapidly prior to insufflation of 1.5 to 2 L of gas, one again is concerned for preperitoneal insufflation.

During insufflation, the abdomen is observed for a uniform distention and hollowness to percussion. The total volume required to appropriately insufflate an abdomen will vary depending on patient habitus and gestational age. Thus, intraperitoneal pressure, rather than total volume of gas, is used to determine adequate peritoneal insufflation. Importantly, during normal insufflation, pressures should not exceed 20 mm Hg. Such elevated pressure can lead to hemodynamic and pulmonary compromise. When an intraperitoneal pressure of 20 mm Hg is achieved, the Veress needle may be withdrawn, and the pneumoperitoneum should assist safe primary trocar insertion. This *transient* elevated intraabdominal pressure provides a volumetric countertension for primary trocar insertion. However, once the primary trocar is inserted, the insufflation pressure in pregnant women is dropped to <12 mm Hg or to the lowest pressure needed to adequately visualize and safely perform the planned procedure. Particularly during pregnancy, attention to safe entry and then reduction of pneumoperitoneum should proceed expeditiously to reduce the physiologic effects of elevated intraabdominal pressures.

Once adequate insufflation is achieved, the primary trocar may then be placed. Initial trocar entry is a blind procedure and is completed with the patient still supine and flat. The Veress needle is removed, and the trocar's tip is placed in the umbilical incision. The trocar handle is cupped in dominant hand's palm, and the same hand's index finger is extended along the trocar shaft to splint and control the trocar from traveling too deep. The angle of trocar insertion should be the same as that for the Veress needle. The anterior abdominal wall is elevated. With control and minimal downward force, the trocar punctures the

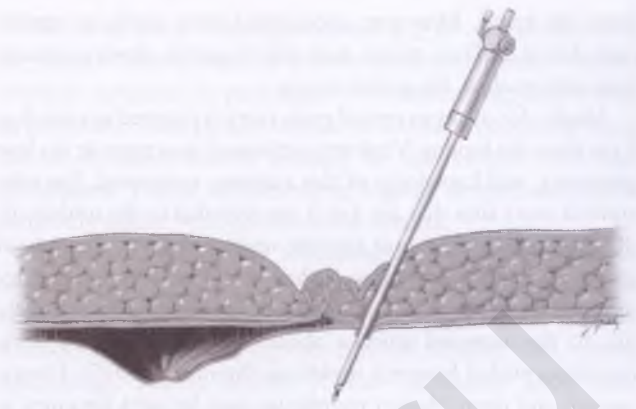


FIGURE 15-14 Veress needle replaced above the umbilicus. (Reproduced with permission from Kho KA, Thompson MJ: Fundamentals of minimally invasive surgery. In Hoffman BL, Schorge JO, Bradshaw KD, et al: Williams Gynecology, 3rd ed. New York, McGraw-Hill Education, 2016.)

fascia and underlying peritoneum and enters the abdominal cavity. After insertion, the trocar obturator is removed, and the cannula may be advanced slightly to ensure adequate placement into the peritoneal cavity. At this point, the laparoscope is inserted through the cannula to visually confirm safe and atraumatic entry.

Left Upper Quadrant Entry

Palmer point is frequently chosen for upper abdominal entry and is located 3 cm below the left costal margin in the midclavicular line. Organs in close proximity to this point are the stomach, left lobe of the liver, spleen, and retroperitoneal structures, which may be as close as 1.5 cm (Giannios, 2009; Tulikangas, 2000).

For entry at Palmer point, one ensures that the stomach is emptied using an orogastric or nasogastric tube. Palpating the area will ensure adequate emptying and exclude incidental splenomegaly. A skin incision adequate for trocar insertion is made at Palmer point. With anterior abdominal wall elevation, the Veress needle is inserted in the skin incision at an angle slightly less than 90 degrees and is directed caudad to avoid liver injury. Initial intraabdominal pressure <10 mm Hg indicates correct intraperitoneal placement. Once adequate insufflation is obtained, the Veress needle may be removed and a trocar inserted.

Alternatively, direct trocar entry may be performed at Palmer point. We favor an optical access trocar to permit each layer of the anterior abdominal wall to be seen as it is penetrated (Vellinga, 2009). For this, the anterior abdominal wall is elevated, and the trocar with laparoscope is placed into the skin incision. The trocar is directed at a 90-degree angle. During insertion, one should observe the following in sequence: subcutaneous fat, outer fascial layer, muscle layer, inner fascial layer, peritoneum, and finally, abdominal organs. Remember that above the level of the arcuate line, posterior rectus sheath fascia is present and is the inner fascial layer.

Subxiphoid Entry

As an alternative to Palmer point, subxiphoid (supraumbilical) primary trocar insertion can also provide a safe distance

from the uterus. Moreover, subxiphoid entry yields an optical port that is midline, which may offer superior viewing around structures such as the gravid uterus.

Ideally, for use as an optical port, entry is planned at a site 8 to 9 cm from the fundus. Vital retroperitoneal structures lie in close proximity, and knowledge of this anatomy is essential. For subxiphoid entry sites that are 3 to 5 cm cephalad to the umbilicus, the aorta remains the most anterior vessel. However, subxiphoid entry, compared with entry at the umbilicus, affords a greater distance from the skin to the retroperitoneum. This is largely due to the increased anterior abdominal wall thickness when moving cephalad from the umbilicus (Stanhiser, 2015). Direct, optical, and open Hasson techniques may be used for entry at the subxiphoid area. An entry angle that is 45 degrees from the horizontal can offer a greater distance to the retroperitoneum.

■ Ancillary Port Placement

Once primary abdominal access is achieved, additional operative ports are needed for operative instruments. The number, location, and size of these cannulas will vary depending on the tools required and the laparoscopic procedure. Ancillary trocars are always placed under direct laparoscopic visualization to minimize puncture risk to anterior abdominal wall vessels or abdominal viscera, including the gravid uterus. With ancillary port placement, care is taken to place ports perpendicular to the skin and thereby avoid traveling obliquely through the anterior abdominal wall. This helps to diminish the workload of instrument manipulation through the abdominal wall.

Appropriate port-site selection is essential. Poorly placed ports can create instrument angles that lead to ineffective movement, surgeon fatigue, and iatrogenic complications. During accessory port placement, to avoid puncture of the superficial epigastric vessels, transillumination of the anterior abdominal wall is useful (Fig. 15-15). During this process, the laparoscope, within the abdominal cavity, is placed directly against the

peritoneal surface of the anterior wall. This light is seen externally as a red circular glow, and the superficial epigastric arteries are seen as dark vessels traversing it. The inferior epigastric arteries lie deep to the rectus abdominis muscle and are poorly seen with transillumination. These arteries, however, can be seen by direct laparoscopic visualization in most cases (Hurd, 2003). Also, anatomic landmarks can be used to limit vessel puncture risks. For example, Epstein and coworkers (2004) noted that the main stem of the inferior epigastric artery can be avoided if trocars are inserted within the lateral third of the distance between the midline and anterior superior iliac spine (ASIS). Rahn and associates (2010) noted that the inferior epigastric vessels were 3.7 cm from the midline at the level of the ASIS and were always lateral to the rectus abdominis muscle at a level 2 cm superior to the pubic symphysis. However, with advancing pregnancy and abdominal wall stretching, these measurements are less valid.

Ideally, port placement will also minimize the risk of ilioinguinal and iliohypogastric nerve injury. Most injuries to these nerves and to the inferior epigastric vessels can be averted by placing the accessory ports superior to the ASIS and >6 cm from the abdomen's midline (Rahn, 2010). Advantageously, most ancillary ports will likely be placed cephalad to these nerves to avoid the gravid uterus. The surgical team should be aware of the depth of the cannula that is left inside the peritoneal cavity. Especially if skin incisions are made too large, the cannula shaft may travel deeper into the abdominal cavity and harm the uterus. If available, cannulas with fixation devices are a benefit. Importantly, once all trocars have been placed, the gravida's left-lateral tilt is reestablished.

■ Uterine Manipulation

During laparoscopy in pregnancy, uterine manipulation is minimized to avoid uterine trauma. Transcervical and intra-uterine manipulators, which are traditionally used in laparoscopy, are contraindicated during pregnancy. When necessary, a sponge stick may be used in the posterior fornix to gently elevate the uterus, but even this is avoided if possible. Instead, the patient's left-lateral positioning may displace the uterus. Also, tilting the plane of the operating table, termed "airplaning," may shift organs.

■ Specimen Removal

Near the end of many MIS procedures, excised tissues must be removed safely. Port-site seeding and inadvertent dissemination of infected, benign, and malignant tissue during specimen fragmentation and extraction are risks. Spillage of cystic or infected materials may worsen prognosis or require additional interventions and is ideally avoided.

Specimens are best removed by placement into an endoscopic bag and elevation of the bag mouth into the delivering cannula. When the specimen is small, the loaded bag may then be pulled through the

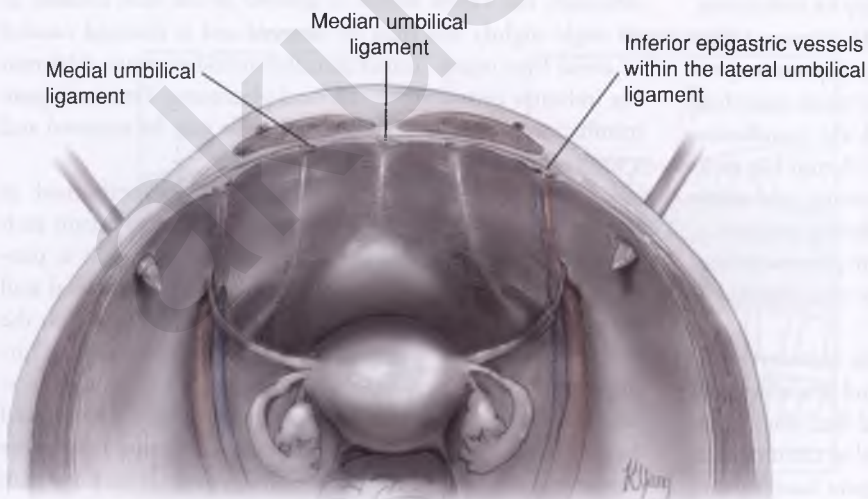


FIGURE 15-15 Umbilical ligaments relative to trocar placement. (Reproduced with permission from Kho KA, Thompson MJ: Fundamentals of minimally invasive surgery. In Hoffman BL, Schorge JO, Bradshaw KD, et al: Williams Gynecology, 3rd ed. New York, McGraw-Hill Education, 2016.)

cannula by gentle traction. With a slightly larger specimen, the cannula may need to be withdrawn from the abdomen first. The bag with its contents then conforms to and squeezes through the fascial and skin incisions.

If the specimen is larger still, the cannula is first removed. The bag mouth is delivered to the skin surface and then opened (Fig. 14-20, p. 235). For cystic lesions, external aspiration will sufficiently reduce the specimen's volume to permit delivery. For more solid tissues, these can be grasped by an Allis clamp and firm traction can compress the specimen adequately for delivery.

For larger or solid specimens, the port incision may need to be extended to allow removal within the bag. If delivery of an intact specimen is not necessary for pathologic analysis, the specimen may be brought up to the anterior abdominal wall and fragmented within the confines of the bag for extraction. The port site is inspected and irrigated copiously if there are any concerns for contamination.

■ Abdominal Incision Closure

Pneumoperitoneum-mediated vascular compression can tamponade low-level venous bleeding. Thus, at the procedure's end and after the pneumoperitoneum is released, the operative field is thoroughly inspected. Secondary port sites are observed using the laparoscope for unsuspected bleeding as cannulas are withdrawn. Last, the primary port site's tunnel through the anterior abdominal wall is inspected. For this, the primary cannula is retracted upward and over the laparoscope's shaft. The site's walls are then directly inspected for bleeding as the laparoscope is slowly removed.

Prior to removal of the Hasson trocar, sutures originally placed in the fascia are unthreaded from the cannula. After cannula removal, one strand from each of these sutures is cut. The other is brought to the midline of the incision, and square knots are tied to close the fascial defect (Fig. 15-16).

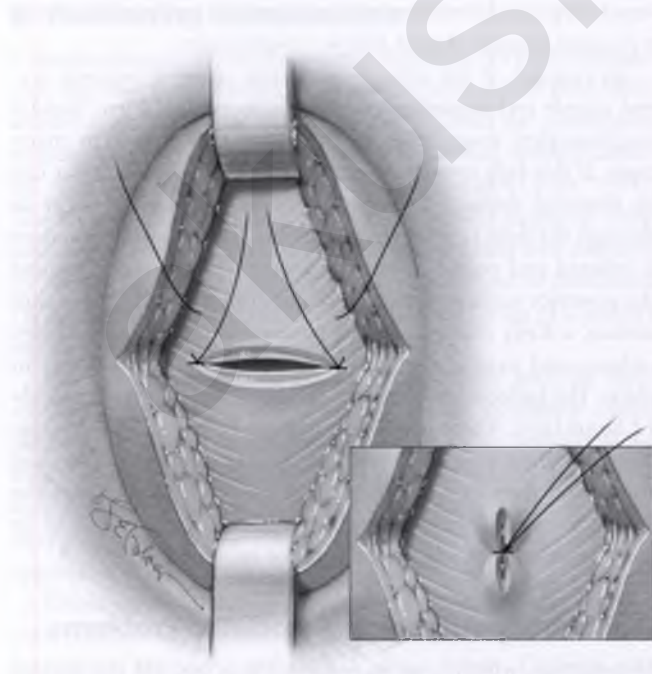


FIGURE 15-16 Fascial incision closure after the Hasson open entry method. For each of the original fascial sutures, one strand is cut and the other ties in the midline.

For other trocar incisions measuring ≥ 10 mm in diameter, the fascia is ideally closed to prevent incisional hernias. Smaller incisions subjected to prolonged or forceful manipulation may have stretched and are also closed. In thinner women, the fascia can be identified directly through the skin incision and reapproximated. Fascial stitches using 0-gauge delayed-absorbable suture are placed with conventional needles.

In women with thicker subcutaneous layers, the fascia can be difficult to discern, and the laparoscope's intraabdominal view can assist with correct suture placement. In these cases, stitches can be placed using conventional needles. Also, several laparoscopic closure devices (Carter-Thomason, EndoClose, and neoClose devices) are available.

The skin is approximated as a separate layer with a subcuticular stitch of 4-0 delayed-absorbable suture. Alternatively, the skin may be closed with cyanoacrylate tissue adhesive (Dermabond) or with benzoin tincture plus skin tape (Steri-Strip Elastic).

SPECIFIC PROCEDURES

Common laparoscopic procedures, such as appendectomy and cholecystectomy, are typically treated by other surgeons and are outlined here to familiarize the reader with pregnancy-relevant issues. Numerous variations to the described techniques exist. Adnexal surgery is another frequent indication, and technical steps are presented in the chapters discussing adnexal mass and ectopic pregnancy.

■ Appendectomy

For this, the optical port is generally placed in the midline at the umbilicus or a subxiphoid site using a 10- to 12-mm trocar via the Hasson technique. A complete diagnostic interrogation of the abdomen and pelvis ideally evaluates for other potential pathology. For bowel manipulation, two ancillary ports are placed in the right and left upper quadrants at levels based on uterine fundal height. The patient is then placed in Trendelenburg position with a tilt to the patient's left side to aid exposure of the cecum.

The appendix is grasped, and its mobility as well as comorbid adhesions or periappendiceal inflammation are assessed. Gangrene, phlegmon, or abscess should prompt strong consideration for conversion to laparotomy.

Multiple avenues allow the appendiceal mesentery to be divided and include laparoscopic stapling devices, advanced bipolar technologies (LigaSure, EnSeal) or harmonic scalpel. With gentle traction on the appendix to lengthen it, vessels within the mesoappendix are sealed and cut. Division of the mesoappendix continues serially and reaches the appendiceal base at the cecum. With continued traction on the appendix tip, the advanced bipolar sealing device, endoscopic stapling device, or endoscopic loops (Endoloops) can then be positioned across or around the clearly delineated appendiceal base. If using a stapling device, the stapler is closed for 15 seconds prior to firing. This allows the tissue to be compressed evenly as consistent force is applied across the device. If using endoscopic loops, the appendiceal base is ligated with three evenly spaced suture loops.

The appendix is amputated between the upper two ligatures, and this leaves two loops around the appendiceal stump.

Following any of these techniques, the freed appendix can then be removed within an endoscopic bag, similar to that in Figure 14-19 (p. 235). The appendiceal stump and mesentery are evaluated to exclude bleeding.

■ Cholecystectomy

For cholecystectomy, trocar placement must be modified in late pregnancy when the uterus encroaches on the right upper abdomen. The patient is generally placed in a slightly reverse Trendelenburg (head up), left-lateral decubitus position. Initial entry may be subxiphoid and additional ports are placed under direct visualization of the gravid uterus.

The technical steps of the procedure follow those employed in nonpregnant patients. In selected cases, laparoscopic cholecystectomy may be performed in conjunction with planned cesarean delivery for obstetric indications or in the immediate puerperium (Dietrich, 1998; Pelosi, 1997b).

POSTOPERATIVE MANAGEMENT

As discussed on page 246, continuous electronic fetal heart rate and uterine activity monitoring are considered postoperatively if fetuses have reached a viable gestational age and obstetric intervention would be planned. Tocolysis, if needed, is instituted for obstetric indications.

In general, laparoscopy reduces the need for postoperative narcotics compared with laparotomy. Pain scores can be further lowered with bupivacaine injected locally at the port sites prior to incision or at the end of the surgery. Acetaminophen often relieves minor postoperative discomfort. Narcotics offer excellent relief for severe pain, and acetaminophen plus codeine is one option. Nonsteroidal antiinflammatory agents are not recommended in pregnancy. These may decrease amniotic fluid volume or close the ductus arteriosus prematurely (Rathmell, 1997).

Postoperative nausea and vomiting are more common after laparoscopy than after laparotomy but typically resolve within the first 24 hours postoperatively (Bailey, 1990). Emesis during pregnancy may be treated with antiemetics that include promethazine (Phenergan) and ondansetron (Zofran). Excessive vomiting should prompt parenteral hydration to offset secondary hypotension or uterine contractions. Warm blankets and avoiding pharyngeal suctioning may be helpful.

COMPLICATIONS

■ Visceral Injuries

Laceration of the bowel, bladder, and stomach is most often associated with the placement of laparoscopic trocars. Less frequently, injury may follow electrosurgical burns or result from sharp or blunt trauma from other instruments. Unfortunately, up to half of these injuries are not recognized during surgery (Chandler, 2001).

Sharp bowel injuries are generally repaired with a two-layer closure, as shown in Chapter 28 (p. 461). This restoration may

be completed by obstetricians with suitable experience or may best be managed in consultation with a general surgeon. Repair can be completed via laparotomy or laparoscopy depending on surgeon experience, extent of damage, and amount of bowel content spillage.

With thermal bowel injury, the ultimate extent of thermal damage may be greater than that seen at the time of surgery. Thus, thermal bowel burns identified intraoperatively require segmental resection with at least a 2-cm margin on each side of the injured tissue (Kadar, 1995; Loffer, 1975).

Bladder lacerations are repaired in two layers with delayed-absorbable suture, as shown in Figure 28-1 (p. 456). Frequently, these procedures require laparotomy to complete an adequate repair. However, with appropriately trained and skilled surgeons, this suturing may be performed laparoscopically. This is followed by postoperative decompression by indwelling catheter for 7 to 10 days (Utric, 1998).

■ Vascular Injuries

Major vessel injury associated with laparoscopy is rare and typically results during primary trocar insertion. Puncture rates are cited as 0.09 to 5 per 1000 cases, and characteristically, the terminal aorta, inferior vena cava, and iliac vessels, particularly the right common iliac artery, may be injured (Bergqvist, 1987; Catarci, 2001; Nordestgaard, 1995). Although rare, injury can be catastrophic, and a significant number of deaths result from large-vessel injury (Baadsgaard, 1989; Munro, 2002). Prevention may include use of the Hasson open entry technique or awareness of the angle and force of trocar insertion. Despite these steps, if a large vessel is punctured, the wounding instrument is not removed because it may act as a vascular plug. Moreover, this tool is held stable to avoid extending the laceration. In most cases, laparotomy, direct manual pressure on the vessel, steps for hemodynamic resuscitation, and notification of a vascular surgeon should follow expeditiously.

In contrast, if the inferior epigastric artery is injured, several simple techniques can control hemorrhage. First, bipolar electrosurgical coagulation of the vessel may suffice in many cases. If this fails to control bleeding, a 14F Foley catheter can be threaded through the cannula of the wounding trocar or through the defect created by this trocar. The Foley balloon then is inflated and pulled upward to create direct pressure against the posterior surface of the anterior abdominal wall. At the skin surface, a Kelly clamp is placed perpendicular across the Foley catheter and parallel to the skin to hold the balloon firmly in place. The balloon and catheter can be removed approximately 12 hours later. Alternatively, sutures can be placed that traverse the abdominal wall and peritoneum, arch under the bleeding vessel, and then exit the abdominal wall to directly ligate the vessel. Similarly, the Carter-Thomason tool can be used to ligate both ends of a lacerated inferior epigastric artery.

■ Pneumoperitoneum-Associated Problems

Hypercapnia, which is an increase in $Paco_2$ beyond the normal physiologic range, is one frequent problem associated with a CO_2 pneumoperitoneum. Although it generally is well tolerated by young, healthy patients, the upper limits of tolerance

to hypercapnia in a given patient are not well defined. The condition, in brief, is reversed by increasing minute ventilation and is prevented by closely monitoring Paco_2 either directly or indirectly.

Gas embolism is rare and typically results from inadvertent insufflation of a blood vessel (Daikun, 1991). This complication is frequently fatal, and early warning signs include tachycardia, arrhythmias, hypotension, “mill wheel” heart murmur, and cyanosis. Anesthesia staff may note increased end-tidal CO_2 values and oxygen desaturation. Foamy blood or gas return from a central line is diagnostic.

Early recognition can be lifesaving. Thus, initial CO_2 insufflation at a slow rate (1 L/min) compared with rapid insufflation is preferred as this slower rate allows adverse physiologic changes to be identified early and addressed. Intraabdominal pressures >10 mm Hg generally suggest improper insufflation, which could indicate visceral, vascular, or preperitoneal placement. Treatment of CO_2 embolism begins with immediate release of the pneumoperitoneum. The patient is repositioned into a steep head-down, left-lateral decubitus position, and hyperventilation is induced. This aids movement of the air from the right outflow tract to the apex of the right ventricle. Here, the air may be aspirated by passing a catheter down the jugular vein into the right ventricle (American College of Obstetricians and Gynecologists, 2015). Cardiopulmonary resuscitation is employed as needed.

Subcutaneous emphysema can occasionally form when CO_2 from the pneumoperitoneum infiltrates the loose areolar tissue of the abdominal wall around trocar sites. This condition is usually without consequence and resolves spontaneously within several hours. Resolution may be expedited by massaging the trapped gas toward the nearest trocar sites.

■ Positioning Complications

Trendelenburg position is frequently employed for pelvic laparoscopy but can increase intraocular venous pressure and potentially worsen acute glaucoma. Trendelenburg position also predisposes to atelectasis by its effects to decrease functional residual capacity, total lung volume, and pulmonary compliance (Joris, 1994). The severity of atelectasis is proportional to the degree of steep positioning employed. These changes are generally well tolerated by healthy patients but are aggravated in the obese or debilitated (Wilcox, 1988). Atelectasis can be minimized by use of a positive end-expiratory pressure (PEEP) of 5 cm H_2O .

Reverse Trendelenburg position, commonly used for laparoscopic cholecystectomy, increases lower extremity blood pooling, decreases cardiac output beyond the hemodynamic effects of pneumoperitoneum, and increases venous stasis in the legs, which predisposes to thromboembolism. Moreover, tight strapping of the legs or excessive pressure on the popliteal fossa aggravates venous stasis and should be avoided.

Either upper or lower extremity nerve injury may complicate postoperative recovery. During laparoscopy, the upper extremities are prone to brachial plexus injury. Damage may derive from compression by an improperly applied shoulder brace or from overextension of the arm. The lower extremities are susceptible to femoral nerve injury from hyperflexion

of the hips. The common peroneal nerve can be injured from compression by poorly fitting or poorly adjusted leg supports (Gombar, 1992). Thus, proper patient positioning as described on page 248 is essential.

■ Wound Complications

Incisional hernias may form at trocar sites if the fascia is not closed (Kadar, 1993). Many such defects can be repaired by conventional methods under local or regional anesthesia, although most are avoidable by fascial closure (p. 255).

Wound infections at trocar sites are uncommon following laparoscopic surgery. Treatment does not differ from that of other incisional infections and consists of drainage, irrigation, and debridement as needed and described in Chapter 32 (p. 508).

SUMMARY

Diagnostic or operative laparoscopy is an effective tool to evaluate and manage surgical disease in pregnancy. Despite a relative lack of prospective studies comparing laparoscopy with laparotomy, morbidity is low and recovery is rapid. Experience and proficiency in MIS techniques in nonpregnant patients is a prerequisite for superior outcomes.

REFERENCES

- Allen JR, Helling TS, Langerfeld M: Intra-abdominal surgery during pregnancy. *Am J Surg* 158(6):567, 1989
- American College of Obstetricians and Gynecologists: Nonobstetric surgery during pregnancy. Committee Opinion No. 474. February 2011, Reaffirmed 2015
- Andersen B, Nielsen TF: Appendicitis in pregnancy: diagnosis, management and complications. *Acta Obstet Gynecol Scand* 78(9):758, 1999
- Baadsgaard SE, Bille S, Egeblad K: Major vascular injury during gynecologic laparoscopy: report of a case and review of published cases. *Acta Obstet Gynaecol Scand* 68(3):283, 1989
- Bailey PL, Streisand JB, Pace NL, et al: Transdermal scopolamine reduces nausea and vomiting after outpatient laparoscopy. *Anesthesiology* 72(6):977, 1990
- Barnard JM, Chaffin D, Droste S, et al: Fetal response to carbon dioxide pneumoperitoneum in the pregnant ewe. *Obstet Gynecol* 85(5 Pt 1):669, 1995
- Bergqvist D, Bergqvist A: Vascular injuries during gynecologic surgery. *Acta Obstet Gynecol Scand* 66(1):19, 1987.
- Bhojru S, Viera MA, Nezhad CR, et al: Trocar injuries in laparoscopic surgery. *J Am Coll Surg* 192(6):677, 2001
- Bider F, Maschiach S, Dulitzky, et al: Clinical, surgical, and pathologic findings of adnexal torsion in pregnant and nonpregnant women. *Surg Gynecol Obstet* 173:363, 1991
- Burke LM, Bashir MR, Miller FH, et al: Magnetic resonance imaging of acute appendicitis in pregnancy: a 5-year multiinstitutional study. *Am J Obstet Gynecol* 213(5):693, 2015
- Camanni M, Bonino L, Delpiano EM, et al: Laparoscopy and body mass index: feasibility and outcome in obese patients treated for gynecologic diseases. *J Minim Invasive Gynecol* 17(5):576, 2010
- Cataci M, Carlini M, Gentileschi P, et al: Major and minor injuries during the creation of pneumoperitoneum: a multicenter study on 12,919 cases. *Surg Endosc* 15:566, 2001
- Chandler JG, Corson SL, Way LW, et al: Three spectra of laparoscopic entry access injuries. *J Am Coll Surg* 192(4):478, 2001
- Chopin N, Malaret JM, Lafay-Pillet MC, et al: Total laparoscopic hysterectomy for benign uterine pathologies: obesity does not increase the risk of complications. *Hum Reprod* 24(12):3057, 2009
- Cohen-Kerem R, Railton C, Oren D, et al: Pregnancy outcome following non-obstetric surgical intervention. *Am J Surg* 190(3):467, 2005
- Cox TC, Huntington CR, Blair LJ, et al: Laparoscopic appendectomy and cholecystectomy versus open: a study in 1999 pregnant patients. *Surg Endosc* 30(2):593, 2016
- Csapo AI, Pulkkinen MO, Wiest WG, et al: Effect of luteectomy and progesterone replacement therapy in early pregnant patients. *Am J Obstet Gynecol* 115:759, 1973

- Cunningham FG, Leveno KL, Bloom SL, et al (eds): General considerations and maternal evaluation. In Williams Obstetrics, 24th ed. New York, McGraw-Hill Education, 2014
- Daikun TA: Carbon dioxide embolism: successful resuscitation with cardiopulmonary bypass. *Anesthesiology* 74(6):1151, 1991
- Danzer E, Sydorak RM, Harrison MR, Albanese CT. Minimal access fetal surgery. *Eur J Obstet Gynecol Reprod Biol* 108(1):3, 2003
- Date RS, Kaushal M, Ramesh A: A review of the management of gallstone disease and its complications in pregnancy. *Am J Surg* 196(4):599, 2008
- Diebel LN, Dulchavsky SA, Wilson RF: Effect of increased intra-abdominal pressure on mesenteric arterial and intestinal mucosal blood flow. *J Trauma* 33(1):45, 1992
- Dietrich NA, Kaplan G: Surgical considerations in the contemporary management of biliary tract disease in the postpartum period. *Am J Surg* 176(3):251, 1998
- Eichenberg BJ, Vanderlinden J, Miguel C, et al: Laparoscopic cholecystectomy in the third trimester of pregnancy. *Am Surg* 62(10):874, 1996
- Eltabbakh GH, Piver MS, Hempling RE, et al: Laparoscopic surgery in obese women. *Obstet Gynecol* 94(5 Pt 1):704, 1999
- Epstein J, Arora A, Ellis H: Surface anatomy of the inferior epigastric artery in relation to laparoscopic injury. *Clin Anat* 17:400, 2004
- Geburz AT, Pertz ME: The acute abdomen in the pregnant patient. Is there a role for laparoscopy? *Surg Endosc* 11(2):98, 1997
- Giannios NM, Gulani V, Rohlck K, et al: Left upper quadrant laparoscopic placement: effects of insertion angle and body mass index on distance to posterior peritoneum by magnetic resonance imaging. *Am J Obstet Gynecol* 201(5):522.e1, 2009
- Gombar KK, Gombar S, Singh B, et al: Femoral neuropathy: a complication of the lithotomy position. *Reg Anesth* 17(5):306, 1992
- Guyatt GH, Akl EA, Crowther M, et al: Executive summary: antithrombotic therapy and prevention of thrombosis, 9th ed. American College of Chest Physicians Evidence-Based Clinical Practice Guidelines. *Chest* 141(2 Suppl): 7s, 2012
- Hasson HM: A modified instrument and method for laparoscopy. *Am J Obstet Gynecol* 110(6):886, 1971
- Hasson HM: Open laparoscopy: a report of 150 cases. *J Reprod Med* 12(6):234, 1974
- Heinberg EM, Crawford BL III, Weitzen SH, et al: Total laparoscopic hysterectomy in obese versus nonobese patients. *Obstet Gynecol* 103(4):674, 2004
- Ho HS, Saunders CJ, Gunther RA, et al: Effector of hemodynamics during laparoscopy: CO₂ absorption or intra-abdominal pressure? *J Surg Res* 59(4):497, 1995
- Hunter JG, Swanstrom L, Thornburg K: Carbon dioxide pneumoperitoneum induces fetal acidosis in the pregnant ewe. *Surg Endosc* 9:272, 1995
- Hurd WW, Amesse LS, Gruber JS, et al: Visualization of the epigastric vessels and bladder before laparoscopic trocar placement. *Fertil Steril* 80:209, 2003
- Hurd WW, Bude RO, Delancey JOL, et al: Abdominal wall characterization with magnetic resonance imaging and computed tomography. The effect of obesity on the laparoscopic approach. *J Reprod Med* 36:473, 1991
- Johannsen G, Andersen M, Juhl B: The effects of general anesthesia on the haemodynamic events during laparoscopy with CO₂ insufflation. *Acta Anaesthesiol Scand* 33:132, 1989
- Joris JL: Anesthetic management of laparoscopy. In: Miller RD (ed), *Anesthesia*, 4th ed. New York, Churchill Livingstone, 1994.
- Joumbat N, Grubbs B, Chmait RH: Incidental fetoscopy during laparoscopy in pregnancy: management of perforation of the gravid uterus. *Surg Laparosc Endosc Percutan Tech* 22(2):e76, 2012
- Kadar N. Atlas of Laparoscopic Pelvic Surgery. Oxford, Blackwell Science, 1995.
- Kadar N, Reich H, Liu CY, et al: Incisional hernias after major laparoscopic gynecologic procedures. *Am J Obstet Gynecol* 168:1493, 1993
- Kho KA, Nezhat C: Management of unintentional fetoscopy. *J Minim Invasive Gynecol* 16(6 Suppl):S6, 2009
- Kho KA, Thompson MJ: Fundamentals of minimally invasive surgery. In Hoffman BL, Schorge JO, Bradshaw KD, et al: *Williams Gynecology*, 3rd ed. New York, McGraw-Hill Education, 2016
- Kinsella SM, Lohmann G: Supine hypotensive syndrome. *Obstet Gynecol* 83(5 Pt 1):774, 1994
- Klauschie J, Wechter ME, Jacob K, et al: Use of anti-skid material and patient-positioning to prevent patient shifting during robotic-assisted gynecologic procedures. *J Minim Invasive Gynecol* 17(4):504, 2010
- Knill-Jones RP, Newman BJ, Spence AA: Anesthetic practice and pregnancy. *Lancet* 2:807, 1975
- Koo YJ, Kim HJ, Lim KT, et al. Laparotomy versus laparoscopy for the treatment of adnexal masses during pregnancy. *Aust N Z J Obstet Gynaecol* 52(1):34–38, 2012
- Kort B, Katz VL, Watson WJ: Effect of non-obstetrical operation during pregnancy. *Surg Gynecol Obstet* 177:371, 1993
- Kuy S, Roman SA, Desai R, et al: Outcomes following cholecystectomy in pregnant and nonpregnant women. *Surgery* 146(2):35, 2009
- Lamvu G, Zolnoun D, Boggess J, et al: Obesity: physiologic changes and challenges during laparoscopy. *Am J Obstet Gynecol* 191(2):669, 2004
- Leiserowitz GS: Managing ovarian masses during pregnancy. *Obstet Gynecol Surv* 61(7):463–470, 2006
- Loffer FD, Pent D: Indications, contraindications and complications of laparoscopy. *Obstet Gynecol Surv* 30(7):407, 1975
- Luciano AA, Maier DB, Koch EI, et al: Comparative study of postoperative adhesions following laser surgery by laparoscopy versus laparotomy in the rabbit model. *Obstet Gynecol* 74:220, 1989
- Lundorff P, Hahlin M, Bjorn K, et al: Adhesion formation after laparoscopic surgery in tubal pregnancy: a randomized trial versus laparotomy. *Fertil Steril* 55:911, 1991
- Mage G, Canis M, Mahnes H, et al: Laparoscopic management of adnexal torsion: a review of 35 cases. *J Reprod Med* 34:520, 1989
- Magrina JF: Complications of laparoscopic surgery. *Clin Obstet Gynecol* 45:469, 2002
- Morice P, Louis-Sylvestre C, Chapron C, et al: Laparoscopy for adnexal torsion in pregnant women. *J Reprod Med* 42(7):435, 1997
- Mourad J, Elliott JP, Erickson L, et al: Appendicitis in pregnancy: new information that contradicts long-held clinical beliefs. *Am J Obstet Gynecol* 182(5):1027, 2000
- Munro MG: Laparoscopic access: complications, technologies, and techniques. *Curr Opin Obstet Gynecol* 14:365, 2002
- Nieboer TE, Johnson N, Lethaby A, et al: Surgical approach to hysterectomy for benign gynaecological disease. *Cochrane Database Syst Rev* 3:CD003677, 2009
- Nordestgaard AG, Bodily KC, Osborne RW Jr, et al: Major vascular injuries during laparoscopic procedures. *Am J Surg* 169:543, 1995
- O'Hanlan KA, Lopez L, Dibble SL, et al: Total laparoscopic hysterectomy: body mass index and outcomes. *Obstet Gynecol* 102(6):1384, 2003
- O'Rourke N, Kodali BS: Laparoscopic surgery during pregnancy. *Curr Opin Anaesthesiol* 19:254, 2006
- Parker WH, Childers JM, Canis M, et al: Laparoscopic management of benign cystic teratomas during pregnancy. *Am J Obstet Gynecol* 174:1499, 1996
- Pearl J, Price R, Richardson W, et al: Guidelines for diagnosis, treatment, and use of laparoscopy for surgical problems during pregnancy. *Surg Endosc* 25(11):3479, 2011
- Peiro JL, Carreras E, Guillen G, et al. Therapeutic indications of fetoscopy: a 5-year institutional experience. *J Laparoendosc Adv Surg Tech A* 19(2):229, 2009
- Pelosi MA III, Pelosi MA: Alignment of the umbilical axis: An effective maneuver for laparoscopic entry in obese patients. *Obstet Gynecol* 92:869, 1998
- Pelosi MA III, Pelosi MA, Giblin S, et al: Gasless laparoscopy under epidural anesthesia for adnexal surgery in pregnancy. *Gynaecol Endosc* 6:17, 1997a
- Pelosi MA III, Pelosi MA, Villalona E: Laparoscopic cholecystectomy at cesarean section: a new surgical option. *Surg Laparosc Endosc* 7(5):369, 1997b
- Perkins KM, Boulet SL, Kissin DM, et al: Risk of ectopic pregnancy associated with assisted reproductive technology in the United States, 2001–2011. *Obstet Gynecol* 125(1):7, 2015
- Phelan JP. Fetal considerations in the critically ill obstetric patient. In: Clark SL, Cotton DB, Hankins GDV, Phelan JP (eds), *Critical Care Obstetrics*, 2nd ed. Boston, Blackwell Scientific, 1990
- Rahn DD, Phelan JN, Roshanravan SM, et al: Anterior abdominal wall nerve and vessel anatomy: clinical implications for gynecologic surgery. *Am J Obstet Gynecol* 202(3):234.e1, 2010
- Rand L, Norwitz ER: Current controversies in cervical cerclage. *Obstet Gynecol* 27(1):73, 2003
- Rathmell JP, Viscomi CM, Ashburn MA: Management of nonobstetric pain during pregnancy and lactation. *Anesth Analg* 85:1074, 1997
- Reedy MB, Galan HL, Bean-Lijewski JD, et al: Maternal and fetal effects of laparoscopic insufflation in the gravid baboon. *J Am Assoc Gynecol Laparosc* 2(4):39, 1995
- Reedy MB, Galan HL, Richards WE, et al: Laparoscopy during pregnancy. A survey of laparoendoscopic surgeons. *J Reprod Med* 42(1):33, 1997a
- Reedy MB, Kallen B, Kuehl TJ: Laparoscopy during pregnancy: a study of five fetal outcome parameters with use of the Swedish Health Registry. *Am J Obstet Gynecol* 177:673, 1997b
- Reynolds JD, Booth JV, de la Fuente S, et al: A review of laparoscopy for non-obstetric-related surgery during pregnancy. *Curr Surg* 60(2):164, 2003
- Richards WO, Scovill W, Shin B, et al: Acute renal failure associated with increased intra-abdominal pressure. *Ann Surg* 197:183, 1983

- Rizzo AG: Laparoscopic surgery in pregnancy: long-term follow-up. *J Laparosc Adv Surg Tech A* 13(1):11, 2003
- Rojansky N, Schenker JG: Heterotopic pregnancy and assisted reproduction: an update. *J Assist Reprod Genet* 13:594, 1996
- Romanowski L, Reich H, McGlynn F, et al: Brachial plexus neuropathies after advanced laparoscopic surgery. *Fertil Steril* 60:729, 1993
- Sala P, Prefumo F, Pastorino D, et al: Fetal surgery: an overview. *Obstet Gynecol Surv* 69(4):218, 2014
- Sauerland S, Jaschinski T, Neugebauer EA: Laparoscopic versus open surgery for suspected appendicitis. *Cochrane Database Syst Rev* 10:CD001546, 2010
- Scribner DR Jr, Walker JL, Johnson GA, et al: Laparoscopic pelvic and para-aortic lymph node dissection in the obese. *Gynecol Oncol* 84(3):426, 2002
- Sesti F, Pietropoli A, Sesti FF, et al: Gasless laparoscopic surgery during pregnancy: evaluation of its role and usefulness. *Eur J Obstet Gynecol Reprod Biol* 170(1):8, 2013
- Shah DK, Vitonis AF, Missmer SA: Association of body mass index and morbidity after abdominal, vaginal, and laparoscopic hysterectomy. *Obstet Gynecol* 125(3):589, 2015
- Shamiyeh A, Glaser K, Kratochwill H, et al: Lifting of the umbilicus for the installation of pneumoperitoneum with the Veress needle increases the distance to the retroperitoneal and intraperitoneal structures. *Surg Endosc* 23(2):313, 2009
- Sharma KC, Brandstetter RD, Brensilver JM, et al: Cardiopulmonary physiology and pathophysiology as a consequence of laparoscopic surgery. *Chest* 110(3):810, 1996
- Soriano D, Yelfet Y, Seidman D, et al: Laparoscopy versus laparotomy in the management of adnexal masses during pregnancy. *Fertil Steril* 71:955, 1999
- Stanhiser J, Goodman L, Soto E, et al: Supraumbilical primary trocar insertion for laparoscopic access: the relationship between points of entry and retroperitoneal vital vasculature by imaging. *Am J Obstet Gynecol* 213(4):506.e1, 2015
- Tarraza HM, Moore RD: Gynecologic causes of the acute abdomen and the acute abdomen in pregnancy. *Surg Clin North Am* 77:1371, 1997
- Thomas D, Ikeda M, Deepika K, et al: Laparoscopic management of benign adnexal mass in obese women. *J Minim Invasive Gynecol* 13:311, 2006
- Torrielli R, Cesarini M, Winnock S, et al: Hemodynamic changes during celioscopy: a study carried out using thoracic electric bioimpedance. *Can J Anaesth* 37:46, 1990
- Tulikangas PK, Nicklas A, Falcone T, et al: Anatomy of the left upper quadrant for cannula insertion. *J Am Assoc Gynecol Laparosc* 7(2):211, 2000
- Utrie JW, Jr: Bladder and ureteral injury: prevention and management. *Clinical Obstet Gynaecol* 41(3):755, 1998
- Vellinga TT, De Alwis S, Suzuki Y, et al: Laparoscopic entry: the modified Alwis method and more. *Rev Obstet Gynecol* 2(3):193, 2009
- Vilos GA, Ternamian A, Dempster J, et al: Laparoscopic entry: a review of techniques, technologies, and complications. *J Obstet Gynaecol Can* 29(5):433, 2007
- Walker HG, Al Samarae A, Mills SJ, et al: Laparoscopic appendectomy in pregnancy: a systematic review of the published evidence. *Int J Surg* 12(11):1235, 2014
- Wilasrusmee C, Sukrat B, McEvoy M, et al: Systematic review and meta-analysis of safety of laparoscopic versus open appendectomy for suspected appendicitis in pregnancy. *Br J Surg* 99(11):1470, 2012
- Wilcox S, Vandam LD: Alas, poor Trendelenburg and his position! *Anesth Analg* 67:574, 1988

CHAPTER 16

Fetal Therapy

BRIEF HISTORY OF FETAL SURGERY	260
CLOSED FETAL THERAPIES	260
OPEN FETAL SURGERY	268
OTHER POTENTIAL BENEFICIAL FETAL INTERVENTIONS	270
EX-UTERO INTRAPARTUM TREATMENT	272
FUTURE OF FETAL THERAPY	273

BRIEF HISTORY OF FETAL SURGERY

Sir William Liley (1963) completed the first successful fetal surgery, which was transuterine fetal intraperitoneal red blood cell transfusion. This was performed for erythroblastosis fetalis, which at the time, without intervention, was a lethal malady. The field rapidly developed, to a large extent fueled by the work of Dr. Michael Harrison, an early pioneer in fetal surgery. In 1982, one of the first organized conferences on fetal intervention was held. Dr. Harrison summarized conclusions of the inaugural meeting, which would later become the International Fetal Medicine and Surgery Society (IFMSS) (Harrison, 1982). One key statement noted that "All case material, regardless of outcome, should be reported to a fetal-treatment registry, so that the benefits and liabilities of fetal therapy can be established as soon as possible." This ethos is as important today as it was three decades ago.

Fetal surgery has evolved during the past three decades from an innovative and ambitious concept to a regulated and leading field of medicine. Refinement of techniques for open surgeries, new technology, advances in minimally invasive

image-guided percutaneous interventions, and development of feasible fetoscopic surgical procedures has fueled this evolution. In addition, protocols to control uterine contractions and preterm labor and to standardize care of neonates delivered preterm after surgery have been honed. Finally, specific fetal anesthesia considerations and intraoperative management algorithms contribute to improved fetal outcomes.

A fetal anomaly raises unique and complex issues for the pregnant woman and her family. The importance of a multidisciplinary team involved in the prenatal evaluation, surgical therapy, and postnatal care cannot be overemphasized. This team generally includes a maternal-fetal medicine specialist, pediatric surgeon, anesthesiologist skilled in maternal and fetal anesthesia, pediatric neurosurgeon, pediatric urologist, pediatric nephrologist, pediatric cardiologist, neonatologist, and bioethicist. The family should also have access to psychosocial support (Bliton, 2003).

CLOSED FETAL THERAPIES

Closed fetal therapies are procedures performed by inserting a needle or endoscopic trocar through the maternal abdominal and uterine wall without the need for hysterotomy. Most closed surgical procedures are performed under direct sonographic guidance and usually involve only one puncture, which typically measures 2.4 mm. This small puncture introduces a needle or trocar through which a shunt, balloon, or semirigid endoscope can be passed. Occasionally, closed fetal interventions are performed using a combination of sonographic and fetoscopic guidance.

In general, a policy should be adopted to administer fetal analgesics for any invasive procedures during which the fetus might experience pain. This is certainly true for 18- to 20-week or older gestations. Intramuscular or intravenous agents are delivered under sonographic or endoscopic guidance using an 22-gauge needle. We usually give vecuronium (0.2 mg/kg),

atropine (20 µg/kg), and fentanyl (15 µg/kg) using estimated fetal weight to immobilize the fetus and to suppress the fetal stress response, which is bradycardia. For the mother, instrument insertion is usually done under local anesthesia, which is injected along the anticipated track of the cannula or trocar and extends down to the myometrium. Supplemental intravenous sedation with remifentanyl is also usually provided.

■ Twin–Twin Transfusion Syndrome

Physiology and Sequelae

The placentas of monochorionic, diamniotic (MCDA) twins frequently share vascular anastomoses. These anastomoses may be arterio-venous, veno-arterial, arterio-arterial, or veno-venous, and multiple types are typically found in a given placenta. Arterio-arterial and veno-venous anastomoses are connections on the placental surface and have the potential for either unidirectional or bidirectional blood flow. Arterio-venous and veno-arterial anastomoses are unidirectional and form when a placental surface vessel from each twin penetrates into the placenta and connects within a common cotyledon. Unbalanced flow through this shared cotyledon underlies the pathophysiology of twin–twin transfusion syndrome (TTTS) (Fig. 16-1). For MCDA twins, TTTS is not uncommon, and the estimated incidence ranges from 9 to 15 percent (Allaf, 2014b; Kagan, 2007; Lewi, 2007; Simpson, 1998).

The imbalance in circulating blood volume that results from these anastomoses directs blood from a *donor twin* to its *recipient twin*. This leads to relative hypovolemia in the donor twin and hypervolemia in the recipient. One effect of this hypervolemia and hypovolemia is markedly differing urine output, which is reflected by hydramnios and oligohydramnios, respectively. In addition, compensatory cardiovascular responses eventually become maladaptive. The donor twin usually maintains normal cardiac function. However, hypervolemia in the recipient twin increases cardiac preload, which leads to right ventricular hypertrophy and eventually to hypertension and cardiomyopathy. The increased systemic pressure may also increase right ventricular afterload and diminish right heart output, which contributes to an acquired pulmonic stenosis and eventual fetal death (Simpson, 1998). Such right ventricular outflow obstruction is observed in close to 10 percent of all recipient twins. Recipient twins who demonstrate cardiac compromise generally have poorer survival rates than their donor cotwin. Cardiac-compromised recipient twins may also have lower survival rates compared with recipient twins with normal cardiac function.

Serious neurologic complications can also result from these vascular anastomoses and include cerebral palsy, microcephaly, porencephaly, and multicystic encephalomalacia. One theory is that ischemic necrosis leads to cavitory brain lesions. In the donor twin, ischemia may result from hypotension, anemia, or both. In the recipient, ischemia may develop from blood pressure instability and episodes of severe hypotension (Lopriore, 2011).

The mortality rate for untreated progressive TTTS approximates 90 percent (Society for Maternal-Fetal Medicine, 2013). Thus, the primary goal of intervention is to restore more

equitable blood flow between the twins and to halt or reverse cardiac decompensation in either fetus. Secondary efforts aim to relieve the fluid volume inequities between TTTS twins.

Intervention

Early identification of TTTS offers the best chance to improve fetal outcomes. For first-trimester diagnosis, the evidence supporting the value of nuchal translucency thickness or crown-rump length discordancy for predicting adverse obstetric outcomes such as TTTS is conflicting. Kagan and coworkers (2007) noted a positive correlation for these measures and later development of TTTS. In contrast, one multicenter study found that first-trimester discordancy in nuchal translucency and crown-rump length measurements did not predict adverse obstetric or neonatal outcomes (Allaf, 2014b). However, this same study group did find that early second-trimester sonographic examination showing abdominal circumference and estimated fetal weight discordance may be associated with an increased risk of subsequent adverse obstetric outcome (Allaf, 2014a).

Fetal echocardiography is recommended in all MCDA twins at 20 to 24 weeks' gestation. This is because the risk of cardiac anomalies is increased ninefold in these twins compared with general-population singletons. The prevalence of congenital cardiac anomalies has been reported to be 2 percent in otherwise uncomplicated MCDA gestations. In cases of TTTS, the prevalence is 5 percent, and a greater prevalence is seen in recipient fetuses (Bahtiyar, 2007). Functional fetal echocardiography may be valuable to detect subtle cardiac signs that can guide intervention timing and the overall management strategy for TTTS.

Treatment options for TTTS include selective fetal reduction, amnioreduction, amniotic septostomy, and laser photocoagulation of the surface placental anastomoses (Moise, 2005; Saade, 1998; Senat, 2004). Of these, amnioreduction uses paracentesis to pierce the uterus and amniochorion and allow excess amniotic fluid to be removed. Associated risks with this technique are preterm premature rupture of the membranes (PPROM), infection, placental abruption, preterm delivery, and neurologic complications in survivors.

With amniotic septostomy, a fetoscope and associated laser are placed transuterine. The laser creates a sizable window in the intervening amnion wall that separated MCDA twins to allow fluid equalization between the sacs. With this procedure, survival rates of 18 to 83 percent for both twins and rates of 80 percent for at least one twin have been reported (Moise, 2005).

With laser photocoagulation, a fetoscope is introduced transuterine under sonographic guidance via a 9F to 12F ported vascular catheter. Once anastomoses are identified, a diode or neodymium-doped yttrium aluminum garnet (Nd:YAG) laser and a 400- or 600-micron fiber are introduced to ablate surface placental vessel anastomoses (Fig. 16-2). This procedure is most commonly performed under local anesthesia.

Several randomized trials and reviews have examined neonatal outcomes with these procedures. First, in one trial, amnion septostomy and serial amnioreduction were compared, and fetal outcomes were similar between the groups (Moise, 2005). Another randomized trial compared amnioreduction with laser

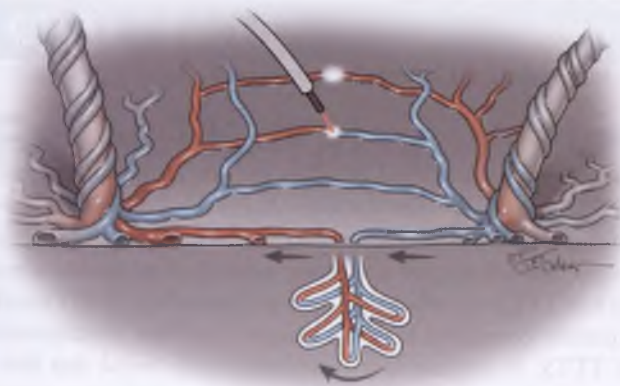


FIGURE 16-1 Twin-twin transfusion syndrome. This image shows the vascular equator in more detail, and in the foreground an arterio-venous anastomosis is depicted in cross section. With fetal therapy, laser energy coagulates the anastomoses along this equator.

photocoagulation and found similar obstetric complications. However, laser therapy offered a significantly higher survival rate and fewer reported neurologic abnormalities in survivors (Senat, 2004). One subsequent Cochrane review also compared laser therapy and septostomy. These authors found no differences in the overall death rate or in the death of at least one fetus per pregnancy (Roberts, 2014). Moreover, treatment groups did not differ in the death rates of both twins in a given pregnancy. However, more children were alive *without* neurologic abnormality at age 6 years in the laser group compared with the amnioreduction group. Of children that were alive at 6 years *with* major neurologic abnormalities, the number from each treatment group was similar. Notably, death outcomes in this 2014 update differ from the previous 2008 Cochrane review. In the earlier review, rate improvements in perinatal death and death of both fetuses per pregnancy were found in the laser intervention arm (Roberts, 2008). Despite the lack of effect on the death rate, the authors of the newer review conclude that endoscopic laser coagulation of anastomotic vessels should continue to be considered in the treatment for all stages of TTTS due to improve neurodevelopmental outcomes (Roberts, 2014).

In an attempt to standardize nomenclature for this condition, Quintero and colleagues (1999) classified TTTS progression into five stages based on the degree of fetal compromise (Table 16-1). Few programs offer intervention for stage I. Most consider laser photocoagulation only for Quintero stage II or higher stages, or stage I with extenuating circumstances that include rapidly worsening hydramnios or signs of impending cardiac compromise. The gestational age beyond which laser photocoagulation should not be offered also varies between programs. Some centers do not offer this therapy after 24 weeks' gestation, whereas others use thresholds of 25 or 26 weeks. There has recently been a call to consider offering laser therapy between 17 weeks' and 26 weeks' gestation based on data suggesting equivalent outcomes (Baud, 2013). This has however not been universally adopted, and further research is awaited.

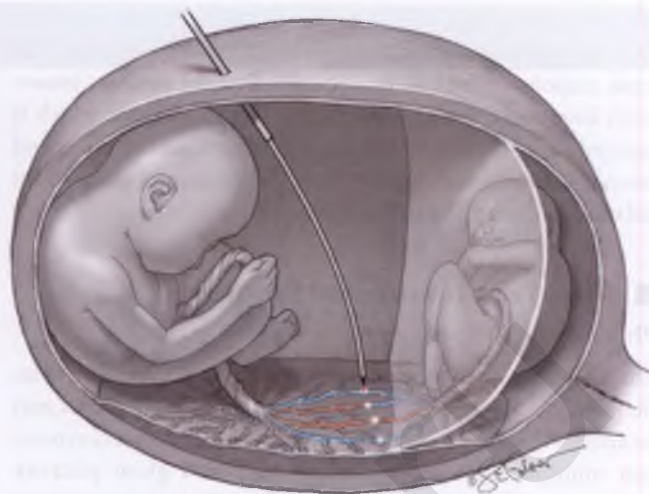


FIGURE 16-2 In this image, the recipient twin (*left*) lies within a hydramnios-expanded sac, while the donor twin (*right*) is "stuck" against the uterine wall. The fetoscope is seen crossing the uterine wall and is positioned inside the uterus, over the vascular equator, and between the two cord insertions.

Laser Ablation Technique

Different surgical techniques have been proposed for performing fetoscopic laser ablation. Initially, nonselective laser coagulation of placental vessels was performed, and any vessels that crossed the intertwin membrane, that is, along the *membranous*

TABLE 16-1. Quintero Classification System for Twin-Twin Transfusion Syndrome

Stage	Classification
I	Amniotic fluid volume is discordant: oligohydramnios with a maximum vertical pocket (MVP) ≤ 2 cm in one sac and hydramnios in other sac (MVP ≥ 8 cm ²). The bladder of the donor twin is visible and Doppler studies are normal
II	Amniotic fluid volume is discordant. The bladder of the donor twin is not visible (during the length of examination, usually around 1 hour), but Doppler studies are not critically abnormal
III	Criteria above plus Doppler studies are critically abnormal in either twin and are characterized as abnormal or reversed end-diastolic velocities in the umbilical artery, reverse flow in the ductus venosus, or pulsatile umbilical venous flow
IV	Fetal ascites, pericardial or pleural effusion, scalp edema, or overt hydrops
V	One or both babies are dead

^aMost European centers use a cutoff of 10 cm for gestations older than 20 weeks. For presentations earlier than 18 weeks, cutoffs have not been agreed upon. Data from Quintero, 1999.

equator, were coagulated (De Lia, 1990). Alternatively, selective laser coagulation of placental vessels (SLCPV) identifies and coagulates only anastomoses that cross between the twins along the *vascular equator* (Ville, 1995). A variant SLCPV procedure coagulates the surface of the placenta to linearly connect ablated anastomotic sites and thereby create a physical separation of donor and recipient vascular territories (Chalouhi, 2011). This is known as *solomonization* or the *Solomon technique*. In a controlled trial, 274 gravidas with twins affected by TTTS were randomly assigned to traditional laser coagulation or to the Solomon technique. Laser coagulation of the entire vascular equator significantly reduced rates of twin anemia polycythemia sequence and of TTTS recurrence, but perinatal mortality and severe neonatal morbidity rates did not differ (Slaghekke, 2014). The superiority of the Solomon technique has also been reported in other studies (Ruano, 2013, 2014).

Of technical hurdles to laser photocoagulation, a completely anterior placenta limits where the fetoscope can be inserted and can thereby hinder straight-on viewing of vessels. Also, the semirigid fetoscope limits angling of the scope. Inadequate visualization of the vascular equator impedes satisfactory ablation of all anastomoses. In addition, as the angle of incidence between the fetoscope and the placental surface becomes more obtuse, laser energy becomes less effective. To overcome these obstacles, a midline laparotomy may be performed to allow the uterus to be exteriorized and the fetoscope to enter the posterior uterine wall (Deprest, 1998). Alternatively, an endoscope with a 70-degree lens can be coupled with intracannula laser deployment (Quintero, 2010). Our team also uses a laparoscopic-assisted approach. With this, a traditionally positioned laparoscope visually guides fetoscope insertion from the woman's dorsal flank and into the posterior uterus. Once inserted, the fetoscope can view anastomoses more directly (Shamshirsaz, 2015).

Similar to TTTS, *fetofetal transfusion syndrome (FFTS)* has been described in both dichorionic and monochorionic triplet gestations. FFTS may develop in 5 percent of dichorionic triplets, and in approximately 8 percent of monochorionic triplets (Blumenfeld, 2015). The perinatal demise in cases of early-onset FFTS in monochorionic-triamniotic or dichorionic-triamniotic triplet pregnancies is substantial. Laser photocoagulation of communicating anastomoses appears to improve neonatal survival rates but is technically more challenging and is potentially associated with lower success rates.

■ Lower Urinary Tract Obstruction

Lower urinary tract obstruction (LUTO) comprises a heterogeneous group of anatomic anomalies of the bladder neck. The two most common are posterior urethral valves, which are obstructing membranes in the proximal male urethra, and urethral atresia in either male or female fetuses (Gunn, 1995). Most urinary tract blockages are minor and not associated with significant morbidity (Wu, 2009). Complete obstruction, however, is associated with major consequences such as bladder dilation and hydronephrosis. If complete urethral obstruction develops before glomeruli are fully formed, renal dysplasia results (Kitagawa, 1999). Subsequent anhydramnios can lead to pulmonary hypoplasia and skeletal deformities.

Almost 45 percent of untreated cases with severe obstruction end in neonatal death (Makayama, 1986). LUTO should be confirmed postnatally to ensure an accurate diagnosis.

LUTO is commonly found during the sonographic fetal anatomic survey at 18 to 20 weeks' gestation. Typical findings include a dilated posterior urethra (keyhole sign), an enlarged bladder (megacystis), and unilateral or bilateral hydronephrosis with or without a cystic appearance of the renal parenchymal (cystic kidney disease). It has been diagnosed as early as 12 weeks' gestation. But, data are few, and the first-trimester diagnosis of LUTO requires further research (Byon, 2013).

A detailed sonographic examination is performed to exclude coexisting anomalies. For some cases, amnioinfusion may create an acoustic window to improve fetal anatomy viewing. Fetal gender should be confirmed, as a female fetus significantly increases the likelihood of complex malformations such as urethral atresia, persistent cloaca, or megacystis microcolon intestinal hypoperistalsis syndrome. Assessment of the fetal karyotyping is also offered to exclude aneuploidy. In our center, to ensure adequate tissue for karyotyping, we perform placental biopsy or fetal blood sampling rather than amniocentesis or, in cases of anhydramnios, fetal vesicocentesis. In addition, examination of fetal urine samples obtained by vesicocentesis may provide some information regarding the degree of renal impairment. Reference ranges for normal fetal urine have been developed, and prognostic values have been proposed for specimens collected between 18 and 22 weeks' gestation (Table 16-2) (Muller, 1996). However, the potential for predicting postnatal renal function using sodium, calcium, and β_2 -microglobulin indices was questioned in a 2007 systematic review of 23 studies (Morris, 2007).

More recently a review of 72 cases of LUTO concluded that fetal urinalysis before 23 weeks' gestation allowed distinction between three groups. These are: (1) fetuses with normal urine biochemistry for which fetal therapy should be discussed; (2) fetuses with abnormal urine biochemistry results that portend poor renal outcome, for which the benefit of fetal therapy is likely to be compromised; and (3) fetuses with urodigestive fistula (Abdennadher, 2014). In our center, we obtain urine

TABLE 16-2. Prognostic Urine Values for Selection of Fetuses for Prenatal Intervention

	Good Prognosis	Poor Prognosis
Sodium	<90 mmol/L	>100 mmol/L
Chloride	<80 mmol/L	>90 mmol/L
Osmolality	<180 mOsm/L	>200 mOsm/L
Calcium	<7 mmol/L	>8 mmol/L
Total protein	<20 mg/dL	>40 mg/dL
β_2 -Microglobulin	<6 mg/L	>10 mg/L

^aBased on the last urine specimen obtained by serial bladder drainage at 24- to 48-hr intervals between 18 and 22 weeks' gestation.

Data from Muller, 1996.

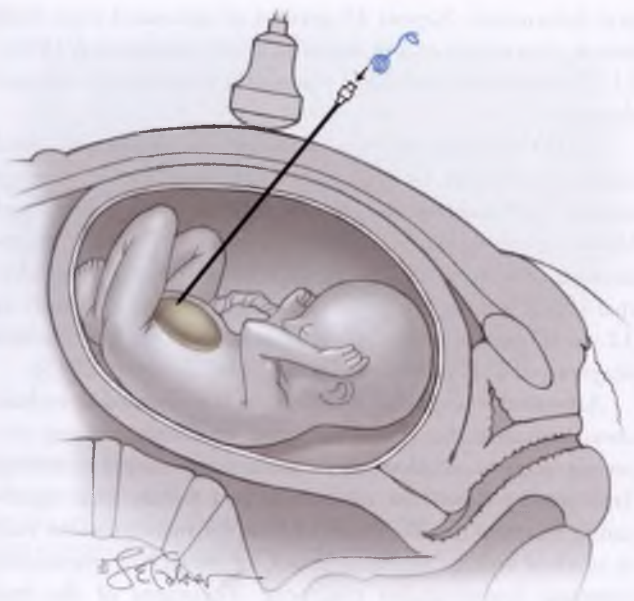


FIGURE 16-3 Insertion of a bladder shunt. In this image, a trocar is inserted into a distended fetal bladder under sonographic guidance. The double-pigtail catheter is about to be deployed down the trocar.

for biochemical testing as part of the initial evaluation that incorporates fetal karyotype, echocardiography, and full sonographic anatomic scan. If the initial biochemistry is favorable, vesicoamniotic shunting may be considered without a second specimen. If the results are unfavorable, a second specimen is obtained 48 hours later and tested. If still unfavorable, shunting is not recommended. In the future, proteomic and metabolomic evaluation of fetal urine and/or blood may offer better prognostic information, but this is not currently standard of care (Klein, 2013).

Antenatal intervention most commonly entails serial percutaneous fetal bladder drainage or placement of a double-pigtail vesicoamniotic shunt to relieve obstruction and thus prevent some or all sequelae. Using intravenous sedation and local anesthesia, shunt placement usually begins with amniocentesis into the amniotic cavity under sonographic guidance. This creates a space to aid visualization of the fetus and also provides sufficient room around the fetus for correct deployment of the shunt's external pigtail loop. With sonographic guidance, the maternal abdomen and then fetal abdomen and bladder are punctured using a needle or trocar, through which the double-pigtail catheter is passed (Fig. 16-3). The proximal end is positioned and curls within the fetal bladder, whereas the distal end is deployed in the amniotic space (Fig. 16-4). Complications with vesicoamniotic shunt are catheter displacement, catheter occlusion from thrombus material, procedure-related placental abruption, PPRM, preterm labor, and preterm birth. However, these are less common than open fetal surgery or fetoscopic procedures.

The Percutaneous Vesicoamniotic Shunting Versus Conservative Management for Lower Urinary Tract Obstruction (PLUTO) trial was performed to assess the effectiveness of vesicoamniotic shunting. Unfortunately, because of poor recruitment, this trial was stopped after only 31 patients were enrolled.

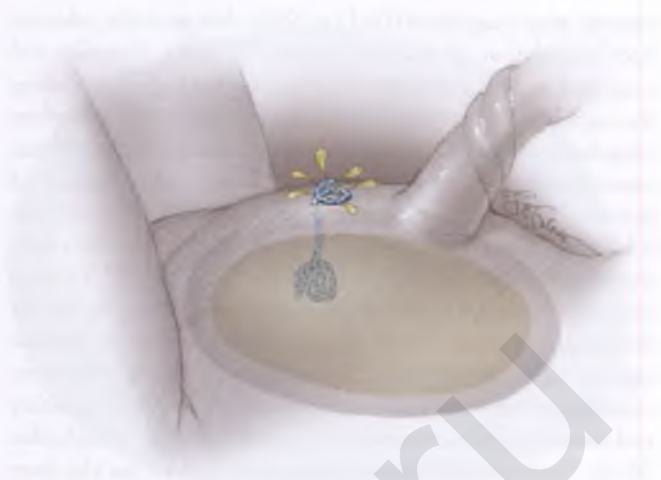

FIGURE 16-4 In this image, a double-pigtail catheter is in place. One end is coiled in the fetal bladder, and the other drains fetal urine into the amniotic sac.

Despite this small sample size, data showed that shunted fetuses had better survival rates than nonshunted fetuses. No conclusions could be made regarding the effects of vesicoamniotic shunting on long-term renal function (Morris, 2013).

As an alternative procedure, some investigators report ablation of posterior urethral valves using fetal cystoscopy combined with either mechanical or laser disruption of the posterior urethral valves (Ruano, 2015). Because of current equipment limitations and the potential for fistula formation following laser fulguration, this approach should be regarded as experimental (Sananes, 2015).

■ Thoracoamniotic Shunting

Fetuses with pleural effusion or fluid-filled, space-occupying chest lesions may be candidates for thoracoamniotic shunt placement. Physiologically, these two chest conditions increase hydrostatic pressure within the fetal thorax. Depending on severity, this may result in pulmonary hypoplasia or compression of the fetal heart that leads to cardiac decompensation and nonimmune hydrops.

Fetal Pleural Effusion

This fluid collection in the pleural space develops in 1 in 10,000 to 15,000 pregnancies. Pleural effusions can present as an isolated or primary finding or as a secondary complication of an associated fetal malformation or karyotypic abnormality. Most isolated pleural effusions reflect a chylothorax that results from abnormal drainage of lymph directly into the pleural space. With secondary pleural effusions, comorbid conditions include fetal aneuploidy, cardiac anomalies, congenital infection, lymphatic anomaly, anemia, congenital cystic adenomatoid malformation, bronchopulmonary sequestration, or congenital diaphragmatic hernia and have been reported in 25 to 75 percent of cases (Rustico, 2007). The two anomalies most commonly associated with pleural effusions are congenital diaphragmatic hernia and trisomy 21. Other chest pathology that must be considered includes tracheoesophageal fistula,

extralobar pulmonary sequestration, and congenital pulmonary lymphangiectasis.

Thus, careful diagnostic evaluation and patient selection are crucial. For this, a detailed sonographic fetal anatomic survey and echocardiography are essential, and fetal karyotyping is recommended (Achiron, 1995). Maternal blood type, antibody status, Kleihauer-Betke testing, and virology testing that screens for toxoplasmosis, rubella, and cytomegalovirus, herpes simplex virus, and parvovirus B19 infections are also recommended to exclude other potential causes of fetal hydrops. The National Institute for Health and Clinical Excellence (NICE) guideline (2006) on this topic states that invasive fetal therapy for fetal hydrothorax should be restricted to fetuses with isolated effusions resulting in hydrops. Some experienced clinicians have suggested intervention should be considered for cases of fetal hydrops with the pleural effusion as the likely etiology or for cases without hydrops but with an isolated pleural effusion that occupies more than 50 percent of the thoracic cavity, causes a shift in mediastinum, rapidly increases in size, or leads to hydramnios (Yinon, 2010). That said, we do not believe that intervention is helpful in nonhydropic fetuses with a unilateral pleural effusion.

Thoracentesis under sonographic guidance is generally the first approach and removes as much pleural fluid as possible. The fluid is assessed to identify chylothorax, and a high lymphocyte count, usually >80 percent, confirms this diagnosis. After fluid drainage, the degree of fetal lung reexpansion is assessed sonographically, and the lungs are simultaneously evaluated to exclude underlying structural abnormalities. Fetuses in whom the effusion rapidly reaccumulates may benefit from thoracoamniotic shunt placement.

Importantly, pleural fluid must be differentiated from a massive pericardial effusion, which in some cases can look similar. The size and shape of the lungs can help differentiate the two. Namely, massive pericardial effusion will compress and flatten the lungs against the posterior chest wall and cause them to appear very small. However, with a pleural effusion, the lungs are usually seen alongside the heart. The most common cause of massive pericardial effusion is right ventricular aneurysm (Hara, 2007). Attempting to drain either of these can be counterproductive. In most cases, unless cardiac function is compromised, massive pericardial effusion from an aneurysm can be expectantly managed and will usually resolve.

The technique for shunt placement for pleural effusion mirrors that for cystic masses, described next. For nonhydropic fetuses with isolated pleural effusion, in utero intervention is associated with a survival rate of 60 to 85 percent. For hydropic fetuses with pleural effusions, rates are 50 to 60 percent (Deurloo, 2007; Knox, 2006; Yinon, 2010). For nonhydropic fetuses, shunt placement in cases of isolated bilateral pleural effusion currently offers, at most, a small increase in survival rates (Knox, 2006).

Congenital Cystic Adenomatoid Malformation

Another congenital abnormality that may benefit from thoracoamniotic shunting is congenital cystic adenomatoid malformation (CCAM), also known as congenital pulmonary adenomatoid malformation (CPAM). A CCAM is a bronchopulmonary

malformation usually identified sonographically as an intrapulmonary mass commonly localized to one lung lobe. The differential diagnosis includes mediastinal teratoma, congenital diaphragmatic hernia, and bronchopulmonary sequestration. The incidence of CCAM ranges between 1 in 25,000 to 1 in 35,000 live births (Lalberge, 2001). These malformations lack normal alveoli but instead show excessive proliferation and cystic dilatation of terminal respiratory bronchioles. CCAMs are classified based on the sonographic size of the cyst(s) (Stocker, 1977). Macrocystic (Stocker type I) lesions contain at least one cyst measuring >5 mm, whereas microcystic (Stocker type III) lesions appear echogenic and lack visible cysts. Type II lesions are mixed.

Fetal Evaluation. During evaluation, fetal pulmonary lesions should be evaluated using color Doppler to differentiate CCAM from bronchopulmonary sequestration. This latter lesion is associated with systemic blood supply from an anomalous aortic vessel. Magnetic resonance (MR) imaging is also useful for imaging fetal chest masses. This modality can help to distinguish CCAMs from other intrathoracic lesions, to localize the lesion to a specific lobe, and to visualize the compressed normal lung (Hubbard, 1999). Fetal echocardiography assists in excluding cardiac anomalies and in evaluating cardiac function in fetuses with evolving or fulminant hydrops. Karyotyping is not indicated for CCAMs unless associated anomalies are present. Most fetuses with antenatally detected CCAMs have a good outcome. Microcystic CCAMs tend to regress spontaneously after a mass growth peak at 26 to 28 weeks' gestation (MacGillivray, 1993). Those CCAMs that remain small, do not contain cysts >1 cm, and do not demonstrate a mass effect within the chest at the time of a 32- to 33-week sonographic examination are unlikely to cause respiratory symptoms after birth. These can be expectantly managed. However, macrocystic lesions generally do not regress, as fluid accumulates in the cysts. Hydrops is the single best predictor of fetal death with CCAMs. Thus, with macrocysts, sonographic surveillance is performed one or two times weekly in fetuses to seek signs of hydrops and monitor changes in CCAM volume.

The CCAM volume ratio (CVR), a sonographically derived ratio, helps identify fetuses at risk for developing hydrops and who therefore require more frequent monitoring. The CCAM volume is measured by using the formula for an ellipse ($\text{length} \times \text{height} \times \text{width} \times 0.52$). A CVR is obtained by dividing the CCAM volume (mL) by the head circumference (cm) to correct for differences in fetal gestational age. A CVR ≤ 1.6 correlates with a 94-percent survival rate and a less than 3-percent risk of developing hydrops (Crombleholme, 2002). Investigations are ongoing to determine whether cardiovascular function assessment, such as calculation of combined cardiac output, may also help identify fetuses at risk for hydrops (Mahle, 2000).

Choosing an appropriate candidate with a macrocystic CCAM for thoracoamniotic shunt placement remains challenging. CCAMs with a large, dominant cyst have responded favorably to thoracoamniotic shunt placement. Shunt placement in hydropic fetuses with macrocystic CCAMs can promote hydrops reversal (Adzick, 1998; Grethel, 2007; Smith, 2005). Thus, shunting should be considered for hydropic fetuses with

macrocytic lung lesions. This is especially true for fetuses with very large lung lesions that enlarge rapidly or are associated with fetal cardiac compromise or hydramnios (Schrey, 2012). At present, the benefit and safety of thoracoamniotic shunt in fetuses with macrocytic lesions and no hydrops is unclear. In fetuses with a chest mass and hydrops, our group has noted that unless the hydrops is associated with cardiac decompensation, intervention may also be unnecessary (Cass, 2012). We administer betamethasone to women whose fetus has a large, high-risk CCAM. Some data suggest that between two and four courses of betamethasone may help improve survival rates in these high-risk cases. Although the mechanism is unclear, steroids may induce CCAM regression or bolster fetal tolerance of associated hydrops (Derderian, 2015).

Thoracoamniotic Shunting Technique. As part of the selection process prior to shunting, initial macrocyst needle drainage allows the percent decline in mass volume to be measured. This correlates with the lung volume gained if the cyst were chronically drained. Prior to needle insertion, color-flow Doppler is used to identify an avascular zone between the fetal chest wall and the dominant macrocyst. Once positioned at the thoracic wall, a 22-gauge needle is sonographically guided into the center of the dominant macrocyst. Observation of cyst decompression helps determine the optimal position for a shunt should the macrocyst reappear. Sonographic chest reevaluation is done 2 to 3 days after this aspiration to look for reaccumulation (Adzick, 1998).

With macrocyst redevelopment, shunt insertion is performed under ultrasound guidance. Steps are similar to LUTO shunt placement (p. 263). To optimize shunt positioning, careful consideration is given to the previously observed pattern of cyst involution during drainage. For shunt placement in the left fetal thorax, the shunt ideally enters the fetal chest at the superior and lateral left aspect of the macrocyst to encourage upward and lateral involution of the cyst. Moreover, shunt insertion in the fetal midclavicular line is discouraged as shunt displacement can potentially interfere with normal restoration of mediastinal structures.

Complications of shunt placement include catheter displacement, shunt occlusion from thrombus material, and procedure-related placental abruption, PPROM, preterm birth, or fatal fetal hemorrhage (Smith, 2005). Two rare postnatal insertion complications include rib deformities at the shunt placement site and fetal arm constriction by an encircling catheter (Belfort, 2016; Merchant, 2007).

Thoracoamniotic Shunting Fetal Outcomes. The overall neonatal survival rate after shunt placement in macrocytic CCAMs is 65 to 79 percent (Cavoretto, 2008; Peranteau, 2007). One systematic review of macrocytic CCAMs showed an improved survival rate of 62 percent (15/24) in treated hydropic fetuses compared with 3 percent (1/33) in those untreated (Cavoretto, 2008). Survival is strongly associated with hydrops resolution following catheter placement. Newborns may require prolonged ventilator support, extended neonatal intensive care unit (NICU) stays, urgent lesion resection in the first days of life, chest tube placement to correct respiratory compromise,

and extracorporeal membrane oxygenation (ECMO) support. It seems that in surviving neonates, thoracoamniotic shunt placement combined with postnatal resection of the congenital lung lesion can minimize the deleterious effect of pulmonary hypoplasia associated with a large intrathoracic mass during development. Resection also addresses associated risks of recurrent infection, pneumothorax, and malignancy (MacGillivray, 1993). Of other intervention for CCAM, the use of interstitial laser for microcystic CCAM lesions cannot currently be supported (Peranteau, 2007; Ruano, 2012a). In cases with a fetal lung mass and hydrops at gestational ages too preterm to allow delivery, open fetal surgery has been described. Survival rates range from 50 to 60 percent (Adzick, 2010; Cass, 2011). Given the highly complex nature of these experimental surgeries, they should only be performed in appropriate centers.

■ Congenital Diaphragmatic Hernia

The incidence of congenital diaphragmatic hernia (CDH) varies from 1.7 to 5.7 per 10,000 liveborn infants (Torfs, 1992). Abdominal contents within the thoracic cavity during critical development of bronchi and pulmonary arteries leads to diminished bronchiolar branching, decreased overall arterial cross-sectional area, and abnormal, thickened muscular walls of peripheral pulmonary arteries (Miniati, 2007). This abnormal pulmonary development results in pulmonary hypoplasia and pulmonary hypertension. There are three types of CDHs. The most common defect occurs in 70 percent of cases and involves the posterolateral (Bochdalek) region of the diaphragm. The second most frequent defect affects the anterior region in 25 to 30 percent (Morgagni), whereas those in central regions compose 2 to 5 percent of cases (Torfs, 1992).

Prenatal diagnosis of CDH is based on several classic sonographic findings. These are abdominal organs (stomach, intestines, liver) seen within the thoracic cavity, displacement of the heart to the hemithorax contralateral to the defect, cardiac axis shift, and hydramnios. MR imaging is useful to confirm the diagnosis of CDH in cases of equivocal sonographic findings.

Between 26 and 58 percent of fetuses with CDH have additional unrelated anomalies that may or may not be associated with a genetic syndrome. Thus, genetic counseling and amniocentesis are offered. Associated anomalies include cardiac, renal, central nervous system (CNS), and gastrointestinal malformations (Holder, 2007). Such cases preclude fetal therapy because of their inherent poor survival rate.

During the past 30 years, the overall survival rate of neonates with isolated CDH has increased from 50 to 80 percent (Skari, 2000). This is primarily attributable to significant advances in postnatal respiratory support (Downard, 2003). Antenatal intervention is generally offered to only the most severe cases with the worst prognosis as predicted by lung measurements and by organ position seen with sonography and MR imaging.

In the late 1980s, anatomic surgical repair was first employed (Estes, 1992; Harrison, 1990). However, for fetuses *without* liver herniation, surgery did not improve survival rates compared with fetuses who were managed expectantly (Harrison, 1997). Conversely, for fetuses *with* liver herniated into the thorax, prenatal reduction of the liver acutely kinks umbilical venous

return, leading to fetal death (Harrison, 1993). These observations put a temporary end to open fetal surgery programs.

Current minimally invasive techniques aid reexpansion of lung compressed by abdominal viscera. This reexpansion helps deflect abdominal contents back into the abdominal cavity and promote lung development. One such approach, reversible tracheal occlusion, allows fluid normally produced by the lung to accumulate (Fig. 16-5) (Deprest, 2004). Expansion of the fetal lungs and lung tissue stretch lead to improved pulmonary growth and development.

In the first randomized trial of percutaneous fetal endoscopic tracheal occlusion (FETO), fetuses with severe left-sided CDH were randomly assigned to FETO or to standard care. No benefit was observed due to an unexpected high survival rate in the expectantly managed group (Harrison, 2003). In Europe, the FETO Task Force subsequently reported that FETO in 201 patients was complicated by PPRM within 3 weeks in only 17 percent of cases (Jani, 2009). On the basis of stratified data from the prenatal CDH registry, FETO therefore increased survival rates in severe cases with left-sided CDH from 24 to 49 percent, and in right-sided CDH from 0 to 35 percent (Jani, 2006). In a more recent trial, 41 fetuses with severe fetal CDH were randomly assigned to FETO or to standard postnatal management. Fifty percent of fetuses in the FETO group survived to age 6 months, whereas only 4.8 percent in the postnatal treatment group lived to this age (Ruano, 2012b). It should be noted that in this trial ECMO was unavailable for either group. The efficacy of FETO remains inconclusive. Thus, it is still considered experimental and should only be performed under a monitored research protocol.

FETO is usually offered before 29 weeks' gestation and commonly between 24 and 28 weeks (Deprest, 2011). The procedure can be completed under general, combined spinal-epidural, or local maternal anesthesia. Sonographic examination determines fetal and placental position to guide optimal trocar insertion. When necessary the fetal position is altered by gentle external manipulation to achieve better access to the trachea and to allow trocar insertion in the upper half of the uterus.

The fetal trachea is accessed percutaneously by placing a trocar into the uterus close to the fetal mouth. A 1.3-mm fetoscope is then introduced into the uterus through the trocar and navigated into the fetal mouth, down the larynx, and through the vocal cords until the carina is visualized. A detachable occlusive balloon is introduced through a channel in the fetoscope and is then inflated and detached just above the fetal carina to block the trachea (Fig. 16-6).

At 34 weeks' gestation, reversal of occlusion is ideally performed by fetoscopy and sonographic guidance. The balloon

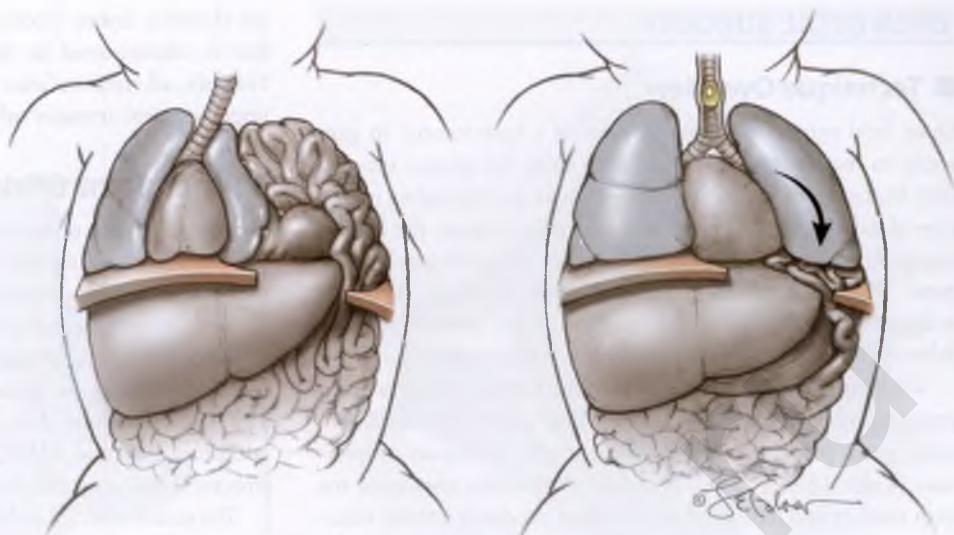


FIGURE 16-5 Fetoscopic endoluminal tracheal occlusion (FETO). The left image shows a left-sided congenital diaphragmatic hernia. In the right image, the endotracheal balloon has been deployed. The blocked trachea allows normal lung fluid to accumulate and expand the lungs.

is first punctured, and the usually high thoracic pressure then flushes it out into the amniotic cavity. Here, it is grasped and removed. This timing helps increase the number of type II pneumocytes (Flageole, 1988). Subsequent delivery can occur according to obstetric principles. In the event that the patient labors before the balloon has been removed, an ex-utero intrapartum treatment (EXIT) procedure is required. This treatment is described on page 272 and maintains fetoplacental circulation while the tracheal obstruction is relieved. In rare cases, a balloon has postnatally been removed or deflated emergently by direct laryngoscopy or percutaneous puncture.

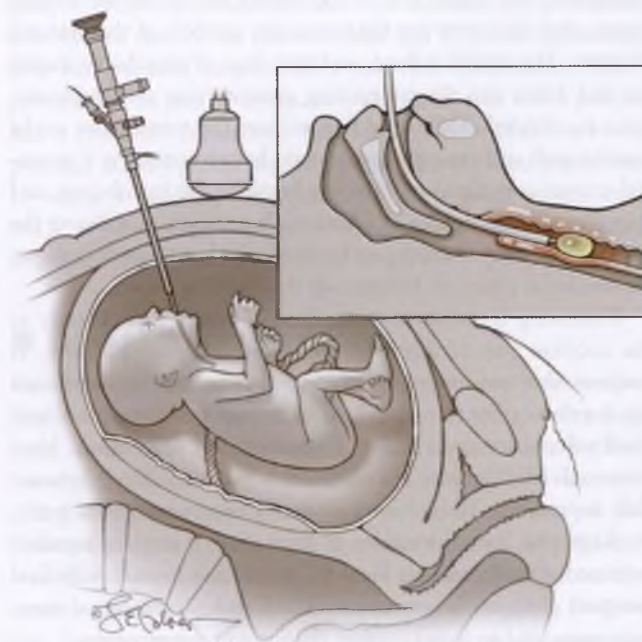


FIGURE 16-6 In this image, the fetoscope enters the fetal larynx and advances down the trachea. Inset: The balloon is inflated and then detached from the endoscope. It remains to occlude the trachea.

OPEN FETAL SURGERY

■ Technique Overview

Open fetal surgery refers to creation of a hysterotomy to gain access to the fetus with the intent to close the uterine incision after fetal surgery to continue the pregnancy. Depending on the type of fetal surgery planned and fetal presentation, the hysterotomy may be made in either the upper or lower uterine segment. This differs from an EXIT procedure, in which the uterus is opened, a procedure is performed with the neonate partially delivered, but then obstetric delivery is completed.

With open fetal surgery, oral indomethacin (50 mg) is given preoperatively for tocolysis. Intravenous antibiotics similar to those given prior to cesarean delivery offer infection prophylaxis (Table 18-4, p. 296). Sevoflurane provides anesthesia for both mother and fetus, and also induces necessary uterine relaxation to prevent intraoperative uterine contractions. Under most circumstances, a low transverse maternal laparotomy incision is performed. Sterile intraoperative sonography with the transducer placed directly on the uterine serosa delineates both the fetal and placental positions. If necessary, the fetus is manipulated by operator hands placed inside the laparotomy but on the exterior of the uterus. The fetus is maneuvered into an appropriate presentation and position for the intended procedure prior to opening the uterus.

The hysterotomy is aided by two absorbable monofilament sutures positioned outside of but parallel to the intended incision site. Under sonographic guidance, these full-thickness suture bites are placed through the uterine wall and thereby plicate the membranes to the myometrium to limit chorioamniotic separation. The myometrium is incised between the sutures. The lower jaw of a uterine stapler is then introduced directly into the amniotic cavity using a piercing attachment on this lower jaw. Thus, once positioned, the upper jaw of the stapler lies across the uterine serosa, and the lower jaw lies across the amnion of the planned incision. The stapler is fired, and two lines of absorbable staples are laid down and the intervening myometrium and chorioamnion are divided. This staple line anchors the membranes to the uterine wall and creates a hemostatic hysterotomy. As a potential serious complication, bleeding between the membranes and uterine wall, leading to a subchorionic hematoma, can dissect the membranes away from the uterine wall. Early recognition allows sutures to be placed to tamponade the bleeding vessels.

Following hysterotomy, the fetus is positioned directly at the incision site, ideally with only minimal manipulation. A catheter that continuously infuses warm saline is placed into the uterine cavity to maintain fetal temperature and amniotic fluid volume for umbilical cord compression prevention. Also, maternal–fetal general anesthesia is a potential fetal myocardial depressant. Thus, we recommend continuous fetal echocardiographic monitoring for all fetal surgery cases to monitor myocardial performance. Fetal bradycardia is treated with fetal position changes, increased amnioinfusion, or maternal measures provided to boost cardiac output and oxygenation.

With surgery completed, the fetus is returned to the uterus. Warmed Ringer lactate solution containing antibiotics is instilled into the amniotic cavity, and the uterine and abdominal incisions

are closed in layers. Tocolysis with intravenous magnesium sulfate is administered as the mother emerges from anesthesia. Notably, all mothers who have had open fetal surgery with an upper segment incision subsequently require cesarean delivery.

■ Open Spina Bifida

Open spina bifida or myelomeningocele (MMC) is a congenital CNS defect resulting from incomplete neural-tube closure and is characterized by protrusion of the meninges and spinal cord through open vertebral arches (Fig. 16-7). Patients with MMC are often limited by mental retardation, bowel and bladder dysfunction, orthopedic disabilities, and lifelong paralysis (Meuli, 1997). Neural-tube defects (NTDs), including anencephaly, encephalocele, and MMC, are the most common congenital structural defects world-wide.

The neural damage in MMC may primarily result from defective spinal cord development. A secondary event stems from damage to the exposed spinal cord. With this *two-hit hypothesis*, primary congenital abnormalities in anatomic development allow a relatively normal spinal cord to become secondarily damaged by amniotic fluid exposure, direct trauma, hydrodynamic pressure, or a combination of these factors (Meuli, 1997). It is this secondary damage that may be ameliorated by early surgical repair. This theory is supported by the observation that only half of affected fetuses have ventriculomegaly before 24 weeks' gestation, but more than 90 percent develop ventriculomegaly by term (Babcock, 2011). This hypothesis also provides the rationale for trying to close the defect at midgestation. Further neurologic damage can occur postnatally from additional surgeries required to replace a malfunctioning or infected ventriculoperitoneal shunt. Thus, any treatment that reduces the need for ventriculoperitoneal shunting would also improve outcome.

As an overview, open fetal surgery for MMC requires access to the fetal lumbosacral neural defect. An elliptic skin incision surrounds the defect and is carried down to the level of the fascia (Fig. 16-8). The dura mater is brought to the midline to cover the exposed neural tissue and is reapproximated with a running suture line (Fig. 16-9). Last, the skin is closed.

To evaluate efficacy, the Management of Myelomeningocele Study (MOMS) trial compared prenatal versus postnatal MMC repair in patients at 19^{0/7} weeks to 25^{6/7} weeks' gestation. All babies had confirmed euploid karyotype and an MMC located between T1 and S1 with evidence of hindbrain herniation (Adzick, 2011). Actual rates of shunt placement were 40 percent in the prenatal surgery group and 82 percent in the postnatal surgery group. Prenatal surgery improved the composite postnatal score for mental development and motor function at 30 months. It also benefited several secondary outcomes that included hindbrain herniation by 12 months and ambulation by 30 months of age. Specifically, at 12 months, the proportion of infants who had no evidence of hindbrain herniation was higher in the prenatal surgery group (36 percent) than in the postnatal surgery group (4 percent). Those children who had prenatal surgery were significantly more likely to have motor function one or two or more levels better than predicted by the level of the neural lesion and had significantly better Bayley Psychomotor Development Index and Peabody Developmental

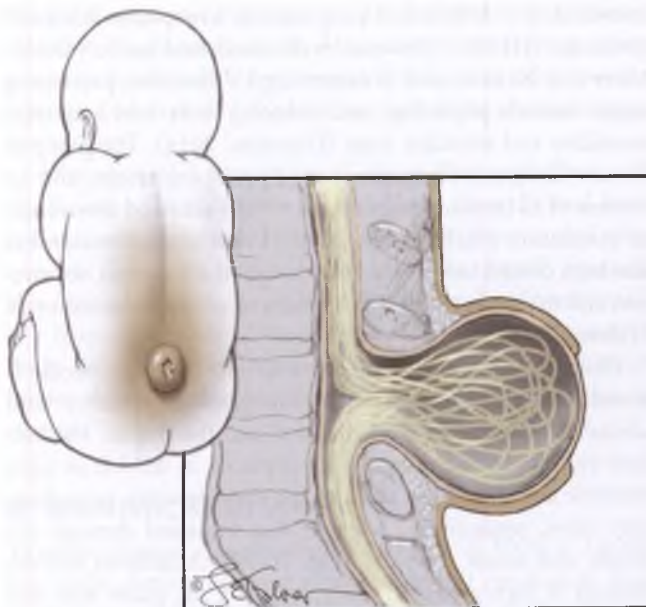


FIGURE 16-7 This image details fetal cystic meningocele anatomy.

Motor Scales scores. Compared with the postnatal group, twice as many children in the prenatal surgery group were walking independently and fewer were not walking at all. Prenatal intervention also lowered rates of brainstem kinking, abnormal fourth-ventricle location, and syringomyelia.

However, in this study, prenatal surgery was associated with an increased risk of preterm delivery and uterine dehiscence at

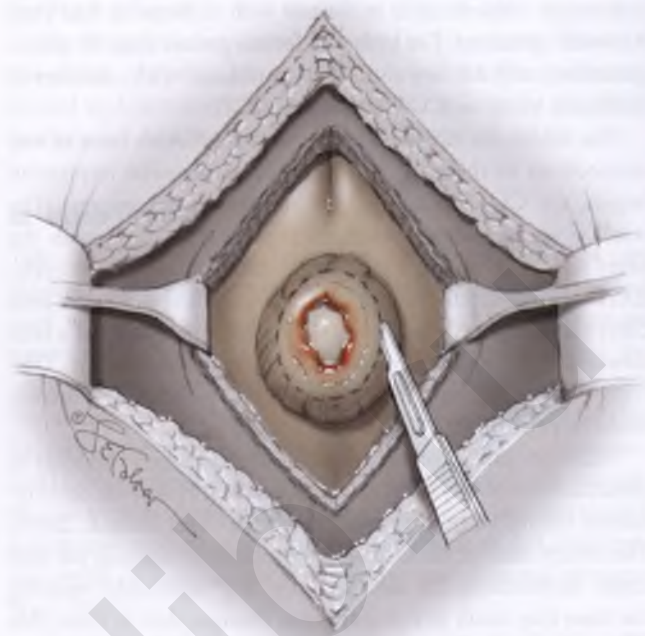

FIGURE 16-8 Open fetal surgical repair of a myelomeningocele. In this image, retractors hold back the laparotomy and hysterotomy edges. A sharp incision is made around the neural-tube defect to release the neural placode from the arachnoid mater.

delivery. Most of the antenatal treatment group delivered preterm, and 13 percent were born before 30 weeks' gestation, 33 percent at 30 to 34 weeks, and 33 percent at 35 to 36 weeks. Other adverse consequences of antenatal surgery included maternal pulmonary edema, placental abruption, oligohydramnios, PPRM, spontaneous labor, and maternal blood transfusion. At the time of the cesarean delivery, 25 percent of women who had prenatal surgery had a very thin hysterotomy site, 9 percent had an area of dehiscence within the site, and 1 percent had a complete dehiscence. In addition, more children in the prenatal surgery group required surgery for tethered spinal cord (8 versus 1 percent) (Adzick, 2011). As a result of this trial, MCC repair can be recommended for women who understand the benefits and risks of this fetal surgery.

■ Lung Lesion Resection

Rarely, some fetuses with a lung mass may benefit from open fetal surgery. One possible candidate is the fetus with a huge lung mass that develops progressive nonimmune hydrops associated with cardiac failure. This contrasts with the fetus with a large lung mass plus an isolated chylothorax or a mass plus hydrops without specific signs of cardiac failure (Cass, 2011). A second excision candidate is a fetus with a huge lung mass that creates a mediastinal shift and compresses developing lung tissue. As described on page 264, thoracoamniotic shunting may be performed and preferred for CCAMs with a large predominant cyst. Open fetal surgery strives to decompress or resect a cystic mediastinal lesion. It is reserved for fetuses with massive

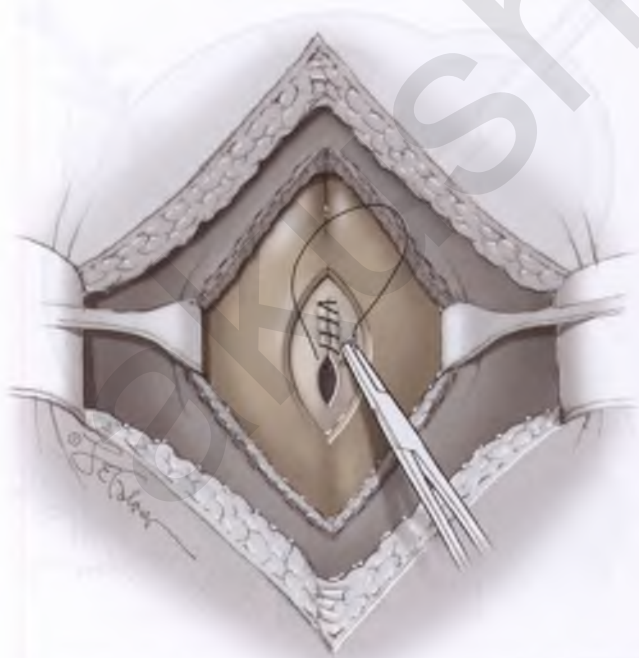


FIGURE 16-9 In this image, the dura mater is sutured closed. To complete the repair, the fetal skin is then reapproximated. Not shown here, closure of the maternal hysterotomy and laparotomy incisions completes the procedure.

multicystic, predominantly solid CCAMs or for bronchopulmonary sequestration in fetuses with hydrops at less than 32 weeks' gestation. For hydropic fetuses greater than 32 weeks' gestation, early delivery should be considered with resection of the lesion using an EXIT strategy (p. 272).

The reason for EXIT is that very large CCAMs have airway connections to the bronchial tree. When neonatal respiration begins, the CCAM fills with air but cannot decompress. The result is an expanding intrathoracic mass that compresses the heart and behaves like a tension pneumothorax. Preventively, EXIT maintains fetoplacental circulation. Meanwhile, the fetal chest can be opened, the lung can be decompressed, and a fetal airway can be established to allow neonatal respiration. The fetus is then delivered and transported to another operating room to perform CCAM resection.

Although case numbers are small, results suggest benefits to prenatal thoracotomy with lung mass excision. Follow-up developmental testing has been normal in most survivors (Adzick, 2009). The abrupt relief of the cardiac compression by opening the fetal chest, exteriorizing the affected lung, and ultimately resecting the mass may result in hemodynamic changes akin to those that follow the emergency relief of pericardial tamponade, namely, fetal hemodynamic collapse and reactive bradycardia. Therefore, before fetal thoracotomy, our approach obtains fetal intravenous access, measures fetal blood gas values and hematocrit, and pre-treats the fetus with intravenous atropine and fluid volume.

OTHER POTENTIAL BENEFICIAL FETAL INTERVENTIONS

■ Critical Aortic Stenosis

Severe aortic stenosis usually presents in midgestation with an enlarged left ventricle (LV) and severe LV dysfunction. If

untreated, LV dysfunction progresses to hypoplastic left heart syndrome (HLHS). However, well-timed fetal aortic valvuloplasty may be successful in preserving LV function, preventing single-ventricle physiology, and reducing short- and long-term morbidity and mortality rates (Donofrio, 2014). The group at Boston Children's Hospital reported promising results, and 43 percent of all liveborn neonates ($n = 100$) achieved biventricular circulation (McElhinney, 2009). Prenatal intervention has also been conducted in fetuses with right outflow tract obstruction and in fetuses with HLHS from a restrictive foramen ovale (Tulzer, 2002).

Once the fetus is motionless, a 17- to 19-gauge needle is introduced transuterine under sonographic guidance and advanced between the fetal ribs and into the thorax. For balloon valvuloplasty, the needle tip is placed in the left or right ventricle and directly in front of the stenotic aortic or pulmonary valve, respectively. A guide wire is passed through the needle and across the valve (Fig. 16-10). A deflated balloon catheter is then advanced along and over the guide wire and positioned such that it straddles the stenotic valve. The balloon diameter is inflated three- to fivefold to reach a predetermined valve aperture diameter (Fig. 16-11).

For cases with an intact interatrial septum that results from a restrictive foramen ovale, the needle is placed into the right atrium. It is advanced across the atrial septum into the left atrium. A guide wire is placed into the atrium, and one of two procedures may then be performed. First, a balloon catheter can be threaded along the guide wire to lie across

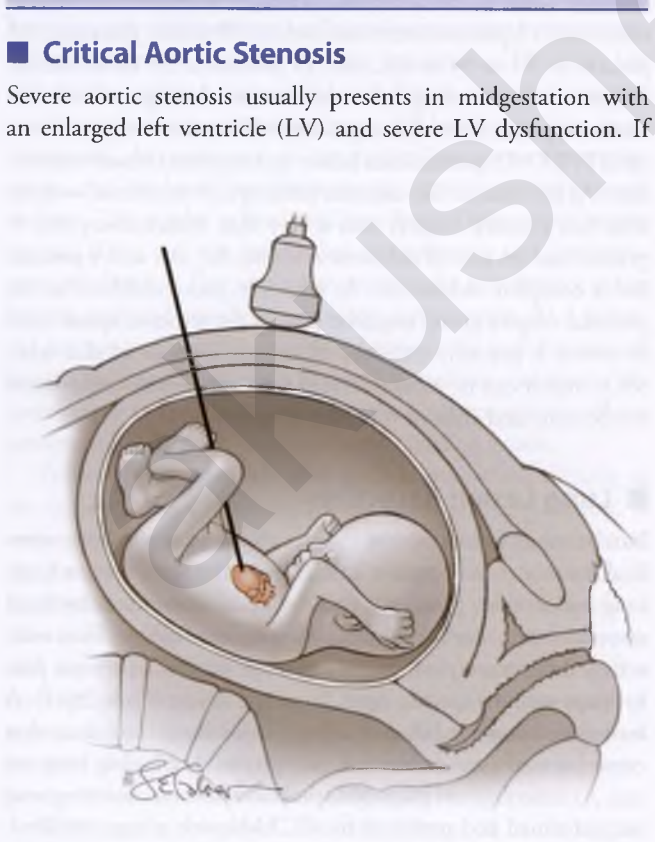


FIGURE 16-10 Percutaneous valvuloplasty. In this image, the needle enters the fetal heart using sonographic guidance.

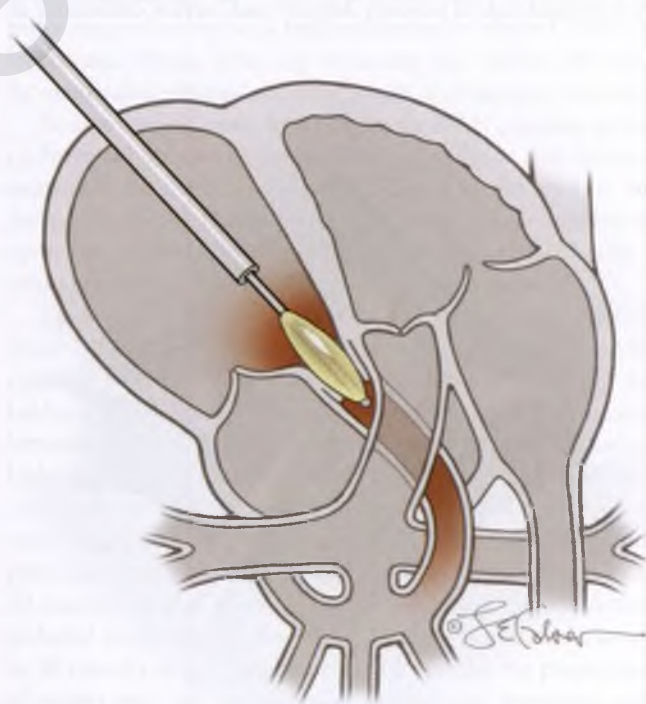


FIGURE 16-11 In this image, the needle lies inside the left ventricle of the fetal heart and is advanced to the aortic valve. A guidewire, followed by a balloon catheter is then passed across the stenosed valve and positioned to traverse the annulus. The balloon is then inflated to perform the valvuloplasty. Notably, the left ventricle is dilated, which is a common early finding in severe aortic stenosis and precedes development of hypoplastic left heart syndrome.

the point of septal constriction. The balloon is then dilated to widen the foramen ovale. Alternatively, a coronary artery stent can be threaded over the guide wire, situated across the septum, and deployed to create an indwelling channel across the septum.

After successful completion of any of these procedures, the needle and balloon catheter are withdrawn from the fetal heart and maternal abdomen. In most cases, a fetal pericardial effusion will develop. If this causes bradycardia or rapidly expands, it is drained using a 22- or 20-gauge needle. Fetal bradycardia is a frequent sequela of these procedures. Thus, resuscitation drugs that include epinephrine, atropine, calcium, and bicarbonate should be ready for fetal intracardiac administration as needed.

■ Amniotic Band Syndrome

This rare prenatal complication occurs in 1 in 3000 to 15,000 live births. Amniotic band syndrome (ABS) can lead to fetal death from umbilical cord strangulation. It can also create congenital limb deformity or loss, presumably caused by ischemia from constriction bands that interfere with vascular perfusion (Fig. 16-12) (Garza, 1988). The underlying causative factors and the pathophysiology of amniotic bands remain unclear. Membrane rupture, either spontaneous or iatrogenic, appears to account for most cases, but congenital anomalies of the amniotic membranes have also been implicated (Sentilhes, 2004).

Fetoscopic release of amniotic bands with minimally invasive surgery has been performed and may allow preservation

of life and/or limb function in cases of ABS. When possible, bands are released by laser or scissors (Fig. 16-13).

The acceptable functional outcome in 50 percent of cases is reassuring. However, more experience and further studies are needed to determine selection criteria that will justify the risk of this invasive in utero therapy for ABS (Javadian, 2013).

■ Vasa Previa

This rare pregnancy complication may be classified as two types. Type 1 vasa previa describes a velamentous umbilical cord insertion that gives rise to fetal blood vessels that are supported only by membranes and that traverse across the internal cervical os. Type 2 describes fetal vessels that traverse the membranes between lobes of a bilobed placenta and that lie across the internal cervical os (Fig. 16-14) (Catanzarite, 2001). Vasa previa is associated with a high perinatal mortality rate from fetal exsanguination after vessel laceration during membrane rupture. Accurate prenatal diagnosis and appropriate timing of cesarean delivery can improve neonatal outcome (Lee, 2000).

Quintero and associates reported a few successful cases of intrauterine laser photocoagulation of type 2 vasa previa (Chmait, 2010; Johnston, 2014; Quintero, 2005). Our team performed in utero laser photocoagulation for type 2 vasa previa vessels at 29^{4/7} weeks' gestation (Fig. 16-15). Neonatal outcome was good (Hosseinzadeh, 2015a). We do recognize that this form of intervention has a limited scope and that the prenatal diagnosis and characterization of the vasa previa type and proportion of placenta affected must be carefully assessed.

■ Chorioangioma

This placental tumor is composed of an abnormal proliferation of blood vessels. Most are asymptomatic and usually escape clinical and sonographic detection, especially those measuring <4 cm in diameter. In contrast, those measuring >4 cm,

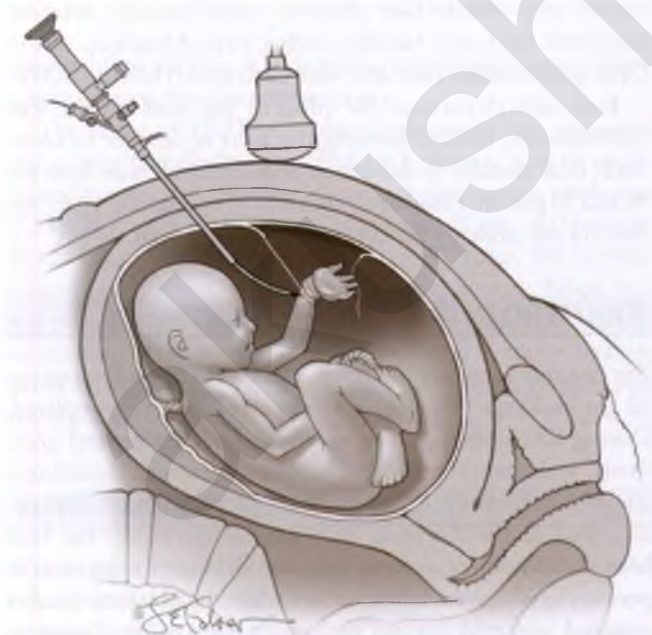

FIGURE 16-12 Amniotic bands. In this image, an amniotic band encircles and constricts the circulation in the fetal wrist. Under sonographic guidance, the fetoscope is inserted through the maternal abdominal wall and into the uterus and is positioned over the area of interest. Note the significant hand edema distal to the amniotic band.

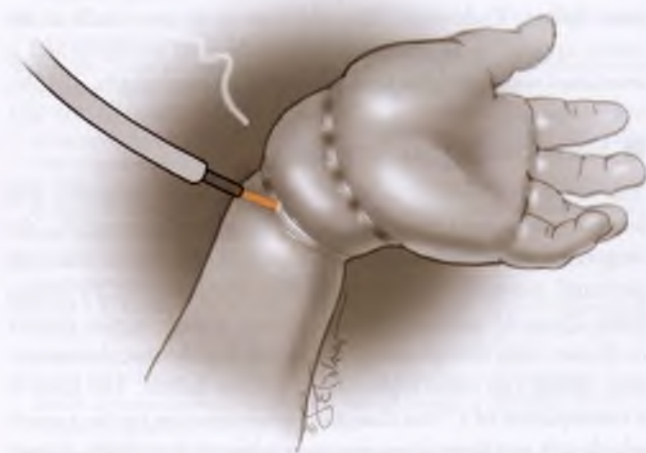


FIGURE 16-13 In this image, the laser can be used to cut the amniotic band and release the constriction. In some cases, microscissors can also be used to cut the band.

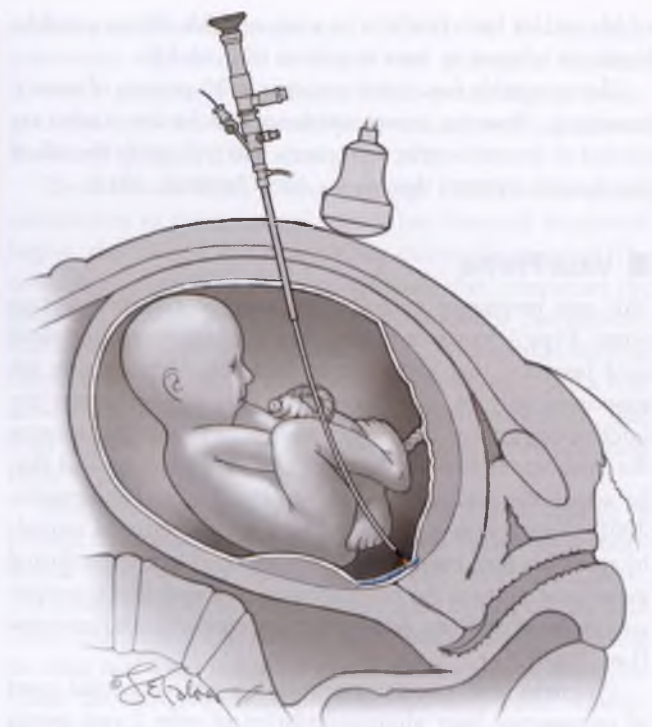


FIGURE 16-14 Fetoscopic laser ablation of vasa previa. In this image, an anterior placenta, succenturiate lobe, and vasa previa are shown. Under sonographic guidance, the fetoscope crosses the maternal abdominal wall and uterine wall and is positioned inside the uterus over the vasa previa vessels.

although rare, may be associated with adverse perinatal complications. A large chorioangioma may act as a peripheral arteriovenous shunt in the fetus that leads to high-output cardiac failure, disseminated intravascular coagulopathy, anemia and thrombocytopenia, cardiomegaly, and ultimately nonimmune hydrops. Other complications include hydramnios, premature delivery, and fetal growth restriction. The overall associated perinatal mortality rate with a large chorioangioma is 30 to 40 percent (Amer, 2010; Guschmann, 2003).

Several fetal therapeutic approaches have been employed to interfere with the vascular supply to the tumor and reverse fetal heart failure. Endoscopic laser ablation of feeder vessels to the tumor appears to be the most frequently used modality and is associated with favorable fetal outcomes (Hosseinzadeh, 2015b).

■ Sacrococcygeal Teratoma

This anomaly develops in 1 to 2 per 20,000 pregnancies. For fetal sacrococcygeal teratoma (SCT) diagnosed postnatally, the long-term outcome is excellent (Swamy, 2008). In contrast, the perinatal mortality rate of prenatally diagnosed SCTs ranges from 25 to 37 percent (Makin, 2006). Death occurs mainly in fetuses with fast-growing, solid, and highly vascular teratomas, which can cause high-output cardiac failure. The latter is a consequence of a “vascular steal” phenomenon by the tumor, which acts as a large arteriovenous malformation. High-output failure leads to hydramnios, hydrops, intrauterine fetal demise, and preterm birth (Benachi, 2006). Assessment of tumor size, growth rate, and fetal cardiac function allows the identification

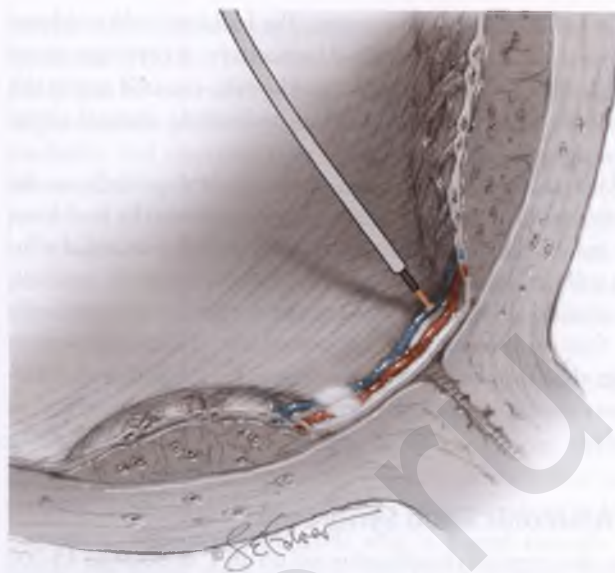


FIGURE 16-15 In this image, the laser ablates the vasa previa vessels both proximally and distally. This ensures hemostatic separation of the succenturiate lobe from the main placental disk.

of those fetuses at particular risk of decompensation (Langer, 1989; Rodriguez, 2011; Westerburg, 2000).

Large vascular fetal SCTs have uniformly dismal outcomes when associated with high-output failure and fetal hydrops before viability (Benachi, 2006; Wilson, 2009). This provides the rationale for fetal therapy for associated hydrops, and both minimally invasive and open fetal surgical approaches have been used. Minimally invasive surgeries occlude vascular flow to the tumors and include laser ablation, radiofrequency ablation, interstitial laser, and vascular coiling (Van Mieghem, 2014). Open interventions have also been described (Hedrick, 2004).

Both aim to decrease the effect of the mass on the fetal cardiovascular system, allowing the fetus to recover in utero. Such fetal therapy is associated with survival rates between 30 and 50 percent compared with no survivors among 10 fetuses that did not undergo fetal therapy (Van Mieghem, 2014).

EX-UTERO INTRAPARTUM TREATMENT

The ex-utero intrapartum treatment (EXIT) offers fetoplacental gas exchange while other fetal procedures are completed. During EXIT, the mother and fetus undergo general anesthesia with neuromuscular blockade. Maternal laparotomy allows hysterotomy using a stapling device and technique described earlier for open fetal surgery (p. 268). The fetal head and shoulders are next delivered through the incision to permit the planned fetal procedure while the placenta remains attached and provides gas exchange (Fig. 16-16). Common fetal procedures include intubation by laryngoscopy or rigid bronchoscopy, tracheostomy, or even tumor resection to establish an airway.

Concurrent uterine bleeding is controlled by the hysterotomy staple line and by communication with the anesthesiologist regarding when to decrease inhaled anesthetics and administer oxytocin. To prevent uterine cavity contraction and possible

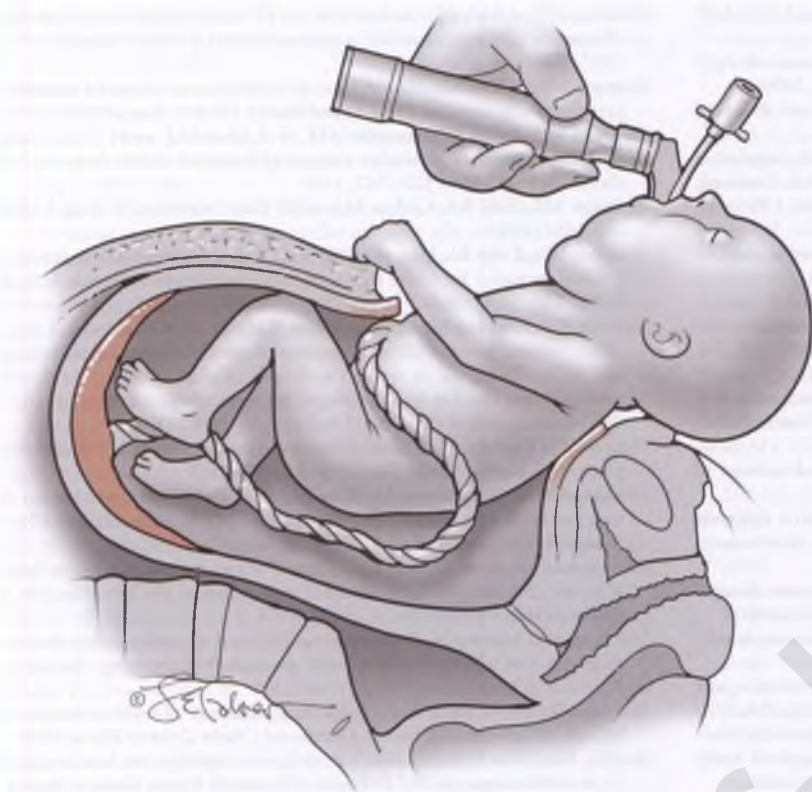

FIGURE 16-16 Ex-utero intrapartum therapy (EXIT). This fetus has an airway-compromising neck mass, and its head and torso have been delivered through the hysterotomy. The fetus remains perfused by the placenta while fetal intubation with an endotracheal tube is completed. With its secured airway, the neonate can then be delivered and separated from its placental circulation.

placental separation or umbilical cord compression, warm saline can be infused into the uterine cavity.

The range of EXIT procedure indications has expanded and currently includes giant fetal neck masses, lung or mediastinal tumors, congenital high-airway obstruction syndrome (CHAOS), and EXIT to ECMO cases (Cass, 2013; Laje, 2012; Lazar, 2011). In one review of 52 cases, the average operating time was 45 minutes, and the average blood loss was 970 mL (Hirose, 2004). This review also noted that a successful EXIT procedure was completed without fetal or maternal compromise even during 150 minutes of placental circulation.

FUTURE OF FETAL THERAPY

Recent experimental advances may serve to revolutionize the field of fetal therapy. Of these, carbon dioxide (CO₂) gas may be introduced into the uterus at or beyond 22 weeks' gestation to create a new surgical space in which fetal surgery can be performed. Promising indications include fetal neural-tube repair and shunt removal (Belfort, 2016). The method we currently favor uses maternal laparotomy to expose the uterus. The fetus is then manipulated to position the affected body area under the access point. We usually remove most of the amniotic fluid and then replace it with CO₂ gas. Two or three access ports

are inserted through the uterine wall and allow insertion of various endoscopes and endoscopic instruments.

Although fetal acidosis from CO₂ insufflation is a theoretic risk, fetal sheep experiments suggest that maternal hyperventilation can reduce this effect. Moreover, we have yet to see evidence of fetal severe acidosis attributable to CO₂ toxicity (Peiro, 2013).

Others have attempted percutaneous fetoscopy in gas to repair fetal neural-tube defects, but currently this approach is hampered by excessive rates of PPROM and preterm delivery (Degenhardt, 2014; Kohl, 2014). This may stem from poorer protection of the membranes using a percutaneous technique. Clearly, the percutaneous technique is less invasive. Thus, going forward, laparotomy, which has higher maternal risk yet offers a greater chance of delivery after 37 weeks' gestation without PPROM, must be reconciled against a less maternally invasive percutaneous approach, which results in delivery closer to 34 weeks' gestation and carries an increased PPROM risk.

As more purpose-built instruments are developed and sophisticated technology is introduced, we believe that fetoscopic surgery will replace open fetal surgery. As a result, many long-lasting and deleterious maternal sequelae from laparotomy and upper-segment hysterotomy can be avoided. Thus, striving for less-invasive options is a worthy cause.

REFERENCES

- Abdennadher W, Chalouhi G, Dreux S, et al: Fetal urine biochemistry at 13-23 weeks of gestation in lower urinary tract obstruction: criteria for in-utero treatment. *Ultrasound Obstet Gynecol* 46(3):306, 2015
- Achiron R, Weissman A, Lipitz S A, et al: Fetal pleural effusion: the risk of fetal trisomy. *Gynecol Obstet Invest* 39:153, 1995
- Adzick NS: Management of fetal lung lesions. *Clin Perinatol* 36(2):363, 2009
- Adzick NS: Open fetal surgery for life-threatening fetal anomalies. *Semin Fetal Neonatal Med* 15:1, 2010
- Adzick NS, Harrison MR, Crombleholme TM, et al: Fetal lung lesions: management and outcome. *Am J Obstet Gynecol* 179:884, 1998
- Adzick NS, Thom EA, Spong CY, et al: A randomized trial of prenatal versus postnatal repair of myelomeningocele. *N Engl J Med* 364: 993, 2011
- Allaf MB, Campbell WA, Vintzileos AM, et al: Does early second-trimester sonography predict adverse perinatal outcomes in monozygotic diamniotic twin pregnancies? *J Ultrasound Med* 33(9):1573, 2014a
- Allaf MB, Vintzileos AM, Chavez MR, et al: First-trimester sonographic prediction of obstetric and neonatal outcomes in monozygotic diamniotic twin pregnancies. *J Ultrasound Med* 33:135, 2014b
- Amer HZ, Heller DS: Chorangioma and related vascular lesions of the placenta—a review. *Fetal Pediatr Pathol* 29(4):199, 2010
- Babcock CJ, Goldstein RB, Barth RA, et al: Prevalence of ventriculomegaly in association with myelomeningocele: correlation with gestational age and severity of posterior fossa deformity. *Radiology* 190:703, 1994
- Bahtiyar MO, Dulay AT, Weeks BP, et al: Prevalence of congenital heart defects in monozygotic/diamniotic twin gestations: a systematic literature review. *J Ultrasound Med* 26:1491, 2007
- Baud D, Windrim R, Keunen J, et al: Fetoscopic laser therapy for twin-twin transfusion syndrome before 17 and after 26 weeks' gestation. *Am J Obstet Gynecol* 208(3):197.e1, 2013
- Belfort MA, Shamshirsaz AA, Whitehead WE, et al: Unusual pleuro-amniotic shunt complication managed using a 2-port in-CO₂ fetoscopic technique:

- technical and ethical considerations. *Ultrasound Obstet Gynecol* 47(1):123, 2016
- Benachi A, Durin L, Maurer SV, et al: Prenatally diagnosed sacrococcygeal teratoma: a prognostic classification. *J Pediatr Surg* 41: 1517, 2006
- Bliton MJ: Ethics: "life before birth" and moral complexity in maternal-fetal surgery for spina bifida. *Clin Perinatol* 30:449, 2003
- Blumenfeld YJ, Shamshirsaz AA, Belfort MA, et al: Fetofetal transfusion syndrome in monochorionic-triamniotic triplets treated with fetoscopic laser ablation: report of two cases and a systematic review. *Am J Perinatol* 5(2):153, 2015
- Byon MI, Kim GJ: Prune-belly syndrome detected by ultrasound in the first trimester and the usefulness of vesicocentesis as a modality of treatment. *Obstet Gynecol Sci* 56(4):265, 2013
- Cass DL, Olutoye OO, Ayres NA, et al: Defining hydrops and indications for open fetal surgery for fetuses with lung masses and vascular tumors. *J Pediatr Surg* 47(1):40, 2012
- Cass DL, Olutoye OO, Cassady CI, et al: EXIT-to-resection for fetuses with large lung masses and persistent mediastinal compression near birth. *J Pediatr Surg* 48:138, 2013
- Cass DL, Olutoye OO, Cassady CI, et al: Prenatal diagnosis and outcome of fetal lung masses. *J Pediatr Surg* 46: 292, 2011
- Catanzarite V, Maida C, Thomas W, et al: Prenatal sonographic diagnosis of vasa previa: ultrasound findings and obstetric outcome in ten cases. *Ultrasound Obstet Gynecol* 18(2):109, 2001
- Cavoretto P, Molina F, Poggi S, et al: Prenatal diagnosis and outcome of echogenic fetal lung lesions. *Ultrasound Obstet Gynecol* 32(6):769, 2008
- Chalouhi GE, Essaoui M, Stirnemann J, et al: Laser therapy for twin-to-twin transfusion syndrome (TTTS). *Prenat Diagn* 31:637, 2011
- Chmait RH, Chavira E, Kontopoulos EV, et al: Third trimester fetoscopic laser ablation of type II vasa previa. *J Matern Fetal Neonatal Med* 23(5):459, 2010
- Crombleholme TM, Coleman B, Hedrick H, et al: Cystic adenomatoid malformation volume ratio predicts outcome in prenatally diagnosed cystic adenomatoid malformation of the lung. *J Pediatr Surg* 37:331, 2002
- Degenhardt J, Schürg R, Winarno A, et al: Percutaneous minimal-access fetoscopic surgery for spina bifida. Part II: maternal management and outcome. *Ultrasound Obstet Gynecol* 44(5):525, 2014
- De Lia JE, Cruikshank DP, Keye WR Jr: Fetoscopic neodymium: YAG laser occlusion of placental vessels in severe twin-twin transfusion syndrome. *Obstet Gynecol* 75: 1046, 1990
- Deprest J, Gratacos E, Nicolaidis KH, et al: Fetoscopic tracheal occlusion (FETO) for severe congenital diaphragmatic hernia: evolution of a technique and preliminary results. *Ultrasound Obstet Gynecol* 24:121, 2004
- Deprest J, Nicolaidis K, Done E, et al: Technical aspects of fetal endoscopic tracheal occlusion for congenital diaphragmatic hernia. *J Pediatr Surg* 46: 22, 2011
- Deprest JA, Van Schoubroeck D, Van Ballaer PP, et al: Alternative technique for Nd:YAG laser coagulation in twin-to-twin transfusion syndrome with anterior placenta. *Ultrasound Obstet Gynecol* 11:347, 1998
- Derderian SC, Coleman AM, Jeanty C, et al: Favorable outcomes in high-risk congenital pulmonary airway malformations treated with multiple courses of maternal betamethasone. *J Pediatr Surg* 50(4):515, 2015
- Deurloo KL, Devlieger R, Lopriore E, et al: Isolated fetal hydrothorax with hydrops: a systematic review of prenatal treatment options. *Prenat Diagn* 27:893, 2007
- Donofrio MT, Moon-Grady AJ, Hornberger LK, et al: Diagnosis and treatment of fetal cardiac disease: a scientific statement from the American Heart Association. *Circulation* 129:2183, 2014
- Downard CD, Jaksic T, Garza JJ, et al: Analysis of an improved survival rate for congenital diaphragmatic hernia. *J Pediatr Surg* 38:729, 2003
- Estes JM, MacGillivray TE, Hedrick MH, et al: Fetoscopic surgery for the treatment of congenital anomalies. *J Pediatr Surg* 27:95, 1992
- Flageole H, Evrard AV, Piedboeuf B, et al: The plug-unplug sequence: an important step to achieve type II pneumocyte maturation in the fetal lamb model. *J Pediatr Surg* 33: 299, 1998
- Garza A, Cordero JF, Mulinare J, et al: Epidemiology of the early amnion rupture spectrum of defects. *Am J Dis Child* 142:541, 1988
- Grethel EJ, Wagner AJ, Clifton MS, et al: Fetal intervention for mass lesions and hydrops improves outcome: a 15-year experience. *J Pediatr Surg* 42:117, 2007
- Gunn TR, Mora JD, Pease P: Antenatal diagnosis of urinary tract abnormalities by ultrasonography after 28 weeks gestation: incidence and outcome. *Am J Obstet Gynecol* 172:479, 1995
- Guschmann M, Henrich W, Dudenhausen JW, et al: Chorioangiomas—new insights into a well-known problem. II. An immuno-histochemical investigation of 136 cases. *J Perinat Med* 31(2):170, 2003
- Hara K, Kikuchi A, Takagi K, et al: Massive pericardial effusion in an early gestational fetus having intrapericardial diaphragmatic hernia. *J Obstet Gynaecol Res* 33(4):561, 2007
- Harrison MR, Adzick NS, Bullard KM, et al: Correction of congenital diaphragmatic hernia in utero VII: a prospective trial. *J Pediatr Surg* 32:1637, 1997
- Harrison MR, Adzick NS, Flake AW, et al: Correction of congenital diaphragmatic hernia in utero: VI. Hard-earned lessons. *J Pediatr Surg* 28:1411, 1993
- Harrison MR, Adzick NS, Longaker MT, et al: Successful repair in utero of a fetal diaphragmatic hernia after removal of herniated viscera from the left thorax. *N Engl J Med* 322:1582, 1990
- Harrison MR, Filly RA, Golbus MS, et al: Fetal treatment. *N Engl J Med* 307:1651, 1982
- Harrison MR, Keller RL, Hawgood SB, et al: A randomized trial of endoscopic tracheal occlusion for severe fetal congenital diaphragmatic hernia. *N Engl J Med* 349:1916, 2003
- Hedrick HL, Flake AW, Crombleholme TM, et al: Sacrococcygeal teratoma: prenatal assessment, fetal intervention, and outcome. *J Pediatr Surg* 39(3):430, 2004
- Hirose S, Farmer DL, Lee H, et al: The ex utero intrapartum treatment procedure: looking back at the EXIT. *J Pediatr Surg* 39:375, 2004
- Holder AM, Klaasens M, Tibboel D, et al: Genetic factors in congenital diaphragmatic hernia. *Am J Hum Genet* 80:825, 2007
- Hosseinzadeh P, Shamshirsaz AA, Cass DL, et al: Fetoscopic laser ablation of vasa previa for a fetus with a giant cervical lymphatic malformation. *Ultrasound Obstet Gynecol* 46(4):507, 2015a
- Hosseinzadeh P, Shamshirsaz AA, Javadian P, et al: Prenatal therapy of large placental chorioangiomas: case report and review of the literature. *Am J Perinatol* 5(2):196, 2015b
- Hubbard AM, Adzick NS, Crombleholme TM, et al: Congenital chest lesions: diagnosis and characterization with prenatal MR imaging. *Radiology* 212:43, 1999
- Jani J, Keller RL, Benachi A, et al: Prenatal prediction of survival in isolated left-sided diaphragmatic hernia. *Ultrasound Obstet Gynecol* 27:18, 2006
- Jani JC, Nicolaidis KH, Gratacos E, et al: Severe diaphragmatic hernia treated by fetal endoscopic tracheal occlusion. *Ultrasound Obstet Gynecol* 34:304, 2009
- Javadian P, Shamshirsaz AA, Haeri S, et al: Perinatal outcome after fetoscopic release of amniotic bands: a single-center experience and review of the literature. *Ultrasound Obstet Gynecol* 42(4):449, 2013
- Johnston R, Shrivastava VK, Chmait RH: Term vaginal delivery following fetoscopic laser photocoagulation of type II vasa previa. *Fetal Diagn Ther* 35(1):62, 2014
- Kagan KO, Gazzoni A, Sepulveda-Gonzalez G, et al: Discordance in nuchal translucency thickness in the prediction of severe twin-to-twin transfusion syndrome. *Ultrasound Obstet Gynecol* 29:527, 2007
- Kitagawa H, Pringle KC, Zuccolo J, et al: The pathogenesis of dysplastic kidneys in urinary tract obstruction in the female lamb model. *J Pediatr Surg* 34: 1678, 1999
- Klein J, Lacroix C, Caubet C, et al: Fetal urinary peptides to predict postnatal outcome of renal disease in fetuses with posterior urethral valves (PUV). *Sci Transl Med* 5(198):198ra106, 2013
- Knox EM, Kilby MD, Martin WL, et al: In-utero pulmonary drainage in the management of primary hydrothorax and congenital cystic lung lesion: a systematic review. *Ultrasound Obstet Gynecol* 28: 726, 2006
- Kohl T: Percutaneous minimally invasive fetoscopic surgery for spina bifida. Part I: surgical technique and perioperative outcome. *Ultrasound Obstet Gynecol* 44(5):515, 2014
- Laberge JM, Flageole H, Pugash D, et al: Outcome of the prenatally diagnosed congenital cystic adenomatoid lung malformation: a Canadian experience. *Fetal Diagn Ther* 16:178, 2001
- Laje P, Johnson MP, Howell LJ, et al: Ex utero intrapartum treatment in the management of giant cervical teratomas. *J Pediatr Surg* 47:1208, 2012
- Langer JC, Harrison MR, Schmidt KG, et al: Fetal hydrops and death from sacrococcygeal teratoma: rationale for fetal surgery. *Am J Obstet Gynecol* 160:1145, 1989
- Lazar DA, Olutoye OO, Moise KJ Jr, et al: Ex-utero intrapartum treatment procedure for giant neck masses—fetal and maternal outcomes. *J Pediatr Surg* 46:817, 2011
- Lee W, Kirk JS, Comstock CH, et al: Vasa previa: prenatal detection by three-dimensional ultrasonography. *Ultrasound Obstet Gynecol* 16(4):384, 2000
- Lewi L, Jani J, Boes AS, et al: The natural history of monozygotic twins and the role of prenatal ultrasound scan. *Ultrasound Obstet Gynecol* 30:401, 2007
- Liley AW: Intrauterine transfusion of foetus in haemolytic disease. *BMJ* 2:1107, 1963
- Lopriore E, Oepkes D: Neonatal morbidity in twin-twin transfusion syndrome. *Early Hum Dev* 87:595, 2011
- MacGillivray TE, Harrison MR, Goldstein RB, et al: Disappearing fetal lung lesions. *J Pediatr Surg* 28:1321, 1993

- Mahle WT, Rychik J, Tian ZY, et al: Echocardiographic evaluation of the fetus with congenital cystic adenomatoid malformation. *Ultrasound Obstet Gynecol* 16:620, 2000
- Makayama DK, Harrison MR, deLorimer AA: Prognosis of posterior urethral valves presenting at birth. *J Pediatr Surg* 21:43, 1986
- Makin EC, Hyett J, Ade-Ajayi N, et al: Outcome of antenatally diagnosed sacrococcygeal teratomas: single-center experience (1993–2004). *J Pediatr Surg* 41:388, 2006
- McElhinney DB, Marshall AC, Wilkins-Haug LE, et al: Predictors of technical success and postnatal biventricular outcome after in utero aortic valvuloplasty for aortic stenosis with evolving hypoplastic left heart syndrome. *Circulation* 120:1482, 2009
- Merchant AM, Peranteau W, Wilson RD, et al: Postnatal chest wall deformities after fetal thoracoamniotic shunting for congenital cystic adenomatoid malformation. *Fetal Diagn Ther* 22(6):435, 2007
- Meuli M, Meuli-Simmen C, Hurchins GM, et al: The spinal cord lesion in human fetuses with myelomeningocele: implications for fetal surgery. *J Pediatr Surg* 32:448, 1997
- Miniati D: Pulmonary vascular remodeling. *Semin Pediatr Surg* 16:80, 2007
- Moise KJ Jr, Dorman K, Lamvu G, et al: A randomized trial of amnioreduction versus septostomy in the treatment of twin-twin transfusion syndrome. *Am J Obstet Gynecol* 193(3 Pt 1):701, 2005
- Morris RK, Malin GL, Quinlan-Jones E, et al: Percutaneous vesicoamniotic shunting versus conservative management for lower urinary tract obstruction (PLUTO): a randomised trial. *Lancet* 382:1496, 2013
- Morris RK, Quinlan-Jones E, Kilby M, et al: Systematic review of accuracy of fetal urine analysis to predict poor postnatal renal function in case of congenital urinary tract obstruction. *Prenat Diagn* 27:900, 2007
- Muller FI, Dommergues M, Bussi eres L, et al: Development of human renal function: reference intervals for 10 biochemical markers in fetal urine. *Clin Chem* 42(11):1855, 1996
- National Institute for Health and Clinical Excellence: Insertion of pleuro-amniotic shunt for fetal pleural effusion. Guideline IPG 190, September 2006
- Peiro JL, Fontecha CG, Ruano R, et al: Single-Access Fetal Endoscopy (SAFE) for myelomeningocele in sheep model I: amniotic carbon dioxide gas approach. *Surg Endosc* 27(10):3835, 2013
- Peranteau WH, Wilson RD, Liechty KW, et al: Effect of maternal betamethasone administration on prenatal congenital cystic adenomatoid malformation growth and fetal survival. *Fetal Diagn Ther* 22:365, 2007
- Quintero RA, Chmait RH, Bornick PW, et al: Trocar-assisted selective laser photocoagulation of communicating vessels: a technique for the laser treatment of patients with twin-twin transfusion syndrome with inaccessible anterior placentas. *J Matern Fetal Neonatal Med* 23(4):330, 2010
- Quintero RA, Martinez JM, L opez J, et al: Individual placental territories after selective laser photocoagulation of communicating vessels in twin-twin transfusion syndrome. *Am J Obstet Gynecol* 192(4):1112, 2005
- Quintero RA, Morales WJ, Allen MH, et al: Staging of twin-twin transfusion syndrome. *J Perinatol* 19:550, 1999
- Roberts D, Neilson JP, Kilby MD, et al: Interventions for the treatment of twin-twin transfusion syndrome. *Cochrane Database System Rev* 1:CD002073, 2008
- Roberts D, Neilson JP, Kilby MD, et al: Interventions for the treatment of twin-twin transfusion syndrome. *Cochrane Database System Rev* 1:CD002073, 2014
- Rodr guez MA, Cass DL, Lazar DA, et al: Tumor volume to fetal weight ratio as an early prognostic classification for fetal sacrococcygeal teratoma. *J Pediatr Surg* 46: 1182, 2011
- Ruano R, da Silva MM, Salustiano EM, et al: Percutaneous laser ablation under ultrasound guidance for fetal hyperechogenic microcystic lung lesions with hydrops: a single center cohort and a literature review. *Prenat Diagn* 32(12):1127, 2012a
- Ruano R, Rodo C, Peiro JL, et al: Fetoscopic laser ablation of placental anastomoses in twin-twin transfusion syndrome using "Solomon technique." *Ultrasound Obstet Gynecol* 42:434, 2013
- Ruano R, Rodo C, Peiro JL, et al: Reply: to PMID 23616360. *Ultrasound Obstet Gynecol* 43(2):239, 2014
- Ruano R, Sananes N, Sangi-Hagheykar H, et al: Fetal intervention for severe lower urinary tract obstruction: a multicenter case-control study comparing fetal cystoscopy with vesicoamniotic shunting. *Ultrasound Obstet Gynecol* 45(4):452, 2015
- Ruano R, Yoshizaki CT, Da Silva MM, et al: A randomized controlled trial of fetal endoscopic occlusion versus postnatal management of severe isolated congenital diaphragmatic hernia. *Ultrasound Obstet Gynecol* 39:20, 2012b
- Rustico MA, Lanna M, Coviello D, et al: Fetal pleural effusion. *Prenat Diagn* 27:793, 2007
- Saade GR, Belfort MA, Berry DL, et al: Amniotic septostomy for the treatment of twin oligohydramnios-polyhydramnios sequence. *Fetal Diagn Ther* 13(2):86, 1998
- Sananes N, Favre R, Koh CJ, et al: Urological fistulas after fetal cystoscopic laser ablation of posterior urethral valves: surgical technical aspects. *Ultrasound Obstet Gynecol* 45(2):183, 2015
- Schrey S, Kelly EN, Langer JC, et al: Fetal thoracoamniotic shunting for large macrocystic congenital cystic adenomatoid malformations of the lung. *Ultrasound Obstet Gynecol* 39(5):515, 2012
- Senat MV, Deprest J, Boulvain M, et al: Endoscopic laser surgery versus serial amnioreduction for severe twin-twin transfusion syndrome. *N Engl J Med* 351:136, 2004
- Sentilhes L, Verspyck E, Eurin D, et al: Favorable outcome of a tight constriction band secondary to amniotic band syndrome. *Prenat Diagn* 24:198, 2004
- Shamshirsaz AA, Javadian P, Ruano R, et al: Comparison between laparoscopically assisted and standard fetoscopic laser ablation in patients with anterior and posterior placentation in twin-twin transfusion syndrome: a single center study. *Prenat Diagn* 35(4):376, 2015
- Simpson LL, Marx GR, Elkadry EA, et al: Cardiac dysfunction in twin-twin transfusion syndrome: a prospective longitudinal study. *Obstet Gynecol* 92:557, 1998
- Skari H, Bjornland K, Haugen G, et al: Congenital diaphragmatic hernia: a meta-analysis of mortality factors. *J Pediatr Surg* 35:1187, 2000
- Slaghekke F, Lopriore E, Lewi L, et al: Fetoscopic laser coagulation of the vascular equator versus selective coagulation for twin-to-twin transfusion syndrome: an open-label randomized trial. *Lancet* 383: 2144, 2014
- Smith RP, Illanes S, Denbow ML, et al: Outcome of fetal pleural effusions treated by thoracoamniotic shunting. *Ultrasound Obstet Gynecol* 26:63, 2005
- Society for Maternal-Fetal Medicine, Simpson LL: Twin-twin transfusion syndrome. *Am J Obstet Gynecol* 208:3, 2013
- Stocker JT, Madewell JE, Drake RM: Congenital cystic adenomatoid malformation of the lung. Classification and morphologic spectrum. *Hum Pathol* 8(2):155, 1977
- Swamy R, Embleton N, Hale J, et al: Sacrococcygeal teratoma over two decades: birth prevalence, prenatal diagnosis and clinical outcomes. *Prenat Diagn* 28:1048, 2008
- Torfs CP, Curry CJ, Bateson TF: A population based study of congenital diaphragmatic hernia. *Teratology* 46:555, 1992
- Tulzer G, Arzt W, Franklin RC, et al: Fetal pulmonary valvuloplasty for critical pulmonary stenosis or atresia with intact septum. *Lancet* 360:1567, 2002
- Van Mieghem T, Al-Ibrahim A, Deprest J, et al: Minimally invasive therapy for fetal sacrococcygeal teratoma: case series and systematic review of the literature. *Ultrasound Obstet Gynecol* 43: 611, 2014
- Ville Y, Hyett J, Hecher K, et al: Preliminary experience with endoscopic laser surgery for severe twin-twin transfusion syndrome. *N Engl J Med* 332:224, 1995
- Westerburg B, Feldstein VA, Sandberg PL, et al: Sonographic prognostic factors in fetuses with sacrococcygeal teratoma. *J Pediatr Surg* 35:322, 2000
- Wilson RD, Hedrick H, Flake AW, et al: Sacrococcygeal teratomas: prenatal surveillance, growth and pregnancy outcome. *Fetal Diagn Ther* 25:15, 2009
- Wu S, Johnson MP: Fetal lower urinary tract obstruction. *Clin Perinatol* 36:377, 2009
- Yinon Y, Grisar-Granovsky S, Chaddha V, et al: Perinatal outcome following fetal chest shunt insertion for pleural effusion. *Ultrasound Obstet Gynecol* 36:58, 2010

CHAPTER 17

Trauma in Pregnancy

INCIDENCE	276
MATERNAL PHYSIOLOGIC CHANGES	276
RISK FACTORS	278
UNINTENTIONAL TRAUMA	278
INTENTIONAL TRAUMA	281
MANAGEMENT	282
FETAL MONITORING	287

INCIDENCE

Trauma is one of the most common reasons for emergency room visits during pregnancy. The exact incidence is unknown, although trauma is estimated to complicate approximately 1 in 12 pregnancies (Hill, 2008). Trauma is also the leading non-obstetric cause of maternal death. In some reports, it accounts for up to 20 percent of all maternal mortalities (Fildes, 1992; Kuhlmann, 1994). As perspective, this represents a larger proportion than the combined mortality rates of several well-known obstetric causes. Of specific events, [Figure 17-1](#) shows the estimated incidences for several types of trauma suffered by gravidas compared with nonpregnant women.

The link between maternal injury and adverse pregnancy outcome is well recognized (Weiss, 2002). Most pregnancy complications directly correlate with the trauma severity, although even minor trauma may be linked to serious obstetric complications. Of sequelae, trauma has been associated with increased incidences of spontaneous abortion, placental abruption, preterm premature rupture of membranes, preterm birth, uterine

rupture, cesarean delivery, and stillbirth (Pak, 1998; Pearlman, 1990; Schiff, 2002b, 2005). Specifically, pregnant women admitted for trauma but not delivered face an associated 2.7-fold increased risk of preterm labor, a 1.5-fold increased risk of abruption, and a fourfold increase in the risk of maternal death compared with noninjured controls (El Kady, 2004).

Fetal morbidity and mortality similarly may follow trauma during pregnancy. Each year almost 4000 fetal losses in the United States will result from motor vehicle crashes (El Kady, 2004). In these deaths, placental abruption is a major contributing factor (Shah, 1998). Only approximately 0.4 percent of women will require admission for trauma during pregnancy, but of those who do, almost one third will deliver during their hospitalization (John, 2011; Kuo, 2007). Thus, many of the consequences for these neonates derive from their preterm birth.

Pregnancy per se does not appear to increase the morbidity or mortality rate attributed to trauma. It may even contribute to a lower adjusted mortality rate (Ikossi, 2005; John, 2011). However, the pattern and severity of the injury may be modified by the qualities of the gravid uterus (Shah, 1998).

Management of a gravida and her fetus is complex. Thus, a multidisciplinary approach is often required to address the challenges posed by trauma in pregnancy. Ideally, experts in neonatology, anesthesiology, radiology, labor and critical care nursing, surgery, and obstetrics are available for consultation.

MATERNAL PHYSIOLOGIC CHANGES

■ Organ Systems

Pregnancy leads to several maternal anatomic alterations and physiologic adaptations that should be considered during evaluation of the gravida following trauma. During pregnancy, the maternal baseline heart rate rises by 10 to 15 beats per minute (bpm). Cardiac output is also estimated to increase by 30 to 40 percent to compensate for the augmented demand of the

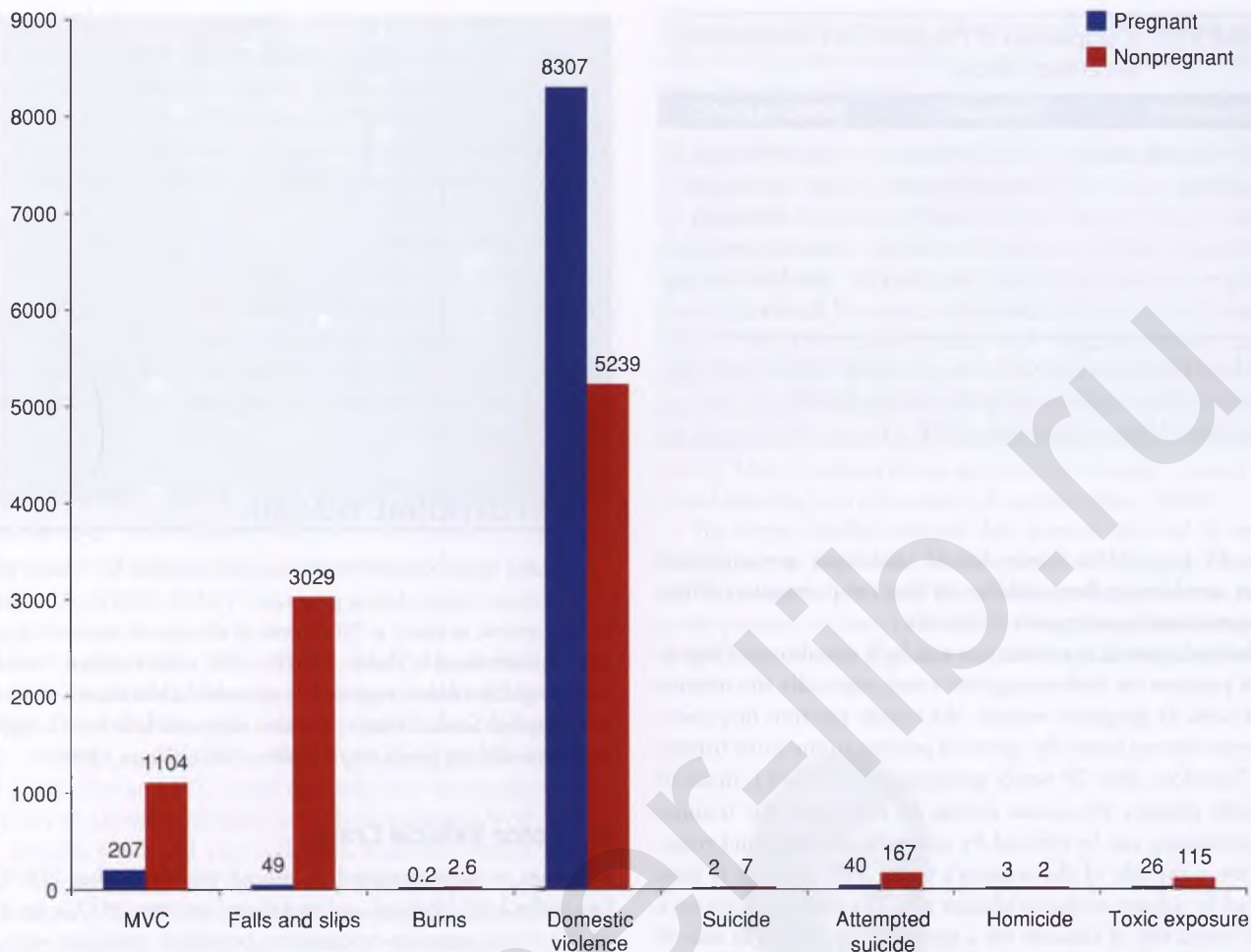


FIGURE 17-1 Estimated incidence of injury by type of trauma during pregnancy. Rates are reported per 100,000 live births in pregnancy and per 100,000 women in the nonpregnant cohort. Rates for nonpregnant women were calculated using 2013 U.S. data from the Centers for Disease Control and Prevention Web-based Injury Statistics Query and Reporting System (WISQARS) (2015) when not available from the literature. MVC = motor vehicle crash.

uterus and developing fetus (Tsuei, 2006). Specifically, the uterus at term may require up to 20 percent of the entire maternal cardiac output. Additionally, the red blood cell mass grows by 20 to 30 percent, and the plasma volume expands by 50 percent. In the first half of pregnancy, blood pressure tends to decline yet rises in later months. For these reasons, maternal hemorrhage may go unrecognized because altered vital signs may not develop until 30 to 35 percent of maternal blood volume has been lost (Marx, 1965). Notably, a nonreassuring fetal heart rate tracing that reflects diminished uterine blood flow may manifest before abnormal maternal signs are noticeable. Tracing changes may include a loss in fetal heart rate variability, late decelerations, or bradycardia.

Of other maternal hematologic changes, elevated concentrations of clotting factors lead to an expected hypercoagulable state in pregnancy. Accordingly, immobility following trauma in pregnancy may exacerbate the risk of venous thromboembolism (VTE). Moreover, VTE risks that are normally associated with orthopedic trauma are accentuated.

Pulmonary changes are also expected in the gravida. In late pregnancy, the resting diaphragm is elevated approximately 4 cm because of the enlarged uterus. This encroachment changes several measured lung volumes. The most significant

ones are reductions in functional residual capacity and its sub-components, expiratory reserve volume and residual volume. Minute ventilation also rises during pregnancy. This stems from an increased tidal volume rather than an increased respiratory rate, which is not appreciably altered during pregnancy. In addition, oxygen uptake and basal metabolism are elevated. The accentuated minute ventilation leads to lower PCO_2 values and a compensated state of metabolic alkalosis (Table 17-1).

Additional maternal adaptations to pregnancy develop in other systems. The gastrointestinal tract has decreased motility as an effect of both compression and hormonal influence. Esophageal sphincter tone is diminished, and gastric emptying time is lengthened. These changes raise aspiration risks and demand preventive measures should tracheal intubation become necessary. Prevention is discussed in Chapter 19 (p. 308).

■ Uterus and Placenta

Unique changes to the gravid uterus can affect trauma management. First, uterine size plays a role. Namely, until approximately 12 weeks' gestation, the uterus is a pelvic organ. By 20 weeks, the fundus has reached the level of the umbilicus and tends to reach the costal margins at approximately 36 weeks

TABLE 17-1. Comparison of Pregnant and Nonpregnant Reference Values

Component	Pregnant	Nonpregnant
Serum bicarbonate	16–22 mEq/L	22–26 mEq/L
Creatinine	0.4–0.8 mg/dL	0.5–1.0 mg/dL
BUN	3–11 mg/dL	7–20 mg/dL
PCO ₂	25–33 mm Hg	38–42 mm Hg
PaO ₂	100–110 mm Hg	90–100 mm Hg
pH	7.39–7.45	7.38–7.42

BUN = blood urea nitrogen; PaO₂ = partial pressure arterial oxygen; PCO₂ = partial pressure carbon dioxide.

Data from Abbassi-Ghanavati, 2009.

(Fig. 15-1, p. 245). These clinical landmarks are important when considering the possibility of fetal involvement at different gestational ages in cases of trauma.

Second, growth in uterine size and bulk can also exert significant pressure on abdominopelvic veins, especially the inferior vena cava. In pregnant women, the supine position may compromise venous return by up to 30 percent in the third trimester. Therefore, after 20 weeks' gestation, every effort is made to laterally displace the uterus during an evaluation for trauma. Repositioning can be effected by manually elevating and rotating the right side of the woman's torso. This position is then braced by a foam wedge or blanket roll. For those patients on a back board out of concern for a spinal injury, the right side of the board can be similarly lifted and braced (Kortbeek, 2008).

Third, these uterine size changes of pregnancy may also alter the expected injury pattern. For example, Elliot (1966) reported that serious retroperitoneal injury was more common in pregnant than nonpregnant women. Other authors report that bowel injury may be less common in gravidas suffering trauma. This may result from the gravid uterus displacing bowel up and under the more protective rib cage or laterally to the flank (Elliot, 1966).

Last, changes in uterine and placental tone respond to traumatic forces differently. The uterine wall has some elasticity, unlike the rather inelastic placenta. Thus, blunt trauma may only indent the uterine wall and displace amniotic fluid. However, the placenta deforms less easily, which makes it susceptible to separation with subsequent abruption.

RISK FACTORS

In this chapter, the causes of trauma are divided into unintentional and intentional groups. Unintentional trauma includes motor vehicle crashes, slips and falls, burns, electric shock, and accidental poisoning. Intentional trauma encompasses domestic/intimate partner violence, penetrating trauma, suicide, and homicide.

The distribution of trauma by trimester appears to be similar among most cases of intentional and unintentional trauma (Tinker, 2010). However, slips and falls may be the exception. According to large, population-based cohort studies,

these are more common in the third trimester (Schiff, 2008). Of risk factors, alcohol consumption, smoking, and drug use appear to be greater among women who report suffering a traumatic injury during pregnancy. Women noting injuries are also more likely to work outside the home. Of other risks, maternal seizure disorders raise the risk of trauma threefold (Tinker, 2010).

Intentional trauma is more commonly reported among women carrying fetuses of uncertain paternity or who describe their pregnancy as unwanted (Tinker, 2010). African American and Hispanic women are not only more likely to experience trauma in pregnancy. These groups are more likely to experience death from homicide during this time (Dannenberg, 1995; Ikossi, 2005).

UNINTENTIONAL TRAUMA

Of trauma types, unintentional trauma accounts for a large portion of major injury during pregnancy (Schiff, 2002b). According to one review, as many as 90 percent of all cases of maternal injury are unintentional (Tinker, 2010). Of unintentional trauma, motor vehicle crash is reported by some to be the most frequently encountered form. Others state that slips and falls have a higher incidence during pregnancy (Tinker, 2010; Weiss, 2008).

■ Motor Vehicle Crash

Pregnant women involved in motor vehicle crashes (MVCs) can suffer both physical and emotional trauma. MVCs are one of the most common mechanisms by which pregnant women suffer blunt abdominal trauma. The overall incidence during pregnancy varies. One study approximates that 7 in every 100,000 pregnant women will experience a life-threatening injury during an MVC (Weiss, 2002). In another estimate by Kvarnstrand and associates (2008), MVCs occur in 207 of every 100,000 pregnancies and have an associated maternal mortality rate of 1.4 per 100,000 pregnancies. The risk of antepartum stillbirth is increased nearly fourfold, thus making MVC one of the leading causes of maternal and fetal mortality. Of all pregnant women involved in an MVC, up to 87 percent of this group receives some sort of medical care (Whitehead, 2013). MVCs are responsible for approximately 3.5 of every 1000 maternal admissions to the hospital. The vast majority of these admissions are after 20 weeks' gestation (Vivian-Taylor, 2012).

Of risks for MVC, even among pregnant women, the use of intoxicants is a factor. In one report, 43 percent of pregnant women evaluated at a major trauma center following an MVC tested positive for an intoxicant (Ikossi, 2005; Patteson, 2007).

Seatbelt use has consistently been linked with higher survival rates after an MVC. Pregnant women may be hesitant to use seatbelts or use them incorrectly, especially during the third trimester. One unfounded belief is that seatbelt use may harm the uterus or the fetus during an accident. However, ejection from the vehicle is associated with a 32-fold increased risk of fetal death, a sixfold higher risk of placental abruption, and greater severity of maternal trauma (Fig. 17-2). Maternal consequences included severe head injury and maternal death (Aboutanos,

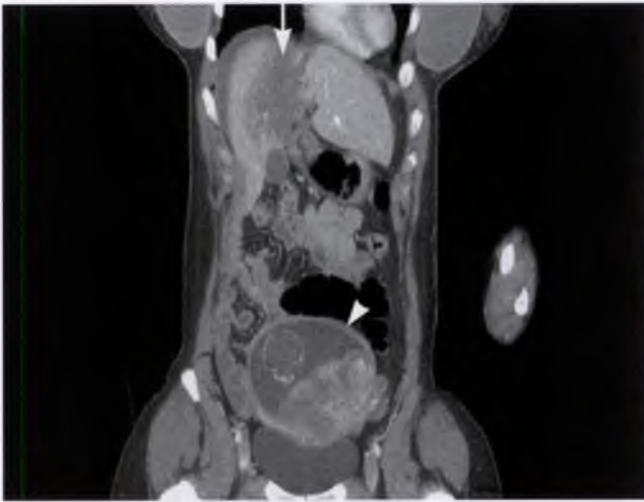


FIGURE 17-2 Grade IV liver laceration (arrow) following a high-speed motor vehicle accident. The arrowhead points to the uterus.

2008; Crosby, 1971; Curet, 2000). Lack of a seatbelt during an MVC doubles the risk of excessive maternal bleeding (Hyde, 2003). Preterm delivery is another complication, and gravidas not wearing a seatbelt are twofold more likely to deliver within 48 hours after an MVC. Such deliveries can be complicated by delivery of a low-birthweight or stillborn neonate (Wolf, 1993).

In both front and rear collisions, maternal impact against the steering wheel can be avoided with proper seatbelt use (Motozawa, 2010). The shoulder harness of the seatbelt should course over the collarbone between the woman's breasts, and the lap belt should lie beneath the pregnant abdomen (Fig. 17-3) (Brown, 2009). In experiments done in near-term nonhuman primates, the use of both a lap and a shoulder harness as opposed to lap belt alone can lower fetal loss rates from 50 to 12.5 percent (Crosby, 1972). In contrast, if the lap belt is placed over the gravid uterus, the injury risk during an MVC may be exacerbated (Brown, 2009).

Proper seatbelt use is likely not stressed sufficiently during prenatal care. In one study, only half of patients noted receiving counseling regarding seatbelt use from their prenatal care provider (Sirin, 2007). Perhaps, as a result, the use of seatbelts during pregnancy has been reported to be as low as 21 percent (Chibber, 2015).

Many studies indicate that air bags are lifesaving in high-speed MVCs. However, the force and speed with which air bags deploy is substantial. Calculated deployment speeds of close to 200 miles per hour (mph) are cited as potential causes for concern in pregnancy (Bard, 2009). That said, no consistent evidence shows that airbag deployment during pregnancy raises the risk of adverse outcomes. In one investigation, air bag deployment after an MVC was not associated with an increased risk of placental abruption (Metz, 2006). Moreover, although some registries list abruption rates as high as 57 percent with air bag deployment, this is more likely related to the severity of the crash than deployment of the air bag (Luley, 2013). National Highway Traffic Safety Administration (2015) guidelines currently state that pregnant women should sit as far from the airbag as possible. This is a dynamic process that warrants seat

adjustment with increasing abdominal girth. If a steering wheel offers a tilt option, the wheel is angled more toward the breast bone than the abdomen.

Several adverse pregnancy outcomes are linked to car crashes. Placental abruption may arise from the combination of several forces. Direct trauma from the steering wheel can clearly lead to placental separation. However, the lack of direct trauma does not eliminate the risk of abruption. When traveling at speeds exceeding 30 mph, an impact and sudden stop can throw the uterus forward and generate 550 mm Hg of pressure (Fig. 17-4). This motion builds both negative pressure and a *contrecoup* effect. These two mechanisms combined with the maternal body folding over the abdomen are sufficient to create almost 600 mm Hg of intraabdominal pressure (El Kady, 2007). These resulting forces are powerful enough to cause placental shearing and subsequent abruption (Reis, 2000).

The largest studies indicate that women involved in severe MVCs are at high risk of complications. Among critically injured women, placental abruption can be seen in as many as 40 percent of cases (Ali, 1997). Pregnant women involved in MVCs also carry a greater risk for cesarean delivery (Schiff,



FIGURE 17-3 Proper seatbelt placement. The shoulder harness courses over the collarbone between the woman's breasts. The lap belt lies under the pregnant abdomen. (Reproduced with permission from Cunningham FG, Leveno KJ, Bloom SL, et al (eds): Critical care and trauma. In Williams Obstetrics, 24th ed. New York, McGraw-Hill Education, 2014a.)



FIGURE 17-4 Mechanism for placental abruption in motor vehicle collision. Forward momentum of the mother is seen early in the collision and forces her to wrap over the uterus. This is followed by a contrecoup, in which forces are directed backward. During each phase, tremendous intraabdominal pressure is generated that can lead to abruption.

2005). Loss of consciousness and pelvic fracture, indicating more severe trauma, are risk factors for poor fetal outcomes including fetal death after an MVC (Aboutanos, 2008). Although pregnant women tend to have less severe trauma after MVC, they are 50 percent more likely to require genitourinary surgery than nonpregnant women involved in motor vehicle crashes (Azar, 2015; Ikossi, 2005).

Of fetal consequences, the risk of preterm birth and perinatal death is increased only if delivery occurs immediately following a crash (Vivian-Taylor, 2012). Immediate delivery after an MVC is uncommon with an estimated rate of 0.4 percent in pregnancies under 20 weeks' gestation and 3.5 percent in those after 20 weeks' (Reis, 2000). In a study evaluating more than 600,000 women, Vivian-Taylor and associates (2012) found that pregnant women who were involved in car crashes and who remained undelivered after this event had similar maternal and fetal outcomes compared with women not involved in such crashes.

■ Slips and Falls

These are responsible for 17 to 39 percent of trauma-related emergency room visits during pregnancy (Dunning, 2010). Greater joint laxity and weight gain can shift the center of gravity and alter gait. Dynamic postural stability declines with pregnancy, especially during the third trimester (McCrorry, 2010). Individually or combined, these changes can predispose gravidas to slips and falls.

As many as one in four pregnant women are estimated to fall at least once while pregnant. Among those who fall, 35 percent did so two or more times. Nearly 60 percent of women experiencing a fall will have a related injury, and one in five of these will require restricted activity following the fall (Dunning, 2010). Schiff (2008) found an incidence of 49 fall-related hospitalizations per 100,000 deliveries. Of these pregnant women,

79 percent were in their third trimester. Fracture of the lower extremity is the most commonly associated harm.

Most falls are indoors, and up to 39 percent will be related to falling from stairs (Dunning, 2010). In a prospective trial conducted by Vladutiu and coworkers (2010), the incidence of injury in gravidas was 4.1 cases per 1000 exercise hours and 3.2 cases per 1000 physical activity hours. Most of these injuries were attributed to falls. Dunning and colleagues (2003) found that 6.3 percent of all employed pregnant women experienced a fall at work. Major risk factors included carrying heavy objects, hurrying, or walking on slippery floors.

Pregnant patients admitted to the hospital after a fall carry elevated risks for adverse pregnancy outcomes. Compared with a control group that was randomly selected, gravidas who had fallen had a 4.4-fold increased risk for preterm labor, an eightfold increase in placental abruption rates, a twofold greater risk for fetal distress, a 1.3-fold increased cesarean delivery rate, a twofold greater risk for labor induction, and a threefold rise in rates of fetal hypoxia (Fig. 17-5) (Schiff, 2008).

■ Burns

The true incidence of burns during pregnancy is difficult to ascertain, as the literature is mostly composed of case reports and case series. Among reproductive-aged women, estimated incidences lie between 1.3 and 7 percent (Akhtar, 1994; Karimi, 2009). In reproductive-aged women in Iran, Maghsoudi and associates (2006) found the incidence of burns among gravidas was 0.17 percent compared with 2.6 percent per 100,000 person-years. From this data, pregnancy per se does not seem to be a risk factor for burns. Moreover, pregnancy does not appear to independently alter maternal survival after severe burns (Akhtar, 1994).

However, several adverse pregnancy outcomes do appear to be increased in gravidas suffering burns. Of clinical characteristics,

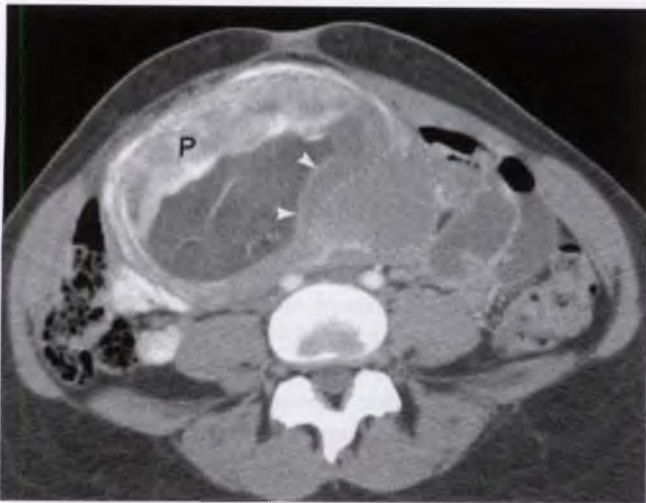

FIGURE 17-5 This axial computed tomography image shows placental abruption after blunt abdominal trauma. Continuous with the unaffected placenta (P), a devitalized tongue of placenta (arrowheads) is seen with a large retroplacental clot (light dotted line) behind it.

the burn depth and the total body surface area (TBSA) burned has the greatest effect on both maternal and fetal outcomes. Specifically, in one series, burns covering 60 percent or more of the woman's TBSA carried both maternal and fetal mortality rates close to 100 percent (Akhtar, 1994). Sepsis is a major contributing factor to this outcome (Chama, 2002). Another significant risk factor for both maternal and fetal mortality is smoke inhalation (Karimi, 2009). Maternal age or the trimester of pregnancy during which the burn occurs does not appear to affect maternal or fetal outcomes. Severe burns during the first trimester have been associated with spontaneous abortion, which is probably secondary to ensuing infection (Jain, 1993). Most of these losses are within 10 days of the burn (Chama, 2002). In another series, intrauterine fetal demises linked to severe burns occurred within 24 hours in 74 percent of cases (Akhtar, 1994). Thermal injury also appears to increase the risk of preterm birth (Rode, 1990). This may be secondary to the severity of the burn, and its effect on maternal health.

■ Electric Shock

Cases of electric shock during pregnancy are infrequent. Isolated case reports have linked electric shock to spontaneous abortion, placental abruption, fetal burns, maternal cardiac arrhythmias, and stillbirth (Goldman, 2003; Yoong, 1990). During pregnancy, the main factor threatening fetal well-being is the electric current path through the mother's body. A vertical current, as in hand-to-foot or head-to-foot pathways, may course through the uterus and harm the fetus (Sparic, 2016).

Severity of the shock also proportionally affects fetal outcome. Among 15 cases of severe electric shock during pregnancy, the fetal mortality rate was 73 percent (Fatovich, 1993). In a case series evaluating 13 cases in which gravidas were struck by lightning, the stillbirth rate was 50 percent. One neonate died a few hours after delivery (García Gutierrez, 2005). In contrast, of 28 women who suffered minor electric shock between 4 and 36 weeks' gestation, most of their newborns (94 percent)

had favorable outcomes. No differences were noted in mode of delivery, birth weight, or gestational age at delivery compared with pregnant controls (Einarson, 1997).

■ Accidental Poisoning

The incidence of accidental poisoning during pregnancy is uncertain but probably low. In a review of more than 400 maternal deaths, only one case was secondary to accidental poisoning (Gissler, 2007). Notably, case reports describe hospitalized pregnant women who received accidental overdoses of medications from epidural and magnesium infusion pump errors (McDonnell, 2010; Patel, 2011).

INTENTIONAL TRAUMA

■ Intimate-Partner Violence

Pregnant women who experience intentional trauma are at significant risk for maternal-fetal morbidity and mortality. The most common form of intentional trauma experienced by gravidas is domestic violence (DV), which is also known as intimate-partner violence (IPV).

IPV is a serious problem during pregnancy. Its true incidence is difficult to assess and varies depending on the population examined and definitions used. Reported rates range from 3 to 57 percent (Arslantas, 2012; Beydoun, 2011; Koenig, 2006; Silva, 2011; Stockl, 2012). In a postpartum survey of more than 100,000 women, Cheng and coworkers (2015) found an IPV rate during pregnancy of 6.4 percent. The IPV rate may rise during pregnancy, especially among high-risk groups. Helton and associates (1987) noted that as many as 1 in 12 inner-city women are victims of IPV. In a prospective Australian study, 40 percent of women who reported depressive symptoms 3 to 12 months postpartum also disclosed suffering IPV (Woolhouse, 2012).

It can be difficult to detect IPV during pregnancy. Victims often present with nonspecific complaints during emergency room or routine prenatal visits. One of the first signs may be depression or substance abuse. Often the perpetrating partner insists on being included in any interaction with a health-care provider.

Maternal risk factors for IPV are numerous. They include low socioeconomic status, low education-level attainment, maternal or intimate-partner substance abuse, unintended pregnancy, experiencing IPV before pregnancy, witnessing violence as a child, and unmarried status (Castro, 2003; Martin, 1996; Meuleners, 2011; Quinlivan 2001; Umeora, 2008).

IPV has been linked with an increased rate of spontaneous abortion, neonatal intensive care unit (NICU) admissions, and low birthweight (Fanslow, 2008; Jagoe, 2000; Yang, 2006; Yost, 2005). In addition, the risk of preterm birth is estimated to rise threefold (Rodrigues, 2008). Women reporting IPV in the year prior to pregnancy are also at increased risk for similar adverse outcomes (Silverman, 2006). Several studies have reported a strong association between IPV and peripartum depression (Ludermir, 2010; Urquia, 2011; Woolhouse, 2012). This included a prospective study that followed more than 13,000 women and infants (Flach, 2011).

Preventively, the American College of Obstetricians and Gynecologists (2012) recommends IPV screening at the first prenatal visit. Screening is repeated at least once per trimester and again at the postpartum visit. Such screening should be done privately and away from family members and friends. Providers ask if the patient has been physically hurt by someone or if they have been threatened by their partner or forced into unwanted sexual activities. Once IPV is identified, patient assistance can be coordinated with social services. The National Domestic Violence Hotline (1-800-799-SAFE [7233]) is a nonprofit telephone referral service that provides individualized information regarding city-specific women's shelter locations, counseling resources, and legal advocacy.

■ Penetrating Trauma

Most reports of penetrating trauma during pregnancy focus on gunshot or stab wounds to the abdomen and consist predominantly of case reports and small cases series. The largest cohorts of women with such injuries come from armed conflicts or civil wars. Therefore, the incidence of penetrating trauma during pregnancy is not known with precision. In one study, penetrating trauma accounted for 9 percent of all pregnant trauma admissions. Of these, 73 percent were handgun-related, 23 percent were from knives, and 4 percent were shotgun wounds (Petrone, 2011). Penetrating abdominal trauma tends to disproportionately affect the fetus. In gravidas who suffer a gunshot wound that penetrates the uterus, only 19 percent of these women will have a concomitant visceral injury (Franger, 1989). Compared with blunt abdominal trauma, penetrating trauma raises the risk of fetal death by 34-fold (95 percent) but not that of maternal death (Petrone, 2011). Awwad and associates (1994) summarized their experience with 14 penetrating trauma cases and large-caliber gunshots in pregnancy during the civil war in Lebanon. In their cohort, the fetal mortality rate was 50 percent, and the maternal mortality rate was 14 percent.

■ Suicide and Homicide

Homicide and suicide are leading causes of death among reproductive-aged females. Using data from the National Violent Death Reporting System, Palladino and coworkers (2011) estimated the rate of suicide and homicide to be 2 and 3 deaths per 100,000 live births, respectively. Suicide may account for as many as 20 percent of postpartum maternal deaths (Lindahl, 2005). Dannenberg and associates (1995) noted that 63 percent of maternal deaths associated with injury were secondary to homicide and 13 percent to suicide. More than 50 percent of the homicides were due to gunshot wounds. However, one retrospective analysis of vital statistics records in North Carolina found the suicide rate was 27-percent lower in a pregnant cohort and 54-percent lower in a postpartum cohort compared with a nonpregnant cohort. Homicide rates were also 73-percent and 50-percent lower in pregnant and postpartum cohorts, respectively (Samandari, 2011).

Several risk factors may heighten surveillance for at-risk gravidas. Substance abuse during pregnancy predisposes women to suicide (Gandhi, 2006). Fetal or neonatal death is another major risk factor for attempting suicide, especially

during the puerperium. In such instances, the risk for a suicide attempt is increased threefold (Schiff, 2006). Also, IPV may be linked to suicide among gravidas in up to 54 percent of cases (Lin, 2011; Palladino, 2011). Of risks for homicide, Cheng and colleagues (2010) estimated that 54 percent of pregnancy-associated homicides were committed by a current or former partner. This percentage varies from 45 to 74 percent throughout the literature (Lin, 2011).

Adverse obstetric outcomes can also be linked to unsuccessful suicide attempts. Attempted suicide occurs in 40 of every 100,000 pregnancies (Samandari, 2011). This is essentially the same rate in the puerperium (Gandhi, 2006). In a review of more than 2000 suicide attempts by pregnant women in California, Gandhi and colleagues (2006) found that women who attempted suicide but were unsuccessful had an increased risk of premature labor, cesarean delivery, and need for transfusion. Their offspring had increased rates of respiratory distress syndrome and were more likely to be low birthweight.

Intentional self-poisoning may harm both fetus and mother (Czeizel, 2008; Petik, 2008; Timmermann, 2008). McClure and associates (2011) found an incidence of acute overdose in pregnancy of 26 per 100,000 person years. The risk may be greatest within the first weeks of gestation. Namely, 38 to 45 percent of all intentional drug overdoses occurred in this time (Czeizel, 1999). In a study spanning more than 20 years by Flint and coworkers (2002), suicide attempted by drug overdose increased the risk of miscarriage by 24-fold. Interestingly, neonates born after intentional drug overdose did not show greater rates of fetal malformations (Czeizel, 2008). In one analysis of nearly 660 suicide attempts by medication ingestion during pregnancy, two women (0.4 percent) died (Czeizel, 1999). The most frequently overdosed drugs during pregnancy are analgesics and antipyretics (McClure, 2011). After a failed suicide attempt, patients should be managed in conjunction with a mental health provider experienced in treating pregnant patients.

MANAGEMENT

■ Initial Assessment

Care of the pregnant trauma patient should be systematic and in many cases multidisciplinary. A primary goal is to stabilize the cardiopulmonary status of the gravida. Fetal outcomes and survival rates are improved if early and aggressive maternal resuscitation is provided (Brown, 2009). First responders should assess the trauma's severity. Some trauma protocols include the use of military antishock trousers (MAST). However, during the second and third trimester, these may be harmful to the fetus by means of diminishing uterine blood flow. Thus, some recommend against their use (Pearse, 1984).

Once in the emergency department, the injured gravida may ideally undergo a combined evaluation by both trauma and obstetric teams. Figure 17-6 presents a suggested algorithm. Gestational age and fetal viability are determined as quickly and accurately as possible. This will dictate and modify several interventions (El Kady, 2004). Several methods have been proposed to quantify severity, although none have been specifically designed for or evaluated in pregnant women. The most commonly used

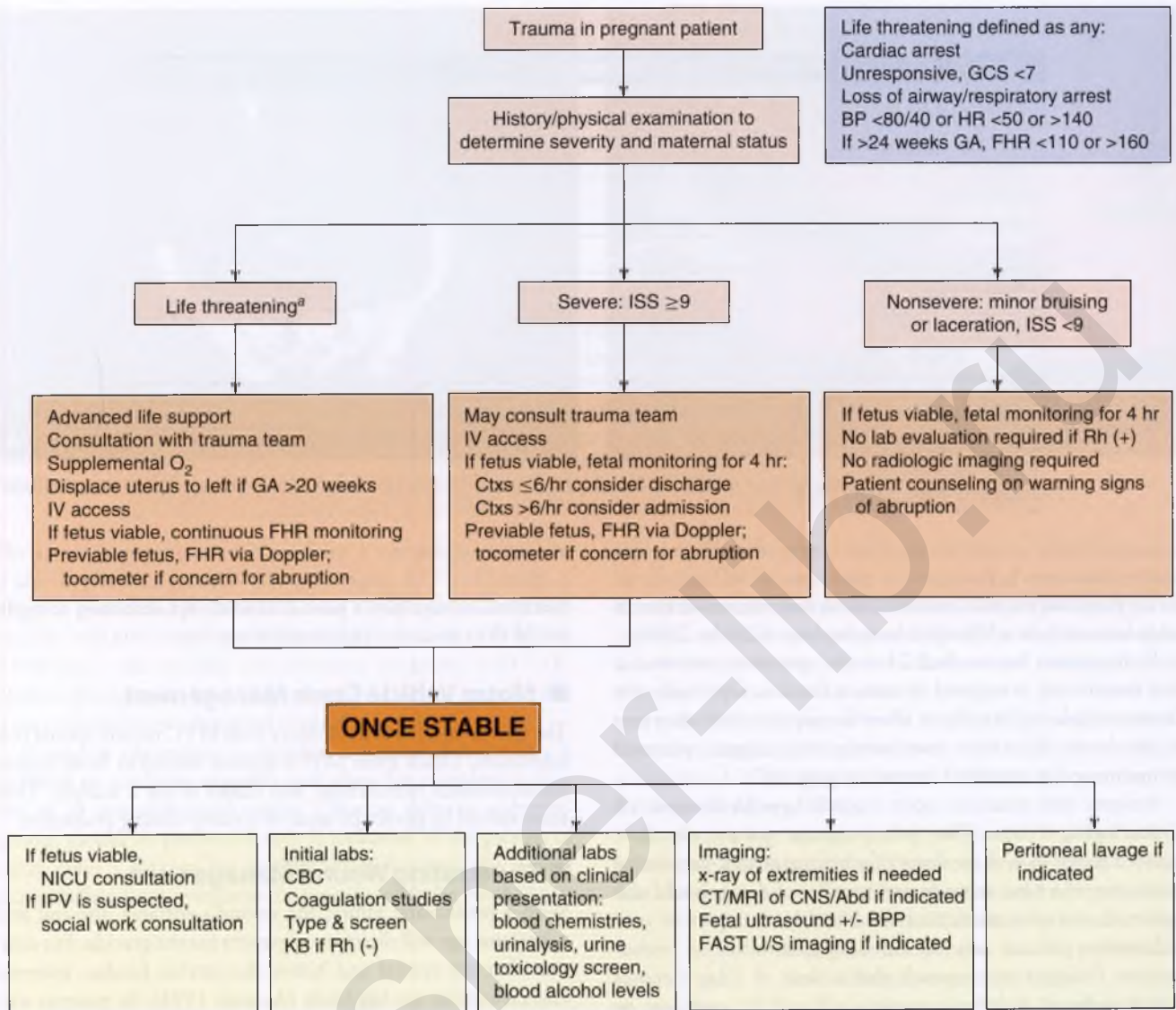


FIGURE 17-6 Algorithm for trauma management in pregnancy. ^aLife-threatening defined in right upper box. Ab = abdomen; BP = blood pressure; BPP = biophysical profile; CBC = complete blood count; CNS = central nervous system; CT = computed tomography; Ctx = contractions; FAST = Focused Assessment with Sonography for Trauma; FHR = fetal heart rate; GA = gestational age; GCS = Glasgow coma score; HR = heart rate; KB = Kleihauer-Betke; IPV = intimate-partner violence; ISS = injury severity score; IV = intravenous; NICU = neonatal intensive care unit; O₂ = oxygen; U/S = ultrasound.

method is an anatomy-based scoring system that provides an overall score for patients with multiple injuries. As shown in Table 17-2, each region is assigned an *abbreviated injury scale (AIS)* value. Each of the three highest values is squared, and these three squared values are then summed to arrive at a total score, termed the *injury severity score (ISS)*. An assigned ISS ranges from 0 to 75 (Baker, 1974). Typically, an ISS >16 defines severe trauma. In pregnancy, most experts agree that an ISS >9 serves as a comparable severe threshold. This threshold value has been determined to be 86-percent sensitive and 71-percent specific in predicting associated fetal death (Schiff, 2002a).

Concurrent with physical assessment, a brief and focused medical history is gathered. Questions center on trauma specifics such as the wounding device, mechanism of injury, and affected body site. With MVCs, the speed at impact, seatbelt use, and airbag deployment are additional queries.

Dangerous initial physical findings include cardiac arrest, loss of airway, blood pressure <80/40 mm Hg, pulse <50 or >140 bpm, respiratory rate per minute <10 or >24, or a fetal heart rate <110 or >160 bpm. These alert the physician to probable life-threatening trauma requiring cardiopulmonary resuscitation that typically requires advanced cardiac life support (ACLS) and advanced trauma life support (ATLS) protocols. Sufficient intravenous (IV) access may necessitate two large-bore IV catheters. All necessary laboratory tests are ordered at this time, and specific tests are listed in Figure 17-6. Supplemental oxygen by mask or nasal cannula should always be considered in gravidas because of the physiologic changes of pregnancy that predispose to hypoxia (p. 276).

Evaluation of the cervical spine may be required in some cases. Direct cervical spine trauma makes securing an airway difficult. An anesthesiologist with experience managing airways

TABLE 17-2. Injury Severity Scoring

Region	Injury Description	AIS Value ^a	Calculation ^b
Head/neck			
Face			
Chest			
Abdomen			
Extremities/pelvic girdle			
External			
Total score			

Abbreviated injury scale (AIS) (1-5)
0 = No injury 1 = Minor 2 = Moderate 3 = Serious 4 = Severe 5 = Critical

^aEach site is assigned an injury scale value from 1 to 5.

^bEach of the top 3 values are squared. These 3 squared values are then summed to reach the assigned total score.

Adapted from Baker, 1974.

during pregnancy is ideal, and intubation may require additional equipment such as a fiberoptic bronchoscope (Crosby, 2006).

If the patient has reached 24 weeks' gestation, continuous fetal monitoring is initiated as soon as feasible. Optimally, the uterus is displaced laterally to allow for adequate venous return to the heart. Electronic monitoring may suggest placental abruption and is described further on page 287.

Patients with traumatic open wounds have an elevated risk of developing tetanus. Therefore, pregnant women who have received fewer than three doses of a tetanus toxoid-containing vaccine or who have an unknown number of doses should also receive the tetanus immunization. Notably, as a part of normal routine prenatal care, the Advisory Committee on Immunization Practices recommends that a dose of Tdap (tetanus toxoid, reduced diphtheria toxoid, and acellular pertussis) be given to women during each pregnancy, optimally between 27 and 36 weeks' gestation to maximize passive pertussis antibody transfer to the fetus (American College of Obstetricians and Gynecologists, 2015; Centers for Disease Control and Prevention, 2013). Thus, for gravidas in these later weeks of pregnancy, Tdap may be preferred to Td (Tetanus, diphtheria) vaccination.

■ Minor Trauma

If only minor trauma is identified during pregnancy, further treatment may be focused and limited. In pregnancy, minor trauma constitutes injury with an ISS of 0 and usually includes only minor bruising, lacerations, or contusions. These patients tend to have favorable outcomes similar to those for noninjured gravidas (Garmi, 2014). However, Cahill and colleagues (2008) prospectively evaluated more than 300 pregnancies complicated by minor trauma. These authors concluded that none of the variables tested in cases of minor trauma were adequate predictors of placental abruption. From this, they recommend that gravidas who have experienced minor trauma may benefit from limited fetal assessment but without maternal radiologic or laboratory evaluation. Tikkanen and associates (2006) also

described sonography's poor sensitivity for detecting retroplacental clots in cases of placental abruption.

■ Motor Vehicle Crash Management

The specific mechanisms of injury with MVC require special considerations. Death from MVCs appears related to head trauma, intraabdominal hemorrhage, and failure to use a seatbelt. Thus, these should be particular areas of scrutiny during evaluation.

■ Penetrating Wound Management

With a penetrating injury, the wound's entrance site and fetal gestational age will direct management for the gravida. For entry sites that are ventral and below the uterine fundus, maternal visceral injuries are less likely (Awwad, 1994). In patients with blunt abdominal trauma experiencing severe abdominal tenderness, several findings will guide care. Namely, surgical exploration of the abdomen is indicated if computed tomography (CT) scans show abnormal findings such as intraabdominal air or moderate-to-large amounts of free fluid. Other indications for exploration include abdominal gunshot wound, penetrating trauma into the peritoneum, or a positive peritoneal lavage. In these cases, consultation with a general surgeon is typically prudent (Fig. 17-7).

Diagnostic peritoneal lavage can be safely done in pregnancy. If required, several authors have suggested a direct visualization technique. First, a Foley catheter and a nasogastric tube are placed to decompress the bladder and stomach, respectively. Approximately 2 cm cephalad to the umbilicus, all layers of the anterior abdominal wall including the skin, linea alba fascia, and peritoneum are opened under direct visualization (Fig. 17-8). A diagnostic peritoneal lavage catheter is then inserted, and direct fluid aspiration should be attempted. If >10 mL of blood or enteric content are aspirated, the lavage is considered positive. If no blood or enteric content is aspirated, 1 liter of warm normal saline is instilled into the abdomen and allowed to drain passively. Of this liter, fluid analysis will require at least 300 mL to be retrieved.

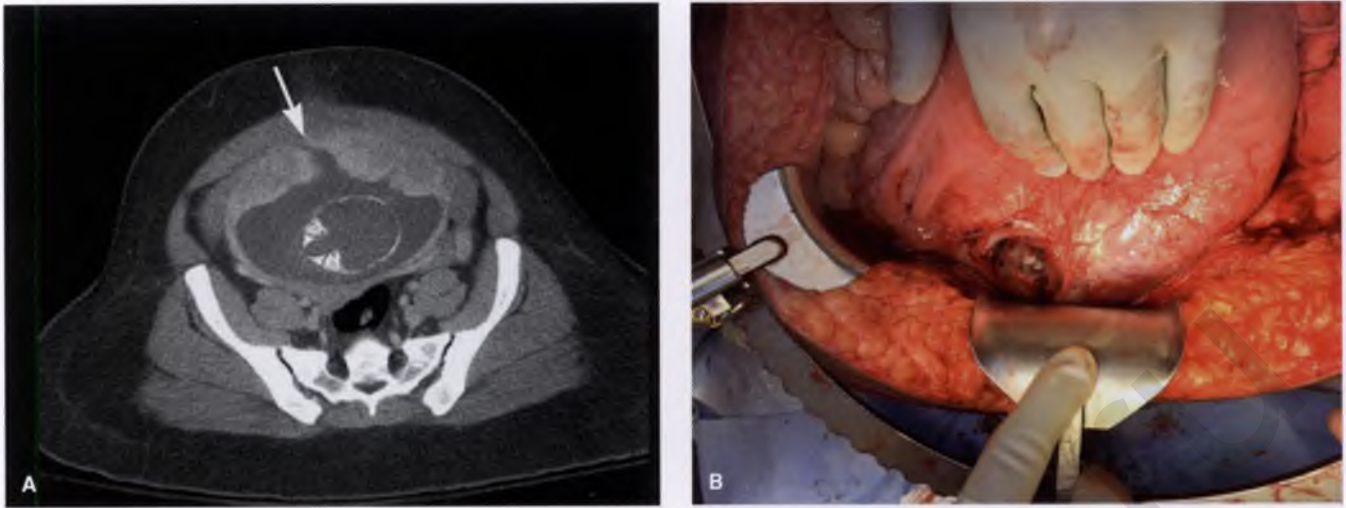


FIGURE 17-7 Computed tomography scan (A) and intraabdominal view (B) of uterine rupture after blunt abdominal trauma.

The same diagnostic criteria used for a nonpregnant patient is also applied to gravidas (Rothenberger, 1977). Namely, a lavage is considered positive if the red blood cell count (RBC) exceeds $100,000/\text{mm}^3$, the white blood cell count (WBC) is $>500/\text{mm}^3$, the amylase concentration measures >20 U/L, alkaline phosphatase level surpasses ≥ 10 U/L, or enteric contents or bacteria are identified (Saunders, 1998).

If surgical exploration is required, a vertical skin incision is preferred to maximize exposure and allow for complete evaluation of all intraabdominal organs. Cesarean delivery or hysterectomy should be performed only if indicated. If the pattern of injury raises a concern for possible stomach injury, the ventral gastric surface from pylorus to the junction with the esophagus is

explored. Also, the greater and lesser curvatures, where lesions may be obscured by the omentum, are inspected. A systematic exploration of the small intestine and mesentery begins proximally at the ligament of Trietz and progresses distally to the ileocecal valve. If bowel injury is detected, immediate control measures include isolating the rent with laparotomy sponges to limit bowel content spill. With a suspected bowel injury, a single preoperative IV dose of an antibiotic with both aerobic and anaerobic coverage is administered. If injury is confirmed, antibiotics are continued for 24 hours (Goldberg, 2012).

In penetrating injuries during pregnancy, fetal intracranial injuries are associated with a 50-percent fetal death rate. Therefore, the decision to deliver a fetus that has suffered a penetrating wound in utero is dictated by lesion severity, fetal heart rate pattern, and the potential for survival based on gestational age.

If a thoracostomy tube is required during advancing pregnancy, the tube should be placed at least one or two intercostal spaces above the usual landmark, which is the fifth intercostal space. This avoids inadvertent abdominal insertion (Brown, 2009).

■ Pelvic Fracture

During evaluation, hematuria raises the concern for a pelvic fracture. This can be life-threatening to the mother and is associated with a fetal death rate of 35 percent (Shah, 1998). Later, from an obstetric standpoint, pelvic fracture is not necessarily an indication for cesarean delivery. Most women can safely attempt vaginal birth even if the fracture occurred during the third trimester.

■ Burn Management

Pregnant burn victims should receive aggressive fluid resuscitation using Ringer lactate solution during the first 24 hours.

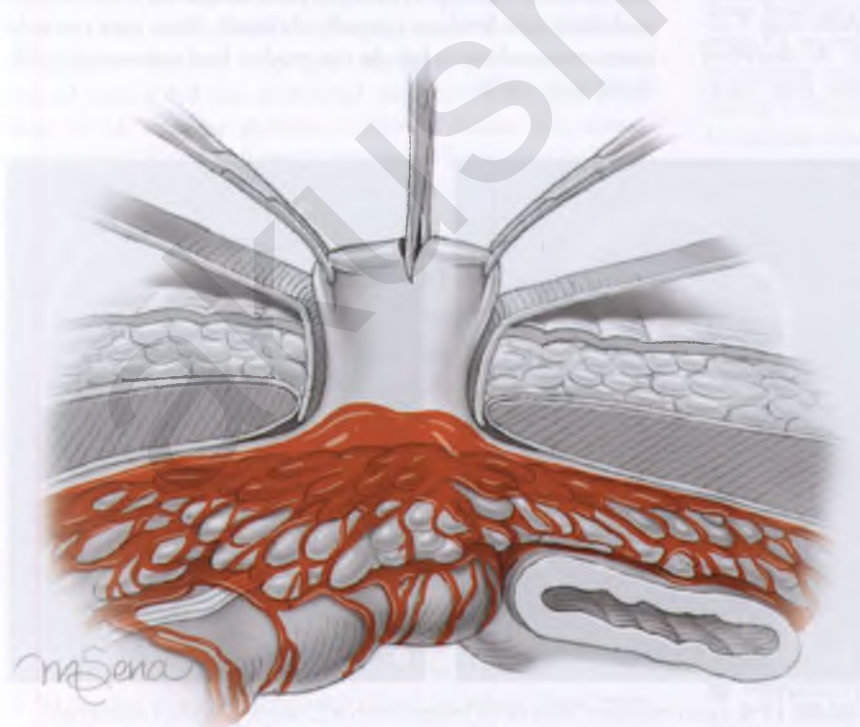


FIGURE 17-8 Diagnostic peritoneal lavage performed using the direct visualization technique. Following skin and linea alba incision, the peritoneum is elevated by hemostats and sharply entered.

The Parkland formula for fluid administration following a burn is: fluid volume (mL) = $4 \times \text{weight (kg)} \times \text{percent TBSA burned}$. Thus, a 50-kg gravida with a 20-percent TBSA burn would require: $4 \times 50 \times 20 = 4000$ mL. Half this volume is infused in the first 8 hours (Baxter, 1968). Respiratory support and initial wound care are also initiated. During patient care, clinicians should be cognizant of the high mortality rate of fetuses in the second and third trimester if the mother has sustained burns exceeding 50 percent of TBSA (Guo, 2001). Ultimately, the patient with a significant burn is best transported to a burn unit facility.

Inhalation injuries complicate a significant percentage of major burns. Distinct problems of inhalation injury include upper airway thermal burns and carbon monoxide poisoning. First, direct inhalation injury can result in significant airway compromise and subsequent hypoxia. For upper airway burns, humidified oxygen, attentive pulmonary toilet, and if indicated, prophylactic endotracheal intubation are treatment mainstays. Carbon monoxide poisoning is also excluded. For this, standard pulse oximetry is insufficient. Rather, a carboxyhemoglobin level obtained from an arterial blood gas specimen is measured. Poisoning is diagnosed with elevated levels of 10 to 15 percent.

■ Imaging

Physical examination of the mother is always completed prior to diagnostic imaging. As a rule, modalities that use nonionizing radiation such as sonography and magnetic resonance (MR) imaging are preferred in pregnancy (Fig. 17-9). However, with the latter, the longer acquisition times and the difficulty with adequate patient monitoring may limit the role of MR imaging for the severely injured patient (Puri, 2012).

During imaging selection, the anticipated total radiation exposure to the fetus is carefully evaluated (American College of Obstetricians and Gynecologists, 2016). As described fully in Chapter 5 (p. 68), most experts agree that intrauterine fetal exposure to <50 mGy (5 rads) is not associated with adverse fetal effects. CT scanning of the abdomen or pelvis exposes the fetus to a total radiation dose of 35 mGy (3.5 rads), which is the most of any imaging modality. Thus, many support sonography as the preferred initial imaging tool for evaluating the pregnant abdomen and pelvis (Hui, 2009).

Gestational age is also an important factor to consider. Doses between 50 to 100 mGy (5 to 10 rads) between 5 and 17 weeks' gestation may be associated with very little risk to the fetus. Outside of this gestational age window, there is probably no risk. Adverse developmental effects are seen with doses above 150 to 200 mGy (15 to 20 rads) between 11 and 17 weeks' gestation but not after this time frame (Puri, 2012).

Chest trauma typically prompts imaging to identify bone fracture or exclude cardiac or pulmonary contusion or blood

collections. If clinically indicated, CT scan can be considered in cases of head or neck trauma. The physical distance from the uterus and abdominal shielding can help to lower anticipated fetal radiation exposure.

Blunt or penetrating abdominal trauma can lead to intraperitoneal hemorrhage, and the liver and the spleen are most likely to be damaged in the second and third trimester. Sonography has become an invaluable tool in this assessment. Specifically, Focused Assessment with Sonography for Trauma (FAST) is a safe and efficient method to detect intraperitoneal free fluid and intraabdominal injuries (Fig. 17-10). This examination can be performed in the emergency department and is done by assessing four areas for evidence of free fluid: the subxiphoid, the right upper quadrant, the left upper quadrant, and the suprapubic area. FAST provides suitable accuracy and has a sensitivity of 61 to 83 percent and a specificity of 94 to 100 percent for detecting intraabdominal injury (Puri, 2012). Additionally, sonography can provide critical information on the fetus, including gestational age, placental location, fetal presentation, and viability.

Abdominal CT is an alternate imaging tool that permits the evaluation of multiple organ systems with one imaging modality. In stable nonpregnant patients, CT scan is the preferred modality (Rhea, 2004). However, the utility of CT as a screening tool following blunt abdominal trauma in pregnancy has not been established, again due to radiation concerns (Puri, 2012).

■ Laboratory Evaluation

With significant maternal injury, complete blood count (CBC), type and screen, and coagulation studies that include prothrombin time (PT), partial thromboplastin time (PTT), and fibrinogen level are typically obtained. These tests can help assess maternal status but do not predict fetal outcome (Cahill, 2008; Pak, 1998).

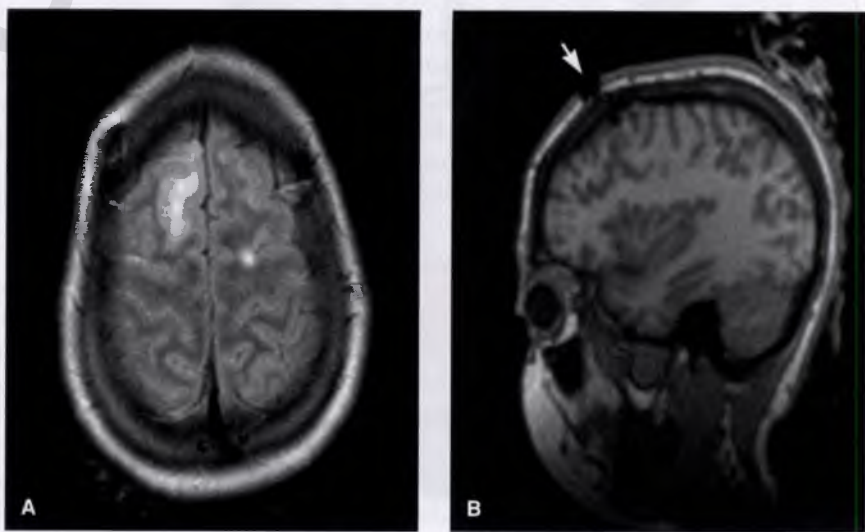


FIGURE 17-9 Head magnetic resonance images from a 22-week-pregnant restrained passenger involved in a high-speed motor vehicle crash. **A.** This fluid attenuation inversion recovery (FLAIR) sequence shows cerebral edema in the frontal lobe, which is seen on the left as an area of increased brightness. **B.** This T1-weighted image shows a soft tissue laceration and adjacent skull fracture (arrow).

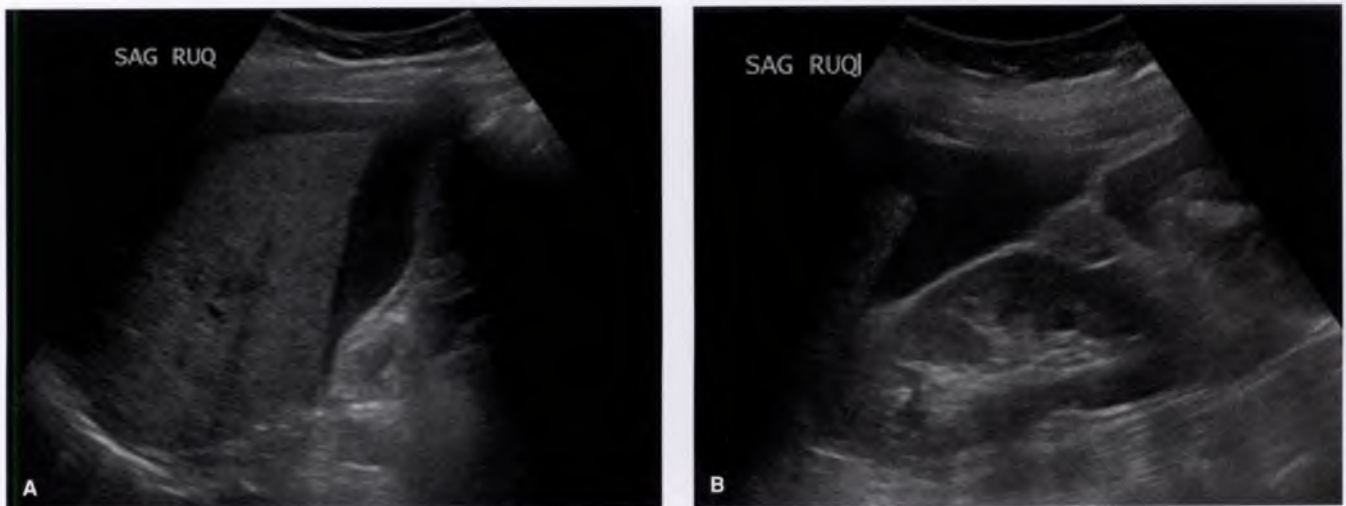


FIGURE 17-10 Right upper quadrant sonographic images show anechoic fluid. **A.** The liver edge is surrounded by fluid. **B.** Fluid is seen between the liver edge and kidney.

Fetal-maternal hemorrhage occurs in up to 30 percent of pregnant women who suffer severe trauma (Pearlman, 1990). The Kleihauer-Betke (KB) acid elution technique can detect this hemorrhage. However, the test is insensitive and poorly predictive of adverse perinatal outcomes, preterm birth, placental abruption, or fetal distress (Dhanraj, 2004; Pak, 1998; Trivedi, 2012). Thus, routine KB testing as part of an acute trauma evaluation in pregnancy is neither cost effective nor practical (Towery, 1993). In cases of minor trauma, it is unnecessary (Cahill, 2008).

However, the KB test does allow calculation of the total dose of Rh immune globulin required for Rh-negative mothers. Specifically, one vial of 300 μ g protects against 30 mL of fetal blood (15 mL of fetal RBCs) (Cunningham, 2014b). Therefore, Rh-negative mothers who have sustained abdominal trauma should have a KB test performed and receive an appropriate dose of Rh immune globulin within 72 hours. The hemorrhaged fetal blood volume is calculated from the Kleihauer-Betke test result using the following formula:

$$\text{Fetal blood volume} = \frac{\text{MBV} \times \text{maternal Hct} \times \% \text{ fetal cells in KB volume}}{\text{newborn Hct}}$$

One method is to estimate the maternal blood volume (MBV) as 5000 mL for a normal-size, normotensive women at term. Thus, for 1.7-percent positive KB-stained cells in a woman of average size with a hematocrit of 35 percent giving birth to a term infant weighing 3000 g and whose hematocrit is 50 percent:

$$\text{Fetal blood volume} = \frac{5000 \times 0.35 \times 0.017}{0.5} = 60 \text{ mL}$$

The fetal-placental blood volume at term approximates 125 mL/kg. For this 3000-g fetus, that would equate to 375 mL. Thus, this fetus has lost approximately 15 percent (60 \div 375 mL) of the fetal-placental volume. Because the hematocrit is 50 percent in a term fetus, this 60 mL of whole blood represents 30 mL of red cells lost over time into the maternal circulation. This loss should be well tolerated hemodynamically but would require two 300- μ g doses of anti-D immunoglobulin to prevent alloimmunization (Cunningham, 2014b).

■ Fetal Monitoring

This is initiated once the maternal condition has been stabilized. The optimal duration for fetal monitoring after maternal trauma has not been established. Recommendations range from 4 to 48 hours (Mirza, 2010). Placental abruption has been reported as late as 24 hours after a traumatic insult (Brown, 2009). However, this is more the exception than the norm.

Several studies provide evidence to guide practice. First, among 205 cases of noncatastrophic trauma, complications developed in 17 of 88 women with contractions, bleeding, or uterine tenderness but in only 1 of 117 women who lacked these findings (Goodwin, 1990). In a prospective study evaluating 85 women with trauma, no adverse outcomes developed in patients who had contractions less than every 15 minutes during 4 hours of continuous monitoring (Pearlman, 1990). In another study, placental abruption was not seen when less than one contraction was present in a 10-minute interval over a 4-hour period (Dahmus, 1993). In one review of nearly 500 trauma cases in pregnancy, no adverse outcomes were reported in women who had normal monitor tracings (Connolly, 1997). Based on these studies, it seems reasonable to discontinue fetal monitoring after 4 hours when uterine contractions are less frequent than every 10 minutes, the fetal heart tracing is overall reassuring, and maternal abdominal pain, uterine tenderness, and vaginal bleeding are absent. Blunt abdominal trauma at 35 weeks' gestation or older is a significant risk factor for contractions and preterm birth and thus may warrant longer monitoring. Some experts advocate hospital admission for 24 to 48 hours of observation (Curet, 2000). Importantly, if tocolytics are used for contractions, they may obfuscate findings, and we do not recommend them.

■ Perimortem Cesarean Delivery

After maternal cardiopulmonary arrest, cesarean delivery can be lifesaving for both mother and fetus. Survival of both depends on multiple factors including the interval between maternal cardiac arrest and delivery, the underlying cause for the arrest,

arrest location, and expertise of the emergency medical team (Thomas, 2000). In a case series of five cardiac arrests following anesthesia induction, Marx (1982) noted that three patients who underwent immediate cesarean delivery had favorable maternal and fetal outcomes. In the other two patients, cesarean delivery was performed 6 and 9 minutes after the arrest, and both mothers suffered irreversible brain damage (Marx, 1982). In a historic review of 269 cases of perimortem cesarean delivery, Katz and associates (1986) noted that fetal survival was rare if delivery occurred more than 10 minutes after maternal death. In another study, fetal survival was noted to be extremely unlikely if more than 15 to 20 minutes had elapsed after the loss of maternal vital signs. Urgent cesarean or perimortem cesarean delivery may be appropriate in the setting of imminent maternal death after 4 minutes of adequate cardiopulmonary resuscitation (CPR). Notably, ineffective CPR efforts may become effective following delivery as a result of decreased fetal-placental mass and improved volume return to the maternal heart. Both neonatal and maternal survival rates are increased if cesarean delivery is initiated within 4 minutes of maternal cardiac arrest and delivery occurs within 5 minutes of initiating CPR (Morris, 1996).

SUMMARY

Trauma in pregnancy is relatively common. Clinicians should be aware of risk factors, physiologic and anatomic changes of pregnancy, efficient diagnostic evaluation, and management options. The major factor dictating outcomes appears to be the severity of trauma. The initial management goal is to stabilize and improve maternal status, especially cardiopulmonary function. Diagnostic imaging should not be withheld secondary to theoretical risks to the fetus. Care often requires a multidisciplinary team to provide the best outcomes possible.

REFERENCES

- Abbassi-Ghanavati M, Greer LG, Cunningham FG: Pregnancy and laboratory studies: a reference table for clinicians. *Obstet Gynecol* 114:1326, 2009
- Aboutanos MB, Aboutanos SZ, Dompkowski D, et al: Significance of motor vehicle crashes and pelvic injury on fetal mortality: a five-year institutional review. *J Trauma* 65:616, 2008
- Akhtar MA, Mulawkar PM, Kulkarni HR: Burns in pregnancy: effect on maternal and fetal outcomes. *Burns* 20:351, 1994
- Ali J, Yeo A, Gana TJ, et al: Predictors of fetal mortality in pregnant trauma patients. *J Trauma* 42:782, 1997
- American College of Obstetricians and Gynecologists: Guidelines for diagnostic imaging during pregnancy. Committee Opinion No. 656, February 2016
- American College of Obstetricians and Gynecologists: Intimate partner violence. Committee Opinion No. 518, February 2012
- American College of Obstetricians and Gynecologists: Update on immunization and pregnancy: tetanus, diphtheria, and pertussis vaccination. Committee Opinion No. 566, June 2013, Reaffirmed 2015
- Arslantas H, Adana F, Ergin F, et al: Domestic violence during pregnancy in an eastern city of Turkey: a field study. *J Interpers Violence* 27:1293, 2012
- Awwad JT, Azar GB, Seoud MA, et al: High-velocity penetrating wounds of the gravid uterus: review of 16 years of civil war. *Obstet Gynecol* 83:259, 1994
- Azar T, Longo C, Oddy L, et al: Motor vehicle collision-related accidents in pregnancy. *J Obstet Gynaecol Res* 41(9):1370, 2015
- Baker SP, O'Neill B, Haddon W Jr, et al: The injury severity score: a method for describing patients with multiple injuries and evaluating emergency care. *J Trauma* 14:187, 1974
- Bard MR, Shaikh S, Pestaner J, et al: Direct fetal injury due to airbag deployment and three-point restraint. *J Trauma* 67:E98, 2009
- Baxter CR, Shires T: Physiologic response to crystalloid resuscitation of severe burns. *Ann N Y Acad Sci* 150:874, 1968
- Beydoun HA, Tamim H, Lincoln AM, et al: Association of physical violence by an intimate partner around the time of pregnancy with inadequate gestational weight gain. *Soc Sci Med* 72:867, 2011
- Brown HL: Trauma in pregnancy. *Obstet Gynecol* 114:147, 2009
- Cahill AG, Bastek JA, Stamilio DM, et al: Minor trauma in pregnancy—is the evaluation unwarranted? *Am J Obstet Gynecol* 198:208 e1, 2008
- Castro R, Peek-Asa C, Ruiz A: Violence against women in Mexico: a study of abuse before and during pregnancy. *Am J Public Health* 93:1110, 2003
- Centers for Disease Control and Prevention: Injury prevention & control: data & statistics (WISQARS). 2015. <http://www.cdc.gov/injury/wisqars/> Accessed November 30, 2015
- Centers for Disease Control and Prevention: Updated recommendations for use of tetanus toxoid, reduced diphtheria toxoid, and acellular pertussis vaccine (Tdap) in pregnant women—Advisory Committee on Immunization Practices (ACIP), 2012. *MMWR* 62(7):131, 2013
- Chama CM, Na'Aya HU: Severe burn injury in pregnancy in Northern Nigeria. *J Obstet Gynaecol* 22:20, 2002
- Cheng D, Horon IL: Intimate-partner homicide among pregnant and postpartum women. *Obstet Gynecol* 115:1181, 2010
- Cheng D, Salimi S, Terplan M, et al: Intimate partner violence and maternal cigarette smoking before and during pregnancy. *Obstet Gynecol* 125:356, 2015
- Chibber R, Al-Harmi J, Fouda M, et al: Motor-vehicle injury in pregnancy and subsequent fetomaternal outcomes: of grave concern. *J Matern Fetal Neonatal Med* 28:399, 2015
- Connolly AM, Katz VL, Bash KL, et al: Trauma and pregnancy. *Am J Perinatol* 14:331, 1997
- Crosby ET: Airway management in adults after cervical spine trauma. *Anesthesiology* 104:1293, 2006
- Crosby WM, Costiloe JP: Safety of lap-belt restraint for pregnant victims of automobile collisions. *N Engl J Med* 284:632, 1971
- Crosby WM, King AI, Stout LC: Fetal survival following impact: improvement with shoulder harness restraint. *Am J Obstet Gynecol* 112:1101, 1972
- Cunningham FG, Leveno KJ, Bloom SL, et al (eds): Critical care and trauma. In *Williams Obstetrics*, 24th ed. New York, McGraw-Hill Education, 2014a
- Cunningham FG, Leveno KJ, Bloom SL, et al (eds): Fetal disorders. In *Williams Obstetrics*, 24th ed. New York, McGraw-Hill Education, 2014b
- Curet MJ, Schermer CR, Demarest GB, et al: Predictors of outcome in trauma during pregnancy: identification of patients who can be monitored for less than 6 hours. *J Trauma* 49:18, 2000
- Czeizel AE, Gidai J, Petik D, et al: Self-poisoning during pregnancy as a model for teratogenic risk estimation of drugs. *Toxicol Ind Health* 24:11, 2008
- Czeizel AE, Timar L, Susanszky E: Timing of suicide attempts by self-poisoning during pregnancy and pregnancy outcomes. *Int J Gynaecol Obstet* 65:39, 1999
- Dahmus MA, Sibai BM: Blunt abdominal trauma: are there any predictive factors for abruptio placentae or maternal-fetal distress? *Am J Obstet Gynecol* 169:1054, 1993
- Dannenber AL, Carter DM, Lawson HW, et al: Homicide and other injuries as causes of maternal death in New York City, 1987 through 1991. *Am J Obstet Gynecol* 172:1557, 1995
- Dhanraj D, Lambers D: The incidences of positive Kleihauer-Betke test in low-risk pregnancies and maternal trauma patients. *Am J Obstet Gynecol* 190:1461, 2004
- Dunning K, LeMasters G, Bhattacharya A: A major public health issue: the high incidence of falls during pregnancy. *Matern Child Health J* 14(5):720, 2010
- Dunning K, LeMasters G, Levin L, et al: Falls in workers during pregnancy: risk factors, job hazards, and high risk occupations. *Am J Ind Med* 44:664, 2003
- Einarson A, Bailey B, Inocencion G, et al: Accidental electric shock in pregnancy: a prospective cohort study. *Am J Obstet Gynecol* 176:678, 1997
- El Kady D: Perinatal outcomes of traumatic injuries during pregnancy. *Clin Obstet Gynecol* 50:582, 2007
- El Kady D, Gilbert WM, Anderson J, et al: Trauma during pregnancy: an analysis of maternal and fetal outcomes in a large population. *Am J Obstet Gynecol* 190:1661, 2004
- Elliott M: Vehicular accidents and pregnancy. *Aust N Z J Obstet Gynaecol* 6:279, 1966
- Fanslow J, Silva M, Whitehead A, et al: Pregnancy outcomes and intimate partner violence in New Zealand. *Aust N Z J Obstet Gynaecol* 48:391, 2008
- Fatovich DM: Electric shock in pregnancy. *J Emerg Med* 11:175, 1993
- Fildes J, Reed L, Jones N, et al: Trauma: the leading cause of maternal death. *J Trauma* 32:643, 1992

- Flach C, Leese M, Heron J, et al: Antenatal domestic violence, maternal mental health and subsequent child behaviour: a cohort study. *BJOG* 118:1383, 2011
- Flint C, Larsen H, Nielsen GL, et al: Pregnancy outcome after suicide attempt by drug use: a Danish population-based study. *Acta Obstet Gynecol Scand* 81:516, 2002
- Franger AL, Buchsbaum HJ, Peaceman AM: Abdominal gunshot wounds in pregnancy. *Am J Obstet Gynecol* 160:1124, 1989
- Gandhi SG, Gilbert WM, McElvy SS, et al: Maternal and neonatal outcomes after attempted suicide. *Obstet Gynecol* 107:984, 2006
- Garcia Gutierrez JJ, Melendez J, Torroero JV, et al: Lightning injuries in a pregnant woman: a case report and review of the literature. *Burns* 31:1045, 2005
- Garmi G, Marjeh M, Salim R: Does minor trauma in pregnancy affect perinatal outcome? *Arch Gynecol Obstet* 290:635, 2014
- Gissler M, Deneux-Tharaux C, Alexander S, et al: Pregnancy-related deaths in four regions of Europe and the United States in 1999–2000: characterisation of unreported deaths. *Eur J Obstet Gynecol Reprod Biol* 133:179, 2007
- Goldberg SR, Anand RJ, Como JJ, et al: Prophylactic antibiotic use in penetrating abdominal trauma: an Eastern Association for the Surgery of Trauma practice management guideline. *J Trauma Acute Care Surg* 73:S321, 2012
- Goldman RD, Einarson A, Koren G: Electric shock during pregnancy. *Can Fam Physician* 49:297, 2003
- Goodwin TM, Breen MT: Pregnancy outcome and fetomaternal hemorrhage after noncatastrophic trauma. *Am J Obstet Gynecol* 162:665, 1990
- Guo SS, Greenspoon JS, Kahn AM: Management of burn injuries during pregnancy. *Burns* 27:394, 2001
- Helton AS, McFarlane J, Anderson ET: Battered and pregnant: a prevalence study. *Am J Public Health* 77:1337, 1987
- Hill CC, Pickinpaugh J: Trauma and surgical emergencies in the obstetric patient. *Surg Clin North Am* 88:421, 2008
- Hui CM, MacGregor JH, Tien HC, et al: Radiation dose from initial trauma assessment and resuscitation: review of the literature. *Can J Surg* 52:147, 2009
- Hyde LK, Cook LJ, Olson LM, et al: Effect of motor vehicle crashes on adverse fetal outcomes. *Obstet Gynecol* 102:279, 2003
- Ikossi DG, Lazar AA, Morabito D, et al: Profile of mothers at risk: an analysis of injury and pregnancy loss in 1,195 trauma patients. *J Am Coll Surg* 200:49, 2005
- Jagoe J, Magann EF, Chauhan SP, et al: The effects of physical abuse on pregnancy outcomes in a low-risk obstetric population. *Am J Obstet Gynecol* 182:1067, 2000
- Jain ML, Garg AK: Burns with pregnancy—a review of 25 cases. *Burns* 19:166, 1993
- John PR, Shiozawa A, Haut ER, et al: An assessment of the impact of pregnancy on trauma mortality. *Surgery* 149:94, 2011
- Karimi H, Momeni M, Rahbar H: Burn injuries during pregnancy in Iran. *Int J Gynaecol Obstet* 104:132, 2009
- Katz VL, Dotters DJ, Droegemueller W: Perimortem cesarean delivery. *Obstet Gynecol* 68:571, 1986
- Koenig LJ, Whitaker DJ, Royce RA, et al: Physical and sexual violence during pregnancy and after delivery: a prospective multistate study of women with or at risk for HIV infection. *Am J Public Health* 96:1052, 2006
- Kortbeek JB, Al Turki SA, Ali J, et al: Advanced trauma life support, 8th edition, the evidence for change. *J Trauma* 64:1638, 2008
- Kuhlmann RS, Cruikshank DP: Maternal trauma during pregnancy. *Clin Obstet Gynecol* 37:274, 1994
- Kuo C, Jamieson DJ, McPheeters ML et al: Injury hospitalizations of pregnant women in the United States, 2002. *Am J Obstet Gynecol* 196:161 e1, 2007
- Kvarnstrand L, Milsom I, Lekander T, et al: Maternal fatalities, fetal and neonatal deaths related to motor vehicle crashes during pregnancy: a national population-based study. *Acta Obstet Gynecol Scand* 87:946, 2008
- Lin P, Gill JR: Homicides of pregnant women. *Am J Forensic Med Pathol* 32:161, 2011
- Lindahl V, Pearson JL, Colpe L: Prevalence of suicidality during pregnancy and the postpartum. *Arch Womens Ment Health* 8:77, 2005
- Ludermir AB, Lewis G, Valongueiro SA, et al: Violence against women by their intimate partner during pregnancy and postnatal depression: a prospective cohort study. *Lancet* 376:903, 2010
- Luley T, Fitzpatrick CB, Grotegut CA, et al: Perinatal implications of motor vehicle accident trauma during pregnancy: identifying populations at risk. *Am J Obstet Gynecol* 208:466 e1, 2013
- Maghsoudi H, Samnia R, Garadaghi A, et al: Burns in pregnancy. *Burns* 32:246, 2006
- Martin SL, English KT, Clark KA, et al: Violence and substance use among North Carolina pregnant women. *Am J Public Health* 86:991, 1996
- Marx GF: Cardiopulmonary resuscitation of late-pregnant women. *Anesthesiology* 56:156, 1982
- Marx GF: Shock in the obstetric patient. *Anesthesiology* 26:423, 1965.
- McClure CK, Patrick TE, Katz KD, et al: Birth outcomes following self-inflicted poisoning during pregnancy, California, 2000 to 2004. *J Obstet Gynecol Neonatal Nurs* 40:292, 2011
- McDonnell NJ, Muchatuta NA, Paech MJ: Acute magnesium toxicity in an obstetric patient undergoing general anaesthesia for caesarean delivery. *Int J Obstet Anesth* 19:226, 2010
- McCrorry JL, Chambers AJ, Dafary A, et al: Dynamic postural stability during advancing pregnancy. *J Biomech* 43:2434, 2010
- Metz TD, Abbott JT: Uterine trauma in pregnancy after motor vehicle crashes with airbag deployment: a 30-case series. *J Trauma* 61:658, 2006
- Meuleners LB, Lee AH, Janssen PA, et al: Maternal and foetal outcomes among pregnant women hospitalised due to interpersonal violence: a population based study in Western Australia, 2002–2008. *BMC Pregnancy Childbirth* 11:70, 2011
- Mirza FG, Devine PC, Gaddipati S: Trauma in pregnancy: a systematic approach. *Am J Perinatol* 27(7):579, 2010
- Morris JD, Abbott JT, Rosenbower TJ, Jurkovich GJ, et al: Infant survival after cesarean section for trauma. *Ann Surg* 223:481, 1996
- Motozawa Y, Hitosugi M, Abe T, et al: Effects of seat belts worn by pregnant drivers during low-impact collisions. *Am J Obstet Gynecol* 203:62 e1, 2010
- National Highway Traffic Safety Administration: Occupant protection. Available at: <http://www.nhtsa.gov/DrivingSafety/OccupantProtection>. Accessed November 27, 2015
- Pak LL, Reece EA, Chan L: Is adverse pregnancy outcome predictable after blunt abdominal trauma? *Am J Obstet Gynecol* 179:1140, 1998
- Palladino CL, Singh V, Campbell J, et al: Homicide and suicide during the perinatal period: findings from the national violent death reporting system. *Obstet Gynecol* 119:1275, 2011
- Patel SH, Zakowski MI, Ramanathan S: Accidental local anesthetic overdose due to epidural pump malfunction. *Int J Obstet Anesth* 20:93, 2011
- Patteson SK, Snider CC, Meyer DS, et al: The consequences of high-risk behaviors: trauma during pregnancy. *J Trauma* 62:1015, 2007
- Pearlman MD, Tintinalli JE, Lorenz RP: A prospective controlled study of outcome after trauma during pregnancy. *Am J Obstet Gynecol* 162:1502, 1990
- Pearse CS, Magrina JF, Finley BE: Use of MAST suit in obstetrics and gynecology. *Obstet Gynecol Surv* 39:416, 1984
- Perik D, Timmermann G, Czeizel AE, et al: A study of the teratogenic and fetotoxic effects of large doses of amobarbital used for a suicide attempt by 14 pregnant women. *Toxicol Ind Health* 24:79, 2008
- Petrone P, Talving P, Browder T, et al: Abdominal injuries in pregnancy: a 155-month study at two level 1 trauma centers. *Injury* 42:47, 2011
- Puri A, Khadem P, Ahmed S, et al: Imaging of trauma in a pregnant patient. *Semin Ultrasound CT MR* 33:37, 2012
- Quinlivan JA, Evans SF: A prospective cohort study of the impact of domestic violence on young teenage pregnancy outcomes. *J Pediatr Adolesc Gynecol* 14:17, 2001
- Reis PM, Sander CM, Pearlman MD: Abruptio placentae after auto accidents. A case-control study. *J Reprod Med* 45:6, 2000
- Rhea JT, Garza DH, Novelline RA: Controversies in emergency radiology. CT versus ultrasound in the evaluation of blunt abdominal trauma. *Emerg Radiol* 10:289, 2004
- Rode H, Millar AJ, Cywes S, et al: Thermal injury in pregnancy—the neglected tragedy. *S Afr Med J* 77:346, 1990
- Rodrigues T, Rocha L, Barros H: Physical abuse during pregnancy and preterm delivery. *Am J Obstet Gynecol* 198:171 e1, 2008
- Rothenberger DA, Quattlebaum FW, Zabel J, et al: Diagnostic peritoneal lavage for blunt trauma in pregnant women. *Am J Obstet Gynecol* 129:479, 1977
- Samandari G, Martin SL, Kupper LL, et al: Are pregnant and postpartum women: at increased risk for violent death? Suicide and homicide findings from North Carolina. *Matern Child Health J* 15:660, 2011
- Saunders CJ, Bartistella FD, Whetzel TP, et al: Percutaneous diagnostic peritoneal lavage using a Veress needle versus an open technique: a prospective randomized trial. *J Trauma* 44:883, 1998
- Schiff MA: Pregnancy outcomes following hospitalisation for a fall in Washington State from 1987 to 2004. *BJOG* 115:1648, 2008
- Schiff MA, Grossman DC: Adverse perinatal outcomes and risk for postpartum suicide attempt in Washington state, 1987–2001. *Pediatrics* 118:e669, 2006
- Schiff MA, Holt VL: Pregnancy outcomes following hospitalization for motor vehicle crashes in Washington State from 1989 to 2001. *Am J Epidemiol* 161:503, 2005
- Schiff MA, Holt VL: The injury severity score in pregnant trauma patients: predicting placental abruption and fetal death. *J Trauma* 53:946, 2002a
- Schiff MA, Holt VL, Daling JR: Maternal and infant outcomes after injury during pregnancy in Washington State from 1989 to 1997. *J Trauma* 53:939, 2002b

- Shah KH, Simons RK, Holbrook T, et al: Trauma in pregnancy: maternal and fetal outcomes. *J Trauma* 45:83, 1998
- Silva EP, Ludermitz AB, de Araujo TV, et al: Frequency and pattern of intimate partner violence before, during and after pregnancy. *Rev Saude Publica* 45:1044, 2011
- Silverman JG, Decker MR, Reed E, et al: Intimate partner violence victimization prior to and during pregnancy among women residing in 26 U.S. states: associations with maternal and neonatal health. *Am J Obstet Gynecol* 195:140, 2006
- Sirin H, Weiss HB, Sauber-Schatz EK, et al: Seat belt use, counseling and motor-vehicle injury during pregnancy: results from a multi-state population-based survey. *Matern Child Health J* 11:505, 2007
- Sparic R, Malvasi A, Nejkovic L, et al: Electric shock in pregnancy: a review. *J Matern Fetal Neonatal Med* 29(2):317, 2016
- Stockl H, Hertlein L, Himsl I, et al: Intimate partner violence and its association with pregnancy loss and pregnancy planning. *Acta Obstet Gynecol Scand* 91:128, 2012
- Thomas R, Sotheran W: Postmortem and perimortem caesarean section. *J R Soc Med* 93:215, 2000
- Tikkanen M, Nuutila M, Hiilesmaa V, et al: Clinical presentation and risk factors of placental abruption. *Acta Obstet Gynecol Scand* 85:700, 2006
- Timmermann G, Czeizel AE, Banhidy F, et al: A study of the teratogenic and fetotoxic effects of large doses of barbital, hexobarbital and butobarbital used for suicide attempts by pregnant women. *Toxicol Ind Health* 24:109, 2008
- Tinker SC, Reefhuis J, Dellinger AM, et al: Epidemiology of maternal injuries during pregnancy in a population-based study, 1997–2005. *J Womens Health* 19:2211, 2010
- Towery R, English TP, Wisner D: Evaluation of pregnant women after blunt injury. *J Trauma* 35:731, 1993
- Trivedi N, Yagan M, Moore TR, et al: Predicting adverse outcomes following trauma in pregnancy. *J Reprod Med* 57:3, 2012
- Tsuei BJ: Assessment of the pregnant trauma patient. *Injury* 37:367, 2006
- Umeora OU, Dimejesi BI, Ejikeme BN, et al: Pattern and determinants of domestic violence among prenatal clinic attendees in a referral centre, South-east Nigeria. *J Obstet Gynaecol* 28:769, 2008
- Urquia ML, O'Campo PJ, Heaman MI, et al: Experiences of violence before and during pregnancy and adverse pregnancy outcomes: an analysis of the Canadian Maternity Experiences Survey. *BMC Pregnancy Childbirth* 11:42, 2011
- Vivian-Taylor J, Roberts CL, Chen JS, et al: Motor vehicle accidents during pregnancy: a population-based study. *BJOG* 119:499, 2012
- Vladutiu CJ, Evenson KR, Marshall SW: Physical activity and injuries during pregnancy. *J Phys Act Health* 7:761, 2010
- Weiss HB, Lawrence B, Miller T: Prevalence and risk of hospitalized pregnant occupants in car crashes. *Annu Proc Assoc Adv Automot Med* 46:355, 2002
- Weiss HB, Sauber-Schatz EK, Cook LJ: The epidemiology of pregnancy-associated emergency department injury visits and their impact on birth outcomes. *Accid Anal Prev* 40:1088, 2008
- Whitehead NS: Prenatal counseling on seat belt use and crash-related medical care. *Matern Child Health J* 17(9):1527, 2013
- Wolf ME, Alexander BH, Rivara FP, et al: A retrospective cohort study of seatbelt use and pregnancy outcome after a motor vehicle crash. *J Trauma* 34:116, 1993
- Woolhouse H, Gartland D, Hegarty K, et al: Depressive symptoms and intimate partner violence in the 12 months after childbirth: a prospective pregnancy cohort study. *BJOG* 119:315, 2012
- Yang MS, Ho SY, Chou FH, et al: Physical abuse during pregnancy and risk of low-birthweight infants among aborigines in Taiwan. *Public Health* 120:557, 2006
- Yoong AF: Electrical shock sustained in pregnancy followed by placental abruption. *Postgrad Med J* 66:563, 1990
- Yost NP, Bloom SL, McIntire DD, et al: A prospective observational study of domestic violence during pregnancy. *Obstet Gynecol* 106:61, 2005

CHAPTER 18

Perioperative Considerations

PREOPERATIVE ASSESMENT	291
PREOPERATIVE PREPARATION	294
INTRAOPERATIVE CARE	302
POSTOPERATIVE CARE	303
PERIOPERATIVE MANAGEMENT OF DIABETES	304

It is not uncommon for pregnant women to undergo invasive diagnostic or therapeutic procedures, including surgical operations. In these cases, gravidas present a dual challenge. Namely, the risks and benefits of a proposed procedure for the mother are balanced against the potential fetal risks and benefits associated with the proposed operation.

PREOPERATIVE ASSESSMENT

This evaluation begins with a detailed maternal history and clinical examination, indicated laboratory testing, and appraisal of fetal status. Preoperative assessment ideally identifies obstetric and medical risks that may be associated with perioperative maternal or fetal morbidity and mortality. Recognition of risks and benefits allows providers to adequately counsel a gravida and permits shared decision making and informed consent. This often requires a collaborative effort with input from anesthesiologists, obstetricians, pediatricians, neonatologists, and associated surgeons. Even so, despite improved obstetric, surgical, and medical care, all operative procedures carry risk.

■ Maternal Assessment

To begin, an inventory of medical comorbidities is assembled. Some may be of greater importance for the surgical patient.

Cardiopulmonary status, which undergoes profound physiologic changes during pregnancy, may be particularly vulnerable during surgery and should be an area of increased focus. A summary of these normal changes in the gravida is found in Chapter 19 (p. 307). Of other clinical points, baseline anemia may increase needs for transfusion. Diabetes mellitus and smoking can elevate wound infection complication risks. Women with prior venous thromboembolism have greater chances for recurrence, especially with long pelvic or orthopedic surgeries. Surgery poses added physical strain, and gravidas taking large doses of corticosteroids may benefit from perioperative stress dosing. Last, a patient's religious beliefs, such as with Jehovah's Witnesses, may limit blood transfusion options.

During physical examination, basic components are completed. Again, cardiopulmonary status is a primary focus. The airway is assessed as described on page 293, and spine inspection should investigate for scoliosis. Aberrations in these areas may merit special anesthesia consultation. Patient body habitus also alters surgical risks. For example, obese patients have diminished pulmonary reserve, and their pannus can influence incision selection. Underweight patients may be at greater risk for nerve injury if not correctly positioned when anesthetized in dorsal lithotomy position for an extended time. Digital cervical assessment to determine dilatation or effacement may be helpful prior to some surgeries that pose a risk for associated preterm labor. Examples include cervical cerclage or fetal surgery, discussed in Chapters 11 and 16, respectively.

■ Laboratory Assessment

For most healthy pregnant women, laboratory testing prior to surgery can be minimal. A complete blood count; chemistry panel that evaluates electrolytes, renal function, and glucose levels; and type and screen are common for procedures with associated blood loss risks. For cases with greater anticipated bleeding, such as with placenta previa or the accrete syndrome, a type and crossmatch is prudent. In women without

prior prenatal care, blood typing to clarify Rh status is also completed.

■ Surgical Route Selection

Unlike gynecology, in which similar procedures may be completed vaginally or abdominally, procedures in obstetrics typically fall clearly into one approach or the other. For those that require abdominal entry, many nonobstetric procedures can be completed by a minimally invasive surgical (MIS) route. Examples include adnexal surgery, appendectomy, and cholecystectomy. This is also true for many fetal surgery procedures. Thus, an initial preoperative decision is the route of surgery.

When feasible, MIS offers the advantages of faster patient recovery, shorter hospital stays, lower postoperative ileus rates, less postoperative pain, and fewer wound complications (Nieboer, 2009; Pearl, 2011). However, not all cases are suitable. First, for a given procedure, MIS may not provide sufficient access to the uterus. Cesarean delivery is an obvious example. Other limits can include known dense adhesive disease, surgeon skill, or facility barriers. Also, large bulky pathology may be difficult to remove or may encroach on needed operating space. As described in Chapter 15 (p. 240), laparoscopy creates unique physiologic changes, which may be incompatible with some maternal cardiopulmonary comorbidities. Also, MIS can require longer operating times, which can expose the mother or fetus to undesirable effects of anesthesia or pneumoperitoneum. Thus, for many cases in pregnancy, laparotomy is required.

■ Laparotomy Incision Selection

In cases warranting laparotomy, a surgeon must select either a low transverse or midline vertical abdominal wall incision for entry. A thorough discussion of these incisions and their characteristics is found in Chapter 4 (p. 49). Briefly, low transverse incisions are often preferred as they produce good cosmetic results and are also less painful. Additionally, these incisions are placed in the lower abdomen and interfere less with postoperative respiratory movement, thereby aiding easier recovery. Transverse incisions, however, do have disadvantages compared with midline vertical ones. Drawbacks are that: (1) the intraabdominal operative space is smaller; (2) the ability to extend the incision is limited; (3) the division of multiple layers of fascia and muscle creates dead spaces for blood or pus to accumulate; (4) surgical bleeding is comparatively greater; and (5) the time required to enter the abdomen is typically longer.

■ Anesthesia Selection

Many obstetric procedures can be completed under local paracervical or pudendal blockade; under neuraxial anesthesia that includes spinal, epidural, or combined spinal-epidural anesthesia; or under general anesthesia. A more detailed discussion of their indications and illustrations are found in Chapters 9 and 19 (p. 136 and 309).

Briefly, local blocks are suitable for small localized surgeries such as perineal laceration repair. When coupled with intravenous (IV) sedation, these can also be selected for dilatation and

curettage. Regional anesthesia is preferred for labor, for operative vaginal delivery, or for cesarean delivery. General anesthesia is often needed for emergency surgery, for laparoscopy, for surgery extending into the upper abdomen, or for cases requiring greater intraabdominal organ manipulation.

■ Fetal Assessment

Of fetal parameters, gestational age, fetal presentation, and placental location are important elements to consider. Of these, gestational age profoundly affects surgical decision making. Examples are numerous and found throughout this text. First, indicated but nonurgent surgeries are often delayed until the second trimester. Abortion techniques and risk vary considerably between the first and second trimester. Preivable gestations are typically excluded from cesarean delivery for fetal indications. In contrast, cervical cerclage is rarely offered after 24 weeks' gestation. Thus, gestational age should be assessed using both last menstrual period and sonographic fetal measurements.

A second parameter, fetal presentation, is most important prior to external version attempts, twin delivery, vaginal breech delivery, and cesarean delivery. This is most often determined sonographically.

A third parameter, placental location, is valuable information prior to cesarean delivery. With an anterior placenta, low transverse hysterotomy may concurrently incise the placenta. This in turn can abruptly lower perfusion to the fetus. Thus, in such cases, expedient fetal delivery is planned. Placenta location can also influence many fetal therapy procedures that often insert needles or trocars through the anterior uterine wall.

If delivery is not planned but significant uterine manipulation may be expected, preoperative sonography is also necessary to determine fetal position, placental location, and planning for the appropriate uterine incision should an unexpected delivery be required.

■ Preoperative Consultation

Depending on the scheduled surgical procedure, additional preoperative considerations may include multidisciplinary consultation from medical and surgical specialists to be involved in the surgery. Examples include staff from anesthesiology, urology, gynecologic oncology, general surgery, blood banking, and intensive care units for the mother or neonate.

Preoperative anesthesia consultation should include a review of the history, clinical examination, and preoperative laboratory testing. The woman's history provides information to assess the physical state prior to selecting an anesthetic and prior to performing a surgery. The American Society of Anesthesiologists (ASA) introduced a simple grading system to describe the patient's general health. Notably, the ASA Physical Status Classification System is not intended to be used to predict operative risk. Table 18-1 summarizes the current classification as approved the ASA House of Delegates.

Clinical examination prior to initiation of anesthesia allows evaluation of the airway status with the intent to detect physical characteristics that may predict a difficult airway. Components of the preoperative airway physical examination are listed

TABLE 18-1. American Society of Anesthesiologists (ASA) Physical Status Classification System

Classification	Patient Status	Examples
ASA I	Normal, healthy	Healthy, nonsmoking, no or minimal alcohol use
ASA II	Mild systemic disease without substantive functional limitations	Current smoker, social alcohol drinker, pregnancy, obesity (BMI 30–40), well-controlled DM/HTN, mild lung disease
ASA III	Severe systemic disease with substantive functional limitations	Poorly controlled DM or HTN, morbid obesity (BMI ≥40), COPD, active hepatitis, alcohol dependence or abuse, implanted pacemaker, moderately reduced EF, ESRD undergoing dialysis, prior (>3 months ago) MI, CVA, TIA, or CAD/stents
ASA IV	Severe systemic disease that is a constant threat to life	Recent (<3 months ago) MI, CVA, TIA, or CAD/stents, ongoing cardiac ischemia or severe valve dysfunction, severely reduced EF, sepsis, DIC, AKI or ESRD not undergoing regularly scheduled dialysis
ASA V	Moribund patient who is not expected to survive without the operation	Ruptured abdominal/thoracic aneurysm, massive trauma, intracranial bleed with mass effect, ischemic bowel in the face of significant cardiac pathology or multiple organ/system dysfunction
ASA VI	Brain-dead; organs are harvested for donor	

The addition of “E” denotes emergency surgery for a condition that would lead to a significant increase in the threat to life or body part if treatment is delayed.

AKI = acute kidney injury; BMI = body mass index; CAD = coronary artery disease; CVA = cerebrovascular disease; COPD = chronic obstructive pulmonary disease; DIC = disseminated intravascular coagulopathy; DM = diabetes mellitus; EF = ejection fraction; ESRD = end-stage renal disease; HTN = hypertension; MI = myocardial infarction; TIA = transient ischemic attack.

Adapted from American Society of Anesthesiologists, 2014.

in **Table 18-2** with the Mallampati evaluation. **Figure 18-1** depicts this classification.

As discussed in Chapter 27 (p. 446), women undergoing cesarean delivery with suspected morbidly adherent placenta should be managed by an experienced multidisciplinary team in a tertiary care center. Care here ensures the capability to provide large amounts of blood products and implement appropriate intensive intra- and postoperative care when indicated (Silver, 2015). Additional preoperative consultations might include

blood bank notification of possible need for massive transfusions. Also, a urologist or gynecologic oncologist may be enlisted to perform intraoperative cystoscopy, to thread ureteral stents, or rarely to resect a portion of the bladder invaded by a percreta. Preoperatively, an interventional radiologist may be consulted to insert balloon catheters into the internal iliac arteries. These can be inflated intraoperatively to stem massive pelvic bleeding.

In such multidisciplinary cases, a preoperative checklist is suggested to confirm that all notifications are complete. This should

TABLE 18-2. Preoperative Airway Physical Examination

Airway Examination	Nonreassuring Findings
Upper incisor length	Relatively long
Maxillary and mandibular incisors during normal jaw closure	Prominent “overbite”—maxillary incisors anterior to mandibular incisors
Maxillary and mandibular incisors during mandible protrusion	Unable to bring mandibular incisors in front of maxillary incisors
Interincisor distance or gap	Decreased: <3 cm
Uvula visibility	Not visible when tongue is protruded with patient sitting (Mallampati class III & IV)
Palate shape	Highly arched or very narrow
Mandibular space compliance	Stiff, indurated, or occupied by mass
Thyromental distance	Decreased: <3 ordinary finger breadths
Neck length	Short
Neck thickness	Thick
Head and neck range of motion	Decreased: unable to touch tip of chin to chest or cannot extend neck

Modified from American Society of Anesthesiologists, 2013.

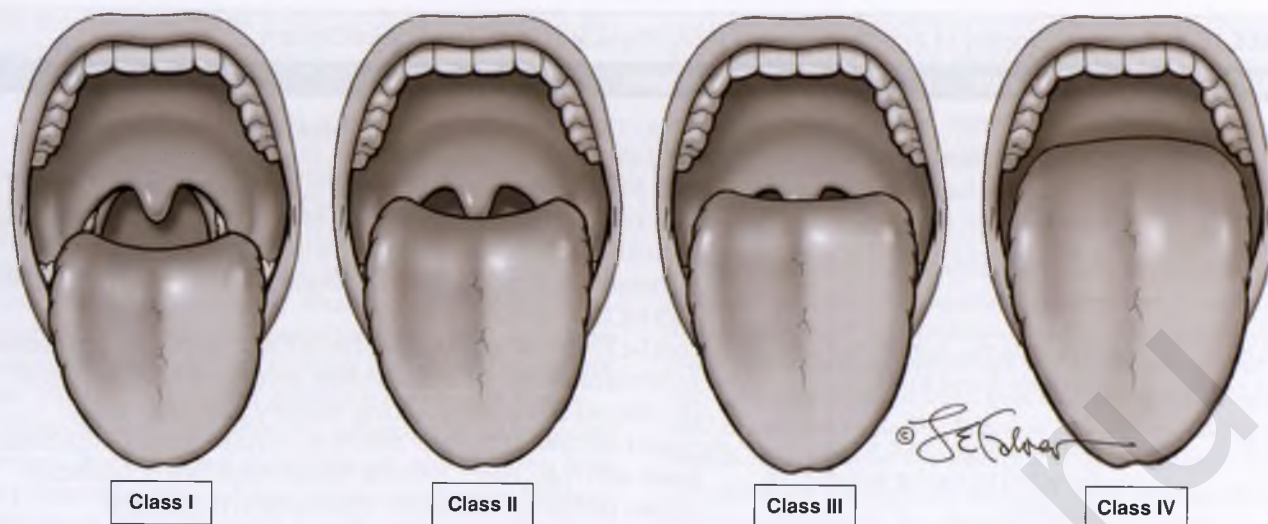


FIGURE 18-1 Modified Mallampati Airway Classification. (Adapted with permission from Mallampati SR, Gatt SP, Gugino LD, et al: A clinical sign to predict difficult tracheal intubation: a prospective study, *Can Anaesth Soc J* 1985 Jul;32(4):429–434.)

also provide readily available names with contact information of potential consultants (American College of Obstetricians and Gynecologists, 2016b; Society for Maternal-Fetal Medicine, 2010).

■ Timing of Nonobstetric Procedures

Considerations for the timing of nonobstetric surgery during pregnancy depend on gestational age and the indication for the surgery. Urgently indicated operations—for example, acute appendicitis—should be performed without regard to gestational age. If the procedure is judged to be indicated during pregnancy but nonurgent, most recommend performing the procedure during the second trimester. This timing minimizes possible teratogen exposure during early embryofetal development. Also, the greatest potential for spontaneous miscarriage has passed. Elective surgery is delayed until the postpartum period (American College of Obstetricians and Gynecologists, 2015b).

PREOPERATIVE PREPARATION

■ Informed Consent

This is a process of communication in which the woman is presented with a comprehensible discussion regarding the diagnosis, recommended treatment, risks and benefits of the proposed procedure, alternative options, and the risks of not proceeding with the recommended treatment. The language of the consent should be understandable, and the patient should be encouraged to ask questions. For non-English-speaking patients, translation should be performed using skilled medical interpreters. Importantly, formal informed consent translation should not be provided by family members. Obtaining consent may also involve agreement to participate in medical research or to accept possible involvement in teaching exercises when appropriate. Many consent forms include routine patient approval for medical photography.

Despite a clinician's recommendations, an informed patient may decline a particular intervention. A woman's decision-making autonomy must be respected, and a clinician documents informed refusal in the medical record. Appropriate documentation includes: (1) a patient's refusal to consent to the

recommended intervention, (2) notation that the value of the intervention has been explained to the patient, (3) a patient's reasons for refusal, and (4) a statement describing the health consequences as described to the patient.

■ Surgical Site Infection Prevention

Surgical site infections (SSIs) are among the most frequent complications associated with operations. Infections can lead to significantly increased hospital length of stay, morbidity, and mortality. Among the various strategies reported to prevent SSI, antibiotic prophylaxis has been shown to reduce postoperative infectious morbidity by 60 to 70 percent (Smaill, 2014; Witt, 2011).

Clinical criteria used to justify perioperative antibiotic prophylaxis include: (1) surgical procedure involving a contaminated operative field, (2) operations with a high incidence of postoperative infection, and (3) complications associated with SSIs that are potentially severe, for example, pelvic or abdominal abscess (Duff, 1987). These criteria are reflected in the accepted surgical wound classification, which categorizes wounds according to the degree of contamination and likelihood of subsequent infection (Table 18-3).

In this system, a *clean wound* is defined as an uninfected wound without inflammation in which the respiratory, alimentary, genital, or uninfected urinary tracts are not entered. Adnexectomy or puerperal sterilization would fall into this category.

A *clean-contaminated wound* is an operative wound in which the respiratory, alimentary, genital, or urinary tracts are entered under controlled conditions without unusual contamination. Clean-contaminated wounds assume no evidence of infection or break in technique (Mangram, 1999). Antibiotic prophylaxis is indicated for certain obstetric clean-contaminated procedures such as cesarean delivery and may be indicated for contaminated wounds such as vaginal delivery complicated by severe perineal lacerations. Antibiotic prophylaxis would not otherwise be indicated for most vaginal deliveries.

Contaminated wounds reflect operations with major breaks in sterile technique or gross gastrointestinal spillage or incisions in which acute, nonpurulent inflammation is encountered (Mangram, 1999). Subsequent infection rates are significant.

TABLE 18-3. Surgical Wound Classification

Class/Term	Definition
Class I/Clean	Uninfected operative wound without inflammation and the respiratory, alimentary, genital, or uninfected urinary tracts are not entered. Primary closure of the wound. If indicated, drained with closed drainage.
Class II/Clean-Contaminated	Operative wound in which the respiratory, alimentary, genital, or urinary tracts are entered under controlled conditions without unusual contamination. Operations involving the biliary tract, appendix, vagina, and oropharynx are included, provided there is no evidence of infection or major break in sterile technique.
Class III/Contaminated	Open, fresh, accidental wounds and operations with a major break in sterile technique or gross spillage from the gastrointestinal tract. Includes incisions with acute, nonpurulent inflammation.
Class IV/Dirty-Infected	Wounds with existing clinical infection or perforated viscera and old traumatic wounds with retained devitalized tissue. This definition implies that the organisms causing postoperative infection were present in the operative field prior to the operation.

Modified from Mangram, 1999.

For this reason, a minimum of 24 hours of perioperative antibiotic administration is suggested.

An *infected* or *dirty* wound implies that bacteria are already present when the surgical incision is made. A common example is the wound involving a cesarean delivery complicated by chorioamnionitis. In this case, prophylactic antibiotics are not given, but instead therapy is continued with antibiotic agents begun for chorioamnionitis.

Of note, patients undergoing certain clean surgical procedures may benefit from antibiotic prophylaxis in situations in which the consequences of infection may be severe. Examples might include incisions involving prosthetic implants or immunocompromised patients (Bratzler, 2013).

Principles of Antibiotic Prophylaxis

Considerations for antibiotic prophylaxis have been developed by a collaborative effort involving the American Society of Health-System Pharmacists (ASHP), the Infectious Disease Society of America (ISA), the Surgical Infection Society (SIS), and the Society for Healthcare Epidemiology of America (SHEA) (Bratzler, 2013).

Antibiotic Agent Selection. The choice of antibiotic prophylaxis is based on patient- and procedure-specific considerations, known institutional-specific factors, the safety profile of the medication, and fetal risks from exposure to the antibiotic agent. The selected antibiotic should possess the narrowest spectrum of activity with proven efficacy to prevent infection. Thus, because of its spectrum of activity against most commonly encountered organisms resulting in SSIs, proven efficacy as an agent of prophylaxis, low cost, and safety profile, a first-generation cephalosporin is the preferred agent for most obstetric operative procedures such as cesarean delivery (Duff, 1987). This is administered intravenously. For prophylaxis following dilatation and curettage, however, oral doxycycline or metronidazole is recommended (p. 302).

Patients with a history of penicillin allergy but without a type 1 or immunoglobulin E (IgE) mediated reaction may

safely receive a cephalosporin or carbapenem. Type 1 reactions include anaphylaxis, urticaria, bronchospasm, or exfoliative dermatitis. Those patients with a history of type 1 (IgE-mediated) allergic reaction from penicillin, cephalosporin, or carbapenem should instead receive a β -lactam antibiotic alternative. For cesarean delivery, the alternative is clindamycin in combination with an aminoglycoside.

Patients with known methicillin-resistant *Staphylococcus aureus* (MRSA) colonization should receive a single dose of vancomycin in addition to the standard antibiotic prophylaxis. Importantly, vancomycin MRSA prophylaxis does not replace standard antibiotic surgical prophylaxis (Bratzler, 2013).

Administration of antibiotic prophylaxis should be within 60 minutes prior to surgical incision. Agents requiring a longer period of administration, such as vancomycin and fluoroquinolones, should begin 120 minutes prior to surgical incision.

Dosing Antibiotic Prophylaxis. Antibiotic prophylaxis requires that adequate serum and tissue levels be delivered prior to the operative incision and that concentrations persist throughout the entire operation. Dosing considerations include body weight, surgery duration, intraoperative blood loss, and renal function.

Obese women present several problems for antibiotic prophylaxis. The prevalence of obesity in the United States has remained stable through 2012. Specifically, 35 percent of adults have a body mass index (BMI) ≥ 30 , and 6.4 percent have a BMI ≥ 40 (Ogden, 2012). Antibiotic dose adjustments based on body weight are considered due to an increased volume of distribution. Also, drug-clearance pharmacokinetics are altered, which can raise SSI risks. However, only limited data are available to define the optimal method of weight-based dosing in these women. For example, the use of actual body weight may result in excessive serum and tissue concentrations when dosing with a hydrophilic medication such as an aminoglycoside. Conversely, the use of ideal body weight may result in subtherapeutic concentrations of a lipophilic medication such as vancomycin (Bratzler, 2013).

TABLE 18-4. Recommended Doses and Redosing Intervals of Antibiotics Commonly Used in Surgical Prophylaxis

Antibiotic	Adult Dose	Half-life (hr) ^a	Redosing Interval (hr) ^b
Ampicillin-sulbactam	3 g	0.8–1.3	2
Aztreonam	2 g	1.3–2.4	4
Cefazolin	1 g; 2 g if >80 kg; 3 g if >120 kg	1.2–2.2	4
Cefuroxime	1.5 g	1–2	4
Cefotaxime	1 g	0.9–1.7	3
Cefoxitin	2 g	0.7–1.1	2
Cefotetan	2 g	2.8–4.6	6
Ceftriaxone	2 g	5.4–10.9	NA
Ciprofloxacin	400 mg	3–7	NA
Clindamycin	900 mg	2–4	6
Ertapenem	1 g	3–5	NA
Gentamicin	5 mg/kg ^c	2–3	NA
Levofloxacin	500 mg	6–8	NA
Metronidazole	500 mg	6–8	NA
Piperacillin-Tazobactam	3.375 g	0.7–1.2	2
Vancomycin	15 mg/kg	4–8	NA

^aFor patients with normal renal function.

^bFollowing initial preoperative dose.

^cGentamicin dose based on actual body weight (ABW).

If ABW is >20% above ideal body weight (IBW), then dosing weight (DW) = IBW + 0.4(ABW – IBW).

Adapted from Bratzler, 2013.

Proven recommendations for weight-based dosing of antibiotic agents in the obese patient that result in decreased SSI rates are not available (Pai, 2007; Wurtz, 1999). That said, recent guidelines suggest increasing the standard 1-g dose of cefazolin to 2 g for women weighing more than 80 kg and using a 3-g dose for patients weighing more than 120 kg (Bratzler, 2013).

When gentamicin is selected in combination with an additional antibiotic for prophylaxis, the recommended dose is 4.5 to 5 mg/kg given as a single dose. However, the decision on which weight-based formula to use remains uncertain. For obese patients weighing more than 20 percent above their ideal body weight (IBW), the ASHP and others recommend that the single dose of gentamicin given preoperatively should be calculated using a dosing weight (DW) (Bauer, 1983; Bratzler, 2013). This DW is their ideal body weight plus 40 percent of the difference between their actual (ABW) and ideal body weight (IBW).

$$DW = IBW + 0.4[ABW - IBW]$$

In the obese patient, others recommend using gentamicin 5 to 7 mg/kg of IBW with a maximum dosage of 480 to 640 mg (Janson, 2012).

In some situations, an additional antibiotic dose may be required to ensure adequate serum and tissue concentrations throughout the procedure. Examples include procedure lengths that exceed two half-lives of the antibiotic agent or procedures associated with excessive blood loss. In patients with known renal insufficiency or renal failure that prolongs the antibiotic half-life, additional doses may not be indicated. The recommended doses and redosing intervals for commonly used antibiotics for surgical prophylaxis are included in [Table 18-4](#).

For standard use, most investigators have observed that the use of a single dose of antibiotic prophylaxis is as efficacious as multiple-dose prophylaxis (American College of Obstetricians and Gynecologists, 2016a; Faro, 1990; Gonik, 1985). If multiple dosing is warranted clinically, coverage should not exceed 24 hours.

TABLE 18-5. Risk Factors and Recommendations to Prevent Surgical Site Infections (SSIs)

Risk Factor	Recommendation
Obesity	Increase dose of prophylactic antibiotic agent
Tobacco	Encourage smoking cessation within 30 days of procedure
Glucose control	Control blood glucose for all surgical patients, including patients without diabetes. For patients with diabetes mellitus, reduce hemoglobin A _{1c} to level <7%
Hair removal	Do not remove hair unless it interferes with the operation. If removal is needed, remove outside the OR by clipping. Do not use razors
Preoperative infections	Identify and treat infections near the surgical site prior to elective surgery
Surgical scrub	Scrub hands and forearms for 2–5 minutes
Skin preparation	Use a dual-agent skin preparation containing alcohol
Antibiotic prophylaxis	Administer when indicated within 1 hour prior to incision. Vancomycin and fluoroquinolones begin 120 minutes prior to incision
Prophylactic agent choice	Select appropriate agent based on surgical procedure, the most common pathogens causing SSIs for a specific procedure, and published recommendations
Prophylaxis duration	Single dose; if continued therapy is indicated, stop antibiotic agent within 24 hours after the procedure
Surgical technique	Careful tissue handling, obtain hemostasis, eradicate dead space
Surgeon gloving	All members should double glove and change gloves when glove perforation is noticed
OR traffic	Minimize
Thermoregulation	Maintain OR temperature >35.5°C

OR = operating room.

Adapted from Anderson, 2014; Reichman, 2009.

Additional Measures

Although antibiotic prophylaxis reduces SSI rates, additional interventions play an essential role in prevention. Among these, adherence to proper surgical technique that obtains meticulous hemostasis, minimizes devitalized tissue, and avoids dead space creation is emphasized. Another step is to avoid hair removal at the incision site unless it interferes with the operation. If necessary, hair is removed by clippers rather than razor. Patient hypothermia is also avoided, and the operating room temperature should be 35.5°C or greater. Surgeons should complete preoperative hand and forearm antisepsis. The surgical site is cleaned using an alcohol-based antiseptic preparation in combination with iodine or chlorhexidine. Additionally, operating room traffic is ideally limited. Patient-related risks include poor nutritional status, diabetes mellitus, obesity, and tobacco use. **Table 18-5** lists risk factors and recommendations to minimize or prevent SSIs.

■ Thromboembolism Prophylaxis

Thromboembolism Incidence and Risks

Physiologic and anatomic changes associated with normal pregnancy result in an increased likelihood of deep-vein thrombosis and embolism. Specifically, elevated levels of coagulation factors create a hypercoagulable state, venous stasis rises from inferior vena caval compression, and mobility declines. As a result, pregnancy is associated with a four- to fivefold increased risk of thromboembolism. The prevalence is 0.5 to 2.0 events per 1000 pregnancies. Deep-vein thrombosis (DVT) accounts for 75 to 80 percent of pregnancy-associated venous thromboembolism cases. Pulmonary embolism accounts for 20 to 25 percent. DVT during pregnancy affects the left leg more often

and is more likely to be proximal due to the compression of the left common iliac vein by the enlarging uterus (Chan, 2010).

Half of all pregnancy-associated thromboembolism develops antepartum, and the risk rises during the third trimester. The greatest risk of DVT and pulmonary embolism is during the puerperium (American College of Obstetricians and Gynecologists, 2014b; Heit, 2005; Pomp, 2008). A recent large population-based cohort study from the United Kingdom reported that the third-trimester risk of thromboembolism was six times higher than for nonpregnant women. This risk rose 22-fold during the first 6 weeks postpartum (Sultan, 2012).

Of sequelae from thromboembolism, data of the Pregnancy Mortality Surveillance System from 2006 to 2010 showed pregnancy-associated thromboembolism to be a persistent leading cause of maternal mortality. Thromboembolism accounted for 9.3 percent of pregnancy-related deaths, and it was identified as one of the three most common preventable causes of death and severe morbidity (American College of Obstetricians and Gynecologists, 2014b; Berg, 2010; Creanga, 2015; D’Alton, 2014).

Thromboembolism Prevention

Prevention of pregnancy-related thromboembolism requires a thorough risk assessment of maternal, obstetric, and surgical factors. Of the various risks as listed in **Table 18-6**, previous thromboembolism, presence of thrombophilia factor, obesity, and cesarean delivery are among the most important (Bates, 2012; Guimicheva, 2013). Currently, the American College of Obstetricians and Gynecologists (2014b) recommends that the woman without additional risk factors undergoing cesarean delivery should have pneumatic compression devices placed prior to delivery. This is followed by early postoperative

TABLE 18-6. Major and Minor Risk Factors for Postpartum Venous Thromboembolism (VTE)

Major Factors (1 poses a postpartum VTE risk >3%)	Minor Factors (2 items or 1 item + emergency cesarean delivery pose a postpartum VTE risk >3%)
Immobility (strict antepartum bed rest ≥ 1 wk)	Body mass index >30 kg/m ²
Postpartum hemorrhage ≥ 1 L with surgery	Postpartum hemorrhage >1 L
Prior venous thromboembolism	Smoking >10 cigarettes/day
Thrombophilia:	Thrombophilia:
Antithrombin deficiency	Protein C deficiency
Factor V Leiden (homo- or heterozygous)	Protein S deficiency
Prothrombin G20210A (homo- or heterozygous)	Pregnancy complications:
Medical conditions:	Preeclampsia
Systemic lupus erythematosus	Fetal growth restriction
Sickle-cell disease	Multifetal pregnancy
Heart disease	
Blood transfusion	
Postpartum infection	

If no risk factors, recommend early mobilization.

If one major or two minor risk factors, recommend prophylactic low-molecular-weight heparin or mechanical prophylaxis in those with contraindications to anticoagulants while in the hospital.

If a higher risk, recommend low-molecular weight heparin plus mechanical prophylaxis.

If significant risk factors persist following delivery, prophylaxis should be extended for up to 6 weeks postpartum.

Adapted from Bates, 2012; Cunningham, 2014b.

ambulation. For those patients with additional risk factors, a pneumatic compression device in combination with unfractionated or low-molecular-weight heparin is suggested. Current thromboprophylaxis guidelines during pregnancy and the postpartum period as recommended by the American College of Obstetricians and Gynecologists and the American College of Chest Physicians are shown in [Table 18-7](#). Suitable agents are listed in [Table 18-8](#).

Anticoagulation Therapy at Time of Delivery. Women requiring antepartum low-molecular-weight heparin (LMWH) during pregnancy should be converted to unfractionated heparin (UFH) in the last 4 to 6 weeks prior to delivery. This minimizes the risk associated with regional anesthesia at the time of labor and delivery and allows a gravida to take advantage of this anesthesia option.

Guidelines from the American Society of Regional Anesthesia and Pain Medicine recommend delaying regional anesthesia for 10 to 12 hours following the last dose of prophylactic of LMWH and 24 hours following the most recent dose of therapeutic LMWH (Horlocker, 2010). These guidelines note that, for patients receiving prophylaxis with subcutaneous UFH in regimens of 5000 units twice daily, there is no contraindication to regional anesthesia. The safety of patients receiving 10,000 units twice daily or more is unknown and is individualized. If a woman begins labor while taking higher-dose UFH, clearance can be verified by an active partial thromboplastin time (aPTT). Reversal of heparin with protamine sulfate is rarely required. For women in whom anticoagulation therapy has temporarily been discontinued, pneumatic compression devices are recommended (American College of Obstetricians and Gynecologists, 2014b).

Postpartum Thromboprophylaxis. Because the puerperium is the time of greatest risk for development of pregnancy-associated thromboembolism, early ambulation following vaginal delivery is recommended for thromboprophylaxis in women without additional risk factors. For the patient undergoing cesarean delivery without additional risk factors, most recommend placement of pneumatic compression devices until she is ambulatory.

When indicated, postoperative UFH or LMWH should not be given sooner than 4 to 6 hours following vaginal delivery or 6 to 12 hours after cesarean delivery. LMWH should not be given for at least 2 hours following removal of the epidural catheter (Horlocker, 2010). Postpartum prophylactic anticoagulation should be continued with either UFH or LMWH for 4 to 6 weeks depending on risk factors. If the woman requires more than 6 weeks of anticoagulation postpartum, she may be bridged to warfarin. The heparin compounds and warfarin are known to be compatible with breastfeeding (American College of Obstetricians and Gynecologists, 2014b).

■ Specific Perioperative Antibiotic Prophylaxis Recommendations

Infective Endocarditis

Antibiotic prophylaxis to prevent infective endocarditis is indicated only for a subset of patients at the greatest risk for developing these serious infections. The American Heart Association (2007, 2014) guidelines state that absent a known enterococcal infection, no evidence supports infective endocarditis prophylaxis. They recommend against the routine use of antibiotic prophylaxis to prevent endocarditis for patients undergoing

TABLE 18-7. Recommendations for Thromboprophylaxis During Pregnancy and Postpartum

Clinical Scenario	Pregnancy		Postpartum	
	American College of Obstetricians and Gynecologists ^a	American College of Chest Physicians ^b	American College of Obstetricians and Gynecologists ^a	American College of Chest Physicians ^b
No Prior VTE				
Following cesarean delivery-based on risk factors	If no additional risk factors, PCD for all women If additional risk factors, PCD and LMWH	See Table 18-6 No recommendations	If no additional risk factors PCD for all women If additional risk factors PCD and prophylactic LMWH × 6 weeks	See Table 18-6 No recommendations
High-risk thrombophilia ^d	Surveillance only or Prophylactic- or intermediate-dose LMWH or UFH	Prophylactic- or intermediate-dose LMWH	Postpartum anticoagulation ^f	Intermediate-dose LMWH or warfarin target INR 2.0–3.0 × 6 weeks
Positive family history VTE and homozygous factor V Leiden or prothrombin 20210A mutation	NSS	Prophylactic- or intermediate-dose LMWH	NSS	Prophylactic- or intermediate-dose LMWH or warfarin target INR 2.0–3.0 × 6 weeks
Negative family history VTE and homozygous factor V Leiden or prothrombin 20210A mutation	Surveillance only or Prophylactic LMWH or UFH	Surveillance only	Postpartum anticoagulation ^f	Prophylactic- or intermediate-dose LMWH or warfarin target INR 2.0–3.0 × 6 weeks
Positive family history VTE and all other thrombophilias ^e	Surveillance only	Surveillance only	Postpartum anticoagulation ^f or Intermediate-dose LMWH or UFH	Prophylactic or intermediate-dose LMWH or in women <u>not</u> protein C or S deficient, warfarin target INR 2.0–3.0
Low-risk thrombophilia ^e	Surveillance only	Surveillance only if no family history	Surveillance only; postpartum anticoagulation with additional risk factors ^f	Surveillance only if no family history
Prior Single VTE				
Risk factor no longer present	Surveillance only	Surveillance only	Postpartum anticoagulation ^f “Surveillance only by some experts”	Prophylactic or intermediate-dose LMWH or warfarin target INR 2.0–3.0 × 6 weeks
Pregnancy- or estrogen-related or no known association (idiopathic) and not receiving long-term therapy	Prophylactic UFH or LMWH or “Surveillance only by some experts”	Prophylactic or intermediate-dose LMWH	Postpartum anticoagulation ^f	Prophylactic or intermediate-dose LMWH or warfarin target INR 2.0–3.0 × 6 weeks
Receiving long-term warfarin	NSS	Adjusted-dose LMWH or 75% of a therapeutic dose of LMWH	NSS	Resume long-term anticoagulation

(continued)

TABLE 18-7. Recommendations for Thromboprophylaxis During Pregnancy and Postpartum (*Continued*)

Clinical Scenario	Pregnancy		Postpartum	
	American College of Obstetricians and Gynecologists ^a	American College of Chest Physicians ^b	American College of Obstetricians and Gynecologists ^a	American College of Chest Physicians ^b
Associated with a high-risk thrombophilia ^d and not receiving long-term anticoagulation or an affected 1st-degree relative	Prophylactic-, intermediate-, or adjusted-dose LMWH or UFH	NSS	Postpartum anticoagulation ^c or intermediate- or adjusted-dose LMWH or UFH × 6 weeks	Prophylactic or intermediate-dose LMWH or warfarin target INR 2.0–3.0 × 6 weeks
Associated with a low-risk thrombophilia ^e and not receiving treatment	Prophylactic- or intermediate-dose LMWH or UFH or Surveillance only	NSS	Postpartum anticoagulation ^c or intermediate-dose LMWH or UFH × 6 weeks	Prophylactic or intermediate-dose LMWH or warfarin target INR 2.0–3.0 × 6 weeks
Two or More Prior VTEs with or without Thrombophilia				
Not receiving long-term therapy	Prophylactic- or therapeutic-dose UFH or LMWH	NSS	Postpartum anticoagulation ^c or Therapeutic-dose LMWH or UFH × 6 weeks	Prophylactic or intermediate-dose LMWH or warfarin target INR 2.0–3.0 × 6 weeks
Receiving long-term anticoagulation	Therapeutic-dose LMWH or UFH	Adjusted-dose LMWH or 75% of a therapeutic dose of LMWH	Resumption of long-term anticoagulation	Resumption of long-term anticoagulation
Antiphospholipid Antibodies				
History of VTE	Prophylactic anticoagulation with UFH or LMWH	NSS	Prophylactic anticoagulation; referral to specialist ^g	NSS
No prior VTE	Surveillance only or Prophylactic LMWH or UFH or Prophylactic LMWH or UFH plus low-dose aspirin if prior recurrent pregnancy loss or stillbirth	Prophylactic- or intermediate-dose UFH or prophylactic-dose LMWH, both given with 75–100 mg/day aspirin ^h	Prophylactic heparin plus low-dose aspirin × 6 weeks if prior recurrent pregnancy loss or stillbirth ^g	NSS

^aAmerican College of Obstetricians and Gynecologists, 2014b, 2015a.

^bAmerican College of Chest Physicians (Bates, 2012).

^cPostpartum treatment levels should be greater than antepartum treatment.

^dAntithrombin deficiency; doubly heterozygous or homozygous for prothrombin 20210A and factor V Leiden.

^eHeterozygous factor V Leiden or prothrombin 20210A; protein S or C deficiency.

^fFirst-degree relative with VTE at <50 years; other major thrombotic risk factors, e.g., obesity, prolonged immobility.

^gWomen with antiphospholipid syndrome should not use estrogen-containing contraceptives.

^hTreatment is recommended if the diagnosis of antiphospholipid syndrome is based upon three or more prior pregnancy losses.

INR = international normalized ratio; LMWH = low-molecular-weight heparin; NSS = not specifically stated; PCD = pneumatic compression device; UFH = unfractionated heparin; VTE = venous thromboembolism.

Prophylactic-, intermediate-, and adjusted-dose regimens are listed in Table 18-8.

Adapted from Cunningham, 2014b.

TABLE 18-8. Anticoagulation Regimens

Indication ^a	Dosage
Prophylactic LMWH	Enoxaparin, 40 mg SC once daily Dalteparin, 5000 units SC once daily Tinzaparin, 4500 units SC once daily
Therapeutic LMWH ^b	Enoxaparin, 1 mg/kg every 12 hr Dalteparin, 200 units/kg once daily Tinzaparin, 175 units/kg once daily Dalteparin, 100 units/kg every 12 hr
Minidose prophylactic UFH	UFH, 5000 units SC every 12 hr
Prophylactic UFH	UFH, 5000–10,000 units SC every 12 hr UFH, 5000–7500 units SC every 12 hr in first trimester UFH 7500–10,000 units SC every 12 hr in second trimester UFH, 10,000 units SC every 12 hr in third trimester, unless aPTT is elevated
Therapeutic UFH ^c	UFH, 10,000 units or more SC every 12 hr
Postpartum anticoagulation	Prophylactic LMWH or UFH for 4–6 wks or Vitamin K antagonist is begun along with initial UFH or LMWH therapy. Continue overlap until INR \geq 2.0 for 2 days. Then, vitamin K antagonist continued alone for 4–6 wks

^aOral direct thrombin inhibitors (dabigatran) and oral anti-Xa inhibitors (rivaroxaban, apixaban) are not recommended in pregnancy or with breastfeeding.

^bTherapeutic anti-Xa level target goal is 0.6–1.0 units/mL for twice daily regimen; slightly higher doses may be needed for once-daily regimen.

^cTherapeutic aPTT level target goal is 1.5–2.5 \times mean normal (sec) at 6 hr after injection.

^dTherapeutic warfarin level target goal is an INR 2.0–3.0.

aPTT = activated partial thromboplastin time; INR = international normalized ratio; LMWH = low-molecular-weight heparin; SC = subcutaneously; UFH = unfractionated heparin.

Adapted from American College of Obstetricians and Gynecologists, 2014d; Bates, 2012; Cunningham, 2014b.

genitourinary or gastrointestinal tract procedures. In the Western world, mitral valve prolapse is the most common condition predisposing to infective endocarditis, however, the incidence of infective endocarditis is extremely low and therefore prophylaxis is no longer recommended. Since adoption of the more restrictive use of infective endocarditis prophylaxis, the rate of clinical cases or deaths from infective endocarditis has not risen (American Heart Association 2007, 2014).

The guidelines do suggest that antibiotic prophylaxis for infective endocarditis is reasonable before vaginal delivery at the time of rupture of membranes for select patients who are at the highest risk of adverse outcomes from endocarditis. Patients include those with a prosthetic cardiac valve or prosthetic material used for valve repair and those with unrepaired and palliated cyanotic congenital heart disease, including surgical palliative shunts and conduit (American College of Cardiology, 2008). Patients with an established genitourinary or gastrointestinal tract infection requiring antibiotic therapy and who have a known cardiac condition are at the greatest risk for adverse outcome from endocarditis. They should also be treated. These include cardiac transplantation recipients, as well as patients with prosthetic cardiac valves, congenital heart disease, or a prior

history of infective endocarditis. The suggested regimen should be active against enterococci, and suitable options are penicillin, piperacillin, ampicillin, or vancomycin (American Heart Association, 2007).

Group B Streptococcal Disease

National guidelines recommend universal antepartum screening and intrapartum antibiotic prophylaxis to prevent group B streptococcal (GBS) disease in the newborn. This practice has reduced early-onset neonatal GBS sepsis by 80 percent. Intrapartum antibiotic GBS prophylaxis is indicated in women found to be at risk for transmission from mother to infant in the following circumstances: positive culture for GBS from either the vagina or rectum, previous infant with invasive GBS disease, or GBS bacteriuria in the current pregnancy. Women who develop intrapartum fever, preterm labor, and prolonged rupture of membranes and in whom the antepartum culture status is unknown should receive intrapartum prophylaxis for GBS. Intrapartum GBS prophylaxis is not recommended for GBS-positive women undergoing a planned cesarean delivery in the absence of rupture of membranes and labor (American College of Obstetricians and Gynecologists, 2015c).

The recommended GBS prophylactic regimen is penicillin G. Ampicillin as an acceptable alternative. Patients with a history of penicillin allergy without a history of anaphylaxis may safely receive GBS prophylaxis with cefazolin. In those patients with a history of type 1 (IgE-mediated) allergic reaction to penicillin, antepartum GBS culture isolates should undergo susceptibility testing to both clindamycin and erythromycin. If the isolate is sensitive to both clindamycin and erythromycin, the patient may receive clindamycin. Resistance to erythromycin may indicate an inducible resistance to clindamycin. Therefore, if an isolate reveals resistance to clindamycin or erythromycin, the patient should receive vancomycin for prophylaxis. Due to increasing resistant isolates, erythromycin is no longer recommended for GBS prophylaxis under any circumstance. If susceptibility testing was not performed or the results are not available, vancomycin is the preferred agent for penicillin-allergic women with a history suggestive of anaphylaxis (American College of Obstetricians and Gynecologists, 2015c; Verani, 2010).

Cesarean Delivery

As discussed on page 294, all women undergoing cesarean delivery should receive antibiotic prophylaxis unless treatment has already been given for another indication, for example, chorioamnionitis.

Perineal Laceration

One Cochrane database review found a single placebo-controlled trial evaluating the use of prophylactic antibiotics (cefoxitin) following third- or fourth-degree laceration (Buppassari, 2014). This study by Duggal and colleagues (2008) reported that the perineal wound complication rate at a 2-week postpartum visit was 8 percent in the treatment group and 24 percent in the placebo group. The American College of Obstetricians and Gynecologists (2014c) concluded that antibiotic prophylaxis in the setting of third- or fourth-degree laceration has not been extensively evaluated. Our practice is to provide a single dose of a second-generation cephalosporin or of clindamycin for penicillin-allergic women.

Cervical Cerclage

The American College of Obstetricians and Gynecologists (2014c) suggests that the evidence is insufficient to recommend perioperative antibiotic prophylaxis at the time of prophylactic, emergency, or abdominal cerclage placement. This is discussed further in Chapter 11 (p. 180).

Abortion

As described in Chapter 9 (p. 149), the use of prophylactic antibiotics at the time of surgical abortion is well studied (Levallois, 1988; Sawaya, 1996). The best prophylactic regimen is less certain, and numerous agents are effective. The American College of Obstetricians and Gynecologists (2016a) suggests a treat-all regimen of doxycycline, 100 mg orally before the procedure and 200 mg postabortion. An alternative is metronidazole, 500 mg orally twice daily for 5 days postprocedure. With complete spontaneous abortion, antibiotics are unnecessary. However, women with incomplete abortions requiring curettage should receive prophylaxis.

Adrenal Insufficiency

Systematic reviews regarding perioperative supplemental doses of corticosteroids find no evidence to support additional supra-therapeutic “stress doses.” Instead, patients should continue their usual daily dose (Kelly, 2013; Marik, 2008). Close hemodynamic monitoring is performed to look for volume-refractory hypotension, at which time stress-dose corticosteroids are initiated for presumed secondary adrenal insufficiency. Notably, Marik and Varon (2008) did suggest that patients receiving corticosteroids due to primary hypothalamic-pituitary-adrenal axis disease (Addison disease) require stress doses perioperatively. One regimen is hydrocortisone 100 mg administered IV every 8 hours and titrated to reduced doses as the patient improves.

INTRAOPERATIVE CARE

■ Surgical Time Out

Communication between all members of the team is vital to complete an operation successfully and avoid patient harm. Toward this goal, the Joint Commission established the Universal Protocol for Preventing Wrong Site, Wrong Procedure, and Wrong Person Surgery (Joint Commission, 2009). This protocol encompasses three components that include preprocedural verification of all relevant documents, marking the operative site, and completion of a “time out” prior to procedure initiation. The “time out” requires attention of the entire team to assess that patient, site, and procedure are correctly identified. Important interactions also includes introduction of the patient care team members, verification of prophylactic antibiotics, expected procedure length, and communication of anticipated complications such as potential for large blood loss. Additionally, requests for special instrumentation are addressed preoperatively.

■ Maternal Positioning

Beyond 20 weeks’ gestation, the aorta and inferior vena cava can be compressed by uterine weight during surgery. This lowers maternal cardiac output and possibly reduces uteroplacental perfusion. If the proposed surgical procedure allows, the use of a left-lateral tilt may minimize the resultant hemodynamic disturbances (Lee, 2012). With this, the right side of a supine woman’s torso is elevated and rotated ≥ 15 degrees to her left. This elevated position is held by a wedge or blanket roll placed beneath.

For women with a suspected accrete syndrome, a woman may be placed in the low dorsal lithotomy position in booted support stirrups. In this position, abducted hips allow intraoperative evaluation of vaginal bleeding, provide access for placement of a vaginal pack, and offer additional space for a surgical assistant between the legs (Society for Maternal-Fetal Medicine, 2010). With poor positioning, nerves can be injured. The common peroneal nerve, now termed the common fibular nerve, originates above the popliteal fossa and crosses the lateral head of the fibula before it descends down the lateral calf. At the lateral fibular head, this nerve is at risk for compression against leg stirrups. Therefore, patient positioning that avoids pressure at this point or the addition of cushioned padding is warranted.

■ Pregnancy Monitoring

The American College of Obstetricians and Gynecologists (2015b) has general guidelines regarding fetal monitoring for the woman undergoing nonobstetric surgery. First, if the fetus is viable, documentation of the fetal heart rate before and after the surgical procedure is sufficient.

If the fetus is viable, at a minimum, electronic fetal heart rate and uterine contraction monitoring should be assessed before the procedure to evaluate fetal well-being and exclude uterine contractions. Intraoperatively, the ultimate decision to use continuous fetal monitoring is individualized. Factors include gestational age, type of surgery, the physical ability to perform the monitoring, availability of an obstetric health-care provider to intervene for fetal indications, and facilities available to care for the fetus. In the immediate postoperative period, simultaneous fetal heart rate and contraction monitoring is performed to ensure fetal well-being and exclude contractions. In women at or beyond 20 to 24 weeks' gestation, maternal positioning should continue to minimize aortocaval compression by implementing a maternal lateral tilt until the woman is awake, alert, and able to mobilize herself. The risk of postoperative labor is highest in the first postoperative week.

■ Foley Catheter

In many instances, a full bladder can encroach on abdominal operating space, artificially elevate the uterine corpus, and increase cystotomy risk. For short procedures, an in-and-out catheterization using a red rubber catheter is sufficient to drain the bladder. For longer cases, an indwelling Foley catheter is preferable. Moreover, this permits monitoring of urine output in cases with increased blood loss.

■ Electrosurgery

Electrosurgery is often used in operations to cut or coagulate. The effects and physics of this tool are described in Chapter 2 (p. 22). If monopolar electrosurgery is planned, a grounding pad is placed on the patient to serve as an exit site for electric current. Ideally, the grounding pad is firmly adhered to a relatively flat body surface that is near the operative field. Thus, in most obstetric procedures, grounding pads are placed along the lateral upper thigh.

POSTOPERATIVE CARE

■ Vital Signs

After transfer to her room, the woman is assessed at least hourly for 4 hours, and thereafter at intervals of 4 hours. Vital signs and urine output are evaluated. In certain cases, uterine tone and vaginal bleeding may also be pertinent and monitored. In cases with known significant blood loss or those with risks for postoperative bleeding, the hematocrit is routinely measured the morning after surgery. It is checked sooner if blood loss was substantial or if hypotension, tachycardia, oliguria, or other evidence suggests hypovolemia. If the hematocrit is decreased significantly from the preoperative level, the measurement is repeated and a search is instituted to identify the cause.

■ Intravenous Fluids and Pain Control

Postoperative IV fluid requirements usually consist of isotonic crystalloid solutions of lactated Ringer solution or 0.9-percent normal saline. Postcesarean delivery, postvaginal delivery, and postabortal fluids will frequently contain oxytocin.

Options for pain control will vary depending on the procedure and whether a fetus remains. For postpartum pain, opioid and nonsteroidal antiinflammatory drugs (NSAIDs) are mainstays. Opioid therapy may be administered via oral, IV, intramuscular (IM), intrathecal, or epidural routes. Notably, women with either preeclampsia or chronic hypertension that persists beyond the first postpartum day should avoid NSAIDs due to their likelihood to aggravate hypertension (American College of Obstetricians and Gynecologists, 2013).

For a woman undergoing a nonobstetric surgery, an important goal should be minimizing the cumulative opioid dosage exposure to the fetus. Acetaminophen may suffice for milder pain, but total daily doses should not exceed 4 g (Food and Drug Administration, 2011). In an ongoing pregnancy, prolonged NSAID use is avoided. Indomethacin may constrict the fetal ductus arteriosus, resulting in pulmonary hypertension. Fetal ductal constriction is more likely when the drug is taken in the third trimester for longer than 72 hours (Rasanen, 1995; Vermillion, 1997). Other NSAIDs are assumed to confer similar risks. These agents may also decrease fetal urine production and thereby reduce amniotic fluid volume (van der Heijden, 1994; Walker, 1994).

■ Postoperative Nausea and Vomiting

After surgery, diet advancement in pregnant or postpartum women mirrors that for nonpregnant women undergoing similar or identical procedures. Postoperative nausea and vomiting (PONV) is frequent in the immediate puerperium. One suitable pharmacologic agent is the serotonin-receptor antagonist ondansetron (Zofran), and an 8-mg dose can be given IV or orally. The histamine H₁-receptor blocking agent promethazine (Phenergan) can be administered IM, IV, orally, or rectally in 12.5- or 25-mg doses every 6 hours. Some evidence also supports the use of metoclopramide (Reglan), 10 mg orally, for postcesarean PONV (Mishriky, 2012).

■ Rh Status and Progesterone Support

If a pregnancy is ended as a result of surgery, then Rh status should be confirmed. This is true for first-trimester ectopic pregnancy, intrauterine pregnancy, and hydatidiform moles. If the woman is D negative and her partner has a blood group that is either D positive or unknown, then 300 µg anti-D immune globulin should be given to prevent anti-D isoimmunization.

Also, fetal-maternal hemorrhage occurs in up to 30 percent of pregnant women who suffer severe trauma (Pearlman, 1990). The Kleihauer-Betke (KB) acid elution technique can detect this hemorrhage. For women who are D negative, the KB test allows calculation of the total dose of Rh immune globulin required for Rh-negative mothers. This calculation is presented in Chapter 17 (p. 287).

As a result of surgery, if the corpus luteum is removed before 10 weeks' gestation, progesterone support is recommended until 10 weeks' gestation to maintain the pregnancy. Suitable

TABLE 18-9. Action Profiles of Commonly Used Insulin

Insulin Type	Onset of Action	Peak of Action (hr)	Duration (hr)
Short Acting			
Lispro, Aspart, Glulisine	<15 min	1–2	3–5
Regular	30–60 min	2–4	4–8
Intermediate & Long Acting			
NPH (isophane)	1–3 hr	5–7	13–18
Lente (zinc)	1–3 hr	4–8	13–20
Ultralente (extended zinc)	2–4 hr	8–14	18–30
Glargine, Detemir	1–4 hr	Minimal peak activity	Up to 24 hr

Modified from American College of Obstetricians and Gynecologists, 2014c; Gabbe, 2003; Powers, 2012.

regimens include: (1) micronized progesterone (Prometrium) 200 or 300 mg orally once daily; (2) 8-percent progesterone vaginal gel (Crinone) one premeasured applicator vaginally daily plus micronized progesterone 100 or 200 mg orally once daily; or (3) intramuscular 17-hydroxyprogesterone caproate (Delalutin), 150 mg. Between 8 and 10 weeks' gestation, only one injection is required immediately after surgery. If the corpus luteum is excised between 6 and 8 weeks' gestation, then two additional doses are given 1 and 2 weeks after the first.

PERIOPERATIVE MANAGEMENT OF DIABETES

General goals in the perioperative/peripartum management of the woman with diabetes should include: (1) maintenance of fluids and electrolytes with caution to avoid fluid deficits from osmotic diuresis, (2) adequate glucose support to prevent catabolism and starvation ketosis and hypoglycemia, and (3) insulin as indicated to prevent extremes in glycemia.

■ Diet-Controlled Gestational Diabetes

In general, women with diet-controlled gestational diabetes may not require special perioperative intervention. Blood glucose levels are evaluated pre- and postoperatively. If glycemic targets are exceeded, they can be controlled with small doses of supplemental short-acting insulin (Table 18-9). In the postpartum period, the hyperglycemic effects of pregnancy resolve rapidly and most women revert to their prepregnancy glycemic state. The Fifth International Workshop Conference on Gestational Diabetes

recommends that women with gestational diabetes should undergo blood glucose monitoring for 24 to 72 hours. Because they are at high risk for developing overt diabetes, these women should undergo a 2-hour, 75-g glucose challenge test at 6 to 12 weeks postpartum (Blumer, 2013; Metzger, 2007).

■ Pregestational Diabetes or Insulin-Requiring Gestational Diabetes

Patients with type 1 or insulin-treated type 2 diabetes should be scheduled for surgery as early as possible in the morning to minimize problems with their diabetes management. For the woman undergoing labor induction, the morning dose of insulin is usually withheld. During active labor, glucose utilization and metabolic clearance of glucose rises. Thus, the need for glucose increases, and insulin requirements decline. Capillary or plasma glucose levels should be evaluated frequently. If glucose levels drop below 70 mg/dL, then 5-percent dextrose IV infusion can be administered. If glucose levels exceed 100 mg/dL, regular (short-acting) insulin can be delivered by an IV solution at a rate of 1.25 U/hr as outlined in Table 18-10. Following placental delivery, maternal insulin sensitivity increases, leading to lowered insulin requirements and a risk for hypoglycemia (Achong, 2014; Maheux, 1996). In the puerperium, insulin requirements decrease rapidly, and many women require no insulin for the first 24 hours postpartum. One half of the pre-delivery insulin dose may be resumed once the woman begins a regular diet (American College of Obstetricians and Gynecologists, 2014a).

TABLE 18-10. Insulin Management During Labor and Delivery

At bedtime, the usual dose of intermediate-acting insulin is given
 Morning dose of insulin is withheld
 Intravenous infusion of normal saline is begun
 Once active labor begins or glucose levels decline to less than 70 mg/dL, the infusion is changed from saline to 5% dextrose and delivered at a rate of 100–150 mL/hr (2.5 mg/kg/min) to achieve a glucose level of approximately 100 mg/dL.
 Glucose levels are checked hourly using a bedside meter allowing for adjustment in the insulin or glucose infusion rate.
 Regular (short-acting) insulin is administered by intravenous infusion at a rate of 1.25 units/hr if glucose levels exceed 100 mg/dL.

Adapted from Cunningham, 2014a.

REFERENCES

- Achong N, Duncan EL, McIntyre HD, et al: Peripartum management of glycaemia in women with type 1 diabetes. *Diabetes Care* 37:364, 2014
- American College of Cardiology/American Heart Association: 2008 guidelines for the management of adults with congenital heart disease. A report of the American College of Cardiology/American Heart Association Task Force on Practice Guidelines. *Circulation* 118(23):e714, 2008
- American College of Obstetricians and Gynecologists: Antibiotic prophylaxis for gynecologic procedures. Practice Bulletin No. 104, May 2009, Reaffirmed 2016a
- American College of Obstetricians and Gynecologists: Antiphospholipid syndrome. Practice Bulletin No. 132, December 2012, Reaffirmed 2015a
- American College of Obstetricians and Gynecologists: Hypertension in pregnancy. Report of the American College of Obstetricians and Gynecologists' Task Force on Hypertension in Pregnancy. Executive summary. *Obstet Gynecol* 122(5):1122, 2013
- American College of Obstetricians and Gynecologists: Nonobstetric surgery during pregnancy. Committee Opinion No. 474, February 2011, Reaffirmed 2015b
- American College of Obstetricians and Gynecologists: Placenta accreta. Committee Opinion No. 529, July 2012, Reaffirmed 2016b
- American College of Obstetricians and Gynecologists: Pregestational diabetes mellitus. Practice Bulletin No. 60, March 2005, Reaffirmed 2014c
- American College of Obstetricians and Gynecologists: Prevention of early-onset group B streptococcal disease in newborns. Committee Opinion No.485, April 2011, Reaffirmed 2015c
- American College of Obstetricians and Gynecologists: Thromboembolism in pregnancy. Practice Bulletin No. 123, September 2011, Reaffirmed 2014d
- American College of Obstetricians and Gynecologists: Use of prophylactic antibiotics in labor and delivery. Practice Bulletin No. 120, June 2011, Reaffirmed 2016c
- American Heart Association/American College of Cardiology: 2014 AHA/ACC Guideline for the management of patients with valvular heart disease: executive summary. *Circulation* 129(23):e521, 2014
- American Heart Association: AHA Guideline. Prevention of infective endocarditis. Guidelines From the American Heart Association. A Guideline From the American Heart Association Rheumatic Fever, Endocarditis, and Kawasaki Disease Committee, Council on Cardiovascular Disease in the Young, and the Council on Clinical Cardiology, Council on Cardiovascular Surgery and Anesthesia, and the Quality of Care and Outcomes Research Interdisciplinary Working Group. *Circulation* 116(15):1736, 2007
- American Society of Anesthesiologists: An updated report by the American Society of Anesthesiologists Task Force on Management of the Difficult Airway. Practice guidelines for management of the difficult airway. *Anesthesiology*: 118(2):251, 2013
- American Society of Anesthesiologists: ASA Physical Status Classification System. 2014. Available at: <https://www.asahq.org/resources/clinical-information/asa-physical-status-classification-system>. Accessed September 14, 2015
- Anderson DJ, Podgorny K, Berríos-Torres SI, et al: Strategies to prevent surgical site infections in acute care hospitals: 2014 update. *Infect Control Hosp Epidemiol* 35(6):605, 2014
- Bates SM, Greer IA, Middeldorp S, et al: VTE, thrombophilia, antithrombotic therapy and pregnancy. Antithrombotic therapy and prevention of thrombosis, 9th ed: American College of Chest Physicians evidence-based clinical practice guidelines. *Chest* 141(2 Suppl):e691S, 2012
- Bauer LA, Edwards WA, Dellinger EP, et al: Influence of weight on aminoglycoside pharmacokinetics in normal weight and morbidly obese patients. *Eur J Clin Pharmacol* 24:643, 1983
- Berg CJ, Callaghan WM, Syverson C, et al: Pregnancy-related mortality in the United States, 1998–2005. *Obstet Gynecol* 116(6):1302, 2010
- Buppassiri P, Lumbiganon P, Thinkhamrop J, et al: Antibiotic prophylaxis for third- and fourth-degree perineal tear during vaginal birth. *Cochrane Database Syst Rev* 10:CD005125, 2014
- Blumer I, Haar E, Hadden DR, et al: Diabetes and pregnancy: An Endocrine Society clinical practice guideline. *J Clin Endocrinol Metab* 98(11):4227, 2013
- Bratzler DW, Dellinger EP, Olsen KM, et al: Clinical practice guidelines for antimicrobial prophylaxis in surgery. *Am J Health-Syst Pharm* 70:195, 2013
- Chan WS, Spencer FA, Ginsberg JS: Anatomic distribution of deep vein thrombosis in pregnancy. *CMAJ* 192(7):657, 2010
- Creanga AA, Berg CJ, Syverson C, et al: Pregnancy-related mortality in the United States, 2006–2010. *Obstet Gynecol* 125:5, 2015
- Cunningham FG, Leveno KJ, Bloom SL, et al: Diabetes. *Williams Obstetrics*, 24th ed. McGraw-Hill, 2014a
- Cunningham FG, Leveno KJ, Bloom SL, et al: Thromboembolic disorders. *Williams Obstetrics*, 24th ed. McGraw-Hill, 2014b
- D'Alton ME, Main EK, Menard K, et al: The national partnership for maternal safety. *Obstet Gynecol* 123:973, 2014
- Duff P: Prophylactic antibiotics for cesarean delivery: a simple cost-effective strategy for prevention of postoperative morbidity. *Am J Obstet Gynecol* 157:794, 1987
- Duggal N, Mercado C, Daniels K, et al: Antibiotic prophylaxis for prevention of postpartum perineal wound complications: a randomized controlled trial. *Obstet Gynecol* 111(6):1268, 2008
- Faro S, Martens MG, Hammill HA, et al: Antibiotic prophylaxis: is there a difference? *Am J Obstet Gynecol* 162:900, 1990
- Food and Drug Administration: FDA drug safety communication: prescription acetaminophen products to be limited to 325 mg per dosage unit; boxed warning will highlight potential for severe liver failure. 2011. Available at: <http://www.fda.gov/Drugs/DrugSafety/ucm239821.htm>. December 10, 2015
- Gabbe SG, Graves CR: Management of diabetes mellitus complicating pregnancy. *Obstet Gynecol* 102(4):857, 2003
- Gonik B: Single-versus three-dose cefotaxime prophylaxis for cesarean section. *Obstet Gynecol* 65:189, 1985
- Guimicheva B, Czuprynska J, Arya R: The prevention of pregnancy-related venous thromboembolism. *Br J Haematol* 168:163, 2015
- Heit JA, Kobbervig CE, James AH, et al: Trends in the incidence of venous thromboembolism during pregnancy or postpartum: a 30-year population-based study *Ann Intern Med* 143(10):697, 2005
- Horlocker TT, Wedel DJ, Rowlingson JC, et al: Executive summary: regional anesthesia in the patient receiving antithrombotic or thrombolytic therapy: American Society of Regional Anesthesia and Pain Medicine Evidence-Based Guidelines (Third Edition). *Reg Anesth Pain Med* 35(1):102, 2010
- Janson B, Thursky K: Dosing of antibiotics in obesity. *Curr Opin Infect Dis* 25(6):634, 2012
- Joint Commission: Universal protocol for preventing wrong site, wrong procedure, and wrong person surgery. Oakbrook Terrace, Joint Commission, 2009
- Kelly KN, Domajenko B: Perioperative stress-dose steroids. *Clin Colon Rectal Surg* 26(3):163, 2013
- Lee SWY, Khaw KS, Ngan Kee WD, et al: Haemodynamic effects from aortic compression at different angles of lateral tilt in non-labouring term pregnant women. *Br J Anaesth* 109(6):950, 2012
- Levallois P, Rioux JE: Prophylactic antibiotics for suction curettage abortion: results of a clinical controlled trial. *Am J Obstet Gynecol* 158:100, 1988
- Maheux PC, Bonin B, Dizasp A, et al: Glucose homeostasis during spontaneous labor in normal human pregnancy. *J Clin Endocrinol Metab* 81:209, 1996
- Mallampati SR, Gatt SP, Gugino LD, et al: A clinical sign to predict difficult tracheal intubation: a prospective study. *Can Anaesth Soc J* 32(4):429, 1985
- Mangram AJ, Horan TC, Pearson ML, et al: Guideline for prevention of surgical site infection, 1999. *Infect Cont Hosp Epidemiol* 20(4):247, 1999
- Marik PE, Varon J: Requirement of perioperative stress doses of corticosteroids: a systematic review of the literature. *Arch Surg* 143(12):1222, 2008
- Metzger BE, Buchanan TA, Coustan DR, et al: Summary and recommendation of the fifth international workshop-conference of gestational diabetes mellitus. *Diab Care* 30(2):S251, 2007
- Mishriky BM, Habib AS: Metoclopramide for nausea and vomiting prophylaxis during and after Caesarean delivery: a systematic review and meta-analysis. *Br J Anaesth* 108(3):374, 2012
- Nieboer TE, Johnson N, Lethaby A, et al: Surgical approach to hysterectomy for benign gynaecological disease. *Cochrane Database Syst Rev* 3: CD003677, 2009
- Ogden CL, Carroll MD, Kit BK, et al: Prevalence of childhood and adult obesity in the United States, 2011–2012. *JAMA* 311(8):806, 2012
- Pai MP, Bearden DT: Antimicrobial dosing considerations in obese adult patients. *Pharmacotherapy* 27(8):1081, 2007
- Pearl J, Price R, Richardson W, et al: Guidelines for diagnosis, treatment, and use of laparoscopy for surgical problems during pregnancy. *Surg Endosc* 25(11):3479, 2011
- Pearlman MD, Tintinalli JE, Lorenz RP: A prospective controlled study of outcome after trauma during pregnancy. *Am J Obstet Gynecol* 162:1502, 1990
- Pomp ER, Lenselink AM, Rosendall FR, et al: Pregnancy, the postpartum period and prothrombotic defects: risk of venous thrombosis in the MEGA study. *J Thromb Haemost* 6(4):632, 2008
- Powers AC: Diabetes mellitus. In: Longo DL, Fauci AS, Kasper DL, et al (eds): *Harrison's Principles of Internal Medicine*, 18th ed. McGraw-Hill, New York, 2012, p 2968
- Rasanen J, Jouppila P: Fetal cardiac function and ductus arteriosus during indomethacin and sulindac therapy for threatened preterm labor: a randomized study. *Am J Obstet Gynecol* 173:20, 1995
- Reichman DE, Greenberg JA: Reducing surgical site infections: a review. *Rev Obstet Gynecol* 2(4):212, 2009
- Samssoon GL, Young JR: Difficult tracheal intubation: a retrospective study. *Anaesthesia* 42(5):487, 1987

- Sawaya GF, Grady D, Kerlikowske K, et al: Antibiotics at the time of induced abortion: the case for universal prophylaxis based on a meta-analysis. *Obstet Gynecol* 87:884, 1996
- Silver RM, Fox KA, Barton JR, et al: Center of excellence for placenta accreta. *Am J Obstet Gynecol* 212(5):561, 2015
- Smaill FM, Grivell RM: Antibiotic prophylaxis versus no prophylaxis for preventing infection after cesarean section. *Cochrane Database Syst Rev* 10:CD007482, 2014
- Society for Maternal-Fetal Medicine: Placenta accreta. *Am J Obstet Gynecol* 203(5):430, 2010
- Sultan AA, West J, Tat LJ, et al: Risk of first venous thromboembolism in and around pregnancy: a population-based cohort study. *Br J Haematol* 156(3):366, 2012
- van der Heijden BJ, Carlus C, Nancy F, et al: Persistent anuria, neonatal death, and renal microcystic lesions after prenatal exposure to indomethacin. *Am J Obstet Gynecol* 171:617, 1994
- Verani JR, McGee L, Schraq SJ, et al: Prevention of perinatal group B streptococcal disease—revised guidelines from CDC, 2010. *MMWR* 59(10):1, 2010
- Vermillion ST, Scardo JA, Lashus AG, et al: The effect of indomethacin tocolysis on fetal ductus arteriosus constriction with advancing gestational age. *Am J Obstet Gynecol* 177:256, 1997
- Walker MPR, Moore TR, Brace RA: Indomethacin and arginine vasopressin interaction in the fetal kidney: a mechanism of oliguria. *Am J Obstet Gynecol* 171:1234, 1994
- Witt A, Doner M, Petricevic L, et al: Antibiotic prophylaxis before surgery vs after cord clamping in elective cesarean delivery: a double-blind, prospective, randomized, placebo-controlled trial. *Arch Surg* 146(12):1404, 2011
- Wurtz R, Itokazu G, Rodvoid K: Antimicrobial dosing in obese patients. *Clin Infect Dis* 25:112, 1997

akushherlib.ru

CHAPTER 19

Anesthesia for the Pregnant Woman

UNIQUE CONSIDERATIONS	307
ANESTHESIA FOR OPERATIVE VAGINAL DELIVERY	309
ANESTHESIA FOR CESAREAN DELIVERY	311
CESAREAN HYSTERECTOMY	314
ANESTHESIA FOR POSTPARTUM TUBAL LIGATION	315
FETAL SURGERY	316
SUMMARY	316

Modern anesthesia practice has an excellent record of safety for the parturient. The anesthesia-related maternal mortality rate in the United States is estimated at 1 per 1 million live births (Hawkins, 2011). Indeed, in the latest report from the Centers for Disease Control and Prevention, Creanga and colleagues (2015) cited anesthesia as the cause of pregnancy-related death in only 0.7 percent of maternal deaths in the United States from 2006

to 2010. Also, the 2010 to 2012 triennial report from the United Kingdom and Ireland described a direct anesthetic mortality rate of 0.17 per 100,000 maternities (Knight, 2014). Finally, the Serious Complication Repository (SCORE) Project of the Society for Obstetric Anesthesia and Perinatology (SOAP) captured data from 257,000 parturients receiving an anesthetic between 2009 and 2014 (D'Angelo, 2014). No deaths were reported, and serious anesthesia-related complications occurred in 1 of 3000 patients. The most frequent was high neuraxial block.

For safe anesthesia administration, the obstetric anesthesiologist should understand the unique characteristics of the gravida. These include alterations in maternal physiology, maintenance of uterine perfusion, and fetal response to anesthetic interventions. So too must the obstetrician be familiar with the effects of anesthesia on these parameters during surgery.

UNIQUE CONSIDERATIONS

Changes in maternal physiology affect several aspects of anesthetic management (Gaiser, 2014). Cardiovascular changes include increases in cardiac output and blood volume that begin in the first trimester. By 28 weeks' gestation, these measure 30 to 40 percent above baseline (Table 19-1). Dilutional anemia caused by plasma expansion reduces the hematocrit.

TABLE 19-1. Cardiovascular Implications of Physiologic Changes of Normal Pregnancy

Variable	Change	Clinical Implications
Blood volume	↑40%	Hypervolemia; can tolerate 1000 mL blood loss well
Plasma volume	↑50%	Greater plasma than red cell expansion causes dilutional anemia
Heart rate	↑15 bpm	Mild baseline tachycardia
Cardiac output	↑40%	More cardiac work to accommodate the increased blood volume
Systemic vascular resistance	↓20%	Blood pressure remains normal despite ↑ cardiac output and blood volume
Aortocaval compression	Varies	Reduces cardiac preload in supine position

bpm = beats per minute.

TABLE 19-2. Respiratory Implications of Physiologic Changes of Normal Pregnancy

Variable	Change	Clinical Implications
Alveolar ventilation	↑70%	Elevated arterial po_2
Minute ventilation (TV × RR)	↑50% overall; RR ↑15%	pcO_2 ↓10 torr, mild tachypnea present
Functional residual capacity	↓20%	Rapid desaturation during apnea or airway obstruction
Metabolic rate	↑20%	Rapid desaturation during apnea
Mucosal edema	Varies; worsens during labor	Difficult intubation risk ↑10-fold compared with nonpregnant patients

pcO_2 = partial pressure of CO_2 ; po_2 = partial pressure of O_2 ; RR = respiratory rate; TV = tidal volume.

Despite the increase in blood volume and cardiac output, the parturient is susceptible to hypotension from aortocaval compression in the supine position. This is especially true after loss of sympathetic tone associated with regional anesthesia. If the uterus occludes the vena cava in the supine position, preload to the heart is obstructed (Lee, 2012b). Only about 10 percent of pregnant patients at term develop symptoms of shock in the supine position. However, fetal compromise from lowered uterine perfusion can develop even in an asymptomatic mother. For this reason, uterine displacement is an encouraged practice after midpregnancy.

The most important respiratory change during pregnancy is the decrease in functional residual capacity (FRC) (Table 19-2). In the second trimester, the FRC declines by 20 percent and causes a decreased supply of oxygen. This is coupled with a 20-percent increase in oxygen demand as the maternal metabolic rate increases. These are compounded by airway closure during normal tidal ventilation, which develops in a third of parturients while in supine position. This effect is even more likely in smokers and older women. The result is rapid oxygen desaturation during periods of apnea or airway obstruction.

Minute ventilation also changes with pregnancy. This parameter increases at term by 50 percent due to an increase in tidal volume. As a result, normal pcO_2 falls about 10 torr, with a compensatory fall in bicarbonate. This new normal for arterial pcO_2 should be taken into account when interpreting arterial blood gases during pregnancy (Table 19-3).

TABLE 19-3. Normal Arterial Blood Gas Values in Nonpregnant Individuals Compared with Normal-Weight and Obese Pregnant Women

Parameter	Non-pregnant	Normal-Weight Pregnant	Obese Pregnant
pH	7.40	7.44	7.44
po_2	95	104	85
pcO_2	40	32	30
Base deficit	+1	-3	-4

pcO_2 = partial pressure of CO_2 ; po_2 = partial pressure of O_2 .

Throughout the respiratory tract, capillary engorgement raises the likelihood of trauma during placement of airways and gastric tubes. Thus, a smaller endotracheal tube—6.0 or 7.0 mm—is recommended. Nasal intubations or nasogastric tubes are avoided.

The parturient may be at increased risk of aspirating gastric contents. Gastric volume, pH, and emptying are probably not altered during pregnancy, but gastroesophageal sphincter tone is usually reduced. For example, gravidas often describe symptoms of gastroesophageal reflux disease (GERD). Heartburn indicates that the pressure gradient across the gastroesophageal junction is diminished. Concomitantly, the patient who receives opioids will have delayed gastric emptying. Thus preventively, prior to anesthesia administration, all pregnant women are given preoperative aspiration prophylaxis with a nonparticulate antacid to neutralize gastric contents. Parturients at increased risk include those with obesity or with concern for a difficult airway. These women may additionally receive an H_2 -receptor antagonist to reduce acid production and metoclopramide to improve motility and raise gastroesophageal sphincter tone (American Society of Anesthesiologists Task Force on Obstetric Anesthesia, 2016).

During pregnancy, requirements for inhalational anesthetics decline 25 to 40 percent, and loss of consciousness may occur even with “sedative” doses of agents (Lee, 2014). Beginning early in pregnancy, dosage requirements for local anesthetics in the epidural and subarachnoid spaces also drop by 30 percent. This is probably secondary to progesterone action. Drug doses are altered accordingly.

Failed tracheal intubation remains a problem in obstetric patients because of many factors, including normal fluid retention made even worse by preeclampsia. Thus, difficult intubation is more common—1 in 533 gravidas—compared with approximately 1 in 2200 nonpregnant surgical patients (D’Angelo, 2014).

Of fetal effects, fetal oxygenation depends on maternal oxygenation and uterine blood flow. Maternal hyperventilation, either spontaneous or during mechanical ventilation, that leads to alkalosis causes a leftward shift of the oxyhemoglobin dissociation curve. This increases maternal affinity for oxygen and decreases its release to the fetus. In addition, the mechanical effects of positive-pressure ventilation may cause a 25-percent fall in uterine blood flow by decreasing venous return to the heart. Maternal hypotension can produce fetal hypoxia as well.

In summary, the physiologic changes of pregnancy most relevant to the anesthesiologist are decreased pulmonary functional

residual capacity, aortocaval compression if supine, decreased lower esophageal sphincter tone, and reduced anesthetic drug requirements. Finally, difficult intubation is more common in pregnant women.

ANESTHESIA FOR OPERATIVE VAGINAL DELIVERY

■ Forceps and Vacuum-Assisted Delivery

Vaginal delivery by forceps or vacuum extraction requires analgesia, muscle relaxation, and patient cooperation. Suitable anesthesia for operative vaginal delivery and perineal repair can include local infiltration or pudendal block, intravenous or inhalational analgesia, spinal (subarachnoid) block, or lumbar epidural block. Of these, pudendal block is often inadequate for operative vaginal delivery other than outlet procedures. General anesthesia is rarely necessary and is not practical or safe when delivery takes place in a labor-delivery-recovery (LDR) room, which typically lacks anesthesia equipment.

Intravenous analgesia is used when neuraxial block is contraindicated or urgency such as acute fetal distress does not allow time for spinal block placement. Narcotic analgesia just prior to delivery is ill advised because of the risk of neonatal depression. In contrast, ketamine is a potent amnesic and analgesic that supports cardiovascular and respiratory functions and produces minimal depression of airway reflexes (Joselyn, 2010). Doses of 0.5 mg/kg intravenously will produce profound analgesia within 1 minute of administration. Its effects last approximately 15 minutes. The drug does cross the placenta but has few or no neonatal effects. Moreover, it does not cause uterine relaxation.

One disadvantage of ketamine is its potent amnesic effects, such that the mother will have little recall of the birth. Another is emergence delirium. Because it is a phencyclidine (“angel dust”) derivative, dreams are common, but unpleasant or frightening hallucinations may also occur. These effects can be attenuated by informing the patient she may have dreams and suggesting they will be pleasant, and by administering a benzodiazepine such as midazolam after delivery, although this will prolong the amnesic effects. Notably, ketamine has sympathomimetic effects and can increase blood pressure and heart rate substantively. Thus, it should be used with caution in women with significant hypertension or preeclampsia.

Inhalational analgesia has rarely been used during labor and delivery in the United States. It requires an anesthesia machine for administration, and regulations require trace anesthetic gas scavenging (National Institute for Occupational Safety and Health, 1994). This changed in 2014 when the Food and Drug Administration approved a mobile device capable of administering 50-percent nitrous oxide by mask that can be used in an LDR room (Barbieri, 2014). This device allows a woman to self-administer nitrous oxide on demand and is scavenged to protect

personnel and family in the LDR room from exposure. In the operating room (OR) setting, nitrous oxide is readily available.

Disadvantages of nitrous oxide analgesia are its amnesic effects and the potential for sedation to progress to unconsciousness with risk of aspiration (Likis, 2014). The mobile device for nitrous oxide administration has a one-way valve that can only be triggered when the woman keeps a tight seal between the mask and her face. In the OR, many anesthesiologists have the woman hold the mask herself so that if she becomes too sedated, it will fall away from her face. Use of nitrous oxide requires monitoring of the level of consciousness and using pulse oximetry to document adequate oxygenation. Both intravenous and inhalational anesthesia options are most effective when supplemented with local anesthesia or a pudendal block. When given alone, they often are insufficient for performing episiotomies or repairing perineal lacerations.

Pudendal nerve block is a minor regional block that is reasonably effective and very safe. It involves injection of 5 to 10 mL of local anesthetic just below the ischial spine (Fig. 19-1). Either 1-percent lidocaine or 2-percent 2-chloroprocaine can be used. Pudendal block is generally satisfactory for spontaneous vaginal deliveries and episiotomies, and for some outlet or low operative vaginal deliveries. However, it may be insufficient for deliveries requiring additional manipulation. The potential for local anesthetic toxicity is higher with pudendal block compared with perineal infiltration because of large vessels proximal to the injection site. Therefore, aspiration of the needle before injection and intermittently during injection is particularly important. When perineal and labial infiltration is required in addition to pudendal block, it is important to closely monitor the total amount of local anesthetic given. Specific calculation of a maximum safe dose for each patient before injection is recommended (Dorian, 2015). The toxic dose of lidocaine approximates 4.5 mg/kg. For a 50-kg woman, this would equal 225 mg. Of note, for any drug solution, 1-percent = 10 mg/mL. Thus, if a 1-percent

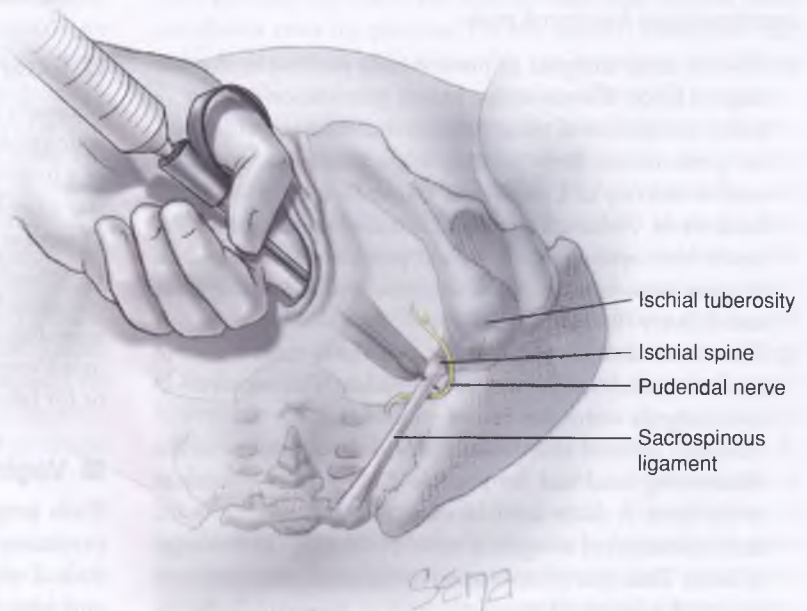


FIGURE 19-1 Pudendal nerve block.

lidocaine solution is used, the calculated allowed amount would be: $225 \text{ mg} \div 10 \text{ mg/mL} = 22.5 \text{ mL}$.

A *spinal block*, which is also called an intrathecal or subarachnoid block, provides excellent anesthesia and muscle relaxation. It is fast and relatively simple to perform, and in hyperbaric preparations provides focused perineal anesthesia—the “saddle block.” Spinal anesthesia for delivery only requires a sensory level of T10, so hypotension is less likely than during cesarean delivery. The ability to push may be compromised by diminished motor strength and significant sensory block. Another disadvantage is that it is time-limited when given as a single injection. However, long-acting local anesthetics such as bupivacaine can provide 2 hours of anesthesia for extensive repairs. Also, preservative-free morphine can be added to the local anesthetic for prolonged postoperative analgesia if the repair is extensive.

If an operative vaginal delivery is anticipated, a lumbar epidural catheter can be placed for labor analgesia and then intensified for delivery with higher concentrations of local anesthetic. Of note, epidural anesthetics are segmental blocks, that is, a confined band of analgesia. As a result, there occasionally is sacral nerve sparing, and perineal anesthesia may be incomplete. Epidural blocks have an upper and lower sensory level. Thus, if the lower sacral nerves are not completely blocked, the obstetrician may need to supplement with local anesthesia or a pudendal block.

■ Vaginal Breech Delivery

The American Society of Anesthesiologists Task Force on Obstetric Anesthesia (2016) has guidelines that support early insertion of a spinal or epidural catheter for obstetric indications such as preeclampsia or vaginal breech delivery or for anesthetic indications such as a difficult airway or obesity. This practice is considered to reduce the need for general anesthesia if an emergent procedure becomes necessary. In these cases, the insertion of a spinal or epidural catheter may precede the onset of labor or a patient’s request for labor analgesia.

In providing analgesia for a vaginal breech delivery, the anesthesiologist has several goals:

1. Provide sacral analgesia to prevent early pushing in the first stage of labor. Women with a breech presentation often have earlier complaints of rectal pressure than are seen with a vertex presentation. Early pushing might result in a prolapsed cord or delivery of a fetal lower extremity through an undilated cervix. Although combined spinal-epidural or continuous lumbar epidural analgesia can provide ideal conditions, frequent reassessments of the block are required during labor and delivery (Benhamou, 2002).
2. The anesthesiologist must ensure that the woman is able to push adequately during second-stage labor. This means effective analgesia without excessive motor blockade.
3. Adequate perineal anesthesia is provided for delivery of the aftercoming head and for possible Piper forceps placement to the head. A dilute solution of local anesthetic usually has been administered as regional anesthesia during the first stage of labor. Thus, it is often necessary to administer a more concentrated solution of anesthetic such as 3-percent 2-chloroprocaine or 2-percent lidocaine at delivery. Although epidural analgesia does not relax the cervix at delivery, it provides

effective pain relief and skeletal muscle relaxation. A relaxed pelvic floor and perineum aids placement of forceps and delivery of the aftercoming head. Of greatest concern is the risk of fetal head entrapment. To relieve this, epidural anesthesia offers suitable relaxation and patient comfort for needed manipulations.

4. There must be an ability to provide anesthesia for an emergency cesarean delivery at any time during management of a breech delivery. This includes emergency administration of general anesthesia if neuraxial analgesia is insufficient for delivery. Thus, delivery should take place in an OR, and a nonparticulate antacid is given at the time of transfer to that room.
5. To satisfy these goals, at the time of delivery, an agent that provides uterine relaxation should be immediately available. Intravenous nitroglycerin boluses have the advantage of acting rapidly, lasting briefly, and creating minimal side effects (Caponas, 2001). Administration of nitroglycerin helps mediate smooth muscle relaxation. Although well-designed clinical trials are lacking, nitroglycerin appears safe for both the mother and fetus/neonate. Reports describe intravenous doses ranging from 50 to 1500 μg . Both the sublingual and intravenous routes provide rapid onset of uterine relaxation, and the effect lasts only minutes. The parturient should be warned about acute onset of headache, and hypotension is treated with a pressor such as phenylephrine.
6. Of other agents, terbutaline provides excellent uterine relaxation but has numerous maternal side effects. It also has a longer duration of action, which may lead to uterine atony after delivery (Kulier, 2000). General anesthesia using a high concentration of an inhaled agent can provide good uterine relaxation. Of disadvantages, it requires emergency airway management with tracheal intubation and may be associated with postpartum hemorrhage.
7. Newborns delivered from a breech presentation tend to be more depressed than those with a vertex presentation. Accordingly, an individual skilled in neonatal resuscitation should be immediately available.

■ External Cephalic Version

Manually turning a malpositioned fetus to a vertex position is described in Chapter 21 (p. 348). External cephalic version of a breech presentation may be assisted by neuraxial anesthesia, namely, spinal or epidural, to decrease procedural pain (American College of Obstetricians and Gynecologists, 2016; Lavoie, 2010). Using combined spinal-epidural or epidural analgesia for the version procedure also has the advantage of providing an epidural catheter for later use. It can be employed in the event of a cesarean delivery if the version is unsuccessful or for labor analgesia if the version is successful.

■ Vaginal Twin Delivery

Twin pregnancies induce exaggerated physiologic changes of pregnancy and rapidly evolving conditions during delivery. Risk of uterine atony and postpartum hemorrhage is increased, and adequate intravenous access is essential. If the first twin (twin A) is in a position other than vertex, a cesarean delivery is most often planned. If twin A is vertex, however, a trial of

labor and vaginal delivery are appropriate in many cases. But even a successful vaginal delivery of twin A may be followed by the need for intrauterine manipulation, breech extraction, or emergency cesarean delivery for the second twin (twin B) (Barrett, 2013). Therefore, the anesthesia plan must be flexible to accommodate any of these needs.

Analgesia or anesthesia for labor, version or breech extraction, or cesarean delivery can be accomplished with continuous combined spinal-epidural or epidural anesthesia. That said, the local anesthetic choice and concentration will vary depending on circumstances. For example, labor analgesia might require only 0.125-percent bupivacaine, whereas intrauterine manipulations or operative vaginal delivery may require a denser sensory block with 0.5-percent bupivacaine or 1.5-percent lidocaine. Last, cesarean delivery may demand a surgical block using 2-percent lidocaine or 3-percent 2-chloroprocaine.

To rapidly respond to these changing conditions, the anesthesiologist must be present in the delivery suite. The epidural catheter should be tested and functioning well. All monitors are in place in case urgent cesarean delivery is needed. Aspiration prophylaxis ideally is given en route to the OR or before. A uterine relaxant such as nitroglycerin should be immediately available (Caponas, 2001). During delivery, it is imperative that the obstetrician and anesthesiologist have ongoing communication. Finally, individuals skilled in neonatal resuscitation should be immediately available.

ANESTHESIA FOR CESAREAN DELIVERY

Four types of anesthesia are used for cesarean delivery: general endotracheal, epidural, spinal, and combined spinal-epidural. As stated in the American Society of Anesthesiologists Practice Guidelines (2016): “The decision to use a particular anesthetic technique for cesarean delivery should be individualized, based on several factors. These include anesthetic, obstetric, or fetal risk factors, for example, elective versus emergency, the preferences of the patient, and the judgment of the anesthesiologist. Neuraxial techniques are preferable to general anesthesia for most cesarean deliveries. An indwelling epidural catheter may provide equivalent onset of anesthesia compared with initiation of spinal anesthesia for urgent cesarean delivery. General anesthesia may be the most appropriate choice in some circumstances, for example, profound fetal bradycardia, ruptured uterus, substantial hemorrhage, or placental abruption.”

In the United States, regional anesthesia is strongly preferred to general anesthesia for cesarean delivery (Traynor, 2016). General anesthesia is used for approximately 5 percent of elective and 15 percent of emergent cesarean births. Spinal, epidural, or combined spinal-epidural anesthetics are used for approximately 90 percent of cesarean deliveries. Local anesthesia for cesarean delivery is possible but is rarely used or taught in modern practice.

Evidence suggests that the relative risk for maternal death is probably the same whether neuraxial or general anesthesia is used (Hawkins, 2011). High neuraxial block is the leading cause of major anesthetic complications, although problems with the airway—including aspiration—are still a significant concern (D’Angelo, 2014). Neuraxial anesthesia may have

benefits for the mother, but neuraxial or general anesthesia results in similar fetal outcomes as ascertained by Apgar scores and blood gas measurements.

Premedication using a sedative or opioid agent is usually omitted because of the risk of newborn depression. To decrease aspiration risk in cases of unplanned cesarean delivery, oral intake during labor should be limited to modest amounts of clear liquids or ice chips. Use of a clear nonparticulate antacid is considered routine for all parturients prior to surgery. Additional aspiration prophylaxis using an H₂-receptor blocking agent and metoclopramide may be given to parturients with risk factors such as morbid obesity, diabetes mellitus, a difficult airway, or having previously received opioids. Chalky-white particulate antacids are avoided because they can produce lung damage if aspirated (Eyler, 1982).

As during labor, the uterus may compress the inferior vena cava and the aorta during cesarean delivery. Compression leads to reduced venous return to the heart, reduced cardiac output, and reduced uteroplacental perfusion. The duration of anesthesia has little effect on neonatal acid-base status when uterine displacement is practiced. However, when the woman remains supine, Apgar scores decline over time.

■ General Anesthesia for Emergent Cesarean Delivery

General anesthesia for cesarean delivery offers several advantages. A woman can be anesthetized quickly for an emergent delivery, and agents provide total pain relief. Moreover, she can be asleep during a major operation, operating conditions are optimal, and 100-percent oxygen can be supplied if needed. Disadvantageously, although the patient will not be awake during the delivery, there is a small risk of undesirable awareness. A recent British audit of awareness during general anesthesia found that obstetric anesthesia was the most overrepresented of all surgical specialties (Pandit, 2014). Other disadvantages are the risk of transient neonatal depression immediately after birth because many anesthetics cross the placenta. For the mother, intubation may cause hypertension and tachycardia, can sometimes be difficult or impossible, and may lead to aspiration of stomach contents.

To provide a general anesthetic, the anesthesiologist administers a short-acting induction agent to render the woman unconscious. Induction agents include *propofol*, *etomidate*, and *ketamine*, all of which are rapidly redistributed in the mother and fetus. Although obstetricians are often concerned about the induction-to-delivery interval during general anesthesia, uterine incision-to-delivery interval is more predictive of neonatal status. With a prolonged induction-to-delivery interval, there is fetal uptake of the inhaled anesthetic and depressed Apgar scores. However, fetal acid-base status is usually normal, and effective ventilation is sufficient for resuscitation.

Immediately after an induction agent is administered, a muscle relaxant is given to aid intubation. *Succinylcholine*, a rapid-onset, short-acting muscle relaxant, is the preferred agent in most cases. As the patient becomes unconscious, pressure on the cricoid cartilage compresses the esophagus to prevent regurgitation and aspiration. To accomplish this, an assistant applies pressure to the cricoid cartilage, just below the thyroid cartilage.

Pressure is not released until an endotracheal tube is placed, the cuff inflated, and its position verified by end-tidal carbon dioxide measurement and auscultation of bilateral breath sounds.

In most cases, intubation proceeds smoothly. However, in approximately 1 in 500 obstetric patients, it is difficult, delayed, or impossible (D'Angelo, 2014). The critical factor is delivering oxygen to the now unconscious and paralyzed patient. The anesthesiologist uses an algorithm for managing the difficult airway, and this algorithm should be practiced as a drill in the labor and delivery unit so that other team members know how to assist (Mhyre, 2011). The patient at risk for a difficult or impossible intubation can often be identified before surgery. Examination of the airway is a critical part of such preanesthetic evaluation. The anesthesiologist will assess (1) the ability to visualize oropharyngeal structures—Mallampati classification; (2) range of neck motion; (3) presence of a receding mandible; and (4) whether protruding maxillary incisors are present. The Mallampati classification is shown in Figure 18-1 (p. 294). Importantly, a woman's airway status can worsen during labor. One study found significant increases in the Mallampati score and the incidence of difficult airways when prelabor and postlabor airway examinations were compared (Kodali, 2008).

When airway abnormalities are recognized or suspected, patients are ideally referred for an early preoperative evaluation by the anesthesiologist. Some examples include obesity; severe edema; anatomic abnormalities of the face, neck, or spine; prior trauma or surgery; abnormal dentition; difficulty opening the mouth; extremely short stature; short neck; neck arthritis; or goiter.

After intubation, nitrous oxide and a low concentration of a volatile halogenated agent is added to provide maternal amnesia and additional analgesia. Volatile agents include isoflurane, sevoflurane, or desflurane. Uterine relaxation does not result from low concentrations of these agents, and bleeding should not be increased secondary to their use. Notably, proceeding without a potent inhalation agent results in an unacceptably high incidence of maternal awareness and recall. Even with the use of one of these agents, maternal awareness and recall occasionally occur. Therefore, all OR personnel should use discretion in their conversations.

In the OR but after delivery, anesthesia is supplemented with an opioid such as fentanyl or morphine. Other intravenous agents such as benzodiazepines may be added to ensure maternal amnesia. Dilute oxytocin is infused intravenously to improve uterine tone. However, bolus injections of oxytocin are avoided because this practice can drop systemic vascular resistance to incite hypotension and tachycardia (Stephens, 2012). To prevent aspiration, the patient must be awake and conscious at the end of the case before extubation. The endotracheal tube is not removed until the patient can respond appropriately to commands.

■ Neuraxial Anesthesia for Cesarean Delivery

As long as fetal status permits and no maternal contraindications are present, regional anesthesia is favored for cesarean delivery (Traynor, 2016). That said, some women prefer not to be awake during this major surgical procedure and will choose general anesthesia. For others, neuraxial anesthesia permits a patient to participate in the birth of her child, and the father is more likely to be allowed in the OR. Greater alertness and

pain control after neuraxial anesthesia also assist initial bonding and breastfeeding. Importantly, intubation difficulties are also avoided, and the risks of maternal aspiration or neonatal drug depression are minimal. A working epidural catheter used for labor analgesia can provide an excellent anesthetic for cesarean delivery without the need to initiate another technique. Postoperative pain control using neuraxial opioids may be superior to intravenous patient-controlled analgesia.

Some drawbacks of a neuraxial anesthetic include inadequate anesthesia; hypotension, which is recognized in 25 to 85 percent of cases; high neuraxial blockade, which necessitates greater airway management; and local anesthetic toxicity. Although rare, permanent neurologic sequelae may result. Nerve injury is the most common reason for obstetric anesthesia liability claims (Davies, 2009).

Most women prefer some type of neuraxial anesthesia for the reasons mentioned. Situations that contraindicate neuraxial anesthesia include patient refusal, hemodynamic instability due to hemorrhage or sepsis, clinical coagulopathy, or infection at the injection site. Technical difficulties may arise from spinal instrumentation placed during prior scoliosis repair.

The choice of neuraxial versus general anesthesia must be made quickly in the setting of an emergent cesarean delivery. The obstetrician and anesthesiologist must communicate their concerns to each other. For example, the obstetrician may feel that time is insufficient to initiate spinal or extend epidural anesthesia, while the anesthesiologist may feel the potential for airway difficulties is significant. In these situations, maternal safety must always come first.

The choice of single-shot spinal, combined spinal-epidural, or epidural anesthesia is often provider-dependent. However, unless a well-functioning epidural catheter is already in place, a spinal anesthetic may be faster and easier to initiate (Fig. 19-2). Although time-limited, a spinal anesthetic with bupivacaine will provide at least 2 hours of surgical anesthesia. If longer surgical duration is anticipated, a combined spinal-epidural technique can be used to achieve the benefits of both techniques. Since the advent of small-gauge spinal needles with pencil-point tip design, the risk of headache is no different after spinal or epidural anesthesia. Most consider spinal block to be easier and quicker to perform, and most believe that the resulting anesthesia will be more solid and complete. Perhaps the most significant advantage of spinal anesthesia is that it requires considerably less local anesthetic. Therefore, the potential for local anesthetic toxicity is reduced. The combined technique provides the benefits of spinal anesthesia to initiate the block plus the ability to prolong the anesthetic if needed by dosing the epidural catheter. Any of these techniques is satisfactory, however, and should provide safe, effective anesthesia for mother and newborn.

■ Postoperative Care

Pain management is an important part of anesthesia care. In addition to comfort, maternal mobility is improved to lower thromboembolism risks and hasten bowel function return. If spinal or epidural anesthesia was used for cesarean delivery, excellent postoperative analgesia can be obtained by addition of preservative-free morphine to the local anesthetic solution.

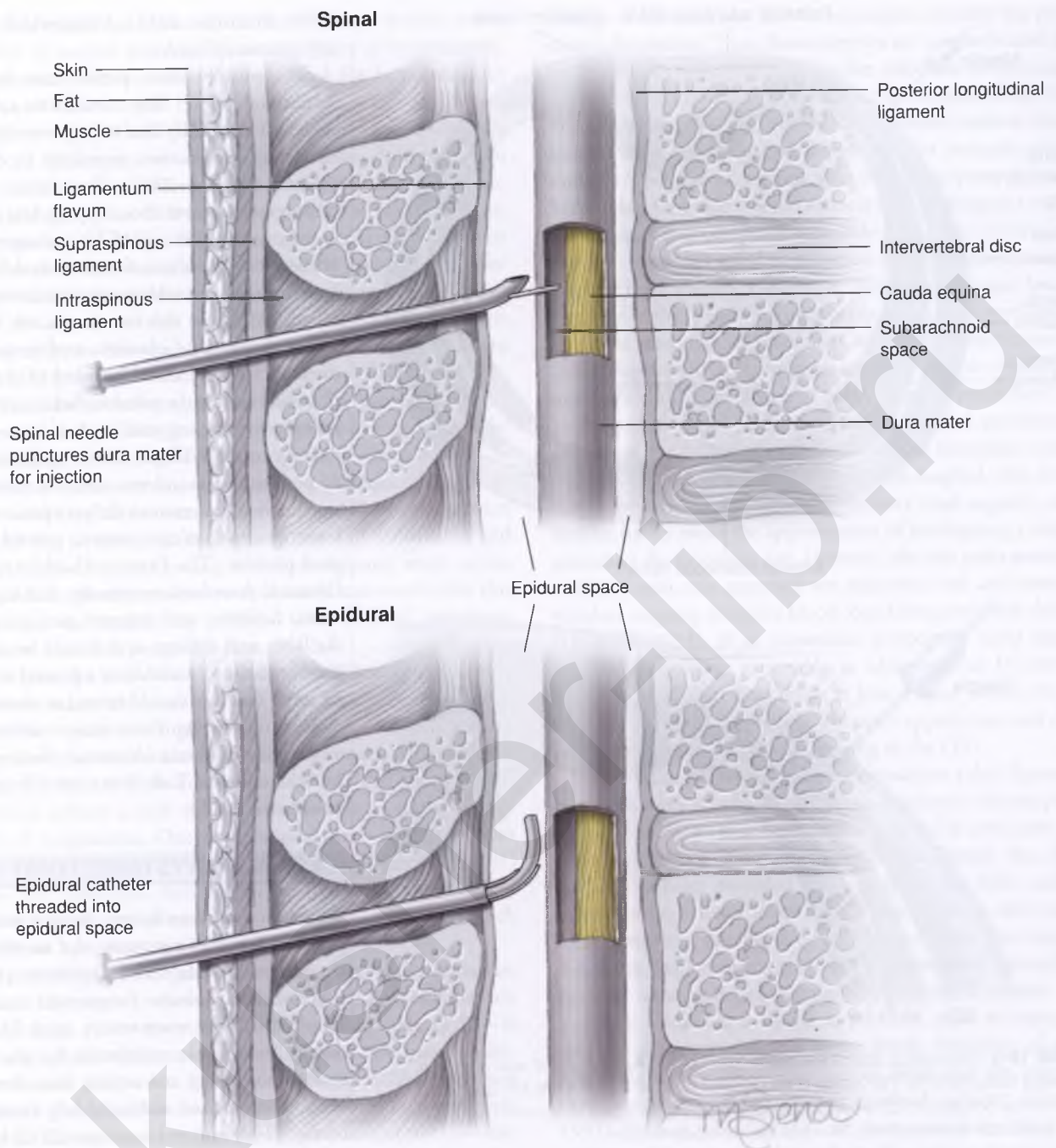


FIGURE 19-2 Neuraxial anatomy for placement of combined spinal-epidural anesthesia.

Morphine acts up to 24 hours, but its water solubility gives it a long onset time and higher incidence of side effects. The most common side effects of spinal and epidural opioids are itching and nausea. Respiratory depression is a rare but serious complication (Crowgey, 2013). Several studies have shown that spinal or epidural opioids provide superior pain relief compared with parenteral opioids—either intramuscular or intravenous patient-controlled analgesia. Moreover, a trend toward earlier hospital discharge and lower cost is seen with spinal or epidural opioids.

If general anesthesia was used or neuraxial opioids provide inadequate pain control, a transversus abdominis plane (TAP) block may be placed (Fig. 19-3). A TAP block is an effective field block that can be administered intraoperatively

by the obstetrician or postoperatively by the anesthesiologist (Sharkey, 2013). Although these blocks provide less effective analgesia than neuraxial morphine, a TAP block results in less itching and nausea (Kanazi, 2010). Unfortunately, because of the large volume of local anesthetic required for bilateral blockade, seizures due to local anesthetic toxicity have been reported. This is despite use of sonographic guidance during placement (D'Angelo, 2014).

When used with neuraxial morphine, the addition of non-steroidal antiinflammatory agents significantly improves pain scores and reduces use of patient-controlled opioids (White, 2012). Intravenous ketorolac, rectal indomethacin, oral ibuprofen, or intravenous or oral acetaminophen can be used as

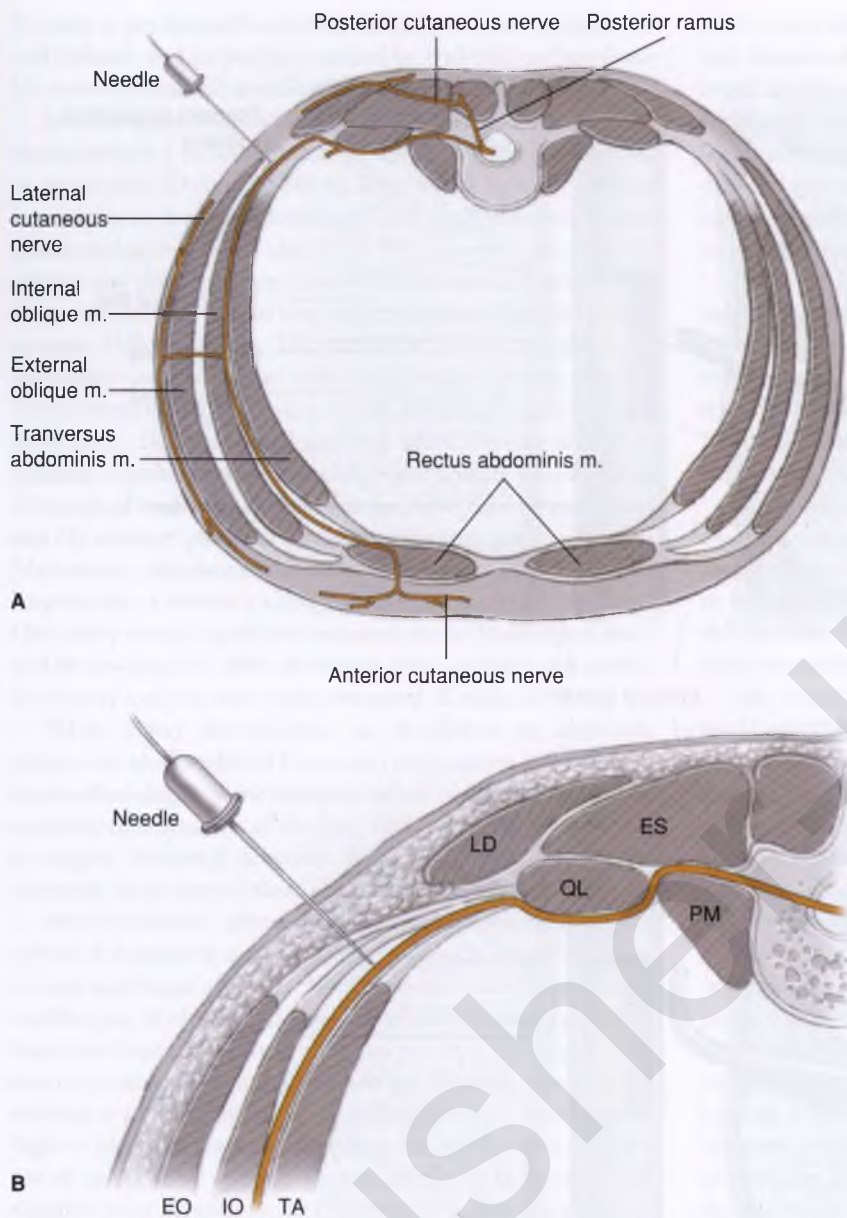


FIGURE 19-3 Transversus abdominis plane (TAP) block. **A.** Abdominal wall anatomy. **B.** Needle placement for TAP block. EO = external oblique m.; ES = erector spinae m.; IO = internal oblique m.; LD = latissimus dorsi m.; m. = muscle; PM = psoas major m.; QL = quadratus lumborum m.; TA = transversus abdominis m.

part of a multimodal regimen. Contraindications to nonsteroidal antiinflammatory agents include renal insufficiency or low urine output, use of gentamicin or other drugs with renal toxicity, thrombocytopenia or other coagulopathy, and uterine atony. Although the package insert for ketorolac states that it is contraindicated for use in breastfeeding mothers, the American Academy of Pediatrics approves its use while women are breastfeeding.

Women who have undergone cesarean delivery may develop postoperative nausea and vomiting. Some risk factors include young age and women who are nonsmokers and who are given opioids. Prevention and treatment of postoperative nausea and vomiting may include metoclopramide, ondansetron, dexamethasone, and a scopolamine patch (Allen, 2012; Harnett,

2007; Mishriky, 2012). Multimodal therapy is most effective.

The postoperative period can be an important time for anesthetic-related maternal morbidity due to hypoventilation or airway obstruction, especially in obese patients (Mhyre, 2007). These cases raise important questions about appropriate postanesthesia care unit (PACU) management after general anesthesia for cesarean delivery and the need for additional monitoring in obese patients at risk for obstructive sleep apnea. A survey of obstetric anesthesiology directors reported that 45 percent of institutions had no specific postanesthesia recovery training for nursing staff in their labor and delivery units (Wilkins, 2009). In addition, 43 percent of respondents rated the recovery care provided to cesarean delivery patients as lower quality than care given to general surgical patients. The Practice Guidelines for Obstetric Anesthesia emphasize that equipment, facilities, and support personnel in the labor and delivery unit should be comparable to those available in a general surgical unit. This care should extend to obstetric patients recovering from major neuraxial or general anesthesia (American Society of Anesthesiologists Task Force on Obstetric Anesthesia, 2016).

CESAREAN HYSTERECTOMY

Whenever a cesarean hysterectomy is anticipated or becomes necessary, the anesthesiologist should adapt the anesthetic plan. Additional large-bore intravenous access is obtained, fluid warmers are used, blood should be available, equipment for placing central monitoring and arterial lines should be in the room, and additional help must be nearby. El-Messidi and associates (2012) have summarized a checklist with all aspects of delivery care including site, resources, person-

nel, and surgical approach. For anticipated cesarean hysterectomy, small hospitals with insufficient blood bank supply or inadequate availability of subspecialty and support personnel should consider antepartum patient transfer to a tertiary perinatal care center.

Although regional anesthesia is not contraindicated, hysterectomy and massive transfusion usually require general endotracheal anesthesia (Parekh, 2000). If a woman is highly motivated to be awake to see her newborn, the case can be started using a neuraxial technique. This is followed by general anesthesia that is induced after delivery (Clark, 2013).

With severe hemorrhage and implementation of a massive transfusion protocol, additional management may include cell salvage and interventional radiology procedures. Massive transfusion protocols are considered in detail in Chapter 7

(p. 98). Peripartum resuscitation should always include maintenance of normal acid-base status, avoidance of hypothermia, and resuscitation measures similarly used for hemorrhage in trauma or other surgical cases (Main, 2015).

Use of red blood cell (RBC) salvage during cesarean delivery has been limited due to concern for amniotic-fluid embolism and for alloimmunization due to fetal RBC contamination. That said, more than 400 case reports of cell salvage in parturients have been reported. With these, no cases of embolism were attributed to infusion of salvaged blood. If banked blood cannot be adequately crossmatched because of atypical antibodies or if the woman refuses transfusion, cell salvage can be life-saving and cost-effective, and it may have fewer complications than banked blood (Goucher, 2015).

Placement of balloon catheters into the iliac vessels by an interventional radiologist either preoperatively or when life-threatening hemorrhage develops may also be considered. The technique seems to be less effective in the presence of coagulopathy or during acute massive hemorrhage. Catheter insertion should not replace ongoing resuscitation and transfusion and should not delay proceeding with hysterectomy when necessary. Although rare, serious complications can result with this technique and include leg ischemia, tissue necrosis, pseudoaneurysms, and even paraplegia (Lee, 2012a).

Despite the lack of randomized controlled trials in obstetric patients, many labor and delivery units have adopted massive transfusion protocols similar to those used for military trauma cases and other traumatic injury. These protocols focus on early administration of fresh frozen plasma (FFP) and platelets with RBCs to achieve a ratio of 1:1:1 without waiting for laboratory tests of coagulation. One observational study of 142 women with postpartum hemorrhage reported that a higher FFP:RBC ratio was associated with a lower requirement for advanced interventional procedures such as embolization, B-Lynch suture, or hysterectomy (Pasquier, 2013).

Laboratory studies are an integral part of resuscitation. Plasma fibrinogen levels may be particularly helpful in obstetric hemorrhage. A low fibrinogen level—less than 200 mg/dL—in the early phase of obstetric hemorrhage is an important predictor of severe postpartum hemorrhage (Butwick, 2013). Because obstetric complications may be associated with increased fibrinolytic activity, some recommend thromboelastometry—also known as thromboelastography (TEG) or rotational thromboelastometry (ROTEM), which are described and illustrated in Chapter 7 (p. 98) (deLange, 2014). These tests give a global picture of real-time clotting activity and can be used to guide component therapy. However, they have not been well studied with obstetric hemorrhage (Cunningham, 2015). Pharmacologic therapy for obstetric hemorrhage may include recombinant factor VIIa and antifibrinolytic agents such as tranexamic acid (Pavord, 2015). These agents are used with caution in postpartum patients because of the risk of thrombotic events.

ANESTHESIA FOR POSTPARTUM TUBAL LIGATION

The timing of postpartum tubal ligation has been controversial. Both the American Society of Anesthesiologists and the American

College of Obstetricians and Gynecologists consider the procedure to be elective. Thus, these surgeries are not performed during times that might compromise other aspects of patient care in a labor and delivery unit. As discussed in Chapter 33 (p. 524), this policy may decrease access to this valuable method of contraception for many puerperal patients. For example, in one study, 47 percent of women who requested puerperal tubal ligation but were not able to receive it became pregnant the following year. This compared with only 22 percent of those who had not requested tubal sterilization and who chose another form of birth control (Thurman, 2010). No woman became pregnant in the group who underwent postpartum sterilization. For these reasons, the American College of Obstetricians and Gynecologists (2014) encourages improved access to puerperal sterilization and considers it to be an “urgent” procedure.

Postpartum tubal ligation may be completed proximate to delivery or the following day. Advantages to immediate surgery include cost savings from 1 less day in the hospital. This timing also allows her to eat shortly after delivery (and surgery), and it enables her to avoid the apprehension of undergoing a surgical procedure the following day. However, the two main anesthetic concerns with this approach are aspiration risk and unrecognized or ongoing excessive blood loss during and after delivery (Hawkins, 2014). If an immediate postpartum tubal ligation is planned, it seems reasonable to administer an H₂-receptor antagonist and metoclopramide at least 1 hour before the procedure, use regional anesthesia whenever appropriate, and check orthostatic vital signs prior to moving to the OR.

The choice of anesthesia for postpartum tubal ligation is based primarily on patient preference. Epidural catheters placed for labor analgesia may be more likely to fail if used more than 8 hours after delivery (Goodman, 1998). Despite this, if the epidural catheter provided good analgesia for labor and the interval since delivery is less than 8 hours, then a short-acting local anesthetic suitable for surgical anesthesia, for example, 3-percent 2-chloroprocaine, may be administered through the epidural catheter. Sedative drugs may be given if needed.

Spinal anesthesia is simple to perform, rapid in onset, and provides dense sensory and motor block. Initiation of spinal anesthesia for the procedure may be faster and less expensive than reactivation of an existing epidural catheter (Viscomi, 1995). Because tubal ligations are short procedures, there is no reason to initiate epidural anesthesia if a catheter is not already in place. A sensory level of T4 is needed with spinal or epidural anesthesia to block visceral pain during exposure and manipulation of the fallopian tubes. Local anesthetic requirements for spinal and epidural anesthesia are decreased during pregnancy, but studies have demonstrated a return to nonpregnant requirements by 36 hours postpartum. The reason for the rapid decrease in sensitivity to local anesthetics is unclear but may be related to the rapid fall in progesterone levels after delivery of the placenta.

If general anesthesia is chosen for puerperal sterilization, a rapid-sequence induction with cricoid pressure and intubation should be used in all postpartum patients. Propofol has some advantages as an induction agent. Its association with rapid awakening and decreased incidence of emesis makes it attractive for short sterilization procedures. Propofol results in negligible neonatal exposure during subsequent breastfeeding. Volatile

anesthetic agents cause uterine relaxation in high concentrations and could potentially increase the risk for postpartum hemorrhage. Fortunately, the reduced anesthetic requirement for volatile anesthetics observed during pregnancy persists for 12 to 36 hours postpartum. This allows lower concentrations to be used.

FETAL SURGERY

Fetal surgical procedures are performed at only a few centers and for limited indications (Lin, 2013). These are discussed in greater detail in Chapter 16 (p. 260). Minimally invasive fetoscopic interventions for conditions such as twin-twin transfusion syndrome involve sonographically guided percutaneous placement of trocar(s) or needles through the uterus and into the amniotic cavity. These procedures can be performed with local anesthetic infiltration or neuraxial techniques coupled with sedation.

Open midgestation fetal surgery is performed for selected indications including closure of myelomeningocele and resection of some intrathoracic lesions (Adzick, 2011). Preterm delivery is the most significant perioperative problem, requiring multiple tocolytics. During surgery, high doses of inhalation agents are used for maternal and fetal anesthesia and for uterine relaxation (Ferschl, 2013).

Ex utero intrapartum treatment (EXIT) is performed at the time of cesarean delivery to secure the airway in fetuses with large oropharyngeal, neck, or thoracic masses. The goal of EXIT is to achieve prolonged uterine relaxation and thereby preserve the uteroplacental circulation until delivery. These fetal procedures are most commonly performed under maternal general anesthesia using high doses of volatile anesthetics such as desflurane to maintain uterine relaxation (Garcia, 2011). With EXIT, the fetal head is delivered. One arm of the fetus is also brought out through the hysterotomy to allow pulse-oximetry monitoring. At this point, the indicated procedure such as endoscopy or a tracheostomy is performed to achieve neonatal endotracheal intubation. After the airway is secured, the inhalational agent is decreased to allow uterine tone to return to normal. Delivery then proceeds as with a normal cesarean delivery. Additional uterotonic drugs should be readily available.

SUMMARY

Anesthetic management of gravidas should be adapted to the physiologic changes of pregnancy. Another key to successfully performed procedures is active communication between the anesthesiologist and the surgeon. Pregnancy and delivery are both exciting and highly emotional times for a woman. Accordingly, anesthesia providers must be cognizant of their patients' concerns and should feel privileged to be a part of their care.

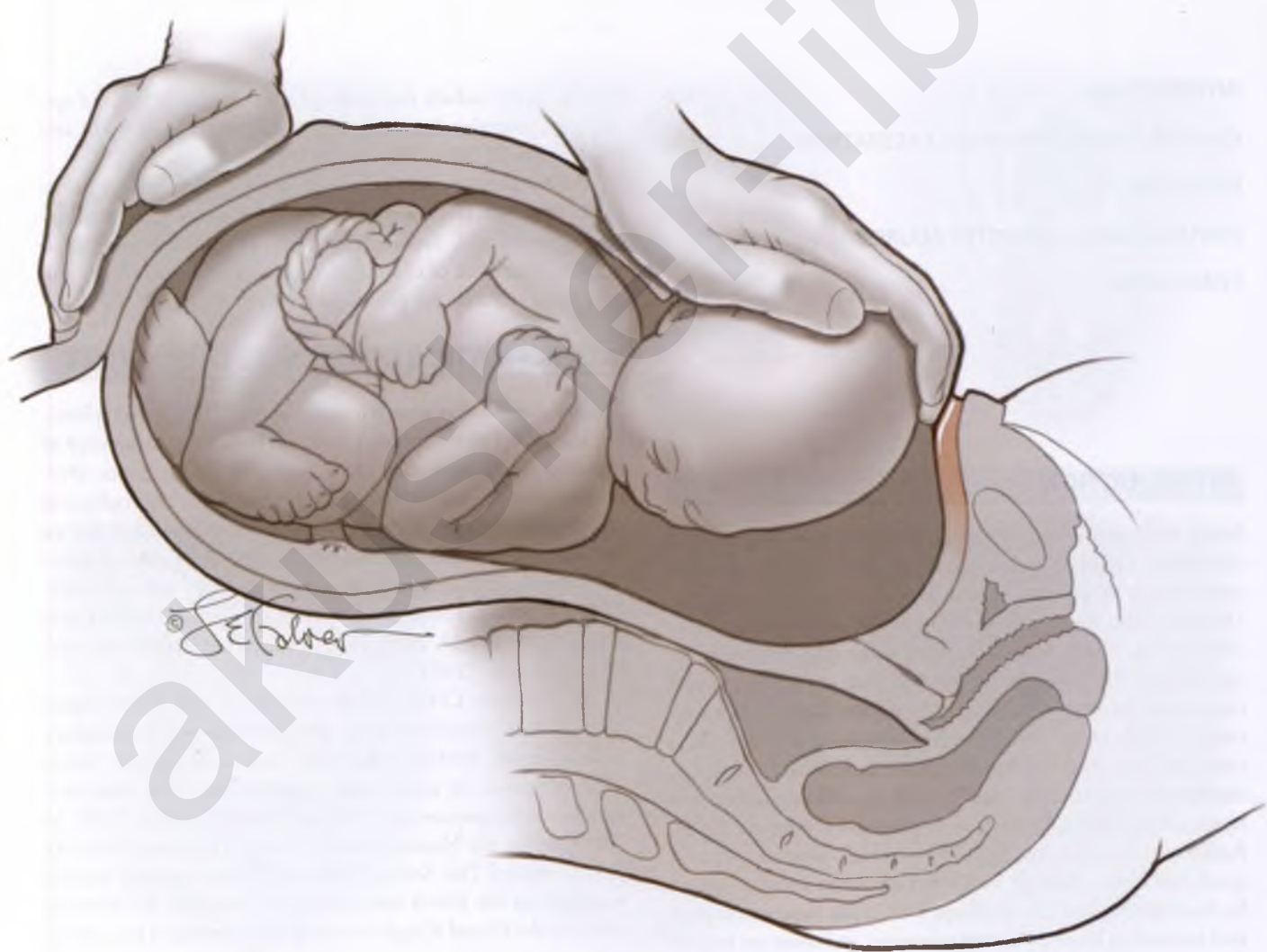
REFERENCES

Adzick NS, Thom EA, Spong CY, et al: A randomized trial of prenatal versus postnatal repair of myelomeningocele. *N Engl J Med* 364:993, 2011
 Allen TK, Jones CA, Habib AS: Dexamethasone for the prophylaxis of postoperative nausea and vomiting associated with neuraxial morphine administration: a systematic review and meta-analysis. *Anesth Analg* 114:813, 2012

American College of Obstetricians and Gynecologists: Access to postpartum sterilization. Committee Opinion No. 530, *Obstet Gynecol* 120:212, July 2012, Reaffirmed 2014
 American College of Obstetricians and Gynecologists: External cephalic version. Practice Bulletin No. 161, February 2016
 American Society of Anesthesiologists Task Force on Obstetric Anesthesia. Practice Guidelines for Obstetric Anesthesia: An updated report by the American Society of Anesthesiologists Task Force on Obstetric Anesthesia and the Society for Obstetric Anesthesia and Perinatology. *Anesthesiology* 124(2):270, 2016
 Barbieri RL, Camann W, McGovern C: Nitrous oxide for labor pain (Editorial). *OBG Manag* 26:10, 2014
 Barrett JFR, Hannah ME, Hutton EK: A randomized trial of planned cesarean or vaginal delivery for twin pregnancy. *N Engl J Med* 369:1295, 2013
 Benhamou D, Mercier FJ, Ben Ayed M, et al: Continuous epidural analgesia with bupivacaine 0.125% or bupivacaine 0.0625% plus sufentanil 0.25 microg/mL: a study in singleton breech presentation. *Int J Obstet Anesth* 11:13, 2002
 Butwick AJ: Postpartum hemorrhage and low fibrinogen levels: the past, present and future. *Int J Obstet Anesth* 22:87, 2013
 Caponas G: Glyceryl trinitrate and acute uterine relaxation: a literature review. *Anesth Intensive Care* 29:163, 2001
 Clark A, Farber MK, Sviggum H, et al: Cesarean delivery in the hybrid operating suite: a promising new location for high-risk obstetric procedures. *Anesth Analg* 117:1187, 2013
 Creanga AA, Berg CJ, Syverson C, et al: Pregnancy-related mortality in the United States, 2006–2010. *Obstet Gynecol* 125:5, 2015
 Crowe TR, Dominguez JE, Peterson-Layne C, et al: A retrospective assessment of the incidence of respiratory depression after neuraxial morphine administration for postcesarean delivery analgesia. *Anesth Analg* 117:1368, 2013
 Cunningham FG, Nelson DB: Disseminated intravascular coagulation syndromes in obstetrics. *Obstet Gynecol* 126(5):99, 2015
 D'Angelo R, Smiley RM, Riley ET, et al: Serious complications related to obstetric anesthesia. *Anesthesiology* 120:1505, 2014
 Davies JM, Posner KL, Lee LA: Liability associated with obstetric anesthesia: a closed claims analysis. *Anesthesiology* 110:131, 2009
 deLange NM, van Rheenen-Flach LE, Lance MD, et al: Peri-partum reference ranges for ROTEM thromboelastometry. *Br J Anaesth* 112:852, 2014
 Dorian R: Anesthesia of the surgical patient. Brunicaudi F, Andersen D, Billiar T, et al (eds): *Schwartz's Principles of Surgery*, 10th ed. New York, McGraw-Hill, 2015
 El-Messidi A, Mallozzi A, Oppenheimer L: A multidisciplinary checklist for management of suspected placenta accreta. *J Obstet Gynaecol Can* 34:320, 2012
 Eyster SW, Cullen BF, Murphy ME, et al: Antacid aspiration in rabbits: a comparison of Mylanta and bicitra. *Anesth Analg* 61:288, 1982
 Ferschl M, Ball R, Lee H, et al: Anesthesia for in utero repair of myelomeningocele. *Anesthesiology* 118:1211, 2013
 Gaizer R: Physiologic changes of pregnancy. In Chestnut DH, Wong CA, Tsen LC, et al (eds): *Chestnut's Obstetric Anesthesia Principles and Practice*, 5th ed. Philadelphia, Elsevier, 2014, p 15
 Garcia PJ, Olutayo OO, Ivey RT, et al: Case scenario: anesthesia for maternal-fetal surgery. The ex-utero intrapartum therapy (EXIT) procedure. *Anesthesiology* 114:1446, 2011
 Goodman EJ, Dumas SD: The rate of successful reactivation of labor epidural catheters for postpartum tubal ligation surgery. *Reg Anesth Pain Med* 23:258, 1998
 Goucher H, Wong CA, Patel SK, Toledo P: Cell salvage in obstetrics. *Anesth Analg* 121:465, 2015
 Harnett MJP, O'Rourke N, Walsh M, et al: Transdermal scopolamine for prevention of intrathecal morphine-induced nausea and vomiting after cesarean delivery. *Anesth Analg* 105:764, 2007
 Hawkins JL: Postpartum tubal sterilization. In Chestnut DH, Wong CA, Tsen LC, et al (eds): *Chestnut's Obstetric Anesthesia Principles and Practice*, 5th ed. Philadelphia, Elsevier, 2014, p 530
 Hawkins JL, Chang J, Palmer SK, et al: Anesthesia-related maternal mortality in the United States: 1979–2002. *Obstet Gynecol* 117:69, 2011
 Joselyn AS, Cherian VT, Joel S: Ketamine for labour analgesia. *Int J Obstet Anesth* 19:122, 2010
 Kanazi GE, Aouad MT, Abdallah FW, et al: The analgesic efficacy of subarachnoid morphine in comparison with ultrasound-guided transversus abdominis plane block after cesarean delivery: a randomized controlled trial. *Anesth Analg* 111:475, 2010
 Knight M, Kenyon S, Brocklehurst P, et al (eds): *Saving Lives, Improving Mothers' Care—Lessons Learned to Inform Future Maternity Care from the UK and Ireland Confidential Enquiries into Maternal Deaths and Morbidity 2009–12*. Oxford, National Perinatal Epidemiology Unit, University of Oxford, 2014

- Kodali BS, Chandrasekhar S, Bulich LN: Airway changes during labor and delivery. *Anesthesiology* 108:357, 2008
- Kulier R, Hofmeyr GJ: Tocolytics for suspected intrapartum fetal distress. *Cochrane Database System Rev* 2:000035, 2000
- Lavoie A, Guay J: Anesthetic dose neuraxial blockade increases the success rate of external fetal version: a meta-analysis. *Can J Anaesth* 57:408, 2010
- Lee HY, Shin JH, Kim J, et al: Primary postpartum hemorrhage: outcome of pelvic arterial embolization in 251 patients at a single institution. *Radiology* 264:903, 2012a
- Lee J, Lee J, Ko S: The relationship between serum progesterone concentration and anesthetic and analgesic requirements: a prospective observational study of parturients undergoing cesarean delivery. *Anesth Analg* 119:901, 2014
- Lee SW, Khaw KS, Ngan Kee WD, et al: Haemodynamic effects from aortic-caval compression at different angles of lateral tilt in non-labouring term pregnant women. *Br J Anaesth* 109:950, 2012b
- Likis FE, Andrews JC, Collins MR: Nitrous oxide for the management of labor pain: a systematic review. *Anesth Analg* 118:153, 2014
- Lin EE, Tran KM: Anesthesia for fetal surgery. *Semin Pediatr Surg* 22:50, 2013
- Main EK, Goffman D, Scavone BM, et al: National partnership for maternal safety: consensus bundle on maternal hemorrhage. *Anesth Analg* 121:142, 2015
- Mhyre JM, Healy D: The unanticipated difficult intubation in obstetrics. *Anesth Analg* 112:648, 2011
- Mhyre JM, Riesner MN, Polley LS, et al: A series of anesthesia-related maternal deaths in Michigan, 1985–2003. *Anesthesiology* 106:1096, 2007
- Mishriky BM, Habib AS: Metoclopramide for nausea and vomiting prophylaxis during and after cesarean delivery: a systematic review and meta-analysis. *Br J Anaesth* 108:374, 2012
- National Institute for Occupational Safety and Health: Controlling exposures to nitrous oxide during anesthetic administration. Publication Number 94–100. 1994. Available at: <http://www.cdc.gov/niosh/docs/94-100>. Accessed December 5, 2015
- Pandit JJ, Andrade J, Bogod DG, et al: 5th National Audit Project (NAP5) on accidental awareness during general anaesthesia: summary of main findings and risk factors. *Br J Anaesth* 113:549, 2014
- Parekh N, Husaini WU, Russell IF: Caesarean section for placenta praevia: a retrospective study of anaesthetic management. *Br J Anaesth* 84:725, 2000
- Pasquier P, Gayat E, Rackelboom T, et al: An observational study of the fresh frozen plasma:red blood cell ratio in postpartum hemorrhage. *Anesth Analg* 116:155, 2013
- Pavord S, Maybury H: How I treat postpartum hemorrhage. *Blood* 125:2759, 2015
- Sharkey A, Finnerty O, McDonnell AG: Role of the transversus abdominis plane block after caesarean delivery. *Curr Opin Anesthesiol* 26:268, 2013
- Stephens LC, Bruessel T: Systematic review of oxytocin dosing at delivery. *Anaesth Intensive Care* 40:247, 2012
- Thurman AR, Janecek T: One-year follow-up of women with unfulfilled postpartum sterilization requests. *Obstet Gynecol* 116:1071, 2010
- Traynor AJ, Aragon M, Ghosh D, et al: Obstetric Anesthesia Workforce Survey: a 30-Year update. *Anesth Analg* 122:1939, 2016
- Viscomi CM, Rathmell JP: Labor epidural catheter reactivation or spinal anesthesia for delayed postpartum tubal ligation: a cost comparison. *J Clin Anesth* 7:380, 1995
- White PF, Raeder J, Kehlet H: Ketorolac: its role as part of a multi-modal analgesic regimen. *Anesth Analg* 114:250, 2012
- Wilkins KK, Greenfield ML, Polley LS, et al: A survey of obstetric postanesthesia care unit standards. *Anesth Analg* 108:1869, 2009

SECTION 3
INTRAPARTUM



CHAPTER 20

Episiotomy and Obstetric Anal Sphincter Lacerations

INTRODUCTION	320
CLASSIFICATION OF PERINEAL LACERATIONS	320
EPISIOTOMY	320
OBSTETRIC ANAL SPHINCTER INJURIES	325
CONCLUSION	332

INTRODUCTION

Injury to the perineum during vaginal childbirth affects millions of women. One half to three quarters of parturients undergo some degree of perineal laceration during vaginal childbirth. However, rates vary considerably by locale and provider (Low, 2000; Webb, 2002). Some lacerations occur spontaneously during delivery. Or, an obstetric provider may cut an episiotomy to increase the vaginal outlet size to aid the birth. Either may result in both short- and long-term symptoms and complications. Initially, most women experience at least temporary discomfort or pain after perineal lacerations, and one in five will report long-term issues, such as dyspareunia (Glazener, 1995). Additional complications include physical, psychologic, and social problems, which all may affect a woman's ability to care for her newborn and family (Sleep, 1991). The most severe perineal lacerations involve the anal sphincter, and these are termed *obstetric anal sphincter injuries (OASIs)*. These tears and their consequences are described in detail throughout this chapter.

Preventively, increasing data are available to guide health-care providers and patients in selecting the optimal perineal strategy for each woman's delivery. No single strategy fits all patients, thus clinicians should devote time during antepartum counseling.

Topics ideally include discussion of the risks and benefits of episiotomy, strategies that may minimize spontaneous OASIs, and expectations of pelvic floor function following delivery.

In this chapter, we review current literature and practices for antepartum, intrapartum, and postpartum perineal management. Specifically, data regarding risks and possible benefits of episiotomy, repair of obstetric lacerations, and their short- and long-term sequelae are presented.

CLASSIFICATION OF PERINEAL LACERATION

Studies suggest that obstetricians may misclassify anal sphincter injuries. This is coupled with an increasing awareness of the association between OASIs and anal incontinence (Fernando, 2006; Sultan, 1995). For these reasons, the traditional classification system for perineal lacerations was modified to include more specific information regarding the anal sphincter complex. This updated system now contains internationally accepted nomenclature and is summarized in [Table 20-1](#) and [Figure 20-1](#) (Koelbl, 2009; Royal College of Obstetricians and Gynaecologists, 2007).

By definition, OASIs include only third- and fourth-degree perineal tears. Intuitively, these are associated with significantly more maternal morbidity than first- and second-degree lacerations. Moreover, in recent years, litigation related to long-term maternal consequences of OASIs has increased (Eddy, 1999). In the report by the National Health Service Litigation Authority (2012) entitled *Ten Years of Maternity Claims*, perineal trauma was listed as the fourth most common indication for obstetric claims in the United Kingdom during a 10-year span (Jha, 2015).

EPISIOTOMY

■ Historic Evolution

Episiotomy is commonly performed in obstetrics and is among the most-debated procedures. Episiotomy refers to a surgical

TABLE 20-1. Classification of Obstetric Lacerations

Tear Type	Injury Description
First degree	Injury to perineal skin only
Second degree	Injury to the perineum involving the perineal muscles but not the anal sphincter
Third degree	Injury involves anal sphincter complex
3a	Less than 50% of EAS is torn
3b	More than 50% of EAS is torn
3c	EAS and IAS are torn, but the anorectal epithelium is intact
Fourth degree	EAS, IAS, and anorectal epithelium are torn

EAS = external anal sphincter; IAS = internal anal sphincter.

incision of the perineum usually performed during the second stage of labor to increase the diameter of the pelvic outlet. Episiotomy was thought to prevent perineal lacerations, aid delivery, and reduce the time for neonate delivery.

Sir Fielding Ould (1742), a Dublin midwife, recommended episiotomy to hasten prolonged labor when the external vaginal opening was deemed too narrow. In the United States, the first report of episiotomy was almost 110 years later. Namely, Taliaferro (1852) used a scalpel to cut a 1-inch left mediolateral episiotomy to aid delivery and avoid a rectal tear in a 16-year-old eclamptic patient.

In the 20th century, more women delivered in hospitals, and this was accompanied by an increase in episiotomy rates (Thacker, 1983). DeLee (1920) recommended forceps-assisted vaginal delivery with mediolateral episiotomy for all nulliparas and claimed that episiotomy provided protection for both mother and fetus. He believed episiotomy would preserve the pelvic floor and introitus, prevent uterine prolapse and rupture

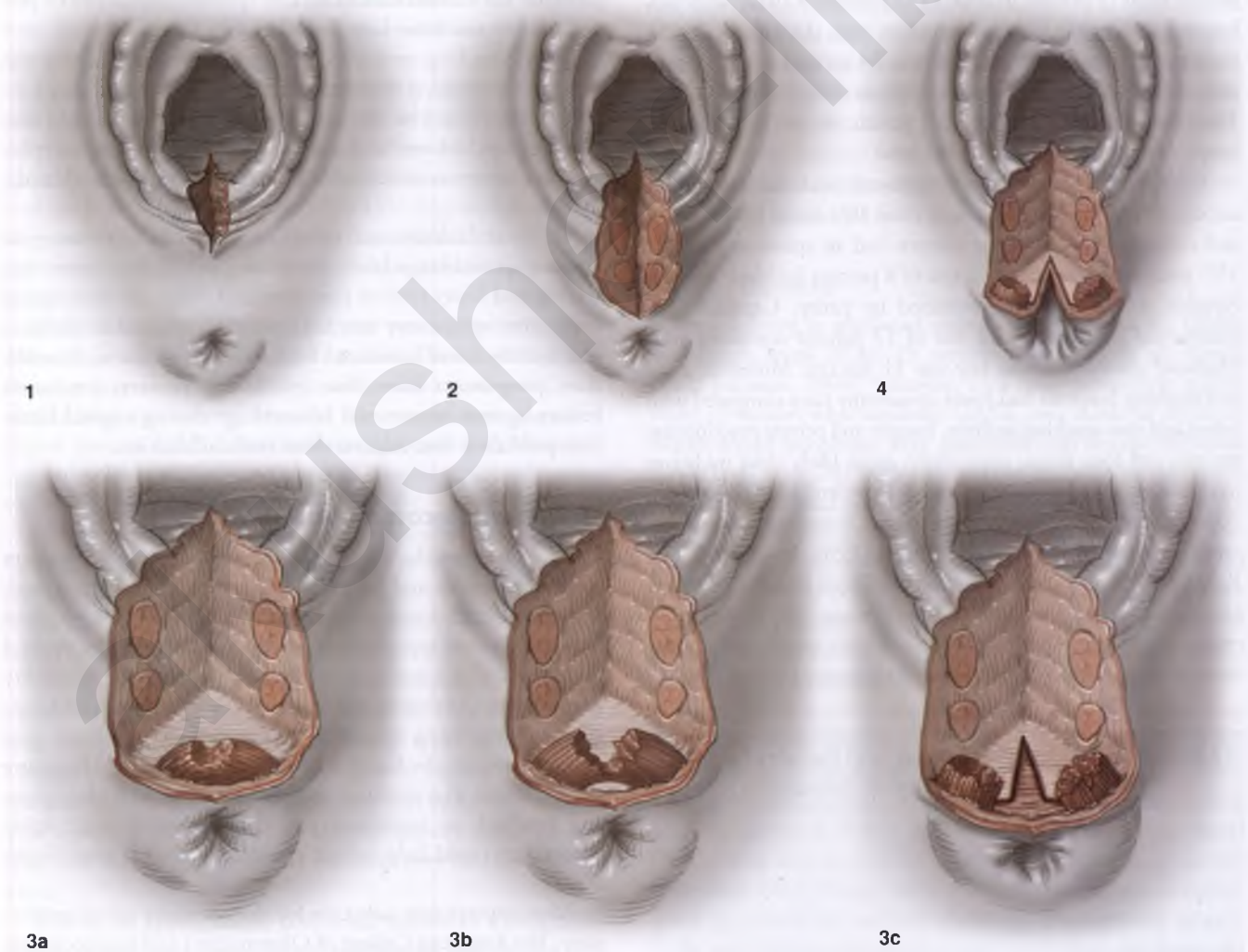

FIGURE 20-1 1. First-degree perineal laceration: injury only to perineal skin. 2. Second-degree perineal laceration: injury to perineum involving the perineal muscles but not to the anal sphincter complex. 3a. Third-degree perineal laceration: less than 50% of the external anal sphincter (EAS) is torn. 3b. Third-degree perineal laceration: more than 50% of the EAS is torn, but the internal anal sphincter remains intact. 3c. Third-degree perineal laceration: external and internal anal sphincters are torn. 4. Fourth-degree perineal laceration: injury to the perineum involves the entire anal sphincter complex and the anorectal epithelium.

of the vesicovaginal septum, and restore virginal conditions. Some also attribute women delivering in lithotomy position to the rise in episiotomy and OASIs during this period. Dorsal lithotomy is thought to place additional stress on the perineal body and lead to tears whether or not an episiotomy is cut (Bromberg, 1986; Thompson, 1987).

In the 1960s, rates of routine episiotomy decreased as opponents questioned its scientific benefits. Investigators argued that widespread use of routine episiotomy did not withstand scientific scrutiny; that episiotomy risks were largely ignored; and that women would likely decline routine episiotomy if adequately informed of the risks and benefits (Kitzinger, 1981; Thacker, 1983).

■ Current Epidemiology

Population-based studies from the United States report that episiotomy rates have declined and were approximately 60 percent in 1979, 31 percent in 1997, and 25 percent in 2004 (Frankman, 2009; Weber, 2002). A recent study of vaginal deliveries in more than 500 hospitals found that episiotomy rates continued to decline from 17 percent in 2006 to 12 percent in 2012. That said, hospital-to-hospital variation remains high (Friedman, 2015). For example, the episiotomy rate was 34 percent in the 10 percent of hospitals in which episiotomy was done most frequently. This compared with a rate of 2.5 percent in the 10 percent of hospitals that used episiotomy the least.

Table 20-2 lists patient, practitioner, and delivery factors associated with higher episiotomy rates. In a study by Friedman and colleagues (2015), white women had an episiotomy rate of 15.7 percent compared with a rate of 8 percent for black women. Notably, factors were not stratified by parity. Gravidas with commercial insurance had a rate of 17 percent compared with Medicaid enrollees, whose rate was 11 percent. Moreover, rural and teaching hospitals had lower episiotomy rates compared with urban and non-teaching facilities. Faculty and private practitioners are two and four times, respectively, more likely than midwives to cut an episiotomy (Gerrits, 1994; Howden, 2004; Robinson, 2000). Likewise, episiotomy use is higher in nulliparas and those receiving epidural anesthesia (Hueston, 1996; Newman, 2001; Robinson, 2000). In contrast, upright or lateral maternal positions are associated with fewer episiotomies (Gupta, 2012). Last, episiotomy is also more common with operative vaginal than spontaneous vaginal deliveries (71 versus 33 percent) (Weber, 2002).

TABLE 20-2. Patient, Practitioner, and Delivery Factors Associated with Higher Episiotomy Rates

Nulliparity
White gravida
Urban hospital
Dorsal lithotomy
Physician provider
Epidural anesthesia
Commercial insurance
Non-teaching hospital
Operative vaginal delivery

■ Maternal and Fetal Indications

The indications for episiotomy vary widely and include those for the mother or the fetus. Of maternal indications, some argue that episiotomy should be considered to reduce spontaneous perineal lacerations and their sequelae. To address this, a Cochrane database review by Carroli and Mignini (2009) included eight randomized trials with 5541 women to assess the effects of routine use versus restrictive use of episiotomy. Seventy-five percent of women in the routine group had episiotomies compared with 28 percent in the restrictive group. Restrictive use of episiotomy was associated with lower rates of severe perineal trauma, suturing, and healing complications. No differences were identified in rates of severe perineal or vaginal trauma or later dyspareunia or in several measures of perineal pain. Women in the restrictive episiotomy group had a higher incidence of anterior perineal trauma. However, this was not associated with greater rates of urinary incontinence or pain. These results were consistent regardless of whether midline or mediolateral episiotomies were done. That said, no comparative trials that specifically compared midline with mediolateral episiotomy were available for their analysis. The authors concluded that episiotomies should be performed in a restrictive manner rather than routinely.

Regarding long-term effects, a prospective cohort study was designed to examine the effects of episiotomy on women whose first delivery was 5 to 10 years earlier. Investigators found that both forceps delivery and perineal lacerations, but not episiotomies, were associated with pelvic floor symptoms (Handa, 2012).

Of fetal indications, some recommend episiotomy to shorten second-stage labor for a category III fetal heart rate tracing and lower rates of poor neonatal outcome. As a second indication, episiotomy may aid resolution of shoulder dystocia and thereby lower associated fetal acidosis or trauma. In addition, proponents assert that episiotomy protects premature fetuses against intracranial hemorrhage during vaginal birth. Few published data address these fetal indications.

■ Current Recommendations

Based in part on the above evidence, the decision to perform an episiotomy should be individualized to each woman with thoughtful consideration of the established risks and potential benefits. Routine use of episiotomy is not supported by medical literature and is associated with increased maternal morbidity in most cases. Hospitals with high episiotomy rates should consider implementing education and quality improvement programs to educate the health-care team. One published literature review found that training courses, audits, a staff champion, and feedback to individual providers regarding their episiotomy rate could help reduce episiotomy rates (Faruel-Fosse, 2006).

Most experts now advocate for the *restrictive use* of episiotomy. The American College of Obstetricians and Gynecologists (2015) has concluded that restricted use is preferred to routine use of episiotomy. The National Quality Forum reported that limiting the routine use of episiotomy was an important quality and patient safety measure and noted increased rates of pain and anal incontinence with the procedure (Main, 2009).

■ Episiotomy Type

There is no international consensus on how to define the different episiotomy techniques, and obstetric textbooks and organization guidelines differ considerably. Kalis and associates (2012) have presented a classification of these, and we agree with the need for terminology standardization.

Midline and mediolateral episiotomies are the two main types and vary by the angle of perineal incision. Their specific surgical steps are described and illustrated on page 324. To summarize, the *midline episiotomy* begins at the fourchette, incises the perineal body in the midline, and ends well before the external anal sphincter is reached. The *mediolateral episiotomy* begins at the midline of the fourchette but is angled toward either the right or the left ischial tuberosity. The *lateral episiotomy* begins at a point 1 to 2 cm lateral from the midline of the fourchette. It too is angled toward either the right or the left ischial tuberosity. Notably, in older texts, lateral episiotomy formerly described incisions that began at 9 o'clock on the perineum and extended directly laterally. This incision is no longer recommended as it fails to provide sufficient perineal relaxation and is associated with bleeding risks from the vestibular bulb and pudendal artery branches (Zuspan, 1988).

Comparing midline and mediolateral types, few data support the indicated use of one over the others. To date, only one randomized trial has compared midline and mediolateral episiotomies (Coats, 1980). Midline episiotomy was associated with a higher likelihood of OASIs, but with less scarring and a quicker return to sexual intercourse. Self-perceived pain scores and dyspareunia were similar in both episiotomy groups.

Most other comparisons of these two episiotomy types derive from case series and cohort studies. These investigations show an increased risk of OASIs with midline compared with mediolateral episiotomy. Namely, one metaanalysis identified higher rates of OASIs after midline compared with mediolateral episiotomy in both nulliparas and multiparas undergoing vacuum-assisted delivery (Sagi-Dain, 2015).

In comparison, both types result in similar rates of pain. Specifically, one prospective cohort study of 300 gravidas found no differences in postpartum pain scores or dyspareunia at 3 months among women receiving midline, mediolateral, or lateral episiotomy techniques (Fodstad, 2014).

There are even fewer studies that compare lateral episiotomy to either mediolateral or midline. One randomized trial compared lateral and mediolateral types in nulliparas. Groups did not differ in pain scores or in vaginal or perineal trauma, including OASIs (Karbanova, 2014a,b). The authors also reported that mediolateral episiotomies required less time and suture for the repair but that they lie closer to the anus.

In sum, in appropriately counseled women in whom episiotomy is indicated, mediolateral episiotomy may be the preferred incision type based on similar pain and dyspareunia outcomes, but reduced rates of OASIs. The American College of Obstetricians and Gynecologists (2015) concludes that mediolateral might be preferable to midline episiotomy in selected cases.

■ Operative Vaginal Delivery

Vacuum-Assisted Delivery

The very conditions that lead to indications for operative vaginal delivery also increase the likelihood of perineal lacerations. Episiotomy is reported in up to two thirds of vacuum-assisted deliveries, although rates vary widely. In their systematic review that included 350,764 vacuum-assisted deliveries, Sagi-Dain and Sagi (2015) found that the rate of OASIs nearly doubled in nulliparas (59 percent) compared with multiparas (34 percent). Of episiotomy types, lateral episiotomy decreased the risk of OASIs in nulliparas. With mediolateral episiotomy, OASIs rates were greater in multiparas, yet for nulliparas, there was a nonsignificant but protective trend. Last, midline episiotomy increased OASIs rates during vacuum-assisted delivery regardless of parity. Although the quality of evidence in this review was poor, these data suggest that the risk for OASIs during vacuum-assisted delivery varies according to parity and episiotomy type. For the fetus, this same review did not ascribe any fetal benefits to any type of episiotomy during vacuum delivery. Evaluated indicators included Apgar score, umbilical artery pH and base excess, neonatal intensive care unit (NICU) admission, and need for neonatal resuscitation.

Of other evidence, a population-based study found that lateral episiotomy was associated with a 46-percent decreased incidence of OASIs in nulliparas who delivered with vacuum assistance (Räisänen, 2012). Similarly, data from the Danish Medical Birth Registry found that in vacuum-assisted deliveries, mediolateral episiotomy was protective compared with no episiotomy (Jangö, 2014).

Forceps Delivery

Forceps delivery is associated with an increased risk for OASIs that ranges from 10 to 35 percent (Bofill, 1996; de Vogel, 2012; Johnson, 2004). Likewise, in a large prospective cohort study of women who sustained OASIs, two thirds of third- or fourth-degree lacerations were associated with forceps deliveries (Lewicky-Gaup, 2015). A retrospective study evaluated OASIs rates and fetal head position prior to forceps delivery. Bradley and coworkers (2013) showed a lower OASIs rate during forceps delivery if fetuses were rotated from occiput-posterior (OP) to occiput-anterior (OA) head position compared with delivery from an OP position. Thus, clinicians may consider rotation of the fetal head to an occiput-anterior position to decrease OASIs rates if forceps are needed.

Retrospective studies suggest that mediolateral episiotomy may provide protection for the anal sphincter during operative delivery, including forceps delivery (de Vogel, 2012; de Leeuw, 2008). Two recent studies found that mediolateral episiotomy during operative deliveries (forceps and vacuum) decreased the odds of OASIs, with one study showing a sixfold reduction of OASIs (Bharucha, 2014; Jangö, 2014). However, routine use of mediolateral episiotomy has not been shown to reduce risk of OASIs.

In sum, forceps delivery is a well-established risk factor for OASIs. Moreover, as with any vaginal delivery, episiotomy use is restricted unless clinical indications are present, and women are counseled regarding increased risks. If episiotomy is done, a mediolateral incision is preferable for many cases (de Leeuw, 2008; de Vogel, 2012; Hirsch, 2008).

■ Surgical Technique

Mediolateral Episiotomy

Prior to performing an episiotomy, a clinician ensures adequate patient anesthesia from an epidural, spinal, or pudendal block. To supplement these, 1-percent lidocaine or other suitable anesthetic agent can be injected as needed into the perineum and surrounding tissues. The incision is typically initiated late in the second stage of labor and as the fetal head crowns and distends the perineum. Prior to incision, the clinician insinuates two fingers between the fetal head and perineal body. These digits exert additional outward pressure on the perineum to flatten it and also protect the presenting fetal part. In most cases, straight Mayo scissors are used to cut the perineum.

With mediolateral episiotomy, the incision begins at the fourchette in the midline. It is directed toward the ipsilateral ischial tuberosity and lies along a line at least 60 degrees from the midline (Fig. 20-2). As such, after delivery, the angle becomes more acute, approximately 45 degrees, because the perineum is no longer stretched by the fetal head. Studies have shown that larger angles are associated with lower risks of OASIs. To better understand the angle of the mediolateral episiotomy incision, investigators compared trigonometric characteristics of the final perineal scars. The ideal angle of the final healed scar ranged from 30 to 60 degrees (Eogan, 2006; Stedenfeldt, 2012). Specifically, Gonzalez-Diaz and coworkers (2015) found that a healed scar that lay at an angle >20 degrees from the sagittal midline correlated with an 87-percent lower risk of OASIs.

The incision should be sufficiently deep to remove perineal resistance for fetal delivery and should extend at least 3 to 4 cm onto the perineum. If the episiotomy is placed too laterally, it will not provide the desired relaxation of the median portion of the levator plate. The anatomic structures traversed during a mediolateral episiotomy include the vaginal epithelium,

superficial transverse perineal muscle, bulbospongiosus (formerly, bulbocavernosus) muscle, and perineal skin. Large episiotomies may also expose ischioanal fat.

Midline Episiotomy

With midline episiotomy, the perineum is incised in the midline from the posterior fourchette toward the anus. However, the incision stops well short of the external anal sphincter. The position of the sphincter is easily ascertained by visualization and palpation.

Midline episiotomy was historically performed in the United States because of perceptions that it was easier to repair and associated with less pain. However, as noted earlier, limited data suggest a higher risk of OASIs with midline compared with mediolateral episiotomy yet similar postpartum pain. Although the data are insufficient to determine the superiority of either approach, mediolateral may be preferred if an episiotomy is necessary.

Lateral Episiotomy

With this episiotomy, the incision begins at the introitus but at a point 1 to 2 cm lateral to the midline. Similar to the mediolateral type, it is directed toward the ipsilateral ischial tuberosity (Kalis, 2012).

■ Surgical Repair

Suture Choice

To properly select an appropriate suture for episiotomy repair, clinicians should be familiar with principles of wound healing and properties of commonly used sutures. These are detailed in Chapter 1 (p. 4). Ideally, closure strives to approximate damaged tissues, promote healing by primary intention, control bleeding, and minimize infection. Most perineal wounds heal by primary intention within 2 weeks of repair. If the sutures remain longer, they can act as a foreign body and initiate an inflammatory response. In turn, this response can potentially lead to poor or delayed wound healing or pain. Thus, the ideal suture material prompts minimal tissue reaction and is quickly absorbed once the tissues are healed. Different tissues will take longer to heal, and these therefore need sutures that maintain their tensile strength for varying lengths of time.

Of absorbable suture materials, two broad categories are catgut, which is absorbable, and synthetic materials, which are considered delayed-absorbable. These differ primarily in the way in which they are absorbed. Catgut is absorbed by phagocytosis and incites a greater inflammatory reaction. Plain catgut elicits a greater inflammatory response than chromic catgut.

Synthetic, delayed-absorbable sutures are absorbed by hydrolysis. Polyglactin 910 (Vicryl) is commonly used in episiotomy and perineal repairs. It maintains its tensile strength for 30 days and is totally absorbed in 90 days. Certain layers of the repair such as the perineal body require sutures to hold their tensile strength longer than the vaginal epithelium. Other important synthetic sutures for episiotomy repairs include Monocryl (poliglecaprone 25) and Vicryl Rapide. The latter is identical in composition to polyglactin 910 but is absorbed faster. Thus, Vicryl Rapide maintains its tensile strength and supports tissues for approximately 14 days and is completely

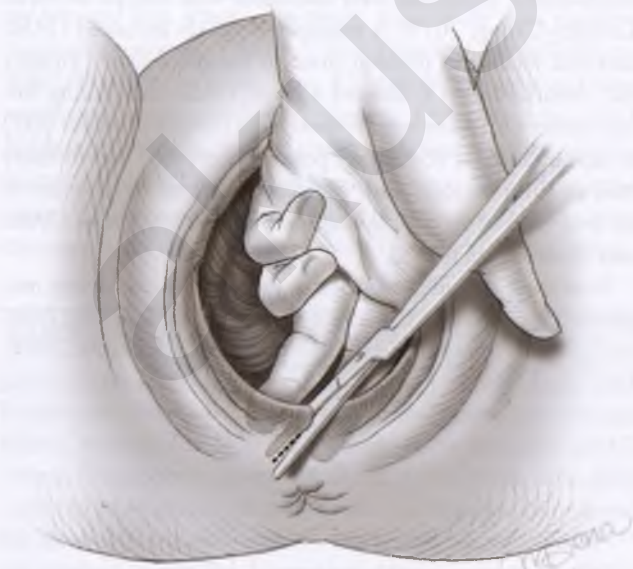

FIGURE 20-2 A mediolateral episiotomy is cut when the baby's head is crowning. The incision is started in the midline and is directed toward the ipsilateral ischial tuberosity. The direction of this incision is important to avert anal sphincter injury.

absorbed within 40 days. Monocryl has low tissue reactivity and maintains high tensile strength with a half-life of 7 to 14 days. It is hydrolyzed by approximately 90 days.

One Cochrane review investigated absorbable and delayed-absorbable sutures for repair of episiotomies and second-degree perineal lacerations (Kettle, 2012). These reviewers found that standard synthetic sutures such as polyglactin 910 were associated with less immediate postpartum pain and less analgesia use than catgut sutures. However, not surprisingly, based on suture properties, more women with standard synthetic sutures required removal of unabsorbed suture material. When standard synthetic sutures were compared with rapidly absorbing synthetic sutures, pain outcomes were similar. However, more women in the standard suture group required suture removal.

With more extensive lacerations involving the internal and external anal sphincter muscles, a monofilament delayed-absorbable suture, such as polydioxanone (PDS II) or polyglyconate (Maxon), are additional options. Delayed-absorbable sutures offer the benefits of an absorbable suture and extended wound support (up to 6 weeks). At 4 weeks, 65 to 90 percent of polydioxanone's original strength is retained and absorption is complete between 180 and 240 days.

Technique

Initially, any vaginal and/or cervical lacerations proximal to the episiotomy site that require suturing are repaired first. Similarly, atony is resolved and manual exploration of the uterus, if needed, is completed prior to episiotomy suturing. With this strategy, upper genital tract bleeding that might obscure episiotomy visualization is minimized. Second, early resolution of these avoids the later need for hands or retractors in the vagina, which can tear a completed episiotomy repair.

Essential steps to repair include good maternal pain control, ideal lighting, and gauze or suction to clear blood from the field. Adequate inspection of the perineum, posterior vaginal wall, and rectum is necessary to ensure that the episiotomy or perineal laceration did not extend into the anal sphincter and/or rectum. Rectal examination is strongly recommended in all cases of significant perineal injury to ensure that defects in the internal anal sphincter and rectal epithelium are not missed.

One metaanalysis showed that continuous suturing techniques compared with interrupted sutures for all layers of perineal closure are associated with less immediate postpartum pain (Kettle, 2012). Additionally, continuous subcutaneous suturing was associated with less postpartum analgesia use compared with interrupted sutures for repair of perineal skin. Suture removal rates were lower in those who received continuous suturing. The need for subsequent wound suturing or long-term pain did not differ between groups. Last, continuous suturing is faster. Thus, a continuous suture technique is generally recommended and described here.

For mediolateral episiotomy repair, a 2-0 or 3-0 gauge suture can be used throughout. To begin, an anchoring stitch is initially placed above the apex of the vaginal incision. The vaginal epithelium and deeper tissues are then closed with a single continuous suture line. A locking stitch may be used if excessive bleeding needs to be controlled (Fig. 20-3A). On reaching the hymen, this suture is tied.

Next, to reconstruct the deeper layers of the perineum, a suture of similar gauge and a continuous non-locking technique is used (Fig. 20-3B). This suture line begins near the introitus and advances distally. Here the suture is tied. Superficial to this layer, a subsequent suture line aims to reapproximate the superficial transverse perineal and bulbospongiosus muscles (Fig. 20-3C). Again, this continuous suture line begins near the introitus and advances distally. This same suture is usually sufficiently long to complete skin closure as well. For this, the perineal skin is approximated using a running subcuticular stitch (Fig. 20-3D). This technique is thought to reduce the tension on perineal tissues, thereby reducing tissue ischemia and pain.

For midline episiotomy repair, closure of the vaginal portion mirrors that for the mediolateral repair (Fig. 20-4). In distinction, midline repair can often be completed with a single suture length. Thus, once the level of the hymen is reached, a transition stitch, shown in Figure 20-4B, is used to redirect suturing from the vagina to the perineum. Subsequent suturing aims to reapproximate the bulbospongiosus and superficial transverse perineal muscles and the perineal body. As shown in Figure 20-4D, the skin is closed with a continuous subcuticular suture line.

OBSTETRIC ANAL SPHINCTER INJURIES

Third- and fourth-degree lacerations are combined under the umbrella term of obstetric anal sphincter injuries (OASIs). These lacerations are associated with significantly more morbidity than first- and second-degree lacerations. For example, OASIs are the most important and modifiable risk factor in the etiology of anal incontinence, which is defined as involuntary loss of gas, liquid, or solid stool. Anal incontinence affects up to 25 to 35 percent of women 6 months after vaginal childbirth complicated by OASI (Evers, 2012; Richter, 2015). It is associated with tremendous clinical, psychological, and social burden (Mellgren, 1999). Common short-term complications after OASIs include perineal pain, dyspareunia, fecal urgency, and defecatory difficulty. Rarely, rectovaginal fistula may develop.

The reported incidence of OASIs varies but may be as high as 7 percent after mediolateral episiotomy and up to 17 percent after midline episiotomy (Fenner, 2003; Nordenstam, 2008; Sultan, 1994; Tetzschner, 1996; Uustal Fornell, 1996). Independent risk factors for OASIs are listed in Table 20-3.

■ Identification of OASIs

The importance of identifying OASIs at the time of vaginal delivery cannot be underscored as timely and proper repair of lacerations impacts long-term maternal outcomes. Identifying OASIs can be challenging if pain control is inadequate. Anatomy may also be poorly defined secondary to poor lighting, obscuring blood, tissue edema from prolonged maternal pushing, and jagged laceration borders. In an attempt to determine the proportion of OASIs that are incorrectly classified at delivery, women delivering at one institution were examined by their provider and then reexamined by a research fellow trained in identifying OASIs (Andrews, 2006). Prevalence of OASIs increased from 11 to 25 percent when women were reexamined.

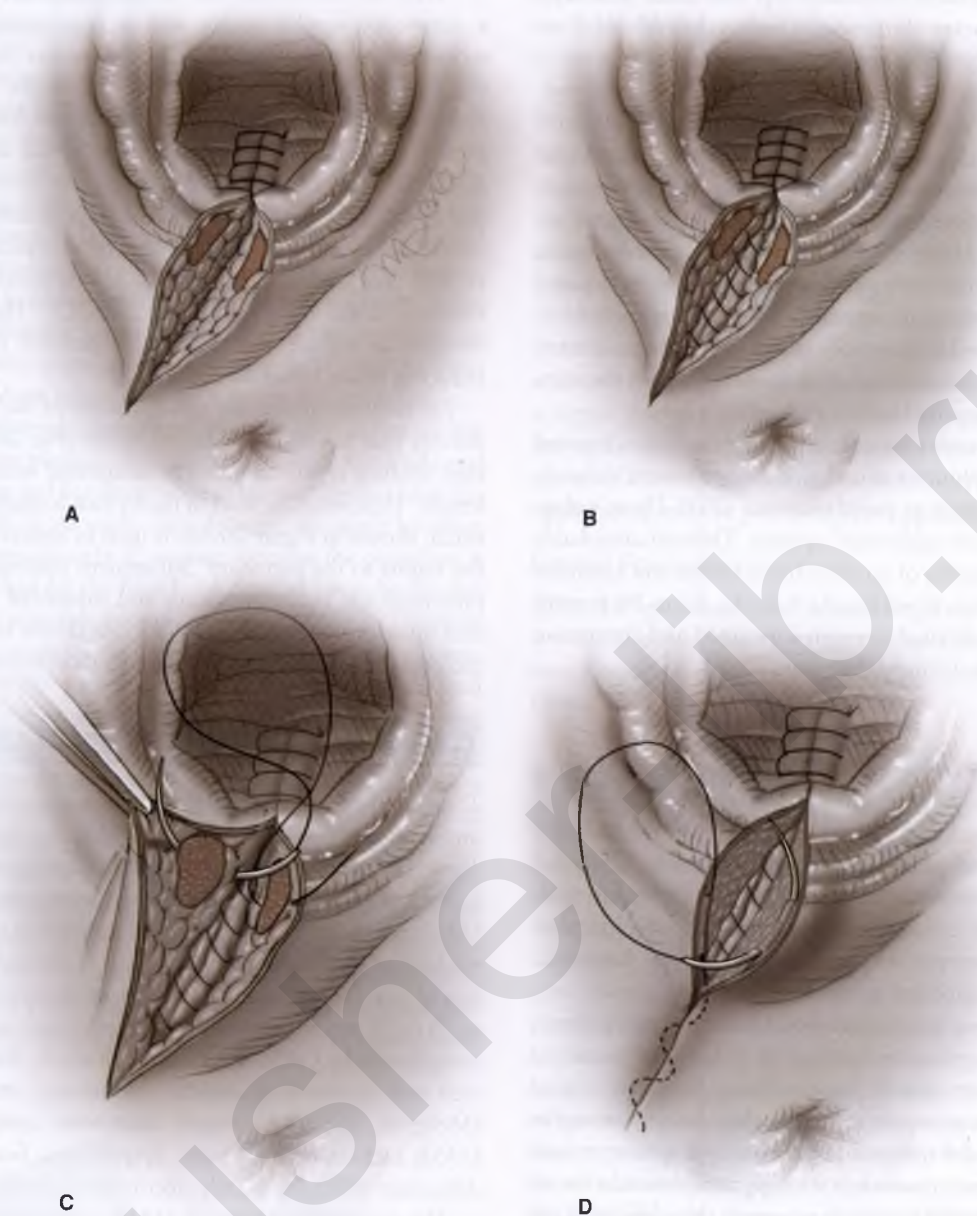


FIGURE 20-3 Mediolateral episiotomy. **A.** The vaginal epithelium and deeper tissues are closed with a single, continuous, locking suture. The angle seems less acute now (approximately 45°) since the perineum is no longer distended. **B.** This image shows the reapproximated vaginal epithelium. The deeper perineal tissue layer has been closed with a single, continuous, nonlocking suture. **C.** By a similar continuous, nonlocking technique, the superficial transverse perineal and bulbospongiosus muscles are reapproximated. **D.** Last, the perineal skin is approximated using a subcuticular stitch.

Of OASIs, 30 followed deliveries by midwives, who misdiagnosed 87 percent of lacerations. In deliveries by physicians, 28 percent of OASIs were initially missed. Study participants also had endoanal ultrasound, which correctly identified all OASIs identified by clinical examination. Imaging identified three additional occult OASIs—one involved the external anal sphincter and two affected the internal anal sphincter.

Sultan and associates (1993) first reported high rates of occult OASIs found sonographically in primiparas and linked this finding with anal incontinence. Numerous clinical investigators have since noted similar rates of occult OASIs using endoanal sonography. Rates in these studies range from 20 to 40 percent

(Abramowitz, 2000; Belmonte-Montes, 2001; Chaliha, 2001; Faltin, 2000; Zetterstrom, 1999). It is uncertain if OASIs identified sonographically are truly occult or are merely misclassified or not identified at delivery.

Whether identification and repair of occult OASIs confer long-term benefits to women is unclear. One small prospective study concluded that occult OASIs identified by postpartum sonography were not associated with deterioration in anal continence during the subsequent 10 years (Frudinger, 2008). However, the study was likely underpowered to show a difference, as only 14 women sustained occult OASIs. In contrast, a randomized trial of 752 women found that endoanal

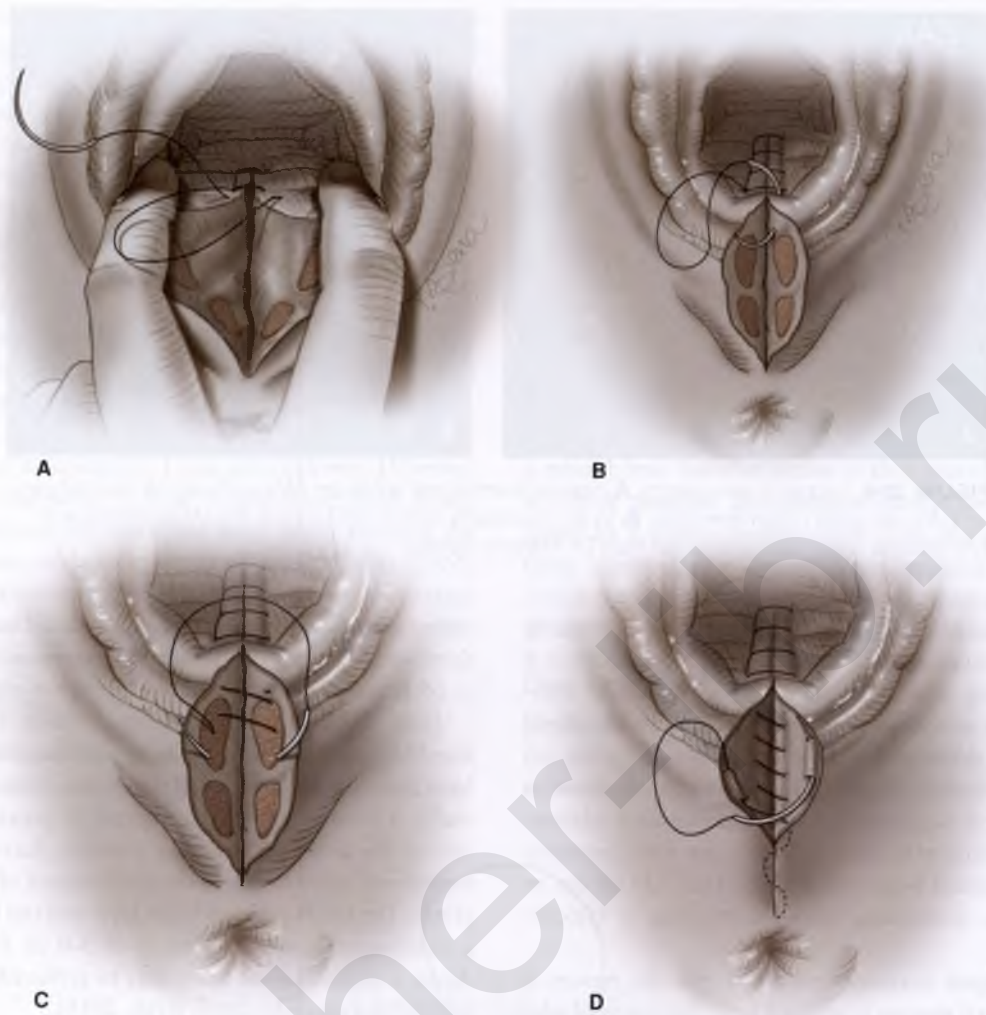


FIGURE 20-4 Midline episiotomy. **A.** The vaginal epithelium and deeper tissues are closed with a single, continuous, locking suture. **B.** A transition stitch redirects suturing from the vagina to the perineum. **C.** The superficial transverse perineal and bulbospongiosus muscles are reapproximated using a continuous, nonlocking technique. **D.** Last, the perineal skin is approximated using a subcuticular stitch.

sonography improved OASI diagnosis rates. Moreover, prompt repair decreased the rate of later severe fecal incontinence (Faltin, 2005). In this study, women without clinically obvious OASIs were randomly assigned to undergo clinical examination immediately postpartum with or without adjunctive endoanal

sonography performed in the delivery suite. When occult OASIs were identified sonographically, the perineum was explored and sphincter repaired (Fig. 20-5). Three months and 1 year after delivery, fewer women who had endoanal sonographic evaluation complained of severe fecal incontinence compared with those who did not undergo sonography. Twenty-nine ultrasound evaluations were needed to prevent one case of severe fecal incontinence.

Regardless, obstetric providers must ensure adequate inspection of the perineum, posterior vaginal wall, and rectum after vaginal deliveries. As an option, a urogynecologists may be consulted in difficult or unclear cases.

■ Surgical Repair

Once OASIs are identified, careful examination, including rectal examination, is essential to identify their full extent. As noted on page 325, good maternal pain control, ideal lighting, adequate assistance, an experienced surgeon, and equipment suitable for tissue retracting and clearing blood from the

TABLE 20-3. Risk Factors for Perineal Trauma

Nulliparity
Midline episiotomy
Asian or Indian race
Advanced maternal age
Neonatal weight >4 kg
Operative vaginal delivery
Prolonged second-stage labor
Occiput-posterior presentation

Data from Benavides, 2005; Burrell, 2015; Ponkey, 2003; Royal College of Obstetricians and Gynaecologists, 2007.

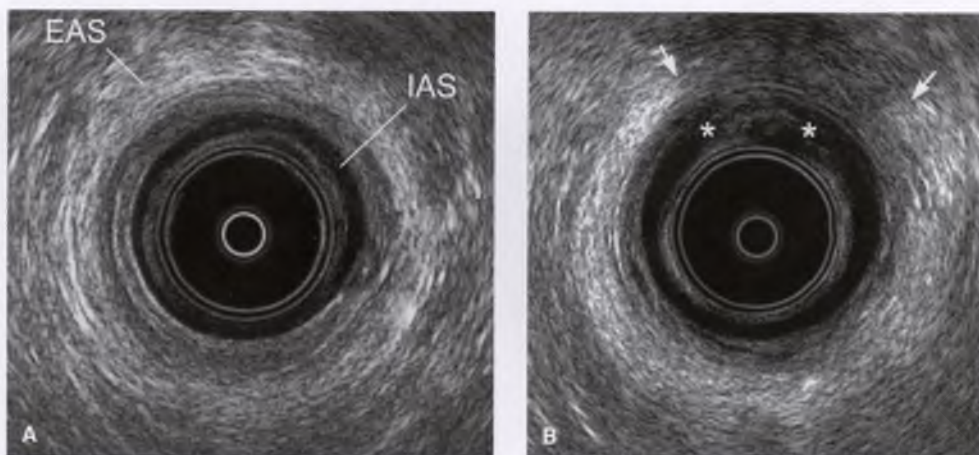


FIGURE 20-5 Endoanal sonography. **A.** Normal internal anal sphincter (IAS) and external anal sphincter (EAS) are intact circumferentially. **B.** In this sonogram, defects are found in the IAS (*asterisks*) and EAS (*arrows*). (Used with permission from Dr. Marlene Corton.)

field are ideally in place. If unavailable, repair is temporarily delayed while arrangements are made ready, and pressure is applied to bleeding points. Providers may also consider moving the mother to an operating suite if the injury is extensive or conditions in the delivery suite are suboptimal.

After uncomplicated vaginal delivery, immediate focus is understandably and usually on the maternal-newborn relationship. However, short-term maternal morbidity from laceration bleeding and potential long-term sequelae from OASIs can be significant. Thus, immediate, extended bonding is typically postponed.

If a fourth-degree laceration extending into the rectum is identified, the rectal mucosa is repaired first. This mucosal edge heals quickly, but bacterial colonization of the rectum is great. Thus, a rapidly absorbable, 2-0 to 4-0 gauge, monofilament may be preferred. **Figure 20-6** shows rectal mucosa reapproximation

with a continuous nonlocking suture line. Notably, the needle skims and incorporates a substantial portion of the inner mucosa to confidently reapproximate the laceration edges.

Next, the internal anal sphincter muscle (IAS) is repaired. The IAS is a thickening of the circumferential smooth-muscle layer and surrounds the distal 3 to 4 cm of the anal canal. Normally, it remains tonically contracted to provide 70 to 85 percent of the anal canal's resting pressure. Accordingly, the IAS contributes substantially to the maintenance of fecal continence at rest. The IAS is a thin, whitish layer and can be repaired using a continuous, nonlocking stitch of 3-0 or 4-0 gauge suture. Again, a monofilament suture may be preferred (**Fig. 20-7**) (Farrell, 2012; Fernando, 2006; Rygh, 2010).

The external anal sphincter (EAS) is approximately 2 cm thick and 3 to 4 cm long and composed of striated muscle that surrounds the distal anal canal. This anatomy permits tonic but

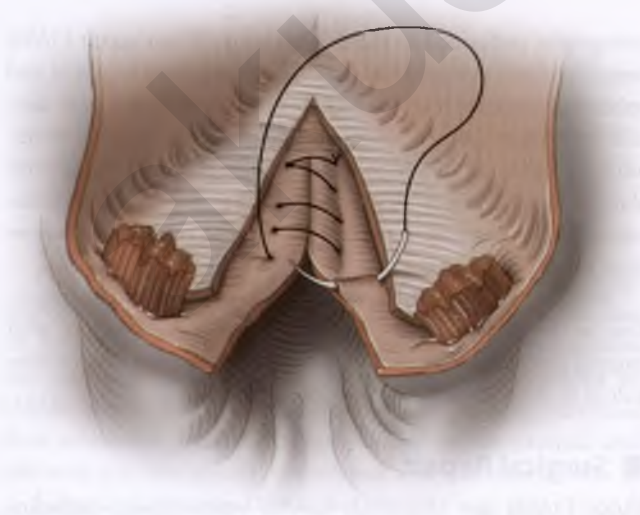


FIGURE 20-6 Repair of the rectal mucosa after a fourth-degree laceration. The mucosa is sutured starting at the apex of the laceration using a continuous nonlocking method and rapidly absorbable suture.

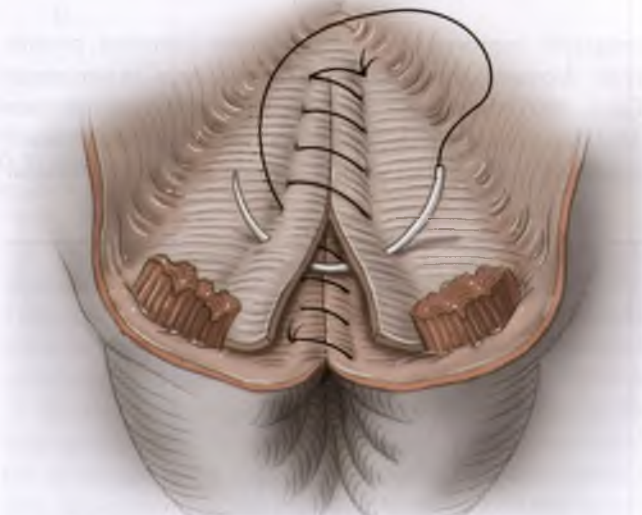


FIGURE 20-7 Internal anal sphincter (IAS) repair. The IAS is repaired using a continuous, nonlocking suture.

also voluntary contraction to sustain continence. It functions as a unit with the puborectalis muscle component of the levator ani muscle (Chap. 3, p. 37).

Two commonly recognized methods of EAS repair are the end-to-end and the overlapping repair methods. Several trials have compared these two, and six randomized trials that included 588 women were summarized by Fernando and coworkers (2013). These investigators reported on the outcomes of these two EAS repair methods with regard to perineal pain, dyspareunia, and anal incontinence 1 year after repair. They found no difference in rates of perineal pain, dyspareunia, or flatal incontinence 1 year after repair. They found lower rates of fecal urgency and lower anal incontinence scores with the overlapping repair. The overlapping repair was also associated with a lower risk of anal incontinence deterioration 1 year after delivery. However, by 3 years, no differences in flatal incontinence, fecal incontinence, or quality-of-life outcomes were found between the groups. Therefore, overlapping repair of the EAS after OASIs may offer some short-term benefits, but long-term advantages are uncertain. Accordingly, clinicians may choose either technique, and both techniques are described here.

End-to-End EAS Repair

As an overview, this closure places fascial stitches that surround the EAS cylinder, and sutures are placed posteriorly, inferiorly,

anteriorly, and superiorly to it (Fig. 20-8). Also, a single figure-of-eight suture reapposes the torn EAS muscle fibers directly.

To begin, the disrupted ends of the EAS are identified laterally. Often, they may retract to the 3 and 9 o'clock positions, and an Allis clamp may be used to grasp each of the torn sphincter ends. The fascial sutures incorporate both the surrounding fascia and a small amount of adjacent sphincter muscle. A 2-0 or 3-0 gauge delayed-absorbable suture maintains suitable tensile strength for reapproximation and tissue healing. Of note, the strength of this closure is obtained by reapproximating the surrounding fascia and not the striated muscle. Thus, at least 1 cm of the adjacent fascia is incorporated on each side using a simple interrupted or figure-of-eight suture.

The fascial sheath is easier to close if the posterior suture is placed first. Another suture is then placed inferiorly at the 6 o'clock position. The sphincter muscle fibers are next reapposed by a figure-of-eight stitch. Last, the remainder of the fascia is closed with a stitch placed anterior to the sphincter cylinder and again with one placed superior to it. All grade 3a and 3b OASIs are repaired using this end-to-end technique.

Overlapping EAS Repair

Similar to the end-to-end technique, the first step is to identify the retracted ends of the muscle bilaterally. The overlapping technique is only used when the full length and thickness of the

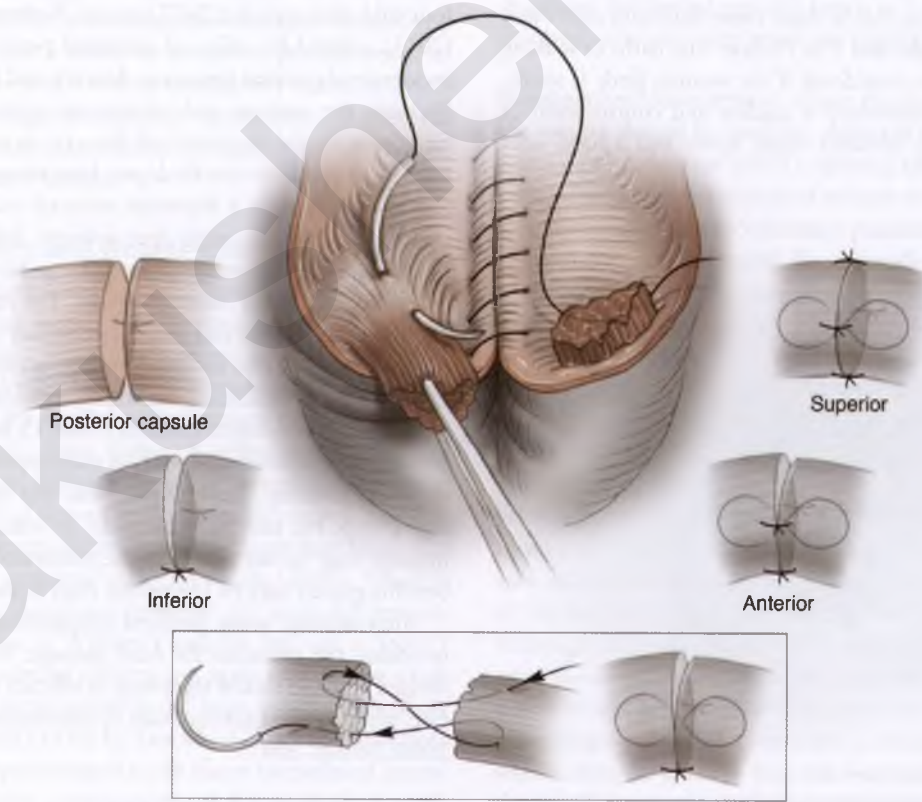


Figure of eight

FIGURE 20-8 End-to-end external anal sphincter (EAS) repair. The torn ends of the EAS muscle and surrounding fascia are identified. Four to six sutures that incorporate the adjacent fascia and small amounts of muscle are placed around the EAS. The first suture is placed posteriorly to maintain clear exposure. Another suture is then placed inferiorly at the 6 o'clock position. The sphincter muscle fibers are next reapposed by a figure-of-eight stitch. Last, the remainder of the fascia is closed with a stitch placed anterior to the sphincter cylinder and again with one placed superior to it.

EAS is disrupted. Once sphincter ends are identified, they are dissected adequately from their adjacent fascia to allow the two ends to overlap each other for approximately 1.5 cm. The two muscle ends are then sutured in a vest-over-pants technique. This arrangement maintains muscle reapproximation despite physiologic fiber contraction and shortening (Fig. 20-9). Once muscle edges overlap, four to six mattress sutures are placed. Traversing the overlapped sphincter, an individual suture travels in a superficial-to-deep path and then in a deep-to-superficial path. The ends of that individual suture are then tied. In placing these mattress sutures, the more lateral row is placed first. In this row, the proximal stitch is placed first, and then the distal one. This order is repeated when adding the medial row of stitches. As with the end-to-end repair, a 2-0 or 3-0 gauge delayed-absorbable suture is suitable.

Once the EAS is repaired by either method, the area is copiously irrigated using pressure to minimize the bacterial load. The remaining repair mirrors that for midline episiotomy, which was shown on page 327.

Postoperative Management

Few evidence-based guidelines direct postpartum management of women with OASIs. We believe perineal care is an important factor in wound healing. For this reason, we encourage women to gently clean the perineum and anus with a handheld shower head or with a squirt bottle filled with warm tap water. This perineal hygiene is done two to three times daily and after every bowel movement for the first 7 to 10 days. Sitz baths or soaking in a warm tub can be considered if the woman finds it soothing. Optimal stool consistency is unclear and controversial. A runny stool may ooze between repair layers and a hard stool



FIGURE 20-9 Overlapping external anal sphincter repair. The torn ends of the muscle are mobilized to allow the two ends to overlap for 1.5 cm. The ends are sutured in a vest-over-pants fashion to accommodate sphincter contraction. Once edges are overlapped, four to six mattress sutures are placed serially as shown by numbers 1–4. Traversing the overlapped sphincter, an individual suture travels in a superficial-to-deep path and then in a deep-to-superficial path before being tied.

may disrupt stitches during evacuation. Thus, an intermediate between these two may be best.

Finally, based on a single trial, we recommend prophylactic antibiotics for these patients. The study evaluated perineal wound complications after OASIs in women receiving placebo or a single prophylactic dose of a second-generation cephalosporin. Two weeks postpartum, 8 percent of women given prophylactic antibiotics and 24 percent of those in the placebo group had wound disruptions and purulent discharge (Buppasiri, 2014).

■ Prevention of OASIs

In an effort to prevent OASIs, clinicians ideally identify individual gravidas with modifiable risk factors and develop a delivery plan that accounts for these. Known risk factors for OASIs are reviewed in Table 20-3. For a woman with a nonmodifiable risk, antepartum care includes a discussion and delivery plan to ideally lessen additional risks.

Some advocate antenatal massage of the perineal body to increase perineal distensibility and thereby minimize perineal trauma. During massage with a lubricant, the perineum is grasped in the midline by the thumb and opposing second and third fingers of each hand. Outward and lateral stretch against the perineum is then repeatedly applied. Sessions are daily or three to four times weekly and last from 4 to 10 minutes.

Evidence for this practice comes from a systematic review of four trials that included 2497 women. Beckmann and coworkers (2013) assessed the effect of antenatal perineal massage on the incidence of perineal trauma at delivery and ensuing morbidity. Between the massage and routine-care groups, no differences were seen in the incidence of first- or second-degree perineal tears or of third- or fourth-degree lacerations. Perineal massage was associated with a 9-percent reduced incidence in perineal trauma requiring suturing after delivery, but only in primiparas. This reduction was explained by a 16-percent lower rate of episiotomy in the massage group. The reason for the lower episiotomy is unclear and may be secondary to massage-induced tissue changes or due to confounding variables, such as patient motivation or education regarding episiotomy and perineal trauma. These reviewers calculated that 15 women (range 10 to 36) would need antenatal perineal massage to prevent one injury requiring suturing. Perineal pain was also reduced in the massage group, but only in multiparas. In sum, antenatal perineal massage may be supported in the motivated gravida, although benefits gained may be less robust than hoped.

Alternatively, some perform *intrapartum* perineal massage to widen the introitus for head passage. Evidence for this is limited and also mixed regarding its efficacy for perineal protection when applied intrapartum (Geranmayeh, 2012; Mei-dan, 2008; Stamp, 2001).

■ Complications of OASIs

Anal Incontinence

This is the involuntary loss of flatus, liquid, or solid stool and can lead to psychologic distress and poor quality of life. Affected women may fail to seek medical attention due to embarrassment. Specifically, Johanson and associates (1996)

noted that one third of women with fecal incontinence did not discuss their symptoms with a health-care provider. Among the etiologies of anal incontinence, OASIs are the most important and modifiable risk factors in women, affecting up to 40 percent of women after childbirth (Haylen, 2010). With primary OASI detection and repair, 60 to 80 percent of women are asymptomatic 1 year after injury (Royal College of Obstetricians and Gynaecologists, 2007). The societal costs of anal incontinence after OASI are high as well. One study from 1999 investigating the long-term costs of anal incontinence after OASI reported an average cost of \$17,166 per patient. Evaluation and follow up charges were \$65,412 (Mellgren, 1999).

Pain

Perineal pain and dyspareunia are common after OASIs and affect up to 50 percent of women with these lacerations. Moreover, pain may limit a mother's ability to care for her newborn (Haadem, 1987, 1990; Lewicky-Gaupp, 2015; Sleep, 1991; Sultan, 1994). As noted on page 325, OASI repair with continuous rather than interrupted suturing may decrease pain. Also, antenatal perineal massage might reduce postpartum pain. This advantage, however, was noted only for multiparas (Beckmann, 2013).

Fistula

Rectovaginal fistulas are a rare complication of OASIs. The incidence after fourth-degree lacerations is less than 3 percent (Rogers, 2007). The two most common etiologies for obstetric rectovaginal fistula are a failure to recognize the full extent of a laceration at delivery or a wound breakdown related to infection. Thus, a thorough intrapartum examination is essential. This includes a rectal examination to confirm rectal mucosa integrity in those with OASIs.

Wound Dehiscence and Wound Infection

Seeking to avoid these complications, several authors recently identified several risk factors for the development of perineal wound complications. Through a large retrospective analysis of women suffering OASIs, Stock and coworkers (2013) elicited several risk factors for wound complications including smoking, increasing body mass index, fourth-degree laceration, and operative vaginal delivery. Similarly, a retrospective case-series touted length of second stage, operative vaginal delivery, mediolateral episiotomy, third- or fourth-degree laceration, and meconium-stained amniotic fluid (Williams, 2006). Notably episiotomy was elucidated as a potential risk factor for perineal wound complications in Williams's analysis, but not in Stock's analysis. Operative vaginal delivery was again identified as a risk factor for wound complications in the large, prospective cohort study of women with OASIs by Lewicky-Gaupp and associates (2015). Although episiotomy is a risk factor for perineal laceration, it is unclear from current evidence if it similarly is a risk factor for postpartum perineal laceration complications.

Of specific complications, perineal wound dehiscence is rare and affects 0.1 to 4.6 percent of women. Perineal laceration breakdown is often indicative of coexisting infection (Goldaber, 1993; Homsy, 1994; Ramin, 1994). In fact, one assessment model of perineal healing, the REEDA (redness,

edema, ecchymosis, discharge, and approximation) model, incorporates dehiscence as a potential sign of wound infection. Because these two are intimately related, their management is discussed together.

Repair Timing. The timeline for repair of perineal laceration dehiscence has shifted in recent years. Prior to the 1980s, reapproximation of a separated wound was delayed 3 to 4 months. This allowed infection and inflammation to clear and viable tissue to return to limit surgical failures (Mattingly, 1985). However, this operative advantage is weighed against impaired sexual function and urinary and bowel control dysfunction in the interim.

The evidence to guide this timing is limited. One Cochrane review examined the utility of early repair compared with healing by secondary intention for second-, third-, or fourth-degree perineal lacerations that had separated (Dudley, 2013). Unfortunately, the review included only one trial with 17 women (Christensen, 1994). The review concluded that surgical repair of perineal laceration breakdown is feasible. However, definitive evidence of benefits and risks is unclear.

Several authors have published case series describing their protocols for early repair of perineal wound dehiscence and their high rates of success (Arona, 1995; Hankins, 1990; Ramin, 1992). These repairs are categorized as "early," but they are not immediate repairs and require wound preparation prior to reconstruction. This period typically lasts 6 to 7 days. Several key steps involved with such early repair are highlighted subsequently.

Preoperative Management. Once the dehiscence is identified, the wound should be carefully inspected for signs of infection. Ramin and colleagues (1992) reported that the most common signs of infection in a cohort of women with separated perineal lacerations were pain (65 percent), purulent discharge (65 percent), and fever (15 percent). As previously mentioned, infection is often present in these wounds. Thus, preoperative antibiotics are administered, and most suggest parenteral administration. We typically recommend a broad-spectrum agent that covers gram-negative rods and anaerobes. With less-severe infection, outpatient oral antibiotic therapy can be administered (Arona, 1995). The remaining wound is opened, retained sutures are removed, and debridement of infected tissue is completed. Most often, this initial debridement is performed in the operating room and with substantial anesthesia. Subsequent daily wound care includes scrubbing, irrigation, and sharp debridement of the wound. Again, adequate patient analgesia is provided. Although authors recommend a mechanical bowel preparation prior to secondary closure if the rectal mucosa is involved, the utility of this practice has been questioned in other areas of the gynecologic and surgical literature. Currently, there are no substantial data on which to base this recommendation. Hence, we do not recommend bowel preparation in these patients.

Intraoperative Management. Once the surface of the wound is free of exudate and is covered with pink granulation tissue, it can be secondarily repaired. Prophylactic broad-spectrum antibiotics are administered preoperatively. Operative dissection is performed until all tissue layers have good mobility.

Importantly, the torn ends of the EAS often retract, so the fibrous tissue adjacent to the EAS should be properly identified and mobilized. This permits tissue approximation of all layers without tension.

The surgical steps mirror those of the primary repair. Notably, we favor an overlapping approach to secondary EAS repair. This is because some data show that at least in the first year, the overlapping technique may be associated with less anal incontinence.

Postoperative Management. This mirrors that following primary closure as described on page 330. We also typically prescribe the broad-spectrum antibiotic ampicillin coupled with clavulanate (Augmentin) or the regimen of ciprofloxacin (Cipro) plus metronidazole (Flagyl) orally for 7 to 10 days after repair. However, no peer-reviewed literature guides this decision.

Outcomes. Early approximation of perineal laceration breakdown was considered “successful” in 94 to 100 percent of patients. Success was defined as a well-healed laceration and continence of flatus and stool. Both Hankins and Arona reported cases of pinpoint rectovaginal fistulas. Two of the fistulas were successfully repaired with a rectal advancement flap, and the other fistula resolved spontaneously. Dyspareunia was observed in 5 to 10 percent of women in these series.

■ Subsequent Deliveries after OASIs

Women with prior OASIs are counseled regarding their higher risk of repeat OASIs in subsequent deliveries. For example, in one study of nearly 640,000 women, those who sustained OASIs at their first delivery had a fivefold higher risk of severe laceration compared with women without an OASIs at their first delivery (7.2 versus 1.3 percent) (Edozien, 2014). This finding is supported by other investigators (Baghestan, 2012; Elfaghi, 2004; Jangö, 2014; Spydslaug, 2005).

Therefore, if a woman elects a repeat vaginal delivery, other OASIs risk factors, such as operative vaginal delivery (especially forceps), occiput-posterior presentation, and midline episiotomy, should be considered carefully and discussed with the patient prior to labor. Together, the provider and patient can establish clear guidelines, expectations, and management strategies for each risk factor. For example, some women may elect vaginal delivery after a prior OASIs but would deviate from the plan to avoid an episiotomy.

Seventy percent of colon and rectal surgeons and 22 percent of obstetrician-gynecologists in the United Kingdom reported that they would recommend elective cesarean delivery to prevent anal incontinence in women with a prior OASIs (Fernando, 2002). A decision analysis to evaluate elective cesarean delivery in women with a prior OASIs found that 2.3 elective cesareans would be necessary to prevent one case of anal incontinence, and this policy would increase the elective cesarean rate by less than 2 percent (McKenna, 2003). They reported an 11-percent risk of maternal morbidity with elective cesarean delivery compared with a 4-percent risk with vaginal delivery. However, the prevalence of permanent anal incontinence was 44 percent. Accordingly, health-care providers and

patients should discuss the risks and benefits carefully. Women with transient anal incontinence after their first delivery have a one in six chance of developing long-term anal incontinence after the next delivery (Elfaghi, 2004; Hannah, 2004).

CONCLUSION

Perineal lacerations, whether spontaneous or surgical, are common during vaginal delivery. Most first- or second-degree lacerations heal easily with few sequelae. In contrast, third- or fourth-degree lacerations are associated with significant short- and long-term consequences. These higher-order injuries are also a primary risk factor for anal incontinence. Thus, obstetric providers strive to minimize each woman’s risk of OASIs by identifying her risk factors and modifying her delivery accordingly. In addition, patient discussions and counseling ideally begin early in pregnancy so that women fully understand the risks and benefits of various intrapartum interventions. Finally, if a perineal laceration does occur, steps to ensure an optimal repair and minimize complications are surgical goals.

REFERENCES

- Abramowitz L, Sobhani I, Ganasia R, et al: Are sphincter defects the cause of anal incontinence after vaginal delivery? Results of a prospective study. *Dis Colon Rectum* 43:590, 2000
- American College of Obstetricians and Gynecologists: Episiotomy. Practice Bulletin No. 71, April 2006, Reaffirmed 2015
- Andrews V, Sultan AH, Thakar R, et al: Occult anal sphincter injuries—myth or reality? *BJOG* 113:195, 2006
- Arona AJ, Al-Marayati L, Grimes DA, et al: Perineal lacerations after outpatient wound preparation. *Obstet Gynecol* 86:294, 1995
- Baghestan E, Irgens LM, Bordahl PE, et al: Risk of recurrence and subsequent delivery after obstetric anal sphincter injuries. *BJOG* 119:62, 2012
- Beckmann MM, Stock OM: Antenatal perineal massage for reducing perineal trauma. *Cochrane Database Syst Rev* 4:CD005123, 2013
- Belmonte-Montes C, Hagerman G, Vega-Yepez PA, et al: Anal sphincter injury after vaginal delivery in primiparous females. *Dis Colon Rectum* 44(9):1244, 2001
- Benavides L, Wu JM, Hundley AF, et al: The impact of occiput posterior fetal head position on the risk of anal sphincter injury in forceps-assisted vaginal deliveries. *Am J Obstet Gynecol* 192:1702, 2005
- Bharucha AE, Prichard D: Mediolateral episiotomy significantly reduces the risk of obstetric-associated anal sphincter injury (OASIS) in women who deliver via vacuum extraction. *Evid Based Med* 19(4):155, 2014
- Bofill JA, Rust OA, Schorr SJ, et al: A randomized prospective trial of the obstetric forceps versus the M-cup vacuum extractor. *Am J Obstet Gynecol* 175:1325, 1996
- Bradley MS, Kaminski RJ, Streitman DC, et al: Effect of rotation on perineal lacerations in forceps-assisted vaginal deliveries. *Obstet Gynecol* 122:132, 2013
- Bromberg MH: Presumptive maternal benefits of routine episiotomy. A literature review. *J Nurse Midwifery* 31:121, 1986
- Buppasiri P, Lumbiganon P, Thinkhamroj J, et al: Antibiotic prophylaxis for third and fourth degree perineal tear during vaginal childbirth. *Cochrane Database Syst Rev* 10:CD005125, 2014
- Burrell M, Dilgir S, Patton V, et al: Risk factors for obstetric anal sphincter injuries and postpartum anal and urinary incontinence: a case-control trial. *Int Urogynecol J* 26:383, 2015
- Carroli G, Mignini L: Episiotomy for vaginal birth. *Cochrane Database Syst Rev* 1:CD000081, 2009
- Chaliha C, Sultan AH, Kalia V, et al: Anal function: effect of pregnancy and delivery. *Am J Obstet Gynecol* 185:427, 2001
- Christensen S, Andersen G, Detlefsen GU, et al: [Treatment of episiotomy wound infections. Incision and drainage versus incision, curettage and sutures under antibiotic cover; a randomized trial]. [Danish]. *Ugesk Laeger* 156(34):4829, 1994
- Coats PM, Chan KK, Wilkins M, et al: A comparison between midline and mediolateral episiotomies. *BJOG* 87:408, 1980

- DeLee J: The prophylactic forceps operation. *Am J Obstet Gynecol* 1:34, 1920
- de Leeuw JW, de Wit C, Kuijken JP, et al: Mediolateral episiotomy reduces the risk for anal sphincter injury during operative vaginal delivery. *BJOG* 115:104, 2008
- de Vogel J, van der Leeuw-van Beek A, Gietelink D, et al: The effect of a mediolateral episiotomy during operative vaginal delivery on the risk of developing obstetrical anal sphincter injuries. *Am J Obstet Gynecol* 206:404.e1, 2012
- Dudley LM, Kettle C, Ismail KM: Secondary suturing compared to non-suturing for broken down perineal wounds following childbirth. *Cochrane Database Syst Rev* 9:CD008977, 2013
- Eddy A: Litigating and quantifying maternal damage following childbirth. *Clin Risk* 5(5):178, 1999
- Edozien LC, Gurol-Urganci I, Cromwell DA, et al: Impact of third and fourth degree perineal tears at first birth on subsequent pregnancy outcomes: a cohort study. *BJOG* 121:1695, 2014
- Elfaghi I, Johansson-Ernste B, Rydstroem H: Rupture of the sphincter ani: the recurrence rate in second delivery. *BJOG* 111:1361, 2004
- Eogan M, Daly L, O'Connell PR, et al: Does the angle of episiotomy affect the incidence of anal sphincter injury? *BJOG* 113:190, 2006
- Evers EC, Blomquist JL, McDermott KC, et al: Obstetrical anal sphincter laceration and anal incontinence 5–10 years after childbirth. *Am J Obstet Gynecol* 207:425.e1, 2012
- Faltin DL, Boulvain M, Floris LA, et al: Diagnosis of anal sphincter tears to prevent fecal incontinence: a randomized controlled trial. *Obstet Gynecol* 106:6, 2005
- Faltin D, Boulvain M, Irion O, et al: Diagnosis of anal sphincter tears by postpartum endosonography to predict fecal incontinence. *Obstet Gynecol* 95(5):643, 2000
- Farrell SA, Flowerdew G, Gilmour D, et al: Overlapping compared with end-to-end repair of complete third-degree or fourth-degree obstetric tears: three-year follow-up of a randomized controlled trial. *Obstet Gynecol* 120(4):803, 2012
- Faruq-Fosse H, Vendittelli F: [Can we reduce the episiotomy rate?]. [French]. *J Gynecol Obstet Biol Reprod (Paris)* 35:1S68, 2006
- Fenner DE, Genberg B, Brahma P, et al: Fecal and urinary incontinence after vaginal delivery with anal sphincter disruption in an obstetric unit in the United States. *Am J Obstet Gynecol* 189:1543, 2003
- Fernando RJ, Sultan AH, Kettle C, et al: Methods of repair of obstetric anal sphincter injury. *Cochrane Database Syst Rev* 12:CD002866, 2013
- Fernando RJ, Sultan AH, Kettle C, et al: Repair techniques for obstetric anal sphincter injuries: a randomized controlled trial. *Obstet Gynecol* 107(6):1261, 2006
- Fernando RJ, Sultan AH, Radley S, et al: Management of obstetric anal sphincter injury: a systematic review & national practice survey. *BMC Health Serv Res* 13:2, 2002
- Fodstad K, Staff AC, Laine K: Effect of different episiotomy techniques on perineal pain and sexual activity 3 months after delivery. *Int Urogynecol J* 25:1629, 2014
- Frankman EA, Wang L, Bunker CH, et al: Episiotomy in the United States: has anything changed? *Am J Obstet Gynecol* 200:573.e1, 2009
- Friedman AM, Ananth CV, Prendergast E, et al: Variation in measures and factors associated with use of episiotomy. *JAMA* 313:197, 2015
- Frudinger A, Ballon M, Taylor SA, et al: The natural history of clinically unrecognized anal sphincter tears over 10 years after first vaginal delivery. *Obstet Gynecol* 111:1058, 2008
- Geranmayeh M, Rezaei Habibabadi Z, et al: Reducing perineal trauma through perineal massage with vaseline in second stage of labor. *Arch Gynecol Obstet* 285(1):77, 2012
- Gerrits DD, Brand R, Gravenhorst JB: The use of an episiotomy in relation to the professional education of the delivery attendant. *Eur J Obstet Gynecol Reprod Biol* 56:103, 1994
- Glazener CMA, Abdalla M, Stroud P, et al: Postnatal maternal morbidity: extent, causes, prevention and treatment. *BJOG* 102:286, 1995
- Goldaber KG, Wendel PJ, McIntire DD, et al: Postpartum perineal morbidity after fourth degree perineal repair. *Am J Obstet Gynecol* 168:489, 1993
- Gonzalez-Díaz E, Moreno Cea L, Fernández Corona A: Trigonometric characteristics of episiotomy and risks for obstetric anal sphincter injuries in operative vaginal delivery. *Int Urogynecol J* 26:235, 2015
- Gupta JK, Hofmeyr GJ: Position in the second stage of labour for women without epidural anaesthesia. *Cochrane Database Syst Rev* 5:CD002006, 2012
- Haadem K, Dahlstrom JA, Ling L, et al: Anal sphincter function after delivery rupture. *Obstet Gynecol* 70(1):53, 1987
- Haadem K, Dahlstrom JA, Lingman G: Anal sphincter function after delivery: a prospective study in women with sphincter rupture and controls. *Eur J Obstet Gynecol Reprod Biol* 35(1):7, 1990
- Handa VL, Blomquist JL, McDermott KC, et al: Pelvic floor disorders after vaginal birth: effect of episiotomy, perineal laceration, and operative birth. *Obstet Gynecol* 119(2 Pt 1):233, 2012
- Hankins GD, Hauth JC, Gilstrap LC III, et al: Early repair of episiotomy dehiscence. *Obstet Gynecol* 75:48, 1990
- Hannah ME, Whyte H, Hannah WJ, et al: Maternal outcomes at 2 years after planned cesarean section versus planned vaginal birth for breech presentation at term: the international randomized Term Breech Trial. *Am J Obstet Gynecol* 191:917, 2004
- Haylen BT, de Ridder D, Freeman RM, et al: An International Urogynecological Association (IUGA)/International Continence Society (ICS) joint report on the terminology for female pelvic floor dysfunction. *Int Urogynecol J* 21(1):5, 2010
- Hirsch E, Haney EI, Gordon TE, et al: Reducing high-order perineal laceration during operative vaginal delivery. *Am J Obstet Gynecol* 198(6):668.e1, 2008
- Homsí R, Daikoku NH, Littlejohn J, et al: Episiotomy: risks of dehiscence and rectovaginal fistula. *Obstet Gynecol Surv* 49(12):803, 1994
- Howden NL, Weber AM, Meyn LA: Episiotomy use among residents and faculty compared with private practitioners. *Obstet Gynecol* 103:114, 2004
- Hueston WJ: Factors associated with the use of episiotomy during vaginal delivery. *Obstet Gynecol* 87:1001, 1996
- Jangö H, Langhoff-Roos J, Rosthøj S, et al: Modifiable risk factors of obstetric anal sphincter injury in primiparous women: a population based cohort study. *Am J Obstet Gynecol* 210:59.e1, 2014
- Jha S, Sultan AH: Obstetric anal sphincter injury: the changing landscape. *BJOG* 122(7):931, 2015
- Johanson JF, Lafferty J: Epidemiology of faecal incontinence: the silent affliction. *Am J Gastroenterol* 91:33, 1996
- Johnson JH, Figueroa R, Garry D, et al: Immediate maternal and neonatal effects of forceps and vacuum-assisted deliveries. *Obstet Gynecol* 103:513, 2004
- Kalis V, Laine K, de Leeuw JW, et al: Classification of episiotomy: towards a standardisation of terminology. *BJOG* 119(5):522, 2012
- Karbanova J, Rusavy Z, Betincova L, et al: Clinical evaluation of early postpartum pain and healing outcomes after mediolateral versus lateral episiotomy. *Int J Gynaecol Obstet* 127(2):152, 2014a
- Karbanova J, Rusavy Z, Betincova L, et al: Clinical evaluation of peripartum outcomes of mediolateral versus lateral episiotomy. *Int J Gynaecol Obstet* 124(1):72, 2014b
- Kettle C, Dowswell T, Ismail KMK: Continuous and interrupted suturing techniques for repair of episiotomy or second-degree tears. *Cochrane Database Syst Rev* 11:CD000947, 2012
- Kitzinger S (ed): *Episiotomy: Physical and Emotional Aspects*. London, National Childbirth Trust, 1981
- Koelbl H, Nitti V, Baessler K, et al: Pathophysiology of urinary incontinence, faecal incontinence and pelvic organ prolapse. In Abrams P, Cardozo L, Khoury, et al (eds): *Incontinence*, 4th ed. Plymouth, Health Publication Ltd, 2009, p 293
- Lewicky-Gaup C, Leader-Cramer A, Johnson LL, et al: Wound complications after obstetric anal sphincter injuries. *Obstet Gynecol* 125(5):1088, 2015
- Low LK, Seng JS, Murland TL, et al: Clinician specific episiotomy rates: impact on perineal outcomes. *J Midwifery Womens Health* 45:87, 2000
- Main EK: New perinatal quality measures from the National Quality Forum, the Joint Commission and the Leapfrog Group. *Curr Opin Obstet Gynecol* 21(6):532, 2009
- Mattingly RF, Thompson JD: Anal incontinence and rectovaginal fistulas. In Mattingly RF, Thompson JD (eds), *TeLinde's Operative Gynecology*, 6th ed. Philadelphia, JB Lippincott, 1985
- McKenna DS, Ester JB, Fischer JR: Elective cesarean delivery for women with a previous anal sphincter rupture. *Am J Obstet Gynecol* 189:1251, 2003
- Mei-dan E, Walfisch A, Raz I, et al: Perineal massage during pregnancy: a prospective controlled trial. *Isr Med Assoc J* 10(7):499, 2008
- Mellgren A, Jensen LL, Zetterstrom JP, et al: Long-term cost of fecal incontinence secondary to obstetric injuries. *Dis Colon Rectum* 42:857, 1999
- National Health Service Litigation Authority: Ten years of maternity claims: an analysis of NHS Litigation Authority data. London, NHS Litigation Authority, 2012
- Newman MG, Lindsay MK, Graves W: The effect of epidural analgesia on rates of episiotomy use and episiotomy extension in an inner-city hospital. *J Matern Fetal Med* 10:97, 2001
- Nordenstam J, Mellgren A, Altman D, et al: Immediate or delayed repair of obstetric anal sphincter tears—a randomised controlled trial. *BJOG* 115(7):857, 2008
- Ould F: *A Treatise of Midwifery*. Dublin, O. Nelson & C. Connor, 1742
- Ponkey SE, Cohen AP, Heffner LJ, et al: Persistent fetal occiput posterior position: obstetric outcomes. *Obstet Gynecol* 101:915, 2003
- Ramin SM, Gilstrap LC III: Episiotomy and early repair of dehiscence. *Clin Obstet Gynecol* 37(4):816, 1994
- Ramin SM, Ramus RM, Little BB, et al: Early repair of episiotomy dehiscence associated with infection. *Am J Obstet Gynecol* 167:1104, 1992

- Räsänen S, Vehviläinen-Julkunen K, Cartwright R, et al: Vacuum-assisted deliveries and the risk of obstetric anal sphincter injuries—a retrospective register-based study in Finland. *BJOG* 119:1370, 2012
- Richter HE, Nager CW, Burgio KL, et al: Incidence and predictors of anal incontinence after obstetric anal sphincter injury in primiparous women. *Female Pelvic Med Reconstr Surg* 21(4):182, 2015
- Robinson JN, Norwitz ER, Cohen AP, et al: Predictors of episiotomy use at first spontaneous vaginal delivery. *Obstet Gynecol* 96:214, 2000
- Rogers RG, Fenner DE: Rectovaginal fistulas. In Sultan AH, Thakar R, Fenner DE (eds): *Perineal and Anal Sphincter Trauma*. London, Springer, 2007, p 168
- Royal College of Obstetricians and Gynaecologists: Management of third and fourth degree perineal tears following vaginal delivery. Guideline No 29. London, RCOG, 2007
- Rygh AB, Korner H: The overlap technique versus end-to-end approximation technique for primary repair of obstetric anal sphincter rupture: a randomized controlled study. *Acta Obstet Gynecol Scand* 89(10):1256, 2010
- Sagi-Dain L, Sagi S: Morbidity associated with episiotomy in vacuum delivery: a systematic review and meta-analysis. *BJOG* 122:1073, 2015
- Sleep J: Perineal care: a series of five randomised controlled trials. In Robinson S, Thompson A (eds): *Midwives, Research and Childbirth*, Vol 2. London, Chapman and Hall, 1991
- Spydslaug A, Trogstad LI, Skrondal A, et al: Recurrent risk of anal sphincter laceration among women with vaginal deliveries. *Obstet Gynecol* 105:307, 2005
- Stamp G, Kruzins G, Crowther C: Perineal massage in labour and prevention of perineal trauma: randomised controlled trial. *BMJ* 322(7297):1277, 2001
- Stedenfeldt M, Pirhonen J, Blix E, et al: Episiotomy characteristics and risks for obstetric anal sphincter injuries: a case-control study. *BJOG* 119:724, 2012
- Stock L, Basham E, Gossett DR, et al: Factors associated with wound complications in women with obstetric anal sphincter injuries (OASIS). *Am J Obstet Gynecol* 208:327.e1, 2013
- Sultan AH, Kamm MA, Hudson CN: Obstetric perineal trauma: an audit of training. *J Obstet Gynaecol* 15:19, 1995
- Sultan AH, Kamm MA, Hudson CN, et al: Third degree obstetric anal sphincter tears: risk factors and outcome of primary repair. *BMJ* 308:887, 1994
- Sultan AH, Kamm MA, Hudson CN, et al: Anal sphincter disruption during vaginal delivery. *N Engl J Med* 329:1905, 1993
- Taliaferro RM: Rigidity of soft parts: delivery effected by incision in the perineum. *Stethoscope Va Med Gazette* 2:383, 1852
- Tetzschner T, Sorenson M, Lose G, et al: Anal and urinary incontinence in women with obstetric anal sphincter rupture. *BJOG* 103:1034, 1996
- Thacker SB, Banta HD: Benefits and risks of episiotomy: an interpretive review of the English language literature, 1860–1980. *Obstet Gynecol Surv* 38:322, 1983
- Thompson DJ: No episiotomy? *Aust N Z J Obstet Gynaecol* 27:18, 1987
- Uustal Fornell EK, Berg G, Hallbook O, et al: Clinical consequence of anal sphincter rupture during vaginal delivery. *J Am Coll Surg* 183:553, 1996
- Webb DA, Culhane J: Hospital variation in episiotomy use and the risk of perineal trauma during childbirth. *Birth* 29:132, 2002
- Weber AM, Meyn L: Episiotomy use in the United States 1979–1997. *Obstet Gynecol* 100(6):1177, 2002
- Williams MK, Chames MC: Risk factors for the breakdown of perineal laceration repair after vaginal delivery. *Am J Obstet Gynecol* 195:7559, 2006
- Zetterstrom J, Mellgren A, Jensen LJ, et al: Effect of delivery on anal sphincter morphology and function. *Dis Colon Rectum* 42:1253, 1999
- Zuspan FP, Quilligan EJ (eds): *Management of delivery trauma*. In Douglas-Stromme *Operative Obstetrics*, 5th ed. East Norwalk, Appleton & Lange, 1988, p 540

CHAPTER 21

Vaginal Breech Delivery

BACKGROUND	335
EPIDEMIOLOGY	336
SELECTION CRITERIA	337
FIRST-STAGE LABOR	338
SECOND-STAGE LABOR	338
PRETERM BREECH	346
EXTERNAL CEPHALIC VERSION	347
CESAREAN DELIVERY	348
SUMMARY	348

Just more than 15 years have elapsed since the publication of the Term Breech Trial. This is the largest randomized trial to compare planned vaginal and planned cesarean delivery for women carrying breech fetuses at term (Hannah, 2000). This monumental effort involved 121 centers in 26 countries. Its results provide many of the core tenets that shape current delivery practices. The authors interpreted their findings to indicate that planned cesarean delivery was the safest method to minimize neonatal morbidity and mortality rates. A secondary conclusion showed no difference in maternal morbidity rates between the two delivery routes. Obviously, they did not consider an abdominal incision and hysterotomy to be a morbid outcome.

The intent of this chapter is not to heap criticism on the conduct or interpretation of the Term Breech Trial—indeed, this has been done by others (Glezerman, 2006; Hauth, 2002; Keirse, 2002; Kotaska, 2004). But still, not all breech-presenting fetuses warrant cesarean delivery. Highly satisfactory outcomes

of vaginal breech delivery have been documented at several centers since the Term Breech Trial. That said, achieving an atraumatic vaginal breech delivery for the fetus and the mother, in appropriately selected cases, requires knowledge, skill, and judgment on the part of the attendant. In this chapter, we present a conservative protocol to assist in selecting candidates for vaginal delivery of the term breech fetus and to emphasize the technical aspects of delivery that should optimize outcome.

Most reports of vaginal breech delivery focus on selection criteria and outcomes. Very little, if any, discussion of technique is provided. A review of 100 years of obstetric manuscripts and textbooks yields disparate views on what constituted proper technique for vaginal breech delivery (Yeomans, 2012). The approach presented here reflects this academic review and many combined years of clinical practice. At the same time, however, there is room for disagreement at almost every point of technique.

Even if the reader does not plan to offer vaginal breech delivery in his or her practice, many technical descriptions are relevant for cesarean delivery of the breech-presenting fetus. Moreover, it is undeniable that some women with a breech fetus may present with labor so advanced that it precludes cesarean delivery (Gilstrap, 2002). Others may refuse cesarean delivery, and in some low-resource settings, the option of cesarean delivery may not be readily available. Thus, the ability to safely deliver the breech fetus is an essential obstetric skill.

BACKGROUND

For the breech-presenting fetus, maternal morbidity and mortality rates are lower with vaginal birth compared with cesarean delivery. The converse is true for the fetuses, who experience higher morbidity and mortality rates compared with their vertex counterparts. Two of the leading contributors to that increase are prematurity and congenital malformations. Therefore, the degree to which mode of delivery increases morbidity and mortality rates is a key question. As noted, not all breeches

require cesarean delivery. A much stronger case can be made that not all breeches are candidates for vaginal delivery.

Thus, a balance between maternal and fetal outcomes must exist and is guided by evidence-based data and clinical expertise. Virtually every article that endorses vaginal breech delivery as a safe option similarly stresses the requirement that an experienced provider must be present as either the primary operator or the senior supervisor. Unfortunately, the pendulum has swung so far in the direction of planned cesarean delivery that currently most training programs provide insufficient case-loads to ensure that today's graduates will ever be certified as "experienced providers." As described in Chapter 6, simulation training may help teach the steps of emergency vaginal breech delivery. However, the ability of simulation to fulfill credentialing requirements is doubtful.

A single-author report by Graves and colleagues (1980) illustrates how that pendulum began to swing 20 years before publication of the Term Breech Trial. One four-person practice accumulated 141 singleton vaginal breech deliveries in 20 years. In the first 10 years, the cesarean delivery rate was 5 percent, but in the final 5 years, the rate had increased to 71 percent. Seven of eight perinatal deaths were in the 103 women undergoing vaginal delivery. Of these seven, three fetuses weighed <1000 g, three had congenital anomalies, and one footling breech weighed 1250 g. These results confirm the previous statement regarding the importance of prematurity and congenital malformations as causes of perinatal mortality. Every member of Dr. Graves' group was well trained in vaginal breech delivery, but the impressive evolution in mode of delivery selection during the two decades merely foreshadowed national trends. By the time randomization for the Term Breech Trial was initiated, the cesarean delivery rate for breech presentation in the United States already exceeded 80 percent. This again echoes concerns regarding the availability of providers experienced in vaginal breech delivery.

EPIDEMIOLOGY

■ Breech Fetus Rates

The frequency of breech presentation at term is 3 to 4 percent. Of these fetuses, approximately 65 percent are frank, 5 percent are complete, and 30 percent are incomplete (Graves, 1980). Breech presentation is more common in preterm fetuses and is roughly inversely proportional to gestational age. In preterm fetuses, the proportions of frank and incomplete are reversed (Seeds, 1982). Older studies found a 5-percent incidence of hyperextended head among term breech fetuses. Because of their appearance on radiographs, the colloquial terms *flying fetus* or *stargazing fetus* were coined. This finding warrants cesarean delivery because of a significant risk for cervical spine injury with vaginal birth (Caterini, 1975).

■ Neonatal Morbidity

More than 45 years ago, at a time when many vaginal breech deliveries were still being performed, a group of investigators at the University of Michigan reported on the frequency and mechanisms of fetal trauma during vaginal breech delivery (Tank, 1971). They concluded that certain injuries resulted from manipulations

TABLE 21-1. Fetal Organs Injured in Breech Delivery

Brain
Cervical spine
Liver
Adrenal
Spleen
Bladder
Long bones
Brachial plexus

used to aid delivery. In order of frequency from highest to lowest, the organs injured were brain, spinal cord, liver, adrenal glands, and spleen. Other injuries involved are shown in [Table 21-1](#). Important lessons regarding technique of vaginal breech delivery can be learned from this list and are highlighted in the section on technique (p. 339). Of note, the composite outcome for neonatal morbidity used in the Term Breech Trial included several outcomes not directly related to trauma or technique ([Table 21-2](#)). Some of these morbidities are likely transient and not indicative of long-term outcome. In fact, in the 2-year follow-up study of infants from the Term Breech Trial, planned vaginal delivery was not associated with a greater risk of infant death or neurodevelopmental delay compared with planned cesarean delivery (Whyte, 2004). In each group of this trial, there was only one death beyond 28 days of life. There were 13 children with neurodevelopmental delay from the planned cesarean delivery group compared with only seven from the planned vaginal delivery group.

■ Maternal Morbidity

Following publication of the Term Breech Trial, the cesarean delivery rate in The Netherlands for term singleton breeches

TABLE 21-2. Neonatal Morbidity for the Composite Outcome in the Term Breech Trial^a

Birth Trauma
Subdural, intracranial, or intraventricular hemorrhage
Spinal cord injury
Skull fracture
Peripheral nerve injury
Genital injury
Seizures at <24 hours of life
Apgar score <4 at 5 minutes
Cord blood base deficit >15 mmol/L
Tube feeding for >4 days
Hypotonia for >2 hours
Stupor, decreased pain response, or coma
Intubation and ventilation >24 hours
Admission to the intensive care unit

^a1 or more of the above qualified as "serious neonatal morbidity."

Data from Hannah, 2000.

increased from 57 percent in 2000 to 81 percent in 2001 (Schutte, 2007). Four mothers died after elective cesarean delivery for breech presentation between 2000 and 2002. This yields a case fatality rate of 0.47 per 1000 operations. Two women died from pulmonary embolism, which more commonly follows cesarean delivery than vaginal birth. Two other women died of sepsis, also seen more often after cesarean delivery. Moreover, for the 547 nulliparas who underwent planned cesarean delivery in the Term Breech Trial, the likelihood that their subsequent deliveries would be repeat cesarean was greater (Hannah, 2000). As a correlate and described in Chapter 25 (p. 415), the rates of adjacent organ injury, placenta previa, placenta accreta, and cesarean hysterectomy all rise with the number of repeat cesarean deliveries. Clearly, maternal outcome deserves consideration in selecting the route of delivery for breech fetuses at term.

SELECTION CRITERIA

■ Selection Overview

For clinicians who offer women the opportunity for planned vaginal breech delivery, many published protocols assist in choosing appropriate candidates. These protocols all share the same two objectives, namely, maximize the likelihood of vaginal delivery and minimize fetal risk. One elaborate template is provided by the Society of Obstetricians and Gynecologists of Canada (Kotaska, 2009). On close examination, their approach is conservative for some recommendations and liberal for others. As a conservative example, induction of labor, even in an otherwise qualified candidate, is not recommended. But more liberally, radiologic pelvimetry is not considered necessary for a safe trial of labor. **Table 21-3** has some prerequisites that many find reasonable. Notably, each criterion has acceptable alternatives, which allow practice to be individualized for a given clinical setting.

Factors that support a successful vaginal breech delivery should be enumerated. One equation for this calls attention

TABLE 21-3. Selection Criteria for Planned Vaginal Breech Delivery

Clinically adequate maternal pelvis
Estimated fetal weight 2000–4000 g
Frank or complete breech
Fetal head flexed or military position
Absence of fetal anomalies that would preclude vaginal delivery
Experienced operator/supervisor
Patient consent

to the difference between selection criteria and the conduct of labor and delivery (Yeomans, 2012):

$$\text{Vaginal breech delivery (VBD) rate} = \frac{\text{Attempted VBD}}{\text{No. term breeches}} \times \frac{\text{Successful VBD}}{\text{Attempted VBD}}$$

With this, the *attempted vaginal breech delivery (VBD)* rate is highly variable, as shown in **Table 21-4**, and it is near zero in many centers in the United States. In centers that evaluate breech presentations for possible planned vaginal delivery, the attempted VBD rate will depend on the liberalness or restrictiveness of their selection criteria. The *successful vaginal breech delivery* rate shows less variability. It is affected to a greater degree by labor management, interpretation of fetal heart rate tracings, conduct of second-stage labor, and willingness to perform maneuvers such as traction in the groin, Pinard maneuver, and total breech extraction. Note that in **Table 21-4**, not all single-center studies clarify whether the category of cesarean delivery before labor applied to both indicated and purely elective cesarean deliveries. That is, it is unclear whether women assigned to the planned cesarean delivery group were suitable candidates for vaginal delivery but chose not to attempt vaginal birth or whether cesarean delivery was performed for recognized indications. Some of the latter include prior cesarean delivery, incomplete breech presentation, or suspected macrosomia, to

TABLE 21-4. Route of Delivery and Neonatal Outcomes from Reports Published after the Term Breech Trial

Author, Year	Total Breech (n)	Prelabor CD	Allowed TOL	Labor CD	VBD	Perinatal Morbidity		Perinatal Mortality	
						VBD	CD	VBD	CD
Lashen, 2002	841	349 (42%)	492 (58%)	238 (48%)	254 (52%)	—	—	2	0
Krupitz, 2005	809	427 (53%)	382 (47%)	98 (26%)	284 (74%)	0.5%	0%	0	0
Pradhan, 2005	1433	552 (38%)	881 (62%)	465 (53%)	416 (47%)	5.9%	0.9%	3	1
Giuliani, 2002	699	218 (31%)	481 (69%)	129 (29%)	352 (71%)	2.3%	0.5%	0	0
Alarab, 2004	641	343 (54%)	298 (46%)	152 (51%)	146 (49%)	0.7%	0%	3	0
Goffinet, 2006	8105	5579 (69%)	2526 (31%)	730 (29%)	1796 (71%)	1.6%	1.4%	2	8
Hopkins, 2007	725	511 (70%)	214 (30%)	76 (36%)	138 (64%)	—	—	0	0
Michel, 2011	1133	711 (63%)	422 (37%)	68 (16%)	354 (84%)	0.5%	0.7%	0	1
Toivonen, 2012	751	497 (66%)	254 (34%)	80 (31%)	174 (69%)	1.2%	0.2%	0	0
Borbolla Foster, 2014	766	523 (68%)	243 (32%)	102 (42%)	141 (58%)	1.6%	0.4%	0	0

CD = cesarean delivery; TOL = trial of labor; VBD = vaginal breech delivery.

name a few. This question of elective or indicated was eliminated by the randomized design of the Term Breech Trial.

■ Specific Criteria

Many of the prerequisites listed in Table 21-3 can be debated. Of these, the practice of obtaining adequate pelvic measurements by radiographic pelvimetry is the most contested. Some rely solely on clinical pelvimetry, supplemented by the observation of good progress in labor. In a study from France, one of the few remaining countries still advocating vaginal breech delivery, more than 80 percent of women selected for vaginal delivery had radiographic pelvimetry (Goffinet, 2006). In contrast, Canadian guidelines state that radiographic pelvimetry is not necessary (Kotaska, 2009).

If radiographic pelvimetry is employed, computed tomography (CT) is the preferred technique. From a study by Collea and coworkers (1980), minimum measurements are an anteroposterior (AP) inlet of 11 cm; transverse inlet of 11.5 cm; AP midplane of 11.5 cm; and transverse midplane of 10 cm. A review of these planes is found in Chapter 3 (p. 45). Other investigators have used slightly different thresholds or have combined pelvimetry with sonographic measurements of the biparietal diameter (Azria, 2012; Christian, 1990; Michel, 2011). For a more complete discussion of clinical pelvimetry, the reader is referred to Yeomans (2006).

If the pelvis is clinically adequate and the fetus is appropriately sized, some women will still develop dystocia due to inadequate contraction force. In this circumstance, labor augmentation with oxytocin is considered acceptable by some. In other obstetric units in the United States, oxytocin is not employed for this indication.

The lower and upper limits of estimated fetal weight are also controversial. Collea and coworkers (1980) used a lower limit of 2500 g. Albrechtsen and associates (1997) used an upper threshold of 4500 g. The lower limit strives to exclude growth-restricted and preterm fetuses. The upper threshold aims to avert fetopelvic disproportion (Kotaska, 2009). Our suggested limits are listed in Table 21-3.

Almost all protocols for planned vaginal breech delivery mandate that the breech configuration be either frank or complete. An exception is the report by Borbolla Foster and colleagues (2014) in which footling breech delivery was considered acceptable. The main concern with an incomplete or with a footling breech is the greater risk of associated cord prolapse in labor. However, in some cases, a woman will present at complete dilation with membranes either intact or ruptured and with feet in the vagina or outside the introitus. Vaginal delivery may be appropriate in this circumstance and may require total breech extraction.

The last two criteria from Table 21-3, experienced operator and patient consent, may ultimately exclude more planned vaginal breech deliveries than all the rest combined. Chinnock and Robson (2007) presented data from a survey showing that only 11 percent of final-year trainees in Australia planned to offer vaginal breech delivery to their patients. As for patient consent, decision making depends in large part on the manner in which evidence-based information is presented. It is appropriate to stress the negative maternal consequences that a first cesarean

delivery poses to the maternal reproductive future. For women who meet selection criteria, this allows decisions to be based on both potential maternal and neonatal outcomes.

FIRST-STAGE LABOR

Once a candidate for vaginal breech delivery has been selected, then spontaneous labor is usually awaited, however, in some centers labor is induced. External version is another option to address breech presentation and is discussed on page 347. During the course of a trial of labor for a breech-presenting term fetus, indicated cesarean delivery is ultimately necessary in 20 to 50 percent of cases. This broad range illustrates that elements of skilled labor management must be considered. Namely, the two leading reasons that lead to intrapartum cesarean delivery of a well-selected breech are fetal distress and dystocia.

Regarding the first instance, electronic fetal monitoring is recommended throughout labor. Importantly, many category II tracings can be tolerated without immediate operative intervention, provided that moderate beat-to-beat variability is maintained.

In the second instance, and discussed earlier, in the absence of dystocia, oxytocin augmentation is acceptable (Kotaska, 2009). Prohibiting oxytocin use for either induction or augmentation will limit the rate of successful vaginal breech delivery (Alarab, 2004).

Intrapartum consultation with anesthesia staff is recommended. Epidural analgesia has advantages, especially during the manipulation needed for delivery of the fetal legs, arms, and head. Early epidural placement is reasonable to accommodate possible rapid labor progression or urgent cesarean delivery.

With a vertex presentation, engagement is defined by passage of the fetal biparietal diameter through the pelvic inlet. With a breech presentation, engagement takes place as the bitrochanteric diameter passes through the inlet. Measured along the long axis of the fetus, the distance from the buttocks to fetal bitrochanteric diameter is shorter than the distance from the vertex to the biparietal diameter in cephalic presenting fetuses. For this reason, engagement of the breech can be confidently assumed when the buttocks are palpated at the level of the ischial spines. At or beyond this time, prolapse of the umbilical cord is distinctly uncommon with frank or complete breeches.

SECOND-STAGE LABOR

This is a period that requires both vigilance and experience as the breech descends deep into the pelvis. Both Kotaska (2009) and Goffinet (2006) and their colleagues recommend a passive second stage of labor with no active pushing once a completely dilated cervix is identified. They allow this passive phase to last for 60 to 90 minutes. Once active pushing begins, its duration is limited to no more than 60 minutes, unless delivery is imminent.

Vaginal breech delivery should be performed in an operating room with equipment and personnel ready for immediate cesarean delivery should the need arise. One method is to use candy-cane stirrups attached to a metal operating table for vaginal breech delivery. Compared with booted support stirrups, these often abduct the thighs to a greater degree to provide needed vaginal access and manipulation space. Typically, epidural

TABLE 21-5. Technical Considerations for Vaginal Breech Delivery

Do	Do Not
Await spontaneous delivery to the umbilicus ^a	Pull on the fetus prematurely
Perform episiotomy as indicated	Grasp the fetal abdomen
Grasp the fetal pelvis over bony prominences (sacrum and iliac crests)	Put transverse pressure on long bones
Apply finger pressure parallel to long bones	Allow the fetus to rotate ventrally
Use forceps for the aftercoming head	Attempt delivery through an incompletely dilated cervix
If forceps not available, maintain flexion of aftercoming head with suprapubic pressure	Panic

^aExcept under unusual circumstances (see text).

analgesia is already in place, but anesthesia personnel should be present, as should an experienced neonatal resuscitation team.

During the normal cardinal movements for vaginal breech delivery, internal rotation will align the fetal bitrochanteric diameter with the anteroposterior diameter of the maternal pelvis. In this position, the fetal back faces left or right. The corresponding positions would be designated left or right sacrum transverse (LST or RST), respectively.

With continued fetal descent, the anterior hip will appear first, but the posterior hip will deliver first, barring any operator interference. With normal cardinal movements, the dorsum will rotate anteriorly. If this does not occur spontaneously, the operator should intervene to complete this rotation.

■ Partial Breech Extraction

Of all breeches that are selected for planned vaginal delivery, those that have hips flexed and legs extended, that is, frank breeches, are by far the most common. Although still a remote possibility, cord prolapse is unlikely because the breech occludes the pelvis almost as effectively as the vertex.

By the time most frank breeches have descended to the pelvic floor, the bituberous diameter is either anteroposterior or in a left- or right-oblique relationship to the maternal pelvis. Some recommend episiotomy as an important adjunct to any vaginal breech delivery (Cunningham, 2014). However, vaginally parous women with a relaxed introitus and a small-to-average sized fetus are unlikely to benefit from an episiotomy. Thus, some reserve episiotomy for certain situations that include nulliparity, a tight introitus, or a relatively large fetus (Table 21-5). The largest diameter of the breech can be permitted to nearly fill the introitus with maternal expulsive effort before the decision is made for performing an episiotomy. Right-handed operators should almost always opt for a right mediolateral episiotomy. Merits to mediolateral versus midline episiotomy are outlined in Chapter 20 (p. 323). A sufficient incision depth of more than 1 inch allows for spontaneous delivery of the buttocks with just a few pushes. Importantly, blood loss can be appreciable if the episiotomy is cut too soon (Moir, 1971).

The posterior hip is usually born first over the intact or incised perineum. In easy cases, no assistance by the operator is necessary or desirable. Once the anterior hip delivers, the operator can encourage the dorsum of the fetus to rotate anteriorly and prepare to assist delivery of the legs. Even this minimal

amount of interference is sometimes unnecessary when the woman is pushing effectively.

For delivery of the fetal left leg, the operator places two fingers of his or her left hand on the medial aspect of the fetus's left leg and parallel to the femur. This maneuver is initiated from below the fetal buttocks and in the midsagittal plane. Once positioned, the hand externally rotates the fetal left hip to move the left leg laterally and away from the fetal body (Fig. 21-1). Often, this will allow the leg to deliver, but light pressure in the popliteal fossa can induce the leg to flex, bringing the foot within reach. A similar procedure is then followed using two fingers of the right hand on the fetal right leg. Importantly, fingers should not be placed on top of the legs. Downward pressure can hyperextend the knee and risk femur fracture. For some reason, this is a commonly encountered misstep. At this point, the lower half of the body is delivered.

In some cases, the frank breech is visible but cannot be pushed out by voluntary maternal efforts. In this instance, the

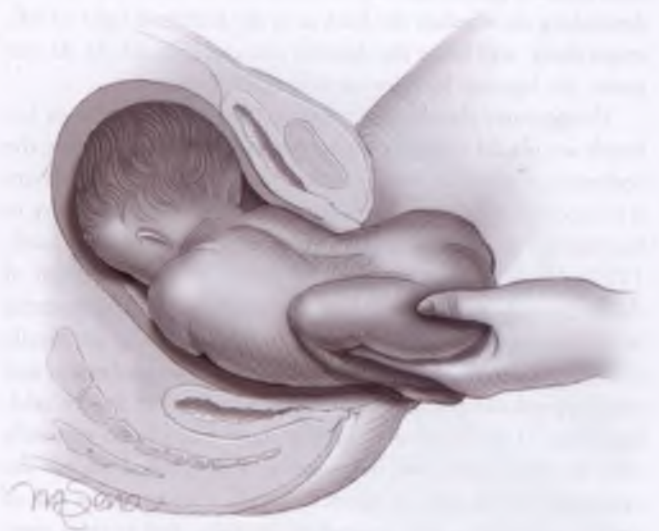

FIGURE 21-1 To deliver the left leg, two fingers of the operator's left hand are placed beneath and parallel to the femur. The thigh is then slightly abducted and pressure from the fingertips in the popliteal fossa should produce flexion of the knee and bring the foot within reach. The foot is then grasped and gentle traction exerted to deliver the entire leg outside the vagina. A similar procedure is followed on the right.

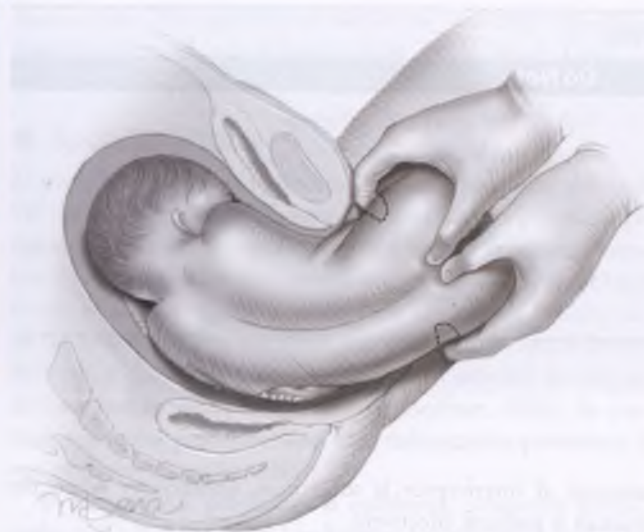

FIGURE 21-2 If the fetal hips do not spontaneously deliver, index fingers of each hand are placed in the anterior (more accessible) and posterior groin. Outward traction is then exerted.

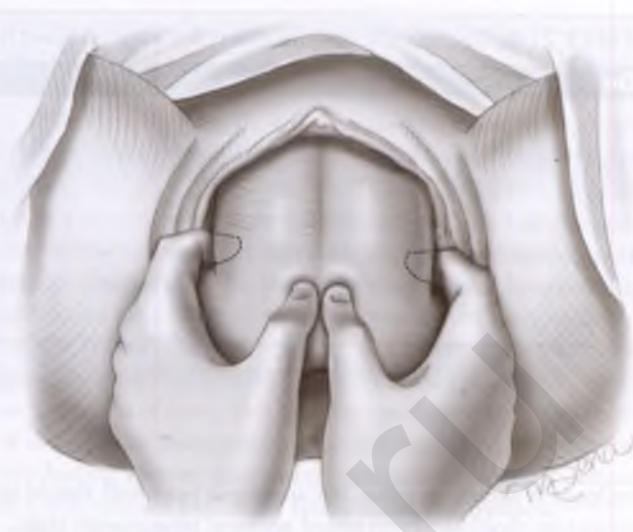


FIGURE 21-3 Once the fetal hips are delivered, the operator rotates the fetus into a dorsum anterior position. Delivery of the lower body is then completed as outlined in Figure 21-1.

operator can place either the index or middle finger in the fetal groin crease that lies anteriorly. To clarify, this fetal groin is the one that lies closest to the maternal symphysis pubis. Some but not all authors advocate using the other hand to grasp and brace the wrist of the operating hand (Douglas, 1976). With descent and rotation, the posterior-positioned fetal groin will become accessible. This allows traction with a finger in each groin crease to deliver the breech (Fig. 21-2). In our experiences, groin traction such as this is employed in a third or more of cases. In contrast, however, Moir and Myerscough (1971) found it “seldom necessary.” Epidural analgesia, used in almost all cases of vaginal breech delivery by most, may limit maternal expulsive effort and make traction assistance necessary. With a finger in each groin, a gentle turn either clockwise or counterclockwise, depending on whether the back is to the maternal right or left, respectively, will bring the dorsum anterior (Fig. 21-3). At this point, the legs can be released as described earlier.

The operator should take great care to ensure that his or her hands are placed correctly on bony prominences. Grasping the abdomen of a breech fetus at either vaginal or cesarean delivery is to be condemned (see Table 21-5). Such actions risk injury to the fetal liver, adrenal glands, spleen, and urinary bladder (Tank, 1971). Many authors recommend wrapping the lower half of the body with a wet towel, but this practice obscures essential bony landmarks. Instead, the thumbs of both hands are ideally placed over the sacrum, such that both the interphalangeal and metacarpophalangeal joints of each thumb meet in the midline (Fig. 21-4). The index fingers should be placed vertically over the iliac crests, not transversely. This method affords the operator a secure grip on the fetal pelvis, eliminates the risk of abdominal injury, aids downward traction, and enables rotation of the trunk, which is described next. The same grip is recommended for use at cesarean delivery.

■ Total Breech Extraction

The Canadian guidelines for vaginal delivery of breech presentation explicitly state that total breech extraction is inappropriate

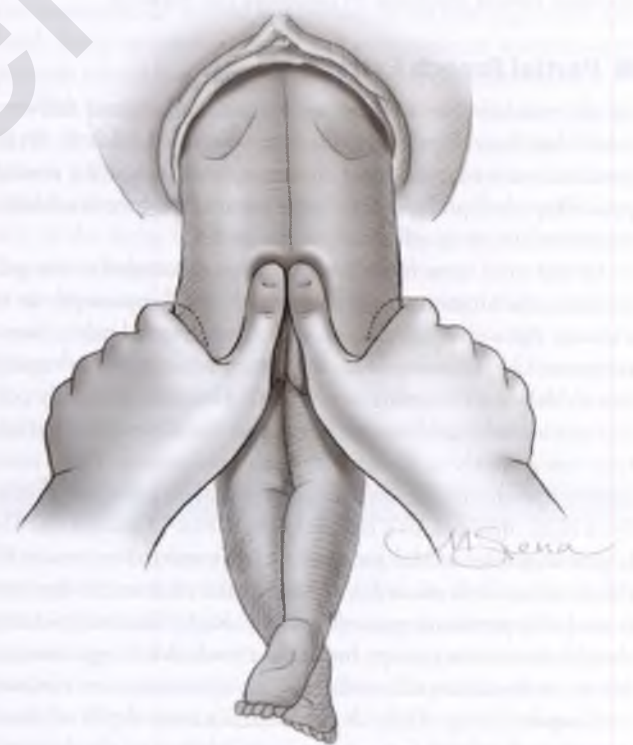


FIGURE 21-4 With the lower half of the fetal body out, the operator’s hand position and direction of traction are very important. Thumbs should be adjacent to each other over the sacrum. Index fingers are placed vertically over the iliac crests and indent the soft tissue slightly. The direction of traction is straight down until the lower thirds of the scapulas become visible, as shown in the figure. Digital pressure on the lower abdomen of the fetus should be avoided.

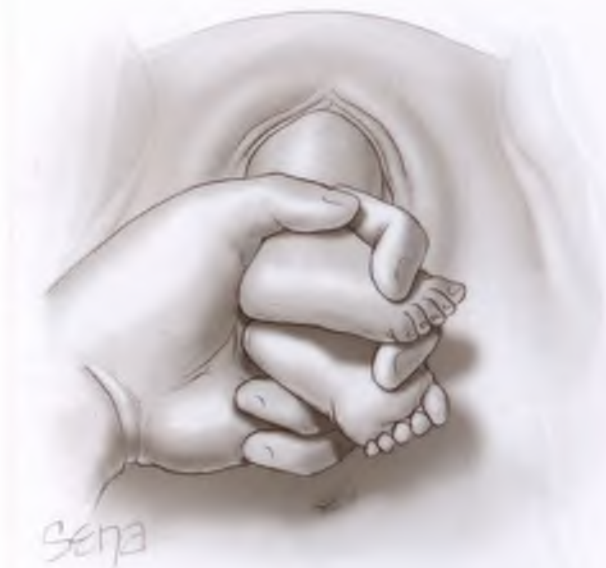

FIGURE 21-5 For total breech extraction, it is ideal to bring out both feet at once, with the operator's middle finger between the medial malleoli. It is permissible to bring down one foot at a time if necessary. (Reproduced with permission from Cunningham FG, Leveno K, Bloom S, et al (eds): *Breech delivery*. In *Williams Obstetrics*, 24th ed. New York, McGraw-Hill, 2014.)

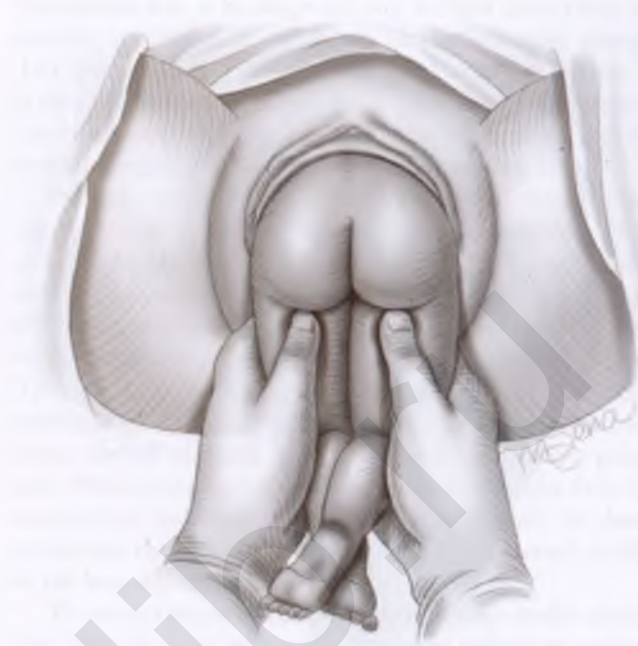


FIGURE 21-6 To deliver the hips, both hands may be placed over the thighs as shown. Often traction on the feet alone may deliver the hips and obviate the need for this step.

for term singleton breech delivery (Kotaska, 2009). That said, at times, total extraction of a complete or incomplete singleton breech may be required (Cunningham, 2014). The technique is the same for breech extraction for the second twin, as described in Chapter 22 (p. 356).

To perform total breech extraction, the operator inserts a hand into the uterus to grasp both feet and bring them down through the introitus (Fig. 21-5). If only one foot can be grasped, it can be brought down into the vagina and held with the appropriate hand, right hand for right foot and left hand for left foot. The best grip on the foot is achieved by forming a circle with the thumb under the plantar surface, the index finger over the Achilles tendon and the heel protruding through the circle. The remaining three fingers are placed over the dorsum of the foot from lateral to medial (Davis, 1912). With that foot secure, the opposite hand can be introduced, passed upward along the leg, and guided into the uterus to locate the other foot. If the remaining hip is extended, it is usually a simple matter to find and bring down the second foot. If the hip is flexed and the foot is near the face, it is necessary to bring the lower half of the fetus down with a finger in that groin. In this case, traction is safe until the leg can be reached and delivered in the manner described for a frank breech and illustrated in Figure 21-1.

Continued traction on both feet will bring the lower legs through the introitus. Further traction on the thighs will expose the sacrum (Fig. 21-6). Now, the maneuvers are identical to those of partial breech extraction starting with Figure 21-4.

Rarely, a frank breech will require conversion or “decomposition” to a footling breech configuration inside the uterine cavity. If membranes are intact and the entire fetus is still in the uterus, the decomposition maneuver described by Pinard can be used (Fig. 21-7). With this, the operator's left hand externally rotates

the hip by pressing on the medial side of the thigh parallel to the femur. As shown by the dotted line, pressure on the popliteal fossa should bring the corresponding foot into contact with the back of the operator's hand. Here, the foot can be grasped and brought into the vagina. However, if the membranes are ruptured and the breech has descended partially into the vagina but

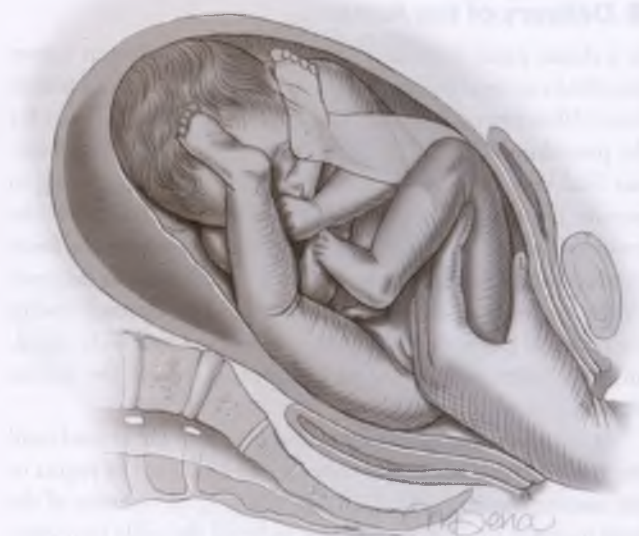

FIGURE 21-7 The Pinard maneuver is performed inside the uterine cavity. Pressure in the popliteal fossa with fingers over the posterior thigh causes the leg to flex and brings the foot within reach. The foot is then grasped and extracted. This procedure, also called breech decomposition, is rarely necessary for singleton breech delivery.

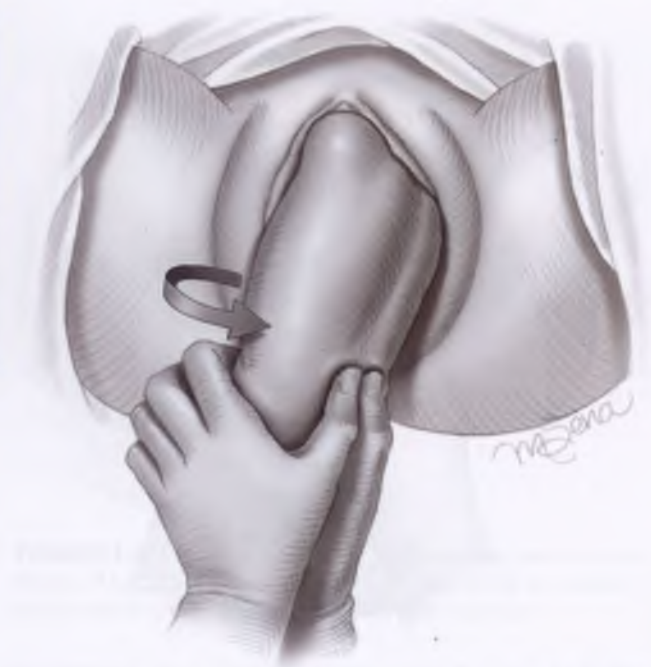

FIGURE 21-8 Once the lower scapulas are visible, the fetal trunk is rotated 90 degrees clockwise. If winging of the left scapula is noted, the operator or assistant should reach over the anterior (left) shoulder, place two fingers parallel to the humerus and sweep the left arm out across the chest (as in Figure 21-10). If the left arm is not ready to be delivered, then delivery of the right arm is initiated as shown in Figures 21-9 and 21-10.

not low enough for the operator to reach the groin, the problem becomes much more serious. Some, but not all, have found tocolytic administration to be helpful in this situation (Cunningham, 2014). General anesthesia with a halogenated agent to relax the uterus is likely to give the best result.

■ Delivery of the Arms

In a classic paper published nearly 80 years ago, Jorgen Lovset described a series of maneuvers for delivering the arms of a breech fetus (Albrechtsen, 1997; Lovset, 1937). The theoretic basis for the procedure that now bears his name capitalizes on the posterior fetal shoulder always being the lower one. In preparing to execute the Lovset maneuver, the direction of traction on the lower half of the body should be straight down toward the floor, without rotation, until the lower third of each scapula becomes visible. At cesarean delivery, traction should be directed toward the maternal feet with minimal elevation of the fetal body, again, until the lower third of the each scapula is seen in the uterine incision.

At this point, the fetal trunk is slowly and gently rotated until the anterior axilla appears at either the entrance of the vagina or the uterine incision (Fig. 21-8). If a 90-degree rotation of the back to either the right or left fails to bring the axilla into view, slow rotation in the opposite direction through 180 degrees may bring the other axilla down. These slow, rotary movements are made with the hands still on the pelvis of the fetus and may need to be repeated more than once. The appearance of the anterior axilla is sometimes associated with “winging” of the

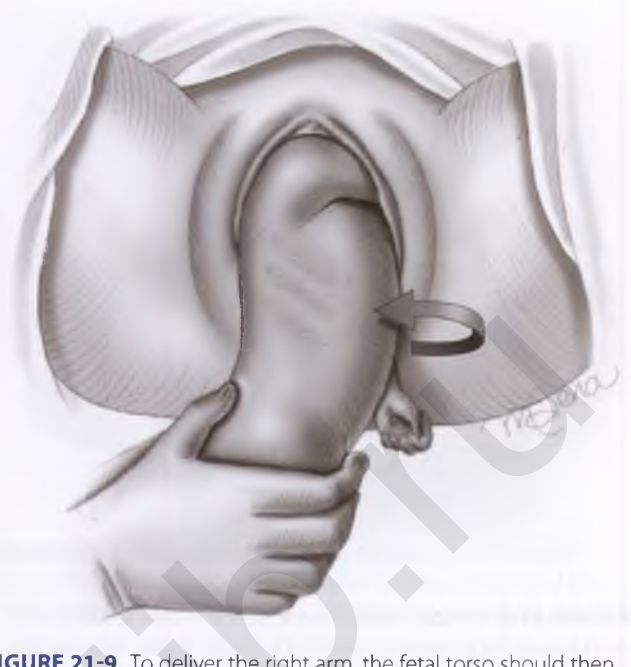

FIGURE 21-9 To deliver the right arm, the fetal torso should then be rotated 180 degrees counterclockwise. This slow rotation may be aided by gentle pressure over the left scapula by an assistant. When the right scapula wings, the right arm is ready to be delivered.

scapula, which can be recognized by a protrusion of the scapula in an outward direction from the fetal back. This signifies the readiness of the anterior shoulder to be delivered (Fig. 21-9). The operator should insert two fingers over the top of the anterior shoulder and exert pressure in the antecubital fossa, parallel to the long axis of the humerus (Fig. 21-10). This allows

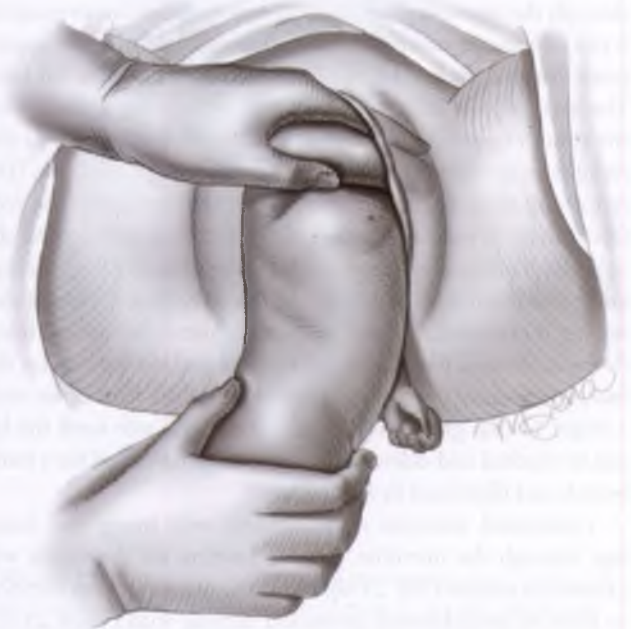

FIGURE 21-10 Delivery of the right arm using the first two fingers of the operator's left hand over the right shoulder and parallel to the humerus is illustrated. Downward pressure will sweep the arm across the chest and out. Digital pressure transverse to the long axis of long bones risks fracture and should be avoided.

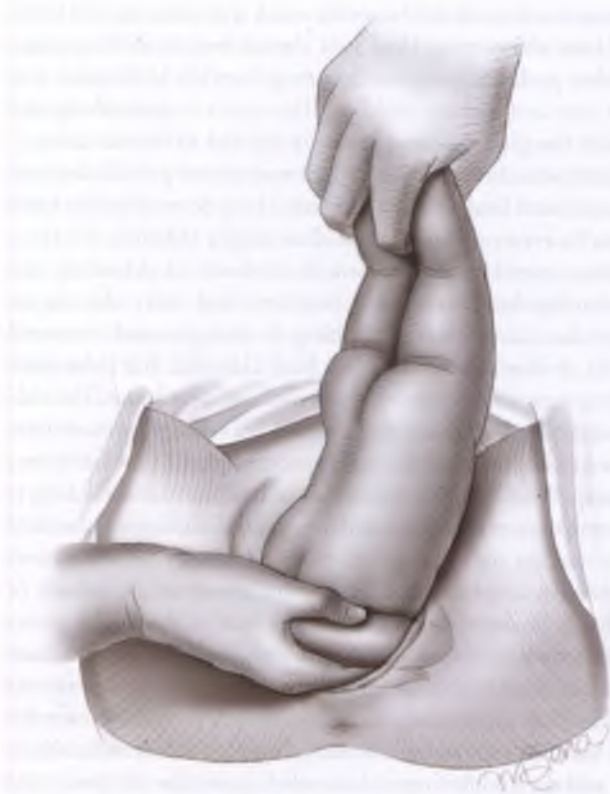

FIGURE 21-11 Infrequently, it may be necessary to deliver the posterior arm first. This is accomplished by raising the lower half of the fetal body up and over the maternal groin (left groin for left shoulder when the fetal head is on the maternal right and right groin for right shoulder when the head is on the left). The operator's fingers are inserted ventral side up under the posterior shoulder and aligned with the humerus.

the anterior arm to be swept out over the fetal chest. Once the anterior arm is out, the body can be slowly rotated through 180 degrees to bring the posterior shoulder to the anterior. It is then delivered in a similar fashion. Light digital pressure over the delivered scapula can assist in accomplishing rotation of the trunk in preparation for delivery of the remaining arm.

Prior to considering methods for delivery of the aftercoming head, two special circumstances must be addressed. First, although highly effective in our experience, the Lovset maneuver does not always work. An alternate plan involves delivery of the posterior arm first and takes advantage of the roominess of the posterolateral portion of the pelvis for manipulations. The ventral surface of the fetus is carried up and over the corresponding maternal groin. As shown in **Figure 21-11**, the fetus crosses the left maternal groin when the left fetal arm is posterior. When choosing to deliver the posterior shoulder first, the arm-delivery technique remains the same. Namely, the hand enters over the shoulder, and finger pressure is exerted parallel to the long axis of the humerus.

The second special circumstance is a single or double nuchal arm. With this, the fetal arm(s) is trapped behind the occiput (**Fig. 21-12**). If this develops, two useful actions can be corrective. First, with the right arm of the fetus behind the neck, the body should be rotated in a counterclockwise direction. The created friction from the birth canal will cause the arm to move in the direction of the chest (**Fig. 21-13**). If the left arm is nuchal, the rotation is clockwise. This movement will enable the operator to deliver the arm without risking fracture of the humerus or clavicle (**Fig. 21-14**). In the event that rotation fails, Piper and Bachman (1929) recommended pushing the fetus back up the birth canal to disengage the shoulders and arms above the pelvic brim. In more than a few cases, nuchal arms are caused iatrogenically by premature traction, which drags the arm or arms up above the head.

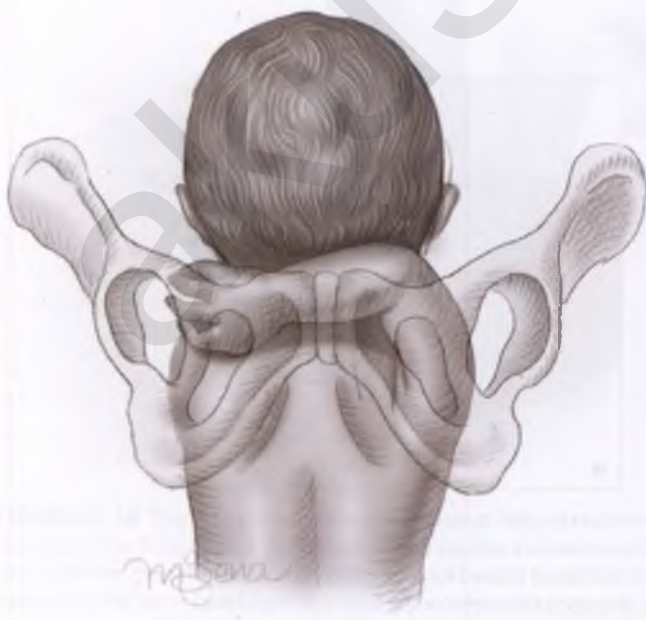

FIGURE 21-12 Entrapment of an arm between the fetal head and anterior pelvis of the mother is termed a nuchal arm.

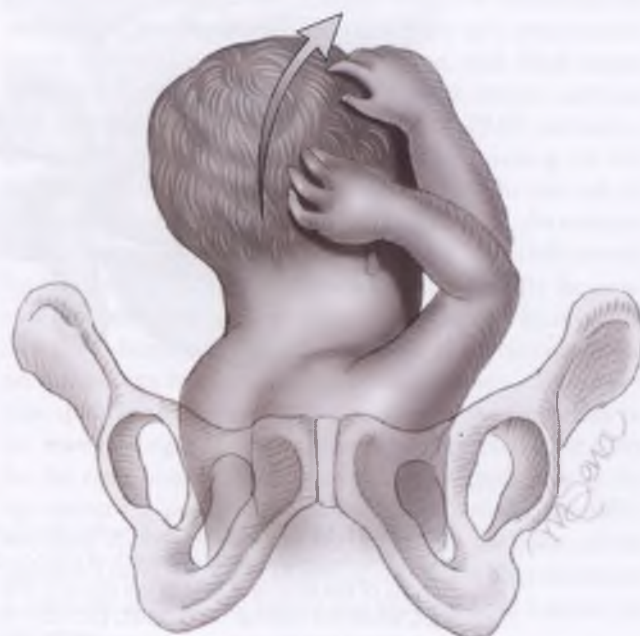

FIGURE 21-13 To release this trapped arm, the fetal dorsum is rotated to the maternal right if the fetal right arm is nuchal.

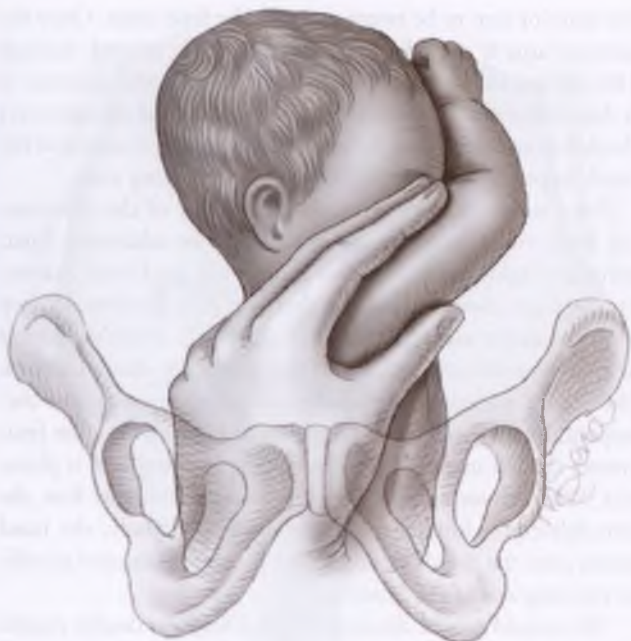

FIGURE 21-14 Friction generated by the birth canal should result in correction of the nuchal arm and permit the operator to position fingers over the shoulder in line with the humerus. This is followed by downward pressure to sweep the arm out across the chest.

■ Delivery of the Head Noninstrumental Delivery

Following delivery of the arms, the final part of the fetus still inside the birth canal is the head. Although the head in a vertex

presentation has several hours to mold and adapt to the birth canal, the aftercoming head in a vaginal breech delivery must be either pushed through or extracted from the birth canal in a short time and without molding. This serves to explain why the brain is the organ most commonly injured in breech delivery and why selection criteria emphasize maternal pelvis adequacy and estimated fetal weight (see Table 21-1). Some consider head size to be even more important than weight (Michel, 2011).

Over several centuries, various methods of delivering the aftercoming head have been described and carry the names of famous accoucheurs. According to Douglas and Stromme (1976), at least 21 methods had been classified, but there have been no new techniques developed in the 40 years since. The oldest method still in use is the *Mauriceau-Smellie-Veit* maneuver, named after obstetricians from France, England, and Germany, respectively. With this bimanual technique, the fetal face is directed toward the floor and the ventral surface of the fetal body rests on the operator's forearm. Originally described, first and second fingers of one hand were placed in the mouth of the fetus, however, this risks formation of a pharyngeal diverticulum or mandibular dislocation and has been largely abandoned. It is preferable to place the first and second fingers over the maxillary eminences. The other hand is positioned over the fetal back with the index and third finger arched over the shoulders and the middle finger is extended against the occiput to aid flexion (Fig. 21-15). The function of the first hand is fetal neck flexion, and the second hand's purpose is traction with only slight flexion.

The main drawback of this maneuver is that traction on the shoulders poses potential serious injury to the fetal

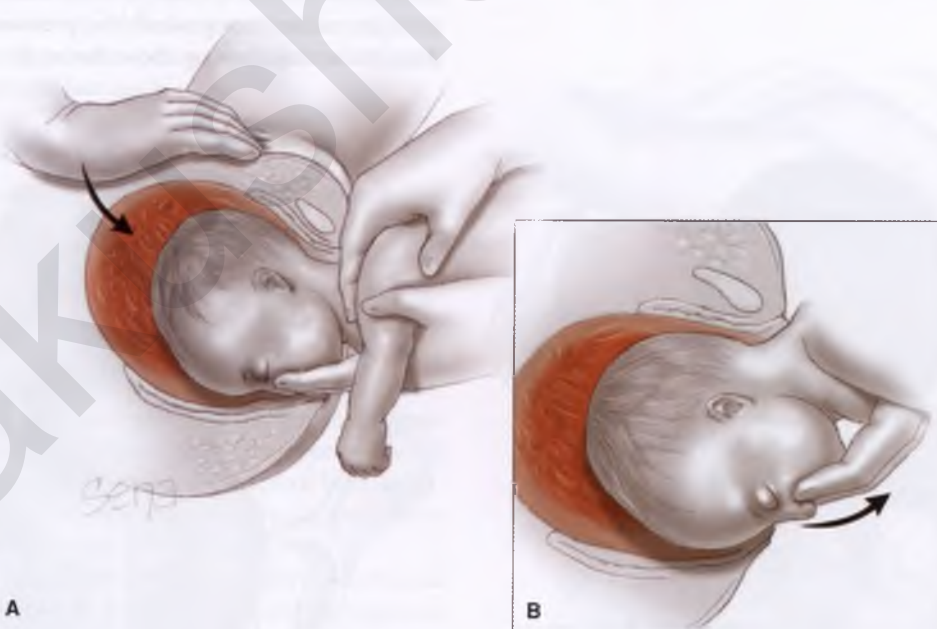


FIGURE 21-15 The Mauriceau-Smellie-Veit maneuver can be used to deliver the aftercoming head. The index and middle fingers of the nondominant hand are placed over the maxillary eminences of the fetal face (not in the mouth). The dominant hand is used for traction on the shoulders, while the internal hand (inset) provides flexion. The use of forceps for the aftercoming head is preferred and illustrated in Figures 21-17 through 21-19. (Reproduced with permission from Cunningham FG, Leveno K, Bloom S, et al (eds): *Breech delivery*. In *Williams Obstetrics*, 24th ed. New York, McGraw-Hill, 2014.)

cervical spine. In easy cases with a small fetus and a parous woman, this risk is minimal. That said, some have abandoned this method of delivering the aftercoming head in favor of forceps delivery.

A variant of the Mauriceau maneuver is the *Wigand-Martin* method. With this, the first hand's position and action mirror that in the Mauriceau maneuver, but the second hand instead applies suprapubic pressure. This still poses a risk for laceration of the tentorium cerebelli from overly vigorous suprapubic pressure. Two other methods, the *Burns-Marshall* and the *Bracht* techniques, have few advocates in the United States (Donald, 1979; Plentl, 1953). In the former, the body of the fetus is allowed to hang from the vulva to effect descent of the head. Following this, the feet are grasped and swung through a wide arc of 180 degrees with the cervical spine of the fetus hyperextended. The Bracht maneuver, still popular in parts of Europe, especially Germany, incorporates suprapubic pressure by an assistant, which is a disadvantage.

The last of the manual maneuvers discussed here is the *Prague* maneuver, which is used only when the dorsum of the fetus cannot be rotated anteriorly. It is obvious that if the operator has been cognizant of the need to maintain the fetus in a dorsum anterior orientation, the Prague maneuver is rarely needed. For this method, one hand elevates the fetal feet and body over the maternal lower abdomen. Simultaneously, the

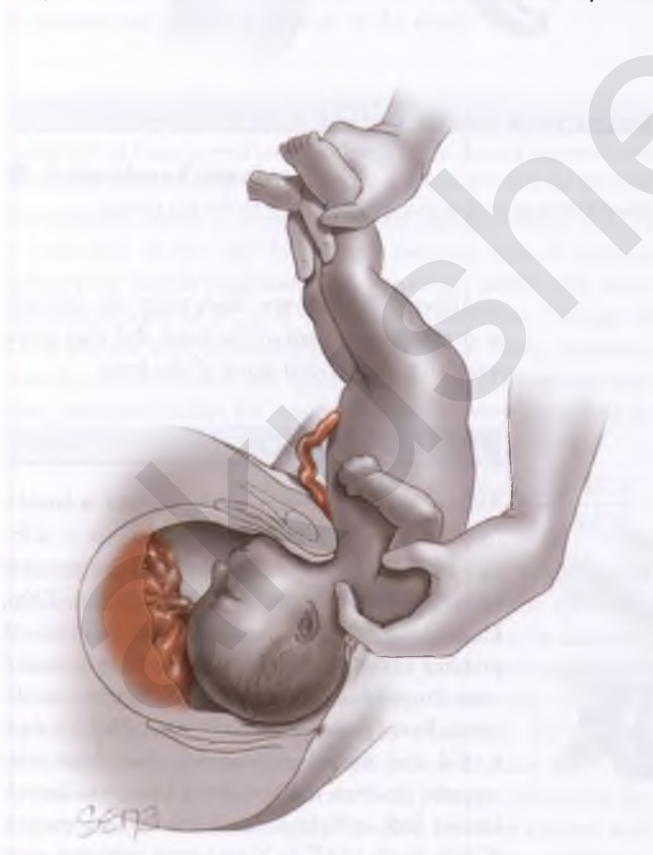

FIGURE 21-16 The Prague maneuver is to be used only when the dorsum of the fetus cannot be rotated anteriorly. One hand elevates the feet over the maternal lower abdomen, while traction is exerted by the other hand, palm up, on the shoulders. (Reproduced with permission from Cunningham FG, Leveno K, Bloom S, et al (eds): *Breech delivery*. In *Williams Obstetrics*, 24th ed. New York, McGraw-Hill, 2014.)

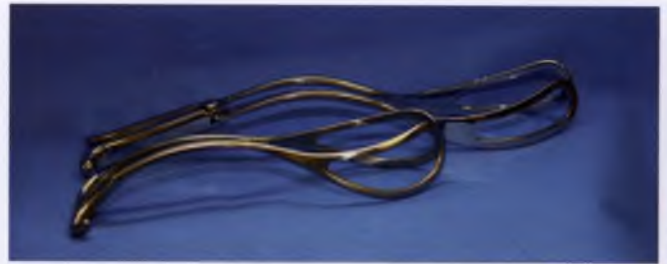

FIGURE 21-17 The Piper forceps (background) and Lafe-Piper forceps (foreground) are similar in shape but markedly different in length. The Piper forceps feature an English lock, in contrast to the pivot lock of the Lafe-Piper forceps. The pivot lock at the distal end of the handles makes the Lafe instrument divergent, that is, the branches never cross.

other hand is positioned palm up beneath the fetus and exerts traction on the shoulders (Fig. 21-16). Because of possible damage to the fetal brain, some now recommend against all of the foregoing manual head-delivering techniques and instead advocate the routine application of forceps to the aftercoming head.

Instrumental Delivery

Championed by Edmund Piper (1929) and endorsed by Milner (1975), prophylactic forceps to the aftercoming head is preferred by many. Although many types of forceps have been used for this indication, Piper forceps were specifically designed for it (Fig. 21-17). Lafe (1967) introduced his “short Piper” forceps, which were subsequently referred to as *Lafe-Piper forceps* (Locksmith, 2001). This instrument incorporates the principle of divergence, wherein the left and right branches never cross. They are joined by a pivot lock at the distal end of the handles. Some find that this short instrument is useful for delivering the aftercoming head at cesarean delivery (Locksmith, 2001). It is also useful for controlling the aftercoming head at vaginal breech delivery of a preterm singleton or twin. During correct application, each blade begins below the fetus and, relative to the mother, travels cephalad and upward. In his original article, Piper (1929) includes a drawing of the operator down on one knee inserting the left branch. This branch is always applied first to the left side of the maternal pelvis and right side of the fetal head. An assistant holds the fetal body in a swayback position but carefully avoids hyperextending the neck. It does not matter whether the assistant holds the fetal hands and feet or whether the fetus is held in a towel hammock. In both instances, the fetal extremities need to be kept from obstructing blade placement. To aid forceps application, the assistant should move the fetal body to the maternal right for the left branch, then back to the left for the right branch. The key to successful application is for the operator to push each vaginal sidewall laterally, forcefully, and then apply the blade of the forceps to the palm of the operator's hand (Figs. 21-18 and 21-19). Once the instrument is correctly applied, the toes of the blades will lie superior to the vertex.

The operator should then insert four fingers of the non-dominant hand, palm-side down, over the posterior vaginal

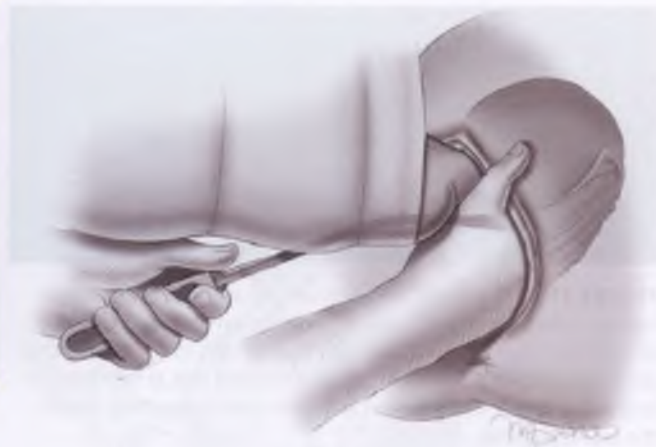

FIGURE 21-18 The left branch of the Piper forceps is always placed first to aid locking. The right hand of the operator is placed in the vagina, and lateral pressure is exerted on the vaginal sidewall. The left blade is then applied to the right hand, and the branch is inserted from below upward using the left hand. During insertion, the handle starts out laterally on the right and below the operating table. When fully applied, the toe of the left blade will lie atop the vertex of the fetal head. The figure shows the extremities wrapped in a towel and held in a swayback position to the right of the midline.

wall (Fig. 21-20). This simple step permits the fetus to breathe before the head is delivered. Placement of a posterior vaginal retractor, illustrated by DeLee and Greenhill (1947), is not necessary if a hand is used as described.

Elevation of the handles will produce flexion of the head. Piper regarded this, and not traction, to be the chief function of his forceps. If necessary, the handles can be lowered and raised again in a pump-handle fashion, to bring the nape of the neck under the pubic arch. The forceps need not be removed before

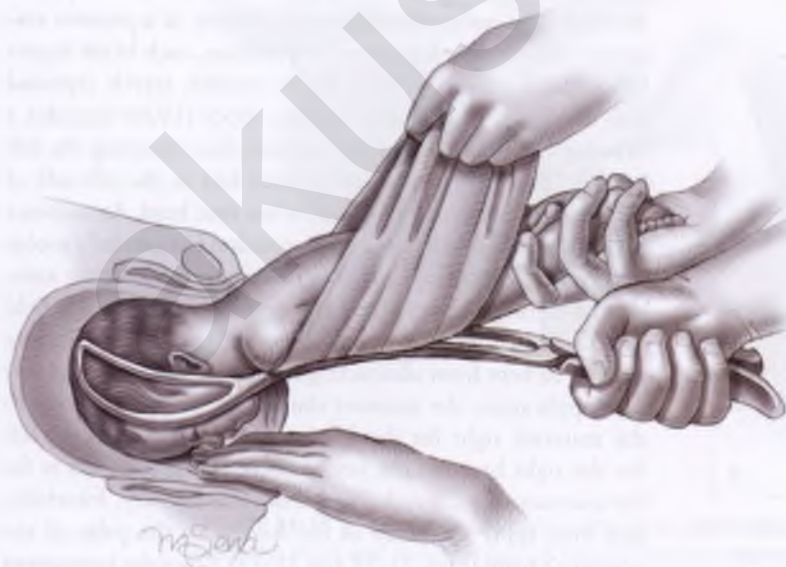


FIGURE 21-20 Once articulated, the handles are elevated in conjunction with the fetal body to produce flexion of the aftercoming head. It is helpful to place four fingers ventral side down along the posterior vaginal wall. Downward pressure creates space for the fetus to breathe.

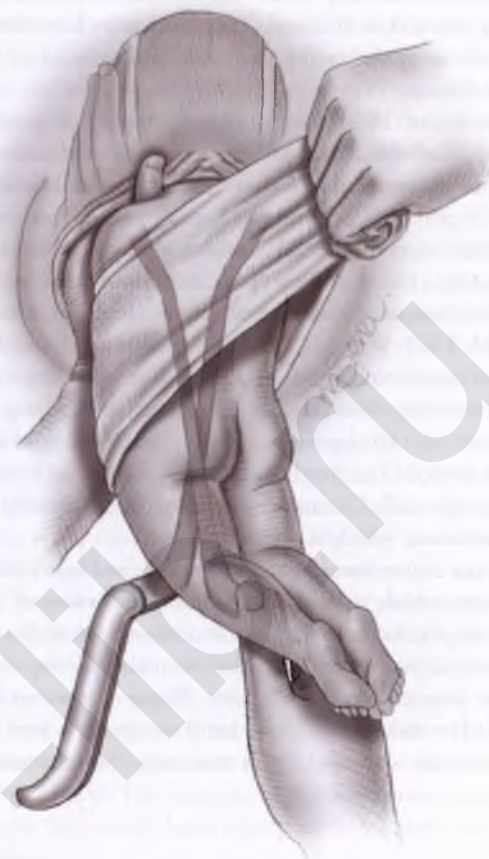

FIGURE 21-19 Now, the fetal body is moved to the left of the midline. The right branch of the Piper forceps is then applied to the operator's left hand in the vagina. It is inserted over the top of the previously placed left branch and in a similar manner to the first branch.

completing the delivery. They assist the operator in controlling the exit of the head, and they avoid stretching the cervical spine of the fetus.

PRETERM BREECH

Although planned vaginal delivery of a breech fetus at term is still a viable option, it is difficult to argue for vaginal delivery of the preterm breech (Bergenhengouwen, 2015; Burke, 2006; Hannah, 2000). The few randomized trials of preterm breech delivery that have been initiated were stopped early due to insufficient enrollment. Forty years ago, an editorial called for such a trial and argued persuasively that those who espouse cesarean delivery for all preterm breech fetuses lack sufficient proof for their approach (Cruikshank, 1977). Now, even without such proof, planned cesarean delivery is almost uniformly favored, at least in the United States. Two reports may help to sustain the practice for a little longer.

First, Kayem and associates (2008) compared 84 women in a planned vaginal delivery group

and 85 women in a planned cesarean delivery group. All gestational ages ranged between 26 and 30 weeks. In this study, the risk of neonatal death was not associated with delivery mode. However, an obvious criticism is the small number of women studied.

A second study from the Netherlands included more than 8000 preterm singleton breech deliveries, which would silence the critics of small studies (Bergenhengouwen, 2015). They extended the gestational age range from 26 to 37 weeks. Intended cesarean delivery of 1935 fetuses, which was a remarkably low number, was associated with a perinatal mortality rate of 1.3 percent. Intended vaginal delivery of 6421 fetuses, which was a remarkably high number, produced a perinatal mortality rate of 1.5 percent. These rates did not differ statistically. It was only when the authors analyzed a *composite outcome* of perinatal mortality and morbidity that intended cesarean delivery offered an advantage.

When faced with the imminent delivery of a preterm breech vaginally, a few technical points deserve emphasis. Epidural analgesia may prevent the mother from bearing down prematurely. Application of forceps to the aftercoming head may prevent the head from “popping out.” This recommended technique can reduce the risk of intracranial hemorrhage and neonatal mortality (Milner, 1975). Somewhat counterintuitively, even small preterm breeches may benefit from an episiotomy to prevent uncontrolled delivery of the head.

EXTERNAL CEPHALIC VERSION

■ Selection Criteria

The primary reason to consider external cephalic version (ECV) is reduction of the very high (>85 percent) rate of cesarean delivery for breech presentation at term (Lee, 2008). The average success rate of ECV is 58 percent (American College of Obstetricians and Gynecologists, 2016). It is likely, however, that the overall version rate is considerably less if the same equation presented earlier for vaginal breech delivery is applied to external version:

$$\text{Version rate} = \frac{\text{Attempt ECV}}{\text{Term breech presentation}} \times \frac{\text{Successful ECV}}{\text{Attempt ECV}}$$

Several factors affect the first term, which represents the rate of contemplated and attempted versions—that is, the *offer rate*. Hemelaar and coworkers (2015) identified failure to diagnose a breech presentation antenatally as the most common reason for a low offer rate. Other factors that lower the offer rate include ECV not being suggested by clinicians, ECV being declined by women, and contraindications limiting ECV. An optimistic figure for the offer rate is 33 percent. Second is the success rate, and this is highly variable between centers and ranges from 16 to 100 percent (American College of Obstetricians and Gynecologists, 2016). Thus, solving the equation above leads to a reasonable estimate of <20 percent for the overall version rate.

Scoring systems to predict ECV success require additional validation, and the predictive power of individual parameters varies among investigators (American College of Obstetricians

and Gynecologists, 2016). For example, low amniotic fluid volume, anterior placenta, and maternal obesity each lower the ECV success rate. Another important negative predictor of success is the combination of frank breech and nulliparity.

As a compounding feature, women who undergo a successful version still face an increased rate of cesarean delivery compared with women with a spontaneous cephalic presentation. A recent systematic review and metaanalysis documented a twofold increased risk for cesarean delivery in pregnancies after successful version. Major indications were dystocia and fetal distress, both with odds ratios of 2.2 (deHundt, 2014). The net benefit of ECV on the total cesarean delivery rate is thus small. Nevertheless, the American College of Obstetricians and Gynecologists (2014, 2016) recommends that all women near term with breech presentations should be offered a version attempt. No studies address whether ECV should be offered to women who meet criteria for planned vaginal breech delivery. ECV for the second twin, described in Chapter 22 (p. 360), although formerly recommended, is associated with a high rate of combined vaginal/cesarean delivery. Total breech extraction with or without internal podalic version is preferred for the management of the second twin.

Notably, in those with skills, vaginal breech delivery may be preferable to many cases considered by others for ECV. Training programs should lead the way in selecting well-qualified candidates for attempted vaginal breech delivery and should consider reserving ECV for some (not all) women who are not candidates for vaginal breech delivery.

■ External Version Technique

There have been no new significant interventions introduced for converting a breech fetus to a cephalic presentation. Before attempting an external version, beta-mimetic agents or calcium-channel blocking agents may be administered to relax the uterus. Beta-mimetic options include terbutaline, ritodrine, or salbutamol. Nifedipine is a calcium-channel blocker. Our practice is to administer 250 µg of terbutaline subcutaneously to most women prior to attempted version. When maternal tachycardia—a known side effect of terbutaline—is noted, then the version attempt is begun. Of evidence-based data, one Cochrane review deemed supporting studies for any of these agents to be of low quality (Cluver, 2015). The reviewers called for additional investigations to evaluate tocolysis, regional analgesia, application of abdominal lubricants, and other adjuncts.

Adoption of a protocol for ECV is recommended. The procedure should be performed in or near a labor and delivery unit between 36 and 39 weeks' gestation. It can be accomplished with one or two operators. It is our experience that the forward roll method is more successful than the back flip (Fig. 21-21). During the maneuver, our practice is to have an assistant provide sonographic monitoring of fetal heart rate. There is no absolute limit for the duration of the procedure, but most successful versions are accomplished within 5 to 10 minutes. If the station of the presenting part is low, placing the woman in slight Trendelenburg position may be helpful.

Following successful version, the fetus should be monitored for 30 minutes. If the gestational age is 39 weeks or greater and the cervix is favorable, induction of labor is a reasonable option.

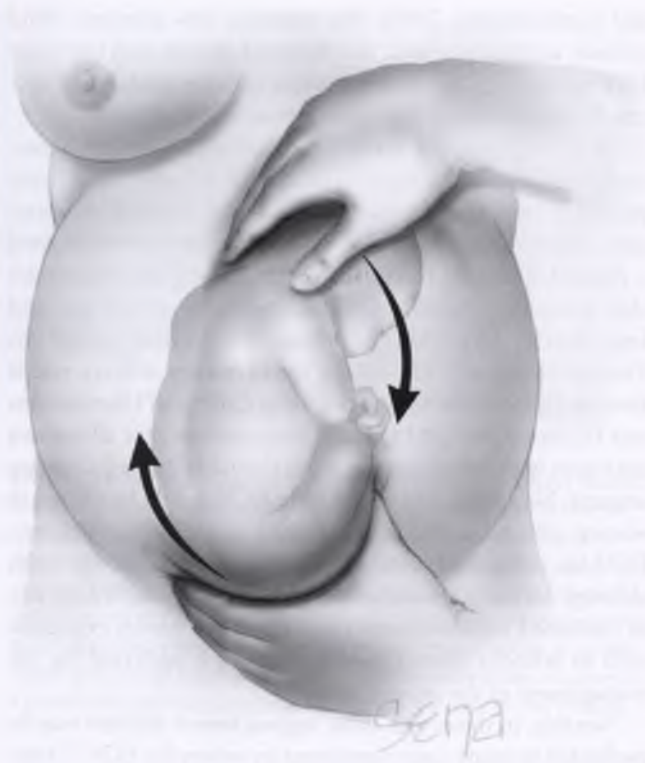


FIGURE 21-21 Shown here is the single-operator technique for external cephalic version. (Reproduced with permission from Cunningham FG, Leveno K, Bloom S, et al (eds): *Breech delivery*. In *Williams Obstetrics*, 24th ed. New York, McGraw-Hill, 2014.)

Given the low reversion rate, most women can be discharged to home with resumption of usual outpatient prenatal care.

CESAREAN DELIVERY

As shown in Table 21-4, when one adds together the number of intrapartum cesarean deliveries and prelabor cesareans, it is obvious that even in centers with current vaginal breech experience, only a minority of breech fetuses deliver vaginally. During surgical delivery, many of the prescriptions in Table 21-5 are equally valid. Importantly, cesarean delivery does not eliminate the risk of the injuries listed in Table 21-1, especially long-bone fractures. As a preventive step, the uterine and laparotomy incision should be sufficiently generous to deliver the fetus without a struggle. When cesarean delivery is performed for a preterm breech, the operator should assess the adequacy of the lower segment before making a transverse incision. For some cases, a vertical uterine incision may be needed to provide sufficient delivery space.

Following hysterotomy, for frank breech fetuses, the buttocks should be lifted through the uterine incision first. Then, simultaneous traction from an index finger in each groin crease may deliver the legs without the need to release them. Concurrently, the dorsum of the fetus is guided to lie anteriorly. However, if a maneuver to free the legs is needed, the fingers of one hand should be placed beneath and behind the thighs to externally rotate the hip in a manner similar to the Pinard maneuver, described on page 341.

For incomplete breeches, first one foot and then the other are delivered through the uterine incision, and traction is applied while holding both feet. Once the buttocks lie outside the incision, the fetal pelvis is grasped. As with vaginal delivery, thumbs overlie the sacrum and fingers rest on the iliac crests. With this placement, traumatic compression of the fetal abdomen can be averted. Once the scapulas are in view, the operator should rotate the trunk to aid delivery of the arms, as described earlier (p. 342).

The aftercoming head can be delivered either by the Mauriceau maneuver or with Lafe-Piper forceps. With either method, hyperextension of the fetal neck by an assistant should be avoided. The fetal body should not be elevated to or beyond the vertical plane. If forceps are used, they should be inserted below the body of the fetus, which is elevated just enough to provide space for maneuvering. During blade application, the operator's hand is positioned inside the uterus and at the extreme lateral aspect of the incision. One branch is grasped by the other hand, and during insertion, the blade skims along the operator's palm that lies within the uterus.

Once both blades have been applied, the pivot lock at the end of the handles can be articulated, and the head is delivered in flexion. Notably, most uterine incisions are transverse. Therefore, turning the head to also align its AP diameter transversely, whether manually or with forceps, may aid delivery.

All of these manipulations should be gentle and purposeful, and not done rapidly in the "heat of the moment." Unlike vaginal breech delivery, the umbilical cord has not been drawn into the pelvis and compressed against the pelvic brim. This permits all actions to be slow and deliberate.

SUMMARY

Regarding the role of vaginal breech delivery in modern obstetrics, Gilstrap (2002) expressed concern that the practice will become rare and that resident experience will diminish or vanish altogether. He cautioned that some women with breech-presenting fetuses will still present before a cesarean delivery can be accomplished. These statements are equally valid almost 15 years later. Van Roosmalen (2014) emphasized in a recent editorial that obstetricians have two dilemmas. First, clinicians must determine the best management of a term breech fetus, especially, but not exclusively, in a nullipara. Second, providers must strive to lower rates of iatrogenic maternal morbidity and mortality associated with the default option of cesarean delivery for all breech-presenting fetuses. He called for improved quality of education regarding vaginal breech delivery. One can only hope that his call will be heard soon.

REFERENCES

- Alarab M, Regan C, O'Connell M, et al: Singleton vaginal breech delivery at term: still a safe option. *Obstet Gynecol* 103:407, 2004
- Albrechtsen S, Rasmussen S, Reigstad H, et al: Evaluation of a protocol for selecting fetuses in breech presentation for vaginal delivery or cesarean section. *Am J Obstet Gynecol* 177:586, 1997
- American College of Obstetricians and Gynecologists: External cephalic version. *Practice Bulletin No. 161*, February 2016
- American College of Obstetricians and Gynecologists: Mode of term singleton breech delivery. *Committee Opinion No. 340*, July 2006, Reaffirmed 2014

- Azria E, Le Meaux JP, Khoshnood B, et al: Factors associated with adverse perinatal outcomes for term breech fetuses with planned vaginal delivery. *Am J Obstet Gynecol* 207:285.e1, 2012
- Berghenhenegouwen L, Vlemmix F, Ensing S, et al: Preterm breech presentation: a comparison of intended vaginal and intended cesarean delivery. *Obstet Gynecol* 126:1223, 2015
- Borbolla Foster A, Bagust A, Bisits A, et al: Lessons to be learnt in managing the breech presentation at term: an 11-year single-centre retrospective study. *Aust N Z J Obstet Gynaecol* 54:333, 2014
- Burke G: The end of vaginal breech delivery. *BJOG* 113:969, 2006
- Caterini H, Langer A, Sama J, et al: Fetal risk in hyperextension of the fetal head in breech presentation. *Am J Obstet Gynecol* 123:632, 1975
- Chinnock M, Robson S: Obstetric trainees' experience in vaginal breech delivery. *Obstet Gynecol* 110:900, 2007
- Christian SS, Brady K, Read J: Vaginal breech delivery: a five-year prospective evaluation of a protocol using computed tomographic pelvimetry. *Am J Obstet Gynecol* 163:848, 1990
- Cluver C, Gyte GM, Sinclair M, et al: Interventions for helping to turn term breech babies to head first presentation when using external cephalic version. *Cochrane Database Syst Rev* 2:CD000184, 2015
- Collea J, Chein C, Quilligan E: The randomized management of term frank breech presentation: a study of 208 cases. *Am J Obstet Gynecol* 137:235, 1980
- Cruikshank D, Pitkin R: Delivery of the premature breech. *Obstet Gynecol* 50:367, 1977
- Cunningham FG, Leveno K, Bloom S, et al (eds): Breech delivery. In *Williams Obstetrics*, 24th ed. New York, McGraw-Hill, 2014, p 558
- Davis E: *Operative Obstetrics*, 1st ed. Philadelphia, Saunders, 1912, p 132
- deHundt M, Velzel J, deGroot C, et al: Mode of delivery after successful external cephalic version. *Obstet Gynecol* 123:1327, 2014
- DeLee J, Greenhill JP: *Principles and Practice of Obstetrics*, 9th ed. Philadelphia, W.B. Saunders Company, 1947, p 867
- Donald I: *Practical Obstetric Problems*, 5th ed. London, Lloyd-Luke, 1979, p 386
- Douglas RG, Stromme WB (eds): *Operative Obstetrics*, 3rd ed. New York, Appleton-Century-Crofts, 1976, p 583
- Gilstrap L III, Cunningham F, VanDorsten JP: *Operative Obstetrics*, 2nd ed. New York, McGraw-Hill, 2002, p 145
- Giuliani A, Scholl W, Basver A, et al: Mode of delivery and outcome of 699 term singleton breech deliveries at a single center. *Am J Obstet Gynecol* 187:1694, 2002
- Glazerman M: Five years to the term breech trial: the rise and fall of a randomized controlled trial. *Am J Obstet Gynecol* 194:20, 2006
- Goffinet F, Carayol M, Foidart JM, et al: Is planned vaginal delivery for breech presentation at term still an option? Results of an observational prospective survey in France and Belgium. *Am J Obstet Gynecol* 194:1002, 2006
- Graves W: Breech delivery in twenty years of practice. *Am J Obstet Gynecol* 137:229, 1980
- Hannah M, Hannah W, Hewson S, et al: Planned caesarean section versus planned vaginal birth for breech presentation at term: a randomised multicentre trial. *Lancet* 356:1375, 2000
- Hauth JC, Cunningham FG: Vaginal breech delivery is still justified. *Obstet Gynecol* 99:1115, 2002
- Hemelaar J, Lim L, Impey L: The impact of an ECV service is limited by antenatal breech detection: a retrospective cohort study. *Birth* 42:165, 2015
- Hopkins LM, Esakoff T, Noah MS, et al: Outcomes associated with cesarean section versus vaginal breech delivery at a university hospital. *J Perinatol* 27:141, 2007
- Kayem G, Baumann R, Goffinet F, et al: Early preterm breech delivery: is a policy of planned vaginal delivery associated with increased risk of neonatal death? *Am J Obstet Gynecol* 198:e1.289, 2008
- Keirse M: Evidence-based childbirth only for breech babies? *Birth* 29:55, 2002
- Kotaska A: Inappropriate use of randomized trials to evaluate complex phenomena: case study of vaginal breech delivery. *BMJ* 329:1039, 2004
- Kotaska A, Menticoglou S, Gagnon R, et al: Vaginal delivery of breech presentation. *J Obstet Gynaecol Can* 226:557, 2009
- Krupitz H, Arzt W, Ebner T, et al: Assisted vaginal delivery versus cesarean section in breech presentation. *Acta Obstet Gynecol Scand* 84:588, 2005
- Lashen H, Fear K, Sturdee D: Trends in the management of the breech presentation at term; experience in a district general hospital over a 10-year period. *Acta Obstet Gynecol Scand* 81:1116, 2002
- Laufe L: An improved Piper forceps. *Obstet Gynecol* 29:284, 1967
- Lee HC, El-Sayed YY, Gould JB: Population trends in cesarean delivery for breech presentation in the United States, 1997–2003. *Am J Obstet Gynecol* 199:59.e1, 2008
- Locksmith GJ, Gei AF, Rowe TF, et al: Teaching the Laufe-Piper forceps technique at cesarean delivery. *J Reprod Med* 46(5):457, 2001
- Lovset J: Shoulder delivery by breech presentation. *J Obstet Gynaecol Br Emp* 44:696, 1937
- Michel S, Drain A, Closset E: Evaluation of a decision protocol for type of delivery of infants in breech presentation at term. *Eur J Obstet Gynecol Reprod Biol* 158:194, 2011
- Milner RD: Neonatal mortality of breech deliveries with and without forceps to the aftercoming head. *BJOG* 82:783, 1975
- Moir JC, Myerscough PR: *Operative Obstetrics*, 8th ed. London, Balliere, Tindall and Cassell, 1971, pp 136–179
- Piper E, Bachman C: The prevention of fetal injuries in breech delivery. *JAMA* 92:217, 1929
- Plentl A, Stone R: The Bracht maneuver. *Obstet Gynecol Survey* 8:313, 1953
- Pradhan R, Mohajer M, Deshpande S: Outcome of term breech births: 10-year experience at a district general hospital. *BJOG* 112:218, 2005
- Schutte J, Steegers E, Santema J, et al: Maternal deaths after elective cesarean section for breech presentation in the Netherlands. *Acta Obstet Gynecol Scand* 86(2):240, 2007
- Seeds J, Cefalo R: Malpresentations. *Clinical Obstet Gynecol* 25:145, 1982
- Tank E, Davis R, Holt J, et al: Mechanisms of trauma during breech delivery. *Obstet Gynecol* 38:761, 1971
- Toivonen E, Palomaki O, Huhtala H, et al: Selective vaginal breech delivery at term—still an option. *Acta Obstet Gynecol Scand* 91:1177, 2012
- Van Roosmalen J, Meguid T: The dilemma of vaginal breech delivery worldwide. *Lancet* 383:1863, 2014
- Whyte H, Hannah M, Saigal S, et al: Outcomes of children at 2 years after planned cesarean birth versus planned vaginal birth for breech presentation at term: the International Randomized Term Breech Trial. *Am J Obstet Gynecol* 191:864, 2004
- Yeomans E: Clinical pelvimetry. *Clinical Obstet Gynecol* 49:140, 2006
- Yeomans ER, Gilstrap LC III: Breech delivery. In *Queenan's Management of High-Risk Pregnancy: An Evidence-Based Approach*, 6th ed. Oxford, John Wiley & Sons, 2012, p 424

Delivery of Twin Gestations

TWIN GESTATIONS	350
ANTEPARTUM MANAGEMENT	352
LABOR MANAGEMENT	353
DELIVERY OPTIONS	354
TRAINING	361

Twins account for 3.3 percent of all births in the United States. This near doubling of the incidence since 1980 is attributable to advancing maternal age at conception and increasing use of assisted reproductive technology (American College of Obstetricians and Gynecologists, 2014a). During roughly the same period, the cesarean delivery rate for twins has increased to 75 percent, thereby reducing the overall experience with vaginal delivery of twins (Lee, 2011). Germane to this, an obstetric care consensus developed jointly by the American College of Obstetricians and Gynecologists (2014b) and the Society for Maternal-Fetal Medicine concluded that perinatal outcomes when the first twin presents cephalic are not improved by cesarean delivery. This document states that for twins with cephalic/cephalic or cephalic/noncephalic presentations, obstetric care providers should counsel women to attempt vaginal delivery. Such a strong recommendation assumes that residents are being trained to perform vaginal twin deliveries and that practicing clinicians are sufficiently competent and confident to manage the labor and delivery of such women (Carroll, 2006). The goal of this chapter is to present a well-illustrated approach to the vaginal delivery of twins.

TWIN GESTATIONS

■ Risks

Twin gestation presents a broad array of maternal, fetal, and neonatal complications, some of which are related to the intrapartum period and some that are not. Gestational hypertension or preeclampsia complicates up to 20 percent of twin pregnancies (Fox, 2015). Postpartum hemorrhage due to uterine atony is more common with multifetal gestations because the uterus is overdistended. Compared with those for singletons, rates for stillbirth are nearly threefold higher, for neonatal death are sevenfold higher, and for very low birth-weight (<1500 grams) are 11-fold higher in twins (Cunningham, 2014).

Of twins, 16 percent have weight discordance of at least 20 percent (Miller, 2012). Discordance is expressed as a percent and defined by the formula below.

$$\frac{\text{Larger twin weight (g)} - \text{Smaller twin weight (g)}}{\text{Larger twin weight (g)}} \times 100$$

Some cases of discordance are caused by fetal growth restriction of the smaller twin, and severe growth restriction increases the risk of mortality. If twin B is more than 25-percent larger than twin A, the planned route of delivery may need to be reconsidered.

Arguably, the most significant complication is preterm birth, occurring in more than 50 percent of twin gestations. Clearly, preterm birth of twins is a major contributor to overall neonatal morbidity and mortality. Congenital anomalies are more frequent in twins and constitute a second important contributor to adverse outcomes.

For this chapter, the appropriate focus is on intrapartum complications. This was the approach taken in the Twin Birth Study (Barrett, 2013). This large randomized trial defined a composite outcome that incorporated serious neonatal morbidity and fetal or neonatal mortality. Serious

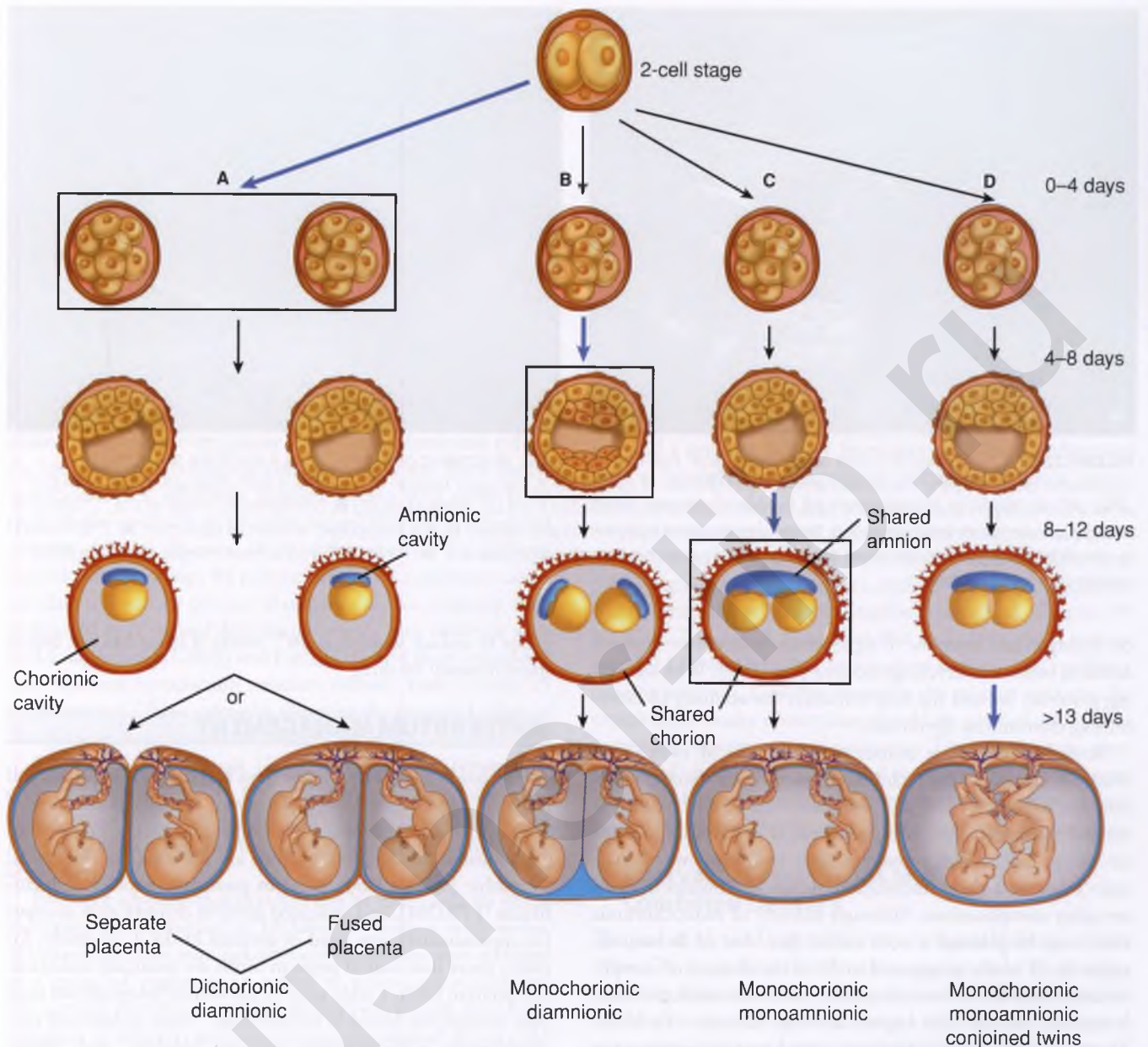


FIGURE 22-1 Mechanism of monozygotic twinning. Dichorionic twinning is not shown here. Black boxing and blue arrows in columns A, B, and C indicate timing of division. **A.** At 0 to 4 days postfertilization, an early conceptus may divide in two. Division at this early stage creates two chorions and two amnions (dichorionic, diamniotic). Placentas may be separate or fused. **B.** Division between 4 and 8 days leads to formation of a blastocyst with two separate embryoblasts (inner cell masses). Each embryoblast will form its own amnion within a shared chorion (monochorionic, diamniotic). **C.** Between 8 and 12 days, the amnion and amniotic cavity form above the germinal disc. Embryonic division leads to two embryos with a shared amnion and shared chorion (monochorionic, monoamniotic). **D.** Differing theories explain conjoined twin development. One describes an incomplete splitting of one embryo into two. The other describes fusion of a portion of one embryo from a monozygotic pair onto the other. (Reproduced with permission from Cunningham F, Leveno K, Bloom S, et al: Multifetal pregnancy. In Williams Obstetrics, 24th ed. New York, McGraw-Hill Education, 2014.)

morbidity was birth trauma, birth asphyxia, neonatal seizures, requirement for resuscitation or intubation, intraventricular hemorrhage, and admission to a neonatal intensive care unit. Notably, in this large trial, composite outcome between planned cesarean and planned vaginal delivery did not differ for all cases in which twin A was in cephalic presentation. Cesarean delivery itself was not considered maternal morbidity, but perhaps it should be if the neonatal outcome is not improved by cesarean.

■ Chorionicity

The diagnosis of “twins” is imprecise, and these gestations should be specifically classified as either dichorionic or monochorionic (Fig. 22-1) (Moise, 2010). Using sonography, the assignment of chorionicity is at least 98-percent accurate in the first trimester (Emery, 2015a). Sonography can help identify the twin peak sign, also called the lambda sign, which indicates apposition of two amnions and intervening chorions. This can

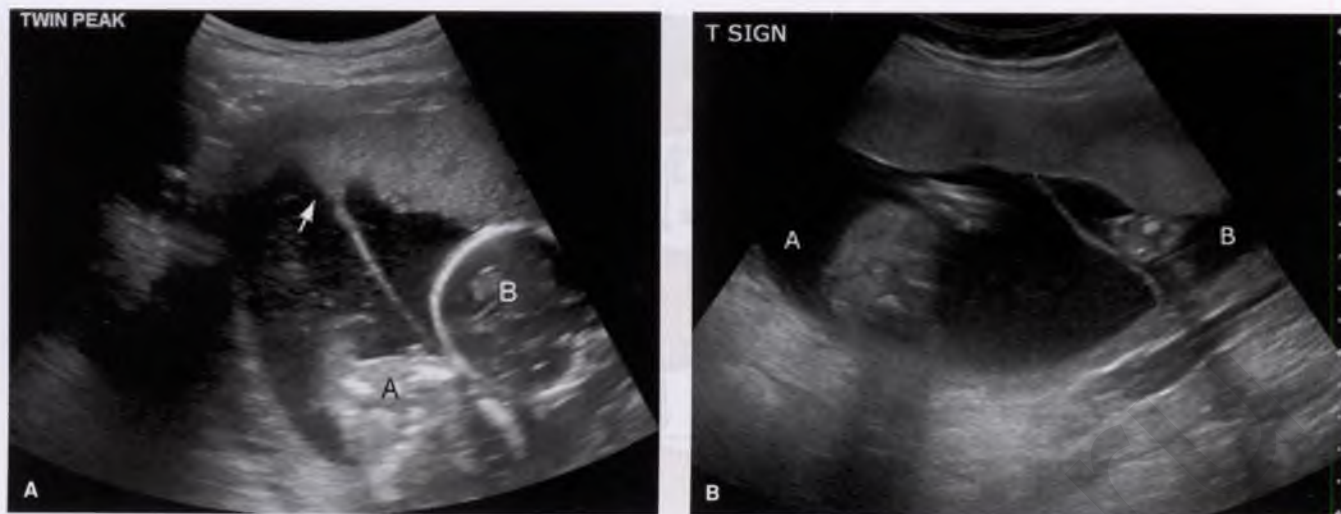


FIGURE 22-2 A. Sonographic image of the “twin-peak” sign in a dichorionic, diamniotic gestation. Twins A and B are separated by a membrane created by the juxtaposed amnion and chorion of each twin. A triangular portion of placenta is seen insinuating between the amniochorion layers and creates the peak (*arrow*). (Used with permission from Dr. Jamie Morgan.) **B.** Sonographic image of the “T” sign in a monochorionic, diamniotic gestation. Twins are separated by a membrane created by the juxtaposed amnion of each twin. A “T” is formed at the point at which amnions meet the placenta. (Used with permission from Jason C. McWhirt, ARDMS.) In both images, twins are differentiated by A and B labels.

be distinguished from the T sign, which reflects two apposed amnions without intervening chorions (Fig. 22-2). With advancing gestation beyond the first trimester, the accuracy of determining chorionicity diminishes.

Several of the more serious complications of twin gestations are limited to monochorionic twins. Twin-twin transfusion syndrome (TTTS) and twin reversed arterial perfusion are two examples, and their treatment is described in Chapter 16 (p. 261). With monochorionic twinning, monoamniotic twins and their uncommon subset of conjoined twins are other complications. Although delivery of monochorionic twins may be planned a week earlier than that of dichorionic twins (at 37 weeks as opposed to 38 in the absence of complications), only for the rare occurrence of monoamniotic twins is cesarean favored over vaginal delivery. Recently, the North American Fetal Therapy Network issued two consensus statements on the management of uncomplicated and complicated monochorionic twin gestations, respectively (Emery 2015a,b). They suggested that uncomplicated monochorionic twins can be offered elective delivery between 36^{0/7} and 37^{6/7} weeks’ gestation (Emery, 2015a). Moreover, they emphasized that vaginal delivery is preferred for monochorionic diamniotic twins, assuming that providers have sufficient expertise in twin vaginal delivery. At most centers in the United States, monochorionic, monoamniotic twins are delivered by cesarean at 32 to 34 weeks’ gestation after providing a course of antenatal corticosteroids. Worldwide some centers still offer vaginal delivery for selected cases of monochorionic, monoamniotic twins (Anselem, 2015).

For dichorionic twins with the first twin presenting cephalic, vaginal delivery is also preferred if appropriate expertise is available. In the absence of complications, spontaneous onset of labor can be awaited. At Parkland Hospital, twin gestations have empirically been considered to be prolonged at 40 weeks’ gestation (Cunningham, 2014). Others, including the author,

prefer to induce women at 38^{0/7} weeks if labor has not begun spontaneously by then.

ANTEPARTUM MANAGEMENT

As previously mentioned, fewer than half of twin gestations will reach 37 weeks’ gestation undelivered. Categories of preterm birth in twins are the same as for singletons, but the proportionate contributions to preterm birth are different. In singletons, idiopathic preterm labor, preterm premature rupture of membranes (PPROM), and indicated preterm delivery each account for approximately one third of preterm births. Conversely, for twins, more than half of preterm births are medically indicated. For preterm birth, a wide array of preventive interventions have been studied and found to be ineffective. These include bed rest, progesterone administration, cerclage, tocolysis, and pessary placement, to name a few. Last, the management of PPRM in twins is the same as that for singletons. However, the latency period in twin gestations is somewhat shorter.

Sonography is an important tool for antepartum surveillance of twin gestations. The recommended interval for monochorionic twins is 2 weeks and for dichorionic twins is 4 weeks (Emery, 2015a). One recent report suggests reducing the interval to 2 weeks for dichorionic twins as well (Corcoran, 2015). The purported advantage of more frequent imaging is earlier detection of fetal growth restriction and abnormal umbilical artery Doppler velocimetry. Such findings may lead to earlier indicated delivery.

Antepartum sonography is also used to detect anomalies, confirm fetal presentation, estimate fetal weights, and diagnose complications such as TTTS or death of one twin. Melamed and associates (2015) analyzed data from one large randomized trial to determine the likelihood of fetal presentation change after 32 weeks’ gestation (Barrett, 2013). The presenting fetus (twin A) tended to persist in vertex presentation, but twin B underwent spontaneous version and change of polarity 25 percent of the

time. Clearly, this can affect delivery planning, and thus repeat sonography is advisable for gravidas presenting in labor.

No consensus guides the necessity, frequency, or method of antepartum fetal surveillance in twin pregnancies. One group recommends weekly biophysical profile evaluation starting at 32 weeks' gestation and suggests that it should be considered as the primary mode of testing (Booker, 2015). However, the American College of Obstetricians and Gynecologists (2014a) found no evidence that such testing was associated with improved perinatal outcomes.

LABOR MANAGEMENT

■ First-Stage Labor

For women with twin gestations who choose to attempt planned vaginal delivery, astute labor management can reduce the incidence of intrapartum cesarean. The Twin Birth Study, described earlier, randomly assigned women with twins at 32 to 39 weeks' gestation to planned vaginal delivery or scheduled cesarean delivery (Barrett, 2013). Of women in the planned vaginal delivery group, 44 percent ultimately underwent cesarean delivery, and 10 percent of surgeries in this subgroup were performed after vaginal delivery of twin A. This contrasts with data from Schmitz (2008) and Fox (2010) and their coworkers, who reported intrapartum cesarean delivery rates of only 15 to 20 percent. These examples illustrate the potential effect of intrapartum management on delivery route.

Leftwich and colleagues (2014) demonstrated slower progression of active labor for both nulliparas and multiparas with twins. Accordingly, they suggest that allowing an additional 2 to 3 hours in labor could lead to fewer cesarean deliveries for failure to progress.

Evidence supports that oxytocin can be safely used for either induction or augmentation of labor in women with twins. When women who required oxytocin with twins were matched to a group of singletons in regard to parity, gestational age, and cervical dilation, the maximum oxytocin dosage, time from initiation to delivery, and rate of successful vaginal delivery did not differ (Fausett, 1997). Thus, it is reasonable to consider a trial of oxytocin prior to deciding on cesarean delivery of twins for failure to progress in labor.

Misinterpretation of electronic fetal heart rate tracings may also contribute to intrapartum cesarean delivery of twins. For this reason, providers should be willing to attempt intrauterine resuscitation before opting for cesarean delivery.

Last, more than 10 percent of intrapartum cesarean deliveries in the Twin Birth Study were performed for malpresentation of twin B (Barrett, 2013). However, adopting the management of twin B outlined on page 356, it may be possible to minimize or even eliminate malpresentation of twin B as the sole indication for cesarean delivery. In sum, lowering the overall cesarean rate for twins requires reducing both prelabor and intrapartum performance of cesarean delivery.

■ Delivery Preparation

For delivery, it is advisable to move laboring women from the labor room to a well-equipped and spacious operating room

(OR). For women with one or more prior vaginal deliveries, transfer to the OR should be accomplished once the cervix is completely dilated. If the cervix is changing rapidly, transfer before complete dilation may be prudent. Conversely, nulliparas can be allowed to push in the labor room unless the head of twin A is already at low station. Transfer can be safely delayed until the head has descended to +2 station.

Once the decision for transfer is made, anesthesia and pediatric personnel are notified to allow them time to arrive at the OR and prepare for delivery. On arrival to the OR, electronic fetal monitoring should be resumed, as well as oxytocin infusion if one was running in the labor room. Suspending the legs in candy-cane stirrups has practical value. It creates room for operative vaginal delivery, intrauterine manipulation, and application of Piper forceps to the aftercoming head if indicated.

Assembled equipment includes forceps, vacuum extractor, and a cesarean delivery instrument set. Also, medications such as nitroglycerin, magnesium sulfate, and various uterotonic agents should all be immediately available in the OR. As previously noted, atony risk is elevated in twins, sometimes necessitating prompt administration of oxytocin (Pitocin), methylergonovine (Methergine), and 15-methyl prostaglandin $F_{2\alpha}$ (Hemabate), which are described further in Chapter 29 (p. 470). The use of a checklist that includes these is recommended (Table 22-1). For twin vaginal delivery in a residency training program, a resident should be the primary operator. An experienced faculty obstetrician should be gowned and gloved to provide supervision and assistance. Training the next generation of obstetricians is essential to developing the necessary technical skills and confidence to maintain the option of twin vaginal delivery in the future and lower cesarean delivery rates.

■ Interval between Twins and Combined Delivery

The goal of planned vaginal delivery is vaginal delivery of both twins. On the surface, this statement appears to be a tautology. However, if the intertwin delivery interval is not shortened, the net result is an increase in combined delivery. This is defined as a vaginal delivery of twin A followed by cesarean delivery of twin B. Thirty years ago Rayburn and associates (1984) showed that intervals of more than 2 hours were not associated with adverse neonatal outcome, as long as electronic fetal monitoring was used and was reassuring. That said, intervals of greater than 30 minutes are associated with a sixfold rise in combined delivery rates (Cruikshank, 2007). Persad and coworkers (2001) found that an intertwin delivery interval of more than 1 hour produced an eightfold higher risk of combined delivery. Leung and associates (2002) concluded that intervals between twins of more than 30 minutes increased the risk of fetal distress and acidosis in the second twin. Interestingly, operative vaginal delivery of the first twin was associated with a decreased risk of cesarean delivery for the second twin (Wen, 2004).

A unique secondary analysis of data collected by the Maternal-Fetal Medicine Network described outcomes for combined delivery of twins (Alexander, 2008). In one group of 179 pregnancies, twin A was delivered vaginally followed by cesarean for twin B. In the comparator group of 849 cases, both twins were delivered by cesarean after labor onset. Intertwin delivery intervals

TABLE 22-1. Checklist for Vaginal Twin Delivery

Equipment: stirrups, forceps, vacuum extractor, electronic fetal monitor, two neonatal resuscitation beds, cesarean delivery instrument set, anesthesia machine. Portable sonography machine (optional)
Setting: spacious OR with cesarean delivery capability
Medications: uterine relaxants, uterotonics
Resuscitation: large-bore IV access, blood for transfusion readily available
Personnel:
Obstetricians—one trainee or junior provider and one senior provider with skills for intrauterine fetal manipulation, breech extraction, and operative vaginal delivery
Anesthesiologist—capable of endotracheal intubation and induction of general anesthesia
Pediatricians—two resuscitation teams
Circulating nurse
Scrub technician

IV = intravenous; OR = operating room.

were not presented. The authors concluded that serious neonatal sequelae were not affected by the route of delivery of the second twin. Notably, a very high percentage of women (17 percent) underwent combined delivery. This suggests a lesser degree of technical skill on the part of the managing obstetricians.

Obstetricians should make every effort to avoid delivering the first twin vaginally followed by urgent or emergent delivery of the second twin (Cruikshank, 2007). However, if the operator's skill is insufficient to complete the delivery vaginally, he or she must make a timely decision to perform a cesarean to optimize neonatal outcome.

The weight of the foregoing evidence suggests that shortening the interval between twins is a meritorious strategy. Such a strategy has been labeled "immediate delivery of twin B" or "active second stage management" in twin pregnancies and is detailed next (Carroll, 2006; Fox, 2010).

DELIVERY OPTIONS

■ Cesarean Delivery

Prior to publication of the Twin Birth Study, no large trial of twins had included the appropriate comparison groups, that is, planned cesarean versus planned vaginal delivery. The importance of this lies in the principle of *intention to treat*, rather than the actual route of delivery, as being the appropriate method of comparison. Namely, the twin literature is replete with retrospective, population-based studies in which cesarean delivery outcomes are compared with vaginal delivery outcomes, and such reports are prone to selection bias (Sentilhes, 2015).

One recent large, retrospective cohort study of twins from 2000 to 2009 serves to illustrate this point (Roberts, 2015). These investigators reported that prelabor cesarean delivery reduced the risk of severe birth hypoxia, neonatal death, and death up to age 5 years compared with either vaginal or cesarean delivery after labor. All 7099 twins in this study were delivered at or beyond 36 weeks' gestation. The large number of twins studied lends statistical power, but the greatest concern is the "headline" effect that prelabor cesarean delivery produces the best outcome. There is no way to discern planned

cesarean delivery from planned vaginal delivery in this series. Women who had an indication for cesarean delivery were analyzed with women who may have been candidates for vaginal delivery but declined. Conversely, women who labored may have had characteristics that favored cesarean but were already in advanced labor when they presented. These factors introduce selection bias.

The actual cesarean procedure for singletons or twins is technically similar. Blood loss may be greater with twins, and uterine atony is the primary cause. A vertical uterine incision to deliver twins should usually be limited to the same indications that would require one for singletons. Short- and long-term risks after cesarean delivery are similar whether a singleton or twins are delivered. These points are outlined in Chapter 25 (p. 415). Thus, one of the most compelling arguments in favor of vaginal delivery of twins is to avoid the immediate and "downstream" consequences of cesarean delivery.

■ Planned Vaginal Delivery

Vertex/Vertex Presentation

Almost all investigators and guidelines recommend attempting vaginal delivery when both twins present vertex. However, an important caveat is that twin B may not remain in vertex presentation after vaginal delivery of twin A. In such cases, operators who lack experience in breech extraction or internal podalic version typically choose to deliver twin B by cesarean after vaginal delivery of twin A. In one series, 50 percent of combined deliveries were performed on twins in labor with initial vertex/vertex presentations (Breathnach, 2011).

Once the gravida is moved to the OR and properly positioned in stirrups, steps to deliver twin A are begun. Options include waiting for spontaneous delivery or proceeding with operative vaginal delivery. Both uterine contractile force and voluntary expulsive effort tend to be less effective in twin pregnancy, so avoiding a prolonged second stage is prudent. Provided that the prerequisites for operative vaginal delivery have been met, low or outlet forceps delivery to shorten the second stage is reasonable. Of note, infrequently, twin A will fail to engage and will necessitate a cesarean delivery despite complete dilation.

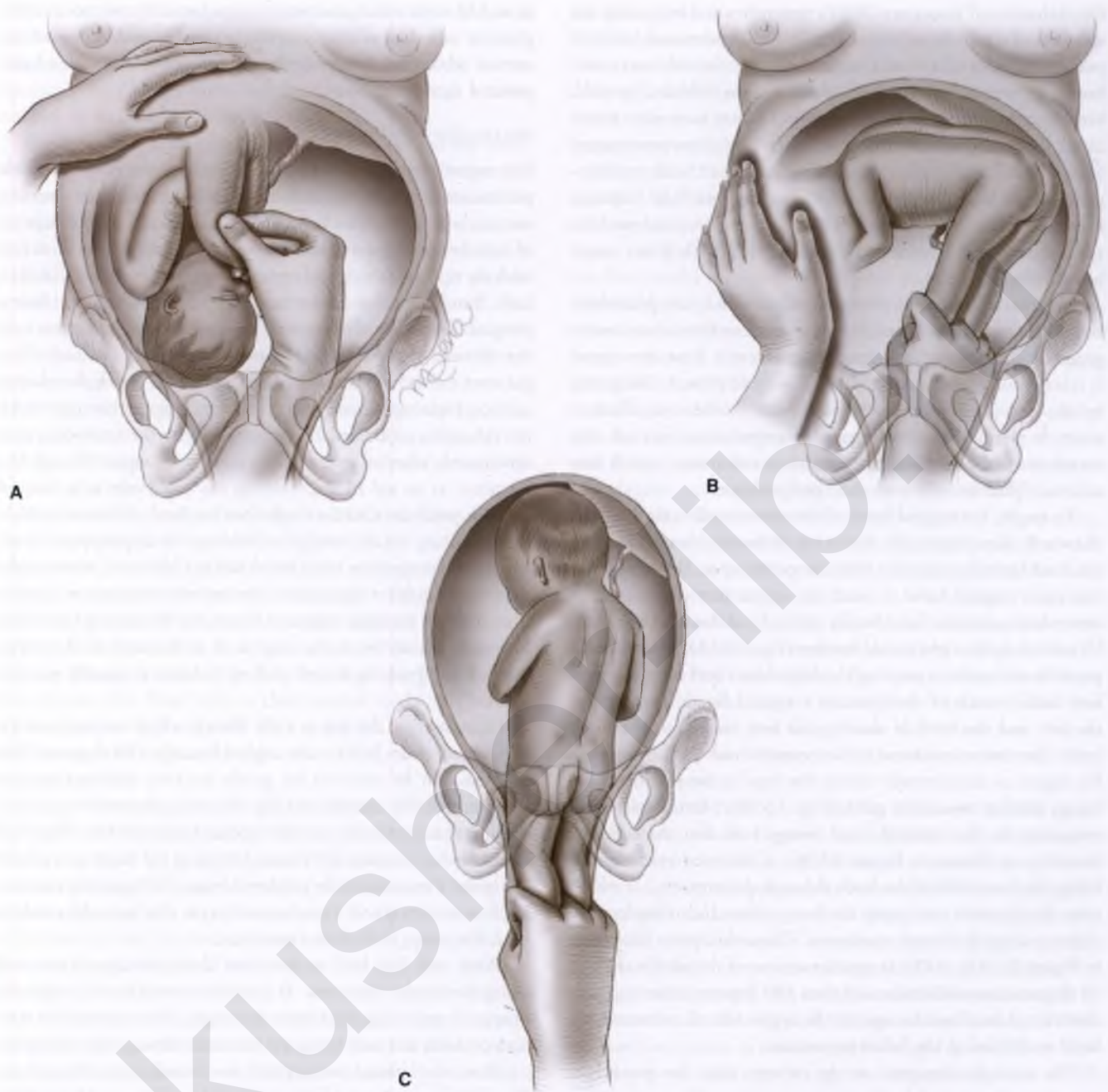


FIGURE 22-3 Internal podalic version of a high vertex. **A.** The abdominal (left) hand of the operator exerts pressure on the right lateral aspect of the fundus to allow the internal (right) hand to locate and grasp the feet. **B.** The abdominal (left) hand of the operator is repositioned to a suprapubic location to elevate the head as the feet are drawn by the right hand toward the pelvis. **C.** Total breech extraction by the internal hand brings both feet through the introitus. Of note, even with a well-functioning epidural anesthetic in place, additional uterine relaxation provided by nitroglycerin or general anesthesia may occasionally be required to accomplish this maneuver.

Once twin A is delivered, the cord is clamped immediately. Delayed cord clamping to potentially boost neonatal red cell volume is not allowed. A vaginal examination is performed to determine the presentation, position, and station of twin B. If twin B has turned to breech, the feet are grasped, membranes are ruptured, and a total breech extraction is performed as described on page 356. If twin B lies transverse, internal podalic version is recommended and is followed by total breech extraction. Internal podalic version is the maneuver in which fetal feet are grasped and

brought through the introitus for breech extraction. Only if the head of twin B is engaged and flexed is delivery of this twin from a vertex presentation planned. Once the head has descended to a station compatible with low or outlet operative vaginal delivery, then this is performed to minimize the interval between twins. Multiparas are often able to quickly push out twin B vaginally without assistance, particularly if the head is small.

For twin B, controversy exists if this fetus is vertex, but the head is unengaged, that is, above 0 station (Fig. 22-3).

Cruikshank and associates (2007) recommended beginning an infusion of oxytocin at 10 mIU/min and condemned internal podalic version of a vertex twin. For experienced operators, however, immediate internal podalic version followed by total breech extraction may be preferable. Others have also advocated internal podalic version of twin B with an unengaged vertex (Fox, 2010; Schmitz, 2008). Compared with resumption of pushing, oxytocin infusion, and artificial rupture of membranes as advocated by Cruikshank, internal podalic version and breech extraction is associated with fewer combined deliveries.

For internal podalic version of a high vertex, the procedure should be performed immediately after detection of an unengaged head to take advantage of several factors. First, the uterus is relaxed for a brief period after delivery of twin A. Moments before, the uterus contained two fetuses, so there is sufficient room to permit easy intrauterine manipulation. Second, the membranes of twin B are almost always still intact, which also aids manipulation and prevents cord prolapse.

To begin, the vaginal hand of the operator elevates the head of twin B. Simultaneously, his or her abdominal hand can push the head laterally and away from the pelvic inlet. This allows the operator's vaginal hand to reach the upper part of the uterine cavity and locate the feet. At this point the abdominal hand can be moved to the right lateral fundus (Fig. 22-3A). Here, caudal pressure will assist in moving the baby lower and bringing fetal feet within reach of the operator's vaginal hand. Transiently, the feet and the head of this second twin will be at the same level. The abdominal hand is then moved back to the suprapubic region to concurrently elevate the head as the internal hand brings the feet toward the pelvis (Fig. 22-3B). Next, total breech extraction by the internal hand brings both feet through the introitus, as shown in Figure 22-3C. Continued traction will bring the lower half of the body through the introitus, at which time the operator can grasp the bony pelvis and complete the delivery using the Lovset maneuver. This technique is illustrated in Figure 21-8 (p. 342). It entails rotation of the fetal body first 90 degrees in one direction and then 180 degrees in the opposite direction. Last, Piper forceps can be applied for the aftercoming head as detailed in the following section.

We strongly disagree, as do others, that the procedure described above is "absolutely contraindicated" or that "no one trained after about 1970 has any idea how to perform the maneuver" (Cruikshank, 2007; Schmitz, 2008). There are centers in the United States that still safely employ and teach this technique. For residents who have performed two or three, assistance by faculty is rarely necessary. In a report on planned vaginal delivery by Fox and colleagues (2010), internal version was employed for the delivery of twin B with an unengaged head only by attending obstetricians. They noted, "House staff were involved in many deliveries, but never as the primary operator." The accompanying editorial called attention to this limitation and appropriately emphasized the need to "train the next generation of obstetricians" (D'Alton, 2010). Whether as operator or as supervisor, an experienced attending should be present to ensure patient safety.

Most internal versions can be successfully accomplished under epidural anesthesia. The procedure should be conducted

in an OR with anesthesia personnel present. Intravenous nitroglycerin in a dose of 200 to 400 μg can be used if needed for uterine relaxation. Infrequently, general anesthesia with a halogenated agent may be necessary.

Vertex/Breech Presentation

For vaginal delivery of twins, this is perhaps the most favorable presentation. If twin B is a double-footing breech, the operator secures both feet with the vaginal hand, ideally before rupture of membranes. Optimal technique entails traction on both feet with the operator's middle finger separating the fetal medial malleoli. If only one foot can be located, traction on that one foot is permissible. The foot is properly grasped with three fingers over the dorsum of the foot from lateral to medial, the index finger over the Achilles tendon, and the thumb under the plantar surface, forming a circle with the index finger, through which the calcaneus protrudes. It is suggested that the fetal toes point downward, whether one or both feet are brought through the introitus, as an aid in maintaining the fetal body in a dorsum anterior position. Once a single foot has been delivered outside the introitus, it can usually be held by the appropriate hand. Namely, the operator's left hand holds a left foot, whereas the right hand holds a right foot. The operator's opposite hand is then inserted into the vagina to locate the remaining foot. That foot may already be in the vagina or at the level of the pelvic inlet. Thus, grasping it and pulling it down is usually not difficult.

Occasionally, the hip is fully flexed, which means that the two legs of twin B form an angle of nearly 180 degrees. This problem can be resolved by gentle traction with a finger in the groin of the undelivered leg. Once the buttocks approach the introitus, pressure on the medial aspect of the thigh will cause the hip to externally rotate, bringing the thigh away from the body. Pressure on the popliteal fossa will bring the remaining foot within reach. Gentle traction on this foot will result in both feet being outside the introitus.

With each foot held as described above, steady traction will bring the thighs into view. It is rarely necessary to change the operator's grip from the feet to the thighs, since most often traction on both feet will bring the buttocks through the introitus.

Now, the operator must place two thumbs over the sacrum. The following steps are fully illustrated in Chapter 21 (p. 340). Some authors employ a wet towel over the pelvis to prevent slippage, but such a maneuver obscures the bony landmarks. It is preferable to position the thumbs on the sacrum so that both the interphalangeal and metacarpophalangeal joints of each are apposed. The index fingers are placed vertically over the iliac crests to obtain a secure grip on the pelvis of twin B with pressure exerted only on bony prominences. The axis of traction should be toward the floor. Rotation of the fetal torso is not attempted until the lower thirds of the scapulae become visible. At this point, gentle rotation, through a 90-degree arc, sometimes repeated through 180 degrees in the opposite direction should produce "winging" of the anterior scapula. This signifies that the anterior arm is ready for delivery.

Either the operator or an assistant can reach over the fetal shoulder, press along the long axis of the humerus, and deliver the anterior arm. Rotation through 180 degrees is aided by

pressure on the delivered scapula and brings the remaining arm anterior. The second arm is then delivered in a similar fashion. This approach to delivering the fetal arms is called the Lovset maneuver. It is highly successful and is associated with a minimal risk of fetal injury (Albrechtsen, 1997).

Rarely, one or both arms may be trapped behind the neck, which is termed a nuchal arm(s). At least two approaches to this problem may be tried. First, the operator can “over-rotate” in the direction of the arm that is nuchal so that friction exerted by the vagina will cause the arm to be released (Fig. 21-13, p. 343). If this maneuver is unsuccessful, the fetus is pushed upward in the birth canal and rotation is again attempted. As a last resort, the nuchal arm can be forcefully delivered. Importantly, such a maneuver may fracture the humerus. On the rare occasion that the Lovset maneuver fails to deliver the anterior arm, the body of the fetus can be elevated over the opposite maternal groin and the posterior arm delivered first (Fig. 21-11, p. 343). Although effective, such a method is quite unusual for delivery of a breech second twin.

With only the head of the baby undelivered, Piper forceps can be applied as illustrated in Figure 21-18 (p. 346). To begin, twin B is held by an assistant in a swayback position, taking care to keep the arms and legs out of the way of the kneeling operator. The use of a towel to support the fetus is a suitable alternative. The fetal body is moved to the maternal right to aid application of the left branch of the Piper forceps from below. The fetal body is then moved to the left for the insertion of the right branch. As a reminder, the branches of the forceps are designated by the side of the mother to which they are applied.

The two branches are articulated, and the handles are elevated. This delivers the head by flexion with very little traction. Pressure exerted by four fingers of the operator’s nondominant hand along the posterior wall of the vagina will bring the mouth and nose into view. Sometimes, the forceps may need to be lowered and elevated a second time. This “pump-handle maneuver” was described by Dennen (1955). The assistant should raise and lower the body of the infant in coordination with the operator’s forceps movement, taking care not to hyperextend the body or the neck. It is not necessary to disarticulate the Piper forceps prior to delivering the head. If extra room is needed for various manipulations of twin B, a mediolateral episiotomy is recommended. For a multipara with a relaxed introitus, an episiotomy may not be necessary.

Although the prophylactic use of Piper forceps is highly recommended, the aftercoming head of twin B can be delivered using a Mauriceau-Smellie-Veit maneuver. This is described and illustrated in Figure 21-15 (p. 344). This technique also emphasizes flexion but involves traction on the fetal shoulders. This in turn stretches the cervical spine of the infant and risks injury.

Vertex/Transverse Presentation

In a series of 758 consecutive sets of twins born after 35 weeks’ gestation with a cephalic first twin, 657 (87 percent) had a planned vaginal delivery (Schmitz, 2008). This unusually high percentage of planned vaginal delivery of twins reflects the fact that vaginal delivery was proposed to every woman with a clinically normal pelvis without prior cesarean delivery, as long as

the second twin’s estimated weight was not 25 percent larger. Of 518 women who delivered twin A vaginally, only 40 women had a second twin that was found to be in a transverse lie. Although these figures may not be generalizable, they indicate that a transverse twin B is likely to be the least common presentation compared with vertex or breech second twins.

The second twin can be transverse with the head to the maternal right or left. In either case, the fetal back can be anterior, posterior, superior, or inferior. For each of these variations, the goal of the operator is to locate, grasp, and bring the feet toward the introitus (internal podalic version). This is followed by total breech extraction. Although most such procedures are easier than turning a vertex twin B with an unengaged head, version of a back-down transverse lie can be challenging and is illustrated in Figure 22-4.

In Figure 22-4A, the operator’s hand must pass well up into the fundus to secure the posterior foot. Then, in the second image, traction on that foot causes the baby to rotate 180 degrees around its long axis in a “barrel roll” fashion (Fig. 22-4B). This illustration shows the hand of the operator approaching the posterior foot from the anterior uterine wall, but following the posterior uterine wall and rotating the baby in the opposite direction can also be tried. Either way, the posterior foot will be brought down first, resulting in descent of the body with dorsum anterior. As shown in Figure 22-4C, traction is exerted on both feet. But again, it is permissible to bring down one foot, secure it, and then reinsert a hand into the uterus to locate and bring down the second foot. Nitroglycerin can be administered intravenously as necessary for uterine relaxation.

If the second twin is in a back-up transverse lie and membranes spontaneously rupture, the umbilical cord can prolapse. Some reports cite this complication as a reason for combined delivery. A preferred approach is to proceed with internal podalic version and total breech extraction (Fig. 22-5). Note that in this figure the umbilical cord is already prolapsed. If uterine relaxation is needed, intravenous nitroglycerin can be administered by anesthesiology staff. The recommended dose varies widely in the literature. In the report by Dufour and coworkers (1998), the dose for version of a transverse lie ranged from 500 to 1500 μg . However, most reports suggest more modest doses of 200 to 400 μg .

Breech Twin A

Figure 22-6 shows a set of breech/breech twins. There is no level I evidence to support a preferred route of delivery in this circumstance. Several reports document satisfactory outcomes with vaginal delivery (Blickstein, 2000; Sentilhes, 2007). In the report by Blickstein and associates (2000), the numbers of breech/vertex and breech/breech twins were nearly equal. For breech/vertex twins, the problem of interlocking has been rarely reported. The incidence varies between 1 per 500 and 1 per 1000. With this complication, the chins of both twins may come in contact with each other in a way that could interfere with breech delivery of twin A.

In the United States, most obstetricians choose cesarean delivery when twin A presents breech. However, salutory results have been achieved with vaginal delivery in other

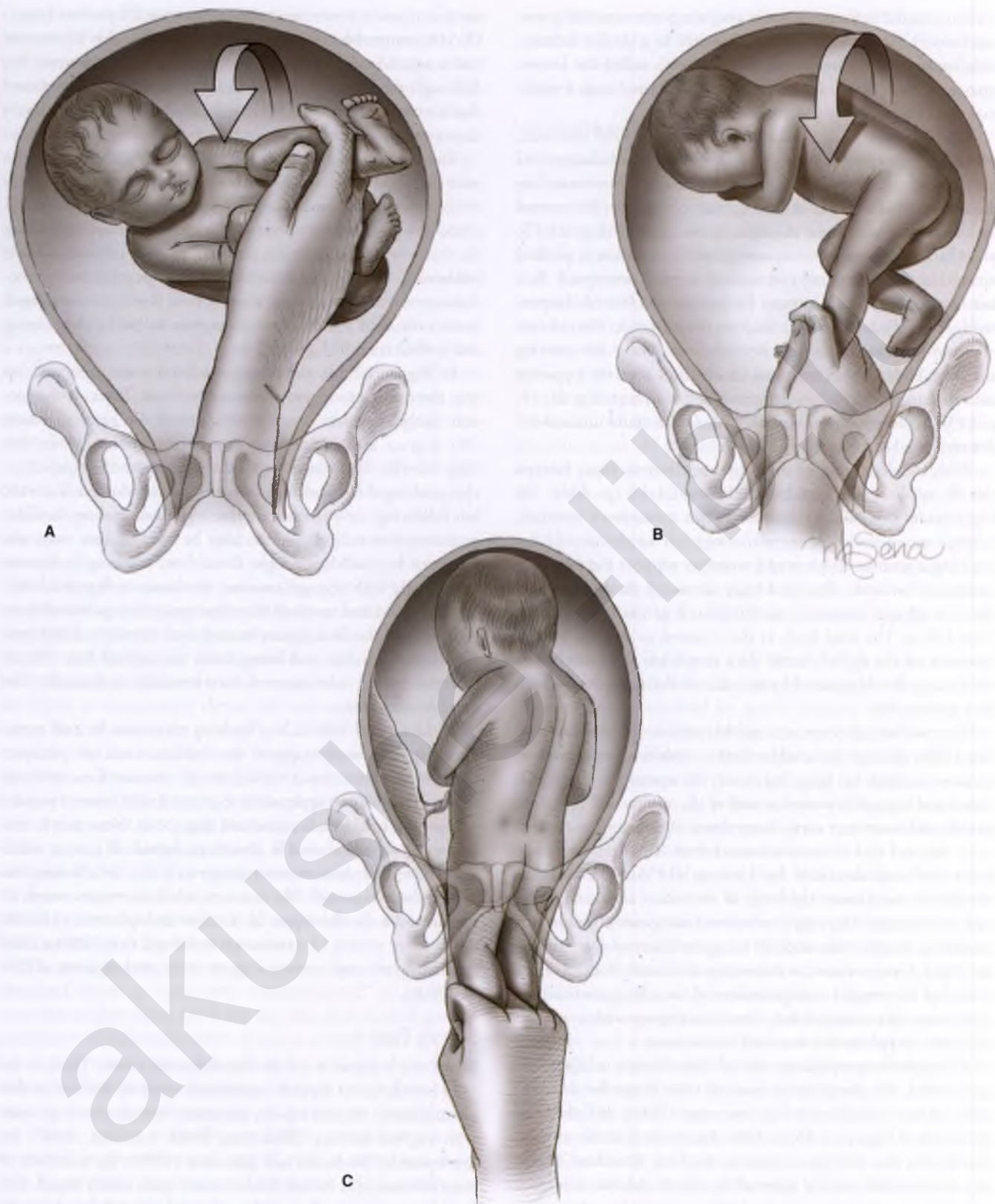

FIGURE 22-4 Version of a back-down transverse lie. **A.** The operator's hand has been inserted nearly to the fundus along the anterior uterine wall to grasp the posterior foot of the fetus. It is sometimes easier to pass the hand along the posterior uterine wall to reach the posterior foot. **B.** The posterior foot is brought around and down in a barrel-roll maneuver, which can be performed in either the direction shown, or in the opposite direction if the operator's hand has passed along the posterior uterine wall. The latter is the author's preference. **C.** Note that in B, the second foot is close enough to reach, after which the operator can bring both feet down and through the introitus. As with internal podalic version for an unengaged vertex, this maneuver for a back-down transverse lie may be aided by the addition of an agent to relax the uterus.

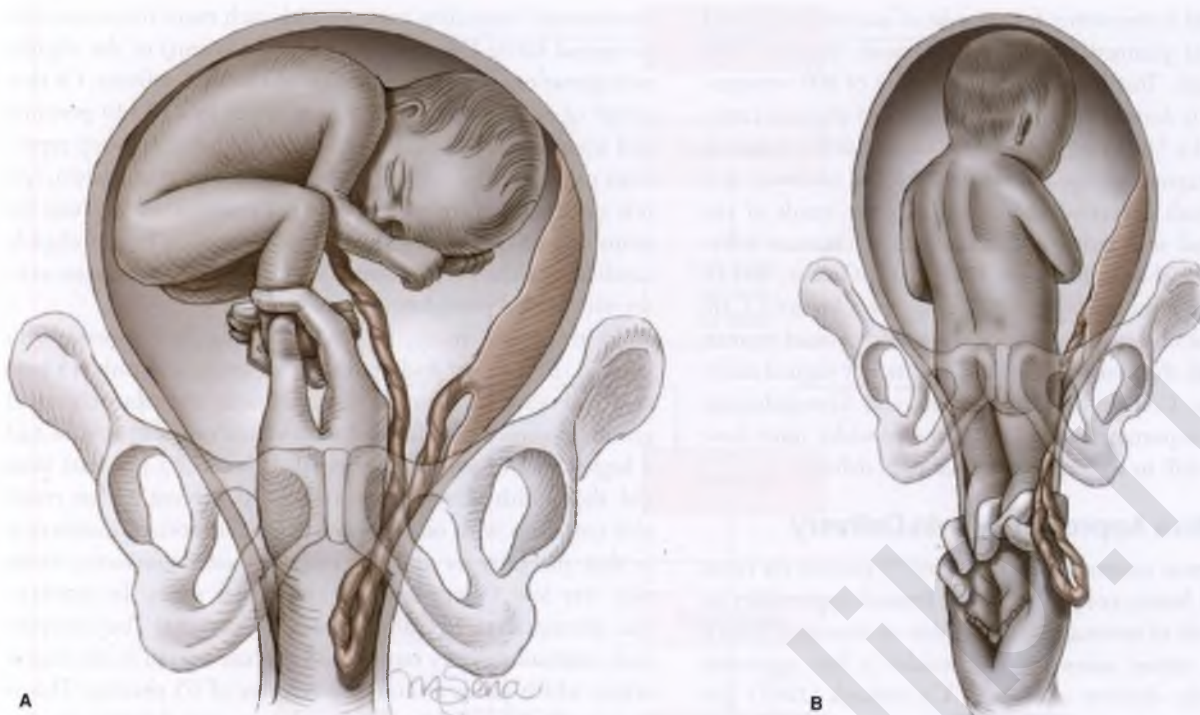


FIGURE 22-5 Back-up transverse lie with umbilical cord prolapse. **A.** Both feet are grasped with the operator's right hand, with the second finger between the medial malleoli. The careful observer will note that this procedure is being performed urgently in this case, not electively, because the umbilical cord has prolapsed. **B.** Both feet have been brought through the introitus simultaneously. It is permissible to bring down a single foot first, secure it, and then locate and bring down the remaining foot (see text). Cord prolapse of twin B is not an emergency that requires immediate cesarean delivery. Breech extraction can be safely and more expeditiously performed.

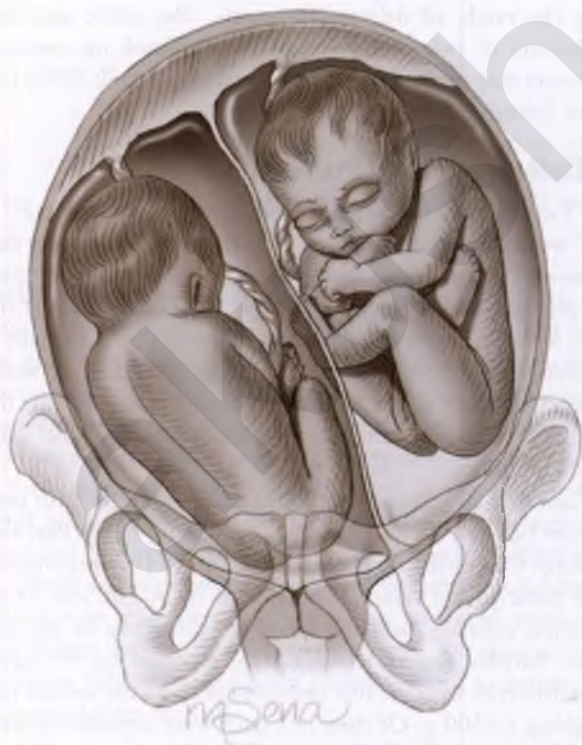

FIGURE 22-6 In up to 20 percent of twin gestations, twin A will present by the breech. In approximately, half of such cases (10 percent), twin B will also be in breech presentation, as shown in this figure. The other half will be breech/vertex. Especially for parous women, this circumstance is amenable to planned vaginal delivery (see algorithm in Figure 22-7).

countries. If vaginal breech delivery of twin A is planned, the prerequisites outlined in Chapter 21 should be met: frank or complete breech, estimated fetal weight of 2000 to 4000 g, fetal head flexed, and maternal pelvis clinically adequate. Once the first twin has been delivered, immediate vaginal examination to determine the presentation of twin B is performed. Management of the second twin should mirror that described when twin A is vertex.

Justification

The approach to planned vaginal delivery just outlined may seem aggressive to some. However, increasing evidence supports such an approach (Barrett, 2013; Carroll, 2006; Fox, 2010; Schmitz, 2008; Vayssière, 2011). The caveat in all these publications emphasizes that “vaginal delivery should be performed by an obstetrician with experience in the vaginal delivery of twins” (Vayssière, 2011). Fox and colleagues (2010) did not report the number of internal podalic versions, but Schmitz and coworkers (2008) reported 209 such versions with only 3 failures. Between these two reports, there were only 3 combined deliveries among 787 planned vaginal deliveries of twins (0.4 percent). In the Twin Birth Study, the 4-percent rate of combined delivery was 10 times higher (Barrett, 2013). This is still acceptable if one considers that the trial involved obstetricians from 106 centers in 25 countries. In this trial, planned cesarean delivery offered no reduction in perinatal mortality or serious neonatal morbidity rates with the first twin in cephalic presentation. Based on these results, one could argue that nearly 800 women in the planned cesarean group underwent unnecessary

laparotomy and hysterotomy for the sake of accumulating level I evidence that planned vaginal delivery with the first twin cephalic was safe. This conservative estimation of 800 unnecessary cesareans is derived from multiplying 1393 planned cesarean deliveries by 56 percent, the actual vaginal delivery rate in the planned vaginal group. Although a leading textbook and an editorial both expressed skepticism that the result of the trial would lead to a reduction in the rate of cesarean delivery for twins, it should (Cunningham, 2014; Greene, 2013). We concur with the recommendation in the Obstetric Care Consensus that obstetric care providers should counsel women with twins with the first twin cephalic to attempt vaginal delivery (American College of Obstetricians and Gynecologists, 2014b). The important caveat is that the provider must have the necessary skill to accomplish vaginal twin delivery.

■ Alternative Approach to Twin Delivery

Given the current cesarean delivery rate of 75 percent for twins in the United States, coupled with the limited opportunity to acquire the skills of internal podalic version or even total breech extraction, it seems necessary to consider a less aggressive approach to the delivery of twin B. Cruikshank (2007) also perceived this need and detailed a workable procedure in his report.

If twin A has been delivered vaginally, the operator should perform a vaginal examination to ascertain the presentation of twin B. If twin B is vertex, either engaged or unengaged, the patient is encouraged to push. Infrequent or ineffective contractions can be improved with the addition of titrated intravenous oxytocin. The anticipated result is descent of the vertex. Delivery is completed either by spontaneous expulsion or by operative vaginal delivery from station +2 or lower.

If examination reveals a back-up transverse lie or an incomplete breech, total breech extraction is ideal. This is with the caveat that operator's skill and experience must be sufficient to complete the delivery. For twin B in frank breech presentation, it would be reasonable to add oxytocin and await descent, as described above for a vertex twin B. For the uncommon situation in which twin B lies transverse and back down, the degree of difficulty of total breech extraction is higher. In this circumstance and in those when the operator is unable to perform total breech extraction, external cephalic version (ECV) with or without the use of a beta-mimetic agent to relax the uterus may be preferable to performing cesarean delivery of twin B straightaway. One of the criticisms of ECV in this setting is a high rate of combined delivery. However, if combined delivery is considered the default option, any successes with ECV would reduce the incidence of combined delivery.

A somewhat less aggressive approach to twin delivery than the one proposed in this chapter was taken at Brigham & Women's Hospital in the United States (Easter, 2016). These authors reported a series of 1250 twin births from 2007 to 2011. Gestational age was ≥ 32 weeks, and exclusion criteria were prior cesarean, contraindications to labor, and others. In sum, 716 sets of twins with the first twin presenting cephalic were eligible. Remember that consensus guidelines from the American College of Obstetricians and Gynecologists (2014b)

recommend counseling patients with such twins for an attempt at vaginal birth. Despite this, 367 (51 percent) of the eligible twin gestations were taken directly to cesarean delivery. Of that group of 367 women, twin B was vertex in 110 (30 percent) and nonvertex in 257 (70 percent). Whether this group represents provider preference or patient preference is unknown, but it is apparent that reducing the overall cesarean delivery rate for twins will be challenging, given that more than half of eligible candidates do not even attempt vaginal delivery at a major center with skilled providers available.

In this same study, of the remaining 349 women who labored, 85 percent had vertex/vertex twins and only 15 percent had vertex/nonvertex twins. Of note, the relatively small group of women who labored with vertex/nonvertex twins had a higher rate of successful vaginal delivery (85 percent) than did those with vertex/vertex twins (70 percent). That result also conforms with our experience. The important distinction is that the offer or attempt rate for vertex/nonvertex twins was very low (15 percent) in the Easter series. In contrast, our attempt rate typically exceeds 75 percent. The intrapartum cesarean delivery rate was 28 percent overall in the Easter series, which yields a total cesarean rate of 65 percent. This is not much different than the crude cesarean delivery rate for twins of 75 percent in the United States. Finally, recall that this series was limited to twins with the first twin cephalic. This implies that the cesarean delivery rate for all twins in this report may be even higher than the national average. Easter and coworkers (2016) concluded that more research is needed to elucidate the role of provider and patient attitudes in planning the mode of delivery for twins. The active approach to delivery of twins proposed in this textbook on operative obstetrics may prove difficult to generalize (Carroll, 2006; Fox, 2010; Schmitz, 2008).

■ Delivery of Very Preterm Twins

The Twin Birth Study enrolled women with twins from 32^{0/7} to 38^{6/7} weeks' gestation (Barrett, 2013). For twins younger than 32 weeks' gestation, no level I evidence is available to guide the provider on the route of delivery for twins with the first twin cephalic. However, retrospective studies lend support to planned vaginal delivery at gestational ages less than 32 weeks. In aggregate, they are underpowered to conclude definitively that outcomes between planned cesarean and planned vaginal delivery do not differ.

Caukwell and coworkers (2002) reported on 30 twin pregnancies between 24 and 31 weeks' gestation with a first twin cephalic. Cases with a cephalic twin B ($n = 14$) were compared with those with a noncephalic twin B ($n = 16$). All 30 sets delivered vaginally, and she found no difference in any outcome. Barzilay and associates (2015) reported on 49 vaginal twin deliveries with the first twin cephalic and the second twin weighing ≤ 1500 g. Of these, 21 pairs were cephalic/cephalic, and 29 pairs were cephalic/noncephalic. Compared to 142 sets of twins delivered by cesarean, the vaginally delivered twins did not have higher morbidity or mortality rates but had a lower incidence of respiratory distress syndrome.

Sentilhes and colleagues (2015) reported experience from six centers in France with twin delivery between 26^{0/7} and 31^{6/7}

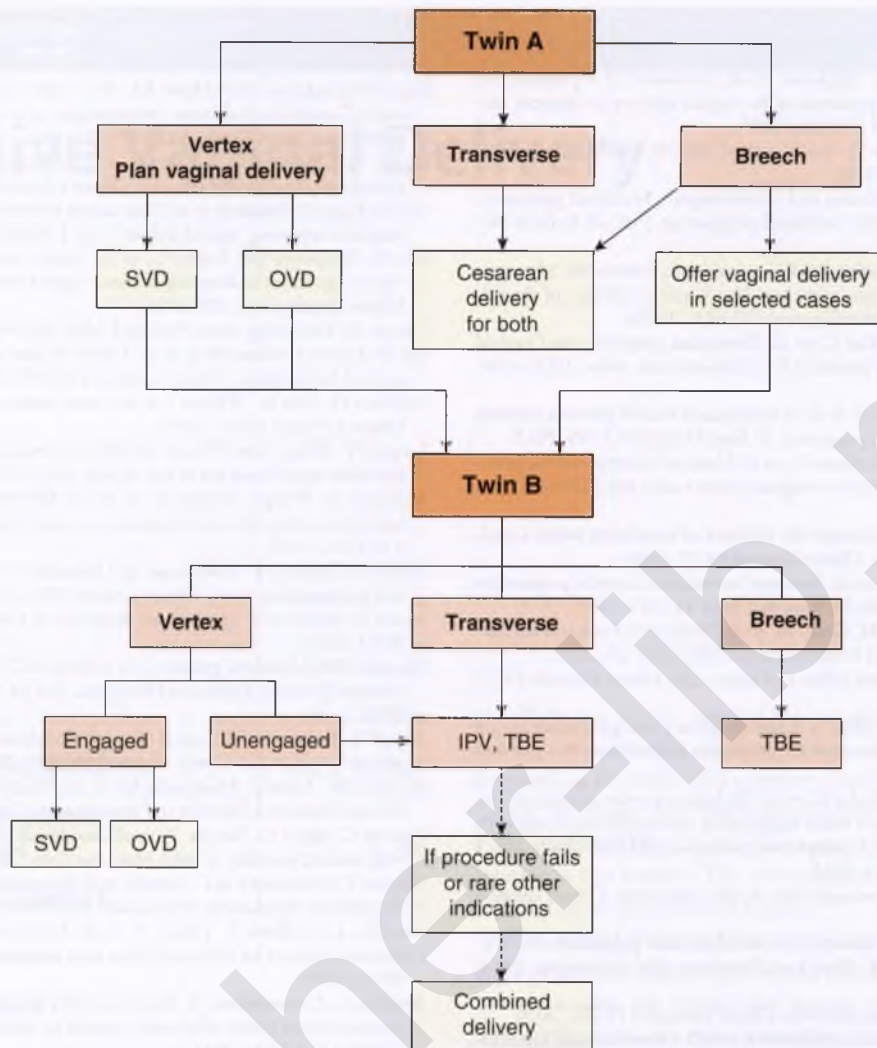


FIGURE 22-7 Algorithm for delivery of dichorionic and monochorionic/diamniotic twins. IPV = internal podalic version; OVD = operative vaginal delivery; SVD = spontaneous vaginal delivery; TBE = total breech extraction.

weeks. The planned vaginal delivery group comprised 248 women, of whom 213 delivered vaginally. In the planned cesarean group ($n = 63$), 13 women delivered vaginally before a cesarean delivery could be performed. Compared with planned cesarean delivery, rates of fetal mortality or severe neonatal morbidity with planned vaginal delivery were not increased.

From these three reports, one can conclude that vaginal delivery of very preterm twins can be undertaken by providers with experience. However, data on the optimal mode of delivery for such twin deliveries are limited. When performing total breech extraction or internal podalic version on very small twins, care is needed to distinguish a foot from a hand. The same principle should be followed as for larger twins in regard to limiting the intertwin delivery interval.

Algorithm

The chapter on multifetal gestations in the second edition of *Operative Obstetrics* concluded with an algorithm summarizing the preferred methods of intrapartum management (Newman, 2002). In the ensuing 13 years, the literature pertaining to

twin delivery has suggested the need for major changes to that algorithm. The approach illustrated in [Figure 22-7](#) is modified from Schmitz and coworkers (2008) and reflects our preference for delivery of twins. Alternatives to most of the decision nodes have been published (Cruikshank, 2007).

TRAINING

It is fitting that a chapter calling for a reduction in the cesarean delivery rate for twins conclude with a plea for training the obstetricians of tomorrow. Active management of the second twin to shorten the interval between twins requires a special set of skills. These include intrauterine manual dexterity, total breech extraction, internal podalic version, and familiarity with the application of Piper forceps to the aftercoming head, to cite a few. For cephalic presentations and delivery of either twin, the ability to accurately diagnose position and safely perform operative vaginal delivery is essential. Undoubtedly, residents can master these skills. Teachers are needed, and they are in short supply.

REFERENCES

- Albrechtsen S, Ranmussen S, Reighstad, et al: Evaluation of a protocol for selecting fetuses in breech presentation for vaginal delivery or cesarean section. *Am J Obstet Gynecol* 177:586, 1997
- Alexander J, Leveno K, Rouse D, et al: Cesarean delivery for the second twin. *Obstet Gynecol* 112:748, 2008
- American College of Obstetricians and Gynecologists: Multifetal gestations: twin, triplet, and higher order multifetal pregnancies. Practice Bulletin No. 144, May 2014a
- American College of Obstetricians and Gynecologists; Society for Maternal-Fetal Medicine: Obstetric care consensus No. 1: safe prevention of the primary cesarean delivery. *Obstet Gynecol* 123:693, 2014b
- Anselem O, Mephon A, Le Ray C, et al: Continued pregnancy and vaginal delivery after 32 weeks of gestation for monoamniotic twins. *EJOG* 194:194, 2015
- Barrett J, Hannah M, Hutton E, et al: A randomized trial of planned cesarean or vaginal delivery for twin pregnancy. *N Engl J Med* 369:1295, 2013
- Barzilay E, Mazaki-Tovi S, Amikam U, et al: Mode of delivery of twin gestation with very low birthweight: is vaginal delivery safe? *Am J Obstet Gynecol* 213:219.e1, 2015
- Blickstein I, Goldman R, Kupferminc M: Delivery of breech first twins: a multicenter retrospective study. *Obstet Gynecol* 95:37, 2000
- Booker W, Fox N, Gupta S, et al: Antenatal surveillance in twin pregnancies using the biophysical profile. *J Ultrasound Med* 34:2071, 2015
- Breathnach FM, McAuliffe FM, Geary M, et al: Prediction of safe and successful vaginal twin birth. *Am J Obstet Gynecol* 205(3):237.e1, 2011
- Carroll M, Yeomans E: Vaginal delivery of twins. *Clin Obstet Gynecol* 49(1):154, 2006
- Caukwell S, Murphy D: The effect of mode of delivery and gestational age on neonatal outcome of the non-cephalic-presenting second twin. *Am J Obstet Gynecol* 187:1356, 2002
- Corcoran S, Breathnach F, Burke G, et al: Dichorionic twin ultrasound surveillance: sonography every 4 weeks significantly underperforms sonography every 2 weeks: results of the prospective multicenter ESPRiT study. *Am J Obstet Gynecol* 213:551.e1, 2015
- Cruikshank D: Intrapartum management of twin gestations. *Obstet Gynecol* 109:1167, 2007
- Cunningham F, Leveno K, Bloom S, et al: Multifetal pregnancy. In Williams Obstetrics, 24th ed. New York, McGraw-Hill Education, 2014, p 891
- D'Alton M: Delivery of the second twin. *Obstet Gynecol* 115:221, 2010
- Dennen EH: Forceps deliveries. In Heaton CE (ed): Obstetrics and Gynecology: a Series of Monographs. Philadelphia, FA Davis, 1955, p 174
- Dufour P, Vinatier D, Vanderstichele S, et al: Intravenous nitroglycerin for internal podalic version of the second twin in transverse lie. *Obstet Gynecol* 92:416, 1998
- Easter SR, Lieberman E, Carusi D: Fetal presentation and successful twin vaginal delivery. *Am J Obstet Gynecol* 214(1):116.e1, 2016
- Emery SP, Bahtiyar MO, Dashe JS, et al: The North American Fetal Therapy Network Consensus Statement: prenatal management of uncomplicated monochorionic gestations. *Obstet Gynecol* 125(5):1236, 2015a
- Emery SP, Bahtiyar MO, Moise KJ: The North American Fetal Therapy Network Consensus Statement: management of complicated monochorionic gestations. *Obstet Gynecol* 126:575, 2015b
- Fausett MB, Barth WH Jr, Yoder B, et al: Oxytocin labor stimulation of twin gestations: effective and efficient. *Obstet Gynecol* 90:202, 1997
- Fox N, Gupta S, Melka S, et al: Risk factors for cesarean delivery in twin pregnancies attempting vaginal delivery. *Am J Obstet Gynecol* 212:106, 2015
- Fox N, Silverstein M, Bender S, et al: Active second-stage management in twin pregnancies undergoing planned vaginal delivery in a U.S. population. *Obstet Gynecol* 115:229, 2010
- Greene M: Delivering twins. *N Engl J Med* 369(14):13652, 2013
- Lee H, Gould J, Boscardin J, et al: Trends in cesarean delivery for twin births in the United States. *Obstet Gynecol* 118:1095, 2011
- Leftwich H, Zaki M, Wilkins I, et al: Labor patterns in twin gestations. *Am J Obstet Gynecol* 254:e1, 2013
- Leung TY, Wing, Tam WH, et al: Effect of twin-to-twin delivery interval on umbilical cord blood gas in the second twins. *BJOG* 109:63, 2002
- Melamed N, Wong J, Asztalos E, et al: The likelihood of change in fetal presentation during the third trimester in twin pregnancies. *Obstet Gynecol* 126:1231, 2015
- Miller J, Chauhan S, Abuhamad A: Discordant twins: diagnosis, evaluation and management. *Am J Obstet Gynecol* 206:10, 2012
- Moise K, Johnson A: There is no diagnosis of twins. *Am J Obstet Gynecol* 203:1, 2010
- Newman RB: Multifetal gestation. In Gilstrap LC III, Cunningham FG, Van-Dorsten JP (eds): Operative Obstetrics, 2nd ed. New York, McGraw-Hill, 2002, p 165
- Persad V, Baskett T, O'Connell C, et al: Combined vaginal-cesarean delivery of twin pregnancies. *Obstet Gynecol* 98:1032, 2001
- Rayburn W, Lavin J, Miodovnik M, et al: Multiple gestation: time interval between delivery of the first and second twins. *Obstet Gynecol* 63:502, 1984
- Roberts C, Algert C, Nippita T, et al: Association of prelabor cesarean delivery with reduced mortality in twins born near term. *Obstet Gynecol* 125:103, 2015
- Schmitz T, Carnavalet Cde C, Azria E, et al: Neonatal outcomes of twin pregnancy according to the planned mode of delivery. *Obstet Gynecol* 111:695, 2008
- Sentilhes L, Goffinet F, Talbot A, et al: Attempted vaginal versus planned cesarean delivery in 195 breech first twin pregnancies. *Acta Obstet Gynecol* 86:55, 2007
- Sentilhes L, Oppenheimer A, Bouhours AC, et al: Neonatal outcome of very preterm twins: policy of planned vaginal or cesarean delivery. *Am J Obstet Gynecol* 213:73.e1, 2015
- Vayssière C, Benoist G, Blondel B, et al: Twin pregnancies: guidelines for clinical practice from the French college of gynaecologists and obstetricians. *Eur J Obstet Gynecol Reprod Biol* 156(1):12, 2011
- Wen SW, Fung KF, Oppenheimer L, et al: Occurrence and predictor of cesarean delivery for the second twin after vaginal delivery of the first twin. *Obstet Gynecol* 103:413, 2004

CHAPTER 23

Operative Vaginal Delivery

HISTORY	363
INSTRUMENT CHARACTERISTICS	365
INDICATIONS, PREREQUISITES, AND CLASSIFICATION	369
PREOPERATIVE ASSESSMENT	370
TECHNIQUE	373
ASSOCIATED MORBIDITY	385
CONCLUSION	387

In the two prior editions of this textbook, forceps delivery and vacuum extraction were covered in separate chapters. Following the lead of Williams Obstetrics (Cunningham, 2014), the two topics have been combined under the heading operative vaginal delivery (OVD) for this third edition. Although overall rates for OVD are declining in the United States, the need is urgent for increased training in and use of these procedures as one method of curbing the escalating cesarean delivery rate (Spong, 2012). This chapter presents a structured approach to resident training in OVD procedures. As a second goal, the technical considerations involved in the use of various types of forceps and vacuum extractors are emphasized.

HISTORY

Forceps have been used for more than four centuries, whereas vacuum extractors date back only 60 years. The first crude forceps, which are Chamberlen forceps, have been modified in small and large ways over the centuries. The first meaningful

modification of the original instrument was the addition of a pelvic curve, variably credited to Levret of France or Smellie of England in the mid 18th century. To best appreciate the pelvic curve, one must view the forceps from the side as they rest on a flat surface (Fig. 23-1). The toes of the blades are elevated relative to the shanks. This corresponds to the axis of the pelvis, referred to as the curve of Carus.

The second major advance was the enunciation of the principle of axis traction by the French obstetrician Tarnier in 1877. Simply stated, the higher the station of the fetal head at forceps application, the more posterior the vector of initial traction should be. This concept is illustrated in Figure 23-2, which shows the need to gradually elevate the forceps handles as the head descends. As a teaching tool for this point, an American obstetrician, Arthur Bill, developed an axis traction device, which can be placed over the finger guards of most forceps (Fig. 23-3A). The instrument has a T-shaped handle, with a laterally placed indicator arrow and line (Fig. 23-3B). When the arrow points directly to the line, traction is along the path of least resistance. This device is a valuable training aid. For the neophyte, it shows



FIGURE 23-1 Tucker-McLane forceps, side view. Anatomy of the blade is labeled.

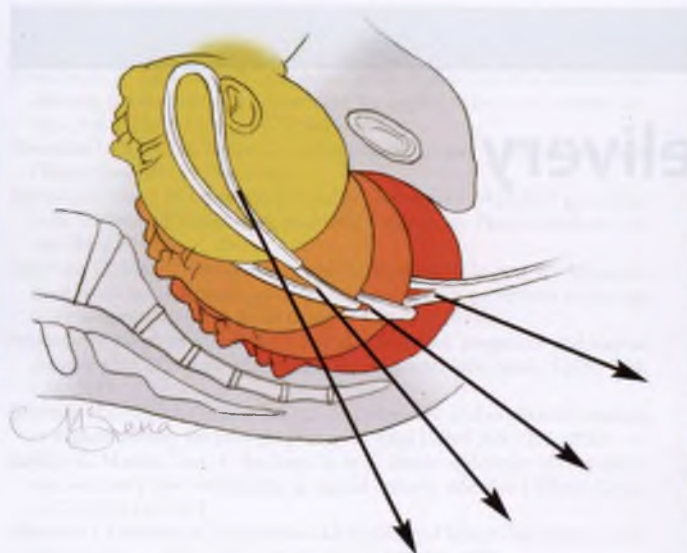


FIGURE 23-2 The higher the fetal head, the more posterior is the initial direction of traction. Of equal importance, the vector of traction must change continuously as the head descends, becoming progressively more anterior.

the starting and finishing positions of the forceps handles and the arc that they transcribe as the head descends.

Beginning in the early 1900s, four American obstetricians developed forceps that are still in use today. Each of the four instruments was crafted for specific purposes. Edmund Piper introduced a long forceps with an exaggerated reverse pelvic curve (Fig. 23-4). This modification makes the instrument ideal for application to the aftercoming head at vaginal breech delivery (Piper, 1929).

From Plattsburgh, New York, Lyman Barton designed a forceps with a hinged anterior branch for application to a fetal head in occiput transverse (OT) position (p. 382). The posterior branch has a pronounced curve for application along the hollow of the sacrum. This instrument is especially valuable in cases in which Kielland forceps are contraindicated, such as with a platypelloid pelvis.

Ralph Luikart (1937) first contributed a blade modification to existing instruments, which he called *pseudofenestration*. In comparison, true fenestrated blades have a through-and-through window within the blade. This reduces the degree of




FIGURE 23-3 A. Bill axis traction device. The arms to the right attach to the forceps. **B.** The direction indicator, which consists of an arrow and line, is found on the side of this device.

head slippage that is associated with solid blades during forceps rotation. Disadvantageously, it can increase friction between the blade and vaginal wall. With pseudofenestration, the forceps blade is solid on the maternal side but indented on the inner fetal surface. The goal is to reduce slipping yet improve the ease and safety of application and removal of forceps compared with pure fenestrated blades. In a second publication, Luikart (1940) presented a forceps of his own design, which incorporated advantages of several previously described instruments. His forceps are illustrated on page 367.

Last, Leonard Laufe (1968a) developed divergent forceps that were designed to reduce fetal head compression (Fig. 23-5).




FIGURE 23-4 Compare the length of Laufe-Piper forceps (foreground) with that of Piper forceps (background).



FIGURE 23-5 Laufe divergent outlet forceps.

The two branches of the Laue divergent forceps do not overlap. Instead, they intersect at a pivot lock built into the handle. In another contribution, Laue (1967) modified the Piper forceps by shortening the instrument length considerably and substituting a pivot lock for the English lock of the Piper forceps (see Fig. 23-4). This “short Piper” instrument is especially useful to deliver the aftercoming head of the breech fetus during cesarean delivery.

These contributions built on the work of previous inventors. British, French, and Mexican obstetricians, to name a few, have developed instruments that enjoy greater popularity in their countries of origin. These include Neville-Barnes, Thierry, and Salinas forceps, respectively.

The history of vacuum extraction is more recent, less varied, but important in light of the current popularity of this method. The Malmstrom vacuum extractor was not the first. Simpson produced an instrument in the mid-nineteenth century, but it failed to achieve widespread adoption. The Malmstrom extractor used metal cups of varying diameters: 40, 50, and 60 mm (Malmstrom, 1965). When suction is applied with a handheld device, the scalp and subcutaneous tissue and fluid fill the interior of the shallow metal cup, producing a *chignon*. This term refers to a woman’s hair fashioned into a bun. As an advantage, traction in most cases produces fetal descent with less distention of the vagina and introitus compared with that from forceps. Subsequent modifications include various soft cups to be discussed later.

INSTRUMENT CHARACTERISTICS

■ Forceps in Common Use

Mechanical obstetrical problems do not require a vast array of instruments for their resolution. Pictured in this section are some popular forceps, and their key features are highlighted in Table 23-1. The nomenclature used to describe the parts of forceps is fairly standard. *Forceps* refers to the paired instrument, and each member of this pair is called a *branch*. Branches are designated left or right according to the side of the maternal pelvis to which they are applied (Fig. 23-6). Some operators use the terms branch and blade interchangeably, but it seems preferable to restrict the term blade to the distal part of the branch.

Each type of blade has a toe, a heel, and two curves, cephalic and pelvic (see Fig. 23-1). The bowing outward of each blade

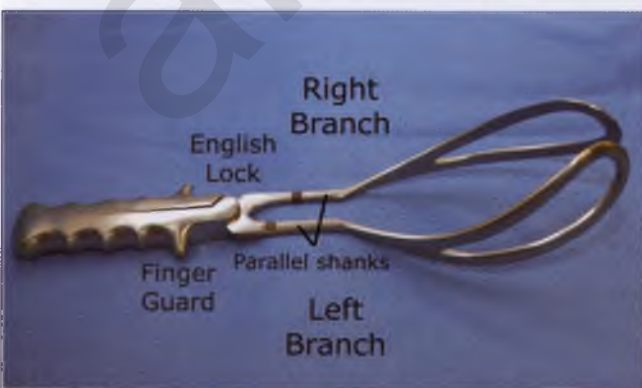

FIGURE 23-6 Simpson forceps. Anatomic parts are labeled. Note the fenestrated blades.

to accommodate the fetal head describes the cephalic curve, which is best seen by viewing the instrument from the top, as shown in part E of Figure 23-7. It is either short and round, which best fits an unmolded head, or long and tapered to fit a molded head. The danger of using forceps with a short and round cephalic curve on a molded head is that the toes of the blades will not be anchored below the malar eminences and may slip off the fetal head. The pelvic curve is best visualized by laying the forceps on a flat surface and noting that the toes of the blades are elevated compared to the heels (see Fig. 23-1).

Blades are of three types: solid, fenestrated, and pseudofenestrated (see Figs. 23-1, 23-6, and 23-7, respectively). Fenestrated blades, from the Latin for window, allow the passage of a finger from the cephalic side to the pelvic side of the blade. They provide the most secure grip on the fetal head but tend to leave forceps marks on the face even when symmetrically applied. As noted earlier, pseudofenestrated blades are solid on the pelvic side but indented on the cephalic side, the Luikart modification (see Fig. 23-7A). This construction offers a more secure grip on the head than solid blades, and they leave less noticeable forceps marks than fenestrated blades. Solid blades are completely smooth on both sides. These blades are slightly thinner, more easily applied, but achieve a less secure grip on the fetal head. These were formerly popular for rotation, but this function has been supplanted by Kielland forceps. Forceps with solid blades are at risk of slipping when firm traction is applied, particularly with a molded head, because the toes may not be anchored below the malar eminences. Despite this potential shortcoming, solid-blade forceps like the Tucker-McLane type retain popularity for delivery of multiparas or other cases with little molding.

Shanks connect the blades to the handles and are either parallel (Simpson type) or overlapping (Elliot type), as shown in Figures 23-6 and 23-7E, respectively. The length of the shanks is variable and contributes to the overall length of the instrument.

Locks are found on all forceps and help to connect the right and left branches and stabilize the instrument. They can be located at the end of the shank nearest to the handles (English lock), at the ends of the handles (pivot lock), or along the shank (sliding lock). Examples are illustrated in Figures 23-6, 23-8, and 23-9, respectively. French and German locks, as seen on the Dewey forceps, consist of a combination of an upright button or bolt joining the shanks, plus a wing nut and screw across the distal handles for added security (Fig. 23-10). French and German locks are infrequently found on forceps in common use in the United States.

Although varied in design, handles, when squeezed, bring the toes closer together and importantly raise compression forces against the fetal head. Innovations to prevent the handles from being brought too closely into apposition include a set screw in the right branch of the Elliot forceps and a bar on the left branch of the Luikart forceps (see Figs. 23-7E and 23-9).

Last, for all but the divergent forceps, lateral projections at the distal end of the handles allow for either manual traction or affixing the Bill axis traction device. These projections are called finger guards or finger grips (Dennen, 1955; Laue, 1968a).

A summary of commonly used forceps together with their primary indications can be found in Table 23-1. Accoucheurs in countries outside the United States will need to substitute

TABLE 23-1. Some Forceps and Their Characteristics

Type & Figure No.	Blade	Lock	Main Function	Undesirable Features	Advantages
Simpson Type —Parallel shanks, long tapered cephalic curve					
Simpson Fig. 23-6	Fenestrated	English	Traction	Forceps marks on infant, distends perineum	Firm grip on head, useful at C/S
Luikart Simpson Fig. 23-7A	Pseudofen.	English	Traction	Distends perineum	Rare forceps marks
Hawks-Dennen Fig. 23-7B	Fenestrated	English	Strong axis traction	Heavy forceps, distends perineum	Built-in axis traction, good for OP pulls
Dewey ^a Fig. 23-7C	Fenestrated	French/ German	Strong axis traction	Prominent forceps marks, distends perineum	Attached axis traction handle, strong traction in correct direction
Piper ^b Fig. 23-7D	Fenestrated	English	Flexion	Long length, rare slipping	Designed for aftercoming head at vaginal breech delivery
Elliot Type —Overlapping shanks, short round cephalic curve					
Elliot Fig. 23-7E	Fenestrated	English	Traction	Forceps marks	Wheel in handle allows for adjustment of compression
Tucker-McLane Fig. 23-7F	Solid	English	Traction/ rotation	Slipping	Useful for multiparas, cases without molding
Luikart-Tucker-McLane Fig. 23-7G	Pseudofen.	English	Traction/ rotation	Slipping, but less than solid blades	Preferable to regular Tucker-McLane
Hybrid Type —Overlapping shanks, long tapered cephalic curve					
Luikart Fig. 23-7H	Pseudofen.	Sliding	Traction/correct asynclitism	Slipping	Combines advantages of several instruments, good all-purpose instrument
Divergent Type —Branches do not cross					
Laufe Fig. 23-4	Pseudofen.	Pivot	Traction for outlet/low	Weak	Minimal compression, best reserved for easy deliveries
Laufe-Piper Fig. 23-5	Fenestrated	Pivot	Flexion	None	Ideal for aftercoming head at C/S, for premature vaginal breech delivery
Special Type —Designed for specific purposes					
Kielland Fig. 23-24	Fenestrated	Sliding	Rotation	Forceps marks, learning curve	Elegant design for rotation
Luikart Kielland Fig. 23-25	Pseudofen.	Sliding	Rotation	May have undesirable pelvic curve	Fewer forceps marks than Kielland, but newer models have a pelvic curve
Barton Fig. 23-32	Fenestrated	Sliding	Traction from OT, rotation	Forceps marks, poor availability	Easier to apply than Kielland, used when Kielland is contraindicated

^aDennen erred in referring to Dewey forceps as DeWees forceps. There are certain similarities, but the work of Das in 1929 clarifies the difference between the two. Both now are rarely used.

^bFor details on application of Piper forceps see Figure 21-18 (p. 302).

C/S = cesarean section; OP = occiput posterior; OT = occiput transverse; Pseudofen = pseudofenestrated.

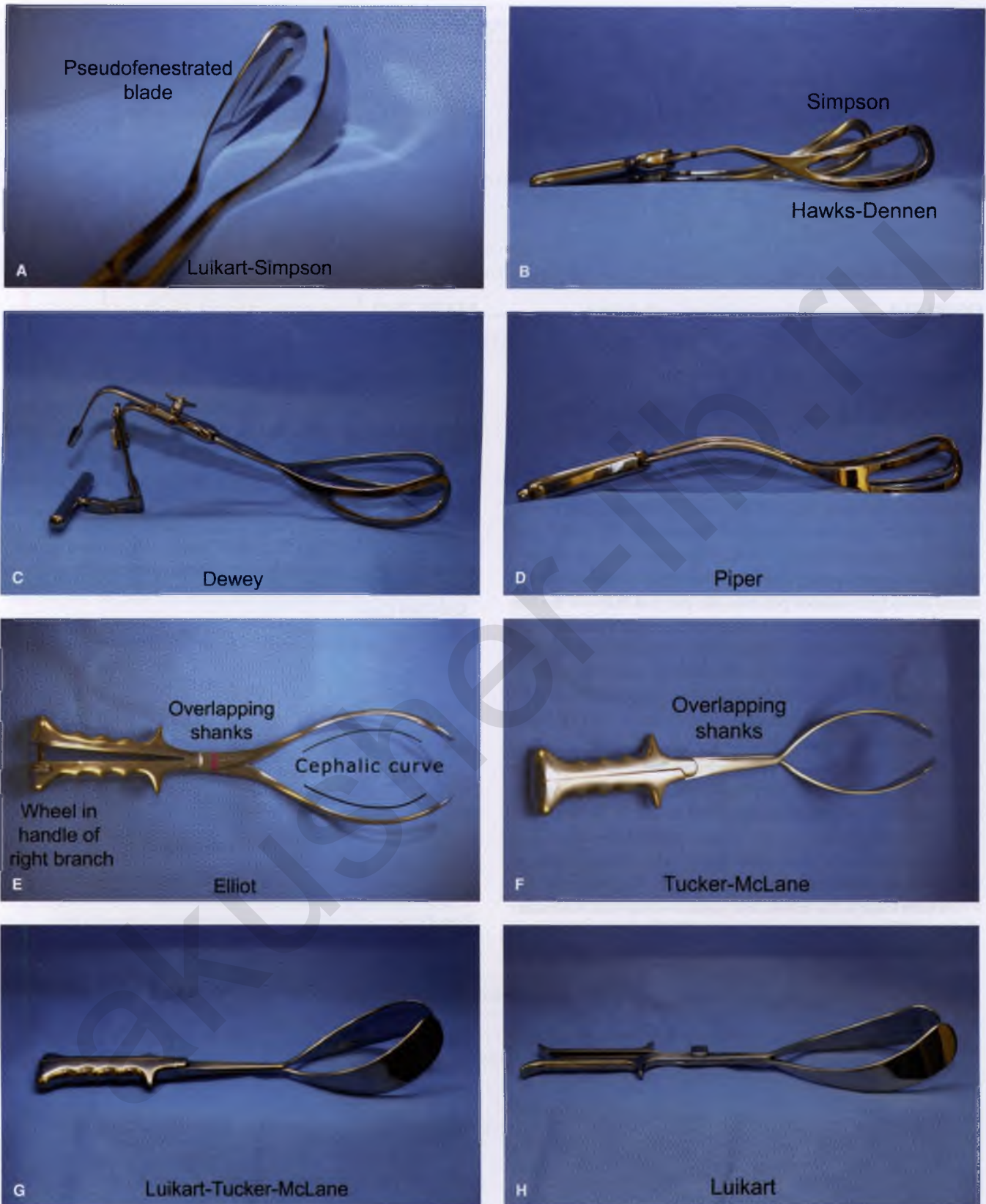


FIGURE 23-7 **A.** Luikart-Simpson forceps. **B.** Hawks-Dennen forceps (*foreground*) with built-in axis traction. Compare with Simpson forceps (*background*). **C.** Dewey forceps. Attached axis-traction handle. **D.** Piper forceps. **E.** Elliot forceps. Note the pivot lock. The cephalic curve is marked. **F.** Tucker-McLane forceps. Note overlapping shanks. **G.** Luikart-Tucker-McLane forceps. **H.** Luikart forceps. Note the pseudofenestrated blades, which are common to all Luikart variants.



FIGURE 23-8 Close-up of the pivot lock of Laue forceps.

their preferences in this table and in the one for vacuum extractors that follows.

■ Vacuum Extractor Features

As a group, vacuum extractors also offer many options, and those in common use are listed in [Table 23-2](#). The differences among vacuum extractors are primarily attributable to the size, shape, and construction of the cup, which is the most important feature. When the cup is applied to a head that is low in the pelvis and nearly in occiput anterior position, the size and shape of the cup are of minimal significance. However, when the fetal head lies at a higher station and is malpositioned, asynclitic, or deflexed, it can be difficult to properly place a bell- or dome-shaped cup. In such cases, a flat, disc-shaped cup offers distinct advantages.

Use of the metal Malmstrom vacuum extractor has diminished considerably with the advent of the various “soft” cups. The first was the Kobayashi Silastic cup, which was bell-shaped and had a fixed diameter of 65 mm. It too has waned in popularity. Among soft cups, some are reusable, whereas others are disposable.

Of secondary importance is whether suction is generated by a handheld device or an electric pump. The handheld pumps are more convenient and less cumbersome.

As with forceps, the station and position of the fetal head affect the ease of cup placement and the likelihood of achieving a successful vaginal delivery. One of the major limitations of vacuum extractors in general is that they fail more often than forceps.

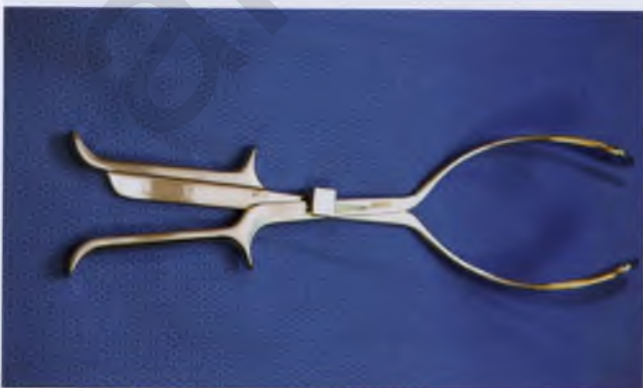

FIGURE 23-9 Luitkart forceps. This view shows the sliding lock and bar in left branch handle.



FIGURE 23-10 Close-up view of French (I-bolt) and German (wing nut and screw) locks seen on Dewey forceps.

■ Instrument Choice

Ideally, forceps or vacuum extractor selection would be evidence-based, but the reality in 2016 does not afford that luxury. For a given clinical situation, more than one instrument is suitable, and most often the choice is based on operator partiality

TABLE 23-2. Vacuum Cups for Operative Vaginal Delivery

Cup Style	Manufacturer
Soft Bell Cup	
GentleVac	OB Scientific
KiwiProCup	Clinical Innovations
MityvacMitySoftBell	CooperSurgical
Pearl Edge Bell Cup	CooperSurgical
SecureCup	Utah Medical Products
SoftTouch	Utah Medical Products
TenderTouch	Utah Medical Products
Tender Touch Ultra	Utah Medical Products
Velvet Touch ^a	Utah Medical Products
Reusable vacuum delivery cup ^a	CooperSurgical
Rigid Mushroom Cup	
Flex Cup	Utah Medical Products
Mityvac M-Style	CooperSurgical
Super M-Style	CooperSurgical
Mityvac M-Select ^b	CooperSurgical
Kiwi OmniCup ^b	Clinical Innovations
Kiwi Omni-MT	Clinical Innovations
Kiwi Omni-C Cup ^c	Clinical Innovations
Metal Cups	
Malmstrom	
Malmstrom with Bird modification ^d	

^aReusable cups.

^bSuitable for occiput posterior positions or asynclitism.

^cFor extractions through a hysterotomy incision during cesarean delivery.

^dThe Bird modification of the original Malmstrom cup moved the traction point away from the center and toward one side of the metal disc.

TABLE 23-3. Prerequisites for Operative Vaginal Delivery

Cervix is fully dilated and retracted
Membranes ruptured
Engagement of the fetal head
Position of the fetal head has been determined
Fetal weight estimation performed
Pelvis thought to be adequate for vaginal delivery
Adequate anesthesia
Maternal bladder has been emptied
Patient has agreed after being informed of the risks and benefits of the procedure
Willingness to abandon trial of operative vaginal delivery and back-up plan in place in case of failure to deliver

Adapted from Royal Australian and New Zealand College of Obstetricians and Gynaecologists, 2015.

(Abenhaim, 2007; Drife, 1996; Yeomans, 2010). Preference, in turn, is based on training and experience. However, these two should not be conflated. Namely, experience is not a substitute for training. It serves only to increase confidence, not skill (Ennis, 1991).

To be fair, advantages and disadvantages exist for both forceps and vacuum extractors. That said, it is untenable to ask someone without training to rotate a fetal head with Kielland forceps just because the literature supports it. However, in certain circumstances, forceps may be the only choice. Examples are face presentation, delivering the aftercoming head of a breech fetus, and for premature births at less than 34 weeks' gestation.

INDICATIONS, PREREQUISITES, AND CLASSIFICATION

The safe performance of OVD requires that operators be familiar with practice guidelines issued by several specialty societies. As expected, these guidelines are not in complete agreement with one another. Insofar as they differ, only clinically important aspects are presented here.

Logically, U.S. obstetricians will adhere to American College of Obstetricians and Gynecologists guidelines. The College

cites three general indications for OVD: prolonged second-stage labor, suspicion of immediate or potential fetal compromise, and shortening of second-stage labor for maternal benefit.

British and French guidelines concur with these three general indications (Royal College of Obstetricians and Gynecologists, 2011; Vayssière, 2011). Of note, the French would consider instrumented delivery after 30 minutes of active pushing if the fetus fails to descend. Such a practice, if adopted in the United States, would quickly reverse the low 3-percent rate of OVD! Prolonged second-stage labor as defined in the United States varies by parity and epidural use and ranges from 1 to 4 hours or more. Interestingly, guidelines from the American College of Obstetricians and Gynecologists (2015) on the topic of OVD do not define prolonged second-stage labor.

Prerequisites for OVD recommended by the American College of Obstetricians and Gynecologists (2015) are shown in [Table 23-3](#). Missing from that list is the requirement for an experienced operator, but this detail remains in the British prerequisites.

Finally, classification of OVD has not changed since it was first published by the American College of Obstetricians and Gynecologists in a 1988 Committee Opinion. Although this committee opinion is no longer current, its classification system is incorporated into the College's (2015) more recent guidelines ([Table 23-4](#)).

TABLE 23-4. Criteria for Types of Forceps Deliveries

Outlet Forceps

Scalp visible at the introitus without separating the labia
 Fetal skull has reached the pelvic floor
 Fetal head is at or on perineum
 Sagittal suture is in anteroposterior diameter or in right or left occiput anterior or posterior position
 Rotation does not exceed 45 degrees

Low Forceps

Leading point of the fetal skull is at station +2 cm or more and not on the pelvic floor
 Without rotation: rotation is 45 degrees or less (right or left occiput anterior to occiput anterior, or right or left occiput posterior to occiput posterior)
 With rotation: rotation is greater than 45 degrees

Midforceps

Station is above +2 cm but head is engaged

Implementation of this system is strongly recommended during documentation of all OVD. British guidelines are adapted from those of the American College of Obstetricians and Gynecologists and emphasize the importance of station and rotation in the definition of OVD types (Royal College of Obstetricians and Gynaecologists, 2011). One difference is that the British recognize two subdivisions of midforceps. These are rotation of ≤ 45 degrees from occiput anterior and rotation of >45 degrees, which include those from occiput posterior positions.

PREOPERATIVE ASSESSMENT

Fetus

Before OVD is attempted, presentation of the fetus as cephalic is an essential requisite. The operator should then carefully assess several other key fetal factors. First, head position must be accurately diagnosed. The three-letter system of nomenclature should be familiar to all obstetricians. Left (L) or right (R) refers to the mother's left or right. For this chapter, the middle letter will always be "O" for occiput. The last letter, "A," "T," or "P," reflects the anterior, transverse, or posterior areas of the maternal pelvis, respectively. Thus, left occiput anterior (LOA) describes a fetal occiput that lies in the anterior and left portion of the maternal pelvis.

However, accurate diagnosis of position is challenging in many cases. First, excess caput succedaneum can cover orienting suture lines. Second, in the multipara, the round fetal head may not undergo molding, and thus suture lines do not override. This can similarly challenge suture identification. Thus, position determination in the first stage of labor beginning at 5 cm of cervical dilation is a recommended practice. It sharpens operator skills and avoids confusion from later caput formation.

Palpation of the fontanel can also mislead. To assess these, the examiner should first identify the sagittal suture. This midline suture is then traced in both directions to determine whether it is directed along an anteroposterior (AP), transverse, or oblique course. When a fontanel is encountered, a small circle should be transcribed with the examining fingers, and the number of lines crossed is carefully counted. The posterior fontanel is triangular and thus will have three lines of intersection: the two lambdoid sutures and the sagittal suture. In contrast, the anterior fontanel is diamond-shaped. It contains four lines of intersection: the sagittal suture, the right and left halves of the coronal sutures, and the frontal (metopic) suture.

In general, the posterior fontanel will be at a higher level in the pelvis than the anterior fontanel if the fetal head is flexed. If both fontanel are felt at the same level, the head is partially extended, which should increase suspicion that the position may be occiput posterior (OP). Identification of an anterior lip of cervix at nearly complete dilation enhances the likelihood that the head position is OP. If only the anterior fontanel is palpable, a brow presentation is a possibility. If so, the fetal orbits may be reached by the tips of the examiner's fingers.

In cases in which fetal head position remains uncertain, the operator should glove the other hand and repeat the above maneuvers. If care is taken not to destation the head, the examiner can try to locate an ear. The posterior ear is usually more accessible. The relationship between the external auditory

meatus and the pinna should lead to an unequivocal determination of position.

The importance of correct position diagnosis cannot be overemphasized, as it is essential for accurate cephalic application of both forceps and vacuum cups. Consistently ascertaining correct position requires "continued practice and constant alertness" (Dennen, 1955). Recently, a randomized trial of sonographic assessment of fetal head position was reported (Ramphul, 2014). The incidence of incorrect diagnosis was significantly lower in the sonographic group than in the standard care group. The authors noted that despite the correct diagnosis of position by sonography, morbidity rates from OVD were not reduced.

In addition to position, the operator should note the fetal head attitude, which may vary from full flexion to full extension. A head that is partially extended may present a larger diameter to the birth canal. Further extension of the head may result in a brow presentation, which is seldom amenable to OVD, especially when it persists after complete dilation.

The head may also flex laterally and expose more of the anterior or posterior parietal bones. This is termed *asynclitism* and is further defined by the parietal bone that presents: anterior (Naegele obliquity) or posterior (Litzmann obliquity) (Fig. 23-11). During cardinal movements of labor and at a step before internal rotation takes place, the sagittal suture most often lies transversely. Anterior asynclitism deviates the sagittal suture posteriorly. Thus, the examiner may feel both fontanel

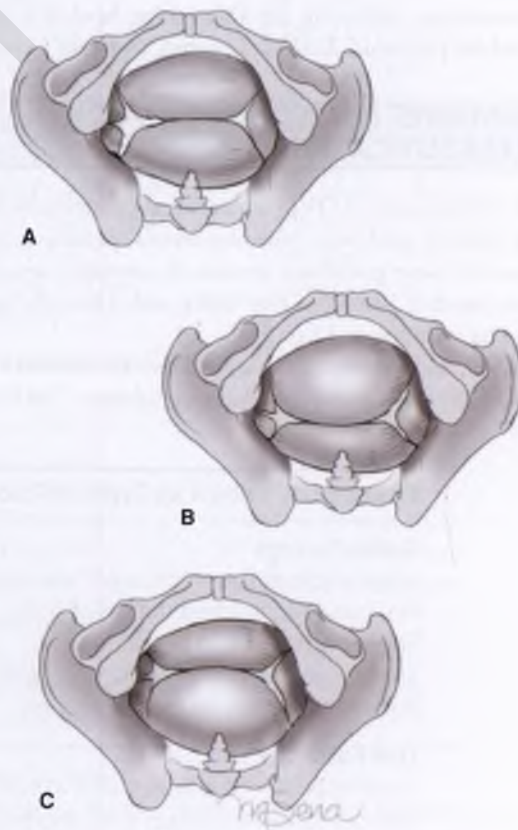


FIGURE 23-11 A. Synclitism: sagittal suture midway between sacrum and symphysis. B. Anterior asynclitism: sagittal suture deviated posteriorly exposing more of the anterior parietal bone. C. Posterior asynclitism: sagittal suture deviated anteriorly, exposing more of the posterior parietal bone.

in anterior quadrants, suggesting the shape of an upright “U.” Posterior asynclitism produces an inverted “U,” with both fontanelles palpated in posterior quadrants. Prior to initiating traction, asynclitism should be corrected. This is one indication for using forceps with a sliding lock.

Another fetal factor is fetal head molding, which may develop either after a long labor or in cases of cephalopelvic disproportion. Molding is detected during examination as overriding sutures, and considerable caput succedaneum often forms concurrently. Such findings suggest relative cephalopelvic disproportion and may render OVD difficult or potentially unwise. The exception may be that a malpositioned head (OP or OT) with caput and/or molding could be rotated to a more favorable anterior position manually or instrumentally and flexed to thereby allow a safe vaginal delivery.

Excessive fetal size may lower the safety and success rate of OVD. Estimated fetal weight using sonography may be helpful but is often inaccurate when the weight equals or exceeds 4000 g. Similarly, manual estimation can be hindered by maternal body habitus. Maternal pelvic capacity should be simultaneously assessed. Thus, an integrated evaluation of both “passenger and passage” is preferable to adhering to estimated weight alone as a limiting factor.

Last, of all fetal assessments, the estimation of fetal station may be the most difficult, least reproducible, and yet the most critical in the current classification of OVD. The definition of station used in this chapter is the depth of the leading bony part of the fetal head in the pelvis. In the former nomenclature used to define fetal station, the long axis of the birth canal above and below the ischial spines was arbitrarily divided into thirds (Fig. 23-12). In the current system, station is measured in centimeter increments, -5 to 0 to $+5$, relative to these spines.

At station zero, the ischial spines represent a fixed landmark that separates the upper limit of midforceps from the obsolete

high forceps class. That said, Dennen (1955) suggested subtracting 1 cm of station from a provider’s clinical assessment when the fetal head position is OP. For example, in cases of OP position with a well-molded head, the leading aspect may be palpated at or below the ischial spines although the biparietal diameter is still above the pelvic inlet, which is the definition of an unengaged head.

The ischial spines reliably define zero station, but there is no marker to identify $+2$ station, which is the dividing line between midforceps and low forceps. Human error, inherent or intentional, in the classification of forceps deliveries may result in a difficult midforceps procedure being classified as low. To compound the difficulty of station assessment, the pelvis has been described as a bent and truncated cylinder, wherein the fetal head may be palpated low in the anterior pelvis but the hollow of the sacrum maybe completely empty. In the current American College of Obstetricians and Gynecologists (2015) classification of OVD, low forceps are subdivided into categories defined by whether or not rotation of the fetal head is required. It makes sense that the midforceps category should be similarly subdivided. Overall, the College’s scheme is predicated on both station and rotation, and both entities are considered components of fetal assessment.

■ Pelvis

Clinical evaluation of the maternal bony pelvis is a dying art. Two reviews by Danforth (1963) and by Yeomans (2006) are recommended for the reader, but a brief overview is presented here and illustrated in Chapter 3 (p. 45). Of the four pelvic types described by Caldwell and Moloy, only approximately half of gravidas have a gynecoid pelvis. Android and anthropoid comprise 20 to 25 percent each. The few remaining cases are the difficult-to-diagnose platypelloid class. Clinical assessment of the pelvis can be accomplished at the initial prenatal visit, on admission in labor, or at any time during the labor course. It is an essential step prior to attempting OVD.

Assessment of the pelvis begins at the inlet and proceeds downward through the midpelvis and to the pelvic outlet. For the inlet, the *diagonal conjugate* represents the distance from the inferior margin of the symphysis pubis to the sacral promontory. Subtracting 1.5 to 2.0 cm from the diagonal conjugate value gives an estimate of the *obstetric conjugate*, which is the narrowest AP diameter through which the fetal head must pass. A deeply engaged head precludes determination of the diagonal conjugate but at the same time renders it unimportant because the head has already passed through the inlet.

In assessing the pelvic inlet, retropubic angle evaluation is often overlooked. This should not be confused with the subpubic angle, which is a feature of the pelvic outlet. To estimate the retropubic angle, the examiner brings two fingers up under the pubic arch, then acutely drops the wrist and palpates with the volar surface of index and middle fingers the symphysis and both superior pubic rami along their posterior surfaces. In an android pelvis, the retropubic angle is sharp and acute. In the platypelloid pelvis the angle is so flat that it nearly forms a straight (180-degree) angle. In the gynecoid pelvis, the retropubic angle starts out flat in the midline but then curves

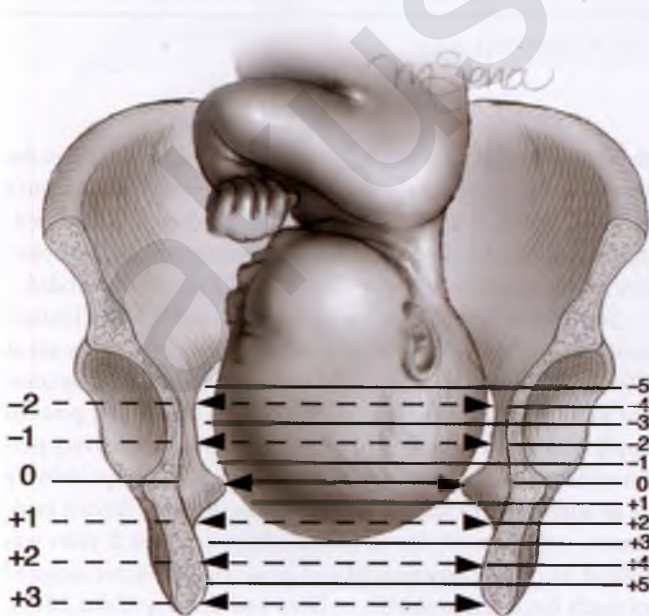

FIGURE 23-12 Shown on the right, station is currently assessed in centimeters above (negative numbers) or below (positive numbers) the ischial spines. Shown on the left, the former system divided the birth canal into thirds and is no longer used.

gently backward laterally. In an anthropoid pelvis, this backward curve is detectable earlier and curves back more sharply.

With the midpelvis, important features include the shape and position of the sacrum, the prominence of the ischial spines, and the width of the sacrospinous notch. This last feature is approximated by determining the width in fingerbreadths of the connecting sacrospinous ligament. It should be at least two fingerbreadths wide. Of the other features, prominent spines and a forward-sloping lower third of the sacrum are characteristic of a contracted midpelvis. In such a pelvis, the biparietal diameter may not have passed the inlet, and thus a forceps delivery might increase the risk of fetal injury.

For the pelvic outlet, the operator inserts two fingers that are ventral side up and raises them until the subpubic arch is reached. If the fingers are not displaced, the arch is deemed to be adequate. In this case, the angle formed by the descending pubic rami approximates 90 degrees. In an android pelvis, this subpubic angle is closer to 60 degrees, and the two fingers overlap. The fetal head must pass under the arch during delivery. A narrow arch will force the head more posteriorly and increase the chance of deep perineal tears, especially with OVD. Next, the coccyx and lower portion of the sacrum are evaluated. In a few instances the coccyx may jut anteriorly into the birth canal, termed a “fish hook” coccyx. Not only does this subject the bone to fracture during delivery, but if forceps are used, the sagittal suture may need to be brought down in an oblique angle rather than straight occiput anterior (OA). In android pelvises, the lower third of the sacrum is sometimes forward, creating a funnel-shaped pelvis and potentially interfering with descent.

Finally, at the pelvic outlet, the operator estimates with a closed fist the interischial tuberosity distance. This should measure >8 cm, which approximates the width of a closed fist, to be considered adequate. If <8 cm, an android pelvis is suspected.

Taken together, thorough preoperative evaluation of the fetus and the pelvis equips the operator with an understanding of fetopelvic relationships. This underpins the clinical judgment necessary for a high rate of successful OVD and a low rate of complications. It may also influence instrument selection for a given situation.

■ Training

No matter what instrument is chosen, proper performance of OVD minimizes the complications for both mother and newborn. As a specialty, we have strayed substantively from the sage advice offered by Dr. Dennen (1955) more than 60 years ago: “The intern, before being allowed to perform a forceps operation, should be given a series of painstaking lectures on the subject. He (or she) should be drilled in detail, repeatedly, on the manikin and should assist at numerous operations which should then be reviewed on the manikin. When the instructor is satisfied that the trainee is properly prepared, the intern is allowed to do an easy case under direct supervision.” In contemporary parlance, this sounds suspiciously like simulation training.

As described in Chapter 6 (p. 85), residents in a simulation laboratory can be taught to recognize the various forceps types, their anatomy, and the appropriate clinical indications for their use. Also, introduction to a checklist can familiarize trainees with

TABLE 23-5. Recommended Checklist for Operative Vaginal Delivery

Identify an indication for assisted delivery
Examine the patient: <ul style="list-style-type: none"> Assess fetal head position and station Evaluate the maternal pelvis Estimate fetal weight
Counsel the patient regarding delivery plan
Decide on delivery location: labor room, OR
Assemble necessary personnel: nurses, faculty, anesthesiologist/neonatal resuscitation team, surgical scrub technician
Select an appropriate instrument
Empty the bladder
Assess anesthesia adequacy
Position the patient properly
Perform a “ghost application” to illustrate the orientation of the instrument once applied
Apply the instrument correctly (see text)
Check application
Rotate if necessary and recheck application
Proceed with a gentle attempt at traction to assess descent and estimate difficulty
Coordinate further traction with patient’s expulsive effort
Evaluate the need for episiotomy and perform if necessary
Remove the instrument prior to delivering the head; ensure that the head will not recede
Complete head delivery using a modified Ritgen maneuver
Inspect the entire birth canal (cervix, vagina, labia, perineum) for lacerations
Perform necessary repairs
Examine the neonate for instrument marks, bruising, cephalohematoma, arm movement
Document the procedure thoroughly (see Table 23-6)

OR = operating room.

the recommended steps of OVD (Table 23-5). The last step in the checklist, documenting the details of the delivery in the patient’s medical record, is essential (Table 23-6). To evaluate the resident’s readiness for clinical work, both a written test and an objective structured clinical examination (OSCE) are recommended.

Simulation training is necessary but insufficient. Today’s residents are far more skilled at cesarean delivery than they are at OVD. Therefore, an experienced faculty member must be present to supervise residents, confirm position assessment prior to application, check blade application, and monitor delivery performance. Teachers are critical to maintaining forceps delivery as an alternative to second-stage cesarean delivery. At one institution, a 59-percent rise in forceps deliveries over 2 years was related to a single experienced and proactive instructor assigned to teach forceps to residents in labor and delivery (Solt, 2011). If lower genital tract laceration or episiotomy repair is needed, the faculty should assist as well. In some training programs, residents get little or no experience repairing third- and fourth-degree lacerations.

TABLE 23-6. Operative Vaginal Delivery Note

Instrument
Forceps type
Vacuum type
Head position
Start of procedure
At delivery
Station at start of procedure
Rotation: direction and enumerate degrees
Manual
Instrumental
Spontaneous
Traction: mild, moderate, strong
Episiotomy type, if elected
Lacerations
Anesthesia: general, spinal, epidural, pudendal, local, none
Classification: outlet, low with rotation ≤ 45 degrees, low with rotation >45 degrees, midpelvic

TECHNIQUE**■ Luikart Forceps****Application**

For a fetal head with the occiput either directly anterior or obliquely anterior, with or without asynclitism, delivery using Luikart forceps is associated with high success and low complication rates. This is partly attributable to its key design features.

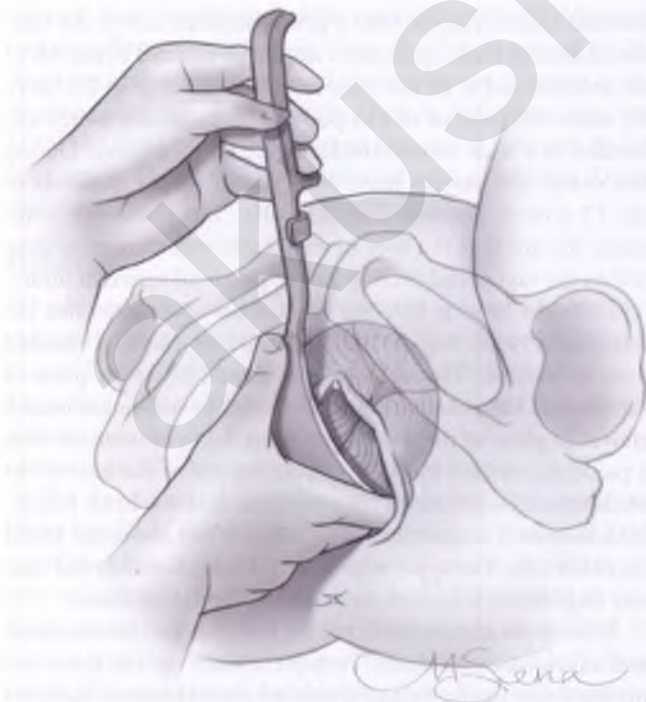

FIGURE 23-13 Placement of the left branch of the Luikart forceps to a head in LOA position. The force of insertion comes mainly from the thumb at the blade's heel.

Namely, these forceps have tapered pseudofenestrated blades, overlapping shanks, a sliding lock, and a bar built into the handle of the left branch to prevent excessive fetal head compression (see Fig. 23-9).

Application of the posterior left branch of the Luikart forceps is illustrated in Fig. 23-13. In this figure, the fetal head position is LOA. Notably, in cases with right occiput anterior (ROA) position, the right blade is placed first. In this drawing, the head is low in the birth canal at either +4 or +5 station.

To begin, the operator holds the handle of the left branch lightly with the left hand. The handle and shank should be oriented vertically. Two or more fingers of the right hand are introduced into the left posterolateral aspect of the vagina in advance of the blade's toe. The fingers serve two purposes. First, they protect the vaginal sidewall from laceration by the blade. Second, fingers maintain the cephalic curve of the blade in constant contact with the fetal head. The thumb of the right hand is placed behind the heel of the blade, and most of the insertion force comes from this thumb.

Once the right hand is positioned, the left hand gently sweeps the handle through the air in a wide counterclockwise arc in the shape of a letter "C." Once the blade has been inserted to the appropriate depth, the right index and middle fingers are placed on the top edge of the blade. Gentle downward pressure directs the blade to its final position beneath the posterior lambdoid suture. This is the easier branch to place! Occasionally, especially in a multipara with a lax introitus, this branch may need to be held in place by an assistant if one is available.

Next, the handle of the right branch should be held by the operator's right hand, but now the handle and shank are no longer vertically oriented. Instead, their orientation should be 30 degrees to the maternal left of vertical and should point toward the maternal left groin (Fig. 23-14). The left hand should be positioned as shown, with the fingers just inside the right posterolateral portion of the vagina in a manner similar to that described above for the insertion of the left branch. The handle should then traverse a clockwise wide arc and nearly touch the patient's left thigh during its path in the shape of a



FIGURE 23-14 Placement of the right branch of Luikart forceps into the right posterolateral aspect of the vagina. From here, the blade will need to be rotated into the right upper quadrant of the pelvis.

backward letter “C.” Simultaneously, the left thumb advances the heel of the blade into the vagina.

Almost immediately, the toe of the blade will contact the right cephalic prominence of the fetal head. This can often hinder sweeping the blade into the right anterior upper quadrant of the maternal pelvis, where it belongs. To overcome this difficulty, the operator should abduct the handle laterally to the left and inferiorly, which will pull the blade away from the forehead. Simultaneously, the index and middle fingers of the left hand should be placed under the lower edge of this blade. Once positioned, these fingers lift the blade up and around the side of the fetal head to lie just below the anterior right lambdoid suture.

With both branches in place, it should be an easy matter to articulate the handles, engage the sliding lock, and correct any asynclitism if present (Fig. 23-15). Asynclitism is corrected by pulling and/or pushing each branch along the long axis of the instrument until the finger guards align. It is recommended in



FIGURE 23-15 Once blades are applied, the handles are articulated and the sliding lock is engaged. These images depict an accurate cephalic application of Luikart forceps. The sagittal suture bisects the plane of the shanks, and the posterior fontanel is one fingerbreadth above the plane of the shanks. The lambdoid sutures are equidistant from the tops of the blades.

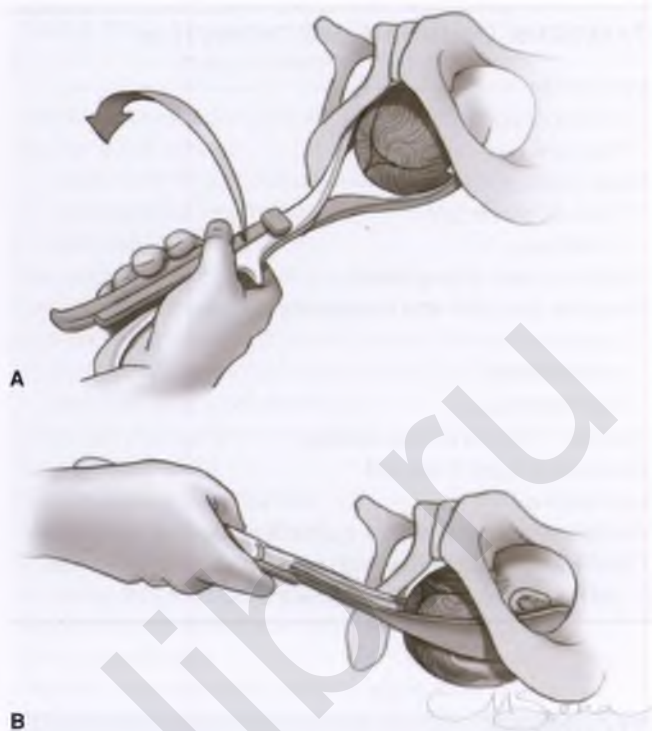


FIGURE 23-16 A. After articulation, the head is usually rotated to OA prior to traction. In this case, the arc of rotation is 45 degrees counterclockwise. **B.** The head is now in OA position. Prior to traction, the application should be carefully checked.

many cases to delay checking the blade application until the head has been rotated to OA. Others prefer to confirm application both before and after rotation.

Rotation

Because Luikart forceps have a generous pelvic curve, the handles following blade application should be situated to the left of the midline and at or just above the horizontal (Fig. 23-16A). To rotate the head to an OA position, the operator swings the handles in a wide counterclockwise arc of 45 degrees. During this sweep, the handles move from the left upper quadrant to the 12 o'clock position (Fig. 23-16B). This maneuver minimizes the arc that the toes of the blades will transcribe deep within the vagina and thereby lessens potential maternal injury.

Once the head is OA, the handles are lowered to flex the fetal head. Now, the application should be carefully checked prior to traction. The sagittal suture should bisect the plane of the shanks. The posterior fontanel should be one fingerbreadth above the plane of the shanks. To assess depth of insertion with a pseudofenestrated blade, the upper border of the heel of the blade should be less than 2 cm away from the bony head. Finally, both lambdoid sutures should be palpable just above the blades on either side. The upper edge of each blade should lie less than one fingerbreadth beneath its respective lambdoid suture.

If the application is incorrect, the branches are disarticulated, and adjustments are made. To move a blade up, the index and middle finger on the ipsilateral side are placed beneath the lower edge of the blade. Upward pressure against this edge sweeps the blade closer to the lambdoid suture. To move a blade down, the index and middle finger of the hand contralateral to the blade

are placed above the upper blade edge. Downward pressure sweeps the blade further from the suture. An accurate cephalic forceps application is shown in Figure 23-15.

Traction

Experts or beginners may choose to employ a Bill axis traction device. As noted earlier, this tool can help ensure that traction is directed properly and can reinforce the continual need to change the axis of traction during forceps delivery. This is especially true for deliveries from higher stations.

In lieu of using an axis traction device, most textbooks describe a technique of bimanual traction called a Pajot-Saxtorph maneuver. For the Luikart forceps, the handles will rest in the upturned palm of the dominant hand with the index and middle fingers over the finger guards. The nondominant hand exerts downward pressure over the shanks, while the dominant hand pulls in an outward direction. When the head is at 0 to +2 station, the initial direction of traction is quite posterior, almost toward the floor. With head descent, the resultant vector of the two forces changes continuously (see Fig. 23-2). This figure is one of the most important in this chapter and deserves careful study prior to attempting forceps delivery of a fetus.

As the head begins to crown, some operators choose to perform an episiotomy if one is planned. Others incise the perineum before placing the forceps. Notably, episiotomy is not required for OVD, and its use has diminished in the past decade. As for the type of episiotomy, mediolateral is favored by many over midline because of the greater risk of extension into the anal sphincter and rectal mucosa associated with midline episiotomy.

With or without an episiotomy, the fingers of the dominant hand, covered by a sterile towel, reach behind the anus to secure the chin. Simultaneously, the thumb exerts pressure directly on the fetal head to prevent sudden egress (Fig. 23-17). Maternal pushing efforts are suspended. Once the chin is secured by the fingertips of the dominant hand, the forceps are removed in the opposite sequence of application. That is, for a fetus that was LOA, the right branch is removed first and is followed by the left branch. The head is then delivered with a modified Ritgen maneuver.

Pitfalls

Whether one chooses Luikart forceps or another suitable conventional forceps, the operation described in the preceding section will constitute most cases for which delivery by forceps is performed. This technique applies to outlet forceps, low forceps without rotation, and midforceps without rotation. Avoiding common pitfalls thus assumes greater importance.

The first potential obstacles present during blade insertion. If the handle of either branch is not swung in a wide arc, the toe of the blade will move medially too soon and prevent insertion by bumping into the side of the fetal head. Related to this, if the entire inner surface of the blade is not maintained in contact with the head during insertion, for example by pulling the handle too far toward the operator, the blade will enter the posterolateral portion of the vagina but cannot be advanced further. Last, if too much force is applied to the handle, risks for vaginal laceration rise.

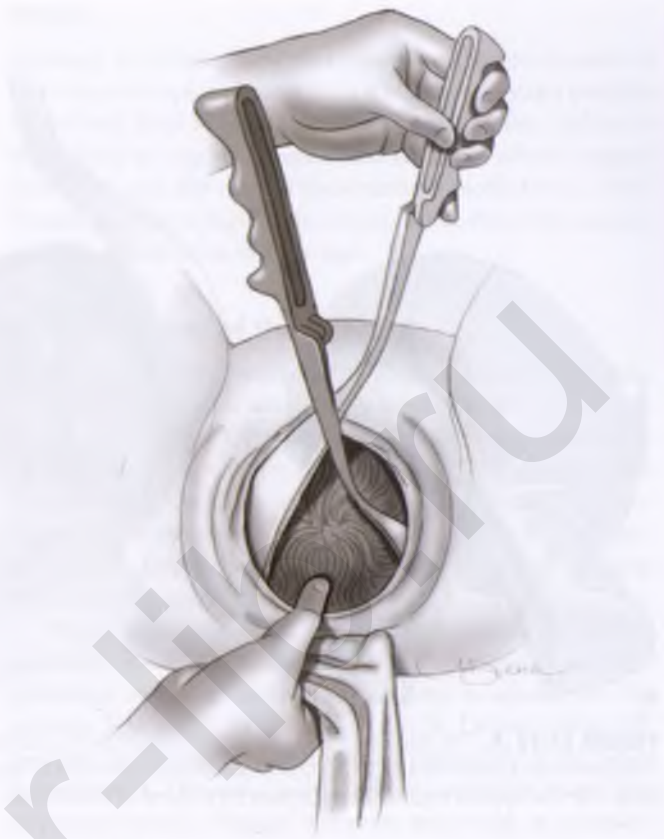


FIGURE 23-17 Removing the forceps before the head is delivered! The branches are removed in the opposite order from that in which they were originally placed. The fingers of the right hand, covered by a sterile towel, are placed behind the anus to reach the chin. The thumb is placed directly on the head to prevent sudden egress.

A second set of potential pitfalls deals with misapplication of the forceps. If the shanks form a 90-degree angle with each other, the lock cannot be engaged and even increased force will not permit articulation. Each application check must be conducted meticulously. If the sagittal suture is found to deviate from a line drawn perpendicular to the shanks, the possibility of an undesirable and potentially injurious brow-mastoid application arises (Fig. 23-18). If the posterior fontanel is too close to the plane of the shanks, traction will lead to excessive flexion of the head. If the posterior fontanel is more than one fingerbreadth away from the plane of the shanks, traction will cause the head to extend. This leads to a larger head diameter being brought down and may require greater traction force with its attendant risks. Finally, if the application is not seated deeply enough, the forceps may slip off the head during traction.

Perhaps the most important difficulty is traction along an incorrect axis. If the pull is too anterior, force will be wasted against the pubic rami and symphysis pubis, which are immovable objects. Conversely, if traction is applied in a posterior direction for too long, the risk of third- and fourth-degree tears increases.

Injury to the pelvic floor is one of the main criticisms of OVD, but the operator may be a more important cause than the instrument. One neglected area of OVD is related to patient positioning. Wide abduction of the legs in stirrups that are not adjustable (one size fits all) contributes to perineal tears.

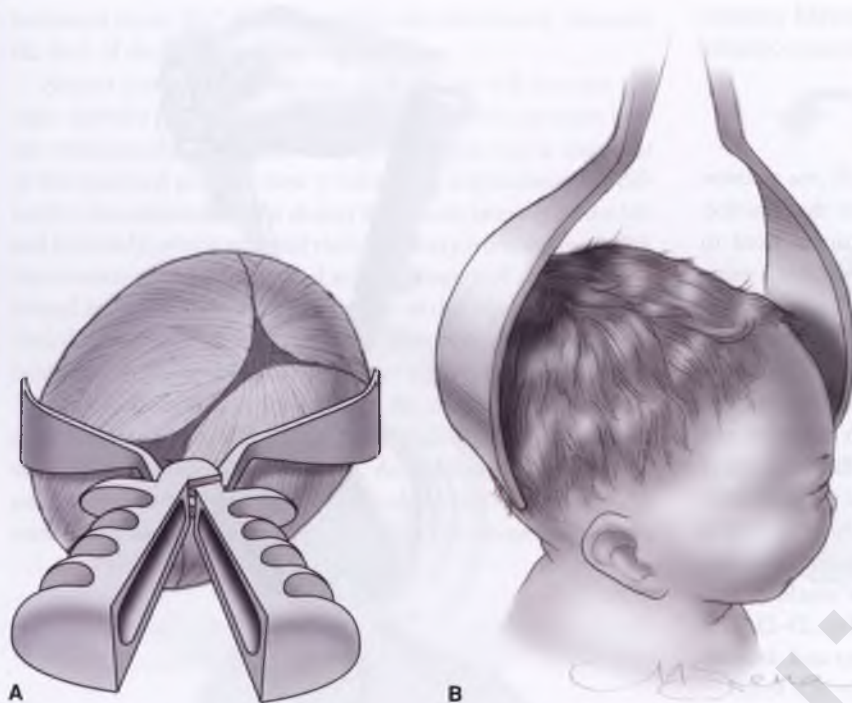


FIGURE 23-18 **A.** This application is incorrect and asymmetric, increasing the risk of injury. This is termed a brow-mastoid application. **B.** Another example of incorrect application. Note that the sagittal suture does not bisect the plane of the shanks.

As described in Chapter 20 (p. 323), defaulting to midline episiotomy when one is deemed necessary puts the external anal sphincter and anterior rectal wall at greater risk for tears. Modern labor rooms and labor beds were clearly not designed with OVD in mind.

A final potential pitfall is failure to remove the forceps prior to delivering the head. Fetal head delivery with the forceps still in place adds to the volume that must pass through the introitus and risks deep perineal lacerations. Although controversial, we and others strongly support the recommendation to remove the forceps before the head is delivered (Dennen, 1955; Yeomans, 2010). During forceps disarticulation and removal, maternal pushing efforts are suspended to help avoid vaginal sidewall lacerations. These may be cut by the blade's toe against a stretched and attenuated vaginal wall. Importantly, before removing the forceps, the operator must ensure that his or her fingers, bent sharply at the last knuckle, have secured the fetal chin through the maternal soft tissue so that it will not recede. Losing the grip on the chin during removal is inelegant and may result in a need to reapply the forceps.

Once both branches are removed, the head is delivered with a modified Ritgen maneuver as previously described. Interestingly, a randomized trial evaluating the effectiveness of the Ritgen maneuver to avert deep perineal tears found no benefit compared with simple perineal support (Jonsson, 2008). This report specifically excluded instrumented deliveries.

Although directed to vaginal delivery in general, the accompanying editorial by Cunningham (2008) asked what could be learned to decrease the incidence of anal sphincter lacerations. A multicenter intervention program to reduce the incidence of anal sphincter tears was subsequently reported that emphasized

four points. These included: (1) correct performance of a modified Ritgen maneuver, stressing a bimanual technique; (2) a delivery position that allows visualization of the perineum during delivery; (3) clear communication between the accoucheur and the parturient, who is instructed to stop pushing while the Ritgen maneuver is completed; and (4) performing only indicated episiotomy and selecting medio-lateral in preference to a midline one. With these relatively simple interventions, the authors reduced the incidence of anal sphincter tears from 4 to 5 percent to 1 to 2 percent (Hals, 2010). Of note, this was also not a study of only OVD.

Research focused on perineal lacerations during OVD is still needed and may aid prevention of needless injuries to the perineum. In the process, we might mitigate one of the major reasons why forceps delivery has declined worldwide.

■ Vacuum Extraction

As with forceps, several different types of vacuum extractors are available for selection. The first distinction was between metal and soft cups. However, soft-cup designs subsequently proliferated and diverged with regard to construction material and shape. Although nuanced differences distinguish these, the discussion that follows presents application and traction for vacuum extractors in general.

Application

Whatever cup is used, one strives to achieve a median flexing application (Fig. 23-19). This means that any vacuum cup should be centered over the sagittal suture, and the posterior

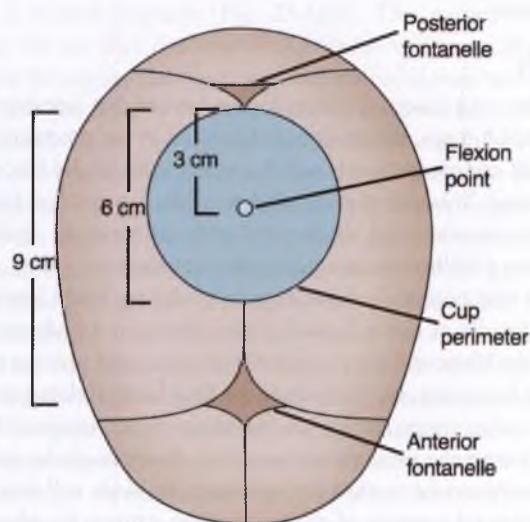


FIGURE 23-19 Median flexing application of a vacuum cup. The posterior edge of the cup is adjacent to the posterior fontanel.

edge of the cup should lie just rostral to the posterior fontanel. This application will permit the fetal head to be flexed effectively when traction is applied. Importantly, no maternal tissue should be trapped under the cup. These tissues can be injured and also may weaken the suction seal.

Occipital malposition and/or asynclitism can make optimal positioning of Silastic or bell-shaped cups difficult. These instances may be better served with a disc cup.

Some posit that vacuum extraction does not require an exact diagnosis of head position, but this is false. The highest success rate and the minimum complication rate both mandate accurate cup placement.

Traction

As with forceps, the direction of traction will change continuously as the head descends through the pelvis.

Similarly, the higher the starting station, the more posterior should be the axis of traction. Notably, rotation is not indicated during vacuum extraction, and twisting the cup may lead to “cookie-cutter” or semilunar laceration of the fetal scalp. In most cases, the fetal head rotates as it descends with traction.

During traction with the dominant hand, fingers of the nondominant hand are placed inside the vagina to monitor for impending detachment. The best results are obtained if the direction of traction is maintained perpendicular to the cup (Fig. 23-20). In contrast to forceps, the vacuum cup should remain in place until the head is delivered.

Caput succedaneum in the form of a chignon is an expected finding once the cup is removed. Vacuum extraction may cause a cephalohematoma, defined as a subperiosteal bleed, in up to 20 percent of cases. However, a clinically more significant finding is subgaleal hematoma, also termed a subaponeurotic hemorrhage. The distinction among these three entities is illustrated on page 386.

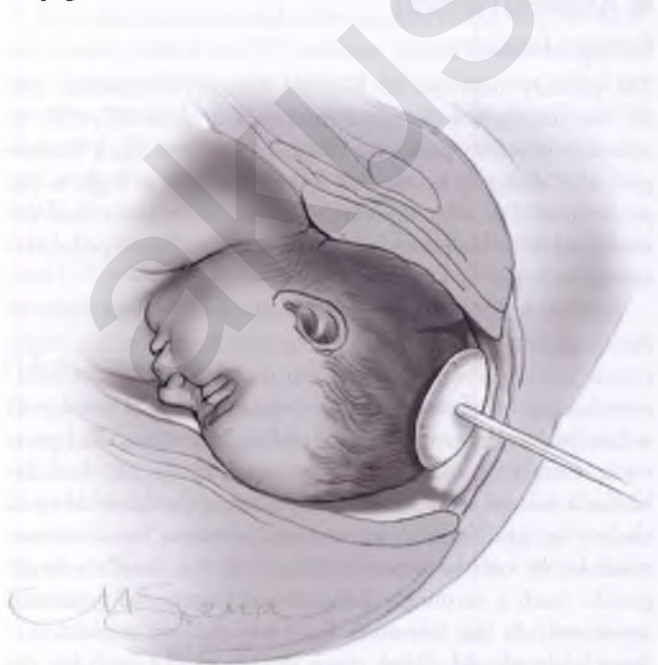

FIGURE 23-20 Traction with a vacuum extractor perpendicular to the cup.

Pitfalls

Although it is widely held that vacuum extraction is easier to learn than forceps, operators must still know the exact position of the fetal head to obtain optimal cup placement. Failure to do so leads to cup detachment and failure to achieve vaginal delivery. It can also cause serious neonatal morbidity (p. 385). Trapping cervix or vaginal mucosa under the rim of the cup can cause lacerations during traction.

■ Malposition of the Occiput

A malpositioned occiput can often prolong second-stage labor. When a woman enters second-stage labor with the fetal head in a persistently OT or OP position, she should be given a chance to push to assess whether the head will descend and rotate spontaneously. As discussed in the manual rotation section, the optimum length for this spontaneous rotation is unclear. However, a long delay leads to extensive caput and molding and leaves the operator only difficult choices.

When spontaneous rotation fails, operator intervention is indicated. Some centers rarely employ instrumented rotation, preferring instead to try manual rotation to achieve an OA position (Ducarme, 2015; Le Ray, 2013). Delivery of an OP position by forceps is another option, particularly if the pelvis is anthropoid. However, such a delivery entails increased risk of perineal injury. Vacuum extraction may result in autorotation to OA, but it may also fail and create the conundrum of either sequential instrument use or cesarean delivery of a deeply impacted head. We favor some type of active rotational maneuver, either manually or using Kielland or Barton forceps. These techniques are detailed below.

■ Manual Rotation

Indications

In some instances, fetal head rotation from OP or OT positions can be completed manually instead of by forceps. To perform a manual rotation, two prerequisites must be fulfilled. The cervix must be completely dilated, and the position of the fetal head must be accurately diagnosed. For experienced operators, morbidity rates do not differ between manual rotation and Kielland rotation for either mother or neonate. This may not be true for trainees, who require close supervision for Kielland rotation to achieve outcomes comparable to those achieved by manual rotation (Healy, 1982). With the decline in use of and training for Kielland rotation, several authors have suggested that manual rotation may reduce the cesarean delivery rate (Barth, 2015; Le Ray, 2013; Reichman, 2008; Shaffer, 2011).

Timing of the attempt at manual rotation is an issue. Le Ray and associates (2013) recommend trying to rotate as soon as full cervical dilation is reached. In contrast, Barth suggests delaying the attempt for 30 to 60 minutes depending on parity. A rationale for this pause is that some fetuses will spontaneously rotate during descent that is augmented by maternal pushing. Older works include a discussion of manual rotation technique but do not address timing (Dennen, 1955; Lafe, 1968b). We prefer to delay a manual rotation attempt for at least 30 minutes into the second stage. However, if the alternative to

manual rotation is cesarean delivery in the second stage for an arrest of descent with an OP position, then manual rotation is ardently advocated. If rotation with Kielland, Barton, or, less commonly, conventional forceps is an option, manual rotation may represent a missed opportunity to train junior operators on rotational forceps procedures. Such an approach would of course mandate the presence of an experienced obstetrician at the delivery.

Manual Rotation Technique

For easy cases, rotation from left occiput posterior (LOP) or right occiput posterior (ROP) position can be accomplished merely with fingers against the raised edge of the respective parietal bone that forms the lambdoid suture. Concurrently, the other hand is placed externally on the corresponding side of the maternal abdomen to pull the fetus back up toward the midline in synchrony with the internal digital pressure. Slight destationing and flexing may improve success rate. This procedure is termed digital rotation.

Manual rotation, in contrast, requires insertion of the operator's entire hand into the vagina. Logically, small hands are an asset. For rotation from ROP, classically the left hand is used. The palm is up, the fingers span the posterior parietal bone, and the thumb lies on the anterior parietal bone (Fig. 23-21A). Three actions are performed simultaneously. The first is fetal head flexion to provide a smaller diameter for rotation and

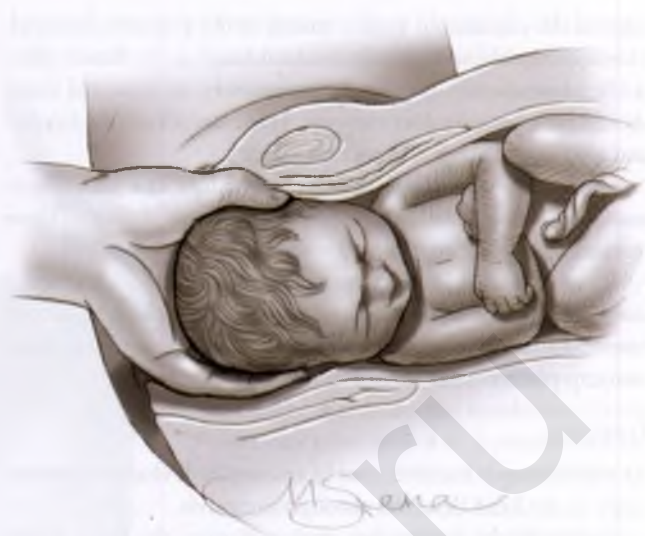

FIGURE 23-22 Prior to and during manual rotation, flexing the head helps to guide the smallest fetal head diameter through the pelvis.

subsequent descent (Fig. 23-22). Second, slight destationing of the fetal head moves the head to a level in the maternal pelvis with sufficient room to complete the rotation. Importantly, destationing should not be confused with disengaging the fetal head, which is proscribed. Last, the hand is pronated to rotate the head counterclockwise (Fig. 23-21B).

Some operators prefer to use the right hand with the palmar surface over the forehead and face to rotate from ROP. This is termed the Holland maneuver and is illustrated in Figure 23-23 (Laufe, 1968b). For both the classical and the Holland maneuver, use of the external hand as previously described may increase success.

■ Kielland Forceps

Forceps Features

The primary function of Kielland forceps is rotation, and the instrument is well suited for rotation from OT, OP, or obliquely posterior positions. Christian Kielland was a Norwegian who designed his forceps for applications as high as the pelvic inlet. For contemporary use, one must insist that the fetal head be at least engaged with the leading bony point at 0 station or lower.

Several design features of Kielland forceps contribute to their usefulness. Each branch is bayonet-shaped, with a slight reverse pelvic curve. The blades feature beveled edges to minimize laceration of maternal soft tissue, the shanks overlap to reduce perineal distention, and a sliding lock assists the operator in correcting asynclitism if present (Fig. 23-24). Luikart-Kielland forceps are a variant that offers a pseudofenestrated blade (Fig. 23-25). With either type, a unique feature is two small knobs on the superior surface of the handle's finger guards. Such a seemingly insignificant feature has generated controversy in the literature. Formerly, authors advised that these knobs should always point to the occiput both for the ghost application and to confirm a proper application once the blades are out of sight in the birth canal (Dennen, 1955;

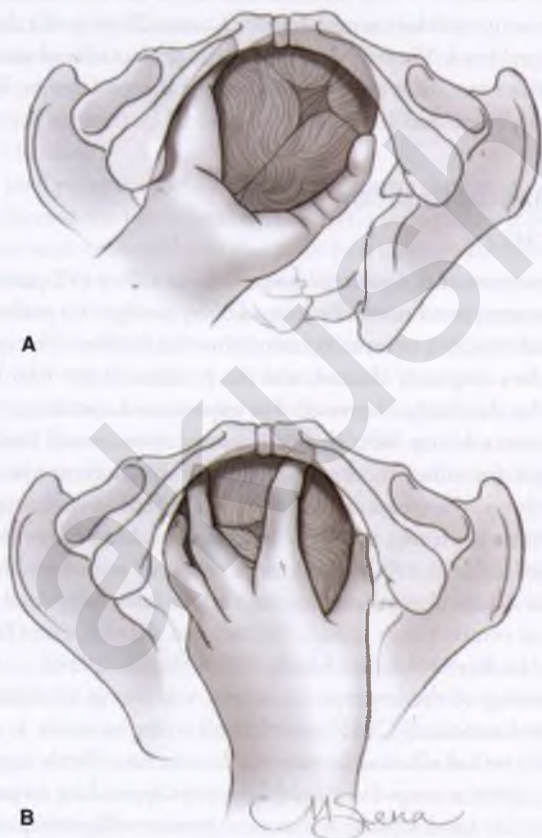


FIGURE 23-21 **A.** "Classic" manual rotation using the left hand, palm-up, to rotate from ROP. **B.** Success involves three simultaneous steps to rotate clockwise through an arc of 135 degrees: flexing, destationing, and pronating. After successful completion, the head is now very close to OA.

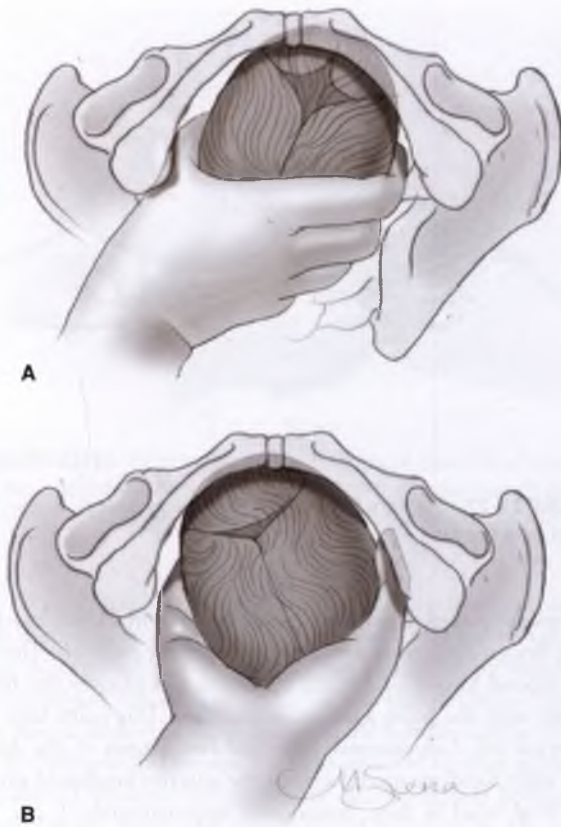


FIGURE 23-23 **A.** The Holland maneuver, using the right hand instead of the left to rotate from ROP. **B.** Completion of manual rotation via supination instead of pronation of the operator's hand.

Laufe, 1968b). More recently, especially for OP applications, others find it acceptable for the knobs to be directed toward the face (Barth, 2015; Gilstrap, 2002).

Even more controversial is the method of applying the anterior branch, which for OT positions should always be applied first. For this chapter, the classical application, also called the inversion method, of placing the anterior branch will not be illustrated. We are aware of some serious complications associated with this classical application, and so are others (Olah, 2002). Instead, the wandering method will be described in detail. In more than 30 years of using Kielland forceps to rotate from OT positions, we have uniformly been able to wander the anterior branch into position behind the symphysis pubis.

Practice

The use of Kielland forceps to rotate from left occiput transverse (LOT) will be considered first. A proper ghost application will have the knobs facing to the left at the 3 o'clock position. Although the branches may sometimes be described as "anterior" or "posterior," relative to the fetal sagittal suture, the terms "left" or "right" in this discussion reflect the branch's laterality *after* rotation is completed.

To begin, the left branch is set aside, and the handle of the right branch should be gently held with the right hand (Fig. 23-26). Two or more fingers of the left hand should be inserted into the right posterolateral vagina in advance of the

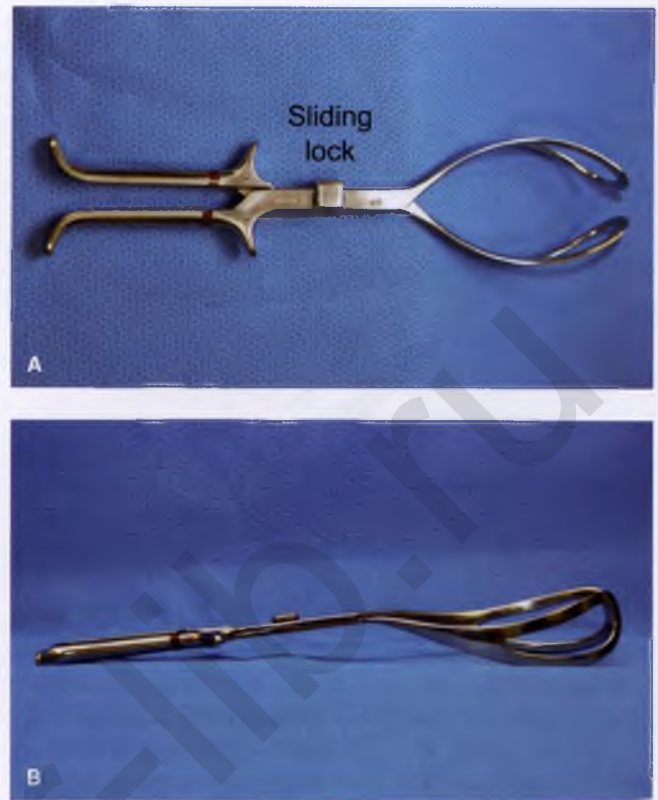


FIGURE 23-24 Kielland forceps. **A.** Top view. **B.** Side view. Note the slightly reversed pelvic curve.

blade's toe. The left thumb is positioned at the blade heel. As the blade is inserted further, the handle should transcribe a counter-clockwise arc in the midline from 12 o'clock to 3 o'clock. This sweeps the blade to lie directly over the face.

The fingers of the left hand are moved beneath the lower edge of this blade (Fig. 23-27). Upward pressure against this edge will sweep or wander the blade into position behind the symphysis pubis (Fig. 23-28). During this sweep, the right hand keeps the handle well lateral on the maternal left. This helps to move the blade away from the fetal face during the sweep. As the blade reaches its final position, the shank and handle come to rest in the midline pointing inferiorly.

The posterior or left branch is grasped at its handle with the right hand, and the blade's cephalic curve faces upward

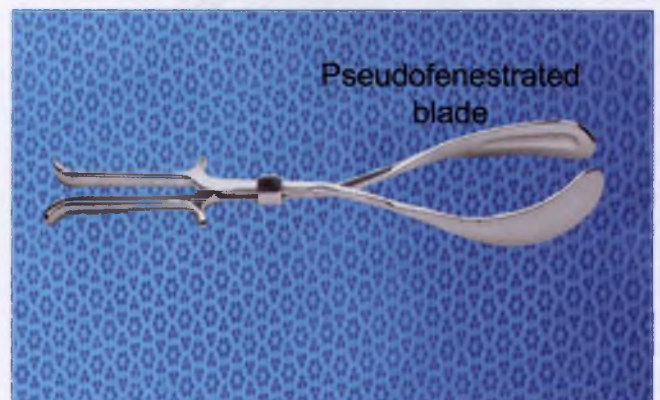


FIGURE 23-25 Luitart-Kielland forceps.

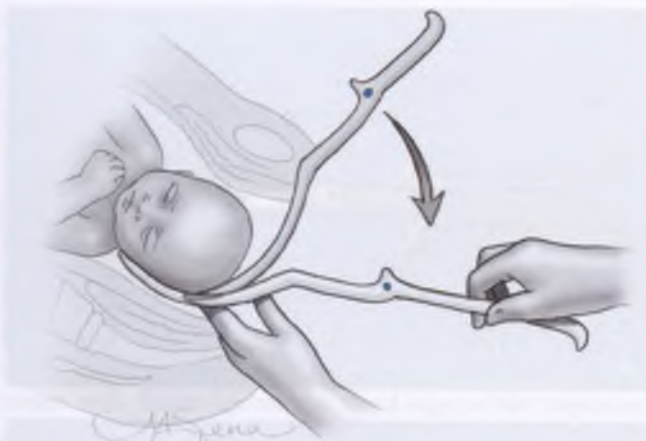

FIGURE 23-26 Application of the right branch of the Kielland forceps to a head in LOT position. The knob on this branch (colored blue) will ultimately face the occiput.

(Fig. 23-29). It is inserted so that its shank and handle lie to the patient's right of the branch that was initially applied. The left hand with the palm up is inserted into the vagina along the posterior wall. The second blade is then guided into position by two or more fingers of the left hand pushing against the outer surface of the blade. This technically is a direct midline posterior application. However, the toe of the blade may need to be moved away from the sacral promontory to either the right or left, taking care that it is placed inside the cervix.

With both branches properly positioned, the blades will come to lie 45 degrees below the horizontal (Fig. 23-30). The knobs on the finger guards face 3 o'clock on the patient's left. After checking the application, the handles of the Kielland

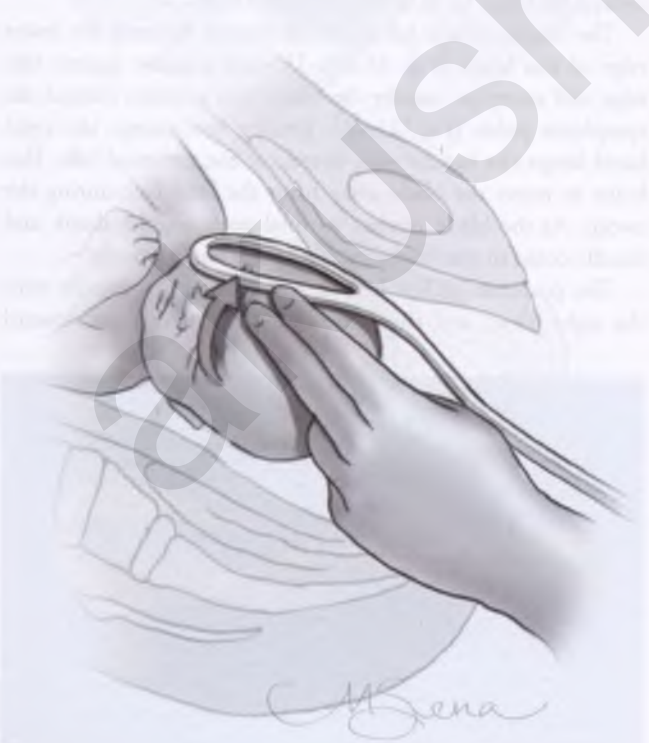


FIGURE 23-28 The right branch is wandered to its final position behind the symphysis.

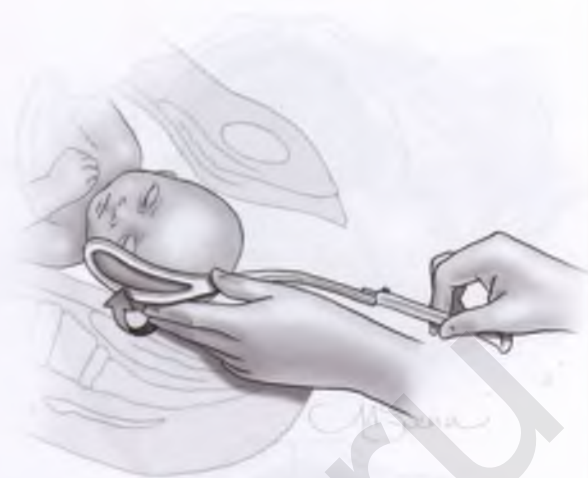

FIGURE 23-27 The right branch of the Kielland forceps is wandered over the face.

forceps are pulled slightly to the patient's right to increase fetal head flexion and create a smaller diameter for rotation. The first and second fingers of the left hand are placed over the finger guards with the palm against the handles. This palm faces the maternal left. Concurrently, the first two fingers of the operator's right hand are placed against the anterior lambdoid suture. The fetal head is then destationed approximately 1 cm. For rotation in a counterclockwise direction, the wrist of the left hand supinates, to direct this palm upward. Simultaneously, two fingers of the right hand press on the edge of the right parietal bone that borders the lambdoid suture. This ensures that the fetal head turns with the blades and does not slip from the blades' grip.

In their final position, the handles lie within the upturned palm of the left hand with the handles pointing approximately 45 degrees below the horizontal (Fig. 23-31). The exact handle location will depend on the station of the fetal head. Specifically, at higher initial stations, the handles will rest farther below the horizontal. The head position after rotation will be at or close to OA.

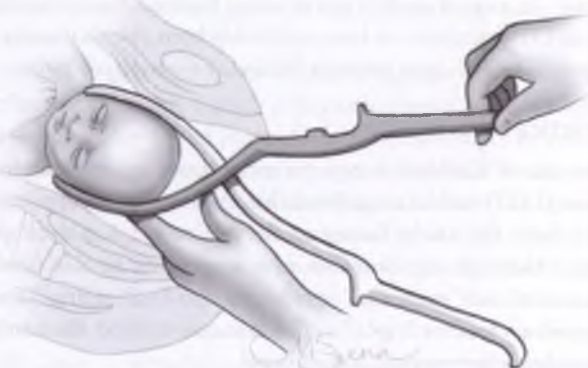


FIGURE 23-29 Insertion of the left branch of the Kielland forceps directly posterior along the hollow of the sacrum. This branch is inserted to the maternal right of the anterior branch to aid engaging the sliding lock.

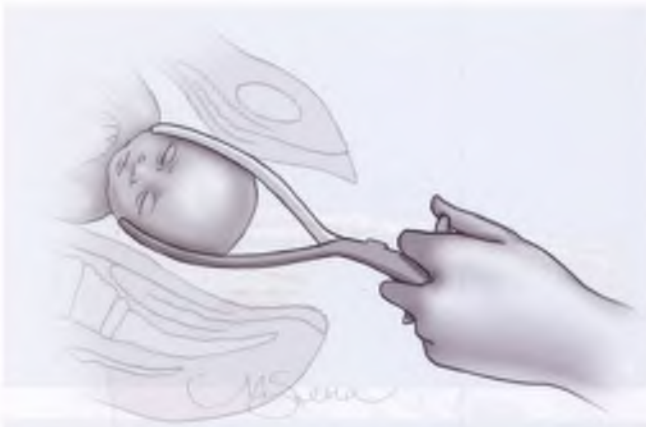

FIGURE 23-30 Proper grip on the handles of the Kielland forceps by the operator's left hand. The knobs on the finger guards cannot be seen because they face toward the occiput on the patient's left.

To apply traction, the operator may choose from two acceptable methods. In one, the operator applies traction on the Kielland forceps using a bimanual grip described previously for conventional forceps (p. 375). When the posterior fontanel has passed under the subpubic arch, the handles can be elevated to the horizontal. Dennen (1955) cautioned against raising the handles of Kielland forceps above the horizontal because the reverse pelvic curve may cause vaginal sulcus tears. He recommended unlocking the forceps and repositioning them further from the posterior fontanel. On occasion, especially with an episiotomy, the handles of these forceps can be raised above the horizontal with no untoward consequences.

Alternatively, some practitioners prefer to remove the Kielland forceps after rotation and replace them with conventional forceps. When such an approach is planned, it is advisable to first employ moderate traction to seat the head lower in the birth canal before switching instruments.

Pitfalls

Traction does not always produce descent after successful rotation. The prudent operator should remain willing to abandon the OVD attempt and opt instead for cesarean delivery if the head fails to descend when traction in the proper axis is applied.

During application, wandering the anterior blade over the face may sometimes be challenging. If so, an attempt is made to insert the anterior branch (first branch) into the lower left side of the pelvis and wander it counterclockwise around the occiput.

The blade of the Kielland forceps is fenestrated and may be difficult to remove. In this case, it is best to deliver the head with one or both branches still in place. Alternatively, one might try to rotate using Kielland forceps with the Luikart modification. With these Luikart-Kielland forceps, the blade is pseudofenestrated.

Last, for those few who still advocate the classical method of application, the thin lower uterine segment can rupture during insertion of the anterior branch. The same outcome may result with this method when rotation of the anterior branch from a cephalic-curve-up to a cephalic-curve-down blade position is performed in the wrong direction. For a head in LOT position,

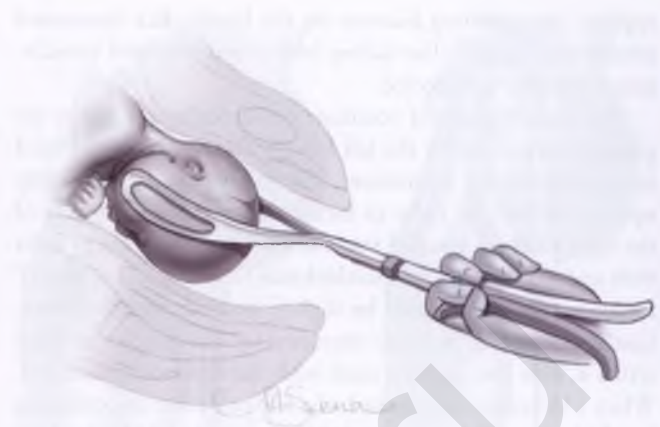


FIGURE 23-31 Completed rotation using Kielland forceps. Head was rotated 90 degrees counterclockwise. The knob on the finger guards (blue) now faces upward.

this rotation of the anterior branch should always be carried out in a counterclockwise direction.

■ Kielland Forceps for Occiput Posterior Positions

Technique

In practice, the opportunities to rotate from OP positions are far greater than those from OT positions. Envious results are achieved with Kielland forceps, which typically outperform other methods that include DeLee key-in-lock maneuver, the Scanzoni maneuver using a solid-blade instrument such as Tucker-McLane forceps, and even the “newer” modifications of the Scanzoni that employ an inverted application.

With an oblique posterior position of the occiput, rotation extends through an arc of 135 degrees. However, the principles of traction are no different from those with OT positions, and thus only the application of Kielland forceps for OP position will be emphasized here. As for the other techniques described in this chapter, application to ROP is simply a mirror image of that for LOP, which is described next. Also, for this discussion, the “left” and “right” Kielland branches describe the orientation of branches relative to the maternal pelvis once the rotation has been completed. For example, during initial application, the left branch is placed on the maternal right.

With LOP positions, similar to LOA, the posterior branch is applied first. For LOP, the left Kielland branch is held by the right hand on the handle with the button on the finger guard facing downward. The fingers of the left hand are inserted in advance of the toe of the blade and into the right posterolateral aspect of the vagina. The initial position of the handle is approximately 30 degrees to the patient's left of vertical. From here, it is rotated through a clockwise arc directed laterally and to the left. The handle comes to rest on the patient's left and below the horizontal.

Next, the right branch, with the button on the finger guard facing downward, is held with the left hand and inserted into the left posterolateral aspect of the vagina. From there, it must be wandered into its final position in front of the right ear in the left upper quadrant of the maternal pelvis. This wandering maneuver takes place over the occiput, not over the face. Once

applied, the orienting buttons on the handle face downward toward the occiput. The sliding lock is engaged, and asynclitism, if present, is corrected.

To begin the act of rotation, the articulated handles are grasped from above by the left hand with the palm downward in preparation for supination. The handles are lifted slightly upward and to the right to increase head flexion. Fingers of the right hand are inserted into the left lower quadrant to assist with and monitor the counterclockwise rotation. Just as for OT rotations, the head should be slightly destationed before rotation is attempted. It is not necessary for the handles to transcribe a wide arc, as they must with the Scanzoni maneuver. When OA position is reached, the left palm and the orienting handle knobs will face upward. After rotation to OA or at least to LOA, traction with the Kielland forceps can be initiated or they can be replaced by conventional forceps.

■ Pitfalls

For right-handed operators, difficulty may be encountered using the left hand on the forceps to rotate. Fortunately, ROP is three to five times more common than LOP positions. For ROP positions, the right hand will grasp the forceps, and the left hand will monitor rotation. If destationing is too vigorous, the umbilical cord may prolapse. Again, successful rotation does not imply that descent will automatically follow. Thus, the operator must be prepared to abandon the procedure. If success seems likely, Kielland rotation may be performed in a labor room. If the outcome is in doubt, it is reasonable to move to an operating room for the attempt.

■ Barton Forceps

Indications

Many obstetricians and obstetric textbooks have relegated Barton forceps to the history books (Hale, 2001). Fifty years ago, Danforth (1965) reported favorably on the use of these forceps in the United States. In 1972, Parry-Jones published an encyclopedic monograph on Barton forceps in England. This work presents intricate details of the design and use of this instrument. Today, at least for some operators, Barton forceps may prove especially helpful for cases in which Kielland forceps are contraindicated, such as deep transverse arrest in a platypelloid pelvis. Moreover, for transverse arrest at 0 station or lower, Barton forceps are easier to apply than Kielland forceps. Last, these can also be applied during cesarean delivery.

At cesarean, Barton forceps are the most useful instrument to deliver a head “floating” cephalad to a low transverse hysterotomy incision (Megison, 1993). Even a novice can apply the hinged blade beneath the anterior uterine wall and over the anterior parietal bone (Fig. 23-32). The posterior branch is then applied along the posterior uterine wall to the patient’s right of the previously positioned anterior branch. The sliding lock is easily engaged to deliver the fetal head transversely through the incision. For delivering a floating head, this method, once tried, may prove preferable to using either a vacuum extractor or conventional forceps. Use of Lafe-Piper forceps for this purpose is described and illustrated in Chapter 25 (p. 411).

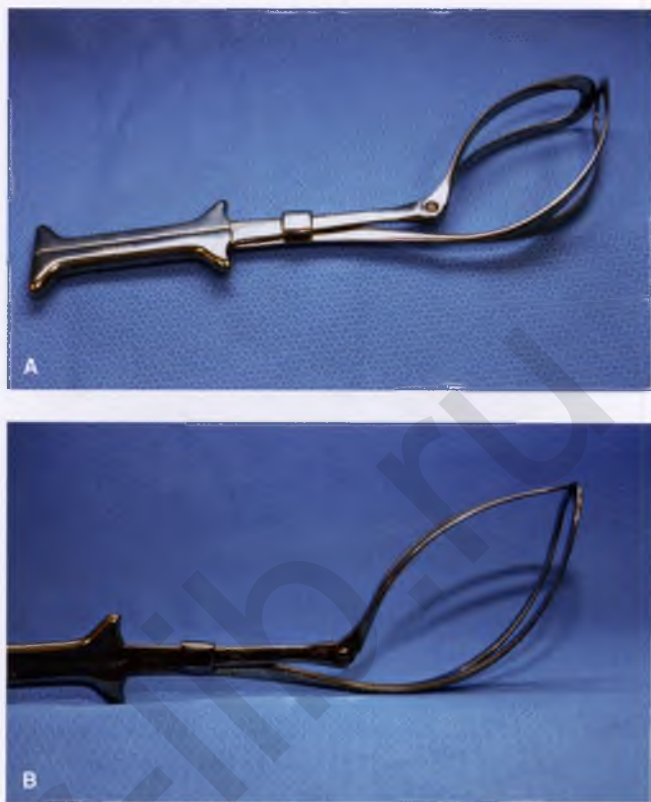

FIGURE 23-32 Barton forceps. **A.** Top view. **B.** Side view.

Practice

For vaginal delivery of a fetal head that is engaged but arrested in LOT position, the operator should hold the handle of the anterior branch with the hinged blade lightly with the right hand (Fig. 23-33). The hinge should be in the closed or locked position. Two or more fingers of the left hand are introduced into the right posterolateral aspect of the vagina in advance of the blade’s toe. This branch should be inserted posteriorly, either in the midline or just to the right of the midline, with the thumb at the heel of the blade.

Some operators may choose to unlock the hinge at this point. Others will keep the hinge locked while the handle transcribes a clockwise 90-degree arc to the left. Simultaneously, the fingers of the left hand protect the right vaginal sidewall, and the thumb assists with insertion. So far this application mirrors that for Kielland forceps, described on page 379.

The key difference with the Barton forceps is that once the blade lies over the face, the hinge is unlocked (Fig. 23-34). The fingers of the left hand are placed beneath the lower edge of the blade. Upward pressure will help to wander the blade into position behind the symphysis pubis. As the blade reaches its final position, the shank and handle come to rest in the midline. With an unlocked hinge, the blade and the shank should form an angle of almost 90 degrees. The hinge lies at the level of the sagittal suture, medial to the posterior fontanel.

Next, the handle of the posterior branch is held lightly with the right hand, again with the fingers of the left hand just in advance of the blade’s toe (Fig. 23-35). This branch is always inserted to the patient’s right of the anterior branch to aid engagement of

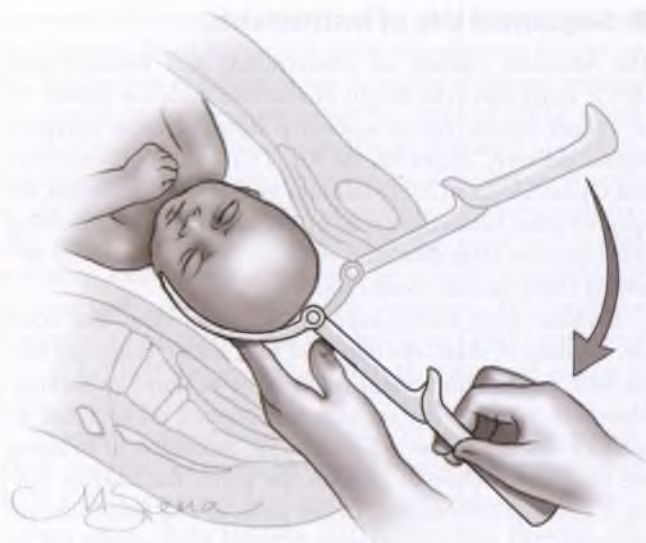

FIGURE 23-33 Placement of the anterior hinged branch of the Barton forceps to a head in LOT position.

the sliding lock. The posterior branch has an exaggerated cephalic curve that enables it to follow the hollow of the sacrum and is easily applied against the posterior fetal parietal bone.

Once both blades are applied, the shank of the hinged anterior branch is inserted into the sliding lock located on the posterior branch. Depending on the station of the head, the handles will either be at or just below the horizontal. As one prepares to apply traction, unlike with any other forceps, the flat surface of the shanks lies in a “vertical” plane (Fig. 23-36). This contrasts with the “horizontal” orientation of most forceps shanks. Despite this plane change, the blades still follow the curve of Carus as traction begins.

A special axis traction attachment designed specifically for the Barton forceps may assist the novice operator. However,

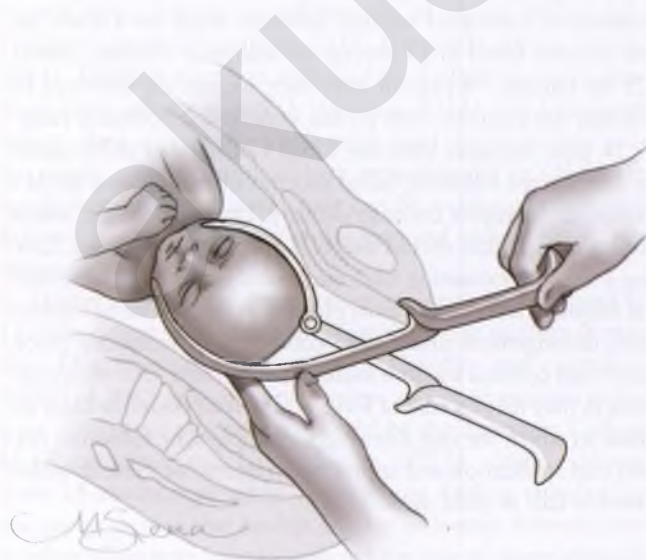


FIGURE 23-35 Insertion of the posterior branch of the Barton forceps along the sacral hollow. As with Kielland forceps, this branch is inserted to the maternal right of the anterior branch.

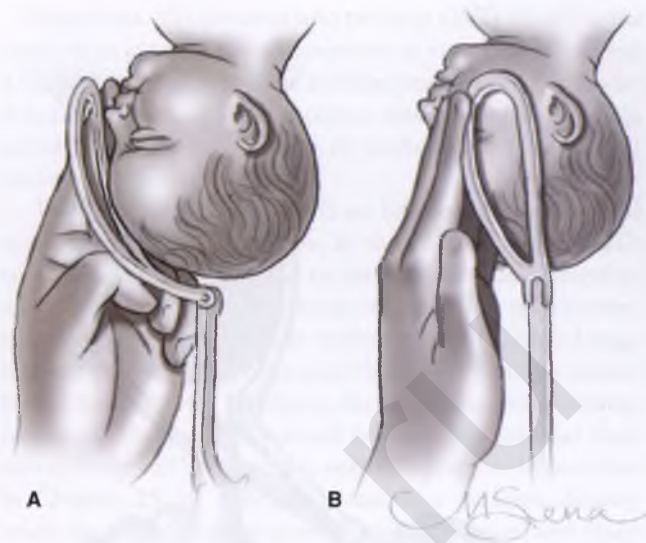


FIGURE 23-34 **A.** “Breaking” the hinge, wandering over the face. **B.** Final position of the anterior branch behind the symphysis, with the hinge at the level of the sagittal suture.

use becomes optional once familiarity with shank orientation accrues. As noted, traction is applied with the Barton forceps’ shanks oriented vertically instead of horizontally. If one elects to use the axis traction handle, it is affixed to the shanks between the sliding lock and the finger guards.

Downward traction is initially applied with the head in the transverse position, usually until the head reaches the pelvic floor in a platypelloid pelvis. At the level of the outlet, the head begins to rotate spontaneously counterclockwise from LOT to OA. Sometimes the operator will need to assist rotation by gently swinging the handles through a wide 90-degree arc to achieve the OA position (see Fig. 23-36).

Once OA, the head is usually easily brought to crowning by finger traction in the crotch of the instrument (Fig. 23-37)

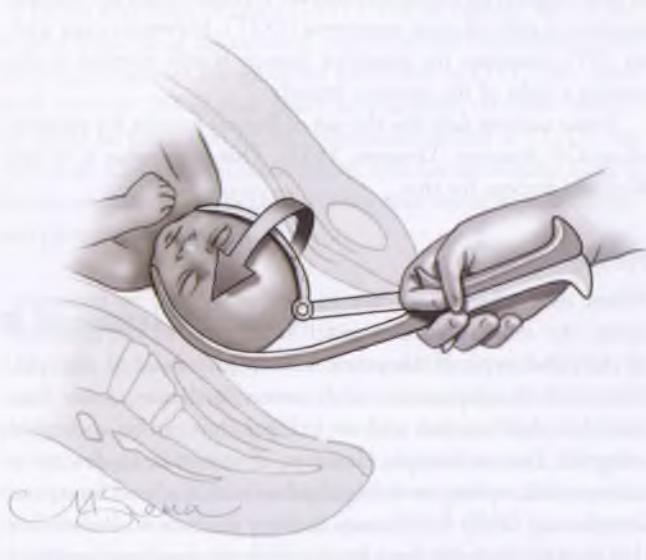


FIGURE 23-36 Traction with the Barton forceps is applied to a transverse head along the pelvic curve of the instrument (not shown). Once the head is on the pelvic floor, the head is rotated through a 90-degree arc counterclockwise in the direction of the arrow.

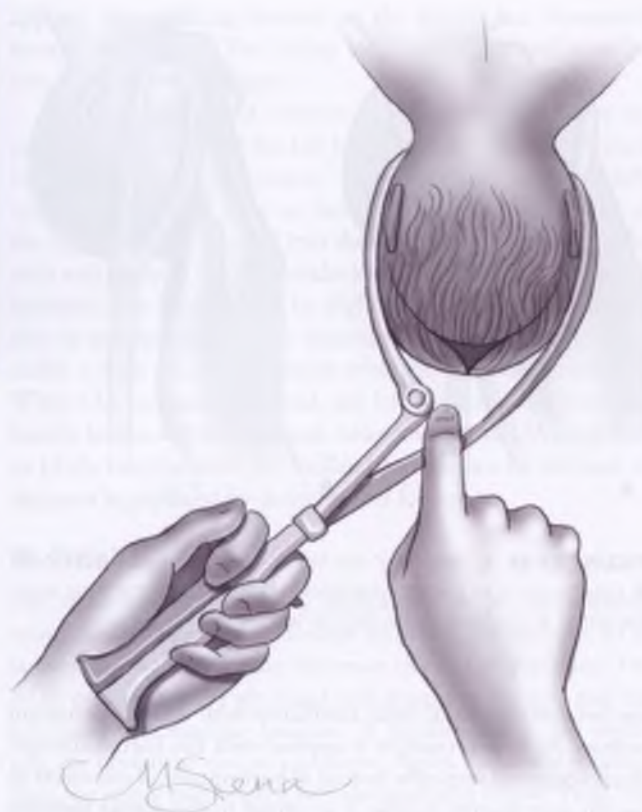

FIGURE 23-37 Following rotation, the handles point obliquely to the right. Traction with a finger in the crotch of the shanks is often successful. If it is not, the operator can switch to a suitable outlet forceps with a pelvic curve.

(Danforth, 1965). As shown, the handles will point obliquely to the right of the midline. Once the chin can be reached, the forceps are removed, and the delivery is completed with a modified Ritgen maneuver. As with other descriptions of technique in this chapter, all manipulations are reversed when the starting position is right occiput transverse (ROT). However, even with an ROT position, the posterior branch is still inserted to the patient's right of the anterior branch.

Some authors describe the use of Barton forceps for rotation of an OP position (Dennen, 1955). Our preference is to use Kielland forceps for this.

Pitfalls

When using Barton forceps to deliver a fetus in transverse arrest, the most important pitfall is an error in the diagnosis of the pelvis type. If the pelvis is android instead of platypelloid, both anteroposterior and transverse diameters are narrow. A trial of traction with an OT position can be attempted using the Barton forceps. However, if resistance to descent is encountered, opting for either rotation with Kielland forceps or abandoning OVD for cesarean delivery is prudent. Remember that traction with Kielland forceps with the fetal head oriented transversely is contraindicated. Last, the fenestrated blades of the Barton forceps enable a firm grasp of the head but tend to leave obvious forceps marks.

Sequential Use of Instruments

The American College of Obstetricians and Gynecologists (2015) notes that “the weight of available evidence appears to be against routine use of sequential instruments at operative vaginal delivery.” However, the Royal College of Obstetricians and Gynaecologists (2011) cautions in their guidelines that the operator must balance the risks of a cesarean delivery following failed vacuum extraction with the risks of forceps delivery following failed vacuum extraction.

Evidence from studies supports this latter view. But notably, in many of these, the details of fetal station following failure with the first instrument (most often vacuum) are lacking. Moreover, whether the vacuum cup popped off or failed to produce descent below +2 station, or succeeded in bringing the head down close to or onto the pelvic floor before failing is essential information. In one series of 288 failed vacuum deliveries, 245 (85 percent) were followed by successful low or outlet forceps, with no increase in serious neonatal morbidity rates (Edgar, 2012). Importantly, this study did specify the station at which forceps were applied following a failed vacuum extraction attempt. Another report compared failed vacuum extraction followed by forceps against cesarean delivery following failed vacuum extraction (Sadan, 2003). Neonatal morbidity rates were higher in the cesarean group than the forceps group. The authors concluded that a clinician should choose the method most suitable to the given circumstances.

If delivery with a single instrument is compared with sequential use, both maternal and neonatal morbidity are greater with the latter (Murphy, 2011). Authors of this report conclude that the aim of OVD should be to complete delivery with one instrument. Because vacuum extraction fails more often than forceps delivery, we are of the opinion that forceps should be the first choice, provided that the operator is appropriately trained. In support of this, one study of 798 emergency OVDs attempted in a labor room found 2 cases of failed forceps and 39 failed vacuum deliveries. All 39 failed vacuums were completed by forceps, not cesarean (Murphy, 2007). Second, in a series of 1000 consecutive attempted vacuum deliveries using the OmniCup, the vacuum failed in 15 percent of nulliparas (Baskett, 2008). Of the failures, 78 percent were then successfully delivered by forceps, not cesarean, with no rise in neonatal morbidity rates.

In sum, we agree with the Royal College that either outlet or low forceps following failed vacuum extraction may avoid a potentially complex cesarean delivery. Importantly, the reason for vacuum failure should weigh heavily in the decision. During a vacuum extraction trial, cup dislodgement due to technical failure or less than optimal placement should not be equated with dislodgement under ideal conditions of exact cup placement and optimal vacuum maintenance. These former circumstances may merit a trial of forceps. The least desirable cases are those in which the cup disengages multiple time following correct cup application and appropriate traction or those in which traction fails to yield descent.

Trial of Operative Vaginal Delivery

Discussion points pertinent to OVD attempts include failed forceps, failed trial of forceps, predictors of OVD failure, and

outcomes following failed OVD. First, the nuanced distinction between *failed forceps* and *failed trial of forceps* focuses on the anticipation of failure. If one is unsure of success, moving the gravida to an operating room for a trial of OVD, which could be followed by immediate cesarean delivery if OVD fails, has merit. In comparison, failed forceps describes an attempt in the labor room that failed, thereby necessitating transferring the patient to an appropriately equipped and staffed operating room. The delay caused by transfer or assembling surgical staff may result in worse outcomes. The American College of Obstetricians and Gynecologists (2015) supports a trial of OVD if the obstetrician feels the chance of success is high.

Second, regarding predictors of OVD failure, some investigators note that increased birthweight, especially if more than 4000 g, and abnormal head position were valuable indicators (Aiken, 2014; Ben-Haroush, 2007). However, Palatnik and coworkers (2016) concluded that potential risk factors identified before an OVD attempt were not predictive.

Last, the consequences of cesarean delivery following failed OVD appear minimal. In one study, more than 600 women who failed OVD and subsequently delivered by cesarean were compared with those undergoing second-stage cesarean. Adverse outcome rates were not greater in the failed OVD group in the absence of a nonreassuring fetal heart rate tracing (Alexander, 2009).

ASSOCIATED MORBIDITY

■ Maternal Morbidity

OVD can result in morbidity for the mother, the neonate, or both. For the mother, the risk for third- and fourth-degree perineal laceration is increased. However, the very conditions that lead to OVD also increase the need for episiotomy and the likelihood of these higher-order perineal lacerations (de Leeuw, 2008). That said, OVD is associated with higher rates of these perineal lacerations and of vaginal wall or cervical lacerations (Hamilton, 2011; Hirayama, 2012; Landy, 2011). Urinary retention and bladder dysfunction are often short-term effects of OVD (Mulder, 2012). Of long-term effects, data specifically implicating anal incontinence, pelvic organ prolapse, and urinary incontinence to OVD are conflicting. In many cases, these can be attributed to vaginal delivery itself or to higher-order perineal lacerations rather than solely to OVD.

Higher-order perineal lacerations appear to be associated to a greater degree with forceps delivery than with vacuum extraction. One example is the study by Caughey and coworkers (2005) of 2075 nonrotational forceps and 2045 vacuum deliveries. This conclusion was reinforced by the American College of Obstetricians and Gynecologists (2015), citing evidence from 13 randomized trials. A surprising finding reported by one group showed that neither number of forceps deliveries nor number of years in practice affected the rate of severe perineal lacerations (Miller, 2014). This study was limited to attending physicians, but collectively they performed only a small number of forceps deliveries annually.

Regardless, all operators who perform OVD should make every effort to avoid these lacerations, as enumerated on page 375. Measures include some combination of early disarticulation and removal of forceps, correct maternal leg positioning, perineal support, and selection of mediolateral episiotomy, if episiotomy is needed.

These maternal risks of OVD are balanced against those of cesarean delivery. Importantly, in this comparison, too little emphasis has been accorded to the morbidity and mortality of second-stage cesarean delivery, which is the only reasonable comparison group. The maternal risks of second-stage cesarean delivery are greater than those of first-stage cesarean (Pergialiotis, 2014). Moreover, for nulliparas who undergo cesarean delivery at full cervical dilation, the risk that their next delivery will be cesarean is nearly 90 percent. As described in Chapter 25 (p. 416), each successive cesarean delivery raises the risk of placenta accreta, uterine rupture, and cesarean hysterectomy. Analogously, for women who deliver their first newborn vaginally, the likelihood of subsequent vaginal delivery is high.

It has become fashionable to examine composite morbidity outcomes rather than analyze separate complications. With this methodology, 2296 OVDs from low or outlet station were compared with 222 cesarean deliveries performed during second-stage labor without attempted OVD from the same station. Maternal composite outcome was the same in both groups (Halscott, 2015). In our view, composite outcome aside, all 222 women in the cesarean group suffered the morbidity of a uterine scar, which will subject them to the just-described complications in subsequent pregnancies. That these cesareans were performed at or below +3 station *without attempting* OVD speaks to the need for training in OVD techniques. In the same study, composite neonatal morbidity was lower in newborns of nulliparas undergoing forceps compared with cesarean delivery. However, the neonatal morbidity composite was higher for vacuum delivery compared with cesarean (Halscott, 2015).

In the first stage of labor OVD is not an option. But in the second stage, all of the cesarean complications cited above must be weighed against the potential morbidity of OVD. We agree with Spencer (2006) that many second-stage cesarean deliveries could be prevented by an obstetrician skilled in OVD. The American College of Obstetricians and Gynecologists (2015) also emphasizes that OVD morbidity may result from the operator, not the instrument.

■ Neonatal Morbidity

Although the risk for serious neonatal injury with OVD is small, some potential neonatal harms includes facial nerve palsy, Erb palsy, skull fracture, retinal hemorrhage, cerebral injury, subgaleal hemorrhage, and cephalohematoma. Despite this, two recent reports also highlight that cesarean delivery for the newborn is not less morbid than OVD. First, in a report by Werner and associates (2011) of more than 100,000 deliveries, forceps delivery carried a reduced risk of adverse neonatal neurologic outcomes compared with either vacuum or cesarean delivery. If the cesarean group had been restricted to

second-stage cesarean deliveries, the reported differences would probably have been even greater. In the second study, Walsh and colleagues (2013) evaluated more than 60,000 second-stage deliveries. Neonatal death and neonatal encephalopathy rates associated with cesarean delivery did not differ from those with OVD. Both of these reports selected the appropriate comparison group, which was cesarean delivery rather than spontaneous vaginal delivery.

Logically, incorrect placement of an instrument for OVD may raise neonatal morbidity rates, but until recently no evidence supported this assumption. In 478 women who underwent OVD, investigators determined that 138 (29 percent) were suboptimally placed (Ramphul, 2015). Poor placement led to a more than fourfold higher incidence of complications defined as facial palsy, Erb palsy, fractures, retinal hemorrhage, cerebral injury, and cephalohematoma. It also resulted in a two times greater requirement for sequential instrument use. These data emphasize the role of the operator in OVD outcomes.

One type of morbidity that occurs much more frequently with vacuum extraction than with forceps is subgaleal hemorrhage (Fig. 23-38). Most of these neonatal hematomas are benign but can be potentially life-threatening. Remarkably, a 1-cm increase in thickness of the subgaleal space can reflect a neonatal blood collection of up to 260 mL, which in turn can lead to hypovolemic shock and death (Boo, 2005; Kilani, 2006). A recent report from Sweden described the outcomes of more than 88,000 vacuum deliveries and compared vacuum successes and failures (Ahlberg, 2016). In that country, 13 percent of all deliveries are by vacuum extraction, and only 0.1 percent are by forceps. The incidence of subgaleal hematoma was more than seven times greater following failed vacuum extraction than after successful vacuum delivery. Whenever a vacuum extraction has been attempted, regardless of whether the attempt succeeded or failed, the neonatal

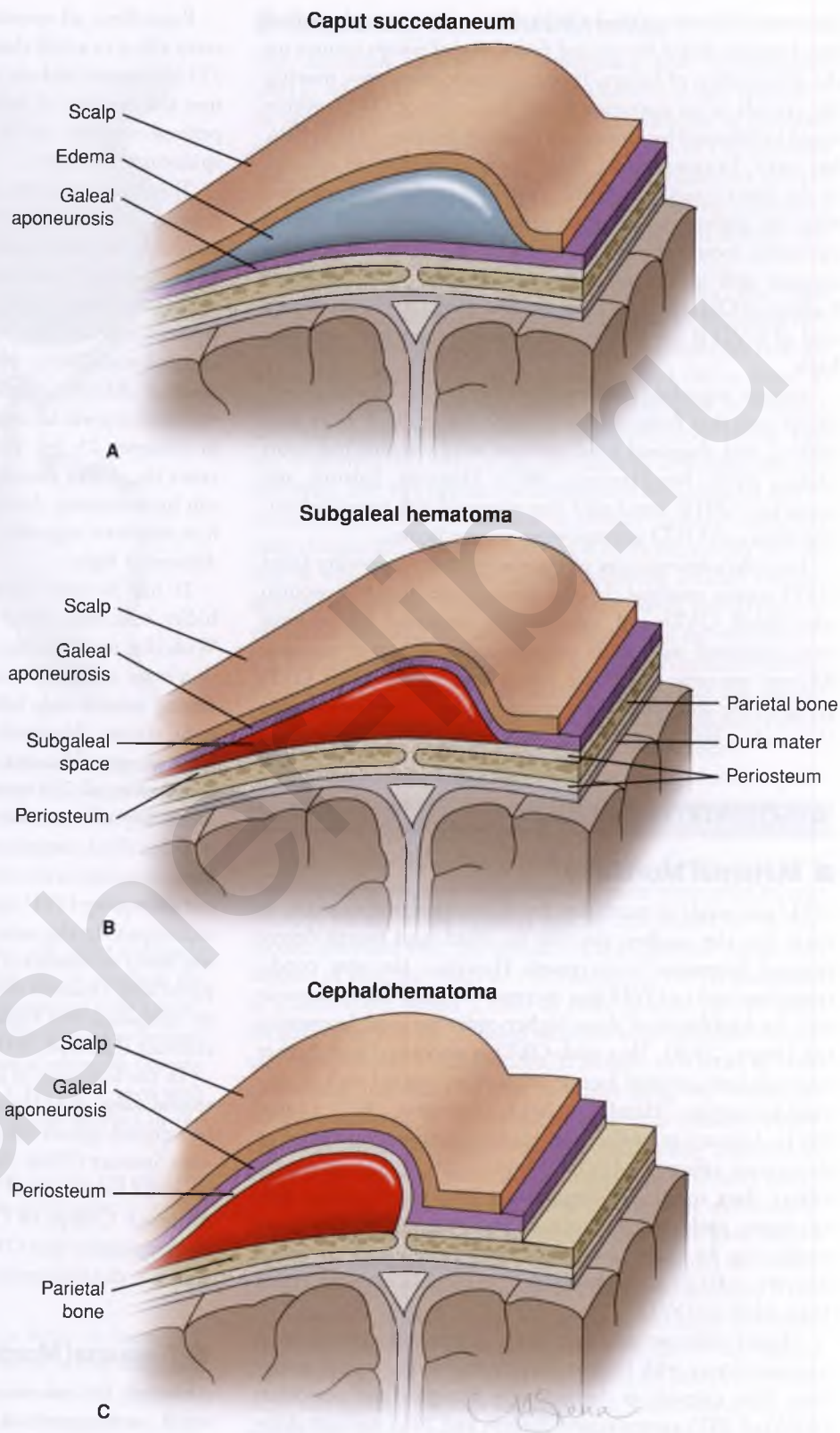


FIGURE 23-38 **A.** Caput succedaneum. Scalp edema crosses suture lines. **B.** Subgaleal hematoma. This collection of blood beneath the galeal aponeurosis crosses suture lines. Hemorrhage can thus be clinically substantial. **C.** Cephalohematoma. This collection of subperiosteal blood does not cross suture lines.

TABLE 23-7. Recent Reports on Kielland Rotational Forceps

Author (yr)	Data Years	No. Attempted	No. Successful (%)	Morbidity
Al-Suhel (2009)	2002–2005	94	89 (95%)	Fewer maternal or neonatal adverse events than other instrumental delivery methods
Bahl (2013)	2004–2006	145	131 (90%)	3 cases of “neonatal trauma”
Bradley (2013)	2008–2011	31	31—only reported successes	Fewer severe lacerations than delivery as OP
Burke (2012)	1997–2011	144	129 (90%)	One 3rd-degree tear
Stock (2013)	2001–2008	873	873—only reported successes	12 cephalohematomas, 13 nerve palsies, 1 stillbirth
Tempest (2013)	2006–2010	1038	1000 (96%)	24% anal sphincter injury rate 10 transient Erb palsy cases

OP = occiput posterior.

care provider should be alerted to observe for potential complications (American College of Obstetricians and Gynecologists, 2015).

■ Morbidity of Midpelvic Delivery

As reflected in the American College of Obstetricians and Gynecologists classification system, station and rotation are important determinants of maternal and neonatal outcomes with OVD. However, a recent study from France showed no difference in maternal or neonatal outcomes between groups undergoing midpelvic OVD or undergoing low or outlet OVD (Ducarme, 2015). These investigators again used composite maternal and neonatal outcome measures to analyze more than 2000 OVDs. As with most studies, they considered only short-term outcomes. Their conclusions, however, may not be generalizable. Of 391 midpelvic deliveries, 324 were accomplished by Thierry spatulas, an instrument seldom used in Great Britain or the United States. Forceps were used only 35 times and only one was rotational.

■ Morbidity of Forceps Rotations

As shown in Table 23-7, the use of Kielland forceps to rotate a malpositioned fetal head to an anterior position has recently increased (Al-Suhel, 2009; Bahl, 2013; Bradley, 2013; Burke, 2012; Stock, 2013; Tempest, 2013). Discouragingly, only one of the listed reports comes from the United States, and this one cites only 31 procedures (Bradley, 2013). However, even in light of the small number of rotational forceps procedures, Bradley concluded that rotation to an occiput anterior position is associated with less severe maternal perineal trauma than forceps delivery from an OP position. In our opinion, the sum total of Kielland rotations recently reported, coupled with their high success and low complication rates, justifies the continued performance of rotational forceps deliveries. This statement comports with the latest guidance from the American College of Obstetricians and Gynecologists (2015). The caveat, of course, is that the operator must have been appropriately trained. We agree with Barth (2015) that training residents in complicated operative vaginal delivery should be restricted to

those who may actually perform those deliveries in their future practice of obstetrics.

CONCLUSION

OVD is on the decline in the United States. It has fallen to an overall rate of 3.3 percent, with a forceps rate of only 0.6 percent (American College of Obstetricians and Gynecologists, 2015). With the cesarean delivery rate tenfold higher and the consequences of such a high rate just beginning to be appreciated, the time is right for a review that highlights the basic principles of OVD and illustrates proper technique for its performance. We urgently call on two groups of providers, trainees in obstetrics and senior clinician/educators, to assist in preserving OVD as an option for future generations of women.

REFERENCES

- Abenhaim HA, Morin L, Benjamin A, et al: Effect of instrument preference for operative deliveries on obstetrical and neonatal outcomes. *Eur J Obstet Gynecol Reprod Biol* 134: 164, 2007
- Ahlberg M, Norman M, Hjelmstedt A et al: Risk factors for failed vacuum extraction and associated complications in term newborn infants: a population-based cohort study. *J Matern Fetal Med* 29:1646, 2016
- Aiken CE, Aiken AR, Brockelsby JC, et al: Factors influencing the likelihood of instrumental delivery success. *Obstet Gynecol* 123:796, 2014
- Alexander JM, Leveno KJ, Hauth JC, et al: Failed operative vaginal delivery. *Obstet Gynecol* 114:1017, 2009
- Al-Suhel R, Gill S, Robson S, et al: Kjelland's forceps in the new millennium. Maternal and neonatal outcomes of attempted rotational forceps delivery. *Aust N Z J Obstet Gynaecol* 49:510, 2009
- American College of Obstetricians and Gynecologists: Operative vaginal delivery. Practice Bulletin No. 154, November 2015
- Bahl R, Van de Venne M, Macleod M, et al: Maternal and neonatal morbidity in relation to the instrument used for mid-cavity rotational operative vaginal delivery: a prospective cohort study. *BJOG* 120:1526, 2013
- Barth WH Jr: Persistent occiput posterior. *Obstet Gynecol* 125:695, 2015
- Baskett TF, Fanning CA, Young DC: A prospective observational study of 1000 vacuum assisted deliveries with the OmniCup device. *J Obstet Gynaecol Can* 30:578, 2008
- Ben-Haroush A, Melamed N, Kaplan B et al: Predictors of failed operative vaginal delivery: a single-center experience. *Am J Obstet Gynecol* 197:308.e1, 2007
- Boo NY, Foong KW, Mahdy ZA et al: Risk factors associated with subaponeurotic hemorrhage in full-term infants exposed to vacuum extraction. *BJOG* 112:1516, 2005

- Bradley MS, Kaminski RJ, Streitman DC, et al: Effect of rotation on perineal lacerations in forceps-assisted vaginal deliveries. *Obstet Gynecol* 122:132, 2013
- Burke N, Field K, Mujahid F, et al: Use and safety of Kielland's forceps in current obstetric practice. *Obstet Gynecol* 120:766, 2012
- Caughy AB, Sandberg PL, Zlatnik MG et al: Forceps compared with vacuum. *Obstet Gynecol* 106:908, 2005
- Cunningham FG: The Ritgen maneuver. *Obstet Gynecol* 112:210, 2008
- Cunningham FG, Leveno KJ, Bloom SL et al: Operative vaginal delivery. In *Williams Obstetrics*, 24th ed. New York, McGraw-Hill Education, 2014, p 574
- Danforth DN: Transverse arrest. *Clin Obstet Gynecol* 8: 854, 1965
- Danforth DN, Ellis AH: Midforceps delivery—a vanishing art? *Am J Obstet Gynecol* 86:29, 1963
- de Leeuw JW, de Wit C, Kuijken JP, et al: Mediolateral episiotomy reduces the risk for anal sphincter injury during operative vaginal delivery. *BJOG* 115: 104, 2008
- Dennen EH: *Forceps Delivery*. Philadelphia, FA Davis, 1955
- Drife JO: Choice and instrumental delivery. *BJOG* 103:608, 1996
- Ducarme G, Hamel JF, Bouet PE, et al: Maternal and neonatal morbidity after attempted operative vaginal delivery according to fetal head station. *Obstet Gynecol* 126:521, 2015
- Edgar DC, Baskett TF, Young DC, et al: Neonatal outcome following failed Kiwi OmniCup vacuum extraction. *J Obstet Gynaecol Can* 34:620, 2012
- Ennis M: Training and supervision of obstetric senior house officers. *BMJ* 303:1442, 1991
- Gilstrap LC III: Forceps delivery. In Gilstrap LC III, Cunningham FG, VanDorsten P (eds): *Operative Obstetrics*, 2nd ed. New York, McGraw-Hill, 2002, p 89
- Hale RW: *Dennen's Forceps Deliveries*, 4th ed. American College of Obstetricians and Gynecologists, 2001, p 3
- Hals E, Oian P, Pirhonen, et al: A multicenter interventional program to reduce the incidence of anal sphincter tears. *Obstet Gynecol* 116:901, 2010
- Halscott TL, Reddy UA, Landy HJ, et al: Maternal and neonatal outcomes by attempted mode of operative delivery from a low station in the second stage of labor. *Obstet Gynecol* 126:1265, 2015
- Hamilton EF, Smith S, Yang L, et al: Third- and fourth-degree perineal lacerations: defining high-risk clinical clusters. *Am J Obstet Gynecol* 204(4): 309.e1, 2011
- Healy DL, Quinn MA, Pepperell RJ: Rotational delivery of the fetus: Kielland's forceps and two other methods compared. *BJOG* 89:501, 1982
- Hirayama F, Koyanagi A, Mori R, et al: Prevalence and risk factors for third- and fourth-degree perineal lacerations during vaginal delivery: a multi-country study. *BJOG* 119(3):340, 2012
- Jonsson ER, Elfaghi I, Rydstrom H, et al: Modified Ritgen's maneuver for anal sphincter injury at delivery. *Obstet Gynecol* 112:212, 2008
- Kilani RA, Wetmore J: Neonatal subgaleal hematoma: presentation and outcome—radiological findings and factors associated with mortality. *Am J Perinatol* 23:41, 2006
- Landy HJ, Laughon SK, Bailit JL, et al: Characteristics associated with severe perineal and cervical lacerations during vaginal delivery. *Obstet Gynecol* 117(3):627, 2011
- Laufe LE: A new divergent outlet forceps. *Am J Obstet Gynecol* 101:509, 1968a
- Laufe LE: An improved Piper forceps. *Obstet Gynecol* 29:284, 1967
- Laufe LE: *Obstetric Forceps*. New York, Harper & Row, 1968b, p 57
- Le Ray C, Deneux-Tharoux C, Khireddine I, et al: Manual rotation to decrease operative delivery in posterior or transverse positions. *Obstet Gynecol* 122:634, 2013
- Luikart R: A modification of the Kielland, Simpson, and Tucker-McLane forceps to simplify their use and improve function and safety. *Am J Obstet Gynecol* 34:686, 1937
- Luikart R: A new forceps possessing a sliding lock, modified fenestra with improved handle and axis traction attachment. *Am J Obstet Gynecol* 40: 692, 1940
- Malmstrom T, Jansson I: Use of the vacuum extractor. *Clin Obstet Gynecol* 8:893, 1965
- Megison JW: Save the Barton forceps. *Obstet Gynecol* 82:313, 1993
- Miller ES, Barber EL, McDonald KD, et al: Association between obstetrician forceps volume and maternal and neonatal outcomes. *Obstet Gynecol* 123:248, 2014
- Mulder F, Schoffemeer M, Hakvoort R, et al: Risk factors for postpartum urinary retention: a systematic review and meta-analysis. *BJOG* 119(12):1440, 2012
- Murphy DJ, Koh DKM: Cohort study of the decision to delivery interval and neonatal outcome for emergency operative vaginal delivery. *Am J Obstet Gynecol* 196:145.e1, 2007
- Murphy DJ, Macleod M, Bahl R, et al: A cohort study of maternal and neonatal morbidity in relation to use of sequential instruments at operative vaginal delivery. *Eur J Obstet Gynecol Reprod Biol* 156:41, 2011
- Olah KS: In praise of Kielland's forceps. *BJOG* 109:492, 2002
- Palatnik A, Grobman WA, Hellendag MG, et al: Predictors of failed operative vaginal delivery in a contemporary obstetric cohort. *Obstet Gynecol* 127: 501, 2016
- Parry-Jones E: *Barton's Forceps*, 1st ed. London, Sector Publishing, 1972
- Pergialiotis V, Vlachos DG, Rodolakis A, et al: First versus second stage C/S maternal and neonatal morbidity: a systematic review and meta-analysis. *Eur J Obstet Gynecol Reprod Biol* 175:15, 2014
- Piper EB, Bachman C: The prevention of fetal injuries in breech delivery. *JAMA* 92:217, 1929
- Ramphul M, Kennelly MM, Burke G, et al: Risk factors and morbidity associated with suboptimal instrument placement at instrumental delivery: observational study nested within the Instrumental Delivery & Ultrasound randomized controlled trial ISRCTN 72230496. *BJOG* 122:558, 2015
- Ramphul M, Ooi PV, Burke G, et al: Instrumental delivery and ultrasound: a multicenter randomised controlled trial of ultrasound assessment of the fetal head position versus standard care as an approach to prevent morbidity at instrumental delivery. *BJOG* 121:1029, 2014
- Reichman O, Gdanský E, Latinsky B, et al: Digital rotation from occipitoposterior to occipito-anterior decreases the need for cesarean section. *Eur J Obstet Gynecol Reprod Biol* 136:25, 2008
- Royal Australian and New Zealand College of Obstetricians and Gynaecologists: Instrumental vaginal birth. College Statement C-Obs 16, July 2002, Reaffirmed 2015. Available at: [file:///C:/Users/bhoffm/Downloads/Instrumental%20Vaginal%20Birth%20\(C-Obs%2016\)%20Review%20March%202016.pdf](file:///C:/Users/bhoffm/Downloads/Instrumental%20Vaginal%20Birth%20(C-Obs%2016)%20Review%20March%202016.pdf). Accessed March 30, 2016
- Royal College of Obstetricians and Gynaecologists: Operative vaginal delivery. Green-top Guideline No. 26, 2011
- Sadan O, Ginath S, Gomel A, et al: What to do after a failed attempt of vacuum delivery? *Eur J Obstet Gynecol Reprod Biol* 107:151, 2003
- Shaffer BL, Cheng YW, Vargas JE, et al: Manual rotation to reduce cesarean delivery in persistent occiput posterior or transverse position. *J Matern Fetal Neonatal Med* 24:65, 2011
- Solt I, Jackson S, Moore T, et al: Teaching forceps: the impact of proactive faculty. *Am J Obstet Gynecol* 204:448.e.1, 2011
- Spencer C, Murphy D, Bewley S: Caesarean delivery in the second stage of labour. *BMJ* 33:613, 2006
- Spong CY, Berghella V, Wenstrom K, et al: Preventing the first cesarean delivery: summary of a joint Eunice Kennedy Shriver National Institute of Child Health and Human Development, Society for Maternal-Fetal Medicine, and American College of Obstetricians and Gynecologists workshop. *Obstet Gynecol* 120:1181, 2012
- Stock SJ, Josephs K, Farquharson S, et al: Maternal and neonatal outcomes of successful Kielland's rotational forceps delivery. *Obstet Gynecol* 121:1032, 2013
- Tempest N, Hart A, Walkinshaw S, et al: A re-evaluation of the role of rotational forceps: retrospective comparison of maternal and perinatal outcomes following different methods of birth for malposition in the second stage of labour. *BJOG* 120:1277, 2013
- Vayssi re C, Beucher G, Dupuis O, et al: Instrumental delivery: clinical practice guidelines from the French College of Gynaecologists and Obstetricians. *Eur J Obstet Gynaecol Reprod Biol* 159:43, 2011
- Walsh CA, Robson M, McAuliffe FM: Mode of delivery at term and adverse neonatal outcomes. *Obstet Gynecol* 121:122, 2013
- Werner EF, Janevic TM, Illuzzi J, et al: Mode of delivery in nulliparous women and neonatal intracranial injury. *Obstet Gynecol* 118:1239, 2011
- Yeomans ER: Clinical pelvimetry. *Clin Obstet Gynecol* 49:140, 2006
- Yeomans ER: Operative vaginal delivery. *Obstet Gynecol* 115:645, 2010

CHAPTER 24

Shoulder Dystocia

DEFINITION	389
INCIDENCE	390
DIFFERENTIAL DIAGNOSIS	390
RISK FACTORS	390
PREDICTION AND PREVENTION	393
SHOULDER DYSTOCIA MANAGEMENT	393
COMPLICATIONS	398
CHART DOCUMENTATION	400
ROLE FOR SIMULATION	400
SUMMARY	400

Shoulder dystocia is one of the most dreaded and dramatic complications encountered in obstetrics. It is a true emergency that can lead to high rates of maternal morbidity as well as neonatal morbidity and mortality. Various maneuvers can free the impacted shoulder to obviate fetal hypoxia. The steps are completed expeditiously, but mechanical force must be tempered to avoid maternal and fetal traumatic injury. The importance of this obstetric complication and its sequelae were emphasized by the appointment of a Task Force by American College of Obstetricians and Gynecologists president Dr. James T. Breeden. This working group published its monograph Neonatal Brachial Plexus Palsy in 2014.

DEFINITION

Shoulder dystocia has been defined in several ways. Following complete emergence of the fetal head during vaginal delivery, the remainder of the body may not rapidly follow despite downward traction and maternal pushing. Resnik (1980) described shoulder dystocia as a condition requiring special maneuvers to deliver the shoulders following an unsuccessful attempt to apply downward traction. Benedetti (1989) more specifically defined it as an arrest of spontaneous delivery due to impaction of the anterior shoulder behind and against the symphysis pubis. The Task Force cited a commonly accepted definition that requires additional maneuvers following failure of gentle downward traction on the fetal head to deliver the shoulders. Other investigators use the head-to-body time interval as the defining factor (Beall, 1998; Hoffman, 2011). Spong and coworkers (1995) reported that the mean head-to-body delivery time in normal births was 24 seconds compared with 79 seconds in those with shoulder dystocia. These investigators proposed that head-to-body delivery time >60 seconds should define shoulder dystocia.

At this time, it is reasonable for the diagnosis to continue to rely on the clinical perception that the normal downward traction needed for fetal shoulder delivery is ineffective. But, whatever definition is used, any perceived shoulder dystocia is an obstetric emergency. The umbilical cord is compressed within the birth canal, and the placenta is variably separated.

HISTORY

Shoulder dystocia has been described in the medical literature for at least two centuries. Swartz (1960) quoted Smellie, writing in 1730: "A sudden call to a gentlewoman in labor. The child's head delivered for a long time—but even with hard pulling from the midwife, the remarkably large shoulder prevented delivery. I have been called by midwives to many cases of this kind, in which the

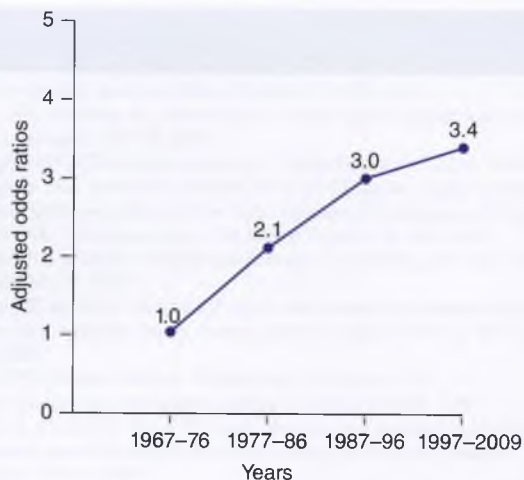


FIGURE 24-1 Incidence of shoulder dystocia according to birth-weight in 2,014,956 Norwegian births. (Data from Øverland EA, Vatten LJ, Eskild A: Pregnancy week at delivery and the risk of shoulder dystocia: a population study of 2,014,956 deliveries, *BJOG* 2014 Jan; 121(1):34-41).

child was frequently lost.” In his premier edition of *Obstetrics*, J. Whitridge Williams (1903) warns against applying excessive traction to avert traumatic brachial plexus stretching. But even as late as 1966, shoulder dystocia received relatively little attention. For example, in the 13th edition of *Williams Obstetrics* by Eastman and Hellman (1966), only one page is devoted to the subject. By way of contrast, this entire contemporaneous chapter is devoted to shoulder dystocia and its management.

INCIDENCE

Understandably, shoulder dystocia incidences differ because of varied definitions and data-reporting methods. According to the American College of Obstetricians and Gynecologists (2015b), the rate lies between 0.6 and 1.4 percent. The incidence is likely rising because of increasing fetal birthweights and improved reporting rates (Fig. 24-1) (MacKenzie, 2007; Øverland, 2014). At the same time, however, the incidence of neonatal brachial plexus palsy appears to be either stable or declining (American College of Obstetricians and Gynecologists, 2014; Chauhan, 2014a). For example, Hopwood (1982) described an increasing rate of shoulder dystocia, which was reported to be 0.2 percent of deliveries between 1966 and 1976. This rose to 1.1 percent

TABLE 24-2. Differential Diagnosis of Difficulty in Completing Vaginal Delivery

Shoulder dystocia
Short umbilical cord
Fetal thoracic or abdominal enlargement
Locked twins
Conjoined twins
Contraction ring

between 1976 and 1981. They attributed the rise to the general trend toward larger fetal birthweight, a finding confirmed by Modanlou and coworkers (1982). Table 24-1 summarizes shoulder dystocia rates with respect to birthweight in several studies. The incidence further varies depending on the specific patient population and the subgroups of patients reported, for example, diabetic versus nondiabetic women.

Steps have been made to make reporting of shoulder dystocia more reproducible. Beall and associates (1998) attempted to validate the definition by Spong noted earlier. Prolonged head-to-body delivery time and/or use of ancillary maneuvers were prospectively evaluated in 722 women. Of the 99 cases of shoulder dystocia using this definition, the practitioner subjectively labeled only 25 percent as “dystocia.” Those deliveries requiring special maneuvers were more likely to be described as dystocia by the practitioner. Deliveries meeting this definition of shoulder dystocia had increased neonatal birthweights, and all fetal injuries were in the identified group. They also reported that 50 percent of those deliveries that required special maneuvers did not have documentation in the medical record.

DIFFERENTIAL DIAGNOSIS

There are only a few conditions in which the fetal body does not deliver promptly following the head. In addition to shoulder dystocia, some other conditions are listed in Table 24-2.

RISK FACTORS

Most cases of shoulder dystocia occur in women without risk factors. That said, several risk characteristics for shoulder dystocia may be identified before or during labor (Table 24-3). Unfortunately, such qualities are so common that they lack both sensitivity

TABLE 24-1. Birthweight and Shoulder Dystocia

Study	No.	Incidence (%)		
		<4000 g	>4000 g	>4500 g
Acker (1985)	13,403	1.0	1.0	24
Gross (1987a)	6729	1.0	9	36
Sandmire (1988)	13,051	0.2	2	4
Gregory (1998)	57,271	1.5	11	ND
Lewis (1998)	1,523	4.2	32	44
Average	91,977	1.5	9.9	20

ND = not determined.

TABLE 24-3. Risk Factors for Shoulder Dystocia**Antepartum**

Fetal macrosomia
 Maternal obesity
 Diabetes mellitus
 Postterm pregnancy
 Male gender
 Advanced maternal age
 Excessive weight gain
 Prior shoulder dystocia
 Platypelloid pelvis
 Contracted pelvis
 Multiparity

Intrapartum

First-stage labor abnormalities
 Protraction disorders
 Arrest disorders
 Prolonged second stage of labor
 Oxytocin augmentation of labor
 Midforceps and midvacuum extraction
 Epidural analgesia

and specificity and thus have limited clinical utility (American College of Obstetricians and Gynecologists, 2014, 2015b).

■ Antepartum Risk Factors

Fetal Macrosomia

A large fetus is a major risk factor for shoulder dystocia. The rate of shoulder dystocia relative to birthweight is listed in Table 24-1 and depicted in Figure 24-2. However, the degree of risk depends on the weight used to define fetal macrosomia. This condition implies growth beyond a specific weight, usually 4000 g or 4500 g, regardless of gestational age. The American College of Obstetricians and Gynecologists (2015a) proposes a defining weight that accounts for available data regarding

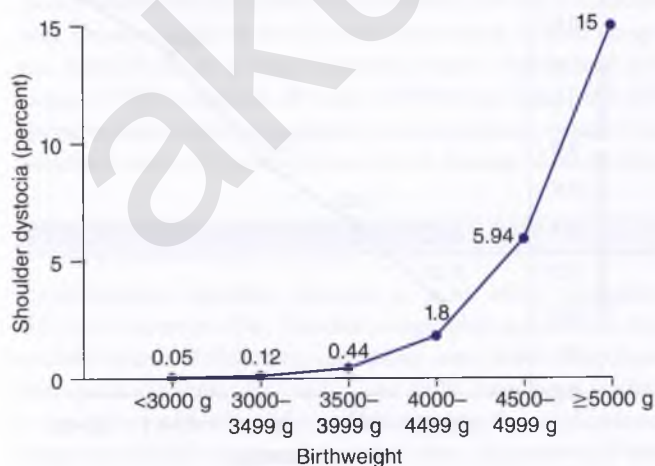


FIGURE 24-2 The incidence of shoulder dystocia among 14,721 deliveries according to birthweight and diabetic status. (Data from Acker DB, Sachs BP, Friedman EA: Risk factors for shoulder dystocia, *Obstet Gynecol* 1985 Dec;66(6):762–768).

Erb palsy, which is a sequela of brachial plexus stretch, and for the known inaccuracies of antepartum estimated fetal weights (EFWs). They suggest that 4500 g is an appropriate EFW beyond which the fetus should be considered macrosomic. Adoption of a lower EFW threshold would label many fetuses as “at risk” despite only a relatively small increase in the risk of morbidity as a consequence of their size. Although there is general agreement with this definition, many studies still use ≥ 4000 g to define macrosomia. As an example of associated risk, Hehir and colleagues (2015) reported that 0.4 percent of pregnancies in contemporary practice weighed >5000 g. Shoulder dystocia was identified in 14 percent of those delivered vaginally.

To minimize shoulder dystocia risks, a more liberal cesarean delivery policy for *suspected* macrosomia has been suggested. Gross and coworkers (1987a) used multiple discriminant analysis to define a model that could predict shoulder dystocia. They calculated that if cesarean deliveries were performed for all neonates weighing ≥ 4000 g, six operations would be required to prevent one case of shoulder dystocia. Rouse and coworkers (1996) constructed a decision analytic model to study this issue and concluded that elective cesarean delivery for sonographically diagnosed macrosomia was not medically and financially feasible for the nondiabetic population. Other investigators have reached similar conclusions (Gonen, 2000; Kolderup, 1997).

Similarly, to lower the risks for shoulder dystocia rates, labor induction because of “impending” macrosomia has generally not been considered feasible (Grobman, 2013; Hansen, 2014). At least one recent investigation, however, has shown such benefits (Boulvain, 2015). In this study, preemptive induction and delivery of fetuses judged to weigh >95 th percentile decreased the shoulder dystocia rate significantly. Importantly, the cesarean delivery rate was not increased.

In view of inaccuracies of antepartum EFWs derived sonographically, along with the fact that no substantial evidence supports early vaginal delivery or cesarean delivery in preventing brachial plexus injuries, management solely based on sonographic EFW is not warranted (American College of Obstetricians and Gynecologists, 2015b; Lee, 2016).

Maternal Obesity

Johnson and associates (1987) reported a 5-percent incidence of shoulder dystocia if maternal weight at delivery is >250 lb compared with 0.6 percent in women who weighed <200 lb. Other investigators have found similar correlation between maternal obesity and shoulder dystocia (Avci, 2015; Crane, 2013; Spellacy, 1985). These studies also note that this link is related to the common cofactor of fetal macrosomia and/or diabetes (Langer, 2016). Conversely, Lewis and colleagues (1998) showed no increased risk of shoulder dystocia or birth trauma with a maternal weight >90 kg.

Diabetes Mellitus

The combination of fetal macrosomia in maternal diabetes mellitus escalates the frequency of shoulder dystocia (Langer, 1991; Nesbitt, 1998). Of possible explanations, fetuses of diabetic women have increased shoulder-to-head and chest-to-head size differences relative to comparable-weight fetuses of nondiabetic mothers (Modanlou, 1982).

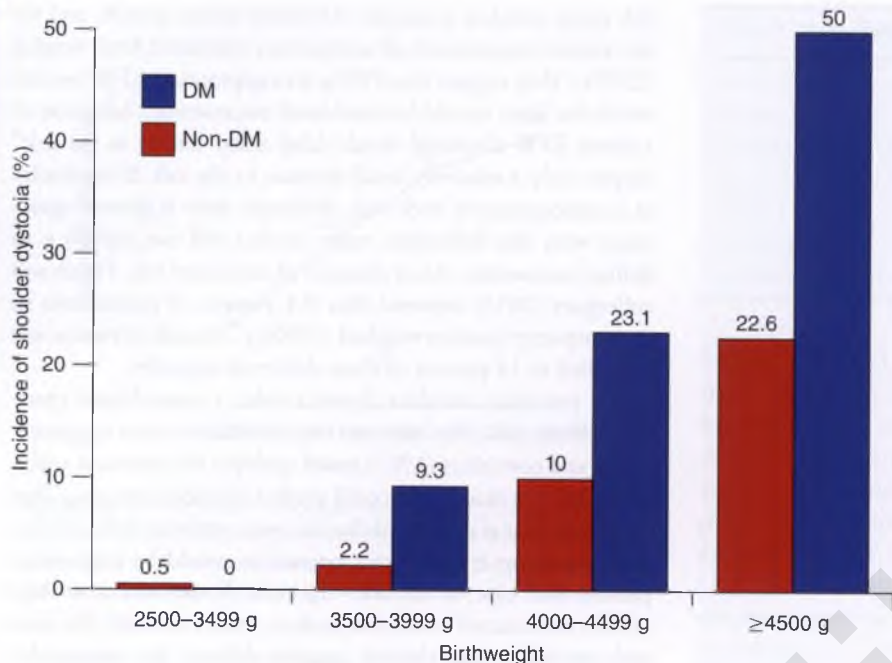


FIGURE 24-3 Risks for shoulder dystocia according to the years of delivery. All values are significant. (Data from Øverland EA, Vatten LJ, Eskild A: Pregnancy week at delivery and the risk of shoulder dystocia: a population study of 2,014,956 deliveries, *BJOG* 2014 Jan;121(1):34–41).

In a study comparing shoulder dystocia rates in diabetic versus nondiabetic women, the incidence rose as birthweight increased for both nondiabetic and diabetic gravidas (Fig. 24-3) (Acker, 1985). In nondiabetic women, the shoulder dystocia incidence was 10 percent in those delivering newborns weighing between 4000 and 4499 g, compared with a 22.6-percent rate for those with neonates weighing >4500 g. These frequencies more than doubled in diabetic women. Cordero and associates (2015) reported a 28-percent rate of shoulder dystocia in macrosomic fetuses of diabetic mothers compared with a 15-percent rate in those born to nondiabetic gravidas.

Of preventive steps for diabetic gravidas, Conway and Langer (1998) noted that elective cesarean delivery for an EFW ≥ 4250 g and elective induction for an EFW ≥ 90 th percentile but < 4250 g significantly decreased the rate of shoulder dystocia—2.4 versus 1.1 percent. Pedersen (1954) described a trend of lower birthweights in neonates of diabetic women given long-term insulin therapy compared with those who had short-term therapy. Coustan and Imarah (1984) also found that insulin therapy decreased the incidences of macrosomia, operative delivery, and birth trauma in gestational diabetic gravidas. Berne and associates (1985) confirmed these observations and proposed the use of prophylactic insulin for this purpose. Somewhat related, Casey and colleagues (2015), however, reported that glyburide added to dietetic therapy did not lower the rate of shoulder dystocia in cases of mild gestational diabetes.

Postterm Pregnancy

Gestations lasting longer than 42 weeks have an associated increased risk for shoulder dystocia (Fig. 24-4) (Eden, 1987; Johnson, 1987). Specifically, nearly half of shoulder dystocia cases are associated with a pregnancy extending beyond 41 weeks' gestation (Hopwood, 1982; Johnstone, 1979). Spellacy and

associates (1985) suggested that postterm pregnancy is a risk factor for macrosomia, which of course is a comorbid risk for shoulder dystocia. Because postterm pregnancies are a minority, the absolute risk for shoulder dystocia is low. Indeed, Acker (1985) and Øverland (2014) and their colleagues found that the overwhelming majority of postterm pregnancies were not associated with shoulder dystocia.

Prior Shoulder Dystocia

The recurrence rate for a woman with previous shoulder dystocia is much higher than for the general population. Estimates as high as 10 percent have been described (Bingham, 2010; Moore, 2008). Ouzounian and coworkers (2012) reported a recurrence risk of 3.7 percent compared with a baseline risk of 0.7 percent.

Other Factors

Male fetuses are more likely to be associated with shoulder dystocia. In several studies, male fetuses composed approximately 70 percent of cases (Hassan, 1988; Parks, 1978; Spellacy, 1985). Advanced maternal age as a risk factor for shoulder dystocia depends on the coexistence of diabetes mellitus and obesity (Langer, 1991; Øverland, 2014). Excessive maternal weight gain during pregnancy has also been linked with macrosomia and shoulder dystocia (Boyd, 1983; Lewis, 1998).

■ Intrapartum Risk Factors

Rapid or Prolonged Second-Stage Labor

Shoulder dystocia is more common with extremely curtailed or prolonged second-stage labor (American College of Obstetricians and Gynecologists, 2014). That said, at least in

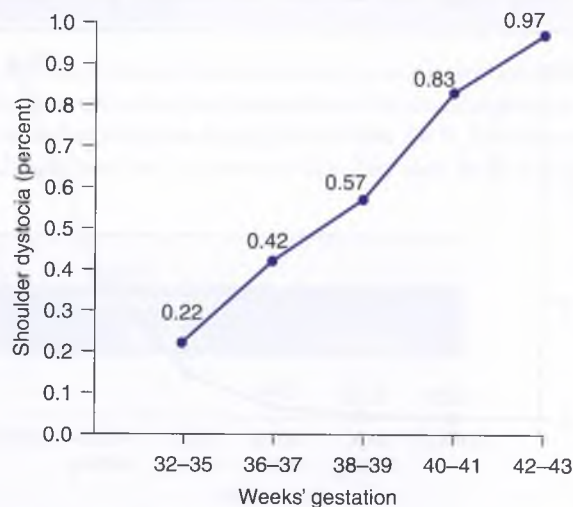


FIGURE 24-4 Risks for shoulder dystocia according to gestation age. (Data from Øverland EA, Vatten LJ, Eskild A: Pregnancy week at delivery and the risk of shoulder dystocia: a population study of 2,014,956 deliveries, *BJOG* 2014 Jan;121(1):34–41).

2016, the definition of a prolonged second stage of labor is undergoing debate and redefinition. In many older studies of shoulder dystocia, prolonged second-stage labor was defined to be >2 hours in a nullipara and >1 hour in multiparous women. Using this definition, a prolonged second stage was associated with an increased risk of shoulder dystocia (Acker, 1985; Gross, 1987a,b). In one study, Benedetti and Gabbe (1978) found that the overall incidence of shoulder dystocia was 0.37 percent of 8890 vertex deliveries. With a prolonged second stage and midpelvic delivery, the incidence of shoulder dystocia was 4.6 percent. Moreover, if birthweight exceeded 4000 g, if the second stage was prolonged, and if midpelvic delivery was performed, the incidence of shoulder dystocia rose to 23 percent. Acker and coworkers (1985) found that 22 percent of women with a shoulder dystocia had protraction disorders, and 8 percent had arrest disorders. That said, 70 percent of women with shoulder dystocia had a normal labor pattern.

Oxytocin Administration

The association of oxytocin administration may be a secondary factor in the development of shoulder dystocia, but no evidence supports a direct causal link. The apparent connection between shoulder dystocia and oxytocin administration may be related to factors such as labor disorders or fetal macrosomia.

Operative Vaginal Delivery

Assisted delivery with either forceps or vacuum extractor is associated with an increased risk for shoulder dystocia. Broekhuizen and associates (1987) noted a 3-percent incidence of shoulder dystocia in women delivered by vacuum extraction compared with 0.3 percent in a group delivered by forceps. This was partially explained by the vacuum group having a higher rate of midpelvic delivery, a higher mean birthweight, and an increased frequency of birthweights >4000 g. In a prospective randomized trial comparing forceps and vacuum extraction with 637 women, Bofill and colleagues (1997) showed higher shoulder dystocia rates with the use of vacuum extraction versus forceps delivery—4.7 versus 1.9 percent. Pelvic station and rotational maneuvers were not associated with an increased risk. But, Tempest and workers (2013) found shoulder dystocia incidences of 3.7 and 6.3 percent with rotational delivery by Kielland forceps and vacuum extractor, respectively. In a large California study, Nesbitt and colleagues (1998) examined all births >3500 g and calculated that operative vaginal delivery in diabetic and nondiabetic women was associated with a 35- to 45-percent rise in shoulder dystocia risk.

PREDICTION AND PREVENTION

Unfortunately, shoulder dystocia is most often unpredictable and unpreventable. Various sonographic parameters that include biparietal diameter, abdominal area, femur length-to-abdominal circumference ratio, and EFW have been studied as predictors of birthweight and thus neonatal complications. Seigworth (1966) reported that the chest circumference was the same or greater than head circumference in 33 of 41 cases (80 percent) of shoulder dystocia. Kitzmiller and associates (1987) measured fetal shoulder width by computed tomography in diabetic women. A shoulder measurement exceeding

14 cm predicted a birthweight >4200 g. The sensitivity was 100 percent, specificity was 87 percent, positive-predictive value was 78 percent, and negative-predictive value was 100 percent.

Bochner and colleagues (1987) evaluated the utility of sonographic measurement of abdominal circumference at 30 to 33 weeks in gestational diabetics to predict macrosomia. An abdominal circumference \leq 90th percentile for gestational age accurately predicted the *absence* of macrosomia, dystocia, and birth trauma. Fetal abdominal circumference >90th percentile between 30 and 33 weeks was not an accurate predictor of macrosomia at term but was associated with a rise in labor dystocia, shoulder dystocia, and birth trauma rates.

Because of the inaccuracies of these studies and the low positive-predictive values for shoulder dystocia, the evolution in obstetric thinking regarding the preventability of shoulder dystocia has been considerable. Although several risk factors are clearly associated with this complication, identification of individual instances before the fact has proved to be impossible. The American College of Obstetricians and Gynecologists (2015b) reviewed available studies and concluded that:

1. Most cases of shoulder dystocia cannot be accurately predicted or prevented.
2. Elective induction of labor or elective cesarean delivery for all women suspected of having a macrosomic fetus is not appropriate.
3. Planned cesarean delivery may be considered for the nondiabetic woman with a fetus whose estimated fetal weight is >5000 g or for the diabetic woman whose fetus is estimated to weigh >4500 g.

SHOULDER DYSTOCIA MANAGEMENT

Proper management of shoulder dystocia requires prior consideration of risk factors, a well-conceived plan of action, and rapid execution. [Table 24-4](#) summarizes one protocol. The

TABLE 24-4. Management of Shoulder Dystocia

Call for help
Initial gentle traction
Suprapubic pressure
Evaluate for episiotomy^a
McRoberts maneuver
Rotation of anterior shoulder
Woods screw maneuver
Posterior arm extraction
Rubin maneuver
Clavicular fracture
"All fours" maneuver

Other Methods to Consider:

Posterior axilla sling traction
Zavanelli maneuver
Abdominal rescue
Symphysiotomy^a
Fundal pressure to augment certain methods^a

^aSee text for discussion of indications.

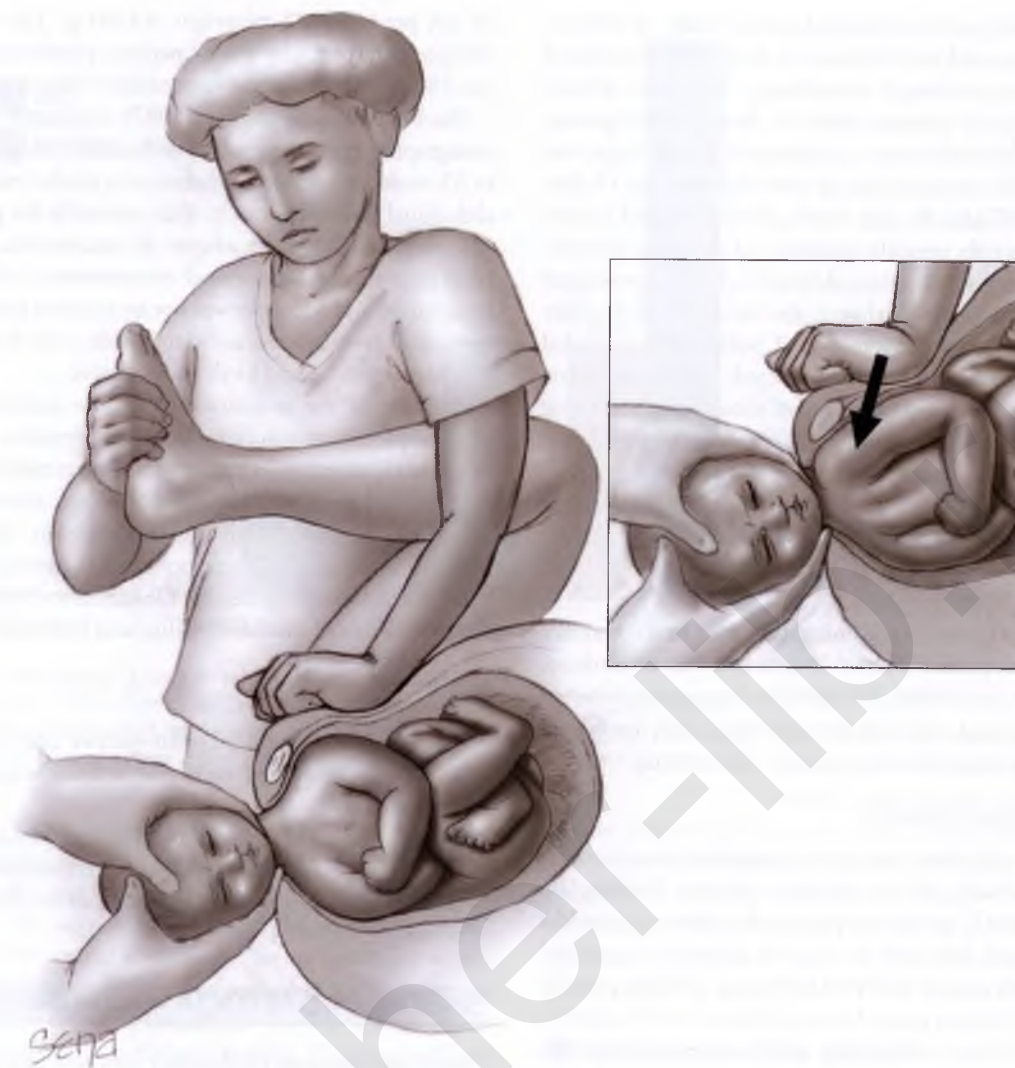

FIGURE 24-5 Inset: suprapubic pressure. An assistant applies oblique suprapubic pressure to free the anterior shoulder. The force should be directed at approximately a 45-degree angle off of vertical to move the fetal shoulder not only down, but also laterally toward the fetal chest. Main image: McRoberts maneuver. The legs are removed from the stirrups and sharply flexed upon the abdomen. Suprapubic pressure may be applied concurrently. (Reproduced with permission from Cunningham FG, Leveno KJ, Bloom SL, et al (eds): *Vaginal delivery*. In *Williams Obstetrics*, 24th ed. New York, McGraw-Hill Education, 2014.)

basic clinical tenets are prompt recognition, expeditiously performed maneuvers to deliver the impacted shoulders, and avoidance of excessive forces to the fetus and mother. Because shoulder dystocia is an uncommon and unpredictable event, prospective clinical trials to determine optimal methods of management have not been and are not likely to be conducted. Nocon and coworkers (1993), in an analysis of risk of obstetric maneuvers for shoulder dystocia, concluded that no single delivery method for shoulder dystocia was superior to another with respect to neonatal injury. They further concluded that no protocol could serve to substitute for clinical judgment and that any reasonable methods were appropriate. This is emphasized by the American College of Obstetricians and Gynecologists (2015b) in that no “one maneuver” in shoulder dystocia management has been proved superior to another in preventing fetal injury.

■ Initial Management

Whenever shoulder dystocia is suspected, swift action is essential. Initial steps include a call for assistance from other obstetric, anesthesia, and pediatric personnel. Some institutions have checklists or team-centered protocols (Grobman, 2014; Lerner, 2011). This call is followed by gentle downward traction in conjunction with maternal expulsive efforts. Swartz (1960) recommended rapidly examining the fetus as far within the birth canal as the hand could be inserted and avoiding excessive angulation of the fetal neck. Morris (1955) studied the brachial plexus of neonates at autopsy. He concluded that traction is least likely to injure the brachial plexus when the cervical and thoracic spine are in a straight line and that flexion, torsion, and jerking of the neck should be avoided. Using tactile sensing gloves to measure traction forces, Gonik (1989) and Sorab (1988) and their coworkers studied clinician-applied forces with

varying degrees of difficulty encountered during delivery. The peak force significantly increased from routine delivery (<60 newtons), to difficult delivery (60 to 90 newtons) and delivery complicated by shoulder dystocia (>90 newtons). These investigators cautioned clinicians to be alert to the degree of traction/force applied.

■ Episiotomy

Performance of an episiotomy is controversial because shoulder dystocia is not typically caused by soft tissue obstruction. An episiotomy may be cut or extended to provide more room for manipulations posteriorly and to avoid other birth canal lacerations. In the event that direct rotational maneuvers or delivery of the posterior arm is attempted, a proctoepisiotomy may be useful to provide more space for manipulation (American College of Obstetricians and Gynecologists, 2015b). At least two studies showed no improved outcomes for women with and without an episiotomy (Gurewitsch, 2004; Paris, 2011). A recent systematic review also found no evidence that episiotomy is advantageous for shoulder dystocia management (Sagi-Dain, 2015).

■ Suprapubic Pressure

This maneuver is simple and safe to perform as shown in Figure 24-5. Many authors suggest suprapubic pressure as an initial measure to overcome shoulder dystocia (Benedetti, 1989; O'Leary, 1990; Resnik, 1980). Although Lee (1987) reported brachial plexus injuries with suprapubic pressure, Gherman and associates (1998a) found no increased incidence of such injury when suprapubic pressure was compared with other maneuvers.

■ McRoberts Maneuver

Many contemporary reviews promote the McRoberts maneuver as a primary technique to resolve shoulder dystocia. Depicted in Figure 24-5, this maneuver is named for William A. McRoberts, who popularized its use at the University of Texas at Houston. As described originally by Gonik and coworkers (1983), it involves exaggerated flexion of the legs, similar to a knee-chest position. This results in straightening of the sacrum relative to the lumbar spine and consequent rotation of the symphysis pubis to decrease the angle of inclination (Gherman, 2000). This maneuver does not change the dimensions of the true pelvis, but rather rotates the symphysis superiorly, thus freeing the impacted anterior shoulder without fetal manipulation. In a laboratory model, the McRoberts maneuver decreased shoulder extraction forces, degree of brachial plexus stretch, and the rate of clavicular fracture (Gonik, 1989).

In a series of 250 cases of shoulder dystocia, the McRoberts maneuver alone successfully alleviated 42 percent of the cases (Gherman, 1997). The combination of the McRoberts maneuver, suprapubic pressure, and/or proctoepisiotomy relieved 54 percent of all shoulder dystocia cases. The need for additional maneuvers was associated with greater birthweight,

longer active-labor phases, and longer second stages. The group requiring additional procedures to relieve shoulder dystocia also had a trend toward an increased incidence of postpartum hemorrhage and brachial plexus injury.

■ Woods Maneuver

In 1943, Woods described a technique to release the impacted shoulder “based on a well-known law of physics applicable to the screw. A screw is a continuous spiral incline plane, which when engaged in suitable threads, is used where we wish to create the greatest resistance to its release by a direct pull. It follows, then, that a direct pull is the most difficult way to release a screw.” He further described the anterior and posterior fetal shoulder passing through three threads, the symphysis pubis, the sacral promontory, and the coccyx. The modified Woods maneuver is shown in Figure 24-6. He recommended “a downward thrust . . . with the left hand on the buttocks of the baby. At the same time, two fingers of the right hand, on the anterior aspect of the posterior shoulder, make gentle clockwise pressure upward around the circumference of the arc to, and past, twelve o'clock.” This maneuver should deliver the posterior shoulder. Woods stated that the operator, not the assistant, should apply the pressure on the fetal buttocks from above to synchronize the pressure of the two hands.

■ Posterior Arm Extraction

If delivery of the fetus is unsuccessful at this stage, Hernandez and Wendel (1990) recommend induction of general anesthesia for subsequent maneuvers unless adequate regional analgesia is already in effect. For posterior arm extraction, shown in

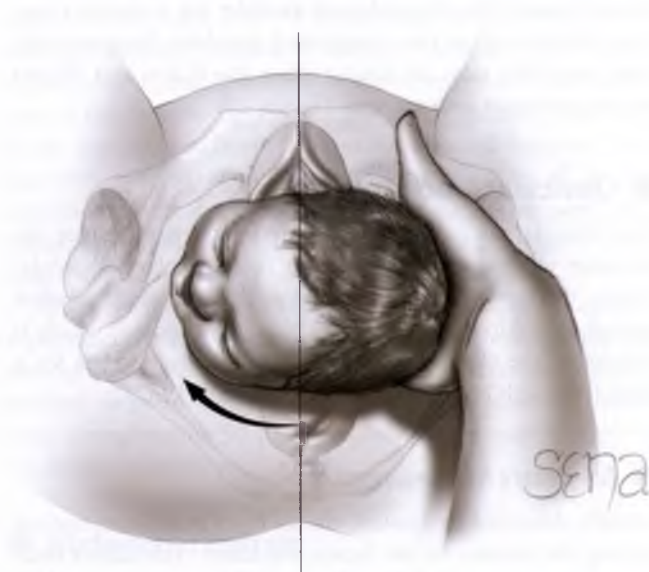

FIGURE 24-6 Woods maneuver. The hand is placed behind the posterior shoulder of the fetus. The shoulder is then rotated progressively 180 degrees in a corkscrew manner so that the impacted anterior one is released. (Reproduced with permission from Cunningham FG, Leveno KJ, Bloom SL, et al (eds): *Vaginal delivery*. In *Williams Obstetrics*, 24th ed. New York, McGraw-Hill Education, 2014.)

Figure 24-7, the hand is gently inserted along the curvature of the sacrum. If the fetal back is toward the maternal right, then the operator's right hand is used. If the back of the fetus is toward the maternal left, then the left hand is used. The arm is splinted and swept across the chest, keeping the arm flexed at the elbow. To flex the elbow, the fingers of the operator can follow along the ventral surface of the humerus to the antecubital fossa. With the index finger, pressure is exerted into the fossa in a maneuver similar to the Pinard maneuver in breech extraction (Fig. 21-7, p. 341). As the arm flexes, the index finger grasps the forearm of the fetus and gently sweeps it across the fetal chest and face and then out of the vagina.

In 20 percent of cases in older series, it was necessary to deliberately fracture the humerus to accomplish this maneuver. It is then usually possible to complete delivery of the anterior shoulder with traction and pressure. When the baby is excessively large, it may be necessary to rotate the extracted posterior arm 180 degrees so that the released shoulder lies anteriorly. The above maneuver is then repeated on the newly seated posterior arm and shoulder. Some studies, but certainly not all, have indicated a higher neonatal injury rate with delivery of the posterior shoulder (Grobman, 2013; Hoffman, 2011; Spain, 2015).

■ Rubin Maneuver

In 1964, Rubin described two maneuvers to relieve shoulder dystocia. The first uses transabdominal rocking of the fetal shoulders to disimpact the anterior shoulder and to permit the shoulders to find a more favorable diameter through the pelvis for descent. The second maneuver is performed vaginally and uses adduction of the most accessible shoulder to reduce the circumference and transverse diameter of the shoulders (Fig. 24-8). Measuring shoulder dimensions of newborns, Rubin showed that the adducted shoulder has a smaller transverse diameter than the straightened shoulder. Pragmatically, fetal morbidity rates are similar when the Rubin and Woods screw maneuvers are compared (Spain, 2015).

■ Clavicular Fracture

The fetal clavicle can be deliberately fractured to reduce the diameter of the fetal shoulders. To avoid subclavian vascular injury, the clavicle is broken most safely by upward pressure against its midportion (Rubin, 1964). Cleidotomy, which is cutting of the clavicle with scissors, is usually reserved for a dead fetus with impacted shoulders (McCall, 1962).

■ All-Fours Maneuver

Initially described by Gaskin, the all-fours maneuver involves placing the woman on her hands and knees. This allows rotation of the maternal pelvis and release of the anterior shoulder beneath the symphysis. Bruner and colleagues (1998) described its use in 82 cases of shoulder dystocia, with success in 83 percent using this maneuver only. The average time required to assume the position and effect delivery was 2 to 3 minutes. This may be more difficult in women with regional analgesia depending on the level of motor impairment.

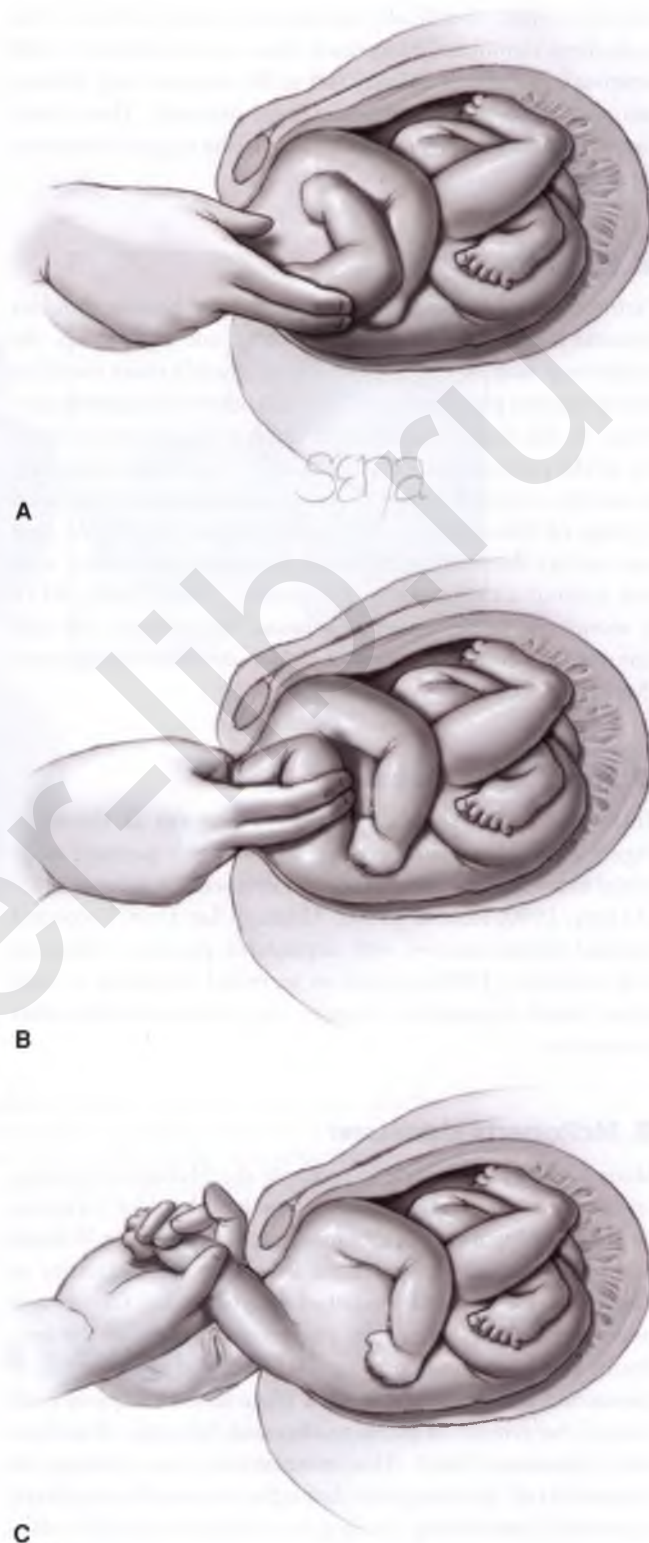


FIGURE 24-7 Delivery of the posterior shoulder for relief of shoulder dystocia. **A.** The operator's hand is introduced into the vagina along the fetal posterior humerus. **B.** The arm is splinted and swept across the chest, keeping the arm flexed at the elbow. **C.** The fetal hand is grasped and the arm extended along the side of the face. The posterior arm is delivered from the vagina. (Reproduced with permission from Cunningham FG, Leveno KJ, Bloom SL, et al (eds): *Vaginal delivery*. In *Williams Obstetrics*, 24th ed. New York, McGraw-Hill Education, 2014.)

were in the anterior arms. More experience with this method is needed before it can be widely recommended.

■ Fundal Pressure

It is generally thought that fundal pressure may further worsen shoulder impaction and may even cause uterine rupture (American College of Obstetricians and Gynecologists, 2015b). Schwartz and Dixon (1958) reported a significantly higher neonatal death rate with traction and fundal pressure compared with posterior arm extraction. Gross and colleagues (1987b) found that when used to treat shoulder dystocia, fundal pressure resulted in a 77-percent complication rate and a high incidence of orthopedic and neurologic damage. Phelan and coworkers (1997) performed a case-control study comparing 59 infants with documented Erb palsy whose birth was complicated by shoulder dystocia with 59 infants with shoulder dystocia and no injury. The incidence of fundal pressure use was significantly higher in the injury group compared with the control group (32 versus 2 percent). Perhaps the only place for fundal pressure is in concert with either external (suprapubic pressure) or internal rotational procedures such as the Woods or Rubin maneuvers.

■ Cephalic Replacement—Zavanelli Maneuver

With this maneuver, the fetal head is returned to its prior intravaginal location, and the fetus is then extracted by cesarean delivery. Sandberg (1985) attributed the first case performed in 1978 to Dr. William Zavanelli. Later, he published the results of 12 years' experience with the Zavanelli maneuver with 103 total cases—92 cephalic and 11 breech presentations (Sandberg, 1999). Cephalic replacement was successful in 84 of 92 cephalic-presenting fetuses (91 percent) and podalic replacement was successful in all 11 breech cases. Eight attempts that were unsuccessful ultimately delivered vaginally. Six fetuses delivered after symphysiotomy, and two fetuses after manipulation of the shoulder through a hysterotomy incision, described in the next section. In all, there were 14 perinatal deaths. Two survivors suffered significant neurologic sequelae, all in the cephalic replacement group. Uterine rupture (three cases) and lacerations of the lower uterine segment/upper vagina (four cases) were the most serious maternal complications.

O'Leary and Gunn (1985) reported four cases of cephalic replacement. They recommended continuous fetal monitoring and subcutaneous terbutaline for uterine relaxation. Another method to provide more rapid uterine relaxation is intravenous nitroglycerine 50 µg, which can be repeated if there is no initial response.

■ Abdominal Rescue

O'Leary and Cuva (1992) described "abdominal rescue" after failed cephalic replacement. This maneuver begins with a low-transverse hysterotomy and is followed by manual depression of the fetal shoulder to a point below the symphysis pubis. This is then followed by vaginal delivery. Abdominal rescue has also been described in the context of breech delivery with entrapment of the aftercoming fetal head (Iffy, 1986).

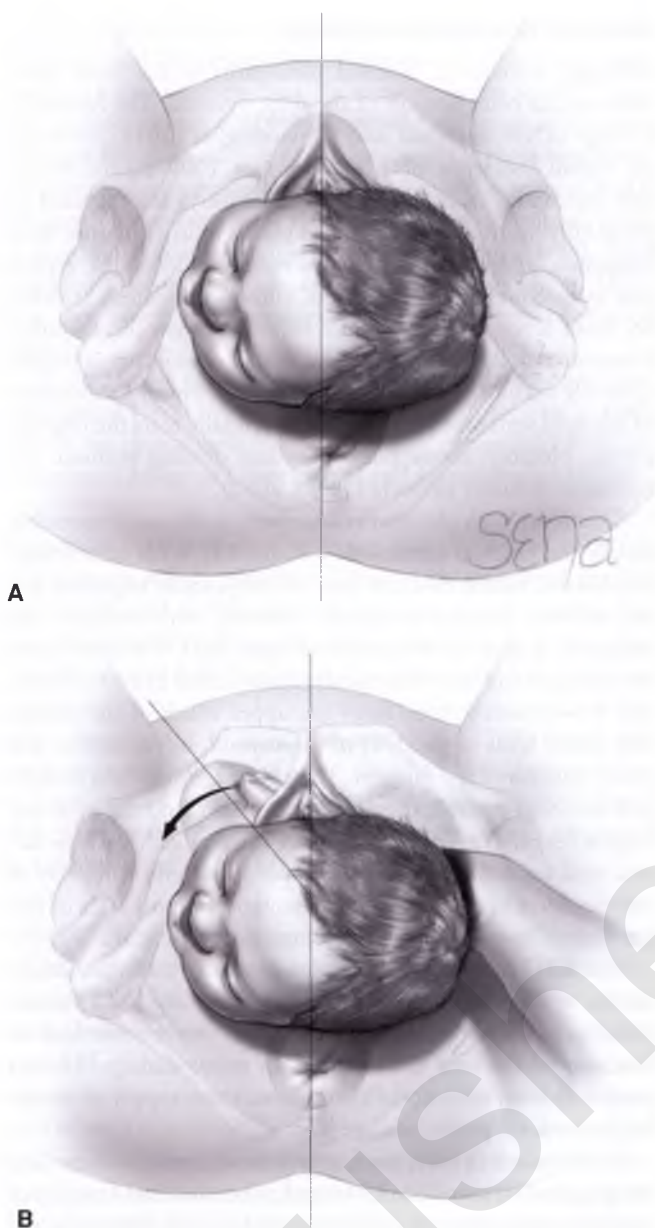


FIGURE 24-8 The second Rubin maneuver. **A.** The shoulder-to-shoulder diameter is aligned vertically. **B.** The more easily accessible fetal shoulder (the anterior is shown here) is pushed toward the anterior chest wall of the fetus (arrow). Most often, this results in abduction of both shoulders, which reduces the shoulder-to-shoulder diameter and frees the impacted anterior shoulder. (Reproduced with permission from Cunningham FG, Leveno KJ, Bloom SL, et al (eds): Vaginal delivery. In Williams Obstetrics, 24th ed. New York, McGraw-Hill Education, 2014.)

■ Posterior Axilla Sling Traction

With this method, a sling fashioned from a suction catheter or firm urinary catheter is threaded through the crease of the posterior axilla. Outward traction applied to this tube loop can rotate and deliver the posterior shoulder (Cluver, 2009; Hofmeyr, 2009). In one review, Cluver and Hofmeyr (2015) examined 19 cases in which the posterior axilla sling traction (PAST) method was used and described as successful in 18 cases. There were three posterior humeral fractures. The five cases of Erb palsy

■ Symphysiotomy

Transcutaneous symphysiotomy has been described as a technique to overcome moderate cephalopelvic disproportion and avoid cesarean delivery in developing countries (Hofmeyr, 2012). In experienced hands, and with a urethral catheter in place, it can be performed in less than 5 minutes using a scalpel (Hartfield, 1973, 1986). Using local analgesia, this operation surgically incises the mons pubis and then divides the symphyseal cartilage and much of its ligamentous support. This can widen the symphysis pubis up to 2.5 cm (Basak, 2011). Lack of operator training and potentially serious maternal pelvic or urinary tract injury explain its rare use in the United States.

Although this technique is described primarily to overcome cephalopelvic disproportion, some authors have suggested its use for relieving shoulder dystocia (Hartfield, 1986; Sandberg, 1985; Schramm, 1983). Goodwin and coworkers (1997) described three women undergoing symphysiotomy for shoulder dystocia unresponsive to standard maneuvers including cephalic replacement. Two of these had significant lower urinary tract complications after emergency symphysiotomy that required blood transfusions. Although shoulder dystocia was promptly relieved in each case, all three neonates suffered severe anoxic injury and later died. Therefore, if symphysiotomy is to be attempted, it should be initiated within 5 to 6 minutes of fetal head delivery because the procedure will take at least 2 minutes from the decision. Because of the significant associated maternal morbidity, it should be undertaken only after all standard maneuvers have failed as a last attempt to preserve fetal life.

COMPLICATIONS

■ Neonatal Complications

Although morbidity accrues to both, shoulder dystocia generally poses greater risks for the fetus than the mother. Of neonatal consequences, asphyxia, brachial plexus injury, bone fracture, and death are especially dire. The relative frequency of some of these injuries is shown in Table 24-5. Importantly, not all cases of neonatal brachial plexus injury are associated with shoulder dystocia. Chang and associates (2016) studied 387 infants with *persistent* brachial plexopathy. They found that 8 percent underwent cesarean delivery and only half of the remaining infants had associated shoulder dystocia during vaginal delivery.

TABLE 24-5. Percentage of 101 Neonatal Injuries in 2018 Cases of Shoulder Dystocia

Injury	Percent
Erb palsy	59
Clavicular fracture	39
Hypoxic-ischemic encephalopathy	6
Klumpke palsy	4
Humeral fracture	2

Data from Consortium on Safe Labor (Hoffman, 2011).

Neonatal Brachial Plexus Palsy

Although infrequent, brachial plexopathy is the most common serious complication of shoulder dystocia. The American College of Obstetricians and Gynecologists (2014) estimates an overall incidence of 1.5 events per 1000 births. Favorable outcomes, including complete recovery, are expected in 50 to 80 percent of cases. Brachial plexus injury can arise from impaction of the anterior or posterior shoulder. The typical case is anterior shoulder dystocia, clinically apparent at delivery from arrest of the shoulder behind the symphysis pubis. Posterior shoulder dystocia at the sacral promontory is usually clinically occult. In either case, ongoing downward movement of the axial vertebrae stretches and potentially tears the brachial plexus. Notably, severe plexopathy can develop without risk factors or shoulder dystocia (Torki, 2012).

The injury with plexopathy is actually to the nerve roots that supply the brachial plexus—C5–8 and T1. With hemorrhage and edema, axonal function may be temporarily impaired, but the recovery chances are good. However, with avulsion, the prognosis is poor. In 90 percent of cases, the C5–6 nerve roots are damaged and cause Erb paralysis, also called Erb-Duchenne. The C5–6 roots join to form the upper trunk of the plexus, and injury leads to paralysis of the deltoid, infraspinatus, and flexor muscles of the forearm. The affected arm is held straight and internally rotated, the elbow is extended, and the wrist and fingers flexed. Finger function usually is retained. Because lateral head traction is frequently employed to effect delivery of the shoulders in normal vertex presentations, most cases of Erb paralysis follow deliveries that do not appear difficult.

The C8-T1 roots supply the lower plexus, and their injury results in Klumpke paralysis, which renders the hand flaccid. Total involvement of all brachial plexus nerve roots lead to flaccidity of the arm and hand. With severe damage, Horner syndrome from interrupted sympathetic nerve supply to the eye leads to miosis, ptosis, and anhidrosis.

As discussed, in most cases, axonal death does not occur, and the prognosis is good. Lindqvist and associates (2012) reported complete recovery in 86 percent of children with C5–6 trauma, which was the most common injury, and in 38 percent of those with C5–7 damage. However, those with global C5-T1 injuries always had permanent disability. Surgical exploration and possible repair may improve function if paralysis persists (Malessy, 2009).

MacKenzie and associates (2007) reviewed 514 cases of shoulder dystocia and found that 11 percent were associated with serious neonatal adverse outcomes. Brachial plexus injury was diagnosed in 8 percent, and 2 percent suffered a clavicular, humeral, or rib fracture. Almost 7 percent showed evidence of acidosis at delivery, and 1.5 percent required cardiac resuscitation or developed hypoxic ischemic encephalopathy. Mehta and colleagues (2007) found a similar number of injuries in a study of 205 shoulder dystocia cases, in which 17 percent had injury. Again, most involved the brachial plexus. Hoffman and coworkers (2011) studied more than 132,000 women delivered vaginally and reported that 1.2 percent had a shoulder dystocia. Of these, 5.2 percent incurred a neonatal injury.

In their review of the literature, Sandmire and O'Hallion (1988) calculated an 11.8-percent rate of brachial plexus

palsy, 7.9-percent rate of stillbirth, 4.3-percent rate of severe asphyxia, and 2.9-percent rate of meconium aspiration associated with shoulder dystocia. In a more recent study, Chauhan and coworkers (2014b) described 1177 cases of shoulder dystocia for an incidence of 2.5 percent. Of these newborns, 11 percent had a brachial plexus injury, and 4 percent had a fracture. These same investigators reviewed 63 studies comprising more than 17 million births (Chauhan, 2014a). They reported a declining incidence of brachial plexus injury. However, permanent palsy persisted in 10 to 18 percent of affected infants.

A discussion of the pathophysiology, causation, and biomechanical forces involved in brachial plexus injuries is available in the monograph *Neonatal Brachial Plexus Palsy* from the American College of Obstetricians and Gynecologists (2014).

Prognosis. The timing of recovery and the degree to which it occurs are highly variable. Curran (1981) reported that 80 percent of cases of Erb palsy recovered by 3 to 6 months, but only 40 percent of Klumpke palsies recovered by 1 year. The combination of Erb-Duchenne-Klumpke palsy had the worst prognosis for recovery. In a Swedish study of 48 cases of brachial plexus palsy, Sjoberg and coworkers (1988) found that most recovered within the first 6 months and that recovery was achieved by 18 months. Nocon and colleagues (1993) found that 96 percent of 28 cases of brachial plexus injuries diagnosed at birth resolved within 6 months after delivery.

Other Causes. Importantly, not all brachial plexus injuries are associated with shoulder dystocia or with excessive lateral neck traction (Sandmire, 2000). In a review of 1611 cases of brachial plexus injuries, Gilbert and colleagues (1999) found that only half of the injuries were associated with shoulder dystocia. Similarly, Jennett and associates (1992) found that only 43 percent of such injuries were associated with shoulder dystocia. In cases of Erb palsy developing without identified shoulder dystocia, the neonates tend to be smaller, and injuries had a higher rate of persistence (Gherman, 1998c). Graham and coworkers (1997) showed that cases of Erb palsy unrelated to shoulder dystocia have a higher rate of persistence at 1 year—41 versus 9 percent, take longer to resolve—6.4 versus 2.6 months, and are more likely to have a second stage of labor <15 min duration—59 versus 22 percent.

As discussed, brachial plexus injury without shoulder dystocia has been reported to occur in the posterior arm. In fact, when shoulder dystocia is absent, the injury affects the posterior arm in 68 percent of cases (Gherman, 1998c). A posterior arm brachial plexus injury with an antecedent shoulder dystocia, or any brachial plexus injury with an atraumatic cesarean delivery, strongly suggests an in utero mechanism (Kolderup, 1997; Rouse, 1996). Gherman and colleagues (1997) described six brachial palsy injuries associated with atraumatic cesarean delivery that exhibited persistent nerve injury at 1 year.

Peleg and coworkers (1997) reviewed 51 cases of Erb palsy and found no perinatal risk factors in nearly a third. Ouzounian and associates (1998) reported 63 cases of permanent Erb palsy. Although shoulder dystocia was present in 94 percent of the cases, most lacked other maternal risk factors. Specifically,

89 percent of gravidas were nondiabetic; 76 percent were nonobese; 91 percent had normal labor; and only 21 percent had a midpelvic operative delivery.

Fractures

As shown in Table 24-5, clavicular fractures are common with shoulder dystocia, and reported rates reach up to 14 percent (Dajani, 2014). However, these fractures are common in all newborns and identified in 0.5 to 2.0 percent (McBride, 1998; Rouse, 1996). As seen with brachial plexus injury, a significant number of these fractures are unrelated to typical risk factors for birth trauma (Peleg, 1997). Investigators further observed that 11 percent of newborns with clavicle fractures had a concomitant brachial plexus injury.

Hypoxic-Ischemic Encephalopathy

Birth asphyxia is the most feared complication of shoulder dystocia. Following delivery of the fetal head, the umbilical cord is compressed in the birth canal, and the neonate is unable to spontaneously breathe. Wood and coworkers (1973) demonstrated a decrease in pH of 0.04 units per minute following delivery of the fetal head. Boyd and associates (1983) reported an incidence of severe birth asphyxia of 14 events per 1000 spontaneous macrosomic deliveries, and 143 events per 1000 macrosomic deliveries complicated by shoulder dystocia. In a case-control study of term newborns with early neonatal seizures, Patterson and associates (1989) found shoulder dystocia to be strongly associated with the development of early neonatal seizures. Importantly, no particular maneuver is more likely to be associated with neonatal depression (Spain, 2015). Last, from their review, Dajani and Magann (2014) cited a fetal death rate with shoulder dystocia of 0.4 percent.

■ Maternal Complications

Postpartum hemorrhage is the main maternal risk from shoulder dystocia (Jangö, 2012; Rahman, 2009). It stems usually from atony but also from lower genital tract lacerations. Benedetti and Gabbe (1978) reported an estimated blood loss >1000 mL in 68 percent of cases of shoulder dystocia with prolonged second-stage labor. In addition, Hernandez and Wendel (1990) cite infection, bladder atony, and uterine rupture as shoulder dystocia complications. In a study of 98 cases of shoulder dystocia, El Madany and coworkers (1991) found a 19-percent incidence of vaginal tears requiring repair, a 14-percent incidence of postpartum hemorrhage, and a 1-percent incidence of ruptured uterus. Goldaber and associates (1993) reviewed 390 cases of fourth-degree perineal tears at Parkland Memorial Hospital. They reported that shoulder dystocia was the only intrapartum characteristic that occurred more frequently in these women.

There are several less common maternal injuries. Gherman and colleagues (1998b) reported a case of symphyseal separation and transient femoral neuropathy after use of the McRoberts maneuver. Although symptoms resolved rather rapidly after delivery, this reinforces the need to avoid overly aggressive hyperflexion and abduction of the maternal thighs onto the abdomen.

TABLE 24-6. Medical Record Documentation of Shoulder Dystocia**Delivery Note**

Spontaneous or operative delivery
 Indication for forceps or vacuum
 Technique of delivery
 Fetal station
 Fetal position

Shoulder Dystocia Maneuvers

Estimation of traction forces
 Specific maneuvers employed
 Time interval from delivery of head to completion of delivery

Neonatal Condition

Estimated fetal weight
 Actual fetal weight
 Apgar scores
 Umbilical cord gases
 Moro reflex
 Evidence of brachial plexus injury
 Evidence of fracture, clavicle or humerus

CHART DOCUMENTATION

In the event of shoulder dystocia, a detailed written or dictated note should describe events, maneuvers, estimation of traction forces, timing of events, and neonatal evaluation (Benedetti, 1989; Hernandez, 1990; Stitely, 2014). Acker (1991) proposed a “shoulder dystocia intervention form,” and Table 24-6 summarizes pertinent information to document in the medical record. Best estimates of “time on the perineum” are obtained if an event clock is activated, or if a timekeeper is designated. Awareness of the shoulder dystocia duration should be integrated into maneuvers being performed. Full discussion of the events should be disclosed to the woman in a straightforward manner.

ROLE FOR SIMULATION

Because of its relative infrequency, its unpredictability, and the need for team member coordination, shoulder dystocia simulation and “drills” are ideal (Grobman, 2013). Such drills have been shown to improve documentation (van de Ven, 2016). This is discussed in detail in Chapter 6 (p. 85).

SUMMARY

Shoulder dystocia is a relatively common but unpredictable and catastrophic complication of obstetrics. Thus, all obstetricians should be well versed in its management. A “shoulder dystocia drill” should be taught to all personnel involved in the delivery of newborns. This practice should include obstetric and anesthesia residents and faculty, nurse midwives, and delivery nurses. One goal is to reduce the head-to-body delivery time.

This is balanced against the second goal, which is avoidance of fetal and maternal injury from aggressive manipulation. Most cases of shoulder dystocia are not preventable, and fetal injury cannot always be averted. It is generally conceded that although injuries are a relatively common outcome associated with shoulder dystocia, they may still occur despite use of appropriate standard obstetric maneuvers. Systematic application of several obstetric maneuvers will successfully relieve most shoulder dystocias. Importantly, no single maneuver has been shown to result in better outcomes or in less maternal and fetal morbidity. Finally, of the 10 to 15 percent of shoulder dystocia cases that are associated with brachial plexus injury, most will resolve spontaneously.

REFERENCES

- Acker DB: A shoulder dystocia intervention form. *Obstet Gynecol* 78:150, 1991
- Acker DB, Sachs BP, Friedman EA: Risk factors for shoulder dystocia. *Obstet Gynecol* 66:762, 1985
- American College of Obstetricians and Gynecologists: Fetal macrosomia. Practice Bulletin No. 22, November 2000, Reaffirmed 2015a
- American College of Obstetricians and Gynecologists: Neonatal brachial plexus palsy. Report of the American College of Obstetricians and Gynecologists Task Force on Neonatal Brachial Plexus Palsy. Executive Summary. *Obstet Gynecol* 123:902, 2014
- American College of Obstetricians and Gynecologists: Shoulder dystocia. Practice Bulletin No. 40. November 2002, Reaffirmed 2015b
- Avci ME, Sanlikan F, Celik M, et al: Effects of maternal obesity on antenatal, perinatal, and neonatal outcomes. *J Matern Fetal Neonatal Med* 28(17):2080, 2015
- Basak S, Kanungo S, Majhi C: Symphysiotomy: is it obsolete? *J Obstet Gynaecol Res* 37(7):770, 2011
- Beall MH, Spong C, McKay J, et al: Objective definition of shoulder dystocia: a prospective evaluation. *Am J Obstet Gynecol* 179:934, 1998
- Benedetti TJ: Added complications of shoulder dystocia. *Contemp Obstet Gynecol* 33:150, 1989
- Benedetti TJ, Gabbe SG: Shoulder dystocia. A complication of fetal macrosomia and prolonged second stage of labor with midpelvic delivery. *Obstet Gynecol* 52:526, 1978
- Berne C, Wibell L, Lindmark G: Ten-year experience of insulin treatment in gestational diabetes. *Acta Paediatr Scand Suppl* 320:85, 1985
- Bingham J, Chauhan SP: Recurrent shoulder dystocia: a review. *Obstet Gynecol Surv* 65(3):183, 2010
- Bochner CJ, Medearis AL, Williams J, et al: Early third-trimester ultrasound screening in gestational diabetes to determine the risk of macrosomia and labor dystocia at term. *Am J Obstet Gynecol* 157:703, 1987
- Bofill JA, Rust OA, Devidas M, et al: Shoulder dystocia and operative vaginal delivery. *J Matern Fetal Med* 6:220, 1997
- Boulvain M, Senat MV, Perrotin E, et al: Induction of labour versus expectant management of large-for-date fetuses: a randomized controlled trial. *Lancet* 385(9987):2600, 2015
- Boyd ME, Usher RH, McLean FH: Fetal macrosomia: prediction, risks, proposed management. *Obstet Gynecol* 61:715, 1983
- Broekhuizen FF, Washington JM, Johnson F, et al: Vacuum extraction versus forceps delivery: indications and complications, 1979 to 1984. *Obstet Gynecol* 69:338, 1987
- Bruner JP, Drummond SB, Merrnan AL, et al: All-fours maneuver for reducing shoulder dystocia during labor. *J Reprod Med* 43:439, 1998
- Casey BM, Duryea EL, Abbassi-Ghanavati M, et al: Glyburide in women with mild gestational diabetes: a randomized controlled trial. *Obstet Gynecol* 126(2):303, 2015
- Chang KW, Ankumah NE, Wilson TJ, et al: Persistence of neonatal brachial plexus palsy associated with maternally reported route of delivery: review of 387 cases. *Am J Perinatol* 33(8):765, 2016
- Chauhan SP, Blackwell SB, Ananth CV: Neonatal brachial plexus palsy: incidence, prevalence, and temporal trends. *Semin Perinatol* 38(4):210, 2014a
- Chauhan SP, Laye MR, Lutgendorf M, et al: A multicenter assessment of 1,177 cases of shoulder dystocia: lessons learned. *Am J Perinatol* 31(5):401, 2014b
- Cluver CA, Hofmeyr GJ: Posterior axilla sling traction: a technique for intractable shoulder dystocia. *Obstet Gynecol* 113 (2 Pt 2):486, 2009

- Cluver CA, Hofmeyr GJ: Posterior axilla sling traction for shoulder dystocia: case review and a new method of shoulder rotation with the sling. *Am J Obstet Gynecol* 212(6):784, 2015
- Conway DL, Langer O: Elective delivery of infants with macrosomia in diabetic women: reduced shoulder dystocia versus increased cesarean deliveries. *Am J Obstet Gynecol* 178:922, 1998
- Cordero L, Paetow P, Landon MB, et al: Neonatal outcomes of macrosomic infants of diabetic and non-diabetic mothers. *J Neonatal Perinatal Med* 8(2):105, 2015
- Coustan DR, Imarah J: Prophylactic insulin treatment of gestational diabetes reduces the incidence of macrosomia, operative delivery, and birth trauma. *Am J Obstet Gynecol* 150:836, 1984
- Crane JM, Murphy P, Burrage L, et al: Maternal and perinatal outcomes of extreme obesity in pregnancy. *J Obstet Gynaecol Can* 35(7):606, 2013
- Cunningham FG, Leveno KJ, Bloom SL, et al (eds): Vaginal delivery. In *Williams Obstetrics*, 24th ed. New York, McGraw-Hill Education, 2014
- Curran JS: Birth-associated injury. *Clin Perinatol* 8:111, 1981
- Dajani NK, Magann EF: Complications of shoulder dystocia. *Semin Perinatol* 38(4):201, 2014
- Eastman NJ, Hellman LM (eds): *Williams Obstetrics*, 13th ed. New York, Appleton-Century-Crofts, 1966
- Eden RD, Seifert LS, Winegar A, et al: Perinatal characteristics of uncomplicated postdate pregnancies. *Obstet Gynecol* 69: 296, 1987
- El Madany AA, Jallad KB, Radi FA, et al: Shoulder dystocia: anticipation and outcome. *Int J Gynaecol Obstet* 34(1):7, 1991
- Gherman RB, Goodwin TM, Ouzounian JG, et al: Brachial plexus palsy associated with cesarean section: an in utero injury? *Am J Obstet Gynecol* 177:1162, 1997
- Gherman RB, Ouzounian JG, Goodwin TM: Obstetric maneuvers for shoulder dystocia and associated fetal morbidity. *Am J Obstet Gynecol* 178:1126, 1998a
- Gherman RB, Ouzounian JG, Incerpi MH, et al: Symphyseal separation and transient femoral neuropathy associated with the McRoberts' maneuver. *Am J Obstet Gynecol* 178:609, 1998b
- Gherman RB, Ouzounian JG, Miller DA, et al: Spontaneous vaginal delivery: a risk factor for Erb's palsy? *Am J Obstet Gynecol* 178:423, 1998c
- Gherman RB, Tramont J, Muffley P, et al: Analysis of McRoberts' maneuver by x-ray pelvimetry. *Obstet Gynecol* 95(1):43, 2000
- Gilbert WM, Nesbitt TS, Danielsen B: Associated factors in 1611 cases of brachial plexus injury. *Obstet Gynecol* 93(4): 536, 1999
- Goldaber KG, Wendel PJ, McIntire DD, et al: Postpartum perineal morbidity after fourth-degree perineal repair. *Am J Obstet Gynecol* 168:489, 1993
- Gonen R, Bader D, Ajami M: Effects of a policy of elective cesarean delivery in cases of suspected fetal macrosomia on the incidence of brachial plexus injury and the rate of cesarean delivery. *Am J Obstet Gynecol* 183:1296, 2000
- Gonik B, Allen R, Sorab J: Objective evaluation of the shoulder dystocia phenomenon: effect of maternal pelvic orientation on force reduction. *Obstet Gynecol* 74:44, 1989
- Gonik B, Stringer CA, Held B: An alternate maneuver for management of shoulder dystocia. *Am J Obstet Gynecol* 145:882, 1983
- Goodwin TM, Bands E, Millar LK, et al: Catastrophic shoulder dystocia and emergency symphysiotomy. *Am J Obstet Gynecol* 177:463, 1997
- Graham EM, Forouzan I, Morgan MA: A retrospective analysis of Erb's palsy cases and their relation to birth weight and trauma at delivery. *J Matern Fetal Med* 6:1, 1997
- Gregory KD, Henry OA, Ramicone E, et al: Maternal and infant complications in high and normal weight infants by method of delivery. *Obstet Gynecol* 92:507, 1998
- Grobman W: Shoulder dystocia. *Obstet Gynecol Clin North Am* 40(1):59, 2013
- Grobman WA: Shoulder dystocia: simulation and a team-centered protocol. *Semin Perinatol* 38(4):205, 2014
- Gross SJ, Shime J, Farine D: Shoulder dystocia: predictors and outcomes. A five-year review. *Am J Obstet Gynecol* 156:1408, 1987a
- Gross TL, Sokol RJ, Williams T, et al: Shoulder dystocia: a fetal-physician risk. *Am J Obstet Gynecol* 156:334, 1987b
- Gurewitsch ED, Donithan M, Stallings SP, et al: Episiotomy versus fetal manipulation in managing severe shoulder dystocia: a comparison of outcomes. *Am J Obstet Gynecol* 191(3):911, 2004
- Hansen A, Chauhan SP: Shoulder dystocia: definitions and incidence. *Semin Perinatol* 38(4):184, 2014
- Hartfield VJ: A comparison of the early and late effects of subcutaneous symphysiotomy and of lower-segment cesarean section. *Aust N Z J Obstet Gynecol* 13:147, 1973
- Hartfield VJ: Symphysiotomy for shoulder dystocia. *Am J Obstet Gynecol* 155:228, 1986
- Hassan AA: Shoulder dystocia: risk factors and prevention. *Aust N Z J Obstet Gynecol* 28:107, 1988
- Hehir MP, McHugh AF, Maguire PJ, et al: Extreme macrosomia—obstetric outcomes and complications in birthweights >5000 g. *Aust N Z Obstet Gynaecol* 55(1):42, 2015
- Hernandez C, Wendel GD: Shoulder dystocia. *Clin Obstet Gynecol* 33:526, 1990
- Hoffman MK, Bailit JL, Brance DW, et al: A comparison of obstetric maneuvers for the acute management of shoulder dystocia. *Obstet Gynecol* 117:1272, 2011
- Hofmeyr GJ, Cluver CA: Posterior axilla sling traction for intractable shoulder dystocia. *BJOG* 116(13):1818, 2009
- Hofmeyr GJ, Shweni PM: Symphysiotomy for fetopelvic disproportion. *Cochrane Database Syst Rev* 10:CD005299, 2012
- Hopwood HG: Shoulder dystocia: fifteen years' experience in a community hospital. *Am J Obstet Gynecol* 144:162, 1982
- Iffy L, Apuzzio JJ, Cohen-Addad N, et al: Abdominal rescue after entrapment of the aftercoming head. *Am J Obstet Gynecol* 154:623, 1986
- Jangö H, Langhoff-Roos J, Rosthøj S, et al: Risk factors of recurrent anal sphincter ruptures: a population-based cohort study. *BJOG* 119(13):1640, 2012
- Jennett RJ, Tarby TJ, Kendrick CJ: Brachial plexus palsy: an old problem revisited. *Am J Obstet Gynecol* 166:1673, 1992
- Johnson SR, Kolberg BH, Varner MW, et al: Maternal obesity and pregnancy. *Surg Gynecol Obstet* 164:431, 1987
- Johnstone NR: Shoulder dystocia: a study of 47 cases. *Aust N Z J Obstet Gynecol* 19:28, 1979
- Kitzmler JL, Mall JC, Gin GD, et al: Measurement of fetal shoulder width with computed tomography in diabetic women. *Obstet Gynecol* 70:941, 1987
- Kolderup LB, Laros RK, Musci TJ: Incidence of persistent birth injury in macrosomic infants: association with mode of delivery. *Am J Obstet Gynecol* 177:37, 1997
- Langer O: Obesity or diabetes: which is more hazardous to the health of the offspring? *J Matern Fetal Neonatal Med* 29(2):186, 2016
- Langer O, Berkus MD, Huff RW, et al: Shoulder dystocia: should the fetus weighing greater than or equal to 4000 grams be delivered by cesarean section? *Am J Obstet Gynecol* 165:831, 1991
- Lee CY: Shoulder dystocia. *Clin Obstet Gynecol* 30:77, 1987
- Lee VR, Darney BG, Snowden JM, et al: Term elective induction of labour and perinatal outcomes in obese women: retrospective cohort study. *BJOG* 123(2):271, 2016
- Lerner H, Durlacher K, Smith S, et al: Relationship between head-to-body delivery interval in shoulder dystocia and neonatal depression. *Obstet Gynecol* 118(2 Pt 1):318, 2011
- Lewis DF, Edwards MS, Asrat T, et al: Can shoulder dystocia be predicted? *J Reprod Med* 43:654, 1998
- Lindqvist PG, Erichs K, Molnar C, et al: Characteristics and outcome of brachial plexus birth palsy in neonates. *Acta Paediatr* 101(6):579, 2012
- MacKenzie IZ, Shah M, Lean K, et al: Management of shoulder dystocia: trends in incidence and maternal and neonatal morbidity. *Obstet Gynecol* 110(5):1059, 2007
- Malessy MJ, Pondaag W: Obstetric brachial plexus injuries. *Neurosurg Clin North Am* 20(1):1, 2009
- McBride MT, Hennrikus WL, Mologne TS: Newborn clavicle fractures. *Orthopedics* 21(3):317, 1998
- McCall JO: Shoulder dystocia: a study of after effects. *Am J Obstet* 83:1486, 1962
- Mehta SH, Blackwell SC, Chadha R, et al: Shoulder dystocia and the next delivery: outcomes and management. *J Matern Fetal Neonatal Med* 20(10):729, 2007
- Modanlou HD, Komatsu G, Dorchester W, et al: Large-for-gestational-age neonates: anthropometric reasons for shoulder dystocia. *Obstet Gynecol* 60:417, 1982
- Moore HM, Reed SD, Batra M, et al: Risk factors for recurrent shoulder dystocia, Washington state, 1987–2004. *Am J Obstet Gynecol* 198(5):e16, 2008
- Morris WI: Shoulder dystocia. *J Obstet Gynecol Br Empire* 62:302, 1955
- Nesbitt TS, Gilbert WM, Herrchen B: Shoulder dystocia and associated risk factors with macrosomic infants born in California. *Am J Obstet Gynecol* 179:476, 1998
- Nocon JJ, McKenzie DK, Thomas LJ, et al: Shoulder dystocia: an analysis of risk and obstetric maneuvers. *Am J Obstet Gynecol* 168:1732, 1993
- O'Leary JA, Cuva A: Abdominal rescue after failed cephalic replacement. *Obstet Gynecol* 80:514, 1992
- O'Leary JA, Gunn D: Cephalic replacement for shoulder dystocia. *Am J Obstet Gynecol* 153:592, 1985

- O'Leary JA, Leonetti HB: Shoulder dystocia: prevention and treatment. *Am J Obstet Gynecol* 162:5, 1990
- Ouzounian JG, Gherman RB, Chauhan S, et al: Recurrent shoulder dystocia: analysis of incidence and risk factors. *Am J Perinatol* 29(7):515, 2012
- Øverland EA, Vatten LJ, Eskild A: Pregnancy week at delivery and the risk of shoulder dystocia: a population study of 2,014,956 deliveries. *BJOG* 121(1):34, 2014
- Paris AE, Greenberg JA, Ecker JL, et al: Is an episiotomy necessary with a shoulder dystocia? *Am J Obstet Gynecol* 205(3):271.e1, 2011
- Parks DG, Zeil HK: Macrosomia. A proposed indication for primary cesarean section. *Obstet Gynecol* 52:407, 1978
- Patterson CA, Graves WL, Bugg G, et al: Antenatal and intra partum factors associated with occurrence of seizures in term infant. *Obstet Gynecol* 74:361, 1989
- Pedersen J: Fetal mortality in diabetic pregnancies. *Diabetes* 3(3):199, 1954
- Peleg D, Hasnin J, Shalev E: Fractured clavicle and Erb's palsy unrelated to birth trauma. *Am J Obstet Gynecol* 177:1038, 1997
- Phelan JP, Ouzounian JG, Gherlam RB, et al: Shoulder dystocia and permanent Erb's palsy: the role of fundal pressure. *Am J Obstet Gynecol* 176: S138, 1997
- Rahman J, Bhattee G, Rahman MS: Shoulder dystocia in a 16-year experience in a teaching hospital. *J Reprod Med* 54(6):378, 2009
- Resnik R: Management of shoulder girdle dystocia. *Clin Obstet Gynecol* 23:559, 1980
- Rouse DJ, Owen J, Goldenberg RL, et al: The effectiveness and costs of elective cesarean delivery for fetal macrosomia diagnosed by ultrasound. *JAMA* 276(18):1480, 1996
- Rubin A: Management of shoulder dystocia. *JAMA* 189:835, 1964
- Sagi-Dain L, Sagi S: The role of episiotomy in prevention and management of shoulder dystocia: a systematic review. *Obstet Gynecol Surv* 70(5):354, 2015
- Sandberg EC: The Zavanelli maneuver: 12 years of recorded experience. *Obstet Gynecol* 93:312, 1999
- Sandberg EC: The Zavanelli maneuver: a potentially revolutionary method for resolution of shoulder dystocia. *Am J Obstet Gynecol* 152:479, 1985
- Sandmire HF, DeMott RK: Erb's palsy: concepts of causation. *Obstet Gynecol* 95:941, 2000
- Sandmire HF, O'Halloin TJ: Shoulder dystocia: its incidence and associated risk factors. *Int J Gynecol Obstet* 26:65, 1988
- Schramm M: Impacted shoulders—a personal experience. *Aust N Z J Obstet Gynecol* 23:28, 1983
- Schwartz BC, Dixon DM: Shoulder dystocia. *Obstet Gynecol* 11:468, 1958
- Seigworth GR: Shoulder dystocia. Review of 5 years' experience. *Obstet Gynecol* 28:764, 1966
- Sjoberg I, Erichs K, Bjerre I: Cause and effect of obstetric (neonatal) brachial plexus palsy. *Acta Paediatr Scand* 77:357, 1988
- Sorab J, Allen RH, Gonik B: Tactile sensory monitoring of clinician-applied forces during delivery of newborns. *IEEE Trans Biomed Eng* 10:1285, 1988
- Spain JE, Frey HA, Tuuli MG, et al: Neonatal morbidity associated with shoulder dystocia maneuvers. *Am J Obstet Gynecol* 212(3):353, 2015
- Spellacy WN, Miller S, Winegar A, et al: Macrosomia—maternal characteristics and infant complications. *Obstet Gynecol* 66:158, 1985
- Spong CY, Beall M, Rodrigues D, et al: An objective definition of shoulder dystocia; prolonged head to body delivery time and/or use of ancillary obstetrical maneuvers. *Obstet Gynecol* 12:338, 1995
- Stitely ML, Gherman RB: Shoulder dystocia: management and documentation. *Semin Perinatol* 38(4):194, 2014
- Swartz DP: Shoulder girdle dystocia in vertex delivery. *Obstet Gynecol* 15:194, 1960
- Tempest N, Hart A, Walkinshaw S, et al: A re-evaluation of the role of rotational forceps: retrospective comparison of maternal and perinatal outcomes following different methods of birth for malposition in the second stage of labour. *BJOG* 120:1277, 2013
- Torki M, Barton L, Miller D, et al: Severe brachial plexus palsy in women without shoulder dystocia. *Obstet Gynecol* 120(3):539, 2012
- van de Ven J, van Deursen FJ, van Runnard Heimel PJ, et al: Effectiveness of team training in managing shoulder dystocia: a retrospective study. *J Matern Fetal Neonatal Med* 29(19):3167, 2016
- Williams JW: Anaesthesia. In *Obstetrics*. New York, D. Appleton & Co., 1903
- Wood C, Ng KH, Dounslow D, et al: Time—an important variable in normal delivery. *J Obstet Br Commonw* 80:295, 1973

CHAPTER 25

Cesarean Delivery

HISTORY	403
CESAREAN DELIVERY RATES	404
EFFORTS TO DECREASE RATES	405
ANESTHESIA	406
CESAREAN DELIVERY TECHNIQUE	406
COMPLICATIONS	415
CARDIAC ARREST AND PERIMORTEM CESAREAN DELIVERY	416

Each year in the United States, approximately one third of more than 4 million neonates are born by cesarean delivery. Indeed, the operation is the most commonly performed major surgery in this country in women aged 18 to 44 years (Boyle, 2012). It follows that the procedure is one of the most often used in modern obstetrics. Until recently, the term “cesarean section” was used to describe operative abdominal delivery, but “cesarean delivery” is considered more accurate for reasons discussed subsequently.

HISTORY

The concept of delivering a living child through an abdominal incision has its origin in prehistoric times. References to these miraculous births are found in the folklore and mythology of both Eastern and Western cultures. Most of the early accounts involved the birth of heroes or gods, demonstrating their superhuman qualities. At the same time, however, the mother was usually dying or dead at the time of birth (Thompson, 1955).

Francis Rousset introduced the idea of performing this operation for a living woman in the 16th century. He suggested several obstetric complications that were more horrific than the surgery itself. In one example, the fetus had escaped into the abdominal cavity during labor and later caused an abdominal abscess that was debilitating to the woman. Next, he sought to establish the feasibility of the operation by giving an account of seven women who survived. He also reported that another successful pregnancy may follow the operation (Young, 1944).

In the 19th century, introductions of diethyl ether as an anesthetic by Morton and of carbolic acid antiseptics by Lister made the possibility of an abdominal operation for childbirth more feasible. Early success in the surgery was compromised by the widespread belief that once uterine muscle was incised it could not be safely sutured, principally out of fear of infection. Against this background, cesarean deliveries performed in Paris between 1787 and 1876 yielded 100-percent maternal mortality rates, mostly due to infection or hemorrhage (Sewell, 1993).

The first major surgical advance in cesarean delivery technique was introduced by Porro in 1876 (Miller, 1992). Influenced by the prevailing concept of not suturing the uterine incision, Porro introduced a technique in which the uterine fundus was amputated following the delivery of the fetus. The cervical stump was then marsupialized to the anterior abdominal wall. Although drastic by modern standards, the Porro technique resulted in a dramatic decline in maternal mortality rates (Speert, 1958). The Porro procedure is described in further detail in Chapter 26 (p. 419).

The era of the modern cesarean operation began when Max Saenger (1882) introduced the technique of suturing the uterus. He advocated performing a vertical incision in the uterus that avoided the lower uterine segment. After delivery of the infant and manual extraction of the placenta, he closed the uterus with two layers. He recommended silver wire for the deep suture and fine silk for the superficial serosa. Although the Saenger classical cesarean became the mainstay for the next half

century, the Porro operation remained popular for many years. Indeed, in one series in 1922 from the eastern United States, 25 percent of abdominal deliveries were performed using Porro's technique (Harris, 1922).

A uterine incision in the lower uterine segment was suggested as early as 1769 by Robert Wallace Johnson, but was not performed until a century later. One of the earliest advocates of its use was Fritz Frank, who performed an extraperitoneal low-transverse uterine incision. He argued that this approach reduced blood loss and infection risk. Later, Kronig in 1912 emphasized that the superior results were obtained not because of the extraperitoneal approach, but because of the lower-segment uterine incision. He recommended a transperitoneal approach with a vertical incision in the lower uterine segment. He and others touted a maternal mortality rate of less than 4 percent (Young, 1944).

Although other obstetricians advocated using a transperitoneal uterine incision, Munro Kerr (1926) recommended a semilunar transverse uterine incision with the curve directed upward. The general objection to this incision was the danger of extending into the uterine vessels at the edges of the incision. Kerr, however, argued that using careful technique the vessels could be avoided. The success of this uterine incision—still used today—along with the development of antibiotics and blood-banking techniques, has caused cesarean delivery to be one of the safest major surgeries performed today.

The origin of the term “cesarean section” is obscure, but several different theories are promulgated. First, the popular belief is that Julius Caesar was born in such a fashion. This theory, however, lacks credibility since Caesar's mother was still alive when he was emperor. Another oft-quoted possibility is from a Roman law—*Lex Regia*—that mandated that any pregnant woman who died must have the fetus cut from her abdomen. When the ruler of Rome was referred to as the Roman Caesar, the law became known as the *Lex Caesar*. Yet another possible origin is from the Latin verb *caedere*, which means “to cut.” Children delivered from dead mothers were known as *caesones*. So, cesarean may simply mean to remove the fetus by cutting (Sewell, 1993).

CESAREAN DELIVERY RATES

In 2013, there were nearly 4 million births in the United States (Martin, 2015). Since 1996, the cesarean delivery rate had increased every year but peaked in 2009 at 32.9 percent of all deliveries (Fig. 25-1). It appears to have plateaued, and in 2013 the rate was slightly lower at 32.7 percent.

Influencing Factors

Several factors have contributed to the declining cesarean delivery rate. In the last few years, the obstetric community has focused on reducing elective inductions before 39 weeks' gestation (American College of Obstetricians and Gynecologists, 2015a). The effort of this campaign is reflected in the gestational age at the time of a cesarean delivery. The overall decline in these induction rates

likely contributed to the decreased cesarean delivery rate at 38, 40, and 41 weeks' gestation (Martin, 2015).

Maternal characteristics also affect the cesarean rate, and race is one variable. In 2013, non-Hispanic blacks (35.8 percent) had a higher rate than either Hispanics (32.2 percent) or non-Hispanic whites (32.0 percent). Second, maternal age influences delivery route. And, as maternal age at the time of cesarean delivery increases, so does the rate of cesarean delivery. Specifically, in gravidas aged 20 years, approximately 1 in 5 babies are born by cesarean delivery. In those aged 40 years or older, 1 in 2 babies are delivered operatively. Yet another factor is maternal obesity. As the body mass index rises, so does the cesarean delivery rate (Kominiarek, 2010).

The cesarean rate is not uniform throughout the United States. In 2013, Utah had the lowest rate at 22.4 percent. Three other states had a rate of 25 percent or less: Alaska, Idaho, and New Mexico. The state with the highest cesarean delivery rate (38.9 percent) was Louisiana. Two other states, Mississippi and New Jersey, had rates approximating 38 percent. Most states mirrored the national trend of cesarean delivery rate decline from 2012 to 2013. In fact, Georgia was the only state with a higher cesarean delivery rate in 2013 compared with that in 2012. Delaware and Montana had the most significant rate drops (Martin, 2015). Significant regional variation is not unique to the United States and can be found in other countries (Hanley, 2010).

Comparative Data

The United States has one of the highest cesarean delivery rates of industrialized countries. Recent data from the Organisation for Economic Cooperation and Development (OECD) (2016) show that Israel has the lowest cesarean delivery rate at 15.4 percent. Three other countries reported rates less than 20 percent: Finland, Sweden, and Norway. Three countries, Turkey, Italy, and Poland, reported rates higher than the United States. In Turkey, almost 1 of every 2 babies is born by cesarean delivery. Similar data were reported from eight Latin American countries. Paraguay reported the highest cesarean section rate

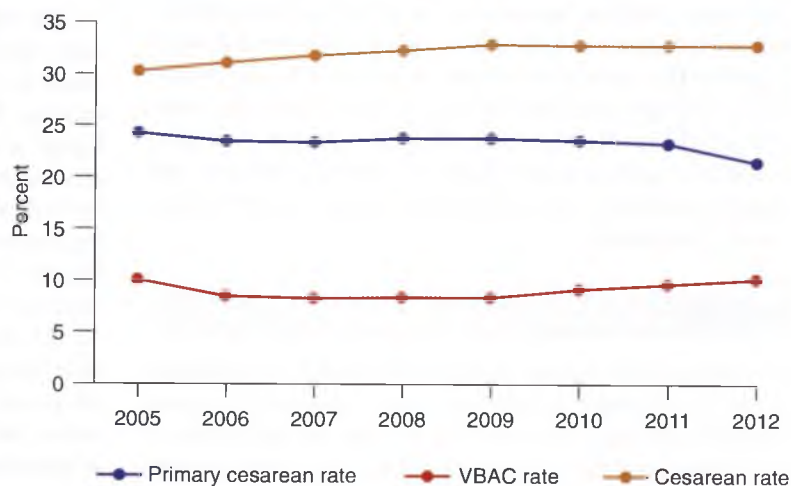


FIGURE 25-1 Total cesarean delivery rates, primary cesarean delivery rates, and vaginal birth after cesarean delivery rates from 2005–2012. (Data from Martin MA, Hamilton BE, Osterman MJ, et al: Births: final data for 2013. 64(1):1, 2015.)

at 41.4 percent, whereas Nicaragua reported the lowest at 24.2 percent. The rate in Brazil parallels that of the United States at 32.2 percent (Taljaard, 2009).

■ Nonmedical Factors

Several nonmedical factors also apparently influence cesarean delivery rates. One example is the type of hospital or hospital system (Bailit, 2012; Maso, 2013). In selected populations, the practice model of individual labor and delivery units is associated with different rates. Also, university services with residents have a lower rate than private practice physicians (Barber, 2011). Obstetric units staffed by laborists and midwife-physician teams also report lower rates (Iriye, 2013; Nijagal, 2015).

EFFORTS TO DECREASE RATES

The concept of an ideal cesarean delivery rate is enigmatic. The World Health Organization (WHO) has opined that a rate of 1 to 5 percent is necessary to avoid severe maternal morbidity and mortality, whereas a rate beyond 10 percent does not lower neonatal mortality rates. This would indicate that a *minimum* cesarean delivery rate should be 5 to 10 percent (Gibbons, 2010). In 1985, the WHO recommended that the upper limit be 15 percent. Although this figure was based on theoretic estimates, observational studies have confirmed this value (Althabe, 2006; Villar, 2006). *Healthy People 2020* recommends a 10-percent reduction in low-risk cesarean delivery rates from 26.5 to 23.9 percent and a 10-percent decline in cesarean births in low-risk women following a prior cesarean delivery. The current percent of low-risk women undergoing repeat cesarean delivery is 90.8 percent, and thus the goal for 2020 is 81.7 percent (Office of Disease Prevention and Health Promotion, 2014).

In the United States, significant health care resources are spent for management of pregnant women and their newborns. Indeed, 25 percent of all hospitalizations in this country are pregnancy related (Werner, 2014). According to the Truven Health Analytics MarketScan Study (2013), cesarean births are 50 percent more expensive than vaginal routes and carry an average cost of \$27,866 for commercial payers and \$13,590 for Medicaid. If the cesarean delivery rate in the United States was

15 percent, as suggested by the WHO, then \$5 billion would be saved annually (Center for Healthcare Quality and Payment Reform, 2013).

Before a reduction in cesarean delivery rates can be accomplished, the indications for primary surgery must be examined. Recent data regarding cesarean delivery rates are shown in Figure 25-1. A primary cesarean operation is defined as the first cesarean delivery regardless of the number of previous vaginal deliveries. These account for approximately 60 percent of all cesarean cases. After the first surgical delivery, however, the probability of a subsequent vaginal delivery approximates only 10 percent.

The most common indications for primary surgery are labor arrest (34 percent), nonreassuring fetal heart rate tracing (23 percent), and fetal malpresentation (17 percent). Other indications, such as preeclampsia (3 percent), multifetal gestation (7 percent), and maternal request (3 percent), account for the remaining fourth of all operations (American College of Obstetricians and Gynecologists, 2014a). At the same time, and as outlined by the American College of Obstetricians and Gynecologists (2015b), operative vaginal delivery rates have declined (Chap. 23, p. 387). But in general, these indications for cesarean delivery in the United States are similar to those from other countries (Gao, 2013; Stjernholm, 2010).

Very few *absolute* indications necessitate primary cesarean delivery. Some examples are complete placenta previa, uterine rupture, and cord prolapse without imminent delivery. Other indications, for example, labor induction, dystocia, or nonreassuring fetal status, are subject to provider interpretation. Thus, the rates for these indications are highly variable and should be modifiable as indicated in Table 25-1. A prime example is labor induction, which increases the cesarean delivery rate in nulliparas (Chauhan, 2012; Grobman, 2012). The rate of inductions in the United States reached an all-time high of 23.8 percent in 2010, but has begun to decline since then. Importantly, induction rates have declined at 36, 37, and 38 weeks' gestation, and the largest decline has been at 38 weeks. Clearly, elective inductions, especially in women with an unfavorable cervix, should be avoided if the goal is to decrease the cesarean delivery rate.

Attempts have been undertaken to more closely study the physiology of normal labor as originally defined by Friedman (1955). More recent studies indicate that the latent phase is longer in oxytocin-induced labors and that the active phase

TABLE 25-1. Some Indications and Prevention Strategies for Primary Cesarean Delivery

Indication	Prevention Strategy
Labor induction	Avoid elective inductions More time for labor progression
Labor dystocia	More time for latent phase progress More time for active phase progress More time for second stage Consider operative vaginal delivery
Abnormal fetal heart rate tracing	Adopt a standard algorithm for category II tracings Standardize fetal heart rate monitoring education
Malpresentation	External cephalic version
Prior cesarean delivery	Trial of labor for attempted vaginal delivery

may not begin as early as Friedman concluded (Harper, 2012). Specifically, 40 percent of women whose latent phase is 12 hours or more will eventually deliver vaginally (Rouse, 2011). Another prominent example comes from the widespread use of labor epidural analgesia, which appreciably prolongs second-stage labor (Sharma, 2004; Zhang, 2010).

The fetus presenting as a breech remains one of the most common indications for cesarean delivery. In 2000, a randomized clinical trial was done to compare vaginal breech delivery and planned cesarean delivery (Hannah, 2000). Perinatal mortality and neonatal morbidity rates were significantly lower in the planned cesarean delivery cohort. This study, coupled with the increasing lack of experience with vaginal breech delivery, has resulted in a cesarean delivery in 85 percent of breech presentations. As indicated in Table 25-1, an alternative is an external cephalic version (ECV), which is successful 50 to 60 percent of the time (American College of Obstetricians and Gynecologists, 2016). Management of the breech-presenting fetus is described in Chapter 21.

■ Subsequent Pregnancies Following Cesarean Delivery

For the woman who is an ideal candidate for a subsequent trial of labor after a cesarean delivery, the success rate for a vaginal delivery approximates 60 percent. And, when a trial of labor was common, overall cesarean delivery rates were at their lowest (MacDorman, 2011). Namely, the vaginal birth after cesarean delivery (VBAC) rate peaked at 28 percent in 1996. After this, it dropped and by 2004 reached a rate <10 percent, which persists today. Also shown in Figure 25-1, in the past decade, once a woman has had a primary cesarean delivery, over 90 percent will undergo a repeat cesarean delivery (Spong, 2012). In fact, repeat cesarean deliveries are now more common than primary operations. This is despite the results of a Consensus Conference by the National Institutes of Health that encouraged a more liberal policy for a trial of labor following one or two low transverse cesarean deliveries (Cunningham, 2010). Discussed earlier were the goals of *Healthy People 2020* that include a 10-percent reduction in the rate of repeat cesarean deliveries in low-risk women. This goal translates to a VBAC rate that approximates 20 percent (Office of Disease Prevention and Health Promotion, 2014).

The decision for a trial of labor or elective repeat cesarean delivery is a risk-versus-benefits balance. And although there are both risks and benefits to the mother and fetus, these are not always parallel. The deciding factor frequently is the risk for uterine rupture with perinatal death or neurologic damage. According to the American College of Obstetricians and Gynecologists (2015c), the risk for an unpredictable uterine rupture with labor is 0.7 to 0.9 percent after one low transverse cesarean delivery, and it is 0.9 to 1.8 percent after two operative deliveries. A principal drawback to multiple cesarean deliveries is the risk for abnormal placentation in subsequent pregnancies. Placental accrete syndromes are discussed further in Chapter 27.

Regardless of the delivery route chosen for an elective induction or a repeat cesarean delivery, it is important for the woman to have completed 39 weeks' gestation (American College of Obstetricians and Gynecologists, 2015a). Delivery between 37 and 39⁰⁷ weeks' gestation poses an elevated risk

of neonatal morbidity and mortality. The primary complications are respiratory-related, and as expected, rates of ventilator use and admission to the neonatal intensive care unit (NICU) are increased (Clark, 2009; Tita, 2009). Importantly, delaying an elective repeat cesarean delivery until 39 weeks does not increase maternal morbidity rates (Tita, 2011). In recent years, quality and safety committees have been effective in encouraging elective deliveries at 39 weeks or later (Martin, 2015).

ANESTHESIA

During the past few decades, anesthesia for cesarean delivery has become a safe endeavor because of the availability of trained professionals who administer neuraxial blockades or general anesthesia. In its most recent report, the Centers for Disease Control and Prevention cited anesthetic complications as the cause of <1 percent of maternal deaths in the United States from 2006 to 2010 (Creanga, 2015). Analgesia and anesthesia are discussed in detail in Chapter 19 (p. 311).

CESAREAN DELIVERY TECHNIQUE

Some of the most essential steps to successful cesarean delivery begin prior to surgery. Perioperative considerations include patient consent, laboratory testing, antibiotic prophylaxis, venous thromboembolism prevention, and anesthesia selection. These are topics covered extensively in Chapter 18 (p. 291).

Intraoperatively, when preparing for a cesarean delivery, the surgeon, surgical assistant, and operating room personnel should observe universal bodily fluid precautions. Once adequate anesthesia is confirmed and presurgical "time out" completed, cesarean delivery begins with a vertical or transverse abdominal incision. The types of laparotomy incisions and indications for their use are discussed in Chapter 4 (p. 49). The current epidemic of obesity has led to emphasis on the importance of the type of abdominal incision for extremely obese women (Marrs, 2014). Following entry into the peritoneal cavity, the position of the uterus, the dome of the bladder, and character of the lower uterine segment are assessed to guide subsequent surgical steps.

■ Uterine Incision Choice

A low transverse uterine incision is performed in greater than 90 percent of cesarean deliveries. One primary advantage is the lower volume of blood lost by incision of the thinner lower uterine segment compared with that into the thicker muscle of the uterine corpus. Second, the risk of uterine incision scar rupture in a subsequent pregnancy is substantially less with low transverse hysterotomy.

A vertical uterine incision may be considered for either maternal or fetal characteristics. With the mother, access to the lower uterine segment may be challenging or deleterious. For example, a densely adhered bladder from previous surgery may preclude safe access to the lower uterine segment without great risk of cystotomy. In other scenarios, a leiomyoma may fill the lower uterine segment, or the cervix may be invaded by cancer. Massive maternal obesity can also preclude safe access

TABLE 25-2. Evidence-Based Cesarean Delivery Techniques

Technique	Evidence-Based Recommendations
Prophylactic antimicrobial treatment	Recommended
Bladder flap development	Not necessary, surgeon preference
Expansion of uterine incision	Blunt, cephalad-caudad direction
Prevention of postpartum hemorrhage	Oxytocin infusion (10–40 IU in 1000 mL crystalloid over 4–8 hours)
Placental removal	Spontaneous
Uterine exteriorization	Surgeon preference
Uterine closure	One- or two-layer
Peritoneal closure	Not recommended
Sutures versus staples for skin	Suture closure has less morbidity
Adhesion barriers	Not recommended

From CAESAR Study Collaborative Group, 2010; Cheong, 2009; Dahlke, 2013; Mackeen, 2015; Roberge, 2011, 2014; Shi, 2011; Walfisch, 2014.

to the lower uterine segment. Some cases of placenta previa with anterior implantation, especially those complicated by morbidly adherent placenta, can pose similar access problems. When the placenta is implanted in the lower uterine segment, the vasculature around it may be prominent. By performing a vertical hysterotomy, a surgeon can avoid the placenta and its feeding vessels. As discussed in Chapter 27 (p. 447), if an abnormally adherent placenta is suspected—placenta accrete syndromes—then the uterine incision should be made superior to the highest edge of the placenta. In some of these cases, the incision may extend through the fundus of the uterus and even posteriorly (Society for Maternal-Fetal Medicine, 2010).

In other instances, fetal indications dictate the need. At times, the lower uterine segment is not thinned and widened, that is, “developed,” sufficiently to accomplish an atraumatic delivery for the mother and fetus. The most common indication for a vertical uterine incision is a preterm fetus in a non-vertex presentation. And if necessary to accommodate the fetal head, a vertical incision can easily be extended upward. Another indication for a vertical uterine incision is the fetus with a back-down transverse lie. With this presentation, the fetal feet may be difficult to grasp through a low transverse incision and can lead to traumatic injury of the uterus or fetus. Intraoperative intraabdominal version to either breech or vertex presentation may avoid vertical uterine incision in this instance. Last, multifetal gestations or certain fetal malformations, such as severe hydrocephaly or conjoined twins, often require the greater operating room afforded by a vertical incision.

Regardless of the incision type, entry into the uterus must be performed carefully. The incidence of fetal lacerations approximates 1 to 2 percent (Pandit, 2013). Preventive steps to avert this are described in the next section. As a final note, if the woman has had a prior vertical uterine incision, another vertical incision is not necessary for a subsequent cesarean delivery.

■ Low Transverse Cesarean Delivery Hysterotomy

Traditionally, once the abdomen is entered, a bladder flap is developed. For this, the visceral peritoneum overlying the lower

uterine segment is incised to permit entry into the vesicouterine space. Dissection in this space divides the bladder’s connective tissue attachments to the lower uterine segment. The bladder can then be moved caudad and away from a planned hysterotomy.

More recent evidence suggests that a bladder flap may be unnecessary in many cases (Table 25-2). Without this step, the time from skin incision to uterine incision is shortened, and rates of intraoperative and postoperative complications such as blood loss, postoperative pain, or urinary tract infections are lowered. However, studies have been underpowered to determine if this approach raises the incidence for bladder injury or any long-term complications (Dahlke, 2013).

When a bladder flap is deemed necessary, the visceral peritoneum overlying the uterus is grasped with forceps and incised with Metzenbaum scissors just above the superior margins of the bladder and below the vesicouterine peritoneum reflection (Fig. 25-2). The vesicouterine peritoneum is then undermined laterally with scissor tips and incised to the left and to the right of the midline. If difficulty is encountered, the incision was most likely made above the vesicouterine peritoneal reflection, and here the parietal peritoneum is densely integrated with the myometrium. In this case, the position of the bladder should be reevaluated such that the incision can be made again but lower.

The inferior margin of the incised peritoneum is then grasped with forceps or a Kelly clamp and undermined with the forefinger. This maneuver results in the development of the potential vesicouterine space between the bladder and the lower uterine segment and creation of the bladder flap. If blunt dissection is performed, the dissecting forefinger should be directed with the fingertip exerting pressure on the lower uterine segment of the uterus rather than on the posterior surface of the bladder. This will minimize the risk of inadvertent blunt cystotomy. Care must also be taken not to dissect too far laterally where vessel injury can lead to profuse bleeding. If a patient has had a prior procedure, the bladder flap may be scarred and sharp dissection may be necessary to develop the potential space (Fig. 25-3). Again, caution reduces the risk of inadvertent cystotomy.

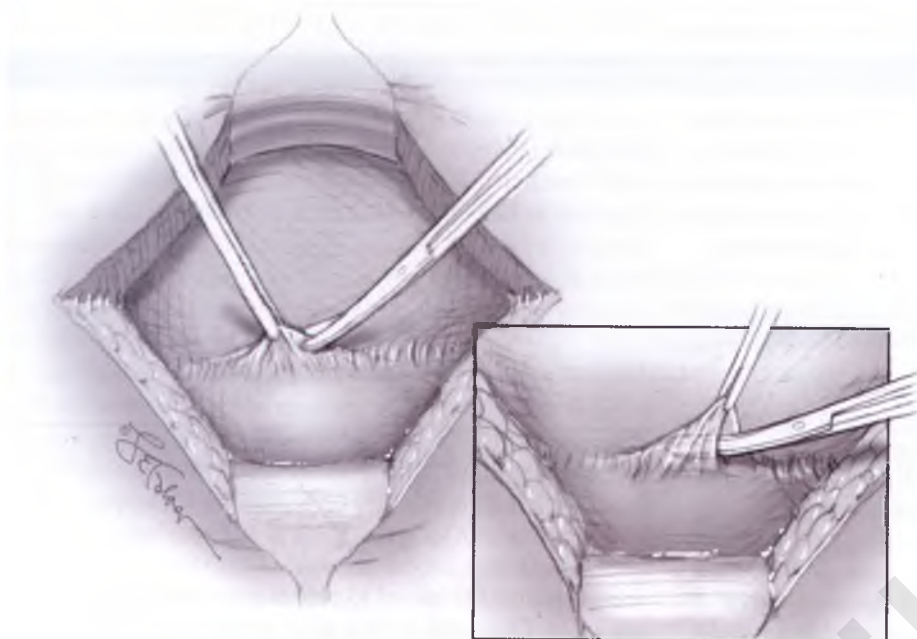


FIGURE 25-2 If a bladder flap is needed, the visceral peritoneum above the bladder reflection is grasped with forceps and incised with Metzenbaum scissors. The incision is undermined and then extended laterally.

The surgeon next inserts a retractor, typically a bladder blade, to move the bladder caudad and away from the operative field. Additionally, a Richardson retractor can be placed cephalad to aid exposure. The lower uterine segment is then incised in

the midline just below the vesicouterine peritoneal reflection (Fig. 25-4). After one or two shallow strokes of the blade, a finger palpates the myometrium to assess the depth needed to reach the membranes or uterine cavity. This layered approach helps avoid fetal laceration. Moreover, blunt entry through the deepest layer of the myometrium with a finger or the back of the scalpel handle has been advocated to decrease fetal laceration risks. Also, during hysterotomy, an Allis clamp may be used to elevate the myometrium away from the fetus (Encarnacion, 2012). Often, blood obscures the operative field at this stage, and continuous suctioning by the assistant is invaluable. When suction is insufficient, firm pressure with sponge sticks above and/or below the myometrial incision may slow bleeding sufficiently to allow visualization. Ultimately, with completed incision of myometrium, the placental membranes are also usually ruptured, if they did not rupture previously during labor.

The surgeon has three methods to extend the hysterotomy opening: sharp incision, blunt stretch, or discharge of a stapling device. Of these, blunt dissection may be performed in two ways. The surgeon may insert index fingers into the hysterotomy incision at its lateral edges, and then traction is directed laterally and cephalad (Fig. 25-5). Another maneuver is to insert one or two fingers in the midline under the superior and inferior edge of the uterine incision. Opposing traction is then simultaneously directed in a cephalad and in a caudad direction (see Table 25-2). Of the two techniques, the latter appears to be safer. Specifically, stretching the uterine incision in the cephalad-caudad direction is associated with a lower risk of unintended extensions and less need for additional suturing. The risk for blood loss exceeding 1500 mL is also diminished (Cromi, 2008).

Sharp incision is a second option. For this, bandage scissor blades straddle the uterine wall of the lower uterine segment. For fetal protection, fingers elevate the uterine wall and also serve as a physical barrier between lower scissor blade and fetus. The myometrium is then incised laterally

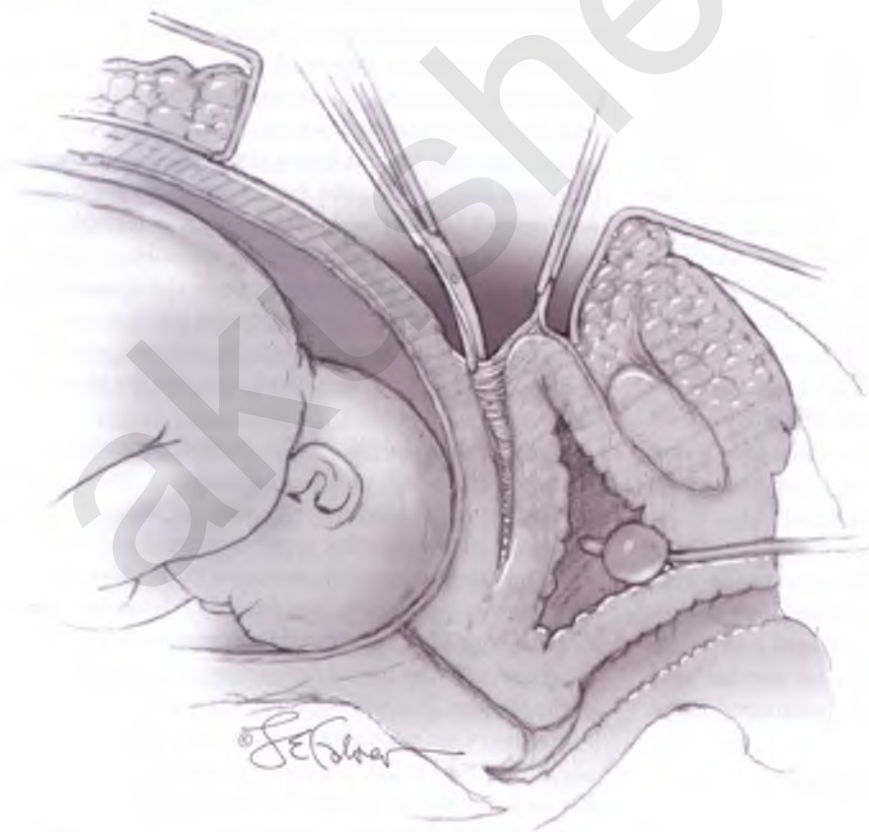


FIGURE 25-3 Blunt or sharp dissection may be used in the vesicouterine space to separate the bladder from the lower uterine segment.

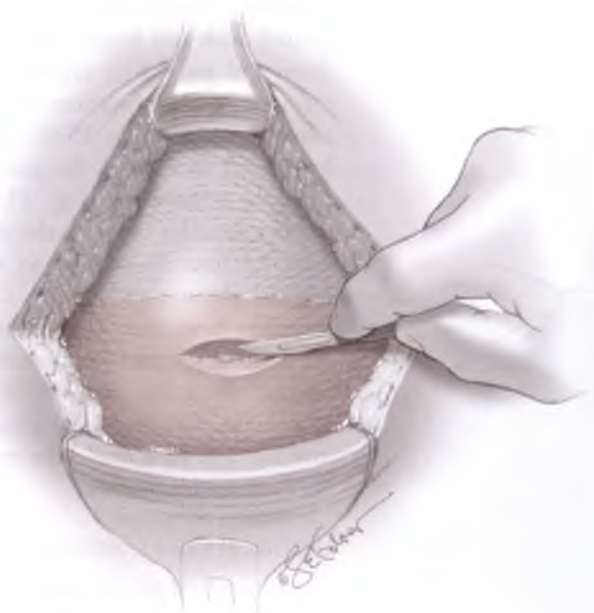


FIGURE 25-4 Following formation of a bladder flap, a bladder blade is placed to retract the bladder away from the planned hysterotomy. A Richardson-type retractor elevates the abdominal wall superiorly. The lower uterine segment is incised sharply.

and slightly cephalad, while the fetus is protected. Of the two techniques, sharp dissection is associated with greater blood loss (Dahlke, 2013; Saad, 2014).

A third option extends the incision by using a specialized uterine stapling device that contains two jaws and absorbable surgical staples. With this, the lower jaw of the stapler is introduced directly into the uterine cavity through the small initial hysterotomy. Once positioned, the upper jaw of the stapler lies outside the uterus and along the planned transverse incision. The lower jaw runs along the inner uterine surface along the same incision path. As the stapler is fired, two lines of absorbable staples are laid down and the intervening myometrium is divided. This staple line creates a hemostatic hysterotomy. However, use of this device does not decrease overall procedure-related blood loss, and it does lengthen operating times (Dodd, 2014). Thus, the additional cost for the disposable stapler and the lack of a definite surgical advantage makes this choice less appealing. This tool offers greater advantages during hysterotomy for fetal surgery, described in Chapter 16 (p. 268).

Uterine Incision Extension

At times, a created low transverse hysterotomy may be insufficiently wide. Examples are cases in which the fetus is macrosomic; has a round, unmolded head; or is breech. This may be especially the case if surgery precedes labor and the lower uterine segment is undeveloped and thus has a narrower width. In many instances, further lateral incision extension may risk laceration of the uterine arteries. Instead, the low transverse incision may be extended upward into the uterine corpus.

The extension can be performed vertically in the midline of the uterus toward the fundus. This is a *T-incision*. Its path mirrors that of a classical incision, shown on page 415, but the T-incision is typically shorter. Alternatively, the lateral edge of a

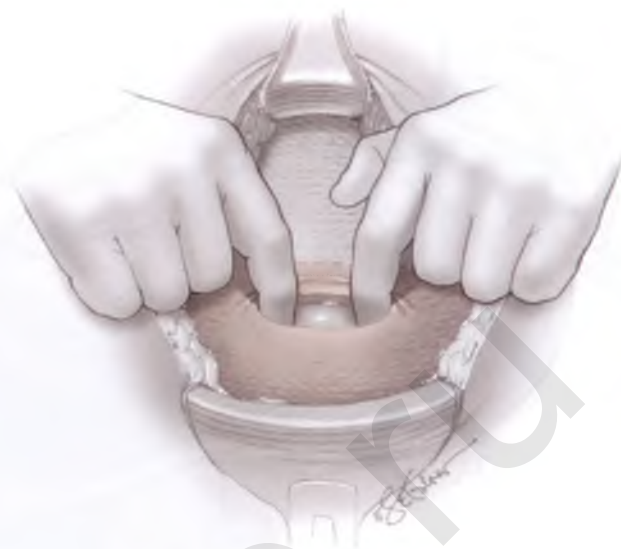

FIGURE 25-5 After entering the uterine cavity, the incision is extended laterally and cephalad with fingers. Here, the amniotic sac is seen beneath and between the operator's fingers.

transverse incision can also be extended at either the right or left angle and again is directed toward the fundus (Fig. 25-6). This is a *J-incision*. With either T or J incisions, fingers are insinuated between the lower scissor blade and fetus to help avert unintended fetal laceration. Notably, these extended incisions are associated with increased blood loss, broad ligament hematomas, and lacerations of the uterine vessels (Pandit, 2013).

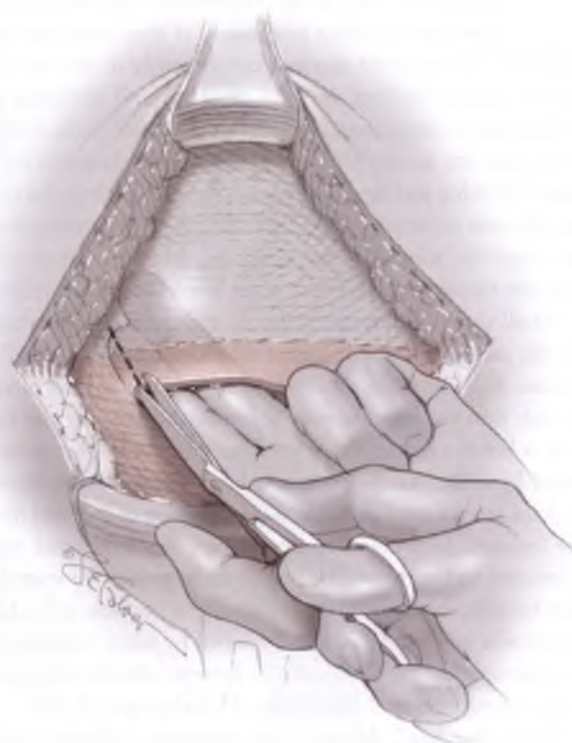


FIGURE 25-6 If a longer hysterotomy is needed, a J-incision can provide additional length and lowers the risk of lateral lacerations into the uterine artery. Fingers are inserted into the lateral aspect of the right or left side of the incision. The fingers elevate the myometrium and serve as a barrier between the lower scissor blade and fetus.

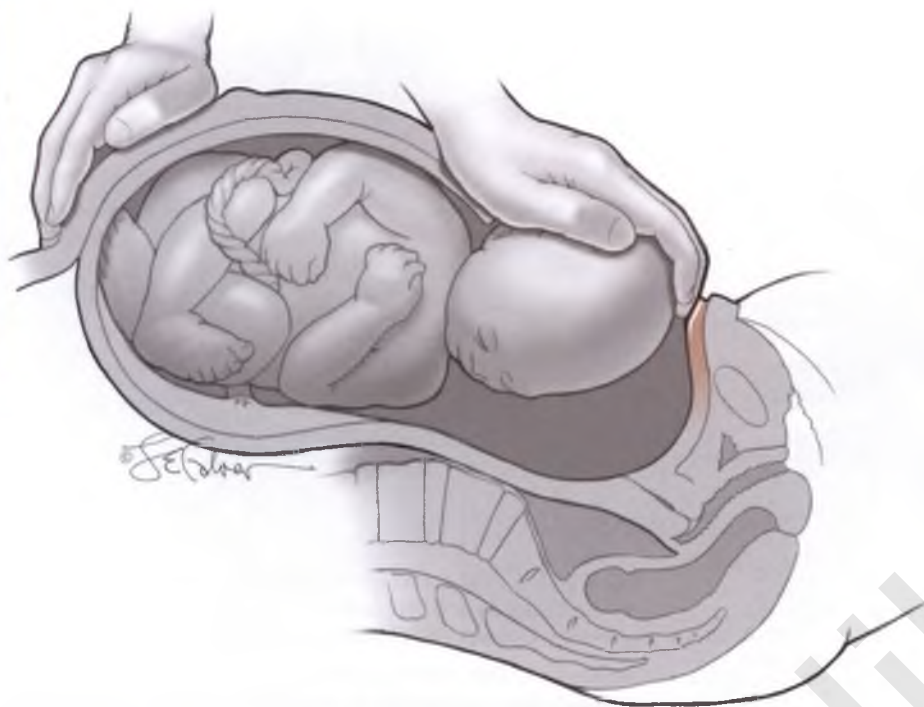


FIGURE 25-7 The fetal occiput is lifted toward the incision. To avoid lacerations in the lower uterine segment, care is taken to avoid using the lower uterine segment as a fulcrum. Thus, the wrist of the delivering hand ideally does not flex. Delivery of the fetal head is assisted by fundal pressure, but this is not applied until the occiput has entered into the uterine incision.

Fetus Delivery

At this juncture, a rent in the membranes can be made with an Allis clamp or a similar instrument if they have not already ruptured. The assistant suctions continuously in the area of the uterine incision to free the field of blood and amniotic fluid. In cephalic presentations, the surgeon then inserts the dominant hand into the hysterotomy and slips fingers beneath the fetal head. By lifting and flexing the head, the hand brings the occiput into the line of incision (Fig. 25-7). If difficulty is encountered at this stage, the surgeon should confirm that the occiput—rather than the sinciput or brow—is being lifted toward the incision.

At all times, the operator should avoid flexing the wrist and thereby using the lower margin of the incision as a fulcrum. Failure to heed this instruction may result in an inferior laceration that extends into the lower uterine segment and possibly the vagina, or in a lateral extension that stretches into the uterine artery and broad ligament. As the occiput is brought into the incision, the assistant exerts fundal pressure to aid expulsion of the head through the incision. In women without labor, the fetal head may be unmolded and without a leading cephalic point. The round head may be difficult to lift through the uterine incision in a relatively thick lower segment that is undeveloped by labor. Some surgeons find the application of vacuum or forceps valuable in extraction of the unengaged fetal head (Figs. 25-8 through 25-10).

Once the head delivers, the remaining delivery proceeds much like a vaginal birth. A finger should be passed across the fetal neck to determine whether it is encircled by one or more umbilical cord loops. If an umbilical cord coil is felt, it should be slipped over the head. The head is rotated to an occiput transverse position, which aligns the fetal bisacromial diameter

vertically. The sides of the head are grasped with two hands, and gentle downward traction is applied until the anterior shoulder enters the hysterotomy incision (Fig. 25-11). Next, by upward movement, the posterior shoulder is delivered (Fig. 25-12). During shoulder delivery, abrupt or powerful force is avoided to avert brachial plexus stretch injury. Once shoulders have cleared the incision, the surgeon provides steady outward traction along the long axis of the fetal body. Gentle fundal pressure may aid this. As a result, the rest of the body readily follows.

Umbilical Cord Clamping

The fetus is laid on the lower maternal abdomen and upper thighs while the umbilical cord is clamped and cut. Timing of cord clamping has been a topic of investigation. For preterm fetuses, delaying the cord clamping for 30 to 60 seconds has several benefits. These include higher red cell volume, decreased need for blood transfusion, better circulatory

stability, and lower rates of intraventricular hemorrhage and of necrotizing enterocolitis (Rabe, 2012; Sommers, 2012).

In term infants, delayed cord clamping decreases iron-deficiency anemia and improves iron stores. This may be particularly valuable in populations in which iron deficiency is prevalent (Abalos, 2009). However, higher hemoglobin concentrations increase risks for hyperbilirubinemia and extended hospitalization for neonatal phototherapy (McDonald, 2013). Delayed cord clamping may also hinder timely and needed neonatal resuscitation. Fortunately, in general, delayed umbilical cord clamping compared with early clamping does not worsen Apgar scores or umbilical cord pH values. Regarding maternal outcomes, rates of postpartum hemorrhage are similar between early and delayed clamping groups (Andersson, 2013). Milking the umbilical cord four to five times, during which the operator pushes blood through the cord toward the newborn, appears to have a similar effect (Al-Wassia, 2015; McAdams, 2014). Fewer data are available regarding this maneuver, but it appears safe and may be advantageous if rapid cord clamping is clinically indicated (Upadhyay, 2013). Long-term outcomes have not been studied, but follow-up at 4 months has suggested no effect on overall neurologic development (Andersson, 2011). The American College of Obstetricians and Gynecologists (2014b) has concluded that there is insufficient evidence to support or refute benefits from delayed umbilical cord clamping for term neonates in resource-rich settings.

Previously, immediate nasopharyngeal bulb suctioning of the newborn was routine to remove secretions. It was found, however, that suctioning of the nasopharynx may lead to neonatal bradycardia (Gungor, 2006). The American Heart Association

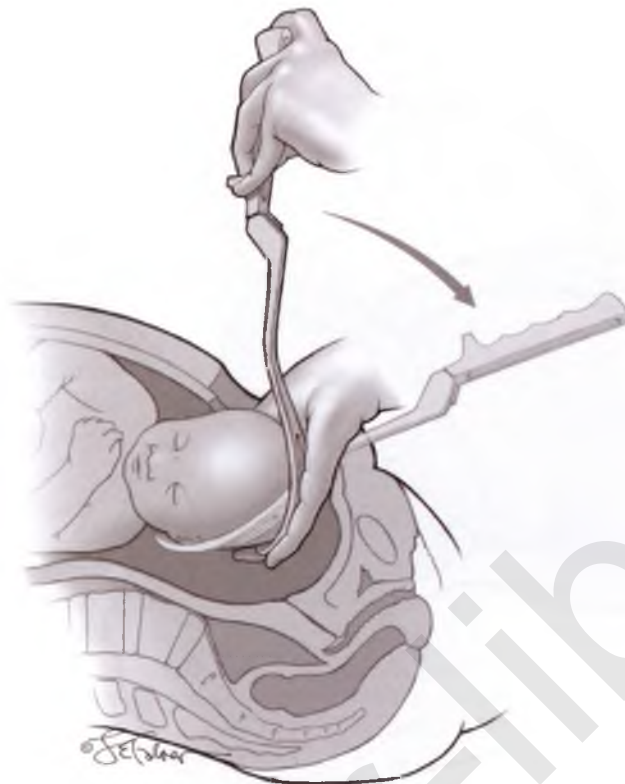


FIGURE 25-8 During cesarean delivery, forceps may be applied in several ways to assist with fetal head delivery. In many instances, the fetal head is manually rotated to an occiput transverse position. The operator's palm is slipped beneath the head. A Laue divergent forceps is guided along the palm and to ultimately lie across the fetal malar and lower parietal bone as in vaginal forceps application.

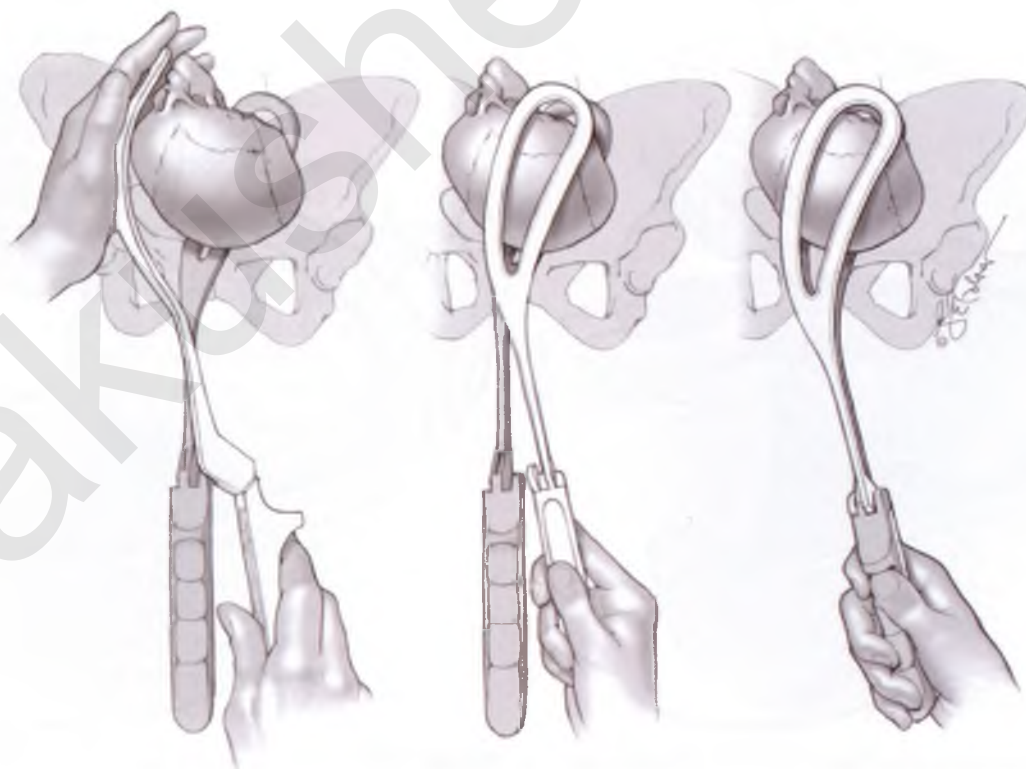


FIGURE 25-9 For application of the second blade, the operator's hand is inserted into the most lateral aspect of the uterine incision and into the uterus. The dorsum of this hand exerts lateral pressure against the uterine wall to provide room for the second blade. This blade is slipped across the palm of this hand until centered across the palm. This hand then guides the blade to overlie the upper malar and parietal bones. Once positioned, the handles are interlocked.

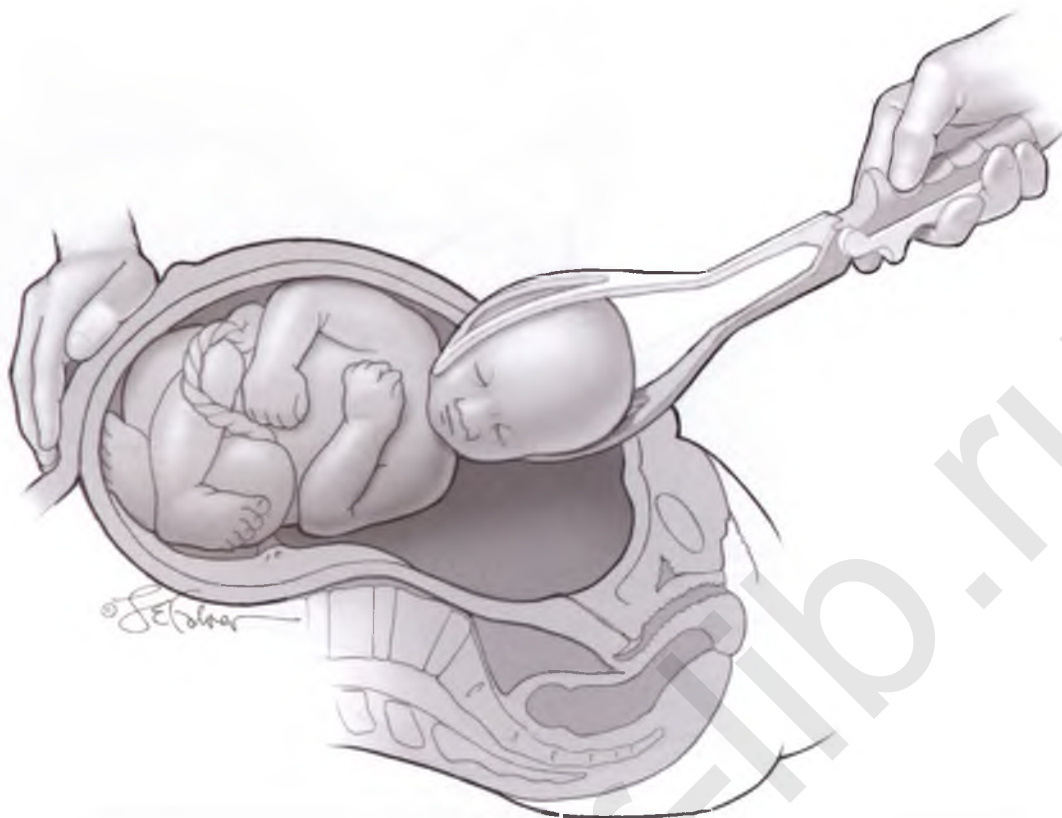


FIGURE 25-10 Traction is directed outward to deliver the head. Once the head is delivered, the handles are disarticulated and removed. The remainder of the fetus is delivered as shown in Figures 25-11 and 25-12.

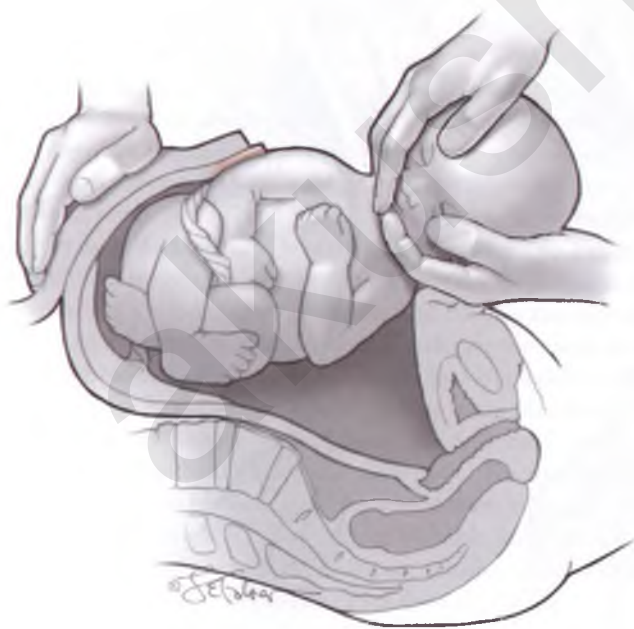

FIGURE 25-11 Hands grasp the fetal neck and gentle downward traction permits the anterior fetal shoulder to clear the uterine incision.

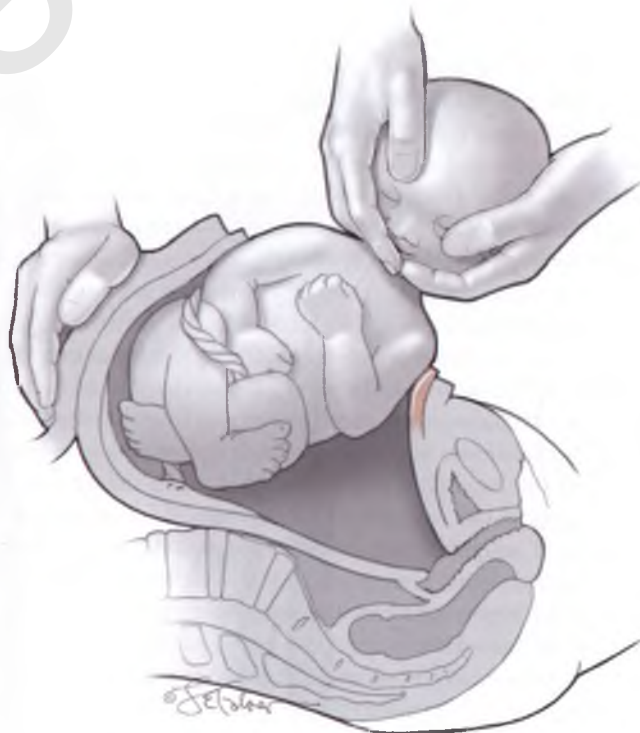

FIGURE 25-12 Gentle upward traction then allows the posterior fetal shoulder to clear the uterine incision.

neonatal resuscitation recommendations currently eschew most suctioning immediately following birth—even with meconium present. This includes bulb syringe aspiration. Suctioning should be reserved for neonates who have obvious obstruction to spontaneous breathing (Kattwinkel, 2010). Once the cord is clamped, the newborn is then passed to the health-care provider responsible for the newborn. The American Academy of Pediatrics and the American College of Obstetricians and Gynecologists (2012) recommend that an individual skilled in neonatal resuscitation should be in the delivery room with all potentially necessary equipment.

Impacted Fetal Head

After a long labor with cephalopelvic disproportion, the fetal head may be tightly wedged in the birth canal. This situation can have negative maternal and fetal results. To relieve this, an assistant may exert pressure vaginally to lift the fetal head toward the incision (Fig. 25-13). This “push” technique dislodges the head and allows its delivery above the symphysis. Because the delivering hand must travel deep into the pelvis, the wrist often lies at the level of the hysterotomy. Flexion of the wrist can increase stress across the hysterotomy. Accordingly, relief of such head impaction increases the risk of hysterotomy extension and associated blood loss. A second risk is fetal skull fracture that can result from vigorous upward pressure from either the surgeon or the assistant hand.

As an alternative, a “pull” method is used in which the fetal legs are grasped and delivered through the hysterotomy opening. In many instances, intentional extension of the incision is needed to provide sufficient space. The fetus is then delivered by traction and completion of a breech extraction. Data for this latter approach are less robust and derive from small randomized trials and metaanalysis (Bastani, 2012; Jeve, 2016; Veisi, 2012).

Placenta Delivery

Occlusive-type clamps such as Pennington or ovum forceps can be placed at any incisional sites of major bleeding to obtain temporary hemostasis while the placenta is removed. A solution of oxytocin, 10 to 40 units diluted in 1000 mL of crystalloid solution, is now administered over 4 to 8 hours (Dahlke, 2013). Fundal massage may begin as soon as the fetus is delivered to hasten placental separation and delivery.

The placenta is preferably delivered spontaneously by gentle traction on the umbilical cord (Fig. 25-14). Compared with manual

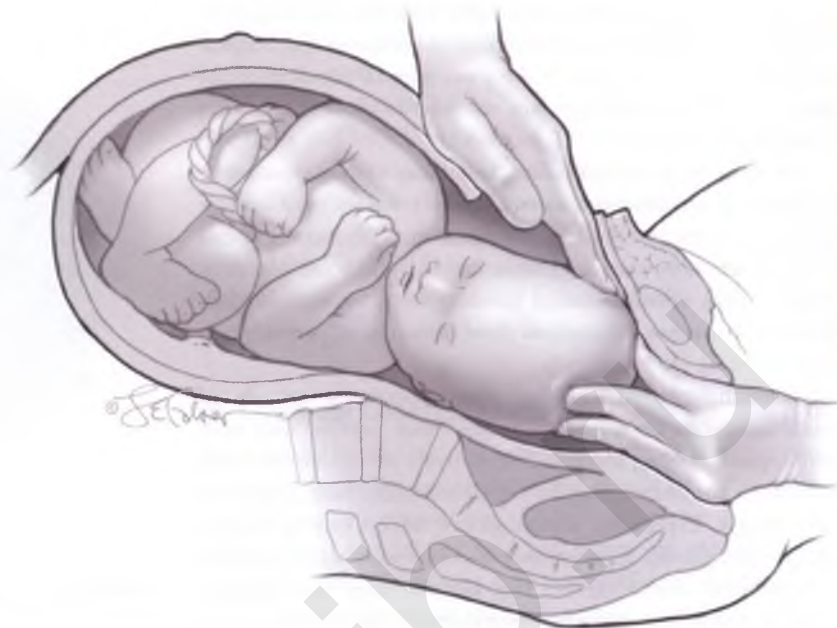

FIGURE 25-13 With cephalopelvic disproportion, the fetal head may be molded and tightly wedged in the birth canal. To relieve this, upward pressure exerted by an assistant’s hand in the vagina will help to dislodge the head and allow its delivery above the symphysis.

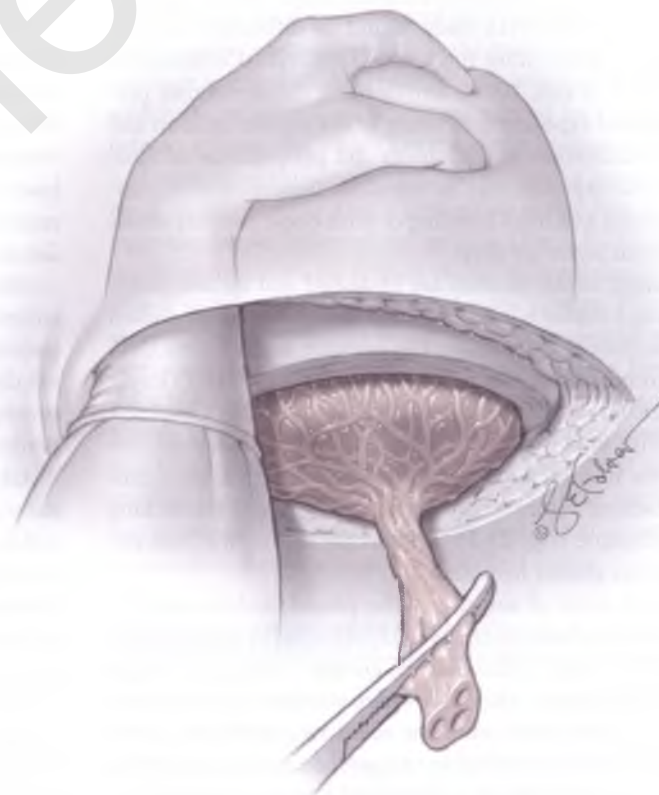

FIGURE 25-14 To deliver the placenta, a hand inside the abdomen but outside the uterus gently massages the fundus to help aid placental separation. The placenta bulges through the uterine incision as the uterus contracts. Slight tension exerted on the umbilical cord can also assist separation and delivery.

extraction, this technique is associated with decreased risks for metritis and blood loss, and a shorter duration in the hospital (see Table 25-2). At least in the past, manual removal of the placenta also incurred a greater risk of Rh alloimmunization (Queenan, 1964).

However, in some cases, especially those with uterine atony or unsuspected placenta accreta, cord traction may initiate inversion of the uterus. In such cases, manual extraction can avert inversion or can diagnose a morbidly adhered placenta. Also, in cases with substantial bleeding from hysterotomy lacerations, manual extraction can speed delivery and permit expedited suturing for hemostasis.

Following placental delivery, any remaining strands of membranes can be teased from the inner uterine wall with Pennington or Ring forceps. Alternatively or additionally, the interior of the uterus may be wiped manually with a laparotomy sponge. Previously, double-gloved fingers or ring forceps placed through the hysterotomy incision were used to dilate an ostensibly closed cervix. This practice does not improve infection rates from potential hematometra and is not recommended (Güngördük, 2009; Liabsuetrakul, 2011). If postcesarean intrauterine device placement is planned, insertion can be completed as described in Chapter 33 (p. 533).

Wound Closure

Attention is next directed toward uterine incision closure. Closure may be performed either with the uterus inside the peritoneal cavity or following its removal through the abdominal incision (see Table 25-2). A metaanalysis and a more recent randomized trial, the CORONIS study, found no differences in clinical outcomes with either method (CORONIS Collaborative Group, 2013; Walsh, 2009). Exteriorizing the uterus may provide additional exposure for closure of the uterine incision and may aid visualization of the adnexa and performance of tubal ligation. This exposure may be especially important with uterine lacerations and brisk bleeding or with obese patients whose subcutaneous layers are deep.

The angles of the incision are identified and an absorbable no. 0 or no. 1 suture is used. The ideal absorbable suture chosen for uterine closure is debatable. For example, in the CORONIS study, chromic catgut was superior to polyglactin 910 (Vicryl). Characteristics of these specific sutures are found in Chapter 1 (p. 4). With either suture, closure is begun just beyond one angle of the incision and run the incision's length using a continuous locking suture technique or a continuous nonlocking suture technique (Fig. 25-15). A locking suture line theoretically provides greater hemostasis.

A second layer of suture may be placed, imbricating the first. In two randomized trials, CAESAR (2010) and CORONIS (2013) study collaborative groups compared single-against double-layer closure. In these studies, no short-term differences were found between these two methods. Items included infectious morbidity, surgery duration, postoperative pain, need for blood transfusion, hospital readmission, and breastfeeding rates (see Table 25-2). The long-term consequences of these two methods regarding uterine scar integrity are debatable. Some studies, but certainly not all, suggest that a double-layer closure is superior if a woman opts for

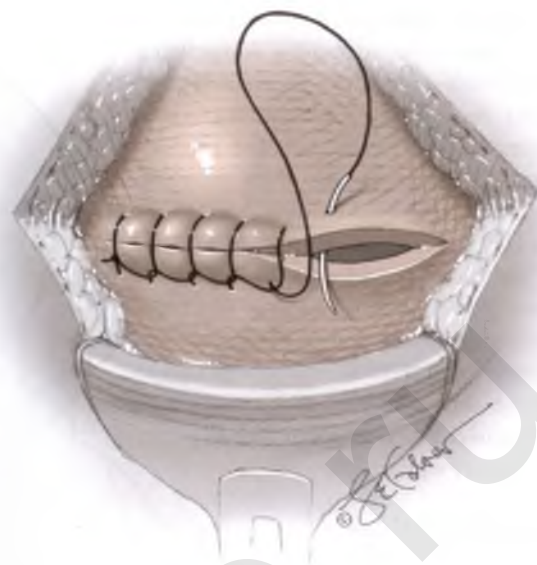

FIGURE 25-15 The cut edges of the hysterotomy are approximated with a transverse running-lock suture line.

a subsequent vaginal birth (Bujold, 2002; Durnwald, 2003; Roberge, 2011, 2014).

Some choose to irrigate the abdominal cavity, especially in cases of chorioamnionitis or with extensive spillage of meconium. Irrigation has been shown to increase the risk for intraoperative nausea and vomiting without decreasing postoperative infectious morbidity (Viney, 2012).

Prior to abdominal closure, the pelvic anatomy is explored. Ovarian or tubal pathology is managed similar to that for non-pregnant women and is presented in Chapter 14 (p. 230). With adequate spinal analgesia or general anesthesia, the upper abdomen can also be explored manually. This often includes both renal fossa and liver surface. An appendectomy is indicated if inspection suggests significant pathology, and this does not increase morbidity (Pearce, 2008).

There is concern with cesarean delivery that intraabdominal adhesions will form and serve to complicate subsequent surgery. In a recent review, Walfisch and colleagues (2014) studied the effects of adhesion barriers and of peritoneal closure on subsequent adhesions. They found no evidence that adhesion barriers are effective and recommend against their use.

Closure of the peritoneum has largely been abandoned in the past decade. Both CAESAR (2010) and CORONIS (2013) collaborative study groups found no differences in short-term clinical outcomes with or without closure. Thus, no short-term benefits appear to be gained by closure or nonclosure of the peritoneum. However, long-term outcomes have not been adequately studied.

Finally, abdominal closure is performed as outlined in Chapter 4 (p. 60). To summarize, the fascia is closed by a continuous nonlocking suture line using delayed-absorbable suture. Subcutaneous layers measuring deeper than 2 cm are typically closed with a continuous suture line or interrupted stitches using plain gut or delayed-absorbable suture. Most studies support the use of sutures over staples for skin closure (Mackeen, 2015; Tuuli, 2011).

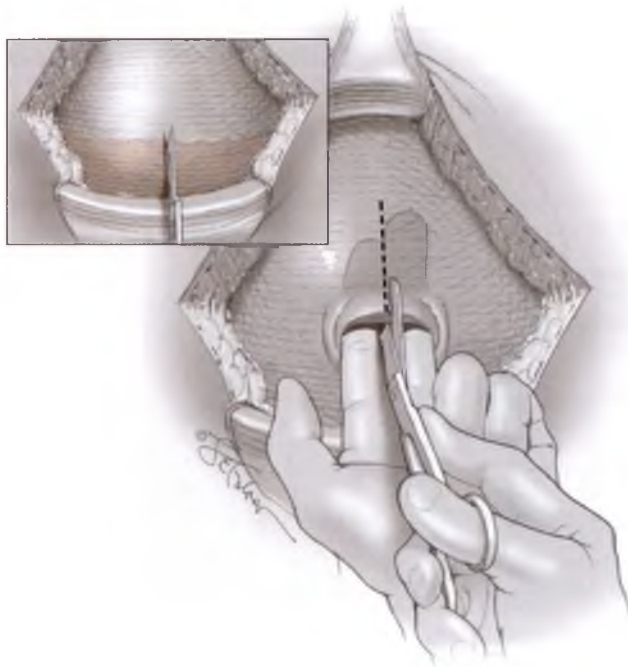


FIGURE 25-16 For a classical cesarean incision, an initial small vertical hysterotomy incision is made in the lower uterine segment. Fingers are insinuated between the myometrium and fetus to avoid fetal laceration. Scissors then extend the incision cephalad as needed for delivery.

■ Joel-Cohen and Misgav-Ladach Techniques

The Pfannenstiel-Kerr technique just described has been used for decades. More recently, Joel-Cohen and Misgav-Ladach modifications have been described. These differ from traditional Pfannenstiel-Kerr entry mainly by their initial incision placement and greater use of blunt dissection.

The Joel-Cohen technique creates a straight 10-cm transverse skin incision 3 cm below the level of the anterior superior iliac spines. The subcutaneous tissue layer is opened sharply 2 to 3 cm wide in the midline. This is carried down, without lateral extension, to the fascia. A small transverse incision is made in the fascia, and a finger from each hand is hooked into the lateral edges of this fascial incision. The incision is then stretched transversely. Once the fascia is opened and rectus abdominis muscle bellies identified, an index finger from each hand is inserted between the bellies. One is moved cranially and the other caudally, simultaneously in opposition, to further separate the bellies. Index finger dissection is used to enter the peritoneum, and again, cranial and caudad opposing simultaneous stretch with index fingers will open this layer. All the layers of the abdominal wall are then manually stretched laterally in opposition to further open the incision. The visceral peritoneum is incised in the midline above the bladder, and the bladder is bluntly reflected inferiorly to separate it from the underlying lower uterine segment. The myometrium is incised transversely in the midline and then opened and extended laterally with one finger hooked into each corner of the hysterotomy incision. Interrupted sutures are used for hysterotomy closure. Neither visceral nor parietal peritoneum is closed. The Misgav-Ladach technique is similar and differs

mainly in that myometrial incision closure is completed with a single-layer, locking continuous suture line (Hofmeyr, 2009; Holmgren, 1999).

These techniques have been associated with shorter operative times and with lower rates of intraoperative blood loss and of postoperative pain (Hofmeyr, 2008; Mathai, 2013). For this reason, they may be favored in cases requiring faster delivery times. They may, however, prove difficult to perform for women with anterior rectus fibrosis and peritoneal adhesions, which often complicate repeat cesarean deliveries (Bolze, 2013). Moreover, long-term outcomes with these techniques are unknown.

■ Classical Cesarean Incision

When possible, this incision is avoided because it encompasses the active upper uterine segment and thus is prone to rupture with subsequent pregnancies. A classical incision is occasionally preferred for delivery, and indications are enumerated on page 406. Some indications stem from difficulty in exposing or safely entering the lower uterine segment. In other instances, fetal indications dictate the need.

To begin, a vertical uterine incision is initiated with a scalpel beginning as low as possible and preferably within the lower uterine segment (Fig. 25-16). If adhesions, insufficient exposure, a tumor, or placenta percreta preclude development of a bladder flap, then the incision is made above the level of the bladder. Once the uterus is entered with a scalpel, the incision is extended cephalad with bandage scissors until it is sufficiently long to permit delivery of the fetus. During scissor use, the fingers of the nondominant hand are insinuated between the myometrium and fetus to prevent fetal laceration. As the incision is opened, numerous large vessels that bleed profusely are commonly encountered within the myometrium. The remainder of fetal and placental delivery mirrors that with a low transverse hysterotomy.

For incision closure, one method employs a layer of no. 0 or no. 1 chromic catgut with a continuous suture line to approximate the deeper halves of the incision (Fig. 25-17). The outer depth of myometrium is then closed with similar suture and with a running stitch or figure-of-eight sutures. No unnecessary needle tracts should be made, lest myometrial vessels be perforated, leading to subsequent hemorrhage or hematomas. To achieve good approximation and to prevent the suture from tearing through the myometrium, it is helpful to have an assistant compress the uterus on each side of the wound toward the midline as each stitch is placed. The edges of the uterine serosa are approximated with continuous 2-0 chromic catgut. The operation is then completed as described earlier.

COMPLICATIONS

In general, cesarean delivery is a safe procedure. However, compared with vaginal delivery, these operations are associated with some short- and long-term morbidity and with mortality. These are discussed in detail in Chapter 32 (p. 503). Some short-term complications include metritis, acute blood loss anemia requiring transfusion, and medical complications such as pneumonia and pulmonary embolism. Long-term sequelae include pelvic pain, adhesion formation, and adverse reproduc-

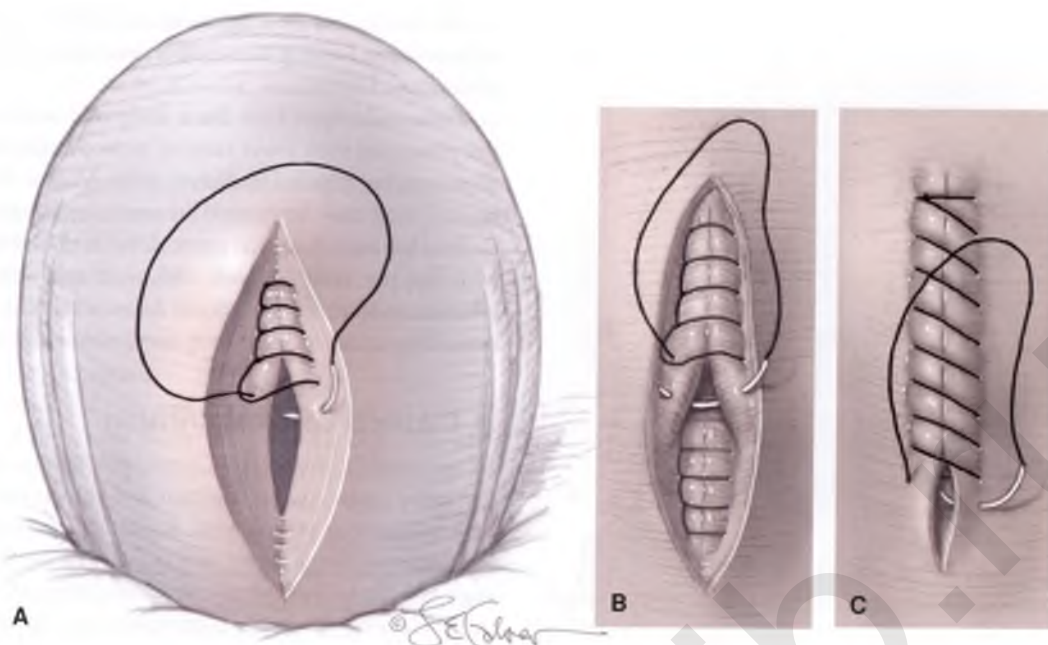


FIGURE 25-17 Classical incision closure. The deeper half (A) and superficial half (B) of the incision are reapproximated in a running fashion. C. The uterine serosa is then closed.

tive effects such as decreased fertility. Subsequent pregnancies following cesarean delivery have a higher chance of placenta previa, placental abruption, fetal growth restriction, preterm birth, and possibly stillbirth (Clark, 2011; Marshall, 2011). The risk of complications at the time of surgery such as cystotomy, bowel injury, and ureteral injury increases with each subsequent cesarean delivery (Silver, 2006). These injuries and their repair are described in Chapter 28 (p. 454). The most profound maternal risk in subsequent pregnancies is a morbidly adherent placenta—placenta accrete syndromes (Chap. 27, p. 442). The risk of maternal death with cesarean delivery is 2.2 per 100,000, which is approximately 10 times higher than for vaginal delivery (Clark, 2008).

In addition to maternal risk, a cesarean delivery increases fetal risk. The fetus can sustain physical injury, such as a scalp laceration (Alexander, 2006). The most common short-term fetal morbidity is respiratory, typically transient tachypnea of the newborn (Silver, 2012). If an elective repeat cesarean delivery is performed prior to 39 weeks' gestation, the rate is increased for adverse respiratory outcomes, mechanical ventilation, newborn sepsis, hypoglycemia, admission to the neonatal ICU, and hospitalization for more than 5 days.

As discussed on page 406, uterine rupture after a prior cesarean delivery carries both maternal and neonatal risks. Maternal risks include increased rates of infection, hysterectomy, and blood transfusions. Neonatal risks include hypoxic ischemic encephalopathy and death (Landon, 2004).

CARDIAC ARREST AND PERIMORTEM CESAREAN DELIVERY

In rare instances, an obstetrician is faced with a pregnant woman who has suffered cardiac arrest or, in other cases, is

agonal. Many of the physiologic changes of pregnancy can compound arrest. First, compared with nonpregnant women, gravidas with a cardiopulmonary arrest become anoxic more quickly. This stems from pregnancy changes that include a smaller pulmonary functional residual capacity but greater metabolic rate. Vena caval compression by the pregnant uterus, especially in the supine position that is required to perform cardiopulmonary resuscitation, may also impede blood return to the heart. For the fetus, insufficient uterine perfusion leads to hypoxia and uncompensated acidemia. As a rule, the quicker the response to cardiopulmonary collapse, the more successful cardiopulmonary efforts may be. Management of a cardiac arrest is described in Chapter 7 (p. 103). Also, the reader is referred to the detailed consensus statement from the Society for Obstetric Anesthesia and Perinatology (Lipman, 2014).

In many of these situations, an emergent cesarean delivery is justified for both maternal and fetal well-being. For the mother, delivery may improve some physiologic parameters. For the fetus, intact neonatal survival is optimized if the fetus is delivered within 5 minutes of cardiac arrest. Cesarean delivery is problematic and difficult to achieve in this timeframe. In one review, Einav and colleagues (2012) reported that the average time to delivery in neonatal survivors was 14 minutes, and it was 22 minutes for nonsurvivors.

The logistics of perimortem cesarean delivery are described in Chapter 7 (p. 106). Notably, precious moments should not be lost preparing a sterile field or moving the woman to an operating room. A bedside delivery can easily be accomplished with a scalpel. Because the patient may survive the event, an operator should avoid unnecessary damage to the bowel and bladder, and some degree of hemostasis should be obtained.

REFERENCES

- Abalos E: Effect of timing of umbilical cord clamping of term infants on maternal and neonatal outcomes: RHL commentary. World Health Organization. 2009. Available at: http://apps.who.int/rhl/pregnancy_childbirth/childbirth/3rd_stage/cd004074_abalose_com/en/. Accessed January 21, 2016
- Alexander JM, Leveno KJ, Hauth J: Fetal injury associated with cesarean delivery. *Obstet Gynecol* 108:885, 2006
- Alhabe F, Sosa C, Belizan JM, et al: Cesarean section rates and maternal and neonatal mortality in low-, medium-, and high-income countries: an ecological study. *Birth* 33:270, 2006
- Al-Wassia H, Shah P: Efficacy and safety of umbilical cord milking at birth: a systematic review and meta-analysis. *JAMA Pediatr* 169:18, 2015
- American Academy of Pediatrics and the American College of Obstetricians and Gynecologists: Guidelines for Perinatal Care, 7th ed. Washington, AAP and ACOG, 2012
- American College of Obstetricians and Gynecologists: External cephalic version. Practice Bulletin No. 161, February 2016
- American College of Obstetricians and Gynecologists: Nonmedically indicated early-term deliveries. Committee Opinion No. 561, April 2013, Reaffirmed 2015a
- American College of Obstetricians and Gynecologists: Operative vaginal delivery. Practice Bulletin No. 154, November 2015b
- American College of Obstetricians and Gynecologists: Vaginal birth after previous cesarean delivery. Practice Bulletin No. 115, August 2010, Reaffirmed 2015c
- American College of Obstetricians and Gynecologists (College); Society for Maternal-Fetal Medicine, Caughey AB, et al: Safe prevention of the primary cesarean delivery. *Am J Obstet Gynecol* 210(3):179, 2014a
- American College of Obstetricians and Gynecologists: Timing of umbilical cord clamping after birth. Committee Opinion No. 543, December 2012, Reaffirmed 2014b
- Andersson O, Hellström-Westas L, Andersson D, et al: Effect of delayed versus early umbilical cord clamping on neonatal outcomes and iron status at 4 months: a randomised controlled trial. *BMJ* 343:d7157, 2011
- Andersson O, Hellström-Westas L, Andersson D, et al: Effects of delayed compared with early umbilical cord clamping on maternal postpartum hemorrhage and cord blood gas sampling: a randomized trial. *Acta Obstet Gynecol Scand* 92(5):567, 2013
- Bailit J: Impact of non-clinical factors on primary cesarean deliveries. *Semin Perinatol* 36:395, 2012
- Barber EL, Lundsberg LS, Belanger K, et al: Indications contributing to the increasing cesarean delivery rate. *Obstet Gynecol* 118:29, 2011
- Bastani P, Pourabolghasem S, Abbasalazadeh F, et al: Comparison of neonatal and maternal outcomes associated with head-pushing and head-pulling methods for impacted fetal head extraction during cesarean delivery. *Int J Gynaecol Obstet* 118(1):1, 2012
- Bolze PA, Massoud M, Gaucherand P, et al: What about the Misgav-Ladach surgical technique in patients with previous cesarean sections? *Am J Perinatol* 30(3):197, 2013
- Boyle A, Reddy U: Epidemiology of cesarean delivery: the scope of the problem. *Semin Perinatol* 36:308, 2012
- Bujold E, Bujold C, Hamilton EF, et al: The impact of a single-layer or double closure on uterine rupture. *Am J Obstet Gynecol* 186: 1326, 2002
- CAESAR study collaborative group: Cesarean section surgical techniques: a randomised factorial trial (CAESAR). *BJOG* 117:1366, 2010
- Center for Healthcare Quality and Payment Reform: How to save \$5 billion in healthcare spending for employers and taxpayers. 2013. Available from: <http://chqpr.org/blog/index.php/2013/01/how-to-save-5-billion-in-healthcare-spending-for-employers-and-taxpayers/>. Accessed December 5, 2015
- Chauhan SP, Ananth CV: Induction of labor in the United States: a critical appraisal of appropriateness and reducibility. *Semin Perinatol* 36:336, 2012
- Cheong YC, Premkumar G, Metwally M, et al: To close or not to close? A systematic review and a meta-analysis of peritoneal non-closure and adhesion formation after cesarean section. *Eur J Obstet Gynaecol Reprod Biol* 147:3, 2009
- Clark EA, Silver RM: Long-term maternal morbidity associated with repeat cesarean delivery. *Am J Obstet Gynecol* 205:S2, 2011
- Clark SL, Belfort MA, Dildy GA, et al: Maternal death in the 21st century: causes, prevention, and relationship to cesarean delivery. *Am J Obstet Gynecol* 199:36.e1, 2008
- Clark SL, Miller DD, Belfort MA, et al: Neonatal and maternal outcomes associated with elective term delivery. *Am J Obstet Gynecol* 200:156.e1, 2009
- CORONIS Collaborative Group, Abalos E, Addo V, et al: Cesarean section surgical techniques (CORONIS): a fractional, factorial, unmasked, randomised controlled trial. *Lancet* 382:234, 2013
- Creanga AA, Berg CJ, Syverson C, et al: Pregnancy-related mortality in the United States, 2006–2010. *Obstet Gynecol* 125:5, 2015
- Cromi A, Ghezzi F, DiNaro E, et al: Blunt expansion of the low transverse uterine incision at cesarean delivery: a randomized comparison of 2 techniques. *Am J Obstet Gynecol* 199:292.e1, 2008
- Cunningham FG, Bangdiwala S, Brown SS, et al: National Institutes of Health consensus development conference statement on vaginal birth after cesarean: new insights. *NIH Consensus State Sci Statements* 27(3):1, 2010
- Dahlke JD, Mendez-Figueroa H, Rouse DJ, et al: Evidence-based surgery for cesarean delivery: an update systematic review. *Am J Obstet Gynecol* 209: 294, 2013
- Dodd JM, Anderon ER, Gates S, et al: Surgical techniques for uterine incision and uterine closure at the time of cesarean section. *Cochrane Database Syst Rev* 7:CD004732, 2014
- Durnwald C, Mercer B: Uterine rupture, perioperative and perinatal morbidity after single-layer and double-layer closure at cesarean delivery. *Am J Obstet Gynecol* 189:925, 2003
- Einav S, Kaufman N, Sela HY: Maternal cardiac arrest and perimortem cesarean delivery: evidence or expert-based? *Resuscitation* 83: 1191, 2012
- Encarnacion B, Zlatnik MG: Cesarean delivery technique: evidence or tradition? A review of the evidence-based cesarean delivery. *Obstet Gynecol Surv* 67:483, 2012
- Friedman EA: Primigravid labor: a graphicostastical analysis. *Obstet Gynecol* 6:567, 1955
- Gao Y, Xue Q, Chen G, et al: An analysis of the indications for cesarean section in a teaching hospital in China. *Eur J Obstet Gynaecol Reprod Biol* 170: 414, 2013
- Gibbons L, Belizan JM, Lauer JA, et al: The global numbers and cost of additionally needed and unnecessary cesarean sections performed per year: overuse as a barrier to universal coverage. World Health Report Background Paper, No. 30, Geneva, World Health Organization, 2010
- Grobman WA: Predictors of induction success. *Semin Perinatol* 36:344, 2012
- Gungor S, Kurt E, Teksoz E, et al: Oronasopharyngeal suction versus no suction in normal and term infants delivered by elective cesarean section: a prospective randomized controlled trial. *Gynecol Obstet Invest* 61(1):9, 2006
- Güngördük K, Yildirim G, Ark C: Is routine cervical dilatation necessary during elective cesarean section? A randomised controlled trial. *Aust N Z J Obstet Gynaecol* 49(3):263, 2009
- Hanley GE, Janssen PA, Greyson D: Regional variation in the cesarean delivery and assisted vaginal delivery rates. *Obstet Gynecol* 115: 1201, 2010
- Hannah ME, Hannah WJ, Hewson SA, et al: Planned cesarean section versus planned vaginal birth for breech presentation at term: a randomised multicentre trial. Term Breech Trial Collaborative Group. *Lancet* 356:1375, 2000
- Harper LM, Caughey AB, Odibo AO, et al: Normal progress of induced labor. *Obstet Gynecol* 119(6):1113, 2012
- Harris JW: A study of the results obtained in sixty-four cesarean sections terminated by supravaginal hysterectomy. *Bull Johns Hopkins Hosp* 33:318, 1922
- Hofmeyr GJ, Mathai M, Shah A, et al: Techniques for cesarean section. *Cochrane Database Syst Rev* 1:CD004662, 2008
- Hofmeyr JG, Novikova N, Mathai M, et al: Techniques for cesarean section. *Am J Obstet Gynecol* 201(5):431, 2009
- Holmgren G, Sjöholm L, Stark M: The Misgav Ladach method for cesarean section: method description. *Acta Obstet Gynecol Scand* 78(7):615, 1999
- Iriye BK, Huang WH, Condon J, et al: Implementation of a laborist program and evaluation of the effect upon cesarean delivery. *Am J Obstet Gynecol* 209:251.e1, 2013
- Jeve YB, Navti OB, Konje JC: Comparison of techniques used to deliver a deeply impacted fetal head at full dilation: a systematic review and meta-analysis. *BJOG* 123(3):337, 2016
- Katrwinkel J, Perlman JM, Aziz K, et al: Part 15: neonatal resuscitation: 2010 American Heart Association Guidelines for Cardiopulmonary Resuscitation and Emergency Cardiovascular Care. *Circulation* 122(18 Suppl 3):S909, 2010
- Kerr JM: The technique of cesarean section with special reference to the lower uterine segment incision. *Am J Obstet Gynecol* 12:729, 1926
- Kominiarek MA, VanVeldhuisen P, Hibbard J, et al: The maternal body mass index: a strong association with delivery route. *Am J Obstet Gynecol* 203:264.e1, 2010
- Landon MB, Hauth J, Leveno KJ, et al: Maternal and perinatal outcomes associated with a trial of labor after prior cesarean delivery. *N Engl J Med* 351:25, 2004
- Liabsuetrakul T, Peeyanjanarassri K: Mechanical dilatation of the cervix at non-labour cesarean section for reducing postoperative morbidity. *Cochrane Database Syst Rev* 11:CD008019, 2011

- Lipman S, Cohen S, Einav S, et al: The Society for Obstetric Anesthesia and Perinatology consensus statement on the management of cardiac arrest in pregnancy. *Anesth Analg* 118:1003, 2014
- MacDorman M, DeClercq E, Menacker F: Recent trends and patterns in cesarean and vaginal birth after cesarean (VBAC) deliveries in the United States. *Clin Perinatol* 38:179, 2011
- Mackeen AD, Schuster M, Berghella V: Suture versus staples for skin closure after cesarean: a metaanalysis. *Am J Obstet Gynecol* 212:621.e1, 2015
- Marrs CC, Moussa HN, Sibai BM, et al: The relationship between primary cesarean delivery skin incision type and wound complications in women with morbid obesity. *Am J Obstet Gynecol* 210:319.e1, 2014
- Marshall NE, Fu R, Guise JM: Impact of multiple cesarean delivery on maternal morbidity: a systematic review. *Am J Obstet Gynecol* 205:262.e1, 2011
- Martin MA, Hamilton BE, Osterman MJ, et al: Births: final data for 2013. *64(1):1*, 2015
- Maso G, Piccoli M, Montico M, et al: Interinstitutional variation of cesarean delivery rates according to indications in selected obstetric populations: a prospective multicenter study. *Biomed Res Int* 2013:786563, 2013
- Mathai M, Hofmeyr GJ, Mathai NE: Abdominal surgical incisions for cesarean section. *Cochrane Database Syst Rev* 5:CD004453, 2013
- McAdams RM: Time to implement delayed cord clamping. *Obstet Gynecol* 123(3):549, 2014
- McDonald SJ, Middleton P, Dowswell T, et al: Effect of timing of umbilical cord clamping of term infants on maternal and neonatal outcomes. *Cochrane Database Syst Rev* 7:CD004074, 2013
- Miller JM: First successful cesarean section in the British Empire. *Am J Obstet Gynecol* 166:269, 1992
- Nijagal MA, Kuppermann M, Nakagawa S, et al: Two practice models in one labor and delivery unit: association with cesarean delivery rates. *Am J Obstet Gynecol* 212:491.e1, 2015
- Office of Disease Prevention and Health Promotion: Healthy people: maternal, infant, and child health. 2014. Available at: <http://www.healthypeople.gov/2020/topics-objectives/topic/maternal-infant-and-child-health/objectives>. Accessed December 5, 2015
- Organisation for Economic Cooperation and Development: Data: health care use: cesarean sections. 2016. Available from: <https://data.oecd.org/healthcare/caesarean-sections.htm>. Accessed January 21, 2016
- Pandit SN, Khan RJ: Surgical techniques for performing cesarean section including CS at full dilation. *Best Pract Res Clin Obstet Gynaecol* 27(2):179, 2013
- Pearce C, Torres C, Stallings S, et al: Elective appendectomy at the time of cesarean delivery: a randomized controlled trial. *Am J Obstet Gynecol* 199:491.e1, 2008
- Queenan JT, Nakamoto M: Postpartum immunization: the hypothetical hazard of manual removal of the placenta. *Obstet Gynecol* 23:392, 1964
- Rabe H, Diaz-Rossello JL, Duley L, et al: Effect of timing of umbilical cord clamping and other strategies to influence placental transfusion at preterm birth on maternal and infant outcomes. *Cochrane Database Syst Rev* 8:CD003248, 2012
- Roberge S, Chaillet N, Boutin A, et al: Single- versus double-layer closure of the hysterotomy incision during cesarean delivery and risk of uterine rupture. *Int J Gynecol Obstet* 115:5, 2011
- Roberge S, Demers S, Berghella V, et al: Impact of single- versus double-layer closure on adverse outcomes and uterine scar defect: a systematic review and metaanalysis. *Am J Obstet Gynecol* 210:453, 2014
- Rouse DJ, Weiner SJ, Bloom SL, et al: Failed labor induction: toward an objective diagnosis. *Obstet Gynecol* 117:267, 2011
- Saad AF, Rahman M, Costantine MM, et al: Blunt versus sharp uterine incision expansion during low transverse cesarean delivery: a metaanalysis. *Am J Obstet Gynecol* 211:683.e1, 2014
- Saenger M: Der Kaiserschnitt bei Uterusfibromen nebst vergleichender Methodik der Sectio Caesarea und der Porro—Operation. Leipzig, 1882
- Sewell JE: Cesarean Section: A Brief History. Washington, American College of Obstetricians and Gynecologists, 1993
- Sharma SK, McIntire DD, Wiley J, et al: Labor analgesia and cesarean delivery: an individual patient meta-analysis of nulliparous women. *Anesthesiology* 100:142, 2004
- Shi Z, Ma L, Yang Y, et al: Adhesion formation after previous cesarean section: a meta-analysis and systematic review. *BJOG* 118:410, 2011
- Silver RM: Implications of the first cesarean: perinatal and future reproductive health and subsequent cesareans, placenta issues, uterine rupture risk, morbidity, and mortality. *Semin Perinatol* 36:315, 2012
- Silver RM, Landon MD, Rouse DJ, et al: Maternal morbidity associated with multiple repeat cesarean deliveries. *Obstet Gynecol* 107:1226, 2006
- Society for Maternal-Fetal Medicine, Belfort MA: Placenta accreta. *Am J Obstet Gynecol* 203(5):430, 2010
- Sommers R, Stonestreet BS, Oh W, et al: Hemodynamic effects of delayed cord clamping in premature infants. *Pediatrics* 129(3):e667, 2012
- Speert H: Eduardo Porro and cesarean hysterectomy. *Surg Gynecol Obstet* 106:243, 1958
- Spong CY, Berghella V, Wenstrom KD, et al: Preventing the first cesarean delivery: summary of a joint Eunice Kennedy Shriver National Institute of Child Health and Human Development, Society for Maternal-Fetal Medicine, and American College of Obstetricians and Gynecologists Workshop. *Obstet Gynecol* 120(5):1181, 2012
- Stjernholm YV, Peterson K, Eneroth E: Changed indications for cesarean sections. *Acta Obstet Gynecol Scand* 89:49, 2010
- Taljaard M, Donner A, Villar J, et al: Understanding the factors associated with differences in cesarean section rates at hospital level: the case of Latin America. *Paediatr Perinat Epidemiol* 23:574, 2009
- Thompson S: *Motif Index of Folk Literature*, 2nd ed. Bloomington, University Press, 1955
- Tita AT: Timing of elective repeat cesarean delivery at term and neonatal outcomes. *N Engl J Med* 360:111, 2009
- Tita AT, Lai W, Landon MB, et al: Timing of elective repeat cesarean delivery at term and maternal perioperative outcomes. *Obstet Gynecol* 117:280, 2011
- Truven Health Analytics MarketScan Study: The cost of having a baby in the United States. 2013. Available at: <http://transform.childbirthconnection.org/wp-content/uploads/2013/01/Cost-of-Having-a-Baby-Executive-Summary.pdf>. Accessed January 21, 2016
- Tuuli MG, Rampersad RM, Carbone JF, et al: Staples compared with subcuticular suture for skin closure after cesarean delivery: a systematic review and meta-analysis. *Obstet Gynecol* 117(3):682, 2011
- Upadhyay A, Gothwal S, Parihar R, et al: Effect of umbilical cord milking in term and near term infants: randomized control trial. *Am J Obstet Gynecol* 208(2):120.e1, 2013
- Veisi F, Zangeneh M, Malekghosravi S, et al: Comparison of “push” and “pull” methods for impacted fetal head extraction during cesarean delivery. *Int J Gynaecol Obstet* 118(1):4, 2012
- Villar J, Valladares E, Wojdyla D, et al: Cesarean delivery rates and pregnancy outcomes: the 2005 WHO global survey on maternal and perinatal health in Latin America. *Lancet* 367:1819, 2006
- Viney R, Isaacs C, Chelmsow D: Intra-abdominal irrigation at cesarean delivery: a randomized controlled trial 110:1106 2012
- Walfisch A, Beloosesky R, Shrim A, et al: Adhesion prevention after cesarean delivery: evidence and lack of it. *Am J Obstet Gynecol* 210:446, 2014
- Walsh CA, Walsh SR: Extraabdominal vs intraabdominal uterine repair at cesarean delivery: a metaanalysis. *Am J Obstet Gynecol* 200:625.e1, 2009
- Werner EF: Cost matters. *Obstet Gynecol* 123:919, 2014
- Young JH: *The History of Cesarean Section*. London, H.K. Lewis, 1944
- Zhang J, Landy HJ, Branch DW, et al: Contemporary pattern of spontaneous labor with normal neonatal outcomes. *Obstet Gynecol* 116:1281, 2010

CHAPTER 26

Peripartum Hysterectomy

HISTORY	419
INCIDENCE	420
CLASSIFICATION	420
RISK FACTORS	421
INDICATIONS	421
SURGICAL PROCEDURE	423
OPERATIVE TECHNIQUE	424
COMPLICATIONS	430
SUMMARY	433

Peripartum hysterectomy refers to surgical removal of the pregnant or recently pregnant uterus. Most procedures follow delivery and are prompted by pregnancy or delivery complications. However, the term also includes hysterectomy with the pregnancy in situ, which is much less frequently performed. Radical hysterectomy early in the second trimester for cervical cancer is one example.

This chapter focuses on peripartum hysterectomy including cesarean hysterectomy and postpartum hysterectomy. These procedures are indispensable for management of intractable obstetric hemorrhage unresponsive to other treatment. In the puerperium, advanced uterine infection with necrosis is another indication.

Peripartum hysterectomy frequently is lifesaving and should be within the capabilities of all obstetric consultants. That said, hysterectomy in these circumstances can be a formidable operation, particularly when performed for a life-threatening

emergency. Skills necessary for its performance are best acquired from an experienced mentor.

HISTORY

■ Pre-Porro Era

Prior to the 19th century, cesarean delivery was uniformly fatal. Thus, peripartum hysterectomy was developed in the late 18th century to improve survival rates. Until that time, bleeding and infections were untreatable complications. Anesthetics were limited, and surgical antisepsis was virtually nonexistent. Moreover, most surgeons lacked the expertise to perform such massive pelvic surgery. Unfortunately, many graduating obstetrician-gynecologists also lack the technical skills needed to perform this operation, and thus further mentoring is essential.

The evolution of peripartum hysterectomy can be divided into epochs before and after the description of hysterectomy technique by Eduardo Porro in 1876. Until the early 20th century, pelvic deformities from nutritional deficiencies or infectious diseases were common. Examples are rickets (rickets) from vitamin D deficiency and tuberculosis. Women in that era had no reliable contraception, and mothers with a very small or distorted pelvis often labored to exhaustion and died along with their fetus. Some attendants used fetal destructive operations to attempt to save the mothers, who often had extensive pelvic soft tissue injuries if they survived.

Joseph Cavallini of Florence developed the concepts that enabled the development of obstetric hysterectomy. In 1768, he disproved the prevailing idea that the uterus was an essential organ for life by removing the uterus successfully in pregnant and nonpregnant animals (Durfee, 1969). Investigators in Germany and England in the early 1800s concluded that abdominal delivery in animals was less dangerous if they removed the uterus after delivery (Young, 1944). These experiments prepared the way for safe cesarean delivery and for obstetric hysterectomy.

The earliest documented human peripartum hysterectomy was performed in 1868 by Horatio Robinson Storer of Boston (Bixby, 1869). Storer was among the first specialists in diseases of women, and he was confronted by a woman whose labor was obstructed by a large uterine tumor. The baby was already dead, but the tumor prevented any fetal destructive procedures. Using chloroform for anesthesia, Storer performed cesarean delivery, and because of life-threatening hemorrhage, he removed the uterus with its “fibrocystic tumor the size of a baby’s head.” Ligatures around the cervix and the tumor pedicle controlled bleeding. The cervical stump was seared with a hot iron and returned to the pelvis, after which the abdominal wound was closed with silver wire. Unfortunately, the woman died 3 days later.

■ Eduardo Porro Era

In 1876, Porro published the first case report to describe a woman who survived hysterectomy after cesarean delivery. For this reason, some clinicians still refer to cesarean hysterectomy as the *Porro operation*. Porro had previously performed an emergency cesarean delivery in a woman with obstructed labor from a rachitic pelvis. Although she had died, he was determined to prove the safety of cesarean delivery and repeatedly rehearsed cesarean hysterectomy in an animal laboratory.

In his report, Porro carefully followed 19th-century surgical principles and techniques. The amphitheater was heated to a precise 18°C. The surgeons washed their hands with dilute carbolic acid. Chloroform anesthesia was induced, and a 12-cm vertical midline infraumbilical incision was made. A vertical uterine incision allowed delivery of a 3300-g female by version and extraction. Attempts at manual and suture control of bleeding after removal of the placenta were unsuccessful. He wrote: “It was providential that we had made all the preparations necessary for hysterectomy; otherwise the patient would surely have died.” An assistant elevated the uterus out of the abdominal wound. Porro slipped the wire noose of a Cintrat constrictor over the uterus and adnexa. The loop was tightened, and the uterus and adnexa were excised with a scalpel. He drained the cul-de-sac, treated the cervical stump with perchloride of iron, and exteriorized the Cintrat constrictor onto the abdominal wall. The abdominal wound was closed around these with silver wire mass sutures. The operation lasted 26 minutes.

The exteriorized constriction device was left on the cervical stump under dressings for 4 days. The wound sutures were removed on postoperative day 7. The ischemic cervical pedicle detached 7 days later. The woman left the hospital at 6 weeks.

■ Post-Porro Era

In 1880, Robert P. Harris reviewed the world literature on cesarean hysterectomy. He collected 50 cases from seven countries and reported a maternal mortality rate of 58 percent and a fetal survival rate of 86 percent. That same year, Isaac Taylor of New York performed the first Porro operation in the United States (Durfee, 1969). The woman survived the surgical procedure but died of a pulmonary embolism 3 weeks later. Soon after, Richardson (1878) reported the first maternal survival after a Porro operation in the United States. In 1884, Clement Godson reviewed a total of 134 cases. At that time, the most common

indication for surgery still was a contracted pelvis due to rickets. He reported a maternal mortality rate of 45 percent. Patients usually succumbed to hemorrhage, peritonitis, and septicemia.

European surgeons modified the Porro procedure in an attempt to reduce operative risks and to improve outcomes. Tait (1890) of England described the Tait-Porro operation that enjoyed increasing popularity. Thereafter and into the 1900s, as surgical and anesthetic techniques improved, indications for the procedure were expanded beyond absolute emergencies.

The extensive experiences with cesarean hysterectomy at Charity Hospital in New Orleans began in 1938 and were reported by Barclay (1970) and Mickal and associates (1969). Subsequent ongoing Charity Hospital experiences were described periodically thereafter with steadily improving outcomes (Bey, 1993; Gonsoulin, 1991; Plauché, 1981, 1983).

Most obstetricians reserved peripartum hysterectomy for life-threatening emergencies. Davis (1951) of Chicago, however, championed elective cesarean hysterectomy and cited a 20-percent incidence of hysterectomy in a series of 736 cesarean deliveries. Brenner and colleagues (1970) concluded that complications outweighed benefits if hysterectomy was performed for sterilization and that tubal ligation after either cesarean or vaginal delivery was safer.

Currently, enthusiasm for nonemergency peripartum hysterectomy varies by region across the United States. Most programs reserve peripartum hysterectomy for major obstetric emergencies, but some perform obstetric hysterectomy when indications for cesarean delivery coexist with gynecologic indications for hysterectomy (Shellhaas, 2009). Currently, there is no codified list of indications for peripartum hysterectomy (Dahlke, 2015).

INCIDENCE

The cited rates for peripartum hysterectomy vary widely and range from 4 to 25 per 10,000 births. By way of example, from the Maternal-Fetal Medicine Units Network, the frequency of cesarean hysterectomy in nearly 185,000 deliveries was 10.1 per 10,000 births (Shellhaas, 2009). The rate at Parkland Hospital during a 22-year period was 17 per 10,000 births (Hernandez, 2013). Evidence indicates that the frequency of obstetric hysterectomy has risen during the past 20 years (Kramer, 2013). One source is Nationwide Inpatient Sample, which totaled more than 56 million births in the United States from 1994 through 2007 (Bateman, 2012). From this database, the rate of peripartum hysterectomy increased 15 percent during these 14 years (Fig. 26-1). This rising rate likely reflects the increasing rates of cesarean delivery and associated complications in a subsequent pregnancy (Bateman, 2012; Bodelon, 2009; Flood, 2009; Orbach, 2011; Owolabi, 2013).

CLASSIFICATION

Obstetric hysterectomy classification considers the timing, indication, extent, and circumstances associated with each case. Hysterectomy can be classified as antepartum, peripartum, or postpartum (Table 26-1). Although peripartum hysterectomy follows cesarean delivery in 75 to 80 percent of cases, 20 to 25 percent are performed in women who have been delivered

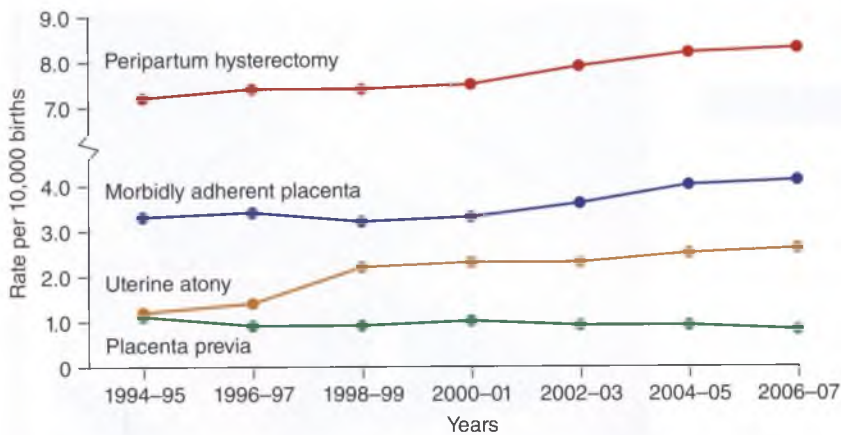


FIGURE 26-1 Changes in rate of peripartum hysterectomy from the Nationwide Patient Sample, United States, 1994–2007. (Data from Bateman BT, Mhyre JM, Callaghan WM, et al: Peripartum hysterectomy in the United States: nationwide 14 year experience. *Am J Obstet Gynecol* 2012; 206(1):63.e1.)

vaginally (Jakobsson, 2015). These operations can further be classified as supracervical, total, or radical and can involve removal of one or both adnexa. Of peripartum hysterectomies performed in this country, half to two thirds are total and the remaining cases are supracervical (Rossi, 2010; Shellhaas, 2009). Finally, each operation may be identified as an emergent, an indicated nonemergent, or an elective case. Only when all these factors are considered can valid conclusions be drawn regarding comparative risks and outcomes.

RISK FACTORS

An imposing list of factors that predispose to peripartum hysterectomy is found in Table 26-2. Many of these are maternal characteristics and antepartum features that can be identified and highlighted prior to delivery. One example is the *placenta accrete syndromes*, that is, placenta accreta, increta, and percreta, which are also known by the term *morbidly adherent placenta*. However, a significant number of factors are not evident or do not evolve until the time of labor and delivery. Thus, intrapartum surveillance for these risks is encouraged.

TABLE 26-1. Classification of Obstetric Hysterectomy

Antepartum Hysterectomy—Fetus in Situ

Subtotal—with or without adnexectomy
 Total—with or without adnexectomy
 Radical—with or without adnexectomy
 —with or without lymph node dissection

Peripartum Hysterectomy

Cesarean hysterectomy—after cesarean delivery

Subtotal—with or without adnexectomy
 Total—with or without adnexectomy

Postpartum hysterectomy—after vaginal delivery

Subtotal—with or without adnexectomy
 Total—with or without adnexectomy

Each classification may be further divided by indication into Emergent, Indicated Nonemergent, and Elective categories.

INDICATIONS

Some indications for obstetric hysterectomy are listed in Table 26-3. These are separated into procedures done for emergent indications and those performed for indicated nonemergent and elective operations.

Emergent Indications

As noted, the absolute rate of emergent peripartum hysterectomies is increasing. However, the proportions of indications for the operation have changed during the past 20 years. For example, arrest of hemorrhage remains the most common reason for obstetric hysterectomy. And, although the causes of hemorrhage have not changed over many decades, their individual contributions to cesarean hysterectomy rates now differ. Three examples are shown in Figure 26-1. Here, the rates of peripartum hysterectomy are increased for accrete syndromes and uterine atony, but not for placenta previa. During these times, morbidly adherent placenta has become much more common coincidental with the cesarean delivery rate. Cesarean delivery currently accounts for approximately one third of all births in

TABLE 26-2. Some Risk Factors for Peripartum Hysterectomy

Maternal characteristics

Obesity
 Great multiparity
 Uterine leiomyomas
 Advanced maternal age

Antepartum features

Hydramnios
 Preterm labor
 Placenta previa
 Multifetal pregnancy
 Preeclampsia syndrome
 Morbidly adherent placenta

Intrapartum factors

Coagulopathy
 Uterine atony
 Tocolytic use
 Uterine rupture
 Prolonged labor
 Labor induction
 Chorioamnionitis
 Cesarean delivery
 Placental abruption
 Cervical lacerations
 Operative vaginal delivery

From Bateman, 2012; Kramer, 2013; Owolabi, 2013; Rossi, 2010; Shellhaas, 2009.

TABLE 26-3. Some Indications for Peripartum Hysterectomy**Emergent Indications**

Placental disorders
 Placenta previa
 Placental abruption
 Morbidly adherent placenta
 Uterine atony
 Uterine rupture
 Traumatic
 Previous scar
 Previously intact
 Müllerian anomaly
 Multiple hysterotomy scars
 Cervical or uterine lacerations
 Uterine leiomyomas
 Puerperal sepsis—necrotic uterus

Indicated Nonemergent and Elective

Gynecologic disorders
 Uterine leiomyoma
 Cervical preinvasive neoplasia
 Genital tract malignancy
 Abdominal pregnancy

the United States (Chap. 25, p. 404). Thus, the relationship between cesarean delivery and a morbidly adherent placenta, coupled with the rise in cesarean delivery rates, helps explain the new contribution from the accrete syndromes.

The evolution of these contributory indications is instructive. In 1964, Bowman and associates reported that 55 percent of cesarean hysterectomies at Charity Hospital were done for postpartum hemorrhage, and two thirds of these were for uterine atony. Almost 30 years later, uterine atony was the indication for only 21 percent of emergent peripartum hysterectomies performed at Brigham and Women's Hospital (Zelop, 1993). At the same time, 64 percent of operations were done to control bleeding from a morbidly adherent placenta. This indication continues to be the most common in the United States, as shown in Figure 26-1. This has also been reported for several European countries (D'Arpe, 2015; Jakobsson, 2015).

At least before 1980, a commonly cited reason for postpartum hysterectomy was a disrupted prior hysterotomy scar. Although these indications included women with an overtly ruptured uterus, it also was contemporaneously acceptable to perform obstetric hysterectomy for a “defective uterine scar” in women with one or more prior cesarean deliveries. Indeed, in the earlier Charity Hospital series, almost half of hysterectomies were done for this indication (Plauché, 1981). Similarly, in a series of planned hysterectomies from private California hospitals, 28 percent were performed because of a defective uterine scar (McNulty, 1984). Today, although an occasional peripartum hysterectomy must be done for an irreparably damaged uterus from dehiscence of a prior uterine incision(s), this is no longer an accepted indication. Indeed, experience has accrued

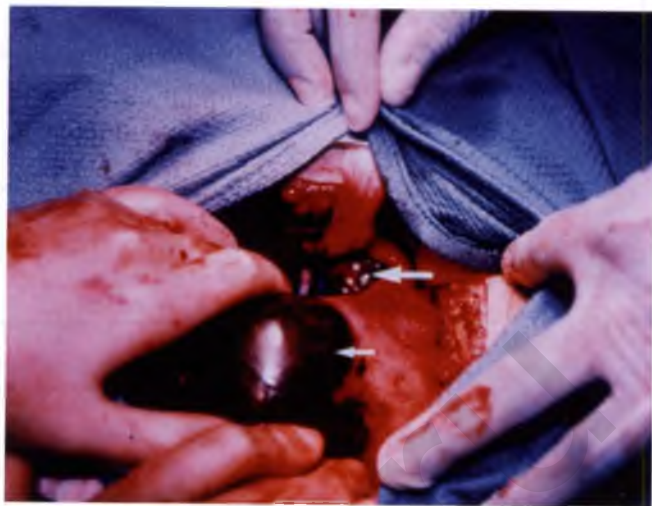

FIGURE 26-2 A fatal case of sepsis syndrome from uterine necrosis caused by group A β -hemolytic streptococcal infection. Arrows point to ballooned-out gangrenous areas seen at the time of hysterectomy. (Reproduced with permission from Cunningham FG, Leveno KJ, Bloom SL, et al (eds): Critical care and trauma. In Williams Obstetrics, 24th ed. New York, McGraw-Hill Education, 2014.)

that thin scars or those with minor separations may be safely repaired rather than performing hysterectomy.

Severe uterine infections that follow cesarean delivery occasionally will require hysterectomy for removal of necrotic tissue. These usually manifest as uterine incisional necrosis and may be associated with peritonitis. This complication is further described in Chapter 32 (p. 512). Particularly virulent are infections caused by group A beta-hemolytic *Streptococcus pyogenes* (Fig. 26-2).

■ Nonemergent Indications

Peripartum hysterectomy is more controversial when performed for reasons other than obstetric emergencies. These indicated but nonemergent procedures are performed when women requiring cesarean delivery also have a gynecologic disorder that would usually be managed by hysterectomy. These have been variously termed nonemergent, planned, or anticipated cesarean hysterectomies (Plauché, 1992b; Zelop, 1993). The rationale is to perform both cesarean delivery and hysterectomy with a single procedure.

Of indications, uterine leiomyomas and cervical intraepithelial neoplasia are common (Plauché, 1992b). In the previously mentioned report, McNulty (1984) reviewed a 10-year experience with 80 planned cesarean hysterectomies performed in eight California private hospitals. The most prevalent diagnoses in this series were uterine leiomyomas—25 percent; defective scars after previous cesarean deliveries—28 percent; other benign gynecologic conditions—25 percent; and pelvic malignancy—5 percent. These are similar to the British experience reported by Sturdee and Rushton (1986). In another report contemporaneous to those times, abnormal gynecologic bleeding was the indication in 34 percent and chronic pelvic pain in 32 percent (Yancey, 1993).

■ Elective Cesarean Hysterectomy

Completely elective obstetric hysterectomies have never been endorsed by most. This was true even in the era of relative permissiveness for the operation (McNulty, 1984; Mickal, 1969; Plauché, 1986). In earlier series, although sterilization was the ostensible indication for peripartum hysterectomy, none of these authors encouraged primary abdominal delivery to create opportunities for surgical sterilization by hysterectomy.

SURGICAL PROCEDURE

■ Preoperative Preparation

Prior to hysterectomy, evaluation includes careful assessment of the woman for complicating conditions, hemodynamic stability, and coagulation status. The availability of appropriate blood replacement products is paramount, and transfusion usually begins before surgery in unstable patients. This is described in detail in Chapter 29 (p. 468). In patients with antepartum indications and confirmed plans for cesarean hysterectomy, perioperative considerations include patient consent, laboratory testing, antibiotic prophylaxis, venous thromboembolism prevention, and anesthesia selection. These topics are covered extensively in Chapter 18 (p. 291).

The surgical team is assembled, and hemodynamic support and anesthetic technique are discussed. Details of the operation are reviewed with the team to ensure maximum efficiency. Instruments and sutures are chosen before the operation begins. Additionally, requests for special instrumentation should be addressed preoperatively to prevent potential patient compromise and intraoperative delays.

A single suture, such as no. 1 or 0 chromic or polyglactin 910 (Vicryl) suture anchored to a general closure needle, usually suffices for most phases of the operation. Selection of a single type and gauge of suture expedites the work of both surgeon and circulating nurse. Some surgeons favor chromic suture, which tends to cut less than Vicryl through edematous tissue or engorged veins. However, the longer half-life of Vicryl may provide longer support of the vaginal apex during the healing phase. No robust data support superiority of one suture material compared with the other.

■ General Considerations

Surgery can be performed through either a vertical or low transverse abdominal wall incision. The steps for these incisions and their specific advantages are outlined in Chapter 4 (p. 49). Adequate visualization of the operative field is essential, and the pregnant uterus often restricts general examination of the abdomen early in the case.

The fastest laparotomy method is the subumbilical midline vertical incision. It offers suitable exposure to explore the entire abdomen, provides access to the pelvic sidewalls, and is easily extended cephalad if greater operating space is needed. Also, this midline incision encounters fewer vessels and thus may be preferred for patients with comorbid disseminated intravascular coagulopathy.

Several anatomic and physiologic changes in gravidas increase the likelihood of intraoperative problems during hysterectomy.

First, the uterus is markedly enlarged and engorged, and pelvic blood vessels are wide-caliber and tortuous. Collateral vessels are similarly expanded. For this reason, rapid control of all vascular supply to the uterus is essential during hysterectomy. To assist, extra clamps are often necessary to avoid retrograde blood loss from severed blood vessels. As a reminder, when placing a clamp, the distal two thirds of most clamp jaws hold tissues and vessels with maximum security. Thus, positioning a clamp across too large of a tissue span increases the risk of tissue slippage and bleeding from escaped vessels. Another prudent practice is to manipulate clamps on vascular pedicles as little as possible. This also applies to clamps across pelvic tissues, which are typically edematous and more friable in gravidas than in nonpregnant women.

When clamped tissue pedicles are ligated, sutures may cut or tear through friable pedicles unless carefully secured. Thus, abrupt ligature cinching is avoided, but this is balanced against delayed cinching in which vessels can escape ligation and bleed. Also, pedicles shrink in size as edema subsides after delivery. Thus, single circumferential sutures may also allow vessels to escape control. Accordingly, some prefer double ligation of vascular pedicles. Moreover, use of a transfixing suture as the second distal ligature improves hemostatic control as edema subsides (Fig. 1-10, p. 13). Notably, hematomas can occasionally result if transfixing sutures are used alone without an initial circumferential proximal tie. Last, all pedicles should be inspected several times for hemostasis before the procedure's end.

Clamps should be supported, not manipulated, during suture placement. Traction or twisting of clamps on vascular pedicles may strip pedicles away from adjacent tissues. This opens blood vessels that are difficult to clamp and suture without injury to nearby structures, particularly the ureter, bladder, and adnexa.

The bulky uterus is usually difficult to manipulate during obstetric surgery. Moreover, it often cannot be safely manipulated by means of clamps across friable adnexal structures at the cornua. In these cases, a tumor tenaculum placed on the uterine fundus is an efficient traction device. A finger in the apex of a vertical hysterotomy incision can also provide effective traction and manipulation. This maneuver, combined with handheld retractors—Deaver or Richardson—provides adequate exposure during the early stages of the operation.

The bladder wall may have become edematous and friable during labor. This may render it vulnerable to injury by blunt dissection. Handheld retractors that are swept from side to side under tension can also injure the bladder. Thus, assistants are encouraged to release traction before repositioning bladder retractors. A laparotomy sponge placed between the retractor blade and the bladder can also help avoid damage.

In some women with one or more prior cesarean deliveries, dense adhesions may fill the vesicouterine space between the bladder and the lower uterine segment. In these cases, if cesarean hysterectomy is planned, the bladder reflection is ideally carried down to the level of the cervix before the uterine incision is made. This time spent prior to hysterotomy and initiation of hysterectomy can help avoid cystotomy and substantial blood loss, which often accrues during tedious dissection in a blood-filled field. Metzenbaum scissors with the curve turned downward, away from the bladder, may best accomplish this meticulous sharp dissection. When blunt dissection is required, a Kittner

dissector sponge or rolled umbilical tape in the tip of a Kelly clamp can be used with small, focused movements. It is important to avoid gross rolling or pushing motions with large sponges.

Bladder injuries are sometimes difficult to identify, but can lead to subsequent vesicovaginal fistula formation if undetected and unrepaired. One method used to confirm bladder integrity uses sterile colored or opaque solutions to fill the bladder and then search for small or hidden perforations of the bladder wall. Many find that infant formula from presterilized plastic nursery bottles is ideal. The circulating nurse attaches a milk-filled, 60-mL syringe to the urethral catheter and fills the bladder repeatedly to instill 200 to 300 mL of formula. As the bladder fills, milk is easily seen flowing from small defects in the bladder wall. Milk can be used repeatedly during a case because it does not stain tissues. If not available, methylene blue is a suitable dye to mix with saline for bladder filling. Indigo carmine was another popular choice, but current nationwide shortages limit its use now. Once identified, bladder defects are repaired promptly using a two-layer closure with absorbable suture as described and illustrated in Chapter 28 (p. 456).

The bladder and the ureter may be damaged or displaced by trauma, hematomas, or pelvic tumors. Recall that during pregnancy the ureter is dilated and sluggish. Its proximity should be observed at all phases of the operation. If there is any question of its safety, dissection to delineate its course is recommended. If necessary, an intentional cystotomy can be used to open the dome of the bladder. Following intravenous injection of methylene blue or indigo carmine dye, blue fluid jets should appear from both ureteral orifices within minutes. Notably, in the volume-depleted patient, jets may be delayed. If ureteral integrity remains in question, retrograde ureteral catheters can be inserted into the ureteral orifices under direct visualization to ensure ureteral integrity and outline their course. Any identified ureteral injury should be repaired and supported by standard methods along with expert intraoperative consultation (Chap. 28, p. 457). Also, in cases with sonographic findings that strongly suggest bladder invasion by the placenta, we often position the patient in low lithotomy position in booted support stirrups. This allows access to the perineum for stent placement and cystoscopy as needed.

As with the other tissues encountered, the vaginal wall in pregnancy is particularly friable and edematous. This is especially so in laboring women. Thus, extreme traction on clamps attached to the vagina may lacerate these tissues. The vaginal wall is also thickened and vascular in the gravida. Thus, bleeding at the vaginal cuff can be brisk following amputation of the uterus and cervix from the vagina. This poses greater risks for postoperative bleeding and for cuff hematoma if the cuff is not hemostatic at the case's end. Infected hematomas may suppurate to form cuff abscesses. These complications can often be avoided by incorporating all vaginal layers in the cuff closure.

Throughout surgery, meticulous hemostatic and aseptic technique reduce infectious complications. Perioperative prophylactic antimicrobials are recommended for all of these women (Chap. 18, p. 295). In grossly infected cases, the skin and subcutaneous tissues may be left open under surgical dressings. Delayed closure after several days of antimicrobial treatment reduces the risk of wound suppuration and dehiscence (Chap. 32, p. 509).

OPERATIVE TECHNIQUE

More than one approach is available to complete peripartum hysterectomy. In some cases, the surgeon's preference determines the method of choice. In others—for example, placenta accreta—the approach depends on the distorted uteroplacental anatomy. Technique may further vary depending on whether the hysterectomy is planned and whether the fetus has already been delivered. Many of the earlier descriptions concerning techniques for peripartum hysterectomy came from experiences gained at Charity Hospital at New Orleans on both the Tulane and Louisiana State University Obstetric Services. Probably the most common approach taken today is the *concurrent ligation technique*. This technique is a variant of the *delayed ligation technique*. Finally, the *tourniquet method* is sometimes needed.

■ Concurrent Ligation Technique

This technique contains the familiar steps used for traditional gynecologic abdominal hysterectomy. Each vascular and tissue pedicle is ligated as it is developed. The concurrent technique is most useful in complicated cases when hematomas, myomas, or placenta accrete syndromes obscure or distort anatomic relationships. The technique is applicable to either elective or emergent peripartum hysterectomy. Compared with the delayed ligation technique, concurrent ligation has the disadvantage in elective cases of taking longer to control all the blood supply to the uterus.

Cesarean Delivery Completion

To begin, cesarean delivery is performed as usual and described in Chapter 25 (p. 406). If hysterectomy is planned, the incision in the vesicouterine fold is extended to meet each round ligament at a point 2 to 3 cm from the uterine wall. Development of the vesicouterine space is also carried down to the cervix at this time. Following this, hysterotomy is performed, preferably using a classical uterine incision. After delivery of the neonate and placenta, the edges of the vertical incision are approximated with three or four towel clips. Some choose to apply several Pennington clamps for hemostasis. A third but more time-consuming method is to approximate the uterine incisional edges with a mass running suture. Any of these techniques will help to achieve hemostasis and provide for better visualization. Closure of the incision will also reduce lochia spill.

Opening the Broad Ligament

The hysterectomy is started from either side by opening the anterior leaf of the broad ligament. If the left side is addressed first, the left round ligament is divided between straight or curved Ochsner (Kocher) clamps placed 2 and 3 cm from the uterus (Fig. 26-3). This step opens the retroperitoneal space to allow identification of the ureter. It also provides later access to uterine vessels for ligation. The round ligament pedicle includes Sampson artery that courses parallel to the round ligament. Thus, the distal round ligament pedicle is doubly ligated. The suture can be tagged and held for traction and identification. Or, it may be cut to minimize instrument clutter and potential tissue tearing from unmonitored traction.

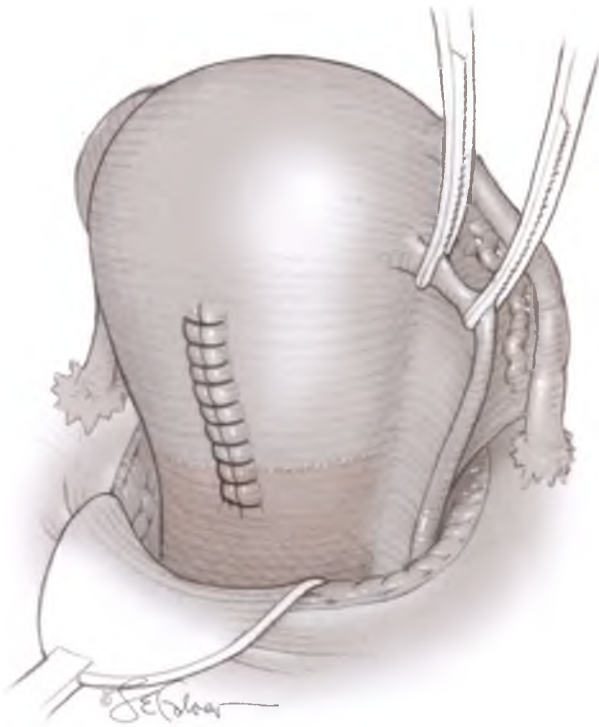


FIGURE 26-3 The round ligament is grasped with Ochsner or Kelly clamps and subsequently divided. This step provides access to the retroperitoneum.

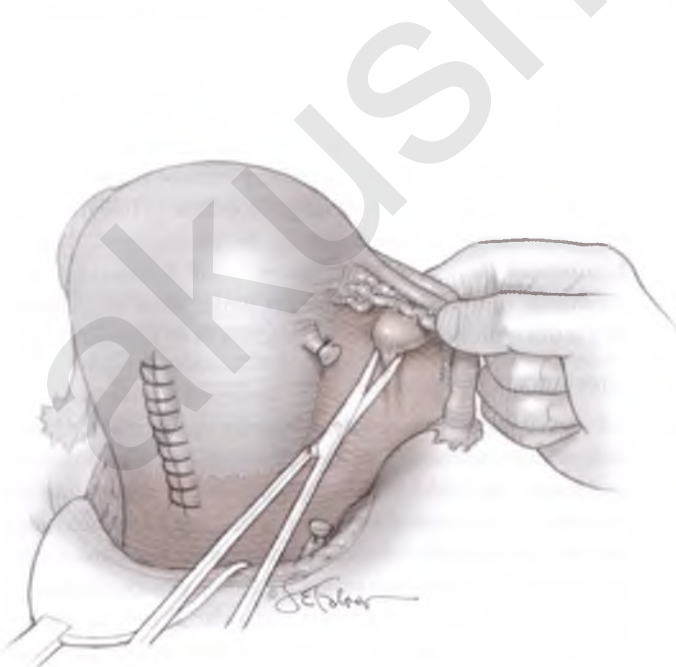
Next, an avascular window in the left broad ligament is identified and a curved Kelly (pean) clamp is pushed through the chosen site. Alternatively, pressure from the surgeon's index finger can create tension across an avascular portion on the broad ligament. Metzenbaum scissors can then incise

the tented broad ligament (Fig. 26-4). The scissor blades are inserted into the created rent and are opened to enlarge the aperture. This permits the fallopian tube and uteroovarian ligament to be isolated for ligation as a part of ovarian preservation. Notably, this opening should lie relatively high within the broad ligament. This allows a clamp to accommodate the width of both tube and uteroovarian ligaments without fear of either structure slipping from the clamp heel.

Both the tube and uteroovarian ligaments have prominent supplying vasculature. To prevent bleeding from the proximal stumps of the soon-to-be-severed tube and uteroovarian ligament, an Ochsner clamp is positioned to encompass these two adnexal structures near the uterus (Fig. 26-4B). The phrase "back bleeding" is a general term that describes flow from a proximal pedicle, and the blood derives from the extensive collateral circulation of the uterus. One remembers that the uterus is served by both uterine arteries and the uterine branches of both ovarian arteries.

An additional Ochsner clamp is placed across the uteroovarian ligament and fallopian tube at a point 1 cm lateral to the proximal clamp. The tips of both Ochsner clamps lie within the opening in the broad ligament to ensure control of all blood vessels.

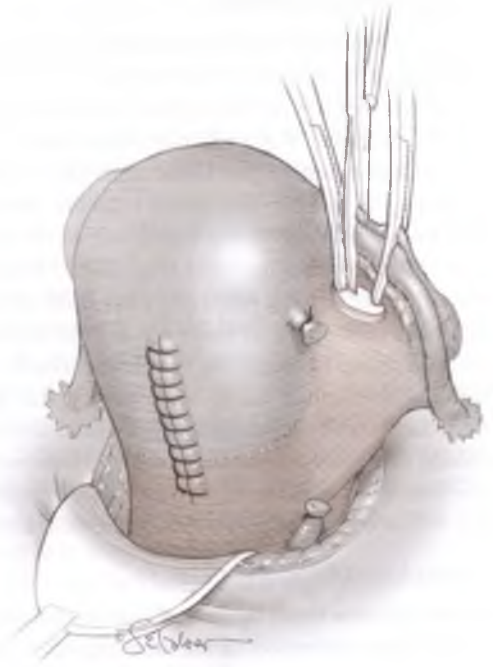
The pedicle containing the uteroovarian ligament and tube is then divided. This adnexal pedicle receives two sutures, namely, a free tie and then a transfixing stitch. For this, a free tie is placed beneath the toe and heel of the lateral clamp. This suture is tied. The second ligature is distal to the first and typically incorporates a stitch through the tissue pedicle. By transfixing the ligature to the pedicle, a surgeon decreases the risk of the suture slipping off the pedicle's end. Importantly, this second ligature is placed distal to the first to avert hematoma formation if a vessel is pierced during transfixion. After passing through



A

FIGURE 26-4 A. An index finger tents the broad ligament beneath and in close proximity of the uteroovarian ligament and fallopian tube.

Once tented, the broad ligament is sharply or bluntly incised. **B.** Two heavy clamps are placed across the fallopian tube and the uteroovarian ligament, and their tips enter the created broad ligament window. One clamp is placed close to the cornua to limit back bleeding. The other is placed 2 to 3 cm lateral to the first. The pedicle between these clamps is then sharply divided and ligated.



B

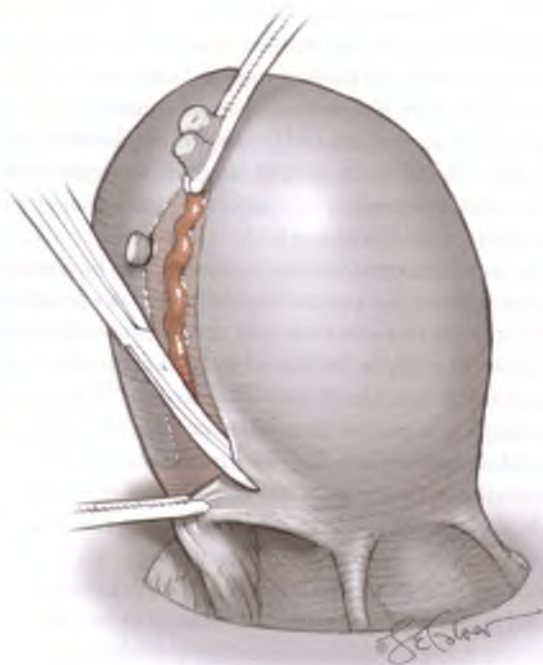


FIGURE 26-5 Incision of the broad ligament's posterior leaf helps to isolate the uterine vessels. This practice also drops the ureter further laterally and away from clamping injury.

the pedicle, suture strands sweep forward, cross in front of the clamp toe, are directed around their respective side of the clamp, and are tied at the heel as the assistant removes the clamp.

Uterine Vessel Isolation

Once the ovarian artery's contribution to the uterus is ligated, attention next moves to the uterine vessels. The left uterine vessels are exposed as the assistant retracts the uterus upward and to the right. This pulls the uterus away from the ureter. The posterior leaf of the broad ligament is incised medially beginning at the previous broad ligament opening. The incision progresses close to the lateral side of the uterus and ends near the uterosacral ligament (Fig. 26-5). This step drops the ureter further into the pelvis and away from clamping injury. It also removes extraneous tissue around the uterine vessels. This allows a clamp to secure the vessels and avoids vessels slipping from an overstuffed clamp. Also toward this goal, a surgeon may dissect away loose connective tissue around the uterine vessels, in a process term *skeletonizing*. However, overly aggressive dissection is balanced against the torrential bleeding that can follow uterine or parametrial vessel laceration.

Ureter Identification

Prior to uterine vessel ligation, the ureter can be seen following careful blunt dissection of the loose areolar tissue in the retroperitoneal space. The ureter is usually easily visualized and can be palpated on the medial leaf of the incised broad ligament. When difficulty is encountered, the following technique is effective. First, a finger is gently placed into the retroperitoneal space laterally and a pulsating artery is isolated along the pelvic

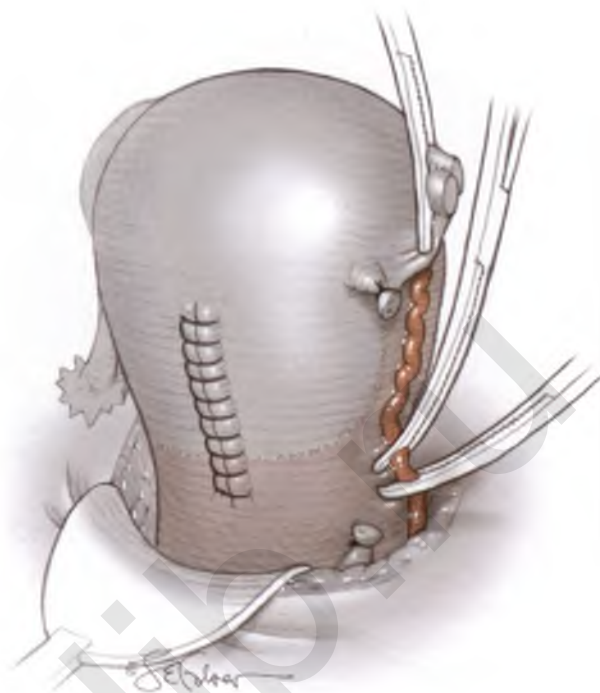


FIGURE 26-6 One Heaney or similar heavy clamp is placed across the uterine artery. A second clamp is positioned above the first to prevent back bleeding. The uterine vascular pedicle between these clamps is then incised and suture ligated.

sidewall by palpation. This is usually the external iliac artery. Using a tonsil-tip suction device or a small “peanut” sponge stick, the surgeon partially clears the areolar tissue surrounding the external iliac artery and follows the artery proximally to the bifurcation of the common iliac artery. Recalling pelvic anatomy as shown in Figure 3-10 (p. 39), the ureter can now be easily found as it lies medial to the ovarian vessels as it crosses the common iliac artery. Observation of peristalsis, either spontaneous or induced by gentle pressure with an instrument, confirms its identity. The course of the ureter may then be traced distally.

This procedure is generally bloodless. However, small bleeding vessels may occasionally be encountered. Use of a laparotomy sponge and pressure or small hemostatic clips is invaluable in obtaining hemostasis under these circumstances and is often preferable to suture placement or extensive cautery.

Uterine Artery Ligation

To secure the uterine vessels, a Heaney clamp is placed on the isolated uterine vessels at a level near the junction of the cervix and uterus (Fig. 26-6). This is slightly below the level of most transverse hysterotomy incisions. The clamp is placed higher on the uterine wall if the anatomic relationships are distorted by a broad ligament hematoma or tumor. A second clamp—a Heaney, Ochsner, or Ballantine—is placed on the uterus to prevent back bleeding. This is positioned above the first clamp.

The uterine vascular pedicle is incised between these clamps with scissors or scalpel. The incision position leaves a small amount of tissue distal to the lower clamp to prevent the escape of tissues from the clamp. Dissection ends at the tip of the lower clamp. A suture needle is then passed beneath the tip of this

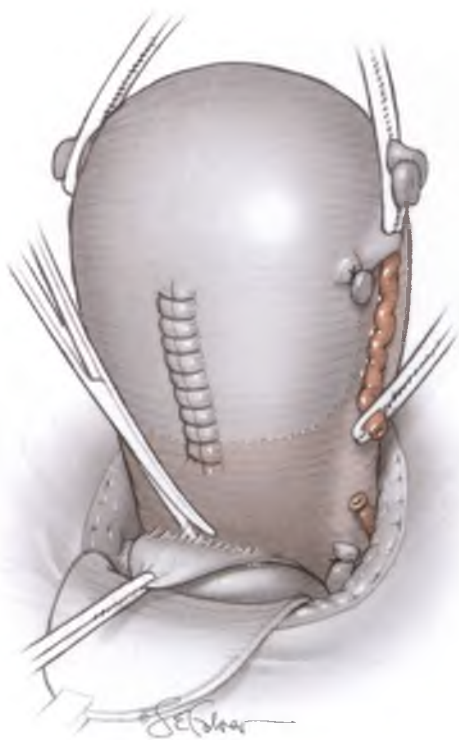


FIGURE 26-7 Sharp dissection in the vesicouterine space allows the bladder to be moved further caudad and away from injury.

clamp. The lower clamp is then gradually released as the first throw of a surgeon's knot is slowly tightened. Some prefer using a simple and then a second transfixing suture for this vascular pedicle. Importantly, slow removal of the clamp helps prevent vessels from retracting toward the sidewall prior to ligation. Retracted vessels can cause bleeding or hematoma formation.

Attention is then directed to the opposite side of the uterus as the assistant elevates the uterus to the left. The right round ligament and adnexal pedicles are clamped, divided, and sutured as on the left side. The right uterine vessels are skeletonized, clamped, divided, and ligated. All major blood vessels supplying the uterus are now controlled.

Cervix Removal

At this juncture, some choose to amputate the bulky uterine fundus to improve exposure. Importantly, the amputation incision should lie above the level of the ligated uterine vessels to avoid substantial bleeding.

After fundectomy, Ochsner clamps are placed on the cervical stump to control bleeding and provide traction and manipulation of the remaining cervix. The bowel and omentum are packed out of the pelvic cavity with laparotomy sponges. Care is taken not to disturb ligated vascular pedicles during this packing. If additional exposure is needed, a self-retaining abdominal wall retractor can be placed. An O'Connor-O'Sullivan retractor may be sufficient for thin patients, whereas a large Balfour retractor may be more suitable for obese women. In cases complicated by a morbidly adherent placenta in which greater pelvic exposure may be required, a Bookwalter retractor may prove advantageous (Chap. 2, p. 18). This must be balanced against the additional time needed for its set-up.

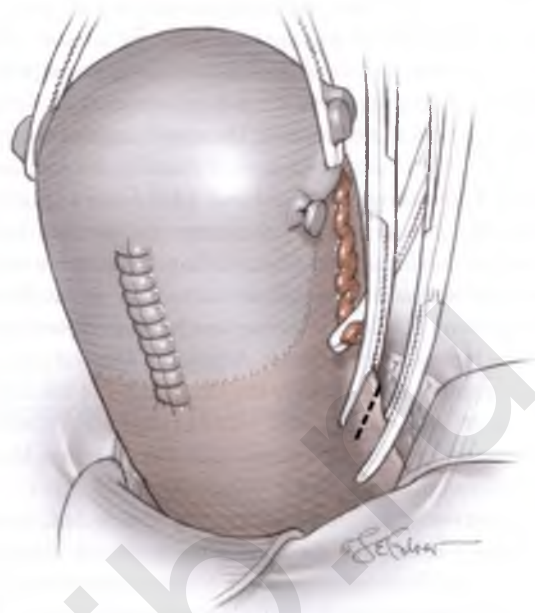


FIGURE 26-8 Two Heaney or similar heavy clamps are placed across the cardinal ligament, which is then sharply incised and ligated. This step is performed two to four times depending on the length of this ligament.

Cervical resection usually requires further mobilization of the bladder. The vesicouterine serosal flap is elevated and the posterior bladder wall is detached from the upper cervix (Fig. 26-7). A plane of thin connective tissue normally permits easy finger dissection. If dense adhesions are present, usually from prior uterine surgery, these are dissected cautiously with fine scissors and small pushing movements as described earlier to avoid bladder injury. Dissection is kept near the midline because lateral dissection often causes troublesome venous bleeding.

The cervix is then resected from its attachments to the cardinal ligaments, uterosacral ligaments, and the vagina. To accomplish this, the cardinal ligaments are successively clamped where they meet the cervix (Fig. 26-8). Each straight Ochsner clamp application encloses 1 to 1½ cm of cardinal ligament. Longer bites risk tissue slipping from the clamp heel. The jaws of the instrument slide off the body of the cervix as they close to ensure the most medial placement of the clamp. This practice helps avoid incorporating the ureter into the clamp and drops the ureter further laterally. One may use a scalpel blade or curved Mayo scissors to incise the pedicle to the tip of the clamp. A suture-bearing needle is then passed exactly beneath the clamp tip, and the tie is tightened slowly down the back of the clamp as it is removed.

Alternating sides can be clamped and ligated to maintain a symmetric dissection. Each cardinal ligament pedicle is clamped medial to the previous one. The ureter progressively falls farther from the dissection with each step. Two or four pedicles are usually necessary to complete the resection of the cardinal ligaments on each side.

The uterosacral ligaments insert on the posterior aspect of the lower cervix. These ligaments may be stretched and attenuated, or

thick and edematous. The uterosacral ligaments are clamped, cut, and sutured separately if they are large or under tension. Otherwise, they can be incorporated into the cardinal ligament pedicles.

Bilateral cardinal ligament dissection continues to the lowest extent of cervical attachment. The upper vagina is palpated between the thumb and forefinger to identify the location of the cervix. If the cervix is effaced and dilated considerably, its softness may obscure of the cervicovaginal junction. In this case, the junction location can be ascertained through a vertical uterine incision made anteriorly in the midline, either through the hysterotomy incision or through an incision created at the level of the ligated uterine vessels. A finger is directed inferiorly through the incision to identify the free margin of the dilated, effaced cervix and the anterior vaginal fornix. The contaminated glove is replaced. Obviously, palpation may not be possible in cases of placenta previa.

If hysterectomy is planned or strongly anticipated, another useful method to identify the cervical margins uses metal skin or vascular clips. Prior to surgery, the patient is placed in lithotomy position, and clips are applied transvaginally at 12, 3, 6, and 9 o'clock positions on the cervical edges. These firm clips can be more easily palpated through the vaginal wall to signal the distal extent of the cervix.

Once the cervix is confidently identified, a suction tip and clean laparotomy sponge are positioned in the cul-de-sac. This prepares for potential contamination when the vagina is opened. Immediately below the level of the cervix, a curved Heaney or similar clamp is placed across the lateral vaginal fornix. This is repeated on the opposite side. Unlike gynecologic hysterectomy, it is common for the two clamp tips not to meet in the midline due to the broad vaginal width. Some surgeons prefer to take only a small bite that incorporates the uterosacral ligament and lateralmost aspect of the vagina. Others prefer to travel farther across the vagina's width. These differences influence cuff closure, discussed in the next section.

The vaginal width above the clamps is incised beginning laterally and progressing medially (Fig. 26-9). For this, large curved Mayo or Jorgenson scissors are suitable. Prior to incision, the bladder and colon should be retracted away from the incision path. Direct visualization assures removal of the entire cervix, preservation of the full vaginal length, and safety of surrounding organs. For surgeons preferring only a small bite across each lateral vaginal aspect, the posterior vaginal wall may be opened transversely just above one clamp. One blade of the scissors is placed within the vaginal cavity and the circumference of the cervix is resected at its junction with the vagina. With either method, the uterus and its contaminated cervix, once freed, are placed in a pan destined to be isolated from the remaining sterile instruments.

The cervix is inspected to ensure that it has been completely removed. If not, the remaining length of cervix can usually be palpated directly by a finger insinuated between the Heaney clamp tips. A second tier of clamps can then be placed again across the vaginal width but below the now-identified distal cervical margin. The first and more proximal tier of clamps is then removed. In some instances, an additional short adjacent segment of cardinal ligament requires clamping and transection on each side to enable positioning of this second tier of clamps.

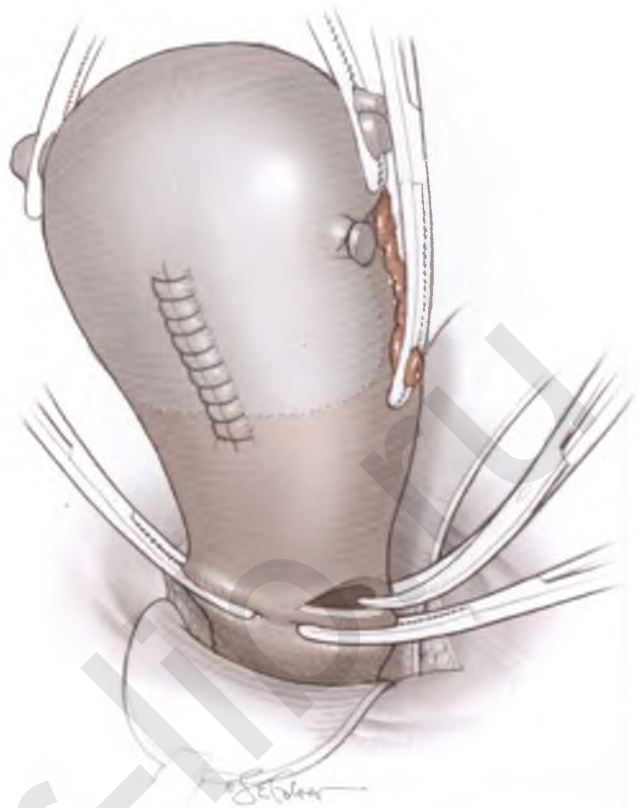


FIGURE 26-9 Two Heaney or similar heavy clamps are positioned across the vagina at a level below the cervix. Sharp incision above these clamps allows the uterus and cervix to be freed and removed from the abdomen.

Vaginal Cuff Closure

Suspension of the vaginal cuff is important and aids long-term vaginal apex suspension. The excised lateral vaginal fornix can be simultaneously doubly ligated and sutured to the stump of the uterosacral ligament. When tied, these sutures bind the upper vagina to the supportive uterosacral ligaments. After this, several methods can be selected to close the cuff and are largely provider driven.

First, if a longer width of vagina was incorporated in the Heaney clamps, most recommend a transfixing stitch for lateral vaginal cuff closure. With this, the needle first pierces at the clamp tip, passes beneath the clamp's midlength, and finally travels under the clamp's heel (Fig. 26-10). The bladder and colon should be retracted away from the suture path to avoid remnant sutures in the bladder and needlestick injury to either organ. Each pass of the needle incorporates the full thickness of both anterior and posterior vaginal walls. The suture is tied at the back of the clamp as the tool is slowly removed. This suture is then held by a hemostat to elevate the cuff for additional suturing. Notably, if a longer length of vagina is incorporated initially by the clamp, transfixion of the vagina is essential and avoids part of the vagina slipping beneath the ligature to cause bleeding. As shown by the dotted line, supplementary interrupted or figure-of-eight stitches are often needed to complete closure of the vagina that was not originally incorporated into the Heaney clamps.

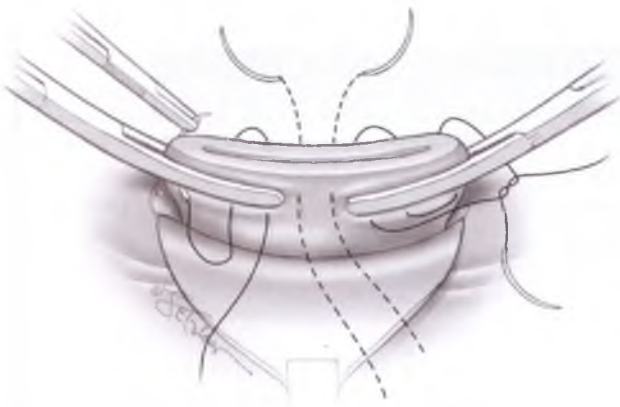


FIGURE 26-10 Several methods can be used to suitably close the vaginal cuff. Here, a transfixing suture is placed on each side to close the lateral vaginal cuff. Interrupted sutures (*dotted lines*) may be needed to close any intervening span of cuff.

For those who prefer to take a smaller bite at the lateral vaginal wall, three cuff suturing options are described here. For all three, lateral vaginal cuff closure is achieved by a suture-bearing needle that passes beneath the Heaney clamp tip and then travels under the heel. The suture is tied at the back of the clamp as the tool is slowly removed. This suture is then held by a hemostat to elevate the cuff for additional suturing. Assistants also grasp the vaginal edges with Allis clamps at 6 and 12 o'clock for added elevation. Gentle upward tension on these clamps reduces the spill of contaminated material from the upper vagina. On balance, care is taken not to tear delicate vaginal tissues.

For the first cuff suturing option, the intervening vaginal cuff is reapproximated along its length by a series of figure-of-eight sutures. Each pass of the needle incorporates the full thickness of both anterior and posterior vaginal walls.

As a second option, after the lateral vaginal wall closure stitch is tied, the needle remains attached to the suture. With this, all layers of the vagina are included in each pass of the suture. Suturing begins laterally and moves medially. Upon meeting at the vagina's midlength, sutures are tied together.

In a third option, others achieve hemostasis by using a running-lock stitch placed through the mucosa and adjacent endopelvic fascia around the entire circumference of the vaginal cuff. For this open vaginal cuff technique, after the lateral vaginal wall closure suture is tied, the anterior and posterior vaginal edges are oversewn individually with continuous locking hemostatic stitches.

All of these techniques allow the vaginal cuff to be closed or left partially open. Many surgeons favor closing the vaginal cuff when there is good hemostasis, no infection, and no injury to bowel or bladder.

Concluding Steps

Following cuff closure, if bladder integrity is in question, it can be filled with sterile milk or dye solution as previously described (p. 423). Any defects in the bladder wall are repaired with a two-layer closure using absorbable suture.

The operative site is irrigated, and each pedicle is inspected for hemostasis. Pressure and patience will achieve hemostasis in many cases. Topical hemostats such as those listed in [Table 26-4](#) can augment this. Some choose to close the pelvic peritoneum, however, other contemporary surgeons do not reperitonealize the pelvis.

At surgery's end but prior to laparotomy closure, all sponges and instruments are removed. An instrument, sponge, and needle count before and after surgery is crucial to operative safety. If counts are not reconciled, then radiographic imaging for retained foreign objects is obtained.

■ Supracervical Hysterectomy

Subtotal hysterectomy may be sufficient to stop hemorrhage, which is the major indication for peripartum hysterectomy. Supracervical hysterectomy may be preferable for women who would benefit from a shorter surgery or for those with extensive adhesions that may predispose to urinary tract injury (Rossi, 2010). To perform a subtotal hysterectomy, the uterus is amputated immediately above the level of the uterine artery pedicle (Matsubara, 2015).

The anterior and posterior walls of the cervical stump are reapproximated with no. 1 or 0 chromic catgut sutures. As with total hysterectomy, the pelvic parietal peritoneum need not be closed. And indeed, this practice may be detrimental if later stump excision is needed for menstrual bleeding or for cervical dysplasia. Namely, closing the peritoneum can more intimately appose the bladder or rectum to the cervical stump. Thus, if later trachelectomy is needed, then urinary tract or bowel injury may be greater risks during the dissection needed for stump excision.

■ Salpingo-oophorectomy

Because of the large adnexal vessels and their close proximity to the uterus, it may be necessary to remove one or both adnexa for hemostasis. The frequency of concurrent salpingo-oophorectomy is usually reported to be 3 to 5 percent, but some cite it to be as high as 25 percent (Briery, 2007; Plauche, 1981; Rossi, 2010). In either event, preoperative counseling should include this possibility.

■ Delayed Ligation Technique

Dyer and colleagues (1953) first described the delayed ligation technique. Other surgeons have modified the method over a period of years to address operative problems. This technique quickly controls all vascular supply to the uterus. The operating principles are simple, and each vascular pedicle supplying the uterus is clamped and severed. The clamped pedicles drop laterally and away from the operative field as the operator proceeds quickly from one pedicle to the next. Suture ligation is delayed until six vascular pedicles are controlled: two round ligaments, two fallopian tube-uteroovarian ligament pedicles, and two uterine vessel pedicles. This technique gains complete hemostasis quickly and should be considered if brisk bleeding, as with uterine atony or rupture, complicates the case. That said,

TABLE 26-4. Topical Hemostatic Agents

Type of Agent	Brand Name	Material
Mechanical Hemostats		
Oxidized, regenerated methylcellulose	Surgicel	Flat loose woven fabric
	Surgicel Fibrillar	Flat peelable layers and tufts
	Surgicel Nu-knit	Flat loose woven fabric
	Surgicel SNoW	Flat nonwoven fabric
Porcine gelatin	Surgifoam	Powder or flat sponge
	Gelfoam	Powder or flat sponge
	Surgiflo ^a	Powder
Bovine collagen	Avitene	Powder, sheet, or flat sponge
	Instat	Powder
Active Hemostats		
Bovine thrombin	Thrombin-JMI	Liquid spray
Bovine thrombin + gelatin	Thrombi-Gel	Flat sponge
Bovine thrombin + methylcellulose	Thrombi-Pad	Flat sheet
Human thrombin	Evithrom ^a	Liquid
Recombinant thrombin	Recothrom	Liquid
Flowable Hemostats		
Bovine gelatin + human thrombin	FloSeal Matrix	Liquid
Porcine gelatin + human thrombin	Surgiflo + Evithrom	Liquid
Fibrin Sealants		
Human thrombin, fibrinogen, plasminogen	Tisseel	Spray or drip application
Human thrombin, fibrinogen	Evicel	Spray or drip application

^aCan be combined to form flowable hemostat. From Hoffman, 2016.

the delayed ligation technique is also suitable for nonemergent and elective cases.

■ Tourniquet Method

Some surgeons still use a tourniquet around the lower uterine segment for hemostasis, as did Porro and his successors. The tourniquet helps control posthysterotomy blood loss from the uterine vessels. However, it does not control collateral circulation from the ovarian vessels.

To use this method, cesarean delivery is performed as usual. The assistant elevates the uterus out of the abdominal cavity, and the operator transilluminates the broad ligaments to identify avascular spaces close to the uterus and at the level of the lower uterine segment. Windows are created by blunt perforation of the broad ligament with a hemostat or by sharp incision using Metzenbaum scissors. Kelly clamps are placed through these windows on each side below the level of the uterine incision. These grasp a tourniquet, which is then passed through the two openings in the broad ligament to encircle the uterus. The tourniquet can be a red rubber catheter, heavy Penrose drain, or plastic intravenous tubing. The tourniquet is drawn tight and secured by an Ochsner clamp at the back of the uterus. Hysterectomy then proceeds using the chosen technique.

COMPLICATIONS

Both intraoperative and postoperative complications of obstetric hysterectomy must be assessed by separating direct surgical complications from those attributable to preexisting disease or injury. Complications are inherently higher and more serious if cesarean hysterectomy is completed emergently for life-threatening hemorrhage. For example, almost all women undergoing emergent procedures require blood transfusion (Zelop, 1993; Zorlu, 1998).

■ Operative Complications

Two major operative complications of peripartum hysterectomy are hemorrhage and urinary tract injury (Table 26-5).

Hemorrhage

As noted, operative blood loss is magnified in that some sort of obstetric hemorrhage is the major indication for peripartum hysterectomy. Control of blood loss depends on surgical technique and careful management of all vascular pedicles. A common cause of hemorrhage is loss of control of a uterine or adnexal vascular pedicle. Uterine vessels usually escape control during manipulation of clamps or tying of sutures. Another

TABLE 26-5. Complications of Emergent Peripartum Hysterectomy for Hemorrhage

Complication	Percent
Operative Complications	
Transfusions	67–84
Urinary tract injury	
Bladder	3–10
Ureter	3
Stent	8
Salpingo-oophorectomy	3–5
Bowel injury	1
Postoperative Complications	
Hemorrhage—reoperation	4
Cuff cellulitis	~10
Cuff abscess	2–3
Wound complications	1–2
Incisional abscess	
Dehiscence	
Maternal death	1–2

Data from Hernandez, 2013; Plauché, 1981; Rossi, 2010; Shellhaas, 2009; Stanco, 1993; Zelop, 1993.

frequent source of intraoperative blood loss is back bleeding from severed pedicles. Clamping vessels close to the uterus before incising pedicles usually controls back bleeding from collateral circulation.

Adnexal bleeding may be encountered during or after surgery for several reasons. First, an ovarian vessel may be torn during manipulation of the adnexal pedicle. Second, a transfixing suture may pierce a vessel that is not controlled by an initial proximal tie or clamp. Last, an ovarian vessel under tension may postoperatively retract out of a ligature around a shrinking pedicle. Preventively, a surgeon can consider securing the adnexal pedicle first with an encircling suture followed by a distal transfixing stitch.

Importantly, these scenarios of adnexal bleeding may result in an expanding adnexal or retroperitoneal hematoma. As discussed, unilateral or even bilateral salpingo-oophorectomy may be necessary to control expansion of such a hematoma. Although adnexectomy presents hormonal and fertility consequences for the woman, a retroperitoneal hematoma can expand rapidly and isolation of the offending vessel can be difficult. In the volume-depleted patient, this additional blood loss may be life-threatening.

Urinary Tract Injuries

The bladder and ureters can be damaged during several procedural steps. Surgical injuries usually do not cause lasting disability if they are recognized and repaired. Unrecognized injuries before or during surgery, however, usually become serious postoperative problems.

Intraoperatively, the bladder is most often lacerated during dissection in the vesicouterine space. This risk rises in a scarred lower uterine segment that results from prior hysterectomy incisions. The bladder may also be injured by inclusion

in a vaginal cuff clamp or suture. Of factors, cross-clamping the upper vagina increases the risk of trauma to the tented lateral bladder wall. In any of these cases, the traumatized bladder wall may undergo necrosis and develop a vesicovaginal fistula. It is possible that vaginal cuff cellulitis or abscess increases this risk.

Urinary tract injuries are more common with emergent procedures. For example, Plauché and associates (1983) reported a 3-percent incidence of bladder injury among 108 private patients with a prior cesarean delivery undergoing elective cesarean hysterectomy. Zelop and colleagues (1993) reported a 7.7-percent incidence of operative cystotomy and a 2.5-percent rate of ureteral injury among 117 emergent peripartum hysterectomies. And, in the 186 emergent cases reported by Shellhaas and coworkers (2009), 2.7 percent had a bladder injury. There was a 7-percent incidence of either intentional cystotomy or passage of a ureteral stent. Importantly, 3 percent of these women had a ureteral injury. To aid identification, the bladder can be back filled to look for leaks as described on page 423. Although used less often in obstetrics, intraoperative cystoscopy can identify these defects as well as ureteral injuries, described next.

There is a particular risk to the ureter when hematomas or tumors distort the pelvic anatomy. These injuries have become more common as severe cases of morbidly adherent placenta are encountered. These are discussed in further detail in Chapter 27 (p. 442). Attempts should be made to identify preoperative displacement or injury to the ureter. Intraoperatively, a ureter can be injured during clamping or ligation of adnexal structures, uterine vessels, or cardinal ligaments. Closure of the lateral vaginal cuff is another at-risk time.

Visualization, palpation, and dissection of its course can usually prevent ureteral injury. Dissection within the cardinal and broad ligaments in pregnant women requires care and experience. The risk of injury to the lower ureter may be reduced by placing clamps exactly against the wall of the cervix, always medial to previous pedicles. Proximal ureteral injury is prevented by visualizing the course of the ureter before clamping adnexal pedicles.

■ Postoperative Complications

Bleeding and infection are the more frequent serious postoperative complications (see Table 26-4).

Postoperative Bleeding

In the series of 186 cases from the Maternal-Fetal Medicine Units Network, 4 percent had a subsequent laparotomy for internal bleeding (Shellhaas, 2009). Similarly, Stanco and colleagues (1993) reported reoperation in 4 percent of cases, and Zelop and associates (1993) cited a frequency of 2.6 percent.

Bleeding immediately postoperatively usually originates from the vaginal cuff. Other bleeding within the abdomen after peripartum hysterectomy usually arises from uterine or adnexal vessels that have slipped from their ligatures. Bleeding may accumulate within the abdominal cavity to create a hemoperitoneum or collect within the retroperitoneal space to form a hematoma. Bleeding from uterine vessels usually collects as a hematoma in the broad ligament. Enlarging broad ligament

hematomas may dissect into the large presacral space or the retroperitoneal spaces along the lateral pelvic walls. Adnexal vessels may bleed into the peritoneal cavity or may form a hematoma in the infundibulopelvic ligament and retroperitoneal flank spaces. Later delayed postoperative vaginal bleeding may stem from trauma to the vaginal cuff or from drainage of a cuff hematoma.

Women with hemoperitoneum show signs of peritoneal irritation. In addition, a focused assessment with sonography for trauma (FAST) scan will reveal increased anechoic or hypoechoic fluid in the cul-de-sacs and potentially in Morison pouch (Chap. 17, p. 286). Bleeding into large retroperitoneal spaces is difficult to detect clinically even when blood loss is extensive. Abdominopelvic computed tomographic (CT) scanning is invaluable when these types of hematomas are suspected (Chap. 30, p. 487).

Stable small hematomas or small hemoperitoneum collections in asymptomatic women usually require no treatment. Exploratory laparotomy may be necessary if hematomas are sizable or enlarging and are not accessible to vaginal drainage. Any woman who is hemodynamically unstable should be emergently evaluated for intraabdominal bleeding. As discussed, sonography, CT, or magnetic resonance (MR) imaging may be helpful in evaluation. Interventional radiologic techniques can be considered to locate and embolize vessels. However, this may be less effective for cases that stem from low-pressure venous bleeding. Transfusions are given as indicated, including correction of associated coagulopathy. Laparotomy is planned if imaging reveals a large or expanding hematoma.

Reexploration is considered if vital signs become unstable, or serial hematocrit values fall after transfusion. If not selected originally, a midline vertical incision is preferred to provide suitable retroperitoneal exposure of a hematoma that may extend well beyond the pelvis. With hemoperitoneum, laparotomy allows suction evacuation of blood and a search for bleeding vessels. Attaining hemostasis mirrors that for retroperitoneal hematomas, described next.

With hematomas, initial observation determines if the mass is indeed expanding. If not, then evacuation may be disadvantageous. Namely, removing the tamponading effects of the taut peritoneum and clot may actually worsen bleeding. However, if a pelvic hematoma is expanding, surgical treatment includes evacuation, securing any visible bleeding vessels, and placing adequate surgical drains (Plauché, 1992a). For the less experienced surgeon, assistance from a gynecologic oncologist or vascular surgeon may be indicated for large retroperitoneal hematomas.

Once the peritoneum is incised and clot is gently removed, distinct bleeding vessels often may not be found. Instead, judicious suturing in areas of greater oozing and application of pressure coupled with topical hemostats found in Table 26-4 may be helpful. In rare cases, if bleeding is substantially slowed but continued blood loss is a concern, then packing with laparotomy sponges and reexploration in 24 to 48 hours may be elected. For ultimate drainage of the evacuated site, Jackson-Pratt or Blake drains may be especially well suited. These are removed at the bedside once serosanguinous output is minimal.

Postoperative Infections

These are among the most common complications after obstetric hysterectomy. Older studies describe febrile morbidity exceeding 30 percent for emergent procedures. Conversely, in women whose surgical procedure was performed before labor, the febrile morbidity rate was only 10 percent (Stanco, 1993; Yancey, 1993; Zelop, 1993). These observations were reported before the routine use of perioperative antimicrobials. For current infection rates, cuff cellulitis develops following perhaps 10 percent of cases, and the rate is 2 to 3 percent for cuff abscesses.

Clinical findings of a cuff abscess or infected hematoma include fever and a tender mass above the cuff. Some of these are discovered with pelvic imaging studies. It is usually possible to drain midline abscesses or hematomas through the vaginal cuff. With an abscess, broad-spectrum antibiotics to cover gram-positive and gram-negative aerobes and anaerobes are selected and begun expeditiously. Gentamicin and clindamycin is one frequent choice, and other options are found in Chapter 32 (p. 507).

For drainage, most women require general or regional anesthesia. Positioning in standard lithotomy position provides access to the cuff. Because the cuff was originally closed abdominally, no distinct sutures are available to grasp and remove. Instead, a Pean clamp can be insinuated into the midlength of the cuff closure suture line at the point of maximal fluctuance. Its jaws are then opened. Notably, injury to major vessels and bleeding may follow if an attempt is made to drain a lateral pelvic hematoma or abscess that does not point near the midline of the vaginal cuff. In these cases, drainage by an interventional radiologist may be possible.

With drainage, pus may be cultured to guide subsequent antibiotic treatment. Once the flow of pus or blood ebbs, the Pean clamp can hold the vaginal cuff aperture open to permit insertion of a drain. Either a Foley or Malecot catheter can be left in place to aid continued abscess or hematoma drainage. Symptoms and signs rapidly resolve after adequate drainage. The drain can be removed once output is minimal. The cuff site will heal by secondary intention.

The frequency of abdominal incisional infections or dehiscence has also decreased with the use of perioperative antimicrobials. In earlier studies, wound infections developed in up to 10 percent of women after cesarean hysterectomy (Plauché, 1986; Stanco, 1993; Yancey, 1993). Wound complications may also be reduced by achieving careful hemostasis and avoiding bacterial contamination of the operative site. Wound infection prophylaxis and treatment are found in Chapters 18 and 32, respectively (pp. 295 and 508).

■ Mortality

Exact figures for maternal deaths associated with peripartum hysterectomy are not available. That said, the mortality rate is relatively low and is directly related to the indication for the surgery. For example, according to the Centers for Disease Control and Prevention, almost 5 percent of maternal deaths from 2006 to 2010 were caused by the obstetric complications with which hysterectomy is commonly associated. These are uterine

rupture, atony, placenta previa, and morbidly adherent placenta (Creanga, 2015). Because of these, mortality rates are higher when obstetric hysterectomy data are compared with those for gynecologic hysterectomy (Sahin, 2014). Information from older studies includes that of Wingo and colleagues (1985), who examined the mortality risk for all hysterectomies in the United States from data collected during 1979 to 1980. They identified 477 deaths among 317,389 women undergoing gynecologic abdominal hysterectomy—a mortality rate of 12 per 10,000 procedures. At the same time, the mortality risk for 5435 women who had a peripartum hysterectomy was 29 per 10,000. These investigators did not correct for disease-related mortality, nor did they separate the various types of obstetric hysterectomies.

Plauché (1992b) presented the 45-year experiences from the Louisiana State University Obstetrics Service for peripartum hysterectomy. There were approximately equal numbers of elective and emergent cases. Mortality rates show significant changes during the years of case collection. In the first 30 years of the series, 7 of 1335 women died after hysterectomy—52 per 10,000 cases. During the next 15 years, there was only one death associated with 435 cases—23 per 10,000. Of the eight maternal deaths in this 45-year report, three women who died were moribund on admission from hemorrhage or sepsis. One woman died of advanced pelvic malignancy and one from postoperative sepsis. The most disturbing cases were those in which fatal intraabdominal bleeding was not recognized early in the postoperative course. Undue delay in performing hysterectomy in an attempt to preserve reproductive function may also lead to complications and even death.

In older series, when mortality associated with elective cesarean hysterectomy is examined, maternal deaths are uncommon. For example, no maternal deaths were recorded in 543 cesarean hysterectomies reported by three private practice groups in New Orleans (McNulty, 1984; Schneider, 1968; Ward, 1965). Similarly, Park and Duff (1980) surveyed 11 series of planned cesarean hysterectomies and found no maternal deaths. They concluded that, after correction for underlying obstetric catastrophes, the mortality rate for cesarean hysterectomy is comparable to that of cesarean delivery or gynecologic hysterectomy alone.

Maternal deaths continue to be disproportionately high for peripartum hysterectomy in resource-poor countries. In some of these, reported mortality rates range from 1.5 to 4.5 percent (Allam, 2014; Begum, 2014; Sahin, 2014; Sakinci, 2014; Wei, 2014).

SUMMARY

Peripartum hysterectomy is an indispensable operation in the obstetrician's armamentarium. Currently, this procedure is usually performed under adverse conditions such as morbidly adherent placenta, catastrophic uterine rupture, or refractory uterine atony with life-threatening maternal hemorrhage. Under these circumstances, it is not surprising that the rate of bladder or ureteral injury and requirement for blood transfusion is increased compared with that for routine cesarean delivery or scheduled interval hysterectomy. Intraoperatively, any concerns of bladder, ureter, or bowel injury should

be thoroughly investigated and resolved prior to closing the abdominal cavity. In cases of severe hemorrhage or disseminated intravascular coagulopathy, use of the supracervical hysterectomy should be considered in lieu of a total hysterectomy. It will decrease operative time and minimize the extent of difficult surgical dissection and blood loss.

And finally, it is paramount to continue to teach this potentially lifesaving operation to obstetric residents and to include it as a major "milestone of competency." Importantly, many graduating residents may need additional mentoring in this procedure during the first few years in practice. The need for this procedure will undoubtedly continue to increase along with the increasing cesarean delivery rate.

REFERENCES

- Allam IS, Gomaa IA, Fathi HM, et al: Incidence of emergency peripartum hysterectomy in Ain-shams University Maternity Hospital, Egypt: a retrospective study. *Arch Gynecol Obstet* 290(5):89, 2014
- Balghobin S, Hamid CA, Hoffman BL: Intraoperative considerations. In Hoffman BL, Schorge JO, Bradshaw KD, et al (eds): *Williams Gynecology*, 3rd ed. New York, McGraw-Hill Education, 2016
- Barclay DL: Cesarean hysterectomy: thirty years experience. *Obstet Gynecol* 35:120, 1970
- Bateman BT, Mhyre JM, Callaghan WM, et al: Peripartum hysterectomy in the United States: nationwide 14 year experience. *Am J Obstet Gynecol* 206(1):63.e1, 2012
- Begum M, Alsafi F, ElFarra J, et al: Emergency peripartum hysterectomy in a tertiary care hospital in Saudi Arabia. *J Obstet Gynaecol India* 64(5):321, 2014
- Bey M, Pastorek JG II, Lu P: Comparison of morbidity in cesarean section hysterectomy versus cesarean section tubal ligation. Presented at annual meeting of District VII, American College of Obstetricians and Gynecologists, St. Louis, September 1993
- Bixby GH: Extirpation of the puerperal uterus by abdominal section. *J Gynecol Soc Boston* 1:223, 1869
- Bodelon C, Bernabe-Ortiz A, Schiff MA, et al: Factors associated with peripartum hysterectomy. *Obstet Gynecol* 114(1):115, 2009
- Bowman EA, Barelay DS, White LC: Cesarean hysterectomy: an analysis of 1000 consecutive operations. *Bull Tulane Med Faculty* 23:75, 1964
- Brenner P, Sall S, Sonnenblick B: Evaluation of cesarean section hysterectomy as a sterilization procedure. *Am J Obstet Gynecol* 108:335, 1970
- Briery CM, Rose CH, Hudson WT, et al: Planned vs emergent cesarean hysterectomy. *Am J Obstet Gynecol* 197(2):154.e1, 2007
- Creanga AA, Berg CJ, Syverson C, et al: Pregnancy-related mortality in the United States, 2006–2010. *Obstet Gynecol* 125:5, 2015
- Cunningham FG, Leveno KJ, Bloom SL, et al (eds): *Critical care and trauma*. In *Williams Obstetrics*, 24th ed. New York, McGraw-Hill Education, 2014
- Dahlke JD, Mendez-Figueroa H, Maggio L, et al: Prevention and management of postpartum hemorrhage: a comparison of 4 national guidelines. *Am J Obstet Gynecol* 13(1):76.e1, 2015
- D'Arpe S, Franceschetti S, Corosu R, et al: Emergency peripartum hysterectomy in a tertiary teaching hospital: a 14-year review. *Arch Gynecol Obstet* 291(4):841, 2015
- Davis ME: Complete cesarean hysterectomy: a logical advance in modern obstetric surgery. *Am J Obstet Gynecol* 62:838, 1951
- Durfee RD: Evolution of cesarean hysterectomy. *Clin Obstet Gynecol* 12:575, 1969
- Dyer I, Nix GF, Weed JC: Total hysterectomy at cesarean section and the immediate puerperal period. *Am J Obstet Gynecol* 65:517, 1953
- Flood KM, Said S, Geary M, et al: Changing trends in peripartum hysterectomy over the last 4 decades. *Am J Obstet Gynecol* 200(6):632.e1, 2009
- Godson C: Porro's operation: introduction to a discussion in the section of obstetric medicine. *BMJ* 1:142, 1884
- Gonsoulin W, Kennedy R, Guidry K: Elective versus emergency cesarean hysterectomy cases in a residency program setting: a review of 129 cases from 1984 to 1988. *Am J Obstet Gynecol* 165:91, 1991
- Hernandez JS, Wendel GD Jr, Sheffield JS: Trends in emergency peripartum hysterectomy at a single institution: 1988–2009. *Am J Perinatol* 30:365, 2013
- Jakobsson M, Tapper AM, Colmorn LB, et al: Emergency peripartum hysterectomy: results from the prospective Nordic Obstetric Surveillance Study (NOSS). *Acta Obstet Gynecol Scand* 94(7):745, 2015

- Kramer MS, Berg C, Abenham H, et al: Incidence, risk factors, and temporal trends in severe postpartum hemorrhage. *Am J Obstet Gynecol* 209(5):449, 2013
- Matsubara S, Ohkuchi A, Suzuki H, et al: Cesarean hysterectomy: amputation-first technique (Matsubara). *Acta Obstet Gynecol Scand* 94(5):552, 2015
- McNulty JV: Elective cesarean hysterectomy—revisited. *Am J Obstet Gynecol* 149:29, 1984
- Mickal A, Begnaud WP, Hawes TP: Pitfalls and complications of cesarean section hysterectomy. *Clin Obstet Gynecol* 12:660, 1969
- Orbach A, Levy A, Wiznitzer A, et al: Peripartum cesarean hysterectomy: critical analysis of risk factors and trends over the years. *J Matern Fetal Neonatal Med* 24(3):480, 2011
- Owolabi MS, Blake RE, Mayor MT, et al: Incidence and determinants of peripartum hysterectomy in the metropolitan area of the District of Columbia. *J Reprod Med* 58(3–4):167, 2013
- Park RC, Duff WP: Role of cesarean hysterectomy in modern obstetric practice. *Clin Obstet Gynecol* 23:601, 1980
- Plauché WC: Cesarean hysterectomy. In Schiarrà J, Dilts PV Jr (eds): *Gynecology and Obstetrics*, Vol 2. Philadelphia, Lippincott, 1986
- Plauché WC: Obstetric genital trauma. In Plauché WC, Morrison JC, O'Sullivan MJ (eds): *Surgical Obstetrics*. Philadelphia, WB Saunders, 1992a
- Plauché WC: Surgical problems involving the pregnant uterus: uterine inversion, uterine rupture and leiomyomas. In Plauché WC, Morrison JC, O'Sullivan MJ (eds): *Surgical Obstetrics*. Philadelphia, WB Saunders, 1992b
- Plauché WC, Gruich FG, Bourgeois MO: Hysterectomy at the time of cesarean section: analysis of 108 cases. *Obstet Gynecol* 58:459, 1981
- Plauché WC, Wycheck JG, Ianessa MJ, et al: Cesarean hysterectomy on the LSU Service of Charity Hospital, 1975–1981. *South Med J* 76:1261, 1983
- Richardson E: Caesarean section with removal of uterus and ovaries after the Porro-Muller method. *Am J Med Sci* 81:36, 1878
- Rossi AC, Lee RH, Chmait RH: Emergency postpartum hysterectomy for uncontrolled postpartum bleeding: a systematic review. *Obstet Gynecol* 115(3):637, 2010
- Sahin S, Guzin K, Eroglu M, et al: Emergency peripartum hysterectomy: our 12-year experience. *Arch Gynecol Obstet* 289(5):953, 2014
- Sakinci M, Kuru O, Tosun M, et al: Clinical analysis of emergency peripartum hysterectomy in a tertiary center. *Clin Exp Obstet Gynecol* 1(6):654, 2014
- Schneider GT, Tyrone CH: Cesarean total hysterectomy: experience with 160 cases. *South Med J* 59:927, 1968
- Shellhaas CS, Gilbert S, Landon MB, et al: The frequency and complication rates of hysterectomy accompanying cesarean delivery. *Obstet Gynecol* 114(2 Pt 1):224, 2009
- Stanco LM, Schrimmer DB, Paul RH, et al: Emergency peripartum hysterectomy and associated risk factors. *Am J Obstet Gynecol* 168:879, 1993
- Sturdee DW, Rushton DJ: Cesarean and post-partum hysterectomy 1968–1983. *BJOG* 93:270, 1986
- Tait L: Address on the surgical aspect of impacted labour. *BMJ* 1:657, 1890
- Ward SV, Smith H: Cesarean total hysterectomy: combined section and sterilization. *Obstet Gynecol* 26:858, 1965
- Wei Q, Zhang W, Chen M, et al: Peripartum hysterectomy in 38 hospitals in China: a population-based study. *Arch Gynecol Obstet* 289(3):549, 2014
- Wingo PA, Huezo CM, Rubin GL, et al: The mortality risk associated with hysterectomy. *Am J Obstet Gynecol* 152:803, 1985
- Yancey MK, Harlass FE, Benson W, et al: The perioperative morbidity of scheduled cesarean hysterectomy. *Obstet Gynecol* 81:206, 1993
- Young JH: *Caesarean section. The history and development of the operation from earliest times*. London, HK Lewis, 1944
- Zelop CM, Harlow BL, Frigoletto FD Jr, et al: Emergency peripartum hysterectomy. *Am J Obstet Gynecol* 168:1443, 1993
- Zorlu CG, Turan C, Isik AZ, et al: Emergency hysterectomy in modern obstetric practice. *Acta Obstet Gynecol Scand* 77:186, 1998

CHAPTER 27

Placenta Previa and Morbidly Adherent Placenta

PLACENTAL PHYSIOLOGY.....	435
PLACENTA PREVIA.....	436
DIAGNOSIS.....	440
MANAGEMENT.....	441
MORBIDLY ADHERENT PLACENTA.....	442
CLINICAL PRESENTATION AND DIAGNOSIS.....	445
MANAGEMENT.....	446

In some pregnancies, the placenta may develop at an abnormal location or may extensively invade the adjacent myometrium. Clinical entities include *placenta previa*, in which trophoblastic cells implant over or near the internal cervical os (Fig. 27-1). In other cases, trophoblast aggressively burrows into the myometrium. Depending on the invasion depth, *placenta accreta*, *placenta increta*, or *placenta percreta* is diagnosed (Fig. 27-2). The term *placenta accrete syndromes* is clinically useful to summarize these three types and is used here and throughout the text. Another interchangeable phrase also often used is *morbidly adherent placenta* (Bailit, 2015; Silver, 2015a).

For the gravida and her newborn, catastrophic sequelae can result from abnormal placental implantation. Of these, obstetric hemorrhage, cesarean hysterectomy, preterm delivery, and their attendant complications are prominent. Worryingly, rates of both placenta previa and accrete syndromes are rising. Most of this trend in the United States derives from the current substantial cesarean delivery rate, which is a known risk factor for both (Chap. 25, p. 404). Early identification and preparation can mitigate several of the associated complications. This chapter emphasizes many of these preventive steps.

PLACENTAL PHYSIOLOGY

In understanding the pathophysiology and management of placental disorders, one key concept is the mechanism by which hemostasis is achieved after normal delivery. First, recall that an incredible volume of blood flows through the intervillous space near term. Accurately measuring uteroplacental blood flow is challenging, and simultaneous calculation of uterine, ovarian, and collateral vessel contributions is currently not technically possible. This limitation stands even if the orthogonal capabilities of magnetic resonance angiography are used (Pates, 2010). With indirect methods that include clearance rates of androstenedione and xenon-133, uteroplacental blood flow has been calculated to increase progressively throughout pregnancy. Estimates at term range from 450 to 600 mL/min (Edman, 1981;

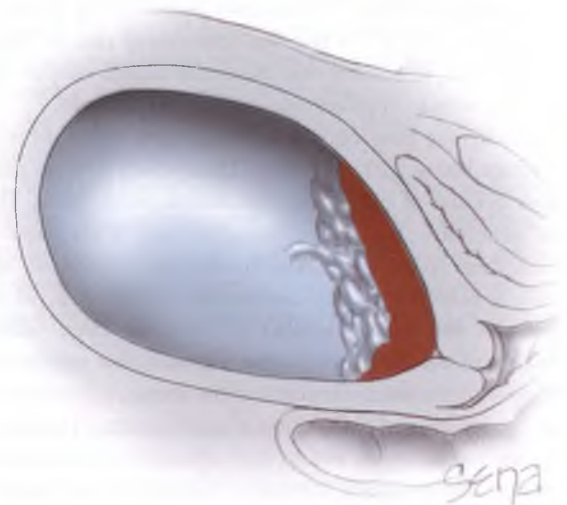


FIGURE 27-1 Placenta previa showing that copious hemorrhage could be anticipated with any cervical dilatation. (Reproduced with permission from Cunningham FG, Leveno KJ, Bloom SL, et al (eds): Obstetrical hemorrhage. In Williams Obstetrics, 24th ed. New York, McGraw-Hill Education, 2014.)

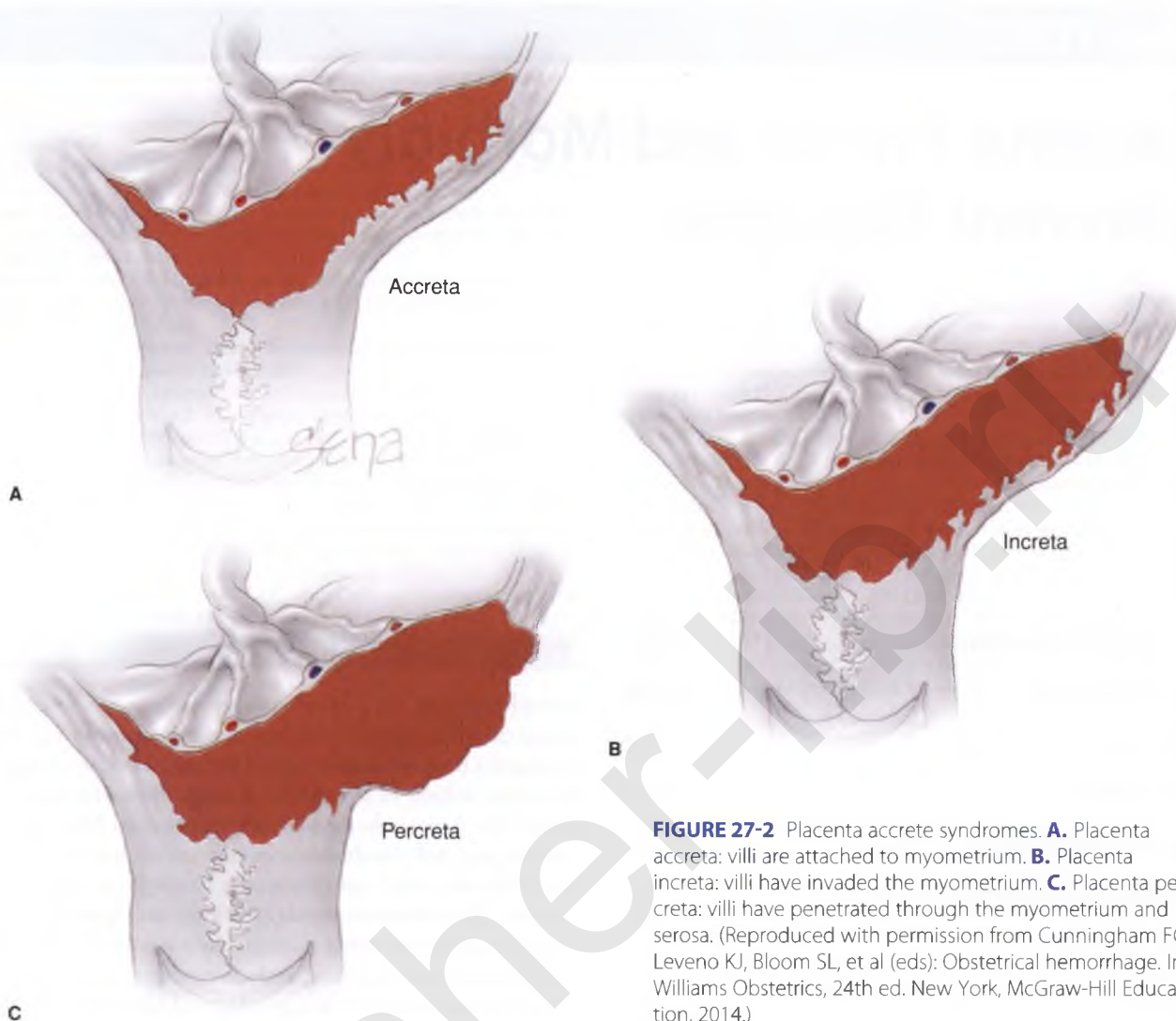


FIGURE 27-2 Placenta accrete syndromes. **A.** Placenta accreta: villi are attached to myometrium. **B.** Placenta increta: villi have invaded the myometrium. **C.** Placenta percreta: villi have penetrated through the myometrium and serosa. (Reproduced with permission from Cunningham FG, Leveno KJ, Bloom SL, et al (eds): *Obstetrical hemorrhage*. In *Williams Obstetrics*, 24th ed. New York, McGraw-Hill Education, 2014.)

Kauppila, 1980). These values are similar to those obtained with invasive methods—500 to 750 mL/min (Assali, 1953; Browne, 1953; Metcalfe, 1955). To put this remarkable rate of blood flow into context, remember that the entire cardiac output of a nonpregnant woman approximates only 3500 mL/min.

This prodigious flow circulates through the spiral arteries, which average 100 to 120 in number. These vessels have no muscular layer because of early endotrophoblastic remodeling. This placental structure creates a low-pressure system. With placental separation, these vessels at the implantation site are avulsed, and hemostasis is achieved first by myometrial contractions, which compress this formidable number of relatively large vessels. Notably, in the normal lower uterine segment, this muscle cell population is diminished. Throughout the uterus, contraction is followed by clotting and obliteration of vessel lumens. Thus, after delivery, the myometrium within and adjacent to the denuded implantation site normally contracts vigorously, and hemorrhage from the implantation site is forestalled. Importantly, an intact coagulation system is not necessary for postpartum hemostasis unless there are lacerations in the uterus, birth canal, or perineum. Conversely, massive hemorrhage can result despite normal coagulation if the placenta is abnormally implanted into the inactive lower uterine segment as with placenta previa. In

these cases, the paucity of myometrial cells that would normally contract and encircle the spiral vessels explains this bleeding. In addition, if placental tissue has attached to or grown into the myometrium, as with placenta accrete syndromes, then hemostasis at the implantation site is further impaired.

PLACENTA PREVIA

The Latin *previa* means *going before*—and in this sense, the placenta goes before the fetus into the birth canal. In obstetrics, placenta previa describes a placenta that is implanted somewhere in the lower uterine segment, either over or very near the internal cervical os. Because these anatomic relationships cannot always be precisely defined, and because they frequently evolve across pregnancy, terminology can sometimes be confusing, as discussed subsequently.

■ Placental Migration

Placenta previas diagnosed early in pregnancy may not persist as gestation advances. In earlier literature, the term *placental migration* was used to describe the apparent movement of the placenta away from the internal os (King, 1973). *Migration* is clearly a misnomer because decidual invasion by chorionic villi on either side

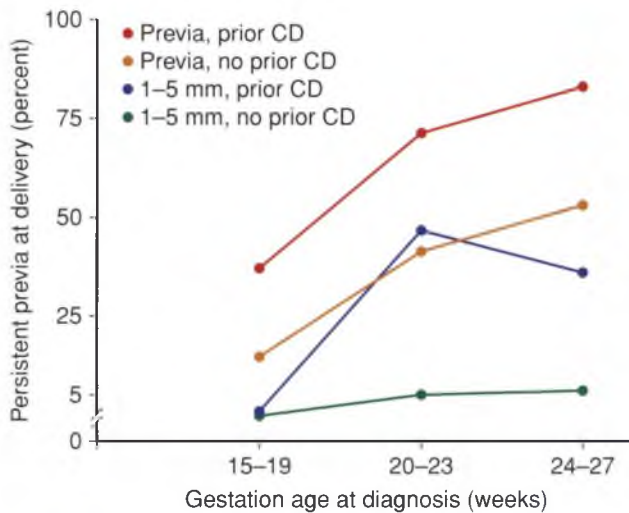


FIGURE 27-3 Likelihood of placenta previa or low-lying placenta persistence at delivery. Data points reflect the sonographic diagnosis at three pregnancy epochs of a previa or placental edges lying 1 to 5 mm from the cervical internal os. (Reproduced with permission from Cunningham FG, Leveno KJ, Bloom SL, et al (eds): *Obstetrical hemorrhage*. In *Williams Obstetrics*, 24th ed. New York, McGraw-Hill Education, 2014; data from Oyelese, 2006.)

of the cervical os persists. Although it is obvious that the placenta does not move per se, the mechanism of *apparent* movement is not completely understood. Several explanations are likely additive.

First, apparent movement of the low-lying placenta relative to the internal os may simply reflect the imprecision of two-dimensional sonography to clearly define this relationship. Second, the lower and upper uterine segments do grow at differing rates as pregnancy progresses (Becker, 2001). The upper uterus establishes greater blood flow, and placental growth, supported by this enhanced supply, favors the fundus. The term *trophotropism* describes this event. Thus, many of the placentas that “migrate” most likely never were circumferentially implanted with true villous invasion that reached the internal cervical os. And, their apparent exodus results from preferential fundal geographic growth.

Placental migration has been quantified in several studies. Sanderson and Milton (1991) studied 4300 women at mid-pregnancy and found that 12 percent had a low-lying placenta. Of those not covering the internal os, previa did not persist, and none subsequently had placenta-associated hemorrhage. Conversely, approximately 40 percent of placentas that covered the os at midpregnancy continued to do so until delivery. Thus, placentas that lie close to but not over the internal os at

a gestational age up to the early third trimester are unlikely to persist as a previa by term (Dashe, 2002; Heller, 2014; Parrott, 2015; Robinson, 2012). Still, Bohrer and associates (2012) reported that a second-trimester low-lying placenta was associated with antepartum admission for hemorrhage and increased blood loss at delivery.

The likelihood that placenta previa persists after being identified sonographically at given epochs before 28 weeks’ gestation is shown in [Figure 27-3](#). Similar findings for twin pregnancies are reported until 23 weeks’ gestation. At later ages, the previa persistence rate is much higher (Kohari, 2012). Also from the figure, the effects of a prior cesarean delivery are obvious, and placenta previa is less likely to “migrate” within a uterus with a prior cesarean hysterotomy scar.

■ Classification

Terminology for placenta previa has been confusing. In a recent Fetal Imaging Workshop sponsored by the National Institutes of Health (Reddy, 2014), the following classification was recommended ([Table 27-1](#)):

- *Placenta previa*—the internal os is covered completely or partially by placenta (see [Fig. 27-1](#) and [Fig. 27-4](#)). In the past, these were further classified as either a total or partial previa.
- *Low-lying placenta*—implantation in the lower uterine segment is such that the placental edge does not reach the internal os but is within 2 cm from it. The discarded term *marginal previa* described a placenta that was at the edge of the internal os but did not overlie it.

Clearly, the classification of some cases of previa will depend on cervical dilatation at the time of assessment (Dashe, 2013; Reddy, 2014). For example, a low-lying placenta and a cervical dilatation of 2 cm may become a placenta previa at 4-cm dilatation because the cervix has dilated to expose the placental edge (see [Fig. 27-4](#)). Conversely, a total placenta previa before cervical dilatation may become partial at 4-cm dilatation because the cervical opening now extends beyond the edge of the placenta. Digital palpation in an attempt to ascertain these changing relations between the placental edge and internal os as the cervix dilates usually causes severe hemorrhage and is generally avoided!

With any degree of placenta previa, a certain element of spontaneous placental separation is an inevitable consequence of lower uterine segment remodeling and cervical dilatation. Although this frequently causes bleeding, and thus technically constitutes a placental abruption, this term is usually not applied in these instances.

TABLE 27-1. Placenta Previa Classification

Placenta previa: the internal os is covered completely or partially by placenta

Low-lying placenta: implantation in the lower uterine segment is such that the placental edge does not reach the internal os but is within 2 cm of it

Discarded term: marginal previa described a placenta that was at the edge of the internal os but did not overlie it

Data from Reddy, 2014.

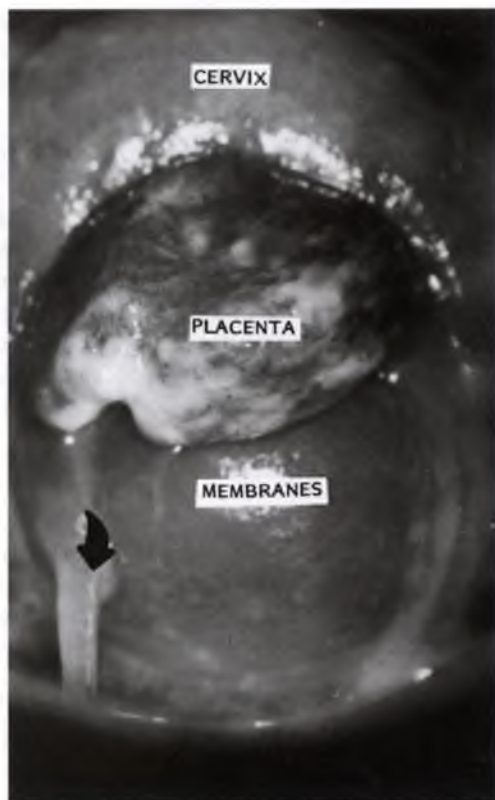


FIGURE 27-4 Second-trimester placenta previa. On speculum examination, the cervix is 3- to 4-cm dilated. The arrow points to mucus dripping from the cervix. (Photographs used with permission from Dr. Kelley S. Carrick. Reproduced with permission from Cunningham FG, Leveno KJ, Bloom SL, et al (eds): *Obstetrical hemorrhage*. In *Williams Obstetrics*, 24th ed. New York, McGraw-Hill Education, 2014.)

Somewhat but not always related is *vasa previa*. With this condition, fetal vessels course through the placental membranes and lie across the cervical os (Bronsteen, 2013). Antepartum treatment of *vasa previa* is discussed in Chapter 16 (p. 271).

■ Incidence and Associated Factors

The reported incidence for placenta previa in the United States is 1 case per 200 to 300 deliveries (Martin, 2005; Silver, 2015a). The frequency at Parkland Hospital from 1988 through 2011 was approximately 1 in 470 for 209,020 singleton births (Wortman, 2015). Similar frequencies have been reported from Canada, England, Finland, and Israel (Crane, 1999; Gurol-Urganci, 2011; Räisänen, 2014; Rosenberg, 2011). The incidence from

TABLE 27-2. Risk Factors Associated with Placenta Previa

Multiparity
Cigarette smoking
Multifetal gestation
Prior placenta previa
Prior cesarean delivery
Prior surgical abortion
Advancing maternal age
Elevated serum maternal alpha-fetoprotein

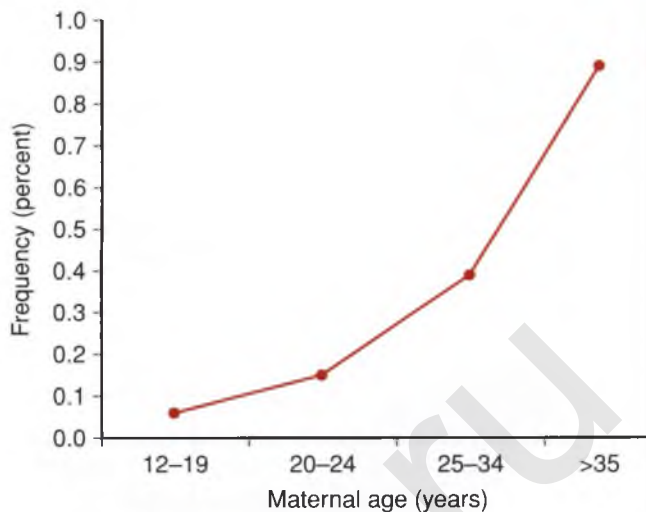


FIGURE 27-5 Frequency of placenta previa for different maternal ages in 365,700 deliveries at Parkland Hospital from 1988 through 2012.

a Japanese study was unusually low at only 1 in 700 deliveries (Matsuda, 2011). Except for the last study, these reported frequencies are remarkably similar considering the lack of precision in definition and classification discussed above.

Several factors increase the risk for placenta previa (Table 27-2). One of these—multifetal gestation—seems intuitive because of the larger total placental surface area. And indeed, the incidence of associated previa with twin pregnancy is increased by 30 to 40 percent compared with that of singletons (Ananth, 2003a; Weis, 2012). Many of the other associated factors are less intuitive.

Maternal Age

The frequency of placenta previa increases with maternal age (Biro, 2012). At Parkland Hospital, this incidence increased from a low rate of approximately 1 in 1660 for women 19 years or younger to almost 1 in 100 for women older than 35 (Fig. 27-5). Also, coincidental with increasing maternal age in the United States and Australia, the overall incidence of previa has increased substantively (Frederiksen, 1999; Roberts, 2012). The FASTER Trial, which included more than 36,000 women, cited the frequency of previa to be 0.5 percent for women <35 years compared with 1.1 percent in those >35 years (Cleary-Goldman, 2005).

Multiparity

The risk for previa increases with parity (Räisänen, 2014). The obvious effects of advancing maternal age and parity can be confounding. Still, Babinszki and colleagues (1999) reported that the 2.2-percent incidence in women with parity of five or greater was increased significantly compared with that of women with lower parity. Alternatively, there seems to be no relationship to interpregnancy intervals (Fox, 2015).

Prior Cesarean Delivery

Women who have undergone one or more cesarean deliveries are at greater risk for subsequent placental disorders that include placenta previa, abruption, or accrete syndromes (Klar, 2014). The cumulative risks for placenta previa that accrue with the increasing number of cesarean deliveries are extraordinary.

In a Network study of 30,132 women undergoing cesarean delivery, Silver and associates (2006) reported an incidence of 1.3 percent for those with only one prior cesarean delivery, but it was 3.4 percent if there were six or more prior cesarean deliveries. In a retrospective cohort of nearly 400,000 women who were delivered of two consecutive singletons, those with a cesarean delivery for the first pregnancy had a significant 1.6-fold increased risk for previa in the second pregnancy (Gurol-Urganci, 2011). These same investigators reported a 1.5-fold increased risk from six similar population-based cohort studies. Gesteland (2004) and Gilliam (2002) and their coworkers calculated that the likelihood of previa was increased more than eightfold in women with parity greater than four and who had more than four prior cesarean deliveries.

In addition, the circumstances of the prior delivery may have implications. For example, Downes and associates (2015) found a higher previa rate in a second pregnancy if the cesarean delivery in the preceding pregnancy was performed prior to labor compared with those performed intrapartum. Moreover, a higher inherent rate of recurrence is seen in women with a prior placenta previa that did not require hysterectomy. Recurrence rates range from 2 to 5 percent (Gorodeski, 1981; Rasmussen, 2000; Roberts, 2012).

Importantly, women with a prior uterine incision and current placenta previa have an increased likelihood that cesarean hysterectomy will be necessary for hemostasis because of an associated accrete syndrome (Wei, 2014). This is discussed in further detail on page 442. In the study by Frederiksen and colleagues (1999), 6 percent of women who had a primary cesarean delivery for previa required a hysterectomy. This rate was 25 percent for women with a previa undergoing repeat cesarean delivery.

As an associated correlate, some evidence supports a greater risk of placenta previa as the number of surgical pregnancy terminations accrues (Barrett, 1981; Faiz, 2003). This relationship is strongest for women specifically with prior curettage (Johnson, 2003).

Cigarette Smoking

The relative risk of placenta previa is increased at least twofold in women who smoke cigarettes (Ananth, 2003a; Usta, 2005). It has been postulated that carbon monoxide hypoxemia causes compensatory placental hypertrophy and greater surface area. Alternatively, smoking may be related to decidual vasculopathy that has been implicated in the genesis of previa.

Elevated Serum Maternal Alpha-Fetoprotein Levels

Women who have otherwise unexplained abnormally elevated prenatal screening levels of maternal serum alpha-fetoprotein (MSAFP) are at increased risk for previa and a host of other abnormalities. Moreover, women with a previa who also have an MSAFP level ≥ 2.0 multiples of the median (MoM) at 16 weeks' gestation are at increased risk for late-pregnancy bleeding and preterm birth.

■ Clinical Features

Bleeding

Painless bleeding is the most characteristic event with placenta previa. Bleeding usually does not appear until near the end of the second trimester or later, but it can begin even before

midpregnancy. Undoubtedly, some late abortions are caused by an abnormally located placenta.

Bleeding from a previa usually begins without warning and without pain or contractions in a woman who has had an uneventful prenatal course. This so-called *sentinel bleed* is rarely so profuse as to prove fatal. Usually it ceases, only to recur. In perhaps 10 percent of women, particularly those with a placenta implanted near but not over the cervical os, there is no bleeding until labor onset. Bleeding at this time varies from slight to profuse, and it may clinically mimic placental abruption.

A specific sequence of events leads to bleeding in cases in which the placenta is located over the internal os. First, the uterine body remodels in labor to form the lower uterine segment. With this, the internal os dilates, and some of the implanted placenta inevitably separates. Bleeding that ensues is augmented by the inherent inability of myometrial fibers in the lower uterine segment to contract and thereby constrict avulsed vessels.

As well as placenta location, cervical effacement has been shown by some to increase the incidence of bleeding with a placenta previa. Stafford and coworkers (2010), but not Trudell and colleagues (2013), found that a previa and a third-trimester cervical length < 30 mm increased the risk for hemorrhage, uterine activity, and preterm birth. Friszer and associates (2013) showed that women admitted for bleeding had a greater chance of delivery within 7 days if the cervix was < 25 mm. However, Trudell and colleagues (2013) did not confirm this.

In addition to antepartum bleeding, blood loss from the lower segment implantation site also frequently continues after placental delivery during cesarean delivery. There may also be lacerations in the friable cervix and lower segment. The latter may be especially problematic following manual removal of a somewhat adhered placenta.

Abnormally Implanted Placenta

A frequent and serious complication associated with placenta previa arises from its abnormally firm placental attachment. This is anticipated because of poorly developed decidua that lines the lower uterine segment. Biswas and coworkers (1999) performed placental bed biopsies in 50 women with a previa and in 50 control women. Trophoblastic giant-cell infiltration of spiral arterioles—rather than endovascular trophoblast—was found in half of previa specimens, but in only 20 percent from those with normally implanted placentas.

Some of these women have pathologically abnormal ingrowth of placental tissue into the myometrium (Fig. 27-6). Placenta accrete syndromes arise from abnormal placental implantation and adherence and are classified according to the depth of placental ingrowth into the uterine wall. These include *placenta accreta*, *increta*, and *percreta*, which are discussed in detail on page 442. In a study of 514 cases of previa reported by Frederiksen and associates (1999), abnormal placental attachment was identified in 7 percent. As discussed above, previa overlying a prior cesarean incision conveys a particularly high risk for morbidly adherent placenta.

Coagulation Defects

Placenta previa is rarely complicated by coagulopathy even when the placenta is extensively separated from its implantation

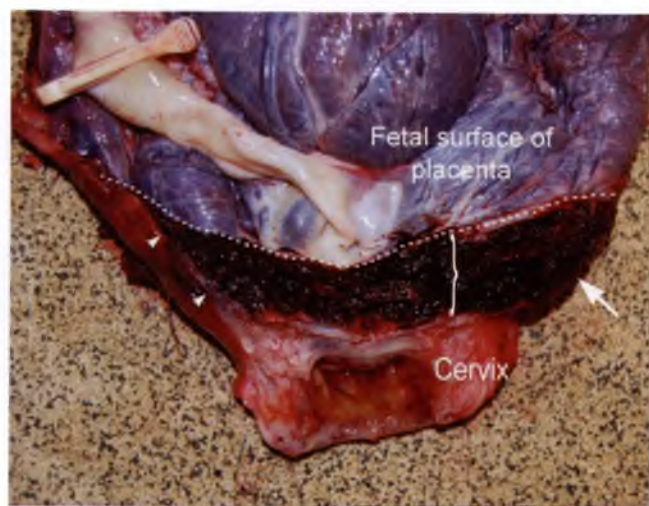


FIGURE 27-6 This cesarean hysterectomy specimen has been bisected and opened to show the placenta (bracket) overlying the cervix. The dotted line demarcates the fetal surface of the placenta previa. In this previa case, the placenta invades up to the uterine serosa on the left (arrowheads) and through the serosa on the right (arrow).

site (Wing, 1996b). Placental thromboplastin, which incites the intravascular coagulation seen with placental abruption, is presumed to readily escape through the cervical canal rather than be forced into the maternal circulation (Cunningham, 2015). The paucity of large myometrial veins in this area may also be somewhat protective.

■ Diagnosis

Whenever uterine bleeding is noted after midpregnancy, placenta previa or abruption should always be considered. In the Canadian Perinatal Network study, placenta previa accounted for 21 percent of women admitted from 22 to 28 weeks'

gestation with vaginal bleeding (Sabourin, 2012). Previa should not be excluded until sonographic evaluation has clearly proved its absence. If necessary, diagnosis by clinical examination is done using the *double set-up* technique because it requires that a finger be passed through the cervix and the placenta palpated. Fortunately, this is rarely indicated because placental location can almost always be ascertained sonographically. If this cannot be done, then a digital examination should not be performed unless delivery is planned. A cervical digital examination is done with the woman in an operating room and with preparations for immediate cesarean delivery because even the gentlest examination can cause torrential hemorrhage.

Sonographic Placental Localization

Evaluation of placental location is a standard component of the routine obstetric sonographic examination (American Institute of Ultrasound in Medicine, 2013). This is usually accomplished with *transabdominal sonography*. If the placenta clearly either overlies the cervix or in contrast lies distant from the lower uterine segment, the examination has excellent sensitivity and negative predictive value (Olive, 2006, Quant, 2014). If a question remains regarding the relationship between the inferior placental edge and the internal cervical os, *transvaginal sonography* is the most accurate method of assessment (Fig. 27-7). This approach is considered safe, even in the presence of bleeding. *Translabial sonography* is less commonly used, but it may be of benefit if transabdominal images are suboptimal and transvaginal sonography is not available.

Sonography can be used to exclude a placenta previa with a high negative predictive value at any gestational age (Reddy, 2014). And quick and accurate localization can be accomplished using standard sonographic techniques (Dashe, 2013). In many cases, *transabdominal sonography* alone is confirmatory. In some women, however, maternal habitus may limit visualization of the lower uterine segment. Moreover, sometimes a large fundal placenta is not appreciated to extend down to the internal

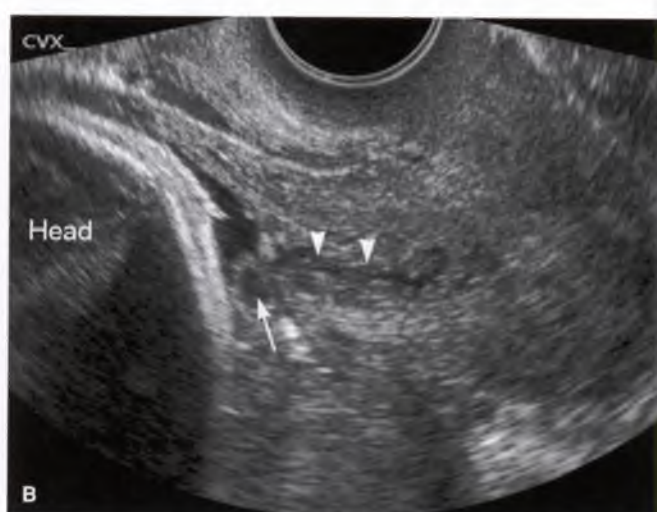
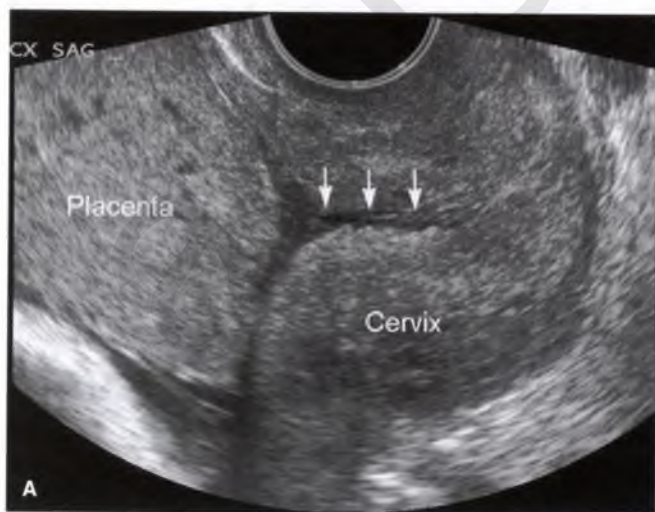


FIGURE 27-7 Placenta previa. **A.** In this transvaginal image at 34 weeks' gestation, the anterior placenta completely covers the internal cervical os. The internal os and endocervical canal are marked by arrows. **B.** This transvaginal image at 34 weeks' gestation depicts a posterior placenta that just reaches the level of the internal cervical os (arrow). The endocervical canal is marked by arrowheads. Whether the placenta partially covers the closed os or just reaches the margin of the os is not considered a distinction that is technically discernible or clinically helpful. (Used with permission from Dr. Jodi Dashe.)

cervical os. Also, a full bladder may artificially elongate the cervix and give the impression that placenta overlies it. Therefore, doubtful cases should be confirmed after bladder emptying. *Transvaginal sonography* is safe, and the results are superior to abdominal sonography. For example, in a comparative study by Farine and associates (1988), the internal os was visualized in all cases using transvaginal sonography but was seen in only 70 percent using transabdominal sonography.

Placenta Previa Imaging. Placenta previa is diagnosed when the placenta covers or just reaches the internal cervical os. In the absence of any other indication, sonography need not be frequently repeated simply to document placental position. Instead, a second sonographic assessment is recommended at approximately 32 weeks' gestation to evaluate for resolution of the previa (Reddy, 2014; Silver, 2015a). If the previa persists, additional transvaginal sonography is then recommended at 36 weeks' gestation.

Low-Lying Placenta Imaging. A low-lying placenta is diagnosed if the placental edge is <2 cm from the internal os, but not covering it (Fig. 27-8). With additional indications, a second sonographic evaluation is scheduled for 32 weeks' gestation. At this time, if the placental edge now is still <2 cm from the internal os, then transvaginal sonography is repeated at 36 weeks. Importantly, in cases of resolved placenta previa or low-lying placenta, localization of the umbilical cord insertion is necessary because these pregnancies are at risk for *vasa previa*.

Magnetic Resonance Imaging

Although several investigators have reported excellent results using magnetic resonance (MR) imaging to visualize placental abnormalities, it is unlikely that this technique will replace sonography for routine evaluation anytime soon. That said, MR imaging has proved useful for evaluation of placenta accrete syndromes, discussed on page 445.

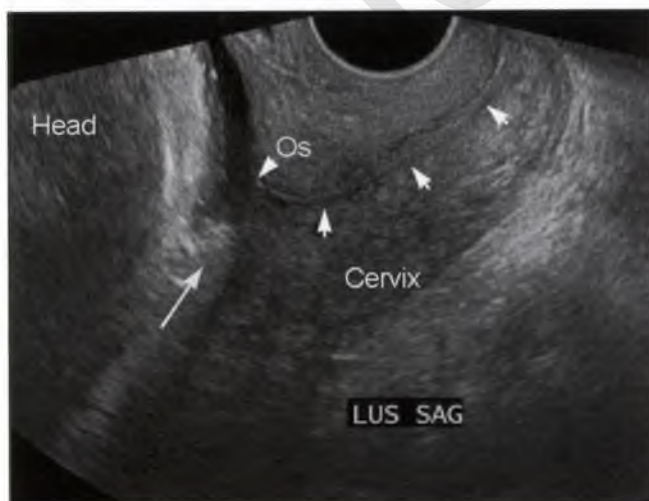

FIGURE 27-8 Low-lying placenta. In this transvaginal image at 34 weeks' gestation, the measurement from the inferior edge of the posterior placenta (*long arrow*) to the internal os (*arrowhead*) is approximately 1 cm. The endocervical canal is marked by short arrows. (Used with permission from Dr. Jodi Dashe.)

Management

Women with placenta previa are managed according to their individual clinical circumstances. The three factors that usually are considered include fetal age and thus maturity, concurrent labor, and bleeding and its severity. Restriction of activity is not necessary unless a previa persists beyond 28 weeks or if clinical findings such as bleeding or contractions develop before this time.

However, antepartum bleeding is common. In one study of 214 women with a previa, 43 percent had an emergent delivery and 46 percent of those were preterm (Eschbach, 2015). But if the fetus is preterm and active bleeding stops, management favors close observation in an obstetric unit. Data are sparse regarding tocolytic administration for uterine contractions. Although quality randomized trials are lacking, most recommend that if tocolytics are given, they be limited to 48 hours of administration (Bose, 2011; Verspyck, 2015). We do not recommend their use.

After bleeding has ceased for approximately 2 days and the fetus is judged to be healthy, the woman can usually be discharged home. However, she and her family must fully appreciate the possibility of recurrent bleeding and be prepared for immediate transport back to the hospital. In some cases, prolonged hospitalization may be ideal. In properly selected patients, no benefits are gained by inpatient compared with outpatient management (Mouer, 1994; Neilson, 2003). In a randomized study by Wing and colleagues (1996a), maternal or fetal morbidity rates did not differ between the two management methods. This trial of inpatient versus home management included 53 women who had a bleeding previa at 24 to 36 weeks' gestation. Of these women, 60 percent had recurrent bleeding. Also, of all 53 women, half eventually required expeditious cesarean delivery. Home management is more economical, and in one study, hospital stays and costs for maternal-neonatal care were reduced by half with outpatient management (Drost, 1994).

For women who are near term and who are not bleeding, plans are made for scheduled cesarean delivery. Timing is important to maximize fetal growth but to minimize the possibility of antepartum hemorrhage. A National Institutes of Health workshop concluded that women with placenta previa are best served by elective delivery at 36 to 37 completed weeks' gestation (Spong, 2011). With suspected placenta accrete syndromes, delivery was recommended at 34 to 35 completed weeks. At Parkland Hospital, we prefer to wait until 37 to 38 weeks' gestation before delivery for placenta previa.

Delivery

It is axiomatic that with few exceptions, most women with placenta previa will undergo cesarean delivery. Many surgeons recommend a vertical skin incision. Importantly, unscheduled cesarean delivery—many times emergent—becomes necessary in more than half of cases because of hemorrhage, for which about a fourth require blood transfusion (Boyle, 2009; Sabourin, 2012).

Although a low transverse hysterotomy is usually possible, this may cause fetal bleeding if the placental site is anterior. Thus, some prefer a vertical uterine incision. When the placenta is cut through, expeditious delivery is mandatory (Silver,

2015a). That said, even when the incision extends through the placenta, maternal or fetal outcomes are rarely compromised. Of note, rates of anterior placenta previa are approximately equal to rates of posterior previa (Salmanian, 2015; Young, 2013). Anterior previas more often lead to hysterectomy, but posterior previas are equally morbid in all other aspects (Young, 2014).

Following placental removal, uncontrollable hemorrhage may ensue because of the poorly contracted smooth muscle of the lower uterine segment. When hemostasis at the placental implantation site cannot be obtained by pressure, the implantation site can be oversewn with chromic sutures. Cho and associates (1991) described interrupted 0-gauge chromic sutures at 1-cm intervals to form a circle around the bleeding portion of the lower uterine segment. They reported that this controlled hemorrhage in all eight women in whom it was employed. Huissoud and coworkers (2012) also described successful use of circular sutures. Kayem (2011) and Penotti (2012) and their colleagues reported that only 2 of 33 women with placenta previa and no accreta and who were subsequently treated with anterior-to-posterior uterine compression sutures following placenta removal required hysterectomy.

Other methods have been recommended. Kumru and associates (2013) reported success with the Bakri balloon in 22 of 25 cases (Fig. 29-5, p. 473). Diemert and coworkers (2012) described good results with combined use of a Bakri balloon and compression sutures. Albayrak and colleagues (2011) described Foley balloon tamponade. Druzin (1989) proposed tightly packing the lower uterine segment with gauze, and the pack was removed transvaginally 12 hours later. Successful use of hemostatic gel has been reported (Law, 2010; Martinez-Gaytan, 2014). Other methods that are described in Chapter 29 include bilateral uterine or internal iliac artery ligation and pelvic artery embolization (p. 475).

If these more conservative methods fail and bleeding is brisk, then hysterectomy is necessary. Indeed, placenta previa—especially with abnormally adherent placental variations—currently is the most frequent indication for peripartum hysterectomy at Parkland Hospital and other institutions (Hernandez, 2012; Wong, 2011). It is not possible to accurately estimate the effect on hysterectomy rates from previa alone without considering the associated accrete syndromes. It is again emphasized that women with placenta previa implanted anteriorly at the site of a prior uterine incision carry an increased likelihood of associated placenta accrete syndromes and need for hysterectomy.

Of reported rates, in one study of 318 peripartum hysterectomies from in the United Kingdom, 40 percent were done for an abnormally implanted placenta (Knight, 2007). In an Australian study of emergent peripartum hysterectomy, 19 percent were done for placenta previa, and another 55 percent for a morbidly adherent placenta (Awan, 2011). In one audit at Parkland Hospital, 24 percent of 444 women delivered for placenta previa required hysterectomy for hemostasis (Wortman, 2015). In another audit done at Parkland Hospital, 44 percent of all cesarean hysterectomies were done because of bleeding from a placenta previa or accrete syndromes. The technique for peripartum hysterectomy is described in Chapter 26 (p. 423). Special concerns for hysterectomy with accrete syndromes are discussed on page 446.

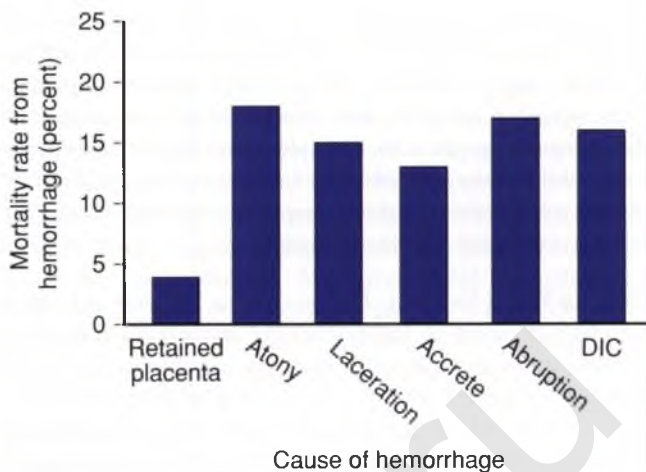


FIGURE 27-9 Contributions to maternal death rates from various causes of obstetric hemorrhage. Percentages are approximations because of different classification schemata used. DIC = disseminated intravascular coagulopathy. (Data from Al-Zirqi, 2008; Berg, 2010; Creanga, 2015; Zwart, 2008.)

■ Maternal and Perinatal Outcomes

A marked reduction in maternal mortality rates from placenta previa was achieved during the last half of the 20th century. Still, as shown in Figure 27-9, placental disorders contribute substantially to maternal morbidity and mortality rates. In one review, the maternal mortality ratio was increased threefold to 30 per 100,000 for women with placenta previa (Oyelese, 2006). In a report from the Centers for Disease Control and Prevention, of 3358 maternal deaths in the United States from 2006 to 2010, placenta previa and accrete syndromes accounted for 16 percent of deaths from hemorrhage (Creanga, 2015).

The report from the Consortium on Safe Labor emphasizes the ongoing perinatal morbidity associated with placenta previa (Lai, 2012). Preterm delivery continues to be a major cause of perinatal death (Nørgaard, 2012). For the United States in 1997, Salihu and associates (2003) reported a threefold increased neonatal mortality rate with placenta previa that was caused primarily by preterm delivery. Ananth and colleagues (2003b) reported a comparably increased risk of neonatal death even for fetuses delivered at term. This is at least partially related to fetal anomalies that are increased two- to threefold in pregnancy with placenta previa (Crane, 1999).

Interestingly, the association of fetal growth restriction with placenta previa is likely minimal after controlling for gestational age (Crane, 1999). In a population-based cohort of more than 500,000 singleton births, Ananth and associates (2001) found that most low-birthweight neonates associated with placenta previa resulted from preterm birth. Harper and coworkers (2010) reported similar findings from a cohort of nearly 58,000 women who underwent routine second-trimester sonographic evaluation at their institution.

MORBIDLY ADHERENT PLACENTA

The placenta accrete syndromes describe the abnormally implanted, invasive, or adherent placenta. These include placenta accreta, increta, and percreta, which are described subsequently.

These abnormalities are referred to as morbidly adherent placenta. Derivation of *accrete* comes from the Latin *ac-* + *crescere*—to grow from adhesion or coalescence, to adhere, or to become attached to (Benirschke, 2012). Accrete syndromes thus include any placental implantation with abnormally firm adherence to myometrium because of partial or total absence of the decidua basalis and imperfect development of the fibrinoid or *Nitabuch layer*. If the decidual spongy layer is lacking either partially or totally, then the physiologic line of cleavage is absent and some or all cotyledons are densely anchored. The surface area of the implantation site involved and the depth of trophoblastic tissue ingrowth are variable between women, but any abnormally adherent placenta can potentially cause significant hemorrhage.

Accrete syndromes have evolved into one of the most serious problems in obstetrics. As subsequently discussed, the likelihood of this syndrome is closely linked to prior uterine surgery, especially cesarean delivery. Thus, related to the currently high rate of cesarean delivery in the United States, the frequency of morbidly adherent placenta has reached seemingly epidemic proportions. And, at least until recently, there has seemed to be no consensus for management (Shamshirsaz, 2015; Silver, 2015a,b; Wright, 2013). To better mitigate some of the serious consequences associated with placenta accrete syndromes, the American College of Obstetricians and Gynecologists (2016) and the Society for Maternal-Fetal Medicine (2010) have taken the lead to address management problems. Accrete syndromes have also been the subject of several excellent reviews (Rao, 2012; Wortman, 2013).

■ Etiopathogenesis

Microscopically, with the accrete syndromes, placental villi are anchored to muscle fibers rather than to decidual cells. Thus, decidual deficiency prevents normal placental separation after delivery. Intuitive thinking and now substantiated data suggest that accrete syndromes are not solely caused by an anatomic layer deficiency (Tantbirojn, 2008). Evidence indicates that the cytotrophoblasts may control decidual invasion through factors such as angiogenesis and growth expression such as with E-cadherin (Cohen, 2010; Duzyj, 2013, 2015; Wehrum, 2011). Indeed, tissue specimens from morbidly adherent placentas show “hyperinvasiveness” compared with otherwise uncomplicated previa specimens (Miller, 2015; Pri-Paz, 2012). As described by Benirschke and colleagues (2012), a “constitutional endometrial defect” predisposes in most cases. The increased risk conveyed by previous uterine trauma—for example, cesarean delivery—may be partially explained by an increased vulnerability of the decidua to trophoblastic invasion following incisions or other traumatic lesions into the decidua (Garmi, 2011; Gill, 2015).

■ Classification

The placenta accrete syndromes are classified by the depth of trophoblastic growth (see Fig. 27-2). *Placenta accreta* indicates that villi are attached to the myometrium. With a decreasing incidence, these are further termed *placenta increta*, in which villi actually invade into the myometrium (Fig. 27-10). Finally, *placenta percreta* defines villi that penetrate through the myometrium and to or through the serosa (Fig. 27-11). In clinical practice, these three variants are encountered in an approximate

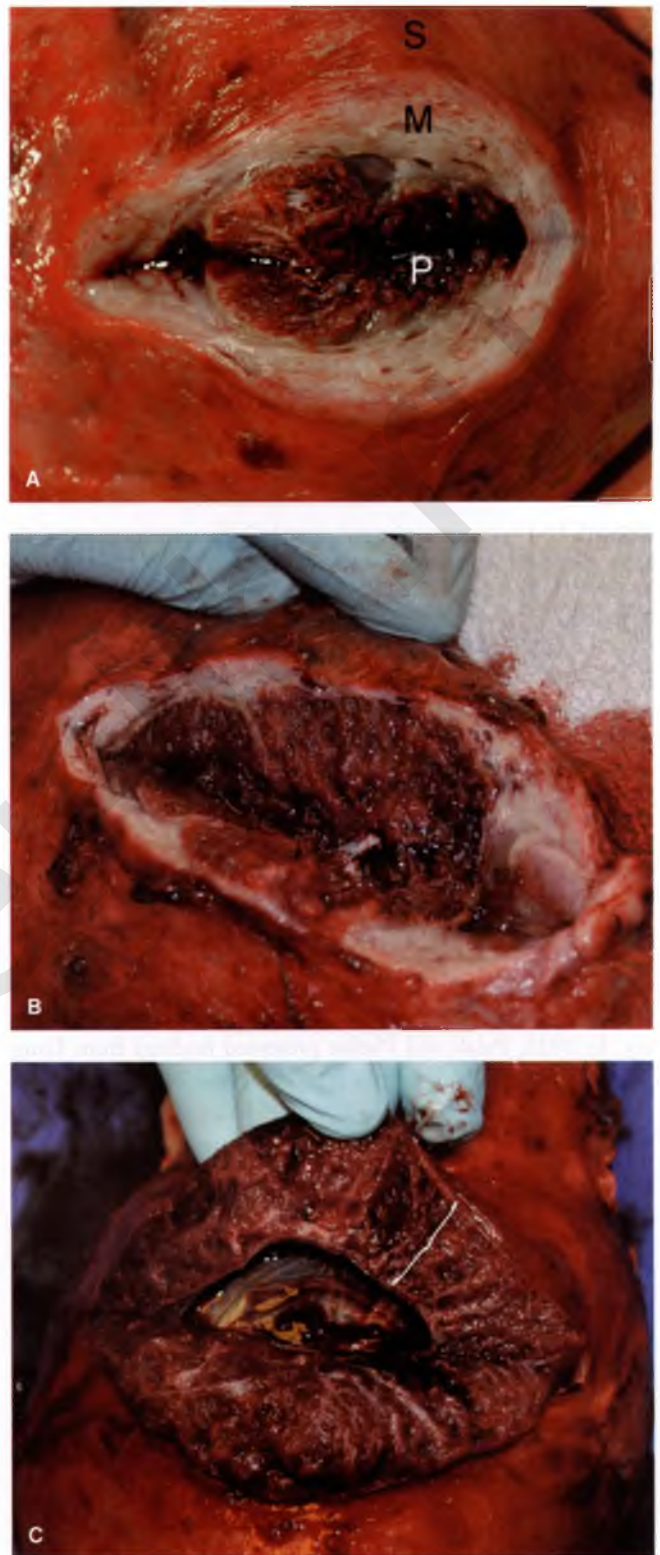


FIGURE 27-10 Varying degrees of myometrial invasion with the accrete syndromes. Incisions begin on the uterine serosal surface and extend through to the placenta. **A.** In this case, the myometrium (*M*) shows minimal invasion by the placenta (*P*). *S* = uterine serosa. **B.** A greater degree of myometrial invasion is seen here. **C.** In this example, the placenta (bracket) extends to the serosal edge, held by the surgeon's hand. No myometrium remains at this site. (Used with permission from Dr. C. Edward Wells.)

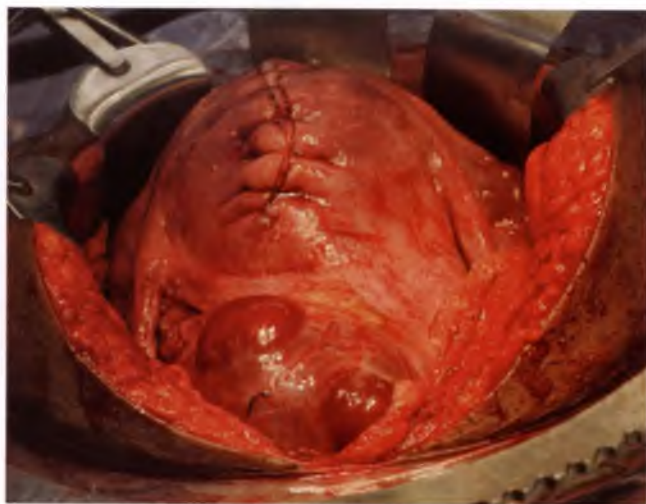


FIGURE 27-11 Placenta percreta seen bulging under the anterior uterine serosa at the time of laparotomy. The classical hysterotomy has been repaired prior to hysterectomy. (Used with permission from Dr. C. Edward Wells.)

ratio of 80:15:5, respectively (Wong, 2008). Abnormal adherence may involve all lobules, for example, *total placenta accreta*. Or, if all or part of a single lobule is abnormally attached, it is described as a *focal placenta accreta*. Histologic diagnosis cannot be made from the placenta alone, and the uterus or curettings with myometrium are necessary for histopathologic confirmation (Benirschke, 2012).

■ Incidence and Associated Conditions

The increased frequency of accrete syndromes during the past 50 years stems from the liberalized practice of cesarean delivery. In 1924, Polak and Phelan presented findings from Long Island College Hospital, in which there was only one case of placenta accreta complicating 6000 deliveries. In a 1951 review by McKeogh, a maternal mortality rate of up to 65 percent was cited. In 1971, Hellman and Pritchard in the 14th edition of *Williams Obstetrics* described placenta accreta to be the subject of case reports. In a review several years later, Breen and coworkers (1977) cited a reported average incidence of 1 in 7000 deliveries.

Since these reports, however, the incidence of accrete syndromes has risen remarkably in direct relationship to the increasing cesarean delivery rate (Chap. 25, p. 404). By the 1980s, the incidence of placenta accrete syndromes was reported to be 1 in 2500. More recently, the American College of Obstetricians and Gynecologists (2016) cites it to be as high as 1 in 533 deliveries. This incidence comports with observations in a recent report from the Maternal-Fetal Units Network (Bailit, 2015). The cited frequency of a morbidly adherent placenta in 115,502 women was 1 per 731 births. Of these, 70 percent required hysterectomy. Similarly, a Canadian study of more than 570,000 deliveries noted an incidence of 1 in 700 births (Mehrabdi, 2015). Still, others report a higher prevalence (Mogos, 2016).

Because of their rising frequency, accrete syndromes are now one of the more serious problems facing obstetricians. In addition to their significant contribution to maternal morbidity and mortality rates, accrete syndromes are a leading cause of intractable postpartum hemorrhage and emergent peripartum

hysterectomy (Awan, 2011; Eller, 2011; Rossi, 2010). Their contribution as a cause of maternal deaths from hemorrhage is shown in Figure 27-9. In their review of 3358 pregnancy-related maternal deaths in the United States from 2006 to 2010, Creanga and associates (2015) reported that 13 percent of deaths due to hemorrhage were caused by accrete syndromes.

Risk Factors

These are similar in many aspects to those for placenta previa (p. 438). That said, the most important risk factors are an associated previa, a prior cesarean delivery, or most likely, a combination of the two (Klar, 2014). In one study, a morbidly adherent placenta was a more common sequela in a second pregnancy if the first pregnancy was delivered by emergent rather than elective cesarean delivery (Kamara, 2013). And, a classical hysterotomy incision has a higher risk for abnormal myometrial invasion in a subsequent pregnancy (Gyamfi-Bannerman, 2012). In fact, more than half of women with a prior cesarean delivery had myometrial fibers seen microscopically adhered to the placenta (Hardardottir, 1996; Miller, 2015; Zaki, 1998). Findings from a Maternal-Fetal Medicine Units Network study by Silver and colleagues (2006) of women with one or more prior cesarean deliveries and who also had a placenta previa are shown in Figure 27-12. The astonishingly elevated frequency of associated accrete syndromes is apparent.

Decidual formation also may follow any other type of myometrial trauma such as curettage or endometrial ablation (Benirschke, 2012; Gill, 2015). But prior myomectomy apparently confers only a low risk (Gyamfi-Bannerman, 2012). Even without a prior hysterotomy, a coexisting placenta previa is additive to frequency. In one study, 10 percent of women with a previa had an associated morbidly adherent placenta. A shorter cervical length with placenta accrete syndromes did not confer a greater risk for preterm delivery compared with those who had placenta previa without an accreta (Rac, 2015a).

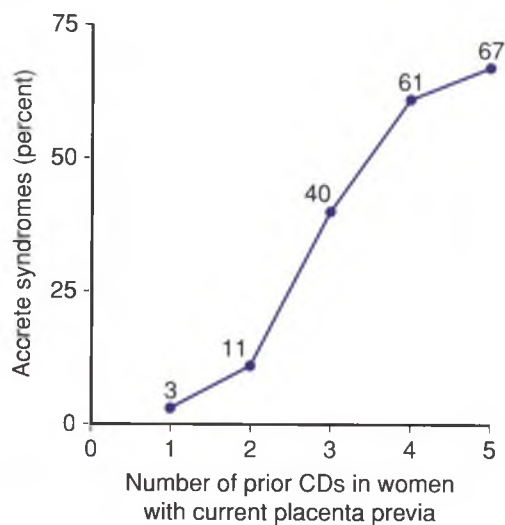


FIGURE 27-12 Frequency of accrete syndromes in women with one to five prior cesarean deliveries (CDs) and now with a previa. (Reproduced with permission from Cunningham FG, Leveno KJ, Bloom SL, et al (eds): *Obstetrical hemorrhage*. In *Williams Obstetrics*, 24th ed. New York, McGraw-Hill Education, 2014; data from Silver, 2006.)

Another risk factor became evident with widespread use of MSAFP screening for neural-tube defects and human chorionic gonadotropin (hCG) screening for aneuploidies. In a study reported by Hung (1999) of more than 9300 women screened at 14 to 22 weeks, the risk for accrete syndromes was increased eightfold with MSAFP levels >2.5 MoM. The risk was increased fourfold when maternal free β -hCG levels were >2.5 MoM.

Cesarean Scar Pregnancy

In some women with a morbidly adherent placenta, adverse outcomes can precede fetal viability. One presentation generally referred to as a *cesarean scar pregnancy* is similar clinically to an ectopic pregnancy (Michaels, 2015; Timor-Tritsch, 2015). Its frequency approximates 1 in 2000 pregnancies (Ash, 2007; Berhie, 2015; Rotas, 2006). Timor-Tritsch (2012) provided a scholarly review of 751 such cases, and the subject is discussed in detail in Chapter 8 (p. 128).

■ Clinical Presentation and Diagnosis

In cases of first- and second-trimester accrete syndromes, hemorrhage is common as the consequence of coexisting placenta previa. In rare cases, uterine rupture develops before fetal viability (Conroy, 2014). In most cases, however, bleeding will usually prompt evaluation and management. In some women who do not have an associated previa, accreta may not be identified until third-stage labor when an adherent placenta is encountered. Unfortunately, currently available imaging modalities are less than perfect to identify all placentas with clinically dangerous myometrial invasion.

Sonography

Ideally, this modality is used for antepartum identification of abnormal placental ingrowth (Chantraine, 2013; Reddy, 2014; Tam Tam, 2012). According to Guy and colleagues (1990), sonographic findings include loss of the normal hypoechoic retroplacental zone between the placenta and uterus, placental vascular lacunae, and placental bulging into the posterior bladder wall (Fig. 27-13). The retroplacental myometrium can also appear thinned. Several changes are notable at the bladder-serosal interface. Here, the normally echogenic interface can be irregular and display increased vascularity. Also, bridging vessels may course from the placenta to this interface (Dashe, 2016).

Using these criteria for sonographic identification, Warshak and associates (2006) calculated the following values with 95-percent confidence intervals noted in parentheses: sensitivity of 77 percent (60–80); specificity of 96 percent (93–97); positive predictive value of 65 percent (49–78); and negative predictive value of 98 percent (95–98). Doyle and coworkers (2015) reported even better results with three-dimensional (3-D) sonography. Similar values for transvaginal sonography are cited by the American College of Obstetricians and Gynecologists (2016) and others (Chalubinski, 2013; Elhawary, 2013; Maher, 2013).

Despite these findings, some investigators report less definitive results with sonography (Primo, 2014). In a study from the University of Utah, Bowman and colleagues (2014) described the sensitivity of sonography to be 54 percent; specificity 88 percent; positive predictive value 82 percent; negative predictive value 65 percent; and accuracy 65 percent. Based on these findings,

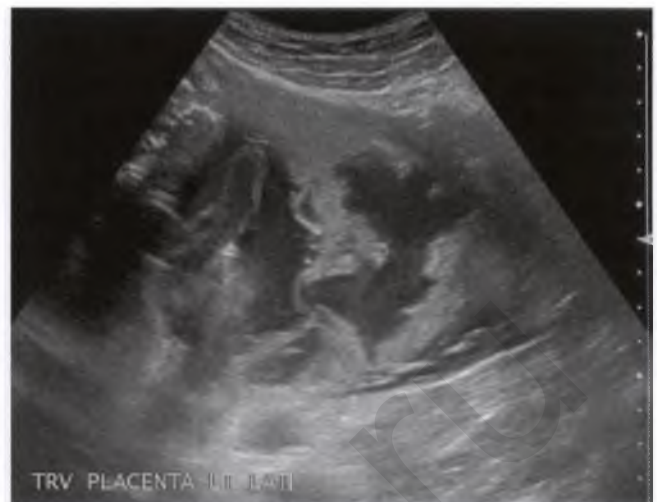

FIGURE 27-13 Transabdominal sonogram of placenta percreta shows multiple and massive anechoic placental “lakes” or “lacunae.” (Used with permission from Dr. Martha Rac.)

Nageotte (2014) concluded that identification of accrete syndromes with sonography alone is a challenge and findings need to be interpreted in concert with clinical and operative findings.

Although somewhat controversial, at Parkland Hospital, we have found that the addition of Doppler color flow mapping is highly predictive of myometrial invasion (Fig. 27-14). This is suspected if the distance between the uterine bladder-serosal interface and the retroplacental vessels is <1 mm and if large intraplacental lacunae are present (Rac, 2015b; Twickler, 2000). Similarly, Cali and associates (2013) reported that hypervascularity of the bladder-serosal interface had the highest positive and negative predictive values for placenta percreta.

Magnetic Resonance Imaging

This imaging modality can be used as an adjunct to sonography to outline anatomy, invasion of adjacent structures, and possible ureteral involvement (Chalubinski, 2013; Palacios Jaraquemada, 2005; Reddy, 2014). Lax and coworkers (2007) identified three

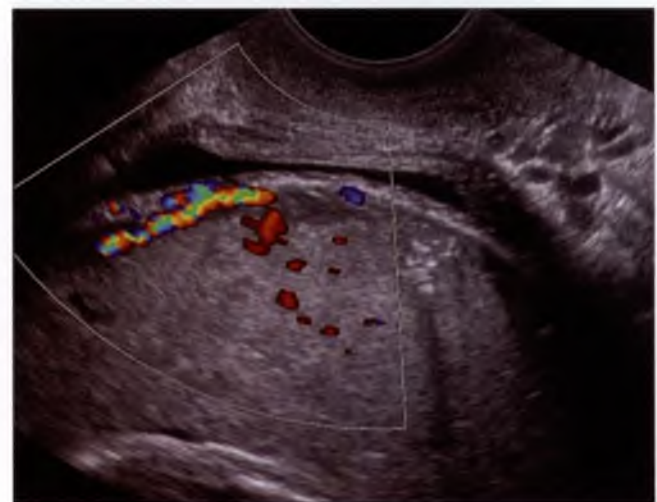


FIGURE 27-14 Transvaginal sonogram showing bridging vessels at the uterine-bladder interface. Lacunae are also seen farther into the placenta body. (Used with permission from Dr. Patricia Santiago-Munoz.)

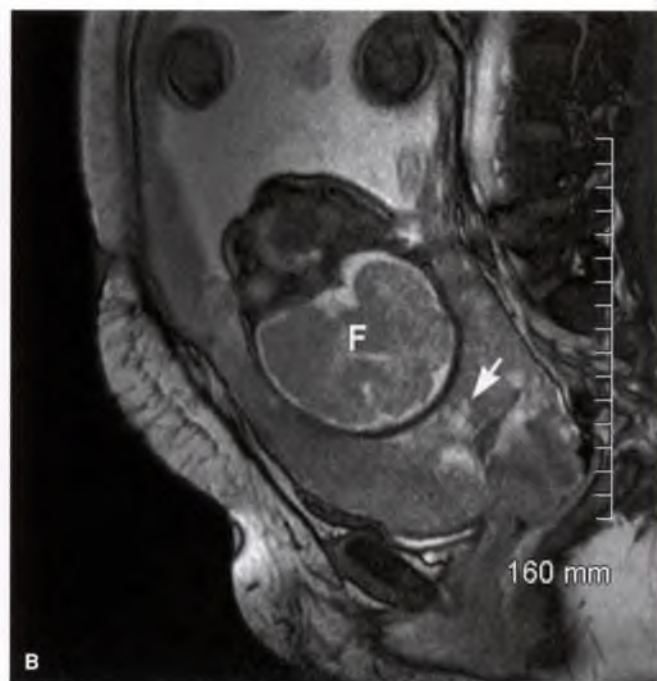
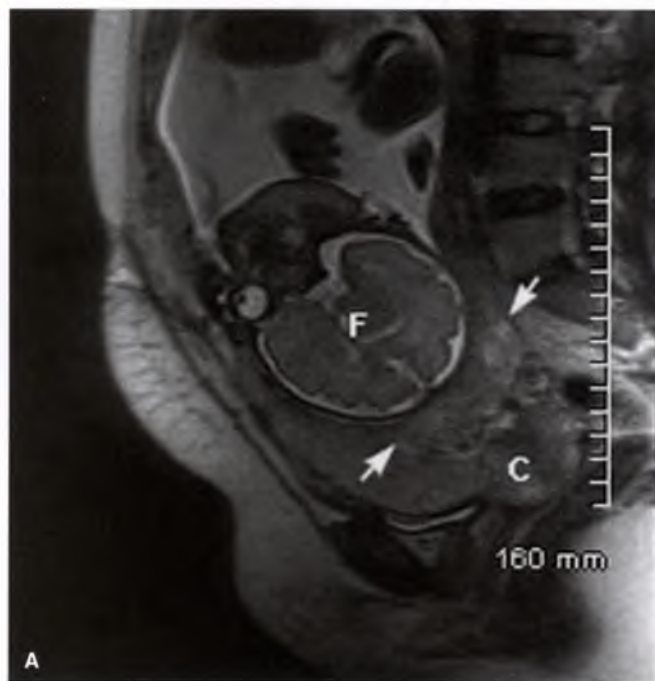


FIGURE 27-15 Magnetic resonance imaging of placenta percreta at 32 weeks' gestation. **A.** This sagittal T2-weighted image through the lower uterine segment shows a complete previa. Heterogeneous signal intensity (*arrows*) is identified in the placenta near the cervix (C), but the integrity of the cervix itself is preserved. **B.** The increased signal intensity within the heterogeneous placenta on the lower balanced sequence suggests vascular flow, as seen in lacunae (*arrow*). F = fetus. (Used with permission from Dr. April Bailey.)

MR imaging findings that suggested accreta: uterine bulging, heterogeneous signal intensity within the placenta that reflect lacunae, and dark intraplacental bands on T2-weighted imaging (Figs. 27-15 and 27-16). Some suggest performance of MR imaging when sonography results are inconclusive or there is a posterior previa (American College of Obstetricians and Gynecologists, 2016; Elhawary, 2013; Silver, 2015a). The use of gadolinium contrast was reported to improve MRI-based diagnosis of morbidly adherent placenta (Millischer, 2016). Possible fetal effects of gadolinium administration to the pregnant woman are discussed in Chapter 5 (p. 76).

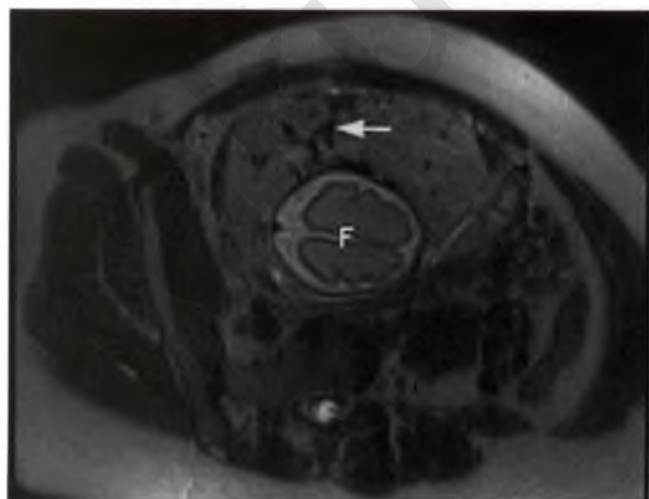


FIGURE 27-16 Magnetic resonance imaging of a complete previa with placenta percreta at 28 weeks' gestation. Dark linear bands representing lacunae (*arrow*) are seen in the expected location of the prior low transverse incision. The fetal vertex is also seen (F). (Used with permission from Dr. April Bailey.)

Management

Preoperative assessment should begin at the time of recognition during prenatal care (Fitzpatrick, 2014; Sentilhes, 2013). Of primary importance, the timing of and the ideal institution for delivery are selected. Exigencies to be considered are appropriate surgical, anesthesia, and blood banking capabilities. An obstetric surgeon or gynecologic oncologist and consultants from surgery, urology, interventional radiology, and transfusion services should be available. This team provides expertise to address possible placental invasion into the bladder, ureteral isolation or repair, extensive dissection within the pelvic retroperitoneum, and need for vessel embolization (Eller, 2011; Shamshirsaz, 2015). Women who refuse blood or its derivatives require especially difficult management decisions (Barth, 2011).

For all these reasons, the American College of Obstetricians and Gynecologists (2016) and the Society for Maternal-Fetal Medicine (2010) recommend planned delivery in a tertiary-care facility. In some of these, especially designed teams have been assembled and are on call (Al-Khan, 2014; Shamshirsaz, 2015; Walker, 2013). Silver and colleagues (2015b) have provided criteria for accreta centers of excellence as shown in Table 27-3.

Criteria can guide the transfer to a facility providing a higher level of care (Table 27-4). If possible, delivery is best scheduled for peak availability of all resources and team members. That said, an emergency contingent plan should be in place to care for women who present with unscheduled bleeding.

Delivery Timing

To accomplish scheduled surgical intervention, preterm delivery is usually necessary and justified given the serious adverse maternal consequences of emergent cesarean delivery. The American College of Obstetricians and Gynecologists (2016) recommends

TABLE 27-3. Suggested Criteria for an Accreta Center of Excellence**Multidisciplinary team**

Maternal-fetal medicine or experienced obstetrician
 Imaging experts
 Pelvic surgeon—gynecological oncology, urogynecology
 Anesthesiologist
 Urologist
 General surgeon
 Interventional radiologist
 Neonatologist

Intensive care facilities

Medical or surgical intensive care unit (ICU)
 Neonatal ICU

Blood availability

Massive transfusion capability
 Cell saver
 Transfusion medicine specialists

From Silver, 2015.

TABLE 27-4. Criteria for Consideration of Delivery in an Accreta Center of Excellence

Suspicion for accreta from sonographic findings
 Placenta previa with abnormal sonographic appearance
 Placenta previa with ≥ 3 prior cesarean deliveries
 Prior classical cesarean delivery and anterior placentation
 Prior endometrial ablation or pelvic radiation
 Inability to adequately evaluate or exclude placenta accreta
 Any other reason to suspect placenta accreta

From Silver, 2015.

individualization of delivery timing. It cites a decision-analysis study that justifies elective delivery without fetal lung maturity testing after 34 completed weeks' gestation (Robinson, 2010). With its multidisciplinary approach, the protocol at the Baylor College of Medicine is elective delivery at 34 to 35 weeks (Shamshirsaz, 2015). At Parkland Hospital, we generally schedule these procedures after 36 completed weeks, however, we are prepared also to manage them in nonelective situations (Rac, 2015c).

Preoperative Arterial or Ureteral Catheters

There has been enthusiasm for placement of intraarterial catheters to mitigate blood loss and to enhance surgical visibility. Balloon-tipped catheters advanced into the internal iliac arteries are inflated after delivery to occlude pelvic blood flow to aid placental removal and hysterectomy (Ballas, 2012; Desai, 2012). Alternatively, the catheters can be used to embolize bleeding arterial sites. Others have concluded that these procedures offer borderline efficacy and have serious risks (Sentilhes, 2013; Yu, 2009). Complications have included thromboses of the common and external iliac arteries (Bishop, 2011; Greenberg, 2007). At this time, we agree with the American College of Obstetricians and Gynecologists (2016) that a firm recommendation cannot be made for or against the use of preoperative arterial catheterization.

The preoperative placement of ureteral stents is controversial. They are used by some clinicians to help prevent inadvertent ureteral injury. If used, they are usually placed in the operating room after epidural analgesia has been administered. As another use described in Chapter 28 (p. 458), if ureteral damage is suspected intraoperatively, open cystostomy can allow retrograde insertion of stent(s).

Cesarean Delivery and Hysterectomy

Before commencing with delivery, the risk of hysterectomy to prevent exsanguination should be anticipated. Confirmation of a percreta or increta almost always mandates hysterectomy. That

said, some of these cases of abnormal placentation—especially placenta accreta, and more so if partial—may be amenable to placental delivery and subsequent hemostatic suture placement.

Because the scope of invasion may not be apparent before delivery of the fetus, it may be advantageous in some cases to attempt to create a wide bladder flap *before* making the hysterotomy incision (Fig. 27-17). Especially in women with one or

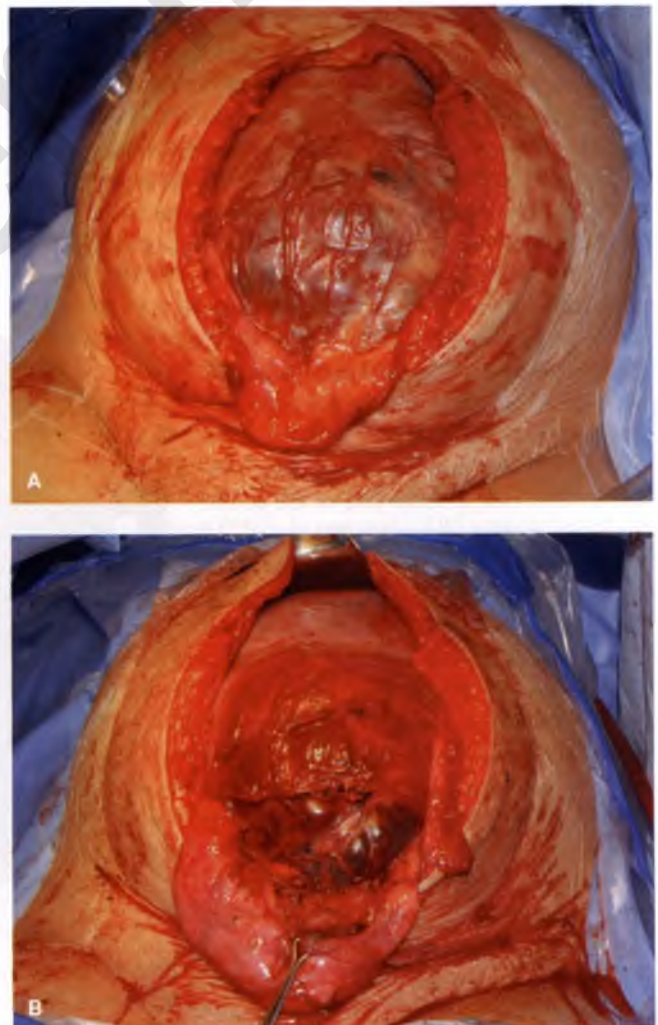


FIGURE 27-17 A. Placenta percreta at time of laparotomy and prior to hysterotomy. **B.** The bladder flap is developed to the degree possible prior to uterine incision. (Used with permission from Dr. Julie Lo.)

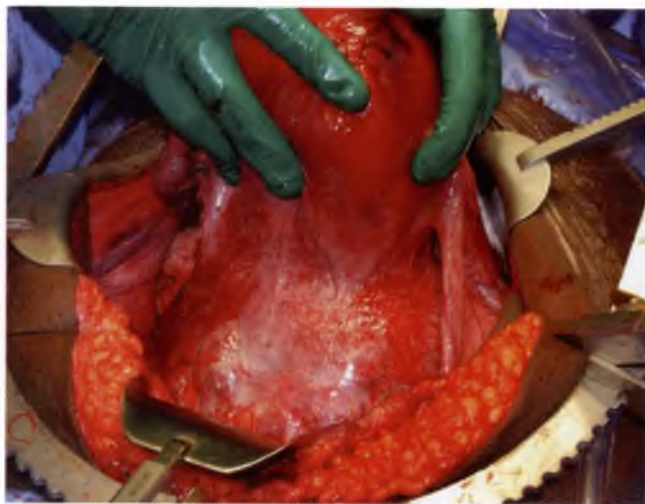

FIGURE 27-18 Placenta percreta extending to the pelvic sidewall is assessed prior to cesarean hysterectomy. Fetal delivery was completed through a fundal incision, now closed, and the surgeon elevated the uterine corpus. (Used with permission from Dr. C. Edward Wells.)

more prior cesarean deliveries, dense adhesions may fill the vesico-uterine space between the bladder and the lower uterine segment. Thus, time spent prior to hysterotomy and initiation of hysterectomy can help avoid cystotomy and limit the substantial blood loss that often accrues during tedious dissection in a blood-filled field. However, some prefer to develop the vesicouterine space after delivery (Pelosi, 1999). A detailed explanation and illustration of cesarean hysterectomy is found in Chapter 26 (p. 423).

Division of the round ligament is an early step of hysterectomy and provides access to the retroperitoneum. With the accrete syndromes, the round ligaments are divided as far from the uterus as possible to permit access to the pelvic sidewalls. This lateral exposure may be needed in cases in which the accreta expanse fills the lower pelvis (Figs. 27-18 and 27-19). The anterior leaf of the broad ligament is then dissected downward. If possible, these incisions extend to encircle the entire placental implantation site that visibly occupies the prevesical space or the posterior bladder wall.

Following development of the bladder flap, a classical hysterotomy incision is made to avoid the placenta and profuse hemorrhage before fetal delivery (Fig. 25-16, p. 415). Some advocate a transverse fundal incision if the placenta occupies the entire anterior wall (Kotsuji, 2013). In some of these cases we have used a posterior fundal incision. A cephalic-presenting fetus typically then requires delivery by breech extraction (Fig. 27-20). The hysterectomy is then closed for hemostasis.

After fetal delivery, the extent of placental invasion is assessed without attempts at

manual placental removal. As discussed, with obvious percreta or increta, hysterectomy is usually the best course, and the placenta is left in situ. In some cases, a focal partial accreta may avulse easily and later emerge as a placental polyp (Benirschke, 2012). With more extensive placental ingrowth—even with total accreta—there may be little or no bleeding until manual placental removal is attempted. Unless there is spontaneous separation with bleeding that mandates emergent hysterectomy, the operation begins after full assessment is made and with the placenta left in situ. With bleeding, successful treatment depends on immediate blood replacement therapy and other measures that include uterine or internal iliac artery ligation, circumferential tourniquet placement to compress the uterine arteries, and balloon occlusion or embolization by an interventional radiologist. Various case reports have described argon beam coagulation and hemostatic combat gauze (Karam, 2003; Schmid, 2012).

Modified Radical Hysterectomy

The group at Baylor College of Medicine has assembled a multidisciplinary “percreta team” with a standardized approach to care for women with accrete syndromes (Shamshirsaz, 2015). Preoperative evaluation is coordinated by the maternal-fetal medicine team members, and gynecologic oncology, anesthesiology, and other services are consulted as needed. Plans are made for delivery at 34 to 35 weeks’ gestation. Following preoperative preparations, a *modified radical hysterectomy* is performed and is designed to ensure wide margins from the friable uterine wall. As a review, this more radical hysterectomy differs from simple hysterectomy at several steps. First, the uterine artery is transected where it crosses the ureter rather than its insertion at the lateral uterine wall. Second, cardinal ligament

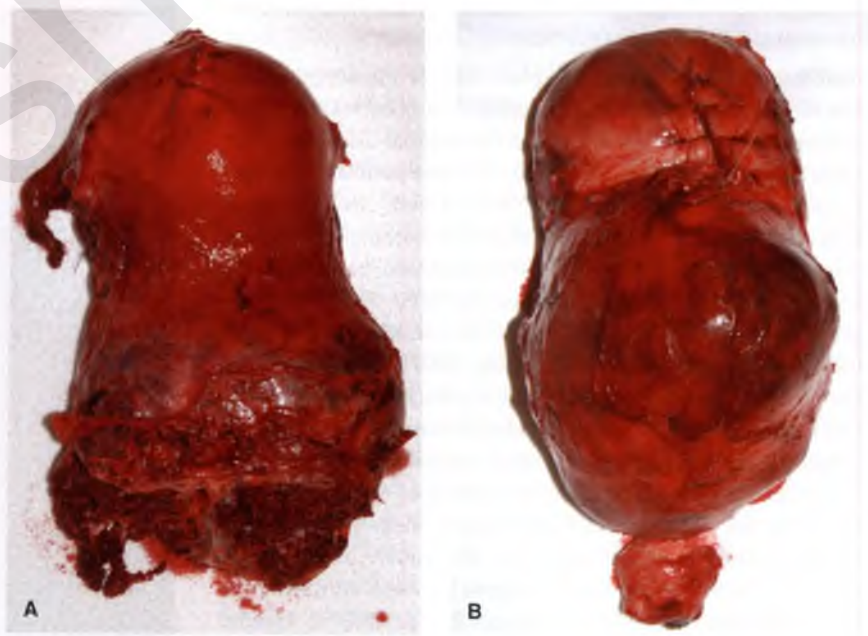


FIGURE 27-19 Hysterectomy specimens with placenta previa complicated by placenta percreta. **A.** In this example from Figure 27-18, the placenta extended to the pelvic sidewalls intraoperatively. Note the fundal incision used for fetal delivery. (Used with permission from Dr. C. Edward Wells.) **B.** In this case, placental bulk was less expansive and bulged ventrally. Note the classical hysterotomy incision used for fetal delivery. (Used with permission from Dr. Christopher Ripperda.)

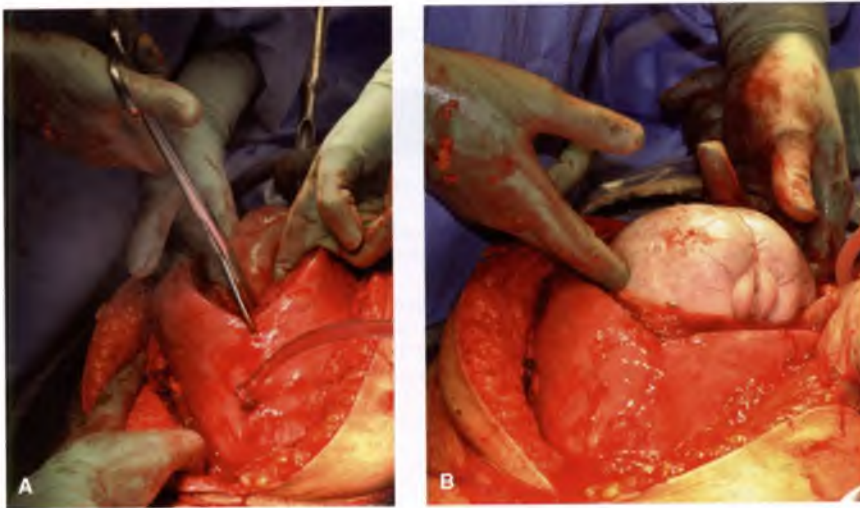


FIGURE 27-20 A fundal incision (A) allows breech extraction (B) without inciting placental bleeding prior to cesarean hysterectomy. (Used with permission from Dr. C. Edward Wells.)

and uterosacral ligaments are transected halfway between the uterus and the pelvic sidewall rather than at their insertion sites to the uterus. Last, a longer margin of upper vagina is removed.

Their management algorithm is depicted in [Figure 27-21](#) and is now summarized:

1. After epidural analgesia is achieved, cesarean delivery is performed while carefully avoiding the placenta. The hysterotomy is closed and ureteral stents are usually placed, depending on the breadth of placental invasion laterally.
2. The lateral retroperitoneum is accessed following division of the round ligaments. The ureters and iliac vessels are exposed.

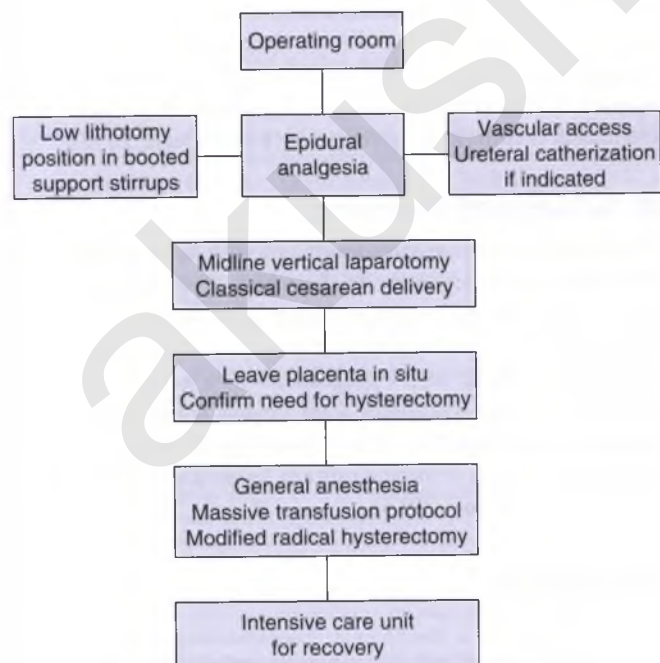


FIGURE 27-21. Management algorithm for morbidly adherent placenta. (Modified with permission from Shamshirsaz AA, Fox KA, Salmanian B, et al: Maternal morbidity in patients with morbidly adherent placenta treated with and without a standardized multidisciplinary approach, *Am J Obstet Gynecol* 2015 Feb;212(2):218.e1–e9.)

3. The uterus is separated from its support structures, leaving a wide margin.
4. The ovaries are preserved, but the fallopian tubes are removed as part of a risk-reducing strategy against ovarian cancer (Chap. 33, p. 525).
5. The uterine arteries are ligated, and the superior vesical arteries are clipped.
6. When necessary, ureterolysis is carried out to protect the ureters and allow step-by-step devascularization of the lower uterine segment followed by separation of the bladder and uterus.
7. In cases with deep placental invasion, intentional cystostomy and partial bladder excision is favored over persistent attempts at bladder dissection and mobilization.
8. In some cases in which the percreta involves the lateral pelvic sidewalls, staged intraoperative angiographic embolization is done before beginning the hysterectomy.

Leaving the Placenta in Situ

In some cases, after the fetus has been delivered, it may be possible to trim the umbilical cord and repair the hysterotomy incision but leave the placenta in situ. This may be the wisest choice for the woman in whom abnormal placentation was not suspected before cesarean delivery and in whom uterine closure stops bleeding. After this, she can be transferred to a higher-level facility for definitive management. Another consideration is the woman with a strong desire for fertility and who has received extensive counseling.

Conservative management was recently reviewed by Perez-Delboy and Wright (2014). In some of these cases in which the placenta is left in situ, it spontaneously resorbed by a median 13.5 weeks (Sentilhes, 2010). In others, a subsequent hysterectomy—either planned or prompted by bleeding or infection—is performed days to weeks postpartum when blood loss might be lessened (Al-Kahn, 2014; Hays, 2008; Lee, 2008; Perez-Delboy, 2014; Timmermans, 2007). In one study of 26 women treated this way, 21 percent ultimately required hysterectomy. Of the remainder, most required additional medical and surgical interventions for bleeding and infection (Bretelle, 2007). In other reports, however, up to 60 percent of such women eventually required emergent hysterectomy (Clausen, 2014; Pather, 2014). Evidence that treatment with methotrexate aids resorption is lacking. Last, for women in whom the placenta is left in situ, serial serum β -hCG measurements are not informative, and serial sonographic or MR imaging is recommended (Timmermans, 2007; Worley, 2008).

We agree with the American College of Obstetricians and Gynecologists (2016) that leaving the placenta in situ is seldom indicated, except for temporization pending transfer to a facility providing a higher level of care.

Undiagnosed Placenta Accrete Syndrome

In some cases, a morbidly adherent placenta is not recognized until the time of laparotomy for cesarean delivery. If there are inadequate resources to surgically manage accrete syndromes, and if

TABLE 27-5. Selected Maternal Outcomes in Women with Placenta Accrete Syndromes Identified Prenatally and Delivered in Tertiary-care Units

Outcome ^a	San Diego ^b n = 62	Utah ^c n = 60	Toronto ^d n = 33	New Jersey ^e n = 42	Houston ^f n = 57
Gestational age (wks)	33.9 ± 1.1	34 (17–41)	~ 32 (19–39)	~34.6 (25–40)	34 (16–39)
Operating time (min)	194 ± 1.6	NS	107 (68–334)	NS	287 (74–608)
Transfusions	~75%	70%	NS	NS	NS
RBC (units)	4.7 ± 2.2	≥4 (30%)	3.5 (0–20)	0–11	4 (0–24)
FFP (units)	4.1 ± 2.3	NS	NS	0–6	NS
Surgical outcomes					
Bladder injury	14 (23%)	22 (37%)	10 (30%)	7 (17%)	17 (30%) ^g
Ureteral injury	5 (8%)	4 (7%)	0	NS	1 (2%)
Postoperative outcomes					
ICU admission	43 (72%)	18 (30%)	5 (15%)	8 (21%)	57 (100%)
LOS (days)	7.4 ± 1.8	4 (3–13)	5 (2–13)	4–13	4 (2–12)

^aOutcomes shown as mean ± 1 standard deviation (SD); as median (range); or as number (%).

^bData from Warshak, 2010.

^cData from Eller, 2011.

^dData from Walker, 2013.

^eData from Al-Khan, 2014.

^fData from Shamshirsaz, 2015.

^gIncludes intentional cystotomy.

FFP = fresh frozen plasma; ICU = intensive care unit; LOS = length of stay; NS = not stated; RBC = red blood cells.

the woman is stable and not bleeding, then one option is to close the abdominal incision and transfer her to a tertiary-care facility. Another option is to cover the operative site with moist laparotomy packs until sufficient help is mobilized. Meanwhile, fetal delivery and uterine manipulation is avoided. Finally, in some situations, the fetus is delivered and the uterine incision closed without placental manipulation. The laparotomy incision is sutured and the woman is then transferred for definitive hysterectomy.

■ Pregnancy Outcomes

Reports describing outcomes with accrete syndromes have limited numbers of patients. That said, several large series provide data from which some basic observations can be made. First and foremost, these types of abnormal placentation can have disastrous outcomes for both mother and fetus. Although the depth of placental invasion does not correspond with perinatal outcome, it is of paramount maternal significance (Seet, 2012). Urologic injuries—bladder and ureter—are common, especially with placenta percreta (Woldu, 2014). Outcomes for women managed at tertiary-care hospitals and in whom the diagnosis of placenta accrete syndromes was made preoperatively are shown in Table 27-5. Despite these advantages, a litany of complications included hemorrhage, urinary tract injury, intensive-care unit admission, and secondary operations. These reports also chronicled outcomes in a second cohort of women managed without the advantages of a tertiary-care facility, a dedicated team, or the preoperative knowledge of the placenta accreta. As expected, morbidity in these latter gravidas was worse, and at least one woman died.

In the Utah experiences, attempts at placental removal increased morbidity rates significantly—67 versus 36 percent—

compared with no attempts at removal prior to hysterectomy. These investigators also found that preoperative bilateral ureteral stenting reduced morbidity rates. But no benefits were accrued from internal iliac artery ligation (Eller, 2011; Po, 2012). Our management at Parkland Hospital is similar. However, the final decision for hysterectomy is not made until assessment at delivery. And although we do not always place ureteral stents preoperatively, we insert stents transvesically if indicated intraoperatively. As discussed on page 447, preoperative arterial catheterization is considered beneficial by some (Desai, 2012).

■ Subsequent Pregnancy

Obviously in many women, treatment with hysterectomy nullifies subsequent pregnancy. In the others, it would seem intuitive, because of the association with prior hysterotomy, that placenta accrete syndromes would have a high incidence of recurrence. Indeed, in 34 pregnancies in a group of women in whom accrete syndromes were treated conservatively, the recurrence rate was 29 percent (Sentilhes, 2010). In addition to recurrence, risks of uterine rupture, hysterectomy, and previa are elevated (Eshkoli, 2013).

REFERENCES

- Albayrak M, Ozdemir I, Koc O, et al: Post-partum haemorrhage from the lower uterine segment secondary to placenta previa/accreta: successful conservative management with Foley balloon tamponade. *Aust N Z J Obstet Gynaecol* 51(4):377, 2011
- Al-Khan A, Gupta V, Illsley NP, et al: Maternal and fetal outcomes in placenta accreta after institution of team-managed care. *Reprod Sci* 21(6):761, 2014
- Al-Zirqi I, Vangen S, Forsen L, et al: Prevalence and risk factors of severe obstetric haemorrhage. *BJOG* 115:1265, 2008

- American College of Obstetricians and Gynecologists: Placenta accreta. Committee Opinion No. 529, July 2016
- American Institute of Ultrasound in Medicine (AIUM): Practice guideline for the performance of obstetric ultrasound examinations. *J Ultrasound Med* 32:1083, 2013
- Ananth CV, Demissie K, Smulian JC, et al: Placenta previa in singleton and twin births in the United States, 1989 through 1998: a comparison of risk factor profiles and associated conditions. *Am J Obstet Gynecol* 188:275, 2003a
- Ananth CV, Demissie K, Smulian JC, et al: Relationship among placenta previa, fetal growth restriction, and preterm delivery: a population-based study. *Obstet Gynecol* 98:299, 2001
- Ananth CV, Smulian JC, Vintzileos AM: The effect of placenta previa on neonatal mortality: a population-based study in the United States, 1989 through 1997. *Am J Obstet Gynecol* 188:1299, 2003b
- Ash A, Smith A, Maxwell D: Caesarean scar pregnancy. *BJOG* 114:253, 2007
- Assali NS, Douglass RA Jr, Baird WW, et al: Measurement of uterine blood flow and uterine metabolism. IV. Results in normal pregnancy. *Am J Obstet Gynecol* 66(2):248, 1953
- Awan N, Bennett MJ, Walters WA: Emergency peripartum hysterectomy: a 10-year review at the Royal Hospital for Women, Sydney. *Aust N Z J Obstet Gynaecol* 51(3):210, 2011
- Babinszki A, Kerenyi T, Torok O, et al: Perinatal outcome in grand and great-grand multiparity: effects of parity on obstetric risk factors. *Am J Obstet Gynecol* 181:669, 1999
- Bailit JL, Grobman WA, Rice MM, et al: Morbidly adherent placenta treatments and outcomes. *Obstet Gynecol* 125(3):683, 2015
- Ballas J, Hull AD, Saenz C, et al: Preoperative intravascular balloon catheters and surgical outcomes in pregnancies complicated by placenta accreta: a management paradox. *Am J Obstet Gynecol* 207(3):216.e1, 2012
- Barrett JM, Boehm FH, Killam AP: Induced abortion: a risk factor for placenta previa. *Am J Obstet Gynecol* 141(7):769, 1981
- Barth WH Jr, Kwolek CJ, Abrams JL, et al: Case records of the Massachusetts General Hospital. Case 23–2011. A 40-year-old pregnant woman with placenta accreta who declined blood products. *N Engl J Med* 365(4):359, 2011
- Becker RH, Vonk R, Mende BC, et al: The relevance of placental location at 20–23 gestational weeks for prediction of placenta previa at delivery: evaluation of 8650 cases. *Ultrasound Obstet Gynecol* 17(6):496, 2001
- Benirschke K, Burton, Baergen RN (eds): *Pathology of the Human Placenta*, 6th ed. New York, Springer, 2012, p 204
- Berg CJ, Callaghan WM, Syverson C, et al: Pregnancy-related mortality in the United States, 1998–2005. *Obstet Gynecol* 116(6):1302, 2010
- Berhie SH, Molina RL, Davis MR, et al: Laparoscopic hysterectomy for 7-week cesarean delivery scar implantation pregnancy. *Am J Obstet Gynecol* 212:247.e1, 2015
- Biro MA, Davey MA, Carolan M, et al: Advanced maternal age and obstetric morbidity for women giving birth in Victoria, Australia: a population-based study. *Aust N Z J Obstet Gynaecol* 52(3):229, 2012
- Bishop S, Butler K, Monaghan S, et al: Multiple complications following the use of prophylactic internal iliac artery balloon catheterization in a patient with placenta percreta. *Int J Obstet Anesth* 20(1):70, 2011
- Biswas R, Sawhney H, Dass R, et al: Histopathological study of placental bed biopsies in placenta previa. *Acta Obstet Gynecol Scand* 78:173, 1999
- Bohrer J, Goh W, Hirai C, et al: Obstetrical outcomes in patients with low-lying placenta in the second trimester. Abstract No. 129. *Am J Obstet Gynecol* 206(1):S69, 2012
- Bose DA, Assel BG, Hill JB, et al: Maintenance tocolytics for preterm symptomatic placenta previa: a review. *Am J Perinatol* 28(1):45, 2011
- Bowman ZS, Eller AG, Kennedy AM, et al: Accuracy of ultrasound for the prediction of placenta accreta. *Am J Obstet Gynecol* 211(2):177.e1, 2014
- Boyle RK, Waters BA, O'Rourke PK: Blood transfusion for caesarean delivery complicated by placenta praevia. *Aust N Z J Obstet Gynaecol* 49(6):627, 2009
- Breen JL, Neubecker R, Gregori C, et al: Placenta accreta, increta, and percreta: a survey of 40 cases. *Obstet Gynecol* 49(1):43, 1977
- Bretelle f, Courbière B, Mazouni C, et al: Management of placenta accreta: morbidity and outcome. *Eur J Obstet Gynecol Reprod Biol* 133(1):34, 2007
- Bronsteen R, Whitten A, Balasubramanian M, et al: Vasa previa. Clinical presentations, outcomes, and implications for management. *Obstet Gynecol* 122(2 Pt 1):352, 2013
- Browne JCM, Veall N: The maternal placental blood flow in normotensive and hypertensive women. *J Obstet Gynaecol Br Emp* 60:141, 1953
- Cali G, Biambanco L, Puccio G, et al: Morbidly adherent placenta: evaluation of ultrasound diagnostic criteria and differentiation of placenta accreta from percreta. *Ultrasound Obstet Gynecol* 41(4):406, 2013
- Chalubinski KM, Pils S, Klein K, et al: Antenatal sonography can predict the degree of placental invasion. *Ultrasound Obstet Gynecol* 42(5):518, 2013
- Chantraine F, Braun T, Gonser M, et al: Prenatal diagnosis of abnormally invasive placenta reduces maternal peripartum hemorrhage and morbidity. *Acta Obstet Gynecol Scand* 92(4):439, 2013
- Cho JY, Kim SJ, Cha KY, et al: Interrupted circular suture: bleeding control during cesarean delivery in placenta previa accreta. *Obstet Gynecol* 78:876, 1991
- Clausen C, Lönn L, Langhoff-Roos J: Management of placenta percreta: a review of published cases. *Acta Obstet Gynecol Scand* 93(2):138, 2014
- Cleary-Goldman J, Malone FD, Vidaver J, et al: Impact of maternal age on obstetric outcome. *Obstet Gynecol* 105:983, 2005
- Cohen M, Wuillemin C, Irion O, et al: Role of decidua in trophoblastic invasion. *Neuro Endocrinol Lett* 31(2):193, 2010
- Conroy K, Hsieh f, Craigon S: Spontaneous uterine rupture from placenta percreta: an increasing phenomenon? *Obstet Gynecol* 123(Suppl 1):142S, 2014
- Crane JM, Van Den Hof MC, Dodds L, et al: Neonatal outcomes with placenta previa. *Obstet Gynecol* 93:541, 1999
- Creanga AA, Berg CJ, Syverson C, et al: Pregnancy-related mortality in the United States, 2006–2010. *Obstet Gynecol* 125(1):5, 2015
- Cunningham FG, Leveno KJ, Bloom SL, et al (eds): *Obstetrical hemorrhage*. In *Williams Obstetrics*, 24th ed. New York, McGraw-Hill Education, 2014
- Cunningham FG, Nelson DB: Disseminated intravascular coagulation in obstetrics. *Obstet Gynecol* 126(5):999, 2015
- Dashe JS: Toward consistent terminology of placental location. *Semin Perinatol* 37(5):375, 2013
- Dashe JS, Hoffman BL: Ultrasound evaluation of the placenta, membranes, and umbilical cord. In Norton M, Scoult L, Feldstein VA (eds): *Callen's Ultrasonography in Obstetrics and Gynecology*, 6th ed. Philadelphia, Saunders, 2016 [In press]
- Dashe JS, McIntire DD, Ramus RM, et al: Persistence of placenta previa according to gestational age at ultrasound detection. *Obstet Gynecol* 99:692, 2002
- Desai N, Tam HT, Fleischer A: Prophylactic arterial catheterization may improve operative morbidity in suspected placenta accreta and reduce the need for hysterectomy. *Am J Obstet Gynecol* 206(1):S44, 2012
- Diemer A, Ortmeyer G, Hollwitz B, et al: The combination of intrauterine balloon tamponade and the B-Lynch procedure for the treatment of severe postpartum hemorrhage. *Am J Obstet Gynecol* 206(1):65.e1, 2012
- Downes KL, Hinkle SN, Sjaarda LA, et al: Previous prelabor or intrapartum cesarean delivery and risk of placenta previa. *Am J Obstet Gynecol* 212(5):669.e1, 2015
- Doyle N, Pullen J, Holliday, et al: 3D ultrasound: the best view of placenta accreta. Abstract No. 108. *Am J Obstet Gynecol* 212(1):S-72, 2015
- Drost S, Keil K: Expectant management of placenta previa: cost-benefit analysis of outpatient treatment. *Am J Obstet Gynecol* 170:1254, 1994
- Druzin ML: Packing of lower uterine segment for control of postcesarean bleeding in instances of placenta previa. *Surg Gynecol Obstet* 169:543, 1989
- Duzjy C, Buhimschi I, Hardy J, et al: Decreased expression of endostatin (ES) and hypoxia-inducible factor 1 α (HIF-1 α) is associated with excessive trophoblast invasion and aberrant angiogenesis in placenta accreta. Abstract No. 105. *Am J Obstet Gynecol* 208(1):S58, 2013
- Duzjy CM, Buhimschi IA, Motawea H, et al: The invasive phenotype of placenta accreta extravillous trophoblasts associates with loss of E-cadherin. *Placenta* 36(6):645, 2015
- Edman CD, Toofanian A, MacDonald PC, et al: Placental clearance rate of maternal plasma androstenedione through placental estradiol formation: an indirect method of assessing uteroplacental blood flow. *Am J Obstet Gynecol* 141(8):1029, 1981
- Elhawary TM, Dabees NL, Youssef MA: Diagnostic value of ultrasonography and magnetic resonance imaging in pregnant women at risk for placenta accreta. *J Matern Fetal Neonatal Med* 26(14):1443, 2013
- Eller AG, Bennett MA, Sharshiner M, et al: Maternal morbidity in cases of placenta accreta managed by a multidisciplinary care team compared with standard obstetric care. *Obstet Gynecol* 117(2 Pt 1):331, 2011
- Eschbach S, Ruiter L, Burgers M, et al: A prediction model for emergency cesarean section in women with placenta previa. Abstract No. 383. *Am J Obstet Gynecol* 212(1):S-200, 2015
- Eshkoli T, Weintraub AY, Sergienko R, et al: Placenta accreta: risk factors, perinatal outcomes, and consequences for subsequent births. *Am J Obstet Gynecol* 208(3):219.e1, 2013
- Faiz AS, Ananth CV: Etiology and risk factors for placenta previa: an overview and meta-analysis of observational studies. *J Matern Fetal Neonatal Med* 13(3):175, 2003
- Farine D, Fox HE, Jakobson S, et al: Vaginal ultrasound for diagnosis of placenta previa. *Am J Obstet Gynecol* 159:566, 1988
- Fitzpatrick K, Sellers S, Spark P, et al: The management and outcomes of placenta accreta, increta, and percreta in the UK: a population-based descriptive study. *BJOG* 121(1):62, 2014

- Fox K, Shamshirsaz A, Salமான B, et al: Is interpregnancy interval a predictor of severity of invasion in morbidly adherent placenta? Abstract No. 821. *Am J Obstet Gynecol* 212(1):S-395, 2015
- Frederiksen MC, Glassenberg R, Strika CS: Placenta previa: a 22-year analysis. *Am J Obstet Gynecol* 180 (6 Pt 1):1432, 1999
- Frizer S, Le Ray C, Tort J, et al: Symptomatic placenta praevia: short cervix at admission is a predictive factor for delivery within 7 days. Abstract No. 158. *Am J Obstet Gynecol* 208(1):S78, 2013
- Garmi G, Samlim R: Epidemiology, etiology, diagnosis, and management of placenta accreta. *Obstet Gynecol Int* 2012:873929, 2012
- Gesteland K, Oshiro B, Henry E, et al: Rates of placenta previa and placental abruption in women delivered only vaginally or only by cesarean section. Abstract No. 403. *J Soc Gynecol Investig* 11:208A, 2004
- Gill LA, Baldwin E, Lessard-Anderson C, et al: Septic abortion with placenta accreta in pregnancy after endometrial ablation. *Obstet Gynecol* 125(4):822, 2015
- Gilliam M, Rosenberg D, Davis F: The likelihood of placenta previa with greater number of cesarean deliveries and higher parity. *Obstet Gynecol* 99:976, 2002
- Gorodeski IG, Bahari CM, Schachter A, et al: Recurrent placenta previa. *Eur J Obstet Gynecol Reprod Biol* 12(1):7, 1981
- Greenberg JL, Suliman A, Iranpour P, et al: Prophylactic balloon occlusion of the internal iliac arteries to treat abnormal placentation: a cautionary case. *Am J Obstet Gynecol* 197:470.e1, 2007
- Gurol-Urganci I, Cromwell DA, Edozien LC, et al: Risk of placenta previa in second birth after first birth cesarean section. *BMC Pregnancy Childbirth* 11:95, 2011
- Guy GP, Peisner DB, Timor-Tritsch IE: Ultrasonographic evaluation of uteroplacental blood flow patterns of abnormally located and adherent placentas. *Am J Obstet Gynecol* 163(3):723, 1990
- Gyamfi-Bannerman C, Gilbert S, Landon MB, et al: Risk of uterine rupture and placenta accreta with prior uterine surgery outside of the lower segment. *Obstet Gynecol* 120(6):1332, 2012
- Hardardottir H, Borgjda AF, Sanders MM, et al: Histologic myometrial fibers adherent to the placenta: impact of method of placental removal. *Am J Obstet Gynecol* 174:358, 1996
- Harper LM, Odibo AO, Macones GA, et al: Effect of placenta previa on fetal growth. *Am J Obstet Gynecol* 203(4):330.e1, 2010
- Hays AM, Worley KC, Roberts SR: Conservative management of placenta praevia. Experience in two cases. *Obstet Gynecol* 112:1, 2008
- Heller HT, Mullen KM, Gordon RW, et al: Outcomes of pregnancies with a low-lying placenta diagnosed on second-trimester sonography. *J Ultrasound Med* 33(4):691, 2014
- Hellman LM, Pritchard JA (eds): Medical and surgical illnesses during pregnancy and the puerperium. In *Williams Obstetrics*, 14th ed. New York, Appleton-Century-Crofts, 1971, p 763
- Hernandez JS, Alexander JM, Sarode R, et al: Calculated blood loss in severe obstetric hemorrhage and its relation to body mass index. *Am J Perinatol* 29(7):557, 2012
- Huissoud C, Cortet M, Dubernard G, et al: A stitch in time: layers of circular sutures can staunch postpartum hemorrhage. *Am J Obstet Gynecol* 206:177.e1, 2012
- Hung TH, Shau WY, Hsieh CC, et al: Risk factors for placenta accreta. *Obstet Gynecol* 93:545, 1999
- Johnson LG, Mueller BA, Daling JR: The relationship of placenta previa and history of induced abortion. *Int J Gynaecol Obstet* 81(2):191, 2003
- Kamara M, Henderson J, Doherty D, et al: The risk of placenta accreta following primary elective caesarean delivery: a case-control study. *BJOG* 120(7):879, 2013
- Karam AK, Bristow RE, Bienstock J, et al: Argon beam coagulation facilitates management of placenta praevia with bladder invasion. *Obstet Gynecol* 102:555, 2003
- Kauppila A, Koskinen M, Puolakka J, et al: Decreased intervillous and unchanged myometrial blood flow in supine recumbency. *Obstet Gynecol* 55(2):203, 1980
- Kayem G, Kurinczuk JJ, Alfirevic A, et al: Uterine compression sutures for the management of severe postpartum hemorrhage. *Obstet Gynecol* 117(1):14, 2011
- King DL: Placental migration demonstrated by ultrasonography. *Radiology* 109:167, 1973
- Klar M, Michels KB: Cesarean section and placental disorders in subsequent pregnancies—a meta-analysis. *J Perinat Med* 42(5):571, 2014
- Knight M, UKOSS: Peripartum hysterectomy in the UK: management and outcomes of the associated haemorrhage. *BJOG* 114:1380, 2007
- Kohari KS, Roman AS, Fox NS, et al: Persistence of placenta previa in twin gestations based on gestational age at sonographic detection. *J Ultrasound Med* 31(7):985, 2012
- Kotsuji F, Nishihima K, Kurokawa T, et al: Transverse uterine fundal incision for placenta praevia with accreta, involving the entire anterior uterine wall: a case series. *BJOG* 120(9):1144, 2013
- Kumru P, Demirci O, Erdogdu E, et al: The Bakri balloon for the management of postpartum hemorrhage in cases with placenta previa. *Eur J Obstet Gynecol Reprod Biol* 167(2):167, 2013
- Lai J, Caughey AB, Qidwai GI, et al: Neonatal outcomes in women with sonographically identified uterine leiomyomata. *J Matern Fetal Neonatal Med* 25(6):710, 2012
- Law LW, Chor CM, Leung TY: Use of hemostatic gel in postpartum hemorrhage due to placenta previa. *Obstet Gynecol* 116(Suppl 2):S28, 2010
- Lax A, Prince MR, Mennitt KW, et al: The value of specific MRI features in the evaluation of suspected placental invasion. *Magn Reson Imaging* 25:87, 2007
- Lee PS, Bakelaar R, Fitzpatrick CB, et al: Medical and surgical treatment of placenta praevia to optimize bladder preservation. *Obstet Gynecol* 112:421, 2008
- Maheer MA, Abdelaziz A, Bazeed MF: Diagnostic accuracy of ultrasound and MRI in the prenatal diagnosis of placenta accreta. *Acta Obstet Gynecol Scand* 92(9):1017, 2013
- Marinez-Gaytan V, Torcida-Gonzalez ME, Felix-Zamudio LL, et al: Gelatin-thrombin matrix hemostatic for management of severe obstetric hemorrhage. *Obstet Gynecol* 123 (Suppl 1):67S, 2014
- Martin JA, Hamilton BE, Sutton PD, et al: Births: final data for 2003. *Natl Vital Stat Rep* 54(2):1, 2005
- Matsuda Y, Hayashi K, Shiozaki A, et al: Comparison of risk factors for placental abruption and placenta previa: case-cohort study. *J Obstet Gynaecol Res* 37(6):538, 2011
- McKeogh RP, D'Errico E: Placenta accreta: clinical manifestations and conservative management. *N Engl J Med* 245(5):159, 1951
- Mehrabadi A, Hutcheon JA, Liu S, et al: Contribution of placenta accreta to the incidence of postpartum hemorrhage and severe postpartum hemorrhage. *Obstet Gynecol* 125(4):814, 2015
- Metcalfe J, Romney SL, Ramsey LH, et al: Estimation of uterine blood flow in normal human pregnancy at term. *J Clin Invest* 34(11):1632, 1955
- Michaels AY, Washburn EE, Pocius KD, et al: Outcome of cesarean scar pregnancies diagnosed sonographically in the first trimester. *J Ultrasound Med* 34(4):595, 2015
- Miller E, Linn R, Ernst L: Does the presence of placental basal plate myometrial fibers in a prior pregnancy improve prediction of placenta accreta? Abstract No. 468. *Am J Obstet Gynecol* 212(1):S-239, 2015
- Millischer AE, Aalomon LJ, Porcher R, et al: Magnetic resonance imaging for abnormally invasive placenta: the added value of intravenous gadolinium injection. *BJOG* June 27, 2016 [Epub ahead of print]
- Mogos MF, Salemi JL, Ashley M, et al: Recent trends in placenta accreta in the United States and its impact on maternal-fetal morbidity and healthcare-associated costs, 1998–2011. *Ultrasound Obstet Gynecol* 29(7):1077, 2016
- Mouer JR: Placenta previa: antepartum conservative management, inpatient versus outpatient. *Am J Obstet Gynecol* 170:1683, 1994
- Nageotte MP: Always be vigilant for placenta accreta. *Am J Obstet Gynecol* 211(2):87, 2014
- Neilson JP: Interventions for suspected placenta praevia. *Cochrane Database Syst Rev* 2:CD001998, 2003
- Nørgaard LN, Pinborg A, Lidgaard Ø, et al: A Danish national cohort study on neonatal outcome in singleton pregnancies with placenta previa. *Acta Obstet Gynecol Scand* 91(5):546, 2012
- Olive EC, Roberts CL, Nassar N, et al: Test characteristics of placental location screening by transabdominal ultrasound at 18–20 weeks. *Ultrasound Obstet Gynecol* 28:944, 2006
- Oyelese Y, Smulian JC: Placenta previa, placenta accreta, and vasa previa. *Obstet Gynecol* 107:927, 2006
- Palacios Jaraquemada JM, Bruno CH: Magnetic resonance imaging in 300 cases of placenta accreta: surgical correlation of new findings. *Acta Obstet Gynecol Scand* 84:716, 2005
- Parrott J, Holland M: Second trimester marginal previa: is follow-up necessary? Abstract No. 653. *Am J Obstet Gynecol* 212(1):S-322, 2015
- Pates JA, Hatab MR, McIntire DD, et al: Determining uterine blood flow in pregnancy with magnetic resonance imaging. *Magn Reson Imaging* 28(4):507, 2010
- Pather S, Strocky D, Richards A, et al: Maternal outcome after conservative management of placenta praevia at cesarean section: a report of three cases and a review of the literature. *Aust N Z J Obstet Gynaecol* 54(1):84, 2014
- Pelosi MA, III, Pelosi MA: Modified cesarean hysterectomy for placenta previa praevia with bladder invasion: retrovesical lower uterine segment bypass. *Obstet Gynecol* 93:830, 1999
- Penotti M, Vercellini P, Bolis G: Compressive suture of the lower uterine segment for the treatment of postpartum hemorrhage due to complete placenta previa: a preliminary study. *Gynecol Obstet Invest* 73(4):314, 2012
- Perez-Delboy A, Wright JD: Surgical management of placenta accreta: to leave or remove the placenta? *BJOG* 121:163, 2014
- Po LK, Simons ME, Levinsky ES: Concealed postpartum hemorrhage treated with transcatheter arterial embolization. *Obstet Gynecol* 120(2 Pt 2):461, 2012

- Primo LF, Arbogast K, Digiacomo T, et al: Placenta accreta: can we forecast its arrival? *Obstet Gynecol* 123(Suppl 1):166S, 2014
- Pri-Paz S, Devine PC, Miller RS, et al: Cesarean hysterectomy requiring emergent thoracotomy: a case report of a complication of placenta percreta requiring a multidisciplinary effort. *J Reprod Med* 57(1-2):58, 2012
- Quant HS, Friedman AM, Wang E, et al: Transabdominal sonography as a screening test for second-trimester placenta previa. *Obstet Gynecol* 13(3):628, 2014
- Rac M, McIntire D, Wells E, et al: Cervical length in patients at risk for placental invasion. Abstract No. 516. *Am J Obstet Gynecol* 212(1):S-258, 2015a
- Rac MW, Dashe JS, Wells CE, et al: Ultrasound predictors of placental invasion: the Placenta Accreta Index. *Am J Obstet Gynecol* 212:343, 2015b
- Rac MW, Wells CE, Twicker DM, et al: Placenta accreta and vaginal bleeding according to gestational age at delivery. *Obstet Gynecol* 125(4):808, 2015c
- Räsänen S, Kancherla V, Kramer MR: Placenta previa and the risk of delivering a small-for-gestational-age newborn. *Obstet Gynecol* 124(2):285, 2014
- Rao KP, Belogolovkin V, Hankowitz J, et al: Abnormal placentation: evidence-based diagnosis and management of placenta previa, placenta accreta, and vasa previa. *Obstet Gynecol Surv* 67(8):503, 2012
- Rasmussen S, Albrechtsen S, Dalaker K: Obstetric history and the risk of placenta previa. *Acta Obstet Gynecol Scand* 79(6):502, 2000
- Reddy UM, Abuhamad AZ, Levine D, et al: Fetal imaging: executive summary of a joint Eunice Kennedy Shriver National Institute of Child Health and Human Development, Society for Maternal-Fetal Medicine, American Institute of Ultrasound in Medicine, American College of Obstetricians and Gynecologists, American College of Radiology, Society for Pediatric Radiology, and Society of Radiologists in Ultrasound Fetal Imaging Workshop. *Obstet Gynecol* 123(5):1070, 2014
- Roberts CL, Algert CS, Warrendorf J, et al: Trends and recurrence of placenta previa: a population-based study. *Aust N Z J Obstet Gynaecol* 52(5):483, 2012
- Robinson AJ, Muller PR, Allan R, et al: Precise mid-trimester placenta localisation: does it predict adverse outcomes? *Aust N Z J Obstet Gynaecol* 52(2):156, 2012
- Robinson CJ, Villers MS, Johnson DD, et al: Timing of elective repeat cesarean delivery at term and neonatal outcomes: a cost analysis. *Am J Obstet Gynecol* 202(6):632, 2010
- Rosenberg T, Pariente G, Sergienko R, et al: Critical analysis of risk factors and outcome of placenta previa. *Arch Gynecol Obstet* 284(1):47, 2011
- Rossi AC, Lee RH, Chmait RH: Emergency postpartum hysterectomy for uncontrolled postpartum bleeding: a systematic review. *Obstet Gynecol* 115(3):637, 2010
- Rotas MA, Haberman S, Luygur M: Cesarean scar ectopic pregnancies: etiology, diagnosis, and management. *Obstet Gynecol* 107:1373, 2006
- Sabourin JN, Lee T, Magee LA, et al: Indications for, timing of, and modes of delivery in a national cohort of women admitted with antepartum hemorrhage at 22+0 to 28+6 weeks' gestation. *J Obstet Gynaecol Can* 34(11):1043, 2012
- Salihu HM, Li Q, Rouse DJ, et al: Placenta previa: neonatal death after live births in the United States. *Am J Obstet Gynecol* 188:1305, 2003
- Salmanian B, Antony K, Fox K, et al: In obstetrics, is surprise ever a good thing? Abstract No. 290. *Am J Obstet Gynecol* 212(1):S156, 2015
- Sanderson DA, Milton PJD: The effectiveness of ultrasound screening at 18-20 weeks gestational age for predication of placenta previa. *J Obstet Gynaecol* 11:320, 1991
- Schmid BC, Rezniczek GA, Rolf N, et al: Postpartum hemorrhage: use of hemostatic combat gauze. *Am J Obstet Gynecol* 206(1):e12, 2012
- Seet EL, Kay HH, Wu S, et al: Placenta accreta: depth of invasion and neonatal outcomes. *J Matern Fetal Neonatal Med* 25(10):2042, 2012
- Sentilhes L, Ambroselli C, Kayem G, et al: Maternal outcome after conservative treatment of placenta accreta. *Obstet Gynecol* 115:526, 2010
- Sentilhes L, Goffinet F, Kayem G: Management of placenta accreta. *Acta Obstet Gynecol Scand* 92(10):1125, 2013
- Shamshirsaz AA, Fox KA, Salmanian B, et al: Maternal morbidity in patients with morbidly adherent placenta treated with and without a standardized multidisciplinary approach. *Am J Obstet Gynecol* 212:218.e1, 2015
- Silver RM: Abnormal placentation: placenta previa, vasa previa, and placenta accreta. *Obstet Gynecol* 126(3):654, 2015a
- Silver RM, Fox KA, Barton JR, et al: Center of excellence for placenta accreta. *Am J Obstet Gynecol*, May 2015b
- Silver RM, Landon MB, Rouse DJ, et al: Maternal morbidity associated with multiple repeat cesarean deliveries. *Obstet Gynecol* 107:1226, 2006
- Society for Maternal-Fetal Medicine, Belfort MA: Placenta accreta. *Am J Obstet Gynecol* 203(5):430, 2010
- Spong CY, Mercer BM, D'alton M, et al: Timing of indicated late-preterm and early-term birth. *Obstet Gynecol* 118 (2 Pt 1):323, 2011
- Stafford IA, Dashe JS, Shivvers SA, et al: Ultrasonographic cervical length and risk of hemorrhage in pregnancies with placenta previa. *Obstet Gynecol* 116(3):595, 2010
- Tam Tam KB, Dozier J, Martin JN Jr: Approaches to reduce urinary tract injury during management of placenta accreta, increta, and percreta: a systematic review. *J Maternal Fetal Neonatal Med* 25(4):329, 2012
- Tantbirojn P, Crum CP, Parast MM: Pathophysiology of placenta accreta: the role of decidua and extravillous trophoblast. *Placenta* 29(7):639, 2008
- Timmermans S, van Hof AC, Duveker JJ: Conservative management of abnormally invasive placentation. *Obstet Gynecol Surv* 62:529, 2007
- Timor-Tritsch IE, Khatib N, Monteagudo A, et al: Cesarean scar pregnancies: experience of 60 cases. *J Ultrasound Med* 34(4): 601, 2015
- Timor-Tritsch IE, Monteagudo A: Unforeseen consequences of the increasing rate of cesarean deliveries: early placenta accreta and cesarean scar pregnancy. A review. *Am J Obstet Gynecol* 207 (1):14, 2012
- Trudell A, Stout M, Cahill A, et al: Second trimester cervical length and persistence of placental previa in the third trimester. Abstract No. 91. Presented at the 33rd Annual Meeting of the Society for Maternal-Fetal Medicine, 11-16 February 2013
- Twickler DM, Lucas MJ, Balis AB, et al: Color flow mapping for myometrial invasion in women with a prior cesarean delivery. *J Matern Fetal Med* 9:330, 2000
- Usta IM, Hobeika EM, Abu Musa AA, et al: Placenta previa-accreta: risk factors and complications. *Am J Obstet Gynecol* 193:1045, 2005
- Verspyck E, Chanavaz-Lacheray I, Dreyfus M, et al: Maintenance nifedipine therapy for preterm symptomatic placenta previa: the PPADAL randomized, multicenter, double-blind, placebo-controlled trial. Abstract No. 20. *Am J Obstet Gynecol* 212(1):S-15, 2015
- Walker MG, Allen L, Windrim RC, et al: Multidisciplinary management of invasive placenta previa. *J Obstet Gynaecol Can* 35(5):417, 2013
- Warshak CR, Eskander R, Hull AD, et al: Accuracy of ultrasonography and magnetic resonance imaging in the diagnosis of placenta accreta. *Obstet Gynecol* 108(3):573, 2006
- Warshak CR, Ramos GA, Eskander R, et al: Effect of predelivery diagnosis in 99 consecutive cases of placenta accreta. *Obstet Gynecol* 115(1):6, 2010
- Wehrum MJ, Buhimschi IA, Salafia C, et al: Accreta complicating complete placenta previa is characterized by reduced systemic levels of vascular endothelial growth factor and by epithelial-to-mesenchymal transition of the invasive trophoblast. *Am J Obstet Gynecol* 204(5):411.e1, 2011
- Wei Q, Zhang W, Chen M, et al: Peripartum hysterectomy in 38 hospitals in China: a population-based study. *Arch Gynecol Obstet* 289(3):549, 2014
- Weis MA, Harper LM, Roehl KA, et al: Natural history of placenta previa in twins. *Obstet Gynecol* 120(4):753, 2012
- Wing DA, Paul RH, Millar LK: Management of the symptomatic placenta previa: a randomized, controlled trial of inpatient versus outpatient expectant management. *Am J Obstet Gynecol* 174:305, 1996a
- Wing DA, Paul RH, Millar LK: The usefulness of coagulation studies and blood banking in the symptomatic placenta previa. *Am J Obstet Gynecol* 174:346, 1996b
- Woldu SL, Ordonez MA, Devine PC, et al: Urologic considerations of placenta accreta: a contemporary tertiary care institutional experience. *Urol Int* 93(1):74, 2014
- Wong HS, Cheung YK, Zucollo J, et al: Evaluation of sonographic diagnostic criteria for placenta accreta. *J Clin Ultrasound* 36(9):551, 2008
- Wong TY: Emergency peripartum hysterectomy: a 10-year review in a tertiary obstetric hospital. *N Z Med J* 124(1345):34, 2011
- Worley KC, Hnat MD, Cunningham FG: Advanced extrauterine pregnancy: diagnostic and therapeutic challenges. *Am J Obstet Gynecol* 198:297.e1, 2008
- Wortman A, Schaefer S, Wilson K, et al: Maternal morbidity associated with placenta previa with and without placental invasion. Abstract No. 601. *Am J Obstet Gynecol* 212(1):S-299, 2015
- Wortman AC, Alexander JM: Placenta accreta, increta, and percreta. *Obstet Gynecol Clin North Am* 40(1):137, 2013
- Wright JD, Silver RM, Bonanno C, et al: Practice patterns and knowledge of obstetricians and gynecologists regarding placenta accreta. *J Matern Fetal Neonatal Med* 26(16):1602, 2013
- Young B, Nadel A, Panda B, et al: Does placenta previa location matter? Surgical morbidity associated with previa location. Abstract No. 101. Presented at the 33rd Annual Meeting of the Society for Maternal-Fetal Medicine, 11-16 February 2013
- Young BC, Nadel A, Kaimal A: Does previa location matter? Surgical morbidity associated with location of a placenta previa. *J Perinatol* 34(4):264, 2014
- Yu PC, Ou HY, Tsang LC, et al: Prophylactic intraoperative uterine artery embolization to control hemorrhage in abnormal placentation during late gestation. *Fertil Steril* 91(5):1951, 2009
- Zaki ZM, Bahar AM, Ali ME, et al: Risk factors and morbidity in patients with placenta previa accreta compared to placenta previa non-accreta. *Acta Obstet Gynecol Scand* 77:391, 1998
- Zwart JJ, Richters JM, Öry F, et al: Severe maternal morbidity during pregnancy, delivery and puerperium in the Netherlands: a nationwide population-based study of 371,000 pregnancies. *BJOG* 115:842, 2008

CHAPTER 28

Urologic and Gastrointestinal Injuries

INCIDENCE	454
URETHRAL INJURIES	455
BLADDER INJURIES	456
URETERAL INJURIES	457
BOWEL INJURIES	461

Cesarean delivery is currently the most frequently performed major surgical procedure for women in the United States. More than 1 million procedures are completed each year (MacDorman, 2008). Associated mortality rates are low with this operation, but it has higher maternal morbidity rates during both initial and subsequent pregnancies. In many instances, associated risks for urinary tract and bowel injury are identified preoperatively, and preemptive steps are taken. However, in other cases, undiagnosed adhesive disease, hysterotomy laceration, or unplanned hysterectomy can increase adjacent organ trauma. Thus, all obstetricians ideally are able to recognize these injuries. Simple repairs can be completed in most cases by a generalist. However, more extensive damage often requires consultation with surgeons skilled in these more difficult repairs. Importantly, differentiation between the two is essential to maximize patient outcome.

INCIDENCE

Injury to the urinary tract during cesarean delivery is infrequent. Rates range from 0.08 to 0.94 percent for bladder injury and from 0.027 to 0.09 percent for ureteral injury (Eisenkop, 1982; Rajasekar, 1997; Tarney, 2013). Virtually all bowel injuries associated with childbirth are to the anal sphincter and lower rectum during vaginal deliveries. These injuries and their repair are described and illustrated in Chapter 20 (p. 325). Bowel

injuries during cesarean delivery are rare, and estimated rates range between 0.04 and 0.08 percent (Davis, 1999).

From 1996 to 2009, the cesarean delivery rate increased from 20.7 percent to 32.9 percent of all births (Osterman, 2014). As described in Chapter 25 (p. 404), these numbers reflect several modifiable factors. Among these are higher labor induction rates, lower operative vaginal delivery rates, emergence of cesarean delivery on maternal request, and a decline in rates of vaginal birth after cesarean (VBAC). In fact, 90.8 percent of women with low-risk pregnancies currently undergo repeat cesarean delivery (Office of Disease Prevention and Health Promotion, 2014). Logically, these trends correspond with an increase in the frequency of urinary tract and bowel injuries (American College of Obstetricians and Gynecologists, 2015; Osterman, 2014).

RISK FACTORS

Several specific patient or pregnancy characteristics raise the risk for gastrointestinal or urinary tract injury and are listed in [Table 28-1](#). In general, these attributes can be divided into those that are identifiable preoperatively and those that are found intraoperatively. The most consistently reported risk factors for injury include prior cesarean delivery, prior pelvic surgery, pelvic adhesions, emergent delivery, cesarean hysterectomy, and cesarean delivery during labor (Davis, 1999; Eisenkop, 1982; Phipps, 2005; Tarney, 2013). Extension of the uterine incision, either by direct trauma or with attempts to control bleeding, can be associated with adjacent ureteral injury. Also, uterine artery ligation used to control postpartum hemorrhage places the ipsilateral ureter at risk. Prior myomectomy, multiple cesarean deliveries, or pelvic surgery that is associated with bowel adhesions to uterus, anterior abdominal wall, or other pelvic structures increases the potential for intestinal injury (Davis, 1999; Eisenkop, 1982). This risk may be especially likely for women with prior classical cesarean delivery. These cases often yield dense adhesions between the anterior abdominal wall and anterior uterus. Thus, an understanding of these preoperative

TABLE 28-1. Risk Factors for Urologic and Gastrointestinal Injuries During Cesarean Delivery**Preoperative**

Previous cesarean delivery
 Prior abdominal or pelvic surgery
 Emergent delivery
 Cesarean delivery during labor
 Failed trial of labor after cesarean
 Ruptured uterus
 Placenta previa
 Arrest of descent
 Malpresentation
 Dysfunctional labor
 Prior pelvic or abdominal infection
 Endometriosis
 Obesity

Intraoperative

Pelvic adhesions
 Hemorrhage
 Morbidly adherent placenta
 Cesarean hysterectomy
 Distended bladder
 Inadequate retraction or mobilization of bladder
 Inexperienced operator
 Surgical haste
 Extraperitoneal cesarean delivery

Data from Davis, 1999; Eisenkop, 1982; Eller, 2009; Francis, 2002; Nielsen, 1984; Phipps, 2005; Shellhaas, 2009; Tarney, 2013; Wright, 2010; Yossepowitch, 2004.

risk factors permits an obstetrician to anticipate and ideally mitigate many of these aspects that lead to organ injury.

Compromised surgical exposure is the unifying thread among most known risk factors for adjacent organ injury (Francis, 2002). Intraoperative risk is further compounded by the altered anatomy of pregnancy and the frequently urgent, abrupt, and stressful circumstances surrounding surgical intervention (Chaliha, 2002; Yossepowitch, 2004). The wise surgeon will assess risk factors to guide decisions regarding the best anesthetic, laparotomy incision type, and surgical assistant to minimize the threat to the patient. Moreover, during emergent cesarean delivery, calm, logical, and controlled decision making should replace reactions spawned by “the heat of the moment.” Surgeons performing obstetric surgery should take every precaution to prevent injuries through identification of risk factors. When prevention is not possible, heightened awareness and vigilance, with recognition and repair of injuries to the gastrointestinal and urinary tracts, substantially reduce patient morbidity.

UROLOGIC INJURIES

Damage to the bladder or ureter is rare during vaginal delivery. In these instances, such damage is most often associated with uterine scar rupture or instrumental deliveries. As one example,

with vaginal sidewall laceration, the vaginal wall overlying the ischial spine is a frequent site. The distal ureter can be damaged from extension of the laceration. In addition, sutures required to repair a sidewall laceration can ensnare the ureter (Kattan, 1997).

During cesarean delivery, the anatomic and physiologic changes that develop during pregnancy place the urinary tract at greater risk for injury. First, as the uterus enlarges, the bladder is drawn upward anteriorly and becomes more of an abdominal organ by the third trimester (Chaliha, 2002). Second, the left ureter may be more prone to injury as uterine dextrorotation brings it more ventral (Davis, 1999). The left ureter is also more difficult to identify, as the physiologic hydroureter of pregnancy is more marked on the right (Rasmussen, 1988). Additionally, the left ureter is frequently hidden beneath the sigmoid colon. Last, marked dilatation of the ovarian vessels places the ureter at greater risk for injury during retroperitoneal dissections and isolation of the infundibulopelvic ligament.

Fortunately, urinary tract injury is infrequent, and intraoperative recognition with immediate repair results in little patient morbidity (Blandy, 1991; Brubaker, 1991; Faricy, 1978; Neuman, 1991). However, if unrecognized, these injuries can lead to significant sequelae, including renal damage and genitourinary fistulas (Yossepowitch, 2004).

Obstetric facilities are equipped for vaginal and abdominal deliveries and may lack necessary equipment for endoscopic and urologic assessment of the urinary tract (Yossepowitch, 2004). Labor and delivery operating tables may not be designed for intraoperative radiography, and the operating time needed to mobilize equipment and personnel can be significantly prolonged (Davis, 1999). Therefore, in cases with a greater chance for these complications, preemptive consultation with a urogynecologist, gynecologic oncologist, or urologist and with labor and delivery nursing staff is prudent to aid evaluation and management of these injuries.

■ Urethral Injuries

In the past, episiotomy was routinely performed during vaginal or instrumental delivery. However, midline episiotomy increases the potential for external anal sphincter or rectal tears. Thus, practice patterns now favor only selective use of this perineal incision. As a result, distention forces during many vaginal deliveries are directed anteriorly. And, anterior inner labial lacerations that extend into the urethral meatus are more common in women in whom an episiotomy is avoided.

In most cases of urethral injury, only the distal meatus is torn and solely at one point around its circumference. Periurethral tissue is extremely vascular in pregnancy, and bleeding can be brisk. However, this same vascularity is responsible for the rapid healing seen with these tears. Thus, for repair, a fine-gauge absorbable suture is appropriate, and interrupted stitches are positioned to reestablish the urethral meatal ring. One option is 3-0 chromic gut suture. This same suture type can also be used for concurrent adjacent inner labial laceration approximation.

Urinary retention can follow these lacerations. Therefore, heightened surveillance for this is reasonable. Foley catheter insertion is needed only to relieve urinary retention or to allow careful urine volume measurement for associated indications such as hypovolemia.

For perineal care, a cool pack applied to the area may help reduce edema and discomfort during the first 24 hours. Most women also appear to gain relief from periodic application of a local anesthetic spray. Beginning approximately 24 hours after delivery, moist heat as provided by warm sitz baths can be used to reduce local discomfort. Mild analgesics can be provided as needed.

■ Bladder Injuries

Incidence and Risks

The bladder is the most frequently injured organ during pelvic surgery. Of risks, women undergoing repeat cesarean delivery carry a more than fourfold greater risk for bladder injury than those undergoing primary surgery (Phipps, 2005). Adhesion formation after primary cesarean ranges from 46 to 65 percent and appears to be a significant etiologic factor for cystotomy during a repeat procedure (Tarney, 2013). Intuitively, the cystotomy rate rises steadily with an increasing number of cesarean deliveries. These rates range from 0.13 percent with the first cesarean up to 4.5 percent with the sixth cesarean delivery (Silver, 2006). In one study, unsuccessful trial of labor after cesarean (TOLAC) was associated with the highest incidence of bladder injury compared with successful vaginal birth after cesarean (VBAC) and with elective repeat cesarean delivery (Cahill, 2008). In addition, peripartum hysterectomy is associated with a ninefold greater cystotomy rate compared with hysterectomy for nonobstetric indications (Wright, 2010).

The bladder is lacerated most often during blunt or sharp dissection in the vesicouterine space to create the bladder flap. The second most frequent circumstance is during peritoneal cavity entry at laparotomy (Phipps, 2005; Rahman, 2009). The dome is lacerated in 95 percent of cases, and injury at the trigone makes up the remainder. The average laceration length is 4.2 cm but ranges from 1 to 10 cm (Phipps, 2005). Recognition is the most important prognostic factor of bladder injury, and failure to diagnose urinary tract trauma during surgery may lead to vesicovaginal, vesicouterine, or ureterovaginal fistula.

Cystotomy Diagnosis

Fortunately, bladder injuries are usually detected intraoperatively and most often after delivery of the newborn and repair of the uterine incision. Intraoperative findings that often indicate bladder injury include visual extravasation of urine, appearance of the Foley bulb, gross hematuria, and visible detrusor laceration.

Instillation of sterile milk through a Foley catheter with intraabdominal spill through the defect confirms injury. For this, many find that infant

formula from prepackaged bottles is ideal, and it is readily available in most labor and delivery units. The circulating nurse attaches a milk-filled, 60-mL syringe to the urethral catheter and fills the bladder repeatedly to instill a total volume of 200 to 300 mL. As the bladder fills, milk is easily seen flowing from a defect in the bladder wall. If milk is not available, methylene blue is a suitable dye to mix with saline for bladder filling. Indigo carmine was another popular choice, but current nationwide shortages limit its use now. In contrast to methylene blue and indigo carmine, infant formula can be used repeatedly during a case because it does not stain surrounding tissues (Davis, 1999). Notably, small defects can be difficult to identify and repair if the tissues surrounding the defect become stained. Unrepaired defects predispose to fistula formation.

Cystotomy Repair

The first step to manage an unplanned cystotomy is evaluation of the size, location, and extent of injury. Inspection of the trigone and ureters for possible involvement is mandatory (Davis, 1999). If the trigone is involved, the surgeon should be careful not to disrupt the ureteral orifices. If the injury is close to either ureter, stents are placed to maintain ureteral patency. Rarely, a bladder laceration involves one or both ureteral orifices such that proper repair without further ureteral injury or obstruction is impossible. This will require ureteroneocystostomy.

A simple cystotomy is closed in two layers (Fig. 28-1). The first layer is a simple running closure of the mucosa with a 3-0

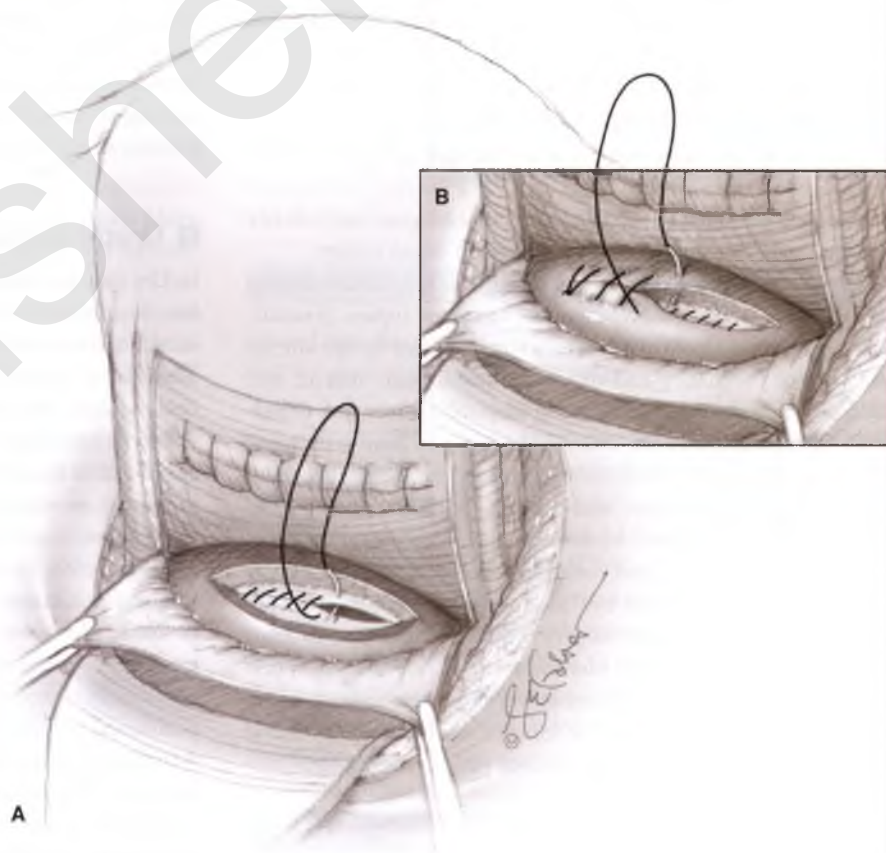


FIGURE 28-1 Cystotomy repair. **A.** The first layer is a continuous running mucosal closure with a 3-0 absorbable or delayed-absorbable suture. **B.** The second layer is an imbricating interrupted suture layer using 2-0 sutures of similar material.

absorbable or delayed-absorbable suture. Suitable options are chromic gut or polyglactin 910 (Vicryl). A second layer uses 2-0 or 3-0 suture of similar material in an imbricating technique to incorporate the bladder submucosa and muscularis. The bladder is then filled with sterile milk or methylene blue-stained saline to confirm integrity of the repair. Leaking defects can be closed with individual interrupted stitches of 2-0 or 3-0 suture. An additional running suture line can be placed in the serosa, if the margins can be approximated without undue tension. Large defects or persistent leak may require revision of the closure.

After the bladder returns to its normal anatomic location, the relative position of suture lines on all organs should be inspected. Placement of the suture line in close proximity to another can increase the risk of fistula formation. To avoid this risk, an omental J-flap can be quickly fashioned and safely interposed between suture lines. That said, this step is infrequently required in obstetrics due to the typical generous distance between suture lines and the rich vascularity of genitourinary tissues in pregnancy. If elected, an omental J-flap is created by ligating the right gastroepiploic artery and mobilizing the omentum off the hepatic flexure of the transverse colon toward the midline. Leftward dissection stops to preserve blood supply to the J-flap from the right gastroepiploic artery. The flap is brought into the pelvis along the left paracolic gutter and fixed in place with one or two strategically placed stitches of 2-0 or 3-0 Vicryl or chromic gut suture (Patsner, 1997).

Following cystotomy repair, the bladder is drained with a transurethral Foley catheter for 7 to 14 days postoperatively to allow healing and minimize risk of fistula formation. Suprapubic catheterization is usually not required, and prophylactic antibiotics are not indicated. Imaging before or after Foley removal is typically unnecessary but can be considered after complex or extensive repair (Davis, 1999; Tarney, 2013). Morbidity associated with intraoperative recognition of bladder injury and proper repair is minimal.

In contrast, unrecognized injury can worsen final patient outcome. Unrepaired cystotomy can manifest as hematuria, oliguria, abdominal pain, ileus, ascites, peritonitis, sepsis, fistula, urinoma, and an elevation of the blood urea nitrogen to creatinine ratio. For diagnosis, retrograde cystography or abdominal computed tomography with cystography can be used (Tarney, 2013). Cystoscopy is also an option, but is more invasive and may require an operating room. Once identified, prompt repair is indicated in most cases. Prolonged catheter drainage may be considered in selected stable patients with small defects.

Prevention

Prevention begins with recognition of risk factors that predispose to injury and with preemptive steps. A preoperative Foley catheter decompresses the bladder, improves exposure, and may help delineate the bladder location by palpation of the bulb. Adhesion prevention includes standard surgical principles of gentle retraction, respect for tissue, meticulous surgical technique, maintenance of tissue moisture, and limiting blood loss. Hysterotomy closure may play a role, and investigators in one small study evaluated adhesions during a second cesarean delivery. They found that double-layer hysterotomy closure during a primary cesarean operation, compared with single-layer

closure, reduced the odds of later developing bladder adhesions. As another factor, vertical midline infraumbilical abdominal incisions have a significantly higher risk for bladder injury than Pfannenstiel incisions. This persists even after controlling for confounding effects of number of cesareans, operator experience, and adhesions. Although these data suggest that Pfannenstiel incisions should be considered, it must be emphasized that the choice of abdominal incision is based on many maternal, fetal, and intrapartum factors and should not be based solely on cystotomy risk reduction. Specific to cystotomy prevention, data are insufficient or too conflicting to support recommendations for or against parietal peritoneal closure, bladder flap creation, type of uterine incision, or exteriorization of the uterus (Tarney, 2013).

■ Ureteral Injuries

Incidence and Risks

As mentioned previously, ureteral injury is rare during cesarean delivery. However, cesarean hysterectomy dramatically increases the incidence of ureteral injury to 3.0 percent. This is a sevenfold increase in the injury rate compared with nonobstetric hysterectomy (Shellhaas, 2009; Wright, 2010).

Diagnosis

Unlike bladder injury, which is almost always recognized at surgery, intraoperative diagnosis of ureteral injury is difficult and requires a high index of suspicion (Yossepowitch, 2004). Isolated ureteral injury or ureteral involvement at the time of bladder injury can be evaluated using intravenous dye. Urine jets from the ureteral orifices can then be sought using transurethral cystoscopy, suprapubic telescopic, or direct visualization through an incidental or intentional cystotomy. When endoscopy is not feasible or incidental cystotomy is not adequate, a midline extraperitoneal intentional cystotomy in the bladder dome gives excellent exposure, aids stent placement, and potentially allows an original incidental cystotomy site to be incorporated into the closure.

Traditionally, 5 mL of indigo carmine is given intravenously and is followed by inspection for spill from the ureteral orifices and for extravasation in the pelvis or retroperitoneum (Davis, 1999). With this method, absence of dye or a significant delay in the appearance of dye from one ureter relative to the other may signify an obstruction. Due to the current short supply of indigo carmine, 50 mg of intravenous methylene blue may be given over 5 minutes as an alternative (Barbieri, 2014). However, the toxicity profile of this agent combined with its long delay to excretion may limit utility (Narasimhulu, 2016). Specifically, methylene blue carries the potential for inciting methemoglobinemia in patients with glucose-6-phosphate dehydrogenase deficiency. One alternative to circumvent some of these issues is direct injection of dye into the ureter above the suspected injury with a fine-gauge needle (O'Leary, 1968). Early investigations with 0.25 mL (25 mg) of 10-percent sodium fluorescein intravenously as an alternative contrast agent are promising (Doyle, 2015). However, long-term safety data with this practice are lacking, and future studies are needed (Grimes, 2015).

Given these problems and the decreased ureteral peristalsis during the third trimester, evaluation for stained urine

flow may be inaccurate and time consuming. Intraoperative conditions such as hypotension or elevated or ongoing blood loss may decrease renal perfusion and urine flow, exacerbating the problem further. Retrograde passage of ureteral catheters cystoscopically or directly through a cystotomy is thus the most definitive diagnostic method. Inadvertent damage to the ureter can be lessened by advancement over a hydrophilic guide wire (Yossepowitch, 2004). Failure to easily advance the catheter may indicate ureteral kinking, ligation, or crush injury. The appearance of the catheter in the abdominal cavity likely indicates partial or complete transection. Repair of ureteral injuries is dependent on the type of injury and location.

Injuries that are identified and managed intraoperatively have overall better outcomes than those found postoperatively. Unrecognized ureteral injury should be considered after surgery in patients with costovertebral angle tenderness, oliguria, unexplained or persistent fever, persistent abdominal distention with or without ileus, unexplained hematuria, or watery vaginal discharge, especially if the cesarean delivery was difficult or complicated (Davis, 1999). Intravenous pyelography (IVP), renal sonography, or computed tomography (CT) will help identify hydronephrosis, urinoma, or abscess. Lack of contrast in the distal ureter on delayed CT images confirms total obstruction (Armenakas, 1999). Retrograde pyelography with fluoroscopic guidance can be used when other imaging is equivocal, or when intravenous contrast is contraindicated. If injury is confirmed, retrograde or antegrade stent placement can be attempted, but if it is unsuccessful, reexploration with repair may be required.

Ureteral Stents

Generalist obstetricians may be uncomfortable with stent placement. That said, a basic understanding can allow needed supplies to be collected while waiting for a surgical specialist to arrive. Ureteral stents are available in various sizes, and those ranging from 4 to 7F are frequently used. Stents vary in length from 20 to 30 cm, and a 24-cm length is appropriate for most adults. Open-ended or whistle-tip stents generally are selected to delineate anatomy or exclude obstruction. In cases in which a ureteral stent is required postoperatively, a double-pigtail stent is used. The proximal coil of the stent prevents renal pelvis injury, and the distal coil secures placement in the bladder (Schaffer, 2016).

Ureteral stents may be placed for three main reasons during surgery. First, stents may be inserted at the beginning of surgery in cases that place the ureter at significant risk of damage. Stents remain throughout the procedure to define anatomy. One notable example is placenta previa and percreta with suspicion for extension toward the pelvic sidewall (Chap. 27, p. 447). For such a purpose, a stent is advanced until resistance is met, which indicates that the renal pelvis has been reached. At the conclusion of surgery, the stent is removed.

Second, stents may be threaded intraoperatively to document ureteral patency and exclude injury. As described earlier, these may be threaded during cystoscopy or, more often in obstetrics, through an intentional cystotomy. Once the ureteral openings are found, a 4 to 6F open-ended or whistle-tip stent is threaded into one orifice. The stent is then manually threaded and advanced. In most obstetric surgery, this would not be higher than the pelvic brim, which should be 12 to 15 cm

from the ureteral orifice in adults. Gentle advancement helps avoid ureteral perforation. If a stent threads easily, obstruction is excluded.

Third, ureteral stents may be positioned and left in place if ureteral injury is suspected or is identified and repaired. For stent placement, a guide wire is first threaded into the ureteral orifice and passed to the renal pelvis. The pigtail stent is then placed over the guide wire and advanced by a pusher device until the distal end enters the bladder. The guide wire is removed, allowing the ends to coil in the renal pelvis and bladder, respectively. Correct upper coil positioning is confirmed intraoperatively using fluoroscopy or plain film radiograph.

The duration of postoperative stenting is variable and based on indications. In general, they are usually kept for 2 to 8 weeks and are generally removed in the office with cystoscopic guidance. In such cases, CT urography or renal sonography is completed 4 to 12 weeks after stent removal to exclude stricture.

Cystoscopy

During obstetric surgery, a cystoscope may be introduced through the urethra. However, this approach is used least often in obstetric surgery because dorsal lithotomy is required and the need for cystoscopy is often not appreciated preoperatively. Some notable exceptions might include known placenta previa and percreta with concern for placental invasion into the bladder or invasion toward the pelvic sidewall.

In most cases that require access to the ureters during obstetric surgery, a substantial intentional cystotomy is made for direct access. As another option, a cystoscope can be inserted through a smaller intentional cystotomy—a procedure termed suprapubic telescopy. For this, the bladder is distended using the transurethral Foley catheter until the bladder wall is tense. A wide purse-string using 2-0 absorbable suture is then placed at the bladder dome, taking deep bites into the bladder muscularis (Fig. 28-2). The two suture ends are elevated, and a small stab incision is made into the purse-string's center. This incision is preferably made in the extraperitoneal portion of the bladder dome to minimize risk of fistula formation. The cystoscope is inserted into the bladder. The two suture ends are then pulled up and held tightly to prevent escape of distending fluid. To allow visualization of the trigone and ureteral orifices, the Foley bulb is deflated but left in place. At the conclusion of telescopy, the cystoscope is removed, and the purse-string suture is tied, closing the cystotomy (Schaffer, 2016).

For cystoscopy, several endoscopic viewing angles are available. For transurethral cystoscopy, a 70-degree endoscope is superior for providing the most comprehensive view. For suprapubic telescopy, a 30-degree cystoscope is most effective.

Distal Ureteral Injuries

Managed by Stenting. In cases of distal ureteral injury, the ureter should be delineated above the level of the suspected injury. The surgeon then dissects the ureter down to the site of damage (Yossepowitch, 2004). Techniques for ureterolysis are described in Chapter 26 (p. 426).

Ureteral kinking, ligation, and crush injuries without devitalization may be treated by clamp or suture removal and placement of a ureteral stent (Davis, 1999). A guide wire is

threaded retrograde through the ureteral orifice to the renal pelvis, and a double-J, 6 to 8F ureteral stent is placed over the guide wire. The guide wire is removed, allowing the stent to coil in the renal pelvis and the bladder. Any intentional cystotomy is repaired as outlined previously (p. 456). If urine leaks from the ureter, a pelvic drain can be placed (Davis, 1999). Suitable options are a Jackson-Pratt or Blake drain (Fig. 2-23, p. 24). An intraoperative abdominal radiograph will confirm proper stent placement. Postoperatively, the bladder is drained for 7 to 14 days. In 3 to 6 weeks, the ureteral stent can be removed via in-office cystoscopy. Prolonged bladder drainage is not necessary if the stents are placed cystoscopically. When injury is more severe, such as crush injuries with devascularization of the ureter, or when adequate healing is in question, IVP is performed before stent removal to evaluate ureteral integrity.

Ureteroneocystostomy. Partial or complete transection of the distal third of the ureter within 6 cm of the ureterovesical junction is usually best handled by ureteroneocystostomy (Fig. 28-3). Vascularity of the distal ureter can be tenuous and yield impaired healing. Therefore, the ureteral adventitia is importantly preserved during ureterolysis to maintain sufficient blood supply.

In any ureteral repair, the most important aspect of the operation is to minimize tension on the anastomotic site. Other important ureteral surgery principles include preservation of blood supply, careful debridement, creation of a watertight spatulated anastomosis, and adequate drainage (Francis, 2002). Consultation with a specialist should be considered for complex injuries, extensive retroperitoneal fibrosis, significant ureteral devascularization, or poor familiarity with urinary tract surgery.

Once the injury is identified, the damaged segment is resected, and the distal portion of the ureter is ligated. Either permanent or delayed-absorbable suture may be used. This distal portion will become a blind-ended nonfunctional tube. In contrast, the proximal portion is mobilized sufficiently to allow the ureter to reach the bladder for anastomosis without tension. The cut end of this proximal ureter is spatulated by a 5-mm longitudinal incision, shown in part A of Figure 28-3. As shown by the inset, spatulation increases the final size of the ureteral orifice to minimize postoperative stenosis. Once spatulated, this end of the ureter is then marked with a suture.

To prepare the bladder, a vertical cystotomy is performed in the dome of the bladder. A tonsil clamp is placed in the bladder and used to penetrate the bladder wall on the ipsilateral side of the dome. The location ideally will create the least tension on the final anastomosis. The suture attached

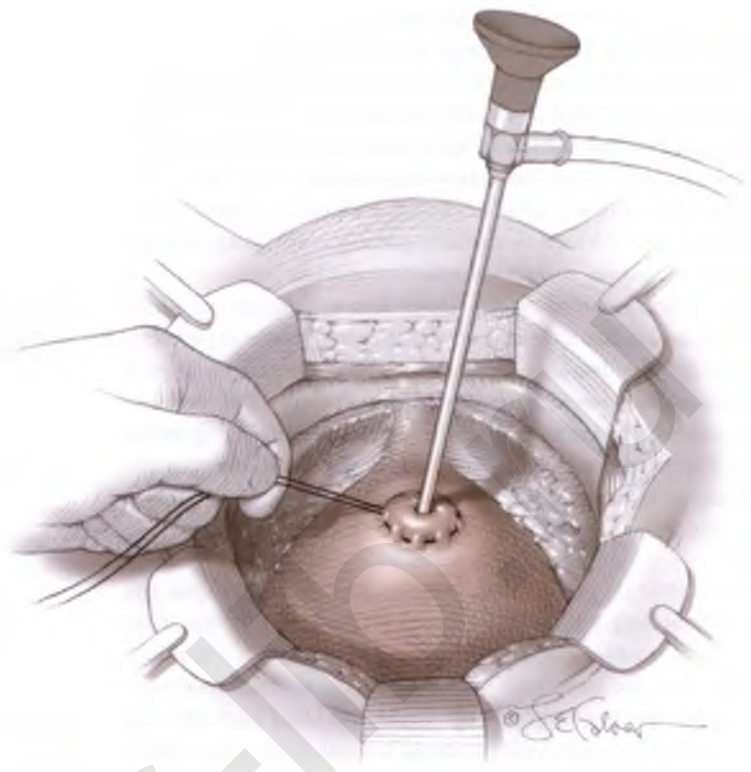


FIGURE 28-2 Suprapubic telescopy. (Reproduced with permission from Schaffer JI, Corton MM, Hoffman BH: Fundamentals of minimally invasive surgery. In Hoffman BL, Schorge JO, Bradshaw KD, et al: Williams Gynecology, 3rd ed. New York, McGraw-Hill Education, 2014.)

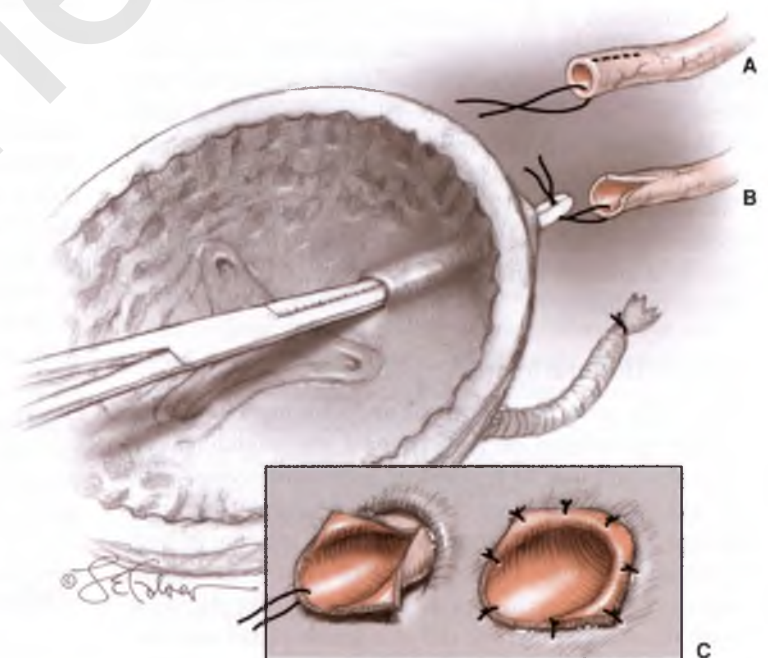


FIGURE 28-3 Ureteroneocystostomy. **A.** To begin repair, the proximal segment of the transected ureter is mobilized and spatulated along the marked dotted line. This end of the ureter is then tagged by suture. **B.** The distal segment of ureter is ligated, and a cystotomy is performed. A tonsil clamp is passed through the cystotomy and used to penetrate the bladder wall. The suture affixed to the proximal ureter segment is grasped and then pulled through the bladder wall. 2-0 absorbable sutures are placed on the bladder serosa to fix the ureter in place. **C.** The ureter is approximated to the bladder mucosa with multiple 4-0 absorbable sutures.

to the proximal ureteral segment is passed to the tonsil clamp, and the ureter is pulled through the bladder wall.

The full-thickness ureter is sewn to the bladder mucosa with five to six 4-0 Vicryl or chromic gut sutures. These are placed in an interrupted fashion to splay open the ureteral lumen. A ureteral stent is placed as previously described, and the cystotomy closed. The ureter is further secured to the bladder serosa with 2-0 or 3-0 Vicryl or chromic gut sutures. This again helps minimize tension at the anastomosis site.

In general, tunneling the ureter is not necessary in adults and increases the risk of ureteral stricture. However, ureteral reflux may be decreased in women who are at risk of urinary infections by tunneling the ureter through the wall of the bladder and thereby creating a flap valve (Harrow, 1968). The tunnel is approximately 1 to 2 cm in length and lies between the muscularis and mucosa. The ureter is spatulated and fixed to the mucosa as above.

Psoas Hitch or Boari Flap. Tension at the anastomosis site impairs healing, and either of these procedures can release stress at the union site. For a psoas hitch, the bladder is mobilized away from the symphysis, and its peritoneal attachments are incised. Now less tethered, the bladder is lifted cephalad and to a level sufficiently high to release tension at the anastomotic site. To secure this new position, the bladder is sewn to the psoas major muscle or its fascia with 3-0 nonreactive permanent suture or 2-0 absorbable suture. Permanent sutures should be placed while the bladder is open. This allows direct viewing of suture placement to exclude a stitch penetrating the bladder mucosa, which would provide a nidus for stone formation.

At completion of the procedure, a one-way suction drain may be placed in the pelvis below the anastomotic site to drain urine that may extravasate. The bladder is drained by Foley catheter for 7 to 14 days postoperatively. The ureteral stents may be removed in 3 to 6 weeks. IVP is obtained in 3 to 6 months to ensure continued patency and exclude stricture.

An alternative to the psoas hitch is the Boari flap. In this procedure, the bladder ipsilateral to the injury is mobilized, and a pedicle of anterior bladder wall is fashioned into a tube to bridge to the ureter.

Midpelvic Ureteral Injuries

Injuries to the ureter at or above the midpelvis most commonly occur during isolation or transection of the infundibulopelvic ligament and may be repaired by ureteroureterostomy. To begin, the ureteral edges are debrided of devitalized tissue and spatulated by making a 5-mm longitudinal incision in both the proximal and distal ureters. A ureteral stent is then placed through a cystotomy incision or the ureterotomy. For placement through the ureterotomy, one end of a double-pigtail stent and its companion guide wire are threaded in a retrograde fashion through the proximal ureter. The guide wire is removed, allowing the proximal portion of the ureteral stent to coil in the renal pelvis (Baron, 1993). The guide wire is then passed through a small hole in the midportion of the ureteral stent through the inferior portion of the stent. The stent and guide wire advance through the distal ureter and into the bladder. The guide wire is removed, and the stent coils within the bladder.

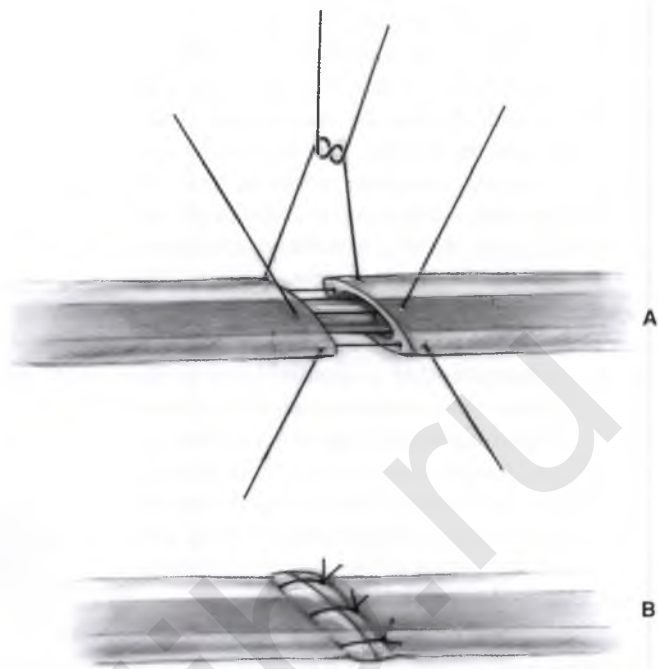


FIGURE 28-4 Ureteroureterostomy. **A.** To begin, the ureteral ends are cut at a 45-degree angle to minimize final lumen narrowing. A ureteral stent has already been inserted as described in the text. Interrupted full-thickness sutures using 4-0 absorbable suture approximate the ureteral ends. **B.** Final repair with tied interrupted sutures. The ureteral stent remains during healing.

The ureter is approximated with 5-0 Vicryl or chromic gut suture in an interrupted fashion with sutures that are full-thickness through the ureteral wall. The suture line lies roughly on a 45-degree angle relative to the luminal direction of the ureter (Fig. 28-4). If the suture line is directly perpendicular to the lumen, contracture during healing increases the risk of stenosis and obstruction. Following lumen reapproximation, a one-way suction drain is placed adjacent to the ureter in case of leakage. The drain should lie a sufficient distance from the anastomosis to avoid negative pressure on the union site.

Postoperatively, the bladder is drained by Foley catheter for 10 to 14 days if cystotomy was performed. The suction drains may be removed if there is less than 15 mL of drainage for 24 hours on two consecutive days. The ureteral stents are left in place until a pyelogram is obtained to document patency and integrity of the anastomosis. The ureteral stent can be removed by in-office cystoscopy after 3 to 6 weeks. Factors that impair healing should be considered when deciding to remove the stents (Table 28-2).

TABLE 28-2. Factors That Impair Healing of the Urinary and Gastrointestinal Tracts

Poor perfusion/devascularization
Anemia
Infection
Bladder dysfunction
Urinary retention
Tension on suture line
Radiation exposure

Prevention

Because of the increased risk of ureteral injury with uterine extension during cesarean delivery, prevention measures should focus on preoperative risk evaluation and intraoperative technique. Extensions are more likely with a large fetus, with prolonged labor and cephalopelvic disproportion, with a breech or low transverse lie brought through a low transverse incision, with emergent delivery, and with difficult extraction of the newborn (Eisenkop, 1982). Intraoperatively, a controlled and adequate hysterotomy is one preemptive step, and options are described and illustrated in Chapter 25 (p. 409). Similarly, gentle and atraumatic neonate delivery may reduce the risk of extension.

If hysterotomy laceration does extend into the broad ligament or vagina, great care is taken during repair or during placement of hemostatic sutures. After sutures are tied, ureters should be identified, if possible, and evaluated for patency. With peripartum hysterectomy, the best prevention is sound intraoperative technique and direct visualization of the peristalsing ureter. This is described in detail in Chapter 26 (p. 426). Also, the ureter may be felt to “snap” if palpated along its course on the broad ligament’s medial leaf. However, vessels, adipose tissue, and peritoneal folds can mimic this. Although prophylactic ureteral stenting is generally not recommended for cesarean delivery, it may have some benefit in reducing morbidity in the setting of peripartum hysterectomy for placenta accreta (Eller, 2009).

BOWEL INJURIES

■ Small-Bowel Injuries

Injury to the gastrointestinal tract during cesarean delivery is uncommon. It is most likely to occur in patients with adhesions, especially when surgery is performed emergently. Diagnosis is usually easily made, as bowel contents spill into the operative field or the injury is seen directly. Management depends on the size, location, depth, number of injuries, and integrity of the bowel blood supply. If injured prior to delivery of the fetus, the bowel defect is marked with a suture and covered with a moist laparotomy sponge. Repair is deferred until delivery and hysterotomy closure are completed (Davis, 1999).

Small serosal injuries seldom require repair. Larger serosal defects may be oversewn using 2-0 or 3-0 absorbable or permanent suture. Interrupted stitches through the serosa and muscularis are used to imbricate and reinforce the injury site. To minimize narrowing of the ultimate bowel caliber, a surgeon places sutures parallel to the lumen. Thus, the final suture line lies perpendicular to the lumen. These injuries do not require any particular modification in routine postoperative care.

Full-thickness enterotomies in the small or large bowel that are less than or equal to half the circumference of the bowel can usually be repaired primarily if the blood supply is not compromised. Using a fine-gauge suture, such as 3-0 silk or Vicryl sutures on a taper needle, stitches are placed at the angles of the wound. Again, these are oriented such that the direction of the wound lies perpendicular to the luminal direction. This latter point is key to prevent later bowel narrowing or stricture and

potential for obstruction. Using the same suture, the wound is closed in an imbricating fashion with stitches spaced approximately 3 to 4 mm apart (Fig. 28-5). These sutures are placed deep enough to include the muscularis and the lamina propria of the bowel. After repair, the bowel lumen is palpated to evaluate the final luminal diameter, which should be at least 1 to 2 cm. The repair site is inspected for leaks by placing luminal contents under mild pressure. If bowel contents leak through the suture line, defects are reinforced with additional interrupted sutures.

Injuries greater than one-half the bowel circumference, multiple injuries, or those with compromised blood supply should be resected. Consultation with a gynecologic oncologist or general surgeon is recommended. Bowel resection can be accomplished either manually or with intestinal staplers. Surgical staplers are preferable because of improved blood supply to the anastomosis and lower incidence of clinically significant leaks (Delgado, 1984). This provides for better healing and greater anastomotic luminal diameter, thus reducing the risk of stenosis and obstruction. Hand-sewn end-to-end anastomosis is preferred if the staplers cannot be applied properly.

After repair, the injury site and abdomen are copiously irrigated. In cases with significant intestinal spillage, placement of a pelvic suction drain is considered. Systemic antibiotics are usually not required postoperatively (Davis, 1999). Similar to urinary tract injuries, prophylactic discussion with a specialist and assembly of potentially needed staplers can aid treatment of injury and avoid equipment delays.

■ Colon Injuries

Large-bowel lacerations increase the risk of fecal peritonitis, sepsis, and poor wound healing. Serosal defects and small lacerations may be managed similarly to those of the small intestine. With more extensive injuries, with a complicated repair, or with a compromised blood supply requiring resection, consultation with a gynecologic oncologist or colorectal surgeon is indicated. Data from randomized trials show that most patients with penetrating colon injuries can be managed with primary repair or with resection and reanastomosis. These can be completed without diverting colostomy, regardless of the amount of fecal contamination (Davis, 1999). Rarely, diversion may be considered for evidence of ischemia, inflammation, bowel compromise, excessive tension on the suture line, or delayed diagnosis with an infected and inflamed abdomen (Mesdaghinia, 2013). Due to the increased infection risk with large-bowel injury, broad-spectrum antibiotic prophylaxis is provided for 24 hours postoperatively. Suitable options are described in Chapter 18 (p. 296), and some include a first-generation cephalosporin or a combination of clindamycin and gentamycin.

■ Postoperative Dietary Management

Available evidence and clinical judgement should prevail in the management of diet after bowel surgery. Routine decompression with nasogastric tube is unnecessary and does not prevent anastomotic leaks (Fanning, 2001). However, obstruction, protracted postoperative ileus, or persistent vomiting with risk of aspiration generally requires nasogastric-tube decompression.

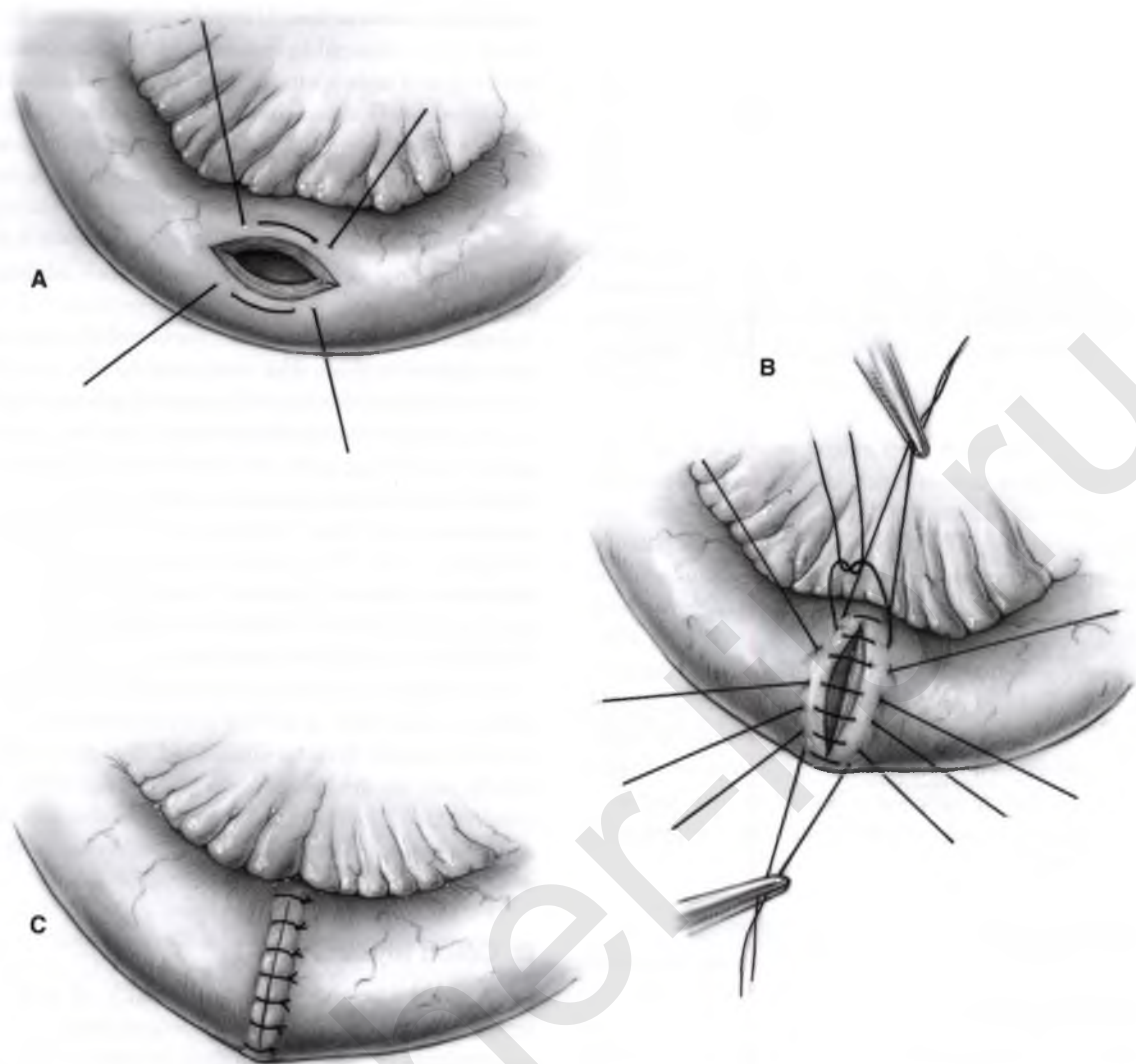


FIGURE 28-5 Enterotomy repair. **A.** Placement of traction sutures lateral to a longitudinal wound. **B.** Conversion of longitudinal wound to transverse wound with placement of imbricating sutures of 3-0 silk. **C.** Completed enterotomy repair.

In general, for both small- and large-intestinal injuries, early feeding is acceptable and is not associated with repair site complications. Passage of flatus is not required to advance diet, but significant nausea and emesis associated with early feeding may inhibit initial progress (Fanning, 2001). There is some accumulating evidence that chewing gum may aid return of bowel function and reduce ileus rates after bowel resection or cesarean delivery (Abd-El-Maeboud, 2009; Chan, 2007). Clearly, patients are monitored clinically for any evidence of ileus, obstruction, or peritonitis, with appropriate dietary adjustment and management based on clinical status.

■ Prevention

Surgeons should have a high suspicion for adhesions in patients with multiple previous abdominal operations. Great caution should be exercised when entering the peritoneal cavity in these patients, with sharp dissection to lyse adhesions and mobilize the bowel (Davis, 1999; Mesdaghinia, 2013). A separate incision or extension of the existing one to an area that has not been previously opened can be considered. Strict adherence to

surgical principles of gentle tissue handling, adequate exposure, gentle retraction, and sparing use of diathermy near hollow organs is also important.

After any extensive pelvic dissection, the bowel should be systematically inspected along its entire length to detect serosal defects and unrecognized perforation. At suspected sites, the bowel is scrutinized for mucosal eversion and content leakage. Intraoperative injury recognition is instrumental in avoiding substantial postoperative morbidity that can include multiple surgeries and the possibility of a stoma (Mesdaghinia, 2013).

SUMMARY

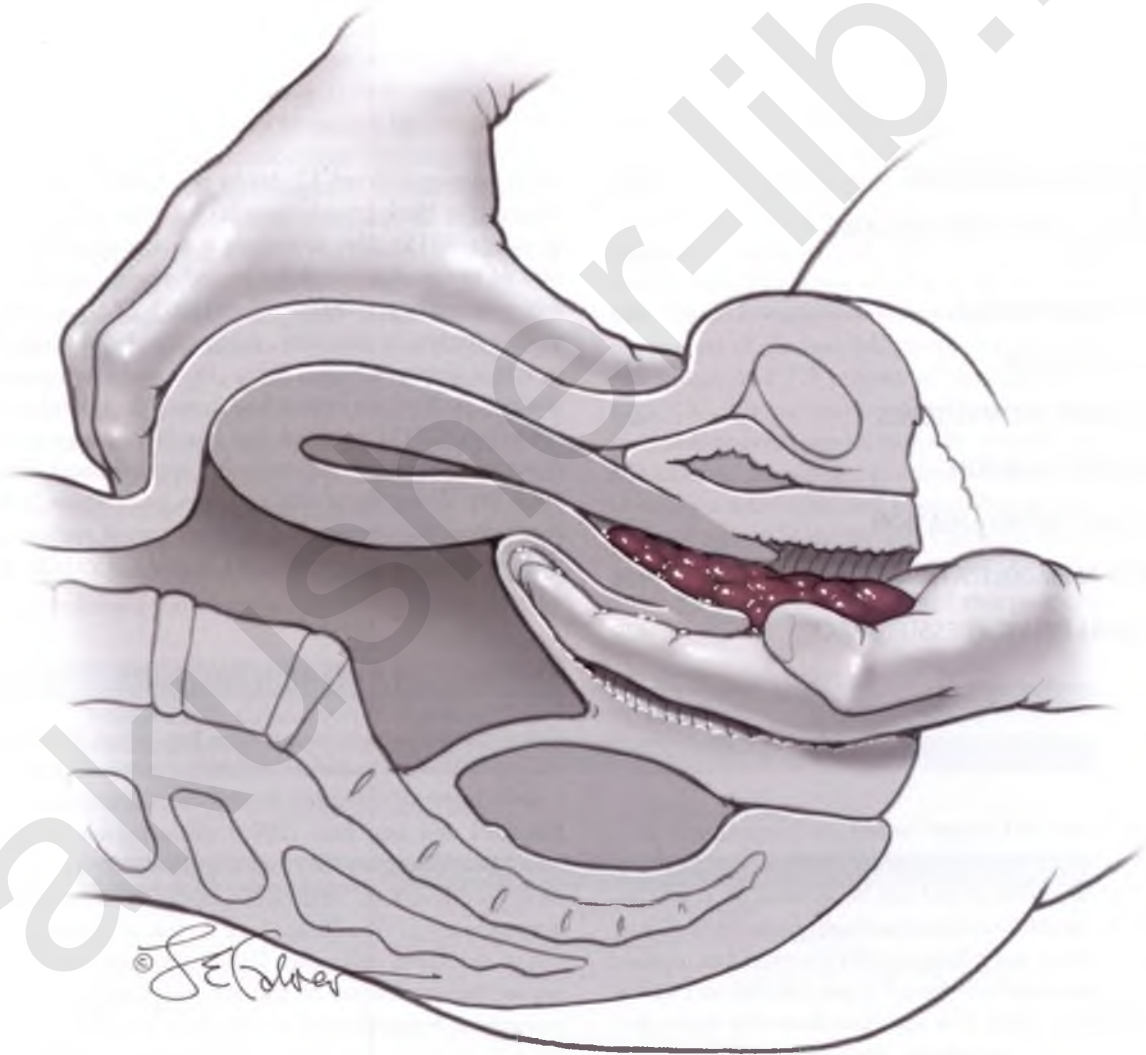Urologic and gastrointestinal injuries are infrequent during obstetric surgical procedures. These most often involve the urinary bladder and occur during cesarean delivery. When urologic or gastrointestinal damage is suspected, the full extent of the injury should be defined, and the need for specialist assistance determined. Intraoperative recognition is essential to avoid significant postoperative morbidity and sequelae. Most bladder

injuries and small-bowel partial- or full-thickness lacerations involving less than half the bowel circumference can usually be repaired primarily. Suspected ureteral injuries, more extensive small- and large-bowel lacerations, and management beyond the expertise of the operating surgeon all justify consultation with the appropriate specialist.

REFERENCES

- Abd-El-Maeboud KH, Ibrahim MI, Shalaby DA, et al: Gum chewing stimulates early return of bowel motility after caesarean section. *BJOG* 116(10):1334, 2009
- American College of Obstetricians and Gynecologists: Cesarean delivery on maternal request. Committee Opinion No. 559, April 2013, Reaffirmed 2015
- Armenakas NA: Current methods of diagnosis and management of ureteral injuries. *World J Urol* 17:8, 1999
- Barbieri RL: Farewell to indigo carmine. *OBG Manag* 26(9): 8, 2014
- Baron JG, Vates TS, Vasselli AJ: A simple technique for intraoperatively stenting a transected ureter. *Urology* 149:535, 1993
- Blandy JP, Bedenoch DF, Fowler CG, et al: Early repair of iatrogenic injury to the ureter or bladder after gynecological surgery. *Urology* 146:761, 1991
- Brubaker LT, Wilbanks GD: Urinary tract injuries in pelvic surgery. *Surg Clin North Am* 71:963, 1991
- Cahill AG, Stout MJ, Stamilio DM, et al: Risk factors for bladder injury in patients with prior hysterotomy. *Obstet Gynecol* 112:116, 2008
- Chaliha C, Stanton SL: Urological problems in pregnancy. *BJU Int* 89:469, 2002
- Chan MK, Law WL: Use of chewing gum in reducing postoperative ileus after elective colorectal resection: a systematic review. *Dis Colon Rectum* 50(12): 2149, 2007
- Davis JD: Management of injuries to the urinary and gastrointestinal tract during cesarean section. *Obstet Gynecol Clin N Am* 26:469, 1999
- Delgado G: The automatic staple versus the conventional gastrointestinal anastomosis in gynecological malignancies. *Gynecol Oncol* 18:293, 1984
- Doyle PJ, Lipetskaia L, Duecy E, et al: Sodium fluorescein use during intraoperative cystoscopy. *Obstet Gynecol* 125(3):548, 2015
- Eisenkop SM, Richman R, Platt LD, et al: Urinary tract injury during cesarean section. *Obstet Gynecol* 60(5):591, 1982
- Eller AG, Porter TF, Soisson P, et al: Optimal management strategies for placenta accreta. *BJOG* 116(5):648, 2009
- Fanning J, Andrews SA: Early postoperative feeding after major gynecologic surgery: evidence-based scientific medicine. *Am J Obstet Gynecol* 185(1):1, 2001
- Farcy PO, Augspurger RR, Kaufman JM: Bladder injuries associated with cesarean section. *Urology* 120:762, 1978
- Francis, SL, Magrina JF, Novicki D, et al: Intraoperative injuries of the urinary tract. *J Gynecol Oncol* 7:65, 2002
- Grimes C, Kim JH: Sodium fluorescein use during intraoperative cystoscopy. *Obstet Gynecol* 125(6):149, 2015
- Harrow BR: A neglected maneuver for ureterovesical reimplantation following injury at gynecologic operations. *Urology* 100:280, 1968
- Kattan SA: Maternal urological injuries associated with vaginal deliveries: change of pattern. *Int Urol Nephrol* 29(2):155, 1997
- MacDorman MF, Menacker F, Declercq E: Cesarean birth in the united states: epidemiology, trends, and outcomes. *Clin Perinatol* 35:293, 2008
- Mesdaghinia, E, Abedzadeh-Kalahroudi M, Hedayati M, et al: Iatrogenic gastrointestinal injuries during obstetrical and gynecological operation. *Arch Trauma Res* 2(2):81, 2013
- Narasimhulu DM, Prabakar C, Tang N, et al: Use of 50% dextrose as the distension medium during cystoscopy for visualization of ureteric jets. *Obstet Gynecol* 127:78, 2016
- Neuman M, Eidelman A, Langer R: Iatrogenic injuries to the ureter during gynecologic and obstetric operations. *Surg Gynecol Obstet* 173:268, 1991
- Nielsen TF, Hokegard KH: Cesarean section and intraoperative surgical complications. *Acta Obstet Gynecol Scand* 63:103, 1984
- Office of Disease Prevention and Health Promotion: Healthy people: maternal, infant, and child health. 2014. Available at: <http://www.healthypeople.gov/2020/topics-objectives/topic/maternal-infant-and-child-health/objectives>. Accessed December 5, 2015
- O'Leary JL, O'Leary JA: A simplified method of determining ureteral patency at operation. *Am J Obstet Gynecol* 101:271, 1968
- Osterman MJ, Martin JA: Primary cesarean delivery rates, by state: results from the revised birth certificate, 2006–2012. *Natl Vital Stat Rep* 63(1):1, 2014
- Patsner B, Hackett TE: Use of the omental J-flap for prevention of postoperative complications following radical abdominal hysterectomy: report of 140 cases and literature review. *Gynecol Oncol* 65:405, 1997
- Phipps MG, Watabe B, Clemons JL, et al: Risk factors for bladder injury during cesarean delivery. *Obstet Gynecol* 105:156, 2005
- Rahman MS, Gasem T, Al Suleiman SA, et al: Bladder injuries during cesarean section in a university hospital: a 25 year review. *Arch Obstet Gynecol* 279:349, 2009
- Rajasekar D, Hall M: Urinary tract injuries during obstetric intervention. *BJOG* 104:731, 1997
- Rasmussen PE, Nielsen FR: Hydronephrosis during pregnancy: a literature survey. *Eur J Obstet Gynecol Reprod Biol* 27:249, 1988
- Schaffer JI, Corton MM, Hoffman BH: Fundamentals of minimally invasive surgery. In Hoffman BL, Schorge JO, Bradshaw KD, et al: *Williams Gynecology*, 3rd ed. New York, McGraw-Hill Education, 2016
- Shellhaas CS, Gilbert S, Landon MB: The frequency and complication rates of hysterectomy accompanying cesarean delivery. *Obstet Gynecol* 114:224, 2009
- Silver RM, Landon MB, Rouse DJ, et al: Maternal morbidity associated with multiple repeat cesarean deliveries. *Obstet Gynecol* 107:1226, 2006
- Tarney CM: Bladder injury during cesarean delivery. *Curr Womens Health Rev* 9(2):70, 2013
- Wright JD, Devine P, Shah M, et al: Morbidity and mortality of peripartum hysterectomy. *Obstet Gynecol* 115:1187, 2010
- Yossepowitch O, Baniel J, Livne PM: Urological injuries during cesarean section: intraoperative diagnosis and management. *J Urol* 172:196, 2004

SECTION 4
POSTPARTUM



CHAPTER 29

Management of Postpartum Hemorrhage

DEFINITION AND RISK FACTORS	466
HYPOVOLEMIC SHOCK AND VOLUME RESUSCITATION	468
CAUSES OF HEMORRHAGE	469
UTERINE TAMPONADE	471
UTERINE COMPRESSION SUTURES	473
UTERINE ARTERY LIGATION	475
INTERNAL ILIAC ARTERY LIGATION	476
ANGIOGRAPHIC EMBOLIZATION	478
TRANSVAGINAL PELVIC PRESSURE PACK	479

In 1986, the Centers for Disease Control and Prevention (CDC) initiated a program of national surveillance of pregnancy-related deaths. It is serially updated and can be accessed at: www.cdc.gov/reproductivehealth/maternalinfanthealth/pmss.html. Using this database, Creanga and colleagues (2015) reported an increase in the maternal mortality rate from 7.2 per 100,000 in 1987 to 17.8 per 100,000 in 2009. It is also clear from this report that hemorrhage remains a significant cause of pregnancy-related deaths, accounting for 11.4 percent of such deaths from 2006 to 2010. This is despite widespread recognition of the consequences of obstetric hemorrhage and the availability of modern blood-banking techniques. Notably, the United States is one of the few countries worldwide that has not reported a decline in maternal mortality rates but instead has shown a significant rise. One worrisome trend was the marked racial disparity in pregnancy-related mortality rates. In data from 2006 to 2010,

white women suffered 12 deaths per 100,000 births, whereas the rate for black gravidas was 36.4 deaths per 100,000 births (Creanga, 2015). Also disturbing is that approximately 90 percent of maternal hemorrhage-related deaths have been considered potentially preventable (Berg, 2005; D'Alton, 2014).

In addition to mortality, postpartum hemorrhage can lead to severe postpartum morbidity. In a multicenter surveillance study of postpartum hemorrhage from Brazil, Rocha Filho and coworkers (2015) reported that the hemorrhage-related incidence of severe maternal morbidity approximated 3 events per 1000 live births. Significant or severe postpartum hemorrhage is estimated to complicate 2 to 4 percent of vaginal deliveries and 6 percent of cesarean births (Combs, 1991a,b; Klapholz, 1990).

DEFINITION AND RISK FACTORS

Although postpartum hemorrhage has always been one of the leading causes of maternal mortality and morbidity, no universally accepted definition for this complication is recognized. Pritchard and associates (1962) quantitatively measured the blood loss in women who had a vaginal delivery, had a repeat cesarean delivery, or underwent repeat cesarean delivery with hysterectomy (Table 29-1). In a review of postpartum blood loss, Gahres and colleagues (1962) reported a mean loss following vaginal delivery of 450 mL for all series. Traditionally, postpartum hemorrhage has been defined as blood loss exceeding 500 mL following vaginal delivery and exceeding 1000 mL following cesarean delivery.

Several problems muddy this definition. First, clinical estimates of blood loss are notoriously inaccurate, and blood loss is often underestimated and underappreciated. Another major problem is that blood loss often approaches or exceeds these amounts without clinical consequences.

Another criterion used to define postpartum hemorrhage is a drop in the hematocrit of 10 percent or more. The major

TABLE 29-1. Estimated Mean Blood Loss for Obstetric Procedures

Procedure	Blood Loss (mL)
Vaginal delivery	450
Cesarean section	1000
Elective cesarean hysterectomy	1400
Emergent cesarean hysterectomy	3200

Data from Chestnut, 1985; Clark, 1984; Gahres, 1962; Gilbert, 1987; Newton, 1961; Pritchard, 1962.

flaw with this definition is that the hematocrit may not reflect current blood volume status in the acutely bleeding patient (American College of Obstetricians and Gynecologists, 2015; Combs, 1991a,b). Namely, hematocrit values typically lag true losses, and values may reflect only the degree of hemorrhage.

Rather than estimating blood loss or relying on laboratory parameters, Gilstrap and Ramin (1994) suggested that postpartum hemorrhage could best be gauged by clinical evaluation of the gravida's hemodynamic status. They suggested that term hemorrhage could best be thought of as that amount of bleeding resulting in hemodynamic instability or that would result in such if left unabated. Used in this context, hemorrhage is "significant or serious" postpartum bleeding.

The precise amount of bleeding that meets this criterion varies depending on several factors. Paramount is the degree of circulating blood volume in a given woman. The equation to calculate blood volume is shown in Table 29-2. For example, a blood loss of 1000 to 1500 mL may be of little consequence following an otherwise uncomplicated twin delivery. In contrast, a similar loss might cause significant hypotension in a woman with severe preeclampsia. Hernandez and associates (2012) prospectively studied 1443 women who received a blood transfusion for hypovolemia from obstetric hemorrhage. These authors

found that median blood loss was 3529 mL and that 93 percent of these parturients had losses ≥ 3000 mL. They concluded that the amount of blood loss sufficient to produce signs and symptoms of hypovolemia—that is, hemodynamic instability—was large and required blood infusion to restore circulation.

Kramer and colleagues (2013) reviewed 8.5 million hospital deliveries in the U.S. Nationwide Inpatient Sample from 1999 to 2008 for risk factors for severe postpartum hemorrhage. Bleeding was defined as severe if hemorrhage was accompanied by blood transfusion, hysterectomy, or surgical repair of the uterus. They found a rise in severe postpartum hemorrhage rates from 1.9 to 4.4 cases per 1000 deliveries during this time period. Risk factors for severe hemorrhage included multifetal pregnancy, leiomyomas, preeclampsia, placenta previa or abruption, cervical laceration, operative vaginal delivery, uterine rupture, and cesarean delivery. Others have identified similar and additional risk factors Table 29-3 (Combs, 1991a,b; Gilstrap, 1987). Importantly, a familiarity with this list can prompt preventive steps when significant or multiple at-risk characteristics are present.

The California Maternal Quality Care Collaborative (CMQCC) has established risk criteria for peripartum hemorrhage (Lyndon, 2015). In a study of more than 10,000 women in a single hospital, Dilla and coworkers (2013) used three defined risk groups. They evaluated whether these three categories correlated with the risk of significant postpartum hemorrhage, which was defined as bleeding requiring transfusion. These investigators reported peripartum hemorrhage in 0.8 percent of the low-risk group, 2.0 percent of the medium-risk group, and 7.3 percent of the high-risk group. For the CMQCC, characteristics that described high-risk gravidas included: placenta previa, morbidly adherent placenta, hematocrit less than 30 percent, platelets less than $100,000/\mu\text{L}$, active bleeding at admission, and known coagulopathy.

In a cohort study by the Canadian Institute for Health Information of more than 2 million deliveries from 2003 to 2010, Mehrabadi (2014) reported that postpartum hemorrhage

TABLE 29-2. Calculation of Maternal Total Blood Volume**Nonpregnant Blood Volume^a**

$$\frac{[\text{Height (inches)} \times 50] + [\text{Weight (pounds)} \times 25]}{2} = \text{Blood volume (mL)}$$

Pregnancy Blood Volume

Varies from 30 to 60 percent of calculated nonpregnant volume
 Increases across gestational age and plateaus at approximately 34 weeks
 Usually larger with low normal-range hematocrit (~30) and smaller with high normal-range hematocrit (~40)
 Average increase is 40 to 80 percent with multifetal gestation
 Average increase is less with preeclampsia—volumes vary inversely with severity

Postpartum Blood Volume with Serious Hemorrhage

Assume acute return to nonpregnant total volume after fluid resuscitation
 Pregnancy hypervolemia cannot be restored postpartum

^aFormula arrived at by measuring blood volume and blood loss in more than 100 women using ⁵¹Cr-labeled erythrocytes.

From Cunningham, 2014; Hernandez, 2012.

TABLE 29-3. Risks for Postpartum Hemorrhage**Fetal**

Hydramnios
Fetal macrosomia
Multifetal pregnancy
Pre- and postterm delivery

Placental

Placenta previa
Placenta accreta
Placenta abruptio
Low-lying placenta

Maternal

Obesity
Nulliparity
Preeclampsia
Thrombocytopenia
Grand multiparity
Congenital coagulopathy
Prior postpartum hemorrhage
Disseminated intravascular coagulopathy

Uterine

Leiomyomas
Uterine rupture
Uterine inversion
Hysterotomy extension
Classical uterine incision

Intrapartum

Episiotomy
Chorioamnionitis
Cesarean delivery
Arrest of descent
General anesthesia
Soft-tissue lacerations
Amniotic fluid embolism
Oxytocin-augmented labor
Operative vaginal delivery
Prolonged third-stage labor

rates increased from 5.1 percent in 2003 to 6.2 percent in 2010. Severe postpartum hemorrhage was defined as postpartum hemorrhage plus blood transfusion, hysterectomy, or other procedures to control bleeding. The rise in bleeding rates was mostly attributed to an increase in uterine atony rates. Lacerations, abnormal placental attachments, and coagulopathy accounted for most of the remaining cases.

HYPOVOLEMIC SHOCK AND VOLUME RESUSCITATION

■ Physiologic Changes

To prevent maternal mortality and morbidity from postpartum hemorrhage, clinicians should be familiar with common preventable errors. These include failures to recognize the degree of blood loss, to appreciate the clinical signs of hypovolemia,

and to promptly initiate lifesaving interventions and restoration of blood volume (Clark, 2012; D'Alton, 2014).

Fortunately, the hypervolemia of pregnancy in most cases allows the parturient to accommodate normal to even excessive blood loss at vaginal delivery without a drop in postpartum hematocrit. In one study, the mean postpartum hematocrit decline was 2.6 ± 4.3 percent, and a third of women either had no decline or had an actual rise (Combs, 1991b). Women undergoing cesarean delivery experienced a mean drop in hematocrit of 4.0 ± 4.2 percent after equilibration, but approximately 20 percent had no decline (Combs, 1991a).

Even with moderate additional blood loss, venous compensatory mechanisms allow most women to tolerate such hemorrhage without hemodynamic compromise. With continued hemorrhage, however, these mechanisms may be overwhelmed and lead to hypotension, decreased tissue perfusion, oliguria, cellular hypoxia, and death. Indeed, hemorrhage is the most common cause of shock in obstetrics and gynecology.

As blood volume deficits exceeds a critical level, compensatory mechanisms usually are inadequate to maintain cardiac output and blood pressure. At this point, additional small blood losses result in rapid clinical deterioration. Despite an initial increase in total oxygen extraction by maternal tissue, maldistribution of blood flow results in local tissue hypoxia and metabolic acidosis. This produces a vicious cycle of vasoconstriction, organ ischemia, and cellular death. Consequently, capillary membrane integrity and additional intravascular volume are lost (Slater, 1973). Increased platelet aggregation is also found in hypovolemic shock. The subsequent, release of several vasoactive mediators causes small vessel occlusion and further impairment of microcirculatory perfusion.

■ Patient Resuscitation

In an extensive “toolkit” developed by the California Maternal Quality Care Collaborative (CMQCC), obstetric hemorrhage is divided into stages 1 through 3. Stage 0 is prevention and recognition of hemorrhage (Lyndon, 2015). Stage 3 is defined as an estimated blood loss of >1500 mL or the administration of greater than two units of packed red blood cells (pRBCs), persistent unstable vital signs, or the suspicion of disseminated intravascular coagulopathy (DIC). For stage 3, this group recommends activation of a *massive transfusion protocol*. This seems a bit overcautious, and elements of this protocol are discussed in further detail in Chapter 7 (p. 98). Surgical approaches to control hemorrhage sometimes are also necessary in this latter stage.

Not surprisingly, opinions vary regarding the most appropriate ratio of plasma, pRBCs, and platelets in the presence of severe postpartum bleeding. As discussed in Chapter 7, generally, 1:1:1 blood product replacement is suggested by many. This ratio refers to one unit of pRBCs to one unit of fresh frozen plasma (FFP) and one unit of platelets. In some instances, plasma and platelets are given even if those laboratory values are normal with the goal of preventing coagulopathy from developing.

From the foregoing, it can be appreciated that fresh whole blood would be preferable in most cases of postpartum hemorrhage. Whole blood provides needed intravascular volume; it increases the fibrinogen level and hematocrit; and it

TABLE 29-4. Blood Products and Some Characteristics

Product	Volume	Content	Shelf Life
Whole blood	450 mL	All blood components	35 days No granulocytes or platelets after 24 hours. Decreased but functionally adequate levels of factors V and VIII for 1–2 weeks.
Packed red blood cells	250 mL	Red cells	5 days
Fresh frozen plasma	200–250 mL	All stable and labile clotting factors	1 year
Cryoprecipitate	50 mL	Factors V; VIII;c; VIII: von Willebrand; XIII; fibronectin fibrinogen	1 year
Platelets	50 mL (per pack)	Platelets	5 days

reduces the risk for acute kidney injury. For example, Alexander and colleagues (2009) summarized outcomes from 1540 women who received a blood transfusion. Of these, 659 were given whole blood, 593 received packed red cells only, and 288 received a combination of blood component therapy. Those transfused with whole blood had a lower incidence of acute kidney injury, intensive care unit admission, and death compared with the other two groups.

Although fresh whole blood is ideal for the management of serious hemorrhage, in practice it is rarely available. Thus, crystalloid solution and pRBCs are the mainstays of volume replacement. When blood loss is massive, however, such replacement may result in a depletion of platelets and soluble clotting factors leading to a dilutional coagulopathy (Cunningham, 2015). This impairs hemostasis and further contributes to blood loss. As shown in Table 29-4, stored whole blood is deficient in factors V, VIII, XI, and platelets, and almost all soluble clotting factors are absent from pRBCs. Thus, severe hemorrhage treated only with pRBC replacement may also lead to diminished fibrinogen levels and prolonged prothrombin (PT) and partial thromboplastin times (PTT). In some cases, frank DIC accompanies shock, and this may confuse the distinction between dilutional and consumptive coagulopathy (Abdul-Kadir, 2014). Fortunately, in most situations encountered in obstetrics, treatment of both is the same (Cunningham, 2015).

Various algorithms have been proposed to guide the replacement of platelets and clotting factors according to the volume of blood loss, especially when using only pRBCs. That said, understandably, patient variability is great. Such component replacement is rarely needed with the acute replacement of five units of pRBCs or less. When blood loss exceeds this amount, consideration often prompts laboratory evaluation of platelet count and fibrinogen levels. Replacement is guided by laboratory values and clinical evidence of bleeding from a coagulopathy. In the woman who is bleeding, the platelet count ideally is kept above 50,000/ μ L by the infusion of platelet concentrates. A fibrinogen level <150 mg/dL or a sufficiently prolonged PT or PTT in a bleeding patient is an indication for fresh-frozen plasma to be given in doses of 10 to 15 mL/kg. Importantly, approximately 30 minutes are required for frozen plasma to thaw. Cryoprecipitate (15 mL per unit) may also be used as a

source of fibrinogen. This product usually offers no advantage compared with FFP for general clotting factor replacement. An uncommon exception may be a woman in whom volume overload is a concern during resuscitation. Following platelet or factor replacement, levels are followed closely until the patient is stable.

CAUSES OF HEMORRHAGE

Proper management of postpartum bleeding requires a thorough search for the specific cause of the hemorrhage. Individual diagnoses require specific management, both in terms of technique and in the rapidity with which such techniques are applied. For example, proper treatment of intermittent uterine atony may at times involve a prolonged period of uterine massage, observation, and continued attempts at pharmacologic reversal. On the other hand, postpartum hemorrhage from placenta percreta will generally require prompt hysterectomy. Errors can be made when the clinician manages “postpartum hemorrhage” without attempts to determine specific etiology.

Fortunately, the causes of severe postpartum hemorrhage are few. In virtually all cases, one or more of four factors are involved: uterine atony; retained placenta, including the placental accrete syndromes; or upper or lower genital tract lacerations, including cesarean delivery. The fourth is coagulopathy that manifests bleeding from the first three causes.

■ Uterine Atony

Risk Factors

The most frequent cause of serious postpartum hemorrhage is failure of the uterus to contract. Risk factors for uterine atony include advanced parity, the use of oxytocin for labor augmentation, chorioamnionitis, arrest disorders of labor, and uterine overdistention, as with macrosomia or multifetal gestation. In the series described by Clark and coworkers (1984), 80 percent of women undergoing hysterectomy for intractable atony had one or more of these risk factors. Recognition of these characteristics should alert the clinician to the possibility of this complication.

Bleeding from atony may be rapid and leave little time for indecision. Therefore, every obstetric unit should establish a

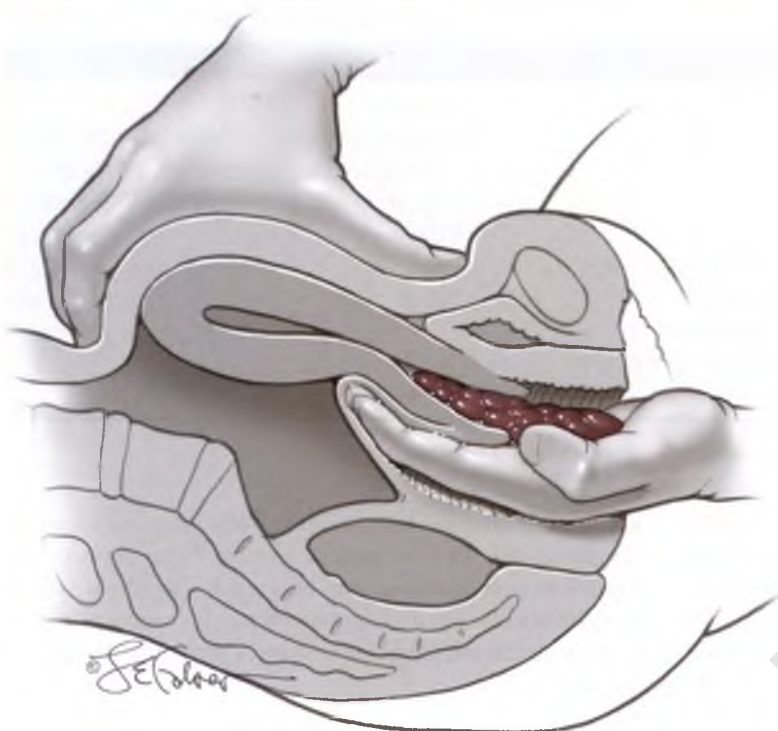


FIGURE 29-1 Bimanual compression. The vaginal hand should also lift the uterus out of the pelvis and toward the abdominal hand.

protocol or checklist for atony treatment. Uterine massage is classically taught as an essential component of third-stage labor to prevent atony and postpartum hemorrhage. However, the benefit of this procedure in the review by Hofmeyr and associates (2013) was inconclusive. Notably, the authors concluded that this was not reason enough to change current practice.

Uterotonic Agents

Despite uterine massage, if atony develops following removal of the placenta, firm compression is exerted on the uterus by bimanual compression (Fig. 29-1). Even if atony does not promptly resolve, such compression can often bring temporary effective control of hemorrhage. This provides time to administer uterotonic agents, obtain blood products, and summon assistance. Simultaneous with such compression, a dilute solution of 20 or 40 units of oxytocin in 1000 mL of crystalloid is infused rapidly. Because rapid crystalloid infusion is the first step in management of such women, the intravenous line can

be opened fully. The direct intravenous bolus injection of undiluted oxytocin may cause a paradoxical hypotensive response and thus is not recommended (Secher, 1978).

If these initial attempts to reverse uterine atony are unsuccessful, additional pharmacologic maneuvers are indicated (Table 29-5). Methylergonovine (Methergine), 0.2 mg, may be given intramuscularly every 2 to 4 hours for up to five doses. It should not be given intravenously. Side effects include nausea, vomiting, and headaches. Severe hypertension can develop in women with preeclampsia or gestational hypertension.

Various prostaglandin preparations can also effectively reverse uterine atony. One commonly used is carboprost tromethamine (Hemabate), which is a synthetic 15-methyl analogue of prostaglandin $F_{2\alpha}$. A single dose of 0.25 mg is usually effective. In selected cases, however, repeat dosing at intervals of 15 to 90 minutes can be given. The decision for additional injections and the dosing interval should be dictated by clinical events. The total dose should not exceed eight doses (Pfizer, 2014). It is administered as an intramuscular injection. It can be given into the myometrium, but is never given intravenously.

The use of intrarectal or sublingual misoprostol (Cytotec) has also been described (Tunçalp, 2012). This is prostaglandin E_1 and available as 200- μ g tablets. Doses of 800 to 1000 μ g are given per rectum.

These agents may be added sequentially, and thus administration can overlap as needed to control bleeding. That said, none of these latter pharmacologic agents has proven to be superior to oxytocin for the treatment of uterine atony.

The use of uterine packing for atony following failure of pharmacologic therapy is controversial but may provide hemostasis in some women. Uterine packing may also be useful as a temporary method to decrease bleeding to a degree to allow for adequate blood replacement prior to attempting surgical control of hemorrhage.

At times, atony may be intermittent, requiring repeated physical or pharmacologic intervention over a period of several hours. Under such circumstances, care is taken to assess ongoing blood losses and to ensure adequate fluid and blood product replacement and hemodynamic stability. If, following the above maneuvers, the patient with atony continues to bleed significantly, surgical intervention is indicated.

TABLE 29-5. Uterotonic Agents

Oxytocin (Pitocin): 20 units in 1000 mL Ringer lactate for continuous IV infusion
One or more other uterotonic agents may be added as needed (prn):
Methylergonovine (Methergine): 0.2 mg = 1 mL = 1 ampule IM every 2–4 hr prn
Carboprost tromethamine (PGF _{2α}) (Hemabate): 250 μ g = 1 mL = 1 ampule IM every 15–90 min prn
Misoprostol (PGE ₁) (Cytotec) : 200 mg tablets for rectal administration, 800–1000 mg once

IM = intramuscularly; IV = intravenous.

■ Lacerations

Lower genital tract lacerations and uterine rupture are discussed in detail in Chapters 20 (p. 320) and 30 (p. 482).

■ Retained Placenta

After birth of the newborn, separation and expulsion of the placenta will typically follow. If spontaneous delivery is delayed, manual extraction may be indicated. In one study of 335 women with postpartum hemorrhage, third-stage labor lasting longer than 18 minutes was associated with a significant risk of postpartum hemorrhage. A third stage lasting more than 30 minutes was associated with a sixfold higher risk for hemorrhage (Magann, 2005).

Manual Curettage

Following its delivery, the placenta is carefully inspected for integrity of the cotyledons. This is especially true if a succenturiate lobe was identified antepartum during routine sonographic evaluation. With this placental anomaly, one or more small accessory lobes develop in the membranes at a distance from the main placenta.

If there is a suggestion of retained fragments, then manual exploration of the uterine cavity is undertaken in the delivery room. This is typically well tolerated by women with regional analgesia in place. However, for others, supplemental analgesia can be provided by anesthesia staff. As discussed in Chapter 19 (p. 309), suitable agents can include intravenous ketamine or inhaled nitrous oxide.

For curettage, an operator can wrap a 4 × 4-inch gauze around one or more fingers. This can generate greater friction against retained placental fragments and membranes to aid removal. During exploration, the membranes typically create a flat slippery uterine cavity surface. In contrast, placental fragments render the decidual surface irregular, raised, and slightly spongy.

To begin, the gauze-covered hand is introduced through the cervix into the uterine cavity and is guided to the fundus. Here, manual pressure against the decidual surface begins at the fundus and moves toward the cervix. After this first pass, the hand reaches again for the fundus but is moved a bit counterclockwise and positioned at a point adjacent to the first pass. A sweep toward the cervix is again completed. This process is repeated until the circumferential area of the cavity has been explored. If slippery or spongy tissue is encountered, it is firmly grasped and teased away from the cavity wall.

Surgical Curettage

If retained fragments cannot be evacuated in this manner, sharp curettage is undertaken. For this, established regional analgesia is sufficient, and curettage can be completed in the labor room. Alternatively, if there is greater concern for a morbidly adherent placenta or if a greater level of analgesia is required, then transfer to the operating room prior to curettage is reasonable. Before and during curettage, dilute oxytocin can be infused simultaneously.

With appropriate anesthesia established and the patient in standard lithotomy position, sharp curettage can be completed.

The steps mirror those for sharp curettage for abortion, described in Chapter 9 (p. 136), but differ in that a large-loop postpartum curette is selected. The large loop easily passes through the dilated cervix and provides a sizable surface area to clear the cavity quickly. Moreover, its wide, blunt tip minimizes the risk of fundal perforation.

To begin, the uterine curette is inserted through the cervix and is advanced to the fundus, following the long axis of the corpus. On reaching the fundus, the sharp surface of the curette is positioned to contact the adjacent decidua. Pressure is exerted against the wall as the curette is pulled toward the lower uterine segment. The curette is then redirected to the fundus and positioned immediately adjacent to the path of the first curettage pass. In this fashion, the entire uterine cavity is sequentially and circumferentially curetted. The collected specimen is sent for pathologic evaluation.

Despite such maneuvers, if pieces of placenta remain adhered and are associated with hemorrhage, morbidly adherent placenta is diagnosed clinically. Exploratory laparotomy and hysterectomy are typically indicated, as discussed in Chapter 27 (p. 446).

UTERINE TAMPONADE

■ Uterine Packing

Packing Efficacy

Two major techniques can be employed for intrauterine tamponade to treat postpartum hemorrhage. These are balloon tamponade or uterine packing with gauze. For either, anesthesia requirements are typically less than for dilatation and curettage. Thus, an epidural previously placed for labor or intravenous sedation is suitable in most cases. These methods can be usually completed in a labor room.

Although once popular, uterine packing curiously fell from routine practice during the past 30 to 50 years. Three specific objections to the practice of uterine packing can be identified. The first objection is that the procedure is unphysiologic, which cannot be denied, but this objection can be set aside for lack of specific scientific relevance. The other two objections are the potential for concealed hemorrhage and infection.

Concealed hemorrhage is probably the single most common concern, although it is unlikely if uterine packing is performed properly. In contrast, an improperly packed uterus invites continued hemorrhage. More than 50 years ago, Taylor (1960) cited 15 years of experience and 65,000 deliveries without one example of a postpartum uterus removed purely for atony. The success of the procedure has been described since then by several investigators (Cavanagh, 1961; Hester, 1974; Lester, 1965; Maier, 1993). All these reports suggest that uterine packing may still be useful in select cases. Schmid (2013) packed the uterus with gauze covered with chitosan—a hemostatic agent—in 19 women. They had postpartum hemorrhage secondary to uterine atony, placenta accreta, or anticoagulation. This technique was successful in 18 of the 19 cases. Makosso (2015) described the use in 99 women and cited a success rate of 92 percent. These authors concluded that this was one option to avoid more invasive surgical procedures.

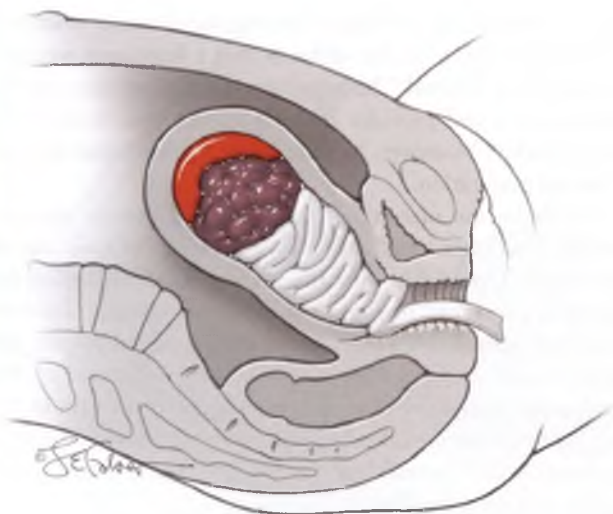


FIGURE 29-2 In this example, the uterine cavity is packed improperly, and the packing material has slipped from the fundal area. As a consequence of this improper technique, the fundal area continues to bleed.

The potential for infection seems logical when the uterine cavity is filled with a foreign body (gauze). Although earlier reports give few details regarding fever, more recent ones specifically state that women who were afebrile when initially packed generally remained so (Druzin, 1989; Maier, 1993). The risk of infection seems to be minimal overall. Caution is advised, however, when considering uterine packing in women who appear to be infected.

Packing Technique

The success of uterine packing is directly related to procedural steps. With atony, packing of the uterus must be uniform,

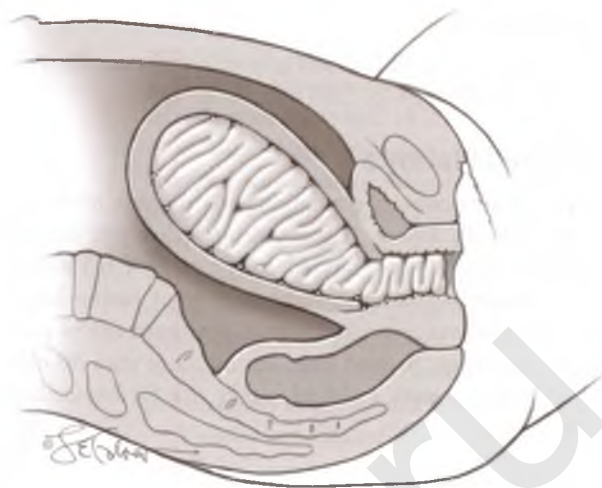


FIGURE 29-4 With proper technique, pressure from the packing is distributed uniformly on all aspects of the uterine cavity.

tight, and complete. Insertion of a wad of packing material in a single thrust into the uterus is ineffective (Fig. 29-2). Instead, authors of successful case series stress technique. That is, the packing material is unrolled and evenly placed in all aspects of the uterine cavity through repeated insertion efforts. As shown, uterine dressing forceps can comfortably reach the more cephalad aspects of the uterus (Fig. 29-3). If more than one roll of material is used, a knot to secure the two rolls is recommended. The gauze is usually supplied in either 5- or 9-yard rolls. Uniform application means that gauze extends completely from side to side and totally fills the uterus from cephalad to caudad (Fig. 29-4). The entire procedure is accomplished in only few minutes by the obstetrician and an assistant.

After packing, the woman must be observed closely. Bleeding through the packing is the most common failure. When this develops, the diagnosis is usually made soon after the procedure. In successfully packed patients, the gauze will become soaked with blood, but external bleeding will be lighter than menstrual flow or normal lochia. In instances of failure and bleeding through the pack, blood loss will approximate that seen before the procedure. Broad-spectrum antibiotics are usually given and are continued as long as the packing material remains in place.

The timing of packing removal is uncertain. Early literature suggested 24 to 36 hours after insertion, but more recent reports have varied in recommendations from 5 to 96 hours. This variation primarily reflects the patient's overall medical condition. For example, of primary importance, the woman should be hemodynamically stable before packing is removed. Removal is generally not painful and bleeding is minimal. The gauze is withdrawn in a gradual layer-by-layer fashion.

Uterine packing should be considered in postpartum hemorrhage related to uterine atony and is suitable for women who have delivered

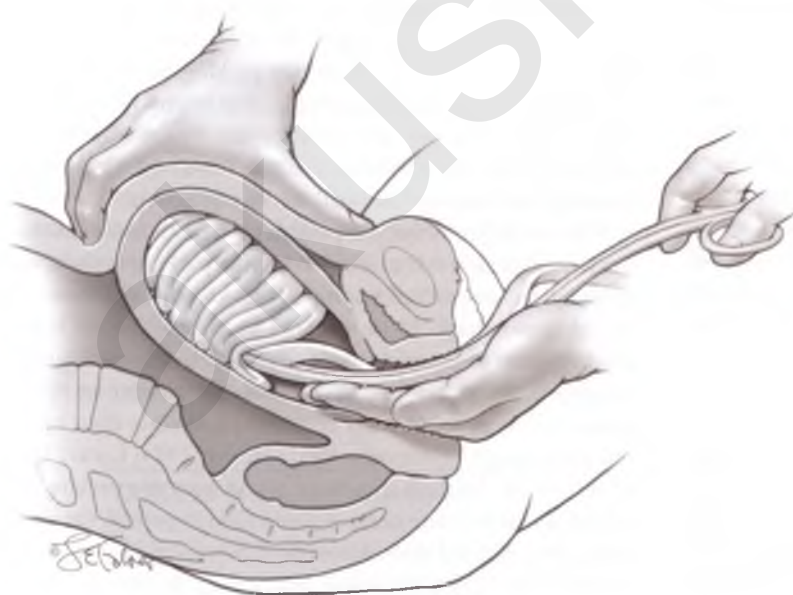


FIGURE 29-3 Correct uterine packing is begun in the fundus. The uterus is steadied by an assistant, while the operator passes gauze to the hand inside the uterine cavity using uterine-dressing forceps. The purpose is to advance packing material uniformly and to completely fill the uterine cavity. More than one roll of gauze is usually required, in which case the ends of the rolls are tied together.

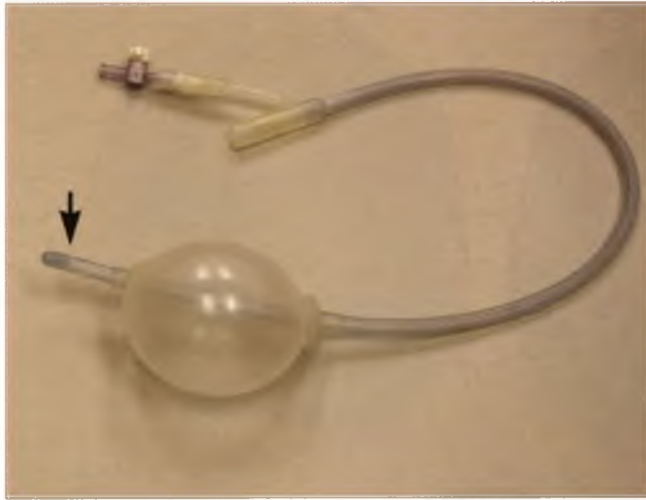

FIGURE 29-5 Bakri balloon device. Its fluted proximal tip (arrow) allows blood collecting above the balloon to drain from the fundus.

either abdominally or vaginally. The procedure has also been used in cases of placenta previa following placenta removal. In these examples, uterine packing can also serve as a temporizing method prior to planned surgical interventions.

There are some instances in which uterine packing likely will not be effective. Distortion of the uterine cavity by leiomyomas, müllerian anomalies, or other conditions may make cavity packing technically unfeasible. Again, other than a temporizing method, packing may be a poor choice in cases with concurrent infection.

■ Balloon Tamponade

Balloon Inflation

The idea of using a balloon for tamponade for postpartum hemorrhage is not new. Early methods used a Foley catheter inflated with 60 to 80 mL of saline. Others have advocated using a Sengstaken-Blakemore or Rusch balloon and even a condom catheter (Georgiou, 2009). The efficacy of these techniques varies, and most of the information regarding their use comes from small observational series or case reports.

Bakri (2001) described the successful use of a silicone, fluid-filled balloon in the treatment of four women with postpartum bleeding from a low-lying placenta or placenta previa. The current device depicted in **Figure 29-5** is a silicone catheter with a balloon capacity up to 500 mL. The balloon is often placed under sonographic guidance, and 300 to 500 mL of saline inflates the balloon (**Fig. 29-6**). The balloon may be displaced or expelled in up to 10 percent of insertions (Wright, 2014). To mitigate this, Matsubara and associates (2015) described a technique of placing ring forceps across the anterior and posterior edges of the cervix to occlude the cervix.

Balloon Efficacy

No randomized trials provide data to evaluate balloon tamponade efficacy. However, numerous case series and observational reports describe its effectiveness and safety. In a recent retrospective study from France, Alouini and coworkers (2015) employed Bakri balloon tamponade in 61 women with severe postpartum hemorrhage. Of these women, 44 (72 percent) had uterine atony. The mean duration of balloon retention was 7 hours, and mean balloon filling was 350 mL. Of these, 63 percent received blood transfusions, and the mean blood loss was 1600 mL, with a range of 1200 to 2250 mL. The balloon was effective in 88 percent of the women. Overall, success of the Bakri balloon in arresting postpartum hemorrhage approximates 68 to 88 percent (Aibar, 2013; Alouini, 2015; Kaya, 2014a; Olsen, 2013).

UTERINE COMPRESSION SUTURES

At the time of laparotomy, one of several procedures can be performed to compress the uterus for control of hemorrhage. Uterine atony is the most common indication for many of these. However, some of these methods can be adapted to control isolated bleeding areas that stem from placenta previa or a morbidly adherent placenta. Many of these pass sutures into the lower uterine segment. Thus, prior to beginning these techniques, bladder location is assessed. Further dissection in the vesicouterine space to develop the bladder flap is often necessary.

■ B-Lynch Method

In 1997, B-Lynch and associates described a method of compression sutures for postpartum hemorrhage as an alternative to hysterectomy in five women. With this technique, a delayed-absorbable suture is placed in the lower uterine segment on one side of the uterus (**Fig. 29-7**). For our example, the uterine right side is stitched first. The suture then loops

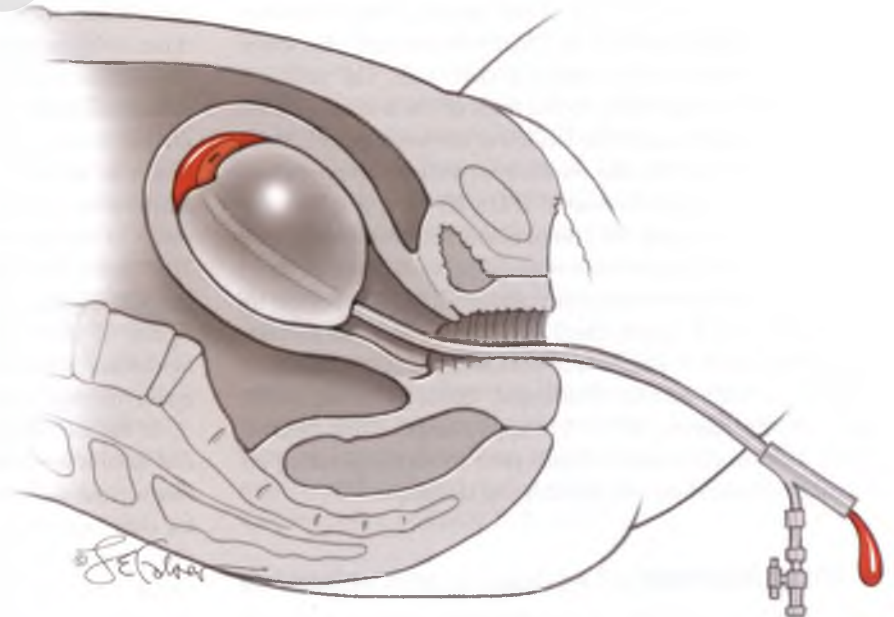


FIGURE 29-6 Uterine cavity compression with the Bakri balloon device.



FIGURE 29-7 The B-Lynch compression-suture technique is illustrated from an anterior view of the uterus in parts A, D, and E and a posterior view in parts B and C. **A.** Beginning below the incision, the needle pierces the lower uterine segment on the maternal right to enter the uterine cavity. The needle exits the cavity above the incision. The suture then loops up and around the fundus to the posterior uterine surface. **B.** The needle pierces the posterior uterine wall on the maternal right to reenter the uterine cavity. The suture then traverses from maternal right to left within the cavity. The needle exits the uterine cavity through the posterior uterine wall. **C.** From the back of the uterus, the suture loops up and around the fundus to the front of the uterus. **D.** The needle pierces the myometrium above the incision to reenter the uterine cavity. The needle exits below the incision. **E.** Sutures are tied below the incision.

over the fundus to the back of the uterus. Here, the same suture is threaded through the myometrium into the lower segment posteriorly to the opposite (left) side. The suture is then looped back anteriorly to the front of the uterus. Finally, the suture passes through the left lower uterine segment. Both suture ends are tied in the midline for uterine compression. We prefer no. 1 polydioxanone (PDS II) as it provides the needed tensile strength for compression yet avoids the tissue cutting that is sometimes seen with polyglactin 10 (Vicryl).

In a personal communication quoted in a 2005 review by El-Hamamy and B-Lynch, there have been “over 1300 successful applications of this technique worldwide.” Success rates vary from 75 to >95 percent (Hackethal, 2008; Hayman, 2002; Kaya, 2014b; Kayem, 2011; Mallappa Saroja, 2010; Nelson, 2007). One would expect efficacy rates to vary depending on the surgical indication and possibly the technique.

■ Other Methods

One proposed weakness of the B-Lynch method is lateral slipping of the suture braces off the fundus. To address this,

three main modifications have been created. First, in several of these revisions, suture travels through both anterior and posterior uterine walls to closely appose and compress the walls. In others, additional horizontal sutures traverse the width of the uterine corpus and have margins that lie outside the vertical braces to stabilize the vertical braces’ position. Finally, some adaptations use an anchoring stitch into the fundal myometrium as the brace suture loops over the fundus (Marasinghe, 2011; Meydanli, 2008; Zheng, 2011). Matsubara and associates (2013) have provided an excellent review with schematic figures of most of these modified methods. Importantly, for hemostatic stitches placed in the lower uterine segment, adequate drainage through the cervix must be maintained.

In the method developed by Cho and coworkers (2000), several sutures are placed to form square outlines across the anterior uterine surface. Selected areas of heavy bleeding are chosen for these squares to avoid closing off the entire uterine cavity so that drainage is adequate. For each square, a no. 1 chromic gut suture travels through the entire uterine wall from the serosa of the anterior wall to the serosa of the posterior wall, and thus passes through the uterine cavity. Both the anterior and posterior

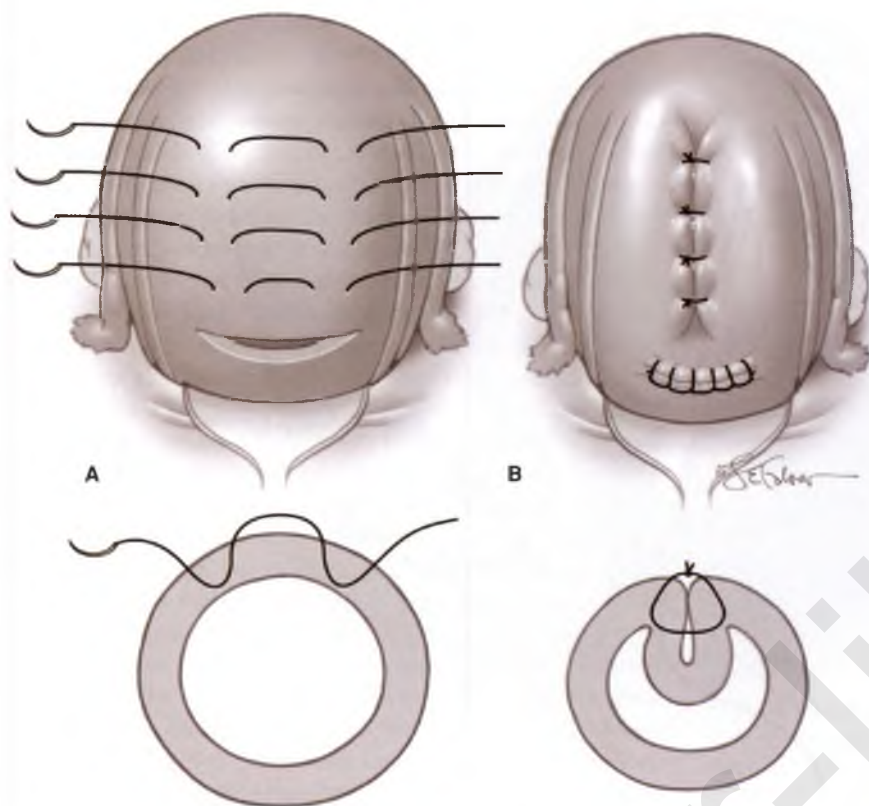


FIGURE 29-8 A. As described by Gilstrap (1999), transverse, interrupted imbricating sutures of no. 1 chromic gut are placed horizontally across the anterior uterine wall. **B.** The uterus is “compressed” by tying the imbricating sutures. The lower two images show a transverse view of these respective surgical steps.

uterine walls are compressed. Advantageously, this technique can also be customized and used solely in the lower uterine segment for heavy bleeding from placenta previa or accreta.

In other modifications, rows of suture are placed horizontally or both horizontally and vertically to compress the uterine corpus and lower uterine segment. These make up the bulk of the restyled methods (Hackethal, 2008; Li, 2015; Makino, 2012; Matsubara, 2013; Ouahba, 2007; Pereira, 2005).

Gilstrap and colleagues (1999) recommended a transverse suture technique for the control of postpartum hemorrhage. For this, interrupted sutures of no. 1 chromic gut travel through the anterior uterine wall as shown in [Figure 29-8](#). Starting at the fundus, serial rows of suture are placed at 3- to 4-cm intervals caudad and include the lower uterine segment. When these individual sutures are tied, the uterus is compressed and gives the appearance of a contracted uterus. Care is taken to not occlude the uterine cavity or obstruct the tubal orifices. Although the sutures do pass through the full thickness of the uterine wall, they do not pass through the cavity to include the opposite uterine wall. At times, it may be necessary to place these sutures posteriorly also. This technique can also be used selectively in the lower segment for bleeding from placenta previa.

■ Compression Suture Complications

Complication rates with compression sutures are low. Uterine cavity synechiae is one potential sequela (Jamard, 2014; Rathat,

2011). Poujade and associates (2011) used hysteroscopy or hysterosalpingogram to examine 15 patients who received uterine compression sutures in the technique described by Hackethal and coworkers (2008). They found that 4 women (27 percent) had developed uterine synechiae. It appears that the risk of uterine synechiae is highest for methods that traverse the uterine cavity. There have also been rare, isolated case reports of uterine ischemic necrosis following placement of compression sutures. The exact incidence is unknown.

Although no large, randomized trials compare the various compression suture techniques, the B-Lynch technique has been used for almost two decades and certainly has passed the test of time. It is relatively easy to perform and appears to be both effective and safe. Further studies are needed that compare the efficacy and safety of this method against other compression suture techniques.

UTERINE ARTERY LIGATION

■ Technique Efficacy

Surgical ligation of the uterine artery has previously been recommended as a uterus-conserving technique for severe postpartum hemorrhage. For most obstetricians, this procedure is easy to perform and is associated with low rates of serious complications. One review addressed more than 200 women undergoing bilateral uterine artery ligation for postcesarean delivery hemorrhage. In this, O’Leary (1986) found the technique to be potentially helpful in 95 percent of cases. Uterine atony was the major indication for vessel ligation. Because this was not a controlled series, the actual efficacy of uterine artery ligation to avert hysterectomy is unknown. In the review by O’Leary, the incidence of significant complications approximated 1 percent and appeared to be associated with operator inexperience. No urologic injury was observed.

We have not been convinced that uterine artery ligation is a reasonable adjunct treatment for uterine atony. We have, however, found it extremely useful for lateral vessel lacerations following transverse hysterotomy incisions. That said, in a study of women with postpartum hemorrhage unresponsive to first-line therapy, Yan and associates (2014) compared three treatments: intrauterine tamponade, B-Lynch compression sutures, and uterine artery ligation. They found no significant differences in blood loss, transfusion rate, and success rate to control bleeding among these three options. This again emphasizes the need for well-designed studies of the various surgical techniques used for severe postpartum hemorrhage.

■ Uterine Artery Ligation Technique

Uterine artery ligation is performed using a large, tapered needle and no. 0 or no. 1 absorbable or delayed-absorbable suture

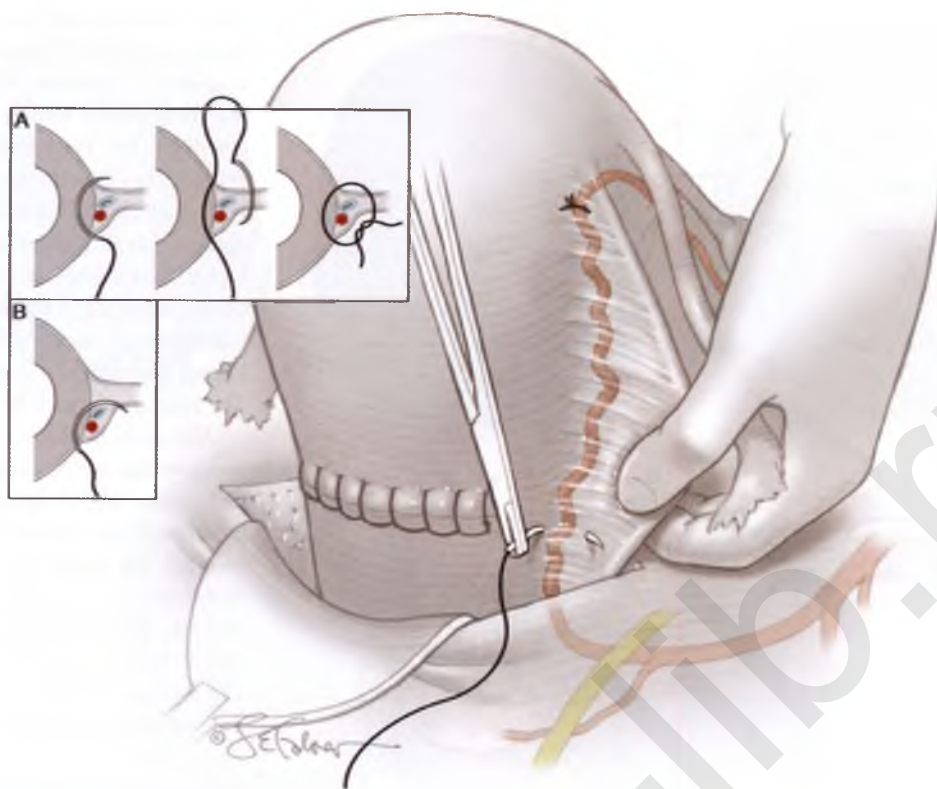


FIGURE 29-9 Uterine artery ligation is performed at the level of the uterine incision. The plexus of veins lateral to the uterus is pulled away from the planned site of suturing. This helps identify avascular sites in the broad ligament for safe needle passage to avoid inadvertent vessel laceration and hematoma formation within the ligament. Rarely, a second ligature is placed at the junction of the uteroovarian ligament and lateral uterine border. **Inset A:** Initially, the needle passes in an anterior-to-posterior direction through lateral uterine wall. The needle is removed from the posterior myometrium and redirected from posterior to anterior through an avascular space in the broad ligament. The suture is then securely tied. **Inset B:** In some instances, the uterine artery is well delineated. Thus, the distance needed for the needle to encompass uterine vessels is short and can be covered in the arc of a single needle pass.

(Fig. 29-9). As this is a vascular ligature that requires only a short suture half-life, we prefer chromic gut. Also, the tendency of chromic not to cut through edematous tissue can be advantageous.

The ligature is placed around the ascending uterine artery and accompanying veins at a level just below the site of a traditional low transverse uterine incision. Prior to needle placement, the adnexa and their vascular plexus are pulled away from the planned site of suturing. This helps avoid inadvertent vessel laceration and hematoma formation within the broad ligament. This tension also clarifies an avascular space in the broad ligament for safe needle passage. Preventively, a retractor blade covers the bladder. Similarly, a malleable retractor can be positioned in the posterior cul-de-sac and in front of the large bowel to avert needlestick injury.

The needle is initially introduced into the myometrium from anterior to posterior approximately 1 cm medial to the lateral margin of the uterus. The needle is removed from the posterior myometrium and redirected from posterior to anterior through an avascular portion of the broad ligament. The suture is then securely tied. Depending on the surgeon's position at the operating table, uterine artery ligation may be more easily performed

by first going anteriorly through an avascular portion of the broad ligament and then posteriorly through the myometrium.

In some instances, the uterine artery is well delineated. Thus, the distance needed for the needle to encompass uterine vessels is short and can be covered in the arc of a single needle pass (see Fig. 29-9, inset B).

Last, anastomoses can lie between branches of the ovarian and uterine arteries in the area of the uteroovarian ligament. Thus, rarely, a second ligature is useful and is placed at the junction of the uteroovarian ligament and lateral uterine border.

INTERNAL ILIAC ARTERY LIGATION

■ Ligation Efficacy

This ligation method has been used for many years to control postpartum hemorrhage (Cunningham, 2014; Joshi, 2007). The anatomy of the internal iliac artery with its anterior and posterior division is detailed in Chapter 3 (p. 40). Branches of the anterior division provide the major blood supply to organs of the female pelvis. Thus, in theory, ligation of the internal iliac artery diminishes the pulse pressure of blood

flow to the uterus (American College of Obstetricians and Gynecologists, 2015).

Indications for this procedure include uterine atony, placenta previa/accreta, uterine rupture, and placental abruption. Boynukalin and colleagues (2013) reported 26 cases of internal iliac artery ligation for severe postpartum hemorrhage secondary to uterine atony, placental abruption, uterine rupture, or placental accrete syndromes. Bleeding was successfully controlled in 20 (77 percent) of these women. Camuzcuoglu and coworkers (2010) described 33 women who underwent internal iliac artery ligation for severe hemorrhage. In their series, 24 women underwent this operation as a primary intervention, and in 18 of these cases (75 percent), hemorrhage was contained. Several other uncontrolled reports have examined the potential efficacy of bilateral internal iliac artery ligation to control obstetric hemorrhage and to avoid hysterectomy. Success rates obviously depend on the skill of the surgeon and the etiology of the hemorrhage. For example, some have found it not particularly useful for uterine atony (Clark, 1985; Joshi, 2007). Moreover, ligation may be far less successful when a uterine or broad ligament laceration is encountered, although occasional efficacy may be seen in these women as well. Namely, in some of such cases, identification and ligation of the lacerated vessels is aided by first performing internal iliac artery ligation. Overall, it would appear that the success rates with internal iliac artery ligation range between 50 and 75 percent (Boynukalin, 2013; Camuzcuoglu, 2010; Cunningham, 2014).

Drawbacks to internal artery ligation are that the procedure is technically difficult and requires skill in retroperitoneal surgery at the pelvic sidewall. In unskilled hands, it can result in significant morbidity and even mortality. In the hands of a surgeon inexperienced with this procedure and without readily available consultation, the patient may be better served by hysterectomy, especially in the presence of profuse, life-threatening hemorrhage. Also, in inexperienced hands, the procedure is time consuming. In a series of 19 women undergoing bilateral internal iliac artery ligation for control of otherwise intractable obstetric hemorrhage, the incidences of ureteral injury and cardiac arrest from blood loss were increased in women undergoing *unsuccessful* ligation followed by hysterectomy compared with those undergoing primary hysterectomy (Clark, 1985). That said, ureteral injuries appear to have been surgically related to the hysterectomy rather than to artery ligation. The authors concluded that the prolonged operative time and extensive blood loss after unsuccessful artery ligation may have led to less meticulous surgical technique during the subsequent hysterectomy, resulting in ureteral injury. Thus, complications associated with unsuccessful internal iliac artery ligation may be related to delay in hysterectomy rather than to the surgical procedure itself.

Reports of term pregnancy after bilateral ligation or embolization of internal iliac arteries attest to the abundant collateral blood supply of the female reproductive tract (Domingo, 2013; Wagaarachchi, 2000). Unilateral artery ligation reduces distal ipsilateral blood flow by only half. A more important clinical effect is an 85-percent diminution of pulse pressure distal to the ligation, thus changing the hemodynamics of the distal arterial tree to one more resembling those of a venous system and amenable to hemostasis via simple clot formation (Burchell, 1968).

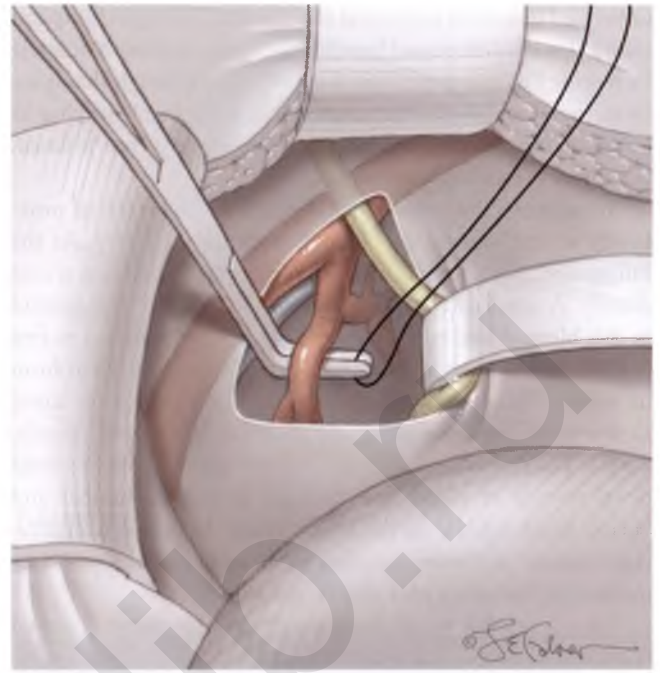


FIGURE 29-10 Ligation of the internal iliac (hypogastric) artery. Here, the retroperitoneum has been opened on the right pelvic sidewall to isolate and retract the ureter from harm. Identification of the common iliac artery allows the internal and external iliac arteries to be differentiated. A Mixer right-angle clamp is inserted beneath the internal iliac artery at a point distal to the artery's posterior division. This minimizes collateral ischemia to structures supplied by that division. The clamp tip moves beneath the artery, and one end of a suture ligature is pulled beneath the internal iliac artery. This tie is then used to ligate the artery. The vessel is doubly ligated but not transected.

Although this extensive collateral circulation generally prevents ischemic complications, central pelvic ischemia, breakdown of perineal skin and episiotomy site, and postischemic lower motor neuron damage with weakness of the lower extremities have been reported as sequelae of internal iliac artery occlusion (Braf, 1979; Greenwood, 1987). Although such complications are rare, the possibility of atypical collateral circulation must be kept in mind when evaluating the appropriateness of this procedure.

■ Ligation Technique

To reach the pelvic sidewall vessels, the retroperitoneal space is sharply entered as shown in [Figure 29-10](#). This may be done either anteriorly between the round and infundibulopelvic ligaments or posteriorly, entering the broad ligament medial to the infundibulopelvic ligament and lateral to the external iliac artery.

Next, the ureter is identified as it runs along the broad ligament's medial leaf. To isolate the ureter at this site, the surgeon bluntly dissects with a finger or suction tip in a sweeping motion from top to bottom along the medial peritoneal leaf to identify and sufficiently mobilize the lateral surface of the ureter.

To free the medial surface, a Babcock clamp grasps the ureter. The tips of a Mixer right-angle clamp are opened and closed parallel to the ureter to develop an avascular space between the

ureter and its medial peritoneal attachment. Through this space, clamp tips are then passed beneath the ureter to grasp a quarter-inch-wide Penrose drain. The drain is pulled through this space to surround and isolate the ureter. This assists in identifying its location throughout the remainder of surgery. Once isolated, the ureter is retracted medially.

The external iliac artery is located and its course traced proximally to the bifurcation of the common iliac artery. At the bifurcation, the internal iliac artery is found and then traced distally. A tonsil suction tip or “peanut” sponge stick is helpful in this blunt dissection. The artery is carefully dissected to free it from surrounding areolar tissue for a distance of 5 cm from its origin. This usually allows vessel ligation at a point distal to the posterior division of the internal iliac artery (Bleich, 2007). Placement at this point permits the surgeon to avoid distal reversal of blood flow through iliolumbar–lumbar and lateral sacral–middle sacral anastomoses. Ischemic complications related to tissues supplied by branches of the posterior division of the artery may also be minimized.

Once a suitable site is chosen, a right-angle clamp is passed beneath the artery. The artery is then double-ligated with non-absorbable suture, no. 0 or no. 1. The artery is not divided.

Four common errors in surgical technique must be avoided during internal iliac artery ligation. The first is misidentification and ligation of the external iliac artery. This is a serious complication, which, if not recognized or corrected, will lead to ischemia and possible loss of the leg. Careful dissection and identification of anatomic landmarks including both external and internal iliac arteries and palpation of femoral pulses following internal iliac artery ligation are essential.

A second potential complication involves laceration of the internal or external iliac veins. These thin-walled structures lie immediately adjacent to the arteries and are easily lacerated if retroperitoneal dissection is too vigorous. They can also be punctured during passage of the right-angle clamp beneath the internal iliac artery. Such lacerations are often difficult to repair and may result in massive hemorrhage. Passage of the right-angle clamp both in a lateral-to-medial direction *and* in a medial-to-lateral path has been advocated to avert vein laceration. No data exist to support one direction as superior. Perhaps more important is keeping the tip of the clamp against the artery when passing beneath it and elevating the artery.

A third serious complication is ureteral injury. This may be avoided by properly identifying the ureter and retracting it immediately upon entering the retroperitoneal space.

Finally, a retroperitoneal hematoma may result if hemostasis in the retroperitoneal space has been inadequate or if the patient has a coagulopathy. Meticulous surgical technique is essential. Small hemostatic clips, manual pressure with a laparotomy sponge, or topical application of hemostatic agents may be helpful in controlling small bleeding vessels within the retroperitoneal space. Possible topical hemostats are listed in Table 26-4 (p. 430). These steps are often superior to suture ligatures or extensive electrocauterization.

The recent development of radiologic techniques for arterial embolization and the effectiveness of synthetic uterotonic agents for cases of uterine atony have combined to make internal iliac artery ligation an infrequently employed technique.

Few individuals currently completing residency training programs in the United States are sufficiently facile in this operation to complete it safely under emergency conditions. Thus, although ligation may be effective in select cases, its performance is never mandated by standard of care and is, in fact, infrequently justified. The risk versus benefit ratio of this procedure in cases of obstetric hemorrhage is probably acceptable only if three criteria are met: the woman is hemodynamically stable, future childbearing is an overwhelming concern for the patient, and an experienced operator is available. Otherwise, hysterectomy may be the preferred procedure.

ANGIOGRAPHIC EMBOLIZATION

■ Embolization Efficacy

In select cases, angiographic embolization can provide an alternative to exploratory laparotomy or internal iliac artery ligation for the control of postpartum hemorrhage. Efficacy rates vary, but success rates up to 90 percent have been reported (Bodner, 2006; Lee, 2012; Poujade, 2012; Sentilhes, 2009; Soyer, 2015). Pelage and colleagues (2014) reviewed the literature on uterine arterial embolization for postpartum hemorrhage. The success rate was 85 to 100 percent. The complication rate was 5 percent. In another review of 117 women who underwent pelvic arterial embolization for postpartum hemorrhage, Cheong and associates (2014) noted a clinical success rate of 88 percent. In more than half the cases, the indication was uterine atony. In addition, angiographic embolization can be elected to halt associated bleeding in cases of postpartum vaginal wall hematomas, abdominal pregnancy, retroperitoneal hematomas, and miscellaneous types of postpartum and postcesarean hysterectomy hemorrhage (Chin, 1989; Gilbert, 1992; Greenwood, 1987; Jander, 1980; Kivokoski, 1988; Smith, 1977). At our institution, these latter indications are the predominant reason to employ embolization.

■ Embolization Technique

Using a percutaneous approach under local anesthesia, arterial access to the femoral artery is obtained. Following vessel catheterization, an aortogram is performed to identify the anatomy of the pelvic vessels and identify specific bleeding sites. The catheter subsequently enters the internal iliac artery using fluoroscopic guidance. A specific bleeding site is identified by the appearance of a “blush” or pooling of contrast medium in an extravascular site. The bleeding vessel is then selectively catheterized and occluded. In general, large vessels require coils, whereas smaller vessels can be treated with microsphere particles, gelatin sponge, or microcoils. Hemostasis can then be confirmed with fluoroscopy. Multiple vessels, including bleeding collaterals, may be occluded in this manner. Alternatively, the anterior division of the internal iliac artery itself may be embolized.

Various agents are available for angiographic embolization. The choice depends on the size of vessel to be occluded and whether short-term or permanent occlusion is desired. Metal wire coils are steel or platinum and contain numerous attached material fibers to promote thrombus formation. These are available in various sizes and provide permanent occlusion of

large vessels. More commonly, small particles of Gelfoam are used to promote short-term (10- to 30-day) occlusion of small, bleeding arterial branches. More recently, Pelage and coworkers (2014) recommended using gelatin sponge pledgets rather than gelatin sponge slurry or powder. As comparison, surgical internal iliac artery ligation acts principally via a general reduction in pulse pressure, whereas angiographic embolization allows direct occlusion of one or more specific bleeding vessels. This technique also avoids the need for general or conduction anesthesia and the morbidity associated with surgical exploration.

The primary disadvantage of the angiographic technique involves the usual need to transfer a bleeding patient to the radiology suite. Thus, such techniques are not useful in settings of rapid life-threatening hemorrhage, in which a direct surgical approach is mandated. Moreover, because the femoral artery must be punctured to insert the catheter during embolization, this is not a suitable choice for women with comorbid coagulopathy.

Complications are uncommon but may be serious. Several authors have described ischemic uterine necrosis. In the large series by Cheong and associates (2014), 3 of the 117 women had uterine necrosis requiring hysterectomy. In a review of the literature regarding uterine necrosis following pelvic arterial embolization, Poujade and colleagues (2013) found 19 cases of necrosis. The mean time interval from embolization to necrosis was 21 days. The main symptoms were fever, bleeding, and abdominal pain. Massive buttock necrosis can also be a rare complication of internal iliac artery embolization (Al-Thunyan, 2012; Gilleard, 2012; Palacios-Jaraquemada, 2012). In two of the reports, embolization resulted in paraplegia (Al-Thunyan, 2012; Palacios-Jaraquemada, 2012). Fertility and subsequent pregnancy rates do not appear to be severely harmed by pelvic arterial embolization used for postpartum hemorrhage (Doumouchtsis, 2014; Sentilhes, 2010).

TRANSVAGINAL PELVIC PRESSURE PACK

In cases of placenta percreta or abdominal pregnancy, bleeding may be diffuse and difficult to control with either suture placement or electrosurgical coagulation. Following postpartum hysterectomy, similar diffuse bleeding may be encountered, especially if the course is further complicated by dilutional coagulopathy. Under these circumstances, a pelvic pressure pack may provide lifesaving hemostasis. Logothetopoulos originally described the use of a pelvic pressure pack in 1926. Several reports since that time have described its successful use for obstetric pelvic hemorrhage (Parenta, 1962; Robie, 1990).

Hallek and coworkers (1991) described one technique of pressure pack construction: a sterile plastic x-ray cassette bag or plastic instrument tray cover is filled with eight rolls of 4- to 5-inch gauze tied end-to-end. Alternately, several cloth laparotomy sponges may be tied together. The gauze- or cloth-filled bag is then placed in the pelvis with the opening of the bag and protruding end of the packing material extending through the vaginal cuff or a separate cul-de-sac incision. This creates a mushroom-shaped pack (Fig. 29-11). This form of pelvic pack is also known as a “parachute pack.” The protruding “stalk” is then tied with intravenous tubing attached directly to a 1-L bag of solution, which is hung over the foot of the bed (Fig. 29-12). The pack is removed 24 to 48 hours later, after the woman is clinically stable.

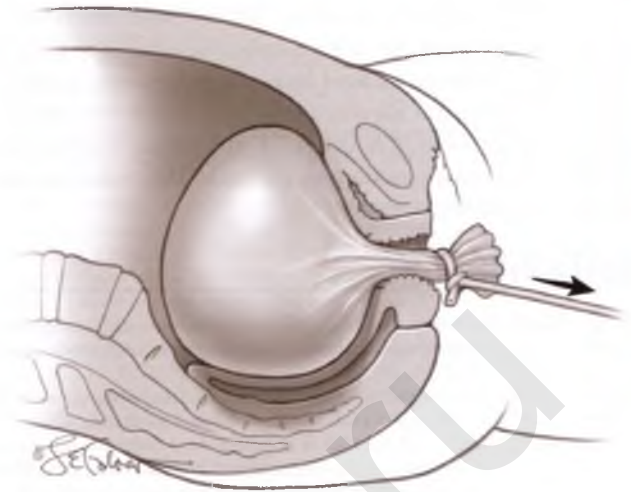


FIGURE 29-11 Transvaginal pressure pack in place.

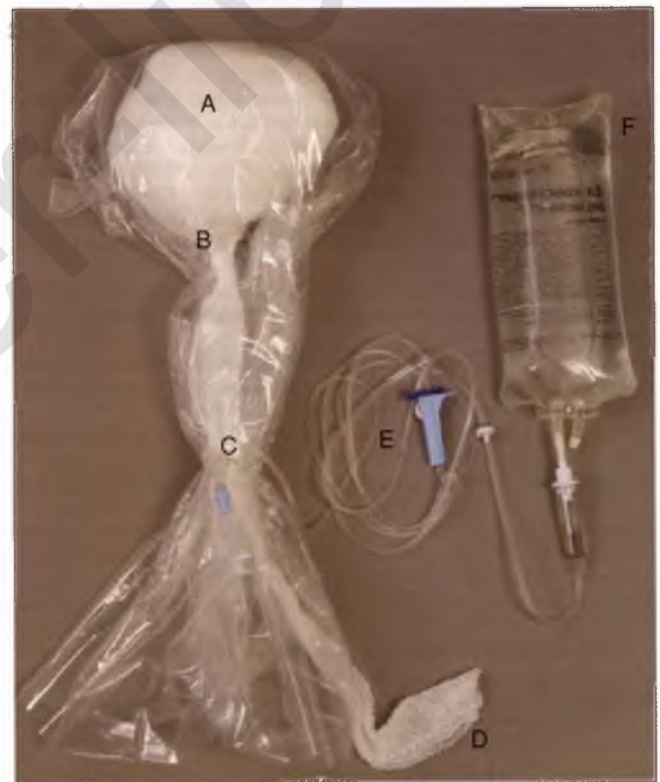

FIGURE 29-12 Assembled items needed to construct a pelvic pressure pack to control hemorrhage. The sterile cover drape of an x-ray cassette (plastic bag) is filled with gauze rolls tied end-to-end. The length of gauze is then folded into a ball (A) and placed within the cassette bag in such a way that the gauze can be unwound eventually with traction on the tail (D). Intravenous tubing (E) is tied to the exiting part of the neck (C) and connected to a 1-liter bag or other suitable weight (F). Once in place, the ball-shaped gauze pack fills the pelvis to tamponade vessels and the narrow upper neck (B) passes to exit the vagina (C). The intravenous bag is suspended off the foot of the bed to sustain pressure by the gauze pack on bleeding sites. (Reproduced with permission from Cunningham FG, Leveno KJ, Bloom SL, et al (eds): *Obstetrical hemorrhage*. In *Williams Obstetrics*, 24th ed. New York, McGraw-Hill Education, 2014.)

Charoenkwan and coworkers (2014) have described a unique use for the Bakri balloon device for a pressure pack in three women with pelvic floor hemorrhage following hysterectomy. The device was filled to a volume of 400 to 550 mL and left in place for 24 to 30 hours. A 1-L intravenous fluid bag was used for continuous traction on the pack. This technique was successful in all three women.

REFERENCES

- Abdul-Kadir R, McLintock C, Ducloy AS, et al: Evaluation and management of postpartum hemorrhage: consensus from an international expert panel. *Transfusion* 54(7):1756, 2014
- Aibar L, Aguilar MT, Puertas A, et al: Bakri balloon for the management of postpartum hemorrhage. *Acta Obstet Gynecol Scand* 92(4):465, 2013
- Alexander JM, Sarode R, McIntire DD, et al: Whole blood in the management of hypovolemia due to obstetric hemorrhage. *Obstet Gynecol* 113(6):1320, 2009
- Alouini S, Bedouet L, Ramos A, et al: Bakri balloon tamponade for severe postpartum hemorrhage: efficiency and fertility outcomes. *J Gynecol Obstet Biol Reprod (Paris)* 44(2):171, 2015
- Al-Thunyan A, Al-Meshal O, Al-Hussainan H, et al: Buttock necrosis and paraplegia after bilateral internal iliac artery embolization for postpartum hemorrhage. *Obstet Gynecol* 120(2 Pt 2):468, 2012
- American College of Obstetricians and Gynecologists: Postpartum hemorrhage. Practice Bulletin No. 76, October 2006, Reaffirmed 2015
- Bakri YN, Amri A, Abdul Jabbar F: Tamponade-balloon for obstetrical bleeding. *Int J Gynaecol Obstet* 74(2):139, 2001
- Berg CJ, Harper MA, Atkinson SM, et al: Preventability of pregnancy-related deaths: results of a state-wide review. *Obstet Gynecol* 106(6):1228, 2005
- B-Lynch C, Coker A, Lawal AH, et al: B-Lynch surgical technique for the control of massive postpartum haemorrhage: an alternative to hysterectomy? Five cases reported. *BJOG* 104(3):372, 1997
- Bleich AT, Rahn DD, Wieslander CK, et al: Posterior division of the internal iliac artery: anatomic variations and clinical applications. *Am J Obstet Gynecol* 197(6):658.e1, 2007
- Bodner LJ, Noshier JL, Gribbin C, et al: Balloon-assisted occlusion of the internal iliac arteries in patients with placenta accreta/percreta. *Cardiovasc Intervent Radiol* 29(3):354, 2006
- Boynukalin FK, Boyar H, Gormus H, et al: Bilateral hypogastric artery ligation in emergency setting for intractable postpartum hemorrhage: a secondary care center experience. *Clin Exp Obstet Gynecol* 40(1):85, 2013
- Braf ZF, Knootz WW Jr: Gangrene of bladder. Complication of hypogastric artery embolization. *Urology* 9(6):670, 1979
- Burchell RC: Physiology of internal iliac artery ligation. *J Obstet Gynaecol Br Commonw* 75(6):642, 1968
- Camuzcuoglu H, Toy H, Vural M, et al: Internal iliac artery ligation for severe postpartum hemorrhage and severe hemorrhage after postpartum hysterectomy. *J Obstet Gynaecol Res* 36(3):538, 2010
- Cavanagh D (ed): *Obstetrical Emergencies*. Springfield, Charles C. Thomas, 1961
- Charoenkwan K: Effective use of the Bakri postpartum balloon for posthysterectomy pelvic floor hemorrhage. *Am J Obstet Gynecol* 210(6):586, 2014
- Cheong JY, Kong TW, Son JH, et al: Outcome of pelvic arterial embolization for postpartum hemorrhage: a retrospective review of 117 cases. *Obstet Gynecol Sci* 57(1):17, 2014
- Chestnut DH, Eden RD, Gall SA, et al: Peripartum hysterectomy: a review of cesarean and postpartum hysterectomy. *Obstet Gynecol* 65(3):365, 1985
- Chin HG, Scott DR, Resnik R, et al: Angiographic embolization of intractable puerperal hematomas. *Am J Obstet Gynecol* 160(2):434, 1989
- Cho JH, Jun HS, Lee CN: Hemostatic suturing technique for uterine bleeding during cesarean delivery. *Obstet Gynecol* 96(1):129, 2000
- Clark SL: Strategies for reducing maternal mortality. *Semin Perinatol* 36(1):42, 2012
- Clark SL, Koonings P, Phelan JP: Placenta accreta and previous cesarean section. *Obstet Gynecol* 66(1):89, 1985
- Clark SL, Yeh SY, Phelan JP, et al: Emergency hysterectomy for the control of obstetric hemorrhage. *Obstet Gynecol* 64(3):376, 1984
- Combs CA, Murphy EL, Laros RK Jr: Factors associated with hemorrhage in cesarean deliveries. *Obstet Gynecol* 77(1):77, 1991a
- Combs CA, Murphy EL, Laros RK Jr: Factors associated with postpartum hemorrhage with vaginal birth. *Obstet Gynecol* 77(1):69, 1991b
- Creanga AA, Berg CJ, Syverson C, et al: Pregnancy-related mortality in the United States, 2006–2010. *Obstet Gynecol* 125(1):5, 2015
- Cunningham FG, Leveno KJ, Bloom SL, et al (eds): *Obstetrical hemorrhage*. In *Williams Obstetrics*, 24th ed. New York, McGraw-Hill Education, 2014
- Cunningham FG, Nelson DB: Disseminated intravascular coagulation syndromes in obstetrics. *Obstet Gynecol* 126(5):999, 2015
- D'Alton ME, Main EK, Menard MK, et al: The National Partnership for Maternal Safety. *Obstet Gynecol* 123(5):973, 2014
- Dilla AJ, Waters JH, Yazer MH: Clinical validation of risk stratification criteria for peripartum hemorrhage. *Obstet Gynecol* 122(1):120, 2013
- Domingo S, Perales-Puchalt A, Soler I, et al: Clinical outcome, fertility and uterine artery Doppler scans in women with obstetric bilateral internal iliac artery ligation or embolization. *J Obstet Gynaecol* 33(7):701, 2013
- Doumouchtsis SK, Nikolopoulos K, Talaulikar V, et al: Menstrual and fertility outcomes following the surgical management of postpartum haemorrhage: a systematic review. *BJOG* 121(4):382, 2014
- Druzin ML: Packing of lower uterine segment for control of post cesarean bleeding in instances of placenta previa. *Surg Gynecol Obstet* 169:543, 1989
- El-Hamamy E, B-Lynch C: A worldwide review of the uses of the uterine compression suture techniques as alternative to hysterectomy in the management of severe post-partum haemorrhage. *J Obstet Gynaecol* 25(2):143, 2005
- Gahres EE, Albert SN, Dodek SM: Intrapartum blood loss measured with CR51-tagged erythrocytes. *Obstet Gynecol* 19:455, 1962
- Georgiou C: Balloon tamponade in the management of postpartum haemorrhage: a review. *BJOG* 116(6):748, 2009
- Gilbert L, Porter W, Brown VA: Postpartum hemorrhage: a continuing problem. *BJOG* 94(1):67, 1987
- Gilbert WM, Moore TR, Resnik R, et al: Angiographic embolization in the management of hemorrhage complications of pregnancy. *Am J Obstet Gynecol* 166(2):493, 1992
- Gilleard O, Stammers J, Ali F: Gluteal necrosis following pelvic fracture and bilateral internal iliac embolization: reconstruction using a transposition flap based on the lumbar artery perforators. *Int J Surg Case Rep* 3(2):86, 2012
- Gilstrap LC 3rd, Hauth JC, Hankins GD, et al: Effect of type of anesthesia blood loss at cesarean section. *Obstet Gynecol* 69(2 Pt 1):328, 1987
- Gilstrap LC 3rd, Ramin SM: Postpartum hemorrhage. *Clin Obstet Gynecol* 37(4):824, 1994
- Gilstrap LC 3rd, Ramin SM, Yeomans E: Transverse sutures for postpartum hemorrhage. Personal communication, 1999
- Greenwood LH, Glickman MG, Schwartz PE, et al: Obstetric and nonmalignant gynecologic bleeding: treatment with angiographic embolization. *Radiology* 164:155, 1987
- Hackethal A, Brueggmann D, Oehmke F, et al: Uterine compression U-sutures in primary postpartum hemorrhage after Cesarean section: fertility preservation with a simple and effective technique. *Hum Reprod* 23(1):74, 2008
- Hallek M, Dildy GA, Hurley TJ, et al: Transvaginal pressure pack for life-threatening pelvic hemorrhage secondary to placenta accreta. *Obstet Gynecol* 78(5 Pt 2):938, 1991
- Hayman RG, Arulkumaran S, Steer PJ: Uterine compression sutures: surgical management of postpartum hemorrhage. *Obstet Gynecol* 99(3):502, 2002
- Hernandez JS, Alexander JM, Sarode R, et al: Calculated blood loss in severe obstetric hemorrhage and its relation to body mass index. *Am J Perinatol* 29(7):557, 2012
- Hester JD: Postpartum hemorrhage and reevaluation of uterine packing. *Obstet Gynecol* 45(5):501, 1974
- Hofmeyr GJ, Abdel-Aleem H, Abdel-Aleem MA: Uterine massage for preventing postpartum haemorrhage. *Cochrane Database Syst Rev* 7: CD006431, 2013
- Jamard A, Turck M, Chéret-Benoist A, et al: [Risk of uterine synechiae following uterine compression sutures during postpartum haemorrhage]. [French]. *Gynecol Obstet Fertil* 42(10):681, 2014
- Jander HP, Russinovich NA: Transcatheter Gelfoam embolization in abdominal, retroperitoneal, and pelvic hemorrhage. *Radiology* 136(2):337, 1980
- Joshi VM, Otiv SR, Majumder R, et al: Internal iliac artery ligation for arresting postpartum haemorrhage. *BJOG* 114(3):356, 2007
- Kaya B, Tuten A, Daglar K, et al: Balloon tamponade for the management of postpartum uterine hemorrhage. *J Perinat Med* 42(6):745, 2014a
- Kaya B, Tuten A, Daglar K, et al: B-Lynch uterine compression sutures in the conservative surgical management of uterine atony. *Arch Gynecol Obstet* 291(5):1005-2014b
- Kayem G, Kurinczuk JJ, Alfirevic Z, et al: Uterine compression sutures for the management of severe postpartum hemorrhage. *Obstet Gynecol* 117(1):14, 2011
- Kivokoski AI, Martin C, Weyman P, et al: Angiographic arterial embolization to control hemorrhage in abdominal pregnancy: a case report. *Obstet Gynecol* 71(3 Pt 2):456, 1988

- Klapholz H: Blood transfusion in contemporary obstetric practice. *Obstet Gynecol* 75(6):940, 1990
- Kramer MS, Berg C, Abenham H, et al: Incidence, risk factors, and temporal trends in severe postpartum hemorrhage. *Am J Obstet Gynecol* 209(5):449.e1, 2013
- Lee HY, Shin JH, Kim J, et al: Primary postpartum hemorrhage: outcome of pelvic arterial embolization in 251 patients at a single institution. *Radiology* 264(3):903, 2012
- Lester WM, Bartholomew RA, Colvin ED, et al: Reconsideration of the uterine pack in postpartum hemorrhage. *Am J Obstet Gynecol* 93: 321, 1965
- Li GT, Li XF, Liu YJ, et al: Symbol "&" suture to control atonic postpartum hemorrhage with placenta previa accreta. *Arch Gynecol Obstet* 291(2):305, 2015
- Logothetopoulos K: Eine absolut sichere Blutstillungsmethode bei vaginalen und abdominalen gynakologischen Operationen. *Zentralbl Gynakol* 50:3202, 1926
- Lyndon A, Lagrew D, Shields L, et al: Improving health care response to obstetric hemorrhage version 2.0. A California quality improvement toolkit. Stanford, California Maternal Quality Care Collaborative, 2015
- Magann EF, Evans S, Chauhan SP, et al: The length of the third stage of labor and the risk of postpartum hemorrhage. *Obstet Gynecol* 105(2):290, 2005
- Maier RC: Control of postpartum hemorrhage with uterine packing. *Am J Obstet Gynecol* 169(2 Pt 1):317, 1993
- Makino S, Tanaka T, Yorifuji T, et al: Double vertical compression sutures: a novel conservative approach to managing post-partum haemorrhage due to placenta praevia and atonic bleeding. *Aust N Z J Obstet Gynaecol* 52:290, 2012
- Makosso M, Koné AB, Rossignol M, et al: [Uterine packing efficacy in postpartum hemorrhage. About 99 cases. The experience of a French hospital level 2 A]. [French]. *J Gynecol Obstet Biol Reprod (Paris)* 44(1):53, 2015
- Mallappa Saroja CS, Nankani A, El-Hamamy E: Uterine compression sutures, an update: review of efficacy, safety and complications of B-Lynch suture and other uterine compression techniques for postpartum haemorrhage. *Arch Gynecol Obstet* 281(4):581, 2010
- Marasinghe JP, Condous G, Seneviratne HR, et al: Modified anchored B-Lynch uterine compression suture for postpartum bleeding with uterine atony. *Acta Obstet Gynecol Scand* 90:280, 2011
- Matsubara S, Baba Y, Takahashi H: Preventing Bakri balloon from sliding out during "holding the cervix": "fishing for the balloon shaft" technique (Matsubara). *Acta Obstet Gynecol Scand* 94(8):910, 2015
- Matsubara S, Yano H, Ohkuchi A, et al: Uterine compression sutures for postpartum hemorrhage: an overview. *Acta Obstet Gynecol Scand* 92(4):378, 2013
- Mehrabadi A, Liu S, Bartholomew S, et al: Maternal Health Study Group of the Canadian Perinatal Surveillance System. Temporal trends in postpartum hemorrhage and severe postpartum hemorrhage in Canada from 2003 to 2010. *J Obstet Gynaecol Can* 36(1):21, 2014
- Meydanli MM, Türkçüoğlu I, Engin-Ustün Y, et al: Meydanli compression suture: new surgical procedure for postpartum hemorrhage due to uterine atony associated with abnormal placental adherence. *J Obstet Gynaecol Res* 34:964, 2008
- Nelson WL, O'Brien JM. The uterine sandwich for persistent uterine atony: combining the B-Lynch compression suture and an intrauterine Bakri balloon. *Am J Obstet Gynecol* 196(5):e9, 2007
- Newton M, Mosey LM, Egli GE, et al: Blood loss during and immediately after delivery. *Obstet Gynecol* 17:9, 1961
- O'Leary JA: Stop OB hemorrhage with uterine artery ligation. *Contemp Ob/Gyn* 28:13, 1986
- Olsen R, Reisner DP, Benedetti TJ, et al: Bakri balloon effectiveness for postpartum hemorrhage: a "real world experience." *J Matern Fetal Neonatal Med* 26(17):1720, 2013
- Ouahba J, Piketty M, Huel C, et al: Uterine compression sutures for postpartum bleeding with uterine atony. *BJOG* 114:619, 2007
- Palacios-Jaraquemada JM: Buttock necrosis and paraplegia after bilateral internal iliac artery embolization for postpartum hemorrhage. *Obstet Gynecol* 120(5):1210, 2012
- Parenta JT, Dlugi H, Weingold AB: Pelvic hemostasis: a new technic and pack. *Obstet Gynecol* 19:218, 1962
- Pelaje JP, Fohlen A, Le Pennec V: Role of arterial embolization in the management of postpartum hemorrhage. *J Gynecol Obstet Biol Reprod (Paris)* 43(10):1063, 2014
- Pereira A, Nunes F, Pedrosa S, et al: Compressive uterine sutures to treat postpartum bleeding secondary to uterine atony. *Obstet Gynecol* 106:569, 2005
- Pfizer: Hemabate, carboprost tromethamine injection: prescribing information. 2014. Available at: <http://labeling.pfizer.com/showlabeling.aspx?id=598>. Accessed February 7, 2016
- Poujade O, Ceccaldi PF, Davitian C, et al: Uterine necrosis following pelvic arterial embolization for post-partum hemorrhage: review of the literature. *Eur J Obstet Gynecol Reprod Biol* 170(2):309, 2013
- Poujade O, Grossetti A, Mouguel L, et al: Risk of synechia following uterine compression sutures in the management of major postpartum haemorrhage. *BJOG* 118(4):433, 2011
- Poujade O, Zappa M, Letendre I, et al: Predictive factors for failure of pelvic arterial embolization for postpartum hemorrhage. *Int J Gynaecol Obstet* 117(2):119, 2012
- Pritchard JA, Baldwin RM, Dickey JC, et al: Blood volume changes in pregnancy and the puerperium. II. Red blood cell loss and changes in apparent blood volume during and following vaginal delivery, cesarean section, and cesarean section plus total hysterectomy. *Am J Obstet Gynecol* 84(10):1271, 1962
- Rathat G, Do Trinh P, Mercier G, et al: Synechia after uterine compression sutures. *Fertil Steril* 95(1):405, 2011
- Robie GF, Morgan MA, Payne GG, et al: Logothetopoulos pack for the management of uncontrollable postpartum hemorrhage. *Am J Perinatol* 7(4):327, 1990
- Rocha Filho EA, Costa ML, Cecatti JG, et al: Brazilian Network for Surveillance of Severe Maternal Morbidity Study Group: severe maternal morbidity and near miss due to postpartum hemorrhage in a national multicenter surveillance study. *Int J Gynaecol Obstet* 128(2):131, 2015
- Schmid BC, Rezniczek GA, Rolf N, et al: Uterine packing with chitosan-covered gauze for control of postpartum hemorrhage. *Am J Obstet Gynecol* 209(3):225, 2013
- Secher NJ, Arnso P, Wallin L: Haemodynamic effects of oxytocin (Syntocinon) and methylergometrine (Methergine) on the systemic and pulmonary circulations of pregnant anaesthetized women. *Acta Obstet Gynecol Scand* 57(2):97, 1978
- Sentilhes L, Gromez A, Clavier E, et al: Fertility and pregnancy following pelvic arterial embolization for postpartum haemorrhage. *BJOG* 117(1):84, 2010
- Sentilhes L, Gromez A, Clavier E, et al: Predictors of failed pelvic arterial embolization for severe postpartum hemorrhage. *Obstet Gynecol* 113(5):992, 2009
- Slater GI, Vladeck BC, Bassin R, et al: Sequential changes in distribution of cardiac output in hemorrhagic shock. *Surgery* 73(5):714, 1973
- Smith DC, Wyatt JF: Embolization of the hypogastric arteries in the control of massive vaginal hemorrhage. *Obstet Gynecol* 49(3):317, 1977
- Soyer P, Dohan A, Dautry R, et al: Transcatheter arterial embolization for postpartum hemorrhage: indications, technique, results, and complications. *Cardiovasc Intervent Radiol* 38(5):1068, 2015
- Taylor ES: Intrapartum and postpartum hemorrhage. *Clin Obstet Gynecol* 3:646, 1960
- Tunçalp Ö, Hofmeyr GJ, Gülmezoglu AM: Prostaglandins for preventing postpartum haemorrhage. *Cochrane Database Syst Rev* 8: CD000494, 2012
- Wagaarachchi PT, Fernando L: Fertility following ligation of internal iliac arteries for life-threatening obstetric haemorrhage: case report. *Hum Reprod* 15(6):1311, 2000
- Wright CE, Chauhan SP, Abuhamad AZ: Bakri balloon in the management of postpartum hemorrhage: a review. *Am J Perinatol* 31(11):957, 2014
- Yan JY, Zhou ZM, Xu X, et al: Risk factors and surgical interventions associated with primary postpartum haemorrhage unresponsive to first-line therapies. *J Obstet Gynaecol* 34(7):588, 2014
- Zheng J, Xiong X, Ma Q, et al: A new uterine compression suture for postpartum haemorrhage with atony. *BJOG* 118:370, 2011

Genital Tract Lacerations and Hematomas

INJURIES TO THE BIRTH CANAL	482
PUERPERAL HEMATOMAS	484
UTERINE RUPTURE	487

Postpartum hemorrhage caused by trauma to the birth canal is obvious in most cases. Important exceptions are unrecognized accumulations of blood within the uterus or vagina as well as uterine rupture with intraperitoneal bleeding. Initial assessment strives to differentiate uterine atony from genital tract lacerations. An understanding of predisposing risk factors shown in [Table 30-1](#) can aid this discrimination. It is axiomatic that persistent bleeding despite a firm, well-contracted uterus suggests that hemorrhage most likely is from lacerations. Bright red blood further suggests arterial bleeding. To confirm that lacerations are a source of bleeding, careful inspection of the vagina, cervix, and uterus is essential.

Sometimes bleeding may be caused by both atony and trauma, especially after forceps- or vacuum-assisted vaginal delivery. Importantly, if significant bleeding follows these types of deliveries, then the cervix and vagina should be carefully examined to identify lacerations. This is easier if epidural or spinal analgesia has been placed for labor and delivery. If no lower genital tract lacerations are found and the uterus is contracted yet supracervical bleeding persists, then manual exploration of the uterus is done to exclude a uterine tear. This is also done routinely after internal podalic version and breech extraction.

INJURIES TO THE BIRTH CANAL

■ Vulvovaginal Lacerations

Childbirth is invariably associated with some trauma to the birth canal, which includes the uterus and cervix, vagina, and

perineum. Injuries sustained during labor and delivery range from minor mucosal abrasions to lacerations that create life-threatening hemorrhage or hematomas.

Small tears of the anterior vaginal wall near the urethra are relatively common even after the most uncomplicated deliveries, especially in nulliparas. They are often superficial with little or no bleeding, and suture repair is usually not necessary. That said, minor superficial perineal and vaginal lacerations occasionally require sutures for hemostasis. A fine-gauge absorbable suture such as 4-0 gauge plain or chromic gut is suitable. Adequate analgesia is necessary to repair such lesions.

Deeper perineal lacerations are usually accompanied by varying degrees of injury to the outer third of the vaginal vault. Some extend to involve the anal sphincter or varying depths of the vaginal walls. The frequency of third- and fourth-degree lacerations in more than 87,000 deliveries from the Consortium on Safe Labor database is shown in [Table 30-2](#). Some factors associated with an increased frequency of lacerations are also shown in the table. One of these is parity, and the frequency of these perineal lacerations was 5.7 percent in nulliparas but only 0.6 percent in multiparas. Lacerations were also more common

TABLE 30-1. Risk Factors for Hemorrhage from Genital Tract Lacerations with Childbirth

Episiotomy
Operative delivery—vacuum and forceps
Cesarean delivery or hysterectomy
Uterine rupture
Obesity
Small woman
Macrosomic fetus
Shoulder dystocia
Rapid labor and delivery
Coagulation defects

TABLE 30-2. Frequency of Third- or Fourth-Degree and Cervical Lacerations in an Obstetric Population from the Consortium on Safe Labor

Maternal Characteristic	Laceration (%)	
	3rd or 4th Degree	Cervical
Total population	2516/87,867 (3%)	536/71,170 (0.8%)
Nulliparous	5.8	1.1
Multiparous	0.6	0.5
Admission BMI		
<25	3.1	0.9
25–29.9	3.4	0.8
30–34.9	2.7	0.8
≥35	2.2	1.1
Operative delivery		
Vacuum	2.0	0.3
Forceps	10.7	1.0
Episiotomy	7.0	0.7
Birthweight (g)		
<2500g	0.9	1.1
2500–3000	1.6	0.9
3000–3500	2.7	0.8
3500–4000	3.9	0.6
4000–5000	5.4	0.7

BMI = body mass index.

Data from Landy, 2011.

with operative vaginal delivery, episiotomy, increasing newborn birthweight, and prolonged second-stage labor (Fong, 2014; Landy, 2011; Laughon, 2014). Episiotomy, perineal laceration, and their repair are discussed in detail in Chapter 20 (p. 320).

Bilateral vaginal lacerations are usually unequal in length, and they are separated by a tongue of vaginal tissue. Lacerations involving the middle or upper third of the vaginal vault usually are associated with injuries of the perineum or cervix. Cervical tears sometimes are missed unless thorough inspection of the upper vagina and cervix is performed. It is worth repeating that bleeding despite a firmly contracted uterus is strong evidence of a genital tract laceration. Vaginal lacerations that extend upward usually are longitudinal. They may follow spontaneous delivery but frequently result from injuries sustained during operative vaginal delivery with forceps or vacuum extractor. Most involve deeper underlying tissues and thus usually cause significant hemorrhage. Bleeding is typically controlled by appropriate suture repair. For this, a running locking suture line begins at the proximal apex of the laceration and progresses distally. In most instances a single-layer closure using a 0- or 2-0 gauge absorbable suture such as chromic gut or polyglactin 910 (Vicryl) is sufficient. Persistent bleeding sites may require selectively placed figure-of-eight sutures for hemostasis.

Extensive vaginal or cervical tears should prompt a careful search for evidence of retroperitoneal hemorrhage or peritoneal perforation with hemorrhage. An extreme example of a posterior fornix tear reported by Sakhare and colleagues (2007) is shown in Figure 30-1. If such a perforation is suspected, laparotomy

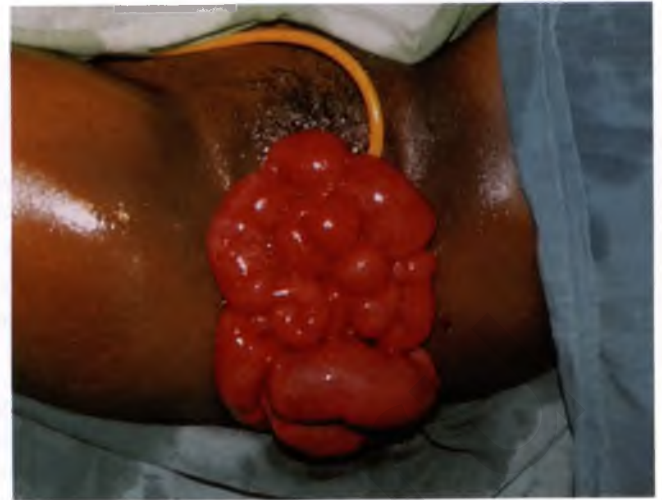

FIGURE 30-1 Laceration of the posterior fornix with small-bowel herniation following a home delivery. (Reproduced with permission from: Sakhare AP, Bhanap PL, Mahale AR: Bowel prolapse through colporrhexis—a complication of home delivery. *J Obstet Gynecol India* 57(6):553, 2007.)

should be considered (Rafi, 2010). Extensive vulvovaginal lacerations also warrant uterine exploration for possible uterine tears or rupture. For deep vulvovaginal lacerations, effective analgesia or anesthesia, vigorous blood replacement, and capable assistance are mandatory during suture repair. In the study reported by Melamed and associates (2009), 1.5 percent of women with these lacerations required blood transfusions. Postoperative infections are also common in these women (Lewicky-Gaup, 2015). With any of the lacerations discussed in this section, those large enough to require extensive repair are typically associated with voiding difficulty. A postoperative indwelling bladder catheter will obviate this. In most cases, the catheter can be removed the following day.

■ Levator Sling Injuries

The levator ani muscles, described in Chapter 3 (p. 35), are usually involved with deep vaginal vault lacerations. Muscle fibers are torn and separated, and their diminished tone may interfere with pelvic diaphragm function to cause pelvic relaxation. In one review, the levator ani muscles were reported to be injured in 13 to 36 percent of women who had a vaginal delivery (Schwertner-Tiepelmann, 2012). In a recent study of nulliparas who underwent operative vaginal delivery—247 vacuum-assisted and 42 forceps deliveries—20 percent had a levator injury. In these women, operative vaginal delivery was the only identifiable risk factor (Chung, 2015). In addition, stretch injuries may also result from overdistention of the birth canal.

The long-term quality of life of these women has not been well studied. However, if the injuries involve the pubococcygeus or puborectalis muscles, urinary and anal incontinence also may result, although the exact incidence is unknown.

■ Cervical Lacerations

Superficial lacerations of the cervix can be seen on close inspection in more than half of all vaginal deliveries. Most of these are less

than 0.5 cm and seldom require repair (Fahmy, 1991). Deeper lacerations are less frequent, but even these often are unnoticed. Due to ascertainment bias, variable incidences are described. For example, in the Consortium on Safe Labor database that included deliveries in which close inspection was employed, the incidence of cervical lacerations was 1.1 percent in nulliparas and 0.5 percent in multiparas (see Table 30-2). This contrasts with an overall incidence of only 0.16 percent reported by Melamed and coworkers (2009), whose study included more than 81,000 Israeli women. In another study, Parikh and associates (2007) reported a 0.2-percent incidence of cervical lacerations that required repair.

Such lacerations may be related to operative vaginal delivery, especially with the use of forceps. For example, in a recent study from California of trends and morbidity associated with operative vaginal delivery, higher rates of cervical laceration repair were reported with forceps use compared with vacuum delivery (Fong, 2014).

Cervical lacerations are not usually problematic unless they cause hemorrhage or extend to the upper third of the vagina. Rarely, the cervix may be entirely or partially avulsed from the vagina—*colporrhexis*—in the anterior, posterior, or lateral fornices. These injuries sometimes follow difficult forceps rotations or deliveries performed through an incompletely dilated cervix with the forceps blades applied over the cervix. In some gravidas, cervical tears reach into the lower uterine segment and involve the uterine artery and its major branches. They occasionally extend into the peritoneal cavity. The more severe lacerations usually manifest as external hemorrhage or as a hematoma, however, they may occasionally be unsuspected. In the large Israeli study reported by Melamed and colleagues (2009), almost 11 percent of women identified as having a cervical laceration required blood transfusions.

Other serious cervical injuries fortunately are uncommon. In one, the edematous anterior cervical lip is caught during labor and compressed between the fetal head and maternal symphysis pubis. If this causes severe ischemia, the anterior lip may undergo necrosis and separate from the rest of the cervix. Another rare injury is avulsion of the entire vaginal portion of the cervix. Such *annular or circular detachment of the cervix* is seen with difficult deliveries, especially forceps deliveries.

Diagnosis

A deep cervical tear should always be suspected in women with profuse arterial hemorrhage during and after third-stage labor, particularly if the uterus is firmly contracted. It is reasonable to inspect the cervix routinely following major operative vaginal deliveries even if there is no third-stage bleeding. Thorough evaluation is necessary, and often the thinned, floppy cervix interferes with digital examination. The extent of the injury can be more fully appreciated with adequate exposure and visual inspection. This is best accomplished when an *assistant* applies firm caudal-directed pressure on the uterus, and the operator exerts traction on the lips of the cervix with ring forceps. A second assistant can provide improved exposure with right-angle vaginal wall retractors.

Management

In general, cervical lacerations measuring 1 and even 2 cm are not repaired unless they are bleeding. Such tears heal rapidly and

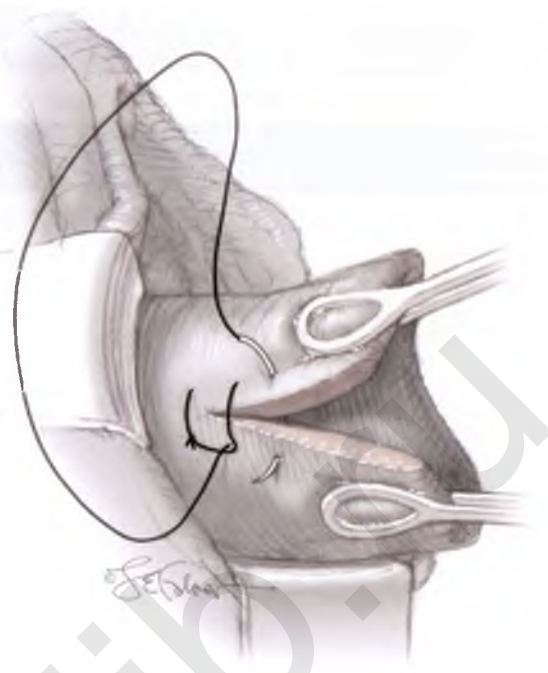


FIGURE 30-2 Deep cervical laceration repair. Absorbable suture is used in a running locking suture line that begins proximal to the apex of the laceration.

are thought to be of no significance. When healed, the external cervical os has an irregular, sometimes stellate, appearance.

Deep cervical tears usually require surgical repair. When the laceration is limited to the cervix or even when it extends somewhat into the vaginal fornix, satisfactory results are obtained by suturing the cervix after bringing it into view at the vulva (Fig. 30-2). While cervical lacerations are repaired, associated vaginal lacerations may be tamponaded with gauze packs to arrest their bleeding. Because hemorrhage usually comes from the upper angle of the wound, the first suture using absorbable material is placed in tissue above the angle. Subsequently, either interrupted or continuous locking sutures are placed outward toward the operator. Either delayed-absorbable or absorbable suture is suitable, and 0- or 2-0 gauge chromic gut or polyglactin 910 is a reasonable choice. If lacerations extend to involve the lateral vaginal sulcus, then attempts to restore the normal cervical anatomic appearance may lead to subsequent stenosis.

Most cervical lacerations are successfully repaired using sutures. However, if there is uterine involvement and continued hemorrhage, then some of the methods described in Chapter 29 (p. 475) may be necessary to obtain hemostasis. For example, Lichtenberg (2003) described successful angiographic embolization for a high cervical tear after failed surgical repair. In other cases, laparotomy and even hysterectomy may be necessary to obtain hemostasis.

PUERPERAL HEMATOMAS

Pelvic hematomas following childbirth are most often associated with a laceration, episiotomy, or an operative vaginal delivery. That said, some may develop following stretch and rupture of a blood vessel without associated lacerations (Nelson, 2012;

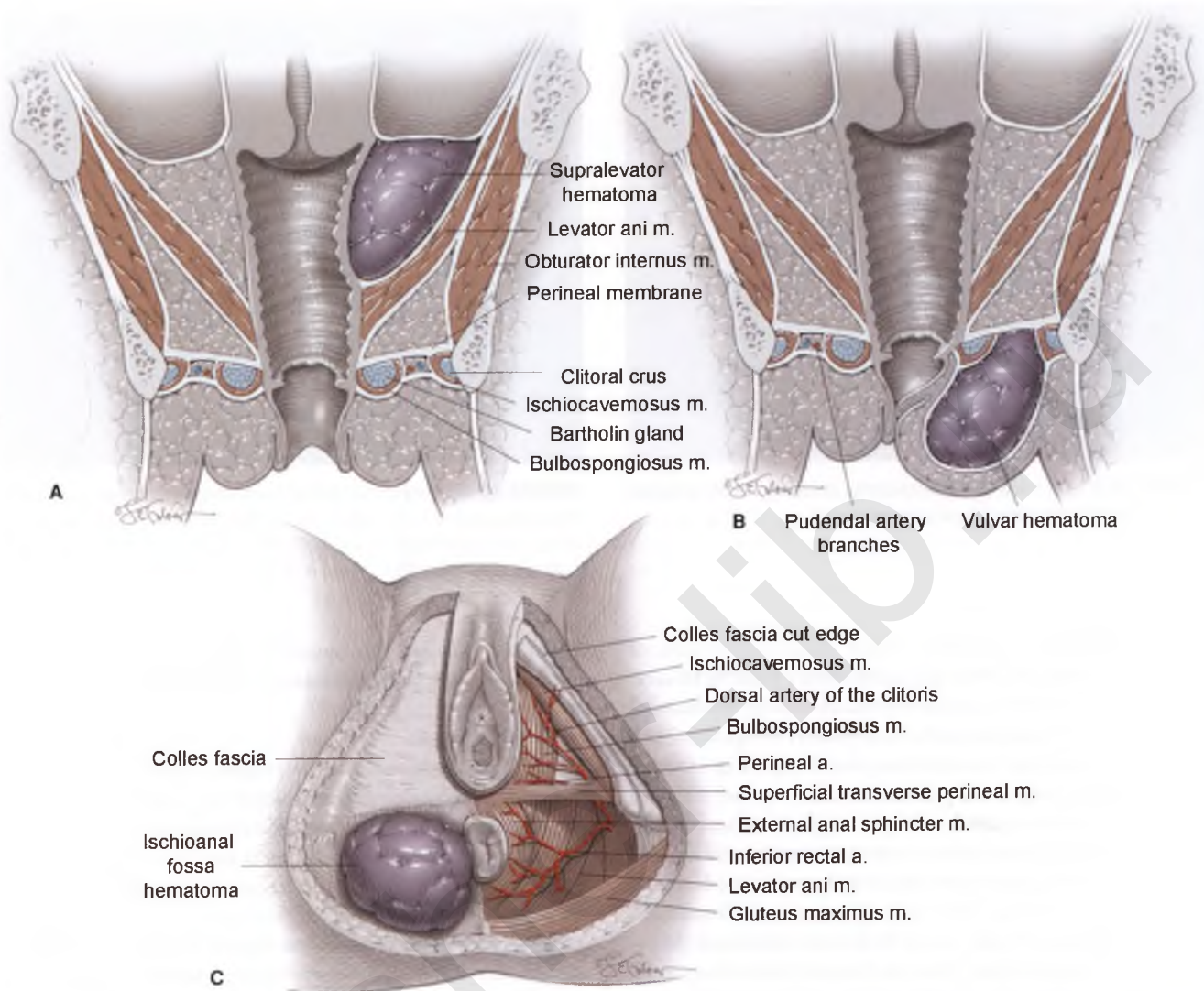


FIGURE 30-3 Schematic drawing showing types of puerperal hematomas. **A.** Coronal view showing a supralelevator hematoma. **B.** Coronal view showing an anterior perineal triangle hematoma. **C.** Perineal view showing posterior perineal triangle anatomy and an ischioanal fossa hematoma.

Propst, 1998; Ridgway, 1995). These hematomas may have any of several anatomic manifestations. In some cases, they are quickly apparent, but in others, hemorrhage may be delayed. Occasionally, they are associated with an underlying acquired coagulopathy such as with placental abruption or acute fatty liver of pregnancy, from therapeutic anticoagulation, or from a congenital bleeding disorder such as von Willebrand disease.

One anatomy-based classification of puerperal hematomas includes vulvar, vulvovaginal, paravaginal, supralelevator, ischioanal, and retroperitoneal hematomas (Fig. 30-3). Vulvar hematomas most often involve branches of the pudendal artery. The three main divisions are the inferior rectal artery, the dorsal artery of the clitoris, and the perineal artery, including its posterior labial artery branch (Fig. 3-7, p. 36). Paravaginal hematomas may involve the descending branch of the uterine artery (Zahn, 1990). In some cases, a torn vessel lies above the levator ani muscles, and a supralelevator hematoma develops. These can extend into the upper portion of the vaginal canal and may almost occlude its lumen. Continued bleeding may dissect up

the retroperitoneal space to form a mass palpable above the inguinal ligament. Finally, it may even dissect up behind the ascending colon to the hepatic flexure at the lower margin of the diaphragm (Rafi, 2010).

■ Vulvovaginal Hematomas

Hematomas of the perineum, vulva, and paravaginal spaces can develop rapidly. They frequently cause excruciating pain, as did the one shown in Figure 30-4. If bleeding ceases, then small- to moderate-sized hematomas may be absorbed. In others, the tissues overlying the hematoma may rupture from pressure necrosis. At this time, profuse hemorrhage can follow. In other cases, the hematoma drains in the form of large clots and old blood. In those that involve the paravaginal space and extend above the levator plate, retroperitoneal bleeding may be massive and occasionally fatal. Finally, we have occasionally encountered hematomas that re-bled up to 2 weeks postpartum, such as the woman shown in Figure 30-5.

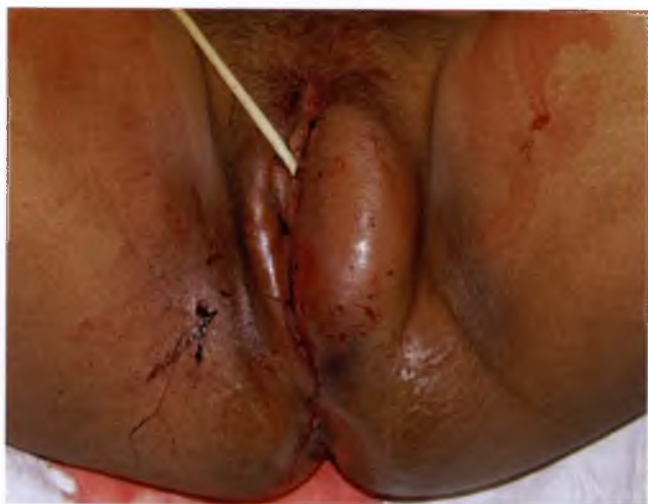

FIGURE 30-4 Left-sided vulvar hematoma associated with a vaginal laceration following spontaneous delivery.

Diagnosis

A vulvar hematoma is usually readily diagnosed because of severe perineal pain. A tense, fluctuant, tender swelling of varying size rapidly develops and is eventually covered by bruised, discolored skin. A paravaginal hematoma may escape detection temporarily. But symptoms of pelvic pressure, pain, or inability to void warrant evaluation and lead to discovery of a round, fluctuant mass encroaching on the vaginal lumen. When there is supralelevator extension, the hematoma extends upward through the paravaginal space and then between the leaves of the broad ligament (**Fig. 30-6**). In some women, the hematoma may escape detection until it can be felt on abdominal palpation or until hypovolemia develops. Imaging with sonography or computed tomographic (CT) scanning can be useful to assess hematoma location and extent (Kawamura, 2014; Takeda,

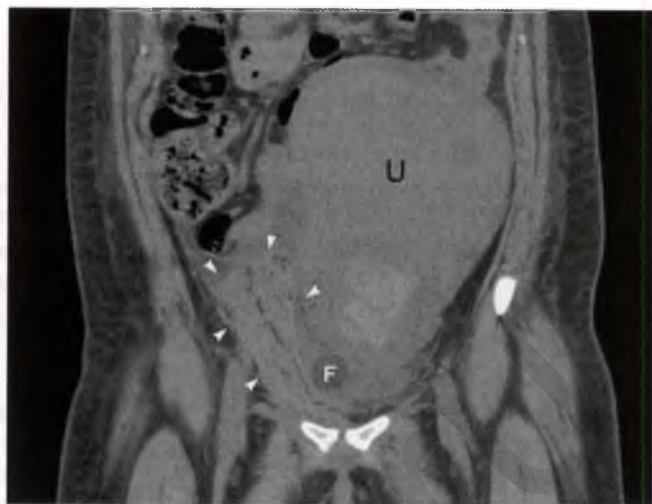

FIGURE 30-6 Coronal computed tomography image of a right-sided paravaginal hematoma (*arrowheads*) that extends past the base of the broad ligament. The hematoma resolved spontaneously during the next 6 weeks. F = Foley balloon; U = postpartum uterus.

2014). As discussed subsequently, supralelevator hematomas are particularly worrisome because they can be fatal.

Management

Vulvovaginal hematomas are managed according to their size, duration since delivery, and whether or not they are expanding. Blood loss with large puerperal hematomas is nearly always considerably more than the clinical estimate. Hypovolemia is common, and transfusions are frequently required when surgical repair is necessary.

In general, smaller vulvar hematomas identified after leaving the delivery room may be treated expectantly (Propst, 1998). But, if pain is severe or the hematoma continues to enlarge, then surgical exploration is preferable. An incision is made at

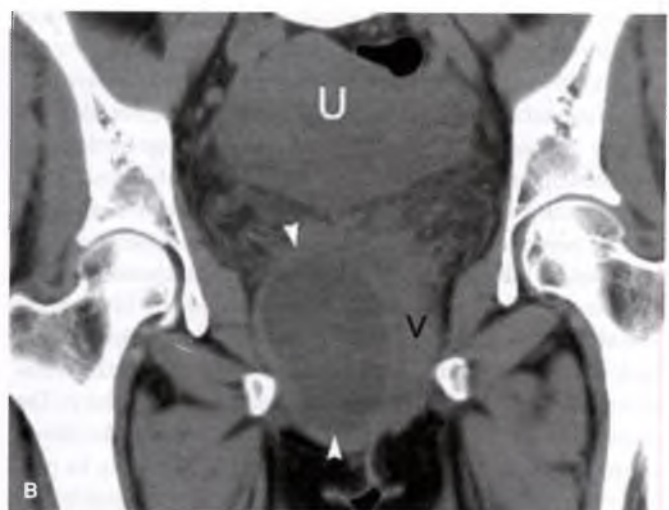
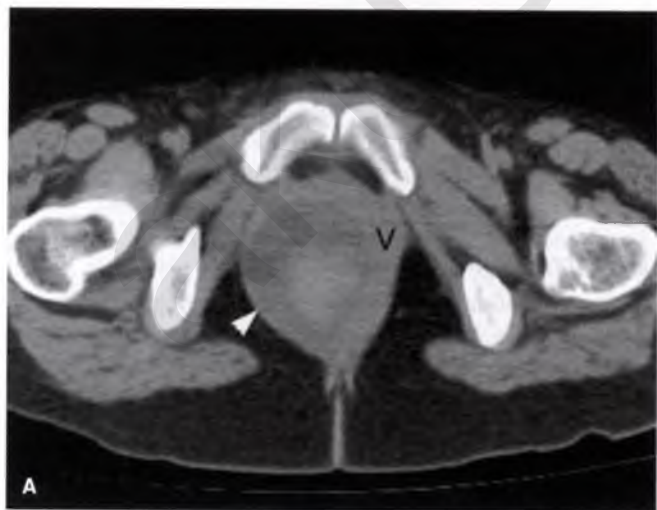
FIGURE 30-5 At delivery, this woman had a nonexpanding right-sided vulvovaginal hematoma that was treated expectantly. She returned 2 weeks postpartum with recurrent pain and swelling. This computed tomographic image taken at this later time shows a 6 × 6 × 8 cm right-sided paravaginal hematoma that had re-bled. **A.** In this axial image, the hematoma (*arrowhead*) displaces the urethra, vagina (V), and rectum laterally. The more dense area seen centrally in the hematoma is most consistent with clot on this noncontrast examination. **B.** This coronal view shows the significant length of this same hematoma (*arrowheads*). The vagina is compressed and deviated laterally. U = uterus; V = vagina.

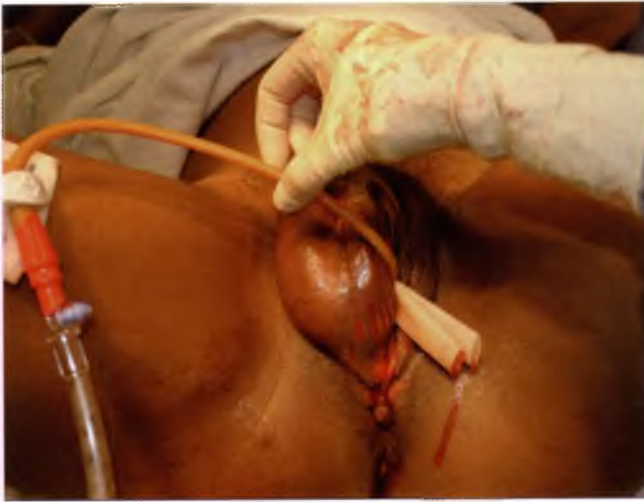

FIGURE 30-7 Right-sided vulvovaginal hematoma has been incised and drained of 500 mL blood and clots. Two ¾-inch Penrose drains were brought out at the incision site, which was partially closed. The drains were removed 24 hours later, at which time there was only scant drainage. The bladder was drained by a Foley catheter.

the point of maximal distention, blood and clots are evacuated, and bleeding points are ligated. However, in many instances, discrete bleeding vessels are not found. The cavity may then be obliterated with interrupted mattress sutures or a running suture line. This may require a closure in layers if the evacuated cavity is deep. Either delayed-absorbable or absorbable suture is suitable, and 0- or 2-0 gauge chromic gut or polyglactin 910 is a reasonable choice.

In cases with prominent vaginal involvement, the vagina is packed for 12 to 24 hours. In some cases the hematoma cavity cannot be approximated, and drains are placed with a liberal-sized ostium (Fig. 30-7). With vulvar hematomas, whether evacuation or observed, cool packs, Foley catheter drainage, and analgesics are frequent adjuncts.

■ Supralelevator and Retroperitoneal Hematomas

Paravaginal hematomas may dissect cephalad along lines of least resistance. These can extend into the upper portion of the vaginal canal, above the plane of the levator ani muscles, and may almost occlude its lumen. Continued bleeding may dissect up the retroperitoneal space to form a mass palpable above the inguinal ligament. Finally, it may even dissect up behind the ascending colon to the hepatic flexure at the lower margin of the diaphragm. Obviously, retroperitoneal hematomas can be life threatening if they are large and expanding. As discussed, continued hemorrhage is frequently underappreciated. In some cases femoral nerve compression, sciatica, and iliopsoas spasm may be encountered (Rafi, 2010). Diagnosis is verified by computed tomography (CT) or magnetic resonance (MR) imaging (Fig. 30-8).

Because of their size and location, supralelevator hematomas are more difficult to treat. Although some can be evacuated by vulvar or vaginal incisions, either laparotomy or angiographic embolization is advisable if there is continued hemorrhage. Embolization has now become popular for management

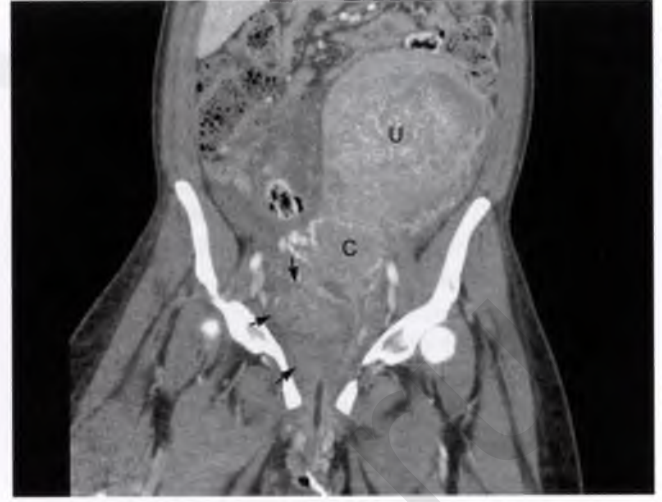


FIGURE 30-8 Coronal computed tomography image showing a large paravaginal supralelevator hematoma (arrows) displacing the vagina to the left and the uterus (U) and cervix (C) cephalad and to the left.

of most of these hematomas. It can be used primarily or may follow failed surgical attempts to gain hemostasis (Distefano, 2013; Lee, 2015; Ojala, 2005). In more than 500 women with various causes of pelvic hemorrhage, embolization was reported to be 90-percent effective (Bodner, 2006; Lee, 2012; Poujade, 2012; Sentilhes, 2009). From his review, Rouse (2013) concluded that embolization in general was successful but that it was less effective with placenta percreta or with concurrent coagulopathy.

After embolization, fertility is not impaired, and subsequent successful pregnancies have been reported (Chauleur, 2008; Fiori, 2009; Kolomeyevskaya, 2009). Complications of embolization are relatively uncommon, but they can be severe. Uterine infection and uterine ischemic necrosis have both been described in cases treating postpartum hemorrhage (Coulange, 2009; Katakam, 2009; Nakash, 2012; Sentilhes, 2009). Finally, Al-Thunyan and coworkers (2012) described a woman with massive buttock necrosis and paraplegia following bilateral internal iliac artery embolization.

The use of a *Bakri balloon* to arrest hemorrhage with a paracervical hematoma has also been reported (Gizzo, 2013; Grönvall, 2013). Similarly, Ghirardini and associates (2012) used a Foley catheter balloon for tamponade. Finally, sonographically guided drainage of a supralelevator hematoma has been described (Mukhopadhyay, 2015). Until more experience accrues with these last three techniques, their use for hematoma management cannot be recommended routinely.

UTERINE RUPTURE

Rupture of the uterus is frequently catastrophic. It is considered to be *primary* if it develops in a previously intact or unscarred uterus. Alternatively, rupture is defined as *secondary* if it is associated with a preexisting myometrial incision, injury, or anomaly. Some of the etiologies associated with uterine rupture are presented in Table 30-3. Importantly, the contribution of each

TABLE 30-3. Some Causes of Uterine Rupture

Primary Rupture	Secondary Rupture
<p>Before delivery:</p> <ul style="list-style-type: none"> Persistent, intense, spontaneous contractions Labor stimulation—oxytocin or prostaglandins Intraamniotic instillation—saline or prostaglandins Perforation by internal uterine pressure catheter External trauma—sharp or blunt External version Uterine overdistention—hydramnios, multifetal pregnancy <p>During delivery:</p> <ul style="list-style-type: none"> Internal version second twin Difficult forceps delivery Rapid tumultuous labor and delivery Breech extraction Shoulder dystocia Fetal anomaly distending lower segment Vigorous uterine pressure during delivery Difficult manual removal of placenta <p>Acquired:</p> <ul style="list-style-type: none"> Placental accrete syndromes Gestational trophoblastic neoplasia Adenomyosis Sacculation of entrapped retroverted uterus 	<p>Surgery involving the myometrium:</p> <ul style="list-style-type: none"> Cesarean delivery or hysterotomy Previously repaired uterine rupture Myomectomy incision through or to the endometrium Deep cornual resection of interstitial fallopian tube Metroplasty Salpingectomy <p>Coincidental uterine trauma:</p> <ul style="list-style-type: none"> Abortion with instrumentation—sharp or suction curette, sounds Sharp or blunt trauma—assaults, vehicular accidents, bullets, knives Silent rupture in previous pregnancy <p>Congenital:</p> <ul style="list-style-type: none"> Defective connective tissue Pregnancy in undeveloped uterine horn

of these underlying causes has changed remarkably during the past 50 years (Al-Zirqi, 2016). Specifically, before 1960, when the cesarean delivery rate was much lower than current rates and when women of great parity were numerous, primary uterine rupture predominated. As the incidence of cesarean delivery increased, and especially as a subsequent trial of labor in these women became prevalent through the mid-1990s, uterine rupture at the site of the cesarean hysterotomy scar became the preeminent cause. For example, from 1988 to 1997, 92 percent of women in one series had undergone prior cesarean delivery (Kieser, 2002). Largely because of this, enthusiasm for a trial of labor in women with prior cesarean delivery diminished. This was detailed by the panel of the National Institutes of Health Consensus Development Conference (2010). Since then, the two types of rupture likely now have somewhat equivalent incidences. Indeed, a 2006 study of 41 cases of uterine rupture from the Hospital Corporation of America reported that only half were in women with a prior cesarean delivery (Porreco, 2009).

■ Incidence and Predisposing Factors

In developed countries, the incidence of rupture was cited by Getahun and associates (2012) to be 1 in 4800 deliveries. This comports with the frequency observed at Parkland Hospital of 0.2 per 1000 deliveries from 2004 to 2014. The incidence of primary rupture is lower and is 1 in 10,000 to 15,000 births (Miller, 1997; Porreco, 2009). This rate has declined during the past 30 to 40 years. One reason may be the decreasing frequency of women of great parity (Maymon, 1991; Miller, 1997).

Another reason for decreased incidence of uterine rupture is that excessive or inappropriate uterine stimulation with oxytocin—previously a frequent cause—has mostly disappeared. This appears to be the case for rupture during a trial of labor after cesarean delivery. Maggio and associates (2014) found no association between the number of Montevideo units and uterine rupture in women undergoing a trial of labor. In addition, in a recent analysis of three trials comparing high-dose versus low-dose oxytocin regimens for induction of labor, the frequency of uterine rupture did not differ between the groups (Budden, 2014). Still, oxytocin use has been cited recently as a risk factor for rupture of the unscarred uterus (Gibbins, 2015). As an aside, and totally anecdotally, we have encountered primary uterine rupture in a seemingly disparate number of women in whom labor was induced with prostaglandin E₁.

Other risks for uterine rupture include any previous operations or manipulations that traumatize the myometrium. Some of these are uterine curettage or perforation, endometrial ablation, myomectomy, hysteroscopy, and interstitial salpingectomy (Kieser, 2002; Kiseli, 2013; Pelosi, 1997; Stanirowski, 2015). In the study by Porreco and colleagues (2009) cited earlier, 7 of 21 women without a prior cesarean delivery had undergone prior uterine surgery. Also, with the rising cesarean delivery rate, and as discussed in Chapter 27 (p. 445), case reports describe rupture associated with placenta accrete syndromes (Conroy, 2014; Deshpande, 2013).

Uncommon causes of uterine rupture include a uterine anomaly and multifetal pregnancy (Tarney, 2013; Tola, 2014). Other cases involve an inherent weakness in the myometrium at

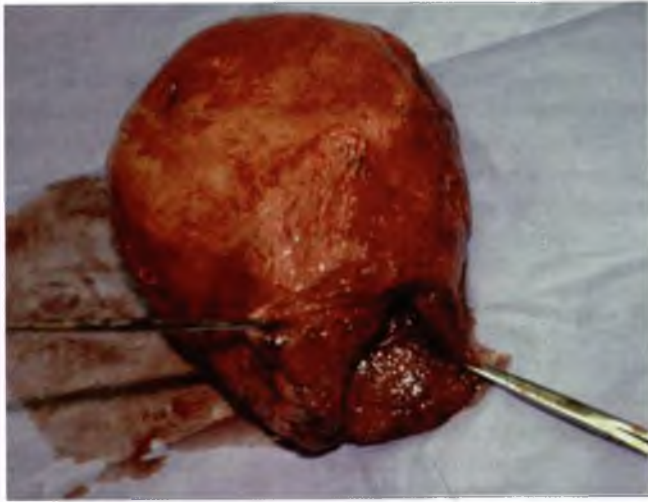


FIGURE 30-9 This primary uterine rupture developed during spontaneous labor with a vertical tear at the left lateral edge of the lower uterine segment.

the site of rupture. Some examples include uterine myomas, adenomyosis, and connective-tissue disorders such as Ehlers-Danlos syndrome and systemic lupus erythematosus (Arici, 2013; Nikolaou, 2013; Noh, 2013; Ramskill, 2014; Tola, 2014).

■ Pathogenesis

Primary rupture of the previously intact uterus during labor most often involves the thinned-out lower uterine segment. When the rent is in the immediate vicinity of the cervix, it frequently extends transversely or obliquely. When the rent is in the portion of the uterus adjacent to the broad ligament, the tear is usually longitudinal. Although these tears develop primarily in the lower uterine segment, it is not unusual for them to extend downward through the cervix and into the vagina or upward into the active uterine segment (Fig. 30-9). In some cases, the bladder may also be lacerated (Rachagan, 1991). If the rupture is of sufficient size, the uterine contents will usually escape into the peritoneal cavity. If the presenting fetal part is firmly engaged, however, then only a portion of the fetus may be extruded from the uterus. Fetal prognosis is largely dependent on the degree of placental separation and magnitude of maternal hemorrhage and hypovolemia. In some cases, the overlying peritoneum remains intact, and this usually is accompanied by hemorrhage that extends into the broad ligament to cause a large retroperitoneal hematoma with extensive blood loss. Occasionally the intact amniotic sac protrudes through a myometrial defect, and some of these have been described as clinically silent (Al-Kufaishi, 2014; Iemura, 2015). Rarely, uterine rupture will manifest as sepsis syndrome postpartum (Narasimhulu, 2015).

■ Clinical Findings and Diagnosis

There is not a specific pattern in the progress of labor that presages either primary or secondary uterine rupture (Graseck, 2012; Harper, 2012). Prior to developing hypovolemic shock, symptoms and physical findings in women with uterine rupture may appear bizarre unless the possibility is kept in mind. For example, hemoperitoneum from a ruptured uterus may result in diaphragmatic irritation with pain referred to the chest. This may direct one to a diagnosis of pulmonary or amniotic fluid embolism instead of uterine rupture. The most common sign of uterine rupture is a nonreassuring fetal heart rate pattern with variable heart rate decelerations that may evolve into late decelerations and bradycardia (American Academy of Pediatrics and American College of Obstetricians and Gynecologists, 2012). Such an example is shown in Figure 30-10. In 36 cases of such ruptures during a trial of labor, there were fetal signs in 24 cases, maternal in 8, and both in 3 (Holmgren, 2012). Few women experience cessation of contractions following uterine rupture, and the use of intrauterine pressure catheters has not been shown to assist reliably in the diagnosis (Rodriguez, 1989). In some women, the appearance of uterine rupture is identical to that of placental abruption. In most, however, remarkably little pain or tenderness is appreciated. Also, because most women in labor are treated for discomfort with either narcotics or epidural analgesia, pain and tenderness may be masked. The condition usually becomes evident because of fetal distress signs and occasionally because of maternal hypovolemia from concealed hemorrhage.

If the fetal presenting part has entered the pelvis with labor, loss of station may be detected during pelvic examination. If the fetus is partly or totally extruded from the uterine rupture site, abdominal palpation or vaginal examination may be helpful to identify the presenting part, which will have moved away from the pelvic inlet. A firm contracted uterus may at times be felt alongside the fetus.

Partial Thickness Rupture—Uterine Tear

On several occasions following vaginal delivery, we have encountered an incomplete tear on the inside of the uterus that extends

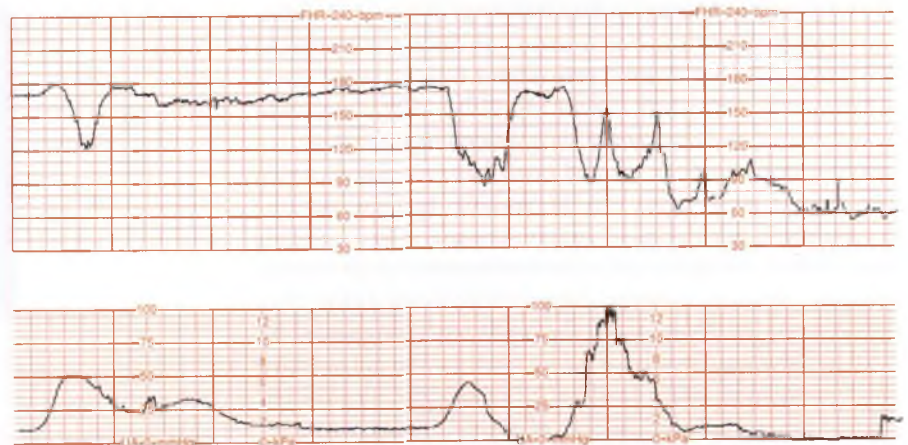

FIGURE 30-10 Electronic fetal heart rate tracing from internal monitors in a woman with a ruptured uterus from a prior cesarean delivery who was pushing during a trial of labor. (Reproduced with permission from Cunningham FG, Leveno, KJ, Bloom SL, et al: *Prior cesarean delivery*. In *Williams Obstetrics*, 24th ed. New York, McGraw-Hill Education, 2014.)

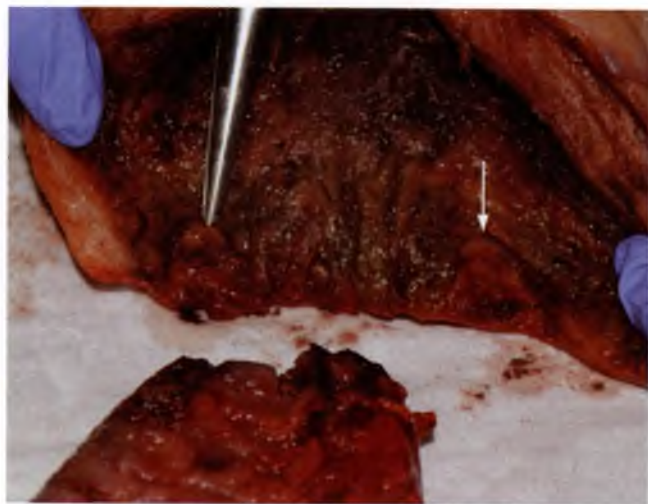


FIGURE 30-11 “Partial uterine rupture” showing two incomplete vertical tears through the uterine myometrium (*arrow and scissor tip*).

vertically and is a source of active hemorrhage (Fig. 30-11). This cause of persistent postpartum hemorrhage was recently described by Conrad and colleagues (2015). These tears are usually not visible from below and are found at the time of hysterectomy for intractable uterine bleeding despite a contracted uterus. Hemorrhage with this type of tear can be torrential, and bleeding is usually not slowed down until the uterine artery pedicles are clamped bilaterally.

■ Management

Emergent laparotomy is indicated for most cases of uterine rupture. Maternal morbidity includes hysterectomy that may be necessary to control hemorrhage. One possible exception to laparotomy is a palpable separation of a prior incision identified in a woman who has just completed a successful trial of labor following a prior cesarean birth. If the uterine incision is covered by serosa, and there is no bleeding, then many recommend observation.

Hysterectomy versus Repair

Most reports concerning surgical treatment of ruptured uterus are from women with a prior cesarean scar. With complete rupture during a trial of labor, hysterectomy may be required. In the reports by McMahon (1996) and Miller (1997) and their coworkers, 10 to 20 percent of such women required hysterectomy for hemostasis. In selected cases, however, suture repair with uterine preservation may be possible. In these women, the likelihood of subsequent rupture appears to be increased. Sheth (1968) described outcomes from a series of 66 women in whom repair of a uterine rupture was elected rather than hysterectomy. In 25 instances, the repair was accompanied by tubal sterilization. Thirteen of the 41 mothers who did not have tubal sterilization had a total of 21 subsequent pregnancies. Uterine rupture recurred in four of these—approximately 25 percent. Usta and associates (2007) identified 37 women with a prior complete uterine rupture delivered during a 25-year period in Lebanon. Hysterectomy was performed in 11, and in the remaining 26 women, the rupture was repaired. Twelve of

these women had 24 subsequent pregnancies, of which a third were complicated by recurrent uterine rupture. Not all reports cite these high rates of subsequent rupture. In the study by Fox and colleagues (2014), there were no cases of recurrent uterine rupture in 20 subsequent pregnancies. The uterine dehiscence rate, however, was 5 percent. In another study, women with a uterine dehiscence were not more likely to have uterine rupture with a subsequent pregnancy (Baron, 2014).

■ Outcomes

Maternal Mortality

Most maternal and perinatal outcomes with uterine rupture also are from reports describing women undergoing a trial of labor following a cesarean birth. According to the Centers for Disease Control and Prevention, approximately 1 percent of maternal deaths are caused by uterine rupture (Creanga, 2015). As shown in Figure 30-12, uterine rupture accounted for an estimated 10 percent of maternal deaths caused by hemorrhage in the United States from 2006 through 2010. From a Canadian database of 2.5 million women who gave birth between 1991 and 2001, there were 1898 cases of uterine rupture, and only four of these—0.2 percent—resulted in maternal death (Wen, 2005). In other regions of the world, however, maternal mortality rates associated with uterine rupture are much higher. In a report from rural India, for example, the maternal mortality rate associated with uterine rupture was 30 percent (Chatterjee, 2007).

Perinatal Morbidity and Mortality

As expected, perinatal morbidity and mortality rates associated with uterine rupture are considerably increased. In addition to stillbirths and neonatal deaths, a major concern is that surviving infants develop severe neurologic impairment (Porreco, 2009). With rupture and expulsion of the fetus into the peritoneal cavity, the chances for intact fetal survival are dismal. Mortality rates range from 50 to 75 percent. Fetal condition depends on the degree to which the placental implantation

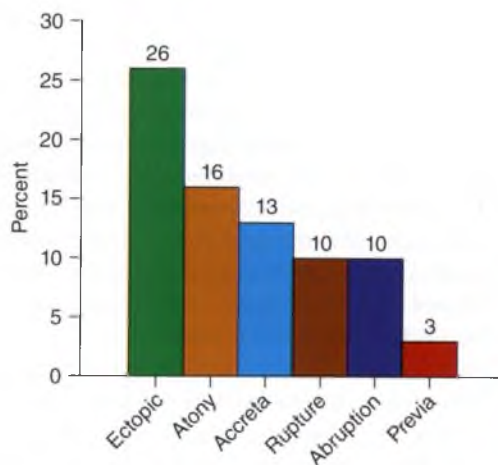


FIGURE 30-12 Causes of maternal deaths from hemorrhage in 382 women as reported to the Centers for Disease Control and Prevention (Data from Creanga AA, Berg CJ, Syverson C, et al: Pregnancy-related mortality in the United States, 2006–2010, *Obstet Gynecol* 2015 Jan;125(1):5–12).

remains intact, although this can change within minutes. With rupture, the only chance of fetal survival is afforded by immediate delivery—most often by laparotomy—otherwise, hypoxia is inevitable. If rupture is followed by immediate total placental separation, then very few fetuses will be salvaged. Thus, even in the best of circumstances, fetal survival will be impaired.

The Utah experiences are instructive here (Holmgren, 2012). Of the 36 laboring patients with a uterine rupture, the decision-to-delivery time was <18 minutes in 17, and none of these infants had an adverse neurologic outcome. Of the 18 infants born >18 minutes from decision time, the three infants with long-term neurologic impairments were delivered at 31, 40, and 42 minutes. There were no deaths, and thus severe neonatal neurologic morbidity developed in 12 percent of these 36 women with uterine rupture.

In a study from the Swedish Birth Registry, Kaczmarczyk and coworkers (2007) found that the risk of neonatal death following uterine rupture was 5 percent—a 60-fold increase in the risk, compared with pregnancies not complicated by uterine rupture. In this study, 7 of the 114 uterine ruptures associated with a trial of labor—6 percent—were complicated by the development of neonatal hypoxic ischemic encephalopathy (Spong, 2007).

■ Traumatic Uterine Rupture

Although the distended pregnant uterus is surprisingly resistant to blunt trauma, pregnant women sustaining such trauma to the abdomen should be watched carefully for signs of a ruptured uterus (Chap. 17, p. 282). Even so, blunt trauma is more likely to cause placental abruption. In a study by Miller (1996), trauma accounted for only three cases of uterine rupture in more than 150 women. Rupture is more likely in a previously scarred uterus and is usually associated with a direct impact of substantial force. Decelerative forces following a collision at 25 miles per hour can generate up to 500 mm Hg of intrauterine pressure in a properly restrained woman (Fig. 17-4, p. 280) (Crosby, 1968).

Clinical findings with a traumatic uterine rupture may be identical to those for placental abruption with an intact uterus, and maternal and fetal deterioration are soon inevitable. Pearlman and Cunningham (1996) described uterine fundal “blow-out” with fetal decapitation in a 20-week pregnancy following a high-speed collision. Similarly, Weir and colleagues (2008) described supracervical uterine avulsion and fetal transection at 22 weeks. CT scanning may be useful to diagnose uterine rupture with a dead fetus or placental separation.

Other causes of traumatic rupture that are uncommon today are those due to internal podalic version and extraction, difficult forceps delivery, breech extraction, and unusual fetal enlargement such as with hydrocephaly.

REFERENCES

Al-Kufaishi A, Erasmus K, Carr D, et al: An unusual cause for epigastric pain in pregnancy. Spontaneous uterine rupture with herniation of the amniotic sac in a 33-week primigravida. *BMJ Case Rep* Mar 5, 2014
 Al-Thunyan A, Al-Meshal O, Al-Hussainan H, et al: Buttock necrosis and paraplegia after bilateral internal iliac artery embolization for postpartum hemorrhage. *Obstet Gynecol* 120(2 Pt 2):468, 2012

Al-Zirqi I, Stray-Pedersen B, Forsen L, et al: Uterine rupture: trends over 40 years. *BJOG* 123(5):780, 2016
 American Academy of Pediatrics and the American College of Obstetricians and Gynecologists: Guidelines for Prenatal Care, 7th ed. Elk Grove Village, 2012
 Arici V, Corbetta R, Fossati G, et al: Acute first onset of Ehlers-Danlos syndrome type 4 with spontaneous rupture of posterior tibial artery pseudoaneurysm. *Vascular* 21(1):43, 2013
 Baron J, Weintraub AY, Eshkoli T, et al: The consequences of previous uterine scar dehiscence and cesarean delivery on subsequent births. *Int J Gynaecol Obstet* 126(2):120, 2014
 Bodner LJ, Nosher JL, Grivvin C, et al: Balloon-assisted occlusion of the internal iliac arteries in patients with placenta accreta/percreta. *Cardiovasc Intervent Radiol* 29:354, 2006
 Budden A, Chen LJ, Henry A: High-dose versus low-dose oxytocin infusion regimens for induction of labour at term. *Cochrane Database System Rev* 10:CD009701, 2014
 Chatterjee SR, Bhaduri S: Clinical analysis of 40 cases of uterine rupture at Durgapur Subdivisional Hospital: an observational study. *J Indian Med Assoc* 105(9):510, 2007
 Chaleur C, Fanger C, Tourne G, et al: Serious primary post-partum hemorrhage, arterial embolization and future fertility: a retrospective study of 46 cases. *Hum Reprod* 23:1553, 2008
 Chung MY, Wan OY, Cheung RY, et al: The prevalence of levator ani muscle injury and health related quality of life in primiparous Chinese women after instrumental deliveries. *Ultrasound Obstet Gynecol* 45(6):728, 2015
 Conrad LB, Groome LJ, Black DR: Management of persistent postpartum hemorrhage caused by inner myometrial lacerations. *Obstet Gynecol* 126:266, 2015
 Conroy K, Hsieh F, Craig S: Spontaneous uterine rupture from placenta percreta: an increasing phenomenon?. *Obstet Gynecol* 123(Suppl 1):142S, 2014
 Coulange L, Butori N, Loffroy R, et al: Uterine necrosis following selective embolization for postpartum hemorrhage using absorbable material. *Acta Obstet Gynecol Scand* 88(2):238, 2009
 Creanga AA, Berg CJ, Syverson C, et al: Pregnancy-related mortality in the United States, 2006–2010. *Obstet Gynecol* 125:5, 2015
 Crosby WM, Snyder RG, Snow CC, et al: Impact injuries in pregnancy. I. Experimental studies. *Am J Obstet Gynecol* 101(1):100, 1968
 Cunningham FG, Leveno KJ, Bloom SL, et al: Prior cesarean delivery. In *Williams Obstetrics*, 24th ed. New York, McGraw-Hill Education, 2014
 Deshpande NA, Carusi DA: Uterine rupture after prior conservative management of placenta accreta. *Obstet Gynecol* 122(2):475, 2013
 Distefano M, Casarella L, Amoroso S, et al: Selective arterial embolization as a first-line treatment for postpartum hematomas. *Obstet Gynecol* 121(2 Pt 2 Suppl):443, 2013
 Fahmy K, el-Gazar A, Sammour M, et al: Postpartum colposcopy of the cervix: injury and healing. *Int J Gynaecol Obstet* 34:133, 1991
 Fiori O, Deux JF, Kambale JC, et al: Impact of pelvic arterial embolization for intractable postpartum hemorrhage on fertility. *Am J Obstet Gynecol* 200:384.e1, 2009
 Fong A, Wu E, Pan D, et al: Temporal trends and morbidities of vacuum, forceps, and combined use of both. *J Matern Fetal Neonatal Med* 27(18):1886, 2014
 Fox NS, Gerber RS, Mourad M, et al: Pregnancy outcomes in patients with prior uterine rupture or dehiscence. *Obstet Gynecol* 123(4):785, 2014
 Getahun BS, Yeshi MM, Roberts DJ: Case records of the Massachusetts General Hospital: case 34–2012: a 27-year-old woman in Ethiopia with severe pain, bleeding, and shock during labor. *N Engl J Med* 367(19):1839, 2012
 Ghirardini G, Alboni C, Mbrouk M: Use of balloon tamponade in management of severe vaginal postpartum hemorrhage and vaginal hematoma: a case series. *Gynecol Obstet Invest* 74(4):320, 2012
 Gibbins KJ, Weber T, Holmgren CM, et al: Maternal and fetal morbidity associated with rupture of the unscarred uterus. *Am J Obstet Gynecol* 213(3):382.e1, 2015
 Gizzo S, Saccardi C, Paztelli TS, et al: Bakri balloon in vaginal-perineal hematomas complicating vaginal delivery: a new therapeutic approach. *J Low Genit Tract Dis* 17:125, 2013
 Graseck AS, Odibo AO, Tuuli M, et al: Normal first stage of labor in women undergoing trial of labor after cesarean delivery. *Obstet Gynecol* 119(4):732, 2012
 Grönvall M, Tikkanen M, Tallberg E, et al: Use of Bakri balloon tamponade in the treatment of postpartum hemorrhage: a series of 50 cases from a tertiary teaching hospital. *Acta Obstet Gynecol Scand* 92(4):433, 2013
 Harper LM, Cahill AG, Roehl KA, et al: The pattern of labor preceding uterine rupture. *Am J Obstet Gynecol* 207(3):210, 2012
 Holmgren C, Scott JR, Porter TF, et al: Uterine rupture with attempted vaginal birth after cesarean delivery: decision-to-delivery time and neonatal outcome. *Obstet Gynecol* 119(4):725, 2012

- Iemura A, Kondoh E, Kawasaki K, et al: Expectant management of a herniated amniotic sac presenting as silent uterine rupture: a case report and literature review. *J Matern Fetal Neonatal Med* 28(1):106, 2015
- Kaczmarczyk M, Sparen P, Terry P, et al: Risk factors for uterine rupture and neonatal consequences of uterine rupture: a population-based study of successive pregnancies in Sweden. *BJOG* 114(10):1208, 2007
- Katakam N, Vitthala S, Sasson S, et al: Complications and failure of uterine artery embolization for intractable postpartum haemorrhage. *BJOG* 116(6):863, 2009
- Kawamura Y, Kondoh E, Hamanishi J, et al: Treatment decision-making for postpartum hemorrhage using dynamic contrast-enhanced computed tomography. *J Obstet Gynaecol Res* 40(1):67, 2014
- Kieser KE, Baskett TF: A 10-year population-based study of uterine rupture. *Obstet Gynecol* 100:749, 2002
- Kiseli M, Artas H, Armagan F, et al: Spontaneous rupture of uterus in midtrimester pregnancy due to increased uterine pressure with previous laparoscopic myomectomy. *Int J Fertil Steril* 7(3):239, 2013
- Kolomeyevskaya NV, Tanyi JL, Coleman NM, et al: Balloon tamponade of hemorrhage after uterine curettage for gestational trophoblastic disease. *Obstet Gynecol* 113:557, 2009
- Landy HJ, Laughon K, Bailit JL, et al: Characteristics associated with severe perineal and cervical lacerations during vaginal delivery. *Obstet Gynecol* 117(3):627, 2011
- Laughon SK, Berghella V, Reddy UM, et al: Neonatal and maternal outcomes with prolonged second stage of labor. *Obstet Gynecol* 124(1):57, 2014
- Lee HY, Shin JH, Kim J, et al: Primary postpartum hemorrhage: outcome of pelvic arterial embolization in 251 patients at a single institution. *Radiology* 264(3):903, 2012
- Lee SL, Kim YH, Lee HJ: Selective angiographic embolisation of an infrallevator vulvovaginal haematoma after birth: case report. *J Obstet Gynaecol* 35(6):639, 2015
- Lewicky-Gaup C, Leader-Cramer A, Johnson LL, et al: Wound complications after obstetric anal sphincter injuries. *Obstet Gynecol* 125:1088, 2015
- Lichtenberg ES: Angiography as treatment for a high cervical tear—a case report. *J Reprod Med* 48:287, 2003
- Maggio L, Forbes J, Carey LL, et al: Association of Montevideo units with uterine rupture in women undergoing a trial of labor. *J Reprod Med* 59(9–10):464, 2014
- Maymon R, Shulman A, Pomeranz M, et al: Uterine rupture at term pregnancy with the use of intracervical prostaglandin E2 gel for induction of labor. *Am J Obstet Gynecol* 165:368, 1991
- McMahon MJ, Luther ER, Bowes WA, et al: Comparison of a trial of labor with an elective second cesarean section. *N Engl J Med* 335(10):689, 1996
- Melamed N, Ben-Haroush A, Chen R, et al: Intrapartum cervical lacerations: characteristics, risk factors, and effects on subsequent pregnancies. *Am J Obstet Gynecol* 200(4):388.e1, 2009
- Miller DA, Goodwin TM, Gherman RB, et al: Intrapartum rupture of the unscarred uterus. *Obstet Gynecol* 89:671, 1997
- Miller DA, Paul RH: Rupture of the unscarred uterus. *Am J Obstet Gynecol* 174:345, 1996
- Mukhopadhyay D, Jennings PE, Banerjee M, et al: Ultrasound-guided drainage of a suprallevator hematoma in a hemodynamically stable patient. *Obstet Gynecol* 126(6):1188, 2015
- Nakash A, Tuck S, Davies N: Uterine sepsis with uterine artery embolization in the management of obstetric bleeding. *J Obstet Gynecol* 32(1):26, 2012
- Narasimhulu DM, Shi S: Delayed presentation of uterine rupture postpartum. *Am J Obstet Gynecol* 212(5):680.e1, 2015
- National Institutes of Health Consensus Development Conference Panel: National Institutes of Health Consensus Development Conference Statement: Vaginal birth after cesarean: new insights. *Obstet Gynecol* 115:1279, 2010
- Nelson EL, Parker AN, Dudley DJ: Spontaneous vulvar hematoma during pregnancy: a case report. *J Reprod Med* 57(1–2):74, 2012
- Nikolaou M, Kourea HP, Antonopoulos K, et al: Spontaneous uterine rupture in a primigravid woman in the early third trimester attributed to adenomyosis: a case report and review of literature. *J Obstet Gynaecol Res* 39(3):727, 2013
- Noh JJ, Park CH, Jo MH et al: Rupture of an unscarred uterus in a woman with long-term steroid treatment for systemic lupus erythematosus. *Obstet Gynecol* 122(2 Pt 2):472, 2013
- Ojala K, Perala J, Kariniemi J, et al: Arterial embolization and prophylactic catheterization for the treatment for severe obstetric hemorrhage. *Acta Obstet Gynecol Scand* 84:1075, 2005
- Parikh R, Brotzman S, Anasti JN: Cervical lacerations: some surprising facts. *Am J Obstet Gynecol* 196(5):e17, 2007
- Pearlman MD, Cunningham FG: Trauma in pregnancy. In *Williams Obstetrics*, 19th ed. Supplement No. 21 Oct/Nov, 1996
- Pelosi MA III, Pelosi MA: Spontaneous uterine rupture at thirty-three weeks subsequent to previous superficial laparoscopic myomectomy. *Am J Obstet Gynecol* 177:1547, 1997
- Porreco RP, Clark SL, Belfort MA, et al: The changing specter of uterine rupture. *Am J Obstet Gynecol* 200(3):269.e1, 2009
- Poujade O, Zappa M, Letendre I, et al: Predictive factors for failure of pelvic arterial embolization for postpartum hemorrhage. *Int J Gynaecol Obstet* 117(2):119, 2012
- Propst AM, Thorp JM Jr: Traumatic vulvar hematomas: conservative versus surgical management. *South Med J* 91:144, 1998
- Rachagan SP, Raman S, Balasundram G, et al: Rupture of the pregnant uterus—a 21-year review. *Aust N Z J Obstet Gynaecol* 31:37, 1991
- Rafi J, Muppala H: Retroperitoneal haematomas in obstetrics: literature review. *Arch Gynecol Obstet* 281(3):435, 2010
- Ramskill N, Hameed A, Beebejaun Y: Spontaneous rupture of uterine leiomyoma during labour. *BMJ Case Rep* September 8, 2014
- Ridgway LE: Puerperal emergency: vaginal and vulvar hematomas. *Obstet Gynecol Clin North Am* 22:275, 1995
- Rodriguez MH, Masaki DI, Phelan JP, et al: Uterine rupture: are intrauterine pressure catheters useful in the diagnosis?. *Am J Obstet Gynecol* 161(3):666, 1989
- Rouse DJ: Epidemiological investigation of a temporal increase in atonic postpartum haemorrhage: a population-base retrospective cohort study. *Obstet Gynecol* 122(3):693, 2013
- Sakhare AP, Bhanap PL, Mahale AR: Bowel prolapse through colporrhesis—a complication of home delivery. *J Obstet Gynecol India* 57:553, 2007
- Schwertner-Tiepelmann N, Thakar R, Sultan AH, et al: Obstetric levator ani muscle injuries: current status. *Ultrasound Obstet Gynecol* 39(4):372, 2012
- Sentilhes L, Gromez A, Clavier E, et al: Predictors of failed pelvic arterial embolization for severe postpartum hemorrhage. *Obstet Gynecol* 113:992, 2009
- Sheth SS: Results of treatment of rupture of the uterus by suturing. *J Obstet Gynaecol Br Commonw* 75(1):55, 1968
- Spong CY, Landon MB, Gilbert S, et al: Risk of uterine rupture and adverse perinatal outcome at term after cesarean delivery. *Obstet Gynecol* 110(4):801, 2007
- Stanirowski PJ, Trojanowski S, Sloma A, et al: Spontaneous rupture of the pregnant uterus following salpingectomy: a literature review. *Gynecol Obstet Invest* 80(2):73, 2015
- Takeda A, Koike W, Imoto S, et al: Three-dimensional computerized tomographic angiography for diagnosis and management of intractable postpartum hemorrhage. *Eur J Obstet Gynecol Reprod Biol* 176:104, 2014
- Tarney CM, Whitecar P, Sewell M, et al: Rupture of an unscarred uterus in a quadruplet pregnancy. *Obstet Gynecol* 121 (2 Pt 2 Suppl 1):483, 2013
- Tola EN: First trimester spontaneous uterine rupture in a young woman with uterine anomaly. *Case Rep Obstet Gynecol* 2014:967386, 2014
- Usta IM, Hamdi MA, Musa AA, et al: Pregnancy outcome in patients with previous uterine rupture. *Acta Obstet Gynecol Scand* 86(2):172, 2007
- Weir LF, Pierce BT, Vazquez JO: Complete fetal transection after a motor vehicle collision. *Obstet Gynecol* 111(2 Pt 2):530, 2008
- Wen SW, Huang L, Liston R, et al: Severe maternal morbidity in Canada, 1991–2001. *CMAJ* 173(7):759, 2005
- Zahn CM, Yeomans ER: Postpartum hemorrhage: placenta accreta, uterine inversion and puerperal hematomas. *Clin Obstet Gynecol* 33:422, 1990

CHAPTER 31

Uterine Inversion

CLASSIFICATION	493
ETIOLOGY	494
DIAGNOSIS	495
MANAGEMENT	495
MATERNAL MORBIDITY AND MORTALITY	500
REINVERSION	500
SUBSEQUENT PREGNANCY	501

Uterine inversion is a rare complication of the third stage of labor but is potentially life-threatening. Although largely preventable, some occurrences are unavoidable. Prompt recognition and management are critical to reduce maternal morbidity and mortality rates, mainly due to hemorrhage.

CLASSIFICATION

The classification systems of uterine inversion are based on either the duration or magnitude of the inversion. Criteria are

found in [Table 31-1](#), and examples are seen in [Figures 31-1](#) and [31-2](#) (Kitchin, 1975; Livingston, 2007; Pauleta, 2010; Watson, 1980; You, 2006). Most are acute and second- or third-degree inversions (Baskett, 2002; Brar, 1989; Dali, 1997; Morini, 1994; Platt, 1981; Shah-Hosseini, 1989; Witteveen, 2013).

INCIDENCE

The reported incidence of uterine inversion varies widely, which may be due to differences in definition, patient populations, and awareness and recognition. The reported incidence ranges from 1 in 500 to 1 in more than 57,000 deliveries (Baskett, 2002; Bunke, 1965; Das, 1940; Hostetler, 2000; Morini, 1994; Shah-Hosseini, 1989; Watson, 1980; Witteveen, 2013). Two single-institution reports that analyzed long epochs cite incidences of 1 in 1860 during cesarean delivery, 1 in 3737 during vaginal delivery, and 1 in 6403 in all delivery settings (Baskett, 2002; Shah-Hosseini, 1989). In a nationwide population-based study, the incidence was 1 in 20,000 vaginal births (Witteveen, 2013).

Previously, uterine inversion during cesarean delivery was considered rare (Chatzistamatiou, 2014; Witteveen, 2013). However, in one series, the incidence of inversion during cesarean delivery was actually twice that associated with vaginal

TABLE 31-1. Classification Systems of Uterine Inversion

System	Categorization	Definition
Duration	Acute	Diagnosed within 24 hr of delivery
	Subacute	Diagnosed >24 hr after delivery but <4 wks postpartum
	Chronic	Diagnosed >4 wks postpartum
Extent	First degree (incomplete)	Fundus does not protrude through cervix
	Second degree (complete)	Fundus protrudes through cervical os
	Third degree (prolapse)	Fundus protrudes to or beyond the introitus
	Fourth degree (total)	Inversion of the uterus and vagina

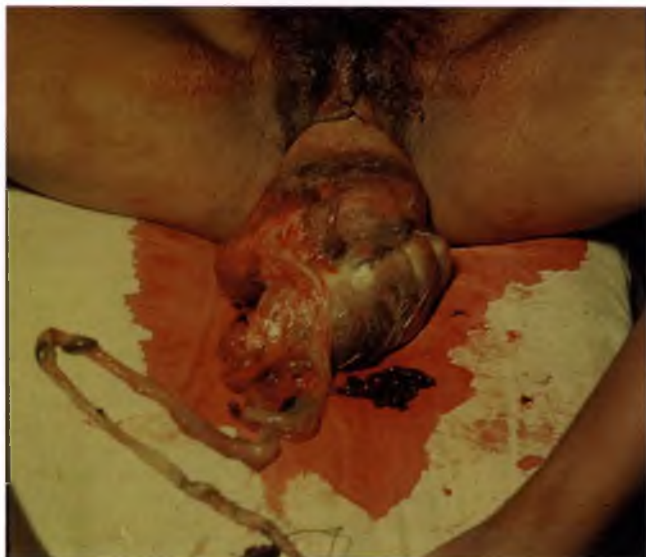

FIGURE 31-1 Complete uterine inversion. The uterus is completely prolapsed and the placenta is still attached to the fundus. (Reproduced with permission from Cunningham FG, Leveno KL, Bloom SL, et al (eds): Hemorrhage. In Williams Obstetrics, 24th ed. New York, McGraw-Hill Education, 2014.)

delivery (Baskett, 2002). As one explanation, management of third-stage labor during cesarean delivery has varied over time and ranged from immediate manual extraction of the placenta to cord traction to promote spontaneous expulsion, which is

an inversion risk. Second, inversion during cesarean delivery is typically recognized and managed more expediently than at vaginal delivery. Accordingly, rates of significant clinical complications such as severe hemorrhage and blood transfusion are lower (Baskett, 2002; Terp, 1998).

ETIOLOGY

Several items have historically been associated with uterine inversion, although no particular factor has been demonstrated conclusively to pose significant risk. Mismanagement of third-stage labor may include excessive cord traction and the Credé maneuver (Das, 1940; Kitchin, 1975; Watson, 1980; You, 2006). With this maneuver, the abdomen is grasped by one hand so that the thumb rests on the anterior fundus and the fingers on the posterior fundus, while firm, steady pressure is directed caudally in the axis of the superior strait. Other reported factors are a short umbilical cord, fundal placental implantation, congenital weakness of the uterine wall, rapid labor and delivery, oxytocin or magnesium sulfate use, and primiparity (Adesiyun, 2007; Brar, 1989; Das, 1940; Kitchin, 1975; Platt, 1981; Witteveen, 2013). Importantly, although mismanagement of third-stage labor is often implicated, this association remains unproven (Shah-Hosseini, 1989; Watson, 1980). In fact, active management of this labor stage may be protective. Baskett (2002) described an active management of third-stage labor that consisted of administration of oxytocin (5 units intravenously [IV] or 10 units intramuscularly [IM]) after delivery of the anterior shoulder.

Implementation of this protocol reduced the incidence of uterine inversion fourfold compared with a prior epoch in which active management was not used.

Whether retained placenta or placenta accreta, or its variants, are associated with uterine inversion is unclear. Specifically, morbidly adherent placenta, which is another term for placenta accreta, is described as a risk for inversion in case reports and in older series. However, this link has not been specifically addressed in more recent articles (Agarwal, 2005; Das, 1940; Hostetler, 2000; Kitchin, 1975). For example, manual removal of the placenta is a suggested risk from newer studies, but a specific association with this maneuver for an undiagnosed morbidly adherent placentation has not been analyzed (Baskett, 2002; Kitchin, 1975; Shah-Hosseini, 1989; Watson, 1980). Moreover, although the prevalence of placenta accreta has risen, a specific association with uterine inversion is described only in case reports (Agarwal, 2005; Tsivos, 2009). Yet, despite a lack of extensive data regarding a link, placenta accreta, particularly if unrecognized, may predispose to uterine inversion and should be kept in mind. This is particularly important in light of the higher cesarean delivery rate in current obstetric practice.

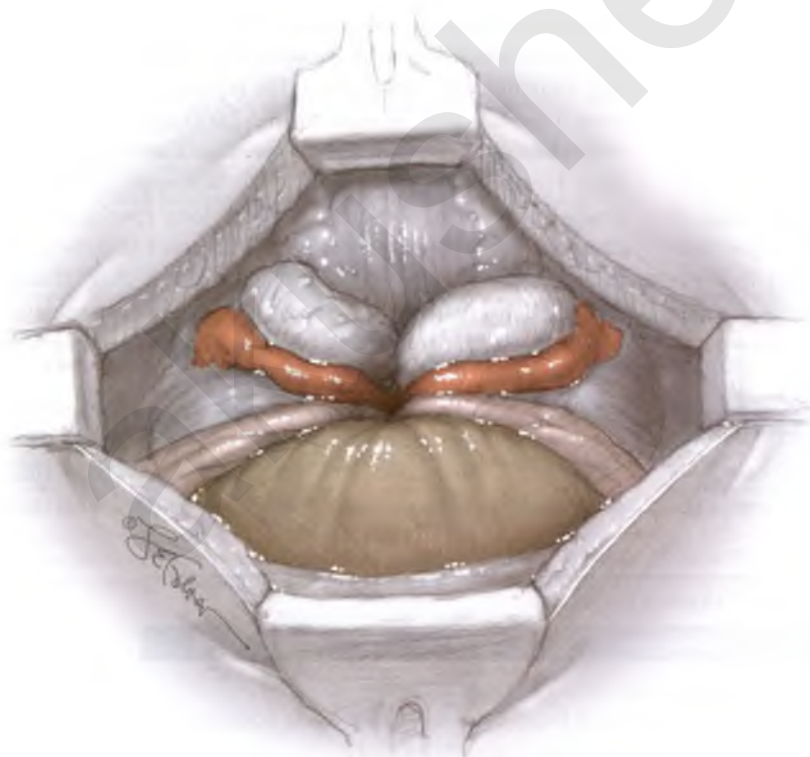

FIGURE 31-2 Depiction of uterine inversion from an abdominal perspective. The inverted fundus appears as a "dimple" with the fallopian tubes and round ligaments drawn into the inversion. The bladder and ovaries rim the top of the "dimple."

DIAGNOSIS

The signs and symptoms of uterine inversion depend to some degree on its acuity and extent. Classically, bleeding, pain, and an intravaginal or protruding mass are found, and the fundus cannot be palpated abdominally. Since most cases are acute and complete, severe hemorrhage is typical and leads to shock with hypotension, altered mental status, and cool, pale skin. Historically, “shock out of proportion to blood loss” has been described. This degree of shock has been attributed to stretching of the pelvic parasympathetic nerves and subsequent increased vagal stimulation. However, no solid evidence supports this supposition. Instead, the degree of shock more likely represents an underestimated blood loss (Baskett, 2002; Beringer, 2004; Das, 1940; Hostetler, 2000; Kitchin, 1975; Platt, 1981; Shah-Hosseini, 1989; Watson, 1980).

Incomplete uterine inversion, although less common, may be more challenging to detect (Morini, 1994). Bleeding may be lighter. Also, vaginal examination may be less clear due to absence of a large vaginal mass and the possibility of still being able to palpate part of the fundus abdominally. For these reasons, incomplete inversion is more likely to be associated with the subsequent diagnosis of subacute or chronic inversion. With chronic inversion, urinary retention may be another finding (Thakur, 2014).

The vast majority of uterine inversion cases are diagnosed clinically, and life-saving management should not be delayed to obtain confirmatory imaging. Imaging may be most helpful with incomplete inversion or with a delayed diagnosis. Sonographic findings for both incomplete and complete inversion include a “mirror sign,” in which the uterus has a U-shaped cavity due to the inverted fundus extending to the cervical os. A “pseudostripe” can be formed by the opposing uterine serosal surfaces. Also, a “target sign” represents the hyperechoic inverted fundus, which is surrounded by the hypoechoic lower uterine segment (Pan, 2015; Rana, 2009; Thakur, 2014). Another sign is the appearance of the ovary(ies) at the indentation site of the inverted uterus (Smulian, 2013). Three-dimensional sonographic imaging has also been used to diagnose incomplete inversion (Pauleta, 2010). In uncertain cases, magnetic resonance (MR) imaging can provide additional anatomic detail (Thakur, 2014). T1-weighted images are usually uninformative, but T2-weighted images can show an inverted cavity. The adnexa and round ligaments may appear to be drawn into this cavity. In addition to diagnosis, sonography can confirm uterine repositioning (Smulian, 2013).

MANAGEMENT

■ General Considerations

Effective management of uterine inversion requires prompt recognition and quick mobilization of resources to minimize maternal morbidity and mortality. If immediate manual replacement fails, transfer to the operating room is considered early in the process to allow hemodynamic monitoring, to restore intravascular volume by administration of fluids and blood products, and to manage hemorrhage. Anesthesiology staff is ideally immediately available. They can assist with volume resuscitation and administer uterine relaxants or tocolytics. They may be called upon to provide general anesthesia for

additional manual vaginal manipulations or for rapid conversion to laparotomy.

As outlined in [Figure 31-3](#), general principles of management include:

1. Promptly recognize and notify support personnel, operating room staff, and anesthesiology providers
2. Withhold uterotonic agents and immediately attempt manual replacement of the uterus with the placenta attached, if possible
3. Administer uterotonic agents if the uterus is successfully repositioned to prevent further atony and repeat inversion
4. Respond early and aggressively to ongoing hemorrhage. This will include serial assessment of vital signs, placement of large-bore IV lines, infusion of crystalloid solution in a 3:1 ratio to estimated blood loss, and activation of postpartum hemorrhage transfusion protocols
5. Obtain blood samples to monitor ongoing blood loss and identify potential disseminated intravascular coagulopathy. Tests include complete blood count (CBC), prothrombin time (PT), partial thromboplastin time (PTT), international normalized ratio (INR), and haptoglobin and fibrinogen levels.

Recent data from the battlefield and trauma centers have shown decreased mortality rates in nonobstetric populations when massive transfusion protocols are used. These involve fresh-frozen plasma:packed red blood cell (FFP:pRBC) ratios of 1:1, 1:1.5, or 1:1.8 (Gonzalez, 2007; Riskin, 2009). Components to be considered and massive transfusion protocols are addressed in greater detail in [Chapter 7](#) (p. 98).

■ Nonsurgical Management

Manual Repositioning

As noted, uterine inversion may occur during vaginal or cesarean delivery, and general steps to reduce it are similar. First, replacement of uterine inversion should be attempted immediately after diagnosis. Manual replacement of the uterus, termed the Johnson maneuver, involves pushing the inverted fundus toward the umbilicus.

With an inversion after vaginal delivery, the fundus is elevated through the contracted myometrial ring, which forms at the upper cervix, to restore normal positioning ([Figs. 31-4](#) and [31-5](#)) (Johnson, 1949). Placing ring forceps on the cervical ring may aid effective countertraction (Henderson, 1948; Kitchin, 1975). If the placenta is still attached, it should remain in place until after reduction of uterine inversion. Premature placental removal can worsen bleeding from the placental site (Watson, 1980).

If an initial manual replacement attempt is unsuccessful, administration of a tocolytic agent can induce myometrial relaxation. This can assist further uterine manipulation and potentially avoid more extensive surgery. Suitable options are terbutaline, ritodrine, nitroglycerine, or magnesium sulfate. The last is preferred if hypotension is present. Dosages are listed in [Table 31-2](#). If still unsuccessful, further attempts at manual reduction are made with the patient under general anesthesia. Abouleish and coworkers (1995) reviewed anesthetic management in 18 cases of acute uterine inversion. Manual repositioning of the uterus was successful in 4 cases (22 percent) without need for any tocolytic agent. Eight women received a single

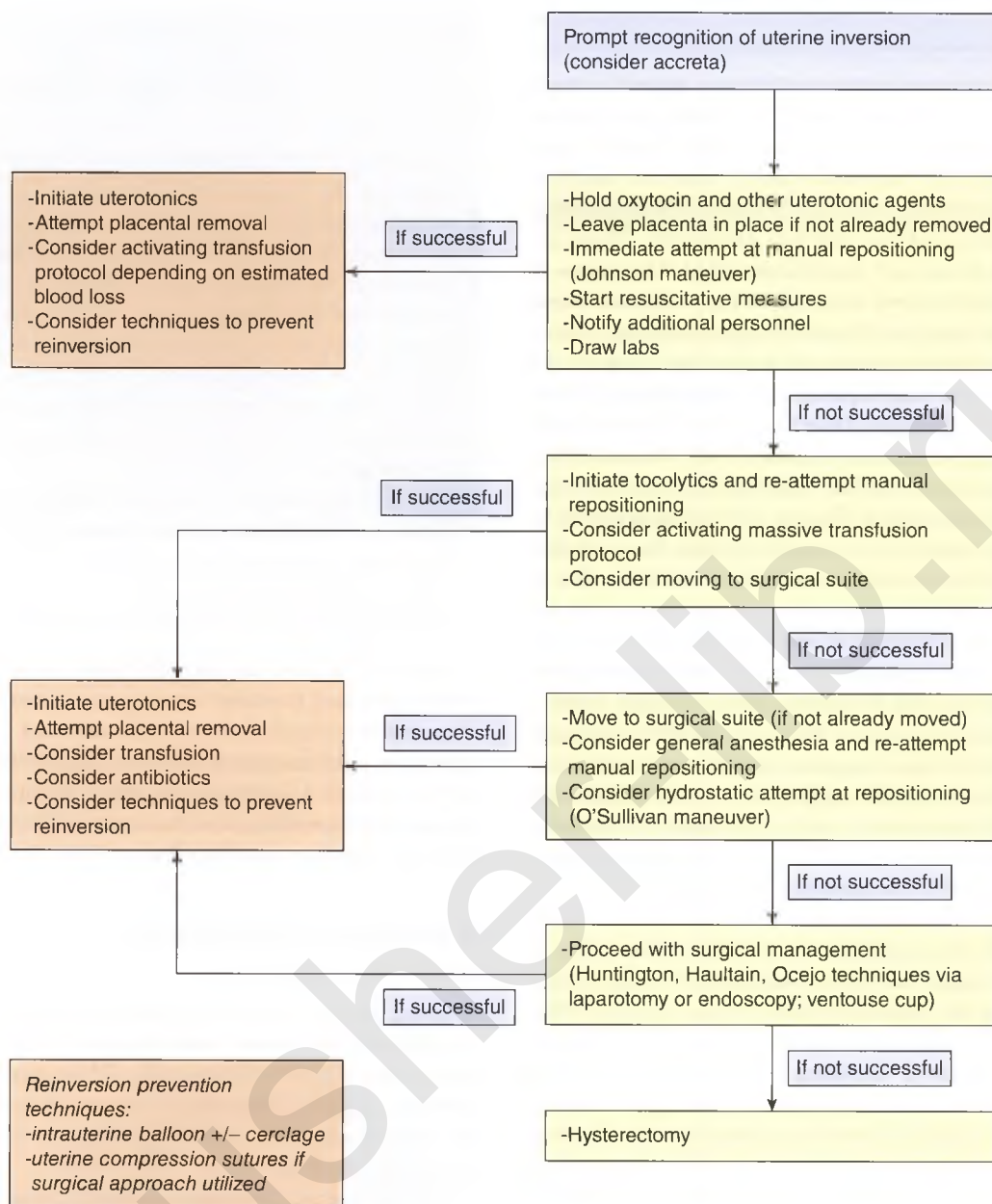


FIGURE 31-3 Management algorithm for uterine inversion.

TABLE 31-2. Potential Medications to Achieve Uterine Relaxation

Agent	Dose	References
Terbutaline	0.25 mg IV or IM	Brar, 1989
Ritodrine	0.15 mg IV	Clark, 1985
MgSO ₄	2–4 g IV over 5–10 minutes	Catanzarite, 1986
Nitroglycerine	100 µg IV 50 µg IV, sequential doses × 4	Dayan, 1996 Zechmeister, 2011

IM = intramuscular; IV = intravenous; MgSO₄ = magnesium sulfate.

dose of 0.25 mg IV terbutaline, with 5 (63 percent) achieving successful uterine reduction. General anesthesia was required in the other 3 cases. The remaining 6 patients underwent general anesthesia as the initial management approach.

If manual replacement is successful, the placenta is then removed. The operator's hand should remain inside the uterus until uterotonic agents can be administered and uterine contractions ensue (Fig. 31-6). Suitable options include: oxytocin, 20 units in 1 L of lactated Ringer solution; methylergonovine maleate (Methergine), 0.2 mg IM every 2 hours; carboprost tromethamine (PGF_{2α}) (Hemabate), 250 µg IM or intrauterine injection every 15 to 90 minutes; or misoprostol (PGE₁) (Cytotec), 800 to 1000 µg once rectally. These are discussed additionally in Chapter 29 (p. 470).

Hydrostatic Techniques

As originally described by O'Sullivan in 1945, hydrostatic pressure can be used to reposition the uterus. With this technique, 2 L of warmed normal saline is rapidly infused via

tubing placed into the vagina. To achieve a watertight seal and thus adequate pressure for replacement, the introitus is occluded with the operator's hand or forearm. To generate sufficient gravity for rapid infusion, the two IV bags are elevated 2 meters above the level of the supine patient. In general, failure of this hydrostatic approach usually stems from inadequate pressure, either because of slow infusion or escape of fluid through the vaginal introitus.

If uterine repositioning is successful, the fluid is allowed slow egress from the vagina, and uterotonic agents are administered. Momani and colleagues (1989) described successful use of this technique in five cases, and the fundus was repositioned within 5 to 10 minutes. A modification of this technique uses a Silc Cup (AB Menox), which is a Silastic cup normally used for vacuum-assisted operative vaginal delivery (Fig. 31-7). The cup is inserted into the vagina to improve the water seal (Oguch, 1997; Tan, 2005). As another alternative, Gupta and associates (2014) described use of a transurethral resection of prostate set (TURP set) in six cases. The set contained two 3-L bags of warm saline to generate sufficient pressure for effective reduction of uterine inversion.

Intrauterine Balloon Tamponade

Once the inverted uterus has been repositioned, an intrauterine balloon may be

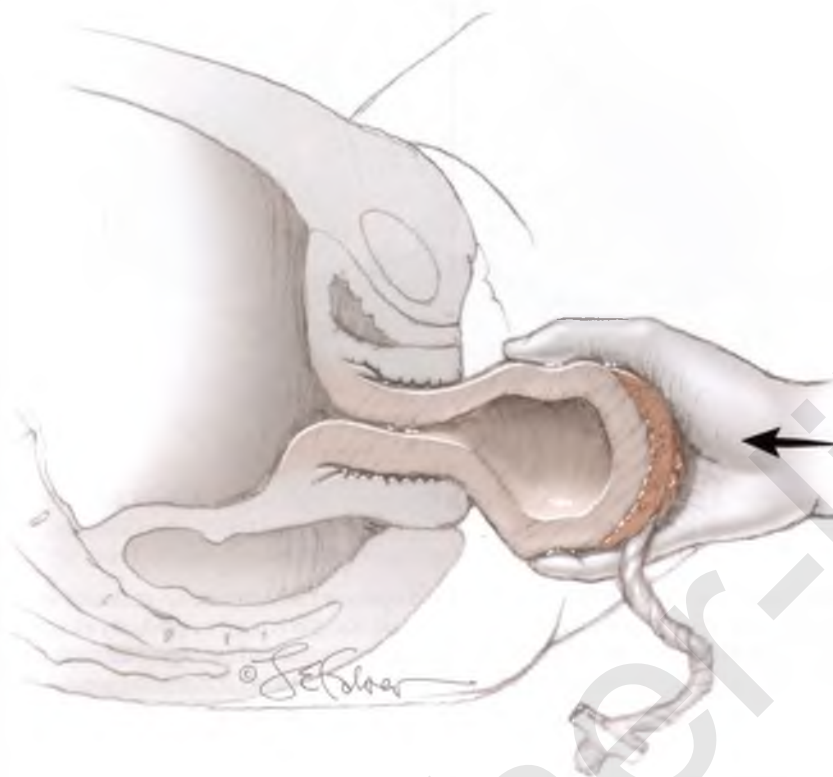

FIGURE 31-4 Manual reduction of uterine inversion (Johnson maneuver). Note that the placenta is left in situ until reduction of prolapse is achieved. Initially, the fundus is grasped and moved cephalad.

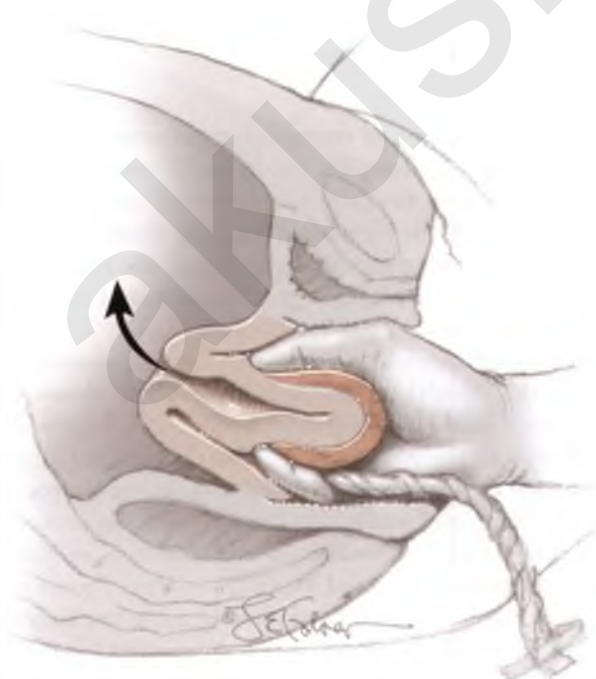


FIGURE 31-5 With insertion, pressure is directed to the center of the fundus to help reverse the inversion.

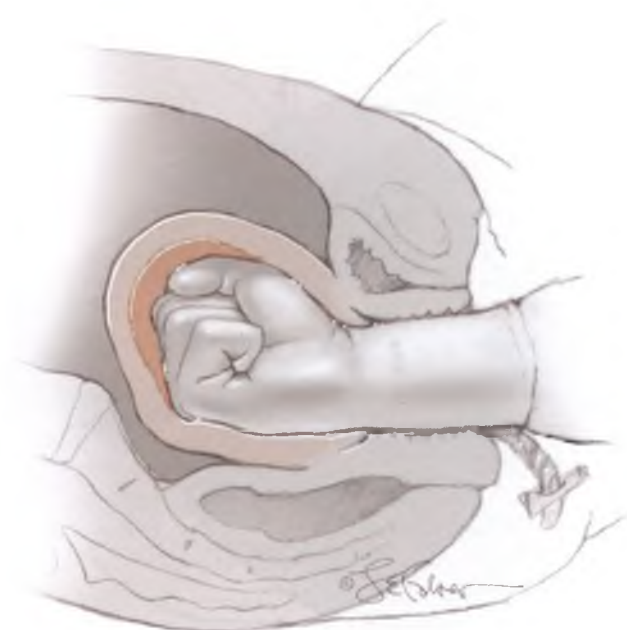


FIGURE 31-6 The operator's hand should remain in the uterine cavity after removal of the placenta until uterine contraction is achieved with the administration of uterotonic agents.

used to complement management. As with treatment of postpartum hemorrhage, the expanded balloon provides pressure inside the uterine cavity to help control hemorrhage and potentially decrease the reinversion risk.

Of devices, a Bakri Postpartum Balloon (Cook Medical) is widely available (Fig. 29-5, p. 473). Case reports describe its use to maintain correct uterine position following the Huntington procedure, described in the next section (Kaya, 2014; Soleymani Majd, 2009). Other suitable devices include the Rusch urologic balloon catheter (Teleflex Inc.) and the ebb Complete Tamponade System (Clinical Innovations), which has distinct, tandem vaginal and uterine balloons (Haeri, 2014; Keriakos, 2011; Majumdar, 2010; Uzoma, 2010). For the Rusch system, these authors credit its ease of use and large capacity. With the ebb system, they note the effectiveness of the vaginal balloon to prevent expulsion of the uterine balloon. An additional modification was described by Marasinghe and colleagues (2015), in which a transvaginal cerclage was placed to prevent expulsion of the tamponade device through the cervix. Notably, use of an intrauterine balloon may be ineffective in cases with uterine anomalies.

The balloon is not left in the uterus for more than 24 hours, although some providers have reported use for up to 48 hours

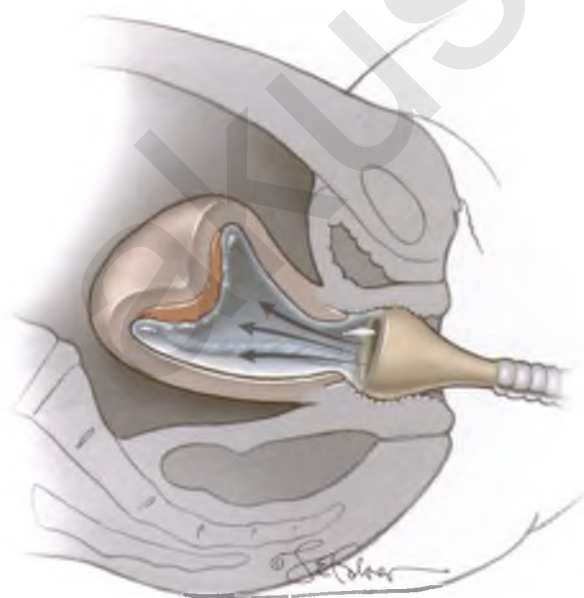


FIGURE 31-7 Hydrostatic replacement. The introitus can be occluded with either the operator's hand or with a soft vacuum cup to improve the seal, as depicted.

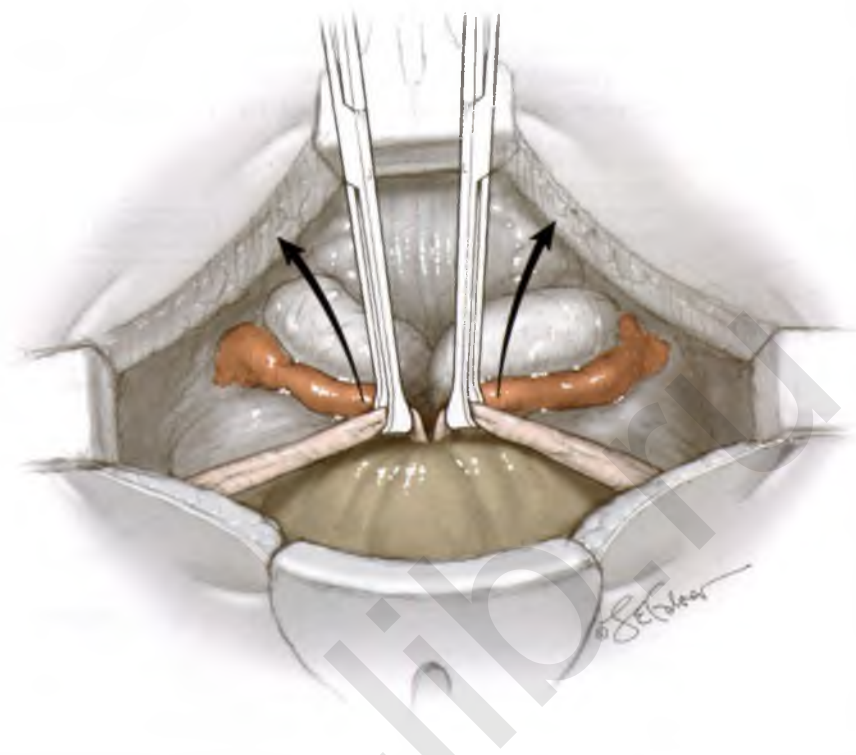


FIGURE 31-8 Huntington technique. The round ligaments are grasped on each side with a Babcock clamp. Gently curving upward and outward traction is used to gradually elevate the fundus. As a modification of the technique, a soft vacuum cup can be passed through the constricted cervical ring and applied on the inverted fundus to aid upward traction.

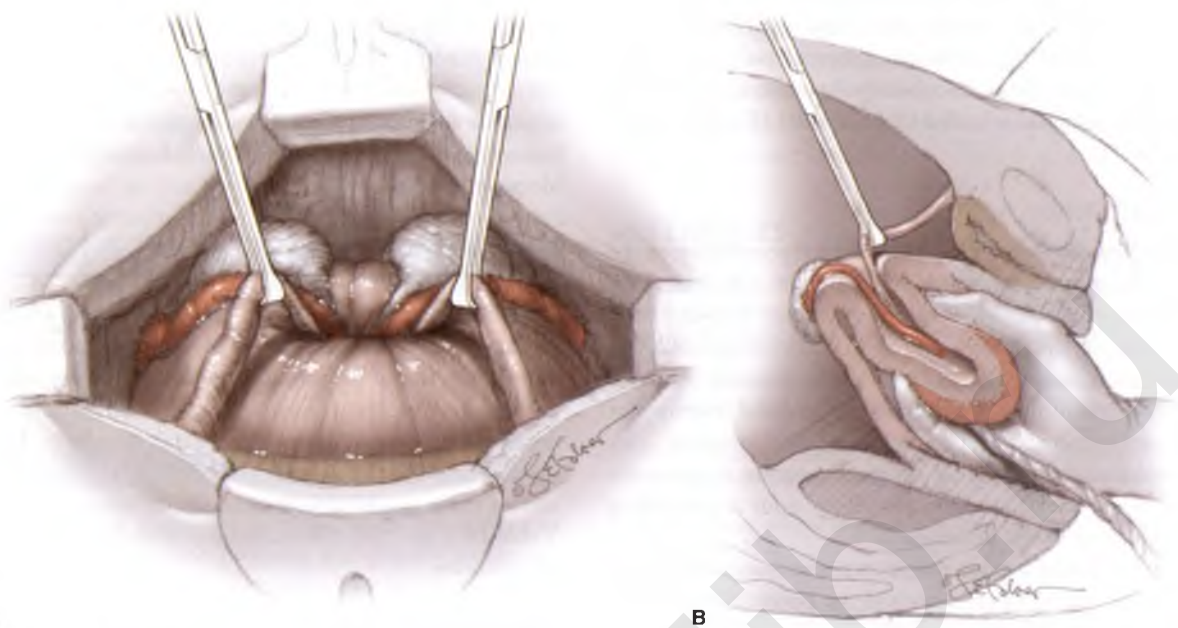
(Soleymani Majd, 2009). No studies guide the use of antibiotics in cases of uterine inversion managed with intrauterine balloon devices. However, most authors report the use of antibiotic prophylaxis while the intrauterine balloon is in place.

■ Surgical Management

Traditional Approaches

At times, a tight ring of contracted myometrium above the cervix can prohibit inversion reduction. If manual replacement under general anesthesia is unsuccessful, potential surgical maneuvers include vaginal and transabdominal approaches. Laparotomy is more commonly selected, and the Huntington, Ocejo, and Haultain techniques have been described (Hostetler, 2000; Shah-Hosseini, 1989; You, 2006).

Of these, the Huntington approach employs upward traction on the round ligaments and the uterus to elevate and reduce the inverted fundus (Huntington, 1928). To provide a greater opening through which to elevate the fundus, a surgeon may stretch the taut myometrial ring with fingers or open the jaws of a stiff clamp within the ring. The round ligaments are grasped as medially as possible on each side with an Allis or similar clamp (Figs. 31-8 and 31-9). On each side, gentle traction is exerted in an upward and outward arc to gradually elevate the fundus. As the fundus rises and the inversion corrects, each clamp is repositioned to grab a more medial purchase of the round ligament along its length. The step is repeated serially to correct the inversion. During these steps, a fist in the vagina



A

B

FIGURE 31-9 **A.** As the fundus rises and the inversion corrects, each Babcock clamp is repositioned to grab a more medial purchase of the round ligament along its length. The step is repeated serially to correct the inversion. **B.** Vaginal elevation against the inverted fundus can simultaneously provide gentle upward force.

and against the inverted fundus can simultaneously provide gentle upward force. Accordingly, initial patient positioning in low dorsal lithotomy for laparotomy may be considered to provide vaginal access and ongoing blood loss assessment.

If the myometrial ring is significantly constricted, incising the anterior cervix (Ocejo) or posterior cervix (Haultain) may be helpful in restoring normal anatomy (Haultain, 1901; Huntington, 1928). With the Haultain incision, a malleable

retractor is placed vaginally between the posterior uterine wall and posterior cervix (Fig. 31-10). Positioned at the planned incision site, this retractor minimizes cervical, vaginal, and bowel laceration. In addition, the rectosigmoid is held laterally during incision of the myometrial ring (Fig. 31-11). Once the ring is opened, the fundus is repositioned by the Huntington technique. Following repositioning, the myometrial incision is closed in one or two layers with absorbable or delayed-absorbable suture.

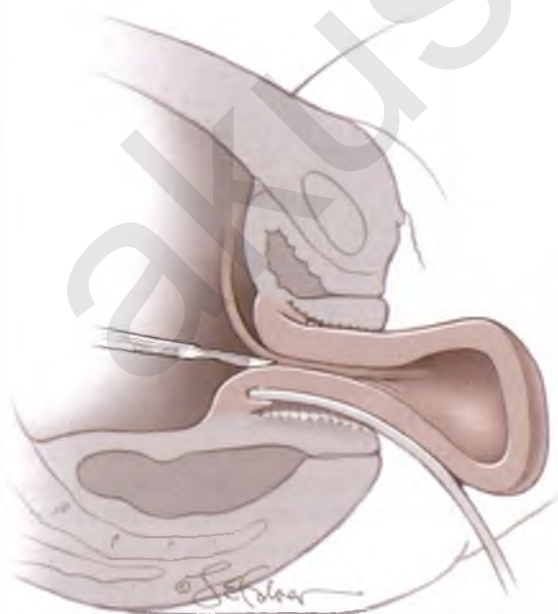


FIGURE 31-10 Haultain technique. A ribbon retractor is placed between the posterior uterine wall and rectum to avoid bowel laceration during myometrial incision.

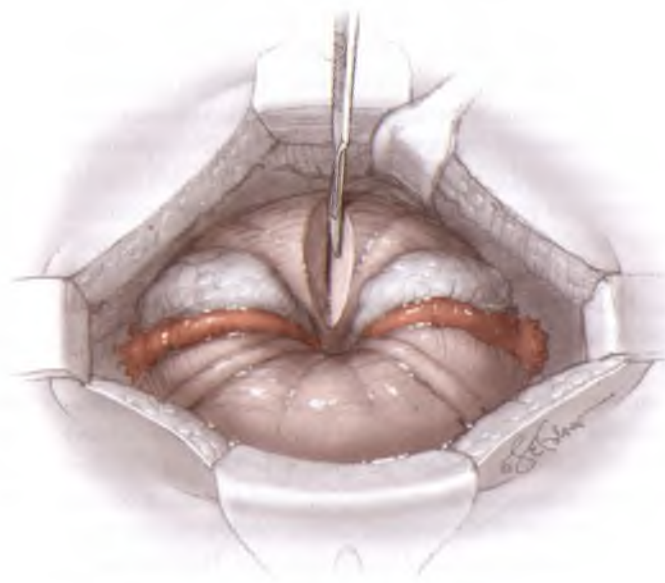


FIGURE 31-11 Due to the constricted cervical ring, the posterior cervix is incised abdominally. Once the constriction is released, the uterine fundus can be elevated as in Figure 31-9.

Vaginal approaches are used less commonly for acute inversion and may be more suitable for chronic inversion. With these, an incision of the constricting myometrial ring can be made, either anteriorly as described by Spinelli, or posteriorly (Kustner procedure) as reported by Cascarides (Kitchin, 1975; Spinelli, 1897).

Novel Approaches

Newer management methods address both repositioning of the inverted uterus and prevention of recurrence. Of these, one technique uses an obstetric ventouse (vacuum) to correct the inversion during laparotomy. Antonelli and colleagues (2006) applied a Silastic cup (Silc cup) during laparotomy onto the inverted uterine fundus after initial unsuccessful attempts at manual replacement. They then reduced the inversion with gentle cephalad traction. This approach may be a reasonable modification of the Huntington procedure, prior to proceeding with Haultain or Oejo incisions.

Given the risk of uterine reinversion after successful fundal repositioning during laparotomy and the potential for continued hemorrhage, compression sutures can provide hemostasis and decrease the risk of acute recurrent inversion. Matsubara and coworkers (2009), using no. 1 delayed-absorbable suture, successfully placed several through-and-through longitudinal stitches that passed from the serosa of the anterior uterus through to the serosa of the posterior uterus. Unlike B-Lynch stitches, these did not arch over the fundus. These were followed by two similar through-and-through horizontal sutures. Sutures tightly apposed the anterior and posterior uterine walls to compress the uterine cavity. To achieve similar compression and apposition, other options include B-Lynch type sutures or Hayman sutures (Matsubara, 2009; Mondal, 2012). These are described and illustrated in Chapter 29 (p. 473) and can control postpartum hemorrhage and reinversion.

Also to prevent reinversion, transabdominal cervical cerclage has been described to treat chronic recurrent uterine inversion (Garrett-Albaugh, 2011). In this case, the acute inversion was reduced manually, and the patient presented with recurrent uterine inversion 39 days postpartum. Attempts at vaginal uterine replacement were unsuccessful, and laparotomy with division of posterior cervix was required to achieve repositioning. An abdominal cerclage was then placed to prevent possible reinversion and potential future cervical insufficiency given the cervical incision. There are no data on rates of cervical insufficiency after the Haultain or Oejo procedures, although theoretical concerns exist. Placement of abdominal cerclage is described in Chapter 11 (p. 174).

A few case reports describe a laparoscopic approach to manage uterine inversion. In one case of acute inversion, cephalad traction on the round ligaments was insufficient to achieve sufficient traction for reduction. Thus, a Teflon rod was used to maintain a constant downward and caudal pressure on one aspect of the apex of the inverted uterus, while a vaginal hand maintained constant cephalad counterpressure. This allowed for complete reduction of the inversion (Vijayaraghavan, 2006).

For chronic uterine inversion, laparoscopic correction has also been described, including successful robotically assisted repositioning (Sardeshpande, 2009; Shepherd, 2010; Zech-

meister, 2011). In some of these cases, the anterior cervix and lower uterine segment were incised to achieve repositioning. Although advantages of laparoscopy include smaller incisions, less pain, quicker recovery, and shorter hospital stay, this approach requires laparoscopic expertise and infrastructure for emergent laparoscopy in a potentially hemodynamically unstable patient.

ANTIBIOTIC PROPHYLAXIS

After replacement, the value of prophylactic antibiotics is unclear and is individualized. Most case reports and series include the use of prophylactic antibiotics, especially if manual removal of the placenta is employed. Additionally, as described on page 498, antibiotics are typically included if an intrauterine balloon is inserted. Suitable regimens and doses mirror those given prior to cesarean delivery and are listed in Table 18-4 (p. 296). One common option is a single 2-g dose of cefazolin.

MATERNAL MORBIDITY AND MORTALITY

Unquestionably, uterine inversion may be a potentially life-threatening situation, particularly if diagnosis and treatment are delayed. Delays can lead to severe hemorrhage, cervical contraction ring formation, and difficulty in repositioning. A slow response to blood loss, including a delay in implementing a transfusion protocol, can be catastrophic.

Previously reported mortality rates ranged from 12 to 41 percent. However, in areas with appropriate resources and in more modern obstetric practice, death is rare (Baskett, 2002; Das, 1940; Kitchin, 1975; Watson, 1980; Witteveen, 2013). Morbidity, however, is still significant, primarily related to hemorrhage, shock, and potential transfusion-related complications. Additional surgery, if required, also adds to morbidity, and infection is a significant concern (Shah-Hosseini, 1989).

Although rare, cardiac arrest has been reported as a complication of inversion, including during cesarean delivery (Khalil, 2006; Marshall, 2010; Nag, 2015). In one case, bradycardia preceded the arrest, leading to the theory that blood loss and parasympathetic stimulation due to traction on the uterine ligaments prompted the arrest (Nag, 2015). These authors concluded that cardiac arrest following uterine inversion may therefore occur with hypovolemia or normovolemia. In another case, a patient developed pulseless electrical activity (PEA) after repositioning of the uterus. The cardiac event was not considered strictly related to hemorrhage since accumulated blood loss at the time of PEA was not deemed excessive (Marshall, 2010). In addition to severe blood loss, these authors concluded that air embolism or neurogenic causes may have a role in cardiac arrest proximate to uterine inversion. Thus, clinicians should be aware of this potential, albeit rare, complication of uterine inversion.

REINVERSION

Uterine atony commonly follows successful repositioning of the uterus and may stem from uterine relaxants given to aid

repositioning. If atony persists, the uterus may invert again acutely and lead to further hemorrhage and potential morbidity. Uterotonic agents are critical to decrease the risk of reinversion.

Management of recurrent inversion in the acute setting is essentially the same as for the initial episode. As addressed in the “Management” section (p. 497), additional techniques to prevent recurrence include cerclage, intrauterine balloon, and uterine compression sutures (Garrett-Albaugh, 2011; Matsubara, 2009, 2013; Soleymani Majd, 2009; Witteveen, 2013). Importantly, repeat inversion may not develop to the same extent or level as the initial occurrence. This can lead to delayed diagnosis or chronic inversion.

SUBSEQUENT PREGNANCY

Few reports address outcomes in pregnancies subsequent to those complicated by uterine inversion, and thus the recurrence risk is unknown. In one report spanning 24 years from a single institution, 20 women subsequently delivered at the same institution, including one woman with three subsequent deliveries. None had a uterine inversion recurrence (Baskett, 2002). One case report describes a woman with a prior inversion, requiring a Huntington procedure to reposition the uterus and uterine compression sutures to prevent recurrence. Three years later, she was delivered of a term neonate vaginally, uterine inversion recurred, and it was successfully managed with manual repositioning (Matsubara, 2009).

A potential consideration in the setting of a pregnancy subsequent to one complicated by inversion is the route of delivery. There are essentially no data specifically addressing this issue, and the route of delivery was not addressed in the 24-year review reported by Baskett (2002). Conceivably, manual repositioning via a vaginal route should not prevent an attempt at labor and vaginal delivery in a subsequent pregnancy. However, if surgical correction is required, particularly if the cervix or uterine wall is incised to assist replacement, then discussions regarding route of delivery in a subsequent pregnancy become more challenging. In one report in which an incision in the anterior uterine wall and the constricting ring was necessary to reposition the uterus, cesarean delivery was recommended for a subsequent pregnancy (Tank Parakshit, 2004).

In women who required surgical correction of uterine inversion in an antecedent pregnancy, the discussion during a subsequent pregnancy regarding delivery route is ideally conducted early in the antenatal period. A multidisciplinary approach that includes perinatology and anesthesia providers may be beneficial during this counseling.

SUMMARY

Uterine inversion, although rare, is a potentially life-threatening and significant cause of maternal morbidity. Prompt recognition and intervention are critical to manage these cases to minimize morbidity. Manual repositioning is attempted, and placental removal ideally waits until after the uterus is successfully repositioned. If repositioning is successful, uterotonic agents are then

administered. If manual repositioning attempts are not successful, other surgical and nonsurgical options may be effective. Aggressive fluid resuscitation, including blood transfusion, is considered early in the process. Although uncommon, team-based drills would likely be beneficial to prepare all involved in a potential uterine inversion.

REFERENCES

- Abouleish E, Ali V, Joumaa B, et al: Anaesthetic management of acute puerperal uterine inversion. *Br J Anaesth* 75:486, 1995
- Adesiyun AG: Septic postpartum uterine inversion. *Singapore Med J* 48:943, 2007
- Agarwal S, Minocha B, Dewan R: Uterine inversion and concomitant perforation following manual removal of placenta. *Int J Gynaecol Obstet* 88:144, 2005
- Antonelli E, Irion O, Tolck P, et al: Subacute uterine inversion: description of a novel replacement technique using the obstetric ventouse. *BJOG* 113:846, 2006
- Baskett TF: Acute uterine inversion: a review of 40 cases. *J Obstet Gynaecol Can* 24:953, 2002
- Beringer RM, Pateril M: Puerperal uterine inversion and shock. *Br J Anaesth* 92:439, 2004
- Brar HS, Greenspoon JS, Platt LD, et al: Acute puerperal uterine inversion. New approaches to management. *J Reprod Med* 34:173, 1989
- Bunke JW, Hofmeister FJ: Uterine inversion—obstetrical entity or oddity. *Am J Obstet Gynecol* 91:934, 1965
- Catanzarite VA, Moffitt KD, Baker ML, et al: New approaches to the management of acute puerperal uterine inversion. *Obstet Gynecol* 68(3 Suppl):7S, 1986
- Chatzistamatiou K, Daniilidis A, Chatzis P, et al: Uterine inversion after controlled cord traction during caesarean section: a case report. *Clin Exp Obstet Gynecol* 41:476, 2014
- Clark SL: Use of ritodrine in uterine inversion. *Am J Obstet Gynecol* 151:705, 1985
- Cunningham FG, Leveno KL, Bloom SL, et al (eds): Hemorrhage. In *Williams Obstetrics*, 24th ed. New York, McGraw-Hill Education, 2014
- Dali SM, Rajbhandari S, Shrestha S: Puerperal inversion of the uterus in Nepal: case reports and review of the literature. *J Obstet Gynaecol Res* 23:319, 1997
- Das P: Inversion of the uterus. *BJOG* 47:525, 1940
- Dayan SS, Schwalbe SS: The use of small-dose intravenous nitroglycerin in a case of uterine inversion. *Anesth Analg* 82:1091, 1996
- Garrett-Albaugh S, Stitely ML, Millan L, et al: Chronic postpartum uterine inversion treated by abdominal replacement and cerclage. *W V Med J* 107:43, 2011
- Gonzalez EA, Moore FA, Holcomb JB, et al: Fresh frozen plasma should be given earlier to patients requiring massive transfusion. *J Trauma* 62:112, 2007
- Gupta P, Sahu RL, Huria A: Acute uterine inversion: a simple modification of hydrostatic method of treatment. *Ann Med Health Sci Res* 4:264, 2014
- Haeri S, Rais S, Monks B: Intrauterine tamponade balloon use in the treatment of uterine inversion. *BMJ Case Rep* January 6, 2015
- Haultain F: The treatment of chronic uterine inversion by abdominal hysterotomy. *BMJ* 2:974, 1901
- Henderson H, Alles RW: Puerperal inversion of the uterus. *Am J Obstet Gynecol* 56:133, 1948
- Hostetler DR, Bosworth MF: Uterine inversion: a life-threatening obstetric emergency. *J Am Board Fam Pract* 13:120, 2000
- Huntington JL: Abdominal reposition in acute inversion of the puerperal uterus. *Am J Obstet Gynecol* 15:34, 1928
- Johnson AB: A new concept in the replacement of the inverted uterus and a report of nine cases. *Am J Obstet Gynecol* 57:557, 1949
- Kaya B, Tüten A, Celik H, et al: Non-invasive management of acute recurrent puerperal uterine inversion with Bakri postpartum balloon. *Arch Gynecol Obstet* 289:695, 2014
- Keriakos R, Chaudhuri SR: Managing major postpartum haemorrhage following acute uterine inversion with Rusch balloon catheter. *Case Rep Crit Care* 2011:541479, 2011
- Khalil A, Raafat A, Calleja-Aguis J, et al: Cardiac arrest associated with uterine inversion during caesarean section. *J Obstet Gynaecol* 26:696, 2006
- Kitchen JD 3rd, Thiagarajah S, May HV Jr, et al: Puerperal inversion of the uterus. *Am J Obstet Gynecol* 123:51, 1975
- Livingston SL, Booker C, Kramer P, et al: Chronic uterine inversion at 14 weeks postpartum. *Obstet Gynecol* 109:555, 2007

- Majumdar A, Saleh S, Bird A, et al: Successful conservative management of inversion of a fibroid uterus by hydrostatic balloon. *J Obstet Gynaecol* 30:202, 2010
- Marasinghe JP, Epitawela D, Cole S, et al: Uterine balloon tamponade device and cervical cerclage to correct partial uterine inversion during puerperium: case report. *Gynecol Obstet Invest* 80(1):67, 2015
- Marshall NB, Catling S: Cardiac arrest due to uterine inversion during caesarean section. *Int J Obstet Anesth* 19:231, 2010
- Matsubara S, Baba Y: MY (Matsubara-Yano) uterine compression suture to prevent acute recurrence of uterine inversion. *Acta Obstet Gynecol Scand* 92:734, 2013
- Matsubara S, Yano H, Taneichi A, et al: Uterine compression suture against impending recurrence of uterine inversion immediately after laparotomy repositioning. *J Obstet Gynaecol Res* 35:819, 2009
- Momani AW, Hassan A: Treatment of puerperal uterine inversion by the hydrostatic method; reports of five cases. *Eur J Obstet Gynecol Reprod Biol* 32:281, 1989
- Mondal PC, Ghosh D, Santra D, et al: Role of Hayman technique and its modification in recurrent puerperal uterine inversion. *J Obstet Gynaecol Res* 38:438, 2012
- Morini A, Angelini R, Giardini G: Acute puerperal uterine inversion: a report of 3 cases and an analysis of 358 cases in the literature. *Minerva Ginecol* 46:115, 1994
- Nag DS, Datta MR, Samaddar DP, et al: Cardiac arrest following acute puerperal uterine inversion. *BMJ Case Rep* February 18, 2015
- Oguch O, Ayida G: Acute uterine inversion: a new technique of hydrostatic replacement. *BJOG* 104:951, 1997
- O'Sullivan JV: Acute inversion of the uterus. *BMJ* 2(4417): 282, 1945
- Pan J, Zhou L, Huang A, et al: Sonographic diagnosis of complete uterine inversion: an unusual case. *Clin Exp Obstet Gynecol* 42(2):240, 2015
- Pauleta JR, Rodrigues R, Melo MA, et al: Ultrasonographic diagnosis of incomplete uterine inversion. *Ultrasound Obstet Gynecol* 36:260, 2010
- Platt LD, Druzin ML: Acute puerperal inversion of the uterus. *Am J Obstet Gynecol* 141:187, 1981
- Rana KA, Patel PS: Complete uterine inversion: an unusual yet crucial sonographic diagnosis. *J Ultrasound Med* 28:1719, 2009
- Riskin DJ, Tsai TC, Riskin L, et al: Massive transfusion protocols: the role of aggressive resuscitation versus product ratio in mortality reduction. *J Am Coll Surg* 209:198, 2009
- Sardeshpande NS, Sawant RM, Sardeshpande SN, et al: Laparoscopic correction of chronic uterine inversion. *J Minim Invasive Gynecol* 16:646, 2009
- Shah-Hosseini R, Evrard JR: Puerperal uterine inversion. *Obstet Gynecol* 73:567, 1989
- Shepherd LJ, Shenassa H, Singh SS: Laparoscopic management of uterine inversion. *J Minim Invasive Gynecol* 17:255, 2010
- Smulian JC, DeFulvio JD, Diven L, et al: Sonographic findings in acute uterine inversion. *J Clin Ultrasound* 41:453, 2013
- Soleymani Majd H, Pilsniak A, Reginald PW: Recurrent uterine inversion: a novel treatment approach using SOS Bakri balloon. *BJOG* 116:999, 2009
- Spinelli PG: Inversione uterine. *Riv Ginecol Contemp Napoli* 11:567, 1897
- Tan KH, Luddin NS: Hydrostatic reduction of acute uterine inversion. *Int J Gynaecol Obstet* 91:63, 2005
- Tank Parakshit D, Mayadeo Niranjan M, Nandanwar YS: Pregnancy outcome after operative correction of puerperal uterine inversion. *Arch Gynecol Obstet* 269:214, 2004
- Terp MR, Rasmussen KL: Uterine inversion during cesarean section. *Acta Obstet Gynecol Scand* 77:788, 1998
- Thakur S, Sharma S, Jhobta A, et al: Sonographic and MR features of puerperal uterine inversion. *Jpn J Radiol* 32:356, 2014
- Tsivos D, Malik F, Arambage K, et al: A life threatening uterine inversion and massive postpartum hemorrhage caused by placenta accrete during Caesarean section in a primigravida: a case report. *Cases J* 2(1):138, 2009
- Uzoma A, Ola B: Complete uterine inversion managed with a Rusch balloon catheter. *J Med Cases* 1:8, 2010
- Vijayaraghavan R, Sujatha Y: Acute postpartum uterine inversion with haemorrhagic shock: laparoscopic reduction: a new method of management? *BJOG* 113:1100, 2006
- Watson P, Besch N, Bowes WA Jr: Management of acute and subacute puerperal inversion of the uterus. *Obstet Gynecol* 55:12, 1980
- Witteveen T, van Stralen G, Zwart J, et al: Puerperal uterine inversion in the Netherlands: a nationwide cohort study. *Acta Obstet Gynecol Scand* 92:334, 2013
- You WB, Zahn CM: Postpartum hemorrhage: abnormally adherent placenta, uterine inversion, and puerperal hematomas. *Clin Obstet Gynecol* 49:184, 2006
- Zechmeister JR, Levey KA: Successful robotically assisted laparoscopic correction of chronic uterine inversion. *J Minim Invasive Gynecol* 18:671, 2011

CHAPTER 32

Postoperative Complications

PUERPERAL INFECTIONS	503
THROMBOEMBOLIC DISEASE	515
SUMMARY	521

According to the Centers for Disease Control and Prevention and the National Hospital Discharge Summary, nearly 1.3 million cesarean deliveries were performed in 2013 (Martin, 2015). This stands as the most common abdominal surgery in the United States and by far the most frequently performed surgery in obstetrics. Cesarean delivery is discussed in detail in Chapter 25 (p. 403), and postoperative complications following this procedure contribute substantively to pregnancy-related morbidity and mortality rates. In their sobering analysis of data from the Pregnancy Mortality Surveillance System, for example, Creanga and colleagues (2015) found that infection, venous thromboembolism, and hemorrhage contributed 13.6 percent, 9.6 percent, and 11.4 percent, respectively, to all pregnancy-related deaths from 2006 to 2010. The contribution from infection actually represented a significant increase compared with previously reported epochs. The importance of recognizing and appropriately managing such postoperative complications is highlighted by the fact that subsets of the resultant deaths are unquestionably preventable.

PUERPERAL INFECTIONS

Puerperal fever is defined by a temperature increase to 38.0°C (100.4°F) or greater in the postpartum period, whereas *puerperal infection* refers to any bacterial infection of the genital

tract. The causes of puerperal fever are numerous, and the presence of fever by itself is not diagnostic of infection. Indeed, transient, low-grade fever in the early postpartum period is usually benign and does not require treatment. However, most persistent or high-grade fevers—39.0°C or higher—are associated with infection, most commonly uterine infection.

Several risk factors for puerperal infection have been identified, but cesarean delivery is the single most important risk for infection, conferring a 20- to 30-fold relative risk compared with vaginal delivery (Maharaj, 2007). In an older study, Filker and Monif (1979) reported that only 21 percent of women febrile in the first 24 hours who were delivered vaginally were found to have infection. This contrasts with 72 percent of those with fever who had undergone cesarean delivery.

Extragenital causes of puerperal fever include breast engorgement, mastitis, urinary tract infection, septic pelvic thrombophlebitis, respiratory tract complications, and, in women who undergo laparotomy, wound infection. The broad differential diagnosis of postpartum fever underscores the importance of a prompt and thorough evaluation in any woman who is noted to have a temperature above these threshold values.

■ Breast Sources

Breast Engorgement

Breast engorgement commonly causes a brief temperature elevation. Approximately 15 percent of all women in the first few postpartum days develop fever from breast engorgement, but it rarely exceeds 39°C. Engorgement is more common in women who do not breastfeed and is typically associated with breast pain and marked bilateral firmness during examination. This fever characteristically lasts no longer than 24 hours. Treatment is supportive with breast binders, cool packs, and oral analgesics as needed. That said, evidence-based recommendations for the management of breast engorgement are lacking (Mangesi, 2010).

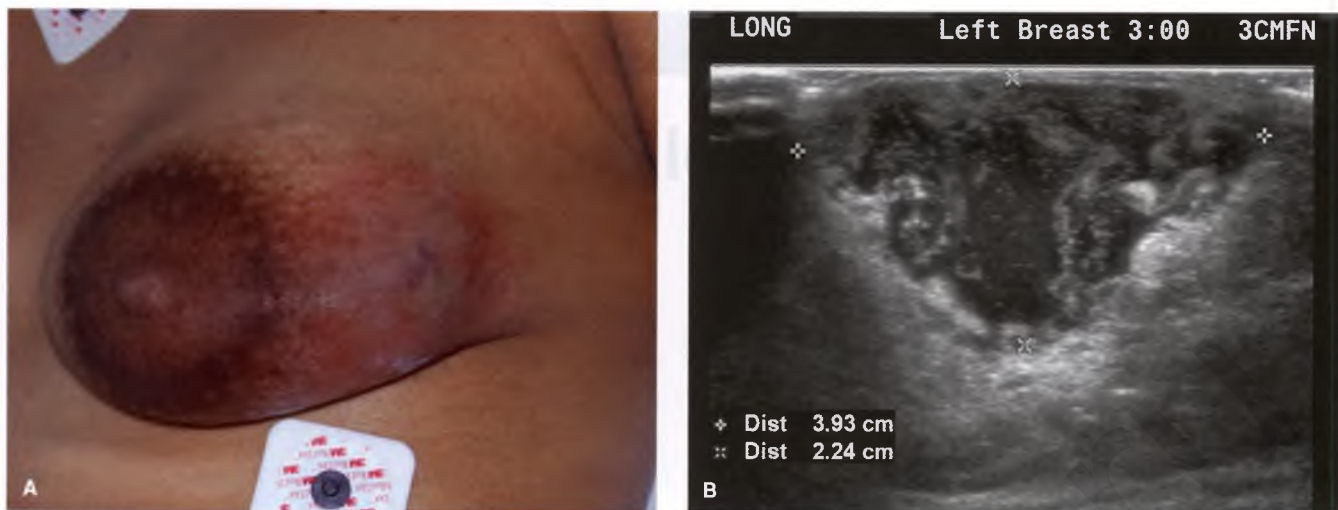


FIGURE 32-1 Postpartum breast abscess. **A.** Firm margins were palpated around the erythematous area in this left breast. This finding was concerning for an abscess and prompted breast sonography. **B.** In this sonogram of the same breast, a predominantly cystic area with complex-appearing fluid is marked by calipers. Following initiation of intravenous antibiotics, the abscess was subsequently drained and packed in the operating room.

Mastitis

In contrast to engorgement, fever from *bacterial mastitis* develops later in the puerperium and usually is sustained. Intense breast pain is typically unilateral, and obvious cellulitis, with erythema and warmth, is evident on the affected breast (Fig. 32-1). Systemic symptoms including chills are common, and tachycardia often accompanies the fever. Mastitis is usually caused by staphylococcal species, and, increasingly, methicillin-resistant *Staphylococcus aureus* (MRSA) is being reported as the principal pathogen in women with these infections (Lee, 2010; Stafford, 2008).

Treatment is empiric and usually includes an antistaphylococcal penicillin. Dicloxacillin, 500 mg orally four times daily, may be selected. Erythromycin is given to women who are penicillin sensitive. Even though clinical response may be prompt, treatment should be continued for 10 to 14 days. For resistant staphylococci, vancomycin or another anti-MRSA antimicrobial is given.

Marshall and coworkers (1975) demonstrated the importance of continued breastfeeding. They reported that the three abscesses that developed in 65 women with mastitis were in 15 women who quit breastfeeding. Vigorous milk expression may be sufficient treatment alone (Thomsen, 1984). Sometimes the newborn will not nurse on the inflamed breast, and a breast pump can be used.

Breast Abscess

An abscess should be suspected when defervescence does not follow within 48 to 72 hours of mastitis treatment or when a mass is palpable. If suppuration is suspected clinically, breast sonography can help confirm the diagnosis of breast abscess. As seen in Figure 32-1B, sonographic identification of a cystic cavity with associated adjacent inflammatory change confirms the diagnosis.

In these cases, drainage of the abscess cavity is indicated in addition to intravenous antibiotics. Incision and drainage

followed by cavity packing is one approach. For substantial abscesses, this often requires general anesthesia. Alternatively, aspiration has been demonstrated to result in more rapid healing compared with surgical incision and drainage and has the added benefit of avoiding exposure to general anesthesia (Naeem, 2012).

Pyelonephritis

Many physiologic and hormonal changes during pregnancy leave the urinary tract vulnerable to infection. These include hydroureter, decreased ureteral muscle tone and peristalsis from increased progesterone levels, and expanded filling capacity and incomplete emptying of the bladder. These persist for several weeks into the puerperium. In one review of 23 cases of postpartum pyelonephritis, 20 cases (87 percent) were diagnosed in the first 3 weeks after delivery (McDonnold, 2012).

Causes for postpartum pyelonephritis include catheterization during labor, operative delivery, and labor trauma. Moreover, sensation of bladder distention is often diminished by conduction analgesia or by discomfort from genital tract lacerations. Normal postpartum diuresis may worsen bladder overdistention, and catheterization to relieve retention can lead to urinary tract infection.

Clinically, pyelonephritis can be difficult to diagnose postpartum. In typical cases, bacteriuria, pyuria, costovertebral angle tenderness, and spiking temperature clearly indicate renal infection. However, the clinical picture can vary. For example, the first sign of renal infection in puerperal women may be a temperature elevation, but costovertebral angle tenderness may not develop until later. The clinical diagnosis is confirmed by demonstrating bacteriuria microscopically and by urine culture. Because lochia can often contaminate clean-catch specimens, a catheterized specimen may be more informative. Blood cultures are not indicated when the diagnosis is straightforward. Even when bacteremia is found, the organisms identified are almost invariably identical to those found in the urine culture. When

the diagnosis is unclear, however, blood cultures can be considered.

Empiric therapy is begun without waiting for culture results. Of suitable regimens, ampicillin plus gentamicin; cefazolin or ceftriaxone; or an extended-spectrum antibiotic were all 95-percent effective in randomized trials (Sanchez-Ramos, 1995; Wing, 1998, 2000). Serum creatinine may require monitoring if nephrotoxic drugs are given for a prolonged period of time or to women with any degree of renal insufficiency. Intravenous hydration is essential to ensure adequate urine flow, and urine output should be monitored carefully in the early course of treatment. Fever is treated with typical oral antipyretics, but marked hyperthermia may require physical cooling such as ice packs or a cooling blanket. With any of the regimens discussed, response is usually prompt, and most women are afebrile by 72 hours (Hill, 2005; Sheffield, 2005; Wing, 2000). After discharge, most continue oral therapy to complete a total of 7 to 14 days.

■ Respiratory Complications

These most often are seen within the first 24 hours following delivery. They typically develop in women delivered by cesarean or those in whom general anesthesia is required. Pulmonary embolism is discussed separately on page 519.

Atelectasis

This is the most common postoperative respiratory complication. It is seen in patients with a diminished cough reflex who have focal airway obstruction from thick secretions. Although it is not conclusively proven that atelectasis causes fever, pyrexia is thought to stem from infection with normal flora that proliferate distal to the obstruction (Engoren, 1995).

Chest radiography is frequently obtained in women with suspected atelectasis, however, findings often do not correlate with postoperative fever (Engoren, 1995; Roberts, 1988). Radiography classically shows linear densities in the lower lung fields.

Atelectasis is best prevented with the use of routine coughing and deep breathing on a fixed schedule, usually every 4 hours for at least the first postoperative day. Incentive spirometry is also frequently recommended to prevent atelectasis, despite that randomized trials have failed to confirm the effectiveness of this strategy (do Nascimento Junior, 2014; Tyson, 2015). Atelectasis is usually temporary (up to 2 days), is self-limited, and rarely slows patient recovery or hospital discharge. Its importance mainly lies in its clinical similarity to other pulmonary conditions. Thus, atelectasis often ultimately is a diagnosis of exclusion.

Aspiration Pneumonitis

The possibility of aspiration of acidic gastric contents must be suspected in the woman with severe or persistent pulmonary findings. Especially with the use of general anesthesia, aspiration can cause severe chemical pneumonitis and has historically been among the most common causes of anesthesia-related deaths in obstetrics. The physiologic changes of pregnancy such as relaxation of the lower esophageal sphincter and delayed gastric emptying place pregnant women at increased risk for aspiration. Labor prolongs gastric emptying times even further.

When highly acidic liquid is inspired, decreased oxygen saturation is likely to develop, along with tachypnea, bronchospasm, rhonchi, rales, atelectasis, cyanosis, tachycardia, and hypotension. At the injury sites, there is pulmonary capillary leakage and exudation of protein-rich fluid containing numerous erythrocytes into the lung interstitium and alveoli. This causes decreased pulmonary compliance, shunting of blood, and severe hypoxemia. Radiographic changes may not appear immediately, and these may be variable, although the right lung most often is affected. Therefore, chest radiographs alone should not be used to exclude aspiration.

Primary treatment is supportive and principally involves providing adequate oxygenation and ventilation. There is no convincing clinical or experimental evidence that corticosteroid therapy or prophylactic antimicrobial administration is beneficial (Marik, 2001, 2011). If clinical evidence of infection develops, however, then vigorous treatment is given. Surveillance for progression to acute respiratory distress syndrome (ARDS) is essential, as described in Chapter 7 (p. 95).

Because of its severity, prevention of aspiration pneumonitis is of paramount importance in obstetrics. Unfortunately, however, according to the American Society of Anesthesiologists Task Force on Obstetric Anesthesia (2007), a specific “safe” fasting time prior to labor or delivery has not been determined. Recommendations from the American Society of Anesthesiologists, which are endorsed by the American College of Obstetricians and Gynecologists (2015), allow a modest intake of clear liquids for women with uncomplicated clinical courses in labor. However, a fasting period of 6 to 8 hours for solids before elective cesarean delivery is recommended. Sodium citrate with citric acid effectively neutralizes gastric contents and should be administered to women before anesthesia induction (Gibbs, 1984). The liberal use of acid-neutralizing agents and avoidance of general anesthesia are probably the two most important aspects of aspiration prevention in gravidas. The management of anesthesia is discussed further in Chapter 19 (p. 311).

■ Uterine Infection Following Cesarean Delivery

As discussed, cesarean delivery places a woman at extraordinary risk for developing uterine infection. Prolonged labor and membrane rupture, multiple cervical examinations, and internal fetal monitoring are recognized risks for metritis, but abdominal delivery is the single biggest factor for developing postpartum infection. The incidence of metritis following surgical delivery varies with socioeconomic factors, but serious infections are now much less common with routine use of perioperative antibiotics, discussed in Chapter 18 (p. 295).

Bacteriology

Organisms that contaminate and invade surgical incisions and lacerations tend to be of relatively low virulence and seldom initiate infection in healthy tissues. Although more virulent bacteria may be introduced from exogenous sources, in modern obstetrics, an epidemic of major puerperal sepsis rarely develops.

As an exception, serious infections with group A β -hemolytic streptococcus—*Streptococcus pyogenes*—have been documented since the 1980s. This highly virulent organism may cause severe

and often necrotizing postpartum genital tract infections and a toxic-shock-like syndrome (Anderson, 2014; Aronoff, 2008; Castagnola, 2008). Moreover, a delay in diagnosis may lead to an increased risk of morbidity and maternal mortality (Boie, 2015). Udagawa and associates (1999) reviewed 30 cases of peripartum or postpartum Group A infections. Of 17 in whom infection manifested before, during, or within 12 hours of delivery, the maternal mortality rate was 88 percent from obvious infection, and the fetal mortality rate was 60 percent. In 13 women who deteriorated more than 12 hours postpartum, the maternal death rate was 55 percent, and there were no neonatal deaths.

Organisms usually responsible for female genital tract infections are listed in Table 32-1. Puerperal pelvic infections are typically polymicrobial and are almost always caused by bacteria that comprise the normal flora of the bowel, vagina, and cervix (Gilstrap, 1979). As mentioned, the individual species of bacteria typically isolated are considered to be of low virulence, but the polymicrobial nature of the infections enhances bacterial synergy. Hematomas and devitalized tissue increase pathogenicity even further. Under these circumstances, virulence is enhanced sufficiently to cause uterine infection that may progress to extensive pelvic cellulitis, abscess, peritonitis, and suppurative thrombophlebitis.

The uterine cavity usually is sterile before rupture of the amniotic sac. As the consequence of labor and associated manipulations, amniotic fluid and presumably the uterus commonly become contaminated with anaerobic and aerobic bacteria. For example, Gilstrap and Cunningham (1979) cultured amniotic fluid obtained at cesarean delivery performed in women in labor with membranes ruptured more than 6 hours. They identified an average of 2.5 organisms from each woman. The following bacteria were isolated in the noted percentages: anaerobic and aerobic organisms, 63 percent;

anaerobes alone, 30 percent; and aerobes alone, 7 percent. Predominant anaerobic organisms were gram-positive cocci, namely, *Peptostreptococcus* and *Peptococcus*, 45 percent; *Bacteroides*, 9 percent; and *Clostridium*, 3 percent. Gram-positive aerobic cocci also were common and included *Enterococcus*, 14 percent, and group B *Streptococcus*, 8 percent. Of gram-negative organisms, *Escherichia coli* composed 9 percent of isolates. Gibbs (1987) reemphasized the importance of these organisms and reported an increasing prevalence of *Bacteroides bivius* as a cause of female pelvic infection. Walmer and colleagues (1988) also provided evidence for *Enterococcus* in the pathogenesis of these infections.

Pathogenesis and Clinical Course

The pathogenesis of uterine infection following cesarean delivery is that of an infected surgical incision. As noted, bacteria gain access to amniotic fluid during labor, and postpartum they invade devitalized uterine tissue. Invariably, with uterine infections that follow cesarean delivery, there is myometritis with parametrial cellulitis. Hence, the term *metritis* is more accurate than endometritis. With early treatment, the infection typically remains limited to the uterus and parametrial tissue. As discussed subsequently, however, the bacteria can spread deeply into the pelvis and cause additional and sometimes severe infectious morbidity.

The clinical picture of metritis varies, but fever is the hallmark sign of postpartum uterine infection. The degree of temperature elevation is intuitively proportional to the extent of infection. When confined to the endometrium (decidua) and superficial myometrium, cases are mild, and fever tends to be low-grade. With more severe infection, temperatures often exceed 38.3°C. Chills may accompany fever and suggest bacteremia, which may be documented in up to one fourth of women with uterine infection following cesarean delivery (DiZerega, 1979). The pulse rate typically follows the temperature curve.

In affected women, abdominal pain is common, and postpartum uterine contractions (afterpains) may be bothersome. One or both sides of the abdomen are typically tender, and parametrial tenderness is elicited during bimanual examination. Even in the early stages, an offensive odor may develop, long regarded as an important sign of uterine infection. However, foul-smelling lochia is found in many women without evidence of infection, and this sign should not be considered pathognomonic. Conversely, some infections, notably those due to group A β -hemolytic streptococci, frequently are associated with scant, odorless lochia. Leukocytosis may range from 15,000 to 30,000 cells per μ L. However, in view of the physiologic leukocytosis of the early puerperium, these findings are difficult to interpret. Bacterial cultures of the genital tract are not typically useful in guiding therapy, and routinely obtaining them is not recommended.

Treatment

Postcesarean delivery metritis is treated empirically with parenterally administered broad-spectrum antibiotics. Initial treatment is directed against most of the mixed flora bacteria listed in Table 32-1. With appropriate antimicrobial coverage,

TABLE 32-1. Bacteria Commonly Responsible for Female Genital Tract Infections

Aerobes

Group A, B, and D streptococci
Enterococcus
 Gram-negative rods: *E coli*, *Klebsiella*, and *Proteus* spp
Staphylococcus aureus
Gardnerella vaginalis

Anaerobes

Peptostreptococcus spp
Prevotella spp
Bacteroides fragilis group
Clostridium spp
Fusobacterium spp

Other

Mycoplasma hominis
Chlamydia trachomatis
Neisseria gonorrhoeae

E coli = *Escherichia coli*.

clinical improvement will be seen in 48 to 72 hours in nearly 90 percent of women treated. Those who have been afebrile for at least 24 hours may typically be discharged. Further oral antibiotic therapy is not needed (Mackeen, 2015). Persistence of fever after 72 hours, however, mandates a careful search for causes of refractory infection, including an assessment for non-pelvic sources. Complications of metritis that cause persistent fever despite appropriate therapy include parametrial phlegmons, surgical incisional and pelvic abscesses, and septic pelvic thrombophlebitis.

Choice of Antibiotics. Several antimicrobial regimens have proven efficacy for the treatment of pelvic infections following cesarean delivery (Table 32-2). Although anaerobic coverage is not typically necessary with postpartum metritis, it is an essential component of the treatment of postcesarean infections given the presence of devitalized tissue.

In 1979, diZerega and coworkers compared the effectiveness of clindamycin plus gentamicin against a regimen of penicillin G plus gentamicin for treatment of pelvic infections following cesarean delivery. Women given the clindamycin and gentamicin regimen had a favorable response 95 percent of the time. Accordingly, most obstetricians now consider this regimen to be the standard against which others are measured (Mackeen, 2015). Walmer and associates (1988) provided evidence that enterococcal infections may be associated with its clinical failure. Thus, many add ampicillin to the clindamycin and gentamicin regimen, either initially or following a failed response by 48 to 72 hours. The University of Alabama group subsequently reaffirmed the efficacy of this regimen given to 322 women with postcesarean metritis and pelvic cellulitis (Brumfield, 2000). Of these, 54 percent were cured with the original two-drug regimen. Another 40 percent in whom ampicillin was added at 48 hours responded. Of the 19 women (6 percent) who did not respond to “triple therapy,” seven had a wound infection that required drainage.

Regarding gentamicin, measuring peak and trough serum gentamicin concentrations is not needed in most women, and once-daily dosing is now used by many. Because the potential for nephrotoxicity and ototoxicity is worrisome with gentamicin in the event of diminished glomerular filtration,

such women can be given a combination of clindamycin and second-generation cephalosporin. Also recommended is a combination of clindamycin and aztreonam, a monobactam compound with activity against gram-negative aerobic pathogens similar to the aminoglycosides.

β -Lactam antibiotics have spectra that include activity against many anaerobic pathogens and have been used successfully for decades to treat these infections. Many of the popular and effective multiagent regimens include a drug from this group. Some of these have been proven effective when used alone. Examples include some cephalosporins—cefotetan, cefotaxime, among others. Extended-spectrum penicillins such as piperacillin, ticarcillin, and mezlocillin are other examples. β -Lactam antibiotics are inherently safe, and except for allergic reactions, they are free of major toxicity. Another advantage is the cost-effectiveness of administering only one drug. The β -lactamase inhibitors clavulanic acid, sulbactam, and tazobactam have been combined with ampicillin, amoxicillin, and ticarcillin to extend their spectra, and these augmented antibiotics are also effective.

Metronidazole has excellent anaerobic coverage and can be used as a substitute for clindamycin. Given with ampicillin and an aminoglycoside, it provides excellent coverage for most bacteria that cause serious pelvic infections.

Imipenem is a carbapenem that has broad-spectrum coverage against most organisms associated with metritis. It is used in combination with *cilastatin*, which inhibits the renal metabolism of imipenem. Although this will be effective in most cases of metritis, it seems reasonable to reserve it for more serious, typically nonobstetric infections.

Antibiotic Prophylaxis. As discussed in Chapter 18 (p. 295), perioperative administration of antibiotics at time of cesarean delivery appreciably reduces infectious morbidity rates. A number of investigators have confirmed reductions in rates of metritis and wound infections when prophylactic antibiotics are utilized (Dinsmoor, 2009; Smaill, 2010). Both laboring women and those undergoing elective cesarean delivery receive benefit from prophylaxis. Administration of antibiotics prior to skin incision results in greater reductions of postoperative metritis rates compared with administration after cord clamping (Sullivan, 2007;

TABLE 32-2. Antimicrobial Regimens for Pelvic Infections Following Cesarean Delivery

Regimen	Comments
Clindamycin + gentamicin	“Gold standard,” 90–97% efficacy, once-daily gentamicin dosing acceptable PLUS
Clindamycin + aztreonam	Ampicillin added with sepsis syndrome or suspected enterococcal infection
Extended-spectrum penicillin	Gentamicin substitute for renal insufficiency Piperacillin, piperacillin tazobactam, ampicillin/sulbactam, or ticarcillin/clavulanate
Cephalosporin	Cefotetan, cefoxitin, or cefotaxime
Vancomycin	Added to other regimens for suspected <i>Staphylococcus aureus</i> infections
Metronidazole + ampicillin + gentamicin	Metronidazole has excellent anaerobic coverage
Carbapenem	Imipenem/cilastatin, meropenem, ertapenem reserved for special indications

Thigpen, 2005). Consequently, the American College of Obstetricians and Gynecologists (2016) recommends that antimicrobial prophylaxis be given to all women undergoing cesarean delivery unless the patient is already receiving appropriate antibiotics, for example, those being treated for chorioamnionitis, and that prophylaxis should be administered up to 60 minutes prior to skin incision when possible. Single-agent, first-generation cephalosporins are considered first-line antibiotics unless a significant allergy is present (American College of Obstetricians and Gynecologists, 2016). They are relatively inexpensive, have an appropriate half-life length for surgical prophylaxis, and are effective against most bacterial species that cause puerperal pelvic infections. Dosing changes related to weight, surgery length, or blood loss are described in Chapter 18 (p. 295).

■ Wound Infections

As noted, the overwhelming majority of women treated for postcesarean metritis have an adequate clinical response within 3 days. Cited earlier, Brumfield and coworkers (2000) found that metritis after cesarean delivery responded within 72 hours to appropriate treatment in 94 percent of cases. In a study from Parkland Hospital, Brown and colleagues (1999) found that only 1 in 650 women with postpartum metritis had fever that persisted for more than 5 days despite adequate antimicrobial therapy. That said, a number of infection-related complications are responsible for persistent fever, and a thorough investigation should be pursued for any woman who fails to respond to antimicrobials. Relatively common are wound infections localized above the level of the abdominal fascia. Occasionally, these infections are from an extension of a uterine infection.

The incidence of postcesarean surgical site infections varies significantly depending on the population of women studied and the degree to which postdischarge evaluations are included. With a 2- to 3-day hospitalization postcesarean delivery, the vast majority of wound infections become symptomatic after discharge. For example, Opøien and coworkers (2007) reported a surgical site infection rate of 8.9 percent within 30 days after cesarean delivery, but only 1.8 percent of these were diagnosed prior to patient discharge. Likewise, analyzing data from the Scottish Surveillance of Healthcare Associated Infection Programme, Reilly and colleagues (2006) found that 1.2 percent of women undergoing cesarean delivery between 2002 and 2004 had surgical site infections when no postdischarge surveillance was performed. This contrasted with an infection rate of 12.2 percent in women who did have posthospitalization surveillance. As noted above, the use of prophylactic antibiotics reduces the risk, and contemporary United States reports identify a 4- to 5-percent incidence of wound infection when antibiotics are universally given (Sullivan, 2007; Thigpen 2005).

Wound infections include superficial skin and soft tissue infections, incisional abscesses, and deep tissue infections that extend below the abdominal fascia and involve pelvic organs. Definitions for these are listed in Table 32-3. Known risk

factors for wound infection include those listed in Table 32-4. As discussed in Chapter 2 (p. 24), the use of subcutaneous drains at time of initial wound closure does not decrease the risk for subsequent infections, even in obese women (Hellums, 2007; Ramsey, 2005).

Diagnosis

For women being treated for postoperative metritis, failure to respond to appropriate antibiotic coverage raises suspicion for an evolving wound infection. Typically, however, wound infections develop later and around the fifth or sixth postoperative day. Erythema and induration are usually present to some degree, and purulent drainage indicates at least an incisional abscess (Fig. 32-2). Fever occurs variably with localized wound infections but almost always accompanies deep tissue infections. Organisms causing these infections usually are the same as those isolated from amniotic fluid at the time of cesarean delivery, but hospital-acquired pathogens must be considered (Emmons, 1988; Gilstrap, 1979).

Treatment

Periincisional cellulitis without evidence of abscess may be adequately treated with antibiotics and close observation. Oral antibiotics and outpatient therapy are often appropriate, provided there are no systemic signs or symptoms. With treatment, the patient can return for a surveillance visit in 24 to 48 hours to ensure improvement. Wounds in which an abscess collection is not initially suspected may eventually suppurate, so close observation is mandatory.

Any wound with an obvious abscess collection requires prompt drainage (Fig. 32-3). Parenteral broad-spectrum antibiotics are also initiated, and those in Table 32-2 are suitable. Surgical drainage includes all purulent material, including pus loculations. Cultures are typically taken and may help to direct subsequent therapy, particularly in women who fail to respond to an empiric antimicrobial regimen. In most cases, the entire length of the wound must be explored to the level of the fascia. Careful inspection for fascial integrity is paramount when the wound is first opened. If the fascial layer is intact, then debridement of the subcutaneous layer and local wound care is appropriate. In some cases, inspection and debridement are initially carried out in the operating room because extensive debridement and exploration requires substantial anesthesia.

After vigorous debridement of all necrotic tissue and drainage of purulent material, the wound cavity is packed with moistened sterile gauze. This dressing is changed at least daily, and preferably twice daily, with appropriate debridement at each dressing change.

It is controversial whether to use antiseptic agents such as hydrogen peroxide, iodine, or Dakin solution, or to use sterile saline. Some clinicians feel strongly about using diluted hydrogen peroxide solutions or iodine solutions for debridement if gross infection is evident. Recall that both of these solutions are also damaging to healthy tissue. Dakin solution—sodium hypochlorite—not only is bactericidal but is known to promote granulation tissue.

TABLE 32-3. Criteria for Defining Surgical Site Infections (SSIs)**Superficial incisional**

Involves only skin and subcutaneous tissue of the incision

Develops within 30 days of surgical procedure

Features at least one of the following:

- Purulent drainage from the superficial incision

- Bacteria in culture obtained aseptically from fluid or tissue from the superficial incision

- Incision deliberately opened by surgeon and is culture positive (or not cultured) *and* patient has at least one of the following incisional signs or symptoms:

- Tenderness or pain

- Heat or redness

- Localized swelling

- SSI diagnosis made by surgeon or attending physician

Stitch abscesses are not included in this category

Diagnosis of “cellulitis,” by itself, does not meet criterion for SSI

Deep incisional

Involves the deep soft tissues (muscle and fascia) of the incision

Develops within 30 days of surgical procedure

Features at least one of the following:

- Purulent drainage from deep incision of surgical site (but not organ or space component)

- Deep incision that spontaneously dehisces or is deliberately opened by a surgeon and is culture-positive (or not cultured) *and* patient has at least one of the following signs or symptoms:

- Temperature $\geq 38^{\circ}\text{C}$ (100.4°F)

- Localized pain or tenderness

Abscess or other infection found by reoperation, histopathology, or radiology

Organ/space

Involves any body part that was opened or manipulated during the operative procedure, excluding the skin incision, fascia, or muscle layers

Develops within 30 days of the surgical procedure

Features at least one of the following:

- Purulent drainage from a drain placed through a stab wound into the organ/space

- Bacteria obtained aseptically from tissue or fluid in that organ/space

- Abscess found by reoperation, histopathology, or radiology

Vaginal cuff infection with purulence, abscess, and/or positive tissue or fluid culture is included in this category

Reproduced with permission from Centers for Disease Control and Prevention, 2014.

TABLE 32-4. Risk Factors for Postcesarean Surgical Site Infection

Smoker
Obesity
Hypertension
Diabetes mellitus
Perioperative anemia
Excessive blood loss
Intraoperative hypothermia
Lower socioeconomic status
Immunocompromised patient
Intrapartum chorioamnionitis
Prolonged surgical procedure
Hematoma or seroma formation
Foreign body placement (catheter, drain, etc.)

Closure

Once infection has cleared, wounds ultimately can heal by secondary intention or be reapproximated by delayed primary closure. With healing by secondary intention, a wound gradually adds granulation tissue from its base and sides to close the defect (Fig. 32-4). This may take several weeks to months depending on the size and depth of the wound.

In contrast, delayed primary closure is aesthetically preferable and results in significantly faster healing times (Wechter, 2005). In this method of management, local wound care is carried out until healthy, pink granulation is noted—typically 4 to 6 days after the initial debridement. At this point, delayed primary closure can be accomplished. Nonabsorbable suture, usually polypropylene or nylon, is placed in interrupted fashion across the length of the wound such that both the subcutaneous tissue and skin edges are apposed. Some surgeons use retention sutures to avoid undue pressure on the skin from the suture. An inexpensive method to accomplish

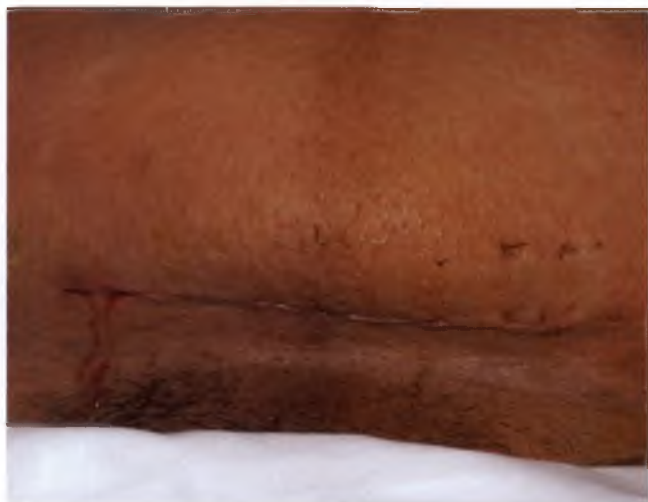

FIGURE 32-2 This patient presented 8 days postoperatively following cesarean delivery with fever and incisional drainage from one corner. Skin and subcutaneous tissues around the incision were mildly erythematous and edematous. During gentle exploration of the draining corner using a cotton swab, the skin and subcutaneous layers along a major portion of the wound spontaneously dehisced and revealed a larger incisional abscess. After initiation of intravenous antibiotics, the wound was subsequently debrided in the operating room.

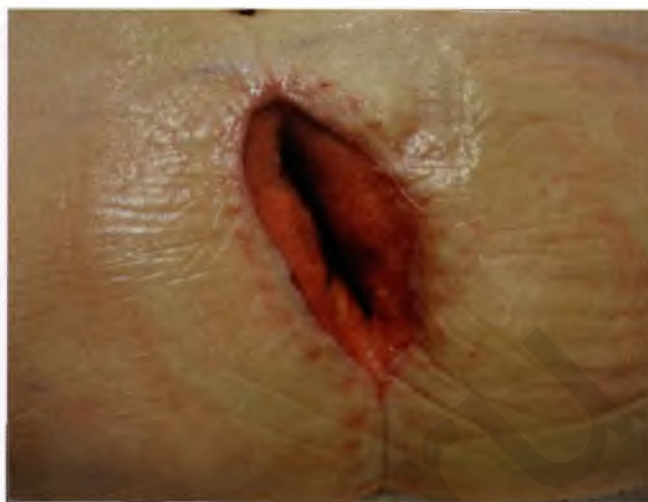

FIGURE 32-4 Healthy granulation tissue seen in the upper portion of a vertical midline incision that is healing by secondary intention following wound infection resolution. (Used with permission from Dr. Benjamin Kogutt.)

the same goal is to use short segments of red rubber catheter and run one end of the suture through the tubing prior to tying the knot (Fig. 32-5). With or without this bridge, the knot should be tied in such a manner that the skin edges are not strangulated. These sutures can be removed on or around postprocedural day 10. Skin closure strips (Steri-Strips) can be applied at that time.

As an alternative, the use of negative pressure therapy—wound vacuum—has been increasing in women with post-cesarean wound infections despite a paucity of data to support

its use. This therapy is discussed and illustrated in Chapter 2 (p. 25).

■ Wound Dehiscence

Wound disruption or dehiscence refers to separation of the wound involving the fascial layer. McNeeley and colleagues (1998) studied 8590 women undergoing cesarean delivery at Hutzel Hospital in Detroit, and they identified fascial dehiscence in 27 cases—approximately 1 in 300 operations. Most disruptions manifest on about the fifth postoperative day. The usual presenting sign is a serosanguinous discharge. Following cesarean delivery, there is usually coexisting infection. Of the 27 fascial dehiscences identified by McNeeley and associates

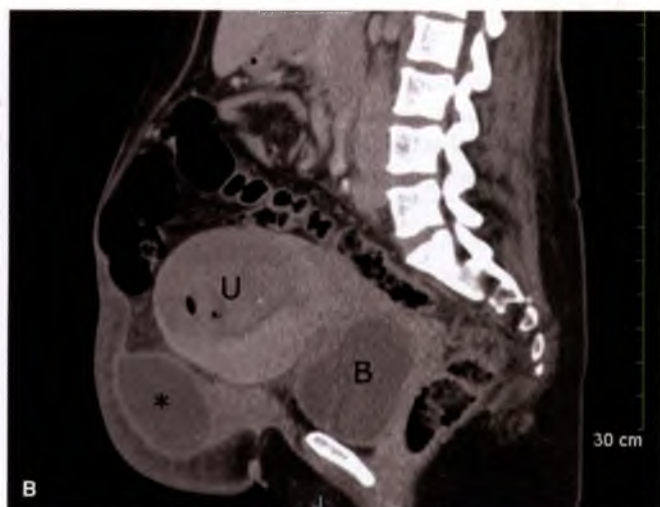
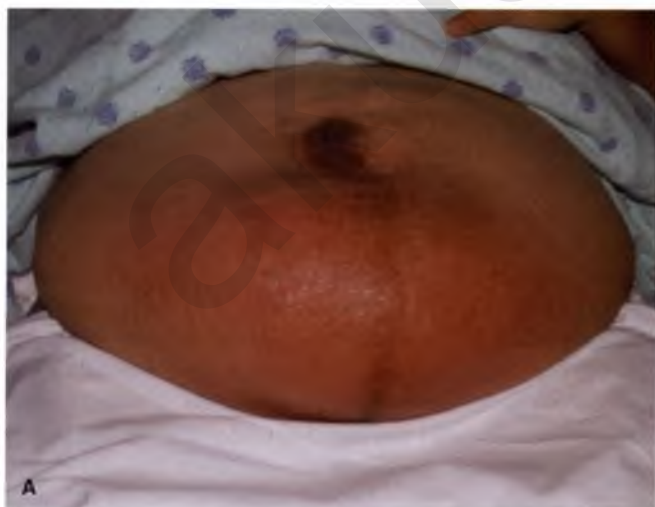
FIGURE 32-3 A. This patient presented with fever and incisional pain 7 days after cesarean delivery. Her Pfannenstiel incision showed minimal erythema, but a large bulging erythematous area was noted between the incision and umbilicus. **B.** Computed tomography was obtained and showed a 12.3 × 6.5 cm fluid collection with indistinct margins (*asterisk*). Evacuation confirmed an infected hematoma beneath the anterior rectus sheath. B = bladder; U = uterus.

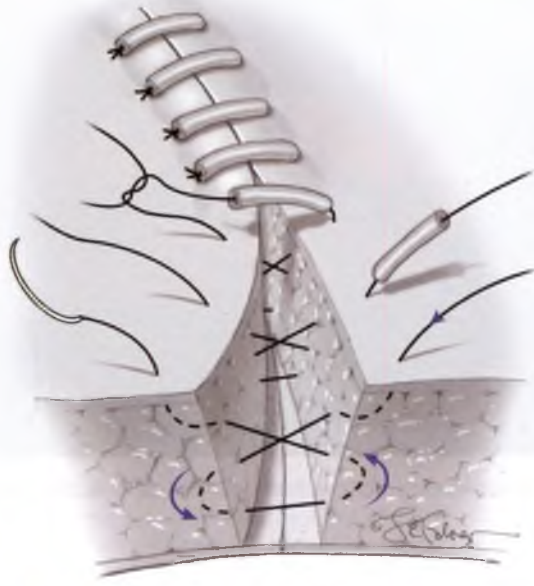


FIGURE 32-5 Abdominal wound closure technique.

(1998), two thirds were associated with infection and tissue necrosis.

In some women, dehiscence becomes apparent when the skin sutures or clips are removed and evisceration follows (Fig. 32-6). In such cases, bowel and abdominal contents are gently packed with saline, broad-spectrum antibiotics are begun, and the patient is urgently taken to the operative suite. Once she is in the operating room and under general anesthesia, the pelvis is explored and the entire bowel is run to exclude perforations or areas of necrosis. Abscesses are drained, and the abdomen is irrigated. If the fascial edges appear necrotic, they should be debrided until healthy tissue is encountered.

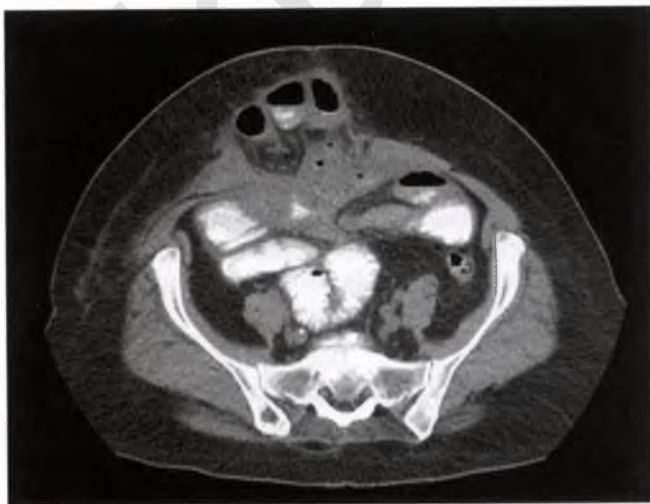

FIGURE 32-6 Fascial dehiscence and bowel evisceration following laparotomy. In this computed tomography image, bowel loops are seen protruding through the anterior abdominal wall defect.

This serious complication requires secondary closure of the abdominal fascia after surgical debridement is completed. If the edges of the fascia are intact and appear that they will hold suture, a Smead-Jones or mass closure may be performed (Figs. 4-20 and 4-21, p. 57). Subcutaneous tissues are packed open, and delayed closure may be performed at a later appropriate time, as described in the last section. Occasionally, extensive resection of necrotic fascia actually precludes secondary closure. These particularly complicated cases are best managed by a team of experienced surgeons.

As with all complications, the best treatment is prevention. The surgeon should be cognizant of risk factors for both wound infection and wound dehiscence. In women at high risk for wound dehiscence, the fascia should be closed with delayed-absorbable or permanent suture in a Smead-Jones or mass closure technique. The subcutaneous layer should have absolute homeostasis, and in contaminated wounds, delayed closure or drainage should be considered.

■ Necrotizing Fasciitis

This uncommon but severe wound infection involves extensive necrosis of muscle and fascia and carries a high mortality rate. In obstetrics, necrotizing fasciitis can follow cesarean delivery but can also complicate perineal wounds and episiotomies (Chap. 20, p. 331). It is seen also with vulvar infections in diabetic and immunosuppressed women. Necrotizing fasciitis develops rarely in otherwise healthy women, and if so, it likely is due to group A β -hemolytic streptococcal infection.

At the University of Alabama, Goepfert and coworkers (1997) reviewed their experience with necrotizing fasciitis of the abdominal wall following cesarean delivery. From 1987 through 1994, there were 5048 cesarean deliveries and nine cases of fasciitis—1.8 per 1000 cesarean deliveries. In two women, including one with metastatic breast cancer, the infection was fatal.

The infections are often polymicrobial with bacterial species similar to those that cause other pelvic infections, but anaerobes predominate. Gram-positive anaerobic cocci or *Clostridium perfringens* usually are isolated along with aerobic cocci, *Bacteroides fragilis*, or *E coli* (Thompson, 1993). Group A β -hemolytic streptococcal infections have reemerged as a cause for particularly severe and rapidly progressive necrotizing infections (Anderson, 2014; de Moya, 2009; González, 2008). Group B streptococci synergistically may cause necrosis (Schorge, 1998; Sutton, 1985).

Diagnosis

Clinically, skin changes usually include erythema, tenderness, and edema in the early stages of infection. Frequently, there are accompanying systemic symptoms of fever, malaise, and generalized toxicity. Initially the skin may be intact, but as gangrene progresses, the skin becomes discolored and vesicles and crepitus appear. These changes are accompanied by cutaneous anesthesia and skin necrosis (Fig. 32-7). Initial symptoms typically develop 3 to 5 days after cesarean delivery, however, group A β -hemolytic streptococcal infections may occur as early as postoperative day 1 (Anderson, 2014).

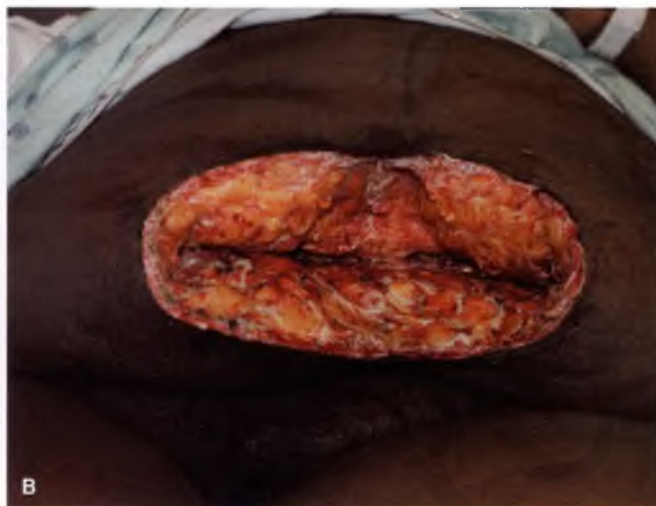
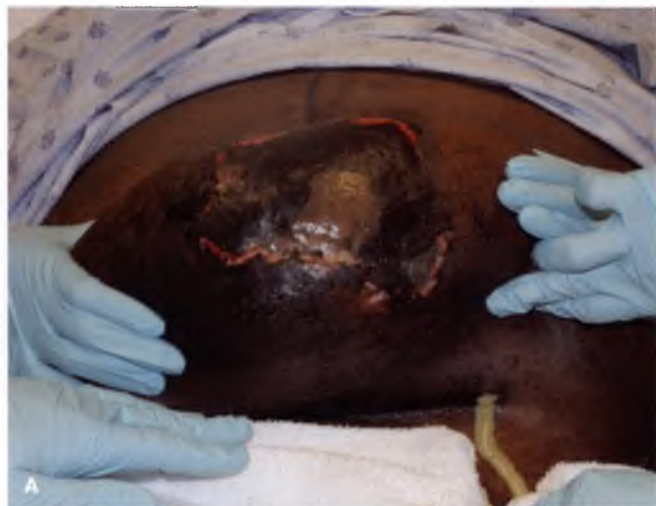
FIGURE 32-7 Necrotizing fasciitis complicating a Pfannenstiel incision following cesarean delivery. **A.** Before debridement. **B.** After initial debridement.

Necrotizing fasciitis of the surgical incision may involve any or all layers of the abdominal wall. Thompson and colleagues (1993) reported that these severe infections also might follow episiotomy, minilaparotomy, diagnostic laparoscopy, and suprapubic catheter placement. The diagnosis may be obvious when the skin changes and symptoms described above are appreciated. Importantly, clinical symptoms vary, and it is often difficult to differentiate superficial infections from deep fascial ones. Therefore, it is imperative to maintain a high index of suspicion. In unclear cases, if computed tomography can be obtained expediently, subcutaneous gas is a classic finding. However, if the diagnosis is uncertain, prompt surgical exploration may be lifesaving. Certainly, if myofasciitis progresses, the woman can become very ill from septicemia, with circulatory failure and death following shortly thereafter.

Treatment

Parenteral antimicrobial therapy is started or continued, and aggressive, wide surgical debridement of all infected tissues is carried out emergently (Goepfert, 1997; McNeeley, 1998). These infections are usually associated with tremendous endothelial cell damage from bacterial toxins. Thus, hemoconcentration and capillary leakage are prominent. Mortality is virtually universal without surgical treatment, and it approaches 50 percent even if aggressive excision is performed. Extensive abdominal wall debridement with unroofing and excision of abdominal fascia is usually required. It is important to excise all infected tissues by debridement carried peripherally until there is no loss of resistance to blunt probing and until the tissue bleeds easily (see Fig. 32-7B). In some cases, extensive fascial debridement precludes primary closure, and a synthetic mesh graft can be placed once tissues are free of infection. McNeeley and colleagues (1998) found this necessary in 6 of 27 women with wound dehiscence following cesarean delivery. They described use of Marlex, Prolene, and Vicryl mesh to accomplish fascial closure.

Wound Hematoma and Seroma

Collections of blood (hematoma) or serous fluid (seroma) often complicate puerperal wounds. Those in the vulvovaginal area are discussed and illustrated in Chapter 30 (p. 484). Those complicating laparotomy may lie in the subcutaneous layer or collect subfascially below the anterior rectus sheath. Common risk factors for hematoma or seroma development include obesity, preeclampsia, and coagulopathy (Fig. 32-8).

Findings evolve in the first few postoperative days. Periincisional bulge and greater than expected incisional pain are classic symptoms. Ecchymosis additionally suggests hematoma. Also, with large hematomas, anemia and hypovolemia may be seen.

Diagnosis can often be made solely from physical findings. In unclear cases, imaging may add clarity, and CT provides simultaneous information regarding pelvic and anterior abdominal wall anatomy.

Small uninfected accumulations require no specific intervention and will be reabsorbed or will spontaneously drain. However, especially if sizable, these may lead to wound infection or incision disruption, described in the prior sections. Thus, larger collections may require surgical evacuation. With hematoma, a distinct bleeding site is rarely identified. If found, vessels or areas of oozing are coagulated or suture ligated.

Following evacuation, wound care mirrors that for wound infections (p. 508). Antibiotics are typically not required for these uninfected fluid collections. However, hematomas and seromas increase the risk for subsequent wound infection, and enhanced surveillance is indicated. With a concern for infection, the antibiotics discussed earlier may be similarly used.

Peritonitis and Adnexal Abscesses

Peritonitis is uncommon after cesarean delivery but almost always develops as a complication of metritis. It typically occurs in conjunction with uterine incisional necrosis and extensive deep-tissue pelvic infection. It may also follow as a consequence of operative injury to the bowel. Rarely, a parametrial or adnexal abscess may rupture and produce catastrophic generalized peritonitis. This is a

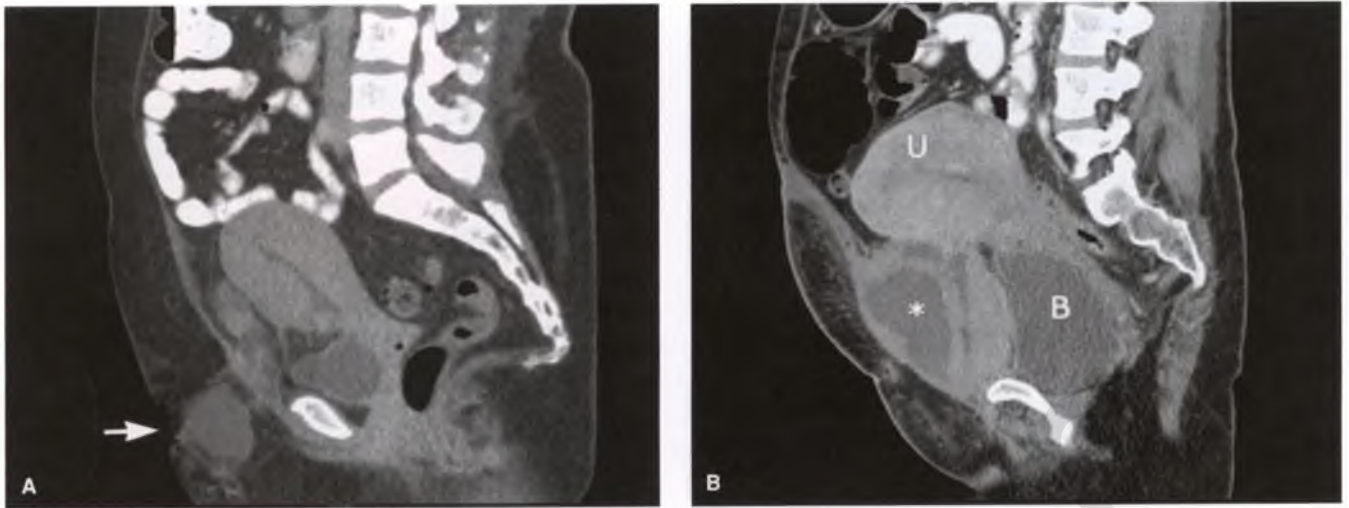


FIGURE 32-8 A. This seroma (*arrow*) was noted on postoperative day 3. **B.** This subfascial hematoma beneath the anterior rectus sheath (*asterisk*) was noted on postoperative day 4. The patient's chronic anticoagulation for a mechanical mitral valve had been restarted 48 hours after her cesarean delivery. B = bladder; U = uterus.

grave complication, and typically, fibrinopurulent exudate binds loops of bowel to one another, and locules of pus may form between the loops. The cul-de-sac and subdiaphragmatic space may then be sites for abscess formation.

Clinically, pain is the hallmark symptom of peritonitis. However, symptoms of an immotile bowel may precede pain in women after cesarean delivery. Nausea, vomiting, and abdominal distention suggest an adynamic ileus and may be the first indication of intraabdominal infection.

It is important to identify the cause of the generalized peritonitis. If the infection began in the uterus and extended into the peritoneum, medical management with broad-spectrum antibiotics and supportive care may be sufficient. Conversely, if peritonitis is the consequence of cesarean scar necrosis, discussed subsequently, or bowel perforation, then emergent surgery is indicated. Sepsis syndrome with shock may supervene.

Puerperal ovarian abscess formation is rare. Most often with puerperal infections the fallopian tubes are involved only with perisalpingitis without subsequent tubal occlusion and sterility. The ovary can become involved, presumably from bacterial invasion through a rent in the ovarian capsule (Wetchler, 1985). The abscess usually is unilateral and women typically present 1 to 2 weeks after delivery. In many cases, rupture causes peritonitis, which prompts surgical exploration. If peritonitis is absent, management may be more conservative and begins with intravenous antimicrobials. That said, radiologic or surgical drainage often becomes necessary.

■ Parametrial Phlegmon

In some women with postcesarean metritis, parametrial cellulitis is intensive and forms an area of induration, termed a *phlegmon*, within the leaves of the broad ligament (Fig. 32-9). These infections are the most common cause of persistent fever despite adequate treatment of pelvic infections that complicate cesarean delivery (DePalma, 1982). Such areas of cellulitis are usually unilateral and frequently remain limited to the base of the broad

ligament. However, if the inflammatory reaction is more intense, cellulitis extends along natural lines of cleavage. The most common form extends laterally, along the base of the broad ligament, with a tendency to extend to the lateral pelvic wall. In response, the uterus is pushed toward the opposite side and is fixed. Posterior extension may involve the rectovaginal septum with the development of a firm mass posterior to the cervix.

Treatment for women with a phlegmon is principally medical with a prolonged course of broad-spectrum intravenous antibiotics. Most women defervesce by 5 to 7 days of adequate

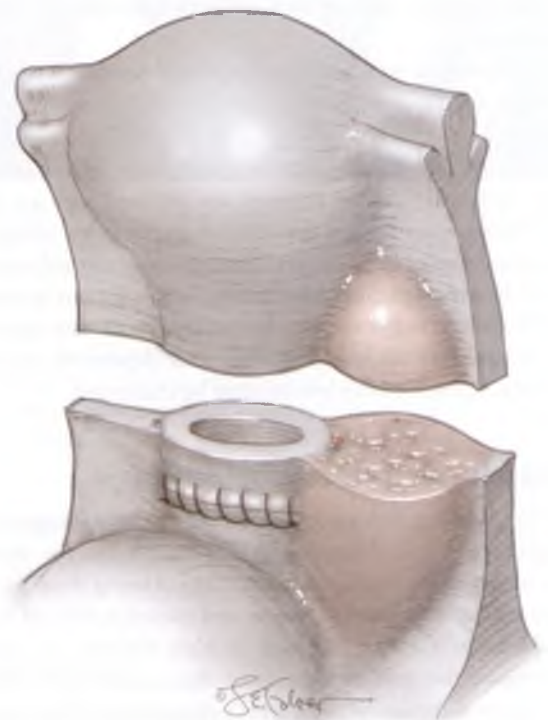

FIGURE 32-9 Left parametrial phlegmon.

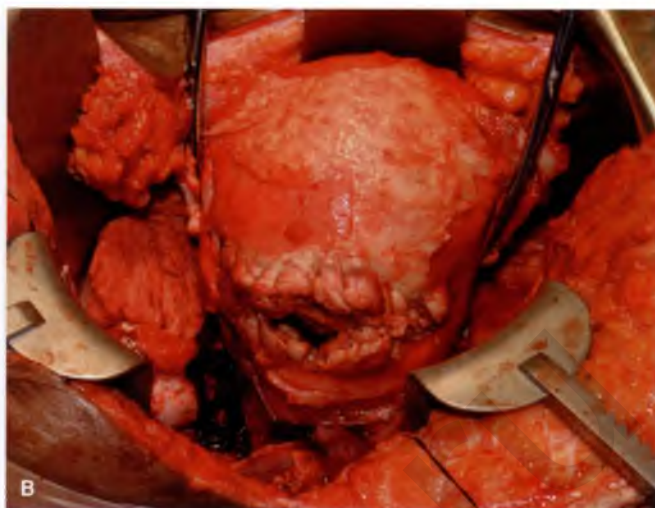
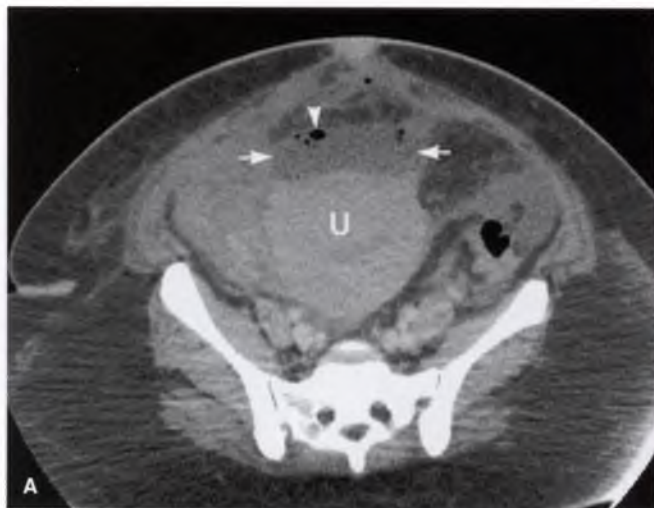
FIGURE 32-10 Postcesarean uterine incision necrosis and dehiscence. **A.** Computed tomography (CT) axial postcontrast image through the pelvis demonstrates a low-density fluid collection (arrows) anterior to the uterus (U). The nondependent foci of air trapped within the fluid suggests complex, thick or septated fluid. Air appears black on CT images, and the largest focus of air is denoted (arrowhead). The stranding within the fat adjacent to the collection suggests edema, possibly related to postsurgical inflammation and/or superimposed infection. (Used with permission from Dr. April Bailey.) **B.** Gross image of uterine incisional necrosis.

treatment, but resolution of pelvic inflammation may take weeks.

Fortunately rare, intensive cellulitis of the uterine incision may cause necrosis and separation with extrusion of purulent material into the peritoneal cavity. (Fig. 32-10). Intraabdominal abscess formation and peritonitis subsequently develop as described above, and wound dehiscence may ensue. Such wound disruptions typically occur with severe infection within the first week or so postpartum. Kindig and colleagues (1998), however, described a case with delayed dehiscence at 6 weeks postpartum.

For women in whom uterine incisional necrosis is suspected or who fail to respond to medical therapy, management is surgical. Hysterectomy and surgical debridement usually are difficult, and often blood loss is appreciable. Frequently, the cervix and lower uterine segment are involved with an intensive inflammatory process that extends to the pelvic sidewall to encompass one or both ureters. Distortions of normal anatomy should be expected. Supracervical hysterectomy can be considered if all infected tissue can be resected with this approach. The adnexa are seldom involved, and depending on their appearance, one or both ovaries may be conserved.

■ Septic Pelvic Thrombophlebitis

In 1951, Collins and associates described the pathogenesis of suppurative pelvic thrombophlebitis in 70 mostly obstetric cases observed from 1937 through 1946. Among these women, septic embolization was common and caused a third of maternal deaths at Charity Hospital of New Orleans. At surgery or autopsy, the authors contrasted these small septic emboli with larger pulmonary emboli that complicated bland venous thrombosis of the pelvis or lower extremities.

Through the 1950s, the predominant therapy for septic pelvic phlebitis was surgical excision of the involved veins

(Collins, 1970). Since the mid-1960s, however, most investigators have recommended empiric intravenous heparin therapy for presumed septic thrombophlebitis manifested as persistent infection (Duff, 1983; Ledger, 1970). It was widely held that defervescence following heparin administration was diagnostic of septic phlebitis. It thus evolved that septic pelvic thrombophlebitis was diagnosed clinically by persistent fever and was only rarely confirmed surgically.

More recent reports document variable incidences for septic pelvic thrombophlebitis. During a 5-year survey of 45,000 women who delivered at Parkland Hospital, Brown and associates (1999) found an incidence of septic thrombophlebitis of 1 in 9000 vaginal births and 1 in 800 cesarean deliveries. The overall incidence of 1 in 3000 deliveries was very similar to 1 in 2000 births reported by Dunnihoo and coworkers (1991). These latter investigators used modern imaging techniques to study women with prolonged fever in a population of more than 60,000 deliveries. More recently, in their analysis of more than 16,000 women undergoing primary cesarean delivery, Rouse and coworkers (2004) reported an incidence of 1 per 400 cesarean deliveries. In this series, the risk for septic phlebitis was almost three times greater in women who had chorioamnionitis compared with those without intrapartum infection.

Septic phlebitis involves an extension of infection along the venous drainage of the pelvic organs, principally the uterus. Intravascular inflammation can lead to thrombosis formation as shown in Figure 32-11. The experiences of Witlin and Sibai (1995) and Brown and coworkers (1999) suggest that puerperal septic pelvic thrombophlebitis is likely to involve one or both ovarian venous plexuses (Fig. 32-12). In perhaps one fourth of these, the clot will extend into the inferior vena cava and occasionally to the level of the renal vein.

The diagnosis of septic pelvic thrombophlebitis is suspected when fever persists despite appropriate antimicrobial treatment for metritis. Although the symptoms associated with

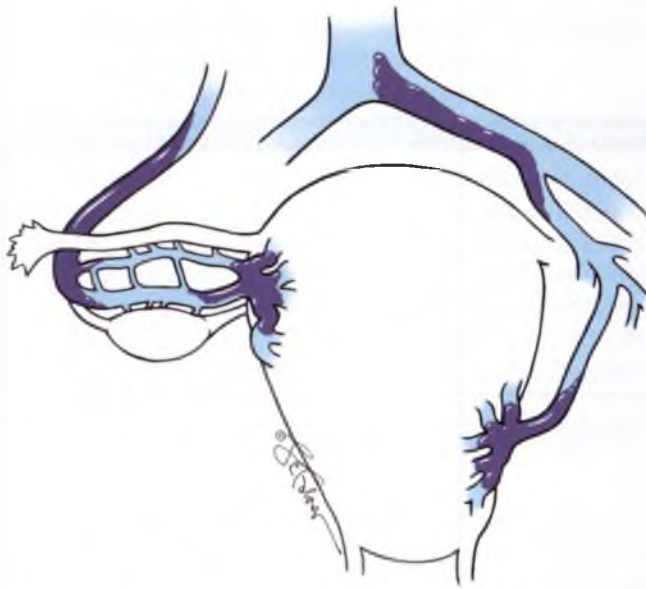


FIGURE 32-11 Septic pelvic thrombophlebitis.

metritis—namely parametrial and uterine pain—may improve with antibiotic treatment, the fever continues. The diagnosis can be confirmed with either CT or MR imaging of the pelvis (Sheffield, 2001).

The mainstay of management for septic phlebitis is continuation of intravenous antimicrobial therapy. Although it was once thought that the addition of heparin hastened resolution of fever, this concept was disproven by Witlin (1995) and Brown (1999) and their colleagues. These latter investigators randomized 14 women with septic pelvic thrombophlebitis to antibiotics plus intravenous heparin versus antibiotics alone and detected no differences in outcomes. The mean hospitalization time was approximately 11 days in both groups of women.

THROMBOEMBOLIC DISEASE

Pregnancy and the puerperium increase appreciably the risk for venous thromboembolism (VTE). Sultan and coworkers (2012) analyzed data from almost 1 million women in a population-based cohort during a 17-year period to assess the risk of a first-episode VTE event. Compared with the risk in nonpregnant women, the risk for women in the third trimester was sixfold higher, and the risk in the first 6 weeks postpartum was 22-fold higher. The incidence of all thromboembolic events approximates 1 event per 1000 pregnancies. Of these, deep-vein thrombosis develops more commonly antepartum, whereas pulmonary embolism is more frequent in the puerperium (Jacobsen, 2008).

The frequency of VTE during the puerperium has decreased remarkably with wide implementation of early postoperative ambulation policies. Maternal mortality rates from thrombotic pulmonary embolism have likewise declined over time. Creanga and associates (2015) noted steady reductions in rates of pregnancy-related deaths from VTE in each of the four epochs studied between 1987 and 2010. Importantly, however, 9.3 percent of all deaths between 2006 and 2010 were still attribut-

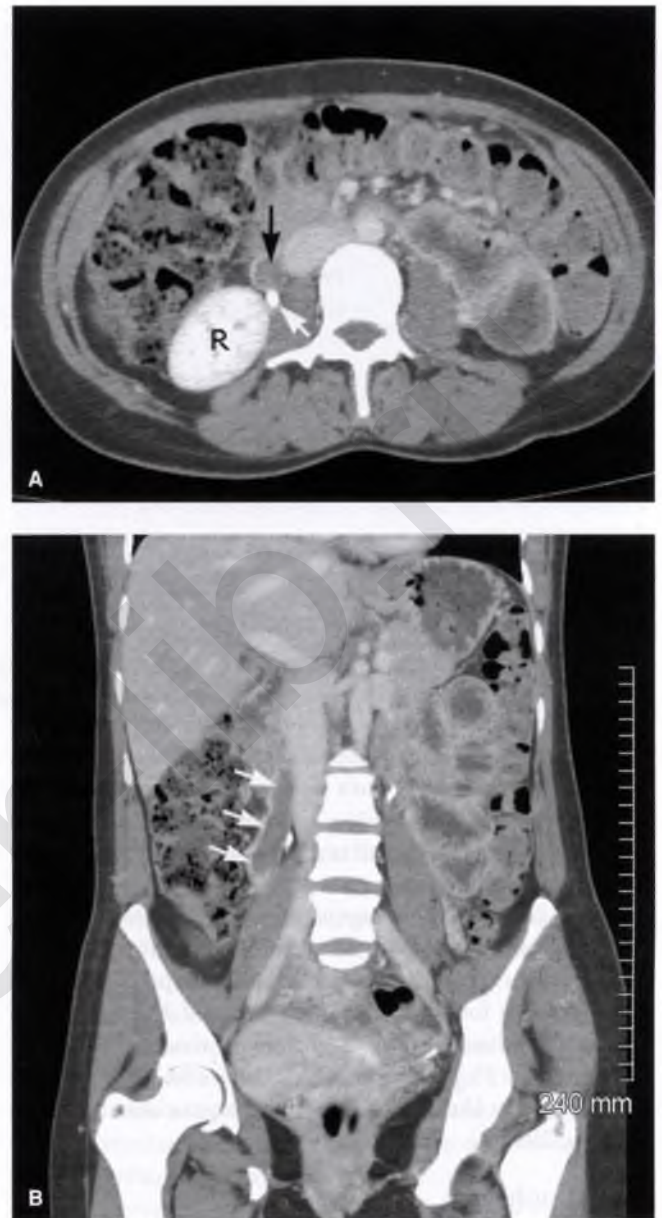


FIGURE 32-12 Septic ovarian vein thrombosis. **A.** Axial contrast enhanced computed tomography (CT) image through the abdomen demonstrates an enlarged right ovarian vein filled with low-density thrombus (*black arrow*). Excreted contrast is seen within the right ureter (*white arrow*) posteriorly. R = lower pole of right kidney. **B.** Coronal contrast-enhanced CT image through the abdomen demonstrates an enlarged right ovarian vein filled with low-density thrombus (*arrows*). (Used with permission from Dr. April Bailey.)

able to thrombotic pulmonary embolism. Taken in total, with amniotic fluid embolism included, embolic phenomena were the single biggest contributor to maternal mortality.

■ Risk Factors

The anatomic and physiologic changes of pregnancy create a prothrombotic state. Markedly augmented hepatic production of procoagulant proteins in conjunction with a reduction in natural anticoagulants—such as protein S—contribute appreciably

TABLE 32-5. Risk Factors Associated with Venous Thromboembolism

Medical	Obstetric
Obesity	Multiparity
Anemia	Transfusion
Diabetes	Prolonged labor
Smoking	Cesarean delivery
Paraplegia	Prolonged bed rest
Heart disease	Multifetal gestation
Sickle-cell disease	Postpartum infection
Nephrotic syndrome	Long-distance air travel
Autoimmune disease	Immobility after delivery
Chronic hypertension	Hyperemesis gravidarum
African-American race	Hemorrhage (antepartum and postpartum)
Myeloproliferative disease	
Advanced maternal age (> 35 years)	

Adapted from James, 2009; Nelson, 2006.

to hypercoagulability (Brenner, 2004). Additionally, compression of the vena cava by advancing gestational uterine bulk progressively limits venous return and worsens venous stasis. By example, venous flow velocities are reduced by approximately half starting in the late second trimester, and this decline persists for approximately 6 weeks postpartum (Mackdon, 1997a,b). Finally, endothelial cell damage is common with labor and delivery, particularly in those gravidas who have pregnancy complications such as hemorrhage, preeclampsia, or sepsis syndrome.

Risk factors for VTE are shown in Table 32-5. The most important of these is a personal history of venous thrombosis. Indeed, 15 to 25 percent of all VTE cases in pregnancy are recurrent events (American College of Obstetricians and Gynecologists, 2014b).

Thrombophilias

More recently, attention has focused on several isolated deficiencies of proteins involved either in coagulation inhibition or in the fibrinolytic system. These deficiencies—collectively referred to as *thrombophilias*—can be inherited or acquired and are the second most important risk factor for thrombosis in pregnancy.

Inherited thrombophilias described to date arise principally from mutations that cause quantitative or qualitative deficiencies of antithrombin, proteins S and C, factor V, and prothrombin. Estimated prevalence rates for the most common inherited thrombophilias in a European population and the associated risk for thrombosis are outlined in Table 32-6. Taken in aggregate, the overall prevalence of these conditions is estimated to be 15 percent. However, a thrombophilia is identified in up to half of pregnancy-related VTEs (Pierangeli, 2011).

The two most prevalent mutations cause prothrombin deficiency or activated protein-C resistance—the factor V Leiden mutation. Both of these are inherited in mendelian fashion, and thus both can be found in the homozygous state. Although rare, homozygosity for either increases the risk for thromboembolism remarkably. For example, the odds ratio for thrombosis

TABLE 32-6. Thrombophilias: Estimated Prevalence and Associated Risk for Thromboembolism in a Pregnant European Population

Thrombophilia	Prevalence (%)	Odds Ratio
Factor V Leiden heterozygote	2–7	8.3
Prothrombin G20210A heterozygote	2	6.8
Antithrombin deficiency	0.3–0.6	4.7
Protein C deficiency	0.2–0.3	4.8
Protein S deficiency	0.03–0.1	3.2

Adapted from Nelson, 2006; Robertson, 2006.

in pregnancy is approximately 34 and 26 for homozygous factor V Leiden and prothrombin mutations, respectively (Robertson, 2006).

Homozygous mutations in the methylenetetrahydrofolate reductase (MTHFR) gene are the commonest cause of hyperhomocysteinemia and have historically been considered a thrombophilia mutation. More recent reports, however, have indicated that hyperhomocysteinemia is a weak risk factor for thrombosis. The American College of Obstetricians and Gynecologists (2014a) concludes that evidence is insufficient to support assessment of the MTHFR polymorphisms or measurement of fasting homocysteine levels in the evaluation of VTE.

Acquired thrombophilia in obstetric populations principally refers to the *antiphospholipid antibody syndrome (APS)*. Uncommon acquired disease states such as malignancy can also increase the risk for venous thrombosis. APS is an autoimmune condition associated with increased rates of arterial and venous thrombosis and untoward pregnancy outcomes. Establishing the diagnosis of APS requires that at least one clinical and one laboratory criterion be met (Miyakis, 2006). Clinical criteria include at least one episode of vascular thrombosis or pregnancy-related morbidity, including: one or more unexplained deaths of a morphologically normal fetus, one or more preterm births <34 weeks' gestation due to severe preeclampsia or placental dysfunction, or three or more consecutive first-trimester pregnancy losses before the 10th week of pregnancy. Those women who fulfill at least one clinical criterion are eligible for laboratory screening. Identification of laboratory benchmark values from Table 32-7, confirmed on two or more occasions that are separated by at least 12 weeks, establishes the diagnosis.

This syndrome appreciably increases the risk for thrombosis, with an estimated 5- to 12-percent risk of thrombosis in pregnancy (American College of Obstetricians and Gynecologists, 2014a). Importantly, these women are at particular risk for arterial thromboses, which may develop in unusual sites such as retinal, subclavian, digital, or brachial arteries. The risk for ischemic stroke is increased as well. Thus, APS is considered in any woman who suffers a stroke in her childbearing years.

■ Superficial Venous Thrombosis

Antepartum or postpartum thrombosis limited strictly to the superficial veins of the saphenous system is treated with analgesia,

TABLE 32-7. Clinical and Laboratory Criteria for Diagnosis of Antiphospholipid Antibody Syndrome^a**Clinical Criteria**

Obstetric:

One or more unexplained deaths of a morphologically normal fetus at or beyond 10 weeks,

or

Severe preeclampsia or placental insufficiency necessitating delivery before 34 weeks,

or

Three or more unexplained consecutive spontaneous abortions before 10 weeks

Vascular: One or more episodes of arterial, venous, or small vessel thrombosis in any tissue or organ

Laboratory Criteria^b

Presence of lupus anticoagulant according to guidelines of the International Society on Thrombosis and Hemostasis,

or

Medium or high serum levels of IgG or IgM anticardiolipin antibodies,

orAnti- β_2 glycoprotein-I IgG or IgM antibody^aAt least one clinical and one laboratory criteria must be present for diagnosis.^bThese tests must be positive on two or more occasions at least 12 weeks apart.

IgG = immunoglobulin G; IgM = immunoglobulin M.

Reproduced with permission from Halvorson LM: First-trimester abortion. In Hoffman BL, Schorge JO, Bradshaw KD, et al: Williams Gynecology, 3rd ed. New York, McGraw-Hill Education, 2016. Compiled from Branch, 2010; Erkan, 2011; Miyakis, 2006.

elastic support, and rest. If it does not soon subside, or if deep-vein involvement is suspected, appropriate diagnostic measures, described next, are taken. If deep-vein involvement is confirmed, anticoagulation is begun. Superficial thrombophlebitis is typically seen in association with superficial varicosities or as a sequela of intravenous catheterization.

■ Deep-Vein Thrombosis

Diagnosis

The great majority of lower-extremity deep-vein thromboses in pregnancy are left-sided. Ginsberg and coworkers (1992) reported that 58 of 60 antepartum women—97 percent—had isolated left-leg thrombosis and that it was bilateral in the other two. James and associates (2005) reported left-sided involvement in three fourths of 53 consecutive confirmed cases of deep-vein thrombosis. Our experiences at Parkland Hospital are similar, with approximately 90 percent of lower-extremity thromboses involving the left leg.

The anatomic distribution of deep-vein thromboses in pregnancy differs from that for nonpregnant women. For example, Chan and associates (2010) demonstrated that approximately two thirds of cases in gravidas were limited to the iliac and femoral veins, without involvement of calf veins. In nonpregnant patients, by contrast, most thromboses originate in calf veins and progress proximally.

Signs and symptoms of deep-vein thrombosis vary greatly, depending in large measure on the degree of occlusion and the intensity of the inflammatory response. The thrombus typically involves much of the deep-vein system to the iliofemoral region. Classic lower-extremity thrombosis is abrupt in onset, with severe pain and edema of the leg and thigh. Calf pain may be spontaneous, may follow manual squeezing, or may follow stretching

the Achilles tendon—*Homans sign*. Importantly, similar pain may instead stem from a strained muscle or a contusion. The latter may be common during the early puerperium as the consequence of inappropriate contact between the calf and the delivery table leg holders. Occasionally, reflex arterial spasm causes a pale, cool extremity with diminished pulsations. Conversely, an appreciable clot may yield little pain, heat, or swelling.

Symptoms can be subtle even with considerable clot burden, and pain and swelling are nonspecific findings. Diagnostic confirmation with imaging is therefore imperative. Venography is the gold standard but is rarely performed today. Instead, non-invasive methods are currently used.

Compression ultrasonography of the proximal veins is the recommended initial test in women suspected of having deep-vein thrombosis (American College of Obstetrics and Gynecology, 2014b). Identification of a noncompressible filling defect confirms the diagnosis (Fig. 32-13). Lensing and colleagues (1989) evaluated 220 consecutive nonpregnant patients with clinically suspected deep-vein thrombosis. They compared contrast venography with real-time sonography and evaluated the common femoral and popliteal veins for full compressibility (no thrombosis) and noncompressibility (thrombosis). Both of these vessels were fully compressible in 142 of 143 patients with a normal venogram result, yielding a specificity of 99 percent. All 66 patients with proximal-vein thrombosis had noncompressible femoral or popliteal veins, or both—sensitivity 100 percent.

A negative result, however, must be interpreted with caution. Namely, the thrombosis may have embolized or be situated in deep pelvic veins, which are inaccessible to ultrasound interrogation. *Importantly, pregnant women frequently have thromboses originating in the iliac vein.* Therefore, if the compression ultrasound study is equivocal or if iliac thrombosis is suspected, then MR imaging is considered. Not only does

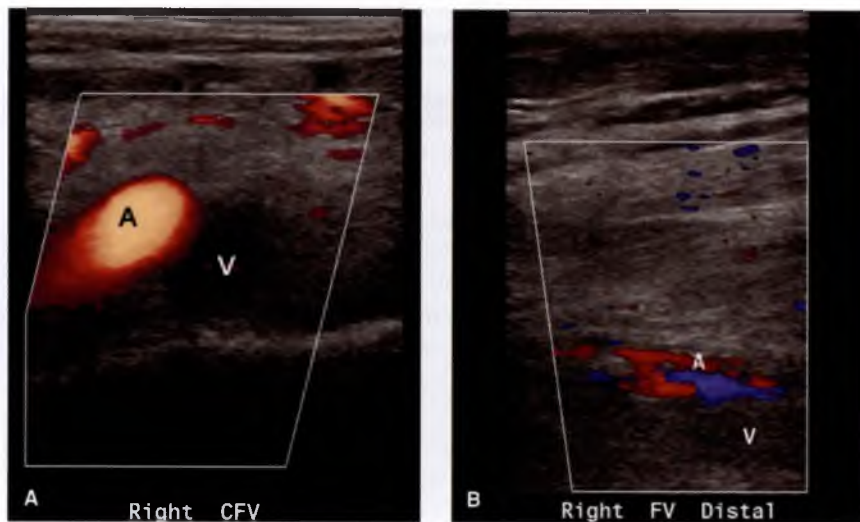


FIGURE 32-13 Deep-vein thrombosis on compression ultrasonography. **A.** Transverse power Doppler image through the right common femoral vein demonstrates flow within the common femoral artery (A) but no flow within the common femoral vein (V). **B.** Longitudinal color Doppler image through the right femoral vein in the same patient again shows no flow within the femoral vein (V). (Used with permission from Dr. April Bailey.)

MR imaging identify thromboses that are missed by sonography, but this technique better delineates and characterizes the extension of clots that are diagnosed with ultrasound (Torkzad, 2010). Erdman and coworkers (1990) reported that MR imaging was 100-percent sensitive and 90-percent specific for detection of venographically proven deep-vein thrombosis in nonpregnant patients. Furthermore, in 44 percent of patients without deep-vein thrombosis, they were able to demonstrate nonthrombotic conditions to explain the clinical findings that originally had suggested venous thrombosis. Examples include cellulitis, edema, hematomas, and superficial phlebitis.

Management

Treatment of deep-vein thrombosis consists of anticoagulation, bed rest, and analgesia. Admission to the hospital is typically recommended to address pain control and initiate anticoagulation. However, outpatient management with close follow-up may be appropriate in selected cases. If outpatient treatment is contemplated, the woman must be adequately educated regarding compliance with a regimen of subcutaneously injected heparin compounds.

Initial anticoagulation for all women is with either unfractionated heparin or low-molecular-weight heparin (LMWH). Both are acceptable and effective. However, the American College of Chest Physicians recommends that LMWH be preferentially used given its better bioavailability, more predictable dose response, and lower rates of complications such as bleeding, osteoporosis, and heparin-induced thrombocytopenia (Bates, 2012). When the diagnosis is made in pregnancy, heparin therapy is continued. For postpartum women, however, heparin therapy is typically transitioned to warfarin, particularly when more than 4 to 6 weeks of postpartum anticoagulation is planned. The leg pain associated with a deep-vein thrombosis usually starts to subside within a few days of therapy. After the signs and symptoms have completely abated, a patient

begins graded ambulation, is fitted with elastic stockings, and continues anticoagulation. Recovery to this stage usually takes 7 to 10 days.

The ideal duration of anticoagulation for pregnant women is uncertain, and recommendations are largely based on expert opinion. The American College of Chest Physicians recommends anticoagulation throughout pregnancy and the postpartum period for a minimum total duration of 3 months (Bates, 2012). These guidelines, however, are based largely on those promulgated for nonpregnant patients coupled with the understanding that pregnancy itself markedly increases the risk for venous thromboembolism (Keaton, 2012). Lockwood (2012) recommends adjusted-dose anticoagulation for 20 weeks in pregnant women followed by prophylactic dosing until delivery. For women diagnosed in the puerperium, he recommends at least 6 months of adjusted-dose anticoagulation.

Unfractionated Heparin. Therapeutic anticoagulation with unfractionated heparin is accomplished with subcutaneous injections given every 12 hours to maintain the activated partial thromboplastin time (aPTT) 1.5 to 2.5 times the control value when measured 6 hours after the injection (American College of Obstetricians and Gynecologists, 2014b).

Some prefer that the initial dosing be with an intravenous infusion to achieve a steady state more rapidly. With this approach, the loading dose is usually 100 U/kg (minimum 5000 U) followed by a continuous infusion of 15 to 25 U/kg/hr. After a steady state is achieved, then aPTT is measured daily, and therapy can be converted to subcutaneous heparin after 5 to 7 days of intravenous administration.

Low-Molecular-Weight Heparin. In this family, derivatives of commercial heparin average 4000 to 5000 daltons compared with 12,000 to 16,000 daltons for conventional heparin. While unfractionated heparin achieves anticoagulation by equally inhibiting both thrombin and factor Xa, LMWH compounds inhibit factor Xa preferentially and have less activity against thrombin. As noted above, the longer half-life and more predictable anticoagulant response to LMWH likely contribute to its fewer associated complications compared with those of unfractionated heparin. An additional benefit is less frequent dosing with LMWH. Subcutaneous injections typically are administered twice daily in an adjusted-dose anticoagulation strategy and once daily with prophylactic dosing.

Several investigators have confirmed that LMWH effectively treats VTE. Simmoneau and coworkers (1997) showed equivalent efficacy for major complications in 612 nonpregnant patients with pulmonary embolism randomized to either subcutaneous tinzaparin or intravenous heparin. The Columbus Investigators (1997) compared low-molecular-weight reviparin

TABLE 32-8. Therapeutic Low-Molecular-Weight Heparin Dosages

Enoxaparin (Lovenox), 1 mg/kg every 12 hr
Dalteparin (Fragmin), 100 units/kg every 12 hr
Dalteparin (Fragmin), 200 units/kg once daily
Tinzaparin (Innohep), 175 units/kg once daily

with unfractionated heparin to treat 1021 patients with VTE, a third of whom had pulmonary embolism. The study drug was as safe and effective as standard heparin. Gould and associates (1999) demonstrated that LMWH was at least as effective at preventing thromboembolic recurrences and actually *reduced* mortality rates during 3 to 6 months compared with rates with unfractionated heparin.

Several LMWH preparations, all of which are pharmacologically unique, are effective in preventing and treating deep-vein thrombosis. The three LMWH agents typically used in pregnancy include enoxaparin, dalteparin, and tinzaparin. Dosing regimens for each of these agents are shown in [Table 32-8](#). After regimen initiation, the need for serum monitoring and dose adjustments during pregnancy remains controversial. Dose adjustments have not yet demonstrated increased therapeutic safety or efficacy. Moreover, the optimal therapeutic anti-Xa range has not been determined (Bates, 2012). Anti-Xa levels also do not correlate well with the risk of bleeding or clot recurrence, and the test lacks accuracy and reliability. For these reasons, the American College of Chest Physicians (Bates, 2012) concludes that routine monitoring of anti-Xa levels is unjustified.

Warfarin. Postpartum venous thrombosis is treated initially with heparin as described above, and if prolonged anticoagulation is anticipated, oral warfarin can be initiated simultaneously. If only 6 weeks of postpartum anticoagulation is planned, the utility of warfarin is limited as it typically takes 1 to 2 weeks before a therapeutic range is attained.

During the transition, heparin is continued for 5 days and until therapeutic warfarin levels are reached for 2 consecutive days. For warfarin, the international normalized ratio (INR) is the appropriate measure, and the therapeutic range is 2.0 to 3.0. This overlapping of agents helps avoid paradoxical thrombosis and skin necrosis from the anti-protein C effect of warfarin therapy.

Warfarin does not accumulate in breast milk, and this medication is considered safe for breastfeeding. To emphasize, *warfarin is generally contraindicated in pregnancy*. This medication is a well-known teratogen with an established pattern of malformations from first-trimester exposure. Outside of the first trimester, warfarin readily crosses the placenta and has been associated with fetal hemorrhage and death.

Complications

The most serious complication with any of these regimens is hemorrhage, which is more likely if there has been recent surgery or lacerations, such as with delivery. Troublesome bleeding also is more likely if the heparin dosage is excessive. Unfortunately, management schemes using laboratory testing

to identify whether heparin dosage is sufficient to inhibit further thrombosis, yet not cause serious hemorrhage, have been discouraging.

An uncommon complication, heparin-induced thrombocytopenia (HIT), has an estimated incidence less than 0.1 percent in obstetric patients using heparin (Linkins, 2012). If HIT is diagnosed, heparin therapy is stopped and alternative anticoagulation initiated. LMWH may not be entirely safe because it has some cross reactivity with unfractionated heparin. The American College of Chest Physicians recommends danaparoid—a sulfated glycosaminoglycan heparinoid (Bates, 2012; Linkins, 2012). Other agents are fondaparinux and argatroban (Kelton, 2013; Linkins, 2012). Argatroban is a direct thrombin inhibitor available in this country to treat HIT. Fondaparinux is a pentasaccharide factor Xa inhibitor that is also used for HIT.

Last, bone loss may develop with long-term heparin or LMWH administration—usually 6 months or longer. Women treated with any heparin are encouraged to take a daily 1500-mg calcium supplement (Cunningham, 2005; Lockwood, 2012).

■ Pulmonary Embolism

The incidence of pulmonary embolism associated with pregnancy varies widely but averages 1 in 7000 deliveries. Antepartum and postpartum diagnoses have an equal prevalence. Almost 80 percent of women who present with pulmonary embolism will have a coexisting deep-vein thrombosis in their legs, and conversely, pulmonary embolism occurs in up to 50 percent of women diagnosed with deep-vein thrombosis (Tapson, 2008). In many cases, but certainly not all, clinical evidence for deep-vein thrombosis of the legs precedes pulmonary embolization. In others, especially those that arise from deep pelvic veins, the first symptoms may be those of acute embolization. The mortality rate of treated acute pulmonary embolism approximates 3 percent, and most deaths are within the first week (Carson, 1992).

Diagnosis

Goldhaber and colleagues (1999) described findings from the International Cooperative Pulmonary Embolism Registry. During a 2-year period, this seven-country study enrolled almost 2500 nonobstetric patients with a proven pulmonary embolism. The most common symptoms were dyspnea (82 percent), chest pain (49 percent), cough (20 percent), syncope (14 percent), and hemoptysis (7 percent). In a more recent report, Pollack and coworkers (2011) reported data on 1880 nonobstetric patients with a confirmed diagnosis of pulmonary embolism. Presenting symptoms were similar: dyspnea at rest (50 percent), pleuritic chest pain (39 percent), dyspnea with exertion (27 percent), cough (23 percent), and dizziness (12 percent). Other notable but less prevalent symptoms included fever, hemoptysis, abdominal pain, syncope, and altered mental status. In these patients, the most common clinical findings were lower-extremity swelling suggestive of deep-vein thrombosis and respiratory distress. Rales and diaphoresis were noted in less than 10 percent of the patients.

Right axis deviation may or may not be evident with electrocardiography. Chest radiography is often nondiagnostic

but may demonstrate other pathology such as atelectasis or an infiltrate. Arterial blood gas analysis will typically demonstrate a widened arterial-alveolar oxygen gradient. However, this finding is nonspecific and confirms the presence of shunt pathophysiology but not the etiology. Unfortunately, even with massive pulmonary embolism, signs, symptoms, and laboratory data to support the diagnosis of pulmonary embolism may be deceptively nonspecific.

The optimal approach to diagnosing pulmonary embolism in pregnancy has not been validated in clinical trials (Bourjeily, 2010). As noted, the symptoms, signs, and clinical findings are frequently nonspecific, and the diagnosis requires a high index of suspicion. Several radiographic modalities have been used, but in contemporary practice, computed-tomographic pulmonary angiography (CTPA) and ventilation-perfusion scintigraphy are employed most frequently.

Computed Tomographic Pulmonary Angiography. This test is the preferred modality for nonpregnant patients and for most pregnant women with suspected pulmonary embolism. CT angiography has advantages over ventilation-perfusion scanning. These include speed and the ability to characterize nonthrombotic pathology and offer an alternate diagnosis (Tapson, 2008). Shahir and associates (2010), for example, reported on 199 pregnant women who underwent 106 CT pulmonary angiographic examinations and 99 perfusion scans. In their study, 14 women found not to have pulmonary embolism had other clinically significant abnormalities identified by CT angiography. This contrasts with the five women who underwent only perfusion scanning and ultimately received other diagnoses—all of which were identified by chest radiography rather than the perfusion scan.

As shown in **Figure 32-14**, CT angiography most accurately diagnoses pulmonary emboli located in the main, lobar, and segmental branches of the pulmonary tree. It is less sensitive at identification of subsegmental emboli. CT angiography also has a high negative-predictive value. Moores and coworkers (2004) performed a metaanalysis evaluating more than 4500 nonpregnant outpatients who had a negative CT angiography study and were not anticoagulated. The 3-month rate of subsequent thromboembolic events was 1.4 percent, and the 3-month rate of fatal pulmonary embolus was 0.5 percent. These investigators concluded that withholding anticoagulation after a negative CT angiography study appeared to be safe. Although less well studied in pregnant women, Bourjeily and colleagues (2012) evaluated follow-up data on 318 women who had a negative CT angiography study performed in pregnancy. The evaluations were done 3 months after the initial presentation or at 6 weeks postpartum. None of these women had any evidence of a venous thromboembolic event at follow-up.

Ventilation-Perfusion Scanning. This test uses a small dose of a radioactive agent, usually technetium (^{99m}Tc) macroaggregated albumin administered intravenously. This scan may not provide a definite diagnosis because many other conditions—for example, pneumonia or local bronchospasm—can cause perfusion defects. Ventilation scans with inhaled xenon-133 or ^{99m}Tc were added to perfusion scans to detect areas of abnormal ventilation in areas of normal perfusion such as with pneumonia or hypoventilation. Thus, although ventilation scanning

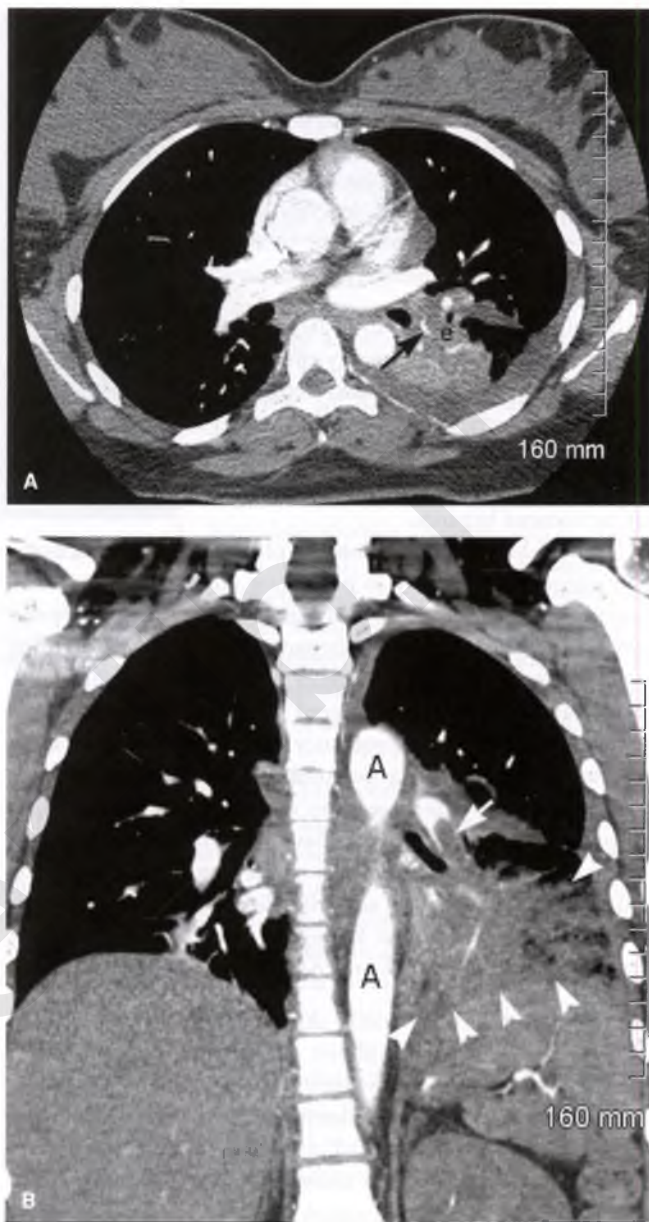


FIGURE 32-14 Computed tomography (CT) angiography demonstrates a pulmonary embolism. **A.** Axial image through the chest demonstrates nearly occlusive low-density pulmonary embolus (*e*) within the artery to the left lower lobe. A thin crescent of intravascular contrast (*arrow*) denotes the residual patent lumen of the artery. **B.** Coronal reformatted image through the chest demonstrates nearly occlusive low-density pulmonary embolus (*arrow*) within the artery to the left lower lobe. There is resultant atelectasis and consolidation of the left lower lobe (*arrowheads*). Intravascular contrast has high density (*white*), as seen in the adjacent thoracic aorta (*A*). (Used with permission from Dr. April Bailey.)

increased the probability of accurately diagnosing pulmonary embolus in patients with large perfusion defects and ventilation mismatches, normal ventilation-perfusion does not exclude pulmonary embolism.

Because of these uncertainties, the National Heart, Lung, and Blood Institute commissioned the Prospective Investigation of Pulmonary Embolism Diagnosis (PIOPED, 1990). This study was designed to determine the sensitivities and specificities of

ventilation-perfusion (V/Q) scans to diagnose pulmonary embolism. It included 933 patients, of whom 931 underwent V/Q scanning and 755 underwent pulmonary angiography. Of the 755 patients studied angiographically, 33 percent had pulmonary embolism. Although almost all patients with an embolism had abnormal V/Q scans of high, intermediate, or low probability, so did most without embolism. This yielded a sensitivity of 98 percent and specificity of 10 percent. Of 116 patients with high-probability V/Q scans, 88 percent had an embolism seen with angiography, but only a minority of patients with a pulmonary embolism had a high-probability scan. This yielded a sensitivity of 41 percent and specificity of 97 percent. Of 322 with intermediate-probability V/Q scans, 33 percent had an embolism on angiography, and for those with a low-probability V/Q scan, the figure was 12 percent. Importantly, 4 percent of patients with a near-normal to normal V/Q scan had pulmonary embolism detected by angiography.

The PIOPED investigators concluded that a high-probability V/Q scan usually indicates pulmonary embolism but that only a small number of patients with emboli have a high-probability scan. A low-probability V/Q scan combined with a strong clinical impression that embolism is unlikely makes the possibility of pulmonary embolism remote. Similarly, near-normal or normal V/Q scans support that an embolism diagnosis is very unlikely. Finally, an intermediate-probability V/Q scan is of no help in establishing the diagnosis. Thus, the V/Q scan combined with clinical assessment permits a noninvasive diagnosis or exclusion of pulmonary embolism for only a minority of patients. Because of these limitations, ventilation-perfusion scanning is now used less frequently than other modalities.

Other Tests. MR imaging also been used to search for pulmonary embolism. Studies in nonpregnant patients suggest that this modality is highly sensitive at detecting central pulmonary emboli but significantly less sensitive at detecting the presence of subsegmental thrombus (van Beek, 2003).

Pulmonary angiography is considered the gold standard for diagnosing pulmonary embolism. However, it is invasive and time-consuming and can be associated with dye-induced allergy and renal failure. Additionally, the procedure carries an approximate 1 in 200 mortality risk (Stein, 1992). Angiography is rarely needed or performed in contemporary practice. At Parkland Hospital, because of its convenience and excellent positive and negative predictive values, CT angiography has become the preferred imaging modality in pregnant or postpartum women suspected of having a pulmonary embolus.

■ Treatment

For pulmonary embolism, management is similar to that for deep-vein thrombosis, but with less-well-documented results. The woman is immediately and fully anticoagulated as described above for the management of deep-vein thrombosis (p. 518).

Vena Caval Filters. Rarely, heparin therapy fails to prevent recurrent pulmonary embolism from the pelvis or legs, or embolism develops from these sites despite heparin. In such cases, a vena caval filter is indicated. Filter placement may also be warranted in women recently diagnosed with a pulmonary

embolism who require major surgery, such as a cesarean delivery (Baglin, 2006). These women present significant management challenges. Namely, cesarean delivery during full anticoagulation can result in life-threatening hemorrhage, whereas withholding or reversing anticoagulation can result in recurrent emboli. In these cases, retrievable filters may be used as short-term protection against embolism. These may be removed before they become endothelialized, or they can be left in permanently.

Neill and colleagues (1997) described use of a *Gunther Tulip* filter placed at 37 weeks' gestation in a gravida with recurrent embolization despite adequate anticoagulation. She underwent cesarean delivery at 38 weeks, and the filter was removed 5 days postpartum. More recently, Liu and associates (2012) described their experience with placement of retrievable filters in 15 women with deep-vein thromboses the day they underwent cesarean delivery. The filter was left permanently in one woman because captured thrombus in the filter was still present. In the other 14, the filter was successfully removed 1 to 2 weeks after surgery. No complications were reported with placement or removal.

SUMMARY

Women undergoing cesarean delivery may develop several postoperative complications. Fortunately, serious complications are uncommon. When they occur, prompt recognition and treatment combined with the usual good health of these young women result in a salutary outcome. Significant postoperative fever is almost always from uterine infection and pelvic cellulitis. It may, however, be due to aspiration pneumonitis, urinary tract infection, or peritonitis. Serious complications can be associated with pelvic infections. These include incisional wound infections—sometimes with dehiscence—as well as pelvic and intraabdominal abscesses. Another important and potentially life-threatening complication is deep-vein thrombosis, which may lead to pulmonary embolization.

REFERENCES

- American College of Obstetricians and Gynecologists: Inherited thrombophilia in pregnancy. Practice Bulletin No. 138, September 2013, Reaffirmed 2014a
- American College of Obstetricians and Gynecologists: Obstetric analgesia and anesthesia. Practice Bulletin No. 36, July 2002, Reaffirmed 2015
- American College of Obstetricians and Gynecologists: Thromboembolism in pregnancy. Practice Bulletin No. 123, September 2011, Reaffirmed 2014b
- American College of Obstetricians and Gynecologists: Use of prophylactic antibiotics in labor and delivery. Practice Bulletin No. 120, June 2011, Reaffirmed 2016
- American Society of Anesthesiologists Task Force on Obstetrical Anesthesia: Practice guidelines for obstetrical anesthesia. *Anesthesiology* 106:843, 2007
- Anderson BL: Puerperal group A streptococcal infection: beyond Semmelweis. *Obstet Gynecol* 123(4):87, 2014
- Aronoff DM, Mulla ZD: Postpartum invasive group A streptococcal disease in the modern era. *Infect Dis Obstet Gynecol* 796892:1, 2008
- Baglin TP, Brush J, Streiff M: Guidelines on use of vena cava filters. *Br J Haematol* 134:590, 2006
- Bates SM, Greer IA, Middeldorp S, et al: VTE, thrombophilia, antithrombotic therapy, and pregnancy: Antithrombotic therapy and prevention of thrombosis, 9th ed: American College of Chest Physicians evidence-based clinical practice guidelines. *Chest* 141:e691s, 2012

- Boie S, Krog J, Tørring S, et al: Life-threatening necrotizing myometritis, due to Group A streptococcus—still a life-threatening condition. *Clin Case Rep* 3(5):291, 2015
- Bourjeily G, Khalil H, Raker C, et al: Outcomes of negative multidetector computed tomography with pulmonary angiography in pregnant women suspected of pulmonary embolism. *Lung* 190:105, 2012
- Bourjeily G, Paidas M, Khalil H, et al: Pulmonary embolism in pregnancy. *Lancet* 375:500, 2010
- Branch DW, Gibson M, Silver RM: Recurrent miscarriage. *N Engl J Med* 363:18, 2010
- Brenner B: Haemostatic changes in pregnancy. *Thromb Res* 114:409, 2004
- Brown CE, Stettler RW, Twickler D, et al: Puerperal septic pelvic thrombophlebitis: incidence and response to heparin therapy. *Am J Obstet Gynecol* 181:145, 1999
- Brumfield CG, Hauth JC, Andrews WW: Puerperal infection following cesarean delivery: evaluation of a standardized protocol. *Am J Obstet Gynecol* 182:1147, 2000
- Carson JL, Kelley MA, Duff A, et al: The clinical course of pulmonary embolism. *N Engl J Med* 326:1240, 1992
- Castagnola DE, Hoffman MK, Carlson J, et al: Necrotizing cervical and uterine infection in the postpartum period caused by Group A Streptococcus. *Obstet Gynecol* 111:533, 2008
- Centers for Disease Control and Prevention: Procedure-associated module: surgical site infection (SSI) event. 2014. Available at: <http://www.cdc.gov/nhsn/PDFs/pscManual/9pscSSICurrent.pdf>. Accessed April 14, 2015
- Chan WS, Spencer FA, Ginsberg JS: Anatomic distribution of deep vein thrombosis in pregnancy. *CMAJ* 182:657, 2010
- Collins CG: Suppurative pelvic thrombophlebitis: a study of 202 cases in which the disease was treated by ligation of the vena cava and ovarian vein. *Am J Obstet Gynecol* 108:681, 1970
- Collins CG, McCallum EA, Nelson ER: Suppurative pelvic thrombophlebitis. I. Incidences, pathology, etiology. *Surgery* 30:298, 1951
- Columbus Investigators: Low-molecular-weight heparin in the treatment of patients with venous thromboembolism. *N Engl J Med* 337:657, 1997
- Creanga AA, Berg CJ, Syverson C, et al: Pregnancy-related mortality in the United States, 2006–2010. *Obstet Gynecol* 125(1):5, 2015
- Cunningham FG: Screening for osteoporosis. *N Engl J Med* 353:1975, 2005
- de Moya MA, del Carmen MG, Allain RM, et al: Case records of the Massachusetts General Hospital. Case 33–2009. A 35-year old woman with fever, abdominal pain, and hypotension after cesarean section. *N Engl J Med* 361:1689, 2009
- DePalma RT, Cunningham FG, Leveno KJ, et al: Continuing investigation of women at high risk for infection following cesarean delivery. *Obstet Gynecol* 60:53, 1982
- Dinsmoor MJ, Gilbert S, Landon MB, et al: Perioperative antibiotics for non-laboring cesarean delivery. *Obstet Gynecol* 114(4):752, 2009
- DiZerega G, Yonekura L, Roy S, et al: A comparison of clindamycin-gentamicin and penicillin-gentamicin in the treatment of post-cesarean section endomyometritis. *Am J Obstet Gynecol* 134:238, 1979
- do Nascimento Junior P, Modolo NS, Andrade S, et al: Incentive spirometry for prevention of postoperative pulmonary complications in upper abdominal surgery. *Cochrane Database Syst Rev* 2:CD006058, 2014
- Duff P, Gibbs R: Pelvic vein thrombophlebitis: diagnostic dilemma and therapeutic challenge. *Obstet Gynecol Surv* 38:365, 1983
- Dunniho DR, Gallaspy JW, Wise RB, et al: Postpartum ovarian vein thrombophlebitis: a review. *Obstet Gynecol Surv* 46:415, 1991
- Emmons SL, Krohn M, Jackson M, et al: Development of wound infections among women undergoing cesarean section. *Obstet Gynecol* 72:559, 1988
- Engoren M: Lack of association between atelectasis and fever. *Chest* 107:81, 1995
- Erdman WA, Jayson HT, Redman HC, et al: Deep venous thrombosis of extremities: role of MR imaging in the diagnosis. *Radiology* 174:425, 1990
- Erkan D, Kozora E, Lockshin MD: Cognitive dysfunction and white matter abnormalities in antiphospholipid syndrome. *Pathophysiology* 18(1):93, 2011
- Filker R, Monif GR: The significance of temperature during the first 24 hours postpartum. *Obstet Gynecol* 53:359, 1979
- Gibbs CP, Banner TC: Effectiveness of Bicitra as a preoperative antacid. *Anesthesiology* 61(1):97, 1984
- Gibbs RS: Microbiology of the female genital tract. *Am J Obstet Gynecol* 156:491, 1987
- Gilstrap LC III, Cunningham FG: The bacterial pathogenesis of infection following cesarean section. *Obstet Gynecol* 53:545, 1979
- Ginsberg JS, Brill-Edwards P, Burrows RF, et al: Venous thrombosis during pregnancy: leg and trimester of presentation. *Thromb Haemost* 67:519, 1992
- Goepfert AR, Guinn DA, Andrews WW, et al: Necrotizing fasciitis after cesarean section. *Obstet Gynecol* 89:409, 1997
- Goldhaber SZ, Visani L, De Rosa M: Acute pulmonary embolism: clinical outcomes in the International Cooperative Pulmonary Embolism Registry (ICOPER). *Lancet* 353:1386, 1999
- Gomi H, Goto Y, Laopaiboon M, et al: Routine blood cultures in the management of pyelonephritis in pregnancy for improving outcomes. *Cochrane Database Syst Rev* 2:CD009216, 2015
- González CA, Rodríguez-Borregan JC, Obeso T, et al: Necrotizing fasciitis after cesarean section. *Arch Gynecol Obstet* 277:579, 2008
- Gould MK, Dembitzer AD, Doyle RL, et al: Low-molecular weight heparins compared with unfractionated heparin for treatment of acute deep venous thrombosis. A meta-analysis of randomized, controlled trials. *Ann Intern Med* 130:800, 1999
- Halvorson LM: First-trimester abortion. In Hoffman BL, Schorge JO, Bradshaw KD, et al: *Williams Gynecology*, 3rd ed. New York, McGraw-Hill Education, 2016
- Hill JB, Sheffield JS, McIntire DD, et al: Acute pyelonephritis in pregnancy. *Obstet Gynecol* 105:38, 2005
- Jacobsen AF, Skjeldestad FE, Sandset PM: Incidence and risk patterns of venous thromboembolism in pregnancy and puerperium—a register-based case-control study. *Am J Obstet Gynecol* 198:233, 2008
- James AH: Venous thromboembolism in pregnancy. *Arterioscler Thromb Vasc Biol* 29:326, 2009
- James AH, Tapson VF, Goldhaber SZ: Thrombosis during pregnancy and the postpartum period. *Am J Obstet Gynecol* 193:216, 2005
- Kearon C, Akl EA, Comerota AJ, et al: Antithrombotic therapy for VTE disease: antithrombotic therapy and prevention of thrombosis, 9th ed: American College of Chest Physicians evidence-based clinical practice guidelines. *Chest* 141:e419s, 2012
- Kelton JG, Arnold DM, Bates SM: Nonheparin anticoagulants for heparin-induced thrombocytopenia. *N Engl J Med* 368:737, 2013
- Kindig M, Cardwell M, Lee T: Delayed postpartum uterine dehiscence. *J Reprod Med* 43:591, 1998
- Ledger W, Peterson E: The use of heparin in the management of pelvic thrombophlebitis. *Surg Gynecol Obstet* 131:1115, 1970
- Lee IW, Kang L, Hsu HP, et al: Puerperal mastitis requiring hospitalization during a nine-year period. *Am J Obstet Gynecol* 203(4):332 e1, 2010
- Lensing AW, Prandon P, Brandjes D, et al: Detection of deep-vein thrombosis by real-time B-mode ultrasonography. *N Engl J Med* 320:342, 1989
- Linkins L-A, Dans AL, Moores LK, et al: Treatment and prevention of heparin-induced thrombocytopenia. *Chest* 141:e495S, 2012
- Liu Y, Sun Y, Zhang S, et al: Placement of a retrievable inferior vena cava filter for deep venous thrombosis in term pregnancy. *J Vasc Surg* 55:1042, 2012
- Lockwood C: Thrombosis, thrombophilia, and thromboembolism: clinical updates in women's health care. *American College of Obstetricians and Gynecologists Vol. 1, No. 4, October 2007, Reaffirmed 2012*
- Mackeen AD, Packard RE, Ota E, et al: Antibiotic regimens for postpartum endometritis *Cochrane Database Syst Rev* 2:CD001067, 2015
- Macklon NS, Greer IA: The deep venous system in the puerperium: an ultrasound study. *BJOG* 104:198, 1997a
- Macklon NS, Greer IA, Bowman AW: An ultrasound study of gestational and postural changes in the deep venous system of the leg in pregnancy. *BJOG* 104:191, 1997b
- Maharaj D: Puerperal pyrexia: a review. Part I. *Obstet Gynecol Surv* 62(6):400, 2007
- Mangesi L, Dowswell T: Treatments for breast engorgement during lactation. *Cochrane Database Syst Rev* 9:CD006946, 2010
- Mangram AJ, Horan TC, Pearson ML, et al: Guideline for prevention of surgical site infection, 1999. *Hospital Infection Control Practices Advisory Committee. Infect Control Hosp Epidemiol* 20:250, 1999
- Marik PE: Aspiration pneumonitis and aspiration pneumonia. *N Engl J Med* 344:665, 2001
- Marik PE: Pulmonary aspiration syndromes. *Curr Opin Pulm Med* 17(3):148, 2011
- Marshall BR, Hepper JK, Zirbel CC: Sporadic puerperal mastitis—an infection that need not interrupt lactation. *JAMA* 344:1377, 1975
- Martin MA, Hamilton BE, Osterman MJ, et al: Births: final data for 2013. *64(1):1*, 2015
- McDonnold M, Friedman A, Raker C, et al: Is postpartum pyelonephritis associated with the same maternal morbidity as antepartum pyelonephritis? *J Matern Fetal Neonatal Med* 25(9):1709, 2012
- McNeeley SG Jr, Hendrix SL, Bennett SM, et al: Synthetic graft placement in the treatment of fascial dehiscence with necrosis and infection. *Am J Obstet Gynecol* 179:1430, 1998
- Miyakis S, Lockshin MD, Atsumi T, et al: International consensus statement on an update of the classification criteria for definite antiphospholipid syndrome (APS). *J Thromb Haemost* 4:295, 2006

- Moores LK, Jackson WL, Shorr AF, et al: Meta-analysis: outcomes in patients with suspected pulmonary embolism managed with computed tomographic pulmonary angiography. *Ann Intern Med* 141:866, 2004
- Naeem M, Rahimnadjad MK, Rahimnadjad NA, et al: Comparison of incision and drainage against needle aspiration for the treatment of breast abscess. *Am Surg* 78(11):1224, 2012
- Neill AM, Appleton DS, Richards P: Retrievable inferior vena caval filter for thromboembolic disease in pregnancy. *BJOG* 104:1416, 1997
- Nelson SM, Greer IA: Thrombophilia and the risk for venous thromboembolism during pregnancy, delivery and puerperium. *Obstet Gynecol Clin North Am* 33:413, 2006
- Opøien HK, Valbø A, Grinde-Anderson A, et al: Post-cesarean surgical site infection according to CDC standards: rates and risk factors. A prospective study. *Acta Obstet Gynecol Scand* 86:1097, 2007
- Pierangeli SS, Leader B, Barilaro G, et al: Acquired and inherited thrombophilia disorders in pregnancy. *Obstet Gynecol Clin North Am* 38:271, 2011
- PIOPED Investigators: Value of the ventilation/perfusion scan in acute pulmonary embolism: results of the Prospective Investigation of Pulmonary Embolism Diagnosis (PIOPED). *JAMA* 263:2753, 1990
- Pollack CV, Schreiber D, Goldhaber SZ, et al: Clinical characteristics, management, and outcomes of patients diagnosed with acute pulmonary embolism in the emergency department. *JACC* 57:700, 2011
- Reilly J, Allardice G, Bruce J, et al: Procedure-specific surgical site infection rates and postdischarge surveillance in Scotland. *Infect Control Hosp Epidemiol* 27:1318, 2006
- Roberts J, Barnes W, Pennock M, et al: Diagnostic accuracy of fever as a measure of postoperative pulmonary complications. *Heart Lung* 17:166, 1988
- Robertson L, Wu O, Langhorne P, et al: Thrombophilia in pregnancy: a systematic review. *Br J Haematol* 132:171, 2006
- Rouse DJ, Landon M, Leveno KJ, et al: The Maternal-Fetal Medicine Units cesarean registry: chorioamnionitis at term and its duration—relationship to outcomes. *Am J Obstet Gynecol* 191:211, 2004
- Sanchez-Ramos L, McAlpine KJ, Adair CD, et al: Pyelonephritis in pregnancy: once a day ceftriaxone versus multiple doses of cefazolin. A randomized double-blind trial. *Am J Obstet Gynecol* 172:129, 1995
- Schorge JO, Granter SR, Lerner LH, et al: Postpartum and vulvar necrotizing fasciitis. Early clinical diagnosis and histo-pathological correlation. *J Reprod Med* 43:586, 1998
- Shahir K, Goodman LR, Tali A, et al: Pulmonary embolism in pregnancy: CT pulmonary angiography versus perfusion scanning. *AJR Am J Roentgenol* 195:W214, 2010
- Sheffield JS, Cunningham FG: Detecting and treating septic pelvic thrombophlebitis. *Emerg Med* 46(3):15, 2001
- Sheffield JS, Cunningham FG: Urinary tract infection in women. *Obstet Gynecol* 106:1085, 2005
- Simonneau G, Sors H, Charbonnier B, et al: A comparison of low-molecular-weight heparin with unfractionated heparin for acute pulmonary embolism. *N Engl J Med* 337:663, 1997
- Small F, Gyte GM: Antibiotic prophylaxis versus no prophylaxis for preventing infection after cesarean section. *Cochrane Database Syst Rev* 12:CD007772, 2010
- Stafford I, Hernandez J, Laibl V, et al: Community-acquired methicillin-resistant *Staphylococcus aureus* among patients with puerperal mastitis requiring hospitalization. *Obstet Gynecol* 112(3):533, 2008
- Stein PD, Athanasoulis C, Alavi A, et al: Complications and validity of pulmonary angiography in acute pulmonary embolism. *Circulation* 85:462, 1992
- Sullivan SA, Smith T, Chang E, et al: Administration of cefazolin prior to skin incision is superior to cefazolin at cord clamping in preventing post-cesarean infectious morbidity: a randomized, controlled trial. *Am J Obstet Gynecol* 197:333, 2007
- Sultan AA, West J, Tata LJ, et al: Risk of first venous thromboembolism in and around pregnancy: a population-based cohort study. *Br J Haematol* 156(3):366, 2012
- Sutton GP, Smirz LR, Clark DH, et al: Group B streptococcal necrotizing fasciitis arising from an episiotomy. *Obstet Gynecol* 66:733, 1985
- Tapson VF: Acute pulmonary embolism. *N Engl J Med* 358:1037, 2008
- Thigpen BD, Hood WA, Chauhan S, et al: Timing of prophylactic antibiotic administration in the uninfected laboring gravida: a randomized clinical trial. *Am J Obstet Gynecol* 192:1864, 2005
- Thompson CD, Brekken AL, Kutteh WH: Necrotizing fasciitis: a review of management guidelines in a large obstetrics and gynecology teaching hospital. *Infect Dis Obstet Gynecol* 1:16, 1993
- Thomsen AC, Espersen T, Maigaard S: Course and treatment of milk stasis, noninfectious inflammation of the breast, and infectious mastitis in nursing women. *Am J Obstet Gynecol* 149:492, 1984
- Torkzad MR, Bremme K, Hellgren M, et al: Magnetic resonance imaging and ultrasonography in diagnosis of pelvic vein thrombosis during pregnancy. *Thromb Res* 126:107, 2010
- Tyson AF, Kendig CE, Mabedi C, et al: The effect of incentive spirometry on postoperative pulmonary function following laparotomy: a randomized clinical trial. *JAMA Surg* 150(3):229, 2015
- Udagawa H, Oshio Y, Shimizu Y: Serious group A streptococcal infection around delivery. *Obstet Gynecol* 94:153, 1999
- van Beek EJ, Wild JM, Fink C, et al: MRI for the diagnosis of pulmonary embolism. *J Magn Reson Imaging* 18:627, 2003
- Walmer D, Walmer KR, Gibbs RS: Enterococci in post-cesarean endometritis. *Obstet Gynecol* 71:159, 1988
- Wechter ME, Peralman MD, Hartmann KE: Reclosure of the disrupted laparotomy wound: a systematic review. *Obstet Gynecol* 106:376, 2005
- Wetchler SJ, Dunn LJ: Ovarian abscess. Report of a case and a review of the literature. *Obstet Gynecol Surv* 40:476, 1985
- Wing DA, Hendershott CM, Debuque L, et al: A randomized trial of three antibiotic regimens for the treatment of pyelonephritis in pregnancy. *Am J Obstet Gynecol* 92:249, 1998
- Wing DA, Park AS, Debuque L, et al: Limited clinical utility of blood and urine cultures in the treatment of acute pyelonephritis during pregnancy. *Am J Obstet Gynecol* 182:1437, 2000
- Witlin AG, Sibai BM: Postpartum ovarian vein thrombosis after vaginal delivery: a report of 11 cases. *Obstet Gynecol* 85:775, 1995

Puerperal Sterilization

TIMING	524
SURGICAL APPROACHES OVERVIEW	525
COUNSELING	525
PUERPERAL STERILIZATION AFTER VAGINAL DELIVERY	528
STERILIZATION AT THE TIME OF CESAREAN DELIVERY	530
IMMEDIATE POSTPARTUM PLACEMENT OF INTRAUTERINE CONTRACEPTION	531
IMMEDIATE POSTPARTUM PLACEMENT OF SUBDERMAL CONTRACEPTIVE	533

INTRODUCTION

In the United States during survey years 2006 to 2010, sterilization was the most commonly reported form of contraception among women aged 15 to 44 years. Specifically, among women using contraception, 36 percent relied on either male or female sterilization (Jones, 2012). The yearly incidence of these procedures cannot be tracked accurately because most interval tubal sterilizations and vasectomies are performed in ambulatory surgical centers. However, according to the National Survey of Family Growth, approximately 643,000 female tubal sterilizations are performed annually in the United States (Chan, 2010).

Sterilization can be offered to women or men. In the United States, female sterilization is approximately three times more common than male sterilization (Guttmacher Institute, 2015). Of sterilization procedures, vasectomy is available to men. For women, options are greater and are presented in this chapter.

When female sterilization is performed at the time of a neonate's birth, either at cesarean delivery or very soon after vaginal birth, such sterilization is called *puerperal* or *postpartum sterilization*. For procedures completed at a time unrelated to delivery, the term *interval sterilization* is used.

PATIENT ACCESS

Unfortunately, access to puerperal sterilization is not universal. One barrier is a federal regulation that requires all women covered by government insurance to sign a surgical consent at least 30 days prior to the procedure (Borrero, 2013, 2014). Another barrier is seen in high-volume labor and delivery units, which typically prioritize limited operating-room availability for intrapartum procedures. Improvement may be achieved by designating postpartum sterilization surgeries as urgent (American College of Obstetricians and Gynecologists, 2014; Potter, 2013).

In women who are unable to achieve the sterilization they desire, effects can be profound. Thurman and colleagues (2010) found the rate of subsequent conception within a year of the delivery in such women doubled compared with women who were also within a year of delivery but had not requested sterilization.

TIMING

Tubal sterilization can be performed concurrently with pregnancy termination that may be cesarean delivery, vaginal delivery, or pregnancy evacuation. Each of these influences options for surgical approach and tubal occlusion method. For example, after vaginal delivery, most procedures are partial salpingectomies completed through an umbilical incision and described later.

If puerperal sterilization cannot be performed, then most surgeons prefer to wait at least 4 to 6 weeks postpartum to ensure complete uterine involution and diminished blood flow to the fallopian tubes. These cases performed later are considered interval sterilization, described next.

Most interval procedures are performed laparoscopically, mainly because of minimally invasive surgery's postoperative advantages. With laparoscopy, sterilization is most frequently achieved with tubal occlusion by mechanical clips, by Silastic bands, by electrosurgical coagulation, or by suture ligation (Pati, 2000). Alternatively, minilaparotomy is infrequently selected for interval partial salpingectomy for women in the United States who elect sterilization (Peterson, 1996). It is an option for situations in which laparoscopy may not be indicated. Examples include cases complicated by extensive adhesions, those in which other concurrent pelvic pathology dictates laparotomy, or those in which laparoscopic equipment or surgical skills are lacking. Last, hysteroscopic sterilization is a minimally invasive, transcervical method to perform surgical sterilization. Currently, only the Essure Permanent Birth Control system is Food and Drug Administration (FDA)-approved and manufactured. This method employs a coiled microinsert that is placed into the proximal section of each fallopian tube. Over time, synthetic fibers within the insert incite local tissue ingrowth from the surrounding tube to occlude the tubal lumen. Generally, interval sterilization is considered in the realm of general gynecologic practice. Thus, interested readers are referred to *Williams Gynecology, 3rd edition*.

SURGICAL APPROACHES OVERVIEW

As noted earlier, the surgical approach to puerperal sterilization is influenced by mode of delivery. With cesarean delivery and its attendant laparotomy, tubal sterilization typically follows hysterotomy closure. After vaginal delivery, sterilization usually is completed through a minilaparotomy incision at the level of the uterine fundus, that is, periumbilically. After a first- or second-trimester pregnancy loss or termination, the uterus is smaller and lies well below the umbilicus. In these cases, a low transverse or midline vertical minilaparotomy incision is chosen and is positioned to allow optimal access to the fallopian tubes. In each of these instances, sterilization is traditionally completed by *partial midsegment salpingectomy*. With this, a midportion of the fallopian tube length is tied with suture and excised. Less often, a clip may be applied across the tube instead. In contrast to these, a risk-reducing *total salpingectomy* may be preferred. The rationale for this choice is described later on this page.

Sterilization timing also influences the choice of anesthesia, and regional or general anesthesia is typical. That used to accomplish cesarean delivery will suffice for concurrent sterilization. Similarly, epidural anesthesia placed prior to vaginal delivery is ideal for an immediate puerperal procedure. Others may prefer to delay obstetric surgery to the morning after vaginal delivery. This approach may be advantageous if there is concern for postpartum hemorrhage complicating recovery or if a delay would allow the status of the newborn to be better ascertained prior to surgery. If scheduled for the first postpartum day, spinal analgesia is preferable to general anesthesia, as postpartum women are at increased risk for aspiration due to delayed gastric emptying. If used, steps are taken to avoid aspiration. Last, in resource-limited areas, where general or regional anesthesia may not be available, local anesthesia can be used.

COUNSELING

The conversation between a clinician and patient regarding sterilization ideally contains a discussion of contraceptive alternatives, procedure goals and limitations, efficacy, and short- and long-term surgical risks. Topics in that discussion are presented here.

■ Mortality and Morbidity

The risk of death from puerperal tubal sterilization is remarkably low. In the United States, the case-fatality rate for all deaths attributed to all tubal sterilization procedures is 1 to 2 deaths per 100,000 procedures (Escobedo, 1989). Complications of general anesthesia are the leading cause of death from tubal sterilization in the United States. Others include sepsis and hemorrhage (Peterson, 1983).

Few studies have evaluated morbidity and mortality associated specifically with puerperal sterilization. The best estimates for puerperal sterilization after vaginal delivery may be taken from studies of minilaparotomy. One of these is the Collaborative Review of Sterilization (CREST), a multicenter cohort study that followed women for up to 14 years after tubal sterilization. These investigators found major complications in 1.7 percent of women undergoing interval laparoscopic sterilization and among 3.5 percent of women undergoing interval minilaparotomy procedures (incision length ≤ 4 cm) (DeStefano, 1983; Layde, 1983). Study participants were not randomized, and women undergoing interval laparotomy procedures likely had intrinsically greater surgical risk factors.

Incision length was also identified as an important determinant of complication rate. Women with an incision 7 cm or longer had a threefold greater complication rate than women with shorter incisions (Layde, 1983). In some of these women, incisions initially ≤ 4 cm may have been extended to manage complications. However, it is likely that incision length is an independent risk factor for complications, and longer incisions raise associated morbidity rates.

■ Risk-Reducing Salpingectomy

The Society of Gynecologic Oncology (2013) issued a statement regarding bilateral total salpingectomy as a prevention measure for ovarian cancer. This consideration of risk-reducing salpingectomy was later echoed by the American College of Obstetricians and Gynecologists (2015). Both organizations recommend consideration of bilateral total salpingectomy at the time of tubal sterilization or hysterectomy. This is especially true for women with the greatest ovarian cancer risk, specifically women with *BRCA1* or *BRCA2* mutation.

The rationale for this practice stems from the theory that most serous tumors of the ovary likely originate in the distal fallopian tube. Thus, total salpingectomy may confer a reduction in serous and endometrioid ovarian cancer rates (Erickson, 2013; Reade, 2014; Sieh, 2013).

In low-risk women, a procedure solely for risk-reducing salpingectomy is likely unwarranted based on current data. However, if hysterectomy or tubal sterilization is planned, all women should be counseled regarding the risks and benefits of bilateral total salpingectomy. Of benefits, in addition to proposed

cancer prevention, total salpingectomy substantially lowers the need for subsequent tubal surgery, especially for tubal ectopic pregnancy. Of disadvantages, operating time may be increased by 10 minutes (Creinin, 2014). Also, the long-term effects on ovarian blood supply from total salpingectomy are unclear. One small pilot studied antimüllerian hormone (AMH) levels up to 3 months in women after hysterectomy with or without total salpingectomy. As a brief review, AMH levels correlate with ovarian follicular reserves and can be a marker for ovarian failure. Investigators found no differences in AMH levels between the two groups. However, the follow-up length in this study was short (Findley, 2013). Finally, data are incomplete regarding increased bleeding complications with total compared with partial puerperal salpingectomy.

With risk-reducing salpingectomy, pelvic washing collection is not required in women at low risk for ovarian cancer. Specimen processing in this group obtains representative sections of the tube, any suspicious lesions, and entire sectioning of the fimbriae. This contrasts with women carriers of *BRCA1* and *BRCA2* mutations undergoing salpingectomy, and this genetic information should be clearly stated on the pathology requisition form. This prompts more thorough tubal specimen sectioning to search for cancer and precancerous lesions, which may already be present in the tubes of *BRCA* mutation carriers.

Regret

Invariably, some women will later express regrets regarding sterilization. From the CREST study, Jamieson and coworkers (2002) reported that by 5 years, 7 percent of women undergoing tubal ligation had regrets. This is not limited to female sterilization, as 6 percent of women whose husbands had undergone vasectomy had similar remorse. The cumulative probability of regret within 14 years of sterilization was 20 percent for women aged 30 or younger at sterilization compared with only 6 percent for those older than 30 years (Hillis, 1999).

Another important finding from the CREST study was the relationship between regret and the timing of sterilization relative to pregnancy (Hillis, 1999). Overall, the cumulative probability of regret decreased as time from the birth of the youngest child increased. This was particularly true for women 30 years or younger at the time of sterilization. Specifically, among these women the 14-year cumulative probability of regret was 16.2 percent for those who underwent sterilization between 2 and 3 years after the birth of their youngest child. The probability was 11.3 percent if sterilized 4 to 7 years after the birth, 8.3 percent at 8 or more years, and 6.3 percent among women with no previous births.

In sum, regret after sterilization is not rare. It is often triggered by life changes, such as divorce and remarriage, which are difficult to predict before sterilization. The fact that young age at sterilization is a strong and consistent predictor of later regret is likely a reflection of this association with life changes. On the other hand, some portion of women who do not choose sterilization may also experience regret. This can stem from subsequent unintended pregnancies or side effects of reversible contraceptive methods.

Although most women do not regret their choice of tubal sterilization, counseling, especially for young women, should empha-

size the permanency of tubal sterilization. Also, alternative, highly effective methods of contraception should each be described. Intrauterine devices (IUDs) and implantable hormonal forms are termed long-acting reversible contraception (LARC) and are considered very effective, first-tier choices. Oral and injectable hormonal contraceptives are other effective options.

Method Failure

Reasons for interval tubal sterilization failure are not always apparent, but some have been identified. First, surgical error may occur and likely accounts for 30 to 50 percent of cases. Second, tubal fistula may later develop. This is especially true with electrocoagulation procedures, but these are rarely used for puerperal sterilization. In some cases, sterilization failure may follow spontaneous reanastomosis of the tubal segments. With faulty clips, occlusion can be incomplete.

The overall failure rate reported from the CREST studies was 1.3 percent of 10,685 tubal sterilization surgeries. As shown in Figure 33-1, these rates vary for different procedures. The lifetime increased cumulative failure rates over time support that failures after 1 year are not likely due to technical errors. Indeed, Soderstrom (1985) found that most sterilization failures were not preventable.

The 10-year cumulative life table probability of failure varied considerably by method and age at sterilization (Table 33-1). But of methods, puerperal partial salpingectomy and laparoscopic unipolar coagulation were the most effective. They each had a 10-year cumulative probability of failure of 1.5 pregnancies per 1000 procedures. The cumulative probability of pregnancy was greater for women sterilized at ages younger than 28 years compared with women sterilized at ages 34 years and older. This trend held for all methods, except interval partial salpingectomy.

Failures occurred throughout the follow-up period. Specifically, the cumulative probabilities of pregnancy between years 5 and 10 after sterilization varied from 1.2 per 1000 procedures with puerperal partial salpingectomy to 8.3 per 1000 procedures for bipolar coagulation. Thus, it is clear from this

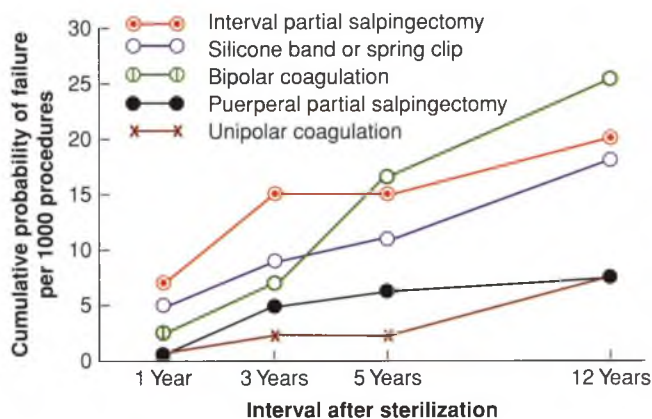


FIGURE 33-1 Data from the U.S. Collaborative Review of Sterilization (CREST) shows the cumulative probability of pregnancy per 1000 procedures by five methods of tubal sterilization. (Data from Peterson, 1996; reproduced with permission from Stuart GS: Contraception. In Hoffman BL, Schorge JO, Bradshaw KD, et al: Williams Gynecology, 3rd ed. New York, McGraw-Hill Education, 2016.)

TABLE 33-1. Life-Table Cumulative Probability of Pregnancy among Women Undergoing Tubal Sterilization by Age and Method^a

Age at Sterilization	No. ^b	Years since Sterilization			
		1	2	5	10
18–27 yr					
Bipolar coagulation	693	3.0 (0.0–7.1)	10.8 (2.9–18.8)	26.4 (12.5–40.4)	54.3 (28.3–80.4)
Unipolar coagulation	280	3.7 (0.0–11.1)	3.7 (0.0–11.1)	3.7 (0.0–11.1)	3.7 (0.0–11.1)
Silicone rubber band application	994	9.5 (3.3–15.7)	10.7 (4.1–17.3)	18.2 (8.9–27.5)	33.2 (10.6–55.9)
Spring clip application	694	24.1 (12.5–35.8)	32.4 (18.8–46.1)	45.3 (28.8–61.8)	52.1 (31.0–73.3)
Interval partial salpingectomy	120	0.0 (0.0–0.0)	9.7 (0.0–28.6)	9.7 (0.0–28.6)	9.7 (0.0–28.6)
Postpartum partial salpingectomy	707	1.5 (0.0–4.3)	7.8 (1.0–14.6)	7.8 (1.0–14.6)	11.4 (1.6–21.1)
28–33 yr					
Bipolar coagulation	786	2.6 (0.0–6.2)	2.6 (0.0–6.2)	18.7 (8.1–29.3)	21.3 (9.6–33.0)
Unipolar coagulation	549	0.0 (0.0–0.0)	2.0 (0.0–5.8)	2.0 (0.0–5.8)	15.6 (0.0–31.4)
Silicone rubber band application	1199	4.3 (0.5–8.1)	7.9 (2.8–13.1)	9.0 (3.4–14.6)	21.1 (6.4–35.9)
Spring clip application	487	21.2 (8.2–34.3)	25.7 (11.4–40.1)	31.3 (15.1–47.5)	31.3 (15.1–47.5)
Interval partial salpingectomy	137	7.5 (0.0–22.0)	15.4 (0.0–36.6)	15.4 (0.0–36.6)	33.5 (0.0–74.3)
Postpartum partial salpingectomy	625	0.0 (0.0–0.0)	1.7 (0.0–5.0)	5.6 (0.0–11.9)	5.6 (0.0–11.9)
34–44 yr					
Bipolar coagulation	788	1.3 (0.0–3.8)	1.3 (0.0–3.8)	6.3 (0.1–12.5)	6.3 (0.1–12.5)
Unipolar coagulation	603	0.0 (0.0–0.0)	1.8 (0.0–5.3)	1.8 (0.0–5.3)	1.8 (0.0–5.3)
Silicone rubber band application	1136	4.5 (0.6–8.4)	4.5 (0.6–8.4)	4.5 (0.6–8.4)	4.5 (0.6–8.4)
Spring clip application	414	5.0 (0.0–11.9)	7.6 (0.0–16.2)	10.4 (0.2–20.5)	18.2 (0.0–36.4)
Interval partial salpingectomy	168	12.3 (0.0–29.2)	18.7 (0.0–39.6)	18.7 (0.0–39.6)	18.7 (0.0–39.6)
Postpartum partial salpingectomy	305	0.0 (0.0–0.0)	0.0 (0.0–0.0)	3.8 (0.0–11.4)	3.8 (0.0–11.4)

^aCumulative probability per 1000 procedures and 95% confidence interval.

^bNumber of women sterilized.

Modified from Peterson, 1996.

information that a small risk of failure continues for many years after sterilization. Patients are so counseled and instructed to seek evaluation for amenorrhea, abnormal uterine bleeding, or pelvic pain, which all may herald ectopic pregnancy.

To help lower failure rates, tubal segments from puerperal partial salpingectomy are sent for histologic evaluation to confirm complete tubal transection bilaterally. If transection is deemed incomplete, then postoperative HSG can be scheduled to evaluate tubal occlusion. In the interim, other contraception should be used. In rare instances, the round ligament or a mesosalpingeal vein was erroneously ligated. For these women, laparoscopic or hysteroscopic sterilization, vasectomy for their partner, or other LARC can be offered.

■ Ectopic Pregnancy

Pregnancies following tubal sterilization have a high incidence of being ectopically implanted compared with the rate in a general gynecologic population (Bhiwandiwala, 1982; Chi, 1980; McCausland, 1980). These rates are especially high following electrocoagulation procedures, in which up to 65 percent of subsequent pregnancies are ectopic. With failures following other methods—Silastic ring, clip, tubal resection—this percentage is only 10 percent (Hendrix, 1999; Peterson, 1999). In the CREST study, the 10-year cumulative probability of

ectopic pregnancy for all methods of tubal sterilization was 7.3 per 1000 procedures.

The risk of ectopic pregnancy also continues long after the sterilization procedure. Again, in the CREST study, the annual rate of ectopic pregnancies was the same across the first 10 years following sterilization (Peterson, 1997).

The absolute risk of ectopic pregnancy for a woman after sterilization reflects both the relative likelihood of ectopic pregnancy when pregnancy occurs after sterilization and the overall likelihood of sterilization failure. Thus, if sterilization failures were rare, an increased relative risk of ectopic pregnancy might have little practical consequence for the individual. However, sterilization fails often enough that some women may be at an overall increased risk of ectopic pregnancy relative to the risk they had with their prior contraceptive method before sterilization.

In comparison with other contraceptive methods, interval sterilization has an ectopic pregnancy risk equal to the risk associated with IUD use. In contrast, puerperal sterilization had a lower ectopic pregnancy risk than IUD use (Holt, 1991; Peterson, 1997).

In sum, these data emphasize that ectopic pregnancy must be excluded when any symptoms of pregnancy develop in a woman who has undergone tubal sterilization. This holds true even if many years have elapsed since sterilization. For any

suspicion of pregnancy, the woman and her clinician should conduct a sensitive hormonal pregnancy test.

■ Menstrual Irregularities

Several studies have evaluated the risk of menorrhagia and intermenstrual bleeding following tubal sterilization, and many have reported no link (DeStefano, 1985; Shy, 1992). In addition, data from the CREST study are informative. Peterson and coworkers (2000) compared long-term outcomes of 9514 women who had undergone tubal sterilization with a cohort of 573 women whose partners had undergone vasectomy. Risks for menorrhagia, intermenstrual bleeding, and dysmenorrhea were similar in each group. Perhaps unexpectedly, women who had undergone sterilization had *decreased* duration and volume of menstrual flow and reported *less* dysmenorrhea, but they had an *increased* incidence of cycle irregularity.

■ Other Effects

Other long-term effects have also been studied. It is controversial whether risks for subsequent hysterectomy are increased (Pati, 2000). In a CREST surveillance study, Hillis and associates (1997) reported that 17 percent of women undergoing tubal sterilization subsequently had undergone hysterectomy by 14 years. Although they did not compare this incidence with a control cohort, the indications for hysterectomy were similar to those for nonsterilized women who had undergone a hysterectomy.

Women are highly unlikely to develop salpingitis following sterilization (Levgur, 2000). Tubal sterilization appears to have a protective effect against ovarian cancer but not breast cancer (Westhoff, 2000). The incidence of functional ovarian cysts is increased almost twofold following tubal sterilization (Holt, 2003).

Some psychological sequelae of sterilization were evaluated in a CREST study by Costello and colleagues (2002). These investigators reported that tubal ligation did not change sexual interest or pleasure in 80 percent of women. In the remaining 20 percent of women who reported a change, 80 percent described the changes to be positive.

■ Tubal Sterilization Reversal

No woman should undergo tubal sterilization believing that subsequent fertility is guaranteed either by surgical reanastomosis or by assisted reproductive technologies. These are technically difficult, expensive, and not always successful. With reanastomosis via laparotomy, rates of live births range from 44 to 82 percent (Deffieux, 2011; Malacova, 2015). In general, pregnancy rates after reversal favor women with ages younger than 35 years, with 7 cm of remaining tube, with a short time from antecedent sterilization, and with isthmic–isthmic repairs (Deffieux, 2011).

Data regarding in vitro fertilization (IVF) in this population is scarce. One retrospective cohort study compared IVF with tubal anastomosis (Boeckstaens, 2007). Authors reported that reanastomosis provided a significantly higher cumulative pregnancy rate for women younger than 37 years. For those older than 37, these rates did not differ.

Importantly, pregnancies that result after tubal sterilization reanastomosis are at risk to be ectopic. The rate of ectopic pregnancy after the procedure is 2 to 10 percent after reanastomosis. This compares with a 2-percent ectopic pregnancy rate in women with prior sterilization undergoing subsequent IVF (American Society for Reproductive Medicine, 2015).

PUERPERAL STERILIZATION AFTER VAGINAL DELIVERY

■ Preoperative Steps

In preparation for puerperal sterilization, several points are considered. As noted earlier, puerperal sterilization after vaginal birth is usually performed under general or regional anesthesia as an inpatient operation. For immediate postpartum procedures, the same regional anesthesia used for labor and birth can be used. Patients refrain from oral food or drink until after surgery. If performed the following day or for women not electing labor anesthesia, then a spinal block is typically selected. Technical aspects, limitations, and contraindications to various anesthesia types are described in Chapter 19 (p. 315). Notably, for those with preeclampsia, HELLP (hemolysis, elevated liver enzyme levels, low platelet count) syndrome, or gestational thrombocytopenia, platelet levels should be greater than 100,000 for spinal blockade.

■ Abdominal Entry

Puerperal sterilization after vaginal delivery is best performed within 24 hours of delivery. At this time, the level of the uterine fundus and thus access to fallopian tubes is close to the umbilicus. In women who delivered preterm or in those with rapid uterine involution, the fundus may lie substantially below the umbilicus. In these cases, the incision may need to be placed more caudad to reach the fallopian tubes. Thus, prior to surgery, the surgeon should palpate the fundus. Moreover, a distended bladder can shift the fundus cephalad. Accordingly, the bladder should be empty prior to surgery.

An infraumbilical skin incision is ideal for several reasons. As noted, the fundus in most cases lies near the umbilicus. Second, in most patients, especially obese women, the umbilicus remains the thinnest portion of the anterior abdominal wall and requires less subcutaneous dissection to reach the linea alba fascia. Third, an infraumbilical incision offers fascia with sufficient integrity to provide a closure that has minimal risk for later incisional hernia. Last, incisions that follow the natural curve of the lower umbilical skin fold yield suitable cosmesis. Surgical steps are described here. These mirror those for open Hassan laparoscopic entry, which is illustrated in Chapter 15 (p. 248).

In most cases, a 2- to 4-cm transverse or vertical skin incision is sufficient for normal-weight women. For obese women, a 4- to 6-cm incision may be needed for adequate abdominal access. In both instances, the small belly of a no. 15 blade may be preferred. Beneath this incision, the subcutaneous tissue is bluntly dissected and separated to reach the linea alba fascia. For this blunt dissection, an Allis clamp can be opened and closed as downward pressure is exerted. Similarly, the blades of two

army-navy or small Richardson retractors both pulling in downward yet opposite directions can part the subcutaneous layer. Clearing the subcutaneous fatty tissue away from the fascia at this early step will allow the fascia to be cleanly closed later without intervening fat, which may impede wound healing.

The fascial incision may be transverse or vertical and follows the same orientation as the skin incision. For this, once the linea alba is reached, it is grasped with two Allis clamps—one placed on either side of the planned fascial incision. This purchase of tissue with each clamp should be substantial and creates a small roll of fascia to be incised.

After incision of the fascia, the peritoneum is grasped with two hemostats and sharply incised. Others may prefer to bluntly enter with a single index finger. At this point, two small retractors such as army-navy, appendiceal, or S-retractors can be used to aid viewing. Notably, if the initial fascial incision is too small, it can be extended with curved Mayo scissors.

■ Fallopian Tube Identification

A common reason for sterilization failure is ligation of the wrong structure, usually the round ligament. Identification and isolation of the fallopian tube prior to ligation and submission of tubal segments for pathologic confirmation is therefore required. In some cases, especially those with associated tubal adhesions, this step may be challenging. Further, lateral extension of the incision may be needed for improved exposure. Women at risk for having extensive adhesions may be better served by choosing a vertical infraumbilical incision, which can be more easily and substantially extended than a transverse one.

For tubal identification, the uterine fundus is first identified. At the cornua, insertion of the fallopian tubes lies posterior to that of the round ligaments, and this orientation can initially guide the surgeon to the correct structure. A primary Babcock clamp is used to elevate the proximal fallopian tube, while a second clamp grasps the tube more distally. The primary clamp is then moved again and is placed distal to the second. The second is then removed and again placed distal to the first. In this manner, the surgeon “marches” down the length of the tube to reach the ampulla and identify fimbria. If possible, the adjacent ovary is also inspected.

■ Fallopian Tube Interruption

Several different techniques, described below, can be used to interrupt the tube. The choice is usually influenced by patient characteristics and surgeon preference.

Parkland Method

With this method of partial salpingectomy, the tube is first conclusively identified and then grasped at its midportion (Cunningham, 2014b). A hemostat is used to bluntly create a window in an avascular portion of the mesosalpinx just beneath the tube. The window is stretched to approximately 2.5 cm by opening the hemostat beneath the tube (Fig. 33-2). Two strands of 0-gauge chromic catgut are then passed through the window. The proximal and distal portions of the fallopian tube on either side of this window are then ligated individually with a single strand. The intervening tubal segment, measuring approximately

2 cm, is then resected. Importantly, the tube is resected to leave a tubal stump distal to each ligature that measures about 0.5 cm each. This tissue stump lowers the risk of the fallopian tube slipping out of its ligature to cause bleeding.

Pomeroy Technique

With this method of partial salpingectomy, the tube is first conclusively identified and then grasped at its midportion by a Babcock clamp. As the tube is elevated through the incision, it drapes downward on either side of the clamp to form a tubal loop. Importantly, the loop should be of sufficient length to ensure the tubal lumen will be completely transected. Next a strand of no. 1 plain catgut suture instead of chromic catgut suture is positioned to encircle the base of this tubal loop. Plain gut, which is absorbed more rapidly, is key. This is because the

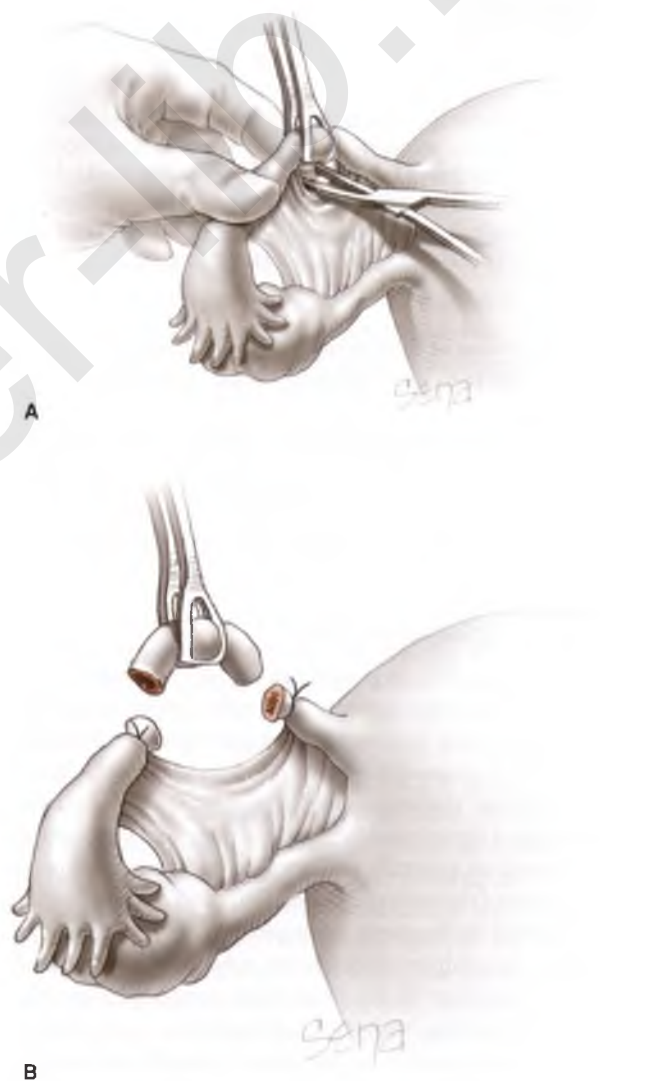


FIGURE 33-2 Parkland method. **A.** A window is bluntly made in the mesosalpinx beneath the fallopian tube using a hemostat. **B.** Once proximal and distal ligatures are placed around the tube, the intervening tubal portion is sharply excised. (Reproduced with permission from Hoffman BL, Corton MM: *Surgeries for benign gynecologic conditions*. In Hoffman BL, Schorge JO, Bradshaw KD, et al: *Williams Gynecology*, 3rd ed. New York, McGraw-Hill Education, 2016.)

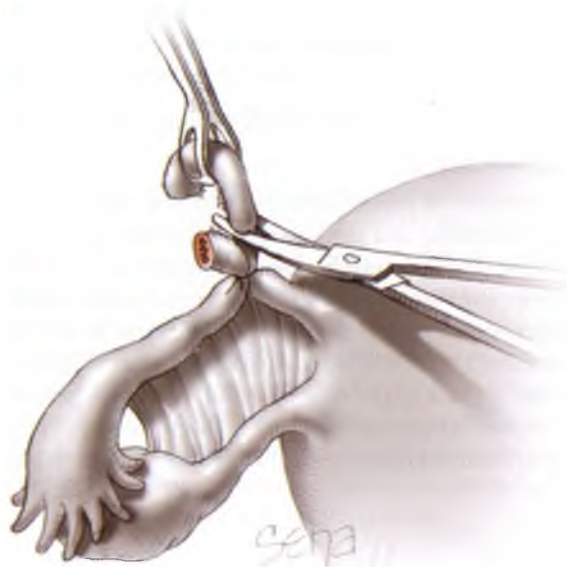

FIGURE 33-3 Pomeroy method. A ligature is placed around a loop of fallopian tube and tied. The loop of fallopian tube above this ligature is then sharply excised. (Reproduced with permission from Hoffman BL, Corton MM: *Surgeries for benign gynecologic conditions*. In Hoffman BL, Schorge JO, Bradshaw KD, et al: *Williams Gynecology*, 3rd ed. New York, McGraw-Hill Education, 2016.)

remaining portions of tube separate as the suture weakens. This separation, similar to the Parkland method, adds to contraceptive efficacy.

Once the loop of fallopian tube is ligated, the fallopian tube above the ligature is then transected with Metzenbaum scissors (Fig. 33-3). As with the Parkland method, the tube portion is resected to leave two tubal stumps that each measure about 0.5 cm.

Risk-Reducing Salpingectomy

As noted on page 525, in patients at low risk for ovarian cancer, risk-reducing salpingectomy may now also be considered in those undergoing hysterectomy or permanent sterilization (Creinin, 2014; Lessard-Anderson, 2014; McAlpine, 2014). However, several challenges may accompany total salpingectomy through a typical incision used for puerperal sterilization. First, the incision generally will need to be larger to allow an adequate view of the tube and mesosalpinx and to place clamps. Second, during midsegment salpingectomy, an avascular portion of the mesosalpinx beneath the tube is ideally selected. This limits laceration of the often large, congested mesosalpingeal veins. However, with total salpingectomy, such selective avoidance is not possible, as the entire mesosalpinx must be divided to free the fallopian tube. Thus, theoretical risks include bleeding and a larger laparotomy or adnexectomy to control this bleeding. Our clinical experience, although not evidence-based, substantiates this concern.

Irving and Uchida Methods

These techniques are rarely used and described here for completeness. With the Irving procedure, the fallopian tube is doubly

ligated and divided approximately 4 cm from the uterotubal junction. The proximal tubal stump is freed from its mesosalpinx. This free stump is then buried into a tunnel created within the posterior uterine wall myometrium and secured within this tunnel (Irving, 1950).

With the Uchida procedure, the fallopian tube is ligated near the uterotubal junction, and approximately 5 cm of the tube is resected (Uchida, 1975). After this, the short proximal tubal stump is allowed to retract into the mesosalpinx. The mesosalpinx edges are then reapproximated, which buries this proximal stump. In contrast, the distal end of the tube remains exteriorized.

Wound Closure and Recovery

Closure of the parietal peritoneum is not required. The fascia is closed using a continuous running suture with a 0-gauge delayed-absorbable suture. We prefer polyglactin 910 (Vicryl), which is easier to tie and requires fewer throws than polydioxanone (PDS II). If the subcutaneous layer measures less than 2 cm, then this layer is not closed. For deeper wounds, interrupted stitches of 2-0 to 4-0 gauge plain gut or delayed-absorbable suture are used to close the subcutaneous layer. The skin is closed with a subcuticular stitch using 4-0 gauge delayed-absorbable suture, staples, or other suitable method.

Recovery following minilaparotomy is typically rapid and without complication, and women may resume regular diet and activities as tolerated. Sterilization is immediate following surgery, and intercourse may resume at the patient's discretion.

STERILIZATION AT THE TIME OF CESAREAN DELIVERY

For patients for whom cesarean delivery is indicated, puerperal sterilization, if desired, can follow hysterotomy closure. In almost all instances, the same anesthesia used for cesarean delivery is used for the sterilization procedure.

Surgically, the biggest difference in puerperal sterilization during cesarean delivery is that the operative field is large, and fallopian tube visualization is straightforward. Yet, the entire fallopian tube length should still be identified prior to midsegment ligation. Tubal interruption approaches are the same as those following vaginal delivery, just described.

Notably, total salpingectomy may be somewhat easier because of the roomier operating field. To begin this procedure, the fimbrial end of one fallopian tube is elevated with a Babcock clamp. A second is positioned more medially, and both aid extension of the mesosalpinx (Fig. 33-4). Beginning at the distal, fimbriated end of the tube, one Kelly clamp or hemostat is placed across a 2-cm-long segment of the mesosalpinx, close to the fallopian tube. The clamp's curve faces the tube. Another clamp is similarly placed, but lies closer to the ovary. These clamps occlude vessels that traverse the mesosalpinx. Scissors then cut the interposed mesosalpinx.

The severed tissue pedicle that is closer to the ovary is then tied with 2-0 or 3-0 gauge absorbable suture, and the clamp is removed. The clamp closer to the tube remains and eventually leaves with the final specimen. Such clamping, cutting, and

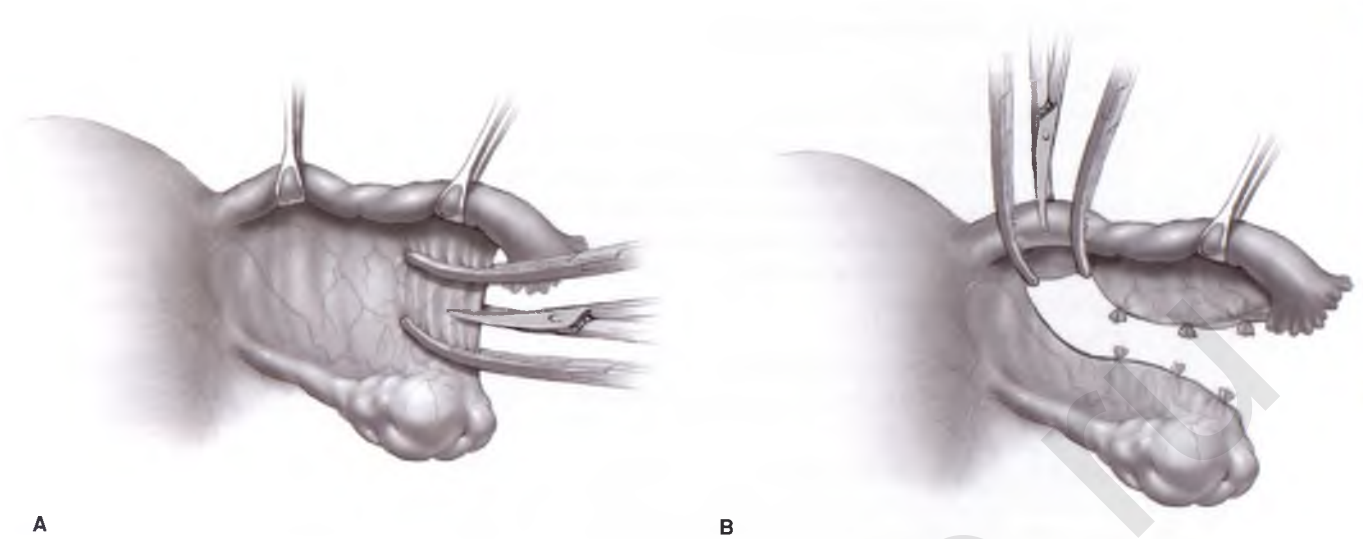


FIGURE 33-4 Total salpingectomy. **A.** The mesosalpinx is sequentially clamped, cut, and ligated. **B.** At the cornu, clamps are placed across the fallopian tube and its adjacent mesosalpinx prior to tubal transection.

ligating are repeated serially, with each clamp incorporating approximately 2 cm of mesosalpinx. Progression is directed from the fimbrial end of the fallopian tube toward the uterus.

The last clamp is placed across the proximal mesosalpinx and fallopian tube. Scissors then cut the mesosalpinx and tube and free these from the uterus. This pedicle is then similarly ligated.

Postoperatively, tubal sterilization adds negligible morbidity to cesarean delivery recovery. Thus, postoperative management and recovery mirror those for cesarean delivery without sterilization.

IMMEDIATE POSTPARTUM PLACEMENT OF INTRAUTERINE CONTRACEPTION

The immediate postpartum period, that is, after a birth but prior to discharge from the hospital, is an underused time to initiate contraceptives (Chen, 2010; Gurtcheff, 2012; Kapp, 2009). Women who desire highly effective contraception but decline sterilization can be offered IUD or subdermal implant placement during this time. This approach with LARC methods is highly effective to lower rates of early repeat pregnancy.

For women who choose to have an IUD placed immediately postpartum, both the copper-containing IUD (Paragard T380A) and the levonorgestrel-releasing intrauterine system (LNG-IUS) (Mirena or Liletta) are suitable options. Advantageously, the IUD can be inserted while parturients use their intrapartum anesthesia method. Contraindications to placement of an IUD immediately after placenta delivery include all contraindications to placement remote from delivery, as shown in Table 33-2. Moreover, an IUD should not be placed immediately postpartum in a woman with rupture of membranes longer than 24 hours or with evidence of peripartum metritis or uterine atony.

Suitable candidates are then counseled regarding the side effects and risks of IUDs in general. Some specific points are unique to puerperal insertion. First, placement of an IUD immediately after placenta delivery has an associated device-expulsion rate that approximates 10 percent for the copper-containing

IUD (Blumenthal, 2011). For the LNG-IUS, this rate may reach 27 percent (Chen, 2010; Dahlke, 2011). Placement of an IUD more than 6 hours after vaginal birth is associated with an expulsion rate of up to 30 percent (Stuart, 2015). Most expelled devices are recognized by the patient and result in repeat placement of a new device at a subsequent clinic visit. Thus, the cost of the expelled IUD combined with the inconvenience and risk of a second insertion procedure should be balanced against the woman's preference for and ease of contraception placement temporally related to vaginal birth. In some cases, the decision is influenced by her access to contraceptive services after leaving the hospital.

Women are also counseled that their IUD strings will likely not be visible or palpable after the uterus completes involution. Of consequences, device removal at a later time is more difficult and may require intrauterine probing with thin dressing forceps or IUD hook to extract the device. These manipulations can potentially increase pain and uterine perforation rates. As of this writing, the string attached to the copper IUD in the United States is shorter than that for the progestin-releasing IUDs. Thus, although not evidence-based, the copper IUD may be more likely to have strings retained in uterine cavity.

For breastfeeding, the copper IUD poses no conflict because it lacks hormones. However, breastfeeding after a progestin-releasing implant or IUD is placed early in the puerperium is the subject of academic discussion. No good data indicate whether or not these progestin-releasing devices are associated with a change in breastfeeding success. Similar data for women who have had a preterm delivery are even more limited. The best source for current literature on these topics is the Centers for Disease Control and Prevention (CDC). Specifically, the CDC's *United States Medical Eligibility Criteria* (2010, 2011) provides evidence-based guidance for the use of all highly effective reversible contraceptive methods by women with various health factors. These guidelines are available and updated regularly at the CDC website: <http://www.cdc.gov/reproductivehealth/UnintendedPregnancy/USMEC.htm>.

TABLE 33-2. Manufacturer Contraindications to IUD Use**ParaGard T 380**

Pregnancy or suspicion of pregnancy
 Abnormalities of the uterus resulting in distortion of the uterine cavity
 Acute PID, or current behavior suggesting a high risk for PID
 Postpartum endometritis or postabortal endometritis in the past 3 months
 Known or suspected uterine or cervical malignancy
 Genital bleeding of unknown etiology
 Mucopurulent cervicitis
 Wilson disease
 Allergy to any component of ParaGard
 A previously placed IUD that has not been removed

Mirena/Liletta

Pregnancy or suspicion of pregnancy
 Congenital or acquired uterine anomaly if it distorts the uterine cavity
 Acute PID or history of unless there has been a subsequent intrauterine pregnancy
 Postpartum endometritis or infected abortion in the past 3 months
 Known or suspected uterine or cervical neoplasia
 Uterine bleeding of unknown etiology
 Untreated acute cervicitis or vaginitis or other lower genital tract infections
 Acute liver disease or liver tumor (benign or malignant)
 Increased susceptibility to pelvic infection
 A previously placed IUD that has not been removed
 Hypersensitivity to any component of Mirena
 Known or suspected breast cancer or other progestin-sensitive cancer

IUD = intrauterine device; PID = pelvic inflammatory disease.

From Actavis, 2015; Bayer HealthCare, 2014; Teva Women's Health, 2013.

■ After Vaginal Delivery

For immediate IUD placement after placenta delivery, the woman is positioned in dorsal lithotomy. This can be achieved with or without the assistance of labor stirrups. Most of the published data in the United States are from studies using sonographic guidance. Such adjunctive imaging can help ensure that the IUD reaches the uterine fundus. For placement, manufacturer's inserters are usually too short to reach this level. Therefore, a ring forceps or a gloved hand is the best method to achieve fundal placement (Fig. 33-5). Importantly, with the LNG-IUS, the jaws of a ring forceps should gently hold the device shaft. A tight grasp can crush the shaft, which is the portion that contains and gradually releases the levonorgestrel. Following placement, the strings are left long and are guided through the cervix and into the vagina.

■ At Cesarean Delivery

Counseling regarding IUD placement at cesarean delivery mirrors that for vaginal delivery. One important difference is that both copper and progestin-releasing IUDs placed after cesarean

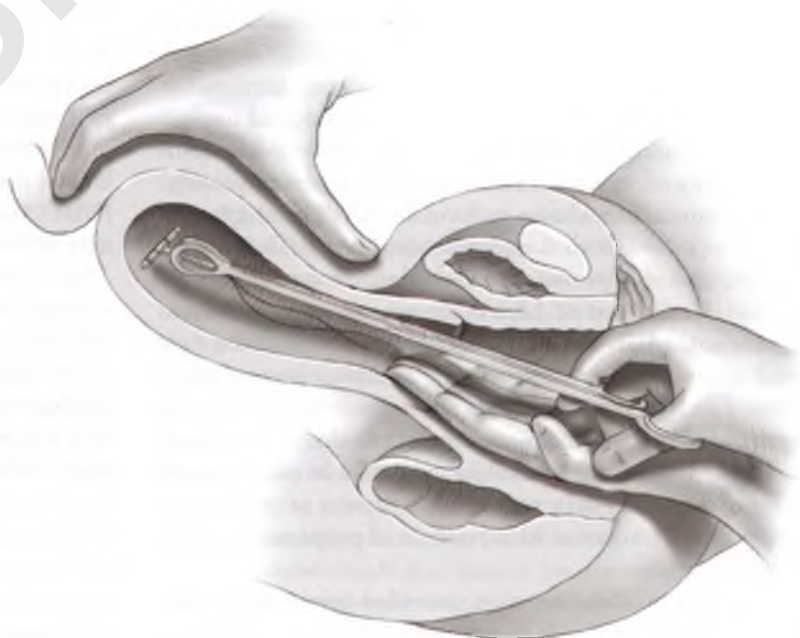


FIGURE 33-5 Intrauterine device (IUD) insertion after vaginal delivery. Ring forceps direct the device to the uterine fundus. Back pressure against the fundus by an abdominal hand can help guide positioning.

delivery are less likely to be expelled than those placed after vaginal delivery (Levi, 2015).

For placement, the manufacturers' inserter can be used and is threaded through the uterine hysterotomy incision (Fig. 33-6). In this setting, the device arms are left out, rather than tucked inside the inserter tube. This practice decreases the degree of required intrauterine manipulation. Once released from the inserter, the IUD strings are then guided into the vaginal canal using ring forceps. The IUD should not be secured to the uterine fundus with suture.

IMMEDIATE POSTPARTUM PLACEMENT OF SUBDERMAL CONTRACEPTIVE

The implant Nexplanon is currently the only subdermal contraceptive implant marketed in the United States. It is a single-rod subdermal implant containing 68 mg of a progestin—*etonogestrel*—and covered by an ethylene vinyl acetate copolymer. Nexplanon has replaced the similar earlier *etonogestrel* implant, Implanon.

Contraindications for this device are similar to those cited for other progestin-containing methods. Specifically, these include pregnancy, thrombosis or thromboembolic disorders, benign or malignant hepatic tumors, active liver disease, undiagnosed abnormal genital bleeding, or breast cancer (Merck, 2014). Importantly, patients are counseled that Nexplanon causes *irregular bleeding* that does not normalize over time. Thus, women who cannot tolerate unpredictable and irregular spotting or light bleeding should select an alternative method. Functional ovarian cysts develop with a greater frequency in women using progestin-only agents, although they do not usually necessitate intervention (Brache, 2002; European Society of Human Reproduction and Embryology, 2001).

For candidates desiring Nexplanon, the implant is inserted subdermally along the biceps groove of the inner arm and 6 to 8 cm from the elbow (Fig. 33-7). Immediately following insertion, the provider and patient should document that the device is palpable beneath the skin.

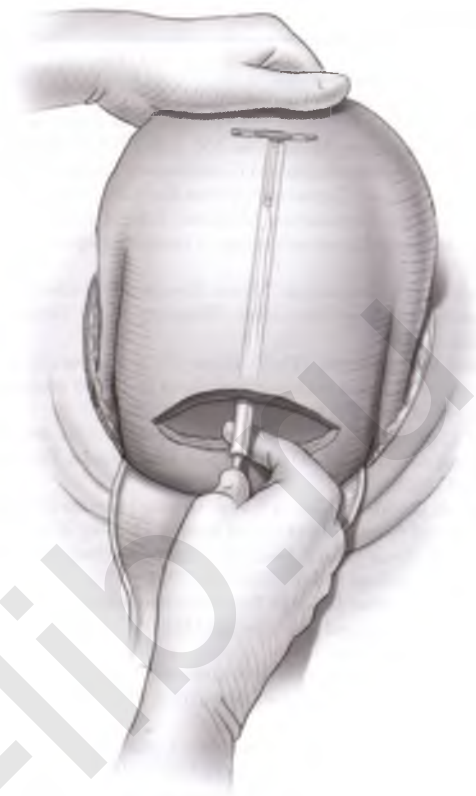


FIGURE 33-6 Intrauterine device (IUD) insertion at cesarean delivery. The device inserter guides the device to the uterine fundus. A hand at the fundus can provide back pressure to stabilize the uterus during insertion.

At a later time when Nexplanon is removed, this superficial location allows in-office extraction of the implant. Through a small incision large enough to admit hemostat tips, the implant is grasped and removed. If desired, a new rod can be placed through this same incision.

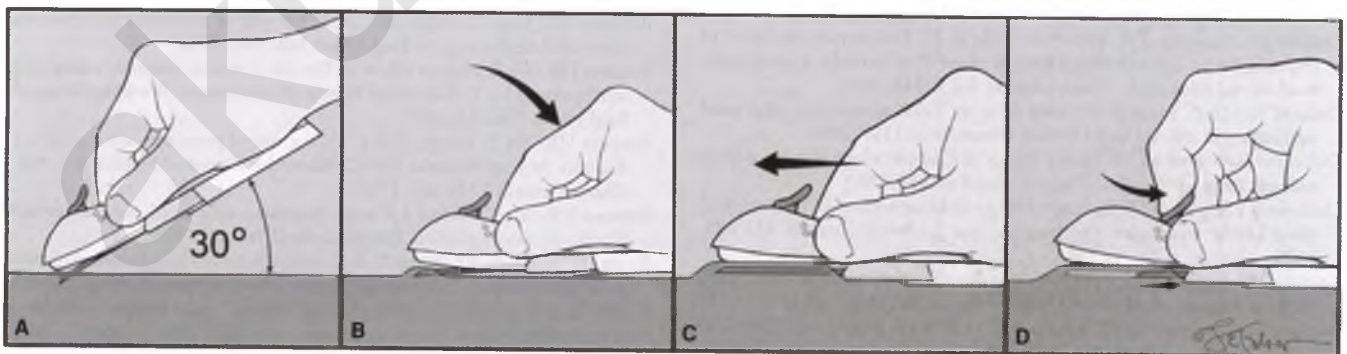


FIGURE 33-7 Nexplanon insertion. A sterile pen marks the insertion site, which is 8 to 10 cm proximal to the medial humeral condyle. A second mark is placed 4 cm proximally along the arm's long axis. The area is cleaned aseptically, and a 1-percent lidocaine anesthetic track is injected along the planned insertion path. **A.** The insertion device is grasped at its gripper bubbles found on either side, and the needle cap is removed outward. The needle bevel can be seen within the needle bore. The needle bevel then pierces the skin at a 30-degree angle. **B.** Once the complete bevel is subcutaneous, the needle is quickly angled downward to lie horizontally. **C.** Importantly, the skin is tented upward by the needle as the needle is slowly advanced horizontally and subdermally. **D.** Once the needle is completely inserted, the lever on the top of the device is pulled backward toward the operator. This retracts the needle and thereby deposits the implant. The device is then lifted away from the skin. After placement, both patient and operator should palpate the 4-cm implant. (Reproduced with permission from Cunningham FG, Leveno KL, Bloom SL, et al (eds): *Contraception*. In *Williams Obstetrics*, 24th ed. New York, McGraw-Hill Education, 2014a.)

REFERENCES

- Actavis: Liletta (levonorgestrel-releasing intrauterine system): prescribing information. Parsippany, Actavis Pharma, 2015
- American College of Obstetricians and Gynecologists: Access to postpartum sterilization. Committee Opinion No. 530, July 2012, Reaffirmed 2014
- American College of Obstetricians and Gynecologists: Salpingectomy for ovarian cancer prevention. Committee Opinion No. 620, January 2015
- American Society for Reproductive Medicine: Role of tubal surgery in the era of assisted reproductive technology: a committee opinion. *Fertil Steril* 103(6):e37, 2015
- Bayer HealthCare Pharmaceuticals: Mirena (levonorgestrel-releasing intrauterine system): prescribing information. Whippany, Bayer HealthCare Pharmaceuticals, 2014
- Bhiwandiwala PP, Mumford SD, Feldblum PJ: A comparison of different laparoscopic sterilization occlusion techniques in 24,439 procedures. *Am J Obstet Gynecol* 144:319, 1982
- Blumenthal P, Shiliya N, Neukom J, et al: Expulsion rates and satisfaction levels among postpartum IUD users in peri-urban Lusaka, Zambia. *Contraception* 84(3):320, 2011
- Boeckstaens A, Devroey P, Collins J, et al: Getting pregnant after tubal sterilization: surgical reversal or IVF? *Hum Reprod* 22:2660, 2007
- Borrero S, Zite N, Potter JE, et al: Medicaid policy on sterilization—anachronistic or still relevant? *N Engl J Med* 370(2):102, 2014
- Borrero S, Zite N, Potter JE, et al: Potential unintended pregnancies averted and cost savings associated with a revised Medicaid sterilization policy. *Contraception* 88(6):691, 2013
- Brache V, Faundes A, Alvarez F, et al: Nonmenstrual adverse events during use of implantable contraceptives for women: data from clinical trials. *Contraception* 65(1):63, 2002
- Centers for Disease Control and Prevention: Update to CDC's U.S. Medical Eligibility Criteria for Contraceptive Use, 2010: revised recommendations for the use of contraceptive methods during the postpartum period. *MMWR* 60(26):878, 2011
- Centers for Disease Control and Prevention: U.S. Medical Eligibility Criteria for Contraceptive Use, 2010. *MMWR* 59(4), 2010
- Chan LM, Westhoff CL: Tubal sterilization trends in the United States. *Fertil Steril* 94(1):1, 2010
- Chen BA, Reeves MF, Hayes JL, et al: Postplacental or delayed insertion of the levonorgestrel intrauterine device after vaginal delivery: a randomized controlled trial. *Obstet Gynecol* 116(5):1079, 2010
- Chi IC, Lafe LE, Gardner SD, et al: An epidemiologic study of risk factors associated with pregnancy following female sterilization. *Am J Obstet Gynecol* 136:768, 1980
- Costello, C, Hillis S, Marchbanks P, et al: The effect of interval tubal sterilization on sexual interest and pleasure. *Obstet Gynecol* 100:3, 2002
- Creinin MD, Zite N: Female tubal sterilization: the time has come to routinely consider removal. *Obstet Gynecol* 124(3):596, 2014
- Cunningham FG, Leveno KL, Bloom SL, et al (eds): *Contraception*. In *Williams Obstetrics*, 24th ed. New York, McGraw-Hill Education, 2014a
- Cunningham FG, Leveno KL, Bloom SL, et al (eds): *Sterilization*. In *Williams Obstetrics*, 24th ed. New York, McGraw-Hill Education, 2014b
- Dahlke JD, Terpstra ER, Ramseyer AM, et al: Postpartum insertion of levonorgestrel—intrauterine system at three time periods: a prospective randomized pilot study. *Contraception* 84(3):244, 2011
- Deffieux X, Morin Surroca M, Faivre E, et al: Tubal anastomosis after tubal sterilization: a review. *Arch Gynecol Obstet* 83(5):1149, 2011
- DeStefano F, Greenspan JR, Dicker RC, et al: Complications of interval laparoscopic tubal sterilization. *Obstet Gynecol* 61:153, 1983
- DeStefano F, Perlman JA, Peterson HB, et al: Long-term risks of menstrual disturbances after tubal sterilization. *Am J Obstet Gynecol* 152:835, 1985
- Erickson BK, Conner MG, Landen CN Jr: The role of the fallopian tube in the origin of ovarian cancer. *Am J Obstet Gynecol* 209(5):409, 2013
- Escobedo LG, Peterson HB, Grubb GS, et al: Case-fatality rates for tubal sterilization in U.S. hospitals, 1979–1980. *Am J Obstet Gynecol* 160:147, 1989
- European Society of Human Reproduction and Embryology—ESHRE Capri Workshop Group: Ovarian and endometrial function during hormonal contraception. *Hum Reprod* 16(7):1527, 2001
- Findley AD, Siedhoff MT, Hobbs KA, et al: Short-term effects of salpingectomy during laparoscopic hysterectomy on ovarian reserve: a pilot randomized controlled trial. *Fertil Steril* 100(6):1704, 2013
- Gurtcheff SE, Turok DK, Stoddard G, et al: Lactogenesis after early postpartum use of the contraceptive implant: a randomized controlled trial. *Obstet Gynecol* 117(5):1114, 2012
- Guttmacher Institute: *Contraceptive Use in the United States*. New York, AGI, 2015. Available at http://www.guttmacher.org/pubs/fb_contr_use.pdf. Accessed September 14, 2015
- Hendrix NW, Chauhan SP, Morrison JC: Sterilization and its consequences. *Obstet Gynecol Surv* 54:766, 1999
- Hillis SD, Marchbanks PA, Tylor LR, et al: Poststerilization regret: findings from the United States Collaborative Review of Sterilization. *Obstet Gynecol* 93:889, 1999
- Hillis SD, Marchbanks PA, Tylor LR, et al: Tubal sterilization and long-term risk of hysterectomy: findings from the United States Collaborative Review of Sterilization. *Obstet Gynecol* 89:609, 1997
- Hoffman BL, Corton MM: *Surgeries for benign gynecologic conditions*. In Hoffman BL, Schorge JO, Bradshaw KD, et al: *Williams Gynecology*, 3rd ed. New York, McGraw-Hill Education, 2016
- Holt VL, Chu J, Daling JR, et al: Tubal sterilization and subsequent ectopic pregnancy: a case-control study. *JAMA* 226:242, 1991
- Holt VL, Cushing-Haugen KL, Daling JR: Oral contraceptives, tubal sterilization, and functional ovarian cyst risk. *Obstet Gynecol* 102(2):252, 2003
- Irving FC: Tubal sterilization. *Am J Obstet Gynecol* 60:1101, 1950
- Jamieson DJ, Kaufman SC, Costello C, et al: A comparison of women's regret after vasectomy versus tubal sterilization. *Obstet Gynecol* 99:1073, 2002
- Jones J, Mosher W, Daniels K: Current contraceptive use in the United States, 2006–2010, and changes in patterns of use since 1995. *Natl Health Stat Report* 60:1, 2012
- Kapp N, Tilley IB, Curtis KM: The effects of hormonal contraceptive use among women with viral hepatitis or cirrhosis of the liver: a systematic review. *Contraception* 80(4):381, 2009
- Layde PM, Peterson HB, Dicker RC, et al: Risk factors for complications of interval tubal sterilization by laparotomy. *Obstet Gynecol* 62:180, 1983
- Lessard-Anderson CR, Handlogten KS, et al: Effect of tubal sterilization technique on risk of serous epithelial ovarian and primary peritoneal carcinoma. *Gynecol Oncol* 135(3):423, 2014
- Levgur M, Duvivier R: Pelvic inflammatory disease after tubal sterilization: a review. *Obstet Gynecol Surv* 55:41, 2000
- Levi EE, Stuart GS, Zerden ML, et al: Intrauterine device placement during cesarean delivery and continued use 6 months postpartum: a randomized controlled trial. *Obstet Gynecol* 126:5, 2015
- Malacova E, Kemp-Casey A, Bremner A, et al: Live delivery outcome after tubal sterilization reversal: a population-based study. *Fertil Steril* 104(4):92, 2015
- McAlpine JN, Hanley GE, Woo MM, et al: Opportunistic salpingectomy: uptake, risks, and complications of a regional initiative for ovarian cancer prevention. *Am J Obstet Gynecol* 210(5):471.e1, 2014
- McCausland A: High rate of ectopic pregnancy following laparoscopic tubal coagulation failures. *Am J Obstet Gynecol* 136:97, 1980
- Merck: Nexplanon (etonogestrel implant) prescribing information. Whitehouse Station, Merck & Co., 2014
- Pati S, Cullins V: Female sterilization: evidence. *Obstet Gynecol Clin North Am* 27:859, 2000
- Peterson HB, DeStefano F, Rubin GL, et al: Deaths attributable to tubal sterilization in the United States, 1977–1981. *Am J Obstet Gynecol* 146:131, 1983
- Peterson HB, Jeng G, Folger SG, et al: The risk of menstrual abnormalities after tubal sterilization. *N Engl J Med* 343:1681, 2000
- Peterson HB, Xia Z, Hughes JM, et al: The risk of ectopic pregnancy after tubal sterilization. U.S. Collaborative Review of Sterilization Working Group. *N Engl J Med* 336:762, 1997
- Peterson HB, Xia Z, Hughes JM, et al: The risk of pregnancy after tubal sterilization: findings from the U.S. Collaborative Review of Sterilization. *Am J Obstet Gynecol* 174:1161, 1996
- Peterson HB, Xia Z, Wilcox LS, et al: Pregnancy after tubal sterilization with bipolar electrocoagulation. *Obstet Gynecol* 94:163, 1999
- Potter JE, Stevenson AJ, White K, et al: Hospital variation in postpartum tubal sterilization rates in California and Texas. *Obstet Gynecol* 121(1):152, 2013
- Reade CJ, McVey RM, Tone AA, et al: The fallopian tube as the origin of high grade serous ovarian cancer: review of a paradigm shift. *J Obstet Gynaecol Can* 36(2):133, 2014
- Shy KK, Stergachis A, Grothaus LC, et al: Tubal sterilization and risk of subsequent hospital admission for menstrual disorders. *Am J Obstet Gynecol* 166:1698, 1992
- Sieh W, Salvador S, McGuire V, et al: Tubal ligation and risk of ovarian cancer subtypes: a pooled analysis of case-control studies. *Int J Epidemiol* 42(2):579, 2013
- Society of Gynecologic Oncology: SGO clinical practice statement: salpingectomy for ovarian cancer prevention. November 2013. <https://www.sgo.org/clinical-practice/guidelines/sgo-clinical-practice-statement-salpingectomy-for-ovarian-cancer-prevention/>. Accessed December 6, 2014

- Soderstrom RM: Sterilization failures and their causes. *Am J Obstet Gynecol* 152:395, 1985
- Stuart GS: Contraception. In Hoffman BL, Schorge JO, Bradshaw KD, et al: *Williams Gynecology*, 3rd ed. New York, McGraw-Hill Education, 2016
- Stuart GS, Lesko CR, Stuebe AM, et al: A randomized trial of levonorgestrel intrauterine system insertion 6 to 48h compared to 6 weeks after vaginal delivery; lessons learned. *Contraception* 91(4):284, 2015
- Teva Women's Health: ParaGard T 380A intrauterine copper contraceptive: prescribing information. Sellersville, Teva Women's Health, 2013
- Thurman AR, Janeczek T: One-year follow-up of women with unfulfilled postpartum sterilization requests. *Obstet Gynecol* 116(5):1071, 2010
- Uchida H: Uchida tubal sterilization. *Am J Obstet Gynecol* 121(2):153, 1975
- Westhoff C, Davis A: Tubal sterilization: focus on the U.S. experience. *Fertil Steril* 73:913, 2000

akusher-lib.ru

INDEX

Note: Page numbers followed by *f* indicates figures; *t* indicates tables.

A

Abbreviated injury scale (AIS), 283

Abdominal incisions, 49

laparoscopic closure of, 255

obesity and, 57–58, 59*f*

retractors for, 18–19, 18*f*

transverse, 49–55

Cherney, 52–53, 53*f*

Maylard, 50*f*, 53–55, 53*f*, 54*f*, 55*f*

Pfannenstiel, 50–52, 50*f*, 51*f*, 52*f*, 53

supraumbilical, 50*f*, 55

vertical, 55–57

midline vertical, 55, 55*t*, 56*f*, 57, 57*f*, 58*t*

paramedian, 57

Abdominal pregnancy, 127–128

diagnosis of, 127

management of, 127–128

primary, 127

secondary, 127

Abdominal rescue in shoulder dystocia, 397

Abdominal trauma, 282, 286, 287

Abdominal ultrasound, 65, 66*f*

Abdominal wall, anterior, 27–30, 28*f*, 49

Abdominopelvic surgery, laparoscopy in, 244

Ablation

endometrial, 444

laser, 262–263

Abortions

anesthesia for, 137, 138*f*

antibiotic prophylaxis for, 302

catheter dilators for, 143

cervical ripening for, 141, 141*t*, 142*f*

curettes for, 137, 137*f*

complications of, 148–151

hemorrhage, 149

infection, 149–150

physiologic and pharmacologic

complications, 147*t*, 150–151

septic abortion, 150

surgical injury, 148–149

dilators for, 137, 137*f*

epidemiology of induced, 133–134

incomplete, 150

indications, 134

instruments for, 136–137, 137*f*

laminaria for, 141–142, 142*f*

legal services, 134–135

limitations to access, 135

provider numbers, 134–135

long-term risks, 151, 152*t*

medical, 144–148

first trimester, 144–145, 145*t*

second trimester, 145–148, 145*t*

mortality from, 134

osmotic dilators for, 141–143, 141*t*

oxytocin for, 147, 147*t*

partial birth, 135

prostaglandins for,

first trimester, 144, 145*t*

second trimester, 145–146, 145*t*

rates, 134

ratio, 134

second-trimester medical versus surgical, 147–148

septic, 150

spontaneous, 276, 281

surgical technique

first trimester, 136–140, 137–140*f*

second trimester, 140–141, 141*f*

third-trimester, 135

tubal, 118

Abscess

adnexal, 512–513

Bartholin gland duct, 192–194

marsupialization, 194, 194*f*

pathogenesis, 192–193, 192*f*

surgical drainage, 193–194, 193*f*

Word catheter, 193, 193*f*

breast, 504

diagnosis, 504, 504*f*

incisional

diagnosis, 508, 510*f*

treatment, 508–510

puerperal ovarian, 513

tubovarian, 199

vulvar, 189–192, 190*f*

hidradentis suppurativa, 191–192

incision and drainage, 189–190

necrotizing infection, 190–191, 191*f*

192*t*

Accidental poisoning, 281

Accrete syndrome. *See* Morbidly adherent placenta

Acidosis, fetal, 273

Active partial thromboplastin time (aPTT), 298

Acute Physiology and Chronic Health Evaluation (APACHE), 92

Acute respiratory distress syndrome, 95–96, 96*t*, 505

Addison disease, 302

Adhesions, 47

during bladder flap creation, 407, 408*f*

intraabdominal, 414

lysis, 416

prevention, 414

Adnexa. *See also* Adnexal masses

fallopian tubes, 43–44, 44*f*

ovaries, 38*f*, 39*f*, 43

Adnexal abscess, 512–513

Adnexal bleeding, as complication in peripartum hysterectomy, 431

Adnexal cyst, rupture of, 227

Adnexal masses, 224–238, 243

complications

cyst rupture or obstructed labor, 227, 227*f*

malignancy, 226–227

torsion, 225–226, 225*f*

diagnostic tools

computed tomography, 230

Doppler interrogation, 229

magnetic resonance imaging, 229–230

sonography, 227–229, 228*f*

tumor markers, 230

differential diagnosis, 224–225, 225*t*

incidence, 224

management, 230–238

asymptomatic masses, 230–232, 232*f*, 233*f*, 234, 234*f*, 235*f*, 236–237, 236*f*

emergent surgical treatment, 230

incidental finding during cesarean delivery, 238

Adnexal torsion, laparoscopy in diagnosing and treating, 242–243

Adnexectomy in evaluating adnexal masses versus cystectomy in, 232

laparoscopic, 237, 237*f*, 238*f*

via laparotomy, 232*f*, 236–237, 236*f*

Adrenal insufficiency, prophylaxis for, 302

Adson suction, 22

Advanced cardiac life support (ACLS), 283

Advisory Committee on Immunization Practices, 284

Age

ectopic pregnancy and, 113

maternal, placenta previa and, 438, 438*f*

as risk in ectopic pregnancy, 113

Air bags, 279

Airway management in managing cardiac arrest, 105

Alcock canal, 38

Alcohol consumption, trauma and, 278

Alexis retractors, 18, 19

Algorithms

for cardiac arrest management, 104*f*

for delivery of twin gestations, 361, 361*f*

for ectopic pregnancy evaluation, 115*f*

for morbidly adherent placenta, 449, 449*f*

for replacement of platelets, 469

- Algorithms (*Continued*)
 for trauma management, 283f
 for uterine inversion, 496f
- All-fours maneuver in shoulder dystocia, 396
- Allis-Adair clamps, 20
- Allis clamps, 20
 in cerclage, 173–174
 in laparoscopy, 249, 250f
 in puerperal sterilization, 528
- Alloimmune thrombocytopenia, 219
- Amenorrhea, 527
- American College of Obstetricians and Gynecologists
 on effects of radiographic imaging during pregnancy, 79, 79t
 guidelines for fetal monitoring, 303
 obstetric simulation and, 84
 Safe Motherhood Initiative of District II of, 98
 Simulations Consortium of, 83–84
- American Society of Anesthesiologists (ASA) Physical Status Classification System, 292, 293t
 Task Force on Obstetric Anesthesia, 310
- American Society of Regional Anesthesia and Pain Medicine, 298
- Amniocentesis, 203–212, 203t
 in advanced gestations, 211
 before cerclage, 179–180
 complications with, 210–211
 in multifetal gestations, 210–211, 211t
 early, 211
 evaluation for fetal genetic abnormalities, 203–204, 203t, 204t, 205t
 evaluation of fetal conditions, 205–206
 fetal complications after, 210
 genetic, 204, 206, 206f, 207f
 needle insertion, 206–207, 206f
 postprocedural activity, 207
 preprocedural steps, 206
 preventing complications, 207
 laboratory considerations, 208–210, 209f
 in multifetal gestations, 207–208, 208f
 in twins, 211
- Amnionic band syndrome, 271, 271f
- Amnionic fluid embolism, 97
- Amnionic fluid leakage, 210
- Amnionic septostomy, 261
- Amnionitis, 210
- Anal canal, 36–37
- Analgesia for the pregnant woman
 inhalational, 309
 intravenous, 309
 nitrous oxide, 309
- Anal incontinence, 330–331, 332
- Anal sphincter complex, 36f, 37–38, 37f
- Anaphylaxis, 295
- Ancillary port laparoscopic placement, 254, 254f
- Androgenesis, 158
- Anemia, 206
 acute blood loss, 98–99, 468–469, 469t
 dilutional, 307
 fetal, 206, 219, 220, 230
 iron-deficiency, 410
- Anesthesia for pregnant woman, 307–316
 aspiration prevention, 308, 311
 cardiovascular considerations, 307, 307t
 for cesarean delivery, 406
 general for emergent, 311–312
 neuraxial, 312, 313t
 postoperative care, 312–314, 314f
 complications
 aspiration, 311
 headache, 312
 neonatal depression, 309, 311–312
 epidural, 312–314, 313f
 for postpartum tubal ligation, 315–316
 general, 311
 inhalational, 308
 laparoscopy and, 244, 246
 paracervical, 137–138, 138f
 perioperative considerations in selection of, 292
 pudendal block, 309, 309f
 respiratory considerations, 308, 308t
 spinal, 312–315, 313f
- Aneuploidies, 445
- Angiographic embolization
 efficacy, 478
 technique, 478–479
- Angiography, 72
- Anogenital condyloma acuminata, 194–196
 medical treatment, 195
 pathogenesis, 194–195
 preventive steps, 195–196, 195f
 surgical treatment, 195
- Anogenital warts, 195
- Anomalous fetuses, 151, 260
 aneuploidy risk with, 204, 204t
 MR imaging for, use of, 78
 therapy for. *See* Fetal therapy
- Antepartum bleeding, 439, 441
 abdominal trauma and, 286
 ectopic pregnancy and, 114, 124
 in molar pregnancy, 158, 159, 162
 motor vehicle accident and, 279
 placenta accrete syndromes and, 445, 448
 placenta previa and, 437, 439–440
- Antepartum hysterectomy, 420
- Antepartum management in twin gestations, 352–353
- Antepartum simulation, 88–89, 89f. *See also* Intrapartum simulation
 cerclage in, 88
 obstetric sonography simulation in, 88–89, 89f
- Antepartum stillbirth, 278
- Anterior abdominal wall, 27–30, 28f, 49
 blood supply, 30
 incisions, 49–57, 50–57f
 infection, 508–510, 510f
 innervation, 30, 28f
 laparoscopic entry, 248–254, 249–254f
 muscles and fascia, 28, 28f
 rectus sheath, 28–29, 29f
 peritoneum, 29–30
 skin and subcutaneous layer, 27
 wound dehiscence, 510–511, 511f
- Anterior superior iliac spine, 254
- Antibiotics/antibiotic prophylaxis
 for abortions, 302
 for adrenal insufficiency, 302
 for cerclage efficacy, 180
 for cervical cerclage, 302
 for cesarean delivery, 302
 for electrosurgery, 303
 for Foley catheter, 303
 for group B streptococcal disease, 301–302
 for infective endocarditis, 298, 301
 obesity and, 296
 for pelvic infections, 507
 for perineal laceration, 302
 for postcesarean delivery, 505–506
 for postoperative infections, 432
 selection of agent, 295
 for suction abortions, 140
 surgical site infection prevention and, 294, 295–296
 at time of surgical abortion, 149
 for uterine infection, 507–508
 for uterine inversion, 500
- Anticoagulation therapy at time of delivery, 298
- Antimicrobial therapy for septic shock, 95
- Antimüllerian hormone, 525
- Antiphospholipid antibody syndrome (APS), 516, 517t
- Antisepsis, 4
- Aortic stenosis, 101
 critical, 270–271, 270f
- Apgar scores, 242, 311, 410
- Appendectomy, 414
 laparoscopy in, 255–256
- Appendicitis
 acute, 294
 diagnosis, 65, 74, 76, 66f, 74f, 76f–77f, 74t
 laparoscopy in diagnosing and treating, 242
- Arms
 delivery of, in vaginal breech delivery, 342–343, 342f, 343f, 356–357
 posterior extraction of, and shoulder dystocia, 395–396, 396f
- Arterial line in hemodynamic monitoring, 102
- Arteriography, vessel embolization by, 148
- Arthrography, 151
- Ascites, 228
- Aspiration pneumonitis, 505
- Aspiration prophylaxis, 311
- Assisted reproductive technology (ART), 225
 ectopic pregnancy and, 113
- Asynclitism in operative vaginal delivery, 370, 370f, 374, 377
- Atelectasis, 95, 257, 505
- Attempted vaginal breech delivery, 337

- Axis traction device in operative vaginal delivery, 363, 364*f*
 Aztreonam for uterine infection, 507
- B**
- Babcock clamp, 20
 in fallopian tube identification, 529
- Back bleeding, 425
- Bacterial mastitis, 504
- Bacterial vaginosis, 196–197, 197*t*
- Bakri balloon
 in abortion complications, 149
 cervical hematoma and, 487
 pelvic floor hemorrhage and, 480
 placenta previa and, 442
 postpartum hemorrhage and, 498
 uterine inversion and, 498
- Balfour retractors, 18*f*, 59
 in peripartum hysterectomy, 427
- Ballantine clamps, 21
 in peripartum hysterectomy, 426
- Balloon catheters
 Foley catheter, 143, 248, 303, 457
 for cervical ripening, 143
 for embolization, placement of, 315
 Word catheter, 193
- Balloon tamponade for postpartum hemorrhage, 473, 473*f*
- Barotrauma, risk for, 96
- Bartholin gland duct abscess, 192–194
 marsupialization, 194, 194*f*
 pathogenesis, 192–193, 192*f*
 surgical drainage, 193–194, 193*f*
 Word catheter, 193, 193*f*
- Bartholin glands, 32–33
- Barton forceps for operative vaginal delivery, 382–384, 382*f*, 383*f*, 384*f*
- Bayley Psychomotor Development Index, 268
- Bench simulators, 83, 83*t*
- Berlin criteria, 95
- Betamethasone, 106
- Beta-mimetic options in vaginal breech delivery, 347
- β-hCG
 ectopic pregnancy and, 114, 123
 for adnexal masses, 230
 molar pregnancy and, 160
 phantom, 166
- β-lactam antibiotics for uterine infection, 507
- β-lactamase inhibitors for uterine infection, 507
- Bicuspid aortic valve, 101
- Bioimpedance in hemodynamic monitoring, 103
- Biopsy
 cervical, 183–184
 cold-knife cone, 183, 184
 endometrial, 118
- Bioreactance in hemodynamic monitoring, 103
- Birth canal, injuries of. *See also* Hematomas and Perineal laceration
 cervical lacerations, 483–484, 483*f*, 484*f*
 levator sling injuries, 483
 vulvovaginal lacerations, 482–483, 483*f*
- Birthweight, shoulder dystocia and, 390, 390*t*
- Bladder
 dysfunction of, as short-term effect of operative vaginal delivery, 385
 Foley catheter in draining of, 248, 303, 457, 460
 injuries to, 149
 cystomy diagnosis, 456
 cystomy repair, 456–457
 incidence and risks, 456
 in peripartum hysterectomy, 424
 prevention, 457
 laparoscopy for lacerations in, 256
 repairing defects in wall, in peripartum hysterectomy, 429
- Bladder flap in cesarean delivery, 447–448, 447*f*
- Blades, scalpel and, 15–16, 15*f*
- Blake drain, 24, 24*f*
 in distal ureteral injuries, 459
 in peripartum hysterectomy, 432
- Bleeding. *See also* Hemorrhage
 adnexal, 431
 antepartum, 439, 441
 arterial, 482
 back, 425
 electro-surgery in minimizing, 51
 fetomaternal, 212, 215
 intermenstrual, 528
 intraabdominal, 243, 433
 intraperitoneal, 482
 irregular, 533
 placenta previa and, 439
 postoperative, in peripartum hysterectomy, 430*t*, 431–432
 retroperitoneal, 485
 vaginal, 210
- Blood product replacement, 98, 468, 469*t*
- B-lymph method
 in managing uterine inversion, 500
 in uterine compression sutures, 473–474, 474*f*
 weakness of, 474–475
- Boari flap, 460
- Bonney forceps, 17
- Bony pelvis, 45–47
 during breech delivery evaluation, 338
 during operative vaginal delivery evaluation, 371–372
 pelvic bones, 45, 45*f*
 pelvic shapes, 46, 46*f*
 planes and diameters of the pelvis, 45–46, 45*f*
 uterine incarceration, 47, 47*f*
- Bookwalter retractors, 18, 18*f*, 59, 427
- Bowel injuries, 416
 colon, 461
 laparoscopy in, 256
 postoperative dietary management, 461–462
 prevention, 462
 small-bowel, 461, 462*f*
 trauma and, 285
- Bow grip, 15
- Bracht technique in vaginal breech delivery, 345
- BRCA1 mutation, 525, 526
- BRCA2 mutation, 525, 526
- Breast abscess, 504, 504*f*
- Breast engorgement, 503
- Breastfeeding, 504
- Breech presentation, 406. *See also* Vaginal breech delivery
 Frank, 339–340
- Breisky-Navratil retractors, 20, 20*f*
- Broad ligaments, 40
 hematoma, 486, 486*f*
 opening in peripartum hysterectomy, 424–426, 425*f*
- Bronchospasm, 295
- Bulbocavernosus muscle, *See* Bulbospongiosus muscle
- Bulbospongiosus muscle, 32–33
- Bupivacaine, 312
- Burns, 280–281
 management of, 285–286
 thermal, 286
- Burns-Marshall method in vaginal breech delivery, 345
- C**
- California Maternal Quality Care Collaborative (CMQCC), 168, 467
- Camper fascia, 27, 31
- Canadian Early and Mid-Trimster Amniocentesis Trial (CEMATI), 211
- Canal of Nuck, 31
- Cancer
 cervical, 183–184, 184*f*, 419, 421, 421*t*
 gestational trophoblastic neoplasia, 161–166
 ovarian, 227, 525
- Cancer antigen 125
 for adnexal masses, 230
- Candidiasis, vulvovaginal, 199
- Capillarity, 4
- Caput succedaneum
 in operative vaginal delivery, 386*f*
 in vacuum extraction, 377
- Carbon dioxide laser, 194
- Carbon monoxide hypoxemia, 439
- Carbon monoxide poisoning, 286
- Carboprost tromethamine (Hemabate), 146, 470
- Cardiac arrest, 103–106
 American Heart Association algorithm for, 104*f*
 in cesarean delivery, 416
 epidemiology and causes, 103, 104*t*
 institutional preparation, 106
 management of, 103–106, 104*f*
 perimortem cesarean delivery, 106

- Cardiac disease, 99–101
 epidemiology in, 99, 100*t*
 management of specific, 100–101, 101*t*
 aortic stenosis, 101
 Eisenmenger syndrome, 100
 hypertensive emergencies, 101, 101*t*, 102*t*
 mitral stenosis, 100–101
- Cardiac Disease in Pregnancy (CARPREG), 99
- Cardiac output, trauma and, 276–277
- Cardinal ligaments, 40, 427–428, 427*f*
- Cardiogenic pulmonary edema, 101
- Cardiopulmonary effects from laparoscopy, 240–241, 241*t*
- Cardiopulmonary effects of pregnancy, 240–241, 307–308, 307*t*, 308*t*
- Cardiopulmonary resuscitation, 288
- Catgut suture, 6, 7, 324–325, 414
- Catheter dilators, 143
- Catheters
 Foley
 antibiotic prophylaxis for, 303
 draining of bladder with, 303, 457, 460
 for cervical ripening, 143
 in intraoperative care, 303
 in peripartum hysterectomy, 432
 Malecot, 24
 in peripartum hysterectomy, 432
 preoperative arterial or ureteral, 447
 pipelle, endometrial biopsy with, 118
 placement of balloon, 315
 Word, 193
- Cellulitis
 cuff, 432
 parametrial, 506
 pelvic, 507
 periincisional, 508
- Central venous catheter in hemodynamic monitoring, 102
- Cephalic replacement in shoulder dystocia, 397
- Cephalohematoma in operative vaginal delivery, 386, 386*f*
- Cerclage
 amniocentesis before, 179–180
 antepartum simulation and, 77, 88
 antibiotic prophylaxis for cervical, 302
 efficacy
 amniocentesis before cerclage, 179–180
 cerclage complications, 180–181
 cerclage removal after membrane rupture, 181
 cerclage removal and labor, 181
 cervical occlusion, 180
 indomethacin or antibiotics, 180
 rescue or emergency, 179
 stitch placement, 180
 transabdominal cervicoisthmic, 179
 transvaginal, 177–179, 178*t*, 179*t*
 techniques, 172–176
 contraindications, 172
 emergency/rescue cerclage, 176, 176*f*, 179
 McDonald, 174, 175*f*
 Shirodkar, 172–174, 173*f*, 181
 transabdominal cervicoisthmic, 174–176, 175*f*, 176*f*, 242–243
- Cervical biopsy, 183–184
 diagnostic excisional procedures, 183–184
- Cervical cerclage, antibiotic prophylaxis for, 302
- Cervical dilation, 136
- Cervical incompetence, 170, 172
- Cervical insufficiency, 170–172
 congenital etiologies, 170–171
 surgically induced defects, 171–172
- Cervical intraepithelial neoplasia, 19
 as indication of peripartum hysterectomy, 422
- Cervical lacerations, 483–484, 483*f*, 484*f*
- Cervical occlusion, 180
- Cervical polypectomy, 184, 185*f*
- Cervical pregnancy, 126–127, 126*f*
- Cervical ripening, 151
 catheter dilators, 143
 laminaria, 141, 142*f*
 pharmacologic, 143–144
 preabortion, 141–144, 141*t*
- Cervix, 39–40, 39*f*
 annular or circular detachment of, 484
 removal of, in peripartum hysterectomy, 427–428, 427*f*, 428*f*
- Cesarean delivery, 403–416, 503
 anesthesia for, 311–314, 313*f*, 314*f*, 406
 general for emergent, 311–312
 neuraxial, 312, 313*t*
 postoperative care, 312–314
 antibiotic prophylaxis for, 302
 associated mortality rates, 454
 cardiac arrest and perimortem, 416
 classical incision, 415, 416*f*
 complications in, 415–416
 efforts to decrease rates, 405–406, 405*t*
 evidence-based techniques, 407*t*
 frequency, 454
 history, 403–404
 hysterectomy and, 447–448, 447*f*, 448
 incidental finding of adnexal masses during, 238
 Intrapartum simulation in, 87, 87*f*
 Joel-Cohel technique, 415
 logistics of perimortem, 106
 low transverse
 fetus delivery, 410, 411*f*, 412*f*
 hysterotomy, 407–409, 408*f*
 impacted fetal head, 413, 413*f*
 placenta delivery, 413–414, 413*f*
 umbilical cord clamping, 410, 413
 uterine incision extension, 409, 409*f*
 wound closure, 414, 414*f*
 maternal death in, 416
 Misgave-Ladach technique, 415
 morbidly adherent placenta and, 422
 motor vehicle crash and, 279–280
 obesity and, 406
 perimortem, 88, 106, 287–288
 Pfannenstiel incision and, 50
 Pfannenstiel-Kerr technique, 415
 prior, and placenta previa, 438–439
 prior to the 19th century, 419
 rates, 404, 404*f*, 421–422
 comparative data, 404–405
 influencing factors, 404
 nonmedical factors, 405
 red blood cell salvage during, 315
 regional anesthesia for, 30
 staples for skin closure following, 13
 sterilization at the time of, 530–531
 subsequent pregnancies following, 406
 third-stage labor during, 494
 in twin gestations, 354
 urinary tract injury during, 454
 uterine incision, 406–407, 407*f*
 uterine infections following, 422, 422*f*, 505–508, 506*t*, 507*f*
 uterine inversion during, 493
 uterine rupture after prior, 416
 vaginal birth after, 406, 454
 vaginal breech delivery and, 336*t*, 337*t*, 348
- Cesarean hysterectomy, 314–315
 classification of, 420–421, 421*t*
 complications of, 430–433, 431*t*
 elective, 423
 for cesarean scar pregnancy, 128–129
 incidence of, 421
 indications for, 421, 422*t*
 instruments for, 21, 21*f*, 423
 risks for, 421, 421*t*
 supracervical, 429
 technique for, 424–429, 424–429*f*
- Cesarean scar pregnancy, 128–129, 129*f*, 445
- Chadwick sign, 40
- Chamberlen forceps in operative vaginal delivery, 363, 364*f*
- Chemotherapy
 for high-risk gestational trophoblastic neoplasia, 165–166
 for low-risk gestational trophoblastic neoplasia, 165
 prophylactic, 160
- Cherney incision, 52–53, 53*f*, 55
- Chest compressions in managing cardiac arrest, 105
- Chest radiography, 70*t*, 17, 96, 96*t*, 160, 519–520
- Chest trauma, 286
- Chignon, 365, 377
- Chimeras, 220
- Chlamydial infection, 113, 189, 192, 198
- Chloroprocaine, 138
- Cholecystectomy, laparoscopic, 242, 256
- Cholecystitis
 imaging for, 65, 67*f*
 laparoscopy in diagnosing and treating, 242
- Chorioamnionitis, 61, 92, 180, 414

- Chorioangioma, 271–272
- Choriocarcinoma, gestational, 161–162, 162*f*
- Chorionicity in twin gestations, 351–352, 351*f*, 352*f*
- Chorionic villus sampling, 212–217
 comparison of transcervical and transabdominal, 212
 complications, 214–216, 214*t*
 cytogenetic result accuracy, 216–217
 fetal abnormality after, 215–216
 in multifetal gestations, 213
 postprocedure recommendations, 214
 procedure-related anatomy, 212, 213*f*
 timing, 212
 transabdominal technique, 213, 214*f*
 transcervical technique, 212–213, 213*f*
- Chromic catgut suture, 7
- Chromosomal microarray, 204, 208, 209*f*
- Chromosomal mosaicism, 208–209
- Cilastin for uterine infection, 507
- Classical cesarean incision, 415, 416*f*, 448
- Clavicular fracture in shoulder dystocia, 396
- Clean contaminated wound, 60, 60*t*, 294
- Clean wound, 60, 60*t*, 294
- Cleidotomy, 396
- Clindamycin for uterine infection, 507
- Clitoris, 32, 32*f*
- Closed fetal therapy, 260–267
 for congenital cystic adenomatoid malformation, 265–266
 for congenital diaphragmatic hernia, 266–267, 267*f*
 for lower urinary tract obstruction, 263–264, 263*t*, 264*f*
 for twin-twin transfusion syndrome, 261–263, 262*f*
 laser ablation technique, 262–263
 thoracoamniotic shunting, 264–266
- Coagulation defects, placenta previa and, 439–440
- Coccyx, 45
- Coefficient of friction, 6
- Coexistent fetus, 161, 161*f*
- Coexisting electrical devices, 24
- Cold-knife cone biopsy, 183, 184
- Collaborative Review of Sterilization (CREST), 525, 526
- Colles fascia, 27, 31, 34–35
- Colon injuries, 461
- Colporrhexis, 484
- Colposcopy, 182–183
- Complete blood count, 286, 291, 495
- Complete hydatidiform mole, 157–158, 157*f*, 158*f*
- Complete tamponade in uterine inversion, 498
- Compression sutures, complication rates with, 475
- Compression ultrasonography in deep-vein thrombosis, 517, 518*f*
- Computed tomography (CT), 72–74, 73*t*
 abdominal, 284, 432
 for appendicitis, 73, 73*t*
 for adnexal masses, 230
 for breech pelvimetry, 338
 contrast, 74
 cranial, 74
 in diagnosing hematomas, 485, 486*f*, 487
 for pulmonary embolism, 73, 73*t*, 520, 520*f*
 for renal stone, 73, 73*t*
 for septic thrombophlebitis, 514, 515*f*
 for supraleator hematoma, 487, 487*f*
 for trauma, 283*f*, 284, 285*f*
 for uterine incisional necrosis, 514, 514*f*
 for vulvovaginal hematoma, 486, 486*f*
 for wound hematoma, 512, 513*f*
 multidetector, 72–73, 73*t*
- Computer-based simulation, 83, 83*t*
- Condylomata acuminata, 194, 195, 195*f*
- Confined placental mosaicism, 216–217
- Congenital anomalies, 250
- Congenital cystic adenomatoid malformation, 265–266
- Congenital diaphragmatic hernia, 266–267, 267*f*
- Congenital high-airway obstruction syndrome (CHAOS), 273
- Conization, 171–172
- Consent
 informed, 294
 laparoscopy and, 247
- Consultation. *See also* Counseling
 intrapartum, 338
 preoperative, 292–294, 293*t*, 294*f*
- Contaminated wound, 60, 60*t*, 294–295
- Continuous fetal monitoring, 101
- Continuous positive airway pressure (CPAP), 96
- Contraceptives. *See also* Sterilization
 copper IUDs in, 113, 531
 gestational trophoblastic disease and, 157
 immediate postpartum placement of, 531–533, 532*f*
 postpartum placement of subdermal, 533, 533*f*
 role in ectopic pregnancy, 113
- Contracoup effect, 279
- Contrast agents
 in magnetic resonance imaging, 76
 radiographic, 74
- Controlled-release needle, 2
- Copper IUDs, 113, 531
- Cordocentesis, 217
- Cord prolapse, 87, 405
- Cornuectomy, technique for, 124*f*
- Corpus luteum cysts, 117, 224–225
- Cosmesis, 49
- Cotton sutures, 8
- Counseling. *See also* Consultation
 abortion, 135
 genetic, 209
 invasive prenatal testing, 202, 203*t*
- Crêpe maneuver in uterine inversion, 494
- Critical care simulation, 88, 88*t*
- Critical illness in pregnancy, 91–107
 amniotic fluid embolism, 97
 cardiac arrest, 103–106
 epidemiology and causes, 103, 104*t*
 institutional preparation, 106
 management of, 103–106, 104*f*
 perimortem cesarean delivery, 106
 cardiac disease, 99–101
 epidemiology in, 99, 100*t*
 management of specific, 100–101, 101*t*
 fetal considerations with, 106–107
 decision for delivery, 107
 drugs and radiation, 106
 fetal monitoring, 107
 hemodynamic monitoring, 102–103
 arterial line, 102
 bioimpedance/bioreactance, 103
 central venous catheter, 102
 determining fluid responsiveness, 103
 echocardiography, 103
 indications for, 103
 pulmonary artery catheter, 102
 hemorrhage, 97–99
 blood replacement strategies, 98
 disseminated intravascular coagulopathy, 97–98
 massive transfusion protocol, 98
 1:1:1 blood product replacement, 98
 tranexamic acid, 99
 viscoelastic assays, 98, 99*f*
 management of, 93–95, 94*t*
 antimicrobial therapy, 95
 fluid resuscitation, 94–95
 vasopressors, 95
 maternal mortality, 91–92, 92*f*
 respiratory failure, 95–97
 acute respiratory distress syndrome, 95–96, 96*t*
 physiologic changes, 95
 treatment of, 96–97, 96*t*
 sepsis, 92–95
 defined, 93
 diagnosis of, 93, 94*t*
 epidemiology in, 92–93
- Cryoprecipitate, 98
- Cryotherapy, 195
- CT. *See* Computed tomography (CT)
- CT angiography, 74
- Cuff cellulitis, 432
- Curettage, 444. *See also* Dilatation and Curettage
 manual, 471
 surgical, 471
- Current density, 23
- Curved Mayo scissors, 16, 16*f*
- Curved needles, 2, 3–4, 3*f*, 4*f*
- Cystectomy, 226
 in evaluating adnexal masses, 238
 versus adnexectomy, 232
 laparoscopic, 232, 234, 234*f*, 235*f*, 236–237
 versus laparotomy, 232, 232*f*, 233*f*
- Cystoscopy, transurethral, 458

- Cystotomy, 52
 in diagnosis of bladder injuries, 456
 in repair of bladder injuries, 456–457
 risk of complications, 416
- Cysts
 adnexal, 227
 corpus luteum, 224–225
 dermoid, 225
 ovarian, 528
 paraovarian, 225
 paratubal, 225
 recurrent, 33
 rupture of, 227, 227f
 symptomatic, 33
 theca-lutein, 148, 225, 228, 229f
- D**
- Dactinomycin in treating gestational trophoblastic neoplasia, 165
- Deaver retractors, 18–19, 59
 in peripartum hysterectomy, 423
- DeBaKey forceps, 18
- Decidua, 40
- Deep-vein thrombosis, 297, 517–519, 518f
- Defibrillation in managing cardiac arrest, 105–106
- Dehiscence, 49, 57. *See also* Wound dehiscence
- Delayed ligation, 424
 in peripartum hysterectomy, 429–430
- Delirium, emergence, 309
- Delivery
 anticoagulation therapy at time of, 298
 decision for in critically ill gravida, 107
 female genital mutilation at, 182, 182f
 forceps in, 323
See also specific
 insulin management during, 304t
 placenta, 413–414, 413f
 preterm, 276, 279, 280, 316
 subsequent, after obstetric anal sphincter lacerations, 332
 vacuum-assisted, 309–310, 309f
 vaginal. *See* Vaginal delivery
 vaginal breech. *See* Vaginal breech delivery
 vaginal twin. *See* Twin gestation of very preterm twins, 360–361
- DEMETER trial, 118
- Denis Browne retractors, 18
- Denniston dilators, 137
- Depression
 intimate-partner violence and, 281
 newborn, 311
 peripartum, 281
 respiratory, 313
- Dermoid cysts. *See* Mature cystic teratoma
- Desflurane, 312
- Deterministic effects, 69t
- Dewey forceps in operative vaginal delivery, 367f, 368f
- Dexamethasone, 314
- Dexon S sutures, 7
- Diabetes mellitus, 291. *See also* Gestational diabetes
 perioperative management of, 304, 304t
 shoulder dystocia and, 391–392
 wound infection and, 509t
- Diagnostic imaging during pregnancy, 79, 79t
- Diagnostic peritoneal lavage, 284–285, 285f
- Diagonal conjugate, 371
- Diaphragmatic hernia, 264
- Dichorionic twins, 351, 351f, 352
 algorithm for delivery of, 361, 361f
- Diet
 in gestational diabetes, 304
 insulin management and, 304t
 post bowel surgery, 461–462
- Diethylstilbestrol exposure in utero, 171
- Dilapan-S, 141–143
- Dilation and curettage (D & C), 134
 first-trimester, 134, 136–140, 136f, 137f, 138f, 139f, 140f, 144, 149, 150
- Dilation and evacuation (D & E)
 intact, 135
 second-trimester, 134, 135, 140, 141f, 150, 151
- Dilute oxytocin, 312
- Dilutional anemia, 307
- Direct cervical spine trauma, 283–284
- Direct inguinal hernias, 28f, 30
- Dirty wound, 60, 60t, 295
- Discordance as risk in twin gestations, 350
- Disseminated intravascular coagulopathy (DIC), 97–98, 468
- Distal ureteral injuries, 458–460, 459f
- DNA analysis, 219
- Donor twin, 261
 in twin-twin transfusion syndrome, 261–263, 262f
- Doppler interrogation for adnexal masses, 229
- Dosimetry, 72
- Double gloving, 3
- Double-ligation of a vascular pedicle, 13f
- Down syndrome, risk assessment for, 203, 204
- Drugs
 in managing cardiac arrest, 105–106
 trauma and use of, 278
- Dührssens incisions, 181–182, 181f, 185
- Dystocia, 405
- E**
- Early amniocentesis, 211
- EASI (extra-amnionic saline infusion), 143
- Ecchymosis, 512
- Echocardiography
 fetal, 261
 in hemodynamic monitoring, 103
 transesophageal, 103
 transthoracic, 103
- Eclamptic seizure, 88
- ECMO (extracorporeal membrane oxygenation), 96, 266
- Ectocervix, 39
- Ectopic molar pregnancy, 160–161
- Ectopic pregnancy, 112–129
 abdominal pregnancy, 127–128
 diagnosis of, 127
 management of, 127–128
 algorithm of evaluation, 115f
 anatomy and, 113–114
 bilateral simultaneous, 114
 cervical pregnancy, 126–127, 126f
 cesarean scar, 128–129, 129f, 136
 diagnosis of, 114–118
 endometrial sampling in, 117–118
 laboratory findings in, 114, 115f, 116
 physical findings in, 114
 sonography in, 116–117, 116f, 117f
 symptoms in, 114
 epidemiology and incidence, 112
 etiology and risk, 113, 113t
 expectant management for, 123
 heterotopic pregnancy, 128
 interstitial pregnancy, 123–124, 124f, 125f
 medical therapy for, 121–123
 medical versus surgical therapy, 123
 surveillance, 123
 systemic methotrexate, 121–123, 122t
 outcomes in, 118
 ovarian pregnancy, 126, 126f
 puerperal sterilization and, 527–528
 surgical therapy for, 118–121
 conservative versus radical surgery, 118
 laparotomy versus laparoscopy, 118
 salpingectomy, 118–120, 119f
 salpingostomy, 120–121, 120f
- Ehlers-Danlos syndrome, 489
- Eisenmenger syndrome, 95, 100
- Elasticity, 5
- Elective cesarean hysterectomy, 423
- Electric shock, 281
- Electrocoagulation, 183
- Electronic monitoring, placental abruption and, 284
- Electrosurgery, 22–24, 303
 antibiotic prophylaxis for, 303
 bipolar, 22f, 24
 coexisting electrical devices, 24
 in minimizing bleeding, 51
 monopolar, 22–24, 22f, 23f, 303
- Elevated serum maternal alpha-fetoprotein levels
 placenta previa and, 439
- Elliot forceps in operative vaginal delivery, 367f
- Embolism
 amniotic fluid, 97
 gas, 257
 pulmonary, 505, 519–521
 diagnosing, 73, 73t, 520–521, 520f
 treating, 521
- Embolization
 angiographic
 efficacy, 478
 technique, 478–479
 in managing hematomas, 487

- Emergence delirium, 309
 Emergency rescue cerclage, 176, 176*f*, 176*t*, 179
 Encephalopathy, hypoxic-ischemic, 399, 416
 Endometrial ablation, 444
 Endometrial biopsy, 118
 Endometrial sampling in diagnosing ectopic pregnancy, 117–118
 Endometriomas, 225
 in adnexal mass diagnosis, 225*t*
 sonographic evaluation of, 228, 229*f*
 surgery for, 230–235
 Endometriosis, 47
 Endometritis, 92, 149
 Endometrium, 40
 Endloop Ligature (Ethicon), 184
 Endoscopy, 72
 End-to-end external anal sphincter repair, 329, 329*f*
 Epidural analgesia in vaginal breech delivery, 340
 Episiotomy
 current epidemiology, 322, 322*t*
 current recommendations, 322
 defined, 320–321
 forceps and, 375
 historic evolution, 320–322
 lateral, 323, 324
 maternal and fetal indications, 322
 mediolateral, 323, 324, 326*f*
 midline, 323, 324, 327*f*
 shoulder dystocia and, 395
 surgical repair of, 324–325
 type of, 323
 Epithelioid trophoblastic tumor, 162
 Erb-Duchenne-Klumpke palsy, 399
 Erb palsy, 386, 399
 Erythroblastosis fetalis, 260
 Esophageal sphincter tone, trauma and, 277
 Essure Permanent Birth Control system, 525
 Ethibond, 9
 Eversion, 40
 EXIT (ex-utero intrapartum treatment) in fetal therapy, 89, 268, 270
 Expectant management in ectopic pregnancy, 123
 External anal sphincter (EAS), 328–329
 anatomy of, 37, 31*f*–33*f*, 35*f*–37*f*
 end-to-end repair of, 329, 329*f*
 overlapping repair, 329–330, 330*f*
 External cephalic version in vaginal breech delivery, 347–348, 348*f*
 Extra-amnionic saline infusion (EASI), 143
 Extracorporeal membrane oxygenation (ECMO), 96, 266
 Extrauterine pregnancy. *See* Ectopic pregnancy
 Extrauterine yolk sac, 121
 Ex-utero intrapartum treatment (EXIT) in fetal therapy, 89, 268, 270, 272–273, 273*f*, 316
- F**
 Facial palsy in operative vaginal delivery, 386
 Factor V Leiden mutation, 516
 Fallopian tubes, 43–44, 44*f*, 113–114
 ectopic pregnancies and, 114
 identification of, in puerperal sterilization, 529
 implantation of embryos in, 113
 interruption of, in puerperal sterilization, 529–530
 Irving procedure and, 530
 Parkland method and, 529, 529*f*
 Pomeroy method and, 529–530, 530*f*
 risk-reducing salpingectomy, 525
 salpingectomy, 118–120, 119*f*, 124, 124*f*, 530–531, 531*f*
 salpingotomy, 120–121, 120*f*
 torsion of, 242–243
 Uchida procedure and, 530
 Fallopian tube stripping forceps, 121
 Falls, 280
 Familial hydatidiform moles, 157
 Febrile morbidity, 432
 Fecal peritonitis, 461
 Female genital mutilation at labor and delivery, 182, 182*f*
 Femoral artery, 30
 Femoral triangle, 28*f*, 30
 Ferris-Smith forceps, 17
 Fetal acidosis, 273
 Fetal anemia, 206, 219, 220, 230
 Fetal aneuploidy, 202
 Fetal anomalies, 172, 260
 screening in identifying, 244
 Fetal assessment, 292
 Fetal blood sampling, 217–220
 indications, 219–220
 preparation for, 218
 success rates and safety, 219
 technique, 218–219, 218*f*
 Fetal considerations with maternal critical illness, 106–107
 Fetal echocardiography, 261
 Fetal endoscopic tracheal occlusion (FETO), 266–267, 267*f*
 Fetal genetic abnormalities, evaluation of, 203–204, 203*t*, 204*t*, 205*t*
 Fetal growth restriction, 272
 association with placenta previa, 442
 Fetal head
 entrapment of, 310
 fracture, 69*f*
 impacted, 413, 413*f*
 molding of, in operative vaginal delivery, 371
 position, 370
 station, 371, 371*f*
 sutures, 370
 Fetal hemolytic disease, 206
 Fetal hypoxia, 280, 308
 Fetal indications, magnetic resonance imaging in, 78–79, 79*f*
- Fetal karyotyping, 161, 263
 Fetal lung maturity, 205
 Fetal macrosomia, shoulder dystocia and, 391, 391*f*
 Fetal-maternal hemorrhage, detection of, 287, 303
 Fetal monitoring, 107
 electronic, 338
 laparoscopy and, 246
 in trauma, 287
 Fetal oxygenation, 308
 Fetal physiologic risks, laparoscopy and, 246
 Fetal pleural effusion, 264–265
 Fetal presentation, 292
 Fetal surgery
 anesthesia and, 316
 history of, 260
 laparoscopy in, 242–243
 Fetal teratogenic risks, laparoscopy and, 246
 Fetal therapy, 260–273
 closed, 260–267
 congenital cystic adenomatoid malformation, 265–266
 congenital diaphragmatic hernia, 266–267, 267*f*
 laser ablation technique, 262–263
 lower urinary tract obstruction, 263–264, 263*t*, 264*f*
 thoracoamniotic shunting, 264–266
 twin-twin transfusion syndrome, 261–263, 262*f*
 ex-utero intrapartum treatment, 272–273, 273*f*
 future of, 273
 open, 268–270, 296*t*
 lung lesion resection, 269–270
 open spina bifida, 268–269, 269*f*
 potential beneficial interventions
 amnionic band syndrome, 271, 271*f*
 aortic stenosis, 270–271, 270*f*
 chorioangioma, 271–272
 sacrococcygeal teratoma, 272
 vasa previa, 271
 Fetal thrombocytopenia, 219–220
 Fetofetal transfusion syndrome (FFTS), 263
 Fetomaternal bleeding, 212, 215
 Fetoscopic release of amniotic bands, 271
 Fetoscopy, 243
 First-stage labor
 in twin gestations, 353
 in vaginal breech delivery, 338
 First trimester, 141
 accrete syndromes in, 445
 dilation and curettage, 134, 136–140, 136*f*, 137*f*, 138*f*, 139*f*, 140*f*, 144, 149, 150
 medical abortion, 144–145, 145*t*
 screening to identify fetal anomalies, 244
 vacuum aspiration, 136
 Fistulas, rectovaginal, 331
 Fluid absorption, 4
 Fluid responsiveness, determining, 103
 Fluid resuscitation in sepsis, 94–95

- Fluorescence in situ hybridization, 209–210
- Fluoroscopy, 72
- Flying fetus, 336
- Focused Assessment with Sonography for Trauma (FAST), 67, 286, 432
- Foley balloon
for cervical ripening, 143
postprocedural hemorrhage and, 127
tamponade, 442
- Foley catheter
antibiotic prophylaxis for, 303
in draining of bladder, 303, 457, 460
intraoperative care, 303
urinary retention and, 455
- Forceps
Barton, for operative vaginal delivery, 382–384, 382*f*, 383*f*, 384*f*
Bonney, 17
DeBakey, 18
in delivery, 323
Dewey, in operative vaginal delivery, 367*f*, 368*f*
Elliot, in operative vaginal delivery, 367*f*
Fallopian tube stripping, 121
Ferris-Smith, 17
Hawks-Dennen, in operative vaginal delivery, 367*f*
- Kielland
in occiput posterior positions, 381–382
in operative vaginal delivery, 368*f*, 378–382, 379*f*, 380*f*, 381*f*, 387, 387*t*
- Laufe, in operative vaginal delivery, 364*f*, 365, 368*f*
- Laufe-Piper
in operative vaginal delivery, 364*f*, 382
in vaginal breech delivery, 345, 348
- Luikart, in operative vaginal delivery, 365, 367*f*, 368*f*, 373–376, 373*f*, 374*f*, 375*f*, 376*f*
- Luikart-Kielland, in operative vaginal delivery, 378, 381
- Luikart-Tucker-McLane, in operative vaginal delivery, 367*f*
- Lulkart-Simpson, in operative vaginal delivery, 367*f*
in operative vaginal delivery, 323, 363*f*, 364*f*, 365–368, 366*t*, 367*f*, 368*f*, 369*t*
- Pennington, 413, 414
- Piper
in operative vaginal delivery, 364*f*, 365, 367*f*
training in use of, 361
in vaginal breech delivery, 310, 345, 345*f*, 346*f*
in vertex/vertex presentation delivery, 256
- Potts-Smith single-toothed, 17
- Ring, 20
in placenta delivery, 414
- Russian, 18
- Simpson, in operative vaginal delivery, 368*f*
- Singley, 18
- sponge, 20
- tissue, 17–18, 17*f*
- Tucker-McLane, in operative vaginal delivery, 363*f*, 367*f*, 368*f*, 381
in vacuum-assisted delivery, 309–310, 309*f*
vacuum-assisted delivery and, 309–310, 309*f*
- Fractures
clavicular, 396
pelvic, 285
in shoulder dystocia, 396, 398*t*, 399
- Frazier suction tip, 22
- Functional residual capacity (FRCs), 308
- Fundal massage, 413
- Fundal pressure in shoulder dystocia, 397
- Funipuncture, 217
- G**
- Gadolinium-based contrast agent (GBCA), 76
- Gadolinium chelates, 76
- Gas embolism, 257
- Gas insufflator, 247
- Gasless laparoscopy, 241
- Gastric emptying time, trauma and, 277
- Gastroesophageal reflux disease (GERD), 308
- Gastrointestinal injuries during cesarean delivery, 454–455, 455*t*
- Gelpi retractors, 20
- Gemeprost (Cervagem), 146
- Genetic amniocentesis, 204, 206
needle insertion, 206–207, 206*f*
postprocedural activity, 207
preprocedural steps, 206
preventing complications, 207
second-trimester, 212
- Genital tract lacerations, 482–491, 482*t*.
See also Episiotomy
cervical, 483–484, 483*f*, 484*f*
levator sling injuries, 483
vulvovaginal, 482–483, 483*f*
- Gentamicin in treating uterine infection, 507
- Gestational choriocarcinoma, 161–162, 162*f*
- Gestational diabetes. *See also* Diabetes mellitus
diet-controlled, 304
insulin-requiring, 304, 304*t*
- Gestational thrombocytopenia, 528
- Gestational trophoblastic disease, 156–167
defined, 156
ectopic, 160–161
epidemiology and risk factors, 156–157, 156*t*
gestational trophoblastic neoplasia, 161–167
assessment of, 163
diagnosis of, 163
histologic classification, 161–162, 162*f*
phantom β -hCG, 166
quiescent gestational trophoblastic disease, 166–167
staging, 163–165, 163*t*, 164*t*
subsequent pregnancy outcome, 166
treatment of, 165–166
hydatidiform mole (molar pregnancy), 157–161
coexistent fetus, 161, 161*f*
complete hydatidiform mole, 157–158, 157*f*, 158*f*
diagnosis of, 159, 159*f*
ectopic molar pregnancy, 160–161
partial hydatidiform mole, 157*f*, 158–159
postmolar surveillance, 160
prophylactic chemotherapy, 160
treatment of, 159–160
modified WHO classification of, 156*t*
Gestational trophoblastic neoplasia, 156, 161–167
assessment of, 163
diagnosis of, 163
histologic classification, 161–162, 162*f*
phantom β -hCG, 166
quiescent gestational trophoblastic disease, 166–167
staging, 163–165, 163*t*, 164*t*
subsequent pregnancy outcome, 166
treatment of, 165–166
- Glove perforation, 3
- Gonorrhoea, 113, 189, 192, 197–198
- Gonzales v. Carhart*, 135
- Goodell sign, 40
- Graves speculum, 20
- Greater vestibular glands, 32–33
- Group A β -hemolytic streptococcal infections, 505–506, 511
- Group B streptococcal disease, antibiotic prophylaxis for, 301
- Gunshot wound, 282, 284
- Gunther Tulip filter in treating pulmonary embolism, 521
- H**
- Hank dilators, 137, 137*f*, 138, 139
- Harmonic scalpels, 24
- Harrington retractors, 19
- Hart line, 31, 32
- Hasson open laparoscopic entry, 248–249, 249*f*, 250*f*, 251, 251*f*, 256, 528
- Hasson trocar, removal of, 255
- HASTE (Half-Fourier Acquisition Single Shot Turbo Spin Echo) sequences, 79
- Haultain technique in managing uterine inversion, 498, 499, 499*f*, 500
- Hawks-Dennen forceps in operative vaginal delivery, 367*f*
- Hayman sutures in uterine inversion, 500
- Head tilt chin lift, 105
- Heancy-Ballantine clamp, 21, 21*f*

- Heaney clamps in peripartum hysterectomy, 426, 427*f*, 428
- Heaney right-angle retractors, 20
- Heaney tissue clamp, 21, 21*f*
- Heartburn, 308
- Hegar sign, 40
- HELLP (hemolysis, elevated liver enzyme levels, low platelet count) syndrome, 528
- Hematomas
 incisional, 512, 513*f*
 paravaginal, 485, 487
 puerperal, 484–487, 485*f*
 retroperitoneal, 478, 487, 487*f*
 supravaginal, 487, 487*f*
 vulvovaginal, 485–487, 486*f*
- Hematometra, 149
- Hemodynamic monitoring, 102–103
 arterial line, 102
 bioimpedance/bioreactance, 103
 central venous catheter, 102
 determining fluid responsiveness, 103
 echocardiography in, 103
 indications for, 103
 pulmonary artery catheter, 102
- Hemoperitoneum, 77*f*, 78*f*, 117, 227, 227*f*
- Hemorrhage, 97–99. *See also* Bleeding
 in abortions, 149
 blood replacement strategies, 98, 468–469, 469*t*
 as complication in peripartum hysterectomy, 430–431
 disseminated intravascular coagulopathy, 97–98
 fetal-maternal, 287, 303
 intraabdominal, 77*f*, 78*f*, 117, 118, 227, 227*f*
 massive transfusion protocol, 98, 449*t*, 468–469, 469*t*
 maternal, 277
 pharmacologic therapy for, 315
 postpartum, 87, 310, 466–480, 482.
See also Postpartum hemorrhage
 profuse, 127
 as reason for obstetrical hysterectomy, 421
 retinal, 386
 retroperitoneal, 487
 subaponeurotic, 377
 subfascial, 512, 513*f*
 tranexamic acid, 99
 viscoelastic assays, 98, 99*f*
- Hemorrhoidal tags, 37
- Hemorrhoids
 external, 37
 internal, 37
- Hemostasis, 50
 postpartum, 456
- Hemostatic hysterotomy, 409
- Heparin
 low-molecular-weight
 in management of deep-vein thrombosis, 518–519, 519*t*
 in management of pulmonary embolism, 521
 perioperative indications for, 298
 unfractionated
 in management of deep-vein thrombosis, 518
 in management of pulmonary embolism, 521
 perioperative indications for, 298
- Heparin-induced thrombocytopenia, 519
- Hernias, 30
 diaphragmatic, 264
 congenital, 266–267, 267*f*
 direct inguinal, 30
 incisional, 257
 indirect, 30
- Hesselbach triangle, 30
- Hetastarch, 94
- Heterotopic pregnancy, 113, 128, 225
 laparoscopy in diagnosing and treating, 242–243
- Hidradentis suppurativa, 191–192
- Homans sign, 517
- Homicide, 282
- Hormone modulators, 143–144
- Human chorionic gonadotropin (hCG)
 ectopic pregnancy and, 114, 123
 for adnexal masses, 230
 gestational trophoblastic disease and, 160
 gestational trophoblastic neoplasia and, 163, 163*t*, 164*t*
 phantom, 166
 screening, 445
- Human immunodeficiency virus (HIV), 91
 testing for, 136
- Human papillomavirus (HPV) infection, 194–195
- Huntington technique, in uterine inversion, 498, 498*f*, 500
- Hydatidiform mole, 157–161
 coexistent fetus, 161, 161*f*
 complete hydatidiform mole, 157–158, 157*f*, 158*f*
 diagnosis of, 159, 159*f*
 ectopic molar pregnancy, 160–161
 partial hydatidiform mole, 157*f*, 158–159
 postmolar surveillance, 160
 prophylactic chemotherapy, 160
 treatment of, 159–160
- Hydramnios, 272
- Hydrolysis, 324
- Hydronephrosis, 73*f*, 458
- Hydroptic degeneration, 159
- Hydrosalpinx, 113, 225
- Hydrostatic pressure in uterine inversion, 497, 498*f*
- Hymen, 33–34, 33*f*
- Hypercapnia, 256–257
- Hypercapnic respiratory failure, 95
- Hyperemesis gravidarum, 148, 158
- Hyperosmolar urea, 147
- Hypertensive emergencies, 101, 101*t*, 102*t*
- Hyperventilation, maternal, 308
- Hypervolemia of pregnancy, 268, 468
- Hypoplastic left heart syndrome (HLHS), 270
- Hypotension, maternal, 308
- Hypovolemia, 455, 467, 486
- Hypovolemic shock and volume resuscitation
 patient resuscitation, 98, 468–469, 469*t*
 physiologic changes, 268
- Hypoxemia, 106
 carbon monoxide, 439
- Hypoxemic respiratory failure, 95
- Hypoxia, fetal, 280, 308
- Hysterectomy, 141, 162
 antepartum, 420
 cesarean delivery and, 314–315, 447–448, 447*f*, 448
 cesarean scar pregnancy and, 128–129, 129*f*
 in repairing uterine repair, 490
 in treating gestational trophoblastic neoplasia, 165
 obstetric, 419
 peripartum, 419–433, 442. *See also* Peripartum hysterectomy
 postpartum, 420, 421*t*
 radical, 419
 modified, 448–449, 449*f*
 subtotal, 429
 supracervical, 429
 uterine incisional necrosis and, 514, 514*f*
- Hysteroscopic sterilization, 525
- Hysteroscopy, 128
- Hysterotomy, 141
 for fetal surgery, 268, 269*f*, 273*f*
 for placenta accreta, 448
 incision closure, 3
 in classical cesarean delivery, 415, 415*f*
 in low transverse cesarean delivery, 407–409, 408*f*
- I**
- Iliac artery, internal ligation of, 476–478, 478*f*
- Ilium, 45
- Imaging. *See* Ionizing radiation; Magnetic resonance imaging (MRI); Sonography
- Imipenem for uterine infection, 507
- Immune thrombocytopenic purpura (ITP), 219
- Immunoglobulin E (IgE) mediated reaction, 295
- Impacted fetal head, in low transverse cesarean delivery, 413, 413*f*
- Impedance, 22
- Incisional hernias, 257
 laparoscopy and, 257
- Incisions
 abdominal, 49
 laparoscopic closure of, 255
 obesity and, 57–58, 59*f*
 retractors for, 18–19, 18*f*
 transverse, 49–55

- Incisions (*Continued*)
- Cherney, 52–53, 53*f*
 - Maylard, 50*f*, 53–55, 53*f*, 54*f*, 55*f*
 - Pfannenstiel, 50–52, 50*f*, 51*f*, 52*f*, 53
 - supraumbilical, 50*f*, 55
 - vertical, 55–57
 - midline vertical, 55, 55*t*, 56*f*, 57, 57*f*, 58*t*
 - paramedian, 57
 - classical cesarean, 415, 416*f*
 - Dührssens, 181–182, 181*f*, 185
 - J, 409
 - in laparoscopy, 19, 255
 - in laparotomy, 106, 292
 - Maylard-Bardenheuer, 53
 - in minilaparotomy, 19
 - Pfannenstiel, 27, 30, 50–52, 50*f*, 51*f*, 52*f*, 175, 457
 - T, 409
 - uterine, in cesarean delivery, 406–407, 407*f*, 409, 409*f*
 - vesicouterine peritoneal reflection, 407*t*, 408, 409*f*
 - vulvar abscess, 189–190
- Incomplete abortion, 150
- Indirect inguinal hernias, 30
- Indomethacin, 180
- Infections
- in abortions, 149–150
 - Bartholin gland duct, 192–194, 192*f*–194*f*
 - Candidiasis, 199
 - chlamydial, 113, 189, 192, 197*t*, 198
 - condyloma acuminata, 194–196, 195*f*
 - gonorrhea, 197–198, 197*t*
 - human papillomavirus, 194–196
 - necrotizing, 190–191, 191*f*, 192*t*, 511–512, 512*f*
 - pelvic inflammatory disease, 199
 - puerperal, 503–515
 - breast sources, 503–504, 504*f*
 - necrotizing fasciitis, 511–512, 512*f*
 - parametrial phlegmon, 513–514, 513*f*, 514*f*
 - peritonitis and adnexal abscesses, 512–513
 - pyelonephritis, 504–505, 505*t*
 - respiratory complications, 505
 - septic pelvic thrombophlebitis, 514–515
 - uterine infection following cesarean delivery, 505–508, 506*t*, 507*f*
 - wound dehiscence, 510–511, 511*f*
 - wound hematoma and seroma, 512, 513*f*
 - wound infections, 508–510, 509*t*, 510*f*
 - surgical site prevention, 294–297, 295*t*
 - trichomoniasis, 197*t*, 198–199
 - vulvar abscess, 189–190, 190*f*
 - wounds, 60, 60*t*, 291, 295
- Infective endocarditis, antibiotic prophylaxis for, 298, 301
- Informed consent, 294
- Infundibulum, 114
- Inhalational analgesia, 309
- Injuries
- to birth canal, 483–484, 483*f*, 484*f*
 - to bladder
 - cystomy diagnosis, 456
 - cystomy repair, 456–457
 - incidence and risks, 456
 - prevention, 457
 - gastrointestinal, during cesarean delivery, 454–455, 455*t*
 - levator sling, 483
 - needlestick, 3
 - obstetric and sphincter, 320, 325–332
 - complications of, 330–332
 - defined, 320
 - identification of, 325–327
 - prevention of, 330
 - subsequent deliveries after, 332
 - surgical repair of, 327–330
 - small-bowel, 461, 462*f*
 - ureteral
 - cystoscopy, 458
 - diagnosis, 457–458
 - distal, 458–460, 459*f*
 - incidence and risks, 457
 - midpelvic, 460, 460*f*
 - psoas hitch or boari flap, 460
 - ureteral stents, 458
 - ureteroneocystostomy, 459–460, 459*f*
 - urologic, 455–461
 - bladder
 - cystomy diagnosis, 456
 - cystomy repair, 456–457
 - incidence and risks, 456
 - prevention, 457
 - bowel
 - colon, 461
 - postoperative dietary management, 461–462
 - prevention, 462
 - small-bowel, 461, 462*f*
 - risk factors, 455*t*
 - ureteral
 - cystoscopy, 458
 - diagnosis, 457–458
 - distal ureteral injuries, 458–460, 459*f*
 - incidence and risks, 457
 - midpelvic, 460, 460*f*
 - psoas hitch or boari flap, 460
 - ureteral stents, 458
 - ureteroneocystostomy, 459–460, 459*f*
 - urethral, 455–456
 - vascular, from laparoscopy, 256
 - visceral, from laparoscopy, 256
- Injury severity score (ISS), 283
- Innominate bones, 45
- Insulin
- in gestational diabetes, 304, 304*t*
 - management during labor and delivery, 304*t*
- Intentional trauma
- intimate-partner violence, 281–282
 - penetrating trauma, 282
 - suicide and homicide, 282
- Intermenstrual bleeding, 528
- Intermittent mandatory ventilation (IMV), 96
- Internal anal sphincter (IAS), 37, 38, 328
- repair of, 328*f*
- Internal iliac artery ligation
- efficacy, 476–477
 - technique, 477–478
- Interrupted sutures, 2
- Interstitial pregnancy, 123–124, 124*f*, 125*f*
- Intimate-partner violence, 281–282
- Intraabdominal adhesions, 414
- Intraabdominal bleeding, 118, 243. *See also* Hemoperitoneum
- in peripartum hysterectomy, 433
- Intraoperative care
- electrosurgery, 303
 - Foley catheter in, 303
 - laparoscopic surgery in pregnancy and, 245*t*, 251
 - maternal positioning, 302
 - pregnancy monitoring, 303
 - surgical time out, 302
- Intrapartum consultation, 338
- Intrapartum simulation, 85–88, 85*t*, 87
- cesarean delivery, 87, 87*f*
 - operative vaginal delivery in, 85–86, 86*f*
 - perineal laceration repair, 87–88, 88*f*
 - postpartum hemorrhage, 87
 - shoulder dystocia, 85, 85*f*
 - vaginal breech delivery, 86–87, 86*f*
- Intraperitoneal bleeding, 482. *See also* Hemoperitoneum
- Intrathecal block, 310
- Intrauterine balloon tamponade, in uterine inversion, 497–498
- Intrauterine devices (IUD), 526, 531. *See also* Sterilization
- copper, 113, 531
 - immediate postpartum placement of, 531–533, 532*f*
 - insertion at cesarean delivery, 533
 - postpartum placement of, 531–533, 532*f*
 - progesterin-releasing, 532
- Intrauterine instillation of nonprostanoid agents
- in second-trimester abortion, 147
- Intrauterine pregnancy, 225
- Intravenous access in managing cardiac arrest, 105
- Intravenous analgesia, 309
- Intravenous fluids and pain control, 303
- Intravenous pyelography (IVP), 458
- Intrinsic genetic and biochemical deficiencies, 170–171
- Intubation, 96
- failed tracheal, 308
 - tools and technique for, 96

- Invasive prenatal diagnostic procedures, 202–220
 amniocentesis, 203–212, 203*t*
 in advanced gestations, 211
 complications with, 210–211
 early, 211
 evaluation for fetal genetic
 abnormalities, 203–204, 203*t*,
 204*t*, 205*t*
 evaluation of fetal conditions, 205–206
 genetic, 206–207, 206*f*, 207*f*
 laboratory considerations, 208–210, 209*f*
 in multifetal gestations, 207–208, 208*f*
 chorionic villus sampling, 212–217
 comparison of transcervical and
 transabdominal, 212
 complications, 214–216, 214*t*
 cytogenetic result accuracy, 216–217
 fetal abnormality after, 215–216
 in multifetal gestations, 213
 postprocedure recommendations, 214
 procedure-related anatomy, 212, 213*f*
 timing, 212
 transabdominal technique, 213, 214*f*
 transcervical technique, 212–213, 213*f*
 fetal blood sampling, 217–220
 indications, 219–220
 preparation for, 218
 success rates and safety, 219
 technique, 218–219, 218*f*
 other procedures, 230
 preprocedural steps
 invasive prenatal testing counseling,
 202, 203*t*
 time out, 202
- In vitro fertilization (IVF), 113, 226, 528
- Ionizing radiation, 68–74, 69*f*
 deterministic effects of, 70–71
 diagnostic radiation, 71–74
 stochastic effects of, 71
 therapeutic radiation, 71
 x-ray dosimetry, 70, 70*t*
- Iron-deficiency anemia, 410
- Irregular bleeding, 533
- Irving method in puerperal sterilization, 530
- Ischioanal fossa, 36
- Ischium, 45
- Isoflurane, 312
- J**
- Jackson-Pratt drain, 24, 24*f*
 in distal ureteral injuries, 459
 in peripartum hysterectomy, 432
- Jaw thrust, 105
- J incision, 409
- Joel-Cohen technique in cesarean delivery,
 415
- Joint Commission Universal Protocol for
 Preventing Wrong Site, Wrong
 Procedure, and Wrong Person
 Surgery, 302
- Jorgenson scissors, 16
 in peripartum hysterectomy, 428
- K**
- Karman suction cannulas, 22
 in first-trimester dilation and curettage, 137*f*
- Karyotyping, fetal, 161, 263
- Kelly clamps, 21, 21*f*, 237
 in low transverse cesarean delivery, 407
 in peripartum hysterectomy, 430
- Ketamine, 309
- Kielland forceps
 in occiput posterior positions, 381–382
 in operative vaginal delivery, 368*f*,
 378–382, 379*f*, 380*f*, 381*f*,
 387, 387*t*
- Kirschner retractors, 18
- Kittner dissector sponge in peripartum
 hysterectomy, 423–424
- Kleihauer-Betke (KS) acid elution, detection
 of fetal-maternal hemorrhage,
 287, 303
- Klumpke palsy, 399
- Knots, 9–12, 9*t*
 breakage of, 10, 11*t*, 12, 12*t*
 efficiency of, 10
 slippage, 9–10, 10*f*
 strength of, 5, 10, 11*t*, 12*t*
 terminology, 9, 9*t*
- Kocher clamps, 21, 21*f*
- L**
- Labia majora, 27, 31
- Labia minora, 31
- Labor. *See also* First-stage labor; Second-
 stage labor; Third-stage labor
 female genital mutilation at, 182, 182*f*
 induction of, 405
 insulin management during, 304*t*
 obstructed, 227, 227*f*
- Laboratory assessment
 in diagnosing ectopic pregnancy, 114,
 115*f*, 116
 in preoperative assessment, 291–294
 trauma and, 286–287
- Lactate dehydrogenase (LDH) for adnexal
 masses, 230
- Lahey thyroid clamps, 20
- Lambda sign, sonography in identifying, 351
- Laminaria tents, 141–142, 142*f*
- Laparoscope, 247
- Laparoscopic adnexectomy in evaluating
 adnexal masses, 237, 237*f*, 238*f*
- Laparoscopic cholecystectomy, 242
- Laparoscopic cystectomy in evaluating
 adnexal masses, 232, 234, 234*f*,
 235*f*, 236–237
- Laparoscopic suture-loop ligation, 119
- Laparoscopy, 240–257
 advantages, 242
 ancillary port placement, 254, 254*f*
 cardiopulmonary effects, 240–241, 241*t*
 complications, 256–257
 pneumoperitoneum-associated
 problems, 256–257
 positioning, 257
 vascular injuries, 256
 visceral injuries, 256
 wound, 257
- equipment
 gas insufflator, 247
 laparoscope, 247
 surgical instruments, 248
 trocars, 247
- gasless, 241, 246
- incisions in, 19, 255
- indications
 adnexal masses, 243
 adnexal torsion, 242–243
 appendicitis, 242
 cholecystitis, 242
 ectopic pregnancy, 118
 fetal surgery, 243, 263
 heterotopic pregnancy, 243
 transabdominal cervicoisthmic cerclage,
 243
- intraoperative steps
 bladder and stomach decompression,
 248
 Hasson open entry technique,
 248–249, 249*f*, 250*f*, 251, 251*f*
 left upper quadrant entry, 253
 patient positioning, 248
 subxiphoid entry, 253–254
 Veress needle entry, 251–253, 252*f*,
 253*f*
- laparoscopic trauma and, 241–242
- laparotomy versus in evaluating adnexal
 masses, 231–232
- patient preparation
 consenting, 247
 initial evaluation, 246–247
 thromboprophylaxis, 247
- postoperative management, 256
- restrictions
 fetal considerations, 244, 246
 general considerations, 243–244
 maternal comorbidities, 244
 neonatal considerations, 246
 surgery timing, 244, 245*t*
- risk of miscarriage and, 242
- specific procedures, 255–256
 appendectomy, 255–256
 cerclage placement, 175–176
 cholecystectomy, 256
 cystectomy, 232, 234, 234*f*–235*f*, 236,
 248
 fetal surgery, 263
 salpingostomy, 118–119
 sterilization, 525, 527 specimen
 removal, 254–255
- in sterilization, 525
- uterine manipulation, 254
- Laparotomy, 150
 in ectopic pregnancy, 118
 in evaluating adnexal masses
 versus cystectomy, 232, 232*f*, 233*f*
 versus laparoscopy, 231–232
 incisions in, 106, 292

- Laparotomy (*Continued*)
 in managing uterine inversion, 498, 500
 repeat, 55
 vertical incision in, 106
- Laser ablation, 262–263
- Laser photocoagulation, 261
- Lateral episiotomy, 323, 324
- Lateral umbilical ligaments, 30
- Laufe forceps in operative vaginal delivery, 364*f*, 365, 368*f*
- Laufe-Piper forceps
 in operative vaginal delivery, 364*f*, 382
 in vaginal breech delivery, 345, 348
- Left uterine displacement in managing cardiac arrest, 105, 105*f*
- Left ventricular end diastolic area (LVEDA), 103
- Legal abortions, 134–135
 limitations to access, 135
- Leiomyomas, 47
 sonographic evaluation of, 228, 229*f*
- Leucovorin rescue, 121
- Levator sling injuries, 483
- Levonorgestrel-releasing intrauterine system (LNG-IUS), 113, 531, 532
- Ligatures, 12–13, 13*f*
- Linear no-threshold (LNT) hypothesis, 71
- Linea terminalis, 45
- Long-acting reversible contraception (LARC), 526, 527, 528
- Loop electrosurgical excision procedure (LEEP), 171, 183–184
- Lovset maneuver
 in vaginal breech delivery, 343
 in vertex/breech presentation for twins, 357
- Lower genital tract. *See also* Hematomas; Perineal laceration
 anatomy
 cervix, 34, 39–40
 perineum, 35–38
 vagina, 33–34
 vulva, 30–33, 31*f*
 procedures in, 170–185
 cerclage efficacy
 amniocentesis before cerclage, 179–180
 cerclage complications, 180–181
 cerclage removal after membrane rupture, 181
 cerclage removal and labor, 181
 cervical occlusion, 180
 indomethacin or antibiotics, 180
 rescue or emergency, 179
 stitch placement, 180
 transabdominal cervicoisthmic, 179
 transvaginal, 177–179, 178*t*, 179*t*
 cerclage techniques, 172–176
 contraindications, 172
 emergency/rescue cerclage, 176, 176*f*
 McDonald cerclage, 174, 175*f*
 Shirodkar technique, 172–174, 173*f*, 181
 transabdominal cervicoisthmic cerclage, 174–176, 175*f*, 176*f*
 cervical biopsy, 182–184
 diagnostic excisional procedures, 183–184
 cervical insufficiency, 170–172
 congenital etiologies, 170–172
 surgically induced defects, 171–172
 cervical polypectomy, 184, 185*f*
 Dührssens incisions, 181–182, 181*f*
 female genital mutilation at labor and delivery, 182, 182*f*
 vaginal septum, 182, 183*f*
 treatment of infections in
 anogenital condyloma acuminata, 194–196
 medical treatment, 195
 pathogenesis, 194–195
 preventive steps, 195–196, 195*f*
 surgical treatment, 195
 bacterial vaginosis, 196–197, 197*t*
 Bartholin gland duct abscess, 192–194
 marsupialization, 194, 194*f*
 pathogenesis, 192–193, 192*f*
 surgical drainage, 193–194, 193*f*
 pelvic inflammatory disease, 199
 sexually transmitted diseases, 197–199
 chlamydial infection, 113, 149, 192, 198
 gonorrhea, 113, 189, 192, 197–198
 trichomoniasis, 189, 198–199
 vaginal flora, 196
 vulvar abscess, 189–192, 190*f*
 hidradentis suppurativa, 191–192
 necrotizing infection, 190–191, 191*f*, 192*t*
 vulvovaginal candidiasis, 199
- Lower urinary tract obstruction (LUTO), 263–264, 263*t*, 264*f*, 266
- Low-lying placenta, 437, 437*t*
 imaging and, 441
- Low-molecular-weight heparin (LMWH)
 in management of deep-vein thrombosis, 518–519, 519*t*
 in management of pulmonary embolism, 518–519
 perioperative indications for, 298
- Low transverse cesarean delivery
 fetus delivery, 410, 411*f*, 412*f*
 hysterotomy, 407–409, 408*f*
 impacted fetal head, 413, 413*f*
 infection following, 508–514, 514*f*
 placenta delivery, 413–414, 413*f*
 umbilical cord clamping, 410, 413
 uterine incision extension, 409, 409*f*
 wound closure, 414, 414*f*
- Luikart forceps in operative vaginal delivery, 365, 367*f*, 368*f*, 373–376, 373*f*, 374*f*, 375*f*, 376*f*
- Luikart-Kielland forceps in operative vaginal delivery, 378, 381
- Luikart-Tucker-McLane forceps in operative vaginal delivery, 367*f*
- Luikart-Simpson forceps in operative vaginal delivery, 367*f*
- Lung lesion resection in fetus, 269–270
- M**
- Macrodeformation, 25
- Magnetic resonance angiography, 455
- Magnetic resonance imaging (MRI), 74–76
 for adnexal masses, 229–230
 contrast agents in, 76
 in deep-vein thrombosis, 517–518
 in diagnosing hematomas, 487
 fetal indications in, 78–79, 79*f*, 265
 maternal indications in, 76, 76*f*, 77*f*, 78*f*
 in morbidly adherent placenta, 445–446, 446*f*
 in placental localization, 441
 safety in, 75–76
- Malecot catheters, 24
 in peripartum hysterectomy, 432
- Mallampati airway classification, 292–293, 294*f*, 312
- Malmstrom vacuum extractor in operative vaginal delivery, 365, 368
- Malposition of the occiput, in operative vaginal delivery, 377
- Management of Myelomeningocele Study (MOMS) trial, 268
- Manual repositioning in uterine inversion, 495–496, 496*t*
- Manual rotation in operative vaginal delivery, 377–378, 378*f*
- Marginal previa, 437
- Marsupialization, 194, 194*f*
- Masterson tissue clamp, 21
- Mastitis, 504
- Maternal age, placenta previa and, 438, 438*f*
- Maternal assessment in preoperative assessment, 291
- Maternal death, 91
- Maternal evaluation, sonography in, 37–68, 65, 66*f*
- Maternal hemorrhage, 277
- Maternal hyperventilation, 308
- Maternal hypotension, 308
- Maternal indications in magnetic resonance imaging, 76, 76*f*, 77*f*, 78*f*
- Maternal morbidity
 in operative vaginal delivery, 385
 in uterine inversion, 500
 in vaginal breech delivery, 336–337, 336*t*
- Maternal mortality, 91–92, 92*f*
 cesarean delivery and, 404
 uterine inversion, 500
- Maternal mortality ratio (MMR), 91
- Maternal obesity, shoulder dystocia and, 391
- Maternal positioning, 302
- Maternal serum alpha-fetoprotein (MSAFP)
 for adnexal masses, 230
 risk for previa and, 439
 in second-trimester screening, 204
- Mature cystic teratoma, 225, 225*f*, 228, 228*f*

- Mauriceau maneuver in vaginal breech delivery, 344, 344f, 345, 348
- Mauriceau-Smellie-Veit maneuver in vaginal breech delivery, 344 in vertex/breech presentation for twins, 344f, 357
- Maylard-Bardenheuer incision, 53
- Maylard incision, 50f, 53–55, 53f, 54f, 55f
- Mayo scissors, 16, 16f in peripartum hysterectomy, 427, 428
- McDonald cerclage, 174, 175f
- McNealy-Glassman viscera retainer, 19, 19f
- McRoberts maneuver, 45 shoulder dystocia and, 395
- MDCT-angiography, 74
- Mechanical index (MI), 63
- Meconium, spillage, 414
- Medial umbilical ligaments, 30
- Median umbilical ligament, 29–30
- Medical abortion, 144–148 first trimester, 144–145, 145t second trimester, 145–148, 145t
- Medical school education, obstetric simulations in, 84, 84f
- Mediolateral episiotomy, 323, 324, 326f repair of, 325
- Membranous equator, 262
- Memory, 5–6
- Menorrhagia, 528
- Menstrual irregularities, 528
- Mersilene sutures, 8–9
- Mesosalpinx, 40
- Mesoteres, 40
- Mesovarium, 40
- Metabolic disorders, 206
- Metastatic placental-site trophoblastic tumor, 162
- Methotrexate in ectopic pregnancy, 121–123, 122t multidose, 122–123, 122t single-dose, 122 in gestational trophoblastic neoplasia, 165
- Methylenetetrahydrofolate reductase (MTHFR) gene, 516
- Methylergonovine (Methergine), 146, 353, 470
- Metoclopramide, 314
- Metreurynters, 143
- Metritis as complication, 507 postcesarean, 513 postoperative, 508
- Metronidazole for uterine infection, 507
- Metzenbaum scissors, 16, 16f in low transverse cesarean delivery, 407 in peripartum hysterectomy, 423, 425, 430
- Microdeformation, 25
- Midline episiotomy, 323, 327t repair of, 325
- Midline vertical incision, 55, 55t, 56f, 57, 57f, 58t
- Midpelvic ureteral injuries, 460, 460f
- Midpelvis, 46
- Mifepristone in medical abortions, 144 in pharmacologic cervical ripening, 143–144
- Migration in wound healing, 60
- Military antishock trousers (MAST), 282
- Minilaparotomy, 525, 530 incisions in, 19
- Minor trauma, 284
- Minute ventilation, 308
- Miscarriage risk of, with laparoscopy, 242 spontaneous, 294
- Misgav-Ladach technique in cesarean delivery, 415
- Misoprostol (Cytotec), 146, 470
- Mitral stenosis, 100–101
- Mitral valve prolapse, 301
- Mobius retractors, 18, 19
- Möbius syndrome, 151
- Modified Early Warning Score (MEWS), 92
- Modified radical hysterectomy, 448–449, 449f
- Molar pregnancy, 157–161 coexistent fetus, 161, 161f complete hydatidiform mole, 157–158, 157f, 158f diagnosis of, 159, 159f ectopic molar pregnancy, 160–161 partial hydatidiform mole, 157f, 158–159 postmolar surveillance, 160 prophylactic chemotherapy, 160 treatment of, 159–160
- Monochorionic, diamnionic (MCDA) twins, 261
- Monochorionic twins, 352 algorithm for delivery of, 361, 361f
- Monocryl Plus, 6, 324
- Monopolar electrosurgery, 22–24, 22f, 23f current, 23–24 patient grounding, 23f, 24 tissue effects, 23, 23f
- Monozygotic twinning, 351, 351f
- Mons pubis, 27, 31
- Morbidity. *See also* Maternal morbidity; Neonatal morbidity febrile, 432 in operative vaginal delivery, 387, 387t perinatal, 490–491 postpartum, 466 from puerperal tubal sterilization, 525
- Morbidly adherent placenta, 435, 442–450, 455, 494 cesarean delivery and, 422 classification, 44f, 436f, 443–444, 443f clinical presentation and diagnosis, 445 magnetic resonance imaging, 445–446, 446f sonography, 445, 445f etiopathogenesis, 443 incidence and associated conditions, 444–445, 444f management, 446–450, 447f cesarean delivery and hysterectomy, 447–448, 447f, 448f delivery timing, 446–447 leaving the placenta in situ, 449 modified radical hysterectomy, 448–449, 449f preoperative arterial or ureteral catheters, 447 undiagnosed placenta accrete syndrome, 449–450 peripartum hysterectomy and, 421 pregnancy outcomes, 450, 450t subsequent pregnancy, 450
- Morison pouch, blood in, 117. *See also* Hemoperitoneum
- Mortality abortion, 134 maternal, 466, 490 perinatal, 490–491 peripartum hysterectomy, 432–433 in peripartum hysterectomy, 432–433 pregnancy-related, 466 from puerperal tubal sterilization, 525
- Mosaicism chromosomal, 208–209 clinical effects of, 217 confined placental, 216–217 management of, 217
- Motor vehicle crash, 278–280, 279f management, 284
- MRI. *See* Magnetic resonance imaging (MRI)
- MTX. *See* Methotrexate
- Mucopolysaccharides, 60
- Multidetector CT (MDCT) imaging, 72–73, 73t
- Multifetal gestations, 438 amniocentesis in, 207–208, 208f chorionic villus sampling in, 213 complications in, 210–211, 211t
- Multineedle technique in amniocentesis, 207
- Multiparity, placenta previa and, 438, 438f
- Muscular dystrophy, 220
- Myelomeningocele, 316
- Myometrial trauma, 444
- Myometritis, 506
- Myometrium, 40
- N**
- Nasopharyngeal bulb suctioning, 410–411
- National ART Surveillance System, 225
- National Domestic Violence Hotline, 281
- National Institute for Health and Clinical Excellence (NICE) guidelines, 265
- Nausea, postoperative, 256, 303, 314
- Necrotizing fasciitis abdominal wound infection, 511–512, 512f vulvar infection, 190–191, 191f, 192t

- Needle driver, 3, 4f
 Needle holders, 3, 17, 17f
 Needles, 2–4
 in amniocentesis, 206–208, 206f, 207f, 210
 blunt point, 3f
 body of, 2–3, 3f
 controlled-release, 2
 conventional cutting, 3f
 curved, 2, 3–4, 3f, 4f
 in fetal blood sampling, 217–219
 length of, 3f
 for neuraxial anesthesia, 312
 open-eyed, 2
 ovoid, 2
 point of, 3, 3f
 reverse cutting, 3f
 swagged, 2
 taper point, 3f
 TAP block, placement for, 314f
 in transabdominal chorionic villus sampling, 213, 214f
 technique in using, 3–4
 Veress, 251–253, 252f, 253f
- Needlestick injuries, 3
- Negative-pressure wound therapy (NPWT), 25, 26, 26f
 prophylactic use of, 58
- Neonatal brachial plexus palsy, 398–399
- Neonatal bradycardia, 410
- Neonatal morbidity
 laparoscopy and, 246
 in operative vaginal delivery, 385–387, 386f
 in vaginal breech delivery, 336, 336t
- Neonatal mortality, laparoscopy and, 246
- Neonatal phototherapy, 410
- Neoplasia
 cervical intraepithelial, 19
 gestational trophoblastic, 156, 161–167
 assessment of, 163
 diagnosis of, 163
 histologic classification, 161–162, 162f
 phantom β -hCG, 166
 quiescent gestational trophoblastic disease, 166–167
 staging, 163–165, 163t, 164t
 subsequent pregnancy outcome, 166
 treatment of, 165–166
 ovarian, 227, 525
- Neural-tube detection, 204–205, 268, 445
- Neuraxial anesthesia for cesarean delivery, 312, 313t
- Newborn depression, 311
- New York Heart Association functional classification, 99, 100t
- Nexplanon, 533, 533f
- Nifedipine in vaginal breech delivery, 347
- Nitabuch layer, 443
- Nitrous oxide analgesia, 309
- No-adverse-effect level (NOAEL), 70
- Noninvasive positive-pressure ventilation (NPPV), 96
- Nonobstetric procedures, timing of, 294
- Nonsteroidal antiinflammatory agents, 313–314
 preoperative administration of, 137
- North American Fetal Therapy Network, 352
- Nuclear Medicine studies, 74
- Nucleic acid amplification testing (NAAT), 193
- Nylon sutures, 8
- O**
- OASIs. *See* Obstetric and sphincter injuries (OASIs)
- Obesity
 abdominal incisions and, 57–58, 59f
 antibiotic prophylaxis and, 296
 cesarean delivery and, 406
 laparoscopy and, 244
 uterine incision choice and, 406–407
 wound healing and, 61
- Obstetric and sphincter injuries (OASIs), 320, 322, 323, 325–332
 complications of, 330–332
 defined, 320
 identification of, 325–327
 prevention of, 330
 subsequent deliveries after, 332
 surgical repair of, 327–330
- Obstetric conjugate, 371
- Obstetric hysterectomy, 419
- Obstetric simulation
 centers and curricula, 83–84, 84f
 evolution of, 82
 future roles for, 89–90
 goals of, 82–83
 in medical student education, 84, 84f
 other scenarios for, 89
 in residency preparation, 85
 types of, 83, 83t
- Obstructed labor, 227, 227f
- Occipital malposition in operative vaginal delivery, 377
- Occiput posterior positions
 Kielland forceps for, 381–382
- Occlusion
 cervical, 180
 fetal endoscopic tracheal, 266–267, 267f
- Ocejo technique for uterine inversion, 498, 499, 500
- Ochsner (Kocher) clamps in peripartum hysterectomy, 424, 425, 426, 430
- O'Connor-O'Sullivan retractors, 18, 59
 in peripartum hysterectomy, 427
- Oligohydramnios, 127
- Omni retractors, 59
- Ondansetron, 314
- Oophorectomy, 126
 adnexal masses and, 238
 versus cystectomy in, 232
 laparoscopic, 237, 237f, 238f
 via laparotomy, 236–237, 236f
- Open-eyed needles, 2
- Open spina bifida, 268–269, 269f
- Operative vaginal delivery. *See under* Vaginal delivery
- Optimal cosmesis, Pfannenstiel incision and, 50
- Organ systems, trauma and, 276–277, 278t
- Oromandibular-limb hypogenesis syndrome, 215
- Ochsner clamps, 21, 21f
- Osmotic dilators, 141–143, 148
- OVA1, 230
- Ovarian cancer, 227, 525
- Ovarian cystadenomas, 225
- Ovarian cysts, 528
- Ovarian fossa, 43
- Ovarian malignancy, 226–227
 diagnosis, 227
 management, 227
- Ovarian pregnancy, 126, 126f
- Ovaries, 39f, 43
 torsion of the, 242
- Overlapping external anal sphincter repair, 329–330, 330f
- Ovoid needles, 2
- Oxytocin (Pitocin)
 dilute, 312
 in second trimester abortion, 147, 147t
 shoulder dystocia and, 393
 in twin delivery, 353
 as uterotonic agent, 470, 470t
- P**
- p57KIP2 protein, 159
- Parachute pack, 479
- Paracolic gutters, blood in, 117. *See also* Hemoperitoneum
- Paramedian incision, 57
- Parametrial cellulitis, 506
- Parametrial phlegmon, 513–514, 513f, 514f
- Parametrium, 40
- Paraovarian cysts, 225
- Paratubal cysts, 225
- Paraurethral glands, 31, 33
- Paravaginal hematoma, 485, 486, 487
- Parietal peritoneum, 29
- Parkland formula for fluid administration, 286
- Parkland method in puerperal sterilization, 529, 529f
- Partial birth abortion, 135
- Partial breech extraction in vaginal breech delivery, 339–340, 339f, 340f
- Partial hydatidiform moles, 157, 157f, 158–159
- Partial thromboplastin times (PTT), 286, 469, 495
- Peabody Developmental Motor Scales score, 269
- Pean clamps, 21, 21f
 in peripartum hysterectomy, 432
- Pelvic cellulitis, 507
- Pelvic fracture, 285
- Pelvic inflammatory disease, 199

- Pelvic innervation, 42–43, 42*f*
 Pelvic ligaments, 40
 Pelvic outlet, 46, 371
 Pelvic ureter, 38*f*, 39*f*, 44. *See also* Ureter
 Pelvic vasculature, 40–42, 41*f*
 Pelvimetry, 74, 338
 Pelvis in preoperative assessment for vaginal delivery, 371–372
 Pencil grip, 15, 16*f*
 Penetrating trauma, 282, 284
 Penetrating wounds, 282
 management, 284–285, 285*f*
 Penicillin allergy, 295
 Pennington clamps in peripartum hysterectomy, 424
 Pennington forceps, 413, 414
 Penrose drain, 24, 24*f*
 in peripartum hysterectomy, 430
 vulvar abscess and, 190
 vulvar hematoma and, 487, 487*f*
 Percutaneous umbilical blood sampling, 217
 Percutaneous valvuloplasty, 270
 Percutaneous Vesicoamniotic Shunting
 Versus Conservative Management for Lower Urinary Tract Obstruction (PLUTO) trial, 264
 Periincisional cellulitis, 508
 Perimortem cesarean delivery, 88, 106, 287–288
 cardiac arrest and, 416
 4 minute rule in, 106
 logistics of, 106
 Perineal laceration, 320, 331. *See also* Episiotomy
 antibiotic prophylaxis for, 302
 classification of, 320–321*t*
 intrapartum simulation in repair of, 87–88, 88*f*
 in operative vaginal delivery, 385
 Perineal nerve, 38
 Perineal pain and dyspareunia, 331
 Perineal trauma, 320
 risk factors for, 327*t*
 Perineum, 34–38
 anterior (urogenital) triangle, 32*f*, 34–35, 35*f*
 pelvic diaphragm, 35–36, 35*f*
 perineal body, 34, 34*f*
 posterior (anal) triangle, 36–38, 36*f*
 pudendal nerve, 36*f*, 38
 Preoperative considerations, 291–304
 assessment, 291–294
 anesthesia selection, 292
 fetal, 292
 laboratory, 291–294
 laparotomy incision selection, 292
 maternal, 291
 preoperative consultation, 292–294, 293*t*, 294*f*
 surgical route selection, 292
 timing of nonobstetric procedures, 294
 intraoperative care
 electrosurgery, 303
 bleeding, 430*t*, 431–432
 infections, 432
 defined, 419
 history
 Eduardo Porro era, 420
 post-Porro era, 420
 pre-Porro era, 419–420
 incidence, 420, 421*f*
 indications, 421–423
 elective cesarean hysterectomy, 423
 emergent, 421–422, 421*t*, 422*f*
 nonemergent, 422
 mortality, 432–433
 operative technique, 424–430
 concurrent ligation technique, 424–429
 cervix removal, 427–428, 427*f*, 428*f*
 cesarean delivery completion, 424
 concluding steps, 429
 opening broad ligament, 424–426, 425*f*
 ureter identification, 426
 uterine artery ligation, 426–427, 426*f*
 uterine vessel isolation, 426, 426*f*
 vaginal cuff closure, 428–429, 429*f*
 delayed ligation technique, 429–430
 salpingo-oophorectomy, 429
 supracervical hysterectomy, 429
 tourniquet method, 430
 risk factors, 421, 421*t*
 surgical procedures
 general considerations, 423–424
 preoperative preparation, 423
 Periparum resuscitation, 315
 Peritoneum, 29–30
 closure of, 414
 Peritonitis, 422
 adnexal abscesses and, 512–513
 fecal, 461
 Pfannenstiel incision, 30
 as abdominal incision, 50–52, 50*f*, 51*f*, 52*f*, 53
 conversion of Maylard incision, 53
 in cystotomy repair, 457
 in transabdominal cervicoisthmic cerclage, 175
 Pfannenstiel-Kerr technique in cesarean delivery, 415
 Phagocytosis, 324
 Phantom β -hCG, 166
 Pharmacologic cervical ripening, 14, 136, 143
 hormone modulators, 143–144
 prostaglandins, 143
 Pharmacologic therapy for obstetric hemorrhage, 315
 Phlebitis, septic, 514
 Phlegmon, parametrial, 513–514, 513*f*, 514*f*
 Photocoagulation, laser, 261
 Photons, 68
 Phototherapy, neonatal, 410

- Physical configuration, 4
- Pinard maneuver
in shoulder dystocia, 396
in vaginal breech delivery, 337, 341, 341*f*
- Pipelle catheter, endometrial biopsy with, 118
- Piper forceps
in operative vaginal delivery, 367*f*
training in use of, 361
in vaginal breech delivery, 310, 345, 345*f*, 346*f*
- Placenta
abnormally implanted, 439
in cesarean delivery, 413–414, 413*f*
low transverse cesarean delivery of, 413–414, 413*f*
delivery of, 413–414, 413*f*
low-lying, 437, 437*t*, 441
morbidly adherent. *See* Morbidly adherent placenta
retained, 150, 471
trauma and, 277–278
- Placenta accreta, 149, 435, 443, 494
focal, 444
total, 444
- Placenta accrete syndrome, 406, 435, 436*f*
peripartum hysterectomy and, 421
undiagnosed, 449–450
- Placenta increta, 435, 436*f*, 443
- Placenta in situ, 449
- Placental abruption, 69*f*, 276, 279, 280*f*, 287
electronic monitoring and, 284
motor vehicle crash and, 279
trauma and, 279
- Placental location, 292
- Placental migration, 436–437
- Placental physiology, 435–436
- Placental-site trophoblastic tumor, 162
- Placenta perceta, 435, 436*f*, 443
medical management of, 128
- Placenta previa, 405, 407, 435, 435*f*, 436–442, 437, 468*t*
association with fetal growth restriction, 442
classification, 437–438, 437*t*
clinical features
abnormally implanted placenta, 439
bleeding, 439
coagulation defects, 439–440
delivery, 441–442
diagnosis, 440–441
magnetic resonance imaging, 441
sonographic placental localization, 440–441, 440*f*
imaging and, 441
incidence and associated factors, 438, 438*f*
elevated serum maternal alpha-fetoprotein levels, 439
maternal age, 438, 438*f*
multiparity, 438
prior cesarean delivery, 438–439
smoking, 439
management, 441, 472–473
maternal and perinatal outcomes, 442, 442*f*
placental migration, 436–437
- Plasticity, 5
- Pliability, 6
- Pneumonia, 92
- Pneumonitis, aspiration, 505
- Pneumoperitoneum, 247, 251
- Pneumoperitoneum-associated problems
from laparoscopy, 256–257
- Points, needle, 3, 3*f*
- Poisoning
accidental, 281
carbon monoxide, 286
intentional self, 282
- Poland syndrome, 151
- Polybutilate sutures, 9
- Polycaprolate sutures, 7
- Polydioxanone (DDS II) sutures, 8
in repairing episiotomies, 325
in wound closure, 530
- Polyester sutures, 8–9
- Polyglactin 910 (Vicryl) sutures, 7–8
in ectopic pregnancy, 124
in episiotomy repair, 324–325
in peripartum hysterectomy, 423
of uterine incisions, 414
in wound closure, 530
- Polyglycolic acid (dexon) sutures, 7
- Polyglyconate (Maxon) sutures, 325
- Polymerase chain reaction (PCR), 220
- Polypectomy, cervical, 184, 185*f*
- Polypropylene suture, 8
- Pomeroy method in puerperal sterilization, 530*f*
- Porro technique, 403
- Portio supravaginalis, 39
- Portio vaginalis, 39
- Postabortion syndrome, 149
- Postamniocentesis chorioamnionitis, 210
- Postcesarean metritis, 513
- Posterior axilla sling traction in shoulder dystocia, 397
- Postoperative bleeding in peripartum hysterectomy, 430*t*, 431–432
- Postoperative care
anesthesia for cesarean delivery, 312–314
intravenous fluids and pain control, 303
postoperative nausea and vomiting, 303
Rh status and progesterone support, 303–304
vital signs, 303
- Postoperative complications, 503–521
puerperal infections, 503–515
breast sources, 503–504, 504*f*
necrotizing fasciitis, 511–512, 512*f*
parametrial phlegmon, 513–514, 513*f*, 514*f*
peritonitis and adnexal abscesses, 512–513
pyelonephritis, 504–505, 505*t*
respiratory complications, 505
septic pelvic thrombophlebitis, 514–515
uterine infection following cesarean delivery, 505–508, 506*t*, 507*f*
wound dehiscence, 510–511, 511*f*
wound hematoma and seroma, 512, 513*f*
wound infections, 508–510, 509*t*, 510*f*
- thromboembolic disease, 515–521
deep-vein thrombosis, 517–519, 518*f*
pulmonary embolism, 519–521
risk factors, 515–516
superficial venous thrombosis, 516–517
thrombophilias, 516
- Postoperative metritis, 508
- Postoperative nausea and vomiting, 256, 303, 314
- Postpartum hemorrhage, 87, 310, 466–480, 482
angiographic embolization
efficacy, 478
technique, 478–479
causes of, 469–471
lacerations, 471
retained placenta, 471
uterine atony, 269–270
uterotonic agents, 470, 470*f*
definition and risk factors, 266–268, 267*t*, 268*t*
hypovolemic shock and volume resuscitation
patient resuscitation, 98, 468–469, 469*t*
physiologic changes, 268
internal iliac artery ligation
efficacy, 476–477
technique, 477–478
intrapartum simulation in, 87
as risk in twin gestations, 350
transvaginal pelvic pressure pack, 479–480, 479*f*
uterine artery ligation
efficacy, 475
technique, 475–476
uterine compression sutures, 473–475
B-lynch method, 473–474, 474*f*
complications with, 475
other methods, 474–475
uterine tamponade
balloon tamponade, 473, 473*f*
uterine packing, 471–473, 472*f*
- Postpartum hemostasis, 456
- Postpartum hysterectomy, 420, 421*t*
- Postpartum morbidity, 466
- Postpartum placement
of intrauterine contraception, 531–533, 532*f*
of subdermal contraceptive, 533, 533*f*
- Postpartum thromboprophylaxis, 298
- Postpartum tubal ligation, 315
anesthesia for, 315–316
- Postterm pregnancy, shoulder dystocia and, 392

- Potts-Smith single-toothed forceps, 17
- Pouch of Douglas, 33, 38
- Power grip, 15, 16*f*
- Practice Guidelines for Obstetric Anesthesia, 314
- Prader-Willi syndrome, 217
- Prague maneuver in vaginal breech delivery, 345, 345*f*
- Pratt dilators, 139
- Preabortion cervical ripening, 141–144, 141*t*
catheter dilators, 143
Dilapan-S, 141–142
laminaria, 141, 142*f*
osmotic dilators, 141–143
pharmacologic, 143–144
- Precision grip, 15
- Preeclampsia, 148, 158
criteria for severe, 101, 101*t*
as risk in twin gestations, 350
- Pregestational diabetes, 304, 304*t*
- Pregnancy
abdominal, 127–128
diagnosis of, 127
management of, 127–128
primary, 127
secondary, 127
cervical, 126–127, 126*f*
cesarean scar, 128–129, 129*f*, 445
critical illness in, 91–107
amniotic fluid embolism, 97
cardiac arrest, 103–106
epidemiology and causes, 103, 104*t*
institutional preparation, 106
management of, 103–106, 104*f*
perimortem cesarean delivery, 106
cardiac disease, 99–101
epidemiology in, 99, 100*t*
management of specific, 100–101, 101*t*
fetal considerations with, 106–107
decision for delivery, 107
drugs and radiation, 106
fetal monitoring, 107
hemodynamic monitoring, 102–103
arterial line, 102
bioimpedance/bioreactance, 103
central venous catheter, 102
determining fluid responsiveness, 103
echocardiography, 103
indications for, 103
pulmonary artery catheter, 102
hemorrhage, 97–99
blood replacement strategies, 98, 468–469, 469*t*
disseminated intravascular coagulopathy, 97–98
massive transfusion protocol, 98
1:1:1 blood product replacement, 98
tranexamic acid, 99
viscoelastic assays, 98, 99*f*
management, 93–95, 94*t*
antimicrobial therapy, 95
fluid resuscitation, 94–95
vasopressors, 95
maternal mortality, 91–92, 92*f*
respiratory failure, 95–97
acute respiratory distress syndrome, 95–96, 96*t*
physiologic changes, 95
treatment of, 96–97, 96*t*
sepsis, 92–95
defined, 93
diagnosis of, 93, 94*t*
epidemiology in, 92–93
diagnostic imaging during, 79, 79*t*
dilation of ureter in, 38
ectopic, 112–129, 527–528. *See also* Ectopic pregnancy
ectopic molar, 160–161
heterotopic, 113, 128, 225, 242–243
hypertrophy of the uterine vasculature in, 42
hypervolemia of, 468
interstitial, 123–124, 124*f*, 125*f*
intrauterine, 225
loss of, 214–215
molar, 157–161
coexistent fetus, 161, 161*f*
complete hydatidiform mole, 157–158, 157*f*, 158*f*
diagnosis of, 159, 159*f*
ectopic molar pregnancy, 160–161
partial hydatidiform mole, 157*f*, 158–159
postmolar surveillance, 160
prophylactic chemotherapy, 160
treatment of, 159–160
monitoring, 303
myometrium in, 40
outcomes with accrete syndromes, 450
ovarian, 126, 126*f*
postterm, 392
stimulation of uterine growth in, 39
subsequent, 166, 450, 501
following cesarean delivery, 406
tubal, 117
- Pregnancy-associated hypertensive disorders, 101, 101*t*, 102*t*
- Pregnancy-associated plasma protein A (PAPP-A), 204
- Pregnancy Mortality Surveillance System, 297
- Pregnancy-related death, 91
- Pregnancy-related mortality ratio, 91, 92
- Pregnancy termination, 172. *See also* Abortions
first- and second-trimester, 133–152
abortion complications, 148–151
hemorrhage, 149
infection, 149–150
physiologic and pharmacologic complications, 147*t*, 150–151
septic abortion, 150
surgical injury, 148–149
abortion indications, 134
abortion mortality, 134
epidemiology of induced abortion, 133–134
legal abortion services, 134–135
limitations to access, 135
provider numbers, 134–135
long-term abortion risks, 151, 152*t*
medical abortion, 144–148
first trimester, 144–145, 145*t*
second trimester, 145–148, 145*t*
methods overview, 136
patient evaluation, 135–136
history and physical examination, 136
laboratory testing, 136
pharmacologic cervical ripening, 143–144
hormone modulators, 143–144
prostaglandins, 143
preabortion cervical ripening, 141–144, 141*t*
catheter dilators, 143
Dilapan-S, 142–143
laminaria, 141, 142*f*
osmotic dilators, 141–142, 142*f*
surgical methods
first-trimester dilation and curettage, 137*f*, 136–140, 136*f*, 138*f*, 139*f*, 140*f*
hysterotomy and hysterectomy, 141
second-trimester dilation and evacuation, 140, 141*f*
- Prenatal screening, 203
- Preoperative consultation, 292–294, 293*t*, 294*f*
- Preperitoneal fat, 29
- Preterm birth, 172, 178, 276, 279, 280, 316
thermal injury and, 281
of twins, 360–361
- Preterm premature rupture of membranes (PPROM), 276
in twin gestations, 352
- Prevena Incision Management System, 26
- Processus vaginalis, 31
- Profuse hemorrhage, 127. *See also* Hemorrhage
- Progesterin-releasing IUDs, 532
- Prolonged prothrombin (PT), 469
- Prophylactic chemotherapy, 160
- Propofol, 315
- Prospective Investigation of Pulmonary Embolism Diagnosis (PIOPED), 520–521
- Prospective Investigation of Pulmonary Embolism Diagnosis (PIOPED–II), 74
- Prostaglandin E₁, 146, 470
for uterine atony, 470, 470*t*
in second-trimester abortion, 146–147
in twin delivery, 353
- Prostaglandin E₂ in second-trimester medical abortion, 146

- Prostaglandins, 151
in pharmacologic cervical ripening, 143
- Prostaglandin F₂α in second-trimester medical abortion, 146
- Prothrombin time (PT), 286, 495
- Pseudofenestration, 364
- Pseudogestational sac, 117
- Pseudomosaicism, 209
- Psoas hitch, 460
- Pubis, 45
- Puborectalis muscle, 38
- Pudendal block, 309–910
- Pudendal nerve, 36*f*, 38, 309*f*
- Pudendum, 30. *See also* Vulva
- Puerperal fever, 503
extragenital causes of, 503
- Puerperal hematomas, 484–487, 485*f*
suprlevator and retroperitoneal, 487, 487*f*
vulvovaginal, 485–487, 486*f*
- Puerperal infections, 503–515
breast sources, 503–504, 504*f*
necrotizing fasciitis, 511–512, 512*f*
parametrial phlegmon, 513–514, 513*f*, 514*f*
peritonitis and adnexal abscesses, 512–513
pulmonary embolism, 519–521
pyelonephritis, 504–505, 505*t*
respiratory complications, 505
risk factors, 515–516
septic pelvic thrombophlebitis, 514–515
uterine infection following cesarean delivery, 505–508, 506*t*, 507*f*
wound dehiscence, 510–511, 511*f*
wound hematoma and seroma, 512, 513*f*
wound infections, 508–510, 509*t*, 510*f*
- Puerperal ovarian abscess, 513
- Puerperal pelvic infections, 506
- Puerperal sterilization, 315, 524–533
after vaginal delivery, 528–530, 529*f*
abdominal entry, 528–529
fallopian tube identification, 529
fallopian tube interruption, 529–530, 529*f*
Irving and Uchida methods, 530
Parkland method, 529, 529*f*
Pomeroy method, 529, 530*f*
risk-reducing salpingectomy, 525–526, 530, 531*f*
wound closure and recovery, 530
counseling, 525–528
ectopic pregnancy and, 527–528
menstrual irregularities and, 528
patient access, 524
surgical approaches, 525
timing, 524–525
tubal sterilization reversal, 528
- Pulmonary angiography, in diagnosing pulmonary embolism, 521
- Pulmonary artery catheter in hemodynamic monitoring, 102
- Pulmonary artery vasodilators, 100
- Pulmonary embolism, 151, 297, 505, 519–521
- Pulseless electrical activity, 500
- Pump-handle maneuver in vertex/breech presentation for twins, 357
- Pyelography, retrograde, 458
- Pyelonephritis, 92, 504–505, 505*t*
- Pyogenic folliculitis, 189
- Pyramidalis muscle, 52
- ## Q
- Quiescent gestational trophoblastic disease, 166–167
- ## R
- Rachitis (rickets), 419
- Radiation
defined, 68
ionizing, 68–74, 69*f*
deterministic effects of, 69, 70–71
diagnostic radiation, 71–74
stochastic effects of, 70, 71
therapeutic radiation, 71
x-ray dosimetry, 70, 70*t*
- Radical hysterectomy, 419
- Radiographic contrast agents, 74
- Radiographic pelvimetry
in vaginal breech delivery, 337
- Radiography, 71–72
chest, 519–520
- Recipient twin, 261
in twin-twin transfusion syndrome, 261–263, 262*f*
- Rectal mucosa, repair of, 328*f*
- Rectouterine pouch, 33, 38
- Rectovaginal fistulas, 331
- Rectus abdominis muscles, 51, 51*f*, 52
- Rectus sheath, 28–29, 29*f*
- Red blood cell alloimmunization, 219
- Red blood cell count, 284–285
postpartum hemorrhage and, 469
in pregnancy prior to surgery, 291
- Red blood cell salvage during cesarean delivery, 315
- REEDA (redness, edema, ecchymosis, discharge, and approximation) model, 331
- Relative effective dose, 68
- Renal toxicity, 314
- Residency
abortion training in, 135
obstetric simulations in, 85
- Respiratory complications, 505
aspiration pneumonitis as, 505
atelectasis as, 505
- Respiratory depression, 313
- Respiratory failure, 95–97
acute respiratory distress syndrome, 95–96, 96*t*
physiologic changes, 95
treatment of, 96–97, 96*t*
- Retained placenta, 150, 471
- Retinal hemorrhage, 386
- Retractors, 59
for abdominal surgery, 18–19, 18*f*, 19*f*
Alexis, 18, 19
Balfour, 18*f*, 59
in peripartum hysterectomy, 427
Bookwalter, 18, 18*f*, 59, 427
Breisky-Navratil, 20, 20*f*
Deaver, 18–19, 59
in peripartum hysterectomy, 423
Denis Browne, 18
Gelpi, 20
Harrington, 19
Heaney right-angle, 20
Kirschner, 18
Mobius, 18, 19
O'Connor-O'Sullivan, 18, 59
in peripartum hysterectomy, 427
Omni, 59
ribbon, 18, 19
Richardson, 18, 59
in low transverse cesarean delivery, 408
in peripartum hysterectomy, 423
self-retaining, 18, 18*f*
sweetheart, 19
for vaginal surgery, 20, 20*f*
- Retrograde pyelography, 458
with fluoroscopic guidance, 458
- Retroperitoneal bleeding, 485
- Retroperitoneal hematoma, 478
- Retroperitoneal injury, trauma and, 278
- Retroperitoneum, 448
- Rh alloimmunization, 210, 414
- Rhesus alloimmunization, 210, 414
- Rh immunoglobulin, 136
- Rh status, 292
- Ribbon retractors, 18, 19
- Richardson retractors, 18, 59, 408, 423
self-retaining, 18, 18*f*
sweetheart, 19
- Ring forceps, 20
in placenta delivery, 414
- Ring of fire, 117
- Risk-reducing salpingectomy, 525–526
in puerperal sterilization, 530, 531*f*
- Ritgen maneuver in operative vaginal delivery, 376
- Ritodrine in vaginal breech delivery, 347
- Roe *v.* Wade, 135
- Rotational thromboelastometry (ROTEM), 98, 99*f*, 315
- Round ligaments, 40
in concurrent ligation technique, 424, 425*f*
- Royal College of Obstetricians and Gynaecologists
obstetric simulation and, 84
ROBuST Course of, 85–86
- Rubin maneuver in shoulder dystocia, 396, 397*f*
- Russian forceps, 18
- ## S
- Sacrococcygeal teratoma, 272
- Sacrum, 45

- operative vaginal delivery and evaluation of, 371–372
- Safety
- double gloving in, 3
 - in magnetic resonance imaging, 75–76
 - needlestick injuries and, 3
 - in sonography, 63, 64*f*, 65, 65*f*
- Salbutamol in vaginal breech delivery, 347
- Salpingectomy
- in ectopic pregnancy, 118–120, 119*f*
 - laparoscopic, 243
 - risk-reducing, 525–526
 - total, 525, 526, 530
- Salpingo-oophorectomy, 429
- adnexal mass and, 230–232
 - bilateral, 431
- Salpingostomy in ectopic pregnancy, 120–121, 120*f*
- Scalpel and blades, 15–16, 15*f*
- grips for, 16, 16*f*
- Scarpa fascia, 27, 30, 35
- Scissors, 16–17, 16*f*
- Jorgenson, 16, 428
 - Mayo, 16, 16*f*
 - curved, 16, 16*f*
 - straight, 16
 - Metzenbaum, 16, 16*f*, 407
- Scopolamine patch, 314
- Seatbelt use, 29*f*, 278–279
- Second-stage labor
- prolonged, in operative vaginal delivery, 369
 - rapid or prolonged in shoulder dystocia, 392–393
 - in vaginal breech delivery, 338–346
 - delivery of the arms, 342–343, 342*f*, 343*f*
 - delivery of the head, 336*t*, 344–346, 344*f*, 345*f*, 346*f*
 - partial breech extraction, 339–340, 339*f*, 340*f*
 - total breech extraction, 340–342, 341*f*
- Second trimester
- abortion mortality in, 134
 - accrete syndromes in, 445
 - dilation and evacuation, 134, 140, 141*f*
 - genetic amniocentesis in, 212
 - intraabdominal surgery in, 244
 - medical abortion, 145–148, 145*t*
 - medical versus surgical abortion in, 147–148
- Selective laser coagulation of placental vessels (SLCPV), 263
- Self-retaining retractors, 18, 18*f*
- Semicircular line of Douglas, 28–29
- Separation pain, 123
- Sepsis, 92–95, 422*f*, 513
- defined, 93
 - diagnosis of, 93, 94*t*
 - epidemiology in, 92–93
 - management, 93–95, 94*t*
 - postpartum, 489
- Sepsis in Obstetrics Score (SOS), 92
- Septic abortion, 150
- Septic pelvic thrombophlebitis, 514–515
- diagnosis of, 514–515
- Septic phlebitis, 514
- Septic shock. *See* Sepsis syndrome
- Septostomy, amnionic, 261
- Seroma, 512, 513*f*
- Sevoflurane, 312
- Sexually transmitted diseases, 189, 197–199
- condyloma acuminata, 194–196, 195*f*
 - chlamydial infection, 113, 149, 192, 198
 - gonorrhea, 113, 189, 192, 197–198
 - pelvic inflammatory disease, 199
 - trichomoniasis, 189, 198–199
- Shirodkar cerclage, 172–174, 173*f*, 181
- Shoulder dystocia, 45, 389–400
- birthweight and, 390, 390*t*
 - chart documentation, 400, 400*t*
 - defined, 389
 - differential diagnosis, 390, 390*t*
 - history, 389–390
 - incidence, 390, 390*f*
 - intrapartum simulation in, 85, 85*f*
 - management, 393–398, 393*t*
 - abdominal rescue, 397
 - all-fours maneuver, 396
 - cephalic replacement--Zavanelli maneuver, 397
 - clavicular fracture, 396
 - episiotomy, 395
 - fundal pressure, 397
 - McRoberts maneuver, 395
 - posterior arm extraction, 395–396, 396*f*
 - posterior axilla sling traction, 397
 - Rubin maneuver, 396, 397*f*
 - suprapubic pressure, 395
 - symphysiotomy, 398
 - Woods maneuver, 395, 395*f*
 - maternal complications, 399
 - neonatal complications, 398–399, 398*t*
 - prediction and prevention, 393
 - risk factors, 390–393, 391*t*
 - diabetes mellitus, 391–392
 - fetal macrosomia, 391, 391*f*
 - maternal obesity, 391
 - operative vaginal delivery, 393
 - oxytocin administration, 393
 - postterm pregnancy, 392
 - rapid or prolonged second-stage labor, 392–393
 - simulation and, 85, 85*f*, 400
- Shunt, 95
- Shunting, thoracoamnionic
- for congenital cystic adenomatoid malformation, 265–266
 - fetal outcomes, 266
 - for fetal pleural effusion, 264–265
 - lung lesion resection and, 269
 - technique in, 266
- Silk Cup in uterine inversion, 497, 500
- Silk sutures, 8
- Simplified Acute Physiology Score (SAPS), 92
- Simpson forceps in operative vaginal delivery, 368*f*
- Simulations
- antepartum, 88–89, 89*f*
 - cerclage in, 88
 - obstetric sonography in, 88–89, 89*f*
 - computer-based, 83, 83*t*
 - critical care, 88, 88*t*
 - faculty-driven, 83, 83*t*
 - intrapartum, 85–88, 85*t*
 - cesarean delivery, 87, 87*f*
 - operative vaginal delivery in, 85–86, 86*f*
 - perineal laceration repair, 87–88, 88*f*
 - postpartum hemorrhage, 87
 - shoulder dystocia, 85, 85*f*
 - vaginal breech delivery, 86–87, 86*f*
 - in medical school education, 84, 84*f*
 - model-based, 83, 83*t*
 - obstetric sonography, 88–89, 89*f*
 - in patient-doctor communication, 89
 - in residency, 85, 135
 - shoulder dystocia and, 85, 85*f*, 400
 - vacuum delivery, 86
- Single forceps, 18
- Skene glands, 31, 32, 33
- Slipknot, 9–10, 10*f*
- Slips and falls, 280
- Small-bowel injuries, 461, 462*f*
- Smead-Jones closure, 57
- Smoking
- ectopic pregnancy and, 113
 - placenta previa and, 439
 - trauma and, 278
 - wound infection and, 291
- Society for Maternal-Fetal Medicine,
 - obstetric simulation and, 84
- Society for Obstetric Anesthesia and Perinatology (SOAP), 105
- Serious Complication Repository (SCORE) Project of the, 307
- Society for Simulation in Healthcare, 82
- criteria for simulation centers, 84
- Society of Critical Care Medicine on sepsis-related disorders, 93
- Solomonization, 263
- Solomon technique, 263
- Sonography, 63–68
- adjunctive use of intraoperative, 139
 - in amniocentesis, 206, 207, 207*f*
 - in assessing hematoma location, 486, 486*f*
 - in diagnosing adnexal masses, 227–229, 228*f*
 - before chorionic villus sampling, 212, 213, 213*f*, 214*f*
 - in diagnosing ectopic pregnancy, 116–117, 116*f*, 117*f*
 - dilation and evaluation and, 139
 - FAST, 286, 287*f*
 - fetal blood sampling with, 218, 218*f*
 - in fetoscopic laser ablation of vasa previa, 271, 272*f*

- Sonography (*Continued*)
 identifying Lambda sign with, 351
 identifying T sign with, 352
 incidental finding of adnexal masses
 during, 224–225, 225*t*
 in maternal evaluation, 65, 66*f*, 67, 68
 in lower urinary tract obstruction, 263
 molar pregnancy, diagnosis of, 159, 159*f*
 in morbidly adherent placenta, 445, 445*f*
 in operative vaginal delivery, 370, 371
 in percutaneous valvuloplasty, 270, 270*f*
 in placental localization, 440–441, 440*f*
 in placenta previa, 441
 in twin–twin transfusion syndrome, 261
 safety in, 63, 63, 64*f*, 64*f*, 65, 65*f*
 simulation, 88–89, 89*f*
 thoracocentesis under guidance of, 265
 transabdominal, 440
 translabial, 440
 transvaginal, 440, 441, 441*f*, 445, 445*f*
 in twin gestations, 351–352
- Specimens, laparoscopic removal of, 254–255
- Spina bifida, open, 204, 268–269, 269*f*
- Spinal anesthesia, 315
- Spinal block, 310
- Sponge forceps, 20
- Spontaneous abortion, 276, 281, 294
- Spontaneous miscarriage, 276, 281, 294
- Spontaneous resolution, 118
- Square knot, 9, 10*f*
- Stainless steel sutures, 9
- Staples, 13
- Stargazing fetus, 336
- Sterilization. *See also* Contraceptives;
 Intrauterine devices (IUD)
 hysteroscopic, 525
 laparoscopy in, 525
 puerperal. *See* Puerperal sterilization
 at the time of cesarean delivery, 530–531
 tubal, 113, 524, 525, 526, 527, 528
 reversal of, 528
- Stillbirth, 276
 antepartum, 278
- Stomach, decompression, 248
- Straight Mayo scissors, 16
- Subaponeurotic hemorrhage, 377
- Subarachnoid block, 310
- Subcostal echocardiography, 103
- Subcuticular sutures, 13
- Subdermal contraceptive, postpartum
 placement of, 533, 533*f*
- Subgaleal hematoma, 377
 in operative vaginal delivery, 386, 386*f*
- Subsequent pregnancies, 450
 after obstetric anal sphincter lacerations,
 332
 following cesarean delivery, 416
 gestational trophoblastic disease and, 157,
 166
 induced abortion on, effects of, 151, 152*t*
 uterine inversion and, 501
- Substance abuse, 282
 intimate-partner violence and, 281
- Subtotal hysterectomy, 429
- Subumbilical midline vertical incision in
 peripartum hysterectomy, 423
- Subxiphoid laparoscopic entry, 253–254
- Suction curettage, 149
- Suicide, 282
- Superficial venous thrombosis, 516–517
- Supracervical hysterectomy, 429
- Suprapubic pressure, shoulder dystocia and,
 395
- Suprapubic teloscopy, 458, 459*f*
- Supraumbilical incision, 50*f*, 55
- Surgeon's throw, 9
- Surgery. *See also specific* abdominal, 18–19,
 18*f*, 19*f*
 for adnexal masses, 230–237
 adnexectomy via laparotomy, 232*f*,
 236–237, 236*f*
 cystectomy versus adnexectomy, 232
 cystectomy via laparotomy, 232, 232*f*,
 233*f*
 laparoscopic adnexectomy, 237, 237*f*,
 238*f*
 laparoscopic cystectomy, 232, 234,
 234*f*, 235*f*, 236–237
 laparotomy versus laparoscopy,
 231–232
 preoperative preparation, 231
 dilation and curettage (D & C), 134
 first-trimester, 136–140, 136*f*, 137*f*,
 138*f*, 139*f*, 140*f*
 dilation and evacuation (D & E), 134
 intact, 135
 second-trimester, 135, 140, 141*f*
 in ectopic pregnancy, 118–121
 conservative versus radical surgery, 118
 laparotomy versus laparoscopy, 118
 salpingectomy, 118–120, 119*f*
 salpingostomy, 120–121, 120*f*
 episiotomy repair, 324–325
 for gestational trophoblastic neoplasia,
 165
 induced defects, 171–172
 prior abdominopelvic, 244
 repair of obstetric and sphincter injuries
 (OASIs), 327–330
 Universal Protocol on, 302
 for uterine inversion, 498–500, 499*f*
 vaginal, 33–34, 33*f*
 retractors for, 20, 20*f*
- Surgical drains, 24–25, 24*f*
 potential complications of, 25*f*
- Surgical Infection Society (SIS), 295
- Surgical instruments, 15–26. *See also specific*
 electrosurgery and, 22–24
 bipolar, 22*f*, 24
 coexisting electrical devices, 24
 monopolar, 22–24, 22*f*, 23*f*
 in laparoscopy, 248
 needle holders, 17
 retractors
 for abdominal surgery, 18–19, 18*f*, 19*f*
 for vaginal surgery, 20, 20*f*
- scalpels
 blades for, 15–16, 15*f*
 grips for, 16, 16*f*
 scissors, 16–17, 16*f*
 suction tips, 22, 22*f*
 surgical drains, 24–25, 24*f*
 tissue clamps, 20–22, 20*f*, 21*f*
 tissue forceps, 17–18, 17*f*
 vacuum-assisted wound closure and,
 25–26, 25*t*
 efficacy, 26
 mechanisms of action, 25–26, 25*f*
 prophylactic use, 26
- Surgical route selection, 292
 laparoscopic entry, 248–254
 Surgical site, infection prevention,
 294–297, 295*t*
- Surgical time out, 302
- Surveillance
 in ectopic pregnancy, 123
 National ART Surveillance System in,
 225
 postmolar, 160
 Pregnancy Mortality Surveillance System
 and, 297
- Surviving Sepsis Campaign, 93
- Sutures, 2, 4–9, 4*t*. *See also specific*
 characteristics of, 4–6, 4*t*, 5*f*
 comparison of absorbable, 6*t*
 comparison of nonabsorbable, 7*t*
 diameter of, 4–5
 handling characteristics of, 6
 interrupted, 2
 subcuticular, 13
 for surgical repair of episiotomy, 324–325
 tissue reactivity to, 6, 6*t*
 types of, 6–9, 6*t*, 7*t*
 catgut, 6, 7, 324–325, 414
 cotton, 8
 Dexon II, 7
 Dexon S, 7
 mersilene, 8–9, 172, 174, 174*f*, 176
 nylon, 8
 polybutilate, 9
 polycaprolate, 7
 polydioxanone (PDS II), 8, 325, 530
 polyester, 8–9
 polyglactin 910 (Vicryl), 7–8, 124,
 324–325, 414, 423, 530
 polyglycolic acid (Dexon), 7
 polypropylene, 8
 silk, 8
 stainless steel, 9
- Suturing, needlestick injuries during, 3
 Swaged needle, 2
 Swage of needle, 2
 Sweetheart retractors, 19
- Symphiotomy in shoulder dystocia, 397
- Synclitism in operative vaginal delivery,
 370*f*
- Systemic Inflammatory Response Syndrome
 (SIRS) criteria, 92, 93
- Systemic lupus erythematosus, 489

- T**
- Tapored needle points, 3
- Tensile strength, 5
- Teratoma, sacrococcygeal, 272
- Terbutaline
 - as uterine relaxant, 310
 - in vaginal breech delivery, 347
- Term Breech Trial, publication of, 335, 336
- Theca-lutein cysts, 148, 225, 228, 229*f*
 - sonographic evaluation of, 228, 229*f*
- Thermal burns, 286
- Thermal index (TI), 63
- Thermal injury, preterm delivery and, 281
- Third-stage labor during cesarean delivery, 494
- Third trimester
 - abortions in, 135
 - falls in, 280
- Thoracoamniotic shunting, 269
 - for congenital cystic adenomatoid malformation, 265–266
 - fetal outcomes in, 266
 - for fetal pleural effusion, 264–265
 - technique in, 266
- Thoracocentesis, 265
- Thoracostomy tube, 285
- Thrombocytopenia
 - alloimmune, 219
 - fetal, 219–220
 - gestational, 528
 - heparin-induced, 519
- Thromboelastography (TEG), 98, 99*f*, 315
- Thromboembolic disease, 515–521
 - deep-vein thrombosis, 517–519, 518*f*
 - pulmonary embolism, 519–521
- Thromboembolism, 151
 - incidence and risk, 297
 - prevention, 297–298, 299–300*t*, 301*t*
- Thrombophilias, 516
- Thrombophlebitis, septic pelvic, 514–515
- Thromboprophylaxis, postpartum, 298
- Thyroid scan, 74
- Tilt test, 244
- Time out, 202
- T-incision, 409
- Tissue clamps, 20–22, 20*f*, 21*f*
- Tissue forceps, 17–18, 17*f*
- Tissue reactivity to sutures, 6, 6*t*
- Tocolysis, laparoscopy and, 246
- Topical negative pressure (TNP), 25
- Torsion
 - adnexal, laparoscopy in diagnosing and treating, 242–243
 - diagnosis, 226
 - incidence and etiology, 225–226, 225*f*
 - treatment, 226
- Total breech extraction in vaginal breech delivery, 340–342, 341*f*
- Total salpingectomy, 525, 526, 530. *See also* Salpingectomy
- Tourniquet method, 424
 - in peripartum hysterectomy, 430
- Tracheal intubation, failed, 308
- Training. *See also* Simulations
 - of future obstetricians, 361
 - in preoperative assessment, 372, 372*t*, 373*t*
 - use of Piper forceps, 361
 - virtual reality, 83, 83*t*
- Tranexamic acid (TXA), 98, 99, 315
 - hemorrhages and, 99
- Transabdominal cervical cerclage, 500
- Transabdominal cervicoisthmic cerclage, 174–176, 175*f*, 176*f*, 179, 242–243
- Transabdominal sonography, 440. *See also* Sonography
- Transesophageal echocardiography, 103
- Transfusion protocols, 314, 431–432
- Translabial sonography, 440
- Transthoracic echocardiography, 103
- Transurethral cystoscopy, 458
- Transvaginal cerclage efficacy, 177–179, 178*t*, 179*t*
- Transvaginal pelvic pressure pack, 479–480, 479*f*
- Transvaginal sonography, 440, 441, 441*f*, 445, 445*f*. *See also* Sonography
- Transversalis fascia, 29
- Transverse incisions, 49–55, 292
 - Cherney, 52–53, 53*f*
 - Maylard, 50*f*, 53–55, 53*f*, 54*f*, 55*f*
 - Pfannenstiel, 50–52, 50*f*, 51*f*, 52*f*, 53
 - supraumbilical, 50*f*, 55
- Transversus abdominis plane (TAP) block, 30, 313
- Trauma
 - abdominal, 282, 286, 287
 - algorithm in managing, 283*f*
 - laparoscopic, 241–242
 - perineal, 320
 - in pregnancy, 276–288
 - incidence, 276, 277*f*
 - intentional, 278
 - inimate-partner violence, 281–282
 - penetrating trauma, 282
 - suicide and homicide, 282
 - management
 - burn, 285–286
 - fetal monitoring, 287
 - imaging, 286, 286*f*
 - initial assessment, 282–284, 283*f*
 - laboratory evaluation, 286–287
 - minor trauma, 284
 - motor vehicle crash, 284
 - pelvic fracture, 285
 - penetrating wound, 284–285, 285*f*
 - perimortem cesarean delivery, 287–288
 - maternal physiologic changes
 - organ systems, 276–277, 278*t*
 - uterus and placenta, 277–278
 - myometrial, 444
 - risk factors, 278
 - unintentional, 278–281
 - accidental poisoning, 281
 - burns, 280–281
 - electric shock, 281
 - motor vehicle crash, 278–280, 279*f*
 - slips and falls, 280
 - uterine rupture in, 491
- Trendelenburg position, 257
 - reverse, 257
- Trial of labor after cesarean (TOLAC), 456
- Trichomoniasis, 189, 198–199
- Trisomy 21, 264
- Trocars, 247
 - wound infections at sites of, 257
- Trophotropism, 437
- T sign, sonography in identifying, 352
- Tubal abortion, 118
- Tubal anastomosis, 528
- Tubal factor infertility, 113
- Tubal interruption, 530
- Tubal ligation, anesthesia for postpartum, 315–316
- Tubal peristalsis, 44
- Tubal pregnancy, 117
- Tubal rupture, 118
- Tubal sterilization, 113, 524, 525, 526, 527, 528
 - reversal of, 528
- Tubovarian abscess, 199
- Tucker-McLane forceps in operative vaginal delivery, 363*f*, 367*f*, 368*f*, 381
- Tumor markers for adnexal masses, 230
- Tumors. *See also* Cancer
 - epithelioid trophoblastic, 162
 - metastatic placental-site trophoblastic, 162
 - placental-site trophoblastic, 162
- Twin Birth Study, 350, 353, 354, 359
- Twin gestations, 350–361
 - algorithm, 361, 361*f*
 - alternative approach to delivery, 360
 - antepartum management, 352–353
 - cesarean delivery in, 354
 - chorionicity in, 351–352, 351*f*, 352*f*
 - coexistent fetus and, 161, 161*f*
 - delivery of very preterm twins, 360–361
 - delivery preparation in, 353, 354*t*
 - first-stage labor in, 353
 - interval between twins and combined delivery, 353–354
 - planned vaginal delivery
 - breech twin A, 357, 359
 - justification, 359–360
 - vertex/breech presentation, 356–357
 - vertex/transverse presentation, 357, 358*f*, 359*f*
 - vertex/vertex presentation, 354–356, 356*f*
 - risks in, 350–351
 - training for, 361
 - vaginal delivery, 310–311
- Twin peak sign, sonography in identifying, 351
- Twin reversed arterial perfusion (TRAP) sequence, 243

- Twins
 amniocentesis in, 211
 donor, in twin-twin transfusion syndrome, 261–263, 262*f*
 recipient, in twin-twin transfusion syndrome, 261–263, 262*f*
- Twin-twin transfusion syndrome (TTTS), 243, 316, 352
 fetal therapy and, 261–263, 262*f*
- Two-hit hypothesis, 268
- U**
- Uchida method in puerperal sterilization, 530
- Ultrasound, abdominal, 65, 66*f*.
See Sonography
- Umbilical cord clamping
 delayed, 410
 in low transverse cesarean delivery, 410, 413
 in vaginal twin delivery with vertex presentation, 355
- Umbilical ligaments, 29
- Umbilical cord pH values, 410
- Unfractionated heparin
 in management of deep-vein thrombosis, 518
 in management of pulmonary embolism, 521
 perioperative indications for, 298
- Unintentional trauma, 278–281
 burns, 280–281
 electric shock, 281
- Uniparental disomy, 217
- Universal Protocol for Preventing Wrong Site, Wrong Procedure, and Wrong Person Surgery, 302
- Upper quadrant laparoscopic entry, 253
- Urachus, 29–30
- Ureaplasma urealyticum*, 196
- Ureter, 38*f*, 40. *See also* Ureteral injuries.
 adnexectomy and, 232
 dilatation during pregnancy, 44
 injury to, risk of, 41
 obstructing stone in, 73*f*
 pelvic, 44
 in peripartum hysterectomy, 424, 426, 431
 placenta accrete syndrome and, 447, 449
 preoperative stents placement, 447
- Ureteral injuries, 416
 cystoscopy, 458
 diagnosis, 457–458
 distal ureteral injuries, 458–460, 459*f*
 incidence and risks, 457
 midpelvic, 460, 460*f*
 in peripartum hysterectomy, 424
 psoas hitch or boari flap, 460
 ureteral stents, 458
 ureteroneocystostomy, 459–460, 459*f*
- Ureteroneocystostomy, 459–460, 459*f*, 460*f*
- Urethra, 33
 injuries to, 455–456
- Urinary retention
 as short-term effect of operative vaginal delivery, 385
- urethral injuries and, 455
- Urinary tract, injuries to
 during cesarean delivery, 454–455, 455*t*
 in peripartum hysterectomy, 431
- Urologic injuries, 455–461
 bladder injuries
 cystomy diagnosis, 456
 cystomy repair, 456–457
 incidence and risks, 456
 prevention, 457
 as common, 450
 risk factors, 455*t*
 ureteral injuries
 cystoscopy, 458
 diagnosis, 457–458
 distal ureteral injuries, 458–460, 459*f*
 incidence and risks, 457
 midpelvic, 460, 460*f*
 psoas hitch or boari flap, 460
 ureteral stents, 458
 ureteroneocystostomy, 459–460, 459*f*
 urethral injuries, 455–456
- Urticaria, 295
- Uterine artery, 41, 175, 310
 ligation of
 efficacy, 475
 in peripartum hysterectomy, 426–427, 426*f*
 technique, 475–476
- Uterine aspiration, 140*f*
- Uterine atony, 149, 500–501
 as cause of postpartum hemorrhage, 469–471
- Uterine compression sutures, 473–475
 B-lymph method, 473–474, 474*f*
 complications with, 475
 other methods, 474–475
- Uterine incarceration, 47, 47*f*
- Uterine incisional necrosis, 422
- Uterine incision in cesarean delivery, 406–407, 407*f*
 extension of, in low transverse, 409, 409*f*
- Uterine infection following cesarean delivery, 422, 422*f*, 505–508, 506*t*, 507*f*
- Uterine inversion, 493–501
 antibiotic prophylaxis, 500
 during cesarean delivery, 493
 classification, 393*t*, 493
 defined, 493
 diagnosis, 495
 etiology, 494
 incidence, 493–494
 management
 general considerations, 495–500, 496*f*
 nonsurgical, 495–498, 496*t*, 497*f*
 surgical, 498–500, 499*f*
 maternal morbidity and mortality, 500
 reinversion, 500–501
 subsequent pregnancy, 501
- Uterine leiomyomas, as indication of peripartum hysterectomy, 422
- Uterine malformations, 171
- Uterine manipulation in laparoscopy, 254
- Uterine myomas, 489
- Uterine packing for atony, 470
- Uterine perforation, 149
- Uterine rupture, 150, 276, 405, 487–491, 488*t*
 clinical findings and diagnosis, 489–490, 490*f*
 incidence and predisposing factors, 488–489
 management, 490
 outcomes
 maternal mortality, 490
 perinatal morbidity and mortality, 490–491
 pathogenesis, 489, 489*f*
 traumatic, 491
- Uterine scar as reason for postpartum hysterectomy, 422
- Uterine size, laparoscopy and, 244
- Uterine tamponade
 balloon, 473, 473*f*
 uterine packing, 471–473, 472*f*
- Uterine tears, 489–490
- Uterine vessel isolation in peripartum hysterectomy, 426, 426*f*
- Uterosacral ligaments, 40
 in peripartum hysterectomy, 427–428
- Uterotonic agents, 149. *See also*
 Methylergonovine, Misoprostol, Carbopros tromethamine
 for abortion, 144
 for decreasing risk of reinversion, 501
 for midtrimester labor induction, 146
 in molar pregnancy, 160
 for postpartum hemorrhage, 87, 470, 470*t*
 for twin vaginal delivery, 353
 in uterine inversion, 495, 496
- Uterus, 33*f*, 38–40, 38*f*. *See also specific procedures*
 cervix, 39–40, 39*f*
 endometrium, 40
 myometrium, 40
 trauma and, 277–278
- V**
- Vacuum aspiration in first trimester, 136
- Vacuum-assisted delivery, 323, 368, 368*t*, 376–377, 376*f*, 377*f*
 forceps and, 309–310, 309*f*
 simulated, 86
- Vacuum-assisted wound closure, 25–26, 25*t*
 efficacy, 26
 mechanisms of action, 25–26, 25*f*
 prophylactic use, 26

- Vacuum curette, 139*f*
- Vagina, 33–34, 33*f*. *See also specific procedures*
- Vaginal birth after cesarean (VBAC), 454, 456
- Vaginal bleeding, 210
- Vaginal breech delivery, 310, 335–348
 - attempted, 337
 - background, 335–336
 - cesarean delivery, 336*t*, 337*t*, 348
 - epidemiology
 - maternal morbidity, 336–337, 336*t*
 - neonatal morbidity, 336, 336*t*
 - rates, 336
 - external cephalic version, 347–348, 348*f*
 - first-stage labor, 338
 - intrapartum simulation in, 86–87, 86*f*
 - preterm breech, 346–347
 - second-stage labor, 338–346
 - delivery of the arms, 342–343, 342*f*, 343*f*
 - delivery of the head, 336*t*, 344–346, 344*f*, 345*f*, 346*f*
 - partial breech extraction, 339–340, 339*f*, 340*f*
 - total breech extraction, 340–342, 341*f*
 - selection criteria, 337–338, 337*t*
 - successful, 337
 - vertex/breech presentation for twin gestations, 356–357
- Vaginal cuff closure in peripartum hysterectomy, 428–429, 429*f*
- Vaginal delivery, 36
 - after cesarean delivery, 406, 454
 - obstetric simulations in, 84, 84*f*
 - operative, 363–387
 - Barton forceps in, 382–384, 382*f*, 383*f*, 384*f*
 - fetus in preoperative assessment, 370–371, 370*f*, 371*f*
 - forceps in, 323, 365–366*t*, 367*f*, 368
 - history, 363–365, 363*f*, 364*f*
 - indications, prerequisites, and classification, 369–370, 369*t*
 - instrument choice in, 368–369
 - intrapartum simulation in, 85–86, 86*f*
 - Kielland forceps in, 378–382, 379*f*, 380*f*, 381*f*
 - Luikart forceps in, 373–376, 373*f*, 374*f*, 375*f*, 376*f*
 - malposition of the occiput in, 377
 - manual rotation in, 377–378, 378*f*
 - maternal morbidity in, 385
 - morbidity of forceps rotation, 387, 387*t*
 - morbidity of midpelvic delivery, 387
 - neonatal morbidity in, 385–387, 386*f*
 - pelvis in preoperative assessment, 371–372
 - sequential use of instruments in, 384
 - shoulder dystocia and, 393
 - training in preoperative assessment, 372, 372*t*, 373*t*
 - trial of, 384–385
 - vacuum-assisted delivery, 323
 - vacuum extraction in, 368, 368*t*, 376–377, 376*f*, 377*f*
- puerperal sterilization after, 528–530, 529*f*
 - abdominal entry, 528–529
 - fallopian tube identification, 529
 - fallopian tube interruption, 529–530, 529*f*
 - Irving and Uchida methods, 530
 - Parkland method, 529, 529*f*
 - Pomeroy method, 529, 530*f*
 - risk-reducing salpingectomy, 530
 - wound closure and recovery, 530
- simulated, 86
- for twins, 310–311
- vertex/vertex presentation, 354–356, 356*f*
- Vaginal flora, 196
- Vaginal lacerations, 483
 - bilateral, 483
- Vaginal septum, 182, 183*f*
- Vaginal spotting, 214
- Vaginal surgery, 33–34, 33*f*
 - retractors for, 20, 20*f*
- Vaginosis, bacterial, 196–197, 197*t*
- Valvuloplasty, percutaneous, 270
- Vasa previa, 243, 271
 - antepartum treatment of, 438
- Vascular clamps, 21*f*
- Vascular endothelial growth factor (VEGF), 26
- Vascular equator, 263
- Vascular injuries from laparoscopy, 256
- Vascular pedicle, double-ligation of a, 13*f*
- Vascular steal phenomenon, 272
- Vasectomy, 524
- Vasopressors
 - for fluid resuscitation, 94
 - judicial use of, 106
 - for septic shock, 95
- Vena caval thrombosis, 76
- Venal caval filters in treating pulmonary embolism, 521
- Venography as gold standard, 517
- Venous thromboembolism (VTE), 291, 515
 - risk of, 277
- Ventilation-perfusion mismatch, 95
- Ventilation-perfusion (V/Q) scanning, 74
 - in diagnosing pulmonary embolism, 520–521
- Ventral wall defects, 151
- Veress needle laparoscopic entry, 251–253, 252*f*, 253*f*
- Vertex/transverse presentation for twin gestations, 356–357, 358*f*, 359*f*
- Vertex/vertex presentation for twin gestations, 354–356, 356*f*
- Vertical incisions, 49, 55–57
 - midline vertical, 55, 55*t*, 56*f*, 57, 57*f*, 58*t*
 - paramedian, 57
- Vesicoamniotic shunt placement, 220
- Vesicouterine peritoneal reflection incision, 407*t*, 408, 409*f*
- Vesicouterine space, in peripartum hysterectomy, 424
- Vesicovaginal space, 33
- Vessel embolization by arteriography, 148
- Vestibular bulbs, 32
- Vestibule, 31*f*, 32
- Viability, 135
- Vicryl Plus, 6, 324–325
- Violin grip, 15
- Virtual reality simulation, 83, 83*t*
- Visceral injuries from laparoscopy, 256
- Viscoelastic assays, 98, 99*f*
- Vital signs, 303
- Vitamin D deficiency, 419
- Volatile agents, 312
- Vomiting, postoperative, 256, 303, 314
- von Willebrand disease, 485
- Vulva, 30–33, 31*f*
 - clitoris, 32, 32*f*
 - greater vestibular (Bartholin) glands, 32–33
 - mons pubis and labia, 31
 - paraurethral glands, 33
 - urethra, 33
 - vestibular bulbs, 32
 - vestibule, 31*f*, 32
- Vulvar abscess, 189–192, 190*f*
 - hidradentis suppurativa, 191–192
 - incision and drainage, 189–190
 - necrotizing infection, 190–191, 191*f*, 192*t*
- Vulvar hematoma, 486
- Vulvovaginal candidiasis, 199
- Vulvovaginal hematomas, 485–487, 486*f*
- Vulvovaginal lacerations, 482–483, 483*f*
 - repair of, 87–88
- W**
- Warfarin in management of deep-vein thrombosis, 519
- Warts, anogenital, 195
- White blood cell (WBC) count, 285
- Woods maneuver, shoulder dystocia and, 395, 395*f*
- Word catheter placement, 193–194
- Wound(s)
 - clean, 60, 60*t*, 294, 295
 - clean contaminated, 60, 60*t*, 294
 - contaminated, 294–295
 - infected, 60, 60*t*, 291, 295
 - penetrating, 282
 - management, 284–285, 285*f*
 - smoking and infection, 291
- Wound closure
 - after puerperal sterilization, 530
 - in low transverse cesarean delivery, 414, 414*f*

- Wound complications, in peripartum hysterectomy, 432
 - Wound dehiscence, 331–332
 - as postoperative complication, 510–511, 511*f*
 - Wound healing, 59–61
 - factors affecting, 61
 - maturation in, 60
 - migration in, 60
 - physiology in, 59–60
 - proliferation in, 60
 - wound classification in, 60, 60*t*
 - wound closure in, 60–61
 - Wound hematoma and seroma, as postoperative complication, 512, 513*f*
 - Wound infections, 60, 60*t*, 295, 331–332
 - as postoperative complication, 508–510, 509*t*, 510*f*
 - Wound security, 12
- X**
- X-ray dosimetry, 70, 70*t*
- Y**
- Yankauer suction tip, 22
 - Yeast infections, 199
- Z**
- Zavanelli maneuver in shoulder dystocia, 397
 - Zeppelin tissue clamp, 21, 21*f*

akusher-lib.ru