

Musculoskeletal Health in Pregnancy and Postpartum

An Evidence-Based Guide
for Clinicians

Colleen M. Fitzgerald
Neil A. Segal
Editors

 Springer

Colleen M. Fitzgerald • Neil A. Segal
Editors

Musculoskeletal Health in Pregnancy and Postpartum

An Evidence-Based Guide for Clinicians



Springer

Editors

Colleen M. Fitzgerald
Department of Obstetrics and Gynecology
Loyola University
Maywood, IL, USA

Neil A. Segal
Department of Rehabilitation Medicine
University of Kansas
Kansas City, KS, USA

ISBN 978-3-319-14318-7 ISBN 978-3-319-14319-4 (eBook)
DOI 10.1007/978-3-319-14319-4

Library of Congress Control Number: 2015934587

Springer Cham Heidelberg New York Dordrecht London
© Springer International Publishing Switzerland 2015

This work is subject to copyright. All rights are reserved by the Publisher, whether the whole or part of the material is concerned, specifically the rights of translation, reprinting, reuse of illustrations, recitation, broadcasting, reproduction on microfilms or in any other physical way, and transmission or information storage and retrieval, electronic adaptation, computer software, or by similar or dissimilar methodology now known or hereafter developed.

The use of general descriptive names, registered names, trademarks, service marks, etc. in this publication does not imply, even in the absence of a specific statement, that such names are exempt from the relevant protective laws and regulations and therefore free for general use.

The publisher, the authors and the editors are safe to assume that the advice and information in this book are believed to be true and accurate at the date of publication. Neither the publisher nor the authors or the editors give a warranty, express or implied, with respect to the material contained herein or for any errors or omissions that may have been made.

Printed on acid-free paper

Springer International Publishing AG Switzerland is part of Springer Science+Business Media
(www.springer.com)

Preface

Pregnancy is an absolutely miraculous ride that forever alters a woman's life. Ask anyone who has carried a pregnancy or their partners. It is transformative and wondrous, can be easy or difficult, or can be novel or old hat, but inarguably memorable. There is nothing more powerful in the study of medicine than the natural process of the generation of life and the physical experience of pregnancy and the postpartum state. Because the life moment of pregnancy is so common, glorious, and shared, many of the hardships that accompany it get lost in the periphery. Women hear stories, witness friends and family, and relegate the words of advice surrounding it to dogma. Motherhood starts here. The expectation is that this tremendous rite of passage brings with it pain and bodily change coupled with joy.

But what is common is not necessarily healthy. The dynamic musculoskeletal changes that accompany pregnancy and the postpartum state are just beginning to be recognized and understood. For many women who develop chronic musculoskeletal pain, the mechanism of injury often starts during the gravid phase, delivery, or postdelivery. Thus, there is a great need for protecting the body during this vulnerable period, in order to spare women from a variety of pathologies that can lead to pain, functional limitations, and reduced quality of life following their reproductive years.

Our goal in writing and editing this book, filled with the expertise of specialists in the field, is to make existing evidence available to clinical practitioners and advance the knowledge of pregnancy-related musculoskeletal medicine. We highlight the work of those who have investigated its significance and provide practical advice to those who care for pregnant/postpartum women. As physicians, clinical researchers, and parents, we hope that this text stimulates discussion regarding an often overlooked clinical area: musculoskeletal health in pregnancy and postpartum. So many women who suffer with treatable pain during pregnancy are told by their clinical providers to just tolerate it until delivery, in hopes that it may spontaneously resolve. In addition, many women are not provided with

advice during pregnancy or delivery that could potentially reduce their risk for development of chronic disabling conditions. Our personal goal is not only to share the current evidence but also to shape the science upon which better care can be provided to mothers.

Maywood, IL, USA
Kansas City, KS, USA
2014

Colleen M. Fitzgerald, MD, MS
Neil A. Segal, MD, MS

akusher-lib.ru

Contents

1 Musculoskeletal Anatomic, Gait, and Balance Changes in Pregnancy and Risk for Falls.....	1
Neil A. Segal and Stacey R. Chu	
2 Hormonal Influence on the Neuromusculoskeletal System in Pregnancy.....	19
Maria E. Reese and Ellen Casey	
3 Musculoskeletal Imaging in the Pregnant and Postpartum Patient.....	41
Catherine J. Brandon	
4 Diagnosis of Pelvic Girdle Pain.....	69
Jaelyn H. Bonder and Laura Fitzpatrick	
5 Treatment, Bracing, and Modalities in Pelvic Girdle Pain.....	81
Danielle Sarno and Farah Hameed	
6 Neural Injury During Pregnancy and Childbirth.....	93
Kelly M. Scott	
7 Interventional Procedures for Musculoskeletal Pain in Pregnancy and Postpartum: Efficacy and Safety.....	115
Christopher T. Plastaras and Malathy Appasamy	
8 Hip Disorders in Pregnancy.....	135
Monica Rho, Fariba Shah, and Eziamaka Okafor	
9 Upper Limb Issues in Pregnancy and Postpartum: Carpal Tunnel Syndrome and DeQuervain’s Tenosynovitis.....	159
Kim M. Stein, Joanne Borg-Stein, and Lindsay N. Ramey	

10 Labor and Delivery Considerations: Pubic Symphysis Separation, Fractures Associated with Transient Osteoporosis of Pregnancy, Sacral Stress Fractures, and Coccydynia/Coccyx Fracture	171
Sarah K. Hwang	
11 Pelvic Floor Injury and Consequences	181
Cynthia A. Brincat	
12 Pelvic Floor Myofascial Pain and Dysfunction	193
Sarah M. Eickmeyer and Dana Seslija	
13 Pelvic Pain After Cesarean Section	209
Allison Bailey	
14 Pharmacological Treatment of Musculoskeletal Conditions During Pregnancy and Lactation	227
Joong Kim and Mary F. Hébert	
15 Exercise in Pregnancy and Postpartum	243
Kate E. Temme	
Epilogue: Where to Go from Here ... Future Research	275
Index	279

Contributors

Malathy Appasamy, MD Department of Physical Medicine and Rehabilitation, University of Pennsylvania, Philadelphia, PA, USA

Allison Bailey, MD Integrated Health and Fitness Associates, Cambridge, MA, USA
Harvard Medical School, Cambridge, MA, USA

Department of Medline, Mount Auburn Hospital, Cambridge, MA, USA

Jaclyn H. Bonder, MD Department of Rehabilitation Medicine, Weill Cornell Medical College—New York Presbyterian, New York, NY, USA

Joanne Borg-Stein, MD Department of Physical Medicine and Rehabilitation, Spaulding Rehabilitation Hospital, Wellesley, MA, USA

Catherine J. Brandon, MD, MS Department of Radiology, University of Michigan, Ann Arbor, MI, USA

Cynthia A. Brincat, MD, PhD Department of Urology and Obstetrics/Gynecology, Loyola University Chicago, Stritch School of Medicine, Maywood, IL, USA

Ellen Casey, MD Department of Family, Community and Preventive Medicine, Sports Medicine Fellowship, College of Medicine, Drexel University, Philadelphia, PA, USA

Stacey R. Chu, BS Roy J. and Lucille A. Carver College of Medicine, University of Iowa Hospitals and Clinics, Iowa City, IA, USA

Sarah M. Eickmeyer, MD Physical Medicine and Rehabilitation, The University of Kansas Medical Center, Kansas City, KS, USA

Laura Fitzpatrick, AB Rehabilitation Medicine, Weill Cornell Medical College—New York Presbyterian, New York, NY, USA

Farah Hameed, MD Department of Rehabilitation and Regenerative Medicine, Columbia University Medical Center, New York, NY, USA

Mary F. Hébert, PharmD, FCCP Department of Pharmacy, University of Washington, Seattle, WA, USA

Sarah K. Hwang, MD Department of Physical Medicine and Rehabilitation, University of Missouri, Columbia, MO, USA

Joong Kim, PharmD Department of Pharmacy, University of Washington Medical Center, Seattle, WA, USA

Eziamaka Okafor, MD Rehabilitation Institute of Chicago, Chicago, IL, USA

Christopher T. Plastaras, MD Department of Physical Medicine and Rehabilitation, University of Pennsylvania, Philadelphia, PA, USA

Lindsay N. Ramey, MD Department of Physical Medicine and Rehabilitation, Spaulding Rehabilitation Hospital, Harvard Medical School, Charlestown, MA, USA

Maria E. Reese, MA, MD Spine and Sports Medicine, Physical Medicine and Rehabilitation, Northwestern University Feinberg School of Medicine/Rehabilitation Institute of Chicago, Chicago, IL, USA

Monica Rho, MD Rehabilitation Institute of Chicago, Chicago, IL, USA

Danielle Sarno, MD Department of Rehabilitation Medicine, New York-Presbyterian/Columbia and Cornell University Medical Centers, New York, NY, USA

Kelly M. Scott, MD Department of Physical Medicine and Rehabilitation, UT Southwestern Medical Center, Dallas, TX, USA

Neil A. Segal, MD, MS Department of Rehabilitation Medicine, University of Kansas, Kansas City, KS, USA

Dana Seslija, MD Physical Medicine and Rehabilitation, Medical College of Wisconsin Affiliated Hospitals, Clement J. Zablocki VA Medical Center, Milwaukee, WI, USA

Fariba Shah, MD Spine & Sports Medicine, Physical Medicine & Rehabilitation, Banner Good Samaritan Rehabilitation Institute, Phoenix, AZ, USA

Kim M. Stein, MD Department of Family Medicine, University of Virginia, Charlottesville, VA, USA

Britt Stuge, PhD Department of Orthopaedics, Oslo University Hospital, Oslo, Norway

Kate E. Temme, MD Department of Physical Medicine and Rehabilitation, Sports Medicine and Women's Health, University of Pennsylvania, Philadelphia, PA, USA

Department of Orthopaedic Surgery, University of Pennsylvania, Sports Medicine Center, Philadelphia, PA, USA

Abbreviations

ALARA	As low as reasonably achievable
AP	Anterior-to-posterior
ASIS	Anterior superior iliac spine
ASLR	Active Straight Leg Raise
BMD	Bone mineral density
CPP	Chronic pelvic pain
CT	Computed tomography
EMG	Electromyography
ICS	International Continence Society
LBP	Low back pain
LDL test	Long dorsal ligament test
MRI	Magnetic resonance imaging
MSK	Musculoskeletal
P4 test	Posterior pelvic pain provocation test
PFM	Pelvic floor muscles
PGP	Pelvic girdle pain
PSIS	Posterior superior iliac spine
PT	Physical therapy or therapist
SI	Sacroiliac
SIJ	Sacroiliac joint
SNRI	Serotonin norepinephrine reuptake inhibitors
STIR	Short tau inversion recovery
T1	T1-weighted: MRI sequence which is predominately used for anatomy
T2	T2-weighted: MRI sequence with high intensity fluid signal
TOP	Transient osteoporosis of pregnancy
US	Ultrasound

Chapter 1

Musculoskeletal Anatomic, Gait, and Balance Changes in Pregnancy and Risk for Falls

Neil A. Segal and Stacey R. Chu

Introduction

Musculoskeletal disorders are common during pregnancy and the postpartum period. These disorders can range from mild aches to disabling low back or pelvic pain, carpal tunnel syndrome, or osteoporosis and osteonecrosis of the femoral heads. Many of these clinically significant changes in women's health are poorly understood, and opportunities for prevention, diagnosis, and treatment are often missed. Even when musculoskeletal pathology or impairments are recognized, a lack of understanding sometimes leads to treatment avoidance by providers who hope that symptoms will spontaneously resolve in the postpartum period. Missed opportunities for appropriate musculoskeletal care during pregnancy can increase the risk for cesarean delivery [1, 2] and may affect the long-term health of both mother and child. Pain is not only an issue of maternal comfort, but also can contribute to future health risks. The resultant reduction in physical activity during pregnancy leads to maternal and child obesity and increased risk of gestational diabetes and preeclampsia [3–7]. Thus “benign neglect” [8] can result in prolonged suffering and participation restrictions in pregnant women in addition to causing undesirable longstanding health effects on both mother and child.

N.A. Segal, MD, MS (✉)

Department of Rehabilitation Medicine, University of Kansas, Rainbow Boulevard,
Mailstop 1046 3901, Kansas City, KS 66160, USA
e-mail: nsegal@kumc.edu

S.R. Chu, BS

Roy J. and Lucille A. Carver College of Medicine,
University of Iowa Hospitals and Clinics, Iowa City, IA, USA
e-mail: stacey-chu@uiowa.edu

To advance the science and knowledge of musculoskeletal care during pregnancy, this book includes chapters focused on diagnosis and treatment of commonly encountered musculoskeletal complaints during pregnancy and the postpartum period. This initial chapter provides a fundamental description of the anatomic changes that occur during pregnancy and describes how these changes affect balance, gait, and risk for falls during pregnancy as well as the long-term health of women even into their post-reproductive years.

Anatomic Changes During Pregnancy

There are numerous hormonal and biomechanical changes that occur during pregnancy. The musculoskeletal system is confronted with the effects of the enlarging gravid uterus, which anteriorly displaces the center of mass [9] and lengthens the moment arm of the pelvic stabilizers (Fig. 1.1). This increases stress on the passive and active stabilizers of the pelvic girdle [10] and spinal structures. Additionally, there are changes in body habitus and ligamentous laxity possibly related to alterations of the hormonal milieu in the context of hosting a developing fetus and preparing for parturition [11, 12]. These changes can contribute to painful axial and appendicular musculoskeletal complaints by either compressing or loosening joints and may also increase risk for injuries.

The most noticeable alteration in the body is the approximately 10–15 kg increase in body mass due to the enlarged uterus and breasts. This increase in and anterior displacement of the center of mass may magnify joint forces by as much as 100 % [10]. The effects of these increased joint loads are compounded by an increase in the laxity of passive restraints in the pelvis, feet, and other joints. Together, these factors

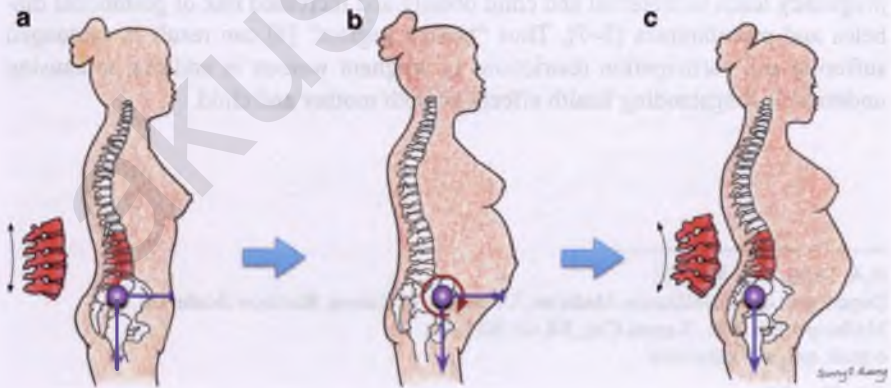


Fig. 1.1 Postural adaptations to altered center of mass: (a) normal posture; (b) anterior displacement of the center of mass lengthens the moment arm of pelvic stabilizers and increases anterior torque at the hip; (c) a compensatory increase in the lumbar lordosis shifts the center of mass back to the neutral position over or slightly posterior to the hip joint center to restore sagittal stability

may contribute to joint pain, reduce coordination, and increase injury risk. This is particularly the case for women who have ligamentous laxity that predates pregnancy such as those with hypermobility syndrome or collagen disorders such as Ehlers–Danlos.

Changes in Spinal Posture

To accommodate the expanding uterus while also preserving pulmonary function, the rib cage expands laterally by 10–15 cm. This increased chest circumference is accompanied by an increase in the subcostal angle and stretching of the abdominal and intercostal muscles. These changes can be associated with complaints of rib or costochondral pain during pregnancy.

There are also changes in the spinal curvatures as well as in the structure and functional capacity of the muscular and ligamentous spinal stabilizers during pregnancy. Some of the most notable changes include a cervical kyphosis, an exaggerated thoracic kyphosis due to increased breast tissue and an increased lumbar lordosis [13]. These skeletal changes are associated with overstretching of the rhomboid and other upper back muscles in the context of increased kyphosis and ligamentous laxity, which reduces spine stability [14]. The pectoral muscles shorten in response to these postural changes, exacerbating depression and rounding of the shoulders.

Conversely, in the lumbar region the expanding uterus and the resulting lordosis cause stretching of the abdominal muscles and compensatory shortening of the paraspinal muscles. Greater laxity of the anterior and posterior longitudinal ligaments of the spine, in the context of the impaired tension in the anterior abdominal core musculature, contributes to impaired spinal stability and can strain the muscular spinal stabilizers (Fig. 1.2). A measureable increase in lumbar lordosis has been reported when the uterus reaches approximately 40 % of full-term mass.

Given the high prevalence of low back pain in pregnancy, there has been great interest in the mechanism for the development of the exaggerated lumbar lordosis. One possible mechanism relates to the approximately 6–7 kg increase in abdominal mass displacing the center of mass anteriorly, thereby increasing anterior torque at the hip joints by eightfold (Fig. 1.1) [15, 16]. As humans are bipedal, this increased anterior torque needs to be counteracted by recruitment of paraspinal muscles to stabilize posture [16, 17]. Thus, as uterine mass increases and anterior and inferior core ligaments and muscles stretch, there is progressive activation of the lumbar paraspinal muscles to maintain sagittal plane stability, enhancing the lumbar lordosis.

While there is not a substantial increase in hip extension during pregnancy ($6^\circ \pm 2^\circ$), extension of the lumbar spine has been reported to be $18^\circ \pm 10^\circ$ at full-term [16]. The degree of self-selected lumbar lordosis is finely tuned to maintain antero-posterior position of the center of mass within a very narrow range at term (3.2 ± 0.7 cm). The spinal compensation for the increasing mass and size of the uterus increases both force and lever arm (Fig. 1.1), increasing zygapophyseal facet joint shear stress by as much as 60 % [16].

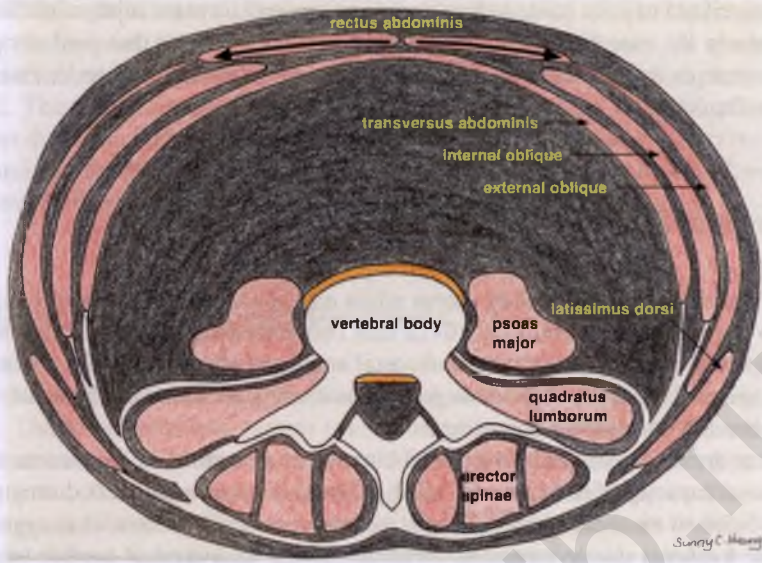


Fig. 1.2 Exaggerated lumbar lordosis with increased tension in posterior core muscles, along with stretching of the anterior abdominal core muscles (*arrows*) and laxity of the anterior and posterior longitudinal ligaments (*depicted in orange*) reduces spinal stability

Changes in Abdominal Musculature

Along with the increased posterior muscular demands and abdominal mass effect, the hormonal milieu increases the flexibility of the transversus abdominis, abdominal oblique, and rectus abdominis muscles. The linea alba stretches and muscle fibers separate in a significant proportion of women [18, 19]. The degree of separation of the rectus abdominis and increase in width of the linea alba that meets criteria for diastasis recti abdominis has been variably defined as 2–4 cm. Diastasis recti is rare in the first trimester and may begin in the second trimester, but incidence typically peaks during the third trimester [18, 19]. There is a mean separation of 3.4 cm at 30 weeks gestation, and further separation by 38 weeks gestation, associated with impaired pelvic stabilization [19]. There is insufficient evidence regarding the epidemiology of diastasis recti, so the degree to which potential risk factors contribute to incidence (e.g., greater age, multiparity, gestational size, obesity) is incompletely understood. Importantly, the effects of rectus abdominis fiber separation from the usual vertical orientation include weakness due to the increased muscle length and functional limitations in posture, multiplanar trunk stabilization, and respiration [18].

Residual Changes in Muscle Balance Following Pregnancy

Upon delivery, there is a sudden reduction in stretch of the anterior abdominal musculature. Despite this reduction, abdominal muscle fibers remain in an elongated state, which contributes to continued weakness, by reducing capacity of muscle fibers to generate force [19]. The duration of this impairment may be related to the prepartum and intrapartum conditions of abdominal musculature as well as to the magnitude of the tension placed on the muscles during the intrapartum and postpartum periods. In addition, the duration of Valsalva maneuver during the active pushing phase of delivery has been observed to relate to the severity of muscular impairment. Additional research is necessary to clarify this potential association, particularly in primiparous women.

To maximize spinal health, the imbalance between strengthened lumbar paraspinal extensor muscles and weakened anterior abdominal muscles that persists postpartum should be considered [20]. To correct this imbalance, exercises should be prescribed while considering additional residual deficits. In cases of diastasis recti abdominis, a residual muscle separation at 8 weeks postpartum has been associated with a persistent impairment in the ability to stabilize the pelvis against resistance [19]. During the postpartum period, women with a residual impairment in rectus abdominis functional capacity should avoid abdominal exercises that require high levels of force generation (such as aggressive sit-ups) and should instead focus on enhancing control of the pelvis (e.g., breathing exercises to control the abdomen, with progression to breathing exercises in more challenging positions). It is important that underlying muscle impairments and anatomical impairments be addressed prior to initiation of resistance exercises.

Changes in the Pelvis

Anterior pelvic tilt increases during pregnancy to compensate for an increased and anteriorly displaced body mass as well as to enable greater lung capacity, offsetting the expanding mass below the diaphragm. This increased anterior pelvic tilt necessitates greater dependence on the hip extensor and abductor muscles as well as the ankle plantar flexor muscles to avoid falling forward [8]. In addition to this change in pelvic position, there are several important changes that occur within the segments of the pelvis.

A combination of hormonal and biomechanical factors acts to compromise pelvic girdle stability. The pubic symphysis and sacroiliac joints, which are typically stable, widen in preparation for delivery, and the increased motion that results can contribute to pain during and following pregnancy. The pubic symphysis begins to widen between weeks 10–12 of pregnancy. While the joint width is normally 3–5 mm, it can become 5–8 mm during pregnancy [21]. Widths above 10 mm are considered to be pathological [22].

This rise in pelvic joint laxity has been hypothesized to increase the risk for pathological processes. However, to date, there has not been sufficient evidence that supports this elevated risk. The lack of evidence could relate to a reduction in physical activity later in pregnancy, when joint laxity is the greatest. It is also possible that the degree of joint laxity may be of an insufficient magnitude to predispose to injury. Thus, the lack of association could relate to either reduced exposure to injury or lower levels of laxity mitigating risk for injury [23].

Evidence suggests that the joints of the pelvis return to their prepregnancy state by 4–12 weeks postpartum (average of 6 weeks), and pelvic pain resolves by 3 weeks postpartum in a majority of women (75 % by 3 weeks and 89 % by 12 weeks) [24]. However, while the pelvic joints may return to their prior state within weeks, the abdominal and pelvic floor musculature, which is significantly stretched and sometimes torn during pregnancy and vaginal delivery, may require additional time to return to its prepregnancy state and may not be achieved without directed exercises.

Changes in the Lower Limbs During Pregnancy

The lower limbs undergo many changes during pregnancy. While each lower limb segment can be examined individually, it is important to realize that the segments of the lower limbs work as an integrated unit—each segment adapting to others in the kinetic chain. Changes to the hips, knees, and feet occur to either enhance postural stability [25], or as a result of hormonal and anatomic changes [26, 27].

While the feet may adequately support and distribute body weight prior to carrying pregnancies, alterations during pregnancy can disrupt these supportive structures. Ligamentous laxity increases during pregnancy, which results in reduction in height of the longitudinal and transverse arches [28]. In addition, women with lower arches prior to pregnancy may experience worsening pes planus [29]. Arch drop and the resultant excessive pronation [29] of the feet may alter loading patterns throughout the lower limbs. A 1 cm lowering of the talar head causes foot pronation and increases lateral foot pressure [30]. As the foot pronates, internal tibial rotation causes patellar maltracking as well as anterior pelvic tilt (Fig. 1.3). Even 2° or 3° of foot pronation have been found to increase anterior pelvic tilt during gait by as much as 50–75 % [31].

As the joint just proximal to the foot and distal to the pelvis, the effects of rearfoot pronation and pelvic tilt are conveyed most directly to the knee. In addition to compensating for changes in biomechanics at adjacent joints, the knees must provide stability and support to the body while also enabling mobility. To achieve this, the knees rely heavily on ligamentous support. Because of this dependence on ligamentous restraints, the knees are susceptible to deformation during pregnancy. As the center of mass shifts anteriorly with increasing uterine mass, the knees must compensate to aid in maintenance of upright posture. This is achieved by hyperextension [32] that may progress to genu recurvatum. The hips also adapt to maintain

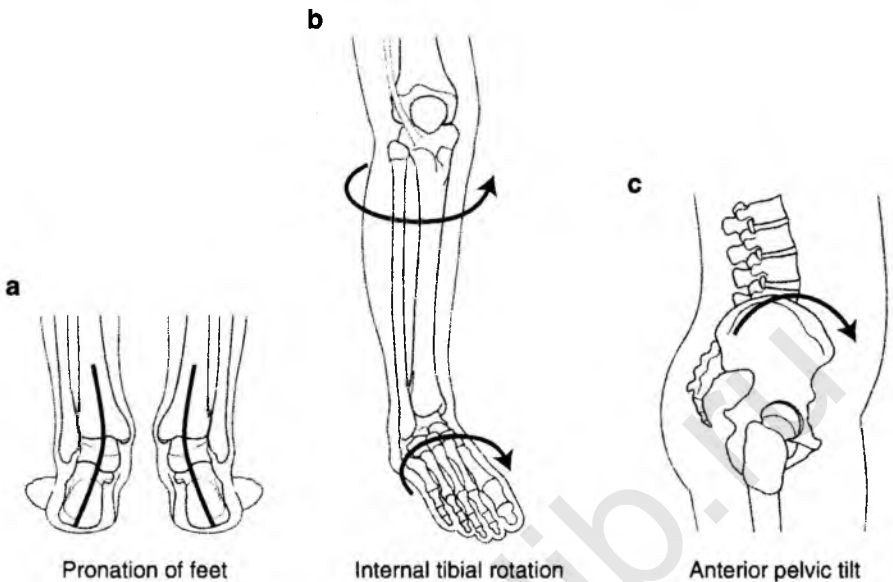


Fig. 1.3 Alterations in the feet during pregnancy and the potential effects of these changes on the lower limb kinetic chain: (a) foot pronation due to loss of longitudinal and transverse arch height; (b) foot pronation internally rotates the tibia, stretching of the knee ligamentous supports and the iliotibial band; (c) anterior tilt of the pelvis compensating for both the internal rotation distally and the need to reduce the hip flexion moment arm by moving the center of mass closer to the hip axis

upright posture. Postural changes, weight increase, and ligamentous laxity can contribute to knee pain during the second half of pregnancy [33].

Due to the effects of rearfoot pronation on the knees and iliotibial bands, along with changes in the pelvis and center of mass, the hips must adapt during pregnancy. To adjust for increasing abdominal mass and an anteriorly shifted center-of-mass, the hips must redistribute weight to increase stability. To accomplish this, the pelvis tilts anteriorly and the femoral heads rotate externally, both of which aid in widening of the base of support. Hip abductor and hip extensor muscle action also increase during pregnancy [8], though pelvic motion is variable depending on the task performed [34]. These changes return to prepregnancy values by 4–12 weeks postpartum [24].

Residual Anatomic Changes Following Pregnancy

Following pregnancy, there is a persistent loss of arch height as a result of ligamentous laxity that also lengthens and widens the feet [28]. Segal et al. conducted a study of 49 women, in which static and dynamic measurements of arch length, width, and function were completed during first trimester and approximately

5 months postpartum [28]. Both arch height and rigidity index (a ratio of standing to seated arch height) significantly decreased, while foot length increased. Primiparous women demonstrated the greatest reduction in arch rigidity along with the greatest arch drop and increase in foot length. However, no changes in the dynamic function of the arch (the center of pressure excursion index) were detected in the sample studied [28]. Thus, pregnancy appears to be associated with a lasting loss of arch height and increase in foot length, with the first pregnancy possibly resulting in the greatest change.

The contribution of these changes to the increased risk for musculoskeletal disorders in women is currently unknown. However, the loss of arch height could have potential clinical significance. In cross-sectional studies, planus foot morphology has been associated with increased odds of ipsilateral knee pain and medial tibiofemoral cartilage damage, with a dose effect as arch height decreases [35]. Though residual changes to the knees following pregnancy are still unclear, it is known that the risk for total knee replacement increases 8 % per delivery [36]. Compared to nulliparous women, the relative risk for total knee replacement for parous women is 2.4 [37]. Knee laxity may partially resolve by 4 months postpartum [33]. However, currently it is unclear whether the elevated risk for total knee replacement is influenced by knee joint laxity. Studies currently underway may reveal the degree to which changes in the feet alter articular contact stress at more proximal joints in the kinetic chain, such as the knees, hips, and spine, as well as whether footwear modifications may prevent these changes to the feet with pregnancy.

For axial and pelvic changes, some adaptations may not completely resolve in the early postpartum period [19, 38], though the uterus returns to its prior nonpregnant size and hormone levels return to normal. Increased magnitude of loads lifted as well as increased frequency and duration of carrying and stooping tasks in the immediate postpartum period may affect the musculoskeletal system, contributing to delayed resolution of certain adaptations.

There also are residual impairments in strength, tone, and endurance of the anterior abdominal [19] and low back muscles at 8 weeks postpartum [39], which may account for residual changes in standing posture during the early postpartum period [34]. If women return to standing work, the environment should be modified to accommodate residual impairments in standing posture during the early postpartum period, so that upright posture can be maintained with more ease despite reduced ability to maintain spinal curvatures.

Changes in Bone Mineralization

A number of factors influence the processes of bone turnover and bone mineralization during pregnancy and the postpartum period. While the relative influences of these factors are incompletely understood, it is clear that there is a maternal need for calcium while nourishing a fetus in utero as well as when breastfeeding an infant.

Studies have reported increases, decreases, and lack of change in bone mineral content during and following pregnancy [40–44]. There are likely several reasons for the inconsistent findings including the potential of cross-sectional designs being less sensitive than longitudinal designs in detecting within-subject variability in comparison with between-subject variability, the inability to use radiographic measures of bone mineral content during pregnancy, the site of measurement of bone mineral density (BMD), and differing subject characteristics (e.g., age, timing of study, race, nutritional factors, etc.). The most recent longitudinal study of bone mass during pregnancy and the puerperium simultaneously measured markers of bone turnover, to provide additional metabolic context in which BMD findings during pregnancy and lactation can be interpreted [45].

Although weight gain and the increased loading forces on bones that result would be expected to have a positive effect on bone mineralization, the calcium requirements of the developing fetus seem to negate this effect and BMD decreases with pregnancy [44]. Notably, in this study of 18, well-nourished healthy women, the 7 who breast-fed their infants for at least 6 months did not demonstrate any loss of bone mass [44].

Gait

As described in the prior sections, changes to the body during pregnancy include anterior displacement of the center of mass, with posterior inclination of the thoracic spine, anterior tilt of the pelvis, increased lumbar lordosis, knee hyperextension, and lowering of the longitudinal arch with increased length and width of the feet. In addition to these static changes, there are also alterations in both the angular kinematics and spatiotemporal parameters of gait during pregnancy, which could contribute to muscle fatigue and pain.

There is increased use of hip extensor, hip abductor, and plantar flexor muscles in pregnant women as they attempt to maintain normal stride length, cadence, and joint angles despite an increased body mass as well as an altered body-mass distribution [8]. Further, these elevated lower limb joint moments (e.g., stance phase hip abduction moment) and joint powers during walking occur without concomitant changes in kinematic parameters (joint range of motion, velocity, and acceleration) during third trimester [8]. Foti suggested that overuse of these muscle groups may be contributing factors to the development of low back and pelvic pain as well as calf cramping and other lower limb overload injuries during pregnancy, particularly in women who have lower levels of muscle fitness prior to pregnancy [8].

Despite attempts to maintain their usual gait patterns, the stride length of pregnant women decreases between the second and third trimesters [46]. The primary contributor to this change is a greater lower trunk inertia restricting trunk rotation in the transverse plane [20]. In the third trimester, stance phase time is increased along with step width [20, 47, 48]. In addition to the increased stance phase time on each leg, the double support phase, in which body weight is distributed to both legs, is

increased. This increased time in double support may be a compensation for the increased hip abductor muscle power required during single-limb support during pregnancy [8, 46].

Widened step width, which resolves by 8 weeks postpartum [20, 49], may relate to increased pelvic width or to redistribution of body mass, but this is currently unclear [8]. In either case, increased step width during pregnancy contributes to greater lateral displacement of the center of mass—a gait pattern sometimes characterized as “waddling” [8, 20, 48], though this has not been detected in all studies of pregnant gait. Large interindividual heterogeneity in gait characteristics has been reported [50]. This heterogeneity may relate to the inclusion of women in both the second and third trimesters in a single group, despite the significant differences in the body habitus and trunk segment inertias [50], or may relate to the small sample sizes (≤ 12 women) in most of these studies.

When present, the waddling gait pattern requires higher hip abduction moments to control the greater side-to-side motion and it has been suggested that these increases may contribute to the decreased coronal plane pelvic drop observed during swing phase in some women [20]. The widened base of support and step width has been thought to be a compensation directed at improving mediolateral stability during stance and gait [8, 48, 49]. However, despite the widened base of support, achieved by external rotation of the feet, pregnant women exhibit greater mediolateral sway and greater oscillation of the center of mass.

At the feet, rearfoot and midfoot pronation increase while plantar flexion angles [51] and propulsion [52] decrease. Studies examining plantar load redistribution including aspects of forefoot and rearfoot loading have produced differing results. Nyska determined that the center of pressure moves laterally, with contact time and peak pressures on the medial forefoot decreasing in third trimester [30]. These stance phase findings were confirmed by Lymbery et al. who found that increased pressure on lateral and hindfoot occurs due to a lateral shift in the center of pressure during stance phase [30, 49]. This shift in the center of pressure has not been associated with changes in the magnitude of the ground reaction force during gait, after adjusting for body mass and gait velocity [49, 53].

In fact, the reduction in gait velocity in pregnant women during third trimester (1.29 ± 0.13 m/s during third trimester vs. 1.33 ± 0.16 m/s during second trimester and 1.47 ± 0.16 m/s in nonpregnant control participants) [53], may be a successful compensatory mechanism aimed at avoiding increases in ground reaction forces and momentum. Although kinematic characteristics of gait during pregnancy have not been consistently found to differ from the nonpregnant state [8, 48, 49], a relatively consistent finding has been a reduced gait velocity [50]. Walking at a gait velocity less than that of comfortable gait requires higher energy, supporting the likelihood that it is a compensatory mechanism to avoid increases in momentum in the context of a larger abdominal and pelvic mass and allow greater time to respond to perturbations of balance [50]. In summary, with the exception of a reduced gait velocity, detected in most [49, 50, 53] but not all [49] studies, there may not be consistent differences in gait parameters between nulliparous and third trimester pregnant women.

Residual Changes in Gait Following Pregnancy

Few studies have examined whether there are residual changes in gait characteristics that persist into the postpartum period. At 8 weeks postpartum, after body mass and center of mass have returned to the nonpregnant state, there is a greater percentage of the gait cycle spent in double-limb stance in comparison with nulliparous women. Step width during gait also may remain increased at 8 weeks postpartum [46, 49], although this finding has not been found in all studies [20]. There may also be alterations in pelvic and spinal range of motion, which remain altered 8 weeks postpartum [20]. For sit-to-stand tasks, kinetic and kinematic changes that occur during pregnancy appear to return to the range measured for nulliparous women by 8 weeks postpartum [54]. Thus, additional study is necessary to reconcile differences in findings to date.

Balance

Initiating Locomotion

The first step in locomotion is the transition from laying to sitting. Changes in the body during pregnancy can make this transition difficult. Excessive lumbar lordosis, anteriorly shifted center of mass, stretched and weakened abdominal wall structures with possible diastasis recti, tight hip flexors, and pelvic girdle pain all contribute to impaired activation of abdominal muscles in transitioning from laying to sitting, and to a lesser extent from sitting to standing. Due to this difficulty, it is recommended that pregnant women log roll (turning with head, torso and lower extremities aligned and moving together) and push with their arms as they sit from a side lying position.

Standing from a chair requires that support from the seating surface be fully transferred to the lower limbs, requiring elevation and anterior movement of the body mass. Transition from sitting to standing is affected by anatomic changes that occur during pregnancy, which include the mass effect of the gravid uterus and weakening of the abdominal wall. Late in pregnancy, there is an increased time required to stand from a seated position, with concomitant reductions in hip joint flexion angle and hip joint flexion velocity at seat-off [54].

Gilleard et al. studied the kinematics and kinetics of sit-to-stand from gestational week 18 to 8 weeks postpartum. During second trimester, the kinematics and kinetics of sit-to-stand in pregnant women were similar to nulliparous women, but changes were observed in the pregnant subjects at weeks 32 and 38 that were consistent with compensatory strategies for overcoming impairments in range of motion and balance [54]. Specifically, width between the feet increased progressively with pregnancy, most likely serving to increase side-to-side stability during sit-to-stand. The increase in medial ground reaction force, out of proportion to the increased

body mass also reflects a strategy to enhance mediolateral stability [25, 54]. Widened stance when rising also serves to widen the space between the knees, reducing contact between the abdomen and thighs during trunk flexion when preparing to transition from sitting to standing.

There are several implications of the alterations in sit-to-stand strategy during pregnancy. Pregnant women in the workplace require sufficient space to accommodate their widened stance and need for safe flexion in the context of increased anterior abdominal girth. Chairs should also be of an appropriate size and width to permit the increased foot and knee width necessary for safe transition from sitting to standing (e.g., chair arms that do not permit appropriate lower limb placement could reduce balance upon sit-to-stand).

Gilleard et al. observed a reduction in hip extension velocity and a delay in onset of the vertical ground reaction force [54], factors that reduced momentum on rising. Rather than indicating difficulty with standing, this reduction in momentum could indicate a compensatory strategy to reduce risk of retropulsion in the context of increased abdominal mass. The tendency to minimize propulsion with movement during pregnancy has been reported by other investigators as well [55]. Finally, to obtain sufficient flexor momentum to rise from the chair while compensating for reduced pelvic motion (due to contact between the enlarged abdomen and thighs), gravid subjects demonstrate increased cervicothoracic flexion range of motion in comparison with nulliparous women. Anticipation of these needs should be considered in arranging the work environment of pregnant women to avoid injury upon standing (e.g., placement of lamps, computer displays, etc.). In addition, pregnant women should be cautioned to reach a stable standing posture following rising from a chair before initiating gait, in order to reduce risk of falls due to postural unsteadiness [55].

Control of Balance

A widened stance is generally preferred during pregnancy [25], to increase the base of support [8, 48, 49]. This widened stance width improves balance and reduces side-to-side postural sway [56]. Jang prospectively assessed balance at 4-week intervals during pregnancy as well as at 6, 12, and 24 weeks postpartum, reporting that pregnant subjects perceived worsening of their balance as pregnancy progressed and that this impairment did not resolve by 6 weeks postpartum [57]. The perception of balance also significantly differed between pregnant and control subjects over the period between 20-week gestation through delivery [57]. Despite a widened stance width, these subjective reports were corroborated by objective measurements of impaired balance in the radial and anteroposterior directions, with incomplete resolution up to 8 weeks postpartum. The persistence of impaired balance in the postpartum period could potentially relate to continued lateral sway despite a correction of the standing width back to normal [57].

Postural changes could be caused by factors including uterine enlargement, weight gain, anterior and superior shift in the center of mass, skeletal changes, ligament and soft tissue laxity and hormonal changes, including increases in relaxin and estrogen. Butler et al. reported that postural sway increases during the second and third trimesters of pregnancy, with a higher rate of pregnant subjects reporting falls in comparison with nonpregnant control subjects [58]. The reduction in postural sway during the third trimester in comparison with the second trimester [59] may reflect more careful or restricted movement.

To advance understanding of balance during pregnancy, there is a need for further study of the roles of constrained stance width in altering sway and perceived balance impairment, the role of foot sensation, lower limb joint range of motion, dependent swelling, and altered neuromuscular function. In addition, assessment of balance in the home and community environment, rather than in the laboratory, could provide valuable insights into the effects of pregnancy on physical function.

Falls

Falls during pregnancy can precipitate fractures, injuries to joints and muscles, damage to intracranial and intra-abdominal structures, placental abruption, rupture of membranes or uterine rupture, and death of the fetus or the gravida [60]. Of these injuries, lower limb fractures are the most common injury suffered by pregnant women following falls [61].

In retrospective studies, roughly one in four [58, 62] pregnant women reported suffering falls, with 10 % suffering two or more falls [62, 63], making falls one the leading precipitating factors for emergency treatment visits during pregnancy. The majority of working women fall between months 5 and 7 of pregnancy, and the majority of falls occur indoors with 39 % of falls occurring on stairs [64]. Risk factors for falls at work include working in a loud environment, performing shift work, and having less control over one's schedule. In addition to these risk factors at work, risk factors for falls at home include the presence of toddlers and the absence of a permanent partner [62]. A limitation inherent to retrospective studies is recall bias—the need for postpartum women to recall falls that occurred during pregnancy. In Jang's prospective study of falls and balance, only 2 out of 15 pregnant women (13 %) reported falls [57]. Thus, there is a need for prospective studies to minimize bias in estimating the incidence of falls during pregnancy.

Fall incidence decreases during third trimester despite the persistence of factors that reduce mediolateral and anteroposterior stability [62, 65]. Reduction in activity participation during third trimester may be the reason that falls are less common in third trimester [53]. However, there is a much higher incidence of falls that lead to hospitalization, with 79.3 % of all falls that led to hospitalization occurring during third trimester [61]. These findings are consistent with the elevated fall risk scores that have been reported with each successive trimester [58, 66].

McCrory et al. conducted the first biomechanical investigation of pregnant women who suffer falls in comparison with pregnant women who do not suffer falls and nonpregnant control participants. This study detected no differences in the center of pressure or ground reaction forces between the second and third trimesters, or between fallers and non-fallers [59]. Lymbery et al., however, reported a more laterally displaced center of pressure in nonpregnant women [49]. Perhaps a more important characteristic of pregnant fallers in comparison with pregnant non-fallers and nonpregnant women is reduced mediolateral sway and sway velocity [59]. Although potentially counterintuitive, reduced mediolateral sway and sway velocity may be indicative of impaired ability to respond appropriately to postural challenges, thereby increasing risk for falls. Thus, pregnant fallers may have altered neuromuscular control and may be less responsive to postural challenges than pregnant non-fallers or nonpregnant women [59]. The underlying reasons for this altered motor control have not been elucidated, but a sedentary lifestyle, compared to a lifestyle involving regular exercise during pregnancy, increases risk for falls [59].

Additional biomechanical changes with pregnancy that could potentially contribute to elevated risk for falls include altered postural biomechanics and impaired neuromuscular control and coordination. These factors are influenced by increased body mass, ligamentous laxity, impaired anterior core muscle strength, and fluid retention. Altered gait biomechanics and reduced visibility around the feet may also contribute to this elevated risk for falls.

As mentioned earlier, 40 % of falls during pregnancy occur on stairs [64]. Assessment of stair locomotion during pregnancy revealed that women in their third trimester, in comparison with those in their second trimester, demonstrated greater mediolateral movement of the center of pressure of the feet during stair ascent, greater anteroposterior braking impulse with longer stance times and greater braking forces, and greater vertical ground reaction force loading during stair descent [67]. It is possible that these alterations contribute to the elevated risk for falls during late pregnancy. While this group of investigators did not find a difference in mediolateral movement of the center of pressure when comparing pregnant fallers with pregnant non-fallers [68], they did find that pregnant fallers had a higher anteroposterior braking impulse and lower anteroposterior propulsive peak during stair descent [68]. These adaptations likely indicate a strategy to enhance stability by women who have suffered falls.

Prevention of Falls

Potential interventions to lower risk for falls during pregnancy include reduced load lifting, enhanced visibility, and increased exercise participation. More specific interventions include use of greater caution on slippery surfaces for food service employees, removal of obstacles for nurses, and proper footwear for sales and other workers. A recent study also reported reduced fall risk for women using maternity support belts [66], but the mechanism for this has not yet been fully elucidated.

Another area of interest relates to ankle strategies. In a retrospective study of postural responses to perturbation of the supporting surface in pregnant fallers, pregnant non-fallers, and nonpregnant control subjects, pregnant non-fallers demonstrated greater ankle stiffness compared with the other groups [69], though it is currently unknown whether interventions to increase ankle stiffness will reduce balance-related fall risk during pregnancy.

Postpartum Falls

Fall risk increases following vaginal or cesarean delivery particularly in the initial 24 h. Contributors to this increased risk include fatigue, muscle weakness, or pain inhibition, altered sensation in the lower limbs following epidural anesthesia, reduced coordination in the context of a sudden change in body-mass distribution, blood loss, hypotension, and side effects of medications. The incidence of falls can be attenuated by explaining the risk of falling in the initial postpartum period and having women agree to call for assistance when ambulating [70]. Several fall prevention programs have been found to be effective in reducing the rate of falls in the early postpartum period.

Further Research

Fall studies to date have been retrospective and suffer from ascertainment bias as only severe cases are identified in studies based on hospital admissions. Additionally, in nonhospitalized study samples, recall bias may confound results. Further research focused on the prospective study of falls and fall risk could be beneficial for expanding existing knowledge on falls.

Conclusion

In conclusion, numerous anatomic changes occur during pregnancy to enable the body to nurture a growing fetus and deliver a baby. Both the direct effects of these changes on the spine, pelvis, core musculature, and lower limb joints as well as compensatory changes in anatomy and physiology have clinically significant effects on pain, balance, gait, and risk for falls. While some changes return to the pre-pregnancy state and others persist postpartum, it is clear that they affect the musculoskeletal health of women during pregnancy and long-term into their post-reproductive years. Therefore, there is a need for recognition of the impacts on physical function and health as well as for additional research regarding how the body can be best protected during this critical period.

References

1. Domenjoz I, Kayser B, Boulvain M. Effect of physical activity during pregnancy on mode of delivery. *Am J Obstet Gynecol.* 2014;211(4):401.e1–11.
2. Price BB, Amini SB, Kappeler K. Exercise in pregnancy: effect on fitness and obstetric outcomes—a randomized trial. *Med Sci Sports Exerc.* 2012;44(12):2263–9.
3. Aune D, Saugstad OD, Henriksen T, Tonstad S. Physical activity and the risk of preeclampsia: a systematic review and meta-analysis. *Epidemiology.* 2014;25(3):331–43.
4. Magnus P, Trogstad L, Owe KM, Olsen SF, Nystad W. Recreational physical activity and the risk of preeclampsia: a prospective cohort of Norwegian women. *Am J Epidemiol.* 2008;168(8):952–7.
5. Saftlas AF, Logsden-Sackett N, Wang W, Woolson R, Bracken MB. Work, leisure-time physical activity, and risk of preeclampsia and gestational hypertension. *Am J Epidemiol.* 2004;160(8):758–65.
6. Sorensen TK, Williams MA, Lee IM, Dashow EE, Thompson ML, Luthy DA. Recreational physical activity during pregnancy and risk of preeclampsia. *Hypertension.* 2003;41(6):1273–80.
7. Muktabhant B, Lumbiganon P, Ngamjarus C, Dowswell T. Interventions for preventing excessive weight gain during pregnancy. *Cochrane Database Syst Rev.* 2012;4, CD007145.
8. Foti T, Davids JR, Bagley A. A biomechanical analysis of gait during pregnancy. *J Bone Joint Surg Am.* 2000;82(5):625–32.
9. Enders LA, Berger K, Chambers AJ, Redfern R, McCrory JL. Biomechanical evidence of waddling during pregnancy. In: *Proceedings of the BMES 2009 Annual Fall Scientific Meeting; 2009 October 7–10; Pittsburgh, PA.*
10. Ritchie JR. Orthopedic considerations during pregnancy. *Clin Obstet Gynecol.* 2003;46(2):456–66.
11. Kristiansson P, Svardsudd K, von Schoultz B. Serum relaxin, symphyseal pain, and back pain during pregnancy. *Am J Obstet Gynecol.* 1996;175(5):1342–7.
12. Marnach ML, Ramin KD, Ramsey PS, Song SW, Stensland JJ, An KN. Characterization of the relationship between joint laxity and maternal hormones in pregnancy. *Obstet Gynecol.* 2003;101(2):331–5.
13. Dumas GA, Reid JG, Wolfe LA, Griffin MP, McGrath MJ. Exercise, posture, and back pain during pregnancy. *Clin Biomech (Bristol, Avon).* 1995;10(2):98–103.
14. Cammarata ML, Dhaheer YY. The differential effects of gender, anthropometry, and prior hormonal state on frontal plane knee joint stiffness. *Clin Biomech (Bristol, Avon).* 2008;23(7):937–45.
15. Jensen RK, Doucet S, Treitz T. Changes in segment mass and mass distribution during pregnancy. *J Biomech.* 1996;29(2):251–6.
16. Whitcome KK, Shapiro LJ, Lieberman DE. Fetal load and the evolution of lumbar lordosis in bipedal hominins. *Nature.* 2007;450(7172):1075–8.
17. Jacobson H. Protecting the back during pregnancy. *AAOHN J.* 1991;39(6):286–91.
18. Boissonnault JS, Blaschak MJ. Incidence of diastasis recti abdominis during the childbearing year. *Phys Ther.* 1988;68(7):1082–6.
19. Gilleard WL, Brown JM. Structure and function of the abdominal muscles in primigravid subjects during pregnancy and the immediate postbirth period. *Phys Ther.* 1996;76(7):750–62.
20. Gilleard WL. Trunk motion and gait characteristics of pregnant women when walking: report of a longitudinal study with a control group. *BMC Pregnancy Childbirth.* 2013;13:71.
21. Parker JM, Bhattacharjee M. Images in clinical medicine. Peripartum diastasis of the symphysis pubis. *N Engl J Med.* 2009;361(19):1886.
22. Dhar S, Anderton JM. Rupture of the symphysis pubis during labor. *Clin Orthop Relat Res.* 1992;283:252–7.

23. Schauberger CW, Rooney BL, Goldsmith L, Shenton D, Silva PD, Schaper A. Peripheral joint laxity increases in pregnancy but does not correlate with serum relaxin levels. *Am J Obstet Gynecol.* 1996;174(2):667–71.
24. Elden H, Hagberg H, Olsen MF, Ladfors L, Ostgaard HC. Regression of pelvic girdle pain after delivery: follow-up of a randomised single blind controlled trial with different treatment modalities. *Acta Obstet Gynecol Scand.* 2008;87(2):201–8.
25. Gillear W, Crosbie J, Smith R. Effect of pregnancy on trunk range of motion when sitting and standing. *Acta Obstet Gynecol Scand.* 2002;81(11):1011–20.
26. MacLennan AH. The role of the hormone relaxin in human reproduction and pelvic girdle relaxation. *Scand J Rheumatol Suppl.* 1991;88:7–15.
27. Dehghan F, Haerian BS, Muniandy S, Yusof A, Dragoo JL, Salleh N. The effect of relaxin on the musculoskeletal system. *Scand J Med Sci Sports.* 2014;24:e220–9.
28. Segal NA, Boyer ER, Teran-Yengle P, Glass NA, Hillstrom HJ, Yack HJ. Pregnancy leads to lasting changes in foot structure. *Am J Phys Med Rehabil.* 2013;92(3):232–40.
29. Bohemen EK. Flatfeet in pregnancy. *Br J Rheumatol.* 1996;35(4):396–7.
30. Nyska M, Sofer D, Porat A, Howard CB, Levi A, Meizner I. Planter foot pressures in pregnant women. *Isr J Med Sci.* 1997;33(2):139–46.
31. Khamis S, Yizhar Z. Effect of feet hyperpronation on pelvic alignment in a standing position. *Gait Posture.* 2007;25(1):127–34.
32. Ribeiro AP, Joao SM, Sacco IC. Static and dynamic biomechanical adaptations of the lower limbs and gait pattern changes during pregnancy. *Womens Health.* 2013;9(1):99–108.
33. Dumas GA, Reid JG. Laxity of knee cruciate ligaments during pregnancy. *J Orthop Sports Phys Ther.* 1997;26(1):2–6.
34. Gillear WL, Crosbie J, Smith R. Static trunk posture in sitting and standing during pregnancy and early postpartum. *Arch Phys Med Rehabil.* 2002;83(12):1739–44.
35. Gross KD, Felson DT, Niu J, Hunter DJ, Guermazi A, Roemer FW, et al. Association of flat feet with knee pain and cartilage damage in older adults. *Arthritis Care Res.* 2011; 63(7):937–44.
36. Liu B, Balkwill A, Cooper C, Roddam A, Brown A, Beral V. Reproductive history, hormonal factors and the incidence of hip and knee replacement for osteoarthritis in middle-aged women. *Ann Rheum Dis.* 2009;68(7):1165–70.
37. Wise BL, Niu J, Zhang Y, Felson DT, Bradley LA, Segal N, et al. The association of parity with osteoarthritis and knee replacement in the multicenter osteoarthritis study. *Osteoarthritis Cartilage.* 2013;21(12):1849–54.
38. Otman AS, Beksac MS, Bagoze O. The importance of 'lumbar lordosis measurement device' application during pregnancy, and post-partum isometric exercise. *Eur J Obstet Gynecol Reprod Biol.* 1989;31(2):155–62.
39. Mannion AF, Dumas GA, Stevenson JM, Cooper RG. The influence of muscle fiber size and type distribution on electromyographic measures of back muscle fatigability. *Spine.* 1998;23(5):576–84.
40. Drinkwater BL, Chesnut 3rd CH. Bone density changes during pregnancy and lactation in active women: a longitudinal study. *Bone Miner.* 1991;14(2):153–60.
41. Sowers M, Crutchfield M, Jannausch M, Updike S, Corton G. A prospective evaluation of bone mineral change in pregnancy. *Obstet Gynecol.* 1991;77(6):841–5.
42. Sowers M, Corton G, Shapiro B, Jannausch ML, Crutchfield M, Smith ML, et al. Changes in bone density with lactation. *JAMA.* 1993;269(24):3130–5.
43. Hayslip CC, Klein TA, Wray HL, Duncan WE. The effects of lactation on bone mineral content in healthy postpartum women. *Obstet Gynecol.* 1989;73(4):588–92.
44. Yamaga A, Taga M, Minaguchi H, Sato K. Changes in bone mass as determined by ultrasound and biochemical markers of bone turnover during pregnancy and puerperium: a longitudinal study. *J Clin Endocrinol Metab.* 1996;81(2):752–6.
45. Kurabayashi T. [Metabolic changes in bone and calcium in pregnancy and puerperium]. *Clin Calcium.* 2011;21(9):1335–46.

46. Branco M, Santos-Rocha R, Aguiar L, Vieira F, Veloso A. Kinematic analysis of gait in the second and third trimesters of pregnancy. *J Pregnancy*. 2013;2013:718095.
47. Carpes FP, Griebeler D, Kleinpaul JF, Mann L, Mota CB. Women able-bodied gait kinematics during and post pregnancy period. *Rev Bras Biomech*. 2008;9(16):33–40.
48. Bird AR, Menz HB, Hyde CC. The effect of pregnancy on footprint parameters. A prospective investigation. *J Am Podiatr Med Assoc*. 1999;89(8):405–9.
49. Lymbery JK, Gilleard W. The stance phase of walking during late pregnancy: temporospatial and ground reaction force variables. *J Am Podiatr Med Assoc*. 2005;95(3):247–53.
50. Wu W, Meijer OG, Lamoth CJ, Uegaki K, van Dieen JH, Wuisman PI, et al. Gait coordination in pregnancy: transverse pelvic and thoracic rotations and their relative phase. *Clin Biomech (Bristol, Avon)*. 2004;19(5):480–8.
51. Hagan L, Wong CK. Gait in pregnant women: spinal and lower extremity changes from pre- to postpartum. *J Women's Health Phys Ther*. 2010;34(2):46–56.
52. Albino MA, Moccellini AS, Firmento Bda S, Driusso P. [Gait force propulsion modifications during pregnancy: effects of changes in feet's dimensions]. *Rev Bras Ginecol Obstet*. 2011;33(7):164–9.
53. McCrory JL, Chambers AJ, Daftary A, Redfern MS. Ground reaction forces during gait in pregnant fallers and non-fallers. *Gait Posture*. 2011;34(4):524–8.
54. Gilleard W, Crosbie J, Smith R. A longitudinal study of the effect of pregnancy on rising to stand from a chair. *J Biomech*. 2008;41(4):779–87.
55. Sunaga Y, Anan M, Shinkoda K. Biomechanics of rising from a chair and walking in pregnant women. *Appl Ergon*. 2013;44(5):792–8.
56. Kirby RL, Price NA, MacLeod DA. The influence of foot position on standing balance. *J Biomech*. 1987;20(4):423–7.
57. Jang J, Hsiao KT, Hsiao-Weckler ET. Balance (perceived and actual) and preferred stance width during pregnancy. *Clin Biomech (Bristol, Avon)*. 2008;23(4):468–76.
58. Butler EE, Colon I, Druzin ML, Rose J. Postural equilibrium during pregnancy: decreased stability with an increased reliance on visual cues. *Am J Obstet Gynecol*. 2006;195(4):1104–8.
59. McCrory JL, Chambers AJ, Daftary A, Redfern MS. Dynamic postural stability in pregnant fallers and non-fallers. *BJOG*. 2010;117(8):954–62.
60. Fildes J, Reed L, Jones N, Martin M, Barrett J. Trauma: the leading cause of maternal death. *J Trauma*. 1992;32(5):643–5.
61. Schiff MA. Pregnancy outcomes following hospitalisation for a fall in Washington State from 1987 to 2004. *BJOG*. 2008;115(13):1648–54.
62. Dunning K, LeMasters G, Levin L, Bhattacharya A, Alterman T, Lordo K. Falls in workers during pregnancy: risk factors, job hazards, and high risk occupations. *Am J Ind Med*. 2003;44(6):664–72.
63. Connolly AM, Katz VL, Bash KL, McMahon MJ, Hansen WF. Trauma and pregnancy. *Am J Perinatol*. 1997;14(6):331–6.
64. Dunning K, Lemasters G, Bhattacharya A. A major public health issue: the high incidence of falls during pregnancy. *Matern Child Health J*. 2010;14(5):720–5.
65. Inanir A, Cakmak B, Hisim Y, Demirturk F. Evaluation of postural equilibrium and fall risk during pregnancy. *Gait Posture*. 2014;39(4):1122–5.
66. Cakmak B, Inanir A, Nacar MC, Filiz B. The effect of maternity support belts on postural balance in pregnancy. *PM R*. 2014;6(7):624–8.
67. McCrory JL, Chambers AJ, Daftary A, Redfern MS. Ground reaction forces during stair locomotion in pregnancy. *Gait Posture*. 2013;38(4):684–90.
68. McCrory JL, Chambers AJ, Daftary A, Redfern MS. Ground reaction forces during stair locomotion in pregnant fallers and non-fallers. *Clin Biomech (Bristol, Avon)*. 2014;29(2):143–8.
69. Ersal T, McCrory JL, Sienko KH. Theoretical and experimental indicators of falls during pregnancy as assessed by postural perturbations. *Gait Posture*. 2014;39(1):218–23.
70. Lockwood S, Anderson K. Postpartum safety: a patient-centered approach to fall prevention. *MCN Am J Matern Child Nurs*. 2013;38(1):15–8; quiz 19–20.

Chapter 2

Hormonal Influence on the Neuromusculoskeletal System in Pregnancy

Maria E. Reese and Ellen Casey

Background of Hormones to Be Discussed

Estrogen

The most potent estrogen produced in the human body is 17 beta-estradiol (estradiol) [1]. In the nonpregnant female, estrogen is produced predominantly by the ovaries and it peaks just prior to ovulation [2] (Fig. 2.1). During pregnancy, estrogen is produced primarily from the placenta and its role is to promote fetal growth and well-being [3–5]. Estradiol has been shown to dramatically increase throughout pregnancy (Fig. 2.2) [6] and to decrease at time of parturition and during lactation [7]. Decreased estrogen levels during lactation seem to result from prolactin-mediated suppression of gonadotropin-releasing hormone, luteinizing hormone, follicular-stimulating hormone but not changes in parathyroid hormone (PTH), or 1,25-dihydroxyvitamin D [7, 8]. Estrogen modulates several neuromusculoskeletal tissues, including bone, cartilage, ligament, myotendinous unit, and the nervous system (Fig. 2.3).

M.E. Reese, MA, MD (✉)

Spine and Sports Medicine, Physical Medicine and Rehabilitation, Northwestern University
Feinberg School of Medicine/Rehabilitation Institute of Chicago, 1030 N Clark, Suite 500,
Chicago, IL 60610, USA
e-mail: mreese@ric.org

E. Casey, MD

Department of Family, Community and Preventive Medicine, Sports Medicine Fellowship,
College of Medicine, Drexel University, Philadelphia, PA, USA
e-mail: ecasey@ric.org; Ellen.Casey@drexelmed.edu

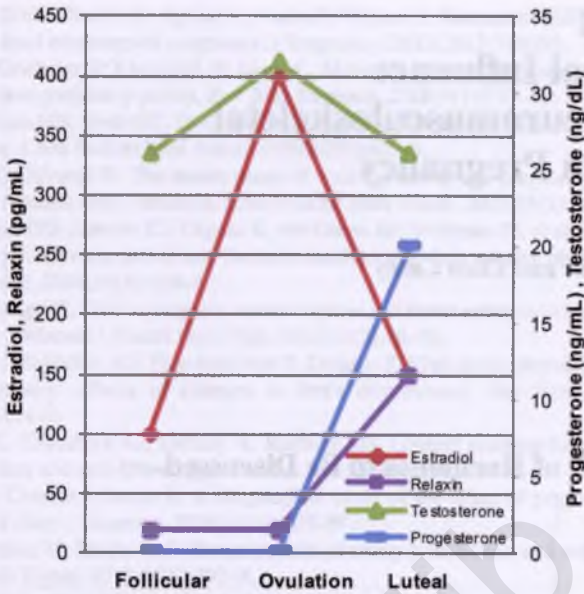


Fig. 2.1 Typical fluctuations of hormones across the menstrual cycle. There is significant intra-person variation in the concentrations of the hormones, so this graph represents the upper level of serum concentrations of estrogen, progesterone, testosterone, and relaxin (Data from: Ahrens, *Annals of Epidemiology*, 2014)

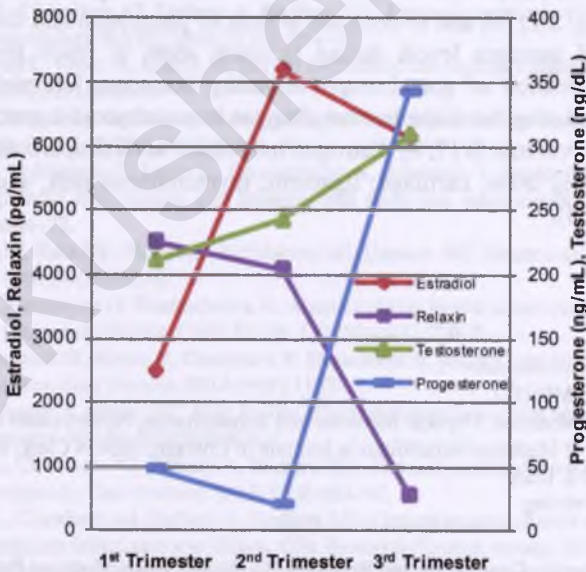


Fig. 2.2 Typical hormonal changes throughout pregnancy. There is significant intra-person variation in the concentrations of the hormones, so this graph represents the upper level of serum concentrations of estrogen, progesterone, testosterone, and relaxin (Data from: Abbassi-Ghanavati, Mina; Greer, Laura; Cunningham, F. *Obstetrics & Gynecology*. 114(6):1326-1331, December 2009; Vollestaad *Man Ther* 2012; Karger 1998; Kristiansson *AJ OB Gyn* 1996.)

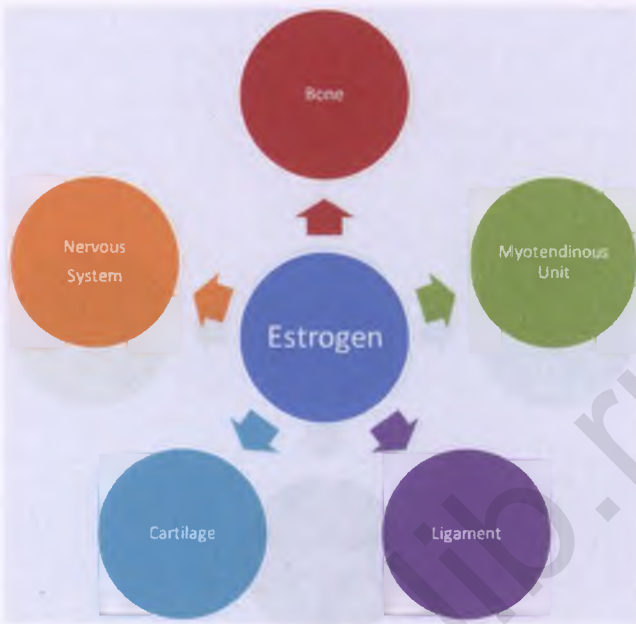

Fig. 2.3 Neuromusculoskeletal tissues affected by estrogen

Progesterone

In nonpregnant women, progesterone is primarily produced by the corpus luteum during the luteal phase of the menstrual cycle [2] (Fig. 2.1). In the pregnant female, progesterone is initially produced by the corpus luteum, but after the first trimester, it is predominantly produced by the placenta [9]. Progesterone levels peak during the third trimester of pregnancy [10] (Fig. 2.2). Progesterone is essential for implantation and the maintenance of pregnancy and is often used pharmacologically to prevent miscarriage and to treat preterm labor [11]. Progesterone's role in the neuromusculoskeletal system is also through modulation of bone, cartilage, ligament, myotendinous unit, and the nervous system (Fig. 2.4).

Relaxin

Relaxin initially came into clinical and research interest in the 1920s when Hisaw found that the blood of pregnant guinea pigs and rabbits contained a factor that stimulated growth and softened the connective tissue that joined the pubic bones [12]. Thereafter, there was a period of uncertainty regarding relaxin's role as it was found that estrogen and progesterone could also relax the pubic bones [12]. However, the role of relaxin in pregnancy and in the musculoskeletal system has continued to receive much attention through animal as well as human studies [12].

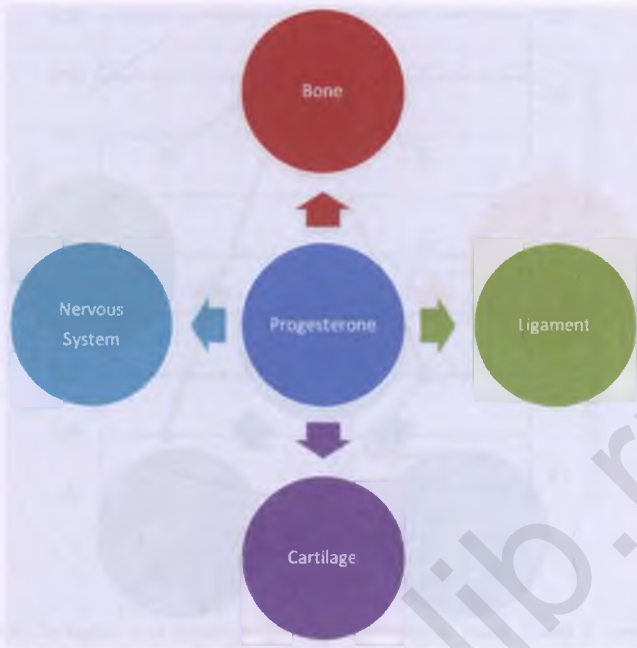


Fig. 2.4 Neuromusculoskeletal tissues affected by progesterone

Structurally, relaxin is related to insulin and insulin-like growth factor and is secreted from the corpus luteum and the placenta [13, 14]. In nonpregnant women, relaxin levels have been shown to increase during the luteal phase of the menstrual cycle [15] (Fig. 2.1). In pregnant women, relaxin levels have been found to increase early in the first trimester of pregnancy, peaking around the twelfth week of pregnancy [12, 16–18] (Fig. 2.2). Thereafter, relaxin levels steadily decrease to around 50 % of peak levels until approximately the 17th–24th week of pregnancy, after which the concentration stabilizes for the remainder of pregnancy [12, 16, 19]. Unlike other mammals, such as pigs and rats, there is no pre-labor relaxin surge in humans [20] and human relaxin levels are undetectable in the first few days postpartum [14]. In pregnant women, relaxin acts to remodel pelvic connective tissue and to inhibit uterine contractility [21]. In the neuromusculoskeletal system, relaxin appears to modulate a variety of tissues, including cartilage, ligament, bone, and the myotendinous unit (Fig. 2.5).

Testosterone/Androstenedione

In females, the ovaries and the adrenal glands produce testosterone. In nonpregnant women, testosterone levels peak during the ovulatory phase of the menstrual cycle [2] (Fig. 2.1) and in pregnant women, levels increase throughout pregnancy [22, 23] (Fig. 2.2). Levels become significantly greater than in nonpregnant females starting

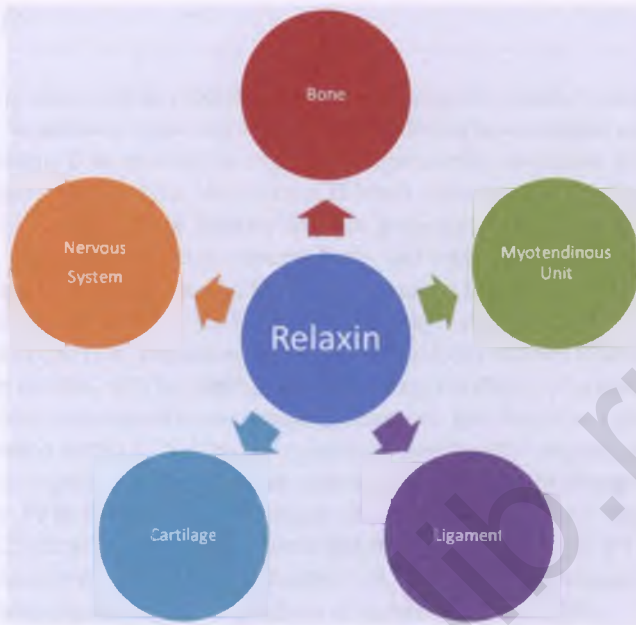

Fig. 2.5 Neuromusculoskeletal tissues affected by relaxin

during weeks 13–16 [23]. Androstenedione also increases during pregnancy but is only significantly elevated during weeks 13–16 and weeks 37–40 [22]. Up until week 28, the rise in free testosterone is thought to be due to a decrease in metabolic clearance and after week 28, production rate of free testosterone increases [22]. Testosterone and androstenedione reach their peak levels at time of parturition [23]. In the first few days after delivery, the levels decrease to those of nonpregnant females [23]. Testosterone modulates the neuromusculoskeletal system at the level of cartilage, ligament, bone, and the myotendinous unit (Fig. 2.6).

Prolactin

Prolactin is produced from the pituitary gland and plays a role in maintaining the corpus luteum during pregnancy and in synthesizing milk during lactation [24]. Prolactin begins to rise during the eighth week of pregnancy, peaks at ten times normal levels, and remains elevated in lactating women [25, 26]. Prolactin concentration depends on lactation status with higher levels of prolactin associated with longer duration of lactation [6, 25, 26].

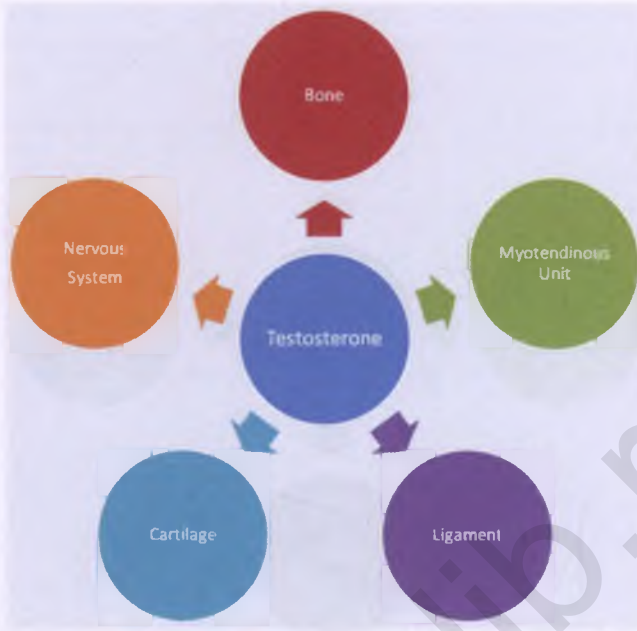

Fig. 2.6 Neuromusculoskeletal tissues affected by testosterone

Parathyroid Hormone

PTH is released from the parathyroid glands and its main role during pregnancy is to maintain calcium homeostasis [27]. PTH has been shown to decrease during mid-pregnancy and rise in late pregnancy in some studies [28]; however, others advocate levels are unchanged compared with those of nonpregnant females [6, 8]. Additionally, there is no consensus regarding PTH concentration in the postpartum phase or in lactating women, as levels have been shown to increase, decrease, or remain unchanged compared to nonpregnant controls [6, 29].

Parathyroid Hormone-Related Peptide

Parathyroid hormone-related peptide (PTHrP) is produced by many maternal tissues, including the placenta, uterus, lactating mammary gland, and fetal tissues during pregnancy. The dominant source is unclear [8, 30]. PTHrP concentration increases throughout pregnancy and continues to increase postpartum [31]. Particularly during early lactation, PTHrP levels increase and are inversely related to PTH concentration [29]. Elevated PTHrP levels have been found to be associated with breastfeeding status, elevated prolactin levels, and lower estradiol levels [7].

Vitamin D

Vitamin D is a secosteroid prohormone that is structurally similar to sex steroid hormones [9]. In addition to its role in regulating calcium homeostasis, animal studies suggest vitamin D is involved in regulating reproductive processes by influencing estrogen synthesis [9]. Also, low vitamin D levels during pregnancy may be associated with increased risk of various adverse pregnancy outcomes, including pre-eclampsia, gestational diabetes, preterm birth, and small for gestational age infants [32]. During pregnancy, serum 1,25-dihydroxyvitamin D increases early in gestation prior to the increase of PTH [6, 8, 28, 29] and is hypothesized to be predominantly placental in origin [29]. Increasing serum 1,25-dihydroxyvitamin D levels have been shown to be parallel with increasing calcium absorption during pregnancy [29]. With respect to other hormones of pregnancy, the literature has shown no significant association between serum 1,25-dihydroxyvitamin D levels with estradiol, progesterone, 17 hydroxyprogesterone, testosterone, androstenedione, insulin-like growth factor 1 (IGF-1), or PTH during early pregnancy [9, 33]. Nor was there any correlation between 1,25-dihydroxyvitamin D levels and estrogen, prolactin, or PTH levels during the remainder of pregnancy [6]. Postpartum, 1,25-dihydroxyvitamin D levels are similar to nonpregnant women regardless of lactation status [6, 29].

Insulin-Like Growth Factor 1

IGF-1 is produced from various cells and plays a role in promoting cell division and growth in various tissues including uterine leiomyomata [34, 35] and mammary tissue [36]. IGF-1 is suppressed in early pregnancy but peaks in the third trimester [6, 37, 38]. Postpartum, IGF-1 levels are suppressed and are lower in women who lactated for more than 4 months compared to controls and those who lactated less than 4 months [6].

Sex Hormone-Binding Globulin

Sex hormone-binding globulin (SHBG) is a glycoprotein with a strong affinity for estradiol. In studies of nonpregnant, menstruating women, SHBG has been found to increase when estradiol increases near ovulation and is thought to help maintain physiologic balance with progesterone [39]. In pregnant women, SHBG levels peak at parturition and then have a rapid decline in the postpartum period [40].

Bone

The key hormones that may affect bone metabolism in pregnant and lactating females include relaxin, estrogen, progesterone, testosterone, PTHrP, and PTH. Relaxin, estrogen, and various growth factors orchestrate the bone remodeling process [13].

Functional progesterone and testosterone receptors of osteoblast and osteoclast lineage, and estrogen receptors of osteoblast lineage exist in human bone cells [41, 42]. Estrogen has indirect and direct effects on bone metabolism and helps maintain a balance between osteoblastic and osteoclastic activity to overall reduce the rate of bone loss [41, 42]. The role of progesterone in maintaining bone health is less well understood than that of estrogen and seems to facilitate estrogen's effects on the skeletal system [42]. For instance, estradiol has been shown to stimulate osteoblast proliferation when used in combination with a pure progesterone [41]. Testosterone stimulates osteoblast proliferation, enhances osteoclast differentiation, and has been shown to have synergistic effects of improving bone mass when used pharmacologically with estrogen [42]. Relaxin is primarily an osteoclast-activating factor that increases bone resorption [13]. However, there is no evidence that higher concentrations of relaxin during pregnancy have any detrimental effects on bone density. On the other hand, there is some evidence to suggest that pregnant women with higher levels of estrogen and relaxin may correlate with increased prevalence of congenital hip dysplasia in neonates [13].

It has been suggested that pregnancy-related bone loss is primarily attributable to changes in estrogen status rather than resulting directly from increased calcium demands during pregnancy or lactation [29, 43]. Elevated estrogen during pregnancy protects against skeletal bone loss [43]. Some advocate that estrogen induces a buildup of a calcium "safety deposit" into the female skeleton from which calcium can be released into the bloodstream to serve the needs of the fetus and newborn during pregnancy and lactation [43].

PTHrP has been shown to increase 1,25-dihydroxyvitamin D and suppress PTH during pregnancy. Collectively, this may help regulate placental calcium transport and protect the maternal bone during pregnancy [8]. Specifically, PTHrP binds to the PTH receptor and stimulates renal calcium absorption [29] and the terminal fragments of PTHrP have been shown to inhibit osteoclast-induced bone resorption [8]. PTHrP is positively associated with increased levels of bone turnover markers, including osteocalcin and type 1 collagen N-telopeptide [7].

The high bone turnover rate during lactation may be related to the combination of low estradiol, high prolactin, high PTH and possibly high PTHrP levels [6, 29]. Changes in vitamin D levels during pregnancy have not been shown to be associated with bone loss during lactation [29]. Upon the resumption of menstruation with cyclic secretions of estrogen, bone mineral density is regained despite continued lactation [43].

Prolactin and PTHrP levels have been shown to be negatively associated with the rate of spine and femoral neck bone mineral density changes in postpartum women aged 20–40 years [7], even after accounting for breastfeeding status, other hormone levels, physical activity, and calcium intake [7]. However, increasing levels of estradiol have been shown to be associated with a positive change of bone mineral density in the spine in postpartum women aged 20–40 years [7]. Lastly, there has not been any proven long-term detrimental effect of pregnancy or lactation on the skeletal mass of mothers [43].

Cartilage

The main hormones that may affect articular cartilage in peripartum and postpartum females include estrogen, testosterone, progesterone, and relaxin. Estrogen and testosterone receptors have been localized in the chondrocytes of the articular cartilage of the knee and estrogen and progesterone receptors additionally in the synoviocytes of the synovial lining [26, 44–47]. While both males and females have testosterone receptors, testosterone has modulatory effects only on male chondrocytes [47]. In males, androgens have been shown to help protect against degradation in rheumatoid arthritis and may play a similar role in osteoarthritis; however, it is unclear if this is due to a direct result from testosterone or from locally produced estrogen [45]. In females, progesterone has been shown to have a role in the development and protection of cartilage [48], and estrogen has been shown to have both protective and detrimental effects on articular cartilage [47]. Animal models have shown antioxidant effects of estrogen in protecting the chondrocytes from reactive oxygen changes [47]. In human models, estradiol increases chondrocytes proliferation, stimulates type II collagen, and protects against osteoarthritis via direct protective actions on the chondrocytes [45]. Subjects with low estradiol were not only found to have increased incidence of arthritic changes, but also found to have greater pain associated with arthritis due to the lack of leukotrienes, which have pain mediating effects [47]. In the postpartum female, the rapid decline of estrogen after parturition may possibly contribute to joint pain. However, there is also evidence of detrimental effects of estrogen on chondrocytes. For example, intra-articular injections of estrogen in a rabbit model caused pathological changes of the articular cartilage consistent with osteoarthritis, including fibrillation and erosion of the articular cartilage leading to exposure of the subchondral bone [47]. Additionally, high levels of estrogen have been shown to lead to increased inflammatory effects of certain interleukins (IL 1beta) in rabbit models [47]. Progesterone, on the other hand, has been found to have anti-inflammatory effects in osteoarthritis [48].

Relaxin appears to decrease knee articular cartilage stiffness through induction of collagenase and metalloproteinase [13]. In an animal model, the collagen content of knee articular cartilage in pregnant rabbits had decreased RNA levels and decreased chondrocyte metabolism [13]. Thus, it is suggested that relaxin may play a role in women's propensity for joint disease [13].

Ligament

The key hormones that may affect ligaments during pregnancy and lactation are estrogen, progesterone, testosterone, relaxin, SHBG, and IGF-1. Multiple sex hormones have been investigated in nonpregnant females in order to determine causation or correlation between hormone levels, ligamentous laxity, and anterior cruciate

ligament (ACL) injuries since estrogen, progesterone, testosterone, and relaxin receptors have been found in the human ACL [13, 26, 39, 44, 49–52]. Despite increasing research in this area, the true modulatory effects of sex hormones are not known, partly because of the difficulty studying this topic and partly because several of these hormones likely act in concert with each other to affect the metabolic properties and function of ligaments.

Estrogen is the most well-studied hormone thought to affect ligaments. Women have been found to have greater knee and ankle laxity when compared to men [53, 54]. While some studies have shown no correlation of the acute fluctuations of estradiol, progesterone, and testosterone across the menstrual cycle with changes in knee or ankle laxity [45, 53–55], others have demonstrated a correlation [39, 56]. Research evaluating daily sex hormone levels in menstruating females has elucidated that approximately 60 % of increased ACL laxity across the menstrual cycle depends on the combined changes of estrogen, progesterone, and testosterone levels without correlation to any one specific hormone [56]. Primarily, this research revealed that when estrogen and testosterone levels peak in the setting of elevated progesterone, females experience a greater increase in knee laxity [56]. Evidence from animal and human studies in nonpregnant females suggests that estrogen may decrease collagen synthesis and fibroblast proliferation, leading to a reduced ability of the ligament to withstand load and increase injury risk [16, 26, 39, 49, 57–59]. Subsequently, several studies have noted increased rates of ACL injury in nonpregnant women during the follicular phase with rising and peak levels of estrogen [60, 61], while other studies have found conflicting results with respect to menstrual cycle phase [62]. These studies have been criticized for multiple limitations [63] and consensus is currently lacking [26] regarding the risk of ligamentous injury and menstrual cycle phase.

Relaxin leads to a marked local decrease in total collagen content by reducing the density and organization of collagen bundles [21, 26, 52, 64]. As collagen is the main load-bearing component of ligaments, changes in collagen could lead to changes in ligament integrity [52]. Relaxin has been implicated in altering the mechanical properties of the ACL in animal [13, 65] and human studies [13, 26, 66] via reduced ligament integrity and higher evidence of and risk for injury [13, 26, 66]. Yet other studies demonstrate that weekly variations of serum relaxin levels in eumenorrheic women are not associated with changes in the anterior translation of the knee [64]. Possibly the variable results can be explained by the influence of estrogen on the expression of relaxin receptors as estrogen priming increases the response of target organs to relaxin [52, 67].

Testosterone, progesterone, IGF-1, and SHBG additionally influence the mechanical properties and functions of ligaments. While testosterone has been associated with increased collagen content in capsular tissue and increased knee ligament repair strength [68], neither total nor free testosterone is an independent predictor of ACL stiffness [68]. Increased concentration of progesterone has been associated with increased fibroblast proliferation and collagen formation [39, 50], yet there is no direct relationship between progesterone levels and ACL stiffness [39]. Higher IGF-1 concentrations and lower serum markers of collagen production have been

shown to predict greater anterior knee laxity in both eumenorrheic women and women using contraceptives [69]. Lastly, SHBG is a glycoprotein that fluctuates with changes of estradiol and progesterone levels during the menstrual cycle [39]. SHBG modulates estrogen's effects on various target tissues including ligaments [39]. However, there is no significant correlation between ACL stiffness and estradiol, progesterone, or SHBG levels during various phases of the menstrual cycle [39].

The earliest evidence of possible increased joint and pelvic laxity during pregnancy dates back to the 1930s, when radiographs of the pubic symphysis demonstrated increased joint displacement in pregnant women [21]. Increased joint laxity over the course of pregnancy and postpartum has been shown [70–72]. However, correlation with relaxin levels has not been demonstrated [12–14, 21, 73], possibly due to relaxin having more of a cumulative rather than an acute effect on joint laxity [21]. Unique to pregnancy, relaxin has been shown to have a role in remodeling connective tissue and reducing soft tissue tension in the pubic symphysis in preparation for parturition [26, 70, 74]. In several mammalian species (humans, guinea pigs, mice), elevated levels of estrogen and relaxin aid in the transformation of the pubic symphysis hyaline cartilage into fibrocartilage and eventually into the interpubic ligament during pregnancy [74]. In a study of ovariectomized mice, it was the interaction of progesterone, relaxin, and estrogen acting together that was necessary to cause structural changes in the pubic symphysis of the pregnant mouse typical of a normal pregnancy [75]. Additionally, some studies in humans have shown that estradiol levels correlate with increased laxity [70], but others have failed to demonstrate a clear relationship between maternal concentrations of estradiol, progesterone, or relaxin and joint laxity [71]. In a case study of a patient 5 weeks postpartum, she was found to have increased knee laxity on the knee that was status post ACL repair 2 months prior to conception [76]. She had minimal laxity at 7 months of gestation and her laxity normalized 3 months postpartum [76]. This case elucidates the likelihood that joint laxity and ligament stability change during pregnancy and postpartum, yet at this time we cannot attribute these changes to any one hormone nor do we know the exact origin of change.

Relaxin appears to decrease knee articular cartilage stiffness through induction of collagenase and metalloproteinase [13]. In an animal model, the collagen content of knee articular cartilage in pregnant rabbits had decreased RNA levels and decreased chondrocyte metabolism [13]. Thus, it is suggested that relaxin may play a role in women's propensity for joint disease [13].

Myotendinous Unit

The most influential hormones for the myotendinous unit during pregnancy and lactation are likely estrogen, relaxin, testosterone, and IGF-1 with possible implications for prolactin. Both estrogen and testosterone receptors have been identified in skeletal muscle [77–81]. From studies of nonpregnant females, increased estrogen

levels during the menstrual cycle have been associated with decreased myotendinous stiffness [77, 82–85] and with diminished response of the rectus femoris muscle stretch reflex [86]. The mechanism is not entirely clear, but high levels of estrogen influence fibroblast proliferation, collagen synthesis, and collagen degradation likely via a cumulative effect [87] and possibly due to suppression of IGF-1 [85]. Decreased myotendinous stiffness may result in decreased joint stability [84] possibly leading to increased injury risk. However, other studies have noted no significant difference in tendon mechanical properties among the changing levels of estrogen with the phases of the menstrual cycle [88]. Furthermore, one study demonstrated inhibition of myofibrillar protein synthesis in tendons of women taking oral contraceptives compared to women not on contraceptives. This suggests that there may be a differential effect of endogenous and exogenous estrogen in regard to tendon stiffness and function [89]. Collectively, these findings may indicate that estrogen has more of a chronic rather than acute impact on tendon behavior [88]. Additionally, neuromuscular control, including fine motor activity and reaction time, has been reported to fluctuate over the menstrual cycle, and alterations of muscle activation patterns (gluteus maximus, semitendinous, and quadriceps) occur with peak estrogen levels [90]. It remains to be seen how the significantly elevated levels of estrogen during pregnancy affect myotendinous stiffness, but it is possible that joint stability might be compromised, especially in muscles spanning two joints and those with longer tendons.

Relaxin has been shown to modulate tendon growth and reduce myotendinous stiffness through activation of collagenase [13, 21, 64]. In young eumenorrheic women, elevated relaxin levels have been found to correlate with decreased patellar tendon stiffness, yet no changes of cross-sectional area were noted [91]. Relaxin has been shown to regulate normal skeletal muscle through the adenylate cyclase and nitric oxide pathways [13]. It has been found to have a role in the healing process by regulating inflammation, remodeling tissue, inhibiting fibrosis, and decreasing scar formation [13], which is crucial for the female body given the profound changes that occur to accommodate a growing fetus and prepare for parturition.

Testosterone is known to increase muscle mass and strength by inducing hypertrophy of type 1 and type 2 muscle fibers and increasing myonuclear and satellite cell number [92]. Additionally, in females, testosterone has been negatively associated with myotendinous stiffness [83], which may lead to decreased joint stability when testosterone levels are elevated as during the second and third trimesters. Similarly, IGF-1 enhances skeletal muscle hypertrophy by inducing protein synthesis and blocking muscle atrophy [38]. As IGF-1 and testosterone are elevated in the third trimester, this may be the most optimal time for pregnant women to strength train to enhance skeletal muscle hypertrophy. They may best benefit from strengthening exercises with minimal joint stress and perturbation due to the negative effects of elevated testosterone and elevated estrogen on myotendinous stiffness that can lead to decreased joint stability and possible increased injury risk [82, 83]. In addition to hormonal considerations, the third trimester may be less optimal for strength

training from a biomechanical perspective given changes such as increased lumbar lordosis and weight gain, which is further explained in other chapters.

Some studies have implicated prolactin in the etiology of DeQuervain's tenosynovitis in pregnant females, as observational studies have shown that DeQuervain's symptoms will resolve after women stop breastfeeding and their prolactin levels have normalized [25]. Similarly, prolactin has also been implicated in the etiology of carpal tunnel syndrome in pregnant and breastfeeding women [26]. The authors feel the role of prolactin is more correlative as these syndromes are associated with mechanical overuse of the wrists in the setting of pregnancy and breastfeeding. Please see additional chapters for more details regarding upper extremity pathology during pregnancy.

Nervous System

The predominant hormones influencing the nervous system in the pregnant female are likely estrogen, progesterone, and relaxin with potential influence from testosterone as well. Sex hormones have been shown to have effects on the excitability of neural structures in the peripheral and central nervous systems of nonpregnant individuals. While estrogen plays a stimulatory role enhancing nerve membrane excitability and synaptic transmission [93–95], progesterone plays an inhibitory and protective role [93, 94]. Exact mechanisms are unknown yet animal models suggest that estradiol and progesterone have an effect via direct receptors in the brain and spinal cord [94, 96–98], by modulating central neuronal excitability [44, 93, 94], altering the plasticity of axonal terminals and dendritic branches [1, 94], modulating motor behavior [1], and providing neuroprotective effects and stimulating myelination [98]. Relaxin specific receptors have been found in the central nervous system [99] and relaxin-3 is a neuropeptide that functions to modulate locomotor control, working memory, attentive state, and learning [99, 100]. Additionally, in animal models, testosterone has been shown to have neuroprotective and neurotherapeutic effects in injured nervous systems [101]. Although the influences of hormones on the central and peripheral nervous systems of the pregnant female are not clearly delineated, one can speculate that during the third trimester when progesterone and testosterone peak, their neuroprotective and neurotherapeutic effects are advantageous for the female in preparation for parturition.

Pain

The main hormones that seem to influence pain in the pregnant and postpartum female are likely estrogen and relaxin with possible influence from progesterone. In observational studies of women, estrogen has been implicated in back and upper

extremity pain [73]. Young menarche age has been associated with chronic upper extremity pain [73] while prior pregnancy, young maternal age at first birth, duration of oral contraceptive use, and use of estrogens during menopause have been associated with chronic low back pain [73]. For pregnant women, it has been theorized that estrogen causes increased joint and ligamentous laxity and that this laxity then leads to greater pregnancy-related low back pain [73]. However, studies have failed to show that increased joint laxity in pregnant women is associated with serum estradiol or relaxin levels [73].

The role of relaxin for women with pelvic girdle pain has received quite a bit of attention in the literature; however, there has yet to be a consensus regarding relaxin's effects [13]. Some studies have shown a correlation between higher levels of relaxin in the third trimester of pregnancy for those with pelvic girdle pain [19, 26, 72, 102, 103], while others have failed to show any correlation between relaxin levels and pelvic girdle [14, 104, 105] or low back pain [73]. Please see subsequent chapters for further discussion regarding pelvic girdle pain.

Lastly, estrogen, progesterone, and relaxin been implicated in the etiology of increased carpal tunnel syndrome and DeQuervain's tenosynovitis during pregnancy [26, 106]. Relaxin has been thought to modify areas of the carpal tunnel causing nerve compression [107]. However, the exact role of hormonal fluctuations and these musculoskeletal injuries have not been defined. Please see additional chapters for further details regarding upper limb issues in pregnancy.

Conclusion

In this chapter, we have reviewed hormonal influences on the neuromusculoskeletal system for the pregnant and postpartum female. Although dedicated literature on pregnant women is limited, we extrapolated from research on nonpregnant females and animal models to provide a framework for the clinician. The majority of the hormones we discussed do not act in isolation but instead act in concert with other hormones and various physiologic processes occurring during pregnancy (Table 2.1). When evaluating each aspect of the neuromusculoskeletal system, it is important for the clinician to consider which trimester patients are in and therefore which hormones may have the most profound influence. Continued dedicated research on the influences of hormones on the neuromusculoskeletal system will greatly benefit clinicians of various specialties caring for pregnant and postpartum females.

Table 2.1 Effect of key sex hormones on the neuromusculoskeletal system

	Bone	Cartilage	Ligament	Myotendinous unit	CNS
Estrogen	Decreases bone resorption	Increased development and maintenance	Increased laxity	Decreased stiffness	Increased excitability
			Decreased stiffness		Increased synaptic transmission and formation
			Decreased load to failure		
Progesterone	Increases bone remodeling	Increased development and protection	Increased collagen production		Decreased excitability Neuroprotective
Testosterone	Stimulate bone formation	Protects against degradation	Increased ligament strength, contributes to increased laxity across menstrual cycle (with estrogen and progesterone)	Increases hypertrophic and hyperplastic response to resistance training	Neuroprotective
				Decreased stiffness	
Relaxin	Increases bone resorption	Decreased stiffness	Increased laxity	Decreased stiffness	Increased attentive state
			Decreased stiffness		

References

1. Heldring N, Pike A, Andersson S, Matthews J, Cheng G, Hartman J, et al. Estrogen receptors: how do they signal and what are their targets. *Physiol Rev.* 2007;87(3):905–31.
2. Ahrens KA, Vladutiu CJ, Mumford SL, Schliep KC, Perkins NJ, Wactawski-Wende J, et al. The effect of physical activity across the menstrual cycle on reproductive function. *Ann Epidemiol.* 2014;24(2):127–34. PubMed PMID: 24345590. Pubmed Central PMCID: Pmc3946734. Epub 2013/12/19. eng.
3. Peck JD, Hulka BS, Savitz DA, Baird D, Poole C, Richardson BE. Accuracy of fetal growth indicators as surrogate measures of steroid hormone levels during pregnancy. *Am J Epidemiol.* 2003;157(3):258–66. PubMed PMID: 12543626. Epub 2003/01/25. eng.
4. Draca S. Estriol and progesterone: a new role for sex hormones. *Int J Biomed Sci.* 2006; 2(4):305–7. PubMed PMID: 23674997. Pubmed Central PMCID: Pmc3614637. Epub 2006/12/01. eng.
5. O'Leary P, Boyne P, Flett P, Beilby J, James I. Longitudinal assessment of changes in reproductive hormones during normal pregnancy. *Clin Chem.* 1991;37(5):667–72. PubMed PMID: 1827758. Epub 1991/05/01. eng.
6. Moller UK, Streym S, Mosekilde L, Heickendorff L, Flyvbjerg A, Frystyk J, et al. Changes in calcitropic hormones, bone markers and insulin-like growth factor I (IGF-I) during pregnancy and postpartum: a controlled cohort study. *Osteoporos Int.* 2013;24(4):1307–20. PubMed PMID: 22855199.
7. Sowers MF, Hollis BW, Shapiro B, Randolph J, Janney CA, Zhang D, et al. Elevated parathyroid hormone-related peptide associated with lactation and bone density loss. *JAMA.* 1996;276(7):549–54. PubMed PMID: 8709404. Epub 1996/08/21. eng.
8. Clarke BL, Khosla S. Female reproductive system and bone. *Arch Biochem Biophys.* 2010;503(1):118–28. PubMed PMID: 20637179. Pubmed Central PMCID: 2942975.
9. Toriola AT, Surcel HM, Husing A, Grankvist K, Lakso HA, Schock H, et al. Association of serum 25-hydroxyvitamin D (25-OHD) concentrations with maternal sex steroids and IGF-1 hormones during pregnancy. *Cancer Causes Control.* 2011;22(6):925–8. PubMed PMID: 21387179. Pubmed Central PMCID: 3131105.
10. Abbassi-Ghanavati M, Greer LG, Cunningham FG. Pregnancy and laboratory studies: a reference table for clinicians. *Obstet Gynecol.* 2009;114(6):1326–31. PubMed PMID: 19935037. Epub 2009/11/26. eng.
11. Di Renzo GC, Mattei A, Gojnic M, Gerli S. Progesterone and pregnancy. *Curr Opin Obstet Gynecol.* 2005;17(6):598–600. PubMed PMID: 16258341. Epub 2005/11/01. eng.
12. Goldsmith LT, Weiss G, Steinetz BG. Relaxin and its role in pregnancy. *Endocrinol Metab Clin North Am.* 1995;24(1):171–86. PubMed PMID: 7781625.
13. Dehghan F, Haerian BS, Muniandy S, Yusof A, Dragoo JL, Salleh N. The effect of relaxin on the musculoskeletal system. *Scand J Med Sci Sports.* 2013 Nov 28. PubMed PMID: 24283470. Epub 2013/11/29. Eng.
14. Aldabe D, Ribeiro DC, Milosavljevic S, Dawn BM. Pregnancy-related pelvic girdle pain and its relationship with relaxin levels during pregnancy: a systematic review. *Eur Spine J.* 2012;21(9):1769–76. PubMed PMID: 22310881. Pubmed Central PMCID: 3459115.
15. Wreje U, Kristiansson P, Aberg H, Bystrom B, von Schoultz B. Serum levels of relaxin during the menstrual cycle and oral contraceptive use. *Gynecol Obstet Invest.* 1995;39(3):197–200. PubMed PMID: 7789917. Epub 1995/01/01. eng.
16. Borg-Stein JP, Fogelman DJ, Ackerman KE. Exercise, sports participation, and musculoskeletal disorders of pregnancy and postpartum. *Semin Neurol.* 2011;31(4):413–22. PubMed PMID: 22113514. Epub 2011/11/25. eng.
17. Dumas GA, Reid JG. Laxity of knee cruciate ligaments during pregnancy. *J Orthop Sports Phys Ther.* 1997;26(1):2–6. PubMed PMID: 9201635. Epub 1997/07/01. eng.
18. Eddie LW, Bell RJ, Lester A, Geier M, Bennett G, Johnston PD, et al. Radioimmunoassay of relaxin in pregnancy with an analogue of human relaxin. *Lancet.* 1986;1(8494):1344–6. PubMed PMID: 2872469.

19. Tincello DG, Teare J, Fraser WD. Second trimester concentration of relaxin and pregnancy related incontinence. *Eur J Obstet Gynecol Reprod Biol.* 2003;106(2):237–8. PubMed PMID: 12551802.
20. Bani D. Relaxin: a pleiotropic hormone. *Gen Pharmacol Vasc Syst.* 1997;28(1):13–22.
21. Schauburger CW, Rooney BL, Goldsmith L, Shenton D, Silva PD, Schaper A. Peripheral joint laxity increases in pregnancy but does not correlate with serum relaxin levels. *Am J Obstet Gynecol.* 1996;174(2):667–71. PubMed PMID: 8623804.
22. Bammann BL, Coulam CB, Jiang NS. Total and free testosterone during pregnancy. *Am J Obstet Gynecol.* 1980;137(3):293–8. PubMed PMID: 7189643. Epub 1980/06/01. eng.
23. Mizuno M, Lobotsky J, Lloyd CW, Kobayashi T, Murasawa Y. Plasma androstenedione and testosterone during pregnancy and in the newborn. *J Clin Endocrinol Metab.* 1968;28(8):1133–42. PubMed PMID: 5676177. Epub 1968/08/01. eng.
24. Voogt JL, Lee Y, Yang S, Arbogast L. Regulation of prolactin secretion during pregnancy and lactation. *Prog Brain Res.* 2001;133:173–85. PubMed PMID: 11589129. Epub 2001/10/09. eng.
25. Johnson CA. Occurrence of de Quervain's disease in postpartum women. *J Fam Pract.* 1991;32(3):325–7. PubMed PMID: 2002325. Epub 1991/03/01. eng.
26. Ireland ML, Ott SM. The effects of pregnancy on the musculoskeletal system. *Clin Orthop Relat Res.* 2000;372:169–79. PubMed PMID: 10738426. Epub 2000/03/30. eng.
27. Cushard Jr WG, Creditor MA, Canterbury JM, Reiss E. Physiologic hyperparathyroidism in pregnancy. *J Clin Endocrinol Metab.* 1972;34(5):767–71. PubMed PMID: 5012492. Epub 1972/05/01. eng.
28. Seki K, Makimura N, Mitsui C, Hirata J, Nagata I. Calcium-regulating hormones and osteocalcin levels during pregnancy: a longitudinal study. *Am J Obstet Gynecol.* 1991;164(5 Pt 1):1248–52. PubMed PMID: 2035567. Epub 1991/05/01. eng.
29. Kalkwarf HJ, Specker BL. Bone mineral changes during pregnancy and lactation. *Endocrine.* 2002;17(1):49–53. PubMed PMID: 12014704. Epub 2002/05/17. eng.
30. Grill V, Hillary J, Ho PM, Law FM, MacIsaac RJ, MacIsaac IA, et al. Parathyroid hormone-related protein: a possible endocrine function in lactation. *Clin Endocrinol (Oxf).* 1992;37(5):405–10. PubMed PMID: 1486689. Epub 1992/11/01. eng.
31. Ardawi MS, Nasrat HA, BA'Aqueel HS. Calcium-regulating hormones and parathyroid hormone-related peptide in normal human pregnancy and postpartum: a longitudinal study. *Eur J Endocrinol.* 1997;137(4):402–9. PubMed PMID: 9368509. Epub 1997/11/22. eng.
32. Wei SQ, Qi HP, Luo ZC, Fraser WD. Maternal vitamin D status and adverse pregnancy outcomes: a systematic review and meta-analysis. *J Matern Fetal Neonatal Med.* 2013;26(9):889–99. PubMed PMID: 23311886. Epub 2013/01/15. eng.
33. O'Brien KO, Donangelo CM, Zapata CL, Abrams SA, Spencer EM, King JC. Bone calcium turnover during pregnancy and lactation in women with low calcium diets is associated with calcium intake and circulating insulin-like growth factor 1 concentrations. *Am J Clin Nutr.* 2006;83(2):317–23. PubMed PMID: 16469990. Epub 2006/02/14. eng.
34. Giudice LC, Irwin JC, Dsupin BA, Pannier EM, Jin IH, Vu TH, et al. Insulin-like growth factor (IGF), IGF binding protein (IGFBP), and IGF receptor gene expression and IGFBP synthesis in human uterine leiomyomata. *Hum Reprod.* 1993;8(11):1796–806. PubMed PMID: 7507128. Epub 1993/11/01. eng.
35. Rutanen EM. Insulin-like growth factors and insulin-like growth factor binding proteins in the endometrium. Effect of intrauterine levonorgestrel delivery. *Hum Reprod.* 2000;15 Suppl 3:173–81. PubMed PMID: 11041233. Epub 2000/10/21. eng.
36. Hawsawi Y, El-Gendy R, Twelves C, Speirs V, Beattie J. Insulin-like growth factor—oestradiol crosstalk and mammary gland tumourigenesis. *Biochim Biophys Acta.* 2013;1836(2):345–53. PubMed PMID: 24189571. Epub 2013/11/06. eng.
37. Handwerker S. Clinical counterpoint: the physiology of placental lactogen in human pregnancy. *Endocr Rev.* 1991;12(4):329–36. PubMed PMID: 1662129.
38. Kedzia A, Tarka A, Petriczko E, Pruski D, Iwaniec K. Placental growth hormone (PGH), pituitary growth hormone (GH1), insulin-like growth factor (IGF-I) and ghrelin in pregnant women's blood serum. *Ginekol Pol.* 2013;84(7):620–3. PubMed PMID: 24032274. Epub 2013/09/17. eng.

39. Romani W, Patrie J, Curl LA, Flaws JA. The correlations between estradiol, estrone, estriol, progesterone, and sex hormone-binding globulin and anterior cruciate ligament stiffness in healthy, active females. *J Womens Health*. 2003;12(3):287–98.
40. Kuijper EA, Ket JC, Caanen MR, Lambalk CB. Reproductive hormone concentrations in pregnancy and neonates: a systematic review. *Reprod Biomed Online*. 2013;27(1):33–63. PubMed PMID: 23669015. Epub 2013/05/15. eng.
41. Ciocca DR, Roig LM. Estrogen receptors in human nontarget tissues: biological and clinical implications. *Endocr Rev*. 1995;16(1):35–62. PubMed PMID: 7758432. Epub 1995/02/01. eng.
42. Balasch J. Sex steroids and bone: current perspectives. *Hum Reprod Update*. 2003;9(3):207–22. PubMed PMID: 12859043. Epub 2003/07/16. eng.
43. Jarvinen TL, Kannus P, Sievanen H. Estrogen and bone—a reproductive and locomotive perspective. *J Bone Miner Res*. 2003;18(11):1921–31. PubMed PMID: 14606503. Epub 2003/11/11. eng.
44. Liu SH, al-Shaikh R, Panossian V, Yang RS, Nelson SD, Soleiman N, et al. Primary immunolocalization of estrogen and progesterone target cells in the human anterior cruciate ligament. *J Orthop Res*. 1996;14(4):526–33. PubMed PMID: 8764860. Epub 1996/07/01. eng.
45. Boyan BD, Hart DA, Enoka RM, Nicoletta DP, Resnick E, Berkley KJ, et al. Hormonal modulation of connective tissue homeostasis and sex differences in risk for osteoarthritis of the knee. *Biol Sex Differ*. 2013;4(1):3. PubMed PMID: 23374322. Pubmed Central PMCID: PMC3583799. Epub 2013/02/05. eng.
46. Silman AJ, Newman J. Obstetric and gynaecological factors in susceptibility to peripheral joint osteoarthritis. *Ann Rheum Dis*. 1996;55(9):671–3. PubMed PMID: 8882147. Pubmed Central PMCID: Pmc1010274. Epub 1996/09/01. eng.
47. Linn S, Murtaugh B, Casey E. Role of sex hormones in the development of osteoarthritis. *PM R*. 2012;4(5 Suppl):S169–73. PubMed PMID: 22632696. Epub 2012/06/01. eng.
48. Wardhana SEE, Datau EA, Ongkowijsaya J, Karema-Kaparang AM. Transdermal bio-identical progesterone cream as hormonal treatment for osteoarthritis. *Acta Med Indones*. 2013;45(3):224–32. PubMed PMID: 24045394. Epub 2013/09/21. eng.
49. Wild CY, Steele JR, Munro BJ. Why do girls sustain more anterior cruciate ligament injuries than boys?: a review of the changes in estrogen and musculoskeletal structure and function during puberty. *Sports Med*. 2012;42(9):733–49.
50. Yu WD, Panossian V, Hatch JD, Liu SH, Finerman GA. Combined effects of estrogen and progesterone on the anterior cruciate ligament. *Clin Orthop Relat Res*. 2001;383:268–81. PubMed PMID: 11210964. Epub 2001/02/24. eng.
51. Yu WD, Liu SH, Hatch JD, Panossian V, Finerman GA. Effect of estrogen on cellular metabolism of the human anterior cruciate ligament. *Clin Orthop Relat Res*. 1999;366:229–38. PubMed PMID: 10627740. Epub 2000/01/11. eng.
52. Dragoo JL, Lee RS, Benhaim P, Finerman GA, Hame SL. Relaxin receptors in the human female anterior cruciate ligament. *Am J Sports Med*. 2003;31(4):577–84. PubMed PMID: 12860548. Epub 2003/07/16. eng.
53. Beynon BD, Bernstein IM, Belisle A, Brattbakk B, Devanny P, Risinger R, et al. The effect of estradiol and progesterone on knee and ankle joint laxity. *Am J Sports Med*. 2005;33(9):1298–304. PubMed PMID: 16002485.
54. Pollard CD, Braun B, Hamill J. Influence of gender, estrogen and exercise on anterior knee laxity. *Clin Biomech (Bristol, Avon)*. 2006;21(10):1060–6. PubMed PMID: 16949187.
55. Park SK, Stefanyshyn DJ, Ramage B, Hart DA, Ronsky JL. Alterations in knee joint laxity during the menstrual cycle in healthy women leads to increases in joint loads during selected athletic movements. *Am J Sports Med*. 2009;37(6):1169–77. PubMed PMID: 19289541.
56. Shultz SJ, Gansneder BM, Sander TC, Kirk SE, Perrin DH. Absolute serum hormone levels predict the magnitude of change in anterior knee laxity across the menstrual cycle. *J Orthop Res*. 2005;24(2):124–31.
57. Slaughterbeck J, Clevenger C, Lundberg W, Burchfield DM. Estrogen level alters the failure load of the rabbit anterior cruciate ligament. *J Orthop Res*. 1999;17(3):405–8. PubMed PMID: 10376730. Epub 1999/06/22. eng.

58. Liu SH, Al-Shaikh RA, Panossian V, Finerman GA, Lane JM. Estrogen affects the cellular metabolism of the anterior cruciate ligament. A potential explanation for female athletic injury. *Am J Sports Med.* 1997;25(5):704–9. PubMed PMID: 9302481. Epub 1997/09/26. eng.
59. Hattori K, Sano H, Komatsuda T, Saijo Y, Sugita T, Itoi E. Effect of estrogen on tissue elasticity of the ligament proper in rabbit anterior cruciate ligament: measurements using scanning acoustic microscopy. *J Orthop Sci.* 2010;15(4):584–8. PubMed PMID: 20721729.
60. Beynon BD, Johnson RJ, Braun S, Sargent M, Bernstein IM, Skelly JM, et al. The relationship between menstrual cycle phase and anterior cruciate ligament injury: a case-control study of recreational alpine skiers. *Am J Sports Med.* 2006;34(5):757–64. PubMed PMID: 16436538.
61. Slauterbeck JR, Fuzie SF, Smith MP, Clark RJ, Xu KT, Starch DW, et al. The menstrual cycle, sex hormones, and anterior cruciate ligament injury. *J Athl Train.* 2002;37(3):275.
62. Griffin LY, Agel J, Albohm MJ, Arendt EA, Dick RW, Garrett WE, et al. Noncontact anterior cruciate ligament injuries: risk factors and prevention strategies. *J Am Acad Orthop Surg.* 2000;8(3):141–50. PubMed PMID: 10874221. Epub 2000/06/30. eng.
63. Smith HC, Vacek P, Johnson RJ, Slauterbeck JR, Hashemi J, Shultz S, et al. Risk factors for anterior cruciate ligament injury: a review of the literature-part 2: hormonal, genetic, cognitive function, previous injury, and extrinsic risk factors. *Sports Health.* 2012;4(2):155–61. PubMed PMID: 23016083. Pubmed Central PMCID: 3435909.
64. Arnold C, Van Bell C, Rogers V, Cooney T. The relationship between serum relaxin and knee joint laxity in female athletes. *Orthopedics.* 2002;25(6):669–73. PubMed PMID: 12083578. Epub 2002/06/27. eng.
65. Dragoo JL, Padrez K, Workman R, Lindsey DP. The effect of relaxin on the female anterior cruciate ligament: analysis of mechanical properties in an animal model. *Knee.* 2009;16(1):69–72. PubMed PMID: 18964043.
66. Dragoo JL, Castillo TN, Braun HJ, Ridley BA, Kennedy AC, Golish SR. Prospective correlation between serum relaxin concentration and anterior cruciate ligament tears among elite collegiate female athletes. *Am J Sports Med.* 2011;39(10):2175–80. PubMed PMID: 21737831.
67. Faryniarz DA, Bhargava M, Lajam C, Attia ET, Hannafin JA. Quantitation of estrogen receptors and relaxin binding in human anterior cruciate ligament fibroblasts. *In Vitro Cell Dev Biol Anim.* 2006;42(7):176–81. PubMed PMID: 16948498. Epub 2006/09/05. eng.
68. Lovering RM, Romani WA. Effect of testosterone on the female anterior cruciate ligament. *Am J Physiol Regul Integr Comp Physiol.* 2005;289(1):R15–22. PubMed PMID: 15790748. Epub 2005/03/26. eng.
69. Shultz SJ, Wideman L, Montgomery MM, Beasley KN, Nindl BC. Changes in serum collagen markers, IGF-I, and knee joint laxity across the menstrual cycle. *J Orthop Res.* 2012;30(9):1405–12. PubMed PMID: 22389002. Pubmed Central PMCID: PMC3371148. Epub 2012/03/06. eng.
70. Charlton WP, Coslett-Charlton LM, Ciccotti MG. Correlation of estradiol in pregnancy and anterior cruciate ligament laxity. *Clin Orthop Relat Res.* 2001;387:165–70. PubMed PMID: 11400878. Epub 2001/06/13. eng.
71. Marnach ML, Ramin KD, Ramsey PS, Song SW, Stensland JJ, An KN. Characterization of the relationship between joint laxity and maternal hormones in pregnancy. *Obstet Gynecol.* 2003;101(2):331–5. PubMed PMID: 12576258. Epub 2003/02/11. eng.
72. Vullo VJ, Richardson JK, Hurvitz EA. Hip, knee, and foot pain during pregnancy and the postpartum period. *J Fam Pract.* 1996;43(1):63–8. PubMed PMID: 8691182. Epub 1996/07/01. eng.
73. Wijnhoven HA, de Vet HC, Smit HA, Picavet HS. Hormonal and reproductive factors are associated with chronic low back pain and chronic upper extremity pain in women—the MORGEN study. *Spine (Phila Pa 1976).* 2006;31(13):1496–502. PubMed PMID: 16741461. Epub 2006/06/03. eng.
74. Samuel CS, Coghlan JP, Bateman JF. Effects of relaxin, pregnancy and parturition on collagen metabolism in the rat pubic symphysis. *J Endocrinol.* 1998;159(1):117–25. PubMed PMID: 9795349.
75. Hall K. The symphysis pubis in mice in which pregnancy was maintained after ovariectomy by injecting progesterone alone or with oestradiol and relaxin. *J Physiol.* 1956;134(2):3P. PubMed PMID: 13398929.

76. Blecher AM, Richmond JC. Transient laxity of an anterior cruciate ligament-reconstructed knee related to pregnancy. *Arthroscopy*. 1998;14(1):77–9. PubMed PMID: 9486338. Epub 1998/03/05. eng.
77. Bryant AL, Crossley KM, Bartold S, Hohmann E, Clark RA. Estrogen-induced effects on the neuro-mechanics of hopping in humans. *Eur J Appl Physiol*. 2011;111(2):245–52. PubMed PMID: 20857138.
78. Lemoine S, Granier P, Tiffoche C, Rannou-Bekono F, Thieulant ML, Delamarche P. Estrogen receptor alpha mRNA in human skeletal muscles. *Med Sci Sports Exerc*. 2003;35(3):439–43. PubMed PMID: 12618573.
79. Wiik A, Glenmark B, Ekman M, Esbjornsson-Liljedahl M, Johansson O, Bodin K, et al. Oestrogen receptor beta is expressed in adult human skeletal muscle both at the mRNA and protein level. *Acta Physiol Scand*. 2003;179(4):381–7. PubMed PMID: 14656376. Epub 2003/12/06. eng.
80. Wiik A, Ekman M, Morgan G, Johansson O, Jansson E, Esbjornsson M. Oestrogen receptor beta is present in both muscle fibres and endothelial cells within human skeletal muscle tissue. *Histochem Cell Biol*. 2005;124(2):161–5. PubMed PMID: 16133122. Epub 2005/09/01. eng.
81. Sinha-Hikim I, Taylor WE, Gonzalez-Cadavid NF, Zheng W, Bhasin S. Androgen receptor in human skeletal muscle and cultured muscle satellite cells: up-regulation by androgen treatment. *J Clin Endocrinol Metab*. 2004;89(10):5245–55. PubMed PMID: 15472231. Epub 2004/10/09. eng.
82. Bryant AL, Clark RA, Bartold S, Murphy A, Bennell KL, Hohmann E, et al. Effects of estrogen on the mechanical behavior of the human Achilles tendon in vivo. *J Appl Physiol*. 2008;105(4):1035–43. PubMed PMID: 18566188. Epub 2008/06/21. eng.
83. Bell DR, Blackburn JT, Norcorss MF, Ondrak KS, Hudson JD, Hackney AC, et al. Estrogen and muscle stiffness have a negative relationship in females. *Knee Surg Sports Traumatol Arthrosc*. 2012;20(2):361–7. PubMed PMID: 21695466. Epub 2011/06/23. eng.
84. Eiling E, Bryant AL, Petersen W, Murphy A, Hohmann E. Effects of menstrual-cycle hormone fluctuations on musculotendinous stiffness and knee joint laxity. *Knee Surg Sports Traumatol Arthrosc*. 2007;15(2):126–32. PubMed PMID: 16821077.
85. Hansen M, Koskinen SO, Petersen SG, Doessing S, Frystyk J, Flyvbjerg A, et al. Ethinyl oestradiol administration in women suppresses synthesis of collagen in tendon in response to exercise. *J Physiol*. 2008;586(Pt 12):3005–16. PubMed PMID: 18420709. Pubmed Central PMCID: 2517199.
86. Casey E, Hameed F, Dhaher YY. The muscle stretch reflex throughout the menstrual cycle. *Med Sci Sports Exerc*. 2014;46(3):600–9. PubMed PMID: 24091990. Pubmed Central PMCID: Pmc3944642. Epub 2013/10/05. eng.
87. Hansen M, Couppe C, Hansen CS, Skovgaard D, Kovanen V, Larsen JO, et al. Impact of oral contraceptive use and menstrual phases on patellar tendon morphology, biochemical composition, and biomechanical properties in female athletes. *J Appl Physiol*. 2013;114(8):998–1008.
88. Burgess KE, Pearson SJ, Onambélé GL. Patellar tendon properties with fluctuating menstrual cycle hormones. *J Strength Cond Res*. 2010;24(8):2088–95.
89. Hansen M, Langberg H, Holm L, Miller BF, Petersen SG, Doessing S, et al. Effect of administration of oral contraceptives on the synthesis and breakdown of myofibrillar proteins in young women. *Scand J Med Sci Sports*. 2011;21(1):62–72. PubMed PMID: 19883384.
90. Dedrick GS, Sizer PS, Merkle JN, Hounshell TR, Robert-McComb JJ, Sawyer SF, et al. Effect of sex hormones on neuromuscular control patterns during landing. *J Electromyogr Kinesiol*. 2008;18(1):68–78. PubMed PMID: 17079166.
91. Pearson SJ, Burgess KE, Onambélé GL. Serum relaxin levels affect the in vivo properties of some but not all tendons in normally menstruating young women. *Exp Physiol*. 2011;96(7):681–8. PubMed PMID: 21478257. Epub 2011/04/12. eng.
92. Rahman F, Christian HC. Non-classical actions of testosterone: an update. *Trends Endocrinol Metab*. 2007;18(10):371–8. PubMed PMID: 17997105.

93. Smith SS, Woolley CS. Cellular and molecular effects of steroid hormones on CNS excitability. *Cleve Clin J Med*. 2004;71 Suppl 2:S4–10. PubMed PMID: 15379294. Epub 2004/09/24. eng.
94. Finocchi C, Ferrari M. Female reproductive steroids and neuronal excitability. *Neurol Sci*. 2011;32 Suppl 1:S31–5. PubMed PMID: 21533709. Epub 2011/05/06. eng.
95. Papka RE, Srinivasan B, Miller KE, Hayashi S. Localization of estrogen receptor protein and estrogen receptor messenger RNA in peripheral autonomic and sensory neurons. *Neuroscience*. 1997;79(4):1153–63. PubMed PMID: 9219974. Epub 1997/08/01. eng.
96. Cardona-Rossinyol A, Mir M, Caraballo-Miralles V, Llado J, Olmos G. Neuroprotective effects of estradiol on motoneurons in a model of rat spinal cord embryonic explants. *Cell Mol Neurobiol*. 2013;33(3):421–32. PubMed PMID: 23322321. Epub 2013/01/17. eng.
97. Vanderhorst VG, Terasawa E, Ralston 3rd HJ. Estrogen receptor-alpha immunoreactive neurons in the brainstem and spinal cord of the female rhesus monkey: species-specific characteristics. *Neuroscience*. 2009;158(2):798–810. PubMed PMID: 18996446. Epub 2008/11/11. eng.
98. Labombarda F, Meffre D, Delespierre B, Krivokapic-Blondiaux S, Chastre A, Thomas P, et al. Membrane progesterone receptors localization in the mouse spinal cord. *Neuroscience*. 2010;166(1):94–106. PubMed PMID: 20025939. Epub 2009/12/23. eng.
99. Smith CM, Ryan PJ, Hosken IT, Ma S, Gundlach AL. Relaxin-3 systems in the brain—the first 10 years. *J Chem Neuroanat*. 2011;42(4):262–75. PubMed PMID: 21693186. Epub 2011/06/23. eng.
100. Callander GE, Bathgate RA. Relaxin family peptide systems and the central nervous system. *Cell Mol Life Sci*. 2010;67(14):2327–41. PubMed PMID: 20213277. Epub 2010/03/10. eng.
101. Wilson RE, Coons KD, Sengelaub DR. Neuroprotective effects of testosterone on dendritic morphology following partial motoneuron depletion: efficacy in female rats. *Neurosci Lett*. 2009;465(2):123–7. PubMed PMID: 19735695. Pubmed Central PMCID: PMC2755210. Epub 2009/09/09. eng.
102. MacLennan AH, Nicolson R, Green RC. Serum relaxin in pregnancy. *Lancet*. 1986;2(8501):241–3. PubMed PMID: 2874276.
103. MacLennan AH. The role of the hormone relaxin in human reproduction and pelvic girdle relaxation. *Scand J Rheumatol Suppl*. 1991;88:7–15. PubMed PMID: 2011710. Epub 1991/01/01. eng.
104. Petersen LK, Hvidman L, Ulbjerg N. Normal serum relaxin in women with disabling pelvic pain during pregnancy. *Gynecol Obstet Invest*. 1994;38(1):21–3. PubMed PMID: 7959320.
105. Bjorklund K, Bergstrom S, Nordstrom ML, Ulmsten U. Symphyseal distention in relation to serum relaxin levels and pelvic pain in pregnancy. *Acta Obstet Gynecol Scand*. 2000;79(4):269–75. PubMed PMID: 10746841. Epub 2000/04/04. eng.
106. Schned ES. DeQuervain tenosynovitis in pregnant and postpartum women. *Obstet Gynecol*. 1986;68(3):411–4. PubMed PMID: 3488531. Epub 1986/09/01. eng.
107. Massey EW. Carpal tunnel syndrome in pregnancy. *Obstet Gynecol Surv*. 1978;33(3):145–8. PubMed PMID: 343016. Epub 1978/03/01. eng.

Chapter 3

Musculoskeletal Imaging in the Pregnant and Postpartum Patient

Catherine J. Brandon

Introduction

Musculoskeletal (MSK) imaging in the pregnant and postpartum patient is not a well-established body of knowledge. Instead, there are numerous case reports and short discussions on isolated topics in the imaging and nonimaging literature. However, the spectrum of MSK pathology experienced by the pregnant and postpartum patient is truly vast and is encountered by a wide array of primary care providers and subspecialties. One of the major contributions imaging can provide to any clinical field is to narrow the diagnosis and point to the most appropriate clinical treatment algorithms and subspecialty referrals [1]. Since treatment plans can diverge based on the specific structures involved, the accurate localization of an injury site and determination of its severity and extent can aid clinical management. For the pregnant and postpartum patient with clinically challenging physical findings, the systematic application of ultrasound (US) and MSK magnetic resonance imaging (MRI) techniques may discover patterns of pathophysiology underlying the symptoms and help development of new clinical management strategies.

Safety of Imaging Modalities and Indications for Use

MRI is the modality of choice for most complex MSK pathology. Although MRI has not demonstrated any deleterious effects on the fetus, the complete safety of MRI during pregnancy has yet to be established. Elective studies should be considered

C.J. Brandon, MD, MS (✉)

Department of Radiology, University of Michigan, 1500 E Medical Center Drive,
SPC 5326, Taubman Center, Room 2910D, Ann Arbor, MI 48109-5326, USA
e-mail: catbrand@umich.edu

only during the first trimester when the benefits outweigh the risk, according to the recommendation of the International Commission on Non-Ionizing Radiation Protection. The American College of Radiology recommends the potential benefits for the mother and fetus must always outweigh the risks during pregnancy [2, 3]. The potential for harm to the fetus comes from possible heating effects of the radio-frequency pulses and from damaging acoustic noise. No significant temperature changes have been recorded with 1.5 Tesla magnets [2, 4]. Contraindications to MRI because of the risk to devices in the magnetic field include most pacemakers and several types of indwelling shunts and stimulators. Because metal can produce severe MRI artifacts, large orthopedic plates in the field of view can limit imaging. Hardware that is screwed into the bone or scarred in typically will not move or cause a problem during the scanning. All patients will have to answer detailed questionnaires on metal devices and if the patient or referring clinician has questions, every MRI facility has someone assigned to research the specific device and make safety recommendations.

In MSK imaging, intravenous contrast agents are not routinely used in either computed tomography (CT) or MRI. Intravenous contrast agents such as the gadolinium-based ones for MRI and iodinated agents for CT have been studied for possible teratogenic effects. Iodinated agents theoretically may pose some risk, not yet demonstrated, to the fetal thyroid and their use is recommended only as needed for the pregnant patient. Gadolinium agents have been shown to have teratogenic effects to the fetus in animal models after high and repeated doses. Therefore, the American College of Radiology recommends gadolinium agents are used with extreme caution during pregnancy and only if the benefit to the mother overwhelmingly outweighs the theoretic risks to the fetus [2–4]. In the lactating postpartum patient less than 1 % of the intravenous maternal dose of gadolinium used for MRI studies and iodinated contrast agents for CT studies are excreted into the breast milk. Less than 1 % of these contrast agents in the breast milk are absorbed by the infant. These levels have not been showed to have any toxic effect [3, 4]. If the mother is concerned, she could pump and discard breast milk for 24 h after receiving these contrast agents [4].

Conventional radiography generally is the first modality for imaging the MSK system, especially in the setting of acute skeletal trauma. Even during pregnancy, conventional radiography with appropriate shielding and dose reduction techniques poses no harm, especially of the extremities [3, 4]. All radiology facilities should have a written policy for screening and management of pregnant or possibly pregnant women which often includes pregnancy testing before any imaging with ionizing radiation [2, 3]. Dose reduction protocols developed in consultation with a medical physicist already should be established for more routine indications in keeping with the principle of ALARA (as low as reasonably achievable) exposure to ionizing radiation [2, 3].

While CT remains an essential imaging modality in the pelvis for viscera and acute traumatic bony assessment, its use in routine MSK imaging is less common than in body imaging. Typically it is used for preoperative orthopedic planning. Certainly the concern for radiation dose to the more radiosensitive fetal tissue limits its use in the pregnant patient to situations in which the clinical indications outweigh

the potential fetal risks. If CT is used, there are several radiation dose reduction methods that can be implemented reducing dose without compromising quality in selected situations far below those doses given in standard “lookup tables” [2, 4]. Consultation with a medical physicist can provide an estimation of the fetal dose if needed as in patients undergoing trauma surgery [3].

In general, US is the imaging modality of choice for visceral pelvic imaging in the pregnant patient and for assessment of the fetus. Ultrasound is used in many settings for evaluating superficial muscle, tendon and ligament injuries as well as assessment of anterior abdominal wall injuries and groin hernias [5]. Its use in deep pelvic MSK evaluation is limited by the overlying soft tissues, which attenuate the beam before it can penetrate to the joints. CT is used in acute pelvic trauma for orthopedic evaluation and for preoperative planning such as detecting intra-articular bony fragments, fracture alignment, or extent of arthritic changes.

MSK MRI sequences are not the same as those used in body imaging. Conventional T1-weighted images depict normal anatomical structures of bones, muscles, and tendons, and can also demonstrate certain results of trauma or degenerative changes such as sclerosis or extensive fat within the bone marrow [6]. Unfortunately most standard sequences including T1- and T2-weighted sequences cannot distinguish between normal fat and small amounts of fluid or edema, which are sensitive indicators of MSK pathology. Specifically tailored fluid-sensitive sequences such as STIR (short tau inversion recovery) or T2-weighted, fat-suppressed (fat-saturated) images are used in MSK MRI to detect fluid or edema not seen with other sequences [7]. Increased fluid or edema is nonspecific and occurs in the setting of trauma, infection, inflammation, malignancy, and compression. Combining the image appearance with the clinical setting aids the diagnosis (Fig. 3.1). While T2-weighted images are obtained to show large volumes of fluid, the T2 fat suppression technique typically is not applied in body imaging so that many MSK injuries go undetected. Currently most clinical work is now performed in “high field-strength magnets” of 1, 1.5, or 3 Tesla, all of which can support the techniques necessary for fluid-sensitive sequences.

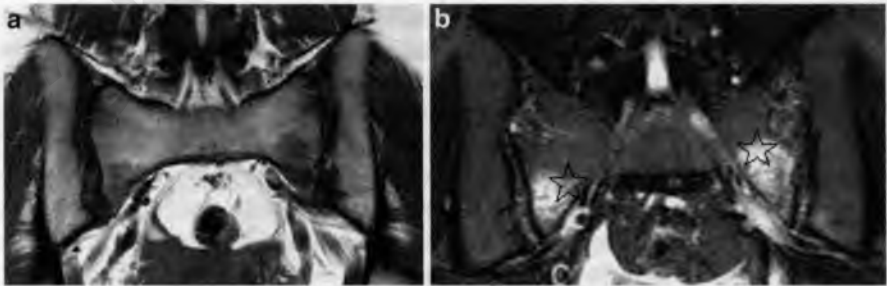


Fig. 3.1 A 29-year-old woman, 3 months postpartum vacuum-assisted vaginal delivery presenting with pelvic girdle pain syndrome and known pubic diastasis. MRI imaging of the sacrum and SI joints with (a) axial T1 sequence and (b) axial T2 fat saturation sequence show how bilateral bone stress injuries (*star*) of the sacral ala as best demonstrated on fluid-sensitive sequence (b)

General Pelvic Pain Syndromes Associated with Pregnancy

In the literature and as discussed throughout this text, there are numerous clinical presentations and proposed pathological mechanisms for pregnancy-related pelvic and back pain including symphysis pubis dysfunction [8], symphyseal pelvic dysfunction [9], pelvic joint syndrome [10], and the more restrictive pregnancy-related pelvic girdle pain [11] or MSK pelvic floor pain [12]. About half of women report pelvic pain during pregnancy and in the early postpartum period with about 6 % describing the pain as severe, limiting activities. Resolution of symptoms may take as long as 6 months or persist for years in a minority [9, 13]. A clinical division of pregnancy-related pelvic pain into groups discovered that 62 % had pain for less than 1 month after delivery but that 21 % of those with pelvic girdle pain still had pain at 2 years [13].

There are many excellent reviews of the physical findings and possible anatomic bases for pelvic pain but they are often limited in their discussion of imaging [11, 12, 14, 15]. Even MRI-based postpartum anatomical studies have used only standard body anatomical sequences [16–20]. It is not surprising that studies evaluating MRI in the assessment of pelvic pain syndromes have found MRI to be limited [21] or frankly nondiagnostic [10]. Studies of MRI imaging of maternal disease of the abdomen and pelvis during pregnancy and postpartum period in the radiological literature typically do not discuss the MSK system [4, 22] and do not discuss any STIR or T2 fat suppression sequences [2, 23]. It is apparent that better assessment techniques for these MSK syndromes are needed to understand the subcategories of pathological change and to direct development of appropriate treatment regimens.

Imaging Spine and Back

About half of women reported low back pain during pregnancy [24, 25]. Subdividing patients by clinical presentation into groups with typical lumbar pain, pelvic girdle pain, and combined lumbar and pelvic girdle pain has enabled a more nuanced approach to pregnancy-related pain [13, 25–27]. While pelvic girdle pain is closely linked to pregnancy, typical lumbar pain is not as closely connected [25, 28]. According to the American College of Radiology Appropriateness Criteria on Low Back Pain [29], uncomplicated acute low back pain or radiculopathy are benign, self-limited conditions that do not warrant any imaging studies [29]. Nonspecific lumbar disc abnormalities are common on MRI especially with STIR or T2 fat suppression sequences, even in asymptomatic patients [29]. Degenerative changes in the lumbar spine may be preset in up to 40 % of patients under 30 years of age and transitional anatomy is seen in about 4 % of the population [30, 31]. Indications of a more complicated status, “red flags,” include significant trauma, focal neurological deficit with progression or disabling symptoms, unexplained weight loss or fever, immunosuppression, prolonged use of corticosteroids, osteoporosis, and duration >6 weeks [29].

MRI of the lumbar spine is the initial imaging modality of choice in complicated low back pain including acute back pain with new radiculopathy since these symptoms suggest the presence of nerve root compression [29]. Urgent MRI is indicated for caudal equina syndrome with bilateral leg involvement, paralysis, and bladder or bowel dysfunction or any other spinal cord compression lesion [25] or in the setting of suspected epidural abscess [32]. Pregnancy-associated osteoporotic compression fractures are reported presenting with sudden onset of severe back pain [25]. While complications derived from obstetric anesthesia are very uncommon, unusual back pain after neuraxial anesthesia should be thoroughly investigated for possible epidural hematoma or abscess. In the case of anterior spinal artery syndrome of cord ischemia, diffusion-weighted MRI is necessary to diagnose early stage acute cord ischemia [32]. Care should be taken to consider a stress fracture or an indolent presentation of infection in cases of low back pain as well.

Stress Injuries and Fractures

The clinical diagnosis of bone stress injuries is difficult and tends to be nonspecific since symptoms are often insidious and diffuse [33]. With the advent of MSK MRI, bone stress injuries and fractures now are recognized to underlie a wide range of injuries and pain syndromes. Plain radiography is not sensitive to early or mild stress injuries and may appear normal even with complete fractures in the sacrum and pelvis. Stress injuries can be grouped into two types. The first are fatigue injuries/fractures caused by abnormal strenuous, repetitive, muscular or mechanical stress applied to a normal bone. The mechanical stresses of pregnancy including the altered biomechanics from supporting an enlarged uterus and the stresses of gait alterations as well as those of delivery could precede this type of injury. The second are insufficiency injuries/fractures caused by normal or physiological muscular or mechanical stress applied to a bone deficient in mineral or elastic resistance [33–35]. Bone mineral density decreases during pregnancy and some women do become osteopenic during pregnancy and the postpartum period [36]. Persistent overuse of bone unaccustomed to these new forces causes microscopic trabecular fractures, which will appear as bone marrow edema, stress injury. While these injuries can repair over a total of 90 days, if the mechanical stress continues they can progress to complete cortical failure, stress fracture [34, 35]. Radiography missed all the insufficiency fractures in the femur, sacrum, and iliac bones in one series of patients with osteomalacia [37] and 78 % on the initial assessment in collegiate track and field athletes [38]. Traditionally, nuclear medicine bone scintigraphy was used to diagnose stress injuries and while it is sensitive; it is also nonspecific and involves radiation. Even in the early onset of stress injuries, MSK MRI has the best combined specificity and sensitivity and is the recommended diagnostic imaging test to assess bone injuries and associated soft-tissue damage in symptomatic patients [34, 38]. MRI also can follow stress injuries and fractures to resolution and monitor response to treatment [34, 37, 38].

In one prospective study of college athletes, the MRI grade of bone stress injuries and the total-body bone mineral density (BMD) emerged as significant and independent predictors of time to return to sports, or clinical healing, with higher-grade MRI appearance and lower BMD having longer recovery periods [38]. Subtle bone marrow edema can be seen in normal controls and low-grade bone marrow edema can be seen in asymptomatic competitive athletes after heavy training [6]. Women athletes had higher-grade injuries than men and longer times to recovery, especially if they had poor nutrition or altered hormonal status. Higher-grade bone injuries were associated with prolonged time to return to sport especially in predominately trabecular sites of the femoral neck, pubic bone, and sacrum. On average, return to play ranged from 11 weeks in the lower grades to 19 weeks for intense bone marrow pattern and 32 weeks for stress fractures [38]. The incidence of pelvic and proximal femur stress injuries was significantly higher in women than men in an MRI evaluation of military recruits in Finland [33]. Most patients with mild stress injuries clinically heal in 6–8 weeks with rest but certain sites such as the pubic ramus may require 2–5 months [34].

Pregnancy-Related Stress Injuries

The three sites of stress injury found in the study on college athletes and military recruits; femoral neck, pubic bone, and sacrum [33, 38], are the three sites where stress injuries/fractures are associated with pregnancy and the early postpartum period. Stress injuries in the sacrum and pubic ramus are considered low-risk stress fractures and are less likely to go on to complete cortical fracture, delayed union or nonunion [39]. While sacral injuries/fractures are described as a “rare condition” among pregnant or postpartum patients [40, 41], their true incidence may be masked by their subtle and nonspecific clinical presentations and by the lack of appropriate MRI evaluation. In case reports of patients presenting with low back pain including radicular symptoms between 3 days and 6 months post vaginal or cesarean delivery, sacral fractures are seen with MRI using T2 fat suppression sequences [40–46]. One patient presented with lower back and buttock pain following cesarean delivery and developed bilateral sacral fractures, the second fracture 6 weeks after the first [47]. Several patients had osteoporosis related to pregnancy [41, 45], or heparin therapy [43] but not in all patients had abnormal BMD [44]. Treatment varied but resulted in resolution of symptoms with recommendations for early rehabilitation and physiotherapy. A pregnant patient with bilateral sacral stress fractures detected with MRI was managed with an epidural catheter for pain control and delivered vaginally [48]. Currently, little is known about the frequency, clinical presentation, and timing of these stress injuries. Clinicians should consider sacral fractures in women presenting with sudden onset of low back and pelvic pain with or without symptoms of lumbar radiculopathy [43, 46] (see Chap. 10).

Postpartum stress injuries/fractures also are seen in the pubic symphysis and pubic ramus. Postpartum stress injuries were seen in 68 % of 19 symptomatic and

asymptomatic women at 2 weeks compared with none in controls [21], in 86 % of symptomatic and 76 % of asymptomatic out of a total 56 vaginally delivered women at 2 weeks [49] and in 61 % of 77 women in both vaginal and cesarean groups at 6 weeks [50]. Both bilateral and unilateral stress injuries occurred predominately in the parasymphyseal pubic bone. Parasymphyseal stress fractures were seen in only high-risk women (17/45) and those with prolonged labor prior to cesarean delivery (4/14) [50] with healed fractures seen at 6 months [51]. None had adductor or rectus abdominis tendinopathy or “secondary cleft-sign” [50]. Parasymphyseal pubic and sacral stress fractures were reported in women with classic insufficiency fractures [52] and in the repetitive stress pathology of osteitis pubis [53]. Pubic ramus fractures are more common in women, tend to present with perineal pain [35] and were reported in one postpartum series [50].

Painful stress injuries in the hip (see Chap. 8) include classic proximal femoral stress fractures typically along the medial cortex of the femoral neck and the poorly understood entity of transient osteoporosis of the hip. However, because of the risk of progression to complete displaced femoral fracture, they are considered high-risk stress injuries [54] and should be referred for orthopedic management. Pregnant and postpartum patients with hip stress fractures and transient osteoporosis had concurrent osteopenia or osteoporosis [55, 56]. Stress fractures of the femoral head and proximal femur may be unremarkable on radiography but with MRI they look like any other stress fracture with bright, increased signal on fluid-sensitive sequences with a linear band of low signal at the actual fracture line on T1-weighted sequences. They can occur associated with pregnancy [56] and with transient osteoporosis of the hip [55]. Transient osteoporosis or transient bone marrow edema of the hip was first described during pregnancy (see Chap. 8) and most women are pregnant at the time of diagnosis [55] but it is most prevalent in middle-aged men [57, 58]. All present with hip pain and should be worked up following the appropriateness criteria for acute hip pain, radiography followed by MRI if necessary [59]. Radiography may initially be normal but progresses to pronounced osteopenia of the femoral head and neck with a normal appearing joint space. It is bilateral in up to 40 % [55, 57, 58, 60]. MRI of transient osteoporosis of the hip during pregnancy shows bone marrow edema without cortical breakage and without linear T1 fracture lines [55, 57, 60, 61] in patients with TOP. The appearance improves dramatically in the early postpartum period [55, 57, 61] with both pregnancy-related and general transient osteoporosis typically resolved with normal MRI in 4–10 months [61]. Treatment focuses on restricted weight bearing to avoid progression to stress fractures, analgesic medication, and physical therapy. More aggressive management includes postpartum open reduction internal fixation with a muscle–pedicle bone graft to prevent progression and improve pain management [58, 61]. Patients that have progressed to displaced fracture which may require total hip arthroplasty [60].

Additional sites of stress injuries include postpartum proximal tibial stress fractures associated with postpartum osteoporosis [62], a common site of low-risk stress fractures [39]. Bilateral transient osteoporosis of the talus during pregnancy with classic MRI appearance presented with severe bilateral foot and ankle pain [63] in a patient who reported similar pain with prior pregnancies. The talus is considered

a site for high-risk stress fractures with increased risk of progression to complete cortical fracture, delayed union, or nonunion [39]. Osteonecrosis or avascular necrosis of the femoral head can be associated with pregnancy without any other known risk factor [24]. It has the same classical features on MRI with fluid-sensitive sequences as seen in the common form: subchondral collapse of dark avascular bone at the superior weight bearing surface of the head with a geographic pattern bordered by a double-line sign of serpiginous, bright increased signal in a zone of attempted healing. There is often surrounding bone marrow edema extending down the femoral neck [57, 61].

Pubic Symphysis Separation and Injuries

Nonspecific pubic pain occurs in approximately 1–16 % of women after childbirth and may cause disability for prolonged periods of time after delivery [64]. Such pain may start in the first delivery with recurrence rates of up to 85 % in subsequent pregnancies [8]. In one study all women with only pubic symphysis pain had resolution by 6 months [13] although pubic pain may be part of more persistent syndromes. Imaging modalities utilized for evaluation of the pubic region include US to measure the width along the superior margin of the symphysis and CT in the postpartum period to exclude displaced fractures and associated SI joint diastasis [64, 65]. In some recent case studies of complex pubic symphysis diastasis, imaging has been limited to radiography [66–68], CT [64, 65, 69] or US [70, 71]. A classic MRI study of peripartum rupture of the pubic symphysis did not use fluid-sensitive sequences [72]. MSK MRI is the modality of choice (Fig. 3.1) and can demonstrate associated soft-tissue injuries such as the bladder and urethra, as well as ligaments, bone marrow, and cortical bone [50, 52, 53]. MRI of the pelvis can be diagnostically useful in nonspecific chronic pubic and groin pain to exclude important causes of referred pain such as labral tear of the hip, various bursitis, sacroiliitis, lumbar disc disease, and pelvic soft-tissue pathology especially in women [6].

Pubic separation and diastasis are important distinct diagnoses. Simply measuring pubic separation during pregnancy and postpartum has not provided insights into the pathophysiology underlying anterior pubic pain [70]. Diagnosis of pubic symphysis diastasis, separation over 10 mm, combines clinical symptoms of severe focal pain and conventional radiography. Normal pubic symphysis measurements vary [73] but by MRI the width is 2–3 mm, expanding up to 8 mm during pregnancy with return to normal 3 mm seen postpartum by 6 weeks [50] and between 4 and 12 weeks [21]. Measurements of interrectus abdominis distance by US do not return to normal width at 6 months [74] or by 12 months [75]. Pubic widening of more than 10 mm by radiography typically corresponds to the appearance of symptoms secondary to ligamentous rupture and instability [65, 69, 72]. Women with clinical symptoms of diastasis and MRI findings of pubic symphysis disruption including capsule rupture and fluid dissection have been reported with only 7 mm of interpubic gap [21], 9 mm gap [72], and with 7 mm gap in one case without clinical history [50]. There is no strong

correlation with the size of diastasis and severity of symptoms [64, 70, 71]. Management and treatment requires a multidisciplinary approach involving obstetrics, orthopedic surgery, and physical therapy with the latter contributing to increased strength, decreased pain, and more rapid recovery [64, 68]. Orthopedic management often is sought in patients with separation over 4 cm [64, 69, 76] since it can be associated with SI joint injury [65] which may cause chronic, persistent symptoms related to the posterior sacroiliac disruption [77], but diastasis of even 2.5 cm apparently can have SI (sacroiliac) ligament damage [69]. There appears to be a high recurrence risk of diastasis, up to 50 % for future vaginal deliveries [64].

The recent interest in MSK MRI evaluation of pubic symphysis pain in athletes, which accounts for 2–5 % of all sports injuries, has begun to clarify the clinical syndromes of “athletic pubalgia,” “chronic exertional groin pain,” and “sports hernia,” which refer to numerous overlapping injuries and have resulted in conflicting recommendations for management. Tailored imaging protocols provided new insights into the functional anatomy and injury patterns as well as selected treatment strategies [1, 78–83]. Two patterns of tendon stress injuries were demonstrated involving the adductor tendons [78, 79, 83] and the rectus abdominis tendons [1, 82, 83]. For adductor tendon injuries, physiotherapy increased core stability and decreased symptoms [79], while rectus abdominis insertional injuries and combined injuries were treated surgically [1, 80, 83]. Tendon tears through the joint capsule into the central joint space formed a “secondary cleft-sign” which correlated with the side of symptoms and was relieved with injection of steroids and local anesthesia [78, 79]. Distinguishing between patients with and without insertional tendon injuries is important for treatment selection. In a heterogeneous group of patients with pubic pain, including pregnancy-related pubic pain, the patients did not benefit from corticosteroid injections of the pubic region [84]. In an evaluation of postpartum stress injuries and soft-tissue damage, none of the women had adductor or rectus abdominis tendinopathy or “secondary cleft-sign” [50]. It appears that optimal treatment modalities may be dependent on understanding specific patterns of local injury (Fig. 3.2).

Osteitis Pubis

The term “osteitis pubis” is nonspecific, referring to a painful pubic symphysis with radiographic joint changes including parasymphyseal sclerosis, cortical irregularities, and osteophyte formation. According to the surgical literature, it can be seen in at least three groups, including elite athletes, patients with prior symphyseal osteomyelitis or septic arthritis, and “others” including postpartum [85]. Increased instability of the symphysis from injury at childbirth is a well-known etiology. Flamingo radiographic views, alternating–single-leg-stance views, can demonstrate instability of the symphysis by measurement of translation and provide a dynamic picture by stressing the pubic symphysis with vertical shear and compression forces [76, 86]. While general studies give upper limits of normal at 2 mm of translation [87], multiparous women have significantly more translation

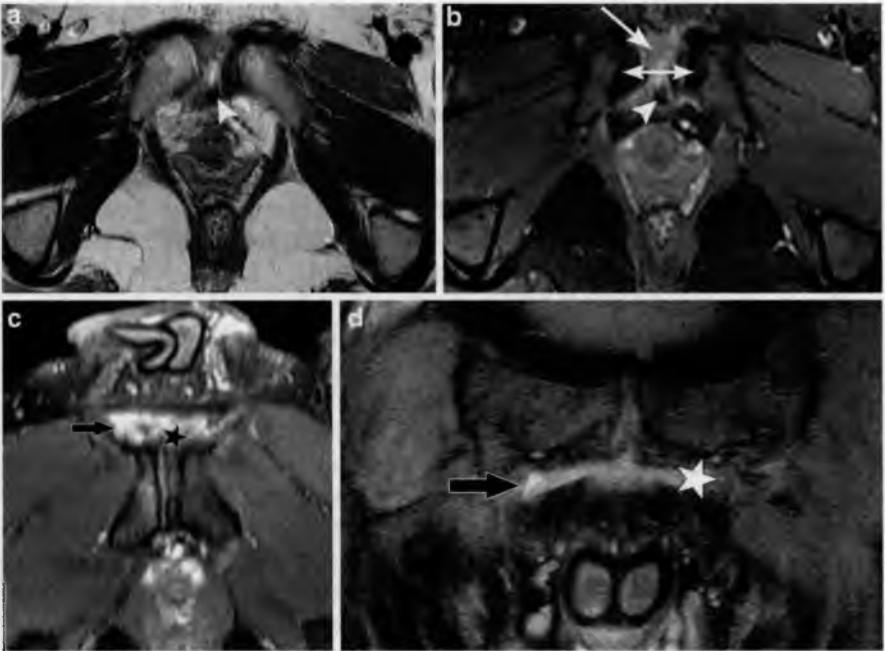


Fig. 3.2 Comparison of pubic symphysis capsular injuries seen postpartum (a, b) with chronic exertional groin pain (c, d). A 29-year-old woman, 3 months postpartum vacuum-assisted vaginal delivery presenting with pelvic girdle pain syndrome and known pubic diastasis, same patient as in Fig. 3.1. MRI imaging of the pubic symphysis and pelvic floor with (a) axial T1 sequence and (b) axial T2 fat saturation demonstrate diastasis of the pubic symphysis (double headed arrow) with posterior displacement of the central fibrocartilaginous disc (arrowhead) and fluid present within the disrupted symphysis (arrow). There are no tears of the muscle insertions. A 28-year-old male soccer player and long distance runner presents with pubic symphysis injuries and a normal pelvic radiography. MRI imaging of the pubic symphysis with (c) axial T2 fat saturation sequence and (d) coronal T2 fat saturated sequence demonstrate right adductor insertional tendon injury (black arrow) and tear of the combined aponeurosis of the rectus abdominis tendon, adductor tendon, and anterior pubic symphysis capsule (star)

(3.1 mm) than nulliparous women (1.6 mm) and men (1.4 mm), with increasing measurements associated with increased number of pregnancies [86]. Women athletes with osteitis pubis before pregnancy can have severe onset of pain soon after returning to their sport postpartum [53] (Fig. 3.3). Bone biopsies in athletes with chronic groin pain and osteitis pubis by imaging all demonstrated new woven bone consistent with chronic reparative process and without evidence of infection, necrosis, or inflammation [88]. Potential explanations of osteitis pubis include repetitive fatigue loading, insertional enthesopathy, and prior unrecognized pubic symphysis joint disruption [53, 82, 87–89].

On MSK MRI in acute cases there is diffuse parasymphyseal marrow edema, often profound, with symphyseal fluid and peripubic soft-tissue edema which are not seen by CT and radiography [52, 87, 89]. Insufficiency fractures can be seen

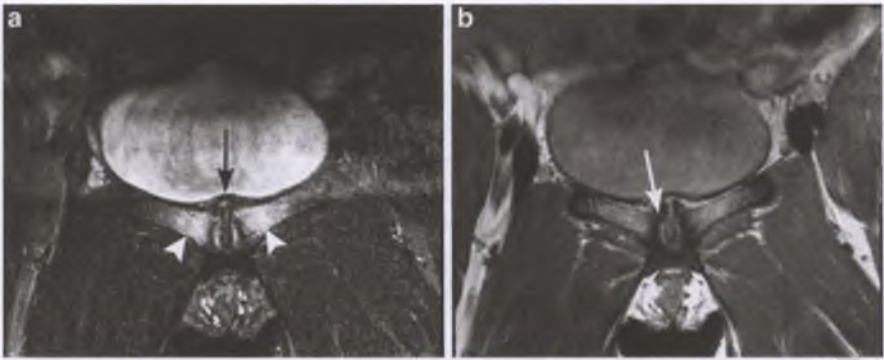


Fig. 3.3 A 30-year-old woman, 6 months after first birth by cesarean section now presents with increasing pubic pain. MRI of the pubic symphysis with (a) coronal STIR demonstrates joint line sclerosis and osteophyte formation (*black arrow*) and bright bone marrow edema from stress injury (*white arrowhead*) consistent with osteitis pubis. Standard body sequence (b) coronal T1 demonstrates only the parasymphyseal sclerosis and osteophyte formation (*white arrow*). The patient had returned to active soccer playing and complained of increased pubic pain now greater than before pregnancy. Postpartum athletes with osteitis pubis before pregnancy can have severe onset of pain soon after returning to their sport [53]

acutely [53]. When symptoms are chronic, greater than 6 months, there is subchondral sclerosis, subchondral resorption, bony margin irregularities, and osteophytes, matching the CT and radiographic appearance [89]. In athletes osteitis pubis may or may not be associated with adductor and/or rectus abdominis tendon injuries and a secondary cleft-sign, but generally the soft-tissue injuries are thought to precede the joint changes [1, 78, 79, 83, 87, 89]. Athletes also have associated increased degenerative changes in the SI joints and even sacral fractures probably due to the abnormal stresses around the pelvic ring [90]. Most osteitis pubis patients, those without true infection, are conservatively managed and respond best if diagnosed earlier [91, 92]. A small percentage respond to symphyseal injections especially if treated early, less than 2 weeks after onset of symptoms [83, 91]. Although osteitis pubis is considered self-limiting [52], chronic osteitis pubis patients generally improve or completely resolve after surgical repair to stabilize the joint [53, 91], with the best results seen in athletes and a more unpredictable outcome in the postpartum group [85]. Actual pubic infection, a topic of considerable concern for the postoperative urinary incontinence patient, is discussed later in the section on infections.

Osteitis Condensans Ilii

Osteitis condensans ilii is another older descriptive radiographic term denoting bilateral, symmetrical, dense bone formation in a triangular pattern along the anterior-inferior iliac side of the SI joint seen on radiography, CT, and MRI (Fig. 3.4).

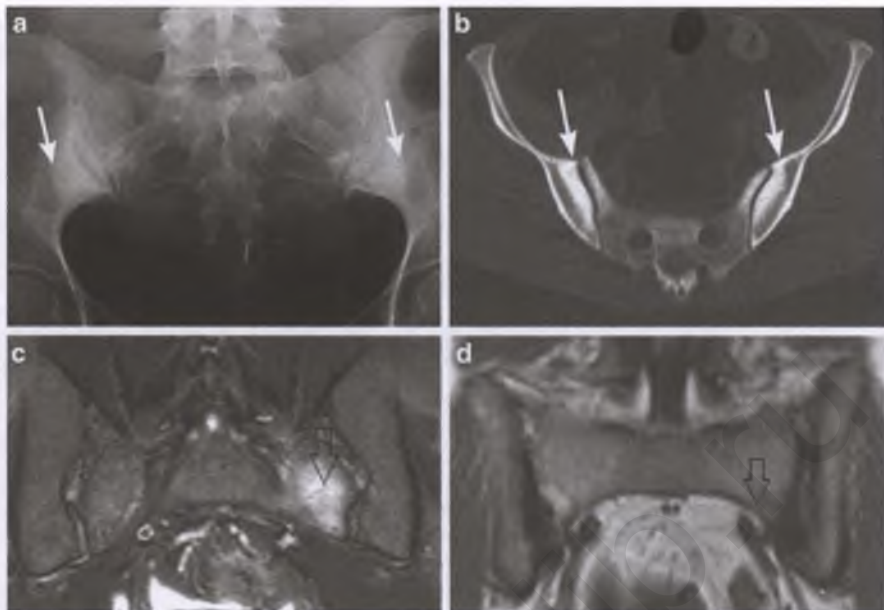


Fig. 3.4 A 36-year-old woman presenting with left back pain 3 months after fifth delivery. She has a history of similar pain after other deliveries. Images taken at 3 months postpartum demonstrate the radiography (a) and CT (b) appearance of osteitis condensans ilii, an older descriptive radiographic term referring to bilateral, symmetrical, dense bone formation (arrows) in a triangular pattern along the anterior-inferior iliac side of the SI joint. Osteitis condensans ilii is associated with previous and recent pregnancies. On the MRI of the sacroiliac joints with (c) axial T2 fat saturated sequence there is an unsuspected small sacral stress fracture (arrow) in the left sacral ala with matching dark line (arrow) on the (d) axial T1 sequence

There can be mild increased sclerosis on the sacral aspect as well [93]. It has been associated with low back pain and SI joint pain in women [94], but the majority of patients were asymptomatic in one radiology-based series [95]. There is a strong association with previous and recent pregnancies [93–95], seen an estimated 1 % of postpartum women and can persist for years [95]. Much less frequently, males and nulliparous females have these changes [93]. The underlying etiology is probably mechanical, involving the auricular portion of the ilium without joint involvement [93–96]. It has no associated inflammatory markers and has no bony destruction, erosions, or joint space narrowing [93, 96]. Treatment is primarily conservative and in the majority of patients symptoms partially or completely resolve [93, 96]. One series of both multiparous and nulliparous women with refractory pain had significant clinical improvement and resolution of radiographic changes 24 months after percutaneous iliac core decompressions were performed [97].

Sacroiliac Joint Inflammatory and Degenerative Changes

Clinical presentations for the SI joint can be nonspecific and confusing, with pain referred to and from the lower back, groin, abdomen, hip, thigh, and even calf [95]. The SI joint is predominately a symphysis designed to resist vertical shear forces between the extensive and strong complex of ligaments and the cartilage covering the iliac and sacral surfaces [98]. Like the pubic symphysis, there is more motion at the SI joint in women compared to men [98]. Only the distal one-third along the anterior-inferior iliac surface resembles a synovial joint with classic degenerative changes of joint space narrowing, osteophytes, and sometimes vacuum joint gas [93, 95, 96, 99]. Single AP pelvis view is adequate for most SI joint assessment in young women. The full series SI joint study with angled joint views could be reserved for questionable cases because of their higher dose and MRI used in the pregnant patient if necessary. Degenerative changes can be focal and asymmetric secondary to altered mechanics such as scoliosis, leg-length discrepancy, hip arthropathy, degenerative changes of the spine, and lumbosacral transitional anatomy [95, 96, 98]. Degenerative changes in the SI joints in young athletes are commonly associated with pubic symphysis injury and instability [90]. In the assessment of sacroiliitis, MRI with STIR or T2 fat suppression sequences is the modality of choice and demonstrates early marrow edema years before plain film changes occur [100]. Only 36 % of patients presenting with inflammatory back/sacroiliac pain had sacroiliitis on MRI with degenerative disc disease, hip joint disease, and lumbosacral transitional anatomy accounting for the symptoms [30].

Intrinsic Hip Pathology

Hip pain is notorious for referring to adjacent and distant areas of the pelvis, back, and lower extremity. While true intra-articular joint pain often is described clinically as deep groin pain, hip pathology in one series contributed about 6 % of patients suspected with sacroiliitis [30] and about 11 % of cases in refractory groin pain [1]. Women are more likely than men to have developmental dysplasia of the hip [12]. Pregnancy probably exacerbates previous underlying hip pathology and hip pain is self-reported in about 20–40 % of pregnant women [56]. Certainly labral tears are seen following pregnancy [101]. The previous discussion of pregnancy-related stress injuries covered proximal femoral stress fractures, avascular necrosis, and transient osteopenia of the hip. A two-view radiography series of the involved hip with shielding should be the initial imaging modality. MRI is the modality of choice for hip pathology including anterior labral tears, cam-type femoroacetabular impingement, osteoarthritis, osteochondral lesions, and primary synovial processes if radiography is not contributory and pain is persistent or severe. Ultrasound in the ideal patient can assess for joint effusion and para-articular masses like iliopsoas or trochanteric bursa, tendon changes like snapping hip and nerve pathology [102].

US can evaluate anterior labral tears but is limited by the bony configuration and depth of the joint. However, US imaging is excellent for lateral hip pain associated with the greater trochanteric overuse tendinopathy of the gluteal tendons and for its treatment with image-guided injections [102, 103].

Coccydynia

Another poorly understood pain source is the coccyx, which is susceptible to injury during vaginal delivery and is an important attachment point for the pelvic floor. Coccydynia is four times more common in women than men [104] and in one series 7 % of coccygeal pain was associated with childbirth, especially “difficult” deliveries with the forceps accounting for half of the postpartum cases [105]. Radiography evaluates gross malalignment; however, there is a wide range of normal variants in the shape and curvature. One study found women with coccydynia had a more ventrally curved coccyx, a lower prevalence of sacrococcygeal joint fusion and a significantly higher frequency of bony spicule formation at the tip [104]. A technique to demonstrate hypermobile coccygeal segments compares lateral standing and seated radiography with the abnormal coccyx subluxing posteriorly in the seated position [105, 106]. Since this technique is not a standard procedure, discussion with the radiology staff would ensure the correct images are obtained. MSK MRI protocol could evaluate for partially fused coccyx, acute fractures, and soft-tissue changes, including nerve lesions [106, 107].

Hernia and Round Ligament Varicosities

In the pregnant and early postpartum patient, round ligament varicosities are far more likely to be the etiology of groin swelling than true groin hernia formation, although the two may be indistinguishable on physical examination. The use of US with color flow Doppler imaging has markedly changed clinical management. There now is recognition that these varicose veins develop only during pregnancy and spontaneously resolve within weeks after delivery [108, 109]. They follow the course of the round ligament into the inguinal canal and appear as multiple tubular fluid-filled structures with hypervascularity on color Doppler and increased in size with Valsalva (Fig. 3.5). New recommendations for management of groin swelling during pregnancy include US with color Doppler with continued follow-up of round ligament varicosities since they do have a risk for rupture and acute variceal thrombosis [109]. This management plan prevents unnecessary surgical interventions. Women tend to have more direct inguinal and femoral hernias than men and these hernias are typically more difficult to diagnose with clinical examination. Groin hernias should be evaluated with US and monitored closely by clinical examination and US as needed during pregnancy with consideration for surgery after delivery [108, 110].

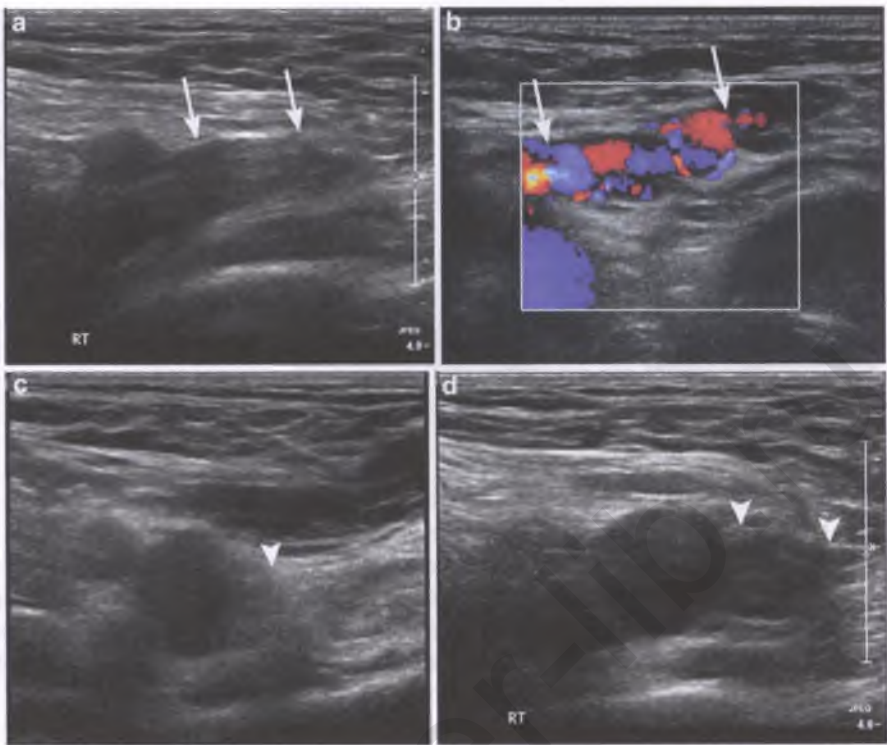


Fig. 3.5 A 26-year-old woman presenting with right groin pain and swelling during pregnancy. Ultrasound demonstrates a hypoechoic mass (*arrows*) in the inguinal canal (**a**) in the longitudinal plane of the canal and with color Doppler (**b**) confirming extensive vascular flow, the classic appearance of round ligament varicosities. In the same patient, at rest in the transverse plane (**c**) there is an unremarkable appearance of the femoral canal (*arrowhead*) but with Valsalva in the transverse plane (**d**) a femoral hernia (*arrowheads*) appears which was clinically occult

Occult Hernias

Establishing the etiology of groin pain can be a clinical and imaging challenge but groin hernias should not be ignored even in the young pregnant patient. The pubic symphysis capsule inserts within millimeters of the superficial inguinal ring. This anatomic proximity helps to explain why pubic symphysis injury and groin hernia can mimic each other on clinical presentations [80]. Occult hernias including indirect inguinal, direct inguinal and femoral hernias should be excluded with imaging (Fig. 3.5), especially in women, since they are more difficult to examine physically than men, and are more likely to have atypical direct inguinal and femoral hernias than men [1, 111]. In one series of 87 women presenting with groin pain, 37 clinically occult groin hernias were documented by ultrasound [111]. Three of these women were pregnant but none proceeded to surgery since their symptoms resolved

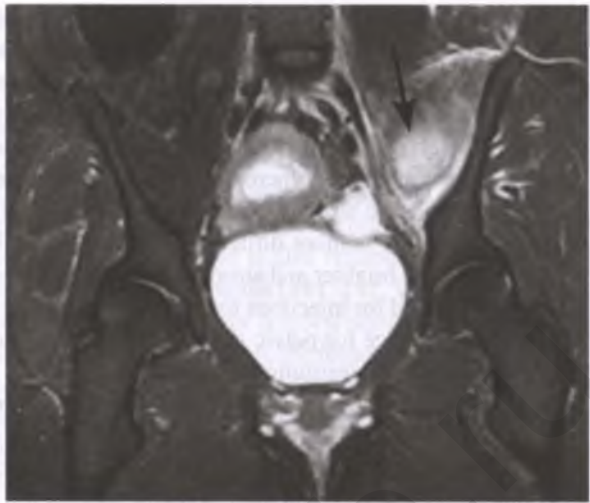
postpartum [111]. Women also can have a cyst form in the canal of Nuck, a remnant of parietal peritoneum extending into the inguinal canal. Such cysts can be concurrent with hernia formation [111].

Musculoskeletal Infection

MSK infections need early diagnosis and treatment to prevent possibly significant complications, especially in the joints. MSK MRI is the imaging modality of choice providing additional information about the extent of tissue involvement [112, 113]. A negative MSK MRI can rule out osteomyelitis. Conventional radiography may have minimal changes even 2 weeks after onset of symptoms. Superficial infections, such as cellulitis, infectious bursitis, and tenosynovitis typically require 1–2 weeks of antibiotic treatment. They often can be well evaluated by ultrasound which can guide aspiration if needed. Deeper infections including pyomyositis of the pelvic muscles, osteomyelitis, spondylodiscitis, and septic arthritis require at least 6 weeks of antibiotic treatment and sometimes, surgical management. These more serious joint and deep tissue infections can have an indolent and nonspecific presentation so that diagnosis is delayed. While most soft-tissue infections are hematogenous in origin, osteomyelitis in greater than 90 % of cases is associated with adjacent soft-tissue infection or ulcer formation. The joints of the pelvis often are infected by hematogenous spread. Gadolinium contrast is used to determine the extent of soft-tissue infection and assess for devitalized tissues. It is not needed for the diagnosis of abscess or osteomyelitis. Joint infections, especially septic hips, are orthopedic emergencies requiring aspiration to confirm the diagnosis combined with operative management to limit joint destruction [112, 113].

In the pubic area, acute postpartum infections clinically can mimic pubic diastasis and the noninfective osteitis pubis while chronic osteomyelitis can appear similar to chronic osteitis pubis on radiography [89, 114, 115]. Septic arthritis and osteomyelitis of the pubic symphysis are definitely different clinical entities than osteitis pubis. In a review of 100 cases of septic pubic joints, pertinent risk factors included female incontinence surgery (24 %) and postpartum patients especially those with complications (2 %) [116]. By the time a septic pubic joint was diagnosed, osteomyelitis already was present in 97 % of the cases. All received an antibiotic course of 6 weeks duration with surgical debridement required in 55 % of patients [116]. The clinical symptoms of MSK infection can be subtle, leading to long delays in diagnosis; however in the high-risk population, such as those with other sources of infection or trauma to the joint [115], aggressive evaluation should be considered. Joint aspiration can be performed with US or CT guidance, to confirm clinical suspicion and support clinical laboratory values [116]. Pregnancy and postpartum patients may present with nonspecific SI joint and MSK back pain but can rarely have iliopsoas pyomyositis, which often presents with limping (Fig. 3.6) [117–119] or postpartum septic sacroiliitis mimicking sciatic neuropathy or sacroiliac

Fig. 3.6 A 19-year-old woman, 10 weeks pregnant presents with low-grade fever, left flank and hip pain with limping. MRI with T2-weighted fat suppression sequence demonstrates an iliopsoas abscess (*black arrow*)



joint pain/dysfunction [120]. Iliopsoas abscesses and pyomyositis can progress to sacroiliac joint osteomyelitis. There are rare cases of septic sacroiliac joint secondary to epidural anesthesia [121]. SI joint infection typically is unilateral.

Ultrasound and MRI for Evaluation of Nerves

Diagnostic tests for neuropathies are based on clinical history, physical examination, and electrodiagnostic examinations with MRI and ultrasound now added as complements to define site and etiology of nerve compression and to exclude other diseases [122, 123]. MSK MRI and MR neurography, using advanced imaging sequences, as well as high-resolution ultrasonography (12–18 MHz transducers) can depict long nerve segments of even small nerves and can improve the outcome of traumatic nerve lesions by differentiating complete from partial injury and locating the exact site of the nerve lesion prior to surgical intervention [113, 124–126]. US or MRI can discover possible anatomic causes for compression, such as ganglion, accessory muscles, vascular lesions, tenosynovitis, nerve sheath tumors, soft-tissue tumors, or other space occupying masses [113, 127]. By US, a normal nerve appears as a bundle of dark fibers with fine bright tissue surrounding each one but pathological nerves in general lose their bright surrounding tissue, secondary to intraneural edema and become thicker and more hypoechoic (darker) with fusiform swelling proximal to the area of compression and entrapment [127, 128]. Neuropathies from pathological tension such as in the foot after ankle sprains may have subtle or unremarkable imaging changes [129]. By MRI, normal nerves have a signal similar to normal muscles. Pathological nerves enlarge and have a signal similar to the vascular system [124, 127].

Over time these changes regress, depending in part on the severity of injury, so that months from injury the appearance maybe unremarkable. Even when individual nerves are hard to see by MRI secondary to their size or orientation, there is a characteristic pattern for muscle denervation limited to the muscle tissue innervated by the involved nerve. Early, on MRI fluid-sensitive sequences, the involved muscle has a diffuse, uniform, slightly increased signal. These denervation changes can persist for months while the atrophy can be permanent [113, 130, 131]. US assessment of muscle denervation is more difficult than MRI but by US denervated muscle over time may become brighter and atrophic [127, 132]. US is widely used when imaging guidance is needed for injections for either diagnostic or therapeutic indications. The use of MRI guidance for pelvic nerve blocks has developed only recently and may not be available at all institutions [133].

In the current literature on neuropathy in the pregnant or postpartum patient, there is limited discussion of the role for US or MRI in diagnosis and management. While, in general, most of the common pregnancy-associated neuropathies are mild and completely resolve soon after delivery, in patients with atypical presentations, those which are unusually severe, prolonged or complex, imaging can provide information which may alter management. Pelvic and lower extremity neuropathies often are attributed to epidural or spinal anesthesia, but the most common association is with obstetric trauma such as instrumented delivery or prolonged labor suggesting compressive neuropathy [32, 134]. Characteristic nerve injuries and their prevention associated with gynecological surgery are reviewed by Bradshaw [135]. MRI can be tailored to evaluate many peripheral nerves but individual nerve imaging studies should be discussed with the neuroradiologist or MSK radiologists to ensure the area of clinical concern is appropriately imaged. Since US imaging of peripheral nerves may be performed by different clinical services, referral patterns may not be limited to radiologists at all institutions.

Carpal tunnel imaging: The most common entrapment neuropathy for both general and pregnant patients is compression of the median nerve by the flexor retinaculum at the carpal tunnel (see Chap. 9). While multiple causes have been discussed for pregnancy-associated median nerve involvement [31, 134, 136, 137], imaging also can assess the severity of the nerve involvement and extent even into the separate palmar cutaneous branch [138]. Normal variants such as bifid median nerves or persistent median arteries may alter operative approaches [127, 132]. When clinically indicated, US can be used to guide injections such as local corticosteroid injections [127, 137]. Carpal tunnel syndrome can continue in the postpartum period especially during breastfeeding, probably due to increased stress on the hand and wrist secondary to awkward hand positions [136]. A similar postpartum presentation can occur in the overuse syndrome of de Quervain's tenosynovitis or "baby wrist" in which the wrist pain is related to inflammation in tendon sheathes in the first dorsal compartment of the wrist [139].

Ulnar neuropathy at the elbow: This classic entrapment neuropathy of the ulnar nerve proximal to the cubital tunnel, along the posterior medial humeral epicondyle, is readily evaluated with US or MRI. US allows for dynamic evaluation of a snapping ulnar nerve in which the nerve displaces over the medial epicondyle with elbow flexion. This anatomic change can be bilateral and asymptomatic [132].

Lower Extremity Neuropathies and Imaging (see Chap. 6)

Lateral femoral cutaneous nerve: Compression or entrapment of this small nerve produces meralgia paresthetica syndrome which is common during pregnancy and is typically unilateral [31, 32, 134, 140–142]. The nerve has a variable course but can be impinged as it exits the abdomen adjacent to the deep fibers of the inguinal ligament just medial to the anterior superior iliac spine. While it can be seen with MRI [113, 140, 143], high-resolution ultrasound is also reliable [144]. US can be used for perineural injections for relief of symptoms [141, 142, 145].

Femoral neuropathy: The most common site for femoral nerve compression is as it exits the pelvis under the inguinal ligament lateral to the femoral vessels [113, 140]. Compression can occur secondary to the lithotomy position or excessive hip flexion [31, 32, 135], but also during the third trimester when it is typically unilateral [134, 136]. MRI can evaluate the path of the nerve in the pelvis and both MRI and US are used in the upper thigh before the nerve divides [113, 141]. A characteristic muscle denervation edema pattern involving the quadriceps muscles can be seen with MRI [113, 140, 141]. The incidence of femoral neuropathy during labor and delivery has decreased in the last 50 years [31].

Peroneal neuropathy: The peroneal or fibular nerve can be compressed as it curves around the fibular neck along the lateral knee, for example by pressure against the stirrups during delivery or operations, producing both sensory changes of the lateral lower leg and the classic foot drop [31, 32, 134–136, 140]. Complex regional pain syndrome was a late complication in one case of compression during labor [146]. The nerve is less likely to be compressed by adjacent cysts in the lateral knee or in the popliteal fossa, however all these areas can be readily imaged with either US or MRI as indicated. MRI shows denervation changes in the gastrocnemius and popliteus muscles for proximal nerve compression and denervation changes only in the anterior and lateral compartment calf muscles for more distal involvement [140].

Obturator neuropathy: The small obturator nerve exits the pelvis underneath the superior pubic ramus in the obturator canal and supplies sensory innervations of the groin and medial thigh and adductors of the hip. Causes for compressive neuropathy include prolonged labor [136] forceps delivery [32], complications of cesarean deliveries [147, 148], surgery in the lithotomy position [141], or hematomas from pudendal nerve blocks near the obturator foramen [31]. The nerve is best seen with MRI in the pelvis and proximal thigh [140, 141, 149] with a classic MRI pattern of denervation edema in the adductor musculature.

Tibial nerve in the tarsal tunnel: The tibial nerve in the tarsal tunnel along the posterior medial ankle may be compressed during pregnancy and postpartum period and present with foot and ankle pain [136]. Evaluation of the tibial nerve is readily performed by either US or MRI [129, 140], although after the nerve branches, the small size of the nerve makes evaluation challenging [129, 140].

Brachial plexus: Idiopathic brachial plexus involvement may occur in the postpartum period. It is even less frequent during pregnancy [136]. Bradshaw discusses some of the gynecologic postoperative neuropathies [135], for example

resulting from the placement of arm boards. MRI remains the imaging modality of choice for most brachial plexus pathologies, especially the newer MR neurography techniques [124] because the plexus anatomy is complex with the structures deep to the clavicle unseen by US secondary to shadowing from the overlying bone [123, 125, 150, 151]. In experienced hands, the specificity of brachial plexus US is very high as in preoperative evaluation of postganglionic mass lesions [151].

Iliohypogastric, ilioinguinal, and genitofemoral nerves are extremely small and imaging is inconsistent unless the nerves are pathologically enlarged, for example by third trimester abdominal expansion or by cesarean section, in which case both MRI neurography and high-resolution US may be useful [113]. The genitofemoral nerve can be seen by high-resolution MR neurography when enlarged [113]. Imaging for intercostal nerves and facial nerve palsy is limited due to the small size of the normal nerves.

Pudendal neuropathy: Pudendal nerve entrapment is a recognized cause of chronic perineal pain [128, 141, 152], with possible nerve damage from compression or tissue laceration during pregnancy and delivery [136]. The nerve is smaller in women than men and courses within a neurovascular bundle which makes evaluation difficult but can be seen with state-of-the-art imaging by US [128, 152] and MRI [113, 141]. CT and US have been used to guide injection at the ischial spine and pudendal (Alcock's) canal [153, 154].

Sciatic neuropathy: The sciatic nerve is best seen with MRI especially in the deep pelvic and upper thigh tissues while US can evaluate it more distally [113, 141]. The controversial entity of the piriformis syndrome may be due to anatomic variations in the course of the nerve and/or in the structure of muscle [140, 141]. In general, the peroneal division of the sciatic nerve is more commonly and more severely compressed than the tibial division [141]. Evaluation of gluteal neuropathy is based on detection of denervation signs in the gluteal muscles [141].

Lumbosacral plexus and radiculopathy: MRI, especially MR neurography, best evaluates the plexus with the referring clinician requesting lumbosacral plexus imaging as opposed to just lumbar spine studies [31, 113]. Unexpected sacral fractures can clinically present as lumbosacral plexus involvement in the peripartum period [40, 41, 45, 46, 140].

Conclusions

MSK imaging for the pregnant and postpartum patient can address a number of well-established clinical entities and has the potential to provide even more diagnostic value with the addition of MSK-specific MRI and the development of the newer techniques of nerve imaging. In general, the range of MSK changes initiated by pregnancy does not require imaging evaluation but in those women with atypical presentations, prolonged symptoms or possible-associated complicated pathology, imaging can help establish a diagnosis and indicate preferred treatment options. For example, current MSK MRI imaging could improve our understanding of the

anatomic basics of diverse regional syndromes such as the contributions of pelvic stress fractures to pelvic pain syndromes. By linking to the expertise already developed in orthopedics, physical medicine and rehabilitation, sports medicine and endocrinology, health care providers can draw on a large body of clinical management experience for pregnant and postpartum women. Incorporating these imaging modalities into a busy obstetrics and gynecology-directed practice may require some alternations of existing practice approaches and even imaging referral patterns. However, for those exceptional patients, the addition of state-of-the-art imaging could provide clarity to clinical impressions by confirming initial suspicions, by redirecting investigations, or by reassuring the patient and provider that the current management strategy will provide recovery.

Acknowledgements Dr. Megan Schimpf, Department of Obstetrics and Gynecology, University of Michigan, Ann Arbor, MI and Dr. David Jamadar, Department of Radiology, University of Michigan and Veterans Affairs Medical Center, Ann Arbor, MI for their reading of the manuscript.

References

1. Zajick DC, Zoga AC, Omar IM, Meyers WC. Spectrum of MRI findings in clinical athletic pubalgia. *Semin Musculoskelet Radiol.* 2008;12(1):3–12. PubMed PMID: 18382940.
2. Katz DS, Klein MA, Ganson G, Hines JJ. Imaging of abdominal pain in pregnancy. *Radiol Clin North Am.* 2012;50(1):149–71. PubMed PMID: 22099493.
3. Tremblay E, Therasse E, Thomassin-Naggara I, Trop I. Quality initiatives: guidelines for use of medical imaging during pregnancy and lactation. *Radiographics.* 2012;32(3):897–911. PubMed PMID: 22403117.
4. Wang PI, Chong ST, Kielar AZ, Kelly AM, Knoepp UD, Mazza MB, et al. Imaging of pregnant and lactating patients: part 1, evidence-based review and recommendations. *AJR Am J Roentgenol.* 2012;198(4):778–84. PubMed PMID: 22451541.
5. Klauser AS, Tagliafico A, Allen GM, Boutry N, Campbell R, Court-Payen M, et al. Clinical indications for musculoskeletal ultrasound: a Delphi-based consensus paper of the European Society of Musculoskeletal Radiology. *Eur Radiol.* 2012;22(5):1140–8. PubMed PMID: 22453857.
6. Paajanen H, Hermunen H, Karonen J. Effect of heavy training in contact sports on MRI findings in the pubic region of asymptomatic competitive athletes compared with non-athlete controls. *Skeletal Radiol.* 2011;40(1):89–94. PubMed PMID: 20582412.
7. Del Grande F, Santini F, Herzka DA, Aro MR, Dean CW, Gold GE, et al. Fat-suppression techniques for 3-T MR imaging of the musculoskeletal system. *Radiographics.* 2014;34(1):217–33. PubMed PMID: 24428292.
8. Leadbetter RE, Mawer D, Lindow SW. Symphysis pubis dysfunction: a review of the literature. *J Matern Fetal Neonatal Med.* 2004;16(6):349–54. PubMed PMID: 15621554.
9. Aslan E, Fynes M. Symphyseal pelvic dysfunction. *Curr Opin Obstet Gynecol.* 2007;19(2):133–9. PubMed PMID: 17353681.
10. Hansen A, Jensen DV, Larsen EC, Wilken-Jensen C, Kaae BE, Frolich S, et al. Postpartum pelvic pain—the “pelvic joint syndrome”: a follow-up study with special reference to diagnostic methods. *Acta Obstet Gynecol Scand.* 2005;84(2):170–6. PubMed PMID: 15683379.
11. Kanakaris NK, Roberts CS, Giannoudis PV. Pregnancy-related pelvic girdle pain: an update. *BMC Med.* 2011;9:15. PubMed PMID: 21324134. Pubmed Central PMCID: 3050758.

12. Prather H, Dugan S, Fitzgerald C, Hunt D. Review of anatomy, evaluation, and treatment of musculoskeletal pelvic floor pain in women. *PM R*. 2009;1(4):346–58. PubMed PMID: 19627918.
13. Albert H, Godsken M, Westergaard J. Prognosis in four syndromes of pregnancy-related pelvic pain. *Acta Obstet Gynecol Scand*. 2001;80(6):505–10. PubMed PMID: 11380285.
14. Apte G, Nelson P, Brismee JM, Dedrick G, Justiz 3rd R, Sizer Jr PS. Chronic female pelvic pain—part 1: clinical pathoanatomy and examination of the pelvic region. *Pain Pract*. 2012;12(2):88–110. PubMed PMID: 21615678.
15. Vleeming A, Albert HB, Ostgaard HC, Sturesson B, Stuge B. European guidelines for the diagnosis and treatment of pelvic girdle pain. *Eur Spine J*. 2008;17(6):794–819. PubMed PMID: 18259783. Pubmed Central PMCID: 2518998.
16. Handa VL, Lockhart ME, Kenton KS, Bradley CS, Fielding JR, Cundiff GW, et al. Magnetic resonance assessment of pelvic anatomy and pelvic floor disorders after childbirth. *Int Urogynecol J Pelvic Floor Dysfunct*. 2009;20(2):133–9. PubMed PMID: 18846311. Pubmed Central PMCID: 2916750.
17. Hayat SK, Thorp Jr JM, Kuller JA, Brown BD, Semelka RC. Magnetic resonance imaging of the pelvic floor in the postpartum patient. *Int Urogynecol J Pelvic Floor Dysfunct*. 1996; 7(6):321–4. PubMed PMID: 9203480.
18. Hoyte L, Damaser MS. Magnetic resonance-based female pelvic anatomy as relevant for maternal childbirth injury simulations. *Ann N Y Acad Sci*. 2007;1101:361–76. PubMed PMID: 17363445.
19. Huerta-Enochian GS, Katz VL, Fox LK, Hamlin JA, Kollath JP. Magnetic resonance-based serial pelvimetry: do maternal pelvic dimensions change during pregnancy? *Am J Obstet Gynecol*. 2006;194(6):1689–94. PubMed PMID: 16731086, discussion 94–5.
20. Novellas S, Chassang M, Verger S, Bafghi A, Bongain A, Chevallier P. MR features of the levator ani muscle in the immediate postpartum following cesarean delivery. *Int Urogynecol J*. 2010;21(5):563–8. PubMed PMID: 20024647.
21. Wurdinger S, Humbsch K, Reichenbach JR, Peiker G, Seewald HJ, Kaiser WA. MRI of the pelvic ring joints postpartum: normal and pathological findings. *J Magn Reson Imaging*. 2002;15(3):324–9. PubMed PMID: 11891978.
22. Singh AK, Desai H, Novelline RA. Emergency MRI of acute pelvic pain: MR protocol with no oral contrast. *Emerg Radiol*. 2009;16(2):133–41. PubMed PMID: 18649091.
23. Leyendecker JR, Gorengaut V, Brown JJ. MR imaging of maternal diseases of the abdomen and pelvis during pregnancy and the immediate postpartum period. *Radiographics*. 2004;24(5):1301–16. PubMed PMID: 15371610.
24. Borg-Stein J, Dugan SA. Musculoskeletal disorders of pregnancy, delivery and postpartum. *Phys Med Rehabil Clin N Am*. 2007;18(3):459–76, ix, PubMed PMID: 17678762.
25. Han IH. Pregnancy and spinal problems. *Curr Opin Obstet Gynecol*. 2010;22(6):477–81. PubMed PMID: 20930629.
26. Fitzgerald CM. Pregnancy-related lumbopelvic pain: what have we learned? *Am J Obstet Gynecol*. 2013;208(4):242. PubMed PMID: 23465783.
27. Sabino J, Grauer JN. Pregnancy and low back pain. *Curr Rev Musculoskelet Med*. 2008;1(2):137–41. PubMed PMID: 19468887. Pubmed Central PMCID: 2684210.
28. Gutke A, Ostgaard HC, Oberg B. Predicting persistent pregnancy-related low back pain. *Spine*. 2008;33(12):E386–93. PubMed PMID: 18496334.
29. Davis PC, Wippold 2nd FJ, Brunberg JA, Cornelius RS, De La Paz RL, Dormont PD, et al. ACR appropriateness criteria on low back pain. *J Am Coll Radiol*. 2009;6(6):401–7. PubMed PMID: 19467485.
30. Jans L, Van Praet L, Elewaut D, Van den Bosch F, Carron P, Jaremko JL, et al. MRI of the SI joints commonly shows non-inflammatory disease in patients clinically suspected of sacroiliitis. *Eur J Radiol*. 2014;83(1):179–84. PubMed PMID: 24168927.
31. Sax TW, Rosenbaum RB. Neuromuscular disorders in pregnancy. *Muscle Nerve*. 2006; 34(5):559–71. PubMed PMID: 16969835.
32. Kowe O, Waters JH. Neurologic complications in the patient receiving obstetric anesthesia. *Neurol Clin*. 2012;30(3):823–33. PubMed PMID: 22840791.

33. Kiuru MJ, Pihlajamaki HK, Ahovuo JA. Fatigue stress injuries of the pelvic bones and proximal femur: evaluation with MR imaging. *Eur Radiol.* 2003;13(3):605–11. PubMed PMID: 12594565.
34. Datir AP. Stress-related bone injuries with emphasis on MRI. *Clin Radiol.* 2007;62(9): 828–36. PubMed PMID: 17662729.
35. Miller C, Major N, Toth A. Pelvic stress injuries in the athlete: management and prevention. *Sports Med.* 2003;33(13):1003–12. PubMed PMID: 14606927.
36. Black AJ, Topping J, Durham B, Farquharson RG, Fraser WD. A detailed assessment of alterations in bone turnover, calcium homeostasis, and bone density in normal pregnancy. *J Bone Miner Res.* 2000;15(3):557–63. PubMed PMID: 10750571.
37. Kanberoglu K, Kantarci F, Cebi D, Yilmaz MH, Kurugoglu S, Bilici A, et al. Magnetic resonance imaging in osteomalacic insufficiency fractures of the pelvis. *Clin Radiol.* 2005; 60(1):105–11. PubMed PMID: 15642300.
38. Nattiv A, Kennedy G, Barrack MT, Abdelkerim A, Goolsby MA, Arends JC, et al. Correlation of MRI grading of bone stress injuries with clinical risk factors and return to play: a 5-year prospective study in collegiate track and field athletes. *Am J Sports Med.* 2013;41(8):1930–41. PubMed PMID: 23825184.
39. Boden BP, Osbahr DC, Jimenez C. Low-risk stress fractures. *Am J Sports Med.* 2001;29(1):100–11. PubMed PMID: 11206247.
40. Karadeli E, Uslu N. Postpartum sacral fracture presenting as lumbar pain. *J Womens Health.* 2009;18(5):663–5. PubMed PMID: 19405869.
41. Park J, Ok E, Park HJ, Hong SH, Lee JI. Postpartum sacral stress fracture mimicking lumbar radiculopathy in a patient with pregnancy-associated osteoporosis. *Ann Rehabil Med.* 2013;37(4):582–5. PubMed PMID: 24020042. Pubmed Central PMCID: 3764356.
42. Beltran LS, Bencardino JT. Lower back pain after recently giving birth: postpartum sacral stress fractures. *Skeletal Radiol.* 2011; 40(4):461–2, 81–2. PubMed PMID: 21063704.
43. Goeb V, Strotz V, Verdet M, Le Loet X, Vittecoq O. Post-partum sacral fracture associated with heparin treatment. *Clin Rheumatol.* 2008;27 Suppl 2:S51–3. PubMed PMID: 18458990.
44. Karatas M, Basaran C, Ozgul E, Tarhan C, Agildere AM. Postpartum sacral stress fracture: an unusual case of low-back and buttock pain. *Am J Phys Med Rehabil.* 2008;87(5):418–22. PubMed PMID: 18303473.
45. Ozturk G, Kulcu DG, Aydog E. Intrapartum sacral stress fracture due to pregnancy-related osteoporosis: a case report. *Arch Osteoporos.* 2013;8(1–2):139. PubMed PMID: 23615864.
46. Thein R, Burstein G, Shabshin N. Labor-related sacral stress fracture presenting as lower limb radicular pain. *Orthopedics.* 2009;32(6):447. PubMed PMID: 19634811.
47. Celik EC, Oflooglu D, Arioglu PF. Postpartum bilateral stress fractures of the sacrum. *Int J Gynaecol Obstet.* 2013;121(2):178–9. PubMed PMID: 23312399.
48. Pishnamaz M, Sellei R, Pfeifer R, Lichte P, Pape HC, Kobbe P. Low back pain during pregnancy caused by a sacral stress fracture: a case report. *J Med Case Reports.* 2012;6:98. PubMed PMID: 22475388. Pubmed Central PMCID: 3375193.
49. Hermann KG, Halle H, Reissauer A, Schink T, Vsianska L, Muhler MR, et al. [Peripartum changes of the pelvic ring: usefulness of magnetic resonance imaging]. *RoFo: Fortschritte auf dem Gebiete der Rontgenstrahlen und der Nuklearmedizin.* 2007; 179(12):1243–50. PubMed PMID: 17929216. Peripartale Veränderungen des Beckenringes: Wie sinnvoll ist die Magnetresonanztomografie?
50. Brandon C, Jacobson JA, Low LK, Park L, DeLancey J, Miller J. Pubic bone injuries in primiparous women: magnetic resonance imaging in detection and differential diagnosis of structural injury. *Ultrasound Obstet Gynecol.* 2012;39(4):444–51. PubMed PMID: 21728205. Pubmed Central PMCID: 3625969.
51. Miller JM, Brandon C, Jacobson JA, Low LK, Zielinski R, Ashton-Miller J, et al. MRI findings in patients considered high risk for pelvic floor injury studied serially after vaginal childbirth. *AJR Am J Roentgenol.* 2010;195(3):786–91. PubMed PMID: 20729461. Pubmed Central PMCID: 3189698.
52. Gibbon WW, Hession PR. Diseases of the pubis and pubic symphysis: MR imaging appearances. *AJR Am J Roentgenol.* 1997;169(3):849–53. PubMed PMID: 9275910.

53. Khan W, Zoga AC, Meyers WC. Magnetic resonance imaging of athletic pubalgia and the sports hernia: current understanding and practice. *Magn Reson Imaging Clin N Am*. 2013;21(1):97–110. PubMed PMID: 23168185.
54. Boden BP, Osbahr DC. High-risk stress fractures: evaluation and treatment. *J Am Acad Orthop Surg*. 2000;8(6):344–53. PubMed PMID: 11104398.
55. Anai T, Urata K, Mori A, Miyazaki F, Okamoto S. Transient osteoporosis of the hip in pregnancy associated with generalized low bone mineral density—a case report. *Gynecol Obstet Invest*. 2013;76(2):133–8. PubMed PMID: 23796944.
56. Steib-Furno S, Luc M, Pham T, Armingeat T, Porcu G, Gamarre M, et al. Pregnancy-related hip diseases: incidence and diagnoses. *Joint Bone Spine*. 2007;74(4):373–8. PubMed PMID: 17560159.
57. Rajak R, Camilleri J. An unusual cause of hip pain. *BMJ Case Rep*. 2011;2011. PubMed PMID: 22679319. Pubmed Central PMCID: 3185398.
58. Wood ML, Larson CM, Dahners LE. Late presentation of a displaced subcapital fracture of the hip in transient osteoporosis of pregnancy. *J Orthop Trauma*. 2003;17(8):582–4. PubMed PMID: 14504581.
59. Ward KA, Adams JE, Mughal MZ. Bone status during adolescence, pregnancy and lactation. *Curr Opin Obstet Gynecol*. 2005;17(4):435–9. PubMed PMID: 15976553.
60. Spinarelli A, Patella V, Speciale D, Petrera M, Vittore D, Pesce V, et al. Hip fracture in a patient affected by transient osteoporosis of the femoral head during the last trimester of pregnancy. *Orthopedics*. 2009;32(5):365. PubMed PMID: 19472951.
61. Aigner N, Meizer R, Meraner D, Becker S, Meizer E, Landsiedl F. Bone marrow edema syndrome in postpartal women: treatment with iloprost. *Orthop Clin North Am*. 2009;40(2):241–7. PubMed PMID: 19358909.
62. Clemetson IA, Popp A, Lippuner K, Ballmer F, Anderson SE. Postpartum osteoporosis associated with proximal tibial stress fracture. *Skeletal Radiol*. 2004;33(2):96–8. PubMed PMID: 14714147.
63. Daniel RS, Farrar EK, Norton HR, Nussbaum AI. Bilateral transient osteoporosis of the talus in pregnancy. *Osteoporos Int*. 2009;20(11):1973–5. PubMed PMID: 19343470.
64. Nitsche JF, Howell T. Peripartum pubic symphysis separation: a case report and review of the literature. *Obstet Gynecol Surv*. 2011;66(3):153–8. PubMed PMID: 21689485.
65. Topuz S, Cital I, Iyibozkurt AC, Dursun M, Akhan S, Has R, et al. Pubic symphysis diastasis: imaging and clinical features. *Eur J Radiol Extra*. 2006;59:127–9.
66. Cowling PD, Rangan A. A case of postpartum pubic symphysis diastasis. *Injury*. 2010;41(6):657–9. PubMed PMID: 20152970.
67. Dunivan GC, Hickman AM, Connolly A. Severe separation of the pubic symphysis and prompt orthopedic surgical intervention. *Obstet Gynecol*. 2009;114(2 Pt 2):473–5. PubMed PMID: 19622966.
68. Shim JH, Oh DW. Case report: physiotherapy strategies for a woman with symphysis pubis diastasis occurring during labour. *Physiotherapy*. 2012;98(1):89–91. PubMed PMID: 22265390.
69. Hou Z, Riehl JT, Smith WR, Strohecker KA, Maloney PJ. Severe postpartum disruption of the pelvic ring: report of two cases and review of the literature. *Patient Saf Surg*. 2011;5(1):2. PubMed PMID: 21232102. Pubmed Central PMCID: 3025835.
70. Bjorklund K, Nordstrom ML, Bergstrom S. Sonographic assessment of symphyseal joint distention during pregnancy and post partum with special reference to pelvic pain. *Acta Obstet Gynecol Scand*. 1999;78(2):125–30. PubMed PMID: 10023875.
71. Scriven MW, Jones DA, McKnight L. The importance of pubic pain following childbirth: a clinical and ultrasonographic study of diastasis of the pubic symphysis. *J R Soc Med*. 1995;88(1):28–30. PubMed PMID: 7884766. Pubmed Central PMCID: 1295070.
72. Kurzel RB, Au AH, Rooholamini SA, Smith W. Magnetic resonance imaging of peripartum rupture of the symphysis pubis. *Obstet Gynecol*. 1996;87(5 Pt 2):826–9. PubMed PMID: 8677103.
73. Becker I, Woodley SJ, Stringer MD. The adult human pubic symphysis: a systematic review. *J Anat*. 2010;217(5):475–87. PubMed PMID: 20840351. Pubmed Central PMCID: 3035856.

74. Liaw LJ, Hsu MJ, Liao CF, Liu MF, Hsu AT. The relationships between inter-recti distance measured by ultrasound imaging and abdominal muscle function in postpartum women: a 6-month follow-up study. *J Orthop Sports Phys Ther.* 2011;41(6):435–43. PubMed PMID: 21289454.
75. Coldron Y, Stokes MJ, Newham DJ, Cook K. Postpartum characteristics of rectus abdominis on ultrasound imaging. *Man Ther.* 2008;13(2):112–21. PubMed PMID: 17208034.
76. Amorosa LF, Amorosa JH, Wellman DS, Lorich DG, Helfet DL. Management of pelvic injuries in pregnancy. *Orthop Clin North Am.* 2013;44(3):301–15, viii. PubMed PMID: 23827834.
77. Kharrazi FD, Rodgers WB, Kennedy JG, Lhowe DW. Parturition-induced pelvic dislocation: a report of four cases. *J Orthop Trauma.* 1997;11(4):277–81; discussion 81-2. PubMed PMID: 9258826.
78. Brennan D, O'Connell MJ, Ryan M, Cunningham P, Taylor D, Cronin C, et al. Secondary cleft sign as a marker of injury in athletes with groin pain: MR image appearance and interpretation. *Radiology.* 2005;235(1):162–7. PubMed PMID: 15731372.
79. Cunningham PM, Brennan D, O'Connell M, MacMahon P, O'Neill P, Eustace S. Patterns of bone and soft-tissue injury at the symphysis pubis in soccer players: observations at MRI. *AJR Am J Roentgenol.* 2007;188(3):W291–6. PubMed PMID: 17312039.
80. Robinson P, Barron DA, Parsons W, Grainger AJ, Schilders EM, O'Connor PJ. Adductor-related groin pain in athletes: correlation of MR imaging with clinical findings. *Skeletal Radiol.* 2004;33(8):451–7. PubMed PMID: 15224172.
81. Robinson P, Salehi F, Grainger A, Clemence M, Schilders E, O'Connor P, et al. Cadaveric and MRI study of the musculotendinous contributions to the capsule of the symphysis pubis. *AJR Am J Roentgenol.* 2007;188(5):W440–5. PubMed PMID: 17449740.
82. Shortt CP, Zoga AC, Kavanagh EC, Meyers WC. Anatomy, pathology, and MRI findings in the sports hernia. *Semin Musculoskelet Radiol.* 2008;12(1):54–61. PubMed PMID: 18382944.
83. Zoga AC, Kavanagh EC, Omar IM, Morrison WB, Koulouris G, Lopez H, et al. Athletic pubalgia and the “sports hernia”: MR imaging findings. *Radiology.* 2008;247(3):797–807. PubMed PMID: 18487535.
84. Fitzgerald CM, Plastaras C, Mallinson T. A retrospective study on the efficacy of pubic symphysis corticosteroid injections in the treatment of pubic symphysis pain. *Pain Med.* 2011;12(12):1831–5. PubMed PMID: 22082118.
85. Mehin R, Meek R, O'Brien P, Blachut P. Surgery for osteitis pubis. *Can J Surg.* 2006;49(3):170–6. PubMed PMID: 16749977. Pubmed Central PMCID: 3207605.
86. Garras DN, Carothers JT, Olson SA. Single-leg-stance (flamingo) radiographs to assess pelvic instability: how much motion is normal? *J Bone Joint Surg Am.* 2008;90(10):2114–8. PubMed PMID: 18829908.
87. Kunderacioglu B, Yilmaz C, Yorubulut M, Kudas S. Magnetic resonance findings of osteitis pubis. *J Magn Reson Imaging.* 2007;25(3):535–9. PubMed PMID: 17326088.
88. Verrall GM, Henry L, Fazzalari NL, Slavotinek JP, Oakeshott RD. Bone biopsy of the parasymphyseal pubic bone region in athletes with chronic groin injury demonstrates new woven bone formation consistent with a diagnosis of pubic bone stress injury. *Am J Sports Med.* 2008;36(12):2425–31. PubMed PMID: 18927251.
89. Budak MJ, Oliver TB. There's a hole in my symphysis—a review of disorders causing widening, erosion, and destruction of the symphysis pubis. *Clin Radiol.* 2013;68(2):173–80. PubMed PMID: 22748520.
90. Major NM, Helms CA. Pelvic stress injuries: the relationship between osteitis pubis (symphysis pubis stress injury) and sacroiliac abnormalities in athletes. *Skeletal Radiol.* 1997;26(12):711–7. PubMed PMID: 9453104.
91. Choi H, McCartney M, Best TM. Treatment of osteitis pubis and osteomyelitis of the pubic symphysis in athletes: a systematic review. *Br J Sports Med.* 2011;45(1):57–64. PubMed PMID: 18812419. Pubmed Central PMCID: 3719975.
92. Kavrouidakis E, Karampinas PK, Evangelopoulos DS, Vlamis J. Treatment of osteitis pubis in non-athlete female patients. *Open Orthop J.* 2011;5:331–4. PubMed PMID: 21966337. Pubmed Central PMCID: 3178876.

93. Mitra R. Osteitis condensans ilii. *Rheumatol Int.* 2010;30(3):293–6. PubMed PMID: 19711079.
94. Jenks K, Meikle G, Gray A, Stebbings S. Osteitis condensans ilii: a significant association with sacroiliac joint tenderness in women. *Int J Rheum Dis.* 2009;12(1):39–43. PubMed PMID: 20374315.
95. Tuite MJ. Sacroiliac joint imaging. *Semin Musculoskelet Radiol.* 2008;12(1):72–82. PubMed PMID: 18382946.
96. Resnick D, Niwayama G, Goergen TG. Comparison of radiographic abnormalities of the sacroiliac joint in degenerative disease and ankylosing spondylitis. *AJR Am J Roentgenol.* 1977;128(2):189–96. PubMed PMID: 401599.
97. Ayoub MA. Refractory osteitis condensans ilii: outcome of a novel mini-invasive surgical approach. *Int Orthop.* 2013;37(7):1251–6. PubMed PMID: 23645082. Pubmed Central PMCID: 3685678.
98. Vleeming A, Schuenke MD, Masi AT, Carreiro JE, Danneels L, Willard FH. The sacroiliac joint: an overview of its anatomy, function and potential clinical implications. *J Anat.* 2012;221(6):537–67. PubMed PMID: 22994881.
99. Puhakka KB, Melsen F, Jurik AG, Boel LW, Vesterby A, Egund N. MR imaging of the normal sacroiliac joint with correlation to histology. *Skeletal Radiol.* 2004;33(1):15–28. PubMed PMID: 14614576.
100. Madsen KB, Schiottz-Christensen B, Jurik AG. Prognostic significance of magnetic resonance imaging changes of the sacroiliac joints in spondyloarthritis—a followup study. *J Rheumatol.* 2010;37(8):1718–27. PubMed PMID: 20516024.
101. Baker JF, McGuire CM, Mulhall KJ. Acetabular labral tears following pregnancy. *Acta Orthop Belg.* 2010;76(3):325–8. PubMed PMID: 20698452.
102. Martinoli C, Garello I, Marchetti A, Palmieri F, Altafini L, Valle M, et al. Hip ultrasound. *Eur J Radiol.* 2012;81(12):3824–31. PubMed PMID: 21571471.
103. Klauser AS, Martinoli C, Tagliafico A, Bellmann-Weiler R, Feuchtner GM, Wick M, et al. Greater trochanteric pain syndrome. *Semin Musculoskelet Radiol.* 2013;17(1):43–8. PubMed PMID: 23487333.
104. Woon JT, Maigne JY, Perumal V, Stringer MD. Magnetic resonance imaging morphology and morphometry of the coccyx in coccydynia. *Spine.* 2013;38(23):E1437–45. PubMed PMID: 23917643.
105. Maigne JY, Rusakiewicz F, Diouf M. Postpartum coccydynia: a case series study of 57 women. *Eur J Phys Rehabil Med.* 2012;48(3):387–92. PubMed PMID: 22820826.
106. Trouvin AP, Goeb V, Vandhuick T, Michelin P, Lequerre T, Vittecoq O. Role for magnetic resonance imaging in coccydynia with sacrococcygeal dislocation. *Joint Bone Spine.* 2013;80(2):214–6. PubMed PMID: 23098924.
107. Maigne JY, Pigeau I, Roger B. Magnetic resonance imaging findings in the painful adult coccyx. *Eur Spine J.* 2012;21(10):2097–104. PubMed PMID: 22354690. Pubmed Central PMCID: 3463700.
108. Lechner M, Fortelny R, Ofner D, Mayer F. Suspected inguinal hernias in pregnancy—handle with care! *Hernia.* 2014;18(3):375–9. PubMed PMID: 23559310.
109. Polat AV, Aydin R, Polat AK, Kececi IS, Karahan G, Taskin GO. Round ligament varicosities: a rare cause of groin swelling in pregnancy. *Abdom Imaging.* 2013;38(5):1178–81. PubMed PMID: 23397551.
110. Buch KE, Tabrizian P, Divino CM. Management of hernias in pregnancy. *J Am Coll Surg.* 2008;207(4):539–42. PubMed PMID: 18926456.
111. Grant T, Neuschler E, Hartz 3rd W. Groin pain in women: use of sonography to detect occult hernias. *J Ultrasound Med.* 2011;30(12):1701–7. PubMed PMID: 22124006.
112. Pattamapasong N, Sivasomboon C, Settakorn J, Pruksakorn D, Muttarak M. Pitfalls in imaging of musculoskeletal infections. *Semin Musculoskelet Radiol.* 2014;18(1):86–100. PubMed PMID: 24515885.
113. Soldatos T, Andreisek G, Thawait GK, Guggenberger R, Williams EH, Carrino JA, et al. High-resolution 3-T MR neurography of the lumbosacral plexus. *Radiographics.* 2013;33(4):967–87. PubMed PMID: 23842967.

114. Dunk RA, Langhoff-Roos J. Osteomyelitis of the pubic symphysis after spontaneous vaginal delivery. *BMJ Case Rep.* 2010;2010. PubMed PMID: 22789689. Pubmed Central PMCID: 3030074.
115. Lentz SS. Osteitis pubis: a review. *Obstet Gynecol Surv.* 1995;50(4):310–5. PubMed PMID: 7783998.
116. Ross JJ, Hu LT. Septic arthritis of the pubic symphysis: review of 100 cases. *Medicine.* 2003;82(5):340–5. PubMed PMID: 14530783.
117. Nelson DB, Manders DB, Shivvers SA. Primary iliopsoas abscess and pregnancy. *Obstet Gynecol.* 2010;116 Suppl 2:479–82. PubMed PMID: 20664425.
118. Sokolov KM, Kreye E, Miller LG, Choi C, Tang AW. Postpartum iliopsoas pyomyositis due to community-acquired methicillin-resistant *Staphylococcus aureus*. *Obstet Gynecol.* 2007;110(2 Pt 2):535–8. PubMed PMID: 17666656.
119. Young OM, Werner E, Sfakianaki AK. Primary psoas muscle abscess after an uncomplicated spontaneous vaginal delivery. *Obstet Gynecol.* 2010;116 Suppl 2:477–9. PubMed PMID: 20664424.
120. Liu XQ, Li FC, Wang JW, Wang S. Postpartum septic sacroiliitis misdiagnosed as sciatic neuropathy. *Am J Med Sci.* 2010;339(3):292–5. PubMed PMID: 20090512.
121. Mulvey JM. Postpartum septic sacroiliitis coincident with labour epidural analgesia. *Anaesth Intensive Care.* 2008;36(6):875–8. PubMed PMID: 19115661.
122. Hobson-Webb LD, Padua L, Martinoli C. Ultrasonography in the diagnosis of peripheral nerve disease. *Expert Opin Med Diagn.* 2012;6(5):457–71. PubMed PMID: 23480810.
123. Martinoli C, Gandolfo N, Perez MM, Klauser A, Palmieri F, Padua L, et al. Brachial plexus and nerves about the shoulder. *Semin Musculoskelet Radiol.* 2010;14(5):523–46. PubMed PMID: 21072730.
124. Chhabra A, Thawait GK, Soldatos T, Thakkar RS, Del Grande F, Chalian M, et al. High-resolution 3T MR neurography of the brachial plexus and its branches, with emphasis on 3D imaging. *AJNR Am J Neuroradiol.* 2013;34(3):486–97. PubMed PMID: 22976233.
125. Padua L, Di Pasquale A, Liotta G, Granata G, Pazzaglia C, Erra C, et al. Ultrasound as a useful tool in the diagnosis and management of traumatic nerve lesions. *Clin Neurophysiol.* 2013;124(6):1237–43. PubMed PMID: 23380690.
126. Padua L, Liotta G, Di Pasquale A, Granata G, Pazzaglia C, Caliendo P, et al. Contribution of ultrasound in the assessment of nerve diseases. *Eur J Neurol.* 2012;19(1):47–54. PubMed PMID: 21554493.
127. Klauser AS, Faschingbauer R, Bauer T, Wick MC, Gabl M, Arora R, et al. Entrapment neuropathies II: carpal tunnel syndrome. *Semin Musculoskelet Radiol.* 2010;14(5):487–500. PubMed PMID: 21072727.
128. Tagliafico A, Bignotti B, Miguel Perez M, Reni L, Bodner G, Martinoli C. Contribution of ultrasound in the assessment of patients with suspect idiopathic pudendal nerve disease. *Clin Neurophysiol.* 2013;7. PubMed PMID: 24368033.
129. Martinoli C, Court-Payen M, Michaud J, Padua L, Altafini L, Marchetti A, et al. Imaging of neuropathies about the ankle and foot. *Semin Musculoskelet Radiol.* 2010;14(3):344–56. PubMed PMID: 20539959.
130. Kamath S, Venkatanarasimha N, Walsh MA, Hughes PM. MRI appearance of muscle denervation. *Skeletal Radiol.* 2008;37(5):397–404. PubMed PMID: 18360752.
131. Kim SJ, Hong SH, Jun WS, Choi JY, Myung JS, Jacobson JA, et al. MR imaging mapping of skeletal muscle denervation in entrapment and compressive neuropathies. *Radiographics.* 2011;31(2):319–32. PubMed PMID: 21415181.
132. Cartwright MS, Walker FO. Neuromuscular ultrasound in common entrapment neuropathies. *Muscle Nerve.* 2013;48(5):696–704. PubMed PMID: 23681885.
133. Fritz J, Chhabra A, Wang KC, Carrino JA. Magnetic resonance neurography-guided nerve blocks for the diagnosis and treatment of chronic pelvic pain syndrome. *Neuroimaging Clin N Am.* 2014;24(1):211–34. PubMed PMID: 24210321.
134. Klein A. Peripheral nerve disease in pregnancy. *Clin Obstet Gynecol.* 2013;56(2):382–8. PubMed PMID: 23563878.

135. Bradshaw AD, Advincula AP. Postoperative neuropathy in gynecologic surgery. *Obstet Gynecol Clin North Am.* 2010;37(3):451–9. PubMed PMID: 20674786.
136. Massey EW, Stolp KA. Peripheral neuropathy in pregnancy. *Phys Med Rehabil Clin N Am.* 2008;19(1):149–62, vii–viii. PubMed PMID: 18194755.
137. Osterman M, Ilyas AM, Matzon JL. Carpal tunnel syndrome in pregnancy. *Orthop Clin North Am.* 2012;43(4):515–20. PubMed PMID: 23026467.
138. Tagliafico A, Pugliese F, Bianchi S, Bodner G, Padua L, Rubino M, et al. High-resolution sonography of the palmar cutaneous branch of the median nerve. *AJR Am J Roentgenol.* 2008;191(1):107–14. PubMed PMID: 18562732.
139. Anderson SE, Steinbach LS, De Monaco D, Bonel HM, Hurtienne Y, Voegelin E. “Baby wrist”: MRI of an overuse syndrome in mothers. *AJR Am J Roentgenol.* 2004;182(3):719–24. PubMed PMID: 14975975.
140. Beltran LS, Bencardino J, Ghazikhanian V, Beltran J. Entrapment neuropathies III: lower limb. *Semin Musculoskelet Radiol.* 2010;14(5):501–11. PubMed PMID: 21072728.
141. Martinoli C, Miguel-Perez M, Padua L, Gandolfo N, Zicca A, Tagliafico A. Imaging of neuropathies about the hip. *Eur J Radiol.* 2013;82(1):17–26. PubMed PMID: 21549536.
142. Tagliafico A, Serafini G, Lacelli F, Perrone N, Valsania V, Martinoli C. Ultrasound-guided treatment of meralgia paresthetica (lateral femoral cutaneous neuropathy): technical description and results of treatment in 20 consecutive patients. *J Ultrasound Med.* 2011;30(10):1341–6. PubMed PMID: 21968484.
143. Chhabra A, Del Grande F, Soldatos T, Chalian M, Belzberg AJ, Williams EH, et al. Meralgia paresthetica: 3-tesla magnetic resonance neurography. *Skeletal Radiol.* 2013;42(6):803–8. PubMed PMID: 23306718.
144. Moritz T, Prosch H, Berzaczky D, Happak W, Lieba-Samal D, Bernathova M, et al. Common anatomical variation in patients with idiopathic meralgia paresthetica: a high resolution ultrasound case-control study. *Pain Physician.* 2013;16(3):E287–93. PubMed PMID: 23703427.
145. Mulvaney SW. Ultrasound-guided percutaneous neuroplasty of the lateral femoral cutaneous nerve for the treatment of meralgia paresthetica: a case report and description of a new ultrasound-guided technique. *Curr Sports Med Rep.* 2011;10(2):99–104. PubMed PMID: 21623291.
146. Butchart AG, Mathews M, Surendran A. Complex regional pain syndrome following protracted labour*. *Anaesthesia.* 2012;67(11):1272–4. PubMed PMID: 22881282.
147. Hong BY, Ko YJ, Kim HW, Lim SH, Cho YR, Lee JI. Intrapartum obturator neuropathy diagnosed after cesarean delivery. *Arch Gynecol Obstet.* 2010;282(3):349–50. PubMed PMID: 20306064.
148. Nogajski JH, Shnier RC, Zagami AS. Postpartum obturator neuropathy. *Neurology.* 2004;63(12):2450–1. PubMed PMID: 15623734.
149. Soldatos T, Durand DJ, Subhawong TK, Carrino JA, Chhabra A. Magnetic resonance imaging of musculoskeletal infections: systematic diagnostic assessment and key points. *Acad Radiol.* 2012;19(11):1434–43. PubMed PMID: 22884398.
150. Tagliafico A, Succio G, Serafini G, Martinoli C. Diagnostic accuracy of MRI in adults with suspect brachial plexus lesions: a multicentre retrospective study with surgical findings and clinical follow-up as reference standard. *Eur J Radiol.* 2012;81(10):2666–72. PubMed PMID: 22071340.
151. Tagliafico A, Succio G, Serafini G, Martinoli C. Diagnostic performance of ultrasound in patients with suspected brachial plexus lesions in adults: a multicenter retrospective study with MRI, surgical findings and clinical follow-up as reference standard. *Skeletal Radiol.* 2013;42(3):371–6. PubMed PMID: 22707095.
152. Tagliafico A, Perez MM, Martinoli C. High-resolution ultrasound of the pudendal nerve: normal anatomy. *Muscle Nerve.* 2013;47(3):403–8. PubMed PMID: 23180573.
153. Fanucci E, Manenti G, Ursone A, Fusco N, Mylonakou I, D’Urso S, et al. Role of interventional radiology in pudendal neuralgia: a description of techniques and review of the literature. *Radiol Med.* 2009;114(3):425–36. PubMed PMID: 19277838.
154. Thoumas D, Leroi AM, Mauillon J, Muller JM, Benozio M, Denis P, et al. Pudendal neuralgia: CT-guided pudendal nerve block technique. *Abdom Imaging.* 1999;24(3):309–12. PubMed PMID: 10227901.

Chapter 4

Diagnosis of Pelvic Girdle Pain

Jaclyn H. Bonder and Laura Fitzpatrick

Introduction

Pelvic girdle pain (PGP) is an important and poorly understood cause of morbidity among pregnant women. With a point prevalence of 20 % in this population [1–3], PGP has been found to be the second-most common reason for sick leave among pregnant women (behind fatigue and sleep problems) [4]. Women with PGP in pregnancy are also three times more likely to experience postpartum depression [5]. Understanding the definition of PGP and techniques to accurately diagnose, it is essential in reducing pain and improving quality of life for pregnant patients.

PGP can be defined as pain experienced between the posterior iliac crest and the gluteal fold. While it is often in the region of the sacroiliac joint (SIJ) and as such is considered a type of low back pain (LBP), it can occur anteriorly in the pelvis as well and may radiate to the area of the posterior thigh. Posterior PGP can occur with or without pain anteriorly in the pubic symphysis area but pain solely in the pubic symphysis region is also considered PGP. Patients with PGP will exhibit diminished capacity for standing, walking, and sitting. It is extremely important to note that the use of the term PGP has been established to refer to non-gynecologic and/or non-urologic disorders of pain.

LBP during pregnancy is a common occurrence and is seen anywhere between 50 and 80 % of healthy pregnancies [6, 7]. It can have many etiologies, including lumbar pathology, mechanical strain, and discogenic pain. Since back pain during

J.H. Bonder, MD (✉) L. Fitzpatrick, AB
Department of Rehabilitation Medicine, Weill Cornell Medical College—New York
Presbyterian, 525 E. 68th St., Baker Pavilion, 16th Floor, New York, NY 10021, USA
e-mail: jab9155@med.cornell.edu; ljf2004@med.cornell.edu

pregnancy is usually associated with radiating pain into the posterior thigh, the term “sciatica” is often used as its cause. However, there is evidence to suggest that typical sciatica, which can be from compression of the sciatic nerve or as a result of a lumbosacral radiculopathy or plexopathy, has a very low incidence during pregnancy [8–10]. However, lumbar causes of LBP such as radiculopathy, sciatic neuropathy, and facet pain need to be excluded in order for patients to be diagnosed with PGP. In addition, PGP can arise from trauma or reactive arthritis. Pregnancy-related PGP must be reproducible by specific clinical tests which are sensitive and that when combined are even more specific for pregnancy-related PGP. Such tests include Patrick’s Faber, Active Straight Leg Raise (ASLR), and posterior pelvic pain provocation (P4) test.

Etiology of PGP

Many potential causes for pregnancy-related PGP have been suggested in the literature. It is unlikely that just one of these is responsible; instead, PGP is likely to arise from a combination of several etiologies. PGP can be mechanical in nature as a result of abnormal motor control (muscle firing patterns). This is believed to result in maladaptive behaviors/positioning of joints, ligaments, or the bony pelvis. Clinically, this manifests as asymmetry or malalignment of the musculoskeletal structures leading to pain because these structures are thought to no longer be in their optimal state to anatomically support the pelvis. Clinicians describe this as mechanical or musculoskeletal dysfunction. Persistent malalignment and instability of the SIJ may lead to further tension and spasm in surrounding muscles which can perpetuate altered neurodynamics of the pelvis and chronic symptoms. It is well established that patients with a previous history of LBP are at high risk for low back and PGP during pregnancy [11] suggesting perhaps persistent mechanical dysfunction predating pregnancy is partly responsible for pregnancy-related PGP.

The likelihood of mechanical dysfunction of ligaments may increase due to the increase in ligament laxity that occurs during pregnancy. This change may be due to the action of the hormone relaxin, an insulin-like peptide hormone which peaks during the first trimester; however, a study done in 2003 by Marnarch et al. showed that the extent of laxity did not correlate with the level of relaxin [12] (see Chap. 2). Additionally, estradiol may also contribute to the increase joint laxity [13]. Whatever its etiology, the increase in joint laxity observed among pregnant women likely contributes to instability and increased movement of all joints during pregnancy. However, the pelvic girdle joints are especially affected, as the pelvis needs to have increased movement in order to widen to accommodate the pregnancy and the birthing process. The SIJ is normally an extremely stable joint; therefore, when the influence of pregnancy hormones compromises this stability, patients may develop pain. This instability can further lead to PGP if it is not compensated for by neuro-motor control alterations and is the reason that much PGP is of SIJ etiology.

SIJ pain can be experienced with or without pain of the pubic symphysis joint. Widening of this joint space is a normal physiologic change that occurs as part of the process a woman's body goes through to prepare for a vaginal birth and to deliver the baby safely. During pregnancy, it will usually increase up to about 2 mm and does not usually increase more than that without some type of trauma. It has been shown that severe pelvic pain in pregnant women is strongly associated with an increased symphyseal separation; however, relaxin levels do not correlate with degree of separation or with pelvic pain [14]. Most cases of a larger separation will be diagnosed postpartum and usually in association with a traumatic and/or instrumented labor and delivery. It has been shown that most pregnant woman will experience pain when the joint width is greater than 9.5 mm versus an average width of 6.3 mm in an asymptomatic pregnant woman [15].

As mentioned earlier, other causes of LBP with radiation down the posterior thigh include lumbar herniated disc or lumbosacral radiculopathy. However, lumbar disc herniations occur in about one in 10,000 pregnant woman, which is not significantly different from the rate in a nonpregnant woman of childbearing age. In a study by Weinreb et al., 53 % of pregnant and 54 % of nonpregnant women had an abnormal disc bulge or herniation at one or more lumbar or lumbosacral segments [16].

While the diagnoses mentioned above are the most common causes of PGP during pregnancy, there are other problems that should remain on the differential diagnosis. These include hip pathology (Chap. 8), inflammatory disorders, collagen abnormalities, and neuropathy (Chap. 6). It is important to note that anything that can happen in the nonpregnant state can happen in pregnancy including fractures and rarely the presentation of cancer. As such these patients need to be monitored for improvement in their symptoms because lack of improvement with proper treatment can point to a more serious etiology of their pain. Worrisome causes of PGP which need to remain on the differential if symptoms progressively worsen during pregnancy include sacral fractures, infections, and tumors. In addition, cauda equina syndrome is possible during pregnancy in patients with complaints of progressive weakness or new bowel/bladder incontinence with immediate imaging and spine surgery consult required.

History

In order to make a diagnosis of PGP and to determine the specific etiology for a given patient, a thorough history and physical examination are extremely important. A combination of specific clinical tests that reproduce the pain or functional disturbances should be performed to differentiate PGP from other sources of pain in the region [2]. The importance of these components in a patient's assessment is magnified by the fact that the practitioner is usually limited in other diagnostic tools such as imaging and injections.

Knowledge of the most common symptoms and risk factors for PGP can help guide the evaluation. The onset of pain can happen at any point during a pregnancy, but most patients will complain of pain between 18 and 36 weeks gestation [17]. Most patients will describe pain as LBP or pain in the region of the buttock, typically over the sacrum or the sacral sulcus. In addition, patients will describe pain in their “hip,” referring to pain in the lateral thigh and/or groin area. The pregnant woman with PGP can also report leg pain as well as numbness and tingling, often radiating down the back of the leg; as such, this pain can mimic lumbar radiculopathy or sciatica. When pain radiates into the inguinal or pubic symphysis region, patients may describe vaginal, rectal, or labial discomfort, indicating that pelvic floor pain may also be a source. Pelvic floor pain during pregnancy may also be characterized as deep pelvic pain, tailbone pain, or dyspareunia (Chap. 12). When this type of complaint is a major part of their clinical picture, it is important for patients to be seen by their obstetrician as well to ensure the health of the baby and rule out serious issues such as preterm labor.

Patients will often describe a feeling of giveaway weakness on the side of pain, making a complete neurologic exam essential in order to exclude a true neurologic deficit. Pain in the region of the SIJ with legs crossed is also a common feature. If patients describe pain with transitional movements such as going from sitting to standing, it is likely attributed to PGP of SIJ origin. Another hallmark symptom is pain that increases with speed of walking, with stair climbing, and with turning in bed. Patients with pain while moving in bed will often describe difficulty sleeping as a result of the discomfort and can awake from the pain. It is key to distinguish this type of nighttime pain from pain that wakes one up at night without any obvious etiology, which can be a cause for concern for possible malignancy.

As mentioned above, pubic symphysis pain from dysfunction is another form of PGP. Patients who experience pain related to the pubic symphysis will describe pain in their lower pelvis in the region of their pubic bone. They often feel pain in the groin or pelvis with weight bearing and walking which can be a cause of functional loss in this population. As a result of the pain they feel with weight bearing, they develop a more prominent waddling gait pattern. These patients will also describe pain with rolling over in bed that is not always relieved with cessation of movement and pain in the pelvis even when lying still in the side-lying position. Another hallmark of pubic symphysis pain is exquisite pain to palpation of the joint which remains after the examiner removes his/her finger. Patients who suffer from a separation or true diastasis of the pubic symphysis will usually describe a sudden pain and/or an audible pop or click during delivery. If it occurs after delivery, they usually have pain and swelling in the area of the pubic symphysis. Most telling of this condition is a patient’s difficulty and pain with trying to roll in bed or ambulate and weakness when lifting the legs. Patients may describe feeling exaggerated movement in the pubic area. Lastly, a woman may also describe that it is easier walking forwards than backwards.

Risk Factors

Risk factors for PGP during pregnancy are numerous. Systematic reviews have determined that physically strenuous work (i.e., work that involves twisting and bending the back several times per hour), history of previous LBP, history of lumbopelvic pain during or after pregnancy, history of PGP, and history of trauma to the pelvis are strong risk factors for PGP [2, 18, 19]. As Wu and colleagues have postulated, such factors could confer excess PGP risk by causing local tissue damage; however, psychological or multifactorial explanations cannot be ruled out [18]. Pelvic joint asymmetry has also been found to be strongly associated with PGP [20]. Other factors that have been found to confer increased risk of PGP include lack of exercise, diabetes, older age at menarche, and low education level [20–22]. A 2011 systematic review found weak evidence with regard to maternal height, maternal weight, fetal weight, oral contraceptives, smoking, prior epidural anesthesia, or prolonged second stage of labor as risk factors for PGP in pregnancy [22]. A 2013 study on 91,721 pregnancies during the years 1999–2008 also demonstrated no association between combination oral contraceptives and PGP. It did show, however, that lifetime exposure to progestin-only contraceptive pills or use of a progestin intrauterine device during the year preceding pregnancy was associated with PGP. The authors concluded that combined oral contraceptives can be used without fear of an elevated risk of PGP in pregnancy but that further research is needed on progestin-only contraceptives [23]. A variety of other factors have been studied and found not to be associated with PGP risk. These include maternal bone density, time since previous pregnancy, full-time work, prior stillbirth, and prior abortion [2].

Physical Exam

The physical examination guides the diagnoses during pregnancy due to the fact that additional diagnostic tools such as radiologic imaging are used on a limited basis (Chap. 3) During pregnancy, a physical exam is the best diagnostic tool. The practitioner must not be afraid to examine a pregnant woman. As mentioned earlier, a diagnosis of PGP can be made once pain related to the lumbar spine has been ruled out. The practitioner needs to examine a patient's SIJ, pubic symphysis, lumbar spine, and hip joint to determine the etiology of the pain, which can then guide treatment protocols.

The first step is a general examination of the pregnant woman, including vital signs. As in the nonpregnant state, pain can elevate one's blood pressure; however, hypertension in pregnancy is a serious complication that should warrant immediate referral to the obstetrician.

Since pain, no matter how severe, can have a significant impact on a woman's daily life and sleep, part of the physical exam should include assessment of patient's affect, mood, and behavior. Any signs of depression should be taken seriously and factored into treatment decisions.

The physical examination includes a thorough neuromuscular examination of the patient, including an evaluation of gait mechanics and posture. Given the anatomical changes that take place during a woman's pregnancy (Chap. 1), maladaptive gait mechanics and posture often develop that are thought to contribute to PGP. Hence, a detailed examination of both is extremely important and working on correcting these dysfunctions with physical therapy is a key component of treatment. Next, the practitioner needs to perform a neurologic exam of the lower extremities complete with manual muscle strength, sensory, and reflex testing. If a concern for upper motor neuron pathology exists, a Babinski reflex should be tested and clonus evaluated. If there are any neurologic findings or deficits such as weakness and/or sensory changes, women should be monitored and further assessed when warranted.

The next step in the physical examination is inspection of the patient's lumbar spine. As part of this portion of the evaluation, the examiner should notice whether the lordotic curve of the lumbar spine in the sagittal plane is increased or decreased. As the pregnancy progresses, most women will have an increased lumbar lordosis as a result of the enlarging uterus and increased ligament laxity along with an anterior pelvic tilt. Other deformities, i.e., scoliosis or rotational issues, should be noticed as well, as they can contribute to or cause lumbar segmental dysfunction and pain. Evaluation for functional leg length discrepancy can also help distinguish between sources of PGP and other mechanical pain. Lumbar range of motion is also useful, as testing in flexion, extension, side bending, and rotation may reveal lumbar spine pain or other lumbar muscular dysfunction which may be the primary pain generator or concomitant process.

Palpation of bony and muscular structures in the lumbosacral region including the vertebral bodies, the spinous processes, the sacral sulci, and the paraspinals is recommended. Tenderness in these areas can help point to the etiology of the back pain. Myofascial pain from weakness and dysfunction of the muscles of the back, hip, lower extremities, and abdomen can lead to both LBP and PGP. As such, assessment of iliopsoas, quadratus lumborum, gluteus medius/maximus, piriformis muscles, tensor fascia lata, iliotibial band, hamstrings, quadriceps, hip adductors, thoracolumbar fascia, and abdominal muscles should be performed for tenderness, tightness, and strength. In addition, muscle imbalances in these groups can lead to asymmetries of the posterior superior iliac spine (PSIS), iliac crest, anterior superior iliac spine (ASIS), pubic symphysis, iliac ala, greater trochanter, and/or gluteal folds and such pelvic obliquities contribute to the pain experience. Hip range of motion should also be examined while the patient is supine, noting any restrictions in range and pain with testing as these can signify a hip joint disorder.

Abdominal muscle evaluation should also include testing for a rectus diastasis. To do this, ask the patient to lie supine with her hips and knees flexed and feet flat on the table. Then, ask the patient to lift her head and shoulders off the table. Finally, palpate a cleft between the two rectus abdominis muscles from the pubic bone to the sternum. A positive and clinically significant test is considered a separation of two or more centimeters.

The next component of the examination is testing of the SIJ and pubic symphysis joint. As part of this evaluation, pelvic joint alignment, motion testing, and provocative maneuvers should be performed. There are several tests that have been studied for the

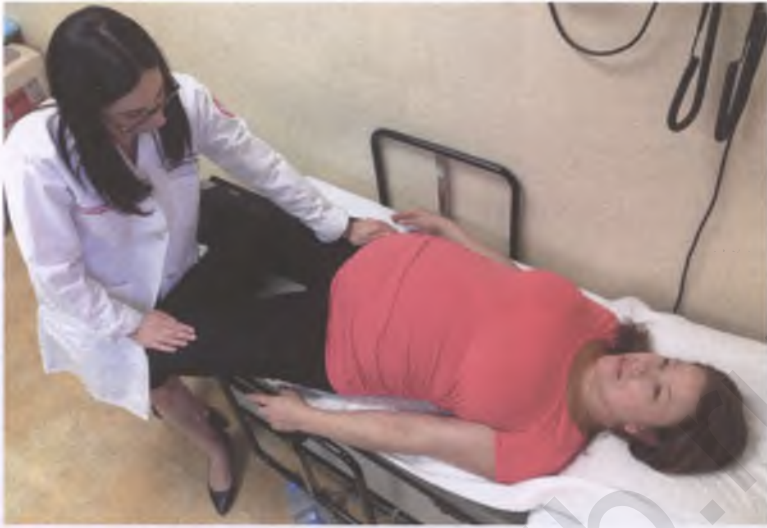
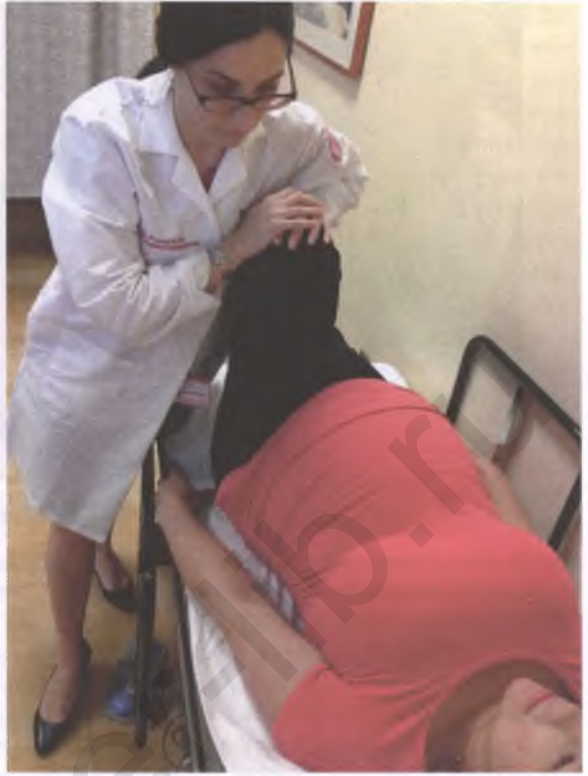
Fig. 4.1 Patrick's Faber test. Patient lays in supine; one leg flexed, abducted, and externally rotated while exerting downward pressure on the ipsilateral knee and contralateral anterior superior iliac spine; positive test is when pain is provoked in SIJ

diagnosis of PGP in pregnancy. In general, the specificity of these diagnostic maneuvers in PGP is generally higher than the sensitivity. Therefore, a frequent recommendation is to perform all the tests together, rather than relying on any individual maneuver for diagnosis [19]. Albert and colleagues examined more than 2,000 pregnant women using inspection of pelvic tilt, palpation of muscles, a test for a locked SIJ, nine pain provocation tests for the SIJ, and two pain provocation tests for the symphysis. The highest sensitivity and specificity for the SIJ were found for the P4 test, Patrick's Faber test, and Menell's test. The highest sensitivity and specificity for the symphysis was found with palpation of the symphysis and the Modified Trendelenburg test [24].

Pain provocation tests for PGP include Patrick's Faber, P4 test, Gaenslen's test, and the Modified Trendelenburg test. Patrick's Faber is performed by having the patient lie supine, and then flexing, abducting, and externally rotating the leg, while exerting downward pressure on the ipsilateral knee and contralateral ASIS (Fig. 4.1). A positive test is when pain is provoked in posterior pelvic joints. The sensitivity for this test in PGP in pregnancy ranges from 0.40 to 0.70 [24, 25] and specificity is 0.99 [24]. The P4 test is specific to pregnancy-related PGP. In this test, the hip is flexed to 90° and a downward/posterior force is applied to the femur while the patient is in a supine position (Fig. 4.2). A positive test is when there is reproduction of a patient's pain in the ipsilateral posterior pelvic girdle when the force is applied. The sensitivity for this test in pregnancy PGP ranges from 0.69 to 0.93 [24, 26–28] and the specificity ranges from 0.69 to 0.98 [24, 26–28]. Gaenslen's test is performed with the hip joint flexed maximally on one side and the contralateral hip joint extended. The exam can be performed by having the patient lie on her back or in side-lying. If done in supine, the flexed knee is pushed towards the patient's chest

Fig. 4.2 Posterior pelvic pain provocation test. Hip is flexed to 90° and a downward/posterior force is applied to the femur while the patient is supine; positive test is reproduction of a patient's pain in the ipsilateral posterior pelvic girdle when the force is applied



while the other leg is allowed to fall off the side of the examination table, and downward pressure is applied to the knee to hyperextend the hip joint (Fig. 4.3). When the test is performed with the patient in the lateral recumbent position, the patient lies with the painful side on top. Then, the lower leg is placed into a position of maximal hip flexion. The involved hip is taken into extension while stability is maintained in the pelvis. The test is considered positive if the patient experiences pain on the hyperextended side. Sensitivity and specificity data for Gaenslen's maneuver have not, to our knowledge, been reported in the literature for pregnancy-related PGP. For the Modified Trendelenburg test which is done while the patient is standing, the patient is asked to stand on one leg and bring the other leg into 90° of hip and knee flexion. A test is considered positive when there is reproduction of pain around the pubic symphysis. Sensitivity for this test in pregnancy PGP ranges from 0.40 to 0.62 [24, 25] and specificity has been reported as 0.99 [24].

Another set of tests that can help with diagnosis are two distinct pain palpation tests: the long dorsal ligament (LDL) test and palpation of the pubic symphysis. For the LDL test, the patient is placed in side-lying and pressure is placed on the LDL, which can be palpated just inferior and medial to the PSIS. To palpate the pubic symphysis effectively, patients are placed in supine. In both tests, a positive test is pain that lasts greater than 5 s after the examiner removes their finger and indicates

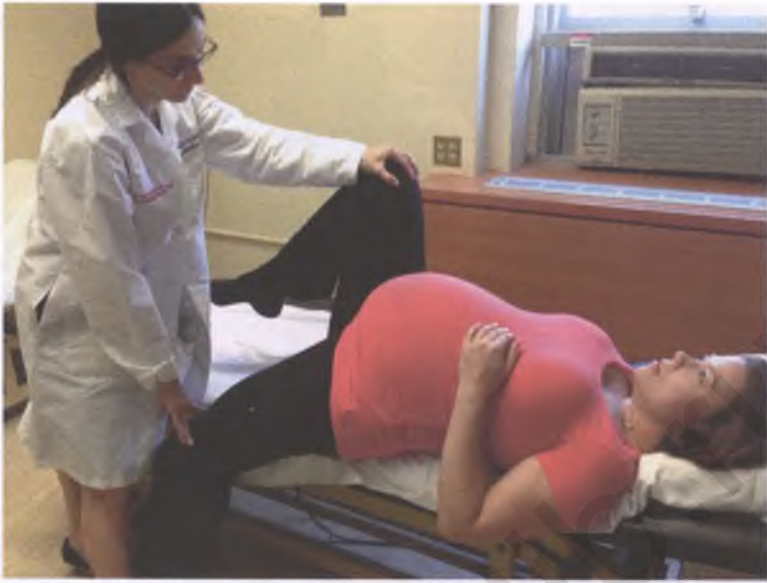

Fig. 4.3 Gaenslen's test. In supine, flexion at hip and knee with the flexed knee pushed towards the patient's chest; painful leg off side of the examination table, and downward pressure is applied to the knee to hyperextend the hip joint

that this area may be a true pain generator. Sensitivity for the LDL test in pregnancy PGP ranges from 0.35 to 0.74 [24, 25, 28] and specificity from 0.98 to 1.00 [24, 28]. Sensitivity for palpation of the pubic symphysis in pregnancy PGP ranges from 0.60 to 0.87 [24, 25, 28] and specificity from 0.85 to 0.99 [24, 28].

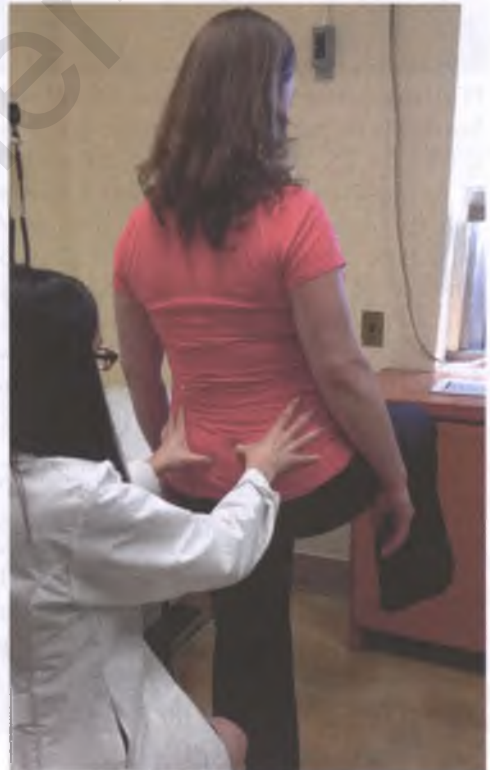
An important functional test, which assesses the ability of the SIJ to transfer load from the lumbosacral spine to the lower extremities, is the ASLR. The first part of the test the patient lies supine and is asked to raise each leg, one at a time. Pain or sensation of one or both of the legs feeling heavy or difficult to raise is noted (Fig. 4.4). A positive test is described when pain or sensation of the leg being heavy is at least partially or completely relieved with externally applied and medially directed compression at a level just beneath the iliac crests. Sensitivity for the ASLR in pregnancy PGP ranges from 0.54 to 0.87 [27, 29–31] and specificity from 0.57 to 0.97 [27, 29–31].

The Modified Trendelenburg test mentioned above can also be used to assess muscle function. When performed, a positive test for muscle dysfunction is a descending hip on the flexed side which indicates weakness. Lastly, the Stork test is a measure of intact load transfer onto the SIJ. The examiner palpates the patient's PSIS on the side to which weight is to be transferred for single-leg stance and with the other hand palpates the sacrum at S2 (Fig. 4.5). The patient is asked to lift the other leg into 90° of hip and knee flexion. A positive test is impaired load transfer onto the stance side, where the SIJ may move anteriorly or shift cephalad.

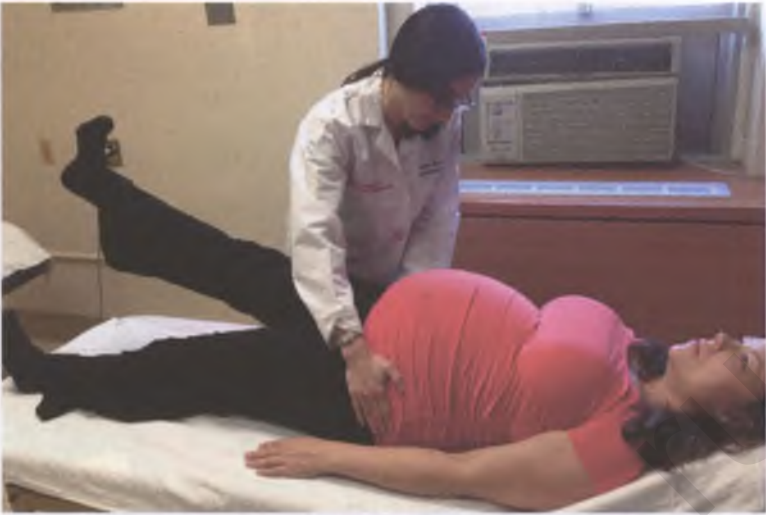

Fig. 4.4 Active Straight Leg Raise. Patient lies supine, asked to raise each leg, one at a time, pain or sensation of heaviness in one or both legs feeling noted; positive test when pain or sensation of the leg being heavy is at least partially or completely relieved with externally applied and medially directed compression

Fig. 4.5 Stork test. Palpate the patient's PSIS on the side to which weight is to be transferred for single-leg stance, the other hand palpates the sacrum at S2, patient is asked to lift the other leg into 90° of hip and knee flexion; positive test is impaired load transfer onto the stance side, where the SIJ may move anteriorly or shift cephalad



Conclusion

The differential diagnosis for pregnancy-related PGP varies from lumbar spine pathology to stress fracture in the sacrum. However, the most common etiologies are SIJ and pubic symphysis dysfunction as a result of increased ligament laxity and poor motor control. It is usually diagnosed clinically by history and physical examination since radiologic imaging is not always possible. For the most accurate diagnosis, it is recommended that practitioners use a combination of several exam maneuvers to reproduce the pain. These patients should be followed regularly to ensure improvement in their symptoms with appropriate therapy.

References

1. Albert HB, Godskesen M, Westergaard JG. Incidence of four syndromes of pregnancy-related pelvic joint pain. *Spine*. 2002;27(24):2831–4.
2. Vleeming A, Albert HB, Ostgaard HC, Sturesson B, Stuge B. European guidelines for the diagnosis and treatment of pelvic girdle pain. *Eur Spine J*. 2008;17(6):794–819.
3. Larsen EC, Wilken-Jensen C, Hansen A, Jensen DV, Johansen S, Minck H, et al. Symptom-giving pelvic girdle relaxation in pregnancy. I: prevalence and risk factors. *Acta Obstet Gynecol Scand*. 1999;78(2):105–10.
4. Dorheim SK, Bjorvatn B, Eberhard-Gran M. Sick leave during pregnancy: a longitudinal study of rates and risk factors in a Norwegian population. *BJOG*. 2013;120(5):521–30.
5. Gutke A, Josefsson A, Oberg B. Pelvic girdle pain and lumbar pain in relation to postpartum depressive symptoms. *Spine*. 2007;32(13):1430–6.
6. Carlson HL, Carlson NL, Pasternak BA, Balderston KD. Understanding and managing the back pain of pregnancy. *Curr Womens Health Rep*. 2003;3(1):65–71.
7. Stapleton DB, MacLennan AH, Kristiansson P. The prevalence of recalled low back pain during and after pregnancy: a South Australian population survey. *Aust N Z J Obstet Gynaecol*. 2002;42(5):482–5.
8. Yoshimoto M, Kawaguchi S, Takebayashi T, Isogai S, Kurata Y, Nonaka S, et al. Diagnostic features of sciatica without lumbar nerve root compression. *J Spinal Disord Tech*. 2009;22(5):328–33.
9. Katirji B, Wilbourn AJ, Scarberry SL, Preston DC. Intrapartum maternal lumbosacral plexopathy. *Muscle Nerve*. 2002;26(3):340–7.
10. Delarue MW, Vles JS, Hasaart TH. Lumbosacral plexopathy in the third trimester of pregnancy: a report of three cases. *Eur J Obstet Gynecol Reprod Biol*. 1994;53(1):67–8.
11. Bastiaanssen JM, De Bie RA, Bastiaenen CH, Essed GG, Van Den Brandt PA. A historical perspective on pregnancy-related low back and/or pelvic girdle pain. *Eur J Obstet Gynecol Reprod Biol*. 2005;120(1):3–14.
12. Marnach ML, Ramin KD, Ramsey PS, Song SW, Stensland JJ, An KN. Characterization of the relationship between joint laxity and maternal hormones in pregnancy. *Obstet Gynecol*. 2003;101(2):331–5.
13. Charlton WP, Coslett-Charlton LM, Ciccotti MG. Correlation of estradiol in pregnancy and anterior cruciate ligament laxity. *Clin Orthop Relat Res*. 2001;387:165–70.
14. Bjorklund K, Bergstrom S, Nordstrom ML, Ulmsten U. Symphyseal distention in relation to serum relaxin levels and pelvic pain in pregnancy. *Acta Obstet Gynecol Scand*. 2000;79(4):269–75.
15. Schoellner C, Szoke N, Siegburg K. [Pregnancy-associated symphysis damage from the orthopedic viewpoint—studies of changes of the pubic symphysis in pregnancy, labor and post partum]. *Z Orthop Grenzgeb*. 2001;139(5):458–62.

16. Weinreb JC, Wolbarsht LB, Cohen JM, Brown CE, Maravilla KR. Prevalence of lumbosacral intervertebral disk abnormalities on MR images in pregnant and asymptomatic nonpregnant women. *Radiology*. 1989;170(1 Pt 1):125–8.
17. Ostgaard HC, Andersson GB, Karlsson K. Prevalence of back pain in pregnancy. *Spine*. 1991;16(5):549–52.
18. Wu WH, Meijer OG, Uegaki K, Mens JM, van Dieen JH, Wuisman PI, et al. Pregnancy-related pelvic girdle pain (PPP), I: terminology, clinical presentation, and prevalence. *Eur Spine J*. 2004;13(7):575–89.
19. Kanakaris NK, Roberts CS, Giannoudis PV. Pregnancy-related pelvic girdle pain: an update. *BMC Med*. 2011;9:15.
20. Gjestland K, Bo K, Owe KM, Eberhard-Gran M. Do pregnant women follow exercise guidelines? Prevalence data among 3482 women, and prediction of low-back pain, pelvic girdle pain and depression. *Br J Sports Med*. 2013;47(8):515–20.
21. Eberhard-Gran M, Eskild A. Diabetes mellitus and pelvic girdle syndrome in pregnancy—is there an association? *Acta Obstet Gynecol Scand*. 2008;87(10):1015–9.
22. Bjelland EK, Eberhard-Gran M, Nielsen CS, Eskild A. Age at menarche and pelvic girdle syndrome in pregnancy: a population study of 74 973 women. *BJOG*. 2011;118(13):1646–52.
23. Bjelland EK, Kristiansson P, Nordeng H, Vangen S, Eberhard-Gran M. Hormonal contraception and pelvic girdle pain during pregnancy: a population study of 91,721 pregnancies in the Norwegian Mother and Child Cohort. *Hum Reprod*. 2013;28(11):3134–40.
24. Albert H, Godskesen M, Westergaard J. Evaluation of clinical tests used in classification procedures in pregnancy-related pelvic joint pain. *Eur Spine J*. 2000;9(2):161–6.
25. Hansen A, Jensen DV, Wormslev M, Minck H, Johansen S, Larsen EC, et al. Symptom-giving pelvic girdle relaxation in pregnancy. II: symptoms and clinical signs. *Acta Obstet Gynecol Scand*. 1999;78(2):111–5.
26. Ostgaard HC, Zetherstrom G, Roos-Hansson E. The posterior pelvic pain provocation test in pregnant women. *Eur Spine J*. 1994;3(5):258–60.
27. Robinson HS, Mengshoel AM, Bjelland EK, Vollestad NK. Pelvic girdle pain, clinical tests and disability in late pregnancy. *Man Ther*. 2010;15(3):280–5.
28. Kristiansson P, Svardsudd K. Discriminatory power of tests applied in back pain during pregnancy. *Spine*. 1996;21(20):2337–43; discussion 43–4.
29. Mens JM, Vleeming A, Snijders CJ, Koes BW, Stam HJ. Reliability and validity of the active straight leg raise test in posterior pelvic pain since pregnancy. *Spine*. 2001;26(10):1167–71.
30. Damen L, Buyruk HM, Guler-Uysal F, Lotgering FK, Snijders CJ, Stam HJ. The prognostic value of asymmetric laxity of the sacroiliac joints in pregnancy-related pelvic pain. *Spine*. 2002;27(24):2820–4.
31. Mens JM, Huis In't Veld YH, Pool-Goudzwaard A. The Active Straight Leg Raise test in lumbopelvic pain during pregnancy. *Man Ther*. 2012;17(4):364–8.

Chapter 5

Treatment, Bracing, and Modalities in Pelvic Girdle Pain

Danielle Sarno and Farah Hameed

Introduction

Pregnancy-related low back pain (PLBP), pregnancy-related pelvic girdle pain (PPGP), and pregnancy-related lumbopelvic pain (PLPP) are common and disabling conditions that have gained attention from the medical and scientific communities. In this chapter, we will discuss the treatment options available for these conditions.

As studies have been methodologically heterogeneous and have used variable definitions for pelvic pain during pregnancy, there are variable incidence and point prevalence rates of these conditions in the literature (ranging from 4 to 76.4 %) [1]. Per Wu et al., approximately 45 % of all pregnant women and 25 % of all women postpartum experience PPGP and/or PLBP, although these values decrease by 20 % if mild symptoms are excluded [2]. There is no consensus yet on the terminology to identify these pain conditions, but it is accepted that PPGP and PLBP can be distinguished diagnostically and are indeed distinct entities [2]. PLPP is considered to be a combination of low back pain and pelvic girdle pain. Of women with PPGP and/or PLBP during pregnancy, approximately 45 % have mild symptoms only, 25 % have very serious pain, and 8 % are severely disabled [2]. Of women with PPGP and/or PLBP postpartum, approximately 80 % have mild symptoms and 7 % have severe symptoms [2].

D. Sarno, MD

Department of Rehabilitation Medicine, New York-Presbyterian/Columbia University
and Weill Cornell Medical Centers, New York, NY, USA
e-mail: daniellesarno11@gmail.com

F. Hameed, MD (✉)

Department of Rehabilitation and Regenerative Medicine, Columbia University
Medical Center, 180 Fort Washington, Suite 1-199, New York, NY 10032, USA
e-mail: Farah.hameed@gmail.com

There are many hypothesized etiologies of pregnancy-related low back and pelvic girdle pain, including mechanical/anatomical changes, hormonal influences leading to ligamentous laxity, as well as inflammatory, vascular, and neural (peripheral and central) factors. During pregnancy, there may be a weight gain of approximately 20–40 lbs [3] and the muscles of the pelvic floor are relied upon to bear the weight of the growing uterus. Anatomical changes during pregnancy include lengthening and separation of the abdominal muscles, a shift in the center of gravity upward and forward [4], thereby causing an increase in lumbar lordosis [4] and rotation of the pelvis on the femora [5]. Due to these altered biomechanics, the erector spinae muscles have to work harder in order to maintain upright posture [6]. Additionally, due to hormonal influences, there may be an increase in ligamentous laxity, especially during the second and third trimester, which has been suggested to increase pelvic girdle relaxation and be a cause of PPGP [7].

It has been demonstrated by Damen et al. that asymmetric laxity of the SI joint as revealed by Doppler imaging is associated with moderate to severe PPGP [8].

Clinical findings of PLPP include the onset of symptoms between 18 and 36 weeks and patient reports of low back, buttock, hip, anterior/groin thigh pain, and leg pain/numbness/tingling [2, 9]. Patients sometimes report pain with crossing of their legs and with transitional motions (e.g., sit to stand, rolling in bed). Pain often is greater with increased speed of walking, increased stride length, getting up from the floor, and climbing stairs [2].

Physical exam can distinguish posterior pelvic pain from lumbar pain by several maneuvers. The posterior pelvic pain provocation (PPPP) test [10], the Active Straight Leg Raise (ASLR) test [11], and the Patrick/FABER test [12] may elicit symptoms in the pelvic girdle and are the most sensitive and specific examination maneuvers to evaluate PPGP [9]. With these tests, the examiner manipulates the patients' legs to put pressure on the pelvic joints. Palpation over the soft tissue of the sacroiliac joint (SIJ), long dorsal ligament, pubic symphysis, and gluteal region helps to distinguish pelvic pain from low back pain [1].

Treatment

It has been shown that many women consider back discomfort as an inevitable part of pregnancy and do not seek treatment from a health care professional. Only 50 % of pregnant women with low back or pelvic pain visit a physician about these symptoms [13]. Women who rate their pain higher on a visual analog scale (VAS) are more likely to see a physician about it [13].

Treatment options include physical therapy/exercise, pharmacologic treatments, bracing, modalities, and integrative therapies, such as acupuncture. Conservative management is preferred during pregnancy. Specific goals of rehabilitation include addressing biomechanical factors and posture, as well as improving neuromuscular control, awareness, and overall function [14, 15].

Physical Therapy and Exercise

Physical therapy is often recommended as first-line conservative treatment of pregnancy-related pelvic and low back pain. In the treatment of PPGP, physical therapy focuses on manual therapy and self-mobilization, postural alignment/pelvic tilt, symmetrical body mechanics education, core/gluteal strengthening, and individualized pelvic stabilization exercises [1]. Physical therapy and exercise as treatment options for pregnancy-related back and pelvic pain have been studied in a limited scope. Although there is conflicting evidence that supports physical therapy as an effective treatment for PLPP, anecdotally, it has been shown to be helpful. Per Stuge et al., it is due to the heterogeneity and the varying quality of the studies that no strong evidence exists regarding the effect of physical therapy interventions on the prevention and treatment of back and pelvic pain related to pregnancy [16]. The prospective controlled clinical trials included in a systematic review by Stuge et al. were heterogeneous regarding participants, outcome measures, and interventions [16].

Back pain-reducing programs involving exercise and education are often implemented early in pregnancy [13]. There is some evidence to suggest that these programs can reduce pain intensity and anxiety, decrease the amount of sick leave taken, and prevent prolonged postpartum back pain and recurrence at 6-year follow-up [13]. Per Sabino et al., exercise before and early in pregnancy strengthens abdominal, back, and pelvic muscles, which improves posture and allows increased weight-bearing ability. Low intensity exercise also can decrease pain once it develops [13]. An exercise program during the second half of pregnancy has been shown to significantly reduce pain [17]. Pelvic tilts, knee pull, straight leg raising, curl up, lateral straight leg raising, and Kegel exercises are particularly effective in relieving lumbar pain in pregnant women [13]. Water gymnastics was found to improve pain intensity and reduce sick leave during pregnancy by one randomized controlled trial of high methodological quality [18]. Additionally, studies have shown that physical fitness before pregnancy reduces the risk of developing LBP in any subsequent pregnancies [15]. This positive effect of exercise is similar to that seen in the general population. The exercises recommended for PLBP are similar to those used in non-pregnant patients with LBP, with minor modifications for pregnancy [15]. Once the acute pain resolves, individually tailored lumbar strengthening and stretching exercises can be started.

As PPGP is thought to be related to decreased stability of the pelvic girdle joints [1], individualized treatment including specific stabilizing exercises may be beneficial to women with PPGP [16]. Based upon a prospective randomized controlled trial examining the effect of physical therapy with specific stabilizing exercises versus physical therapy without specific stabilizing exercises, Stuge et al., concluded that a treatment program with specific stabilizing exercises, integrated functionally, is effective in reducing pain and improving quality of life in women with PGP after pregnancy [16]. The specific stabilizing exercises included training of the transverse abdominal wall muscles with co-activation of the multifidi in the lumbosacral region and training of the gluteus maximus, latissimus dorsi, oblique abdominal muscles,

erector spinae, quadratus lumborum, and hip adductors and abductors. Individual guidance and exercise program adjustments were given by the physical therapist. Stuge et al. noted that the maintained improvements may be due to the effect of integrating specific stabilizing exercises into daily activities. The goals of the exercises provided were to obtain an improved ability to dynamically stabilize the lumbopelvic region during functional tasks as well as to alter automatic patterns of muscle recruitment within the trunk musculature. A study by Cholewicki and Gill demonstrated the importance of motor control to coordinate muscle recruitment between the small intrinsic spine muscles and the large musculature to ensure stability during daily activities [19]. Additionally, Ostgaard et al. found that an individualized training program based on ergonomic advice and exercises resulted in reduction of sick leave in women with PLBP, but not in those with PGP [15]. In a prospective controlled cohort study by Noren et al., the intervention group was given education and physical therapy and was found to have less “sick days” and improved LPP compared to the control group who was given no specific treatment (30.4 vs. 53.6 days/women) [14].

Another notable treatment option is osteopathic manipulative therapy (OMT) [20]. OMT is a hands-on, whole body approach to diagnose, treat, and prevent illness or injury, during which the osteopathic physician moves muscles and joints using techniques including stretching, gentle pressure, and resistance. Manual therapy is thought to influence the spinal “gating” mechanism and the descending pain suppression system at spinal and supraspinal levels to decrease pain. In addition, it is thought to return a vertebra to its normal position or restore lost mobility [21]. Spinal manipulation and mobilization are part of a manual therapy package that may also include soft tissue/myofascial release. Gentle OMT is considered to be safe during pregnancy [20], although contraindications to OMT for low back pain in pregnancy include undiagnosed vaginal bleeding, ectopic pregnancy, placental abruption, untreated deep vein thrombosis, elevated maternal blood pressure, pre-term labor, unstable maternal vital signs, and fetal distress [22].

Per guidelines by the American College of Obstetricians and Gynecologists (ACOG) for exercise during pregnancy and the postpartum period, pregnant women with uncomplicated pregnancies should be encouraged to continue and engage in physical activities [23]. All active pregnant women should be examined periodically to assess the effects of their exercise programs on the developing fetus, so that adjustments can be made if necessary [23]. Women with medical or obstetric complications should be carefully evaluated before recommendations on physical activity participation during pregnancy are made [23]. Despite the fact that pregnancy is associated with profound anatomical and physiological changes, exercise has minimal risks and confirmed benefits for most women [23]. However, it is important to be aware of the absolute and relative contraindications to aerobic exercise during pregnancy are depicted in Table 5.1 [23].

As there is a high prevalence of pregnancy-related back and pelvic pain among women, there is a great need for future studies in this field using high methodological standards [24]. Interventions to be evaluated should be based on established principles of treatment for lumbopelvic pain [24].

Table 5.1 Contraindications to aerobic exercise during pregnancy [23]

Absolute contraindications to aerobic exercise during pregnancy	Relative contraindications to aerobic exercise during pregnancy	Warning signs to terminate exercise while pregnant
• Hemodynamically significant heart disease	• Severe anemia	• Vaginal bleeding
• Restrictive lung disease	• Unevaluated maternal cardiac arrhythmia	• Dyspnea before exertion
• Incompetent cervix/ cerclage	• Chronic bronchitis	• Dizziness
• Multiple gestation at risk for premature labor	• Poorly controlled type I diabetes	• Headache
• Persistent second or third trimester bleeding	• Extreme morbid obesity	• Chest pain
• Placenta previa after 26 weeks gestation	• Extreme underweight (body mass index <12)	• Muscle weakness
• Premature labor during the current pregnancy	• History of extremely sedentary lifestyle	• Calf pain or swelling (need to rule out thrombophlebitis)
• Ruptured membranes	• Intrauterine growth restriction in current pregnancy	• Preterm labor
• Pregnancy-induced hypertension	• Poorly controlled hypertension/ preeclampsia	• Decreased fetal movement
	• Orthopedic limitations	• Amniotic fluid leakage
	• Poorly controlled seizure disorder	
	• Poorly controlled thyroid disease	
	• Heavy smoker	

From Artal, R. and M. O'Toole, Guidelines of the American College of Obstetricians and Gynecologists for exercise during pregnancy and the postpartum period. *Br J Sports Med*, 2003; 37(1): 6-12; discussion 12. Reprinted with permission from BMJ Publishing Group Ltd.

Medications

Prior to prescribing medication to a pregnant patient, it is important to determine the pregnancy risk category of the medication as labeled by the "Food and Drug Administration (FDA)." The pregnant patient should also be aware of the FDA-assigned pregnancy categories as described in Table 5.2 (see also Chap. 14).

Bracing

Maternity support garments are designed to alleviate pain in the lumbar back and/or pelvic regions [25]. They can be categorized into four main types: belts, briefs, cradles, and torso supports [25]. The maternity support belts are also known as pelvic supports, pelvic belts, sacroiliac or trochanteric support belts, binders, or braces [10, 14, 26].

Table 5.2 The FDA-assigned pregnancy categories as used in the drug formulary

Category	FDA Guidelines
A	Adequate and well-controlled studies have failed to demonstrate a risk to the fetus in the first trimester of pregnancy (and there is no evidence of risk in later trimesters)
B	Animal reproduction studies have failed to demonstrate a risk to the fetus and there are no adequate and well-controlled studies in pregnant women
C	Animal reproduction studies have shown an adverse effect on the fetus and there are no adequate and well-controlled studies in humans, but potential benefits may warrant use of the drug in pregnant women Despite potential risks
D	There is positive evidence of human fetal risk based on adverse reaction data from investigational or marketing experience or studies in humans, but potential benefits may warrant use of the drug in pregnant women despite potential risks
X	Studies in animals or humans have demonstrated fetal abnormalities and/or there is positive evidence of human fetal risk based on adverse reaction data from investigational or marketing experience, and the risks involved in use of the drug in pregnant women clearly outweigh potential benefits

Source: U.S. Food and Drug Administration

Maternity support belts are thought to be preferred by pregnant women and health care providers because they are easy to wear, adjust, and remove, and allow a wider range of fit for the increasing abdominal girth [25]. Although not based upon evidence-based medicine, manufacturers reported anecdotal evidence that the maternity support garments reduce fatigue, pressure, stress and strain of the back, prevent and/or relieve back pain, and correct or improve posture [25].

One hypothesized mechanism of pain improvement with pelvic support belts is that the use of a support belt may improve lumbopelvic stability [25]. Ligamentous laxity is theorized to negatively influence mechanical instability, thereby increasing stretch and strain on the pelvis and the low back and thus, leading to pain [27]. Increasing joint stability with a support belt is demonstrated to help with pain reduction [15, 25]. The support may either press the articular surfaces of SIJ together and/or it may place the SIJ in a position to provide improved stability [25]. The pelvic support belt is also believed to have a stabilization effect as it might stimulate the actions of different local stabilizers [28]. For example, a lumbar support belt worn in a high position may simulate the action of the transversus abdominis by the anterior compression on the anterior superior iliac spines and simulate the action of the multifidus muscle by the posterior compression on the posterior superior iliac spines [25]. In a low position, a pelvic support belt may simulate the action of pelvic floor muscles [25]. This hypothesized mechanism is consistent with studies that found that lumbopelvic stability can be achieved through specific training of the transverses abdominis, multifidus, and pelvic floor muscles [29]. Per Mens et al., a pelvic joint belt reduced rotation by 19 % and application of pelvic belt in high position decreased SI joint laxity to a significantly greater degree than the low position [28]. A supportive pelvic/SI joint belt should be worn just below level of the anterior superior iliac spines, rather than at the level of the symphysis pubis [28].

Additionally, by studying active straight leg raising and estimating the effective load transfer through the pelvis, one study by Mens et al. showed that these loads can be improved with utilization of a pelvic/SI joint belt [11].

A review by Ho critically evaluated the effectiveness of maternity support belts in the treatment of PLBP and/or PPGP [25]. When compared to no specific treatment, wearing maternity support belts may be beneficial for pain relief and improved functional status in patients with PLBP and/or PPGP [25]. There is limited evidence that usage of maternity support belt by itself prevents and/or treats PLBP and/or PPGP, so it is recommended that maternity support belt usage is in combination with individually designed and delivered exercises and ergonomics education program [15, 25].

Modalities

The use of devices such as a wedge-shaped pillow has been found to be useful in decreasing pain and insomnia during late pregnancy [30]. This type of pillow can support the gravid uterus and abdomen while lying on one's left side [30]. Women using a wedge-shaped pillow reported less backache than women using a standard cushion [30]. Other strategies that may be beneficial include a lumbar roll placed behind the lower back while resting with feet slightly elevated on a low step stool [30]. Women should be encouraged to experiment with cushions and pillows of various sizes and shapes to support different parts of their body, such as their back, abdomen, and knees for pain relief [30]. In addition, stockings that promote venous return may reduce lower extremity edema and low back pain at night [30].

Other interventions studied include local application of heat and cold. Per Cochrane review (2006), superficial application of heat/cold has been found in limited studies to be mildly effective in treating acute/subacute low back pain [31]. There is limited evidence to support the common practice of superficial heat and cold for low back pain, and there is a need for future higher quality randomized controlled trials [31]. There is moderate evidence in a small number of trials that heat wrap therapy provides a small short-term reduction in pain and disability in a population with a mix of acute and subacute low back pain, and that the addition of exercise further reduces pain and improves function [31]. Heat treatments include hot water bottles, soft heated packs filled with grain, poultices, hot towels, hot baths, saunas, steam, heat wraps, heat pads, electric heat pads, and infra-red heat lamps [31]. Cold treatments include ice, cold towels, cold gel packs, ice packs, and ice massage [31].

In a small randomized controlled trial studying pregnant women (without specific inclusion criteria), Field et al. found benefit of massage in patient with PLBP when comparing massage to progressive muscle relaxation therapy [32]). They found that the massage improved low back pain intensity, reduced anxiety, improved mood, and helped with sleep [32]. Soft tissue massage techniques have been shown to relieve tense and strained spinal musculature [32]. It has been recommended to utilize massage as part of a multifactorial individualized treatment program, as opposed to a standalone treatment [1].

Another modality utilized in pregnancy is transcutaneous electrical nerve stimulation (TENS). There are no randomized controlled trials of TENS during pregnancy; however, there have been trials of TENS during labor. There have been theoretical concerns about stimulation of certain acupuncture points which have been used to induce labor, fetal malformations, and passage of current through fetal heart while using TENS [30]. However, no negative effects have been reported from the use of TENS during any stage of pregnancy [30]. TENS can be used in pregnancy provided the current density is kept low, the abdomen, pelvis, and acupuncture points used to induce labor are avoided [30], the patient does not have a pacemaker, diminished sensation, bleeding disorder, allergy to electrodes, seizure disorder, or atrophic skin [33]. According to a Cochrane review (2008), there was limited and inconsistent evidence to support the use of TENS as an isolated intervention even in the management of chronic low back pain [34]. However, there is some evidence that TENS is better than giving no treatment in chronic low back pain [30]. Given the limited options available for pain relief during pregnancy, there appears to be no risk in trying TENS. It is cost-effective, readily available, and poses less risk than analgesic medications [30]. It should be used as a second-line treatment for PLBP/PPGP [30].

Integrative Medicine

Limited studies have shown that complementary and alternative medicine therapies may have an effect on decreasing back pain during pregnancy [35]. International research demonstrates that 25–30 % of women use complementary and alternative medicine to manage low back and pelvic pain in pregnancy [35]. The most popular therapies include acupuncture, massage, relaxation, yoga, and chiropractic therapy.

Acupuncture

The use of acupuncture for PPGP/PLBP is increasing [35]. Acupuncture is generally considered safe during pregnancy, but certain acupuncture points that stimulate the cervix and uterus should be avoided [30]. In a randomized controlled trial by Kvorning et al., acupuncture led to improved LBP and PGP at 24–37 weeks without serious adverse effects, 43 % decrease in pain vs. 9 %, respectively [36].

Most studies are controlled trials of series of small numbers of patients, and they suffer potential bias from their lack of blinding of both the patient and the investigator. The majority of the older studies have found that acupuncture provides effective analgesia to women with PPGP and/or PLBP [30]. A randomized double-blinded controlled trial with 115 patients diagnosed with PPGP showed that acupuncture had no significant effect on pain or on the degree of sick leave compared with non-penetrating sham acupuncture, although there was some improvement in performing

daily activities [30]. However, acupuncture has been widely shown to be of benefit in the management of chronic lower back pain [36]. Given its effectiveness for these conditions and the limited treatment options available during pregnancy, it can be used as a second-line treatment for pregnancy-related pain [30]. Further high-quality trials are needed to evaluate its use for PGP/ PLBP.

Management of Labor

At this time, there are limited studies on the management of labor in women with PPGP/PLBP. “The Association of Chartered Physiotherapists in Women’s Health” produced guidelines for the management of labor in women with PPGP [30]. This group recommends avoiding undue abduction of the hips during labor in affected women (especially under the pain-masking effect of spinal/epidural anesthesia) to prevent further damage to the pelvic girdle joints [30]. It further recommends promoting the most comfortable position for the mothers during labor, vaginal examination, operative vaginal delivery, and suturing [30]. This is likely to be a lateral decubitus position or on “all fours” [30]. If lithotomy position is needed, it should be maintained for as short a duration as possible and care should be taken to ensure simultaneous movement of legs into, and out of, this position [30]. Cesarean section does not confer any benefit on outcome but may be the only option in women in whom there is severe pain and limitation of movement, making comfortable birthing position practically impossible [30]. Following birth, the guidelines suggest that women start on analgesics or anti-inflammatory medications (see section “Medication”) [30]. Once the pain is controlled, and after a period of bed rest, women should gradually mobilize as tolerated, using aids such as SI joint belts and a cane/walker to help with ambulation if needed [30].

Prognosis

PPGP and PLBP are considered self-limiting conditions and symptoms generally resolve within a few weeks to 3 months after delivery. Risk factors associated with long-term PPGP or PLBP include pre-pregnancy LBP, the onset of severe pain at early gestation, non-education, high pain intensity during pregnancy, prolonged duration of labor, a high number of positive pain provocation tests, a low mobility index, and the inability to return to pre-pregnancy weight. Women with complete PPGP (pain in symphysis pubis and both SI joints) have the worst long-term prognosis. Additionally, Damen et al. found that the intensity of pain during pregnancy and early onset of pain predicts moderate to severe PPGP persisting postpartum [8]. Approximately 8–10 % of the women with PPGP continue to have pain for 1–2 years. Although PPGP/PLBP tends to recur in future pregnancies, there are no studies that have shown PPGP/PLBP to be associated with future back pain without pregnancy [30].

Studies have also found that pelvic girdle pain is more challenging to treat and can last longer than low back pain [15]. Furthermore, women with moderate to severe PGP and asymmetric laxity of the SI joint during pregnancy have a much higher risk of moderate to severe PGP postpartum than those with symmetric laxity [1].

Patient Education

Individualized education and training programs have been found to be effective in reducing absenteeism from work in women with PLBP and in some instances those with PGP [14, 15]. Back care training programs focus on educating women on the relevant anatomy, appropriate ergonomics, guidance on correct posture, pain management strategies, and relaxation techniques [30].

Pregnant women with back pain should avoid fatigue and twisting while lifting, maintain proper upright posture, use symmetrical body mechanics when lifting, and take frequent periods of rest [30]. In addition, women with PPGP should avoid jarring activities such as bouncing, unequal weight bearing on legs (e.g., while dressing), hip abduction, and activities that strain the joints to their extreme [20]. With transitional movements, such as getting out of bed and standing up from seated position, knees should be flexed and squeezed together [30]. Although there are no studies that have evaluated patient education as a single intervention, providing adequate information and reassurance is considered useful and may help reduce the risk of injury [30].

In pregnant women with nocturnal pain, decreased time spent sleeping in the supine position may alleviate symptoms [37]. Advising women to sleep on their left side may reduce pressure on the vena cava and resolve pain that is possibly vascular in origin [37]. Women who report posterior pelvic pain, specifically, should be advised to refrain from prolonged stair climbing, standing on one leg, extreme motion at the hips and back, and other positions that overload the pelvis in order to minimize symptoms. Those who present with both lumbar and posterior pelvic pain symptoms should avoid lumbar extension exercises until the posterior pelvic symptoms resolve as these symptoms may worsen with those exercises. In addition, comfortable shoes without heels are recommended to reduce symptoms [13].

Conclusion

PPGP and PLBP are common problems during pregnancy. Not all pain during pregnancy should be considered “normal” and these symptoms can improve with appropriate treatment. Exercise prior to and during pregnancy may help minimize the onset of symptoms. Careful history and physical examination is critical to help diagnose the issue and help guide suitable treatments. Physical therapy and exercise should be considered as first-line treatment in PLPP with a focus on lumbopelvic

and core stability/strengthening. There is evidence to support the use of bracing (pelvic support belt) with patients with PPGP and this should be recommended as an option to improve pain with standing and walking. Modalities such as pillows, heat/cold, TENS can also be utilized as conservative treatments to help with pain. Medications, especially those in category B, are considered safe and can be used throughout pregnancy to help improve symptoms. Complementary therapies, such as acupuncture can also be considered as long as stimulating certain pressure points for the cervix and uterus are avoided. Patient education and a review of appropriate body mechanics with activities should be discussed and evaluated with the patient in order to avoid worsening pain. If pain continues during pregnancy until the time of delivery, the lithotomy position should be avoided, and consideration of more comfortable positions and the use of vacuum assistance can be offered. In general, PPGP and PLBP are considered self-limiting conditions and symptoms generally resolve within a few weeks to 3 months after delivery.

References

1. Vleeming A, et al. European guidelines for the diagnosis and treatment of pelvic girdle pain. *Eur Spine J.* 2008;17(6):794–819.
2. Wu WH, et al. Pregnancy-related pelvic girdle pain (PPP), I: terminology, clinical presentation, and prevalence. *Eur Spine J.* 2004;13(7):575–89.
3. Paisley TS, Joy EA, Price Jr RJ. Exercise during pregnancy: a practical approach. *Curr Sports Med Rep.* 2003;2(6):325–30.
4. Wang TW, Apgar BS. Exercise during pregnancy. *Am Fam Physician.* 1998;57(8):1846–52, 1857.
5. Hartmann S, Bung P. Physical exercise during pregnancy—physiological considerations and recommendations. *J Perinat Med.* 1999;27(3):204–15.
6. Sandler SE. The management of low back pain in pregnancy. *Man Ther.* 1996;1(4):178–85.
7. Kristiansson P, Svardsudd K, von Schoultz B. Reproductive hormones and aminoterminal propeptide of type III procollagen in serum as early markers of pelvic pain during late pregnancy. *Am J Obstet Gynecol.* 1999;180(1):128–34.
8. Damen L, et al. The prognostic value of asymmetric laxity of the sacroiliac joints in pregnancy-related pelvic pain. *Spine (Phila Pa 1976).* 2002;27(24):2820–4.
9. Rost CC, et al. Pelvic pain during pregnancy: a descriptive study of signs and symptoms of 870 patients in primary care. *Spine (Phila Pa 1976).* 2004;29(22):2567–72.
10. Ostgaard HC, Zetherstrom G, Roos-Hansson E. The posterior pelvic pain provocation test in pregnant women. *Eur Spine J.* 1994;3(5):258–60.
11. Mens JM, et al. The active straight leg raising test and mobility of the pelvic joints. *Eur Spine J.* 1999;8(6):468–73.
12. Albert H, Godskenen M, Westergaard J. Evaluation of clinical tests used in classification procedures in pregnancy-related pelvic joint pain. *Eur Spine J.* 2000;9(2):161–6.
13. Sabino J, Grauer JN. Pregnancy and low back pain. *Curr Rev Musculoskelet Med.* 2008;1(2):137–41.
14. Noren L, et al. Reduction of sick leave for lumbar back and posterior pelvic pain in pregnancy. *Spine (Phila Pa 1976).* 1997;22(18):2157–60.
15. Ostgaard HC, et al. Reduction of back and posterior pelvic pain in pregnancy. *Spine (Phila Pa 1976).* 1994;19(8):894–900.
16. Stuge B, et al. The efficacy of a treatment program focusing on specific stabilizing exercises for pelvic girdle pain after pregnancy: a randomized controlled trial. *Spine (Phila Pa 1976).* 2004;29(4):351–9.

17. Garshasbi A, Faghieh Zadeh S. The effect of exercise on the intensity of low back pain in pregnant women. *Int J Gynaecol Obstet*. 2005;88(3):271–5.
18. Kihlstrand M, et al. Water-gymnastics reduced the intensity of back/low back pain in pregnant women. *Acta Obstet Gynecol Scand*. 1999;78(3):180–5.
19. Cholewicki J, McGill SM. Mechanical stability of the in vivo lumbar spine: implications for injury and chronic low back pain. *Clin Biomech (Bristol, Avon)*. 1996;11(1):1–15.
20. Pennick V, Liddle SD. Interventions for preventing and treating pelvic and back pain in pregnancy. *Cochrane Database Syst Rev*. 2013;8, CD001139.
21. Maigne JY, Vautravers P. Mechanism of action of spinal manipulative therapy. *Joint Bone Spine*. 2003;70(5):336–41.
22. Chila A. Foundations of osteopathic medicine. 3rd ed. Baltimore: Lippincott Williams & Wilkins; 2011.
23. Artal R, O'Toole M. Guidelines of the American College of Obstetricians and Gynecologists for exercise during pregnancy and the postpartum period. *Br J Sports Med*. 2003;37(1):6–12; discussion 12.
24. Stuge B, Hilde G, Vollestad N. Physical therapy for pregnancy-related low back and pelvic pain: a systematic review. *Acta Obstet Gynecol Scand*. 2003;82(11):983–90.
25. Ho SS, et al. Effectiveness of maternity support belts in reducing low back pain during pregnancy: a review. *J Clin Nurs*. 2009;18(11):1523–32.
26. Mens JM, Snijders CJ, Stam HJ. Diagonal trunk muscle exercises in peripartum pelvic pain: a randomized clinical trial. *Phys Ther*. 2000;80(12):1164–73.
27. Ritchie JR. Orthopedic considerations during pregnancy. *Clin Obstet Gynecol*. 2003;46(2):456–66.
28. Mens JM, et al. The mechanical effect of a pelvic belt in patients with pregnancy-related pelvic pain. *Clin Biomech (Bristol, Avon)*. 2006;21(2):122–7.
29. Richardson CA, et al. The relation between the transversus abdominis muscles, sacroiliac joint mechanics, and low back pain. *Spine*. 2002;27(4):399–405.
30. Vermani E, Mittal R, Weeks A. Pelvic girdle pain and low back pain in pregnancy: a review. *Pain Pract*. 2010;10(1):60–71.
31. French SD, Cameron M, Walker BF, Reggars JW, Esterman AJ. Superficial heat or cold for low back pain. *Cochrane Database Syst Rev*. 2006 (1).
32. Field T, et al. Pregnant women benefit from massage therapy. *J Psychosom Obstet Gynaecol*. 1999;20(1):31–8.
33. Jones I, Johnson M. Transcutaneous electrical nerve stimulation. Continuing education in anaesthesia. *Crit Care Pain*. 2009;9(4).
34. Khadilkar A, et al. Transcutaneous electrical nerve stimulation (TENS) versus placebo for chronic low-back pain. *Cochrane Database Syst Rev*. 2008;4, CD003008.
35. Close C, et al. A systematic review investigating the effectiveness of Complementary and Alternative Medicine (CAM) for the management of low back and/or pelvic pain (LBPP) in pregnancy. *J Adv Nurs*. 2014;70(8):1702–16.
36. Kvorning N, et al. Acupuncture relieves pelvic and low-back pain in late pregnancy. *Acta Obstet Gynecol Scand*. 2004;83(3):246–50.
37. Sneag DB, Bendo JA. Pregnancy-related low back pain. *Orthopedics*. 2007;30(10):839–45; quiz 846–7.

Chapter 6

Neural Injury During Pregnancy and Childbirth

Kelly M. Scott

Introduction

Neural injury is thankfully a rare occurrence in pregnant and parturient patients. When such a complication does occur, however, it can create significant pain and functional deficits. This chapter will address neuropathy arising from the lumbosacral plexus and its terminal branches. Radiculopathy will be covered in Chap. 7 and upper extremity neuropathies (including carpal tunnel syndrome) will be discussed in Chap. 9.

Anatomy of the Lumbosacral Plexus

The lumbosacral plexus is made up of branches derived from the L1-S5 nerve roots [1]. The lumbar portion of the plexus originates from L1 to L4, and the sacral portion is typically considered to derive from L4-S5. Table 6.1 lists the major branches of the lumbosacral plexus with their innervations. Figure 6.1 shows the lumbosacral plexus and its relation to bony and ligamentous anatomy.

K.M. Scott, MD (✉)

Department of Physical Medicine and Rehabilitation, UT Southwestern Medical Center,
5323 Harry Hines Blvd., Dallas, TX 75390-9055, USA
e-mail: kelly.scott@utsouthwestern.edu

Table 6.1 Major branches of the lumbosacral plexus

Nerve	Originating spinal roots	Muscular innervations	Sensory innervations
Iliohypogastric	L1 (\pm T12)	Lower fibers of transverse abdominal and internal oblique muscles	Lateral gluteal region and lower abdominal area above the pubis
Ilioinguinal	L1 (\pm T12)	Lower fibers of transverse abdominal and internal oblique muscles	Superior and medial aspect of femoral triangle, root of penis and anterior scrotum in men, mons pubis, and labia majora in women
Genitofemoral	L1 and L2	Cremaster muscle	Thigh adjacent to the inguinal ligament and around the femoral triangle, spermatic cord and scrotum in men, labia majora in women
Obturator	L2-L4	Adductor magnus, adductor brevis, adductor longus, obturator externus, pectineus, and gracilis muscles	Medial thigh
Femoral	L2-L4	Iliopsoas, quadriceps, pectineus, and sartorius muscles	Upper and anterior thigh, knee joint
Lateral femoral cutaneous	L2 and L3	None	Anterior and lateral thigh
Superior gluteal	L4-S1	Gluteus medius, gluteus minimus, and tensor fasciae latae muscles	None
Inferior gluteal	L5-S2	Gluteus maximus	None
Sciatic	L4-S3	Biceps femoris, semitendinosus, semimembranosus, adductor magnus muscles	Hip joint, popliteal fossa, lower leg (except the medial part)
Posterior femoral cutaneous	S1-S3	None	Inferior gluteal region, posterior thigh, perineum
Pudendal	S2-S4	Sphincters of the urinary bladder and rectum	External genitalia including penis/clitoris, perineum, anus

Mechanism of Neural Injury

Neural injury in pregnant and parturient women is most commonly due to nerve compression or traction [2]. The nerves in certain anatomic locations are more susceptible to compression injury. The lumbosacral plexus, for example, is susceptible to pressure from the descending fetal head as it courses along the lateral pelvic sidewall. Compression injury can also easily occur in superficial nerves such as the

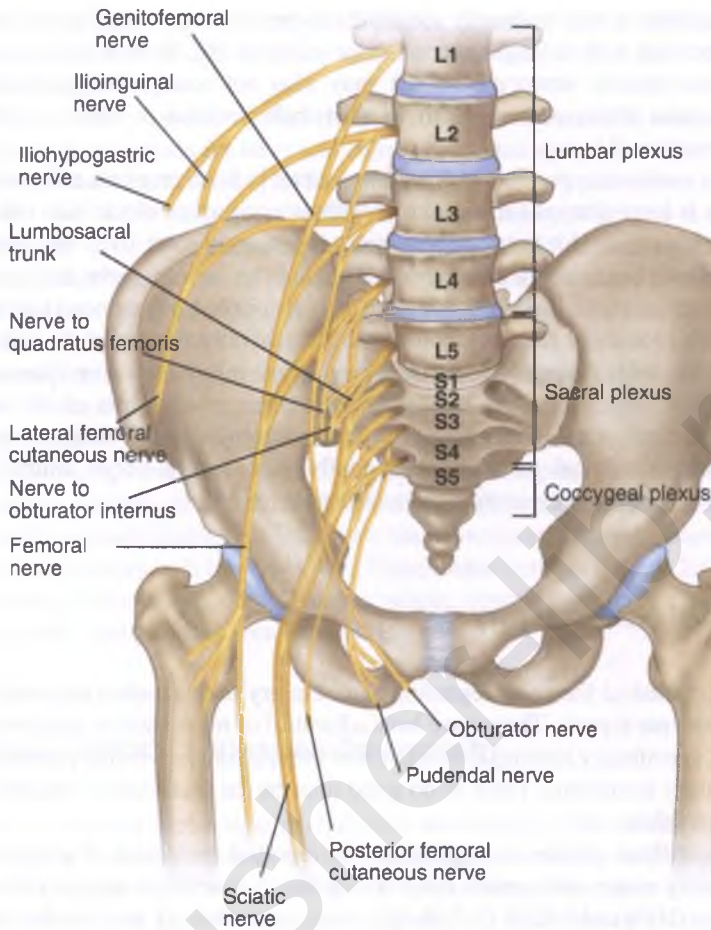


Fig. 6.1 The lumbosacral plexus in relation to the bony anatomy of the spine and pelvis

common peroneal nerve at the fibular head. Traction neuropathies result from an overstretch injury, which can occur either as a result of the body's physiologic changes during pregnancy or as a result of labor and delivery positioning. During delivery, there is added potential for nerve injury via laceration (such as during a cesarean birth), ischemia, or due to the use of instrumentation such as forceps. Factors thought to be associated with the development of pregnancy-related neuropathies include excessive weight gain, hypermobility, and increased edema [2–4]. Neural injury during childbirth is thought to be related to nulliparity, prolonged second stage of labor, cephalopelvic disproportion, the use of thigh-hyperflexion pushing position, and assisted (forceps or vacuum) vaginal deliveries [3, 5]. Intrapartum neural injury has not been shown to be associated with maternal or fetal weight or mode of delivery [6]. There is conflicting data at present as to whether neuraxial anesthesia/analgesia is associated with increased incidence of nerve injury [3, 6, 7].

Neuraxial anesthesia may indirectly contribute to the development of neural injury as it is associated with a longer second stage of labor [8]. Women with neuraxial anesthesia-induced sensory blockade may also not recognize symptoms of impending nerve injury and may fail to shift their position in order to relieve nerve compression [6].

The most common type of neural pathology seen in both pregnant and postpartum patients is focal demyelination, with or without conduction block (also referred to as neuropraxia) [2]. This type of nerve injury is generally short-lived and patients can expect a good recovery within days to weeks. More severe nerve damage can result in axonal loss with Wallerian degeneration (also called axonotmesis). In these cases, a more prolonged recovery course would generally be expected, with full recovery on the order of months to a year. Severe crush injuries or nerve transection injuries (collectively referred to as neurotmesis) often involve loss of the nerve stroma and disruption of nerve continuity. With such injuries full recovery is not possible without surgical intervention. Luckily such severe nerve injuries are exceedingly rare in the pregnant/postpartum population [6].

Incidence of Neural Injury

Most of the published literature regarding neural injury in this patient population is in the form of case reports. There have been a handful of retrospective and prospective studies, specifically looking at incidence of intrapartum nerve injury producing lower extremity symptoms. There is no good data on the incidence of pregnancy-related neuropathies.

Looking at these studies in aggregate, the reported incidence of postpartum lower extremity motor and sensory dysfunction due to neurologic injury is thought to be between 0.008 and 0.92 % [3, 7, 9–12]. Study methodology seems to be related in large part to the wide variation in reported incidences, with studies which utilized individual patient follow-up reporting a higher incidence than either retrospective or prospective survey studies [6]. In addition, reported incidence seems to be inversely related to the sample size. For most of the published literature, the localization of nerve injury is determined solely based on history and physical examination—nerve conduction studies, EMG, and other types of diagnostic testing are rarely used. Therefore, the reported location of the injury within the plexus cannot always be assumed to be accurate.

The highest quality study to date is a prospective study by Wong et al. [3] in 2003, which estimated incidence of intrapartum nerve injury to be 0.92 %. This number was far higher than previously reported. The study looked at all women who delivered a live-born infant over a 1-year period of time at the Prentice Women's Hospital in Chicago. Over 6,000 women included in the study were asked if they had any leg numbness or weakness on the day after delivery, and diagnosis was made with physical examination alone. This study found that the lateral femoral cutaneous nerve was the most commonly injured, followed by the femoral nerve,

common peroneal nerve, lumbosacral plexus, obturator nerve, and sciatic nerve. The study did not evaluate for injury to abdominopelvic nerves such as the pudendal or ilioinguinal.

A prospective, case-controlled study of 3,341 parturients who received regional analgesia or anesthesia for labor and delivery reported symptoms of nerve injury in 0.58 % of study participants [7]. Two prospective survey studies from the 1990s of 467,491 and 48,066 deliveries found rates of nerve injury to be 0.01 % and 0.04 %, respectively [10, 12]. A retrospective review of 23,827 deliveries over a 9-year period found the incidence of paresthesias and motor dysfunction to be 0.189 % [9]. A second retrospective review of 143,019 deliveries over a 16-year period reported an incidence of 0.008 % [11].

Neuropathies which have been reported during pregnancy include that of the lateral femoral cutaneous, femoral, lumbosacral plexus, sciatic, and abdominal cutaneous nerves (iliohypogastric and thoracic lateral cutaneous). Intrapartum nerve injury during spontaneous vaginal delivery has been reported to the lateral femoral cutaneous, femoral, lumbosacral plexus, sciatic, obturator, common peroneal, ilioinguinal, and pudendal nerves [3]. Injury has been reported during cesarean delivery (or other surgeries with low transverse Pfannenstiel incisions) to the lateral femoral cutaneous, femoral, lumbosacral plexus, sciatic, common peroneal, iliohypogastric, ilioinguinal, and genitofemoral nerves [13].

Lateral Femoral Cutaneous Neuropathy

Otherwise known as meralgia paresthetica, neuropathy of the lateral femoral cutaneous nerve is the most common lower extremity nerve injury in both pregnant and postpartum patients [3, 4]. Symptoms include numbness and pain of the anterolateral thigh without motor weakness. Symptoms are unilateral in a vast majority of cases, but bilateral injury has been described [14, 15].

The nerve is typically injured via compression or traction at the anterior superior iliac spine or in the region of the inguinal ligament. Anatomic variation can play a role, as the nerve may bifurcate around the inguinal ligament, which makes it more susceptible to traction or compression by the posterior fascicle of the ligament [16]. In pregnancy, increased abdominal girth and lumbar lordosis are thought to be predisposing factors for the development of meralgia paresthetica [3]. Other risk factors can include obesity, excessive pregnancy weight gain, carrying a large fetus, concurrent diabetes, wearing tight clothing, or prolonged hip flexion [17, 18]. Carrying an older child on the ipsilateral hip can also exacerbate symptoms [2]. During delivery, the nerve may be injured during prolonged thigh flexion during the pushing phase of labor [3]. It has been proposed that the elastic belts used to hold monitors in place over the lower abdomen during delivery may also contribute to compression injury of the lateral femoral cutaneous nerve [3]. It also can be infrequently damaged during cesarean section delivery via stretch injury or with an excessively wide incision or poor retractor placement [19–21].

In a case-controlled study of general practitioners, the incidence rate of meralgia paresthetica in the general population was 4.3 per 10,000 person years, and was found to be 12 times more likely to occur in pregnant women compared with non-pregnant patients [22]. Wong et al. [3] found that the lateral femoral cutaneous nerve was the most commonly injured during labor and delivery, comprising 38 % of all nerve palsies identified. The overall incidence of new meralgia paresthetica in postpartum women was 0.4 %. In this study, one third of postpartum women with meralgia paresthetica actually reported having symptoms that initially started during pregnancy. Four out of the 24 women with new onset meralgia paresthetica after delivery underwent cesarean section before the second stage of labor.

Femoral Neuropathy

The femoral nerve is the second most common lower extremity nerve injured during childbirth, and it has also been reported infrequently during pregnancy. Patients with a femoral neuropathy can have a pure sensory deficit or combined sensory and motor loss [3]. Sensory loss is typically in the anterior thigh, although with a severe axonal injury to the femoral nerve, there could also be sensory abnormalities in the distribution of the saphenous nerve (medial lower leg and foot). Knee extension weakness is the most common motor finding, and knee buckling with attempts at standing or ambulation can occur with more severe injuries. Ascending and descending stairs and performing transitional movements such as rising from a seated position can be difficult. The femoral nerve innervates the iliopsoas muscle proximal to the inguinal ligament; if hip flexion weakness is also present, a more proximal femoral neuropathy should be suspected. There can also be diminished or absent patellar reflexes on physical examination.

Risk factors for the development of femoral neuropathy in pregnancy and childbirth are likely similar to those mentioned above for meralgia paresthetica, as the nerves are both located outside of the true pelvis, and therefore are unlikely to be injured via direct compression from the fetal head [3]. The femoral nerve is most likely injured during delivery due to compression or traction at the inguinal ligament during prolonged thigh flexion, external rotation, and abduction [3]. The intrapelvic portion of the femoral nerve is thought to be poorly vascularized, making the nerve more susceptible to stretch-induced ischemia with typical modern childbirth posturing in the semi-Fowler-lithotomy position [2, 23]. There has been one case report of femoral neuropathy associated with symphyseal separation as a complication of the McRoberts' maneuver, done for the management of shoulder dystocia [24]. A split femoral nerve is a recognized anatomic variant, with bifurcation around slips of the psoas or iliacus muscles, and such anatomy could hypothetically make the nerve more prone to traction or compression injury [3, 25]. There have been multiple case reports of femoral neuropathy following lower abdominal surgery using a Pfannenstiel incision, although none of these reports involved a cesarean delivery [26–28]. In most cases, the etiologic factor seemed to be poorly

placed self-retaining retractors. Femoral nerve injury has also been described after cesarean delivery complicated by a retroperitoneal hematoma [29].

The incidence of femoral neuropathy in the early twentieth century was reported as 3.2–4.7 % of all parturients, and 25 % of cases were bilateral [5, 11]. Femoral neuropathy is certainly much less common in modern times, perhaps due to changes in labor and delivery methods, decreased duration of labor, and increased use of cesarean delivery [11]. In the study by Wong et al. [3], femoral neuropathy was found to be the cause of 30 % of postpartum neuropathic symptoms (22 out of 63 patients), giving an overall incidence for postpartum femoral neuropathy of 0.36 %. Eight patients had unilateral sensory deficits, 13 patients had unilateral sensory loss combined with motor weakness, and one patient had bilateral sensory and motor deficits. All 14 patients with motor deficit presented with hip flexion weakness as well as loss of knee extensor strength, indicating injury proximal to the inguinal ligament. Femoral neuropathy in pregnancy is not common, but there have been at least two case reports, both of which indicated bilateral involvement [30, 31]. Both of these patients required cesarean section because of leg weakness and severe pain, and one delivery was performed early at 32 weeks gestation due to severity of symptoms.

Lumbosacral Plexopathy

A lumbosacral plexopathy can have varying clinical presentations, depending on severity and which portions of the plexus are involved. The part of the plexus originating at the L4 and L5 nerve roots seems to be the most often injured as it crosses anterior to the sacral ala and sacroiliac joint. Clinically, this makes intrapartum lumbosacral plexopathy hard to distinguish from a sciatic neuropathy. Foot drop is a common clinical manifestation, with dorsiflexion, eversion, and great toe extension weakness out of proportion to plantarflexion weakness (because L4 and L5 are more involved than the sacral portions of the plexus). There can be sensory loss below the knee, particularly of the anterolateral leg and foot dorsum. It is important to remember that a postpartum foot drop should not be automatically attributed to a lumbosacral plexopathy, as a sciatic neuropathy, common peroneal neuropathy, or radiculopathy could also cause similar clinical findings. A careful physical examination can often aid in distinguishing the etiology, although further diagnostic testing may ultimately be necessary and will be discussed later in this chapter.

Lumbosacral plexus lesions typically occur due to compression of the lumbosacral trunks against the pelvic brim by the fetal head [32]. Lumbosacral plexopathy has been reported to occur both in the late third trimester of pregnancy and during the second stage of labor [4, 32, 33]. Risk factors for the development of plexopathy include short stature, primiparity, increased fetal size, cephalopelvic disproportion, malpresentation (such as occiput posterior), and an arrested second stage of labor [4, 16, 32, 34]. Specific pelvic anatomic features may also play a predisposing role, such as a straight sacrum, a flat and wide posterior pelvis, posterior displacement of the transverse diameter of the inlet, wide sacroiliac notches, and prominent ischial spines [6, 16].

There is conflicting evidence as to whether the use of forceps is an independent variable leading to the development of intrapartum lumbosacral plexopathy, particularly because forceps are often used in cases of cephalopelvic disproportion and prolonged second stage of labor which are themselves known risk factors [32].

Most of what we know about intrapartum lumbosacral plexopathy is through individual case reports and case series [32, 34–36]. It seems to be predominantly demyelinating in origin with proximal conduction block, based on one series of seven patients which presented detailed nerve conduction study (NCS) and electromyography (EMG) data [32]. Wong et al. [3] reported that 3 out of their 63 patients with symptoms of postpartum nerve injury had a lumbosacral plexopathy. Seven additional patients, however, were described as having symptoms of either a sciatic neuropathy or a radiculopathy. No electrodiagnosis was done to differentiate between these clinically similar etiologies. It is certainly possible that all ten of these patients actually had a lumbosacral plexopathy, given that lumbosacral plexopathy is thought to be much more common in this patient population than either sciatic neuropathy or lumbar radiculopathy [6].

Lumbosacral plexopathy has been rarely reported as a complication of late pregnancy [33, 35, 37, 38]. In all of these cases, the symptoms began in the middle to late third trimester. Low back pain, foot drop, and sensory loss in the lateral lower leg were the most common clinical findings. Most of these cases were presented with associated electrodiagnostic data confirming the plexus as the origin of the symptoms. It is important to note that most cases of pregnancy-related low back pain which radiates down the leg are attributable to a pelvic girdle etiology and not to lumbosacral plexopathy [2].

Sciatic Neuropathy

Because the clinical presentation of lumbosacral plexopathy so closely mirrors sciatic neuropathy, it can be very difficult to tell the two apart clinically. On physical exam, sciatic neuropathy can differ from lumbosacral plexopathy in that sensation to the posterior thigh is usually intact (as this is innervated by the posterior femoral cutaneous nerve which comes off the plexus just inferior to the sciatic nerve). The peroneal portion of the sciatic is often injured more significantly than the tibial, leading to relative preservation of plantarflexion compared to dorsiflexion strength [4].

Mechanism of injury to the sciatic nerve apart from the rest of the plexus could be due to stretch injury during prolonged second stage of labor, particularly in the lithotomy or “tailor” positions [16, 39]. There have been several case reports of sciatic neuropathy associated with piriformis muscle spasm or other pathology, and this etiology is a reasonable one to consider as a cause of sciatic neuropathy both in pregnancy and in postpartum patients [40–42]. Wong et al. [3] reported one patient with symptoms of sciatic neuropathy that started during pregnancy in addition to two patients with new symptoms after delivery. There have been a few case reports

of sciatic neuropathy presenting as foot drop after cesarean delivery [43, 44]. The proposed mechanism in each case was that the left lateral tilt position used during surgery caused compression of the left gluteal structures and ultimately the sciatic nerve.

Obturator Neuropathy

Obturator neuropathy has been rarely reported as a potential intrapartum injury. Clinically, this lesion presents as pain and numbness along the medial thigh along with adductor weakness. Obturator lesions are uncommon because the nerve is relatively protected within the deep pelvis and the medial thigh [45]. Both unilateral and bilateral neuropathies have been described in case reports [45–49]. Contributing factors to the development of intrapartum obturator neuropathy include compression by the fetal head or forceps as the nerve crosses the pelvic brim and prolonged time in the lithotomy position [3, 4]. The lithotomy position worsens the angulation of the nerve as it exits the obturator foramen [16]. Obturator neuropathies have also been described after cesarean delivery, and suggested mechanisms of nerve injury include stretching, compression by a retractor, or development of a hematoma [49]. One case has been reported of obturator neuropathy related to the development of a hematoma after an obstetric pudendal nerve block [5]. In the study by Wong et al. [3], only 3 out of 63 patients had symptoms of obturator neuropathy.

Common Peroneal Neuropathy

The common peroneal nerve is typically injured as it crosses superficially behind the fibular head. Symptoms of common peroneal neuropathy include ankle dorsiflexion and eversion weakness with numbness of the lateral lower leg and foot dorsum. The resultant gait is often described as a “slapping gait” as the foot hits the ground with an audible sound due to loss of dorsiflexion control. Plantarflexion of the ankle is preserved. The common peroneal nerve is most often injured during delivery via direct external compression, either by inappropriate leg positioning in stirrups or during hyperflexion of the knees with the mother’s hand on the lateral, upper aspect of the leg [3, 4, 50–52]. It has also been described secondary to squatting during childbirth, a practice which is common in some parts of the world [53, 54]. The compression time required to cause nerve injury is variable and can be as short as a few minutes, therefore patients need to be encouraged to change position frequently, and hand placement during the second stage of labor needs to be monitored [4, 54]. Wong et al. [3] identified just 3 patients out of 63 who had symptoms consistent with common peroneal neuropathy.

Abdominal Wall and Groin Neuropathies

There is one reported case of thoracic lateral cutaneous neuropathy in pregnancy, which clinically caused severe disabling lower abdominal wall pain [55]. Iliohypogastric neuropathy in pregnancy has also been described, with symptoms of severe lower abdominal and groin pain [56]. Associated regional numbness is also possible. It has been proposed that the rapidly expanding abdominal wall causes a traction on the nerves as they exit between the planes of abdominal wall musculature [56]. Spontaneous iliohypogastric nerve entrapment has been estimated to occur in 1 out of every 3,000 to 1 out of every 5,000 pregnancies [57]. Ilioinguinal and genitofemoral neuralgia have not been explicitly described in pregnancy, but it is reasonable to assume they could occur via a similar mechanism.

Ilioinguinal, iliohypogastric, and genitofemoral neuropathies have been described in postpartum patients as well [57, 58]. The ilioinguinal and iliohypogastric nerves are particularly susceptible to injury if a Pfannenstiel or low transverse incision is dissected too far laterally beyond the edge of the rectus abdominis muscles [13, 58]. Damage can occur from direct injury to the nerves, incorporation during the fascial closure, suture entrapment, or as a result of scar tissue formation after the surgery [13, 58]. Neuroma formation is common after such nerve damage and can be a source of chronic pain [59]. Compression of the genitofemoral nerve can be caused by poor placement of self-retaining retractors [13]. The Pfannenstiel incision is a common source of chronic pain, with 12.3–33 % of all postsurgical patients reporting symptoms [58–60]. A study by Loos et al. [59] noted that one third of almost 900 patients with a Pfannenstiel incision after cesarean section reported chronic incisional pain 2 years later. Eight percentage of the patients in that study rated their pain as moderate or severe, leading to limitations in daily functioning. Ilioinguinal and/or iliohypogastric nerve entrapment was found in 53 % of the patients reporting moderate-to-severe pain. Risk factors for the development of ilioinguinal and iliohypogastric neuropathy after cesarean section include a wide incision beyond the borders of the rectus abdominis muscle, emergency cesarean delivery, and recurrent surgeries with Pfannenstiel incisions [59]. Overall incidence of ilioinguinal and/or iliohypogastric nerve injury after a Pfannenstiel incision has been estimated at 2–4 % [58, 59, 61].

Pudendal Neuropathy

Injury to the pudendal nerves during vaginal delivery has been well-reported in the literature, and pudendal neuropathy has been implicated as a possible contributing factor to new onset postpartum urinary and fecal incontinence [62, 63]. Pudendal neuropathy can also present with symptoms of sexual dysfunction, dyspareunia, and pelvic pain [64, 65]. The pudendal nerve and its terminal branches (the inferior rectal nerve, the perineal nerve, and the dorsal nerve to the clitoris) are vulnerable to stretch or compression injury by the descending fetal head [65].

The distal terminal branches can also be injured as a result of perineal lacerations. Using 3D computer modeling, Lien et al. [66] looked at maximum nerve strains for the terminal pudendal branches, defined as $(\text{final length} - \text{original length}) / \text{original length} \times 100$. They demonstrated that the inferior rectal branch which innervates the external anal sphincter is the most affected, typically stretching well beyond the 15 % strain threshold known to cause permanent damage in appendicular peripheral nerves. They also found that the degree of perineal descent during the second stage of labor influences the strain on the pudendal nerve.

This modeling correlates well with what others have found regarding denervation injury to the sphincter and pelvic floor after childbirth. Allen et al. [67] recruited a group of 75 women who agreed to pudendal nerve terminal motor latency testing and needle EMG of the external anal sphincter at 36 weeks gestation and again at 2 months postpartum. While pregnant, pudendal neurophysiology testing was normal, but EMG evidence of pelvic floor reinnervation potentials were seen in 80 % of the postpartum women. Women who had prolonged second stage of labor and larger babies were noted to have the most EMG evidence of nerve damage. Forceps delivery and perineal tears did not seem to affect the amount of damage seen. There was a correlation between the most significant EMG findings and the immediate postpartum development of urinary and/or fecal incontinence. Women who had elective cesarean section delivery had EMG findings comparable to antenatal values, but those who underwent cesarean section after a failed trial of labor had EMG evidence of reinnervation, implying that labor itself rather than delivery, per se, may play a role in the denervation damage sustained. Multiple other studies have also demonstrated high incidence of pelvic floor denervation injury after vaginal delivery, and have shown correlates to the development of postpartum urinary and fecal incontinence [63, 64, 68–70]. It has been hypothesized that pudendal nerve injury during childbirth may be one of many etiologic factors leading to the development of pelvic floor disorders (including pelvic organ prolapse and incontinence) later in life [62, 71, 72].

Prognosis for Recovery from Neural Injury

By and large, most pregnant and postpartum patients with symptoms of lower extremity nerve injury will recover without treatment within a relatively short period of time after delivery. This is largely due to the fact that most of these injuries are predominantly demyelinating in nature, regardless of whether they are caused by compression, traction, or a combination of the two [3]. Wong et al. [3] reported that the median duration of symptoms in their study was 2 months, with a range from 1 week to greater than 14 months (in 2 out of their 63 injured patients). Ong et al. [9] reported resolution within 72 h for a majority of the 45 patients in their study, and Dar et al. [7] found that symptoms usually resolve within 6 months time. Recovery of most cesarean-related lower extremity nerve injuries has also been shown to follow a similar time course. One study of neuropathies associated with gynecologic surgery reported that symptoms had resolved in 93 % of patients within 6 months [73].

There is not a lot of data as to whether pudendal, ilioinguinal, and iliohypogastric injuries recover at similarly rapid rates, in part because it can be clinically more difficult to determine whether these nerves have fully healed. Postpartum patients may experience weeks to months of abdominopelvic pain and numbness regardless of whether a nerve injury occurred due to myofascial trauma and episiotomy and cesarean incisions. However, some of the studies reported earlier in this chapter seem to indicate the potential for these nerves to not heal as quickly or completely as injuries to nerves in the rest of the lumbosacral plexus. The ilioinguinal and iliohypogastric nerves can be injured via transection during cesarean section or become entrapped in scar tissue, which would more likely lead to higher degree of axonal involvement [58, 59]. The pudendal nerves can also become entrapped in scar, and the smaller, distal terminal branches can be transected in situations where there is significant high-grade perineal tearing. Certainly, most of the published postpartum pudendal nerve electrodiagnostic studies have indicated significant axonal (as well as demyelinating) neural injury, indicating less potential for swift recovery [67, 68].

Diagnosis of Neural Injury

Because most symptoms resolve fairly quickly after delivery, the diagnosis of neural injury is largely clinical and should be based on history and physical examination. Any patient with postpartum complaints of lower extremity weakness, numbness, or pain should be thoroughly evaluated. Important aspects of the history include delivery details such as duration of the second stage of labor, pushing position, mode of delivery, the use of neuraxial anesthesia, and degree of perineal laceration [6]. It is important to note whether any of the symptoms were present during pregnancy, as certain neuropathies like meralgia paresthetica may be present in mild form in pregnancy but then worsen considerably after delivery. Progression of symptoms is important to ascertain, because the symptoms of intrapartum injuries should be stable or improving over the initial hours to days after delivery. If symptoms are worsening, the patient may need to be evaluated emergently for infection, hemorrhage, or other obstetric comorbidities [6]. A thorough neurologic and musculoskeletal examination should be performed. It may be wise to consider obtaining XR imaging of the pelvis to rule out pubic symphysis or sacroiliac joint separation, coccyx fracture, or stress fracture in patients with significant postpartum pelvic or hip pain in weight bearing, as the symptoms from these musculoskeletal complications can sometimes mimic neural injury.

If symptoms persist for longer than 3 weeks after delivery, NCS and EMG can be conducted to attempt to localize the lesion, determine degree of axonal involvement and extent of denervation, and to look for signs of early reinnervation. NCS/EMG can be an important prognostic tool. Electrophysiologic studies cannot be conducted prior to 3 weeks postpartum because Wallerian degeneration will take time to progress to the point where abnormalities can be seen using the needle electrode at the level of the muscle [74]. If the patient has profound weakness immediately postpartum and axonal injury is suspected, it may be a good idea to obtain

NCS/EMG within a few days of delivery to establish the patient's baseline neural function (as any abnormalities seen on such testing would be indicative of problems the patient had prior to delivery). NCS/EMG is considered safe in pregnancy.

In addition to the standard NCS/EMG studies typically conducted in the lower extremities, the pudendal nerve can be evaluated electrophysiologically via a number of different methods. Pudendal nerve terminal motor latency (PNTML) can be obtained through the use of a St. Mark's electrode, with nerve stimulation at the ischial spine and recording of muscle contraction response at the external anal sphincter (see Fig. 6.2) [62]. The usefulness of PNTML has been questioned, as it has been shown to have a high rate of interobserver and intraobserver variability [75]. Needle EMG of the external anal sphincter or bulbospongiosus muscles can be performed, either with concentric needle electrodes or with single-fiber electrodiagnostic technique [67]. The bulbocavernosus reflex latency (BCRL) can also be obtained by stimulating at the clitoris [64]. Electrodiagnostic testing for pudendal neuropathy may be less well-tolerated than standard NCS/EMG of the extremities.

NCS/EMG has minimal diagnostic value for predominantly sensory neuropathies (lateral femoral cutaneous, genitofemoral, ilioinguinal, iliohypogastric), because EMG testing is only available for motor nerves, and the NCS responses for these sensory nerves are often extremely difficult to obtain. Diagnostic nerve blocks are a potentially good option for the diagnosis of painful sensory neuropathies. A positive response to infiltration of a local anesthetic around a purely sensory nerve is thought to be a reliable indicator of etiologic correlation, and techniques for performing diagnostic blocks of the lateral femoral cutaneous, ilioinguinal, iliohypogastric, and genitofemoral nerves have all been described [76–78]. It is always preferable to use ultrasound, pulsed radiofrequency, or CT guidance for better accuracy when performing these diagnostic injections. Diagnostic pudendal nerve blocks have also been described, but it is less clear that a positive response is definitively correlated with true pudendal pathology [79]. Pudendal nerve blocks should always been done under CT guidance for accuracy [75].

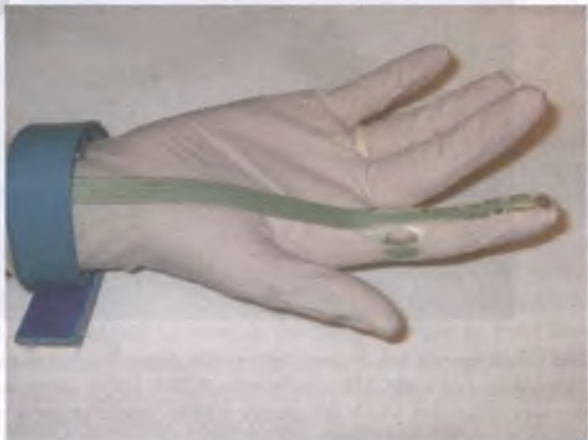

Fig. 6.2 A St. Mark's electrode, used for PNTML testing. With kind permission from Springer Science + Business Media: Vaginal Surgery for Incontinence and Prolapse, Neurophysiologic Testing, 2006, p 68, Kenton K., Fig. 6.2

Imaging of neural injury will also be discussed in Chap. 3 of this text. Neuromuscular ultrasound is one possible imaging modality that can be used. Nerve injury most typically appears as focal enlargement of the nerve, often just proximal to the site of entrapment if such an entrapment exists [80]. Sonographic evaluation of neuropathy has been described for the common peroneal nerve at the fibular head, the lateral femoral cutaneous nerve, and the sciatic nerve, among others [80–82]. Ultrasound, in general, is not particularly useful for evaluating nerve injuries about the hip and pelvis, because these nerves are typically too deep to allow for long segment exploration and good visualization [83].

Traditional MRI sequence protocols are not especially sensitive for neural injury, but with appropriate spatial resolution certain types of nerve pathology, particularly involving the larger nerves, can be readily seen [83]. MR neurography technology, however, is rapidly becoming recognized as one of the most effective diagnostic tools for nerve injury, and is thought to be far superior for nerve visualization than standard MRI [42, 84]. MR neurography of the lumbosacral plexus is especially valuable because it is able to show injury to the small nerves within the abdominal wall and deep pelvis for which there are few reliable electrophysiologic testing options available. MR neurography can also readily demonstrate a proximal demyelinating lesion within the lumbosacral plexus, which would likely have normal or minimally abnormal NCS/EMG findings. Another advantage of MR neurography is that abnormal appearance of the pathologic nerve can be visible within hours of injury. Figure 6.3 is an axial MR neurography image of an axonal left sciatic neuropathy in a patient who is 3 months postpartum.

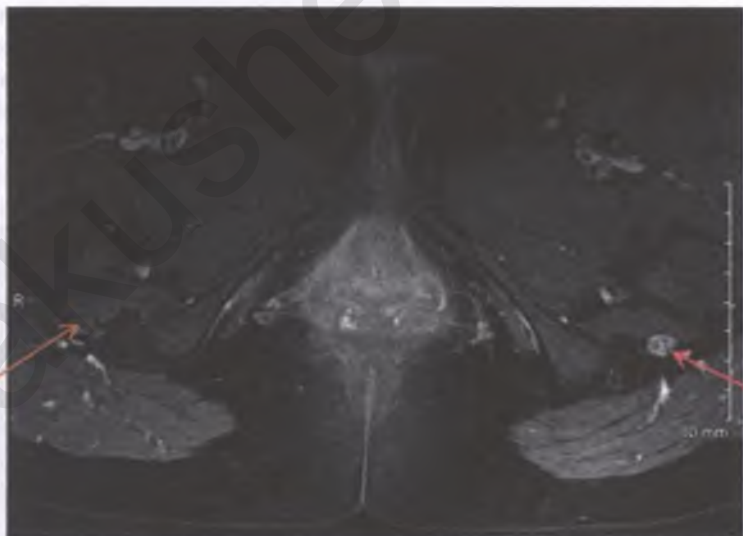


Fig. 6.3 Arrow on left. Normal right sciatic nerve. Isointense and without prominent visible fascicles. Arrow on right. Abnormally enlarged left sciatic nerve, which appears hyperintense. Note the nerve fascicles which are clearly visible. Image courtesy of Dr. Avneesh Chhabra of UT Southwestern Medical Center

Treatment of Neural Injury During Pregnancy and in the Postpartum Period

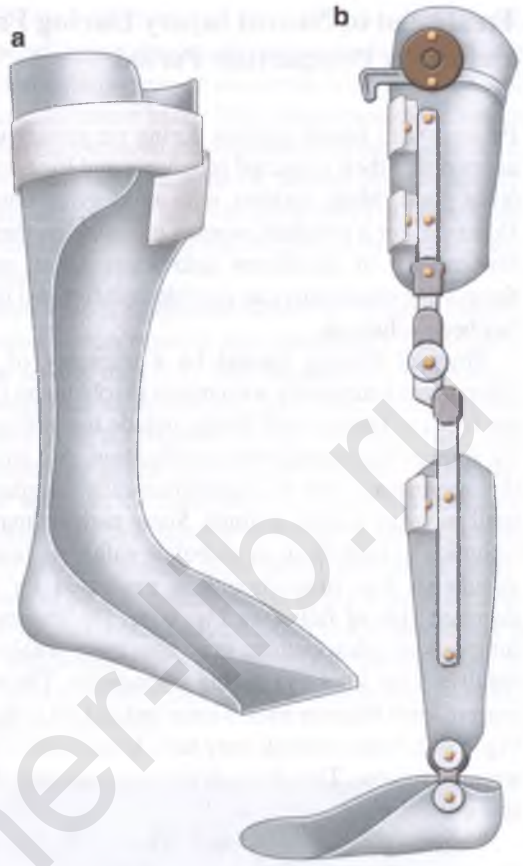
Patients with neural injuries during pregnancy and postpartum can be reasonably assured that their expected prognosis and long-term functional outcomes should be quite good. Most patients with mild symptoms will not require any treatment. However, for a pregnant woman or a new mother with an infant to care for, even a few months of significant neurologic deficit and pain can be a real challenge. Supportive treatments can provide comfort and increase safety until nerve recovery has been achieved.

Physical therapy should be a mainstay of treatment for any pregnancy or postpartum neuropathy with motor involvement [2]. As with any neuropathic injury, the focus of therapy will likely include increasing strength, endurance, and flexibility, improving balance and coordination, and ensuring that the patient understands the appropriate way to biomechanically compensate for their neurologic deficits until recovery can be attained. Some patients may benefit from assistive devices or orthotics to help them to ambulate safely as healing progresses. Any patient with significant foot drop should be evaluated for an ankle-foot orthosis (AFO) to decrease risk of falls (see Fig. 6.4a) [6]. Patients with femoral neuropathies and lumbosacral plexopathies may also have weakness of the quadriceps which can result in knee buckling during ambulation. These patients may benefit from a supportive knee brace or even a knee-ankle-foot orthosis (KAFO) in extreme cases (see Fig. 6.4b). Some patients may have to use a cane or a walker to ambulate safely until strength returns. The physical therapist can help the patient to learn to use the adaptive equipment effectively.

The specifics of medication prescription for pregnant and lactating women are discussed in Chap. 14. For pregnant women with neuropathic pain (most often due to meralgia paresthetica), there are limited options for effective pain control. Tylenol and topical lidocaine patches or creams, and capsaicin can be tried as they are all pregnancy class B. Neuropathic pain medications are typically pregnancy class C or D. These should be used with caution and only with the expressed approval of the patient's obstetrician for a patient with severe symptoms. Opioid medications should generally be avoided. Corticosteroids are pregnancy class C, but are routinely given to hasten fetal lung maturity in patients at risk for preterm labor [85]. A short course of low dose oral steroids may be helpful for severe pain symptoms, but again this needs to be discussed with the patient's obstetrician. Most pregnant women with meralgia paresthetica are comforted simply by being told that the symptoms should resolve after delivery and will not desire any treatment.

For postpartum patients, there are many neuropathic pain medications available such as gabapentin, pregabalin, duloxetine, venlafaxine, amitriptyline, and nortriptyline. Lactating mothers may want to use caution in deciding whether to treat their pain with these medications, because potential risks to the infant have not been well established for most of these medications. Compounded neuropathic pain creams are being prescribed more frequently in recent years. These creams often consist of a

Fig. 6.4 (a) An ankle-foot orthosis (AFO). (b) A knee-ankle-foot orthosis (KAFO)



mixture of various neuropathic medications (gabapentin, amitriptyline), but the key ingredient is typically ketamine at a concentration of 5–10 % [86, 87]. Other additives to the creams may include muscle relaxers such as baclofen or cyclobenzaprine and local analgesics like tetracaine. There is minimal data on the effectiveness of neuropathic pain creams—of the two randomized, placebo-controlled, double-blind trials which have been conducted, one showed a benefit and the other did not [88, 89]. Systemic absorption is thought to be low and side effects are typically minimal. A short course of oral corticosteroids (such as a tapered dosing of methylprednisolone) may be an option to consider for severe pain. It is important to remember that steroids can impair wound healing and affect the immune system and hypothalamic-pituitary-adrenal (HPA) and hypothalamic-pituitary-gonadal (HPG) axes [90].

There have been a variety of interventional treatments described for painful sensory neuropathies derived from the lumbosacral plexus. Most of what has been reported has been in the form of isolated case reports or retrospective case series; there have been very few prospective studies to date. Therapeutic injections of corticosteroid mixed with local anesthetic, delivered either as a single intervention or

as an injection series, have been reported to be helpful for lateral femoral cutaneous, ilioinguinal, iliohypogastric, genitofemoral, thoracic lateral cutaneous, and pudendal neuropathies [75–78, 91]. As with diagnostic injections, therapeutic injections should ideally be performed under ultrasound or CT guidance. Some such injections have even been reported as successful and low risk in pregnant patients, when done by an experienced practitioner with proper ultrasound guidance and with the consent of the patient's obstetrician [55, 56, 92]. Sciatic neuropathy has been reportedly treated with perisciatic injections, transsacral blocks, or piriformis muscle trigger point or botox injections [93–96]. Radiofrequency ablation and pulsed radiofrequency treatments for some of these nerves have also been described [97–99]. There is one case report of alcohol denaturation of the lateral femoral cutaneous nerve [100]. There have been a few descriptions of successful treatment of ilioinguinal or pudendal neuropathic pain via neuromodulation either at the level of the spinal cord, sacral plexus, or of the individual nerves themselves, but at this time neuromodulation has not been studied extensively enough to recommend its use in this patient population [101–104]. A therapeutic trial should always be conducted to assess for effectiveness before proceeding with the implantation of a neurostimulator.

Surgery can be an effective solution in some cases, particularly for chronic lateral femoral cutaneous, ilioinguinal, iliohypogastric, and genitofemoral neuralgia [58, 76, 105–107]. Two main surgical approaches have been described. Neurolysis involves the release of the nerve sheath and the breaking up of perineural adhesions while leaving the nerve itself intact. Neurectomy is also known as nerve resection or transection. Some have reported that neurectomy is preferable to neurolysis for the treatment of the cutaneous sensory nerves listed above, as the risk of long-term recurrence is lessened [105]. Rates of complete or moderate pain relief after neurolysis or neurectomy for the lateral femoral cutaneous, ilioinguinal, iliohypogastric, and genitofemoral nerves have been reported in the range of 66–100 % of patients [58, 105–107]. Surgical exploration and neurolysis has also been described for the sciatic, femoral, and common peroneal nerves with good treatment outcomes in terms of improved pain control as well as improved motor function and sensation [108–111].

Various approaches have been described for decompression of the pudendal nerve in cases of entrapment [75]. Outcomes for pudendal decompression surgeries have not been uniformly good. Short-term improvement of some degree has been seen in 50–70 % of patients after 3–12 months, but 50–66 % of all patients undergoing surgery have no long-term benefit [112, 113]. Appropriate patient selection and a high level of surgeon experience seem to be the keys to successful outcomes with higher satisfaction rates [65]. Hibner et al. [65] anecdotally reported that 70 % of their pudendal neuropathy patients have improvement of neuropathic symptoms after transgluteal decompression, although they also stated that many of these patients are still left with pelvic floor myofascial pain after surgery. There are many etiologies of pelvic pain which can mimic the symptoms of pudendal neuropathic pain, including inferior cluneal neuralgia, pelvic floor myofascial pain, and primary urologic, gynecologic, and anorectal pathologies. Patients with these conditions, with or without comorbid pudendal neuropathy, might not be expected to do as well with surgical decompression of the pudendal nerve.

Conclusion

Neural injury to the lumbosacral plexus and its terminal branches during pregnancy and childbirth is an infrequent complication, with the exception of pudendal neuropathy which seems to be quite common after vaginal delivery. More research is needed to clarify ways to further reduce the incidence of these injuries. Some data suggest that potential benefit might be derived by reducing the amount of time spent in the second stage of labor and specifically in the semi-Fowler lithotomy position, limiting the extent of perineal descent during the pushing phase, reducing the incidence of instrumented deliveries, and using care with surgical technique during cesarean delivery [3]. Maternal neuropathies typically improve significantly within months of delivery, and prognosis is generally very good. Diagnosis and treatment options are available for those patients with more severe neural injury.

References

1. Henry G. Anatomy of the human body. Philadelphia: Lea & Febiger; 1918. Bartleby.com, 2000. www.bartleby.com/107/.
2. Borg-Stein J, Dugan S. Musculoskeletal disorders of pregnancy, delivery, and postpartum. *Phys Med Rehabil Clin N Am.* 2007;18(3):459–76.
3. Wong C, Scavone B, Dugan S, et al. Incidence of postpartum lumbosacral spine and lower extremity nerve injuries. *Obstet Gynecol.* 2003;101(2):279–88.
4. Sax T, Rosebaum R. Neuromuscular disorders in pregnancy. *Muscle Nerve.* 2006;34(5):559–71.
5. Donaldson J. Neurology of pregnancy. Philadelphia: WB Saunders; 1989.
6. Wong C. Nerve injuries after neuraxial anaesthesia and their medicolegal implications. *Best Pract Res Clin Obstet Gynaecol.* 2010;24(3):367–81.
7. Dar A, Robinson A, Lyons G. Postpartum neurologic symptoms following regional blockade: a prospective study with case controls. *Int J Obstet Anesth.* 2002;11:85–90.
8. Sharma S, McIntire D, Wiley J. Labor analgesia and cesarean delivery: an individual patient meta-analysis of nulliparous women. *Anesthesiology.* 2004;100:142–8.
9. Ong B, Cohen M, Esmail A, et al. Paresthesias and motor dysfunction after labor and delivery. *Anesth Analg.* 1987;66:18–22.
10. Scott DB, Tunstall ME. Serious complications associated with epidural/spinal blockade in obstetrics: a two-year prospective study. *Int J Obstet Anesth.* 1995;4:133–9.
11. Vargo M, Robinson L, Nicholas J, et al. Postpartum femoral neuropathy: relic of an earlier era? *Arch Phys Med Rehabil.* 1990;71(8):591–6.
12. Holdcroft A, Gibberd FB, Hargrove RL, et al. Neurological complications associated with pregnancy. *Br J Anesth.* 1995;75:522–6.
13. Bradshaw A, Advincula A. Postoperative neuropathy in gynecologic surgery. *Obstet Gynecol Clin North Am.* 2010;37(3):451–9.
14. Tsen L. Neurologic complications of labor analgesia and anesthesia. *Int Anesthesiol Clin.* 2002;40:67–88.
15. Paul F, Zipp F. Bilateral meralgia paresthetica after cesarian section with epidural analgesia. *J Peripher Nerv Syst.* 2006;11(1):98–9.
16. Aminoff M. Neurological disorders and pregnancy. *Am J Obstet Gynecol.* 1978;12:1–5.
17. Kein A. Peripheral nerve disease in pregnancy. *Clin Obstet Gynecol.* 2013;56(2):382–8.
18. Van Diver T, Camann W. Meralgia paresthetica in the parturient. *Int J Obstet Anesth.* 1995;4(2):109–12.

19. Redick L. Maternal perinatal nerve palsies. *Postgrad Obstet Gynecol.* 1992;12:1–5.
20. Peters G, Larner AJ. Meralgia paresthetica following gynecologic and obstetric surgery. *Int J Gynecol Obstet.* 2006;95(1):42–3.
21. Yanaru T, Katori K, Higa K, et al. Unilateral temporary meralgia paresthetica after caesarian section: report of a case. *Masui.* 2012;61(10):1099–101.
22. van Slobbe AM, Bohnen AM, Bernsen RM, et al. Incidence rates and determinants in meralgia paresthetica in general practice. *J Neurol.* 2004;251(3):294–7.
23. al Hakim M, Katiirji B. Femoral mononeuropathy induced by the lithotomy position: a report of 5 cases with a review of literature. *Muscle Nerve.* 1993;16(9):891–5.
24. Gherman R, Ouzounian J, Incerpi M, et al. Symphyseal separation and transient femoral neuropathy associated with the McRoberts' maneuver. *Am J Obstet Gynecol.* 1998;178(3):609–10.
25. Spratt J, Logan B, Abrahams P. Variant slips of psoas and iliacus muscles, with splitting of the femoral nerve. *Clin Anat.* 1996;9:401–4.
26. Brasch R, Bufo A, Kreienberg P, et al. Femoral neuropathy secondary to the use of self-retaining retractor. *Dis Colon Rectum.* 1995;38:1115–8.
27. Al-Ajmi A, Rousseff RT, Khuraibet AJ. Iatrogenic femoral neuropathy: two cases and literature update. *J Clin Neuromuscul Dis.* 2010;12(2):66–75.
28. Huang W, Lin P, Yeh C, et al. Iatrogenic femoral neuropathy following pelvic surgery: a rare and often overlooked complication—four case reports and literature review. *Chang Gung Med J.* 2007;30(4):374–9.
29. Chao A, Chao A, Wang CJ, Chao AS. Femoral neuropathy: a rare complication of retroperitoneal hematoma caused by cesarean section. *Arch Gynecol Obstet.* 2013;287(3):609–11.
30. Kofler M, Kronenberg MF. Bilateral femoral neuropathy during pregnancy. *Muscle Nerve.* 1985;21(8):1106.
31. Pildner von Steinburg S, Kuhler A, Herrmann N, et al. Pregnancy-associated femoral nerve affection. *Zentralbl Gynakol.* 2004;126(5):328–30.
32. Katiirji B, Wilbourn A, Scarberry S, et al. Intrapartum maternal lumbosacral plexopathy. *Muscle Nerve.* 2002;26(3):340–7.
33. Delarue MW, Vles JS, Hasaart TH. Lumbosacral plexopathy in the third trimester of pregnancy: a report of three cases. *Eur J Obstet Gynecol Reprod Biol.* 1994;53(1):67–8.
34. Bademosi O, Osuntokun B, Van de Werd H, et al. Obstetric neuropriaxia in the Nigerian African. *Int J Gynecol Obstet.* 1980;17(6):611–4.
35. Brusse E, Visser LH. Footdrop during pregnancy or labor due to obstetric lumbosacral plexopathy. *Ned Tijdschr Geneesk.* 2002;146(1):31–4.
36. Rabeth J, Saurenmann E, Waespe W. Postpartum footdrop due to compression of the lumbosacral trunk. *Gynakol Geburtshilffliche Rundsch.* 2000;40(2):68–70.
37. Turgut F, Turgut M, Menteş E. Lumbosacral plexus compression by fetus: an unusual cause of radiculopathy during teenage pregnancy. *Eur J Obstet Gynecol Reprod Biol.* 1997;73(2):203–4.
38. Yoshimoto M, Kawaguchi S, Takebayashi T, et al. Diagnostic features of sciatica without lumbar nerve root compression. *J Spinal Disord Tech.* 2009;22(5):328–33.
39. Ley L, Ikhouane M, Staiti G, et al. Neurological complication after the “tailor posture” during labour with epidural anesthesia. *Ann Fr Anesth Reanim.* 2007;26(7–8):666–9.
40. Vallejo M, Mariano D, Kaul B, et al. Piriformis syndrome in a patient after cesarean section under spinal anesthesia. *Reg Anesth Pain Med.* 2004;29(4):364–7.
41. Kinahan A, Douglas M. Piriformis pyomyositis mimicking epidural abscess in a parturient. *Can J Anaesth.* 1995;42(3):240–5.
42. Petchprapa C, Rosenberg Z, Sconfienza L, et al. MR imaging of entrapment neuropathies of the lower extremity. Part 1. The pelvis and hip. *RadioGraphics.* 2010;30:983–1000.
43. Roy S, Levine A, Herbison G, et al. Intraoperative positioning during cesarean as a cause of sciatic neuropathy. *Obstet Gynecol.* 2002;99(4):652–3.
44. Postaci A, Karabeyoglu I, Erdogan G, et al. A case of sciatic neuropathy after cesarean section under spinal anaesthesia. *Int J Obstet Anesth.* 2006;15(4):317–9.

45. Nogajski J, Shnier R, Zagamim A. Postpartum obturator neuropathy. *Neurology*. 2004;63(12): 2450–1.
46. Haas D, Meadows R, Cottrell R, et al. Postpartum obturator neurapraxia. A case report. *J Reprod Med*. 2003;48(6):469–70.
47. Lindner A, Schulte-Mattler W, Zierz S. Postpartum obturator nerve syndrome: case report and review of the nerve compression syndrome during pregnancy and delivery. *Zentralbl Gynakol*. 1997;119(3):93–9.
48. Hakoiwa S, Hoshi T, Tanaka M, et al. Case of bilateral obturator neuropathy after caesarean section. *Masui*. 2011;60(6):721–3.
49. Hong B, Ko Y, Kim H, et al. Intrapartum obturator neuropathy diagnosed after cesarean delivery. *Arch Gynecol Obstet*. 2010;282(3):349–50.
50. Colachis Iii SC, Pease WS, Johnson EW. A preventable cause of foot drop during childbirth. *Am J Obstet Gynecol*. 1994;171(1):270–2.
51. Sahai-Srivastava S, Amezcua L. Compressive neuropathies complicating normal childbirth: case report and literature review. *Birth*. 2007;34(2):173–5.
52. Radawski M, Strakowski J, Johnson E. Acute common peroneal neuropathy due to hand positioning in normal labor and delivery. *Obstet Gynecol*. 2011;118(2):421–3.
53. Reif M. Bilateral common peroneal nerve palsy secondary to prolonged squatting in natural childbirth. *Birth*. 1988;15:100–2.
54. Babayev M, Bodack M, Creatura C. Common peroneal neuropathy secondary to squatting during childbirth. *Obstet Gynecol*. 1998;91(5):830–2.
55. Peleg R, Gohar J, Koretz M, et al. Abdominal wall pain in pregnant women caused by thoracic lateral cutaneous nerve entrapment. *Eur J Obstet Gynecol Reprod Biol*. 1997;74(2): 169–71.
56. Carter B, Racz G. Iliohypogastric nerve entrapment in pregnancy: diagnosis and treatment. *Anesth Analg*. 1994;79(6):1193–4.
57. Racz G, Hagstrom D. Iliohypogastric and ilioinguinal nerve entrapment: diagnosis and treatment. *Pain Dig*. 1992;2:43–8.
58. Loos M, Scheltinga M, Roumen R. Surgical management of inguinal neuralgia after a low transverse Pfannenstiel incision. *Ann Surg*. 2008;248(5):880–5.
59. Loos M, Scheltinga M, Mulders L, et al. The Pfannenstiel incision as a source of chronic pain. *Obstet Gynecol*. 2008;111(4):839–46.
60. Nikolajsen L, Sorensen H, Jensen TS, et al. Chronic pain following Caesarean section. *Acta Anaesthesiol Scand*. 2004;48:111–6.
61. Luijendijk R, Jeekel J, Storm R, et al. The low transverse Pfannenstiel incision and the prevalence of incisional hernia and nerve entrapment. *Ann Surg*. 1997;225:365–9.
62. Connolly A, Thorp J. Childbirth-related perineal trauma: clinical significance and prevention. *Clin Obstet Gynecol*. 1999;42(4):820–35.
63. Fynes M, Donnelly V, Behan M, et al. Effect of second vaginal delivery on anorectal physiology and faecal continence: a prospective study. *Lancet*. 1999;354(9183):983–6.
64. Ismael SS, Amarengo G, Bayle B, et al. Postpartum lumbosacral plexopathy limited to autonomic and perineal manifestations: clinical and electrophysiological study of 19 patients. *J Neurol Neurosurg Psychiatry*. 2000;68(6):771–3.
65. Hibner M, Castellanos M, Desai N, Balducci J. *Glob. Libr. Women's Med.* (ISSN: 1756-2228) 2011; DOI:10.3843/GLOWM.10468
66. Lien K-C, Morgan DM, Delancey JOL, et al. Pudendal nerve stretch during vaginal birth: a 3D computer simulation. *Am J Obstet Gynecol*. 2005;192(5):1669–76.
67. Allen RE, Hosker GL, Smith AR, et al. Pelvic floor damage and childbirth: a neurophysiological study. *Br J Obstet Gynaecol*. 1990;97:770–9.
68. Snooks S, Setchell M, Swash M, et al. Injury to innervation of pelvic floor sphincter musculature in childbirth. *Lancet*. 1984;2(8402):546–50.
69. Tetzschner T, Sorensen M, Lose G, et al. Pudendal nerve function during pregnancy and after delivery. *Int Urogynecol J*. 1997;8(2):66–8.

70. Thorp J, Jones L, Bowes W, et al. Electromyography with acrylic plug surface electrodes after delivery. *Am J Perinatol.* 1995;12:125–8.
71. Pla-Martí V, Moro-Valdezate D, Alos-Company R, et al. The effect of surgery on quality of life in patients with faecal incontinence of obstetric origin. *Colorectal Dis.* 2007;9(1):90–5.
72. Oberwalder M, Dinnewitzer A, Baig M, et al. The association between late-onset fecal incontinence and obstetric anal sphincter defects. *Arch Surg.* 2004;139(4):429–32.
73. Warner M, Warner D, Harper M, et al. Lower extremity neuropathies associated with lithotomy positions. *Anesthesiology.* 2000;93:938–42.
74. Dumitru D, Amato A, Zwarts M. *Electrodiagnostic medicine.* Philadelphia: Hanley & Belfus; 2002.
75. Hibner M, Desai N, Robertson L, et al. Pudendal neuralgia. *J Minim Invasive Gynecol.* 2010;17:148–53.
76. Starling J, Harms B. Diagnosis and treatment of genitofemoral and ilioinguinal neuralgia. *World J Surg.* 1989;13(5):586–91.
77. Suresh S, Patel A, Porfyris S, et al. Ultrasound-guided serial ilioinguinal nerve blocks for management of chronic groin pain secondary to ilioinguinal neuralgia in adolescents. *Paediatr Anaesth.* 2008;18(8):775–8.
78. Tagliafico A, Serafini G, Lacelli F, et al. Ultrasound-guided treatment of meralgia paresthetica (lateral femoral cutaneous neuropathy): technical description and results of treatment in 20 consecutive patients. *J Ultrasound Med.* 2011;30(10):1341–6.
79. Labat J, Riant T, Robert R, et al. Diagnostic criteria for pudendal neuralgia by pudendal nerve entrapment (Nantes criteria). *NeurourolUrodyn.* 2008;27(4):306–10.
80. Cartwright M, Walker F. Neuromuscular ultrasound in common entrapment neuropathies. *Muscle Nerve.* 2013;48(5):696–704.
81. Aravindakannan T, Wilder-Smith E. High-resolution ultrasonography in the assessment of meralgia paresthetica. *Muscle Nerve.* 2012;45(3):434–5.
82. Kara M, Ozcakar L, Tiftik T, et al. Sonographic evaluation of sciatic nerves in patients with unilateral sciatica. *Arch Phys Med Rehabil.* 2012;93(9):1598–602.
83. Martinoli C, Miguei-Perez M, Padua L, et al. Imaging of neuropathies about the hip. *Eur J Radiol.* 2013;82(1):17–26.
84. Soldatos T, Andreisek G, Thawait G, et al. High-resolution 3-T MR neurography of the lumbosacral plexus. *RadioGraphics.* 2013;33:967–87.
85. Surbek D, Drack G, Irion O, et al. Antenatal corticosteroids for fetal lung maturation in threatened preterm delivery: indications and administration. *Arch Gynecol Obstet.* 2012;286(2):277–81.
86. Quan D, Wellish M, Gilden D. Topical ketamine treatment of postherpetic neuralgia. *Neurology.* 2003;60(8):1391–2.
87. Poterucha T, Murphy S, Rho R, et al. Topical amitriptyline-ketamine for treatment of rectal, genital, and perineal pain and discomfort. *Pain Physician.* 2012;15(6):485–8.
88. Mahoney J, Vardaxis V, Moore J, et al. Topical ketamine cream in the treatment of painful diabetic neuropathy: a randomized, placebo-controlled, double-blind initial study. *J Am Podiatr Med Assoc.* 2012;102(3):178–83.
89. Finch P, Knudsen L, Drummond P. Reduction of allodynia in patients with complex regional pain syndrome: a double-blind placebo-controlled trial of topical ketamine. *Pain.* 2009;146(1–2):18–25.
90. Melillo N, Corrado A, Quarta L, et al. Corticosteroids, a review. *Panminerva Med.* 2007;49(1):29–33.
91. Vancaille T, Eggermont J, Armstrong G, et al. Response to pudendal nerve block in women with pudendal neuralgia. *Pain Med.* 2012;13(4):596–603.
92. Harney D, Patijn J. Meralgia paresthetica: diagnosis and management strategies. *Pain Med.* 2007;8(8):667–77.
93. Reus M, de Dios BJ, Vázquez V, et al. Piriformis syndrome: a simple technique for US-guided infiltration of the perisciatic nerve—preliminary results. *Eur Radiol.* 2008;18(3):616–20.

94. Childers M, Wilson D, Gnatz S, et al. Botulinum toxin type a use in piriformis muscle syndrome: a pilot study. *Am J Phys Med Rehabil.* 2002;81(10):751–9.
95. Eker H, Cok O, Aribogan A. A treatment option for post-injection sciatic neuropathy: trans-sacral block with methylprednisolone. *Pain Physician.* 2010;13(5):451–6.
96. Naja Z, Al-Tannir M, El-Rajab M, et al. The effectiveness of clonidine-bupivacaine repeated nerve stimulator-guided injection in piriformis syndrome. *Clin J Pain.* 2009;25(3):199–205.
97. Rhame E, Levey K, Gharibo C. Successful treatment of refractory pudendal neuralgia with pulsed radiofrequency. *Pain Physician.* 2009;12(3):633–8.
98. Fowler I, Tucker A, Mendez R. Treatment of meralgia paresthetica with ultrasound-guided pulsed radiofrequency ablation of the lateral femoral cutaneous nerve. *Pain Pract.* 2012;12(5):394–8.
99. Rozen D, Ahn J. Pulsed radiofrequency for the treatment of ilioinguinal neuralgia after inguinal herniorrhaphy. *Mt Sinai J Med.* 2006;73(4):716–8.
100. Chen CK, Phui VE, Saman MA. Alcohol neurolysis of lateral femoral cutaneous nerve for recurrent meralgia paresthetica. *Agri.* 2012;24(1):42–4.
101. Carmel M, Lebel M, Tu L. Pudendal nerve neuromodulation with neurophysiology guidance: a potential treatment option for refractory chronic pelvi-perineal pain. *Int Urogynecol J.* 2010;21:613–6.
102. Rigoard P, Delmotte A, Moles A, et al. Successful treatment of pudendal neuralgia with tri-column spinal cord stimulation: case report. *Neurosurgery.* 2012;71(3):E757–63.
103. Heinze K, Nehiba M, van Ophoven A. Neuralgia of the pudendal nerve following violent trauma: analgesia by pudendal neuromodulation. *Urologe.* 2012;51(8):1106–8.
104. Rauchwenger J, Giordano J, Rozen D, et al. On the therapeutic viability of peripheral nerve stimulation for ilioinguinal neuralgia: putative mechanisms and possible utility. *Pain Pract.* 2008;8(2):138–43.
105. Emamhadi M. Surgery for meralgia paresthetica: neurolysis versus nerve resection. *Turk Neurosurg.* 2012;22(6):758–62.
106. Zacest A, Magill S, Anderson V, et al. Long-term outcome following ilioinguinal neurectomy for chronic pain. *J Neurosurg.* 2010;112(4):784–9.
107. Benezis I, Boutaud B, Leclerc J, et al. Lateral femoral cutaneous neuropathy and its surgical treatment: a report of 167 cases. *Muscle Nerve.* 2007;36(5):659–63.
108. Kyriacou S, Pastides P, Singh V, et al. Exploration and neurolysis for the treatment of neuro-pathic pain in patients with a sciatic nerve palsy after total hip replacement. *Bone Joint J.* 2013;95-B(1):20–2.
109. Martin H, Shears S, Johnson J, et al. The endoscopic treatment of sciatic nerve entrapment/ deep gluteal syndrome. *Arthroscopy.* 2011;27(2):172–81.
110. Ducic I, Dellon L, Larson E. Treatment concepts for idiopathic and iatrogenic femoral nerve mononeuropathy. *Ann Plast Surg.* 2005;55(4):397–401.
111. Ramanan M, Chandran K. Common peroneal nerve decompression. *ANZ J Surg.* 2011;81(10):707–12.
112. Robert R, Labat J, Bensignor M, et al. Decompression and transposition of the pudendal nerve in pudendal neuralgia: a randomized controlled trial and long-term evaluation. *Eur Urol.* 2005;47(3):403–8.
113. Mauillon J, Thoumas D, Leroi A, et al. Results of pudendal nerve neurolysis-transposition in twelve patients suffering from pudendal neuralgia. *Dis Colon Rectum.* 1999;42(2):186–92.

Chapter 7

Interventional Procedures for Musculoskeletal Pain in Pregnancy and Postpartum: Efficacy and Safety

Christopher T. Plastaras and Malathy Appasamy

Background

Definitions

Low back pain (LBP) is usually defined as pain between the 12th rib and gluteal fold. Pelvic girdle pain (PGP) is pain between the posterior iliac crest and gluteal fold. PGP mostly encompasses the sacroiliac joints (SIJs) [1]. Pelvic girdle syndrome (PGS) includes pain in all three pelvic joints (both SIJs and symphysis pubis). Differentiation of PGP from lumbar causes is possible but can be difficult due to overlap of anatomical pain distribution pattern particularly with radiation to posterior thigh with or without coexistent symphysis pubis pain.

Epidemiology

Global prevalence of LBP and PGP has a wide range between 24 and 90 %, in part, because of the lack of universally recognized classification system [1, 2]. About two-thirds of patients suffer with LBP and PGP in pregnancy [3, 4]. Relapse rates are higher in subsequent pregnancies [4, 5] and postpartum prevalence is 24 % (0.6–67 %) [6], however, more than 50 % of these patients receive little or no interventions from the healthcare provider [4, 7]. In a prospective study of pregnant

C.T. Plastaras, MD (✉) • M. Appasamy, MD
Department of Physical Medicine and Rehabilitation, University of Pennsylvania,
1800 Lombard Street, Philadelphia, PA 19146, USA
e-mail: Christopher.Plastaras@uphs.upenn.edu; apmala01@gmail.com

patients, the prevalence of PGP was reported to be 33 %, the prevalence of lumbar pain to be 11 %, and 18 % had combined PGP and lumbar pain [8]. The majority of patients (62.5 %) had disappearance of pain 1 month after delivery. Persistent pelvic pain 2 years postpartum was reported in 8.6 % of patients who were diagnosed with PGP syndrome [9].

Etiology

Muscle dysfunction, particularly lower trunk muscle endurance, decreased hip extension and slow gait has been shown to be associated with LBP related to lumbar causes and pelvic girdle in pregnancy and postpartum [8]. PGP usually arises in relation to pregnancy, trauma, reactive arthritis, and osteoarthritis and associated with reduced endurance for standing, walking, and sitting. The exact mechanism that leads to the development of PGP is uncertain. Several hypotheses have been proposed including hormonal, biomechanical, traumatic, metabolic, or degenerative changes. The accumulated evidence advocates in favor of a multifactorial cause for this condition in pregnancy and postpartum [10]. In pregnancy there is increased secretion of hormones such as relaxin to maintain pregnancy and initiate delivery. This results in increased ligament laxity in the pelvic girdle and other joints in the body. However, the association between these hormones and pelvic pain is not established [11, 12]. If increased laxity is not accompanied by altered neuromotor control, it can result in joint instability and pain [13].

O'Sullivan et al. [13, 14] emphasized the need for multifactorial biopsychosocial framework for classification and treatment of chronic LBP and PGP. The authors proposed that there were three subgroups of patients that present with LBP and PGP. Group 1 included disorders where there is high level of pain and disability. This group included patients who may warrant early surgical referral such as new onset weakness, neurological deficits, bowel, or bladder changes (which may indicate radiculopathy, myelopathy, or cauda equine syndrome), night pain, fevers, chills (indicative of infectious process), weight loss, loss of appetite, and night pain (suggestive of malignancy). These patients may also have a pathological cause such as disc protrusions, central and foraminal stenosis with radicular pain and neurological deficits, internal disc protrusion, and associated inflammatory pain or Grade 2–4 spondylolisthesis. In these patients, secondary movement or control impairments could be an adaptive response and can present with antalgic movement patterns and altered motor control driven directly by the pain disorder. This group would benefit from direct medical and specifically targeted interventions. Group 2 includes patients where the pain disorder is the result of psychosocial and nonorganic causes. These patients present with dominant psychosocial features, including anxiety, depression, negative beliefs, and poor coping strategies [15, 16]. Management of this group should involve cognitive behavioral therapy and psychiatric management [16]. The third subgroup has maladaptive movement and control impairments associated

with faulty coping strategies and commonly associated with psychosocial stressors. This group should be addressed by a combined approach aiming towards improving their physical ailments as well as addressing the cognitive aspects. It is recommended that a diagnosis of PGP is made after exclusion of lumbar causes.

Risk Factors

Previous history of LBP or PGP, strenuous work, and trauma to the pelvis are shown to be risk factors for PGP [1, 6]. Factors that have not been shown to be associated with PGP include use of contraceptive pills, time interval since last pregnancy, height, weight, and age and smoking habits [1].

Terminology

There is a lack of consensus on therapeutic interventions primarily due to the multiplicity and overlapping of terminology and related definitions [10]. Prior to discussing interventions, this section will address the varying terminologies used and their definitions. Table 7.1 lists the various terminologies used in literature to describe causes for peripartum musculoskeletal pain.

Table 7.1 Terminology used to describe musculoskeletal pain in the peripartum period

Name	Description
Pelvic girdle pain	Mainly encompasses sacroiliac joints; includes posterior iliac crest to gluteal fold and anteriorly symphysis pubis
PGP (pregnancy-related pelvic girdle pain)	Mainly encompasses sacroiliac joints; includes posterior iliac crest to gluteal fold and anteriorly symphysis pubis
PLBP (pregnancy-related low back pain)	Described as pain between 12th rib and gluteal fold; sometimes from naval to gluteal fold
Symphysis pubis dysfunction	Suprapubic, sacroiliac or thigh pain due to diastasis of pubic symphysis (abnormally wide gap >1 cm between the two pubic bones)
Lumbopelvic pain	Includes PGP and PLBP
Backache during pregnancy	Lumbar and pelvic girdle pain
Peripartum pelvic pain	Lumbar and pelvic girdle pain
Relaxation of pelvic joints in pregnancy	Mostly involves sacroiliac joints and pubic symphysis
Pelvic instability	Sacroiliac joint dysfunction
Symphysiolysis	Pubic symphysis diastasis
Pelvic girdle relaxation	Sacroiliac joint laxity

Interventions

Evidence-Based Consensus for Management of LBP and PGP

European guidelines on management of PGP recommend conservative approach focused on reassurance, patient education, and individualized exercise program for pregnant patients and multifactorial approach for nonpregnant patients [1]. It was acknowledged that these guidelines were based on very few systematic reviews and randomized controlled trials. There is a lack of consensus regarding incidence, clinical manifestations, treatment algorithms, and final outcome due to the lack of professional certainty in the terminology. A primary cause for the initial lack of consensus was the lack of professional certainty in the terminology utilized and this was partially addressed in the European guidelines.

Interventions that have been used to date to help manage pain include exercises, frequent rest, hot and cold compresses, abdominal support belts, massage, acupuncture, chiropractic adjustments, aromatherapy, relaxation, herbs, yoga, Reiki, and acetaminophen [2]. A Cochrane systematic review examined 4,093 pregnant patients in 26 randomized trials on the efficacy of interventions in pregnancy-related pelvic and LBP [17]. Based on the review, there was moderate quality evidence to suggest acupuncture significantly reduced pelvic pain compared to exercise therapies or usual care [18–20]. There was very low quality evidence that exercises, use of pelvic belts, osteopathic manipulation therapy (OMT), or a specially designed pillow significantly reduced LBP. There was moderate quality evidence that an 8–20-week individualized exercise program that focused on stabilization exercises reduced the incidence of women reporting lumbopelvic pain. The review concluded that in order to have more confidence in the results, future research would benefit from a classification system in which consensus is reached regarding how to categorize women according to presenting symptoms.

Evidence-Based Consensus on Injection Therapies for Management of LBP and PGP

The Cochrane review on effective interventions for LBP and pelvic pain in pregnancy failed to identify evidence-based recommendations for injection options [17]. This is in part because of lack of comprehensive knowledge on the available options and concern for safety in pregnancy.

In the nonpregnant population, fluoroscopically guided SIJ anesthetic blocks with 1 % lidocaine compared to normal saline have been studied. When performed by specifically trained physicians based on highly specific provocative SIJ tests, these injections are 100 % specific and 87 % sensitive [21] for the diagnosis of SIJ pain in nonpregnant patients with PGP. Intra-articular therapeutic SIJ injections for patients suffering from nonspecific spondyloarthropathies and ankylosing spondylitis have been shown to be helpful in 60–88 % of patients [22, 23]. Fluoroscopy-guided intra-articular SIJ injections can be efficacious and are safe

with minimal adverse effects with the most common immediate adverse event being vasovagal reaction and late adverse event being injection site soreness [24, 25].

Fluoroscopy-guided injection of corticosteroids into the pubic symphysis may be effective for immediate and short-term pain relief but not recommended for long-term pain relief according to a retrospective study in nonpregnant patients with PGP secondary to pubic symphsitis [26].

Ultrasound-guided ganglion impar block can accurately place the needle in the sacrococcygeal junction followed by establishment with lateral fluoroscopy for safe depth and ultrasound has been recommended as an adjunct to fluoroscopy for this injection [27]. However, ultrasound-guided ganglion impar injection has been shown to be safely and effectively performed in conjunction with loss of resistance technique [28].

There is no evidence to suggest radiofrequency denervation or prolotherapy or operative management in the form of surgical fusion is effective in the management of lumbopelvic pain [1]. There have been isolated case reports of the potential role of epidural analgesia in the management of LBP and PGP and it has been suggested that epidural analgesia be reserved for patients with severe symptoms, while awaiting fetal maturation thereby avoiding premature induction of labor or C-section [29, 30].

Clinical Approach to Interventional Procedures and Injection Techniques in Management of Musculoskeletal Pain in Pregnancy and Postpartum

In our opinion, injection therapies for management of musculoskeletal pain in the peripartum period are insufficiently explored due to lack of comprehensive knowledge and fear of inducing risks to the fetus by the treating physicians. In this chapter, we will discuss the possible injection options that can be safely performed by an experienced physician for management of LBP and PGP in pregnancy and postpartum period. In order to tailor the treatment options to specific diagnosis, it is necessary to approach the management based on diagnosis in the two different groups of patients: intrapartum and postpartum group. We recommend a similar clinical approach for clinical diagnosis based on thorough history and physical exam in both groups. However, the treatment approach, the risks and benefits, and possible options for various interventional procedures will be different for the two groups due to the limitations for image guidance in the pregnant population. Completion of a careful history and physical examination findings will enable clinicians to arrive at a differential diagnosis in both groups as enumerated in Fig. 7.1.

History

A detailed history with particular attention to red flags as listed in Fig. 7.1 is the starting point. This should be followed by a careful pain history to determine the acuity, location, referral pattern, and aggravating and relieving factors are obtained to arrive at a differential diagnosis.

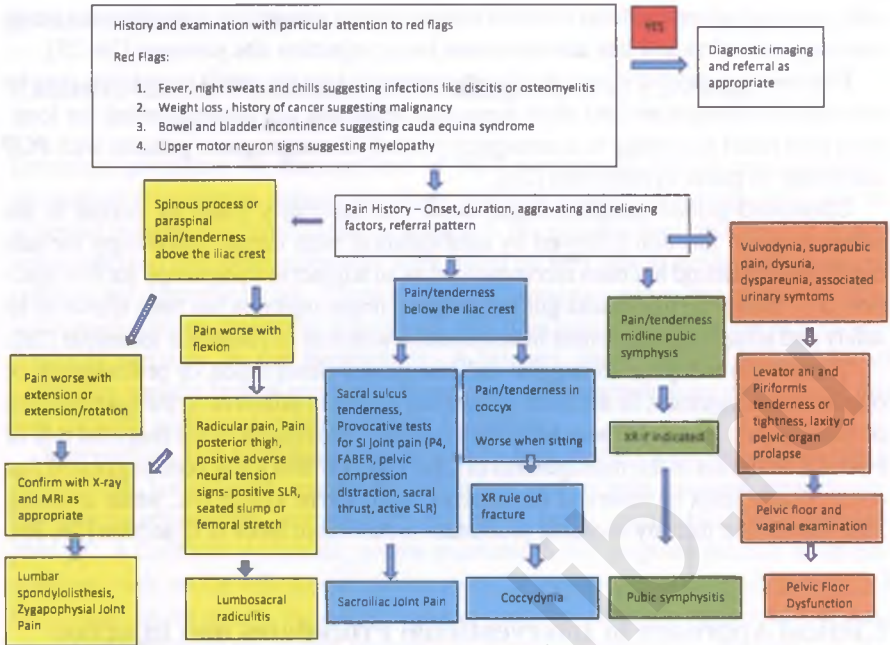


Fig. 7.1 Stepwise approach to diagnosis of peripartum musculoskeletal pain (first trimester to 6 months postpartum)

Physical Examination

We recommend that a detailed musculoskeletal and neurological exam be performed in pregnant patients similar to nonpregnant patients. Examination should start with inspection of lumbar curvature. Loss of lordosis and maladaptive movement patterns may indicate acute lumbar pathology, such as radiculitis secondary to disc pathology. Assessment of lumbar range of motion and limitations, lower extremity strength, muscle stretch reflexes (MSR), sensory changes, neural tension signs, and upper motor neuron signs are essential to help identify lumbar causes for pain. Particular attention should be given to the specific provocative tests as listed in Fig. 7.1. There are several provocative tests for SIJ dysfunction but the four provocative tests (posterior pelvic pain provocation test—P4/thigh thrusts, Patrick's FABER, palpation of long dorsal SIJ ligament and Gaenslen's test) have been shown to have the highest specificity (0.80–0.98) and sensitivity (0.69–0.76) [1]. Active straight leg raise (ASLR) can be used as a functional test for SIJ dysfunction [1]. In the author's experience treating pregnant patients, these provocative tests may not require high degrees of force to obtain the provocative response, therefore, these provocative physical exam tests should be performed with low levels of force initially and gradually increase force as the patient tolerates. In the second and third trimester, physical examination tests that normally are performed in the prone position should be done in the side lying position.

Table 7.2 Differential diagnosis of LBP and PGP

Lumbar causes	Radiculitis (secondary to disc protrusions or zygapophysial (Z) joint arthropathy causing foraminal stenosis)
	Synovial cyst in Z-joint
	Axial low back pain worse with extension (secondary to central disc protrusions, Z-joint arthropathy, central stenosis)
Sacroiliac joint pain	Sacroiliitis (secondary to increased ligament laxity or dysfunction or spondyloarthropathy such as ankylosing spondylitis)
Coccyx pain	Coccydynia secondary to sacrococcygeal ligament laxity
Symphysis pubis pain	Symphysitis, osteitis pubis, dysfunction due to widening
Pelvic floor pain	Levator ani spasms, tightness in obturator internus, prolapse of uterus with or without cystocele and rectocele

Investigations

Conventional radiography has no role to play in the diagnosis of PGP. Radiation dosage of computerized tomography (CT) is high and since degenerative changes are sometimes found in young healthy individuals, CT is not recommended as a standard diagnostic imaging test in either the pregnant or nonpregnant population. Magnetic resonance imaging (MRI) is a sensitive test to diagnose ankylosing spondylitis and tumors and therefore recommended only to confirm if there is a clinical suspicion of spondyloarthropathy or “red flag signs” and when surgical intervention procedures are considered [31]. Radio nucleotide bone scan has not shown to be sensitive or specific for sacroiliitis and therefore is not recommended. Pain referral maps can be a useful adjunct in differentiating lumbar from pelvic causes [1].

Differential Diagnosis for LBP and PGP in the Peripartum Period

The history and physical exam described above, including the provocative tests, is helpful in determining the likely etiology that can be broadly classified into five groups: (a) Lumbar causes; (b) SIJ-mediated pain; (c) Coccyx pain; (d) Symphysis pubis dysfunction; and (e) pelvic floor muscle dysfunction. The differential diagnosis for pain mediated from each anatomical region is listed in Table 7.2.

Injection Therapies for Management of LBP and PGP in Pregnancy and the Postpartum Period

For the purpose of this chapter, we will discuss the possible diagnostic and therapeutic injections for LBP and PGP related to lumbar spine causes, SIJ pain, coccyx pain and pubic symphysis pain, and pelvic floor dysfunction in the peripartum period. Since the imaging guidance and medication options are different in the two groups, the treatment approach for the two groups is discussed separately (see also Chap. 14).

Injection Therapy During Pregnancy

As discussed earlier, injection therapies in pregnancy are underexplored and currently there are no evidence-based recommendations for injection care in pregnancy for the management of musculoskeletal pain related to lumbar or pelvic girdle causes. The injection techniques discussed below can be performed safely by experienced personnel and are based on both referenced literature and our personal experiences. The decision to proceed to interventional care during pregnancy should be made in collaboration between the obstetrician and the patient after failure of non-interventional care, as outlined above and detailed in other chapters of this book. The injections outlined below should be used as an adjunct to the non-interventional treatment options and should not be used in isolation (Fig. 7.2.).

Image Guidance for Injections

Due to potential serious risks of radiation exposure to the unborn fetus with fluoroscopy, we do not recommend the use of fluoroscopy for needle guidance in pregnancy as a first-line choice of treatment. The use of fluoroscopy in pregnancy would require a very special circumstance and would also involve close collaboration of not only the obstetrician but also a radiation physicist to help estimate and limit radiation dose. Alternatives using blind technique and ultrasound-guided approaches will be discussed. Due to the unknown risks of using contrast media

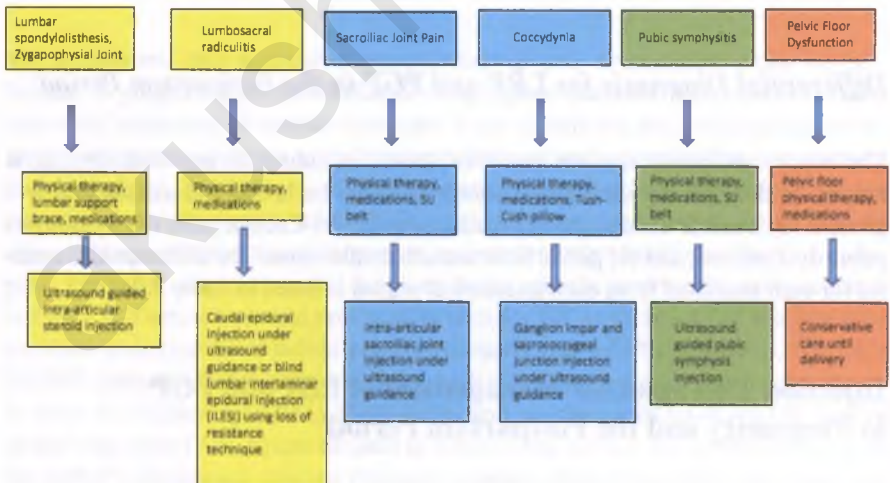


Fig. 7.2 Integration of interventional care treatment of musculoskeletal pain in pregnancy based on specific diagnosis

(iodinated or gadolinium-based) in pregnancy, injection procedures are performed under direct visualization of the needle under ultrasound guidance or blind technique only. Blind techniques have the disadvantage of inaccurate needle placement even in the most experienced hands but can be easily performed in the office at low cost and patient convenience. Ultrasound-guided procedures are radiation-free and can improve accuracy of needle placement over nonguided techniques, but require the interventionalist to have the necessary equipment and additional training. There is additional cost of adding ultrasound guidance to the procedure, although this cost is considerably less than for fluoroscopic guidance. While ultrasound technique using color Doppler can identify vascular structures to avoid it is not capable of identifying intravascular uptake as contrast enhanced live fluoroscopy can [32]. Because of the intravascular detection issue, in the author's opinion, non-particulate steroid that is safe in the intravascular space is considered as a safe choice of steroid medication. Coordination of care with the treating obstetrician is essential to exclude contraindications for the medications used, particularly corticosteroids. The various injection techniques that can be used for pregnancy-related musculoskeletal pain are discussed below:

Caudal Epidural Steroid Injection Using an Ultrasound-Guided Approach

Indications: Lumbosacral radiculitis secondary to disc pathology or stenosis

Medications: Local anesthetic: Preservative-free lidocaine 1—2 mL

Injectate: Non-particulate steroid such as Dexamethasone—2 mL (10 mg/mL) and 8 mL preservative-free normal saline

Technique: The patient is positioned prone. The skin is prepared in the usual sterile manner, including use of sterile gel and a sterile ultrasound transducer cover. The curvilinear ultrasound transducer is positioned to provide a transverse view of the inferior sacrum and sacral hiatus in longitudinal plane with a 6–12 MHz linear array transducer. The bony prominence of the sacral cornua on both sides is identified. The transducer is then rotated longitudinally to 90° to visualize the sacral hiatus. The caudal epidural injection is begun by anesthetizing the skin and soft tissues with approximately 2 mL of 1 % lidocaine administered with a sterile 25-gauge 1.5-in. needle. Using ultrasound guidance, a sterile 22-gauge 3.5-in. spinal needle is then positioned at the sacral hiatus between the sacral cornua with a characteristic pop appreciated upon passing through the ligament under longitudinal view. Then 10 mL of injectate is administered, visualizing the needle tip under real time ultrasound guidance as described [33]. It should be ensured that no blood or CSF is present on aspiration and no fluid is observed accumulating in the soft tissues under live ultrasound. The following solution is then injected: 2 mL of non-particulate steroid such as Dexamethasone (10 mg/mL) and 8 mL preservative-free normal saline.

Diagnostic or Therapeutic Sacroiliac Joint Injection Using Ultrasound Guidance

Indication: SIJ-mediated pain identified using provocative tests as listed in Fig. 7.1.

Medications: Local anesthetic—preservative-free, 1 % lidocaine (2 mL—10 mg/mL)

Injectate: Preservative-free 2 % lidocaine (10 mg/mL)—2 mL for diagnostic injections. For therapeutic injections, combine 1 mL of 2 % lidocaine with 1 mL of dexamethasone (10 mg/mL)

Technique: The patient is positioned prone. The skin is prepared in the usual sterile manner. The 4–5 MHz linear ultrasound transducer is positioned to view the SIJ. According to the method described by Jee et al. [34], the spinous process of the fifth lumbar vertebra is taken as the initial anatomical landmark and the transducer is moved caudally until the posterior aspect of the S2 foramen is visible. The posterior sacral foramen 2, the lateral sacral crest, the dorsal margin of the SIJ, and the iliac bone are then visualized by moving the transducer laterally while orienting its lateral edge 20° cranially. After the delineation of the SIJ cleft, injection is begun by anesthetizing the skin and soft tissues with approximately 1 mL of 1 % lidocaine administered with a sterile 25-gauge 1.5-in. needle. Using ultrasound guidance, a sterile 22-gauge 3.5-in. spinal needle is then positioned at the SIJ under real time ultrasound. Precise needle placement is confirmed and unidirectional flow into the joint is observed. Then 2 mL of the injectate is administered with no fluid observed accumulating in the soft tissues under live ultrasound.

If the patient attains significant relief from the diagnostic injection (ideally 80 % or more relief), a subsequent therapeutic injection under ultrasound guidance with corticosteroid can be injected into SIJ using the above technique.

Ganglion Impar and Sacrococcygeal Ligament Injection Under Blind or Ultrasound Guidance

Indication: Coccyx pain

Medications: Local anesthetic: Preservative-free lidocaine 1–2 mL

Injectate: Dexamethasone—1 mL (10 mg/mL)

Technique: The patient is positioned prone with internal rotation of lower extremities with toes pointing towards the opposite foot to hold the gluteal masses apart and achieve a flatter skin surface at the sacral hiatus. The skin is prepared in the usual sterile manner. For blind approach, the tip of the coccyx is palpated followed by palpation of the sacrococcygeal junction. For ultrasound-guided injection, the ultrasound transducer is positioned transversely at midline to obtain a transverse view of the sacral hiatus and the sacrococcygeal ligament. The transducer is rotated 90° to provide a longitudinal view of the sacral hiatus. The first cleft caudal to the sacral

hiatus is identified to be the sacrococcygeal junction. The sacrococcygeal injection is begun by anesthetizing the skin and soft tissues with approximately 2 mL of 1 % lidocaine administered with a sterile 25-gauge 1.5 in. needle. Using ultrasound guidance, a sterile 22-gauge 1.5-in. spinal needle is then positioned at the sacrococcygeal junction that is felt by a loss of resistance, indicating that the needle tip is anterior to the ventral sacrococcygeal ligament. Precise needle placement is confirmed and the following solution is injected: 1 mL of 1 % lidocaine mixed with 1 mL of dexamethasone solution.

Interlaminar Epidural Steroid Injection (ILESI) Using Palpation and Blind Approach and Using the Loss of Resistance Technique

Indications: Lumbosacral radiculitis secondary to disc pathology or stenosis

Medications: Local anesthetic: Preservative-free lidocaine 1–2 mL

Injectate: Non-particulate steroid such as Dexamethasone—2 mL (10 mg/mL)

Technique: The patient is positioned prone. The skin is prepped in the usual sterile manner. The L5 spinous process is palpated and L4-5 or L5-S1 interlaminar space is identified by palpation. The interlaminar epidural injection is begun by anesthetizing the skin and soft tissues with approximately 2 mL of 1 % lidocaine administered with a sterile 25-gauge 1.5-in. needle. A sterile 3.5-in., tuohy needle is then positioned at the interlaminar space using a loss of resistance syringe with saline. The following solution is then injected through microbore tubing:

2 mL of 1 % lidocaine as a test dose without adverse effect followed by 2 mL of dexamethasone (10 mg/mL).

Symphysis Pubis Injection Using Ultrasound Guidance

Indication: Osteitis pubis, symphysis

Medications: 1 mL of 1 % lidocaine (preservative-free) mixed with 1 mL of beta-methasone solution (6 mg/mL) or triamcinolone (40 mg/mL) or dexamethasone (10 mg/mL).

Technique: The skin is prepared in the usual sterile manner. Using ultrasound guidance (curvilinear 4–5 MHz transducer) or palpation, the tender point is identified in midline in the area of symphysis pubis. The transducer is placed transversely over the anterior superior iliac spine and moved inferior and medial to identify the pubis. A sterile 22- or 25-gauge spinal needle is then positioned in the pubic symphysis under real time ultrasound guidance. A combination of lidocaine and choice of steroid (dexamethasone, betamethasone, or triamcinolone) is then injected, and flow into the joint is observed under ultrasound.

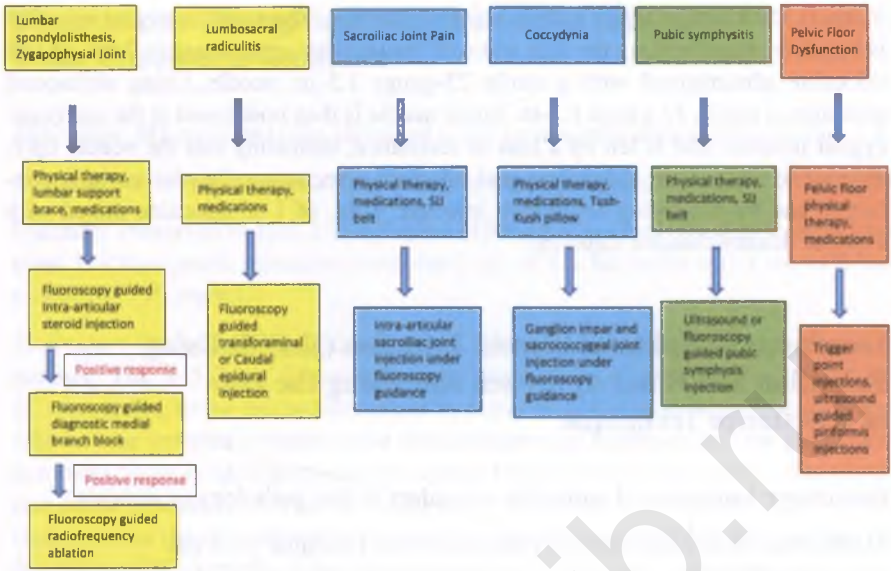


Fig. 7.3 Integration of interventional care treatment of musculoskeletal pain in the postpartum period based on specific diagnosis

Injection Therapies for Management of Musculoskeletal LBP and PGP in the Postpartum Period

In contrast to pregnancy, there is no contraindication for using fluoroscopy for performing procedures in the postpartum period and this offers a wide range of injection possibilities. It is still necessary to closely coordinate the care with the obstetrician to ensure no contraindications to using these medications in breastfeeding women. The various injection techniques that can be used for musculoskeletal pain in the postpartum period are discussed below. The recommendations for injections and techniques in the postpartum period are based on International Spine Intervention Society (ISIS) guidelines [35] for several of the following injections (Fig. 7.3).

Transforaminal Epidural Steroid Injection (TFESI) Under Fluoroscopy Guidance [35]

Indications: Lumbosacral radiculitis secondary to an inflammatory pathology and for whom nonsurgical interventions have failed or are not indicated.

Medications: Local anesthetic: Preservative-free lidocaine 1–2 mL

Injectate: Dexamethasone—2 mL (10 mg/mL)

Contrast: Water soluble, non-ionic contrast suitable for intravenous or intrathecal use (e.g., isohexol or iopamidol)

Technique: The patient is positioned prone. The skin is prepared in the usual sterile manner. The fluoroscope is positioned to provide an oblique view so that the X-ray beam passes tangential to the inferior endplate of the upper of the two vertebrae of the target segment. The optimal target point for the subpedicular approach is the “six o’clock” position of the pedicle. The target point is termed as the “safe triangle” that is formed by a transverse line tangential to the lower margin of the pedicle, a sagittal line tangential to the lateral margin of the pedicle, and a hypotenuse passing obliquely inferiorly and laterally from the medial corner of the pedicle [35]. The transforaminal epidural injection is begun by anesthetizing the skin and soft tissues with approximately 2 mL of 1 % lidocaine administered with a sterile 25-gauge 1.5-in. needle. Using fluoroscopic guidance, a sterile 22-gauge spinal needle is then positioned at the foramen in the superior aspect above the exiting spinal nerve. Precise needle placement is confirmed by fluoroscopy using an anteroposterior view to confirm needle tip is not medial to the “six o’clock” position and on lateral view to confirm needle tip is on the back of the vertebral body below the pedicle. 1–2 mL of contrast dye is injected through microbore tubing under live fluoroscopy and intravascular uptake excluded. It is ensured that a medial and superior epidural flow pattern and no evidence of intrathecal flow. The following solution is then injected through microbore tubing: 1 % lidocaine as a test dose without adverse effect followed by 4–16 mg dexamethasone.

Therapeutic Intra-articular Zygapophysial Joint Injection Using Fluoroscopy Guidance

Indications: Axial zygapophysial joint-mediated pain secondary to zygapophysial joint cyst, synovitis, or arthropathy.

Medications: Local anesthetic—0.2 mL of 1 % lidocaine (preservative-free)

Injectate—0.8 mL of dexamethasone solution (10 mg/mL)

Contrast—Water soluble, non-ionic, iodinated contrast suitable for intravenous or intrathecal use (e.g., Isohexol or iopamidol).

Technique: The patient is positioned prone. The skin is prepared in the usual sterile manner. The fluoroscope is positioned to provide an oblique view and the corresponding zygapophysial joint lucency identified. The zygapophysial joint injection is begun by anesthetizing the skin and soft tissues with approximately 2 mL of 1 % lidocaine, administered with a sterile 25-gauge 1.5 in. needle. Using fluoroscopic guidance, a sterile 22-gauge spinal needle is then positioned at the zygapophysial joint. Precise needle placement is confirmed by fluoroscopy using anteroposterior view. 0.2 mL of contrast dye is injected through microbore tubing under live fluoroscopy showing an arthrogram and characteristic dumbbell-shaped contrast pattern filling the inferior and superior recesses of the joint. It is ensured that there is no

intravascular uptake or intrathecal flow and there is flow into the joint observed following which lidocaine mixed with steroid injectate is administered.

The procedure can be repeated for any additional joints that mediate pain.

Lumbar Diagnostic Medial Branch Block Using Fluoroscopy Guidance [35]

Indications: Axial LBP secondary to zygapophysial joint pathology or transient relief with therapeutic zygapophysial joint injections. The purpose of the medial branch blocks is to test if anaesthetizing the nerves targeted relieves the patient's pain. A positive response identifies the source of pain and predicts a good chance of obtaining complete relief of pain from percutaneous radiofrequency neurotomy. If negative response, it is possible that the patient's pain is mediated by other medial branches or that it is arising from a source not innervated by lumbar medial branches. Control blocks are recommended in order to reduce the number of false positive results [35].

Medications: 0.5 mL of (preservative-free) 2 % lidocaine or 0.25 %/0.5 % bupivacaine.

Contrast—Water soluble, non-ionic contrast suitable for intravenous or intrathecal use (e.g., Isohexol or iopamidol).

Technique: The patient is positioned prone. The skin is prepared in the usual sterile manner. The fluoroscope is positioned to provide an oblique view. The lumbar medial branch diagnostic injection is begun by anesthetizing the skin and soft tissues with approximately 0.5 mL of 1 % lidocaine administered with a sterile 25-gauge 1.5-in. needle. Using fluoroscopic guidance, a sterile 22-gauge spinal needle is then positioned at the vertebral body immediately below the medial branch to be blocked at the junction of the superior articular process and the transverse process for lumbar levels L1–4. The needle is placed at the ala of the sacrum to block the L5 dorsal ramus. Precise needle placement is confirmed by fluoroscopy. 0.2 mL of contrast dye is injected through microbore tubing under live fluoroscopy. Soft tissue flow is verified without intravascular or intrathecal flow.

The following solution is then injected: 0.5 mL of lidocaine or bupivacaine

In order to anesthetize one zygapophysial joint, the medial branch above and below the joint needs to be blocked. For example, the L5-S1 joint is innervated by the L4 medial branch which crosses the L5 transverse process and by the dorsal ramus of L5 which crosses the ala of the sacrum. The procedure can be repeated for multiple medial branches based on clinical suspicion. A pre- and postpain score on visual analog scale (VAS) or Numeric Pain Rating Scale (NPRS) is obtained and 80 % or more reduction is considered a positive response. Because there is a significant 40 % false positive rate with a single block, a double block paradigm has been recommended by ISIS. Two confirmatory medial branch blocks are indicated to ascertain the diagnosis of zygapophysial joint pain prior to embarking on a therapeutic radiofrequency ablation (RFA) procedure with a goal of providing longer periods of relief from zygapophysial joint-mediated pain per ISIS guidelines [35].

Radiofrequency Ablation Using Fluoroscopy Guidance [35]

Indications: Zygophysal joint pain with transient relief after therapeutic Z-joint injections and/or confirmed by diagnostic medial branch blocks. Radiofrequency neurotomy is a nonselective method of coagulating the peripheral nerves. The rationale of percutaneous radiofrequency lumbar medial branch neurotomy is that if pain is mediated by a medial branch, it can be relieved by coagulating the nerve to prevent conduction of nociceptive impulses along it. It is considered a palliative procedure. Both the medial branches that innervate a given joint are targeted.

Mechanism of action: Radiofrequency neurotomy achieves its effect by alternating a high-frequency electrical current between a large surface area on a ground plate and a small area on the uninsulated tip of the electrode. When current is strong, it coagulates the tissue near the tip of the electrode in a radial direction perpendicular to the long axis of the electrode. The temperature is gradually increased at the rate of 1° per second to 80° and maintained at 80° for 90 s to ensure maximum volume of coagulated tissue. In order to coagulate a wide volume of tissue, electrodes are placed no more than one electrode-width between consecutive placements. When patients are carefully selected with controlled, diagnostic blocks of the target medial branches, about 60 % patients receive 80 % pain relief and 80 % of patients receive 60 % pain relief at 12 months follow-up [35].

Medications: 0.5 mL of preservative-free 2 % lidocaine and 1 mL of 1 % lidocaine.

Technique: The patient is positioned prone. A grounding pad is secured. The skin is prepped in the usual sterile manner. The fluoroscope is positioned to provide an oblique view and pillar view. The medial branch radiofrequency neurotomy is begun by anesthetizing the skin and soft tissues with approximately 2 mL of 1 % lidocaine, administered with a sterile 25-gauge 1.5-in. needle. Using fluoroscopic guidance, a sterile 18-gauge 100 mm curved tip RF cannula with 10 mm active tip is then positioned at the corresponding vertebral body at the junction of the superior articular process and the transverse process. The angle of needle position is important. A caudad to cephalad and lateral to medial orientation parallel to the medial branch nerve is imperative when using standard radiofrequency heat ablation probes because these probes lesion parallel to the exposed needle shaft and not at the distal end of the cannula. Precise needle placement is confirmed by fluoroscopy in multiple views ensuring position posterior to the foramen. A radiofrequency probe is then inserted in the cannula. A practice option that many choose to execute is obtaining sensory and motor thresholds. 1–2 mL of 1 % lidocaine is injected to provide medial branch anesthesia. Next, a continuous lesion is applied for 90 s at 80°C . The probe is slightly retracted and lateral view again checked. Next, a continuous lesion is applied for 90 s at 80°C to complete a second lesion. Depending on the needle position, another lesion can be created alongside of the superior articular process as necessary. The more lesions performed with a larger gauge cannula, the broader the area of nerve lesion that will be created. The procedure can be repeated at additional levels as clinically indicated.

Fluoroscopy-Guided Sacroiliac Joint Injection

Indications: SIJ pain

Medications: Local anesthetic: Preservative-free lidocaine 1—2 mL

Injectate: 1 mL of steroid (betamethasone solution (6 mg/mL) or triamcinolone (40 mg/mL) or dexamethasone (10 mg/mL)) mixed with 1 mL of 1 % or 2 % lidocaine or 0.5 % ropivacaine.

Contrast: Water soluble, non-ionic, iodinated contrast suitable for intravenous or intrathecal use (e.g., Isohexol or iopamidol).

Technique: The patient is positioned prone. The skin is prepared in the usual sterile manner. The fluoroscope is positioned to provide a slightly oblique view illuminating the confluence of the anterior and posterior joint lines of the lower one-third of the SIJ, dubbed the “sweet spot”. The SIJ injection is begun by anesthetizing the skin and soft tissues with approximately 2 mL of 1 % lidocaine administered with a sterile 25-gauge 1.5-in. needle. Using fluoroscopic guidance, a sterile 22-gauge 3.5-in. spinal needle is then positioned at the inferior aspect of SIJ. Precise needle placement is confirmed by fluoroscopy. 0.2 mL of contrast media is injected through microbore tubing under live fluoroscopy. After confirming no intravascular uptake and intra-articular flow is observed usually filling the inferior joint recess first, 2 mL of injectate containing steroid and local anesthetic (as above) is then injected.

Caudal ESI Injection Using Fluoroscopy Guidance

Indications: Lumbosacral radiculitis secondary to disc pathology or stenosis

Medications: Contrast—Water soluble, non-ionic contrast suitable for intravenous or intrathecal use (e.g., Isohexol or iopamidol).

Injectate: 2 mL of dexamethasone solution (10 mg/mL) with 4 mL of 1 % lidocaine (preservative-free) and 4 mL of saline for combined volume of 10 mL. Ten milliliters of injectate will frequently reach the L5-S1 interspace. It is thought that larger volumes of 15 mL are necessary to reach the L4-5 interspace.

Technique: The patient is positioned prone. The skin is prepared in the usual sterile manner. The fluoroscope is positioned to provide a lateral view of the inferior sacrum to identify the sacral hiatus. The caudal epidural injection is begun by anesthetizing the skin and soft tissues with approximately 2 mL of 1 % lidocaine administered with a sterile 25-gauge 1.5-in. needle. Using fluoroscopic guidance, a sterile 22-gauge 3.5-in. spinal needle is then positioned at the sacral hiatus with needle tip below the S2 level between the sacral cornua with characteristic pop of ligament appreciated. Precise needle placement is confirmed by fluoroscopy in AP and lateral views. Approximately 1.5 mL of contrast dye is injected through microbore tubing under live fluoroscopy. After ensuring no intravascular or intrathecal flow, the injectate of steroid, lidocaine, and saline is then slowly injected.

Ganglion Impar and Sacrococcygeal Injection Using Fluoroscopy Guidance

Indications: Coccydynia

Medications: Local: Preservative-free lidocaine 1 %—2 mL

Injectate: Dexamethasone—1 mL (10 mg/mL) with 1 mL of preservative-free 1 % lidocaine or 0.25–0.5 % bupivacaine.

Contrast: Water soluble, non-ionic, iodinated contrast suitable for intravenous or intrathecal use (e.g., Isohexol or iopamidol).

Technique: The patient is positioned prone. The skin is prepared in the usual sterile manner. The fluoroscope is positioned to provide a lateral view of the inferior sacrum. The sacrococcygeal junction injection is begun by anesthetizing the skin and soft tissues with approximately 2 mL of 1 % lidocaine administered with a sterile 25-gauge 1.5-in. needle. Using fluoroscopic guidance, a sterile 22-gauge 1.5-in. spinal needle is then positioned at the sacrococcygeal junction. For ganglion impar block, the needle tip must be advanced just anterior to the anterior border of the sacrum. Precise needle placement is confirmed by fluoroscopy. Up to 1.5 mL of contrast dye is injected through microbore tubing under live fluoroscopy. After confirming no intravascular uptake and intrathecal flow, the following is injected: 1 % lidocaine, mixed with dexamethasone.

Conclusions

Lumbopelvic pain is the most common cause for musculoskeletal pain in pregnancy and the postpartum period and causes significant morbidity and socioeconomic impact. Interventional options for management need to be expanded to offer injection therapy in addition to individualized physical therapy and supportive care. Management options should also take into consideration patient's preferences, organization obstacles, and cost implications with an ultimate goal to prevent long-term complications, pain, and disability. Therefore, an interdisciplinary and multifactorial approach is often necessary to develop an individualized treatment program. The above discussed injection therapies can be safely offered to this population by experienced physicians involving multiple disciplines to improve women's experiences and prevent long-term complications.

References

1. Vleeming A, Albert HB, Ostgaard HC, Sturesson B, Stuge B. European guidelines for the diagnosis and treatment of pelvic girdle pain. *Eur Spine J.* 2008;17(6):794–819.
2. Vermani E, Mittal R, Weeks A. Pelvic girdle pain and low back pain in pregnancy: a review. *Pain Pract.* 2010;10(1):60–71.

3. Mousavi SJ, Parnianpour M, Vleeming A. Pregnancy related pelvic girdle pain and low back pain in an Iranian population. *Spine (Phila Pa 1976)*. 2007;32(3):E100–4.
4. Skaggs CD, Prather H, Gross G, George JW, Thompson PA, Nelson DM. Back and pelvic pain in an underserved United States pregnant population: a preliminary descriptive survey. *J Manipulative Physiol Ther*. 2007;30(2):130–4.
5. Mogren IM, Pohjanen AI. Low back pain and pelvic pain during pregnancy: prevalence and risk factors. *Spine (Phila Pa 1976)*. 2005;30(8):983–91.
6. Wu WH, Meijer OG, Uegaki K, Mens JM, van Dieën JH, Wuisman PI, Ostgaard HC. Pregnancy-related pelvic girdle pain (PPP), I: terminology, clinical presentation, and prevalence. *Eur Spine J*. 2004;13(7):575–89.
7. Greenwood CJ, Stainton MC. Back pain/discomfort in pregnancy: invisible and forgotten. *J Perinat Educ*. 2001;10(1):1–12.
8. Gutke A, Ostgaard HC, Oberg B. Association between muscle function and low back pain in relation to pregnancy. *J Rehabil Med*. 2008;40(4):304–11.
9. Albert H, Godsken M, Westergaard J. Prognosis in four syndromes of pregnancy-related pelvic pain. *Acta Obstet Gynecol Scand*. 2001;80(6):505–10.
10. Kanakaris NK, Roberts CS, Giannoudis PV. Pregnancy-related pelvic girdle pain: an update. *BMC Med*. 2011;9:15.
11. Albert H, Godsken M, Westergaard JG, Chard T, Gunn L. Circulating levels of relaxin are normal in pregnant women with pelvic pain. *Eur J Obstet Gynecol Reprod Biol*. 1997;74(1):19–22.
12. Hansen A, Jensen DV, Larsen E, Wilken-Jensen C, Petersen LK. Relaxin is not related to symptom-giving pelvic girdle relaxation in pregnant women. *Acta Obstet Gynecol Scand*. 1996;75(3):245–9.
13. O'Sullivan PB, Beales DJ. Diagnosis and classification of pelvic girdle pain disorders—Part 1: a mechanism based approach within a biopsychosocial framework. *Man Ther*. 2007;12(2):86–97. Review.
14. O'Sullivan PB, Beales DJ. Diagnosis and classification of pelvic girdle pain disorders, Part 2: illustration of the utility of a classification system via case studies. *Man Ther*. 2007;12(2):e1–12. Review.
15. Linton SJ. A review of psychological risk factors in back and neck pain. *Spine (Phila Pa 1976)*. 2000;25(9):1148–56.
16. Bergström G, Bodin L, Jensen IB, Linton SJ, Nygren AL. Long-term, non-specific spinal pain: reliable and valid subgroups of patients. *Behav Res Ther*. 2001;39(1):75–87.
17. Pennick V, Liddle SD. Interventions for preventing and treating pelvic and back pain in pregnancy. *Cochrane Database Syst Rev*. 2013;8, CD001139.
18. Elden H, Ladfors L, Olsen MF, Ostgaard HC, Hagberg H. Effects of acupuncture and stabilising exercises as adjunct to standard treatment in pregnant women with pelvic girdle pain: randomised single blind controlled trial. *BMJ*. 2005;330(7494):761.
19. Guerreiro da Silva JB, Nakamura MU, Cordeiro JA, Kulay Jr L. Acupuncture for low back pain in pregnancy—a prospective, quasi-randomised, controlled study. *Acupunct Med*. 2004;22(2):60–7.
20. Kvorning N, Holmberg C, Grennert L, Aberg A, Akeson J. Acupuncture relieves pelvic and low-back pain in late pregnancy. *Acta Obstet Gynecol Scand*. 2004;83(3):246–50.
21. Broadhurst NA, Bond MJ. Pain provocation tests for the assessment of sacroiliac joint dysfunction. *J Spinal Disord*. 1998;11(4):341–5.
22. Luukkainen RK, Wennerstrand PV, Kautiainen HH, Sanila MT, Asikainen EL. Efficacy of periarticular corticosteroid treatment of the sacroiliac joint in non-spondylarthropathic patients with chronic low back pain in the region of the sacroiliac joint. *Clin Exp Rheumatol*. 2002;20(1):52–4.
23. Maugars Y, Mathis C, Berthelot JM, Charlier C, Prost A. Assessment of the efficacy of sacroiliac corticosteroid injections in spondylarthropathies: a double-blind study. *Br J Rheumatol*. 1996;35(8):767–70.

24. Plastaras CT, Joshi AB, Garvan C, Chimes GP, Smeal W, Rittenberg J, Lento P, Stanos S, Fitzgerald C. Adverse events associated with fluoroscopically guided sacroiliac joint injections. *PM R*. 2012;4(7):473–8.
25. Slipman CW, Lipetz JS, Plastaras CT, Jackson HB, Vresilovic EJ, Lenrow DA, Braverman DL. Fluoroscopically guided therapeutic sacroiliac joint injections for sacroiliac joint syndrome. *Am J Phys Med Rehabil*. 2001;80(6):425–32.
26. Fitzgerald CM, Plastaras CT, Mallinson T. A retrospective study on the efficacy of pubic symphysis corticosteroid injections in the treatment of pubic symphysis pain. *Pain Med*. 2011;12(12):1831–5.
27. Lin CS, Cheng JK, Hsu YW, Chen CC, Lao HC, Huang CJ, Cheng PH, Narouze S. Ultrasound-guided ganglion impar block: a technical report. *Pain Med*. 2010;11(3):390–4.
28. Johnston PJ, Michálek P. Blockade of the ganglion impar (Walther) using ultrasound and a loss of resistance technique. *Prague Med Rep*. 2012;113(1):53–7.
29. Fuller JG, Janzen J, Gambling DR. Epidural analgesia in the management of symptomatic symphysis pubis diastasis. *Obstet Gynecol*. 1989;73(5 Pt 2):855–7.
30. Scicluna JK, Alderson JD, Webster VJ, Whiting P. Epidural analgesia for acute symphysis pubis dysfunction in the second trimester. *Int J Obstet Anesth*. 2004;13(1):50–2.
31. Royal College of General Practitioners 1996/1999. *Clinical guidelines in management of acute low back pain*. London: RCGP.
32. Renfrew DL, Moore TE, Kathol MH, el-Khoury GY, Lemke JH, Walker CW. Correct placement of epidural steroid injections: fluoroscopic guidance and contrast administration. *AJNR Am J Neuroradiol*. 1991;12(5):1003–7.
33. Park Y, Lee J-H, Park KD, Ahn JK, Park J, Jee H. Ultrasound-guided vs. fluoroscopy-guided caudal epidural steroid injection for the treatment of unilateral lower lumbar radicular pain: a prospective, randomized, single-blind clinical study. *Am J Phys Med Rehabil*. 2013;92:575–86.
34. Jee H, Lee JH, Park KD, Ahn J, Park Y. Ultrasound-guided versus fluoroscopy-guided sacroiliac joint intra-articular injections in the noninflammatory sacroiliac joint dysfunction: a prospective, randomized, single-blinded study. *Arch Phys Med Rehabil*. 2014;95(2):330–7.
35. International Spine Intervention Society. *Practice guidelines for spinal diagnostic and treatment procedures*. San Francisco: International Spine Intervention Society; 2004.

Chapter 8

Hip Disorders in Pregnancy

Monica Rho, Fariba Shah, and Eziamaka Okafor

Introduction

Hip pain in pregnancy is commonly attributed to “round ligament” pain and often considered a normal part of pregnancy. Although it may be the most likely cause of groin pain in pregnancy, there are many other hip disorders that can account for pain in a pregnant woman. This chapter will address the spectrum of hip disorders associated with pregnant women. Unfortunately, the current literature is sparse in capturing the prevalence of these disorders in the pregnant population specifically. However, this chapter will address common hip disorders found in women of child-bearing ages and add the clinical implications of addressing these issues in pregnant and postpartum women.

Hip pain can often times be a confusing clinical diagnosis due to the overlapping pain referral patterns of the hip and lumbopelvic region. Hip disorders can be categorized as extra-articular or intra-articular hip pain. Extra-articular hip pain is caused by bone or soft tissues structures (i.e., muscle, tendon, or nerve) whereas intra-articular hip pain originates from the hip joint itself (i.e., bone, synovium, cartilage, and labrum). Distinguishing between intra- and extra-articular hip pain should be the first step in the diagnosis and management of peripartum women with hip pain.

M. Rho, MD (✉) • E. Okafor, MD
Rehabilitation Institute of Chicago, Chicago, IL 60610, USA
e-mail: mrho@ric.org; eziamaka.okafor@gmail.com; eokafor@ric.org

F. Shah, MD
Spine & Sports Medicine, Physical Medicine & Rehabilitation, Banner Good Samaritan
Rehabilitation Institute, 1012 East Willetta Street, Phoenix, AZ 85006, USA
e-mail: fariba.sshah@bannerhealth.com

Extra-articular Hip Pain

Round Ligament

Hip pain during pregnancy is commonly attributed to round ligament pain. The round ligament of the uterus (RLU) is a remnant of the female gubernaculum, an embryonic structure that is important in development. The upper cranial part of the gubernaculum becomes the ovarian ligament and the lower caudal part forms the RLU [1]. The RLU originates at the uterine horns where the uterus and the uterine tube meet, passes through the inguinal canals, and inserts at the labium majus [2, 3]. The ligaments are approximately 10–12 cm-long and contain veins, branches from the ovarian artery, lymphatics, smooth muscles, and nerves. The function of the round ligament is to maintain the anteversion of the uterus [2, 4].

Round ligament pain is defined as a sharp pain or jabbing feeling felt in the lower abdomen or hip area during pregnancy. This pain can be unilateral or bilateral with possible extension to the groin area. The RLU stretches throughout pregnancy to accommodate the changes within the body. It is this stretching of the ligaments that is theorized to elicit the “round ligament” pain. Movement also can trigger round ligament pain. It is a self-limiting disorder and completely resolves once the body has adjusted to stretch of the round ligament or once the baby is delivered.

Considered a normal part of pregnancy, round ligament pain is one of the most commonly diagnosed conditions during pregnancy. Ultimately, it is a diagnosis of exclusion. Although women’s healthcare providers are quick to diagnose this in pregnant women with groin pain, the medical literature on the musculoskeletal manifestations of round ligament pain is significantly lacking. Alternative diagnoses should be considered in pregnant women presenting with persistent and functionally limiting hip pain.

Transient Osteoporosis of Pregnancy

Introduction

Transient osteoporosis describes a self-limiting condition of acute pain with the development of localized osteoporosis in periarticular bone. The condition has been reported to mainly affect pregnant women in their third trimester of pregnancy and middle-aged men [5–7]. The exact etiology is unknown, though chemical, hormonal, mechanical, genetic, viral, and neurovascular theories have been proposed [6, 8]. There is difficulty in early diagnosis, limitation of treatment regimes in pregnancy, and a risk of fracture [9].

Epidemiology

Ravault described the first case of transient osteoporosis of pregnancy (TOP) in 1947; Curtiss and Kincaid later described three cases of TOP affecting the hip joint in 1959 [6, 7, 9–15]. The term transient osteoporosis of the hip (TOH) was used by Lequesne in 1968 and described the periarticular osteopenia seen in plain radiographs 3–6 weeks after the onset of pain [16]. Subsequently several authors have reported similar cases. TOP has been reported as a rare condition with several 100 cases published in the literature, but it seems the real incidence is underestimated [9, 11, 17]. These reports have given rise to different names and descriptions, the more common including: transient osteoporosis, regional or transient migratory osteoporosis, migrational osteolysis, transient hip demineralization, hip algodystrophy, and bone marrow edema syndrome [7, 8, 13, 17]. Transient osteoporosis has been described in two unique populations: men in their fourth and fifth decades of life and peripartum young women. In both groups, transient osteoporosis is usually unilateral, but bilateral disease has been reported. The most commonly affected joint is the hip, followed by the knee, foot and ankle, and less frequently, the shoulder, lumbosacral spine, elbow, wrist, and hand [7, 13, 16]. It is estimated that the hip joint is affected 76 % of the time, particularly on the left side, with bilateral hip involvement in 25–30 % of patients [13, 18]. Risk factors include poor nutrition, low calcium intake, and a family history of osteoporosis [6, 7, 19].

Pathogenesis

The pathogenesis of TOP remains elusive. Multiple causal mechanisms of TOP have been proposed, including: microvascular injury, abnormal mechanical stress, neurogenic dysfunction, maternal demands of calcium, viral pathogens, minor trauma to the joint, genetic factors, and venous stasis inducing reversible ischemia of pregnancy [12, 19]. Angiographical and scintigraphical studies have shown that the arteries supplying nutrients to the femoral head are dilated and the perfusion in this area is higher than in the unaffected contralateral side, suggesting that ischemia is the most likely cause of the initial insult [6, 7]. Curtiss and Kincaid described intermittent mechanical compression caused by the fetal head on the mother's obturator nerve as a cause for local demineralization leading to osteopenia of the hip. Similarly, compression of the pelvic nerves by the enlarged uterus or venous compression with impairment of venous flow has been theorized as predisposing factors to ischemia and thrombosis [10, 18]. Another potential hypothesis is the concept of an ischemic threshold that determines whether the lesion will progress from a reversible intraosseous hypoxia (TOP) to an irreversible intraosseous anoxia avascular necrosis (AVN). Neurologic disturbances have also been implicated in the pathogenesis of TOP based on electromyographic abnormalities. Familial presentation has been reported, and although a specific HLA association seems unlikely, a possible genetic predisposition cannot be excluded [13].

In pregnancy, TOP may be related to the unmasking of a preexisting low bone mass. Pregnancy is viewed as a stress on calcium homeostasis during which physiologic hypercalciuria and transient reduction in bone mass is seen. Hormonal factors with increased maternal demands of calcium can contribute to the demineralization of bone [13]. There are three possible sources of calcium to support fetal bone mass: increased intestinal calcium absorption, renal calcium conservation, and mobilization of calcium from the maternal skeleton [20]. Increased intestinal calcium absorption appears to be an important compensatory mechanism for securing additional calcium during pregnancy; the fractional absorption of calcium increases 54–62 % in the third trimester. However, despite the increased need for calcium, renal calcium excretion increases by 46 % due to the increase in glomerular filtration rate that occurs during pregnancy [20]. There is an average loss of 30 g of total body calcium in the pregnant population because of fetal skeletal mineralization and overload due to increased body weight. This is compensated for by an increase in the active form of vitamin D, 1, 25-dihydroxyvitamin D₃, which increases GI absorption of calcium. This hypothesis, however, does not fully explain the selective demineralization in this entity.

Clinical Presentation

Transient osteoporosis usually occurs during the last trimester of pregnancy or the immediate postpartum period. The most commonly affected joint that is reported in the literature is the hip. The clinical presentation of TOP varies based on the location of the transient osteoporosis. This section will mainly address the clinical presentation of TOH. The pain manifests as disabling pain that occurs suddenly with no prior history of trauma, infective episodes, steroid therapy, or alcohol abuse [5, 10, 11]. Patients will typically refuse to bear weight or require the use of assistive devices to ambulate, such as canes or crutches [13]. The pain is localized to the buttock, groin, greater trochanter, or anterior part of the thigh. The pain increases with weight bearing. Walking without support is commonly difficult or impossible. Rest and non-weight-bearing relieves the pain.

On physical examination active range of motion is generally limited by pain [13]. Passive range of motion is typically preserved but provokes pain at end range [5, 11, 19, 21]. Provocative hip maneuvers such as: log roll test, flexion adduction internal rotation (FADIR), active straight leg raise, anterior–posterior glide, single-leg stance, and single-leg hop can reproduce pain.

The clinical course of TOH is typically self-limited, and radiographic findings return to normal in 3–6 months after delivery. Recurrence of TOH with multiple pregnancies in the same patient has been reported [22]. The course may be complicated by insufficiency fractures. Femoral neck fractures are the most common pathological fracture and are often caused by a low-energy trauma [5, 6, 11, 18, 21]. Stress fractures are classified as either compression or tension fractures. Compression fractures occur on the inferior aspect of the femoral neck and treatment includes a period of protected weight bearing. Tension fractures occur on the superior aspect

of the femoral neck, causing a transverse fracture across the femoral neck. Tension-sided fractures are considered high-risk due to their tendency to displace to complete fracture, which results in increased risk of AVN and often require surgical management.

Diagnostics

Magnetic resonance imaging (MRI) is the best noninvasive investigative tool to diagnose TOP. Abnormalities on MRI have been reported within 48 h after the onset of symptoms. In the case of TOH, MRI reveals low-signal intensity of bone marrow on T1-weighted images, and high-signal intensity of bone marrow on T2-weighted images suggestive of bone marrow edema (Fig. 8.1). The bone marrow edema usually involves the femoral head, neck, and sometimes the intertrochanteric area, and a small joint effusion is invariably present [6, 16, 23]. The detection of bone marrow edema is important because of its diagnostic and prognostic value. It occurs in

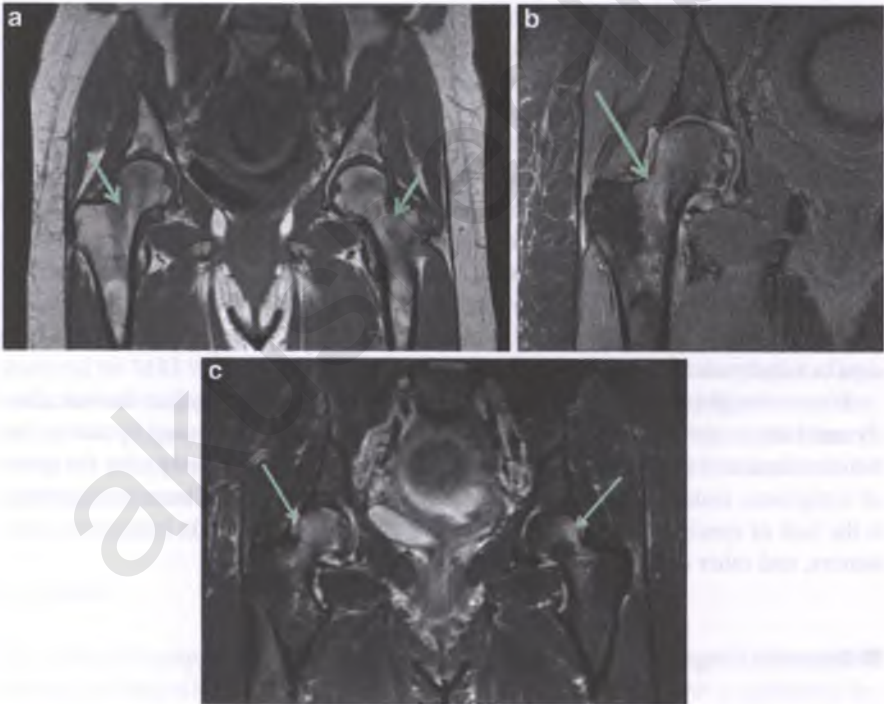


Fig. 8.1 A 39-year-old G1P0 female at 37 weeks with right TOH. (a) Coronal T1-weighted image with low signal intensity of the femoral head and neck, greater on the right than left. (b) Coronal T2-weighted image with notable increased signal intensity localized to the femoral head and neck. (c) Coronal short tau inversion recovery (STIR) with high signal intensity of the femoral head and neck, right greater than left

isolation and is often reversible. An MRI uses strong magnetic fields and radio waves to produce cross-sectional images of organs and internal structures in the body, and does not use ionizing radiation; therefore, it is recommended for the diagnosis of TOP in pregnant women. Diffusion-weighted MRI allows quantification of marrow edema and could be more sensitive than conventional MRI to detect inflammation [20]. Long-term follow-up of TOP can be achieved by the use of MRI because the abnormalities on serial scans normalize after approximately 6–9 months.

Plain radiographs, bone density scans, and bone scintigraphy all involve radiation. In the pregnant population with suspected TOP this can pose an unwarranted risk to the fetus for birth defects and childhood cancers and should be avoided. However, they can be used for diagnosis in the postpartum period. Bone mineral density (BMD) has been used for the quantification of bone demineralization and for long-term evaluation of TOP in the postpartum period. Three factors predict fracture risk: the rate of bone loss of the femoral neck, the baseline BMD at the femoral neck, and advancing age [20]. The period for risk of pathological fractures is when there is high rate of bone loss and when the BMD is at its lowest. For this reason, non-weight-bearing is advised [24]. Bone loss during pregnancy appears to be regained over 12–24 months postpartum [20]. Bone density scans use beams of very low-energy radiation to determine the density of the bone, about one-tenth of the radiation dose from a chest X-ray. Regardless, bone density scans are not advised during pregnancy, however it is useful during the postpartum period if symptoms persist with conservative management.

In the nonpregnant patient with transient osteoporosis, plain radiographs are normal initially and evidence of osteopenia may appear later. Radiographic changes are not evident until 4–8 weeks after the onset of symptoms [15, 21]. In TOH, osteopenia of the femoral head and neck may progress to complete effacement of the subchondral cortex of the femoral head, to near total disappearance of the osseous architecture. Rarely the trochanters, acetabula, iliac wings, and ischiopubic rami may be affected. The joint space is always preserved, and at no time is osseous erosion or subchondral collapse observed [7].

Bone scintigraphy uses an injection of radioactive dye to visualize the vascularity and bone turnover. In TOH, this would show an intense increased uptake in the femoral head and neck extending to the intertrochanteric line shortly after the onset of symptoms, usually within 48 h [10, 21]. The disadvantage of bone scintigraphy is the lack of specificity. The increased tracer uptake is also seen in infections, bone tumors, and other conditions with high bone turnover [15].

Differential Diagnosis

The diagnosis of TOP is usually made based on history, examination, and imaging studies. The differential diagnosis is wide and includes: pubis symphysiolysis (pubic symphysis separation), septic arthritis, synovial disorders, primary or metastatic malignancy, stress fracture of femoral neck, lumbosacral radiculopathy, reflex sympathetic dystrophy (RSD), regional migratory osteoporosis (RMO), hip labral

tear, hip osteoarthritis and AVN [8, 21]. Usually it is not difficult to differentiate between TOH and the other mentioned conditions, except for early AVN. Pubic symphysiolysis can easily be diagnosed with a plain film that demonstrates loosening of the pelvic joints with separation of the symphysis. Laboratory tests can help differentiate between an infectious process and rheumatologic cause of hip pain. MRI can differentiate between occult stress fractures of the femoral head and TOH. Clinical features unique to RSD that are not usually present in TOH include a history of previous trauma, burning pain associated with muscle spasms, cutaneous trophic features, and disease chronicity. Historically TOH has been thought of as a variant of RMO. However, key differences are the migratory nature and the predilection for lower limb regions, with the ankle, foot, and knee being the most commonly affected joints in RMO [22].

In the early stages of the disease, TOH is both clinically and radiologically indistinguishable from AVN. While the cause of TOH is unknown, AVN results from ischemic injury to bone and marrow tissues. It has been suggested that TOH may represent the early reversible phase of AVN [22]. The differentiation between transient osteoporosis and AVN is essential for prognosis and avoidance of surgical decompression or arthroplasty [18]. The clinical presentation and imaging studies may help differentiate the two. The pattern of pain in TOH is sudden onset, induced by weight bearing, and relieved by rest. In AVN the pain characteristics are insidious in onset, continuous at rest, and gradually increase without spontaneous recovery [8]. Radiological distinction between TOH and AVN is potentially achievable. There is subchondral collapse of the femoral heads on X-ray in the case of severe AVN. On bone scintigraphy of AVN, the tracer uptake is less intense and typically limited to the femoral head. Occasionally there is decreased uptake over the antero-superior region of the femoral head, forming a photopenic area, or cold spot, and a low femoral head/reference area ratio that is pathognomonic for AVN [18]. In contrast, the diagnosis of TOH can be made with evidence of osteopenia on plain film and diffusely increased tracer uptake on bone scintigraphy. Bone marrow edema is observed on MRI in both TOH and AVN. Since this is the main radiographic diagnostic tool during pregnancy, these two diseases are difficult to differentiate from each other. Diagnosis of TOH may only be achieved retrospectively as the natural course of the disease proceeds. Therefore, invasive surgical treatment should be postponed unless significant fractures occur [6, 7, 22, 25].

Treatment

The goals of therapy in TOP are prompt relief of pain and acceleration of functional recovery of the affected joint. Conservative management of TOP is preferred by restricting weight-bearing on the affected limb, usually with the aid of crutches. Although rare, women with bilateral TOP will require total non-weight-bearing of both lower extremities with the use of a wheelchair for mobility for 4–8 weeks. Pregnancy limits the choices of pharmacotherapy; however, most women will start to feel better once they are made non-weight-bearing in the affected limb.

The severe acute pain from TOP should be managed appropriately in pregnancy with analgesic medications (see also Chap. 14). Acetaminophen, an analgesic and antipyretic, can be used safely in the pregnant population with mild pain. Opioids such as codeine, oxycodone, hydromorphone, hydrocodone, and morphine can safely be used to treat moderate-to-severe pain in this population. Nonsteroidal anti-inflammatory drugs (NSAIDs) are inhibitors of cyclooxygenase, a potent dilator of the ductus arteriosus and pulmonary resistance vessels in the fetus. NSAIDs are contraindicated in pregnancy since they are associated with severe adverse neonatal outcomes including: premature heart valve closure, pulmonary hypertension, congenital heart defects, intracranial hemorrhages, renal toxicity, and orofacial clefts.

The use of intra-articular and systemic corticosteroids in the treatment of TOP has not been associated with a significant reduction in the duration of the illness. Deltacortisone in a dose of 30 mg/day for 4 months and prednisone in doses up to 40 mg/day showed no benefit in changing the natural history of the disease. Intra-articular steroids showed similar lack of efficacy. Only the bone-sparing steroid, deflazacort, administered in a dose of 60 mg orally for 1 week and tapered over 1 month, was effective with complete recovery in 2–4 weeks after initiating treatment [7, 13, 26]. Short-term use of steroids during pregnancy is safe and can decrease pain significantly; however, it will not alter the duration of recovery.

Antiresorptive agents, bisphosphonates, and calcitonin, have shown beneficial effects in the treatment of TOP in reducing the length of symptoms, duration of the disease, and have a positive effect on BMD. The mode of action of antiresorptive agents in TOH is unknown. Bisphosphonates (pamidronate, alendronate, and clodronate) have been shown in case series to reduce the duration of TOP. Three doses of intravenous pamidronate (45 mg) in 15 patients with TOH led to complete resolution of symptoms in 2 months and normalization of the MRI in 3 months [27]. Alendronate (10 mg/day) provided dramatic relief of joint pain and accelerated functional recovery in one reported case [26]. Intravenous clodronate (30 mg/day for 10 days) led to complete recovery in three patients after 8–16 weeks [28]. There is a potential risk of bisphosphonate use in pregnancy, as it has been shown that it can cross the placental barrier when administered to animals at doses 10–35 times the human dose and may lead to skeletal abnormalities. However, all of these pharmaceutical studies had small sample sizes and lacked case-controls. Thus, the potential benefits of these agents should be weighed against the risks involved [7]. Bisphosphonates are more commonly used during the postpartum period, but not while the mother is breastfeeding. There are limited studies looking at the absorption of bisphosphonates by an infant via breast milk; therefore, generally it is not recommended in nursing mothers.

Calcitonin use was reported in two patients with TOH during pregnancy at a dose of 1,000 IU subcutaneously twice a day in one case, and 200 IU nasal puffs per day in the other. Three weeks after the start of calcitonin therapy, both patients showed 50–70 % improvement in both symptoms and range of motion [13]. Calcitonin can be a safe therapeutic medicine in the pregnant population, as it does not cross the placental barrier. Calcitonin has been reported to alleviate pain, but failed to prevent new attacks [18].

Surgical core decompression has been performed to eliminate the risk of progression to full osteonecrosis, to relieve pain, and to reduce symptom duration. However, this procedure seems unnecessarily aggressive for a condition that is self-limited and has a good prognosis without operative intervention. Sympathectomy and a sympathetic nerve blockade appeared to provide pain relief, but did not accelerate recovery [13]. In general, operative and invasive intervention is not recommended for TOP.

To minimize the risk of fracture, pregnant patients are instructed to avoid full weight bearing on the affected side. They are instructed to use analgesia for pain. Once symptoms subside and bone mineralization begins to improve, they are encouraged to undertake low-impact exercises such as swimming until delivery [19, 22]. Prolonged non-weight-bearing will lead to muscle atrophy in these patients; therefore, conditioning and strengthening exercises that do not provoke pain are an important component of conservative treatment. Cesarean section is preferable to vaginal delivery to avoid the risk of further trauma to the demineralized bone. Ultimately, the outcome of TOP is usually excellent in the majority of cases and it takes about 12–24 months for complete remission [6, 9, 11, 18]. If a true fracture occurs, surgery should be considered, followed by an early rehabilitation program [11].

Greater Trochanteric Pain Syndrome

Introduction

Greater trochanteric pain syndrome (GTPS) is a spectrum disorder that encompasses any pain overlying the lateral aspect of the hip, located at or around the greater trochanter (GT). Historically most patients with the combination of lateral hip pain and tenderness have been classified as having trochanteric bursitis. GT bursitis was first described by Stegemann in 1923 and refers to inflammation of the subgluteus maximus bursa located immediately beneath the iliotibial band at the point of insertion of the gluteus medius tendon [29]. In 1958, Leonard proposed the phrase “trochanteric syndrome,” reflecting the spectrum of possible causes for pain localized to the GT [30–33]. GTPS has since become the preferred terminology for pain and reproducible tenderness in the region of the GT, buttock, or lateral thigh. It is now recognized that the pain in this region can originate not only from more than just bursal inflammation but also from tendinopathies or partial-/full-thickness tears of gluteal tendons.

Epidemiology

Although reports on the incidence of GTPS vary depending on the population studied, GTPS is common. In one primary care study, the incidence of GTPS was reported to be approximately 1.8 patients per 1,000 per year [34]. Most reports show an increased prevalence in women compared to men [35]. Back pain may be a risk factor for GTPS. Several studies report an increased incidence of GTPS in patients with musculoskeletal low back pain ranging from 20 to 35 % [36–38].

Anatomy

The GT is a large quadrilateral process that arises from the junction of the femoral neck and the lateral aspect of the upper shaft of the femur. The GT is the site of attachment for five muscles: the gluteus medius and gluteus minimus tendons laterally and the piriformis, obturator externus, and obturator internus posteriorly.

The fluid-filled sacs that provide glide between the bony prominences and the surrounding soft tissues are known as bursae. Commonly implicated in the etiology of lateral hip pain, the trochanteric bursae are thought to cushion the gluteus tendons, iliotibial band, piriformis, and tensor fascia lata at the bony GT [32]. While both the anatomy and number of bursae described around the region of the GT are complex and somewhat controversial [30, 32, 39], two bursae are consistently present in most individuals: the subgluteus medius bursa and the subgluteus maximus bursa [40]. The subgluteus maximus bursa lies deep to the iliotibial band and between the gluteus medius tendon and the gluteus maximus muscle, while the subgluteus medius bursa is found deep to the gluteus medius tendon [30, 41]. The subgluteus maximus bursa is the largest and often the culprit of “trochanteric bursitis” [42]. The inconsistent number of bursae, together with their variable locations, adds to the spectrum of clinical presentation and the reported variable response to injection therapy.

Etiology and Pathophysiology

Many risk factors have been associated with GTPS, including age older than 40 years, female gender, knee or hip osteoarthritis, obesity, low back pain, and iliotibial band tightness or contracture [30, 32]. No specific studies have looked at the incidence in pregnancy, though there is a clear gender predominance that cannot be ignored. The reason for increased prevalence in women is unclear, but may be attributed to altered biomechanics associated with pelvic anatomy or physiology (hormonal effects on bursal irritation or pain generators), both of which are clearly present during pregnancy [30, 32, 35].

Tendinopathy and Tears

While GTPS can develop from several processes, the most commonly reported primary pathology of GTPS is hip abductor tendinopathy, principally of the gluteus medius and gluteus minimus tendons, with trochanteric bursitis more likely a secondary and reactive response [29, 41–43]. The reported incidence of gluteus medius tears far exceeds that of those involving the gluteus minimus [43, 44]. Tears of the tendon insertions can be interstitial, partial thickness or full thickness [44–46]. Additionally, gluteal tendinopathy is almost four times more common in females than males [29, 44, 46]. Although the true prevalence of gluteus medius and minimus tears and tendinopathy are not known, studies have suggested that tears occur in up to 25 % of late middle-aged women and 10 % of similarly aged men [47].

The tendinopathy encountered in GTPS can be secondary to acute direct injury (trauma), overuse (chronic microtrauma), intrinsic degenerative, or tension from the ITB [32, 41, 43, 44]. Macrotrauma, whether direct or caused by hyperadductive stress, has been reported to lead to tendon strains and tears [32, 43]. It is widely believed that the development of tendinopathy results from repetitive microtrauma. Connell et al. found that the histologic changes observed in the gluteal tendons were similar to those observed in other tendons prone to intrinsic degeneration, such as lateral elbow [48], Achilles [49] and rotator cuff [50]. The insertion of the tendons of the gluteus medius and minimus on the GT has been equated to the insertion of the rotator-cuff tendons on the greater tuberosity of the humerus [32, 51]. These muscles can be considered the “rotator cuff of the hip.”

Clinical Presentation

GTPS classically presents as chronic, persistent, lateral hip pain in the region of the GT or peritrochanteric soft tissues, which may radiate to the buttock, groin, or low back. The onset of symptoms may be acute or insidious and is often described as related to physical activity. Symptoms may be exacerbated by lying on the affected side, prolonged standing, repetitive hip flexion-extension activities (such as walking or running), leg crossing, transitioning from a sitting to standing position, or single-legged activities [30, 32, 40].

The physical examination of a patient with GTPS characteristically reveals point tenderness directly over or posterolateral to the GT. Lateral hip pain produced with active internal rotation, active external rotation, or resisted hip abduction, suggests gluteus medius, or gluteus minimus dysfunction [32]. A positive 30 s single-leg stance test, in which pain is reproduced while standing on the affected limb for 30 s, is 100 % sensitive and 97.3 % specific for gluteal tendinopathy [52]. The resisted external derotation test is 88 % sensitive and 97.3 % specific for gluteal tendinopathy when lateral hip pain is reproduced. It involves the examiner holding the hip in 90° of flexion and external rotation, while resisting the patient's attempts to bring the hip back to neutral rotation [52]. Additionally, a positive Trendelenburg or compensated Trendelenburg test can aid in detecting gluteus medius tendon tears, with 73 % sensitivity and 77 % specificity [29]. Symptoms associated with GTPS may also be reproduced by the FABER maneuver (passive hip flexion with abduction and external rotation). An examination of the lumbosacral spine and pelvis are indicated to exclude potential mimickers in the differential diagnosis. Though these tests have not been specifically validated in the pregnant/postpartum state, there may be relevance for their clinical utility in this population.

Diagnostics

Typically the diagnosis of GTPS can be made on the basis of clinical history and physical examination, particularly in the case of pregnant women. However, if needed in postpartum women, diagnostic imaging may provide valuable clues to exclude other pathology or to evaluate cases of unresolved pain after initial treatment.

Plain film radiography is effective in assessing hip arthritis, AVN of the femoral head, neck of femur fractures, FAI, bony avulsions, and sacroiliac joint pathology. In GTPS, plain X-rays are typically negative, but trochanteric exostoses or osteophytes may be seen in long-standing cases. Calcifications, when present, are generally found at the insertion of the gluteus medius tendon at the greater trochanter or within the bursa [29, 40]. As in the shoulder, the amount of calcium observed may vary from a pea-sized to a dense accumulation several centimeters in diameter. The presence of calcific deposits about the hip joint is nonspecific and does not indicate a diagnosis of GTPS. Again analogous to the shoulder, such calcification may exist for undetermined periods without symptoms or functional impairment [40].

MRI provides high-resolution imaging of the complex peritrochanteric anatomy. MRI has the ability to evaluate direct signs (peritendinitis, tendinosis, and partial or complete tears) and indirect signs (bursal fluid, muscular fatty atrophy, bony changes or calcifications) of tendon pathology. MRI findings for partial- and full-thickness tears in the hip abductors are defined by the focal absence of intact tendon fibers and tendon discontinuity (or avulsed bone fragment), respectively [45]. Based on the criteria described by Kingzett-Taylor et al., tendinosis is diagnosed by the presence of thickening or increased intrasubstance T2 hyperintensity [45]. Peritendinitis is suggested when soft tissue edema surrounding intact tendon is seen on MRI. MRI should be sparingly used in pregnant women and should only be used to rule out more serious hip pathology (TOP, insufficiency stress fractures, AVN). It should not be ordered if a clinical diagnosis of GTPS can be made on history and examination.

Musculoskeletal ultrasonography (US) is emerging as an accurate, cost-effective, readily available, and easily applied imaging modality in musculoskeletal medicine. Similar to MRI, the gluteal anatomy is easily evaluated with US. Tendinopathy on US can be characterized by hypertrophy, heteroechoogenicity, neovascularization, disturbed tendon architecture, and possible calcifications [32, 53]. An enthesophyte, or bone spur, may be seen at the insertion of the tendon onto the bone. Partial-thickness and full-thickness tendon tears are seen, directly, as hypoechoic or anechoic foci or, indirectly, as contour defects, through transmission enhancement, or edge artifacts [32]. Bursal effusions are seen as large anechoic collections. Compared to MRI, sonography has superior spatial resolution and therefore may be more sensitive for identifying focal areas of degeneration, macroscopic partial tears, foci of calcification and bony irregularity [44]. Muscle wasting with fatty infiltration and bursal fluid accumulation can also be appreciated on US. Additionally, US can guide fluid aspiration and therapeutic injection of corticosteroid if necessary. It is the ideal diagnostic modality for pregnant women.

Treatment

Most cases of GTPS are self-limiting and typically resolve with conservative measures [30, 54]. The initial treatment of GTPS involves conservative modalities which include: topical ice or heat (to decrease pain and facilitate physical exercise); physical therapy (to promote muscle strengthening and improve joint mechanics); and correction of any underlying gait disturbances (i.e., orthotics, shoe lift) [54].

The true efficacy of these conservative treatments has not been reported in controlled studies [41]. While NSAIDs are commonly used in the general population with GTPS, it is not recommended for pregnant women with GTPS.

When conservative interventions fail, local anesthetic and corticosteroid bursa injections have been shown to provide good symptom relief with response rates ranging from 60 to 100 % in older studies [40, 55]. Now that it is known that GTPS is not always an inflammatory issue, the utility of GT bursa injections has been called into question. Although studies continue to conclude that corticosteroid injections into the GT bursa improve pain [56], a recent systematic review of GTPS management concluded that option management remains unclear [57]. In pregnant women, it is advised to try noninvasive management strategies first and pursue injections only if the pain is recalcitrant to these methods, preferably in the postpartum period.

Intra-articular Hip Pain

The term “prearthritic hip disorders” has emerged since the early 2000s as a way to encompass the variety of intra-articular hip disorders demonstrating abnormalities of the articular surfaces of the acetabulum and femur before the onset of osteoarthritis. Prearthritic hip disorders are associated with “young hips”; therefore, they are a part of the spectrum of hip disorders in pregnant/postpartum women. As a group, they are often overlooked by multiple providers. The average time to diagnosis of femoroacetabular impingement (FAI), developmental dysplasia of the hip (DDH), and hip labral tears, respectively, are 3.1, 5.1, and 1.75 years with reports of 4.5, 3.3, and 3.3 “healthcare providers seen” prior to the correct diagnosis [58–60]. Although it is important to note that becoming pregnant does not increase your risk of developing a prearthritic hip disorder, it is equally important to not dismiss the possibility of intra-articular hip pain in this population of childbearing women.

Femoroacetabular Impingement

Introduction

FAI is a bony hip deformity or spatial malorientation of the femoral head, femoral head/neck junction, acetabulum, or both [61]. The bony deformity causes limited hip range of motion and is often associated with hip girdle pain. FAI was first described in the literature in 1999 [62], but drew significant attention in 2003, when it was first implicated as a cause of hip osteoarthritis [63]. Advancements in imaging modalities have led to increased identification of FAI in the younger population. There are three types of FAI: cam deformity, pincer deformity, or mixed deformity [61, 63]. The cam deformity presents as femoral head asphericity at the femoral head–neck junction. The pincer deformity is characterized by overcoverage of the femoral head by the acetabulum. The mixed deformity is a combination of the cam and pincer deformities.

Epidemiology

Reports of FAI in an asymptomatic population vary from 14 to 35 % [64–66]. Radiographic evidence of at least one sign of FAI can be seen in 87 % of young patients (18–50 years old) complaining of hip pain [67]. There are sex differences in the prevalence of FAI. A population-based survey in Denmark found the prevalence of pincer deformities to be 19.4 % in women and 15.2 % in men, while the prevalence of cam deformities was 5.2 % in women and 19.6 % in men. Mixed deformities were even less prevalent in women (0.9 %) than men (2.9 %) in the general population of Denmark [68].

Clinical Implications of FAI

The bony deformity of the hip in FAI causes an irregular contact between the femoral head/neck junction and the acetabular rim at end range of hip motion [69]. Patients with FAI are typically limited in hip flexion and internal rotation. It is widely believed that repetitive contact of the femoral head/neck against the acetabulum leads to tearing at the chondrolabral junction, which could progress to cartilage delamination and eventually osteoarthritis [63, 70, 71]. In both cam and pincer deformities, the most common location of chondral or labral damage is in the anterior/superior acetabulum [72].

Presentation

Hip pain from FAI is classically described in the anterior groin, however individuals with FAI also present with anterior thigh, knee, buttock, posterior thigh, low back, and lateral thigh pain as well [58]. Often there is more than one location of pain on presentation. Absence of groin pain does not automatically exclude FAI: at least 12 % of individuals with FAI present without any groin pain [58].

Women with FAI pain are more likely to present postpartum after vaginal delivery. Vaginal delivery, which often requires aggressive hip flexion ($>90^\circ$), or prolonged stage two labor can lead to repetitive or sustained impingement of the hip. Women that receive epidural anesthesia for labor pain are at increased risk of impingement as they are unable to sense pain from prolonged hip flexion until after the epidural effects wear off post-delivery. FAI pain can also present during the third trimester of pregnancy. The redistribution of the center of mass along with increased joint laxity as a result of hormone fluctuations can cause biomechanical alterations aggravating the hips. The onset of painful FAI during pregnancy would be slow and insidious in the absence of trauma or falls. The pain is usually intermittent and is exacerbated by physical activities, particularly ones that involve repetitive hip flexion or internal rotation. Prolonged sitting in a low chair that promotes hip flexion can also exacerbate the pain.

Diagnostics

Physical examination is the first line for diagnosis of FAI. Women with painful FAI have limited hip flexion and internal rotation. Pain can be reproduced with: FADIR maneuver, flexion abduction external rotation (FABER) maneuver, log roll of the leg, hip scour, single-leg hop, resisted active straight leg raise (Stinchfield's maneuver), or single-leg stance. Severe cases of painful FAI will present with an antalgic gait and a preference to keep the hip externally rotated in sitting, standing, and lying down.

Suspicion for FAI based on physical examination should then lead to radiographic imaging. X-ray, computed tomography (CT), and MRI have all been identified as a means to determine the presence of FAI and quantify the degree of deformity. However, in pregnant women, X-ray and CT are not recommended due to the radiation exposure to the growing fetus. MRI of hips/pelvis could be done, however, usually it is not clinically warranted. Unless the patient has severe pain and there is concern for an insufficiency stress fracture, stress reaction, or AVN, diagnostic confirmation can usually wait until after delivery.

Treatment

Conservative management of FAI pain is warranted in pregnant/postpartum women. Physical therapy and education for behavior modification are the mainstays of conservative treatment. The role of physical therapy is to improve hip motion by strengthening: iliopsoas, gluteus maximums, gluteus medius, lateral hip rotators, and abdominals. There should be emphasis to: decrease anterior glide of the femur, prevent hip hyperextension, prevent rotation of acetabulum on femur under load, and prevent the dominance of quadriceps and hamstring muscles [73]. The simple act of teaching patients to avoid the positions of impingement, hip flexion, and internal rotation, can also reduce pain.

Surgical management of FAI in the peripartum woman is rare, unless there is severe pain not responsive to conservative management. Hip arthroscopy with femoral and/or acetabular osteotomy is currently the main surgical option for treatment.

Developmental Dysplasia of the Hip

Introduction

DDH is a spectrum disorder that encompasses congenital dislocation of the hip, hip subluxation, acetabular dysplasia, and malformation of the femoral head. It is one of the most common congenital malformations [74]. There is a screening process in infancy, and it can be treated with hip bracing early on, though many cases are not recognized at infancy and present later in life. This section will focus on the types of DDH seen in young women of childbearing age: acetabular dysplasia and femoral head asphericity. The most common sequela of DDH in this group is early hip osteoarthritis. DDH accounts for 29 % of total hip replacements in people under 60 years old [75].

Epidemiology

Although there are no reports of the prevalence of DDH in pregnant women, the prevalence of DDH is estimated to be 1.3 per 1,000 in the general population [76]. DDH has been found to be 2–3 times more common in women than men [77, 78]. DDH accounts for 20–40 % of all hip osteoarthritis [79, 80].

Clinical Implication of DDH

Acetabular dysplasia and femoral head asphericity is associated with excessive movement of the hip joint and decreased stability of the joint. This excessive motion is believed to repetitively load the joint abnormally and lead to degenerative changes early in life. In pregnancy, the hormone relaxin peaks at 12 weeks gestation and at delivery to induce pelvic laxity in preparation for the growing fetus and birth. The increased laxity of the hip joint, which already had excessive motion due to the nature of the DDH, can increase pain in the hip over the course of the pregnancy.

Presentation

Hip pain from DDH presents in the anterior groin, anterior thigh, knee, buttock, or lateral hip. These symptoms are often overlapping with 66 % of DDH patient complaining of groin pain, 28 % anterior thigh/knee pain, 64 % lateral hip pain, and 29 % buttock pain [59]. The pain is typically worse with activity, but also can be present at night and disrupt sleep. Running, standing, and walking are the most aggravating activities.

Pregnant women with DDH should be the most cautious around the time of delivery. Excessive range of motion of the hips coupled with increased joint laxity could predispose pregnant woman to be placed in extreme positions during the pushing stage of labor that would abnormally load the joint and precipitate pain or a potential hip labral tear. Particularly if epidural anesthesia is used during delivery, assistants to the delivery may place the hips in suboptimal positions when in the dorsal lithotomy position without the recognition of pain by the patient. As a result, first time hip pain from DDH most commonly occurs after delivery.

Diagnostics

In pregnant women, all attempts should be made to diagnose DDH using a thorough physical examination. Excessive hip range of motion is a common feature of DDH. There is often increased hip flexion, internal rotation, and external rotation secondary to the under-coverage of the femoral head by the acetabulum. Asymmetry of hip range of motion can also be an indicator of DDH. FADIR, FABER, log roll of the leg, hip scour, single-leg hop, Stinchfield's maneuver, or single-leg stance/hop have also been known to provoke DDH hip pain. Severe cases of DDH will manifest with an antalgic gait.

Treatment

Most women with moderate–severe DDH will require surgery on their hips, whether it is a peri-acetabular osteotomy (PAO), hip resurfacing, or a total hip arthroplasty (THA). However, conservative management can be employed prior to surgery to manage symptoms and prolong the time to surgery. In pregnant women, conservative management is the only option to minimize unnecessary risk to the fetus. Conservative management includes physical therapy, aquatherapy, rest, education on behavior modifications, and intra-articular corticosteroid injections. Physical therapy should be aimed at pelvic girdle strengthening exercises, including: gluteus medius, gluteus maximums, deep lateral hip rotators, iliopsoas, quadriceps, and hamstrings. Patients should avoid hip end range of motion to decrease the amount of loading on abnormal regions of the joint.

Hip Labral Tear

Introduction

The hip labrum is a fibrocartilaginous contiguous structure attached to the rim of the acetabulum [81]. It provides enhanced hip stability by acting as an extension of the acetabular edge over the femoral head and protects intra-articular cartilage. In effect, it acts as the seal of the hip joint, preserving the joint fluid within the space between the labrum and articular cartilage [81].

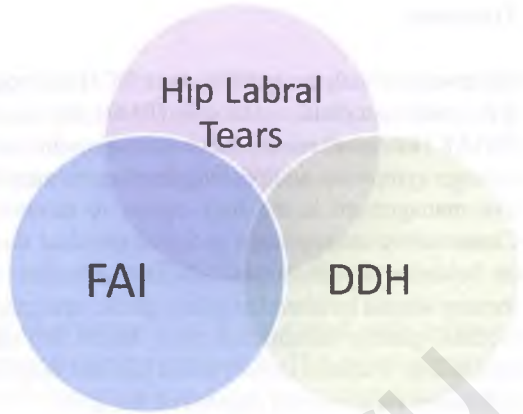
Epidemiology

Hip labral tears can exist in combination with bony deformities (FAI and DDH) or in isolation (Fig. 8.2). The association of hip labral tears with FAI is quite high. Nearly 87 % of patients with cam-type FAI are believed to have concomitant labral tear or cartilage lesion [82]. Also, there are reports that 48 % of labral tears have associated DDH [83]. Although there have been no large studies looking at the prevalence of hip labral tears in pregnant/postpartum women, there are case reports that detail this clinical problem specifically post-delivery [84, 85].

Clinical Implication of Hip Labral Tears

When the labrum is torn, it exposes the joint to abnormal loading and potential degeneration. There are varying degrees of hip labral pathology. Some minor labral tears are completely asymptomatic, while a complete labral detachment is typically severely painful. While there is no evidence that pregnancy is a risk factor for a hip labral tear, the altered biomechanics of the pelvis during pregnancy could theoretically predispose pregnant women to abnormal loading or shearing of the labrum.

Fig. 8.2 Intra-articular hip disorders: the intra-articular hip disorders can be found in isolation but more often overlap with each other



The labrum is at great risk of injury during vaginal delivery due to typical labor positions, which can involve: squatting, kneeling, and the dorsal lithotomy position with fully flexed and abducted hips when pushing. All these positions involve end-range hip flexion, which should be avoided with a known labral tear and minimized in patients with FAI or DDH.

Presentation

Hip pain from a labral tear is classically described in the anterior groin, presenting in 92 % of all hip labral tears confirmed by arthroscopy; however, individuals with FAI also present with anterior thigh, knee, buttock, and lateral hip pain as well [60]. Many times there is more than one location of pain on presentation.

Women will report pain aggravated with activity, particularly weight bearing, pivoting, and stairs. Prolonged sitting can also aggravate the pain depending on the location of the hip labral tear. Tears located in the anterior superior portion of the acetabulum will provoke pain when sitting with hip flexion $>90^\circ$. Oftentimes, women with hip labral tears will report mechanical symptoms, such as locking, popping, catching, or giving out. The most common provoking movement of these mechanical symptoms is going from a sitting to a standing position.

Women with a hip labral tear are most likely to present after a successful or attempted vaginal delivery. Typically there is insidious onset of pain, however some may describe a specific injury during delivery marked by a pop, twist, or sudden sharp pain. The mechanism of injury during delivery is typically a forceful flexion and internal rotation of the hip. Oftentimes an assistant (husband, relative, or health-care professional) during delivery will cause the excessive hip flexion or internal rotation in the heat of the moment. Women who have had epidural anesthesia are less likely to provide the proper feedback that the position is painful. Furthermore, for primigravida women or those attempting vaginal delivery for the first time, any type of pain or discomfort is believed to be a part of the normal birthing process; therefore, this type of hip pain is overlooked.

Diagnosics

As with the other intra-articular hip disorders, physical examination is the first line for diagnosis in a peripartum female. Pain will be provoked with hip range of motion. Depending on the location of the labral tear, the pain can be provoked with hip flexion, internal rotation, external rotation, or extension. Pain-provoking maneuvers include: FABER, FADIR, log roll, Stinchfield's, single-leg hop, deep squat, and single-leg stance. Women may also present with an antalgic gait depending on the severity of the labral tear.

X-rays can be performed in the postpartum female if there is suspicion for FAI or DDH, though they do not help distinguish the presence of a hip labral tear and should also be avoided in the pregnant female. Further diagnosis is needed in severe cases of unremitting pain in the postpartum female and includes a diagnostic hip injection. Reports of discovering intra-articular hip pathology on MRI in asymptomatic people are high, ranging from 58 to 69 % [86–88]. Given the potential for finding asymptomatic labral tears on MRI, current thought dictates that a diagnostic hip injection can help the clinician to decide if the patient truly has intra-articular hip pain before ordering diagnostic imaging [89–91]. These injections should be done in conjunction with a physical examination of the hip prior to and following installation of local anesthetic into the joint. It is recommended to use image-guidance for these injections. In peripartum women, ultrasound would be the safest form of image-guidance and has demonstrated excellent accuracy in confirming intra-articular hip pain [92]. A positive diagnostic injection demonstrates a significant reduction in self-reported pain as well as improvement in the physical examination hip provocative maneuvers. Once that is achieved, diagnostic MR imaging can be considered.

MR arthrograms of the hip are considered the gold standard for diagnosis of hip labral tears. Recently, however, with improvements in MR technology, some reports show that 3.0 Tesla (T) MRIs of the hips are demonstrating accuracy in detecting labral tears and chondral lesions that approaches the accuracy of MR arthrograms. A 1.5-T MRI of the hip is considered inferior to MR arthrogram in the evaluation of the labrum [93].

Treatment

Depending on the severity of the hip labral tear, conservative management should be tried initially. Physical therapy protocols for hip labral tears are similar to these for FAI, particularly due to the overlap of these two hip disorders. Education on the disorder and behavioral modifications to avoid pain-provoking positions should be taught to patients, particularly pregnant women who must rely on conservative management. Severe cases of hip labral tears in a pregnant patient can be managed acutely with non-weight-bearing until she delivers. Rest and analgesics should be used as needed. The efficacy of intra-articular corticosteroids has not been confirmed for labral tears. There is some concern over the chondrotoxicity of local anesthetics and corticosteroids administered intra-articularly, particularly in this young age group of peripartum women [94–100]. The risks and benefits of an intra-articular corticosteroid injection should be discussed with the patient prior to injection.

Hip Osteoarthritis and THA

Osteoarthritis (OA) of the hip is not a typical issue for women of childbearing age; however, there is a small subset of women in this population who have been diagnosed OA from DDH, osteonecrosis, juvenile inflammatory arthritis, and trauma that have already undergone a THA. Pain in the hip is common during pregnancy in women who already have preexisting OA or a THA. One of the greatest concerns of a young woman requiring a hip replacement is whether or not it will be safe for her to become pregnant and deliver a child. The largest study to date involves 343 young women with a THA and an average of 16 years follow-up. Forty-seven women became pregnant after their primary THA. Thirty of these women delivered vaginally and 17 women had a Cesarean section (C-section). Of the 17 women who had a C-section, only two reported that the selection of C-section was directly related to the THA. There were no immediate prosthetic complications, dislocations, fractures, or loosening during pregnancy or childbirth. Sixty percent of women reported hip pain during pregnancy. There was an overall 40 % risk of revision in the entire population of young women with THA; however, having a child after the THA did not increase the risk of revision [101]. Ultimately, multiple studies have confirmed that it is safe to become pregnant and have a vaginal delivery or C-section following a THA [101–104]. There is no increased risk of prosthetic failure requiring revision, but hip pain (likely extra-articular) may flare while pregnant.

References

1. Acien P, Sanchez del Campo F, Mayol MJ, Acien M. The female gubernaculum: role in the embryology and development of the genital tract and in the possible genesis of malformations. *Eur J Obstet Gynecol Reprod Biol.* 2011;159(2):426–32.
2. Tokue H, Tsushima Y, Endo K. Magnetic resonance imaging findings of extrapelvic endometriosis of the round ligament. *Jpn J Radiol.* 2009;27(1):45–7.
3. Khatri VP. Total abdominal hysterectomy. In: Khatri VP, editor. *Operative surgery manual.* Philadelphia: Saunders; 2003.
4. Gui B, Valentini AL, Ninivaggi V, Marino M, Iacobucci M, Bonomo L. Deep pelvic endometriosis: don't forget round ligaments. Review of anatomy, clinical characteristics, and MR imaging features. *Abdom Imaging.* 2014;39(3):622–32.
5. Willis-Owen CA, Daurka JS, Chen A, Lewis A. Bilateral femoral neck fractures due to transient osteoporosis of pregnancy: a case report. *Cases J.* 2008;1(1):120.
6. Bin Abdulhak AA, Ba-Mougadam FA, Al-Nakshabandi NA, Al-Tannir MA. Transient osteoporosis of the hip/bone marrow edema syndrome with soft tissue involvement: a case report. *Oman Med J.* 2011;26(5):353–5.
7. Diwanji SR, Cho YJ, Xin ZF, Yoon TR. Conservative treatment for transient osteoporosis of the hip in middle-aged women. *Singapore Med J.* 2008;49(1):e17–21.
8. Emami MJ, Abdollahpour HR, Kazemi AR, Vosoughi AR. Bilateral subcapital femoral neck fractures secondary to transient osteoporosis during pregnancy: a case report. *J Orthop Surg (Hong Kong).* 2012;20(2):260–2.
9. Uematsu N, Nakayama Y, Shirai Y, Tamai K, Hashiguchi H, Banzai Y. Transient osteoporosis of the hip during pregnancy. *J Nippon Med Sch (Nippon Ika Daigaku Zasshi).* 2000;67(6):459–63.

10. Kim YL, Nam KW, Yoo JJ, Hong SH, Kim HJ. CT evidence for subchondral trabecular injury of the femoral head in transient osteoporosis of the hip: a case report. *J Korean Med Sci.* 2010;25(1):192–5.
11. Spinarelli A, Patella V, Speciale D, Petrera M, Vittore D, Pesce V, et al. Hip fracture in a patient affected by transient osteoporosis of the femoral head during the last trimester of pregnancy. *Orthopedics.* 2009;32(5):365.
12. Curtiss Jr PH, Kincaid WE. Transitory demineralization of the hip in pregnancy. A report of three cases. *J Bone Joint Surg Am.* 1959;41-A:1327–33.
13. Arayssi TK, Tawbi HA, Usta IM, Hourani MH. Calcitonin in the treatment of transient osteoporosis of the hip. *Semin Arthritis Rheum.* 2003;32(6):388–97.
14. Beaulieu JG, Razzano CD, Levine RB. Transient osteoporosis of the hip in pregnancy. *Clin Orthop Relat Res.* 1976;115:165–8.
15. Hockings M, Surwaliwala KH. Hip pain in the third trimester of pregnancy. *Hosp Med.* 1999;60(11):836–7.
16. Ververidis AN, Drosos GI, Kazakos KJ, Xarchas KC, Verettas DA. Bilateral transient bone marrow edema or transient osteoporosis of the knee in pregnancy. *Knee Surg Sports Traumatol Arthrosc.* 2009;17(9):1061–4.
17. Ribera Zabalbeascoa J, Santos Rodas A, Mella Sousa M, Uceda Carrascosa P, Benito CM. Transient osteoporosis of the hip. *Int Orthop.* 1999;23(4):244–6.
18. Rozenbaum M, Boulman N, Rimar D, Kaly L, Rosner I, Slobodin G. Uncommon transient osteoporosis of pregnancy at multiple sites associated with cytomegalovirus infection: is there a link? *Isr Med Assoc J.* 2011;13(11):709–11.
19. Daniel RS, Farrar EK, Norton HR, Nussbaum AI. Bilateral transient osteoporosis of the talus in pregnancy. *Osteoporos Int.* 2009;20(11):1973–5.
20. Kalkwarf HJ, Specker BL. Bone mineral changes during pregnancy and lactation. *Endocrine.* 2002;17(1):49–53.
21. Fokter SK, Vengust V. Displaced subcapital fracture of the hip in transient osteoporosis of pregnancy. A case report. *Int Orthop.* 1997;21(3):201–3.
22. Rajak R, Camilleri J. An unusual cause of hip pain. *BMJ Case Rep.* 2011;2011.
23. Takatori Y, Kokubo T, Ninomiya S, Nakamura T, Okutsu I, Kamogawa M. Transient osteoporosis of the hip. Magnetic resonance imaging. *Clin Orthop Relat Res.* 1991;271:190–4.
24. Niimi R, Sudo A, Hasegawa M, Fukuda A, Uchida A. Changes in bone mineral density in transient osteoporosis of the hip. *J Bone Joint Surg.* 2006;88(11):1438–40.
25. Steib-Furno S, Luc M, Pham T, Armingeat T, Porcu G, Gamarre M, et al. Pregnancy-related hip diseases: incidence and diagnoses. *Joint Bone Spine.* 2007;74(4):373–8.
26. Samdani A, Lachmann E, Nagler W. Transient osteoporosis of the hip during pregnancy: a case report. *Am J Phys Med Rehabil.* 1998;77(2):153–6.
27. Varenna M, Zucchi F, Binelli L, Failoni S, Gallazzi M, Sinigaglia L. Intravenous pamidronate in the treatment of transient osteoporosis of the hip. *Bone.* 2002;31(1):96–101.
28. Varenna M, Sinigaglia L, Binelli L, Beltrametti P, Gallazzi M. Transient osteoporosis of the hip: a densitometric study. *Clin Rheumatol.* 1996;15(2):169–73.
29. Bird PA, Oakley SP, Shnier R, Kirkham BW. Prospective evaluation of magnetic resonance imaging and physical examination findings in patients with greater trochanteric pain syndrome. *Arthritis Rheum.* 2001;44(9):2138–45.
30. Williams BS, Cohen SP. Greater trochanteric pain syndrome: a review of anatomy, diagnosis and treatment. *Anesth Analg.* 2009;108(5):1662–70.
31. Leonard MH. Trochanteric syndrome; calcareous and noncalcareous tendonitis and bursitis about the trochanter major. *JAMA.* 1958;168(2):175–7.
32. Ho GW, Howard TM. Greater trochanteric pain syndrome: more than bursitis and iliotibial tract friction. *Curr Sports Med Rep.* 2012;11(5):232–8.
33. Genth B, Von Doring M, Von Engelhardt LV, Ludwig J, Teske W, Von Schulze-Pellengahr C. Analysis of the sensory innervations of the greater trochanter for improving the treatment of greater trochanteric pain syndrome. *Clin Anat.* 2012;25(8):1080–6.
34. Lievense A, Bierma-Zeinstra S, Schouten B, Bohnen A, Verhaar J, Koes B. Prognosis of trochanteric pain in primary care. *Br J Gen Pract.* 2005;55(512):199–204.

35. Segal NA, Felson DT, Torner JC, Zhu Y, Curtis JR, Niu J, et al. Greater trochanteric pain syndrome: epidemiology and associated factors. *Arch Phys Med Rehabil.* 2007;88(8):988–92.
36. Collee G, Dijkmans BA, Vandenbroucke JP, Rozing PM, Cats A. A clinical epidemiological study in low back pain. Description of two clinical syndromes. *Br J Rheumatol.* 1990;29(5):354–7.
37. Tortolani PJ, Carbone JJ, Quartararo LG. Greater trochanteric pain syndrome in patients referred to orthopedic spine specialists. *Spine J.* 2002;2(4):251–4.
38. Swezey RL. Pseudo-radiculopathy in subacute trochanteric bursitis of the subgluteus maximus bursa. *Arch Phys Med Rehabil.* 1976;57(8):387–90.
39. Woodley SJ, Mercer SR, Nicholson HD. Morphology of the bursae associated with the greater trochanter of the femur. *J Bone Joint Surg Am.* 2008;90(2):284–94.
40. Gordon EJ. Trochanteric bursitis and tendinitis. *Clin Orthop.* 1961;20:193–202.
41. Hugo D, De Jongh H. Greater trochanteric pain syndrome. *SA Orthop J.* 2012;11(1):28–33.
42. Strauss EJ, Nho SJ, Kelly BT. Greater trochanteric pain syndrome. *Sports Med Arthrosc.* 2010;18(2):113–9.
43. Kingzett-Taylor A, Tirman PF, Feller J, McGann W, Prieto V, Wischer T, et al. Tendinosis and tears of gluteus medius and minimus muscles as a cause of hip pain: MR imaging findings. *AJR Am J Roentgenol.* 1999;173(4):1123–6.
44. Connell DA, Bass C, Sykes CA, Young D, Edwards E. Sonographic evaluation of gluteus medius and minimus tendinopathy. *Eur Radiol.* 2003;13(6):1339–47.
45. Kong A, Van der Vliet A, Zadow S. MRI and US of gluteal tendinopathy in greater trochanteric pain syndrome. *Eur Radiol.* 2007;17(7):1772–83.
46. Bunker TD, Esler CN, Leach WJ. Rotator-cuff tear of the hip. *J Bone Joint Surg.* 1997;79(4):618–20.
47. Robertson WJ, Gardner MJ, Barker JU, Boraiah S, Lorch DG, Kelly BT. Anatomy and dimensions of the gluteus medius tendon insertion. *Arthroscopy.* 2008;24(2):130–6.
48. Kraushaar BS, Nirschl RP. Tendinosis of the elbow (tennis elbow). Clinical features and findings of histological, immunohistochemical, and electron microscopy studies. *J Bone Joint Surg Am.* 1999;81(2):259–78.
49. Astrom M, Rausing A. Chronic Achilles tendinopathy. A survey of surgical and histopathologic findings. *Clin Orthop Relat Res.* 1995;316:151–64.
50. Sano H, Ishii H, Trudel G, Uthoff HK. Histologic evidence of degeneration at the insertion of 3 rotator cuff tendons: a comparative study with human cadaveric shoulders. *J Shoulder Elbow Surg.* 1999;8(6):574–9.
51. Voos JE, Shindle MK, Pruett A, Asnis PD, Kelly BT. Endoscopic repair of gluteus medius tendon tears of the hip. *Am J Sports Med.* 2009;37(4):743–7.
52. Lequesne M, Mathieu P, Vuillemin-Bodaghi V, Bard H, Djan P. Gluteal tendinopathy in refractory greater trochanter pain syndrome: diagnostic value of two clinical tests. *Arthritis Rheum.* 2008;59(2):241–6.
53. Nazarian LN. Musculoskeletal ultrasound: applications in the hip. *J Dance Med Sci.* 2011;15(4):173–6.
54. Wilson JJ, Furukawa M. Evaluation of the patient with hip pain. *Am Fam Physician.* 2014;89(1):27–34.
55. Shbeeb MI, Matteson EL. Trochanteric bursitis (greater trochanter pain syndrome). *Mayo Clin Proc.* 1996;71(6):565–9.
56. Lustenberger DP, Ng VY, Best TM, Ellis TJ. Efficacy of treatment of trochanteric bursitis: a systematic review. *Clin J Sport Med.* 2011;21(5):447–53.
57. Del Buono A, Papalia R, Khanduja V, Denaro V, Maffulli N. Management of the greater trochanteric pain syndrome: a systematic review. *Br Med Bull.* 2012;102:115–31.
58. Clohisy JC, Knaus ER, Hunt DM, Leshner JM, Harris-Hayes M, Prather H. Clinical presentation of patients with symptomatic anterior hip impingement. *Clin Orthop Relat Res.* 2009;467(3):638–44.
59. Nunley RM, Prather H, Hunt D, Schoenecker PL, Clohisy JC. Clinical presentation of symptomatic acetabular dysplasia in skeletally mature patients. *J Bone Joint Surg Am.* 2011;93 Suppl 2:17–21.

60. Burnett RS, Della Rocca GJ, Prather H, Curry M, Maloney WJ, Clohisey JC. Clinical presentation of patients with tears of the acetabular labrum. *J Bone Joint Surg Am.* 2006;88(7):1448–57.
61. Leunig M, Beaulé PE, Ganz R. The concept of femoroacetabular impingement: current status and future perspectives. *Clin Orthop Relat Res.* 2009;467(3):616–22.
62. Myers SR, Eijer H, Ganz R. Anterior femoroacetabular impingement after periacetabular osteotomy. *Clin Orthop Relat Res.* 1999;363:93–9.
63. Ganz R, Parvizi J, Beck M, Leunig M, Notzli H, Siebenrock KA. Femoroacetabular impingement: a cause for osteoarthritis of the hip. *Clin Orthop Relat Res.* 2003;417:112–20.
64. Laborie LB, Lehmann TG, Engesaeter IO, Eastwood DM, Engesaeter LB, Rosendahl K. Prevalence of radiographic findings thought to be associated with femoroacetabular impingement in a population-based cohort of 2081 healthy young adults. *Radiology.* 2011;260(2):494–502.
65. Hack K, Di Primio G, Rakhra K, Beaulé PE. Prevalence of cam-type femoroacetabular impingement morphology in asymptomatic volunteers. *J Bone Joint Surg Am.* 2010;92(14):2436–44.
66. Reichenbach S, Juni P, Werlen S, Nuesch E, Pfirrmann CW, Trelle S, et al. Prevalence of cam-type deformity on hip magnetic resonance imaging in young males: a cross-sectional study. *Arthritis Care Res.* 2010;62(9):1319–27.
67. Ochoa LM, Dawson L, Patzkowski JC, Hsu JR. Radiographic prevalence of femoroacetabular impingement in a young population with hip complaints is high. *Clin Orthop Relat Res.* 2010;468(10):2710–4.
68. Gosvig KK, Jacobsen S, Sonne-Holm S, Palm H, Troelsen A. Prevalence of malformations of the hip joint and their relationship to sex, groin pain, and risk of osteoarthritis: a population-based survey. *J Bone Joint Surg Am.* 2010;92(5):1162–9.
69. Standaert CJ, Manner PA, Herring SA. Expert opinion and controversies in musculoskeletal and sports medicine: femoroacetabular impingement. *Arch Phys Med Rehabil.* 2008;89(5):890–3.
70. Jaber FM, Parvizi J. Hip pain in young adults: femoroacetabular impingement. *J Arthroplasty.* 2007;22(7 Suppl 3):37–42.
71. Jager M, Wild A, Westhoff B, Krauspe R. Femoroacetabular impingement caused by a femoral osseous head-neck bump deformity: clinical, radiological, and experimental results. *J Orthop Sci.* 2004;9(3):256–63.
72. Beck M, Kalhor M, Leunig M, Ganz R. Hip morphology influences the pattern of damage to the acetabular cartilage: femoroacetabular impingement as a cause of early osteoarthritis of the hip. *J Bone Joint Surg.* 2005;87(7):1012–8.
73. Hunt D, Prather H, Harris Hayes M, Clohisey JC. Clinical outcomes analysis of conservative and surgical treatment of patients with clinical indications of prearthritic, intra-articular hip disorders. *PM R.* 2012;4(7):479–87.
74. Dezateux C, Rosendahl K. Developmental dysplasia of the hip. *Lancet.* 2007;369(9572):1541–52.
75. Furnes O, Lie SA, Espehaug B, Vollset SE, Engesaeter LB, Havelin LI. Hip disease and the prognosis of total hip replacements. A review of 53,698 primary total hip replacements reported to the Norwegian Arthroplasty Register 1987–99. *J Bone Joint Surg.* 2001;83(4):579–86.
76. Leck I. Congenital dislocation of the hip. In: Wald N, Leck I, editors. *Antenatal and neonatal screening.* 2nd ed. Oxford: Oxford University Press; 2000. p. 398–424.
77. Chan A, McCaul KA, Cundy PJ, Haan EA, Byron-Scott R. Perinatal risk factors for developmental dysplasia of the hip. *Arch Dis Child Fetal Neonatal Ed.* 1997;76(2):F94–100.
78. Ortiz-Neira CL, Paolucci EO, Donnon T. A meta-analysis of common risk factors associated with the diagnosis of developmental dysplasia of the hip in newborns. *Eur J Radiol.* 2012;81(3):e344–51.
79. Solomon L. Patterns of osteoarthritis of the hip. *J Bone Joint Surg Br.* 1976;58(2):176–83.
80. Harris WH. Etiology of osteoarthritis of the hip. *Clin Orthop Relat Res.* 1986;213:20–33.
81. Grant AD, Sala DA, Davidovitch RI. The labrum: structure, function, and injury with femoroacetabular impingement. *J Child Orthop.* 2012;6(5):357–72.
82. Meermans G, Konan S, Haddad FS, Witt JD. Prevalence of acetabular cartilage lesions and labral tears in femoroacetabular impingement. *Acta Orthop Belg.* 2010;76(2):181.

83. Haene RA, Bradley M, Villar RN. Hip dysplasia and the torn acetabular labrum: an inexact relationship. *J Bone Joint Surg.* 2007;89(10):1289–92.
84. Baker JF, McGuire CM, Mulhall KJ. Acetabular labral tears following pregnancy. *Acta Orthop Belg.* 2010;76(3):325–8.
85. Brooks AG, Domb BG. Acetabular labral tear and postpartum hip pain. *Obstet Gynecol.* 2012;120(5):1093–8.
86. Cotten A, Boutry N, Demondion X, Paret C, Dewatre F, Liesse A, et al. Acetabular labrum: MRI in asymptomatic volunteers. *J Comput Assist Tomogr.* 1998;22(1):1–7.
87. Silvis ML, Mosher TJ, Smetana BS, Chinchilli VM, Flemming DJ, Walker EA, et al. High prevalence of pelvic and hip magnetic resonance imaging findings in asymptomatic collegiate and professional hockey players. *Am J Sports Med.* 2011;39(4):715–21.
88. Register B, Pennock AT, Ho CP, Strickland CD, Lawand A, Philippon MJ. Prevalence of abnormal hip findings in asymptomatic participants: a prospective, blinded study. *Am J Sports Med.* 2012;40(12):2720–4.
89. Ilgen 2nd RL, Honkamp NJ, Weisman MH, Hagenauer ME, Heiner JP, Anderson PA. The diagnostic and predictive value of hip anesthetic arthrograms in selected patients before total hip arthroplasty. *J Arthroplasty.* 2006;21(5):724–30.
90. Pateder DB, Hungerford MW. Use of fluoroscopically guided intra-articular hip injection in differentiating the pain source in concomitant hip and lumbar spine arthritis. *Am J Orthop (Belle Mead NJ).* 2007;36(11):591–3.
91. Byrd JW, Jones KS. Diagnostic accuracy of clinical assessment, magnetic resonance imaging, magnetic resonance arthrography, and intra-articular injection in hip arthroscopy patients. *Am J Sports Med.* 2004;32(7):1668–74.
92. Yoong P, Guirguis R, Darrach R, Wijeratna M, Porteous MJ. Evaluation of ultrasound-guided diagnostic local anaesthetic hip joint injection for osteoarthritis. *Skeletal Radiol.* 2012;41(8):981–5.
93. Smith TO, Hilton G, Toms AP, Donell ST, Hing CB. The diagnostic accuracy of acetabular labral tears using magnetic resonance imaging and magnetic resonance arthrography: a meta-analysis. *Eur Radiol.* 2011;21(4):863–74.
94. Farkas B, Kvell K, Czompoly T, Illes T, Bardos T. Increased chondrocyte death after steroid and local anesthetic combination. *Clin Orthop Relat Res.* 2010;468(11):3112–20.
95. Braun HJ, Wilcox-Fogel N, Kim HJ, Pouliot MA, Harris AH, Dragoo JL. The effect of local anesthetic and corticosteroid combinations on chondrocyte viability. *Knee Surg Sports Traumatol Arthrosc.* 2012;20(9):1689–95.
96. Dragoo JL, Braun HJ, Kim HJ, Phan HD, Golish SR. The in vitro chondrotoxicity of single-dose local anesthetics. *Am J Sports Med.* 2012;40(4):794–9.
97. Grishko V, Xu M, Wilson G, Pearsall 4th AW. Apoptosis and mitochondrial dysfunction in human chondrocytes following exposure to lidocaine, bupivacaine, and ropivacaine. *J Bone Joint Surg Am.* 2010;92(3):609–18.
98. Jacobs TF, Vansintjan PS, Roels N, Herregods SS, Verbruggen G, Herregods LL, et al. The effect of Lidocaine on the viability of cultivated mature human cartilage cells: an in vitro study. *Knee Surg Sports Traumatol Arthrosc.* 2011;19(7):1206–13.
99. Kamath R, Strichartz G, Rosenthal D. Cartilage toxicity from local anesthetics. *Skeletal Radiol.* 2008;37(10):871–3.
100. Piper SL, Kramer JD, Kim HT, Feeley BT. Effects of local anesthetics on articular cartilage. *Am J Sports Med.* 2011;39(10):2245–53.
101. Sierra RJ, Trousdale RT, Cabanela ME. Pregnancy and childbirth after total hip arthroplasty. *J Bone Joint Surg.* 2005;87(1):21–4.
102. McDowell CM, Lachiewicz PF. Pregnancy after total hip arthroplasty. *J Bone Joint Surg Am.* 2001;83-A(10):1490–4.
103. Yazici Y, Erkan D, Zuniga R, Bateman H, Salvati EA, Magid SK. Pregnancy outcomes following total hip arthroplasty: a preliminary study and review of the literature. *Orthopedics.* 2003;26(1):75–6.
104. Stea S, Bordini B, De Clerico M, Traina F, Toni A. Safety of pregnancy and delivery after total hip arthroplasty. *J Womens Health (Larchmt).* 2007;16(9):1300–4.

Chapter 9

Upper Limb Issues in Pregnancy and Postpartum: Carpal Tunnel Syndrome and DeQuervain's Tenosynovitis

Kim M. Stein, Joanne Borg-Stein, and Lindsay N. Ramey

Introduction

Musculoskeletal problems are commonly associated with pregnancy. Though lower extremity complaints are most prevalent, upper extremity complaints are also common. As with all pregnancy-related musculoskeletal problems, upper extremity disorders are caused by a combination of changes in activity, physiology, and biochemical factors during pregnancy, and they will frequently resolve following delivery. Nevertheless, the two major upper extremity pathologies in pregnancy—carpal tunnel syndrome (CTS) and DeQuervain's tenosynovitis—can cause a great deal of dysfunction and may even lead to permanent damage in the absence of treatment. This chapter reviews the scientific basis of these diagnoses, including the relevant anatomic structures, etiology, and specific contributions of physiologic changes in pregnancy. We then discuss current clinical data, including prevalence, typical presentation, and diagnostic strategies. Lastly, we conclude with suggested treatments based on the most recent studies and our clinical experience.

K.M. Stein, MD
Department of Family Medicine, University of Virginia,
1215 Lee Street, Charlottesville, VA 22903, USA
e-mail: kms4rb@virginia.edu

J. Borg-Stein, MD (✉)
Department of Physical Medicine and Rehabilitation, Spaulding Rehabilitation Hospital,
SRH-Wellesley 65 Walnut Street, Wellesley, MA 02481, USA
e-mail: jborgstein@partners.org

L.N. Ramey, MD
Department of Physical Medicine and Rehabilitation, Spaulding Rehabilitation Hospital,
Harvard Medical School, Charlestown, MA 02129, USA
e-mail: lramey@partners.org

Carpal Tunnel Syndrome

Prevalence

Wrist and hand pain are the second most common musculoskeletal symptoms during pregnancy [1]. Studies have estimated the prevalence of CTS among pregnant women to be anywhere from 2 to 25 % [2, 3]. Most practitioners agree that pregnancy is a time of increased risk for CTS compared to baseline. The prevalence of CTS during pregnancy varies by source but has been cited to range from 36 to 62 % when diagnosed by clinical symptoms [4, 5].

Anatomy

The carpal tunnel is composed of a bony arch formed posteriorly by the carpal bones, including the scaphoid, lunate, triquetrum, and pisiform proximally and the trapezium, trapezoid, capitate, and hamate distally. The proximal carpal bones articulate with the radius at the radiocarpal joint and the distal carpal bones articulate with the metacarpals. This bony arch is bridged anteriorly by the flexor retinaculum to form the carpal tunnel (see Fig. 9.1). The structures that run through the tunnel include the tendons of the flexor digitorum superficialis (FDS), flexor digitorum profundus (FDP), and flexor pollicis longus (FPL), as well as the median nerve [6]. It is the median nerve that is of particular concern and is affected in CTS. The borders of the carpal tunnel are rigid structures and arranged in a way that limits expansion within the tunnel.

Etiology

CTS is a neuropathy of the median nerve caused by injury to the nerve as it passes along the palmar surface of the carpal bones from the anterior compartment of the forearm to the hand within the carpal tunnel. The common final pathway for all symptomatic carpal tunnel disease is compression of the nerve, leading to ischemia and mechanical disruption. Overuse of the FDS, FDP, and FPL muscles is believed to be a frequent trigger for inflammation within the carpal tunnel. Given the fixed volume of the tunnel, inflammation of any of its components leads to increased pressure with resulting compression of the median nerve. Though the precise mechanism is debated, the favored theory is that this pressure causes direct damage from compression as well as ischemia from decreased endoneurial blood supply [7]. Due to this irritation, over time, the nerve itself becomes inflamed and the pain becomes more frequent and severe.

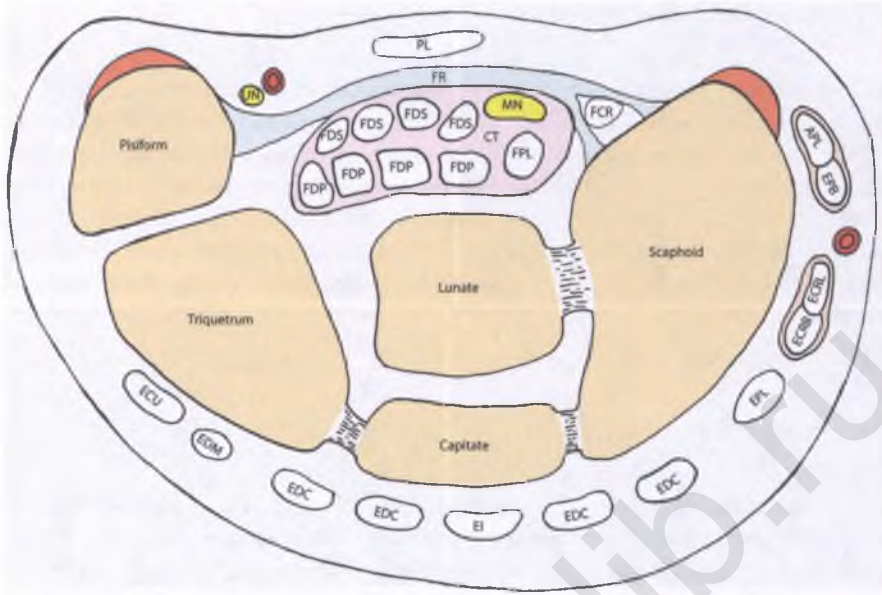


Fig. 9.1 Cross-sectional anatomy of the carpal tunnel at the level of the proximal carpal bones. *APL* abductor pollicis longus, *EPB* extensor pollicis brevis, *ECRL* extensor carpi radialis longus, *ECRB* extensor carpi radialis brevis, *EPL* extensor pollicis longus, *EI* extensor indicis, *EDC* extensor digitorum communis, *EDM* extensor digiti minimi, *ECU* extensor carpi ulnaris, *PL* palmaris longus, *FCR* flexor carpi radialis, *FDS* flexor digitorum superficialis, *FDP* flexor digitorum profundus, *FPL* flexor pollicis longus, *MN* median nerve, *FR* flexor retinaculum, *CT* carpal tunnel, *UN* ulnar nerve

Physiologic Changes in Pregnancy

The increased risk of CTS during pregnancy is believed to be due to increased fluid retention, caused by a combination of vasodilation, progesterone activity on the mineralocorticoid receptors, and increased antidiuretic hormone and aldosterone secretion [1]. These factors serve to increase total body fluid volume and decrease osmolality leading to tissue edema. Approximately 80 % of women report soft-tissue edema during pregnancy [8]. Padua et al. found a positive correlation between soft-tissue edema within the carpal tunnel and compression of the median nerve in pregnant women. It has also been shown that women with swelling in their fingers, independent of overall weight gain, have increased incidence of CTS, suggesting that local edema may play a role in the physiology of the disease [3]. The proposed mechanism is that this increased inflammation is present within the carpal tunnel, where the mechanical restrictions and fluid retention prevent appropriate expansion and lead to direct damage and ischemia.

Symptoms and Presentation

CTS classically presents with pain and paresthesias in the first three digits of the hand and the lateral half of the fourth digit. It can occur unilaterally or bilaterally. Symptoms are often worse at night and after repetitive wrist flexion and extension. Paresthesias may extend proximally up the ventral forearm to the shoulder. Over time more severe cases may lead to motor deficits, including diminished grip strength and difficulty with opposition. Thenar wasting may be appreciated if the process is more severe. These symptoms most often present during the second and third trimesters [1].

Diagnostic Strategies

Diagnosis of CTS is primarily a clinical diagnosis. Classically, a positive Phalen's or Tinel's test and decreased pinprick sensation in the median nerve distribution have been used to support a clinical diagnosis of CTS in the context of appropriate symptoms. Tinel's test involves tapping over the median nerve at the level of the wrist and is considered positive if this elicits paresthesias in the median nerve sensory distribution. In Phalen's test, the patient is asked to maintain their hand in full wrist flexion with the dorsum of the hand against a firm surface for 60 s; the test is positive if this reproduces the patient's symptoms. However, in a systematic review by D'Arcy et al. Tinel's and Phalen's tests had poor correlation with positive electrodiagnostic tests for median nerve dysfunction at the carpal tunnel, suggesting a low diagnostic yield [9]. The findings that were most predictive of positive electrodiagnostic testing included hyperalgesia, weak thumb abduction, and specific patterns of symptoms on the Katz hand diagram (see Table 9.1) [10].

Table 9.1 Definitions of physical exam findings in CTS

Test/Finding	Definition
Tinel's test	Paresthesias in distribution of median nerve elicited when clinician taps on wrist over median nerve at the carpal tunnel
Phalen's test	Paresthesias in distribution of median nerve elicited when patient flexes symptomatic wrist to 90° for 60 s
Hypalgesia	Diminished ability to detect painful stimuli on the palmar aspect of index finger compared to ipsilateral little finger
Katz hand diagram	Patients are instructed to draw the location of their symptoms on a diagram of the hand. Classic pattern includes involvement of at least 2 digits from digits 1–3 without palmar involvement. Pattern for a “probable” diagnosis includes at least 2 digits from digits 1–3 with palmar symptoms [8]
Thumb abduction weakness	Weakness detected when patient is instructed to raise thumb perpendicular to palm while clinician applies downward pressure on distal phalanx

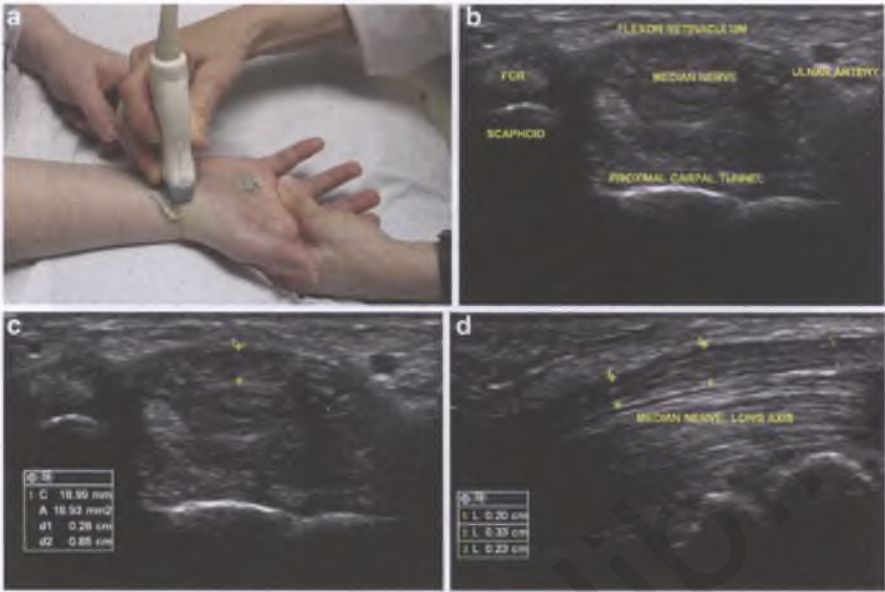


Fig. 9.2 Ultrasound imaging of the carpal tunnel. (a) Proper positioning of the patient and ultrasound transducer for carpal tunnel ultrasound. (b) Ultrasound image of an enlarged median nerve as it passes through the carpal tunnel; *FCR* flexor carpi radialis. (c) Measuring the cross-sectional area of an enlarged median nerve (18.93 mm^2) within the carpal tunnel on ultrasound; *C* circumference, *A* Area, *d1* height, *d2* width. (d) Long axis view of the median nerve with increased dimensions noted centrally at the level of the carpal tunnel (measurement 2) in comparison to more proximal and distal measurements; *L* length

The main diagnostic tests used to confirm CTS include electrodiagnostic studies (EMG) and ultrasound. Ultrasound is used more often in Europe than in the USA for diagnosis of CTS. Findings of abnormal median nerve size have correlated well with EMG findings [11]. To evaluate the median nerve via ultrasound, the patient is seated with elbow flexed, forearm supinated, and wrist resting in slight extension. Fig. 9.2a shows the position of the patient and ultrasound transducer. Fig. 9.2b shows the median nerve as it passes through the proximal carpal tunnel (transverse view). Many sonographic measurements have been cited to establish a diagnosis of CTS. This author prefers to use the cross-sectional area of the median nerve as the primary means of diagnosis by ultrasound (see Fig. 9.2c, transverse view). Findings of abnormal median nerve size have correlated well with EMG findings [11]. While studies vary on the specific cutoff for median nerve area, an area of 12 mm^2 or greater has been shown to have a high sensitivity and specificity for CTS [12, 13]. An increase in the area of the median nerve at the level of the carpal tunnel compared to the more proximal level of the pronator quadratus is another useful tool [12, 13]. The median nerve should always be viewed in short axis and long axis throughout the length of the carpal tunnel for thorough evaluation (see Fig. 9.2d for longitudinal view).

The American Academy of Physical Medicine and Rehabilitation recommends confirmation of median nerve compression by electrodiagnostic testing for a formal diagnosis of CTS. The authors agree with this recommendation prior to any invasive intervention. However, in a pregnant woman with classic symptoms, many practitioners will start with a trial of therapeutic splinting, given the low cost and minimal risk, prior to further diagnostic workup.

Effective Treatments

CTS symptoms that develop during pregnancy frequently resolve completely within days to weeks following delivery. An estimated 43–95 % of women have resolution of symptoms within 2 weeks postpartum [1]. However, one study demonstrated prolonged recovery time after delivery in women with onset of CTS symptoms in early pregnancy [14]. Given that most cases will resolve after delivery, conservative management is recommended whenever possible.

Patient education is key. All women with CTS during and after pregnancy should be provided education on correct neutral positioning of the wrist, activity modification for occupational and child-care activities, and the need for frequent repositioning during repetitive use. Adjunctive occupational therapy is often helpful for guidance and reinforcement of these practices. Nocturnal wrist splints are indicated for initial treatment in essentially all pregnant women [15]. This involves applying a removable splint shaped to support the wrist in a neutral to slightly extended position to limit movement at the wrist during the night (see Fig. 9.3). One study showed that greater than 80 % of pregnant women had good symptomatic relief with night splints for 2 weeks [2]. For patients in whom relief is incomplete, it is recommended that the practitioner verify correct use of the splint prior to declaring splint failure.

In patients who fail splinting, a local injection of corticosteroid may be considered. Steroid injections have been shown to be more effective than placebo injection [16]. Surgical release, a mainstay of therapy in advanced cases in nonpregnant adults, is rarely indicated in pregnant women. Indications for surgical intervention during pregnancy or the postpartum period include severe symptoms with electrodiagnostic confirmation as well as significant disruption in daily functioning after failure of more conservative measures. Surgical release has been shown to be safe and effective under local anesthesia in pregnant women [17].

DeQuervain's Tenosynovitis

Prevalence

Although there are no studies looking at the incidence of DeQuervain's tenosynovitis during or after pregnancy, it is commonly thought that the repetitive use during nursing and child rearing activities results in an increased incidence of DeQuervain's

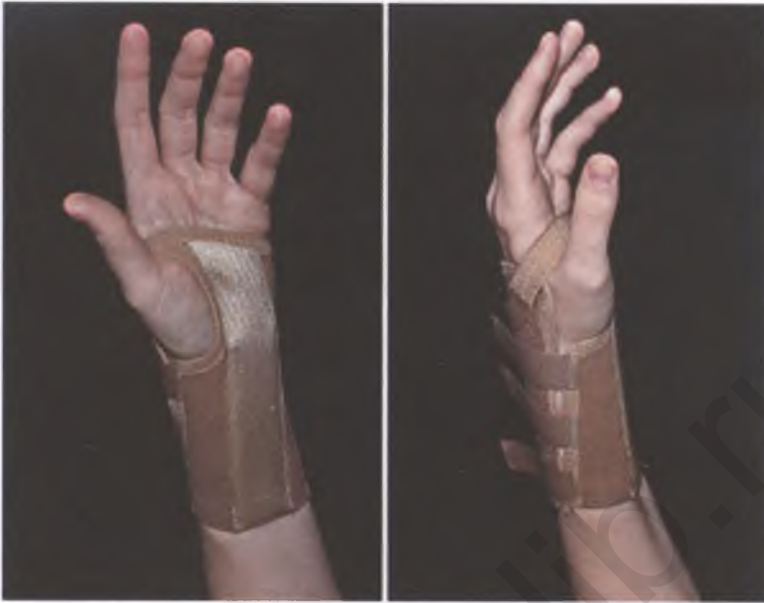

Fig. 9.3 Volar rigid stay splint for CTS. The splint holds the wrist in neutral position and limits wrist movement

tenosynovitis in the postpartum period [1]. Commonly called “mommy thumb,” “baby wrist,” or “new mother’s thumb,” it is more frequently associated with the postpartum period than with pregnancy, but it can occur in both periods.

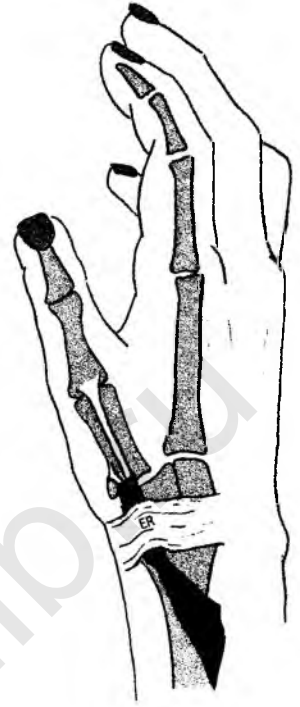
Anatomy

Tendons in the dorsal wrist run in six osseofibrous tunnel-like structures formed between the extensor retinaculum and the underlying carpal bones, making six extensor compartments of the wrist. The first, most lateral, compartment is located on the radial side of the wrist and can be found overlying and extending distally from the radial styloid process [18]. This compartment contains the tendons and synovial sheath of the abductor pollicis longus (APL) and the extensor pollicis brevis (EPB) muscles (see Fig. 9.4). As their name implies, these muscles are responsible not only for extending and abducting the thumb but also play a role in wrist flexion and radial deviation.

Etiology

DeQuervain’s tenosynovitis is caused by impaired movement and irritation of the EPB and APL tendons. Symptomatic tenosynovitis is thought to be caused by thickening of the extensor retinaculum of the wrist, which causes mechanical

Fig. 9.4 Anatomy of the first extensor compartment of the wrist. Location of pain and irritation in DeQuervain's tenosynovitis; *EPB* extensor pollicis brevis, *APL* abductor pollicis longus, *ER* extensor retinaculum



compression of the tendons as they attempt to slide over the styloid process. This results in inflammation of the tendons and associated pain. The most common trigger for this cycle is attributed to overuse of the EPB and APL muscles.

Physiologic Changes in Pregnancy

Similar to CTS, it has been hypothesized that fluid retention due to the hormonal changes during pregnancy, as described above, contributes to the pathophysiology of DeQuervain's tenosynovitis [1]. Pregnancy is commonly identified as an independent factor in the development of the inflammation even in the context of similar use patterns to the antepartum period.

It is also thought that increased use of the wrist and thumb during child care, particularly with new activities such as nursing or repeated lifting and holding of an infant, results in thickening of the EPB and APL tendons and their fibrous sheath in the postpartum period [19]. This restricts the normal gliding of the tendons within the sheath and perpetuates further inflammation, pain, and restricted motion.

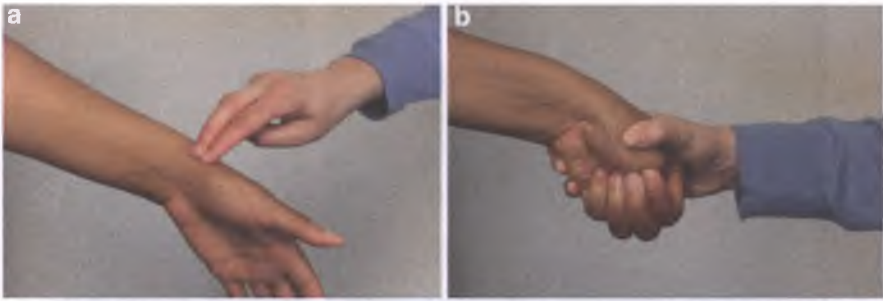


Fig. 9.5 Exam maneuvers for DeQuervain's tenosynovitis. (a) Focal tenderness to palpation over the radial styloid process as the first extensor compartment crosses over. (b) Demonstration of Finkelstein's test

Symptoms and Presentation

DeQuervain's tenosynovitis typically presents with pain along the radial aspect of the wrist. Certain wrist and hand motions, such as pincer grasp or lateral thumb and wrist movements, will often elicit the pain. The pain may also radiate to the thumb, forearm, or shoulder [18]. Patients with advanced disease may present with poor grip strength due to pain and weakness. Clinically, it is similar to intersection syndrome, which is less common inflammation of the extensor carpi radialis brevis and longus tendons where they intersect the EPB and APL tendons. The differential diagnosis should also include scapho-lunate ligament injury, ganglion cyst, flexor carpi radialis tendonitis, or scaphoid fracture. Scaphoid fracture should not be missed the later diagnosis to avoid the potential for nonunion and avascular necrosis. Though the pain is similar in all of these diagnoses, diagnostic testing can help isolate DeQuervain's tenosynovitis.

Diagnostic Strategies

DeQuervain's tenosynovitis is primarily a clinical diagnosis. The diagnosis is made based on history, symptom location, and local tenderness over the first extensor compartment. In examining the patient, there may be local tenderness to palpation over the distal radial styloid process (see Fig. 9.5a). The main provocative maneuver used in diagnosis is Finkelstein's test. In this test, pain is reproduced with flexion and adduction of the thumb inside a closed fist with wrist ulnar deviation (see Fig. 9.5b). Finkelstein's test can help distinguish DeQuervain's tenosynovitis from other diagnoses, though the sensitivity and specificity of this test have not been reported [20]. If clinical suspicion is high, imaging should be obtained to rule out scaphoid fracture in order to avoid its severe sequela. However, as other local tendon and ligament injuries listed in the differential would be treated similarly to DeQuervain's tenosynovitis, a trial of conservative treatment may be appropriate.

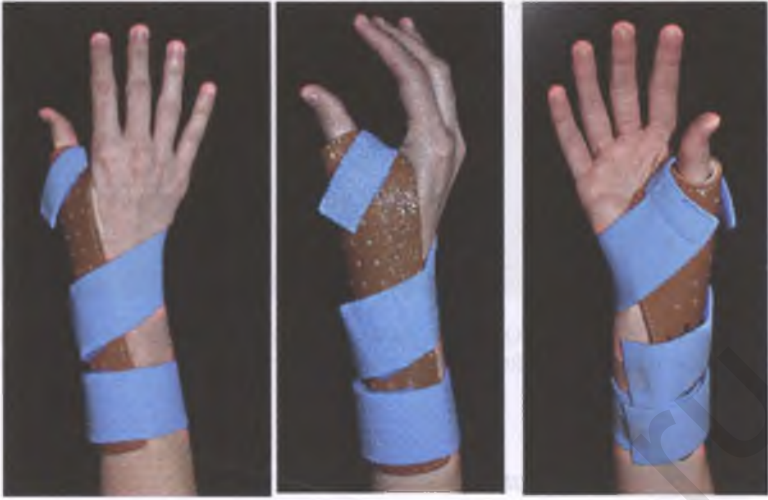

Fig. 9.6 Spica splint used for treatment of DeQuervain's tenosynovitis

Effective Treatments

Symptoms are usually self-limited and respond to conservative management, including thumb spica splint, icing, and activity modification [21]. Education is essential. Activity modification should focus on limiting ulnar deviation of the wrist and any other maneuvers that increase pain. Given that lifting and holding a newborn is often the offending activity, this recommendation may be difficult for patients to follow. The spica splint functions as a physical barrier against these thumb movements to allow the irritated muscles to rest and minimize inflammation. It also helps to stabilize the wrist and reinforces activity modification (Fig. 9.6). It is important to prescribe a splint with a smooth palmar surface that will not irritate the baby's skin during lifting or holding to help promote compliance. Most women will respond to either splinting or minimizing the aggravating activities. Oral anti-inflammatory medications can be used in the postpartum patient, but should be avoided during pregnancy, particularly in the last trimester. Ibuprofen has been the most extensively studied and has minimal transfer to breast milk [22].

If more conservative management is not effective, local corticosteroid injection of the tendon sheath or first dorsal compartment is an additional option. In one small study of 18 pregnant or nursing women, local corticosteroid injections were shown to be more effective than splinting alone [23]. If pain continues in the postpartum period, surgical release may be an option [24]. Overall, most patients with symptoms during pregnancy will resolve following delivery with conservative measures. Among those who develop symptoms in the postpartum period, there is a greater chance of requiring steroid injection to supplement activity modification and splinting. Surgery is uncommonly required.

References

1. Heckman JD, Sassard R. Musculoskeletal considerations in pregnancy. *J Bone Joint Surg Am*. 1994;76(11):1720–30.
2. Ekman-Ordeberg G, Sälgeback S, Ordeberg G. Carpal tunnel syndrome in pregnancy. A prospective study. *Acta Obstet Gynecol Scand*. 1987;66(3):233–5.
3. Voitk AJ, Mueller JC, Farlinger DE, Johnston RU. Carpal tunnel syndrome in pregnancy. *Can Med Assoc J*. 1983;128(3):277–81.
4. Bahrami MH, Rayegani SM, Fereidouni M, Baghbani M. Prevalence and severity of carpal tunnel syndrome during pregnancy. *Electromyogr Clin Neurophysiol*. 2005;45(2):123–5.
5. Pazzaglia D, Caliendo P, Aprile I, et al. Multicenter study on carpal tunnel syndrome and pregnancy incidence and natural course. *Acta Neurochir Suppl*. 2004;92:35–9.
6. Moses KP, Nava PB, Banks JC, Petersen DK. Wrist and hand joints. In: Moses KP, Nava PB, Banks JC, Petersen DK, editors. *Atlas of clinical gross anatomy*. Philadelphia: Elsevier; 2012. p. 268–81.
7. Keir PJ, Rempel DM. Pathomechanics of peripheral nerve loading. Evidence in carpal tunnel syndrome. *J Hand Ther*. 2005;18(2):259–69.
8. Ritchie JR. Orthopedic considerations during pregnancy. *Clin Obstet Gynecol*. 2003;46(2):456–66.
9. D'Arcy CA, McGee S. The rational clinical examination. Does this patient have carpal tunnel syndrome? *JAMA*. 2000;283(23):3110–7.
10. Katz JN, Stirrat CR, Larson MG, Fossel AH, Eaton HM, Liang MH. A self-administered hand symptom diagram for the diagnosis and epidemiologic study of carpal tunnel syndrome. *J Rheumatol*. 1990;17(11):1495–8.
11. Visser LH, Smidt MH, Lee ML. High-resolution sonography versus EMG in the diagnosis of carpal tunnel syndrome. *J Neurol Neurosurg Psychiatry*. 2008;79(1):63–7.
12. Klauser AS, Halpern EJ, De Zordo T, Feuchtner GM, Arora R, Gruber J, et al. Carpal tunnel syndrome assessment with US: value of additional cross-sectional area measurements of the median nerve in patients versus healthy volunteers. *Radiology*. 2009;250(1):171–7.
13. Duncan I, Sullivan P, Lomas F. Sonography in the diagnosis of carpal tunnel syndrome. *AJR Am J Roentgenol*. 1999;173(3):681–4.
14. Padua L, Aprile I, Caliendo P, Mondelli M, Pasqualetti P, Tonali PA, Italian Carpal Tunnel Syndrome Study Group. Carpal tunnel syndrome in pregnancy: multiperspective follow-up of untreated cases. *Neurology*. 2002;59(10):1643–6.
15. O'Connor D, Marshall S, Massy-Westropp N. Non-surgical treatment (other than steroid injection) for carpal tunnel syndrome. *Cochrane Database Syst Rev*. 2003;1, CD003219.
16. Marshall S, Tardif G, Ashworth N. Local corticosteroid injection for carpal tunnel syndrome. *Cochrane Database Syst Rev*. 2007;2, CD001554.
17. Assmus H, Hashemi B. [Surgical treatment of carpal tunnel syndrome in pregnancy: results from 314 cases]. *Nervenarzt*. 2000;71(6):470–3.
18. Moore JS. De Quervain's tenosynovitis. Stenosing tenosynovitis of the first dorsal compartment. *J Occup Environ Med*. 1997;39(10):990–1002.
19. Schumacher HR, Dorwart BB, Korzeniowski OM. Occurrence of De Quervain's tendinitis during pregnancy. *Arch Intern Med*. 1985;145(11):2083–4.
20. Malanga GA, Nadler S. *Musculoskeletal physical examination: an evidence-based approach*. Philadelphia: Mosby; 2006.
21. Borg-Stein J, Dugan SA. Musculoskeletal disorders of pregnancy, delivery and postpartum. *Phys Med Rehabil Clin N Am*. 2007;18(3):459–76. ix.
22. Spencer JP, Gonzalez LS, Barnhart DJ. Medications in the breast-feeding mother. *Am Fam Physician*. 2001;64(1):119–26.
23. Avci S, Yilmaz C, Sayli U. Comparison of nonsurgical treatment measures for de Quervain's disease of pregnancy and lactation. *J Hand Surg Am*. 2002;27(2):322–4.
24. Capasso G, Testa V, Maffulli N, Turco G, Piluso G. Surgical release of de Quervain's stenosing tenosynovitis postpartum: can it wait? *Int Orthop*. 2002;26(1):23–5.

Chapter 10

Labor and Delivery Considerations: Pubic Symphysis Separation, Fractures Associated with Transient Osteoporosis of Pregnancy, Sacral Stress Fractures, and Coccydynia/Coccyx Fracture

Sarah K. Hwang

Introduction

Just as many musculoskeletal issues can arise during pregnancy, labor and delivery is also a time at which musculoskeletal injuries may occur. These musculoskeletal injuries may result in long-term sequelae and pain for the patient; therefore, appropriate diagnosis and acute management is important.

Pubic Symphysis Separation

The pubic symphysis is a cartilaginous joint with a fibrocartilaginous intrapubic disc. Four ligaments hold the joint together: the anterior pubic, posterior pubic, superior arcuate, and inferior arcuate ligaments. With the hormonal shifts during pregnancy and the shift in the center of gravity, pregnancy is recognized as a time when the pubic symphysis is subjected to increased mechanical stresses [1]. Some widening of the pubic symphysis during pregnancy and delivery is normal. The pubic symphysis can separate up to 9 mm without symptoms. Widening of 10 mm or greater is considered pubic symphysis separation, or pubic symphysis diastasis. Separation of greater than 40–60 mm can be associated with sacroiliac joint involvement [2–4]. The incidence of pubic symphysis separation has varied widely in the literature, with ranges of 1:300 births to 1:30,000 births [5, 6]. A more recent retrospective review performed by Snow noted an incidence of 1:569 births [6].

S.K. Hwang, MD (✉)

Department of Physical Medicine and Rehabilitation, University of Missouri,
One Hospital Drive, DC 046.00, Columbia, MO 65212, USA
e-mail: hwangsa@health.missouri.edu

Several factors have been proposed as to the etiology of pubic symphysis separation [3, 7]. These factors include a rapid labor, larger birth weight of the infant, delivery using instrumentation, cephalopelvic disproportion, abnormal presentation of the infant, and excessive forceful abduction of the thighs during delivery.

Pubic symphysis separation is typically a clinical diagnosis. A patient's symptoms usually begin intrapartum or within the first 24 h after delivery; however, some women can present with symptoms antepartum or even up to 48 h postpartum [7]. Antepartum symptoms may include difficulty with ambulation or sharp pelvic or groin pain, and these symptoms can start weeks prior to delivery. Women may experience a popping sensation intrapartum or hear an audible pop or crack during delivery. In all cases of pubic symphysis separation, women report postpartum symptoms, but the timing of these symptoms may vary from one woman to another, especially if epidural anesthesia was utilized during the delivery. These symptoms may include pain, both in the area of the pubic symphysis as well as in adjacent structures, including the lumbar region, sacroiliac region, coccygeal region, groin, and legs [6]. Women often present with increased pain with weight-bearing that leads to difficulty with ambulation. In women who are able to ambulate, a characteristic waddling gait has been described [3, 8]. Some women may have lower extremity weakness [6]. They may also have swelling and bruising in the area of the pubic symphysis. A palpable defect or cleft is felt in some women. Adductor and hamstring spasm may be present as well as positive Trendelenburg sign [8]. There have been reports of urinary retention as well as reports of incontinence [6, 9, 10].

Physical exam of the patient with suspected pubic symphysis separation should include examination of the skin overlying the pubic symphysis. The musculoskeletal exam should include palpation of the pubic symphysis and palpation posteriorly of the long dorsal ligament. Characteristic pain can be evoked by bilateral pressure on the greater trochanters toward midline or by flexing the hip while the legs remain in extension. These maneuvers can result in severe pain and are not always necessary for diagnosis.

While the diagnosis of pubic symphysis separation is based on clinical presentation, imaging is often done to confirm the diagnosis. Imaging also may be important in following the progress of healing and treatment. Pelvic radiographs have been utilized in the majority of cases. Ultrasound has been described as a method for measuring the intrapubic gap [11, 12]. The primary benefit of ultrasound over plain radiograph is the lack of ionizing radiation. Therefore, this method of imaging can also be used during pregnancy.

Magnetic resonance imaging (MRI) has been described as a beneficial imaging tool in pubic symphysis separation [13, 14] (see Chap. 3 on Musculoskeletal Imaging). MRI provides a means to evaluate for soft tissue injury associated with pubic symphysis separation. Kurzel et al. reported on two cases with pubic symphysis separation that showed MRI evidence of effusions and hemorrhage collections within the cartilage and ligaments. In both studies evaluating MRI as a diagnostic tool, there were reports of a woman with symphyseal cartilage rupture and fluid collection within the intrapubic gap with a symphyseal separation of less than 10 mm [13, 14].

It is important to remember that the degree of the separation does not always correlate with the severity of symptoms or the extent of disability. Treatment should be based on symptom severity rather than size of the separation measured with imaging [3, 11, 13, 14].

Initial treatment for pubic symphysis separation is conservative in nature, even when symptoms are severe. Treatment may include relative bed rest in the lateral decubitus position and utilization of a pelvic brace or binder [7]. Physical therapy with graded exercise protocols can often be initiated early to avoid complications of prolonged bed rest. Ambulation should be done with an assistive device, such as a walker. Pain control often can be achieved with nonsteroidal anti-inflammatory medications; however, at times, patients may require opioid pain medications for symptom relief. Some authors recommend immediate surgical management if the diastasis is greater than 40 mm [4]; yet, most recommendations are for surgical intervention only after failure of conservative treatment, inadequate reduction, or recurrent diastasis [6]. Several surgical procedures have been described including external fixation and open reduction with internal fixation [4, 15].

One review noted that most women have resolution of symptoms in 6–8 weeks with conservative measures alone [6]. As mentioned previously, radiographs or ultrasound can be used to document progressive resolution of the diastasis. There are case studies that report continued pain up to 16 months after the pubic symphysis diastasis [16]. Another review in 2011 by Nitsche and Howell reported that approximately 36 % of patients underwent surgical management. This surgical management was at varied times in the course of treatment, described both after the failure of conservative treatment to use of surgery as an initial management [17]. There have been reports of conservative management being utilized in women with a separation up to 9.5 cm in size, with an accompanying 3–5 mm widening of the sacroiliac joints [18].

Pubic symphysis separation may predispose women to recurrence during subsequent deliveries; however, there are several studies that note normal vaginal deliveries without complication after a patient has sustained pubic symphysis separation in previous pregnancies [19]. There have been case series demonstrating that repeat severe separation is unlikely and that elective cesarean section should only be performed for other obstetrical indications [3]. In this particular report, five patients had repeat deliveries (from one to four deliveries), four of whom had no symptoms postpartum and one of whom had slight pelvic pain for 2 days postpartum, which rapidly disappeared.

Transient Osteoporosis of Pregnancy

Transient osteoporosis of pregnancy (TOP) is a rare, but a likely underreported condition. It was initially described by Curtiss and Kincaid in 1957 and since that time over 200 cases have been published [20, 21]. A study performed by Steib-Furno et al. [20] concluded that the incidence of symptomatic TOP was three in 4,900 pregnancies. TOP generally affects otherwise healthy women in the second or third

trimester of pregnancy and has been described as a self-limiting condition that resolves spontaneously within several months after delivery [21]. However, fracture has been reported as a complication of this disease by many authors; therefore, correct diagnosis of TOP during pregnancy is important. There have been multiple reports in the literature of misdiagnosis of this disease as pubic symphysis pain/dysfunction [22, 23]. MRI is helpful in the diagnosis of TOP during pregnancy. For further details please see Chap. 8: Hip Disorders in Pregnancy.

Clinical symptoms typically arise during pregnancy when women present with unexplained joint pain. The hip is the most commonly affected joint, but there have been reports of TOP affecting other bones, including the knee, ankle, wrist, elbow, spine, and sacrum [23–27].

The etiology of TOP is unclear. Several authors have proposed various etiologies but none have gathered substantial proof [21, 28]. These hypotheses include genetic predisposition, compression of the obturator nerve, vasodilation, deficiencies in bone metabolism, bone medullary hypertension, and small vessel ischemia, and chemical or hormonal factors related to pregnancy. The only recognized risk factor thus far is pregnancy.

TOP is a condition that requires important considerations for labor and delivery. Vaginal deliveries in patients with TOP are not recommended due to the reports of fracture during delivery. Furthermore, in women who do not elect to utilize epidural anesthesia, positioning for a vaginal delivery often can be too painful for the patient [28, 29]. For these reasons, cesarean section should be the delivery of choice in patients with TOP.

There have been several reports of hip fractures during delivery in women with TOP. Some authors have reported fracture of a single hip during delivery [30], while others have reported bilateral hip fractures occurring during delivery [22, 23]. Intrapartum fractures may present immediately postpartum or presentation may be delayed several days. Some women report hearing an audible click during delivery [23].

Clinical examination of suspected hip fracture postpartum reveals the inability to bear weight and decreased bilateral hip movements due to severe pain [23].

Postpartum imaging should start with plain radiographs if a fracture is suspected. If a fracture is detected, an orthopaedic surgery consult should be obtained for possible operative management of the fracture. Breastfeeding should be cautioned in women with this diagnosis, as calcium losses are greater in nursing mothers than during pregnancy [27]. Further history and workup to rule out other secondary causes of osteoporosis may be beneficial, including thyroid disease, parathyroid disease, anorexia nervosa, or medication history of corticosteroids or heparin. Transient osteoporosis may recur in subsequent pregnancies [31] but should only require cesarean section if symptoms are present during pregnancy.

There also have been reports of vertebral fractures associated with TOP [27]. In a case report by Ofluoglu, a woman presented with moderate back pain during her last month of pregnancy that worsened postpartum. Imaging revealed eight vertebral compression fractures. Bone mineral density was consistent with osteoporosis. This woman had no neurologic sequelae and was treated with a thoracolumbosacral

orthosis. She was advised to cease breastfeeding and prescribed a physical therapy program that focused on muscle strengthening, range of motion, and relaxation exercises as well as weight-bearing exercises. This particular patient also was started on alendronate, calcium, and vitamin D.

Imaging of suspected vertebral fractures should include plain radiographs initially. If a compression fracture is noted on radiographs, MRI is useful to determine the age of the compression fracture as well as to assess for fracture stability. Kyphoplasty or vertebroplasty may be considered in this patient population as well [27].

Sacral Stress Fractures

Sacral stress fractures are classified into two groups: insufficiency fractures and fatigue fractures [32]. Insufficiency fractures occur in weakened bones under normal mechanical loading, whereas fatigue fractures are due to unusual mechanical loading in normal bone. Sacral fractures occurring during labor and delivery can be classified as fatigue fractures or a combination of insufficiency and fatigue fracture if the patient has TOP.

Several risk factors for sacral stress fractures during labor and delivery have been proposed, including vaginal delivery of a high birth weight infant, increased lumbar lordosis, excessive weight gain, and rapid vaginal deliveries [33]. Several other factors have been identified as possible promoting factors, including vitamin D insufficiency, anticoagulation therapy with heparin and TOP.

Women typically present with low-back pain, buttock pain, pelvic pain, or hip pain with or without radicular symptoms [32, 34] soon after vaginal delivery. There have been reports of sacral fracture with associate lumbosacral plexus lesions [35]. Physical exam reveals tenderness over the sacrum and buttocks. Sacroiliac provocation tests are often positive as well, including Gaenslen test, the flexion-abduction-external-rotation (FABER) test and the squish test.

Imaging plays an important role in confirming the diagnosis of sacral stress fractures. Initially, plain radiograph may be obtained but is often unremarkable early in the course of the stress fracture [32]. A fracture line may be visible 3 weeks or later, after the onset of symptoms. MRI is helpful early on in the course of this condition and is considered the gold standard in imaging [34]. The presence of bone marrow edema on MRI is consistent with acute or subacute fracture. Computed tomography also can be used to determine the fracture line which appears as increased sclerosis with or without vertical cortical disruption through the fracture line or to follow the healing fracture line [32]. However, computed tomography is not recommended in pregnant or lactating women [33]. Postpartum dual energy X-ray absorptiometry should be used to assess for TOP. It is important to remember that the Z score should be used to determine the presence of osteoporosis during childbearing years. If a sacral fracture line diagnosed during pregnancy closely approximates the sacral nerves roots, a cesarean delivery may be considered to preserve sacral nerve function.

Initial treatment is aimed at pain control, where acetaminophen or opioid pain medications may be utilized [32, 33]. The majority of postpartum sacral stress fractures are stable and require no surgical intervention. Early mobilization is recommended once pain is controlled. Supervised progressive ambulation with an assisted device is recommended as weight-bearing stimulates osteoblastic activity, facilitating fracture healing. Early mobilization also minimizes the complications associated with immobility. Treatment with calcium and vitamin D also should be initiated in these women.

Coccydynia and Coccyx Fracture

The coccyx is the most distal aspect of the vertebral column and is composed of three to five vertebral segments that partially or fully fuse during adulthood [36, 37]. The sacrococcygeal joint typically is articulated by a fibrocartilaginous disc, composed of hyaline cartilage. The joint also can be a synovial joint in some cases and, when this is the case, the joint is more mobile. The coccyx serves as the attachment site of the gluteus maximus muscle, the coccygeus muscle, and the levator ani (ilcococcygeus) muscle, making this structure important with relation to the functions of the pelvic floor muscles.

Coccydynia is defined as pain in the coccyx region [38]. Pain typically is aggravated with sitting or arising from the seated position. Women also may note a frequent urge to defecate or pain with defecation. Coccydynia typically is the result of traumatic etiology, but idiopathic cases have been identified as well. Typical traumatic events that can lead to coccydynia include a fall onto the buttocks, micro-trauma from cycling and parturition [39]. It has been estimated that approximately 7 % of women suffer from postpartum coccydynia [40].

One study showed a high proportion of women (approximately 50 % in one study) who suffer from postpartum coccydynia required the use of forceps during delivery [40]. There have been other studies that have estimated 12–17 % of postpartum coccydynia in women with instrumented delivery [41, 42]. Some women do note a cracking noise during delivery. Symptoms of pain typically appear in the first day postpartum when the patient first uses a sitting position. Exam of these patients should include musculoskeletal exam of the lumbar spine and pelvis and neurologic exam. Manual examination of the coccyx should be performed as well as internal exam of the pelvic floor to evaluate for pain and spasm. Resisted hip extension also may reproduce the woman's pain due to the attachment of the gluteus maximus muscle onto the coccyx.

Imaging can be beneficial in these women and should include lateral radiographs of the coccyx. Dynamic radiological images of the coccyx also can be utilized as described by Maigne [43, 44]. In this method, the angle is measured in standing and sitting (coccygeal stress) positions. A difference between the angles of 2°–25° is considered normal.

Two characteristic lesions have been described in postpartum coccydynia, both of which are thought to be the result of the coccyx being pushed rearwards by the child's head [40]. The first type of lesion is luxation in the sitting position, which is revealed by dynamic radiographs as described above. It can be attributed to rupture of the sacrococcygeal ligaments or disc. The second type of lesion is fracture of the coccyx or the S5 vertebrae while the sacrococcygeal joint remains rigid.

Management is conservative and may include nonsteroidal anti-inflammatory drugs as well as adapted sitting with a donut shaped pillow and ice. Stool softeners should be started in postpartum patients with coccydynia. Physical therapy should be initiated early to address postural correction to ensure proper sitting posture when holding the baby and breastfeeding [37]. Physical therapy will eventually focus on mobilization of the coccyx, as well as eventual myofascial release and downtraining of the pelvic floor muscles. This treatment is typically started after the obstetrician has cleared the patient at 6 weeks postpartum. Reports have shown the benefit of physical therapy over placebo [45]. This study also noted increased benefit if therapy was started within 1 year of the onset of symptoms. If physical therapy alone fails, injections can be performed using corticosteroids and local anesthetic. Studies have showed that injection alone can have a 60 % success rate whereas the combination of injection with coccygeal manipulation had a success rate of 85 % for a 3-month time period [46]. Surgical treatment for coccygectomy is not recommended [47, 48]. This procedure has moderate results long-term, and the risk of major complications is high. As mentioned previously, the pelvic floor muscles insert onto the coccyx and subsequent negative impact of coccygectomy on these muscles is often seen.

Conclusions

Labor and delivery is a time when women are susceptible to musculoskeletal injuries. While these injuries do not occur frequently, correct diagnosis and treatment are crucial to prevent chronic pain and disability.

References

1. Prather H, Dugan S, Fitzgerald C, Hunt D. Review of anatomy, evaluation, and treatment of musculoskeletal pelvic floor pain in women. *PM R*. 2009;1(4):346–58.
2. Topuz S, Cital I, Iyibozkurt AC, Dursun M, Akhan SE, Has R, et al. Pubic symphysis diastasis: imaging and clinical features. *Eur J Radiol Extra*. 2006;59(3):127–9.
3. Callahan JT. Separation of the symphysis pubis. *Am J Obstet Gynecol*. 1953;66(2):281–93.
4. Kharrazi FD, Rodgers WB, Kennedy JG, Lhowe DW. Parturition-induced pelvic dislocation: a report of four cases. *J Orthop Trauma*. 1997;11(4):277–81; discussion 81–2.
5. Kubitz RL, Goodlin RC. Symptomatic separation of the pubic symphysis. *South Med J*. 1986;79(5):578–80.

6. Snow RE, Neubert AG. Peripartum pubic symphysis separation: a case series and review of the literature. *Obstet Gynecol Surv.* 1997;52(7):438–43.
7. Lindsey RW, Leggon RE, Wright DG, Nolasco DR. Separation of the symphysis pubis in association with childbearing. A case report. *J Bone Joint Surg Am.* 1988;70(2):289–92.
8. Kane R, Erez S, O'Leary JA. Symptomatic symphyseal separation in pregnancy. *Surg Gynecol Obstet.* 1967;124(5):1032–6.
9. Shippey S, Roth J, Gaines R. Pubic symphysis diastasis with urinary incontinence: collaborative surgical management. *Int Urogynecol J.* 2013;24(10):1757–9.
10. Valsky DV, Anteby EY, Hiller N, Amsalem H, Yagel S, Hochner-Celnikier D. Postpartum pubic separation associated with prolonged urinary retention following spontaneous delivery. *Acta Obstet Gynecol Scand.* 2006;85(10):1267–9.
11. Scriven MW, Jones DA, McKnight L. The importance of pubic pain following childbirth: a clinical and ultrasonographic study of diastasis of the pubic symphysis. *J R Soc Med.* 1995;88(1):28–30.
12. Bjorklund K, Bergstrom S, Lindgren PG, Ulmsten U. Ultrasonographic measurement of the symphysis pubis: a potential method of studying symphyseolysis in pregnancy. *Gynecol Obstet Invest.* 1996;42(3):151–3.
13. Kurzel RBAA, Rooholamini SA, Smith W. Magnetic resonance imaging of peripartum rupture of the symphysis pubis. *Obstet Gynecol.* 1996;87(5):826–9.
14. Wurdinger S, Humsch K, Reichenbach JR, Peiker G, Seewald HJ, Kaiser WA. MRI of the pelvic ring joints postpartum: normal and pathological findings. *J Magn Reson Imaging.* 2002;15(3):324–9.
15. Rommens PM. Internal fixation in postpartum symphysis pubis rupture: report of three cases. *J Orthop Trauma.* 1997;11(4):273–6.
16. Hierholzer C, Ali A, Toro-Arbelaez JB, Suk M, Helfet DL. Traumatic disruption of pubis symphysis with accompanying posterior pelvic injury after natural childbirth. *Am J Orthop.* 2007;36(11):E167–70.
17. Nitsche JFHT. Peripartum pubic symphysis separation: a case report and review of the literature. *Obstet Gynecol Surv.* 2011;66(3):153–8.
18. Jain N, Sternberg LB. Symphyseal separation. *Obstet Gynecol.* 2005;105(5 Pt 2):1229–32.
19. Culligan PHS, Heit M. Rupture of the symphysis pubis during vaginal delivery followed by two subsequent uneventful pregnancies. *Obstet Gynecol.* 2002;100(5):1114–7.
20. Steib-Furno S, Luc M, Pham T, Armingeat T, Porcu G, Gamberre M, et al. Pregnancy-related hip diseases: incidence and diagnoses. *Joint Bone Spine.* 2007;74(4):373–8.
21. Rocchietti March M, Tovaglia V, Meo A, Pisani D, Tovaglia P, Aliberti G. Transient osteoporosis of the hip. *Hip Int.* 2010;20(3):297–300.
22. Bircher C, Afors K, Bircher M. Transient osteoporosis of the hip in pregnancy resulting in bilateral fracture of the neck of the femur. *Int J Gynaecol Obstet.* 2012;116(2):176–7.
23. Lidder S, Lang KJ, Lee HJ, Masterson S, Kankate RK. Bilateral hip fractures associated with transient osteoporosis of pregnancy. *J R Army Med Corps.* 2011;157(2):176–8.
24. Arayssi TK, Tawbi HA, Usta IM, Hourani MH. Calcitonin in the treatment of transient osteoporosis of the hip. *Semin Arthritis Rheum.* 2003;32(6):388–97.
25. Stamp L, McLean L, Stewart N, Birdsall M. Bilateral transient osteoporosis of the knee in pregnancy. *Ann Rheum Dis.* 2001;60(7):721–2.
26. Grey A, Dalbeth N, Doyle A. Clinical images: transient regional osteoporosis. *Arthritis Rheum.* 2009;60(10):3145.
27. Ofluoglu O, Ofluoglu D. A case report: pregnancy-induced severe osteoporosis with eight vertebral fractures. *Rheumatol Int.* 2008;29(2):197–201.
28. Maliha G, Morgan J, Vrahas M. Transient osteoporosis of pregnancy. *Injury.* 2012;43(8):1237–41.
29. Shifrin LZ, Reis ND, Zinman H, Besser MI. Idiopathic transient osteoporosis of the hip. *J Bone Joint Surg.* 1987;69(5):769–73.
30. Thomas E, Cox C, Murphy D, Beddard K. Hip fracture during labour due to transient osteoporosis of the hip in pregnancy. *J Obstet Gynaecol.* 2000;20(2):197–8.

31. Trusczyńska A, Walczak P, Rapala K. Transient peripartum osteoporosis of the femoral head in first and third pregnancy. *J Clin Densitom.* 2012;15(4):467–71.
32. Karatas M, Basaran C, Ozgul E, Tarhan C, Agildere AM. Postpartum sacral stress fracture: an unusual case of low-back and buttock pain. *Am J Phys Med Rehabil.* 2008;87(5):418–22.
33. Longhino V, Bonora C, Sansone V. The management of sacral stress fractures: current concepts. *Clin Cases Miner Bone Metab.* 2011;8(3):19–23.
34. Ozturk G, Kulcu DG, Aydog E. Intrapartum sacral stress fracture due to pregnancy-related osteoporosis: a case report. *Arch Osteoporos.* 2013;8(1–2):139.
35. Murray DJ, Bhatti W. Maternal sacral fracture during delivery causing foot drop. *Int J Gynaecol Obstet.* 2011;115(3):289–90.
36. Patel R, Appannagari A, Whang PG. Coccydynia. *Curr Rev Musculoskelet Med.* 2008;1(3–4):223–6.
37. Ryder I, Alexander J. Coccydynia: a woman's tail. *Midwifery.* 2000;16(2):155–60.
38. Fogel GR, Cunningham 3rd PY, Esses SI. Coccygodynia: evaluation and management. *J Am Acad Orthop Surg.* 2004;12(1):49–54.
39. Patijn J, Janssen M, Hayek S, Mekhail N, Van Zundert J, van Kleef M. 14. Coccygodynia. *Pain Pract.* 2010;10(6):554–9.
40. Maigne JYRF, Diouf M. Postpartum coccydynia: a case series study of 57 women. *Eur J Phys Rehabil Med.* 2012;48:387–92.
41. Dupuis O, Silveira R, Redarce T, Dittmar A, Rudigoz RC. [Instrumental extraction in 2002 in the “AURORE” hospital network: incidence and serious neonatal complications]. *Gynecol Obstet Fertil.* 2003;31(11):920–6.
42. Revicky V, Mukhopadhyay S, Morris EP, Nieto JJ. Induction of labour and the mode of delivery at term. *J Obstet Gynaecol.* 2011;31(4):304–6.
43. Maigne JY, Guedj S, Straus C. Idiopathic coccygodynia. Lateral roentgenograms in the sitting position and coccygeal discography. *Spine (Phila Pa 1976).* 1994;19(8):930–4.
44. Maigne JYDL, Chatellier G. Causes and mechanisms of common coccydynia. *Spine (Phila Pa 1976).* 2000;25(23):3072–9.
45. Maigne JYCG, Le Faou M, Archambeau M. The treatment of chronic coccydynia with intrarectal manipulation. *Spine (Phila Pa 1976).* 2006;31(18):E621–7.
46. Wray CC, Easom S, Hoskinson J. Coccydynia. Aetiology and treatment. *J Bone Joint Surg Br.* 1991;73(2):335–8.
47. De Andres J, Chaves S. Coccygodynia: a proposal for an algorithm for treatment. *J Pain.* 2003;4(5):257–66.
48. Khan SA, Kumar A, Varshney MK, Trikha V, Yadav CS. Dextrose prolotherapy for recalcitrant coccygodynia. *J Orthop Surg (Hong Kong).* 2008;16(1):27–9.

Chapter 11

Pelvic Floor Injury and Consequences

Cynthia A. Brincat

Introduction

The prevalence of pelvic floor disorders (PFDs) as well as their surgical management creates a large burden on patients, providers, and the health care system in general. Surgical management of PFDs is common, with a lifetime risk of undergoing a surgery for pelvic organ prolapse or incontinence by age 80 being 11.1 % [1]. Projections from United States Census Bureau data, indicates that the prevalence of symptomatic PFD will increase by 56 % from 28.1 to 43.8 million from 2010 to 2050 [2].

An accepted risk factor for PFDs is vaginal birth, and concomitant pelvic floor injury. PFD at this stressful and exciting time of life offer their own challenges including interruptions of early parenting, frustration with unmet expectations, plus significant time and cost. Within this, it is beneficial to understand the prognosis of common issues and complications that arise within this period in a woman's life. In what follows, the literature regarding prognosis for the issues surrounding birth, birth trauma, and pelvic floor injury will be addressed.

Obstetric Anal Sphincter Injury

Of the spectrum of PFD with the most profound effect on quality of life in the postpartum period, fecal and anal incontinence are arguably most disruptive. Fecal incontinence is the complaint of involuntary loss of solid or liquid feces and anal incontinence includes the complaint of involuntary loss of feces or flatus. What is

C.A. Brincat, MD, PhD (✉)

Department of Urology and Obstetrics/Gynecology, Loyola University Chicago, Stritch School of Medicine, 2160 South First Avenue Building 103, Suite 1004, Maywood, IL 60153, USA
e-mail: cbrincat@lumc.edu

often overlooked in considering these issues is fecal urgency with or without incontinence, including the sudden compelling desire to defecate that is difficult to defer [3]. The most common cause of these disorders in young women is injury to the anal sphincter complex at childbirth.

The anal sphincter complex is comprised of the external anal sphincter (EAS) and the internal anal sphincter (IAS). These are separated by a shared longitudinal coat. The EAS is a striated muscle and appears red, like skeletal muscle. It is innervated by the inferior rectal branch of the pudendal nerve. Unlike other striated muscles, it contributes up to 30 % of the resting tone of the sphincter complex. The vast majority of the tone of the sphincter complex comes from the IAS. This IAS is a continuation of the circular fibers of the rectum and remains in a state of tonic contraction. Perineal tears are classified as first through fourth degree. Third-degree tears include some degree of disruption of the EAS, and at their worst, involve the IAS (see Table 11.1).

The prevalence of anal incontinence reported in the literature among women with sphincter injuries ranges from 20 to 50 % reporting some sort of anal incontinence symptoms in the near postpartum period [4–6]. Anal incontinence can occur in up to one third of women with obstetrical sphincter injuries with immediate or delayed onset of symptoms [7]. Because of occult injury, the incidence of anal sphincter damage at the time of vaginal delivery is higher than the number of observed injuries would suggest. Overt anal sphincter injury is relatively rare in women without episiotomy or operative vaginal delivery, with an incidence that ranges from 0 to 6.4 % [7–10]. The incidence of occult anal sphincter laceration identified by ultrasonography, ranges from 6.8 to 44 % in parous women [6, 11]. Additionally, data from a large US population-based study indicated that 29.3 % of postpartum women suffer from fecal incontinence (including flatus) when assessing for immediate postpartum symptoms and one in five of these women had undergone a cesarean delivery [12]. Clearly, this is a multifactorial problem that is prevalent in not only with vaginal delivery but also with the cesarean delivery population.

In differentiating fecal or flatal incontinence, a systematic review of comparative studies, with short-term follow-up, showed that anal incontinence was increased after spontaneous vaginal delivery as compared to cesarean delivery (OR 1.32; 95 % CI 1.04–1.68). However the risk of anal incontinence was not increased between these two groups [13]. Likewise, in a longitudinal cohort study of women 5–10 years after their first delivery, there was no significant difference in anal incontinence.

Table 11.1 Classification of perineal trauma [51]

First degree: laceration of the vaginal epithelium or perineal skin only
Second degree: involvement of the perineal muscles but not the anal sphincter
Third degree: disruption of the anal sphincter muscles:
3a: <50 % thickness of EAS torn
3b: >50 % thickness of EAS torn
3c: internal sphincter also torn
Fourth degree: a third-degree tear with disruption of the anal epithelium as well

tinence symptoms in women who had been delivered by cesarean compared to those with spontaneous or instrumented delivery [14].

Episiotomy and operative vaginal delivery increase the incidence of severe pelvic floor trauma, yet were performed in 29 % and 9 % of vaginal births, respectively, in 2001 [15, 16]. A meta-analysis of six randomized trials compared restrictive to liberal use of episiotomy in 4,850 women concluded that liberal use of episiotomies conferred no benefit and was associated with other complications [17]. Much of the incidence of obstetric anal sphincter injury (OASIS) depends upon the type of episiotomy performed. In these cases where mediolateral episiotomies are practiced, the rate of OASIS is 1.7 % in all comers and 2.9 % in primiparous patients [18]. Much higher rates are noted in those instances of midline episiotomy, at rates of 12 % for all comers [19] and 19 % in primiparous patients [20]. Operative vaginal delivery was similarly reviewed in 2,582 women and it was concluded that vacuum delivery was associated with a much lower risk of anal sphincter laceration than delivery with forceps (relative risk: 0.41; 95 % CI 0.33–0.50) [21]. Prevention of anal sphincter laceration and subsequent development of anal incontinence partly lies in decreasing the use of these interventions at the time of delivery.

While vaginal birth alone is not clearly a risk for fecal incontinence, OASIS increases the risk of subsequent fecal incontinence. Estimates range from 9 to 28 % [10, 22–24]. Likewise the risk of fecal incontinence is increased when there is a disruption of the IAS, as compared to the EAS alone [24]. Although fecal incontinence from birth injury is debilitating in younger women, studies of older women in the 50–60s, seem to eradicate the correlation of birth injury in explaining fecal incontinence. Most convincingly, a study of over 2,600 women in their 50s demonstrated no significant difference between the prevalence of fecal incontinence between nulliparous, primiparous, and multiparous women. These groups had fecal incontinence rates of 11 %, 9 %, and 9 %, respectively. This similarity prevailed among parous women, irrespective of the mode of delivery [25]. De Leeuw et al. reported a retrospective cohort study of 125 matched pairs with median follow-up of 14 years after index delivery. FI was reported in 39 women with sphincter lacerations compared to 16 controls (OR 3.1; 95 % CI 1.57–6.10) [25]. In an American cohort of sphincter injury patients followed at 6 months, the presence of FI was associated with white race, antenatal UI, fourth versus third-degree sphincter tear, older age at time of delivery, and higher BMI. There were no factors associated with FI at the 6-month postpartum mark in the vaginal delivery group without OASIS or who had undergone a cesarean delivery [26].

The role of midline versus mediolateral episiotomy has been identified as a possible causal factor in explaining the higher rates of anal and fecal incontinence involved in an American cohort, where episiotomies, when performed are midline versus mediolateral. Careful evaluation of findings and subsequent outcomes need to assess this mechanism of OASIS versus that which occurs in the setting of mediolateral episiotomy.

In counseling patients for outcomes of primary repair, rates of fecal and anal incontinence vary greatly, not surprisingly, based on the variations in repair techniques, as well as the study design and the manner in which data was collected.

A recent prospective study of 241 women at their first vaginal delivery, 59 of whom experienced OASIS, with subsequent repair with trained providers showed no fecal incontinence and no difference in flatal incontinence as compared to those women who had not had a sphincter disruption at 4 years postpartum [27]. What is most hopeful about this study, is that when evidence-based protocols are established and implemented, not surprisingly, patient outcomes improve, and thus prognostic indicators improve as well.

In counseling women about future route of delivery, it appears that there is only a modest increase in risk for recurrent OASIS. A retrospective review of a large American cohort ($n=658$) showed recurrent OASIS in only a small percentage of women at 3.2 %, with operative vaginal delivery and birth weight of $\geq 4,000$ g to be associated with recurrent OASIS [28]. This is consistent with a large Swedish cohort which although showed an increase of sixfold in incidence of sphincter rupture, the incidence was only 3 %. It was however somewhat lower than in other large studies ($n=774$), which showed a rate that was still quite low at 7.5 % [20].

Urinary Incontinence

The role of vaginal birth as it leads to stress urinary incontinence is well established. Stress (SUI) is defined as the urinary leakage during physical activity, such as coughing, sneezing, laughing, or exercise. The case for urge (UUI) (involuntary loss of urine that usually occurs when a person has a strong, sudden need to urinate) incontinence as the result of birth injury is less common. Rates in the initial postpartum period vary. Prevalence of SUI and UUI incontinence 5 years after first vaginal delivery has been shown to be 30 % and 15 %, respectively with presence of symptoms at 3 months postpartum being predictive of more and longer lasting symptoms [29].

Most studies are short term in their follow-up, but in the observational analysis by Altman et al., women were followed 10 years out from their first delivery. They found that there were significant increases in stress as well as UUI symptoms at 10 years follow-up compared with baseline and also compared with the 10 years preceding delivery. Most of those in the analyzed cohort experienced mild to moderate symptoms, with a 5–6 time increase in incidence of urinary incontinence episodes from the time of their first vaginal delivery [30]. Perineal trauma did not correlate with the presence of incontinence 10 years after the first delivery, nor did repeat vaginal deliveries [30]. In an American cohort 5–10 years after vaginal or cesarean delivery, spontaneous vaginal birth was associated with a significantly greater odds of SUI (OR 2.9; 95 % CI 1.5–5.5) as compared to cesarean without labor [14]. These findings are not dissimilar to the large population study of Rortveit et al. which found 14.7 % of parous women having symptoms of SUI, as compared to 4.7 % of nulliparous women. In this cohort of greater than 15,000 women, a relative risk of 2.4 % for developing SUI was noted, and the number of vaginal deliveries was of limited importance for the outcome as compared to that of the first vaginal delivery [31].

Predictors of postpartum urinary incontinence in several studies include leaking during pregnancy [31, 32] and predictors of incontinence at the 1-year mark, include persistent leakage 4–8 weeks postpartum [33]. Association of other factors with incontinence is worthy of investigation, with findings indicative of OASIS being associated with both pure UII and mixed incontinence. In a large American cohort of 943 women, UII incontinence alone was found in 16.2 % of women and mixed incontinence was found in 14.6 % of women. Stress symptoms were present in 21.3 % of women [34].

Assessments of persistence of urinary incontinence are difficult to obtain. In a longitudinal comparison of women undergoing spontaneous vaginal delivery complicated by OASIS, vaginal delivery without OASIS and cesarean delivery without labor of all of the women reporting urinary incontinence at 6 weeks, about 40 % did not report incontinence at 6 months, and about one-third of the urinary incontinence reported at 6 months was not in women who reported incontinence at the 6-week postpartum point [26].

Understanding the significant association is only a first step in the analysis. Further understanding of the structures involved and the mechanism by which the damage occurs can be helpful in assessing pathology and prognosis. In an analysis of primiparous stress incontinent versus continent women at 9–12 months postpartum, maximal urethral closure pressure was 25 % lower in stress incontinent women. In the same analysis comparing primiparous stress continent to nulliparous women, the two groups had similar values [35]. This points to sphincter function as a key component in the continence mechanism and a potential target for therapeutic interventions.

Additionally, primiparous women with SUI are twice as likely to have visible levator ani (LA) or pelvic floor muscle pubococcygeus defects compared to continent primiparous [35]. However further analysis of this relationship showed that urethral function measured as a urodynamic variable did not differ in women with and without levator ani muscle injury. This is both frustrating and hopeful. It requires a careful analysis of the continence mechanism of urethral closure pressure and levator ani support, as after birth maximum urethral closure pressure (MUCP) change may not necessarily accompany LA change or other anatomical changes [36]. Second, birth events that injure the LA do not necessarily limit a woman's ability to augment MUCP with a Kegel (pelvic floor muscle contraction) effort in the postpartum period as well as later in life [36, 37].

Levator Ani Injury

It is well established that vaginal delivery leads to higher rates of levator ani damage particularly involving the pubovisceral (pubococcygeus) portion of the levator ani muscle [38]. In an assessment of 160 primiparous women, 32 of the 160 (20 %) were found to have levator ani defects on MRI. These women with muscle defects were more likely to have had a difficult delivery with an odds ratio of 14.7 for

forceps delivery, 8.1 for anal sphincter rupture, and 3.1 for episiotomy [39]. Later in life these levator defects are more commonly found in women with prolapse (55 %) as compared to normal controls (16 %), leading to an adjusted odds ratio of 7.3 for prolapse in those with a levator ani defect as compared to their counterparts without a muscle defect [40].

The consequences of levator ani injury in the short term are not completely clear other than those with a muscle defect were found to have weaker pelvic floor muscles in the 9–12-month postpartum period as compared to controls [35]. Birth-related changes to the levator ani muscles persist in both function and structure with a significant amount of remodeling present in the course of normal postpartum healing. Analysis of the dynamic MRIs of those patients who had experienced those factors putting them at risk for levator tear demonstrated that at rest diameters of the urogenital and levator hiatus were smaller on late scans (~7 months postpartum) compared with early scans (~1 month postpartum) by 7.7 and 3.2 mm, respectively ($p, 0.05$) [41]. These findings were independent of the status of the levator muscles in this cohort. It was also demonstrated by Tunn et al., that the at-rest locations of the perineal body, levator, and urogenital hiatus locations improve greatly from the 1-day and 2-weeks postpartum mark [42]. This points to an aggressive early resolution of postpartum change in position, just by virtue of time, without any intervention. There was however no statistically significant difference in the ability to displace structures during Kegel and Valsalva in the comparison of 1-month and 7-month scans, showing that in this group there is little change in function of the muscles from the early to the later postpartum period [41]. It is not known, however if LAD contributes to persistent postpartum pelvic girdle or low back pain or what overall impact the injury denotes to the musculoskeletal pelvis as a whole.

In those patients who had undergone a vaginal delivery, pelvic floor muscle strength 6–11 years after vaginal delivery was similarly assessed with a significant reduction in both strength and duration of contraction in those who had undergone either spontaneous or assisted vaginal delivery. Further, among women with at least one vaginal delivery, pelvic muscle strength was lower among the women with a PFD as compared to those without ($p=0.12$) This finding was additionally associated with the obstetric variables at delivery of macrosomia, perineal laceration, episiotomy, anal sphincter laceration, as well as the number of vaginal deliveries [43]. Further, 5–10 years after vaginal delivery an associate of prolapse to or beyond the hymen was found (OR 5.6; 95 % CI 2.2–14.7) as compared to cesarean without labor [14].

Sexual Function

It is well known that the prevalence of sexual dysfunction is high in the female population. More so, there is a large body of epidemiologic data describing short-term postpartum sexual dysfunction. Like any postpartum dysfunction, sexual function is a manifestation of multiple factors, including the new parenting responsibility, sleep deprivation, adjustment of the family members, hormonal changes, and not least of all pre-pregnancy sexual functions and intimacy.

One component of sexual dysfunction in the postpartum period is pain with intercourse. Several studies have pointed to the consequence of worsening perineal trauma in the form of assisted vaginal delivery as a predictor of increased sexual pain postpartum. A large cross-sectional study out of Australia, using mail surveys at 6–7 months postpartum showed a nearly fivefold increased risk of perineal pain, and a twofold risk of sexual problems with vacuum or forceps delivery as compared to spontaneous vaginal delivery (OR 4.69; 95 % CI 3.2–6.8 and OR 2.06; 95 % CI 1.4–3.0, respectively). This was the case even after controlling for the duration of labor, infant birth weight, and degree of perineal trauma [44]. An American cohort had similar findings with no resumption of sexual intercourse at 7 weeks postpartum in those undergoing an assisted delivery. This same group had also endorsed that the delivery had adversely affected their experience of sexual activity as compared to those who had undergone spontaneous vaginal delivery [44].

In light of the prevalence of sexual dysfunction, it is important to keep in mind that nonetheless resumption of sexual activity after delivery occurs relative soon after the traditional interval of “vaginal rest.” Data indicates that approximately half of the women resume sexual activity by 5–6 weeks postpartum [45]. A somewhat lower number of 40 % of women reported being sexually active at the 7-week postpartum point. 241 patients were included in this prospective analysis, 98 of whom underwent episiotomy (mediolateral). In this cohort, being sexually active was not affected by the type or degree of perineal trauma that occurred with delivery [46]. At the 6-month postpartum point, an American cohort of over 500 women reported 94 % having resumed sexual activity. This cohort demonstrated slightly lower rates in those having undergone OASIS (88 %) and cesarean delivery (86 %) [47].

Most frustrating in any analysis of postpartum sexual function is the lack of attention it garners. In a London teaching hospital with a large obstetrics unit, only 15 % of women with a sexual problem postpartum felt comfortable raising these issues with their healthcare provider and only 18 % of all obstetric patients reported receiving information about changes in sexual function postpartum. Although as reported, a vast majority of women have resumed intercourse at the 3-month postpartum mark, analysis of a different cohort demonstrated that the 2-month postpartum mark, 55 % of women experienced painful penetration and 45 % experienced painful intercourse [48]. Determining who these patients will be is more complicated than merely screening those who in their delivery experienced perineal trauma or assisted delivery. Clearly, predelivery sexual function plays a role as lack of satisfaction with one’s relationship at the 1-year postpartum mark was predicted by not being sexually active at 12 weeks of pregnancy [49].

As with many postpartum issues, longer-term analysis is somewhat confounding. Studies of identical twins demonstrated that those who were sexually active were more likely to be premenopausal and multiparous as compared to their opposite counterparts. However, beyond that, nulliparous women who were sexually active reported superior sexual satisfaction scores compared with parous women, regardless of age and mode of delivery of their parous counterparts [49]. Another population-based study of a cohort of 40 years old or older demonstrated no significant associations between parity or mode of delivery and the outcomes of low sexual desire, less than monthly sexual activity, or low overall sexual satisfaction.

This was the case with the exception that those who had undergone operative vaginal delivery were more likely to report low sexual desire (OR 1.38; 95 % CI 1.04–1.83) [50]. These studies point to some resolution or at least an adaptation to the short-term postpartum effects on sexual function. In the setting of a paucity of intervention-based versus observational research on the consequences of parity, birth, and birth trauma on sexual function and the high prevalence of sexual dysfunction in women, we would be well served to screen women during their pregnancy and in the postpartum period.

Summary

In general, medicine has a limited ability to determine prognosis in complicated multifactorial cases. Nowhere is this more apparent than in predictions involving pelvic floor injury and its consequences. There is clearly a large need for well-designed randomized controlled trials for interventions in the postpartum period. Much of this work is likely to come from the well-established postpartum perineal clinics.

In light of the prevalence of disorders, there needs to be an emphasis on screening new mothers and newly delivered multiparous women for the consequences and signs of the various manifestations of postpartum sexual dysfunction and PFD.

In summary, when determining the prognosis of women with pelvic floor injury, we can make some generalizations. Women that develop urinary incontinence during pregnancy are more likely to suffer urinary incontinence after delivery. If she continues to leak urine after 3 months, she may improve, but is likely to have some persistent symptoms. Anal incontinence immediately after delivery is common with a sphincter laceration, but in the vast majority of cases will resolve. As the woman ages, she may be at increased risk for developing FI, but the data is unclear. Levator ani muscle tears are associated with pelvic organ prolapse, UI and FI. The immediate impact of the muscle tears is not well studied. There are strong associations with LA tears and pelvic organ prolapse as the woman age. But again not all women with LA tears have clinically relevant prolapse and we do not know the prognostic factors to determine which women will go on to develop problems later in life. Sexual function within the first 6 months of delivery is often painful for women, especially if there has been a perineal laceration or sphincter tear. Fortunately most discomfort will resolve by a year.

Some women are no doubt innately more prone to the development of PFD based on genetic factors, body weight and muscle mass, levels of physical activity, etc. A birth injury in one woman may lead to devastating consequences, while another woman with the same injury may heal and suffer no symptoms. Our challenge now is to determine which women will suffer the injuries, what are the modifiable risk factors, and how can we stop the progression of disease and symptoms. Without a clear understanding, we are limited in describing associations, and our understanding of these disorders and thus of our patients is limited as well.

References

1. Olsen AL, Smith VJ, Bergstrom JO, Colling JC, Clark AL. Epidemiology of surgically managed pelvic organ prolapse and urinary incontinence. *Obstet Gynecol.* 1997;89:501–6.
2. Wu JM, Kawasaki A, Hundley AF, Dieter AA, Myers ER, Sung VW. Predicting the number of women who will undergo incontinence and prolapse surgery, 2010 to 2050. *Am J Obstet Gynecol.* 2011;3:230.
3. Haylen BT, de Ridder D, Freeman RM, Swift SE, Berghmans B, Lee J, Monga A, Petri E, Rizk DE, Sand PK, Schaer GN, International Urogynecological Association, International Continence Society. An International Urogynecological Association (IUGA)/International Continence Society (ICS) joint report on the terminology for female pelvic floor dysfunction. *Neurourol Urodyn.* 2010;29:4–20.
4. Sultan AH, Kamm MA, Hudson CN, et al. Anal-sphincter disruption during vaginal delivery. *N Engl J Med.* 1993;329:1905–11.
5. Sultan AH, Kamm MA, Hudson CN, et al. Effect of pregnancy on anal sphincter morphology and function. *Int J Colorectal Dis.* 1993;8:206–9.
6. Sultan AH, Kamm MA, Hudson CN, et al. Third degree obstetric anal sphincter tears: risk factors and outcomes of primary repair. *BMJ.* 1994;308:887–91.
7. Thacker SB, Banta HD. Benefits and risks of episiotomy: an interpretative review of the English language literature, 1860-1980. *Obstet Gynecol Surv.* 1982;38:322–38.
8. Helwig JT, Thorp JM, Bowes WA. Does midline episiotomy increase the risk of third and fourth degree lacerations in operative vaginal deliveries? *Obstet Gynecol.* 1993;82:276–9.
9. Combs CA, Robertson PA, Laros RK. Risk factors for third-degree and fourth-degree perineal lacerations in forceps and vacuum deliveries. *Am J Obstet Gynecol.* 1990;163:100–4.
10. Zetterstrom J, Lopez A, Anzen B, et al. Anal sphincter tears at vaginal delivery: risk factors and clinical outcome of primary repair. *Obstet Gynecol.* 1999;94:21–8.
11. Varma A, Gunn J, Gardiner A, et al. Obstetrical anal sphincter injury: prospective evaluation and incidence. *Dis Colon Rectum.* 1999;42:1537–43.
12. Guise JM, Morris C, Osterwil P, Li H, Rosenberg D, Greenlick M. Incidence of fecal incontinence after childbirth. *Obstet Gynecol.* 2007;109:281–8.
13. Pretlove SJ, Thompson PJ, Tooz-Hobson PM, et al. Does the mode of delivery predispose women to anal incontinence in the first year postpartum? A comparative systematic review. *BJOG.* 2008;115:421.
14. Handa V, Blomquist J, Knoepp L, Hoskey K, McDermott KC, Muñoz A. Pelvic floor disorders 5-10 years after vaginal or cesarean childbirth. *Obstet Gynecol.* 2011;118:777–84.
15. Martin JA, Hamilton BE, Sutton PD, Ventura SJ, Menacker F, Munson ML. Births: final data for 2002. National vital statistics reports; vol 52, no 10. Hyattsville: National Center for Health Statistics; 2003.
16. Hall MJ, DeFrances CJ. 2001 National Hospital Discharge Survey. Advanced data from vital and health statistics; no 332. Hyattsville: National Center for Health Statistics; 2003.
17. Carroli G, Belizan J. Episiotomy for vaginal birth (Cochrane Review). In: *The Cochrane Library, Issue 4.* Oxford: Update Software; 2000.
18. Harkin R, Fitzpatrick M, O'Connell PR, O'Herlihy C. Anal sphincter disruption at vaginal delivery: is recurrence predictable? *Eur J Obstet Gynecol Reprod Biol.* 2003;109(2):149–52.
19. Coats PM, Chan KK, Wilkins M, Beard RJ. A comparison between midline and mediolateral episiotomies. *Br J Obstet Gynaecol.* 1980;87:408–12.
20. Peleg D, Kennedy CM, Merrill D, Zlatnik FJ. Risk of repetition of a severe perineal laceration. *Obstet Gynecol.* 1999;93(6):1021–4.
21. Johanson RB, Menon BKV. Vacuum extraction versus forceps for assisted vaginal delivery (Cochrane Review). In: *The Cochrane Library, Issue 4.* Oxford: Update Software; 2000.
22. Sanagalli MR, Floris L, Faltin D, Weil A. Anal incontinence in women with third or fourth degree perineal tears and subsequent vaginal deliveries. *Aust NZ J Obstet Gynaecol.* 2000; 40:244.

23. Pollack J, Nordenstam J, Brismar S, et al. Anal incontinence after vaginal delivery: a five year prospective cohort study. *Obstet Gynecol.* 2004;104:1397.
24. Nygaard IE, Rao SS, Dawson JD. Anal incontinence after anal sphincter disruption: a 30-year retrospective cohort study. *Obstet Gynecol.* 1997;89:896.
25. Fritel X, Ringa V, Varnoux N, et al. Mode of delivery and fecal incontinence at midlife: as study of the 2640 women in the Gazel cohort. *Obstet Gynecol.* 2007;110:31.
26. Borello-France D, Burgio KL, Richter HE, et al. Fecal and urinary incontinence in primiparous women. *Obstet Gynecol.* 2006;108:863.
27. Andrews V, Shelmeridine S, Sultan A, Thakar R. Anal and urinary incontinence 4 years after a vaginal delivery. *Int Urogynecol J.* 2013;24:55–60.
28. Basham E, Stock L, Lewicky-Gaup C, Mitchell C, Gossett D. Subsequent pregnancy outcomes after obstetric anal sphincter injuries. *Female Pelvic Med Reconstr Surg.* 2013;19:328–32.
29. Viktrup L. The risk of lower urinary tract symptoms five years after the first delivery. *Neurourol Urodyn.* 2002;21(1):2–29.
30. Altman D, Ekström Å, Gustafsson C, López A, Falconer C, Zetterström J. Risk of urinary incontinence after childbirth: a 10-year prospective cohort study. *Obstet Gynecol.* 2006;108(4):873–8.
31. Rortveit G, Daltveit AK, Hannestad YS, Hunskaar S, Norwegian EPINCONT Study. Urinary incontinence after vaginal delivery or cesarean section. *N Engl J Med.* 2003;348:900–7.
32. Thomason AD, Miller JM, DeLancey JO. Urinary incontinence symptoms during and after pregnancy in continent and incontinent primiparas. *Int Urogynecol J Pelvic Floor Dysfunct.* 2007;18(2):147–51.
33. Schytt E, Lindmark G, Waldenström U. Symptoms of stress incontinence 1 year after childbirth: prevalence and predictors in a national Swedish sample. *Acta Obstet Gynecol Scand.* 2004;83(10):928–36.
34. Fenner D, Genber B, Brahma P, Marek L, DeLancey JO. Fecal and urinary incontinence after vaginal delivery with anal sphincter disruption in an obstetrics unit in the United States. *Am J Obstet Gynecol.* 2003;189:1543–50.
35. DeLancey JO, Miller JM, Kearney R, Howard D, Reddy P, Umek W, et al. Vaginal birth and de novo stress incontinence: relative contributions of urethral dysfunction and mobility. *Obstet Gynecol.* 2007;2:354–62.
36. Brincat C, DeLancey JO, Miller J. Urethral closure pressures among primiparous women with and without levator ani muscle defects. *Int Urogynecol J.* 2011;22:1491–5.
37. Miller JM, Umek WH, Delancey JO, Ashton-Miller JA. Can women without visible pubococcygeal muscle in MR images still increase urethral closure pressures? *Am J Obstet Gynecol.* 2004;191:171–5.
38. Delancey JO, Kearney R, Chou Q, Speights S, Binno S. The appearance of levator ani muscle abnormalities in magnetic resonance images after vaginal delivery. *Obstet Gynecol.* 2003;1:46–53.
39. Kearney R, Miller JM, Ashton-Miller JA, DeLancey JO. Obstetric factors associated with levator ani muscle injury after vaginal birth. *Obstet Gynecol.* 2006;107:144–99.
40. DeLancey JO, Morgan DM, Fenner DE, Kearney R, Guire K, Miller JM, et al. Comparison of levator ani muscle defects and function in women with and without pelvic organ prolapse. *Obstet Gynecol.* 2007;109:295–302.
41. Yousuf A, DeLancey JO, Brandon C, Miller J. Pelvic structure and function at 1 month compared to 7 months by dynamic magnetic resonance after vaginal birth. *Am J Obstet Gynecol.* 2009;201(5):514.e1–7.
42. Tunn R, DeLancey JO, Howard D, Throp JM, Ashton-Miller JA, Quint LE. MR imaging of levator ani muscle recovery following vaginal delivery. *Int Urogynecol J Pelvic Floor Dysfunct.* 1999;10:300–7.
43. Friedman S, Blomquist J, Nugent J, McDermott K, Muñoz A, Handa V. Pelvic muscle after childbirth. *Obstet Gynecol.* 2012;120(5):1021–8.
44. Brown S, Lumley J. Maternal health after childbirth: results of an Australian population based survey. *Br J Obstet Gynaecol.* 1998;105:156–61.

45. Lydon-Rochelle MT, Holt VL, Martin DP. Delivery method and self-reported postpartum general health status among primiparous women. *Paediatr Perinat Epidemiol.* 2001;15:232–40.
46. Rogers RG, Borders N, Leeman LM, Albers LL. Does spontaneous genital tract trauma impact postpartum sexual function? *J Midwifery Womens Health.* 2009;54:98–103.
47. Andrews V, Thakar R, Sultan A, Jones P. Evaluation of postpartum perineal pain and dyspareunia—a prospective study. *Eur J Obstet Gynecol Reprod Biol.* 2008;137:152–6.
48. Brubaker L, Handa VL, Bradley CS, Connolly A, Moalli P, Brown MB, et al. Sexual function 6 months after first delivery. *Obstet Gynecol.* 2008;111:1040–4.
49. Barrett G, Pendry E, Peacock J, Victor C, Thakar R, Manyonda I. Women's sexual health after childbirth. *BJOG.* 2000;107:186–95.
50. Van Brummen HJ, Bruinse HW, van de Pol G, Heintz AP, van der Vaart CH. Which factors determine the sexual function 1 year after childbirth? *BJOG.* 2006;113:914–8.
51. Royal College Obstetricians & Gynaecologists (RCOG). Management of third and fourth degree perineal tears following vaginal delivery. Guideline no 29. London: RCOG Press; 2001.

Chapter 12

Pelvic Floor Myofascial Pain and Dysfunction

Sarah M. Eickmeyer and Dana Seslija

Introduction

Women are at increased risk to develop pain in the pelvic region compared to men due to unique anatomy and biomechanics, especially during and after pregnancy. Women have a more broad and shallow pelvis requiring greater muscular and ligamentous stiffness to provide support to the bony pelvic girdle [1]. During pregnancy, the muscles of the pelvic floor bear the weight of the growing uterus and will eventually allow passage of the fetus [2]. Changes occur in the ability of ligaments, fascia, and muscles of the pelvic girdle to provide support to the pelvis due to increasing abdominal girth, changes in load transfer, and ligamentous laxity caused by the hormones relaxin and estrogen [3]. Thus, pelvic girdle pain (PGP), or pain between the posterior iliac crest and the gluteal folds, which includes the sacroiliac joint (SIJ) and the pubic symphysis, is a common cause of pain in pregnant women [4] (Chap. 4). Pregnancy-related anatomic and hormonal changes may have effects on biomechanical patterns of the pelvic floor muscles (PFM), leading to changes in contraction, relaxation, muscle strength, and myofascial pain [5]. PGP and PFM pain may be related in pregnancy and the postpartum period. In a recent study, women with PGP during pregnancy had more PFM pain than women without PGP [6]. Additionally, parous women with PGP had anatomic and manometric findings consistent with increased PFM activity compared to controls [7].

S.M. Eickmeyer, MD (✉)

Physical Medicine and Rehabilitation, The University of Kansas Medical Center,
3901 Rainbow Boulevard, Kansas City, KS 66160, USA
e-mail: seickmeyer@kumc.edu

D. Seslija, MD

Physical Medicine and Rehabilitation, Medical College of Wisconsin Affiliated Hospitals,
Clement J. Zablocki VA Medical Center, 8701 Watertown Plank Road, Milwaukee, WI 53226, USA
e-mail: dseslija@mcw.edu

Table 12.1 Possible etiologies of pelvic floor pain or dysfunction by medical specialty

Gynecological	Gastrointestinal/Genitourinary	Musculoskeletal	Psychological
Vulvodynia	Interstitial cystitis	Low back pain	Anxiety
Dysmenorrhea	Urgency/frequency syndrome	Lumbar radiculopathy	Depression
Endometriosis	Levator ani syndrome	SIJ dysfunction	History of abuse
Fibroids	Bowel/bladder incontinence	Coccydynia	
Organ prolapse		Hip disorders	

SIJ sacroiliac joint

Pelvic floor myofascial pain is characterized by muscular pain, taut bands, and trigger points that cause pain referral with pressure, usually due to underlying overuse or weakness [8]. Myofascial trigger points can develop from functional events through overuse, repetitive strains, motion injuries, or dysfunctional posturing as well as a result of a viscerosomatic reflex [9]. In pregnancy, the PFM may become overactive and painful in an attempt to compensate for the anatomic and hormonal changes in the pelvic region. Due to previous delivery trauma, muscle tearing, or nerve injury, the PFM may also be underactive and painful. Pelvic floor myofascial dysfunction refers to abnormal muscle activation patterns that may result from injury or compensatory change [6].

Pelvic floor myofascial pain and dysfunction can contribute to the symptom of dyspareunia, or painful sexual intercourse. It should be noted that vulvodynia is another cause of dyspareunia, but the two terms and conditions are not interchangeable. Vulvodynia, or vulvar vestibulitis, refers to severe pain on vestibular touch or vaginal entry, tenderness to pressure localized within the vulvar vestibule, and physical findings confined to vestibular erythema of varying degrees [10]. Pelvic floor myofascial pain and dysfunction, PGP, dyspareunia, and vulvodynia can all contribute to long-term, chronic pelvic pain (CPP) in women.

CPP is nonmalignant pain perceived in structures related to the pelvis of either men or women [11]. CPP is pain that occurs between the umbilicus and thigh, either anterior or posterior, occurring for greater than 3 months and is not exclusive to sexual intercourse or menstruation [12]. It is important to correctly understand the anatomic basis and differences between these conditions, and to identify musculoskeletal causes of pelvic pain to provide appropriate rehabilitation treatments in a timely manner. While CPP includes several visceral and somatic causes (Table 12.1), many patients undergo surgical interventions for presumed visceral origins before musculoskeletal etiologies are entertained, which delays diagnosis and treatment of musculoskeletal pelvic pain [13, 14]. This chapter will explain the rehabilitation approach to treating pelvic floor myofascial pain and dysfunction.

Epidemiology

In a 2008 study which included fecal and urinary incontinence and pelvic organ prolapse, the prevalence of symptomatic pelvic floor disorders in the United States was estimated to be approximately 24 % [15]. Pelvic floor myofascial pain and

dysfunction can contribute to CPP, which affects 25 % of community-dwelling adult women [16]. Prevalence rates of PFM pain found on vaginal physical examination in girls and women with CPP (ages 14–79 years old) were documented at 22 % [17]. Less is known about prevalence of pelvic floor myofascial pain during pregnancy. A recent small study of 51 pregnant women highlighted the association of pregnancy-related PGP and deep PFM pain. In this study, 70 % of women with pregnancy-related PGP had deep PFM pain during the second trimester; while only 15 % of women without PGP had deep PFM [6]. Pelvic floor myofascial pain may also be associated with chronic lumbopelvic pain after pregnancy. Abnormal PFM function measured by intravaginal palpation and surface electromyography (EMG) was found in 52 % of postpartum women with chronic lumbopelvic pain that began during pregnancy [5]. In addition, 20 % of women with lumbopelvic pain in pregnancy avoid subsequent pregnancies [18].

Pelvic Floor Neuromusculoskeletal Anatomy

The pelvic floor is a bowl of muscles, ligaments, and fascia that acts as a cradle to support the bladder, uterus, and rectum. This cradle of soft tissue is enclosed by the bony scaffolding formed by two innominate bones made up of the ilium, ischium, and pubis which articulate with the sacrum posteriorly, and each other anteriorly (Fig. 12.1). Extending from the sacrum is the coccyx which acts as an important ligamentous and tendinous anchor. The structures of focus in this chapter will be on the minor or lesser pelvis which houses the urogenital structures.

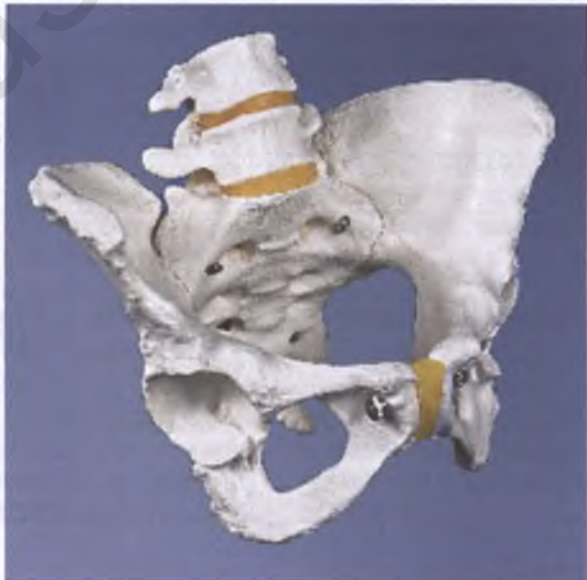

Fig. 12.1 The bony pelvic girdle consists of the two innominate bones and the sacrum, which are connected by two posterior sacroiliac joints and one anterior pubic symphysis joint

The articulating surfaces of the pelvis achieve closure through both force and form. Force closure is achieved through the fascial and tendinous attachments of the muscle systems within the pelvis, whereas form closure is achieved through the ligaments providing passive stability [3]. In the posterior pelvic ring there are two sacroiliac joints with both anterior and posterior capsules. Anteriorly the joint is stabilized by the anterior sacroiliac ligaments comprised of the anterior longitudinal ligament, the anterior SI ligament, and the sacrospinous ligament. Their primary function is to resist upward movement of the sacrum and lateral movement of the ilium. The posterior sacroiliac ligaments are made up of the short and long dorsal sacroiliac ligament, the supraspinous ligament, the iliolumbar ligament, and the sacrotuberous ligament. They function to resist downward and upward movement of the sacrum and medial motion of the ilium. Of note, the long dorsal sacroiliac ligament is believed to be a source of posterior pelvic pain due to the forces transmitted from the SIJ and hip joint to the nociceptors and proprioceptors within the ligament [19]. Anteriorly, the pubic symphysis is another cartilaginous joint between the two pubic bones reinforced by superior, inferior, anterior, and posterior ligaments. Functionally it resists tension, shearing, and compression, and subject to great mechanical stress as it widens during pregnancy.

The deep PFM lining the inner walls of the pelvis are made of the levator ani and coccygeus, which along with the endopelvic fascia comprise the pelvic diaphragm (Table 12.2). The levator ani is composed of three muscles which are the puborectalis, pubococcygeus, and iliococcygeus (Fig. 12.2). Located most anteriorly is the pubococcygeus, which is a main contributor to the levator ani. It originates from both the posterior pubic bone and then anterior portion of the arcus tendineus, it

Table 12.2 Pelvic floor musculature anatomic origins, insertions, innervation, and function

Muscle	Origin	Insertion	Innervation	Function
Puborectalis	Pubic symphysis	Pubic symphysis		Raise the pelvic floor
Pubococcygeus	Posterior pubic bone and arcus tendineus	Anococcygeus ligament and coccyx	S3–5, direct innervation from sacral nerve roots	Maintains floor tone in upright position
Iliococcygeus	Ischial spine and arcus tendineus	Anococcygeal raphe and coccyx		Voluntary control of urination
Coccygeus	Ischial spine	Lower sacral and upper coccygeal bones		Support of fetal head
Piriformis	Anterior sacrum	Posterior-surface greater trochanter	S1–2 via nerve to piriformis	Lateral rotation, abduction of thigh. Retroversion of pelvis
Obturator Internus	Pelvic surface of ilium, ischium, and obturator membrane	Posterior-surface greater trochanter	L5, S1–2 via nerve to obturator internus	Lateral rotator of thigh

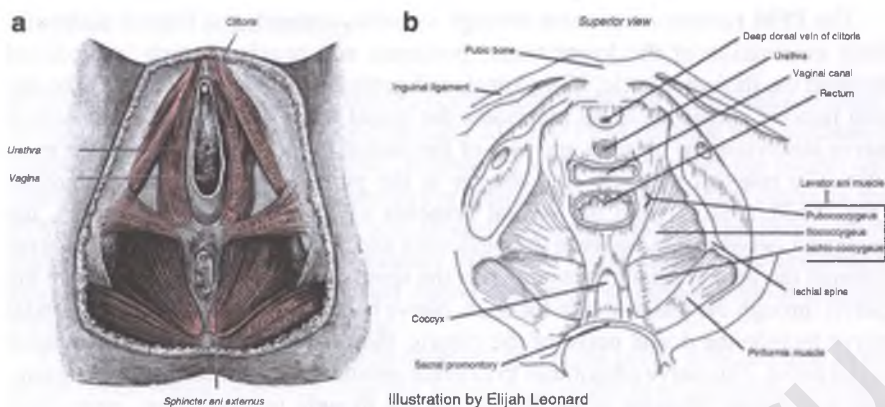


Fig. 12.2 The muscles of the (a) superficial pelvic floor and (b) deep pelvic floor. Illustration by Elijah Leonard. From Prather H, Dugan S, Fitzgerald C, Hunt D. Review of anatomy, evaluation, and treatment of musculoskeletal pelvic floor pain in women. *PM R* 2009; 1:346–358. Reprinted with permission from Elsevier Limited

inserts into the anococcygeus ligament and the coccyx. The iliococcygeus is the posterior part of the levator ani, and is often underdeveloped. It originates from the posterior part of the arcus tendineus and ischial spine and attaches along the anococcygeal raphe and coccyx. Lastly, the puborectalis is located below the pubococcygeus and forms a U-shaped sling around the rectum. Its sphincter-like action pulls the anorectal junction forward contributing to continence. The coccygeus muscle is triangular in shape, reinforcing the posterior pelvic floor by arising from the ischial spine and inserting on the lower sacral-coccygeal bones and is contiguous with the sacrospinal ligament. The perineal body or central perineal tendon is located between the vagina and anus. This is a site where the pelvic muscles and sphincters converge to provide support to the pelvic floor. Rupture of this entity during childbirth can lead to pelvic organ prolapse. The PFM functions to support the pelvic organs by coordinated contraction and relaxation [20]. At rest, the pelvic floor provides active support through muscular activity and passive support from the surrounding connective tissue and fascia. With an increase in intra-abdominal pressure, the PFM contract with upward movement and closure of the vagina, urethral, and anal sphincters. This action is important for maintaining continence. Pelvic floor relaxation returns the muscles to their resting state and allows for normal micturition and defecation.

Lining the lateral walls of the pelvis, the piriformis arises from the anterior sacrum, with the sacrotuberous ligament and attaches on the superior border of the greater trochanter. When the sacrum is fixed the piriformis laterally rotates an extended thigh, or abducts a flexed thigh. If the femurs are fixed it can retrovert the pelvis. The obturator internus, also a lateral rotator of the thigh arises from the pelvic surfaces of the ilium, ischium, and obturator membrane. It too attaches just distally to the piriformis on the greater trochanter.

The PFM receive innervation through somatic, visceral, and central pathways. Skin innervation of the lower trunk, perineum and proximal thigh is mediated through the iliohypogastric, ilioinguinal, and genitofemoral nerves (L1–3). The lateral femoral cutaneous nerve innervates the lateral thigh (L2–3), and the obturator nerve innervates the muscles and skin of the medial thigh (L2–4). Perhaps the most clinically relevant nerve to this chapter is the pudendal nerve and its branches (Fig. 12.3). Arising from the ventral branches of S2–4 of the sacral plexus, the pudendal nerve passes between the piriformis and coccygeal muscle as it traverses through the greater sciatic foramen, over the spine of the ischium and back into the pelvis through the lesser sciatic foramen. Nerve branches arising from the pudendal nerve include the dorsal nerve of the clitoris, the perineal branch, and the inferior rectal nerve. This nerve contributes to external genital sensation, continence, orgasm, and ejaculation. Muscles of the levator ani are thought to have direct innervation from sacral nerve roots S3–5 [21]. Given the complicated course of the pudendal nerve, and its close relationship with the nerves to the levator ani, the susceptibility to injury is increased during vaginal childbirth and urogynecological surgery.

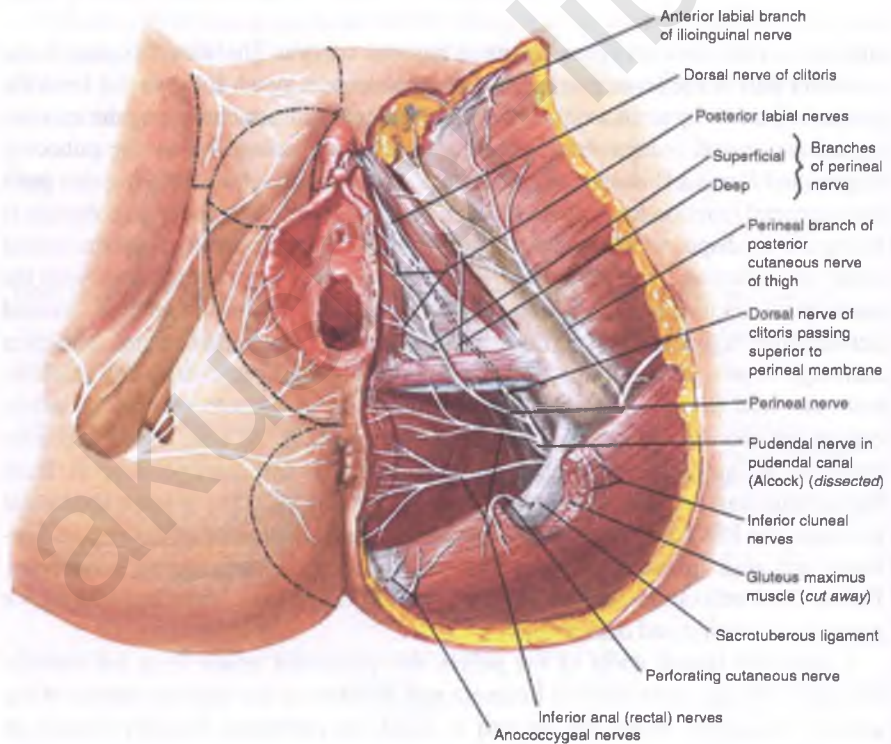


Fig. 12.3 Innervation of the pelvic floor. From Prather H, Dugan S, Fitzgerald C, Hunt D. Review of anatomy, evaluation, and treatment of musculoskeletal pelvic floor pain in women. *PM R* 2009; 1:346–358. Reprinted with permission from Elsevier Limited

Overview of Terminology

In 2005, the International Continence Society (ICS) presented a standardized terminology for PFM function and dysfunction [20]. The PFM function by coordinated contraction and relaxation as a unit. *Voluntary contraction* is when the patient can contract the PFM on demand; *voluntary relaxation* is when the patient can relax the PFM on demand after a contraction. *Involuntary contraction* of the PFM occurs during a rise in intra-abdominal pressure to prevent incontinence, such as during a cough. *Involuntary relaxation* occurs during a strain or Valsalva maneuver to allow for normal micturition or defecation.

Contraction and relaxation can be observed during the pelvic floor physical exam as described below. A *non-contracting pelvic floor* refers to no palpable voluntary or involuntary contraction of the PFM on physical exam. A *non-relaxing pelvic floor* refers to no palpable voluntary or involuntary relaxation of the PFM on palpation during physical exam. A *non-contracting, non-relaxing pelvic floor* means there is neither a palpable contraction nor a palpable relaxation of the PFM on palpation during physical exam. These categories can be helpful for generating a differential diagnosis for possible etiologies of pelvic floor dysfunction (Table 12.1).

Based on examination of PFM contraction and relaxation, the following conditions have been defined by the ICS: *Normal PFM* refers to muscles that can voluntarily and involuntarily contract with normal strength and relax completely. *Overactive PFM* is a condition in which PFM do not relax and may paradoxically contract when relaxation is needed, such as during micturition or defecation. *Underactive PFM* is a condition in which the PFM cannot voluntarily contract when desired. *Nonfunctioning PFM* refer to no palpable PFM action and can be based on a non-contracting, non-relaxing pelvic floor.

History

Women with pelvic floor myofascial pain will report pain that is “deep” and internal. They may report associated symptoms of dysuria, dyschezia, dysmenorrhea, or dyspareunia, but often must be prompted with direct questioning due to the intimate nature of pelvic floor pain. It is often easier for women to report pain in the low back, hips, and legs than the pelvic floor region. Pelvic floor dysfunction should be obtained by inquiring about urinary or bowel incontinence or retention, urinary or bowel urgency or frequency, and any known organ prolapse. Pelvic floor myofascial pain and dysfunction are often related to painful bladder syndrome/interstitial cystitis, urinary urgency/frequency syndrome, and vulvar vestibulitis. A history of related pelvic visceral disorders such as infection, endometriosis, or fibroids should be ascertained as these can be related to pelvic floor pain and dysfunction via the viscerosomatic reflex. History of birth trauma, instrumentation (forceps), prolonged labor, or perineal tears during vaginal delivery may point to injury to the PFM.

A history of abuse—physical, sexual, or emotional—can present as pelvic pain. Finally, a poor response to traditional therapy and treatments for hip and low back pain can often indicate an underlying pelvic floor disorder.

Pelvic Floor Physical Exam

A thorough musculoskeletal exam of the lumbar spine, hips, pelvic girdle, lower limbs, and PFM will guide the differential diagnosis and is reviewed elsewhere (Chap. 4). Of note, the active straight leg raise test, which is a test associated with PGP, may also cause a contraction of the PFM, suggesting the intimate relationship between these pelvic structures in pain syndromes [22]. Trained professionals including physicians, physical and occupational therapists may obtain subspecialty training in the internal musculoskeletal pelvic floor exam. The exam consists of vaginal and rectal examination of the PFM function and a neurological examination of the lower sacral segments. A musculoskeletal pelvic floor exam does not obviate the need for regular gynecologic evaluation, as visceral structures are not evaluated. Verbal consent from the patient is required. The exam should occur in a private exam or treatment room. The musculoskeletal pelvic floor examination is not typically performed during pregnancy and often delayed for at least 6 weeks in the postpartum period.

The exam begins with external inspection for swelling, cysts, scars, and lesions that may necessitate appropriate referral for gynecologic evaluation. Next, the examiner visualizes the lift of the perineal body with a voluntary contraction and involuntary contraction (cough), as well as normal descent of the perineal body with voluntary relaxation and then involuntary relaxation (Valsalva maneuver). The vestibule is evaluated for any visible organ prolapse. The Q-tip test for vulvodynia is performed by lightly touching a cotton swab inside the vestibule to elicit any pain or allodynia. The examiner proceeds to an external sensory exam of the S2–5 sacral dermatomes (Fig. 12.3). An anal wink reflex is obtained near the anus to test the sacral reflex arc. The superficial PFM are palpated for any tenderness.

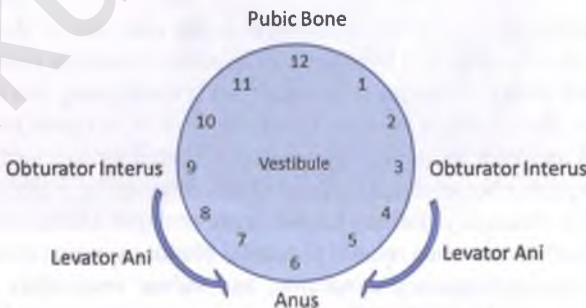


Fig. 12.4 A clock face diagram can be useful for locating the pelvic floor muscles during examination. 12 o'clock is the pubic bone and 6 o'clock is the anus. Levator ani is located from 3 to 5 o'clock on the left and 7 to 9 o'clock on the right. Obturator internus is located just above 3 o'clock on the left and 9 o'clock on the right

Table 12.3 Modified Oxford scale used to grade internal manual muscle testing of the pelvic floor muscles

Grading	Contraction	Lift or tighten
0/5	No	No
1/5	Flicker	No
2/5	Weak	No
3/5	Moderate	Some lifting/tightening, contraction visible
4/5	Good	Holds for 5+ seconds
5/5	Strong	Holds for 10+ seconds

Next, the examiner moves on to the internal pelvic floor examination. One lubricated, gloved finger is inserted into the introitus to palpate the PFM internally. A clock face diagram is useful to correctly identify the anatomic positions of the PFM with the pubic bone at 12 o'clock and the anus at 6 o'clock (Fig. 12.4). Levator ani is located from 3 to 5 o'clock on the left and 7 to 9 o'clock on the right. Obturator internus is located just above 3 o'clock on the left and 9 o'clock on the right, and separated from the levator ani by locating the arcus tendineus, similar to a guitar string on palpation (Fig. 12.2). Obturator internus can also be identified by having the patient externally rotate the hip to activate the muscle. Internally, PFM are palpated for tenderness, taut bands, and referring trigger points. PFM tone can be assessed as either an increased or decreased resting state of the muscle. A Tinel's sign can be obtained by tapping over the pudendal nerve as it courses inferior to the ischial spine and may provoke pelvic floor or perineal paresthesias.

Voluntary contraction of the PFM is felt as a tightening, lifting, and squeezing action under the examining finger that occurs upon demand [20]. Voluntary contraction is graded using the Modified Oxford scale [23]. Similar to manual muscle testing used on limb muscles, the scale ranges from 0/5 which is "absent" to 5/5 which is "lift, tighten and maintain for 10 s" (Table 12.3). Strength testing should be performed in four quadrants, especially in patients with neurologic deficits such as hemiplegia. *Voluntary relaxation* of the PFM is felt as a termination of the contraction as the muscles return to their resting state. The examiner then has the patient cough to look for presence or absence of *involuntary contraction*, and then perform a Valsalva maneuver to look for presence or absence of *involuntary relaxation*. Endurance is tested by asking the patient to hold a full contraction for 10 s. Coordination is tested by performing "quick flicks" or asking the patient to contract and relax the PFM quickly. Finally, the patient is asked to turn on her side to perform a digital rectal exam. Anal sphincter tone is assessed for normal, increased, or decreased tone. PFM may also be palpated internally using the same clock face orientation. The coccyx is palpated internally for pain, mobility, or deviation to one side. Strength and coordination can also be assessed by manual muscle testing, endurance, and quick flicks on the rectal portion of the exam.

Diagnostic Testing

The diagnosis of pelvic floor myofascial pain and dysfunction is made clinically by a combination of a focused history and physical exam. Diagnostic imaging can be useful to aid in ruling out other musculoskeletal causes of lumbopelvic pain [4]. Typically, a conventional pelvic and lumbar radiograph is useful to evaluate the structural integrity of the spine and pelvis; based on physical examination findings, the practitioner may consider the addition of hip radiographs. Musculoskeletal imaging during pregnancy should be limited and typically is not necessary to make the diagnosis (Chap. 3). Magnetic resonance imaging (MRI) of the spine, hip, or pelvis may be useful to rule out serious causes of pelvic pain, including herniated lumbosacral disc, sacral fracture, or transient osteoporosis of pregnancy. Ultrasound is a safe modality in pregnancy, with increasing musculoskeletal applications to evaluate soft tissue, superficial joints, and neural structures.

Treatment

Women with pelvic floor myofascial pain and dysfunction often benefit from an interdisciplinary rehabilitation approach to improve function and reduce pain. Physiatrists, specialists in physical medicine and rehabilitation, with experience in acute and chronic pain, neurologic and musculoskeletal conditions, and neurogenic bowel/bladder management, are well-suited to direct the patient's care. The role of the physiatrist is to summarize the musculoskeletal findings of the history, physical examination, and diagnostic testing and to provide a specific physical therapy prescription [1]. This prescription allows the physiatrist to convey impressions and suggest specific interventions for the pelvic floor as well as other related musculoskeletal structures (e.g., lumbar spine, pelvis, and hip). The rehabilitation provider must be aware of when to consult obstetrics–gynecology, urology, colorectal surgery, gastroenterology, and psychology specialists to provide additional expertise care (Table 12.1).

Pelvic Floor Physical Therapy

Physical therapists (PT) may receive specialty training through the Section on Women's Health from the American Physical Therapy Association, the Herman and Wallace Pelvic Rehabilitation Institute and through women's health residency programs with directed mentorship. A trained women's health PT can perform an internal vaginal and rectal examination that will guide the treatment plan. The goals of therapy are to restore muscle imbalances, improve function, and reduce pain. Therapeutic options for myofascial pain are based upon myofascial release

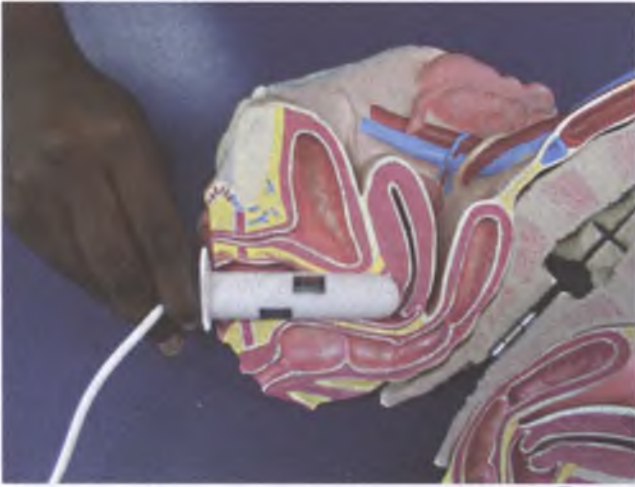

Fig. 12.5 Intravaginal biofeedback may be used during physical therapy to provide objective feedback to the patient about pelvic floor muscle activation and relaxation

techniques combined with neuromuscular reeducation to inactivate trigger points [24]. Soft tissue mobilization can address adhesions, diminish trigger points, and desensitize tissue. Manual techniques for myofascial trigger points include manual release, acupressure, muscle energy, and strain-counterstrain. Because the PFM are intimately related to the anatomic structures of the pelvic girdle, hip, spine, and core musculature, exercises are also prescribed to restore normal movement patterns, joint range of motion, and muscle strength [1].

Adjuvant treatments include the use of vaginal or rectal biofeedback to improve muscle firing patterns in both underactive and overactive PFM by providing the patient with objective feedback about muscle activation at rest and with activities of daily living (Fig. 12.5). Electrical stimulation can be used to increase PFM activity in underactive muscles or provide pain relief in overactive muscles by the use of surface electrodes or vaginal/rectal probes. Unfortunately, there is little evidence-based data to support these modalities particularly in the postpartum period but clinical application is common and becoming more routine. Additionally, many PTs are being trained in dry needling techniques (see Injections below).

Bracing

If there is concurrent PGP, particularly SIJ pain, a trial of a SIJ belt may be useful. The SIJ belt should be worn low over the pelvis to provide additional support to the pelvis and is often useful in later months of pregnancy. However, the utility of bracing in pelvic floor myofascial pain and dysfunction is otherwise limited.

Medications

Medication use in pelvic floor myofascial pain and dysfunction is aimed at reducing pain, treating anxiety, and restoring restful sleep. During pregnancy, medication options may be limited (Chap. 14). Postpartum medications such as nonsteroidal inflammatory medications are often used for acute pain but are often limited from long-term use by gastrointestinal side effects and the risk of bleeding. Tricyclic antidepressants (e.g., nortriptyline) and related medications such as trazodone and cyclobenzaprine may be used to address pain, mood, and sleep in myofascial pain syndromes, but can cause anticholinergic side effects such as dry mouth, constipation, or urinary retention. If there is a neurogenic or central sensitization component, antiepileptics (e.g., gabapentin or pregabalin) or serotonin norepinephrine reuptake inhibitors (SNRI) (e.g., duloxetine or venlafaxine) may also be useful. SNRIs may be better tolerated than antiepileptics due to less sedating side effects. Muscle relaxants (e.g., cyclobenzaprine) may be helpful, especially for painful night-time muscle spasms, but are limited by the side effect of sedation and are not recommended for long-term use. Care should be taken to avoid long-term use of narcotic pain medications. These neuromodulator medication options have not been studied in breastfeeding women and hence not currently utilized. Topical medications are often a helpful adjuvant treatment option, including estrogen creams and topical anesthetics (e.g., lidocaine cream) and can be used in breastfeeding mothers. Antispasmodic medications such as valium or baclofen may be used as an intravaginal suppository or made into a compounded cream. It is often helpful to use intravaginal valium or baclofen before pelvic floor PT, before sexual intercourse, or before going to sleep at night once breastfeeding has ended.

Injections

When the previously mentioned rehabilitation treatment interventions do not provide adequate relief from pelvic floor myofascial pain, injections can be used to reduce pain and increase participation in therapeutic exercises. This option may be considered particularly in breastfeeding women due to its predominant local effect. Combining trigger point injections with manual techniques in PT may provide additional, longer lasting relief. Specific medical management techniques for myofascial trigger points include local anesthetic, botulinum toxin, corticosteroid injections, as well as dry needling [24]. The use of botulinum toxin for trigger point injections remains an off label indication and is not recommended in breastfeeding. If the patient also complains of posterior pelvic pain, a trial of an ultrasound-guided piriformis muscle trigger point injection may be indicated. Cadaveric studies demonstrate that the piriformis and obturator internus muscles are fused in approximately 40 % of people [25], while the combination of piriformis and obturator internus injection provided substantial relief in subjects with posterior pelvic pain [26].

Additionally, fluoroscopic-guided SIJ, pubic symphysis, or hip intra-articular steroid injections may be additional targets to reduce pain and improve function, given the anatomic relationships described above. Injection treatment should be guided by a detailed history and musculoskeletal physical examination to identify potential pain generators. Injection interventions should not be used in isolation, but as part of a comprehensive rehabilitation plan to aid in diagnosis, progress goals in therapy, reduce pain, and improve function.

Complementary Therapies

According to the National Center for Complementary and Alternative Medicine, nearly 40 % of Americans use nonconventional approaches for management of specific conditions or for overall well-being [27]. More than 3.1 million adults in the United States use acupuncture annually [28]. Analgesia with acupuncture has been shown to have sustained depression of dorsal horn neurons in the spinal cord [29]. There is some evidence suggesting that standard treatment with acupuncture is more effective than standard treatment alone for relieving pelvic and back pain in pregnancy [30]. Yoga and pilates are two forms of body conditioning that have a strong focus on mind-body awareness and core strengthening. A 2013 systematic review of yoga for chronic low back pain found evidence for short- and long-term effectiveness in the management of chronic low back pain [31]. There is an increasing focus on incorporating pelvic floor training into these types of therapies, and likewise use of their techniques in standard forms of therapy.

Conclusion

Pelvic floor myofascial pain and dysfunction are common, but treatable, musculoskeletal conditions during and after pregnancy. Understanding the anatomic relationship of the PFM with the pelvic girdle, spine, and hips will aid the rehabilitation provider in diagnosis, management, and appropriate referrals. Pelvic floor myofascial pain and dysfunction are diagnosed mainly by clinical examination of the PFM by specialists in women's health rehabilitation. The treatment consists of pelvic floor PT, medications, bracing, and judicious use of injection therapy, as well as consideration of complementary treatment options.

Disclosures Dr. Eickmeyer: This publication was supported by the National Center for Research Resources and the National Center for Advancing Translational Sciences, National Institutes of Health, through Grant Number 8UL1TR000055. Its contents are solely the responsibility of the authors and do not necessarily represent the official views of the NIH.

References

1. Prather H, Dugan S, Fitzgerald C, Hunt D. Review of anatomy, evaluation, and treatment of musculoskeletal pelvic floor pain in women. *PM R*. 2009;1:346–58.
2. Ashton-Miller JA, Delancey JO. On the biomechanics of vaginal birth and common sequelae. *Annu Rev Biomed Eng*. 2009;11:163–76.
3. Vleeming A, Stoeckart R, Volkers AC, Snijders CJ. Relation between form and function in the sacroiliac joint. Part I: clinical anatomical aspects. *Spine*. 1990;15:130–2.
4. Vleeming A, Albert HB, Ostgaard HC, Sturesson B, Stuge B. European guidelines for the diagnosis and treatment of pelvic girdle pain. *Eur Spine J*. 2008;17:794–819.
5. Pool-Goudzwaard AL. Relations between pregnancy related low back pain, pelvic floor activity and pelvic floor dysfunction. *Int Urogynecol J Pelvic Floor Dysfunct*. 2005;16:468–74.
6. Fitzgerald CM, Mallinson T. The association between pelvic girdle pain and pelvic floor muscle function in pregnancy. *Int Urogynecol J*. 2012;23:893–8.
7. Stuge B, Sætre K, Braekken IH. The association between pelvic floor muscle function and pelvic girdle pain—a matched case control 3D ultrasound study. *Man Ther*. 2012;17(2):150–6. doi:10.1016/j.math.2011.12.004. Epub 2012 Jan 15.
8. Cummings M, Baldry P. Regional myofascial pain: diagnosis and management. *Best Pract Res Clin Rheumatol*. 2007;21:367–87.
9. Simons DG, Travell JG, Simons LS, editors. *Travell & Simons' myofascial pain and dysfunction: the trigger point manual*. Vol. 1: The upper half of body. Vol. 2: The lower extremities. Baltimore: Lippincott Williams & Wilkins; 1992, 1983.
10. Friedrich EG. Vulvar vestibulitis syndrome. *J Reprod Med*. 1987;32:110–4.
11. Fall M, Baranowski AP, Elneil S, Engeler D, Hughes J, Messelink EJ, et al. European Association of Urology. EAU guidelines on chronic pelvic pain. *Eur Urol*. 2010;57:35–48.
12. Zondervan KT, Yudkin PL, Vessey MP, Jenkinson CP, Dawes MG, Barlow DH, et al. Chronic pelvic pain in the community—symptoms, investigations, and diagnoses. *Am J Obstet Gynecol*. 2001;184:1149–55.
13. Burnett RS, Della Rocca GJ, Prather H, Curry M, Maloney WJ, Clohisey JC. Clinical presentation of patients with tears of the acetabular labrum. *J Bone Joint Surg Am*. 2006;88:1448–57.
14. Daniels J, Gray R, Hills RK, Latthe P, Buckley L, Gupta J, et al. Laparoscopic uterosacral nerve ablation for alleviating chronic pelvic pain: a randomized controlled trial. LUNA trial collaboration. *JAMA*. 2009;302:955–61.
15. Nygaard I, Barber MD, Burgio KL, Kenton K, Meikle S, Schaffer J, et al.; Pelvic Floor Disorders Network. Prevalence of symptomatic pelvic floor disorders in US women. *JAMA*. 2008;300:1311–6.
16. Latthe P, Latthe M, Say L, Gülmezoglu M, Khan KS. WHO systematic review of prevalence of chronic pelvic pain: a neglected reproductive health morbidity. *BMC Public Health*. 2006;6:177.
17. Tu FF, As-Sanie S, Steege JF. Prevalence of pelvic musculoskeletal disorders in a female chronic pelvic pain clinic. *J Reprod Med*. 2006;51:185–9.
18. Brynhildsen J, Hansson A, Persson A, Hammar M. Follow-up of patients with low back pain during pregnancy. *Obstet Gynecol*. 1998;91:182–6.
19. Vleeming A, Pool-Goudzwaard AL, Hammudoghlu D, Soeckart R, Snijders CJ, Mens JM. The function of the long dorsal sacroiliac ligament: its implication for understanding low back pain. *Spine*. 1995;21:556–62.
20. Messelink B, Benson T, Berghmans B, Bø K, Corcos J, Fowler C, et al. Standardization of terminology of pelvic floor muscle function and dysfunction: report from the pelvic floor clinical assessment group of the International Continence Society. *NeuroUrol Urodyn*. 2005;24:374–80.
21. Barber MD, Berner RE, Thor KB, Dolber PC, Kuehl TJ, Coates KW. Innervation of the female levator ani muscles. *Am J Obstet Gynecol*. 2002;187:64–71.
22. Stuge B, Sætre K, Ingeborg HB. The automatic pelvic floor muscle response to the active straight leg raise in cases with pelvic girdle pain and matched controls. *Man Ther*. 2013;18(4):327–32. doi:10.1016/j.math.2012.12.004. Epub 2013 Jan 11.

23. Frawley H. Pelvic floor muscle strength testing. *Aust J Physiother.* 2006;52:307.
24. Itza F, Zarza D, Serra L, Gómez-Sancha F, Salinas J, Allona-Almagro A. Myofascial pain syndrome in the pelvic floor: a common urological condition. *Actas Urol Esp.* 2010;34:318–26.
25. Windisch G, Braun EM, Anderhuber F. Piriformis muscle: clinical anatomy and consideration of the piriformis syndrome. *Surg Radiol Anat.* 2007;29:37–45.
26. Dalmau-Carolà J. Myofascial pain syndrome affecting the piriformis and the obturator internus muscle. *Pain Pract.* 2005;5:361–3.
27. National Center for Complementary & Alternative Medicine. Complementary, alternative, or integrative health: What's in a name? National Center for Complementary & Alternative Medicine Website. <https://nccih.nih.gov/health/chiropractic/introduction.htm>. Accessed 11 Feb 2014.
28. National Institutes of Health Consensus Panel. Acupuncture: National Institutes of Health Consensus Development Conference Statement. National Institutes of Health Website. consensus.nih.gov/1997/1997acupuncture107html.htm. Accessed 11 Feb 2014.
29. Sandkuhler J. Learning and memory in pain pathways. *Pain.* 2000;88:113–8.
30. Ee CC, Manheimer E, Pirodda MV, White AR. Acupuncture for pelvic and back pain in pregnancy: a systematic review. *Am J Obstet Gynecol.* 2008;198:254–9.
31. Cramer H, Lauche R, Hiller H, Dobos G. A systematic review and meta-analysis of yoga for low back pain. *Clin J Pain.* 2013;29:450–60.

Chapter 13

Pelvic Pain After Cesarean Section

Allison Bailey

Introduction

From hundreds of medical school lectures, a second year obstetrics talk stands out clearly in my mind. “For the women in the room, you should all request cesarean sections, if you give birth,” stated the gynecologist speaking to us that afternoon. At that time, the late 1990s, delivery by cesarean section had gained sufficient popularity to be placed on a medical pedestal; a straightforward, easy way to avoid the unwanted and unpleasant complications of vaginal birth.

Early reports of cesarean delivery date back to ancient times. According to Greek mythology, Apollo removed his son, Asclepius, the god of medicine, healing, and rejuvenation, from his mother’s abdomen (Fig. 13.1). The procedure’s title is said to originate from the supposed surgical birth of Julius Caesar; however, the truth of this tale has been questioned as Caesar’s mother lived a long postpartum life [1]. Until relatively recently, surgical deliveries were performed solely in the setting of a dead or dying mother in a (typically vain) attempt to save her infant. It wasn’t until the late nineteenth century with dramatic improvements in surgical and anesthetic techniques, that cesarean section was considered as a potentially life-saving procedure for both mother and infant in the case of medical or obstetric complications.

Today, cesarean section is one of the most commonly performed surgical procedures worldwide [2]. The rates of cesarean delivery have increased by over 40 % since 1996 [3]. By 2009, a record high of nearly one-third of all deliveries performed in the United States were by cesarean section [4]. This dramatic increase reflects, in

A. Bailey, MD (✉)

Integrated Health and Fitness Associates, 36 Spinelli Place, Cambridge, MA 02138, USA

Harvard Medical School, Cambridge, MA USA

Department of Medilene, Mount Auburn Hospital,
330 Mount Auburn Street, Cambridge, MA 02138, USA
e-mail: dr.bailey@ihfaboston.com

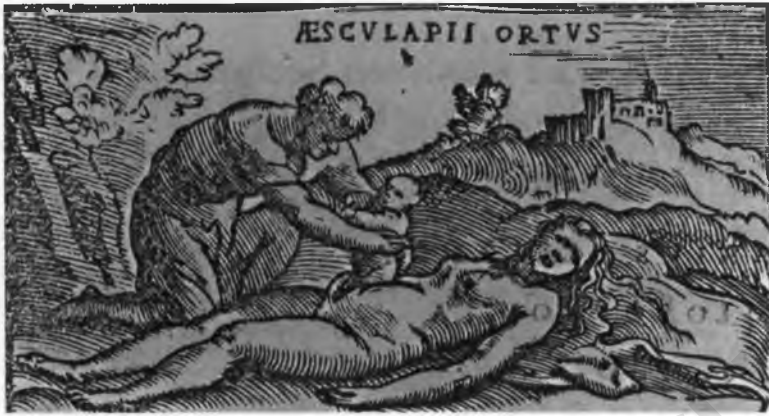

Fig. 13.1 Cesarean birth of Asclepius. Source: National Library of Medicine (NLM)

part, an increase in the rate of surgical delivery by maternal request, without other medical or obstetrical indication, mirroring the attitude of my memorable medical school lecturer. Cesarean delivery on request accounts for 4–18 % of all cesareans. In a survey of 583 Swedish prenatal clinics, 92 of 1,284 (7.2 %) of primiparas preferred cesarean. The only significant predictor in this study was fear of labor (tocophobia) [5]. Multiparous patients, on the other hand, typically requested cesarean due to past adverse experience with previous labor and delivery. In surveys of both obstetricians and midwives conducted in the United Kingdom, New Zealand, Ireland, Canada, and Israel, between 7 and 30 % of obstetricians and 4.4 % of midwives preferred cesarean delivery for themselves or their partners [6]. In addition, 62–81 % of the obstetricians surveyed expressed willingness to perform cesarean based on patient request alone. However, the right of a woman to elect surgical delivery raises important medical, as well as philosophical concerns and remains a debated topic within the field of obstetrics.

Lumbopelvic Pain Postpartum

Of the four million women who give birth in the United States each year, somewhere between 50 and 80 % will experience lumbopelvic pain during pregnancy, and 30 % of pregnant women have pain they rate as severe [7–12]. Pelvic girdle pain is a specific type of low back pain that commonly arises in relation to pregnancy, affecting an estimated one in five women [13]. Traditionally, women have been advised that pain is an inevitable part of pregnancy, and little effort has been made on the part of the medical community to offer prevention or treatment strategies. This “grin and bear it” attitude suggests that pain during pregnancy is normal, not treatable, and will resolve completely after delivery. Yet, current research on pain in pregnancy dispels such beliefs as out-of-date myths that should be relegated to the realm of “old wives’ tales.”

Lumbopelvic pain in pregnancy has significant short-term and long-term consequences. Thirty to fifty percent of women with severe pain will lose time from work or social activities [14, 15]. Of women with severe pain in pregnancy, 20 % will avoid a future pregnancy due to fear of pain [16]. Unfortunately, pregnancy-related pain does not appear to be the time-limited malady it has often been touted to be. Although many women will experience symptom remission after delivery, a significant percentage of women will have pain that persists. The number of women reporting ongoing pain has varied according to study. Larsen reported that 2–3 % of all women had ongoing significant symptoms 1 year after delivery [17]. However, among women with moderate to severe pain during pregnancy, 68 % continued to have pain after delivery [12]. In another study, over 20 % of women at 2 years postpartum reported ongoing pain [18]. Risk factors for persistent pain included severe, early onset pain in pregnancy and inability to return to prepartum weight. Low back pain in the general population is more common in women than in men [19], and 10–15 % of women with chronic back pain relate the onset of their pain issues to pregnancy [20]. In fact, pregnancy appears to be a critical risk factor for low back pain in women, increasing the probability of this disabling condition by at least fourfold [21, 22].

Women who experience pain in pregnancy may be more likely to undergo cesarean delivery. Pubic symphysis pain during pregnancy has been shown to be an independent risk factor for cesarean delivery [23]. In addition, at least one survey indicated pain during pregnancy may be associated with maternal preference for cesarean [24]. Women who experience severe pelvic pain symptoms during pregnancy may be more likely to fear the consequences of vaginal delivery on the pelvis. They may also feel less certain about their ability to deliver vaginally and, therefore, be more likely to request cesarean section. Thus, pelvic girdle pain may in fact be the primary reason for surgical delivery in some women [25]. Despite the perception that surgical delivery would be more apt to protect the pelvis, recent studies examining the prognosis of pelvic girdle pain after delivery, have suggested the opposite [26, 27]. There is growing evidence that cesarean section may be a risk factor for persistent pelvic girdle pain. In addition, cesarean section appears to be associated with an increased risk of pelvic pain of gynecological sources [28, 29] and chronic pain in general [30].

This chapter will review the current literature on cesarean section and chronic pelvic pain of both musculoskeletal and gynecological etiologies. This is an evolving field with a growing body of research. At this time, further studies are needed in order to fully understand the implications of mode of delivery on persistent pain after pregnancy. Potential sources and mechanisms of pelvic pain following cesarean section will be discussed from both neuromusculoskeletal and gynecological perspectives.

Gynecological Pain After Cesarean Section

Chronic pelvic pain is a common, costly, yet poorly understood gynecological problem. The condition can be defined as noncyclic pain in the lower abdomen, groin, upper thighs, or genital region last greater than 6 months [31]. The condition is estimated to affect greater than ten million women in the United States alone and accounts

for healthcare costs greater than \$880 million in doctor visits alone [32]. Chronic pelvic pain is also the reason for 10 % of all gynecologic office visits and 20 % of laparoscopies. Laparoscopy is currently considered the gold standard of diagnostic procedure for chronic pelvic pain. Among the most common findings on laparoscopy in these patients are endometriosis, pelvic adhesive disease, consequences of pelvic inflammatory disease, and uterine fibroids. Sixty one percent of women who undergo diagnostic laparoscopy, however, will remain without a clear diagnosis postoperatively. The pathophysiology of the condition remains incompletely understood and the treatments aimed at ameliorating symptoms are often inadequate. Clearly, prevention, whenever possible, would be the preferable avenue.

With the currently high rate of cesarean section, a correlation of this procedure with chronic pelvic pain is important to investigate. Almeida et al. performed a retrospective case-control analysis on 199 Brazilian women admitted over a 2-year period for either diagnostic laparoscopy for chronic pelvic pain ($n=116$) or for surgical sterilization procedure ($n=83$). A history of cesarean section was observed in 67.2 % of cases and in only 38.5 % of controls. The association between cesarean section and chronic pelvic pain was independent of other findings detected by laparoscopy including endometriosis and sequelae of pelvic inflammatory disease [28]. Latthe et al. performed a systematic literature review to determine risk factors for chronic pelvic pain [29]. Previous cesarean section was one of several risk factors identified for noncyclical chronic pelvic pain. Yet the origin of pain in these studies is not well described. It is likely that many women with chronic pelvic pain after cesarean may have pain of nongynecological origin that emanates from myofascial structures or represents centralized pain syndromes. However, what remains unclear is how previous cesarean section may increase risk of pain directly of gynecological origin.

One potential mechanism for postcesarean gynecological pain is cesarean scar defects which have recently been recognized as a potential source of abnormal uterine bleeding and other gynecologic complications including pelvic pain, infertility, and cesarean scar ectopic pregnancy [33]. Many previous studies have demonstrated an association between abnormal uterine bleeding and cesarean section [34–37]. The proposed mechanism for abnormal uterine bleeding and cesarean scar defect is the presence of a pouch or “isthmocele” in the uterus. However, these defects have been identified in asymptomatic patients as well. It has been proposed that in some women, the isthmocele may predispose to chronic inflammation that may give rise to abnormal bleeding as well as pain.

A major challenge in determining the significance of cesarean scar defects has been the absence of consensus on appropriate diagnostic criteria. A scar defect is typically defined as thinning of the myometrium or a triangular defect in the myometrium identified on transvaginal ultrasound or saline infusion sonohysterography. However, the degree of thinning that defines a defect is not universally accepted. Some researchers have advocated for the degree of deficiency to be defined by the ratio of the myometrial thickness at the scar to the thickness of adjacent myometrium with a ratio of 50 % being considered severe deficiency [38]. Others have defined a large defect as remaining myometrial thickness of 2.2 mm on TVUS or 2.5 mm on the sonohysterogram. These numbers were determined on the basis of

correlation between objective measurements and subjective ultrasound examiner perception [39]. The risk factors for developing a cesarean scar defect remain under investigation. Possible risk factors for cesarean scar defect are summarized in Box 13.1 below and include those with supporting evidence and those still under investigation [33].

The clinical significance of cesarean scar defects remains unclear. In one retrospective study, 76 out of 92 patients with findings of a defect on transvaginal ultrasound had abnormal uterine bleeding [35]. In another study, the size of the defect was shown to be significant, with larger defects more likely to result in clinical symptoms [36]. Morris examined uterine specimens in 51 subjects with prior cesarean section who had undergone hysterectomy with an attempt to correlate pathological finding with clinical symptoms that had led to hysterectomy [40]. There was distortion of the lower uterine segment in 75 %, congested endometrium “overhanging” the scar in 61 %, polyp formation within the scar in 16 %, significant lymphocytic infiltration in 65 %, residual suture material with giant cell reaction in 92 %, capillary dilatation in 65 %, free red blood cells suggesting recent hemorrhage in 59 %, and adenomyosis confined to the vicinity of the scar in 28 %. These findings suggest that cesarean scar defects could give rise to clinical symptoms such as abdominopelvic pain, dyspareunia, and dysmenorrhea. In a cross-sectional study by Wang et al., 53.1 % of women with a cesarean scar defect had dysmenorrhea and 39.6 % had chronic pelvic pain [36]. These symptoms could possibly be explained by the lymphocytic infiltration and anatomical distortion documented at pathologic examination [40]. Cesarean section scars have also been suggested as a potential site for implantation of endometriosis.

Box 13.1 Risk Factors for Chronic Postsurgical Pain After Cesarean*

- High somatization score
- Back pain
- Migraines
- Menstrual pain
- Scar hyperalgesia from prior cesarean
- Genetic susceptibility (ABCB1)
- General anesthesia
- Emergency delivery
- Repeat incision >2
- Length of Pfannenstiel incision
- Uterine exteriorization
- Closure of peritoneum
- Acute postoperative pain
- Postpartum depression

*From Landau R, Bollag L, Ortner C. Chronic pain after childbirth. *Int J Obstet Anest* 2013;22:133–145. Reprinted with permission from Elsevier Limited.

Endometriosis has been reported in 15–44 % of reproductive aged women who undergo laparoscopy or laparotomy [41]. Cesarean section scars have been described as the most common site of anterior abdominal or pelvic wall endometriosis with an estimated incidence of 0.03–0.4 % of all women [42].

Cesarean section scars can be treated by surgical resection with a variety of techniques. Currently, recommendations are for surgical management only in symptomatic patients, rather than for prevention purposes in those without symptoms [33]. Although recognizable on transvaginal ultrasound, saline-infused sonography better delineates the defects and is the recommended diagnostic procedure for the purpose of surgical planning [43]. Cesarean scar defects should be considered in the differential diagnosis for women with a history of cesarean section who present with symptoms of abnormal uterine bleeding, pelvic pain, or infertility.

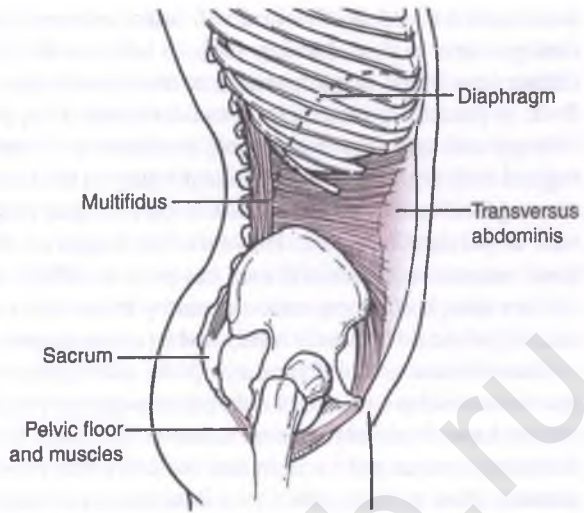
Musculoskeletal Pain After Cesarean Section

Lumbopelvic pain is a specific type of low back pain that often arises in association with pregnancy and the postpartum period [13]. It is believed to arise from a combination of hormonal and biomechanical factors [44]. These changes act to disrupt the physiological and structural integrity of the body's center or "core." The center of gravity of the human body in anatomic position resides within the pelvis, anterior to the second sacral vertebrae [45]. This is the theoretical location that represents the balance point of the body within a gravitational field (the point around which the body will be balanced when acted upon by Earth's gravity). This center is, therefore, the region from which all functional and athletic activities of the body arise. Disruption of this center and resultant faulty biomechanics may be one mechanism to explain pain of the pelvic girdle and lumbosacral spine.

The stability of any body area or joint can be thought of as a balance between two aspects of stability, form, and force closure [46]. Form closure is composed of the intrinsic properties of a joint such as its shape, friction between its surfaces, and relative integrity of the joint capsule and ligaments that provide a passive aspect of stability. Force closure is the active component of stability, composed primarily of factors extrinsic to the joint, primarily the strength and coordination of the muscle groups acting upon that area. When there is a decrease in form closure of a joint (or in the case of the pelvis a group of joints), stability must be gained through alternate strategies, often by an increase in force closure of the muscle groups involved. However, these muscles may then be vulnerable to overuse conditions that may result in myofascial pain.

When investigating pelvic girdle pain in relation to mode of delivery, it is critical to consider the effect that vaginal versus surgical delivery has on key muscle groups involved in pelvic girdle stabilization. The pelvic girdle is composed of three joints (the anterior pubic symphysis and the posterior sacroiliac joints), and their associated supporting ligamentous and myofascial structures. The inner muscle group that provides stability to the pelvis includes the transversus abdominis, pelvic floor muscles,

Fig. 13.2 The deep stabilizing muscles of the pelvic girdle include the multifidus, transverse abdominus, and the pelvic floor muscles. From Magee D. *Pelvis*. In: *Orthopedic Physical Assessment*. Philadelphia: Elsevier Sciences; 2002; p 570. Reprinted with permission from Elsevier Limited



and multifidus (Fig. 13.2). Richardson showed that independent transversus abdominis contraction decreased laxity of the sacroiliac joints to a significantly greater degree than the decrease in laxity seen with a more general bracing action using all the lateral abdominal muscles [47]. The pelvic floor muscles have also been shown to contribute to sacroiliac joint stiffness. In an EMG study of the pelvic floor muscles during arm movements, pelvic floor contraction occurred in anticipatory fashion to contribute to postural stability prior to arm movement [48]. The pubic symphysis is a fibrocartilaginous joint stabilized by anterior and posterior ligaments. Surrounding muscular attachments include the rectus abdominis muscle superiorly and the adductor longus muscle inferiorly [49]. An aponeurosis surrounds the joint and these muscular attachments. Injury to the aponeurosis, the attachments of these muscles or to the joint itself (osteitis pubis) has been demonstrated on magnetic resonance imaging in the syndrome of athletic pubalgia [50].

The following sections will explore the potential differing effects of vaginal and cesarean delivery on the integrity and function of the pelvic floor and abdominal muscles. The intention is to propose *potential hypotheses* for persistent pelvic girdle pain after cesarean section in particular.

Pelvic Floor Muscle Dysfunction

Pelvic floor muscle trauma is a known complication of vaginal birth. In computer simulations of vaginal delivery based on pelvic floor MRI data the pubococcygeal portion of the levator ani muscle demonstrates a stretch ratio of 3.26 times its normal length, over 217 % greater than the largest noninjurious stretch observed in skeletal muscle in nonpregnant individuals [51]. It is, therefore, not surprising that

an estimated 10–15 % of women will suffer serious injuries to the levator ani muscle during a first vaginal delivery [52]. In addition to direct muscle trauma, vaginal delivery can result in compression and/or stretch injury to the nerves of the pelvic floor. In particular, stretch injury to the branch of the pudendal nerve supplying the external anal sphincter is one likely mechanism of anal incontinence resulting after vaginal delivery [53]. Neuromuscular injury to the pelvic floor may result in symptoms of fecal or urinary incontinence, pelvic organ prolapse, sexual dysfunction, as well as pelvic girdle pain. However, the long-term effect of vaginal delivery on these symptoms particularly pain has proven difficult to quantify. Despite the lack of clear data, a common reason given by those who request cesarean is the avoidance of pelvic floor muscle injury and its consequences.

Incontinence is a common symptom after pregnancy. However, whether this association is due to mode of delivery or pregnancy itself remains unclear. Multiple studies have documented an association with both urinary and anal incontinence following forceps and vacuum-assisted deliveries [54–57]. This must be taken into account when studying this topic. Retrospective studies have commonly excluded patients with complicated vaginal deliveries or late cesareans occurring long after the onset of labor, instead comparing those with normal vaginal deliveries to those undergoing elective cesareans only [58]. In order to fully quantify the effects of vaginal delivery on the pelvic floor and on symptoms such as incontinence, the full spectrum of consequences of both modes of delivery must be examined in an intention-to-treat manner [59]. In addition, some variation in the rate of incontinence is expected to occur according to the length of time after delivery. The ideal postpartum time point at which to study symptoms of pelvic floor dysfunction is unclear. Studies may be difficult to compare as they have occurred at variable times after delivery, resulting in varying rates of persistent incontinence.

Studies on the risk of vaginal delivery on urinary incontinence (UI) vary. In a large primiparous sample in Nova Scotia at 6 months postpartum, the overall incidence of UI was 26 and 4 % demonstrated daily incontinence episodes. The rates of UI were found to vary by mode of delivery as follows; spontaneous vaginal delivery 22 %, forceps delivery 33 %, and cesarean 10 % [60]. At 1 year after delivery, another study found nonsignificant differences in UI in women who underwent spontaneous vaginal delivery versus those who underwent cesarean for obstructed labor [61]. However, those having forceps or vacuum deliveries were excluded from this analysis. Though, some epidemiologic studies have suggested that these differences become insignificant over time and that the long-term risk for UI may not vary based on mode of delivery [57, 62]. A large cohort study of Norwegian women aged 20–65 examined women who were either nulliparous, or had undergone only vaginal delivery or only cesarean section. The rates of UI were 10.1 % in nulliparous, 15.9 % after cesarean, and 21 % after vaginal delivery [62]. However, in the 50–64-year-old age group there was no difference in UI rates in those who had vaginal versus surgical delivery.

Anal incontinence also occurs to variable degrees after vaginal delivery. Without documented sphincter injury about 1.5 % of women develop persistent flatal incontinence after a first vaginal delivery. In the early postpartum period

(6 weeks postbirth) one cohort study found 19 % of 200 women to have some degree of anal incontinence after normal vaginal delivery (6.5 % were isolated flatal incontinence) [63]. In the setting of overt perineal injury (third- and fourth-degree lacerations), rates of persistent anal incontinence range from 8 to 59 % [64–66]. Risk factors for third-degree lacerations include forceps delivery (RR 13.3), vacuum delivery (RR 7.4), primiparity (RR 7), birth weight greater than 4,000 g (RR 29), and occipitoposterior position (RR 4) [54, 67, 68]. Again, in long-term studies the effects of vaginal delivery on anal incontinence have been questioned [69, 70]. Among 271 pairs of sisters, mode of delivery was not found to be a significant risk factor for anal incontinence. Menopause, body mass index, parity greater than two, and stress urinary incontinence were the only significant risk factors for anal incontinence in the group studies [71]. Several studies have examined occult sphincter injuries diagnosed by endoanal ultrasound in the setting of an intact perineum [71–75]. Meta-analysis has revealed the incidence of occult sphincter injuries in primiparas to be 26.9 % and of new injuries in multiparous to be 8.5 % [76]. The long-term consequences of these injuries remain under investigation.

Pudendal nerve injuries can also give rise to symptoms of anal incontinence. Whether or not this is a direct effect of vaginal delivery is unclear. Pudendal nerve terminal motor latencies have been shown to increase with labor [65]. Cesarean section in late labor has been shown to be a risk factor for pudendal nerve injuries. Only cesarean prior to labor has been shown to be protective against pudendal neuropathy [77]. However, in a systematic review aimed to investigate the ability of cesarean to protect against anal incontinence, Nelson et al. concluded that cesarean delivery alone is insufficient to prevent anal incontinence [58].

Pelvic organ prolapse is a potential long-term complication of vaginal delivery and vaginal delivery is considered the strongest risk factor for prolapse. Again, cesarean section in the second stage of labor has not shown any protective benefit in preventing pelvic organ prolapse [78]. The Pelvic Organ Support Study demonstrated that a single vaginal delivery increases the risk of prolapse by 1.2 times [79]. The risk of pelvic organ prolapse increases with each subsequent vaginal delivery with women after two vaginal deliveries with 8.4 times the risk [80].

Dyspareunia may also occur after childbirth, but in most cases resolves within 6 months of delivery. Forty-six percent of 655 women surveyed experienced dyspareunia during first intercourse postpartum [81]. Persistence longer than 6 months occurred more commonly in women who had episiotomies (10 %) or instrumented vaginal deliveries (14 %), whereas only 3.4 % of women with normal vaginal or cesarean section delivery had ongoing dyspareunia [81]. In another study of 484 women, at 3 months the rate of dyspareunia was higher in those who had vaginal delivery as compared to cesarean but at 6 months postpartum the rates were the same [82].

Although vaginal delivery has been implicated in playing a major role in pelvic floor muscle trauma, the long-term effects on the majority of known symptoms of pelvic floor muscle dysfunction are less clear. Parity alone does appear to have some effect on pelvic floor muscle dysfunction. In addition, some of the potential protection to the pelvic floor offered by cesarean section does not seem to be true for

cesarean performed after the onset of labor. With the information currently available to us, any modest protective effect of cesarean on pelvic floor muscle function must be weighed carefully against the potential risks of elective cesarean. Most discussions of cesarean section risk have focused on surgical risks to the mother and infant. However, with recent research implicating cesarean delivery as a risk factor for chronic pelvic girdle pain, the musculoskeletal and biomechanical consequences of this common operative procedure must also be considered.

Role of Abdominal Muscles

In addition to the pelvic floor muscles, the abdominal muscles provide significant stabilization function to the pelvic girdle. There is a surprising and glaring paucity of data on the effect of pregnancy and, in particular, mode of delivery on postpartum abdominal muscle structure and function. Conflicting reports exist regarding whether or not abdominal muscles are significantly weakened by pregnancy. This is partially due to the hesitation of performing abdominal strengthening maneuvers during pregnancy and the immediate postpartum, and discrepancy about the best test for measuring this. For example, Gilleard and colleagues found that the ability to contract the abdominal muscles in order to perform and maintain a posterior pelvic tilt was a superior measure of abdominal muscle strength and function in pregnancy and postpartum than an abdominal curl-up exercise. They measured both rectus abdominis muscle diastasis distance, as well as function of the abdominal muscles in six subjects prior to, during, and after pregnancy. They found that separation occurred in the majority of subjects between 18 and 38 weeks of pregnancy, and the ability to perform the posterior pelvic tilt diminished in half of subjects by week 26 and in all subjects by week 30. These changes persisted at the 8 weeks postpartum examination [83]. Fast et al. showed that the abdominal muscles in the third trimester were weakened relative to the abdominal muscles of nonpregnant control subjects [84]. Another study demonstrated a correlation between rectus diastasis and decreased abdominal muscle function, which improved but not to baseline at 6 months postpartum [85]. Deconditioning, in general, appears to be a problem associated with pregnancy. However, very few studies have tried to measure changes in physical fitness before and after pregnancy and the majority of these have focused on aerobic fitness alone, excluding other measures of fitness such as muscle strength [86, 87]. The limited evidence available suggests that pregnancy decreases both aerobic fitness and muscle strength. Treuth et al. examined 124 moderately active women and obtained measures of physical fitness before and after delivery, finding decreases in both VO_2 max as well as upper and lower body strength measures that were not completely regained by 27 weeks postpartum. However, abdominal muscle strength was not measured in this study and mode of delivery was not taken into account [88].

Rectus abdominis muscle diastasis, also known as diastasis recti abdominis (DRA), can be defined as the stretching and thinning of the linea alba, a condition

commonly associated with pregnancy. DRA affects approximately 66 % of women in their third trimester of singleton gestation. The presence of DRA is a common finding in women with pelvic floor muscle dysfunction [89]. In this study, patients presenting with DRA were older, had a higher gravity and parity, and had weaker pelvic floor muscles than patients without the condition. It is not clear if DRA is a risk factor for pelvic floor dysfunction or if the two conditions commonly arise due to another common risk factor (i.e., pregnancy). Increased parity has been shown to be a risk factor for diastasis recti [90]. Whereas, in primiparas mode of delivery does not appear to significantly increase the risk for DRA, repeat cesarean section has been demonstrated to increase the risk, although more studies are needed to answer this question definitively [90].

Few studies have examined abdominal muscle function after cesarean section. Pereira et al studied 81 women divided into four groups: healthy nulliparous women, primigravid pregnant women at 24 weeks or more of gestation, primiparous postpartum women after vaginal delivery and primiparous postpartum women after cesarean section. On surface EMG during voluntary isometric contraction, the nulliparous women were the only group to demonstrate co-activation of the pelvic floor muscles, transversus abdominis, and internal oblique muscles. The pattern was altered in the pregnant and postpartum women regardless of mode of delivery [91].

Recently, there has been interest within the physical therapy community in addressing DRA. One small case-control study showed increased inter-rectus distance as measured by ultrasound in a postpartum group versus nulliparous group. Performing isometric contraction of the abdominal muscles significantly decreased the inter-rectus distance [92]. Mode of delivery was not examined. Benjamin et al. performed a systematic review of nonsurgical, exercise-based interventions for preventing or treating DRA. They identified eight studies enrolling 336 women during the pregnancy or postpartum time periods. The papers were of poor methodological quality, but suggested that targeted abdominal muscle exercise may help reduce DRA during pregnancy or postpartum [93]. Again, mode of delivery was not examined as an important variable.

Given the known importance of the transversus abdominis muscle in providing stabilization to the pelvic girdle [47], one potential mechanism by which cesarean section may increase the risk of pelvic girdle pain is through adverse effects on the abdominal muscles. It is unclear how surgical delivery would exert its adverse effects but possible means include increasing DRA, decreasing overall abdominal muscle strength, adverse sensory/proprioceptive effects, or through exerting an inhibitory effect on lower abdominal muscle recruitment. At this time, further studies with larger sample sizes are needed to confirm or refute this hypothesis and to examine these proposed mechanisms. Another interesting area for study would be to examine the effect of a variety of cesarean section incisions and closure techniques on subsequent abdominal muscle function and pelvic girdle pain. Although the Joel-Cohen incision has shown some advantages over the Pfannenstiel incision in terms of fever and acute postoperative pain, the long-term morbidity and mortality of these different techniques remain unclear at this time [94].

Chronic Postsurgical Pain and Cesarean Section

Chronic postsurgical pain (CPSP) is known to occur to variable degrees after surgical procedures and the rate appears to be procedure specific (Table 13.1) [95]. The definition of CPSP includes the following criteria; pain that occurs after a surgical procedure, pain that lasts at least 2–3 months, other causes of pain such as chronic infection are excluded, and pain is not due to a preexisting painful condition aggravated by the surgery [96]. The mechanisms by which CPSP is proposed to occur include peripheral and central sensitization. Compared to other commonly performed surgical procedures, the incidence of CPSP after cesarean is relatively low, suggesting that pregnancy may confer a protective effect on these mechanisms [95]. However, Almeida et al reported that a history of cesarean delivery may be a risk factor for chronic pelvic pain [28]. Whereas, the presence of adhesions did not appear to increase the risk of chronic pelvic pain in this study implicating another mechanism.

Factors related to surgical technique may also play a role in CPSP after cesarean section. Although the Pfannenstiel incision has been favored for its esthetic benefits and low incidence of incisional hernias, this technique has now been recognized as a possible source of CPSP due to the relatively higher incidence of nerve entrapment syndromes of the iliohypogastric or ilioinguinal nerves [97]. The most common location for chronic incisional pain after Pfannenstiel has been shown to occur at most the lateral portions of the incision particularly when extended beyond the lateral edges of the rectus sheath [95]. Other surgical techniques requiring further study in terms of their effect on CPSP after cesarean include peritoneal closure, single versus double uterine closure, and uterine exteriorization [95]. Besides operative variables, a variety of risk factors for chronic pain after cesarean have been identified (see Box 13.1).

A variety of management techniques have been evaluated for prevention and treatment of chronic postoperative cesarean pain. A major problem in terms of prevention is the ability to identify women who are at risk. Therefore, further research on risk factors is needed. In general, improving the management of acute postoperative pain is believed to help in prevention of that pain becoming chronic. Among the treatment strategies for postcesarean pain believed to help prevent CPSP are intrathecal clonidine, wound infiltration, transversus abdominis plane block, intravenous

Table 13.1 Incidence of chronic postsurgical pain by procedure

Procedure	Estimated incidence of chronic pain (%)
Amputation	30–50
Breast surgery	20–30
Thoracotomy	30–40
Inguinal hernia repair	10
Coronary artery bypass	30–50
Cesarean delivery	10

From Landau R, Bollag L, Ortner C. Chronic pain after childbirth. *Int J Obstet Anest* 2013;22:133–145. Reprinted with permission from Elsevier Limited

magnesium sulfate, intravenous ketamine, and oral gabapentin and pregabalin [95]. Although these treatments are promising, there remains much variation in terms of when these are applied and ongoing debate regarding how long-term pain is expected to persist after delivery, particularly after cesarean section.

Conclusion

Only recently has attention been drawn to the issue of lumbopelvic pain in pregnancy and postpartum. Therefore, it is not surprising that relatively little is known at this time regarding the effect of mode of delivery on the persistence or occurrence of pelvic girdle pain after delivery. However, given the recent suggestion that cesarean delivery may increase the risk of chronic pelvic pain and the very high current rate of cesarean delivery, research into this association is essential. This chapter has proposed both musculoskeletal and gynecological potential mechanisms for chronic pain after cesarean. However, in both areas of expertise, data is currently lacking and research into potential mechanisms, as well as prevention and treatment strategies, is desperately needed. Hopefully, texts such as this will increase the recognition of the need for further research in the area of pain and pregnancy and postpartum.

References

1. <https://www.nlm.nih.gov/exhibition/cesarean/index.html>
2. Kainu JP, Sarvela J, Tippiana E, et al. Persistent pain after cesarean section and vaginal birth: a cohort study. *Int J Obstet Anesth.* 2010;19:4–9.
3. Menacker F, Declercq E, Macdorman MF. Cesarean delivery: background, trends, and epidemiology. *Semin Perinatol.* 2006;30:235–41.
4. Martin J, Hamilton BE, Ventura SJ, et al. Births: final data for 2009. *Natl Vital Stat Rep.* 2011;60:1–70.
5. Hildingsson I, Radestad I, Rubertson C, et al. Few women wish to be delivered by cesarean section. *BJOG.* 2002;109:618–23.
6. Wax J, Cartin A, Pinette MG, et al. Patient choice cesarean: an evidence-based review. *Obstet Gynecol Surv.* 2004;59:601–16.
7. Berg G, Hammar M, Mollernielsen J, et al. Low-back pain during pregnancy. *Obstet Gynecol.* 1988;71:71–5.
8. Ostgaard HC, Andersson GBJ, Karlsson K. Prevalence of back pain in pregnancy. *Spine.* 1991;16:549–52.
9. Wang SM, Dezinno P, Maranets I, et al. Low back pain during pregnancy: prevalence, risk factors, and outcomes. *Obstet Gynecol.* 2004;104:65–70.
10. Mogren IM, Pohjanen AI. Low back pain and pelvic pain during pregnancy—prevalence and risk factors. *Spine.* 2005;30:983–91.
11. Kristiansson P, Svardsudd K. Discriminatory power of tests applied in back pain during pregnancy. *Spine.* 1996;21:2337–43.
12. Stapleton DB, MacLennan AH, Kristiansson P. The prevalence of recalled low back pain during and after pregnancy: a South Australian population survey. *Aust N Z J Obstet Gynaecol.* 2002;42:482–5.

13. Vleeming A, Albert HB, Ostgaard HC, et al. European guidelines for the diagnosis and treatment of pelvic girdle pain. *Eur Spine J*. 2008;17:794–819.
14. Noren L, Ostgaard S, Nielsen TF, et al. Reduction of sick leave for lumbar back and posterior pelvic pain in pregnancy. *Spine*. 1997;22:2157–60.
15. Kristiansson P, Svardstudd K, von Schoultz B. Serum relaxin, symphyseal pain, and back pain during pregnancy. *Am J Obstet Gynecol*. 1996;175:1342–7.
16. Brynhildsen J, Hansson A, Persson A, et al. Follow-up of patients with low back pain during pregnancy. *Obstet Gynecol*. 1998;91:182–6.
17. Larsen EC, Wilken-Jensen C, Hansen A, et al. Symptom-giving pelvic girdle relaxation in pregnancy, I: prevalence and risk factors. *Acta Obstet Gynecol Scand*. 1999;78:105–10.
18. To WWK, Wong MWN. Factors associated with back pain symptoms in pregnancy and the persistence of pain 2 years after pregnancy. *Acta Obstet Gynecol Scand*. 2003;82:1086–91.
19. Treaster DE, Burr D. Gender differences in prevalence of upper extremity musculoskeletal disorders. *Ergonomics*. 2004;47:495–526.
20. Svensson HO, Andersson GBJ, Hagstad A, et al. The relationship of low back pain to pregnancy and gynecological factors. *Spine*. 1990;15:371–5.
21. Wijnhoven HA, de Vet HC, Smit HA, et al. Hormonal and reproductive factors are associated with chronic low back and chronic upper extremity pain in women—the MORGEN study. *Spine*. 2006;31(13):1496–502.
22. Frymoyer JW, Pope MH, Costanza MC, et al. Epidemiologic studies of low-back pain. *Spine*. 1980;5(5):419–23.
23. Lebel DE, Levy A, Holcberg G, et al. Symphysiolysis as an independent risk factor for cesarean delivery. *J Matern Fetal Neonatal Med*. 2010;23:417–20.
24. Kringeland T, Daltveit AK, Moller A. What characterizes women in Norway who wish to have a cesarean section? *Scand J Public Health*. 2009;37:364–71.
25. Fitzgerald CM. Pregnancy-related lumbopelvic pain: what have we learned? *Am J Obstet Gynecol*. 2013;208:242.
26. Bjelland EK, Stuge B, Vangen S, et al. Mode of delivery and persistence of pelvic girdle syndrome 6 months postpartum. *Am J Obstet Gynecol*. 2013;208:298.e1–7.
27. Mukkannavar P, Desai BR, Mohanty U, et al. Pelvic girdle pain after childbirth: the impact of mode of delivery. *J Back Musculoskelet Rehabil*. 2013;26:281–90.
28. Almeida EC, Nogueira AA, Candido dos Reis FJ, Rosa e Silva JC. Cesarean section as a cause of chronic pelvic pain. *Int J Gynaecol Obstet*. 2002;79:101–4.
29. Latthe P, Mignini L, Gray R, et al. Factors predisposing women to chronic pelvic pain: systematic review. *BMJ*. 2006;332:749–55.
30. Nikolajsen L, Sorensen HC, Jensen TS, et al. Chronic pain following cesarean section. *Acta Anaesthesiol Scand*. 2004;48:111–6.
31. Beard RW. Chronic pelvic pain. *Br J Obstet Gynaecol*. 1998;105:8–10.
32. Kuppermann M, Liberman RF, et al. Chronic pelvic pain: prevalence, health-related quality of life, and economic correlates. *Obstet Gynecol*. 1996;87:312–27.
33. Tower AM, Frishman GN. Cesarean scar defects: an underrecognized cause of abnormal uterine bleeding and other gynecologic complications. *J Minim Invasive Gynecol*. 2013;20:562–72.
34. Belinda Centeio L, Scapinelli A, Depes D, Lippi U, Lopes R. Findings in patients with postmenstrual spotting with prior cesarean section. *J Minim Invasive Gynecol*. 2010;17:361–4.
35. Fabres C, Aviles G, De La Jara C, et al. The cesarean delivery scar pouch: clinical implications and diagnostic correlation between transvaginal sonography and hysteroscopy. *J Ultrasound Med*. 2003;22:695–700.
36. Wang CB, Chiu WW, Lee CY, et al. Cesarean scar defect: correlation between Cesarean section number, defect size, clinical symptoms and uterine position. *Ultrasound Obstet Gynecol*. 2009;34:85–9.
37. Uppal T, Lanzarone V, Mongelli M. Sonographically detected caesarean section scar defects and menstrual irregularity. *J Obstet Gynaecol*. 2011;31:413–6.

38. Ofili-Yebovi D, Ben-Nagi J, Sawyer E, et al. Deficient lower-segment cesarean section scars: prevalence and risk factors. *Ultrasound Obstet Gynecol.* 2008;31:72–7.
39. Vikhareva Osser O, Valentin L. Risk factors for incomplete healing of the uterine incision after caesarean section. *BJOG.* 2010;117:1119–26.
40. Morris H. Surgical pathology of the lower uterine segment cesarean section scar: is the scar a source of clinical symptoms? *Int J Gynecol Pathol.* 1995;14:16–20.
41. Blanco RG, Parithivel VS, Shah AK, et al. Abdominal wall endometriomas. *Am J Surg.* 2003;185:596–8.
42. Gidwaney R, Badler RL, Yam BL, et al. Endometriosis of abdominal and pelvic wall scars: multimodality imaging findings, pathologic correlation, and radiologic mimics. *Radiographics.* 2012;32:2031–43.
43. Thurmond AS, Harvey WJ, Smith SA. Cesarean section scar as a cause of abnormal vaginal bleeding: diagnosis by sonohysterography. *J Ultrasound Med.* 1999;18:13–6.
44. O'Sullivan PB, Beales DJ. Diagnosis and classification of pelvic girdle disorders-Part 1: a mechanism based approach within a biopsychosocial framework. *Man Ther.* 2007;12:86–97.
45. Kerrigan DC, Annaswamy TM. Biomechanical correlates of movement: principles of gait. In: Frontera W, Dawson DM, Slovik DM, editors. *Exercise in rehabilitation medicine.* Champaign: Human Kinetics; 1999. p. 23–39.
46. Magee D. Pelvis. In: Magee D, editor. *Orthopedic physical assessment.* Philadelphia: Elsevier Sciences; 2002. p. 567–605.
47. Richardson CA, Snijders CJ, Hides JA, et al. The relation between the transversus abdominis muscles, sacroiliac joint mechanics and low back pain. *Spine.* 2002;27:399–405.
48. Hodges PW, Sapsford R, Pengel LHM. Postural and respiratory functions of the pelvic floor muscles. *NeuroUrol Urodyn.* 2007;26:362–71.
49. Willard F. The neuroanatomy of female pelvic pain. In: Bailey A, Bernstein C, editors. *Pain in women: a clinical guide.* New York: Springer; 2013.
50. Zoga AC, Kavanagh EC, Omar IM, et al. Athletic pubalgia and the “sports hernia”: MR imaging findings. *Radiology.* 2008;247:797–807.
51. Lien KD, Mooney B, DeLancey JOL, et al. Levator ani muscle stretch induced by simulated vaginal birth. *Obstet Gynecol.* 2004;103:31–40.
52. Ashton-Miller JA, DeLancey JOL. *Annu Rev Biomed Eng.* 2009;11:163–76.
53. Lien KC, Morgan DM, Delancey JOL, et al. Pudendal nerve stretch during vaginal birth: a 3D computer simulation. *Am J Obstet Gynecol.* 2005;192:1669–76.
54. Eason E, Labrecque M, Marcoux S, Mondor M. Anal incontinence after childbirth. *Can Med Assoc J.* 2002;166:326–30.
55. Groutz A, Fait G, Lessing J, et al. Incidence and obstetric risk factors of postpartum anal incontinence. *Scand J Gastroenterol.* 1999;34:315–8.
56. Mazouni C, Bretelle F, Battar S, Bonnier P, Gannerre M. Frequency of persistent anal symptoms after first instrumental delivery. *Dis Colon Rectum.* 2005;48:1432–6.
57. MacLennan A, Taylor A, Wilson DH, Wilson D. The prevalence of pelvic floor disorders and their relationship to gender, age, parity and mode of delivery. *Br J Obstet Gynaecol.* 2000;107:1460–70.
58. Nelson R, Westercamp M, Furner S. A systematic review of the efficacy of caesarean section in the preservation of anal incontinence. *Dis Colon Rectum.* 2006;49:1587–95.
59. Turner CE, Young JM, Solomon MJ, et al. Incidence and etiology of pelvic floor dysfunction and mode of delivery. *Dis Colon Rectum.* 2009;52:1186–95.
60. Farrell S, Allen V, Baskett T. Parturition and urinary incontinence in primiparas. *Obstet Gynecol.* 2001;97:350–6.
61. Groutz A, Rimon E, Peled S, et al. Cesarean section: does it really prevent the development of postpartum stress urinary incontinence? A prospective study of 363 women one year after their first delivery. *NeuroUrol Urodyn.* 2004;23:2–6.
62. Rortveit G, Daltveit A, Hannestad Y, et al. Urinary incontinence after vaginal delivery or cesarean section. *N Engl J Med.* 2003;348:900–7.

63. Fynes M, Donnelly V, O'Connell P, et al. Cesarean delivery and anal sphincter injury. *Obstet Gynecol.* 1998;92:496–500.
64. Zetterstrom J, Lopez A, Holmstrom B, et al. Obstetric sphincter tears and anal incontinence: an observational follow-up study. *Acta Obstet Gynecol Scand.* 2003;82:921–8.
65. Haadem K, Ohrlander S, Lingman G. Long-term ailments due to anal sphincter rupture caused by delivery—a hidden problem. *Eur J Obstet Gynecol Reprod Biol.* 1988;27:27–32.
66. Poen A, Felt-Bersma R, Strijders R, et al. Third degree obstetric perineal tear: long term clinical outcome and functional results after primary repair. *Br J Surg.* 1998;85:1433–8.
67. Sultan A, Kamm M, Hudson C, Bartram C. Third degree obstetric anal sphincter tears: risk factors and outcome of primary repair. *BMJ.* 1994;308:887–91.
68. Fenner D, Genberg B, Brahma P, Marek L, DeLacey JO. Fecal and urinary incontinence after vaginal delivery with anal sphincter disruption in an obstetric unit in the United States. *Am J Obstet Gynecol.* 2003;189:1543–50.
69. Abramov Y, Sand P, Botros S, et al. Risk factors for female anal incontinence: new insight through the Evanston-Northwestern twin sisters study. *Obstet Gynecol.* 2005;106:726–32.
70. Bollard R, Gardiner A, Duthie G, Lindow S. Anal sphincter injury, fecal and urinary incontinence. A 34 year follow up after forceps delivery. *Dis Colon Rectum.* 2003;46:1083–8.
71. Sultan A, Kamm M, Hudson C, et al. Anal sphincter disruption during vaginal delivery. *N Engl J Med.* 1993;329:1905–11.
72. Abramowitz L, Sobhani I, Ganansia R, et al. Are sphincter defects the cause of anal incontinence after vaginal delivery? Results of a prospective trial. *Dis Colon Rectum.* 2000;43:590–6.
73. Varma A, Gunn J, Gardiner A, et al. Obstetric anal sphincter injury: prospective evaluation of incidence. *Dis Colon Rectum.* 1999;42:1537–43.
74. Fynes M, Donnelly V, Behan M, et al. Effect of second vaginal delivery on anorectal physiology and faecal continence: a prospective study. *Lancet.* 1999;354:983–6.
75. Faltin D, Boulvain M, Irion O, et al. Diagnosis of anal sphincter tears by postpartum endo-sonography to predict faecal incontinence. *Obstet Gynecol.* 2000;95:643–7.
76. Oberwalder M, Connor J, Wexner S. Meta-analysis to determine the incidence of obstetric anal sphincter damage. *Br J Surg.* 2003;90:1333–7.
77. Allen R, Hosker G, Smith A, Warrell D. Pelvic floor damage and childbirth: a neurophysiological study. *Br J Obstet Gynaecol.* 1990;97:770–9.
78. Dietz H. Levator function before and after childbirth. *Aust N Z J Obstet Gynaecol.* 2004;44:19–23.
79. Swift S, Woodman P, O'Boyle A, et al. Pelvic Organ Support Study (POSST): the distribution, clinical definition and epidemiology of pelvic organ support defects. *Am J Obstet Gynecol.* 2005;192:795–805.
80. Mant J, Painter R, Vessey M. Epidemiology of genital prolapse: observations from the Oxford Family Planning Association Study. *Br J Obstet Gynaecol.* 1997;104:579–85.
81. Buhling K, Schmidt S, Robinson J, et al. Rate of dyspareunia after delivery in primiparae according to mode of delivery. *Eur J Obstet Gynecol Reprod Biol.* 2006;124:42–6.
82. Barrett G, Peacock J, Victor C, Manyonda I. Caesarean section and postnatal sexual health. *Birth.* 2005;32:306–11.
83. Gilleard WL, Brown JMM. Structure and function of the abdominal muscles in primigravid subjects during pregnancy and the immediate postbirth period. *Phys Ther.* 1996;76:750–62.
84. Fast A, Weiss L, Ducommun EJ, et al. Low-back pain in pregnancy. Abdominal muscles, sit-up performance, and back pain. *Spine.* 1990;15:28–30.
85. Liaw LJ, Hsu MJ, Liao CJ, et al. The relationships between inter-recti distance measured by ultrasound imaging and abdominal muscle function in postpartum women: a 6-month follow-up study. *J Orthop Sports Phys Ther.* 2011;41:435–43.
86. Pivarnik JM, Ayres NA, Mauer MB, et al. Effects of maternal aerobic fitness on cardiorespiratory responses to exercise. *Med Sci Sports Exerc.* 1993;25:993–8.
87. Wong SC, McKenzie DC. Cardiorespiratory fitness during pregnancy and its effect on outcome. *Int J Sports Med.* 1987;8:79–83.

88. Treuth MS, Butte NF, Puyau M. Pregnancy-related changes in physical activity, fitness, and strength. *Med Sci Sports Exerc.* 2005;37:832–7.
89. Spitznagle TM, Leong FC, Van Dillen LR. Prevalence of diastasis recti abdominis in a urogynecological patient population. *Int Urogynecol J Pelvic Floor Dysfunct.* 2007;18:321–8.
90. Turan V, Colluoglu C, Turkyilmaz E, et al. *Ginekol Pol.* 2011;82:817–21.
91. Pereira LC, Bothelho S, Marques J, et al. Are transversus abdominis/oblique internal and pelvic floor muscles coactivated during pregnancy and postpartum? *Neurourol Urodyn.* 2013;32:416–9.
92. Pascoal AG, Dionisio S, Cordeiro F, Mota P. Inter-rectus distance in postpartum women can be reduced by isometric contraction of the abdominal muscles: a preliminary case-control study. *Physiotherapy.* 2014;100(4):344–8. pii: S0031-9406(14)00015-7.
93. Benjamin DR, Van de Water AT, Peiris CL. Effects of exercise on diastasis of the rectus abdominis muscle in the antenatal and postnatal periods: a systematic review. *Physiotherapy.* 2014;100:1–8.
94. Mathai M, Hofmeyr GJ, Mathai NE. Abdominal surgical incisions for caesarean section. *Cochrane Database Syst Rev.* 2013;5, CD004453.
95. Landau R, Bollag L, Ortner C. Chronic pain after childbirth. *Int J Obstet Anesth.* 2013;22: 133–45.
96. Macrae WA, Davies HT. Chronic postsurgical pain. In: Crombie S, Linton S, Croft P, Von Korff M, LeResche L, editors. *Epidemiology of pain.* Seattle: International Association for the Study of Pain; 1989. p. 125–42.
97. Loos MJ, Scheltinga MR, Mulders LG, Roumen RM. The Pfannenstiel incision as a source of chronic pain. *Obstet Gynecol.* 2008;111:839–46.

Chapter 14

Pharmacological Treatment of Musculoskeletal Conditions During Pregnancy and Lactation

Joong Kim and Mary F. Hébert

Pregnancy

The primary goal in the management of pain in pregnancy is to relieve pain and suffering in a safe and effective manner. The use of the lowest dose, frequency, and length of therapy needed to achieve effective pain relief is prudent in order to minimize the risks; however, achieving pain relief is critical. Otherwise, fetal exposure is occurring without benefit to the mother. All medications cross the placenta to some degree, but most do not result in major malformations (Table 14.1). Gestational age at the time of fetal exposure affects the risks of medications. In the first 4 weeks of pregnancy, in utero exposure to medications usually has an all-or-nothing effect in which the embryo develops without abnormalities or the embryo does not survive [1]. Organogenesis occurs during weeks 4–10 of pregnancy and minimizing harmful and unnecessary drug exposure during this time is prudent. Abnormalities that may arise due to fetal exposure in the second and third trimesters of pregnancy may result in developmental syndromes or intrauterine growth restriction [2]. Other than teratogenic effects, medications can adversely influence conception and the physiology of pregnancy.

J. Kim, PharmD

Department of Pharmacy, University of Washington Medical Center,
1959 NE Pacific St., Box 356015, Seattle, WA 98195-6015, USA
e-mail: jkim53@u.washington.edu

M.F. Hébert, PharmD, FCCP (✉)

Department of Pharmacy, University of Washington, 1959 NE Pacific St., H-375 Health Sciences Center, Box 357630, Seattle, WA 98195-7630, USA
e-mail: mhebert@uw.edu

Table 14.1 Pharmacological management of musculoskeletal pain during pregnancy

Acetaminophen	Safe for short-term use
NSAIDs	
Ibuprofen	Probably safe for 48–72 h in second trimester
Naproxen	Probably safe for 48–72 h in second trimester
Aspirin	Avoid doses greater than 100 mg
Opiates	Probably safe for 48–72 h with lowest dose needed
Benzodiazepines	
Lorazepam	Probably safe for 1–2 doses within a 24-h period
Diazepam	Avoid in pregnancy
Other skeletal relaxants	
Carisoprodol	Avoid in pregnancy due to limited or no human data
Cyclobenzaprine	Avoid in pregnancy due to limited or no human data
Methocarbamol	Avoid in pregnancy due to limited or no human data
Local anesthetics	
Lidocaine with epinephrine	Safe for short-term use
Bupivacaine	Safe for short-term use
Ropivacaine	Use alternative agent
Mepivacaine	Use alternative agent

In order to optimize care for pregnant women, it is necessary to not only consider the safety of medications for the fetus, but to also assure that dosage strategies optimize efficacy for the mother. Pregnancy is associated with significant physiologic changes that can alter the pharmacokinetics of drugs. It is well documented that pregnancy increases the apparent activity of some drug metabolizing enzymes (CYP3A, CYP2D6, CYP2C9, UGT) while others have an apparent decrease in activity (CYP1A2 and CYP2C19) [3–6]. In addition, renal filtration and active drug transport have been reported to markedly increase in pregnancy [3, 7]. Body weight, plasma drug-binding proteins, and hematocrit are known to change during pregnancy [8, 9]. All of these factors can affect the disposition of medications during gestation. These changes can lead to higher or lower concentrations of therapeutic agents depending on their route of administration and other chemical characteristics. The effects of pregnancy on drug dosing will not be addressed in detail in this chapter, but should be considered when determining appropriate treatment regimens for pregnant women. With any pharmacological treatment, the benefits to treating the mother must be carefully weighed against the risks of untreated conditions or diseases as well as medications to the mother, fetus, and neonate.

Acetaminophen

Acetaminophen is generally considered to be the treatment of choice for management of mild pain during pregnancy [10]. Acetaminophen does cross the placenta,

but there is a large amount of data suggesting that acetaminophen does not cause major or minor malformations [11–13]. It is considered safe when used in appropriate doses for short periods of time (less than 14 days) throughout all three trimesters of pregnancy.

Non-steroidal Anti-Inflammatory Drugs

The use of Non-Steroidal Anti-Inflammatory Drugs (NSAIDs) such as ibuprofen and naproxen in early pregnancy and around the time of conception is weakly associated with miscarriage [13–15]. Epidemiological studies have had conflicting results with some reporting an increased risk of cardiac defects and gastroschisis with early pregnancy exposure to NSAIDs while others have not [14, 16–19]. Inhibition of fetal prostaglandins late in pregnancy can cause closure of the ductus arteriosus [20]. Therefore, NSAIDs for pain management should be avoided after 30 weeks of gestation.

Low-dose aspirin (≤ 100 mg/day) has minimal risk in pregnancy [21, 22]. However, aspirin doses used for pain relief should be avoided in pregnancy due to associations with miscarriage, fetal anomalies, increased fetal mortality, intra-uterine growth restriction, premature closure of the ductus arteriosus, pulmonary hypertension, and increased risk of hemorrhage [23, 24]. Furthermore, aspirin's irreversible inhibition of platelets may increase the risk of intracranial hemorrhage in neonates as well as maternal hemorrhage during delivery [25].

Due to the risks of NSAIDs, they should be avoided during the first and third trimesters of pregnancy and acetaminophen should be used instead when possible. If NSAIDs are used, ibuprofen or naproxen at the lowest effective dose may be used judiciously in the second trimester of pregnancy for short periods of time (48–72 h). Aspirin should be avoided.

Opioids

Severe pain may require the use of opiates in pregnancy. The National Birth Defects Prevention Study reported statistically significant associations of birth defects with opioid use from 1 month before to 3 months after conception, including structural heart defects, spina bifida, and gastroschisis [26]. Chronic exposure to any opiate in utero, especially in large doses and in the third trimester, may lead to neonatal abstinence syndrome and respiratory depression [27, 28]. The amount of opiates that must be used to lead to neonatal abstinence syndrome is not known. Characteristics of neonatal abstinence syndrome are high-pitched cry, irritability, motor and tone control issues, vomiting, loose stools, and autonomic dysfunction [28, 29]. Furthermore, opioids should be used judiciously to treat pain, as tolerance and addiction are risks of therapy. Codeine, oxycodone, hydrocodone, hydromorphone,

and morphine are opiates that should have their use limited in the first and third trimester of pregnancy. Limiting use to the lowest dose needed to control pain for the shortest period of time would be prudent.

Benzodiazepines

Benzodiazepines cross the placenta and can accumulate in the fetus [30]. Prolonged use of benzodiazepines during pregnancy, especially in late pregnancy, has been associated with “floppy infant” syndrome, hypotonia, decreased suckling, cyanosis, hypothermia, and withdrawal [30–32]. Premature infants are particularly susceptible to this effect [33]. Published studies with diazepam and lorazepam have been conflicting with respect to associations with congenital malformations such as diazepam and cleft palate as well as lorazepam and anal atresia [34, 35]. Diazepam and its active metabolites are long acting, cross the placenta, and accumulate in the fetus at about 1–3 times the maternal serum concentration [34, 35]. Therefore, diazepam should be avoided in pregnancy. Lorazepam is less likely to accumulate in the fetus and does not cross the placenta as readily as diazepam [36, 37]. If used, the lowest effective dose should be given for the shortest period of time necessary, for example 1–2 doses within a 24-h period. Abrupt discontinuation of chronic benzodiazepines can result in severe maternal withdrawal symptoms and in some cases result in substitution of other substances such as ethanol to treat symptoms.

Skeletal Muscle Relaxants

Carisoprodol

There is limited information regarding the safety of carisoprodol in pregnancy. Carisoprodol is metabolized to its active metabolite, meprobamate. There have been 16 reports of human pregnancies with normal outcomes after exposure to carisoprodol [38–40]. Data available on meprobamate in pregnancy are more substantial, but conflicting with respect to malformations. No consistent pattern of congenital anomalies with in utero exposure to meprobamate has been reported [41, 42]. There is insufficient data to know the effects of carisoprodol on major or minor malformations.

Cyclobenzaprine

There is limited human data on the safety of cyclobenzaprine use during pregnancy [43]. There is insufficient evaluable data to know the effects of cyclobenzaprine on major or minor malformations.

Methocarbamol

There is limited data on the safety of in utero exposure to methocarbamol. Twenty-two cases have been reported with no apparent increase in malformations [39]. In another 340 women, given prescriptions for methocarbamol in the first trimester of pregnancy there did not appear to be an increase in malformations [44].

Corticosteroids

Corticosteroids are used intravenously, topically, orally, and in epidurals. Dose and route of administration affects the fetal risk of corticosteroids. Although the placenta inactivates some prednisone and prednisolone before it reaches the fetus, corticosteroids are expected to cross the placenta to some degree [45]. Topical and epidural administration is not expected to pose increased fetal risk [45]. However, systemic steroid use in pregnancy has been associated with case reports of congenital cataracts, immunosuppression (when used in conjunction with azathioprine), and neonatal adrenal insufficiency [45–47]. Increased risk of in utero growth restriction and cleft lip with or without cleft palate have been suggested to be risks of corticosteroid exposure based on cohort and case–control studies [48]. Maternal immunosuppression may also pose risks for infections and lead to associated complications during pregnancy.

Local Anesthetics

Local lidocaine use during pregnancy does not appear to cause major or minor malformations [39]. Although there is no data for the second and third trimesters of pregnancy, the Collaborative Perinatal Project suggests that locally administered lidocaine in early pregnancy did not increase the malformation risk [39]. In contrast, mepivacaine was associated with an increased incidence of congenital malformations in the same study, but no confirmatory studies are available [39]. The use of mepivacaine near term may be associated with behavioral effects in the newborn [49, 50]. Local bupivacaine is also commonly used and does not appear to be associated with teratogenicity or adverse events [51]. However, when bupivacaine is used as maternal anesthesia, decreased fetal heart rate has been reported [52]. Ropivacaine crosses the placenta but there is insufficient data to determine its safety during pregnancy [53]. At this time, local lidocaine or bupivacaine are preferred over mepivacaine and ropivacaine during pregnancy.

Radiologic Contrast Media

Diagnostic imaging studies and exposure to radiologic contrast media should be avoided if possible. There is limited clinical information on the use of iodinated contrast media and its effects on the fetus. Iodinated contrast media crosses the placenta and there has been a reported case of transient fetal thyroid dysfunction when used for amniocentesis [54, 55]. A recent clinical study of 23 women receiving intravenous nonionic iodinated contrast agents resulted in no infant adverse effects on the fetal thyroid function following in utero exposure [55].

Gadolinium-based contrast agents utilized with magnetic resonance imaging cross the placental barrier [56]. The American College of Radiology cautions the use of gadolinium during pregnancy due to ions entering the fetal circulation and then its subsequent sequestration in the amniotic fluid [57]. However, there have been a small number of reported cases describing the use of gadolinium in pregnant patients without adverse effects to the fetus [58–60].

Lactation

The use of pharmacologic therapy during lactation may be indicated for women where lifestyle modification and non-pharmacologic therapy are inadequate. The benefits of breastfeeding, and growing evidence defining the risk of taking medications while nursing, allow mothers and healthcare providers to make educated decisions in using medications while breastfeeding. Many drugs are excreted into the human milk, but most pose little risk to the nursing infant (Table 14.2) [33]. Drug properties, such as lipophilicity, molecular weight, volume of distribution, protein binding, active drug transport, acid/base characteristics (pK_a), plasma concentrations, and oral absorption by the breastfeeding infant affect the extent to which the drug accumulates in the human milk and ultimately, the infant's exposure to the medication. It is also important to consider how comorbidities, age of the infant, ability of the infant to excrete the medication (renal and hepatic function), whether the drug is orally absorbed and gestational age at birth will influence the infant concentration and risk for adverse events [33]. Using the lowest effective dose for the shortest period of time needed decreases the risk of adverse effects for the infant. Furthermore, timing the maternal dose just after nursing or taking the dose at the beginning of a time period when the infant is not expected to feed from the breast, such as when the infant is sleeping, are strategies to decrease infant exposure for some medications. However, other medications reach peak concentrations in the maternal blood or breast milk several hours after the dose is taken. Therefore, this strategy does not apply to all medications. Generally speaking, nursing infant exposure to maternal weight-adjusted doses less than 10 % are considered compatible with breastfeeding unless adverse events have been reported in the infant or accumulation of drug is known to occur in the nursing infant [61]. We recommend the online searchable LactMed website (<http://toxnet.nlm.nih.gov>) as an up-to-date resource supported by the National Library of Medicine for medication use during lactation.

Table 14.2 Recommendation for the compatibility of medications and breastfeeding

Drug	AAP recommendation [33, 112]	WHO recommendation [113]
Acetaminophen	Usually compatible with breastfeeding	Compatible with breastfeeding
Ibuprofen	Usually compatible with breastfeeding	Compatible with breastfeeding
Naproxen	Usually compatible with breastfeeding	No recommendation available
Aspirin	Aspirin has been associated with adverse effects and should be given to nursing mothers with caution Low doses <162 mg/day may be acceptable	Short courses safe in usual dosage Monitor the infant for adverse effects
Celecoxib	Usually compatible with breastfeeding	No recommendation available
Morphine	Usually compatible with breastfeeding	Occasional doses are compatible with breastfeeding Avoid repeated doses, if possible Monitor infant for adverse effects
Oxycodone	Use while breastfeeding is discouraged	No recommendation available
Codeine	Usually compatible with breastfeeding, but other agents are preferred	Occasional doses are compatible with breastfeeding Avoid repeated doses, if possible Monitor infant for adverse effects
Hydrocodone	Usually compatible with breastfeeding, but other agents are preferred	No recommendation available
Hydromorphone	Usually compatible with breastfeeding	No recommendation available
Lorazepam	Drugs for which the effect on nursing infants is unknown but may be of concern	Compatible with breastfeeding in single dose Avoid repeated doses, if possible Monitor infant for drowsiness
Diazepam	Drug for which the effect on nursing infants is unknown but may be of concern	Compatible with breastfeeding Monitor infant for side-effects May prefer short acting benzodiazepine, such as lorazepam
Carisoprodol	May decrease milk production Monitor infant for side-effects (sedation)	No recommendation available
Cyclobenzaprine	No recommendation available	No recommendation available
Methocarbamol	No recommendation available	No recommendation available
Prednisone	Usually compatible with breastfeeding	No recommendation available
Prednisolone	Usually compatible with breastfeeding	Compatible with breastfeeding
Lidocaine (local)	Usually compatible with breastfeeding	Compatible with breastfeeding
Bupivacaine (local)	No recommendation available	Compatible with breastfeeding
Ropivacaine (local)	No recommendation available	No recommendation available
Mepivacaine (local)	No recommendation available	No recommendation available

AAP American Academy of Pediatrics, WHO World Health Organization

Acetaminophen

A small amount of acetaminophen is excreted into the breast milk. A nursing infant is exposed to approximately 0.1–1.85 % of the maternal weight-adjusted dose [62]. Infants exposed to acetaminophen via breast milk usually do not experience adverse events; however there is a case report of an infant rash from acetaminophen in the breast milk [63]. When dosed appropriately, acetaminophen is compatible with breastfeeding.

Non-steroidal Anti-Inflammatory Drugs

Ibuprofen

A very small amount of ibuprofen is excreted into the breast milk. Nursing infants are exposed to approximately 0.0008 % of the maternal weight-adjusted dose [64]. No infant adverse events have been reported. Ibuprofen is compatible with breastfeeding.

Celecoxib

A very small amount of celecoxib is excreted into the breast milk. Nursing infants are exposed to approximately 0.2–0.3 % of the maternal weight-adjusted dose [65]. Nursing infant concentrations are below the limit of assay detection [66]. No infant adverse events have been reported.

Naproxen

A small amount of naproxen is excreted into the breast milk. Nursing infants are exposed to 2–3 % of the maternal weight-adjusted dose [67]. Prolonged bleeding time, thrombocytopenia, and anemia have been reported in an infant exposed to naproxen via the breast milk [67]. Given the longer half-life of naproxen and the reported adverse event in the nursing infant exposed to naproxen via breast milk, ibuprofen would be a better therapeutic choice for a nursing mother [67].

Aspirin

Aspirin is excreted into the breast milk. Nursing infants are exposed to 9–10 % of the maternal weight-adjusted dose [68, 69]. Metabolic acidosis has been reported in one 16-day-old infant exposed to aspirin via breast milk [70]. Thrombocytopenia,

fever, anorexia, and petechiae developed in a 5-month-old nursing infant 5 days after the mother started taking aspirin [71]. Hemolysis was also reported in a 23-day-old nursing G-6-P-D nursing infant exposed to aspirin via breast milk [72]. Infants with viral infections exposed to aspirin are at risk for Reye's syndrome [73]. The risk of Reye's syndrome following exposure to aspirin via breast milk is unknown.

Opiates

Hydrocodone, oxycodone, codeine, hydromorphone, and morphine are all excreted into breast milk with nursing infant maternal weight-adjusted doses being approximately 1.5–4 %, 8 %, 1–2 %, <1 %, and 0.8–12 %, respectively [74–80]. Central nervous system depression has been reported in up to 24 % of infants exposed to codeine via breast milk [81]. Certain genotypes (ABCB1 2677 T/T as well as CYP2D6 extensive or ultra-rapid metabolizers) are associated with maternal and infant codeine toxicity [82]. ABCB1 is a polymorphic gene, which encodes for a drug transporter (p-glycoprotein) that effluxes morphine out of the brain. The T/T genotype is associated with lower expression of p-glycoprotein and higher brain morphine concentrations [83]. CYP2D6 is a polymorphic enzyme with individuals categorized as poor, intermediate, extensive, and ultra-rapid metabolizers. Codeine (pro-drug) is converted to its active metabolite, morphine, by CYP2D6 [82]. Following maternal codeine intake, morphine is excreted into breast milk with the highest amount excreted by CYP2D6 ultra-rapid metabolizers [82]. Morphine is further metabolized by UGT2B7 to morphine-6-glucuronide [84]. Both morphine and morphine-6-glucuronide are highly active compounds [84].

In 2006 there was a case report of an infant mortality from exposure to codeine and its active metabolites (morphine and morphine-6-glucuronide) via breast milk. Although the mother was on a relatively low dose of codeine (initially 60 mg twice daily and reduced on day 2–30 mg twice daily), she was a CYP2D6 ultra-rapid metabolizer and experienced somnolence and constipation with the drug. On day 7 the infant experienced lethargy and difficulty breastfeeding. Day 11, the infant was brought to the Pediatrician with concerns about skin color and decreased milk intake, but the infant's weight was back to birth weight, so the infant was sent home. Day 13 the infant was cyanotic and resuscitation was unsuccessful [82]. A clinical tool has been developed by the Motherisk program to improve safety of codeine use during breastfeeding [85]. Key components of their guidelines suggest the following: if the mother develops symptoms of CNS depression, the infant should be examined; if the infant is symptomatic (not feeding well, does not gain weight, has to be woken up to feed or shows limpness), they should be examined by a physician; discontinue codeine by day 4 if possible; if codeine is needed beyond day 4, decrease the dose or switch to non-codeine pain-relievers; and breastfeed infant just before codeine dose to maximize the time to eliminate codeine between feeds.

Other opiates such as hydrocodone, oxycodone, and tramadol also undergo metabolism via CYP2D6 to active metabolites [86, 87]. Infants have very low expression of drug metabolizing enzymes at birth, which gradually increase with age [88]. The ontogeny of drug metabolizing enzymes put newborn infants at risk for drug toxicity. Central nervous system depression has been reported in 20 % of breastfeeding infants whose mothers took oxycodone [89]. Of note, there is a case report of therapeutic plasma oxycodone concentrations in a nursing infant [90]. Morphine is not metabolized by CYP2D6, but it does have an active metabolite. Similar to oxycodone, there is a report of a breastfed infant with therapeutic plasma concentrations of morphine [80]. Regardless of which opiate is used, it is important to consider that they are all excreted into the breast milk and may accumulate in the infant. Lactating mothers should be instructed to contact their clinical provider for potential infant adverse events, including sleepiness, feeding difficulties, breathing difficulties, cyanosis, and/or limpness. Maternal opiate intake should be limited to the lowest dose needed for the shortest period of time to control pain and supplement with non-narcotic analgesics if necessary.

Benzodiazepines

Lorazepam is excreted into breast milk. Infant exposure via breast milk is approximately 2.5 % of the maternal weight-adjusted dose as parent drug and 8.5 % when including the parent and glucuronide metabolite [91]. A telephone follow-up survey of 64 women taking lorazepam during lactation reported no sedation in the nursing infants [92]. As with other medications, single doses or short duration of treatment should be used when possible. Lorazepam has a short half-life, which is preferred over the use of other longer acting benzodiazepines such as diazepam. Diazepam and its active metabolite, nordiazepam, are excreted into the breast milk and may accumulate in the infants. Infant serum concentrations following exposure to diazepam via breast milk have been reported to be as high as 25–50 % of maternal concentrations [93, 94]. Neonatal drowsiness and lethargy have been reported in infants whose mothers were taking diazepam [94–96]. If benzodiazepines are used, mothers should be instructed to monitor their infants for sedation and decreased suckling [97].

Other Skeletal Muscle Relaxants

Carisoprodol

Carisoprodol is excreted into breast milk. Nursing infants are exposed to approximately 6–7 % of the maternal weight-adjusted dose via breast milk [38, 40]. Infant sedation has been reported [40]. Two case reports found no infant adverse effects from carisoprodol via breast milk [38, 40]. If carisoprodol is necessary during lactation, infants should be monitored for signs of sedation and difficulties feeding [40].

Cyclobenzaprine

There are no lactation studies available on cyclobenzaprine and it is unknown whether it is excreted into the breast milk.

Methocarbamol

There are no lactation studies available on methocarbamol and it is unknown whether it is excreted into the breast milk.

Corticosteroids

Small amounts of prednisone, prednisolone, and methylprednisolone are excreted into breast milk [98–101]. Infant exposure via breast milk to prednisone/prednisolone is <2 % of the maternal weight-adjusted dose [101]. No infant adverse events have been reported due to prednisone, prednisolone, or methylprednisolone exposure via breast milk [102, 103]. Large doses of corticosteroids into joints have been associated with a temporary reduction in milk production [104, 105]. Similarly, corticosteroids administered for lung maturation during premature labor can result in delayed lactogenesis II and lower milk volume in the first 10 days postpartum [106].

Local Anesthetics

Small amounts of lidocaine, bupivacaine, and ropivacaine are excreted into breast milk [107–110]. Nursing infants are exposed to approximately 0.9 % of the maternal weight-adjusted dose of local lidocaine 2 % without epinephrine [107]. Infant exposure to ropivacaine is expected to be even lower as ropivacaine has been shown to have the lowest milk-serum concentration ratio of the three agents [110]. Impact of infant exposure via breast milk is also limited by poor oral bioavailability of local anesthetics such as lidocaine, bupivacaine and ropivacaine [102, 110, 111]. Due to insufficient data for the use of mepivacaine during breastfeeding, it is recommended to use lidocaine, bupivacaine, or ropivacaine as local anesthetics during breastfeeding.

Radiologic Contrast Media

Less than 1 % of iodinated contrast medium maternal dose and 0.04 % of gadolinium contrast medium maternal dose is excreted into the breast milk in the first 24 h [33, 56]. Infant absorption is 1–2 % of the ingested dose [56]. The risk to the infant is expected to be low. If the mother decides to temporarily discontinue nursing

during the treatment, breast milk can be expressed and discarded for 24 h. However, there is no expected benefit from interrupting breastfeeding for longer than 24 h due to the short half-life of the agents. Normal renal function should eliminate the agent from the body in 24 h.

References

1. Rathmell JP, Viscomi CM, Ashburn MA. Management of nonobstetric pain during pregnancy and lactation. *Anesth Analg.* 1997;85(5):1074–87.
2. Ostrer H. Genetic and environmental causes of birth defects. In: Post TW, editor. UpToDate. Waltham; 2013. Topic 6829 Version 11.0. Accessed 24 Feb 2014.
3. Hébert MF, Easterling TR, Kirby B, Carr DB, Buchanan ML, Rutherford T, et al. Effects of pregnancy on CYP3A and P-glycoprotein activities as measured by disposition of midazolam and digoxin: a University of Washington specialized center of research study. *Clin Pharmacol Ther.* 2008;84(2):248–53.
4. Zhou L, Naraharisetti SB, Liu L, Wang H, Lin YS, Isoherranen N, et al. Contributions of human cytochrome P450 enzymes to glyburide metabolism. *Biopharm Drug Dispos.* 2010;31(4):228–42.
5. Buchanan ML, Easterling TR, Carr DB, Shen DD, Risler LJ, Nelson WL, et al. Clonidine pharmacokinetics in pregnancy. *Drug Metab Dispos.* 2009;37(4):702–5.
6. de Haan GJ, Edelbroek P, Segers J, Engelsman M, Lindhout D, Devile-Notschaele M, et al. Gestation-induced changes in lamotrigine pharmacokinetics: a monotherapy study. *Neurology.* 2004;63(3):571–3.
7. Andrew MA, Easterling TR, Carr DB, Shen D, Buchanan ML, Rutherford T, et al. Amoxicillin pharmacokinetics in pregnant women: modeling and simulations of dosage strategies. *Clin Pharmacol Ther.* 2007;81(4):547–56.
8. Zheng S, Easterling TR, Umans JG, Miodovnik M, Calamia JC, Thummel KE, et al. Pharmacokinetics of tacrolimus during pregnancy. *Ther Drug Monit.* 2012;34(6):660–70.
9. Zheng S, Easterling TR, Hays K, Umans JG, Miodovnik M, Clark S, et al. Tacrolimus placental transfer at delivery and neonatal exposure through breast milk. *Br J Clin Pharmacol.* 2013;76(6):988–96.
10. Black RA, Hill DA. Over-the-counter medications in pregnancy. *Am Fam Physician.* 2003;67(12):2517–24.
11. Cleves MA, Savell Jr VH, Raj S, Zhao W, Correa A, Werler MM, et al. Maternal use of acetaminophen and nonsteroidal anti-inflammatory drugs (NSAIDs), and muscular ventricular septal defects. *Birth Defects Res A Clin Mol Teratol.* 2004;70(3):107–13.
12. Persky V, Piorkowski J, Hernandez E, Chavez N, Wagner-Cassanova C, Vergara C, et al. Prenatal exposure to acetaminophen and respiratory symptoms in the first year of life. *Ann Allergy Asthma Immunol.* 2008;101(3):271–8.
13. Li DK, Liu L, Odouli R. Exposure to non-steroidal anti-inflammatory drugs during pregnancy and risk of miscarriage: population based cohort study. *BMJ.* 2003;327(7411):368.
14. Nielsen GL, Skriver MV, Pedersen L, Sorensen HT. Danish group reanalyses miscarriage in NSAID users. *BMJ.* 2004;328(7431):109.
15. Nielsen GL, Sorensen HT, Larsen H, Pedersen L. Risk of adverse birth outcome and miscarriage in pregnant users of non-steroidal anti-inflammatory drugs: population based observational study and case-control study. *BMJ.* 2001;322(7281):266–70.
16. Kallen BA, Otterblad Olausson P. Maternal drug use in early pregnancy and infant cardiovascular defect. *Reprod Toxicol.* 2003;17(3):255–61.
17. Torfs CP, Katz EA, Bateson TF, Lam PK, Curry CJ. Maternal medications and environmental exposures as risk factors for gastroschisis. *Teratology.* 1996;54(2):84–92.

18. Werler MM, Mitchell AA, Shapiro S. First trimester maternal medication use in relation to gastroschisis. *Teratology*. 1992;45(4):361–7.
19. Ofori B, Oraichi D, Blais L, Rey E, Berard A. Risk of congenital anomalies in pregnant users of non-steroidal anti-inflammatory drugs: a nested case-control study. *Birth Defects Res B Dev Reprod Toxicol*. 2006;77(4):268–79.
20. Momma K, Takeuchi H. Constriction of fetal ductus arteriosus by nonsteroidal antiinflammatory drugs. *Adv Prostaglandin Thromboxane Leukot Res*. 1983;12:499–504.
21. Leslie GI, Gallery ED, Arnold JD, Ross MR, Gyory AZ. Neonatal outcome in a randomized, controlled trial of low-dose aspirin in high-risk pregnancies. *J Paediatr Child Health*. 1995;31(6):549–52.
22. Low dose aspirin in pregnancy and early childhood development: follow up of the collaborative low dose aspirin study in pregnancy. CLASP collaborative group. *Br J Obstet Gynaecol*. 1995;102(11):861–8.
23. Lewis RB, Schulman JD. Influence of acetylsalicylic acid, an inhibitor of prostaglandin synthesis, on the duration of human gestation and labour. *Lancet*. 1973;2(7839):1159–61.
24. American Medical Association Department of Drugs. *AMA drug evaluations*. 6th ed. Chicago: American Medical Association; 1986.
25. Rumack CM, Guggenheim MA, Rumack BH, Peterson RG, Johnson ML, Braithwaite WR. Neonatal intracranial hemorrhage and maternal use of aspirin. *Obstet Gynecol*. 1981;58(5 Suppl):52S–6.
26. Broussard CS, Rasmussen SA, Reefhuis J, Friedman JM, Jann MW, Riehle-Colarusso T, et al. Maternal treatment with opioid analgesics and risk for birth defects. *Am J Obstet Gynecol*. 2011;204(4):314.e1–11.
27. Sardemann H, Madsen KS, Friis-Hansen B. Follow-up of children of drug-addicted mothers. *Arch Dis Child*. 1976;51(2):131–4.
28. Levy M, Spino M. Neonatal withdrawal syndrome: associated drugs and pharmacologic management. *Pharmacotherapy*. 1993;13(3):202–11.
29. Janson LM. Neonatal abstinence syndrome. In: Rose B, editor. *UpToDate*. Waltham; 2014. Topic 5016 Version 22.0. Accessed 24 Feb 2014.
30. Kanto JH. Use of benzodiazepines during pregnancy, labour and lactation, with particular reference to pharmacokinetic considerations. *Drugs*. 1982;23(5):354–80.
31. Cree JE, Meyer J, Hailey DM. Diazepam in labour: its metabolism and effect on the clinical condition and thermogenesis of the newborn. *Br Med J*. 1973;4(5887):251–5.
32. Gillberg C. “Floppy infant syndrome” and maternal diazepam. *Lancet*. 1977;2(8031):244.
33. Sachs HC. The transfer of drugs and therapeutics into human breast milk: an update on selected topics. *Pediatrics*. 2013;132(3):e796–809.
34. Kanto J, Erkkola R, Sellman R. Accumulation of diazepam and N-demethyl diazepam in the fetal blood during the labour. *Ann Clin Res*. 1973;5(6):375–9.
35. Jorgensen NP, Thurmann-Nielsen E, Walstad RA. Pharmacokinetics and distribution of diazepam and oxazepam in early pregnancy. *Acta Obstet Gynecol Scand*. 1988;67(6):493–7.
36. McBride RJ, Dundee JW, Moore J, Toner W, Howard PJ. A study of the plasma concentrations of lorazepam in mother and neonate. *Br J Anaesth*. 1979;51(10):971–8.
37. Kanto J, Aaltonen L, Liukko P, Maenpaa K. Transfer of lorazepam and its conjugate across the human placenta. *Acta Pharmacol Toxicol*. 1980;47(2):130–4.
38. Nordeng H, Zahlsten K, Spigset O. Transfer of carisoprodol to breast milk. *Ther Drug Monit*. 2001;23(3):298–300.
39. Heinonen OP, Slone D, Shapiro S. *Birth defects and drugs in pregnancy*. Littleton: Publishing Sciences Group; 1977. p. 357–65.
40. Briggs GG, Ambrose PJ, Nageotte MP, Padilla G. High-dose carisoprodol during pregnancy and lactation. *Ann Pharmacother*. 2008;42(6):898–901.
41. Milkovich L, van den Berg BJ. Effects of prenatal meprobamate and chlordiazepoxide hydrochloride on human embryonic and fetal development. *N Engl J Med*. 1974;291(24):1268–71.
42. Hartz SC, Heinonen OP, Shapiro S, Siskind V, Slone D. Antenatal exposure to meprobamate and chlordiazepoxide in relation to malformations, mental development, and childhood mortality. *N Engl J Med*. 1975;292(14):726–8.

43. Flannery DB. Syndrome of imperforate oropharynx with costovertebral and auricular anomalies. *Am J Med Genet.* 1989;32(2):189–91.
44. Rosa F. Personal communication. 1993. Cited in: Briggs GG, Freeman RK, Yaffe SJ. *Drugs in pregnancy and lactation: a reference guide to fetal and neonatal risk.* 8th ed. Philadelphia: Lippincott Williams & Wilkins; 2008. p. 345, 1175.
45. Prednisone. In: Reprotox [database on the Internet]. Ann Arbor: Truven Health Analytics; 2014. www.micromedexsolutions.com. Subscription required to view. Accessed 24 Feb 2014.
46. Cote CJ, Meuwissen HJ, Pickering RJ. Effects on the neonate of prednisone and azathioprine administered to the mother during pregnancy. *J Pediatr.* 1974;85(3):324–8.
47. Saulnier PJ, Piguel X, Perault-Pochat MC, Cszimadia-Bremaud C, Saulnier JP. Hypoglycaemic seizure and neonatal acute adrenal insufficiency after maternal exposure to prednisone during pregnancy: a case report. *Eur J Pediatr.* 2010;169(6):763–5.
48. RAYOS (prednisone) oral delayed-release tablets. Horizon Pharma USA Inc; 2012. Package insert.
49. Higuchi M, Takeuchi S. [Studies on neurobehavioral response (Scanlon test) in newborns after epidural anesthesia with various anesthetic agents for cesarean section]. *Nihon Sanka Fujinka Gakkai Zasshi.* 1982;34(12):2143–8.
50. Ransjo-Arvidson AB, Matthiesen AS, Lilja G, Nissen E, Widstrom AM, Uvnas-Moberg K. Maternal analgesia during labor disturbs newborn behavior: effects on breastfeeding, temperature, and crying. *Birth.* 2001;28(1):5–12.
51. Bupivacaine. In: DRUGDEX System [database on the internet]. Ann Arbor: Truven Health Analytics; 2014. www.micromedexsolutions.com. Subscription required to view. Accessed 24 Feb 2014.
52. Abouleish E. Foetal bradycardia during caudal analgesia: a discussion of possible causative factors. *Br J Anaesth.* 1976;48(5):481–4.
53. Johnson RF, Cahana A, Olenick M, Herman N, Paschall RL, Minzter B, et al. A comparison of the placental transfer of ropivacaine versus bupivacaine. *Anesth Analg.* 1999;89(3):703–8.
54. Rodesch F, Camus M, Ermans AM, Dodion J, Delange F. Adverse effect of amniocentesis on fetal thyroid function. *Am J Obstet Gynecol.* 1976;126(6):723–6.
55. Atwell TD, Lteif AN, Brown DL, McCann M, Townsend JE, Leroy AJ. Neonatal thyroid function after administration of IV iodinated contrast agent to 21 pregnant patients. *AJR Am J Roentgenol.* 2008;191(1):268–71.
56. Chen MM, Coakley FV, Kaimal A, Laros Jr RK. Guidelines for computed tomography and magnetic resonance imaging use during pregnancy and lactation. *Obstet Gynecol.* 2008; 112(2 Pt 1):333–40.
57. Kanal E, Barkovich AJ, Bell C, Borgstede JP, Bradley Jr WG, Froelich JW, et al. ACR guidance document for safe MR practices: 2007. *AJR Am J Roentgenol.* 2007;188(6):1447–74.
58. Marcos HB, Semelka RC, Worawattanakul S. Normal placenta: gadolinium-enhanced dynamic MR imaging. *Radiology.* 1997;205(2):493–6.
59. Barkhof F, Heijboer RJ, Algra PR. Inadvertent i.v. administration of gadopentetate dimeglumine during early pregnancy. *AJR Am J Roentgenol.* 1992;158(5):1171.
60. De Santis M, Straface G, Cavaliere AF, Carducci B, Caruso A. Gadolinium periconceptional exposure: pregnancy and neonatal outcome. *Acta Obstet Gynecol Scand.* 2007;86(1):99–101.
61. Hale TW. *Medications and mothers' milk* 2012. Fifteenth ed. Hale Publishing: Amarillo; 2012.
62. TYLENOL(R) oral, acetaminophen oral. Skillman: McNeil Consumer Healthcare; 2012. Package insert.
63. Matheson I, Lunde PK, Notarianni L. Infant rash caused by paracetamol in breast milk? *Pediatrics.* 1985;76(4):651–2.
64. Walter K, Dilger C. Ibuprofen in human milk. *Br J Clin Pharmacol.* 1997;44(2):211–2.
65. Gardiner SJ, Doogue MP, Zhang M, Begg EJ. Quantification of infant exposure to celecoxib through breast milk. *Br J Clin Pharmacol.* 2006;61(1):101–4.
66. Hale TW, McDonald R, Boger J. Transfer of celecoxib into human milk. *J Hum Lact.* 2004;20(4):397–403.

67. Jamali F, Stevens DR. Naproxen excretion in milk and its uptake by the infant. *Drug Intell Clin Pharm.* 1983;17(12):910-1.
68. Putter J, Satravaha P, Stockhausen H. [Quantitative analysis of the main metabolites of acetylsalicylic acid. Comparative analysis in the blood and milk of lactating women (author's transl)]. *Z Geburtshilfe Perinatol.* 1974;178(2):135-8.
69. Bailey DN, Weibert RT, Naylor AJ, Shaw RF. A study of salicylate and caffeine excretion in the breast milk of two nursing mothers. *J Anal Toxicol.* 1982;6(2):64-8.
70. Clark JH, Wilson WG. A 16-day-old breast-fed infant with metabolic acidosis caused by salicylate. *Clin Pediatr.* 1981;20(1):53-4.
71. Terragna A, Spirito L. [Thrombocytopenic purpura in an infant after administration of acetylsalicylic acid to the wet-nurse]. *Minerva Pediatr.* 1967;19(13):613-6.
72. Harley JD, Robin H. "Late" neonatal jaundice in infants with glucose-6-phosphate dehydrogenase-deficient erythrocytes. *Australas Ann Med.* 1962;11:148-55.
73. Bennett PN, Jensen AA. *Drugs and human lactation: a comprehensive guide to the content and consequences of drugs, micronutrients, radiopharmaceuticals, and environmental and occupational chemicals in human milk.* 2nd ed. Amsterdam: Elsevier; 1996. ix, 712 p.
74. Anderson PO, Sauberan JB, Lane JR, Rossi SS. Hydrocodone excretion into breast milk: the first two reported cases. *Breastfeed Med.* 2007;2(1):10-4.
75. Sauberan JB, Anderson PO, Lane JR, Rafie S, Nguyen N, Rossi SS, et al. Breast milk hydrocodone and hydromorphone levels in mothers using hydrocodone for postpartum pain. *Obstet Gynecol.* 2011;117(3):611-7.
76. Marx CM, Pucino F, Carlson JD, et al. Oxycodone excretion in human milk in the puerperium. *Drug Intell Clin Pharm.* 1986;20:474; Abstract.
77. Findlay JW, DeAngelis RL, Kearney MF, Welch RM, Findlay JM. Analgesic drugs in breast milk and plasma. *Clin Pharmacol Ther.* 1981;29(5):625-33.
78. Naumburg EG, Meny RG, Findlay J, et al. Codeine and morphine levels in breast milk and neonatal plasma. *Pediatr Res.* 1987;21(4, pt 2):240A; Abstract.
79. Edwards JE, Rudy AC, Wermeling DP, Desai N, McNamara PJ. Hydromorphone transfer into breast milk after intranasal administration. *Pharmacotherapy.* 2003;23(2):153-8.
80. Robieux I, Koren G, Vandenberg H, Schneiderman J. Morphine excretion in breast milk and routine exposure of a nursing infant. *J Toxicol Clin Toxicol.* 1990;28(3):365-70.
81. Madadi P, Ross CJ, Hayden MR, Carleton BC, Gaedigk A, Leeder JS, et al. Pharmacogenetics of neonatal opioid toxicity following maternal use of codeine during breastfeeding: a case-control study. *Clin Pharmacol Ther.* 2009;85(1):31-5.
82. Koren G, Cairns J, Chitayat D, Gaedigk A, Leeder SJ. Pharmacogenetics of morphine poisoning in a breastfed neonate of a codeine-prescribed mother. *Lancet.* 2006;368(9536):704.
83. Meineke I, Freudenthaler S, Hofmann U, Schaeffeler E, Mikus G, Schwab M, et al. Pharmacokinetic modelling of morphine, morphine-3-glucuronide and morphine-6-glucuronide in plasma and cerebrospinal fluid of neurosurgical patients after short-term infusion of morphine. *Br J Clin Pharmacol.* 2002;54(6):592-603.
84. Chau N, Elliot DJ, Lewis BC, Burns K, Johnston MR, Mackenzie PI, et al. Morphine glucuronidation and glucosidation represent complementary metabolic pathways which are both catalyzed by UDP-glucuronosyltransferase 2B7: kinetic, inhibition and molecular modelling studies. *J Pharmacol Exp Ther.* 2014;349(1):126-37.
85. Kelly LE, Chaudhry SA, Rieder MJ, 't Jong G, Moretti ME, Lausman A, et al. A clinical tool for reducing central nervous system depression among neonates exposed to codeine through breast milk. *PLoS One.* 2013;8(7):e70073.
86. Cascorbi I. Pharmacogenetics of cytochrome p4502D6: genetic background and clinical implication. *Eur J Clin Invest.* 2003;33 Suppl 2:17-22.
87. Madadi P, Avard D, Koren G. Pharmacogenetics of opioids for the treatment of acute maternal pain during pregnancy and lactation. *Curr Drug Metab.* 2012;13(6):721-7.
88. Benedetti MS, Whomsley R, Canning M. Drug metabolism in the paediatric population and in the elderly. *Drug Discov Today.* 2007;12(15-16):599-610.

89. Lam J, Kelly L, Ciszkowski C, Landsmeer ML, Nauta M, Carleton BC, et al. Central nervous system depression of neonates breastfed by mothers receiving oxycodone for postpartum analgesia. *J Pediatr.* 2012;160(1):33–7.e2.
90. Seaton S, Reeves M, McLean S. Oxycodone as a component of multimodal analgesia for lactating mothers after Caesarean section: relationships between maternal plasma, breast milk and neonatal plasma levels. *Aust N Z J Obstet Gynaecol.* 2007;47(3):181–5.
91. Whitelaw AG, Cummings AJ, McFadyen IR. Effect of maternal lorazepam on the neonate. *Br Med J (Clin Res Ed).* 1981;282(6270):1106–8.
92. Kelly LE, Poon S, Madadi P, Koren G. Neonatal benzodiazepines exposure during breast-feeding. *J Pediatr.* 2012;161(3):448–51.
93. Erkkola R, Kanto J. Diazepam and breast-feeding. *Lancet.* 1972;1(7762):1235–6.
94. Wesson DR, Camber S, Harkey M, Smith DE. Diazepam and desmethyldiazepam in breast milk. *J Psychoactive Drugs.* 1985;17(1):55–6.
95. Patrick MJ, Tilstone WJ, Reavey P. Diazepam and breast-feeding. *Lancet.* 1972;1(7749):542–3.
96. Chaves RG, Lamounier JA, Cesar CC. Association between duration of breastfeeding and drug therapy. *Asian Pac J Trop Dis.* 2011;1:216–21.
97. Lorazepam oral tablets. Corona: Watson Laboratories; 2008. Package insert.
98. Katz FH, Duncan BR. Letter: entry of prednisone into human milk. *N Engl J Med.* 1975;293(22):1154.
99. Sagraves R, Kaiser D, Sharpe GL. Prednisone and prednisolone concentrations in the milk of a lactating mother. *Drug Intell Clin Pharm.* 1981;15:484; Abstract.
100. Berlin Jr CM, Kaiser DG, Demers L. Excretion of prednisone and prednisolone in human milk. *Pharmacologist.* 1979;21:264; Abstract.
101. Ost L, Wettrell G, Bjorkhem I, Rane A. Prednisolone excretion in human milk. *J Pediatr.* 1985;106(6):1008–11.
102. Schaefer C. *Drugs during pregnancy and lactation: handbook of prescription drugs and comparative risk assessment: with updated information on recreational drugs.* 1st ed. Amsterdam: Elsevier; 2001. xi, 368 p.
103. Anderson PO. Corticosteroid use by breast-feeding mothers. *Clin Pharm.* 1987;6(6):445.
104. Babwah TJ, Nunes P, Maharaj RG. An unexpected temporary suppression of lactation after a local corticosteroid injection for tenosynovitis. *Eur J Gen Pract.* 2013;19(4):248–50.
105. McGuire E. Sudden loss of milk supply following high-dose triamcinolone (Kenacort) injection. *Breastfeed Rev.* 2012;20(1):32–4.
106. Henderson JJ, Hartmann PE, Newnham JP, Simmer K. Effect of preterm birth and antenatal corticosteroid treatment on lactogenesis II in women. *Pediatrics.* 2008;121(1):e92–100.
107. Giuliani M, Grossi GB, Pileri M, Lajolo C, Casparrini G. Could local anesthesia while breast-feeding be harmful to infants? *J Pediatr Gastroenterol Nutr.* 2001;32(2):142–4.
108. Baker PA, Schroeder D. Interpleural bupivacaine for postoperative pain during lactation. *Anesth Analg.* 1989;69(3):400–2.
109. Ortega D, Viviani X, Lorec AM, Gamberre M, Martin C, Bruguerolle B. Excretion of lidocaine and bupivacaine in breast milk following epidural anesthesia for cesarean delivery. *Acta Anaesthesiol Scand.* 1999;43(4):394–7.
110. Matsota PK, Markantonis SL, Fouteri MZ, Pandazi AK, Manikis DE, Christodouloupoulou TC, et al. Excretion of ropivacaine in breast milk during patient-controlled epidural analgesia after cesarean delivery. *Reg Anesth Pain Med.* 2009;34(2):126–9.
111. Goodman LS, Gilman A, Brunton LL. *Goodman & Gilman's manual of pharmacology and therapeutics.* New York: McGraw-Hill Medical; 2008. ix, 1219 p.
112. American Academy of Pediatrics Committee on Drugs. Transfer of drugs and other chemicals into human milk. *Pediatrics.* 2001;108(3):776–89.
113. World Health Organization, UNICEF. *Breastfeeding and maternal medication. Recommendations for drugs in the eleventh WHO model list of essential drugs.* Geneva: WHO, UNICEF; 2002.

Chapter 15

Exercise in Pregnancy and Postpartum

Kate E. Temme

Introduction

The benefits of physical activity in the nonpregnant population are well-documented in the literature. Regular physical activity decreases the incidence of type II diabetes (T2DM), metabolic syndrome, and cardiovascular disease [1]. Prevalence of certain cancers is lower among those who exercise regularly. Exercise and physical activity play a critical role in blood pressure and weight control, and are associated with improved lipid profiles and insulin sensitivity [1]. Overall, physically active individuals demonstrate lower morbidity and mortality when compared to their sedentary peers, as evidenced by improved metabolic, physiologic, psychological, and cognitive health [1–3].

These well-documented benefits served as a basis for the 2008 US Department of Health and Human Services Federal Physical Activity Guidelines and the associated 2011 American College of Sports Medicine (ACSM) Position Stand [1, 4]. Both organizations recommend that adults complete at least 150 min of moderate-intensity aerobic physical activity/exercise per week (~1,000 kcal/week), in intervals of ≥ 30 min on ≥ 5 days/week, unless medically contraindicated. Alternatively, these recommendations can be met with shorter intervals of vigorous intensity exercise (≥ 20 min, ≥ 3 days/week, ≥ 75 min/week), or a combination of moderate and vigorous intensity exercise [4]. Additionally, the ACSM recommends that strength training, flexibility, and neuromuscular control exercises be incorporated into an individual's exercise regimen at least twice per week [4].

K.E. Temme, MD (✉)

Department of Physical Medicine and Rehabilitation, Sports Medicine and Women's Health, University of Pennsylvania, 1800 Lombard Street, 1st Floor, Philadelphia, PA 19146, USA

Department of Orthopaedic Surgery, University of Pennsylvania, Sports Medicine Center, 235 S. 33rd Street, Philadelphia, PA 19104, USA

e-mail: Kate.temme@uphs.upenn.edu

While it may seem intuitive that exercise would promote similar benefits among pregnant and postpartum women, applicable research and recommendations have historically lagged behind those targeted to the general adult population.

Pregnancy and Exercise: A Historical Perspective

The importance of exercise during pregnancy and the postpartum period has gained support in recent years as research has enhanced our appreciation of the benefits, and the safety, of exercise in these women [1, 4]. This challenges earlier recommendations for more limited exertion in pregnancy that was based upon hypothetical safety concerns for the mother and fetus. In the 1950s, pregnant women were allowed to continue household chores and walk 1 mile/day, divided into brief intervals, but were discouraged from participation in formal sports and exercise regimens [5].

In 1985, the American College of Obstetricians and Gynecologists (ACOG) released their first official guidelines for exercise during pregnancy [6]. Due to limited available research, recommendations were conservative. Pregnant women were advised to exercise at a heart rate ≤ 140 beats per minute (bpm) and to limit strenuous exercise to ≤ 15 min intervals. The upper limit of this recommendation roughly correlated to the ACSM's lower limit of physical activity for the general healthy adult population [7]. Additionally, obesity and sedentary maternal lifestyles were considered relative contraindications to exercise in pregnancy. In general, ACOG advised that previously inactive women avoid vigorous exercise in pregnancy and that previously active women reduce exercise intensity to prevent fetal harm [6].

In 1994, based upon a proliferation of relevant research, ACOG's updated guidelines removed the heart-rate restriction and relaxed the exercise recommendations to encompass ≥ 30 min on 3 or more days per week [8]. Activity adjustments were to be based on maternal symptoms, and women were encouraged to resume exercise gradually as tolerated postpartum. To date, the 2002 ACOG guidelines (reaffirmed in 2009) are the most progressive guidelines published by the organization [9]. These guidelines support the many benefits of regular exercise for pregnant women and the lack of maternal and fetal risks. ACOG recommends that after clinical evaluation, and in the absence of contraindications (Table 15.1), pregnant women should follow the same physical activity guidelines proposed by the ACSM-CDC for the nonpregnant population [10]. Participation in ≥ 30 min of moderate-intensity exercise is recommended on most, if not all, days of the week [9, 10]. The guidelines acknowledge that safety information for vigorous activity is limited, and high intensity activity in conditioned athletes requires close medical supervision. Previously inactive individuals required medical evaluation prior to exercise program initiation. Supine exercise should be avoided after the first trimester, motionless standing is discouraged throughout pregnancy, and certain sports should be avoided due to risk of injury to mother and fetus (Table 15.2). Additionally, ACOG recommends

Table 15.1 ACOG guidelines: contraindications to aerobic exercise during pregnancy [9]^a

Absolute contraindications	Relative contraindications	Warning signs for exercise termination
Hemodynamically significant heart disease	Severe anemia	Vaginal bleeding
Restrictive lung disease	Unevaluated maternal cardiac arrhythmia	Dyspnea prior to exertion
Incompetent cervix/ cerclage	Chronic bronchitis	Dizziness
Multiple gestation at risk for premature labor	Poorly controlled type 1 diabetes	Headache
Persistent second- or third-trimester bleeding	Extreme morbid obesity	Chest pain
Placenta previa after 26 weeks of gestation	Extreme underweight (BMI < 12)	Muscle weakness
Premature labor during the current pregnancy	History of extremely sedentary lifestyle	Calf pain or swelling
Ruptured membranes	Intrauterine growth restriction in current pregnancy	Preterm labor
Preeclampsia	Poorly controlled hypertension	Decreased fetal movement
Pregnancy-induced hypertension	Orthopedic limitations	Amniotic fluid leakage
	Poorly controlled seizure disorder	
	Poorly controlled hyperthyroidism	
	Heavy smoker	

^aFrom: Practice, C.o.O., ACOG committee opinion. Exercise during pregnancy and the postpartum period. Number 267, January 2002. American College of Obstetricians and Gynecologists. International journal of gynaecology and obstetrics: the official organ of the International Federation of Gynaecology and Obstetrics, 2002. 77(1): p. 79. Reprinted with permission from Wolters Kluwer Health

Table 15.2 ACOG: recommendations for exercise by sport type [9]

Recommended sports	Sports to avoid	Extreme risk
<i>Large muscle groups:</i> walking, swimming, stationary cycling, low impact aerobics	<i>Fall risk:</i> gymnastics, horseback riding, downhill skiing, road cycling, vigorous racquet sports	Waterskiing, surfing
	<i>Collision risk:</i> ice hockey, soccer, basketball	Scuba diving (decompression sickness, inability to filter bubble formation) Altitude >6,000 ft (nonacclimated)

activity reduction in the second and third trimester for women at risk for preterm labor or intrauterine growth restriction [9].

The 2008 Federal Physical Activity Guidelines for pregnant women similarly recommend that, in the absence of contraindications, a woman may begin or maintain a moderate-intensity physical activity regimen during pregnancy and the postpartum period [1]. The Federal guidelines recommend that less active individuals gradually build up to 150 min of moderate-intensity physical activity, spread throughout the week. For highly active pregnant women, physical activity in pregnancy can be maintained in the setting of continued health, and with appropriate intensity adjustments over time [1]. For all groups, activity should be terminated if certain warning signs appear (Table 15.1).

The liberalization of these guidelines allow for greater levels of physical activity among pregnant and postpartum women. However, implementation must overcome persistent historical beliefs that exercise poses both maternal and fetal health risks. Adoption of these guidelines should be a public health priority that utilizes educational initiatives to target both health practitioners and patients, while additionally supporting clinician counseling efforts in the prenatal period [11].

Prevalence of Physical Activity in Pregnancy

Physical activity refers to any skeletal muscle—induced body movement that increases energy expenditure above resting metabolic expenditure. Exercise is structured physical activity that is planned and repeated for fitness and health benefits [1]. In the literature, exercise, physical activity, and leisure time physical activity (LTPA) are terms often used interchangeably in the description of activity performed for fitness and health. The benefits of regular physical activity/exercise in pregnancy include improved maternal and fetal health, and decreased chronic disease risk factors. Aerobic exercise may maintain, or even improve, maternal physical fitness throughout pregnancy [12]. Despite these benefits, many pregnant women do not meet the current ACOG or Federal guidelines for physical activity. National Health and Nutrition Examination Survey (NHANES) data from 1999 to 2006 reported that only 57 % of pregnant women participated in some level of moderate to vigorous leisure time physical activity (LTPA), and only 54 % participated in any similar intensity household activity during the previous month [13]. In a recent study of >3,000 pregnant women, only 1/3 reported meeting current Federal guidelines [14]. A nationally representative sample study found lower rates of LTPA in pregnant versus nonpregnant counterparts (66 % vs. 73 %), with pregnant women showing greater deficits in LTPA guideline compliance (16 % vs. 21 %) [15]. Pregnant women in this study were more likely to engage in LTPA if they were younger, more educated, and in very good or excellent health. Negative predictors of prenatal LTPA participation included having other children, multiple gestations, pelvic girdle pain, and nausea [16].

Among pregnant women who do participate in LTPA, activity intensity and time commitment have been found to decline with each subsequent trimester [17–19]. At the international level, decreased physical activity participation and/or maintenance have also been noted in Irish, Danish, British, and Brazilian pregnancy studies [20–23]. The Brazilian study reported the most disquieting data, as less than 5 % of subjects remained physically active throughout pregnancy and only 13 % engaged in some physical activity during pregnancy [23].

Barriers to Physical Activity in Pregnancy

In 2008, almost seven million US women were pregnant, representing a pregnancy rate of 105 pregnancies per 1,000 women aged 15–44 [24]. This highlights the public health significance of physical activity participation in pregnancy, yet the majority of US pregnant women currently fail to meet these recommendations. Barriers to LTPA participation are numerous and occur at societal, medical, and individual levels. Physicians are advised to counsel women to exercise regularly in pregnancy, yet few women report receiving such instruction [25]. Multiple surveys of prenatal care providers report that a significant percentage fail to discuss exercise with their prenatal patients, which mirrors the studies in which patients report that counseling on physical activity during prenatal care is lacking [25, 26]. Inadequate knowledge dissemination of updated guidelines, combined with insufficient instruction on physical activity counseling in medical training may leave healthcare providers uncomfortable with this subject matter [27]. Additionally, while prenatal care affords the opportunity for frequent face-to-face contact, providers need feasible tools to track physical activity and provide appropriate counseling in a time-efficient manner.

In this regard, *Exercise is Medicine*®—a multiorganizational initiative spearheaded by the ACSM—seeks to improve national public health and well-being through promotion of regular physical activity counseling and prescriptions from healthcare and fitness providers. *Exercise is Medicine*® advocates the use of brief, validated clinical assessment tools such as the Physical Activity Vital Sign (PAVS), which quantifies weekly physical activity, and can efficiently be incorporated into clinical practice [11, 28]. After patient physical activity assessment, utilization of successful behavior change technique tools such as the “five A’s approach” (*assess, advise, agree, assist, arrange*) are recommended to facilitate change in physical activity levels in this population of women [11, 29, 30]. Studies have demonstrated that prenatal providers trained in behavioral change approaches to physical activity have positive effects on LTPA duration and maintenance in their pregnant patients [29, 31, 32].

Beyond the obstacles to LTPA associated with medical counseling and knowledge dissemination, there exist multiple barriers at the sociocultural level. In the United States, minority physical activity participation consistently ranks lower than that of Non-Hispanic Whites, with disparities more significant among women [33].

Socioeconomic factors play a major role in this disparity, with lower socioeconomic status and educational level being negatively correlated with physical activity levels [33, 34]. Previous intervention programs for African-American and Hispanic women have identified cultural, family, and friend support as critical influences in physical activity participation [35]. Access to safe, affordable exercise facilities, leisure time availability, and childcare options are often not feasible for low-income, minority, prenatal patients [35, 36]. At the cultural level, family and work obligations often supersede LTPA, which is frequently viewed as an individual indulgence reserved for higher-income populations [35]. Given that chronic diseases are disproportionately represented among US minority populations, public health initiatives must address these persistent barriers to LTPA in those women most at risk for negative health outcomes.

Importance of Physical Activity in Pregnancy: Maternal and Fetal Health Outcomes

Gestational Weight Gain, Prenatal, and Postpartum Obesity

The national obesity epidemic is far-reaching and of significant importance for pregnant and postpartum women and their health care providers. In 2011–2012, 2/3 of the US adult population qualified as overweight/obese, and more than 1/3 were obese [37]. The majority of US women of childbearing age are overweight or obese based on the Institute of Medicine (IOM) body mass index (BMI) guidelines (Table 15.3), which increases maternal risk of gestational diabetes, hypertensive complications, delivery of abnormal-weight infants, cesarean delivery, birth complications, and future incidence of obesity and chronic disease [38–40]. While being overweight or obese decreases fertility, those that do conceive have higher rates of birth-related complications, longer hospitalizations, higher delivery costs, and more frequent neonatal intensive care admissions than their normal-weight peers, as reflected by a fivefold increase in prenatal hospital care costs [41]. Infants born to morbidly obese mothers (BMI > 40) are more likely to experience fetal distress and low APGAR scores at delivery [41].

Additionally, nearly half of normal-weight women and 2/3 of overweight/obese women exceed the IOM gestational weight gain (GWG) guidelines in pregnancy (Table 15.3) [40, 42]. Compliance with Federal physical activity guidelines may be protective of excessive GWG [43]. Excessive GWG is independently associated with negative pregnancy outcomes, including prematurity, large-for-gestational-age infants, increased cesarean delivery, and decreased breastfeeding initiation rates [44]. The contributions of maternal obesity and excessive GWG to the fetal environment have delayed effects on offspring, as evidenced by increased incidence of obesity and chronic diseases in childhood [45]. Even among normal-weight women, high GWG predicts infant weight and adiposity at birth, which is predictive of later

Table 15.3 IOM guidelines: gestational weight gain by prepregnancy BMI classification [40]

BMI categorization (WHO)	BMI (kg/m ²)	GWG recommendations	Rates of GWG
			Second/Third trimester (lb/week) ^a
Underweight	<18.5	28–40	1.0 (1.0–1.3)
Normal weight	18.5–24.9	25–35	1.0 (0.8–1.0)
Overweight	25.0–29.9	15–25	0.6 (0.5–0.7)
Obese (all classes)	≥30	11–20	0.5 (0.4–0.6)

^aAssumes 0.5–2 kg (1.1–4.4 lb) weight gain in the first trimester

overweight and obese status in these offspring [46]. Excessive GWG is also a predictor of postpartum weight retention and subsequent categorization as overweight or obese by IOM standards. Among women with normal prepregnancy BMI who gain more than 20 kg in pregnancy, 1/4 will move up one BMI category at 6 months postpartum [44, 47]. Excessive GWG and failure to lose pregnancy weight by 6 months postpartum is a strong indicator of long-term maternal obesity, which is an independent risk factor for many chronic diseases, including cardiovascular disease and T2DM [46, 48].

Due to the documented effects of excessive GWG and obesity in regards to prenatal and maternal outcomes, the IOM revised their GWG recommendations in 2009 [40]. Two major changes occurred in the updated guidelines. First, BMI categories were updated from prior Metropolitan Life Insurance Table cutoffs to more stringent World Health Organization (WHO) categories. Second, based upon prepregnancy BMI, overweight or obese women were advised to gain progressively less weight during pregnancy than their normal-weight peers (Table 15.3) [40]. A recent large-scale study investigating the IOM guideline changes (2009 vs. 1990) on maternal prepregnancy BMI categorization noted that almost 17 % of women were re-categorized using 2009 IOM guidelines, with higher rates of overweight and obese categorization, which subsequently impacted GWG recommendations [49]. Based upon the updated IOM guidelines, over 50 % of subjects were classified as over-gainers during pregnancy, a trend that has been supported by multiple studies investigating GWG [43, 49]. Knowledge dissemination and acceptance of these guidelines becomes an important factor in prevention of excessive GWG in the future prenatal population.

While the sequelae of physical activity and exercise on weight control and obesity prevention are well supported in the general population, this association has been less thoroughly studied in pregnancy, especially in regards to overweight/obese women. There are multiple changes in cardiorespiratory responses attributed to obesity. Obesity has independent effects on the mechanical efficiency of breathing and ventilatory control [50]. Adipose deposition may decrease rib compliance, promoting rapid, shallow breathing. Additionally, the increased cost of moving larger limbs, decreased peripheral motor efficiency, and increased work of breathing contribute to changes in the ventilation-work rate relationship. From a cardiovascular

standpoint, obesity increases stroke volume and cardiac output in relation to body mass, with little effect on heart rate. Oxygen pulse (which estimates stroke volume) and arteriovenous oxygen difference are unchanged by obesity [50].

In pregnancy, cardiac output, stroke volume, and heart rate increase during the first trimester, while oxygen pulse remains stable in early pregnancy. In pregnant women, ventilation is increased at rest and with exercise at the same power output in comparison to the nonpregnant state. However, ventilation is increased in excess of metabolic demand, unlike in obesity, which is felt to be related to additional influences from increased levels of circulating female sex hormones. The combined cardiorespiratory effects of obesity and pregnancy in weight-bearing exercise were first evaluated in a small study of progressive treadmill testing that compared nonpregnant and normal-weight pregnant women to obese pregnant women [50]. Exercise promoted increased ventilatory responses in pregnant versus nonpregnant women, and this response was further increased by obesity. However, this additional augmentation was explained by the heightened metabolic demand of exercise in obese patients. The usual heart-rate augmentation of pregnancy in exercise was not further affected by obesity at submaximal work rates. In the obese pregnant group, overall exercise performance was decreased, as evidenced by reduced maximally tolerated speed and exercise duration, while the peak heart rate, aerobic capacity, and work rate were similar across groups. In obese pregnant subjects, this study demonstrated a reduced exercise capacity compared to normal-weight pregnant and nonpregnant women, but not due to ventilatory limitations to submaximal exercise (such as walking), lending support to the safety and feasibility of such exercise prescriptions in this population.

Walking is the most popular activity for pregnant women and frequency increases with pregnancy duration, as opposed to progressive declines in all other forms of physical activity [51]. Walking is an important avenue for aerobic exercise that is economical and easily implemented. Additionally, it seems intuitive that programs to prevent excessive GWG and affect obesity outcomes should include an exercise as well as a nutritional component. To date, a limited number of studies have evaluated the effects of combined nutrition and exercise interventions, and only a few have focused on outcomes in overweight/obese pregnant women. Of these studies, those that used education alone were not successful [52–55], nor were behavior-based interventions that lacked an individualized nutrition and exercise component [54].

However, a few studies have shown promise. A semi-supervised, moderate-intensity exercise program (utilizing walking or semi-recumbent biking) in combination with a nutritional intervention improved weekly exercise time and decreased weekly weight gain in obese pregnant women with gestational diabetes (GDM) in comparison to a diet-only group [56]. Mean exercise time was 153 min/week for the exercise and diet group, with 50 % of these subjects exceeding Federal physical activity recommendations. A pilot study of overweight GDM subjects participating in a mild walking program (30 % estimated heart-rate reserve- $\{HRR\}$), with incremental increase in time from 25 min, 3–4 sessions per week to 40 min per session was successful in regards to improved glucose regulation, and ½ of subjects avoided

excessive GWG [57]. In combination with activities of daily living, subject pedometer step counts approached 10,000 on exercise days.

A study investigating the effects of a Nutrition and Exercise Lifestyle Intervention Program (NELIP) in overweight and obese pregnant women used similar intervention protocols [58]. Subjects followed an individualized nutritional program (~2,000 kcal/day, 40–55 % carbohydrate) and a low-intensity walking program (30 % HRR) 3–4 times per week, utilizing pedometers. While excessive weight gain was found to occur prior to study commencement at 16–20 weeks gestation, only 20 % exceeded recommended GWG while on NELIP. Weight retention at 2 months postpartum was low for both groups.

The health implications of excessive GWG are not exclusive to overweight and obese women, as up to 40 % of normal-weight women will gain excessively during pregnancy [46]. A large prospective study of multiparity in normal-weight women showed that excessive GWG during a women's first pregnancy increased her risk of being overweight by her second pregnancy [59]. Similarly, a prospective cohort study demonstrated that 14 % and 4 % of previously normal-weight women were overweight and obese, respectively, at 1 year postpartum [60]. A recent study of normal-weight pregnant women demonstrated that nutritional control in conjunction with a supervised low (30 % HRR) or moderate-intensity (70 % HRR) walking program (gradually increased from 25 to 40 min, 3–4 times per week), prevented excessive GWG during the intervention in 70 % of the low-intensity and 77 % of the moderate-intensity experimental group [46]. Additionally, weight retention of ≤ 2 kg at 2 months postpartum was more common in the combined nutrition and exercise groups versus nutritional control group, with greater reductions in the moderate-intensity group [46]. However, excessive weight gain was also noted prior to the interventions' second trimester initiation. Given that excessive GWG in the first half of pregnancy more strongly predicts infant adiposity at birth than overall maternal weight gain, early initiation of nutrition and exercise interventions may have more significant effects on pregnancy outcomes, and more strongly affect childhood BMI [61]. These studies demonstrate that even low-intensity walking programs can affect GWG and subsequent outcomes, which highlights implementation feasibility, especially among previously sedentary obese prenatal patients [46, 58].

Gestational Diabetes: Prevention, Management, and Long-Term Sequelae

GDM is the most common metabolic disorder of pregnancy, affecting approximately 7 % of US pregnancies and representing 200,000 cases annually [62]. GDM is defined by glucose intolerance that first presents in pregnancy, and usually resolves postpartum. GDM is often considered a transient form of T2DM, triggered by pregnancy-induced metabolic and hormonal changes. GDM is usually diagnosed between 24 and 28 weeks gestation, based upon abnormal glucose tolerance test results [62]. Uncontrolled GDM has many potential negative acute health risks for

both the mother and fetus. GDM is associated with large-for-gestational age (LGA) infants with increased adiposity due to increased maternal glucose available for fetal growth. This growth is often disproportional in regards to shoulder growth, which in combination with larger weight, may contribute to the higher rates of cesarean section with GDM [5]. Additionally, higher rates of stillbirth and infant hypoglycemia immediately following delivery are reported [63, 64].

Postpartum, women with a history of GDM or impaired prenatal glucose tolerance demonstrate declines in pancreatic β -cell function, which likely contribute to increased incidence of T2DM within 5–10 years postpartum, a risk that is intensified by elevated BMI [62, 65, 66]. Delayed offspring effects include increased risk of obesity, insulin resistance, T2DM, and metabolic syndrome later in life [67]. Due to the potential adverse effects of GDM on long-term outcomes for mother and child, prevention and management becomes a critical priority for prenatal care.

Adaptive metabolic changes of normal pregnancies to promote fetal growth include increased mid-pregnancy insulin resistance, a phenomenon which continues until delivery. The placenta releases placental growth hormone, which promotes relative maternal skeletal muscle insulin resistance, and increases maternal blood glucose availability for fetal growth and development. Additionally, human placental lactogen and prolactin promote maternal dietary intake increases [68]. These effects are usually compensated for by maternal pancreatic β -cell expansion and subsequent increases (>200 %) in circulating insulin concentration [69]. However, in some women, β -cell insulin production cannot counterbalance increased insulin resistance, leading to GDM. This risk is further increased by elevated BMI, physical inactivity, and poor dietary choices [70]. Additionally, a previous history of GDM, macrosomic delivery, advanced maternal age, high-risk racial/ethnic populations, polycystic ovarian syndrome, and corticosteroid use are also associated with an elevated risk of GDM development [67].

GDM Prevention

Given that the prenatal metabolic changes in insulin sensitivity occur at the skeletal muscle level, it seems intuitive that physical activity might affect GDM incidence and outcomes. This relationship has been demonstrated in the nonpregnant population, where physical activity is associated with improved glucose parameters, insulin sensitivity, and prevention of T2DM [67, 71, 72]. A prospective cohort study of >20,000 women demonstrated protective effects of prepregnancy physical activity (both moderate and high intensity) for the prevention of GDM [73]. Prior studies evaluating GDM prevention and management have been limited, and differing methodologies, patient populations, and compliance rates impair study comparisons. Recent systematic reviews and a meta-analysis found no difference between exercise interventions and routine prenatal care in regards to GDM incidence [74–76]. Inclusion in these reviews was restricted to randomized controlled trials,

for which data is currently limited. A 2013 review of exercise-based (+/- nutritional component) GDM prevention and management interventions, including all study types, found mixed results among the eight study outcomes [67]. Three studies with high exercise compliance found improved glucose parameters versus controls, yet no effect on the incidence of GDM [77–79]. The remaining five exercise intervention studies, including two combined exercise and nutrition interventions, did not improve glucose tolerance, insulin sensitivity, or prevent GDM [80–84]. All but one reported poor compliance, which may limit interpretation of results. Overall, the limitations of available results highlight the need for further large-scale investigation of the possible protective effect of physical activity against GDM.

GDM Management

In the setting of GDM management, results have been more promising. Since GDM diet therapy is still considered the cornerstone of GDM management [62], studies have investigated the additional effect of activity-based interventions on glycemic control in GDM. Several studies have demonstrated improved glycemic control and/or decreased insulin requirements compared to those receiving only medical nutritional management. A 6-week arm ergometry study (20 min, 3–4 times per week) normalized fasting and 1-h postprandial glucose levels and hemoglobin A1C in women with GDM [85]. A study that compared the effects of nutrition plus insulin to nutrition plus exercise (stationary bike, 45 min, 3 times per week) demonstrated similar glycemic control, suggesting exercise increases insulin sensitivity and may replace/decrease insulin requirements in GDM management [86]. In a pilot study of 30 GDM patients, the low-intensity walking group (30 % HRR, 3–4 times per week) demonstrated improved glucose concentrations and lower insulin requirements as compared to the conventional management group [57]. In a randomized, circuit-based resistance exercise plus nutrition program (versus nutrition alone), decreased insulin prescription and prolonged latency to insulin initiation was demonstrated in the exercise group, especially among the overweight/obese exercises [87]. Other studies have shown improved cardiorespiratory fitness [88], and controlled GWG [56], but failed to show improvements in glycemic control and/or insulin requirements.

To date, despite limited and sometimes conflicting literature, in the absence of medical contraindications, exercise is recommended as an adjunctive treatment for GDM by several organizations including the American Dietetic Association (ADA), ACOG, ACSM, and the Canadian Diabetes Association [5]. Given the well-documented benefits of regular exercise in nonpregnant T2DM management [89], it is hopeful that future large-scale, well-controlled studies will better solidify a similar benefit of exercise for the treatment of GDM. Additionally, further investigation will be essential to clarify the frequency, intensity, type, and time (FITT) of physical activity necessary to best improve GDM outcomes [90].

Preeclampsia

Hypertensive disorders of pregnancy are a leading cause of maternal death worldwide, and account for up to 15 % of maternal deaths in the United States [91, 92]. Many potentially lethal outcomes are associated with maternal hypertensive disorders including disseminated intravascular coagulation, placental abruption, cerebral hemorrhage, and hepatic and renal failure [93]. Preeclampsia is a common hypertensive disorder in pregnancy, with an incidence of 2–7 % among healthy nulliparous women [94]. Preeclampsia usually presents in the second half of pregnancy as persistent hypertension and proteinuria, and is associated with other metabolic abnormalities commonly found in coronary heart disease (CHD). In the absence of proteinuria, it is also diagnosed in the setting of persistent hypertension with evidence of major organ dysfunction.

Women with preeclampsia, in comparison to their normotensive counterparts, have a higher risk of abnormal lipid profiles, antioxidant deficiency, elevated inflammatory markers, insulin resistance, sympathetic overdrive, and vasoconstriction [5]. Placental hypoperfusion is felt to play an important role in preeclampsia development [94]. Placental lesions in preeclampsia are similar to atherosclerotic lesions [95], with more severe lesions associated with increased disease severity and maternal death [96]. Preeclampsia can have devastating effects on both mother and fetus, and is responsible for 15 % of preterm deliveries, with subsequent associated morbidity and mortality [97]. Intrauterine growth restriction and fetal death are also associated with preeclampsia [98]. Prompt identification and management of preeclampsia has improved maternal and fetal outcomes in developed countries, but mortality remains higher in developing countries. While the underlying processes responsible for preeclampsia often begin in early pregnancy, the symptoms usually present in mid to late pregnancy, and can escalate rapidly. Preeclampsia can evolve into eclampsia (including life threatening seizures and/or coma) or HELLP syndrome (hemolysis, elevated liver enzymes and low platelet count) and necessitate immediate delivery regardless of gestational age.

Given that the current standard of treatment for preeclampsia is appropriately timed delivery, identification and management of risk factors and development of other prevention strategies is of significant clinical importance. Preeclampsia occurs most often in primiparous women, with higher risks noted in younger women and those with multiple gestations [94]. Prior history of preeclampsia increases the occurrence in future pregnancies. Other risk factors for preeclampsia include obesity, sedentary lifestyle, diabetes, depression, anxiety, and a family history of essential hypertension [5]. Given the overlap in pathophysiology and epidemiology between preeclampsia, essential hypertension, and CHD, it is not surprising that a history of gestational hypertension or preeclampsia predicts an elevated incidence of essential hypertension in the years following affected pregnancies [99].

Sedentary lifestyles are considered by the American Heart Association (AHA) to be one of the five major risk factors (including obesity, hypertension, abnormal lipid profiles, and smoking) for the development of CHD [100]. CHD in active individuals

occurs less often, later in life and is usually less severe [100]. Exercise is supported for primary disease prevention and management of various cardiovascular conditions by the CDC, ACSM, and AHA. In the nonpregnant population, exercise is well documented to decrease cardiac risk factors through blood pressure control, weight loss, and lipid profile optimization.

While cardiovascular complications have significant maternal mortality implications, little is known about the cardiovascular benefits of regular physical activity in pregnant women. In pregnant women with mild prenatal hypertension, gestational hypertension or familial risk factors, exercise has demonstrated trends in decreased diastolic blood pressure [101]. In regards to preeclampsia, proposed underlying mechanisms for the role of physical activity in preeclampsia prevention include stimulation of placental vascularity and growth, reduction in oxidative stress, and reversal of maternal endothelial dysfunction [94]. Potential mediators include decreases in inflammatory cytokines, leptin, and oxidative stress, and improvements in lipid profiles and lipoprotein concentrations [5]. Placental analysis of exercising mothers demonstrates increased vascularity and decreased nonfunctional tissue in relation to placentas from high-risk pregnancies, which is felt to occur as adaptive responses to transient decreases in fetal and placental oxygen supply during exercise [94]. Additionally, regular exercise promotes adaptive antioxidant upregulation, which likely mitigates the prooxidant stressors of acute exercise, and may reduce the oxidative stress that contributes to endothelial dysfunction in preeclampsia [94].

Several prior studies have supported the possible protective effect of regular physical activity on preeclampsia development. A retrospective study evaluated the effects of LTPA during the first half of pregnancy and found a reduction of preeclampsia and gestational hypertension in active primiparous women compared to sedentary controls. Those who dedicated more time to LTPA experienced greater reduction in risk for preeclampsia [102]. Another study demonstrated that regular LTPA in the first 20 weeks of pregnancy correlated with an overall 35 % risk reduction of preeclampsia, which decreased in relation to the intensity and energy expended in LTPA [103]. Moderate and vigorous intensity exercises were associated with 24 % and 54 % risk reduction, respectively. Those who engaged in vigorous recreational activity in the year prior to pregnancy had a 60 % relative risk reduction. Additional benefits were noted in women who climbed stairs regularly, regardless of LTPA participation. These findings were supported by a case-control study of work and leisure time physical activities in the development of preeclampsia, but found no effects on gestational hypertension incidence [104]. A recent systematic review found an overall protective trend of physical activity (including LTPA and sports) on preeclampsia prevention, but noted concerns for increased risks among women with physically demanding occupations [105]. Limitations of the review included heterogeneity of the studies sampled and scarcity of randomized controlled trials. A 2013 systematic review and meta-analysis of the effects of occupational physical activity exposures (including work hours, shift work, lifting, standing and heavy physical activity) on preeclampsia and gestational hypertension found insufficient data to affect workplace guidelines [106].

Sedentary women with a prior history of preeclampsia are at high risk for recurrence in subsequent pregnancies. The benefits of structured exercise programs for the prevention of recurrent preeclampsia have been evaluated. In a pilot study by Yeo et al., sedentary, pregnant women with a previous history of preeclampsia were randomized to a walking or stretching exercise program [107]. While the rate of gestational hypertension was higher in the stretching group (40 % vs. 22 %, $p=0.110$), the incidence of recurrent preeclampsia was surprisingly higher in the walking group (14.6 % vs. 2.6 %, $p=0.141$). During labor, stretchers demonstrated a higher mean transferrin level, a marker of antioxidant status, suggesting an antioxidant contribution of stretching to preeclampsia prevention in these high-risk women. Though limited by a small sample size, the authors suggested that stretching might have been better tolerated in this high-risk, sedentary group. A follow-up larger cohort study of high-risk women found more favorable effects on resting heart rate and blood pressure in the stretching group, possibly associated with higher compliance rates versus the walking group [108]. Additionally, while both groups' activity participation declined as their pregnancies progressed, a sharper decline was noted in the walking group. This suggests that activity compliance and feasibility, in addition to cardiovascular effects, should be considered in preeclampsia prevention in sedentary individuals.

Since ACOG considers pregnancy-induced hypertension and preeclampsia to be absolute contraindications to aerobic exercise in pregnancy [9], the primary role of exercise in these conditions is preventative. Evidence suggests that regular physical activity in pregnancy is protective of gestational hypertension and preeclampsia, and these benefits may be more profound in the setting of prepregnancy and early pregnancy physical activity. Further well-designed, large-scale, randomized controlled trials will be necessary to clarify the protective role of physical activity in the prevention of preeclampsia and related hypertensive disorders, and to quantify the FITT activity parameters necessary to maximize beneficial outcomes.

Low Back and Pelvic Girdle Pain

Musculoskeletal complaints are common in pregnancy, yet often overlooked by both health care professionals and patients. Musculoskeletal concerns are limiting in regards to quality of life and functional status during prenatal and postpartum periods. Early identification and treatment may decrease the level of disability attributed to many of these conditions.

Low back pain (LBP) is a common occurrence in pregnancy, affecting up to two thirds of women [109]. While common, LBP should not be considered an unavoidable consequence of pregnancy. LBP can be disabling, as 1/3 of pregnant women report adverse effects on daily function, and 11 % of women will take sick leave in response to LBP [109]. Persistent LBP in pregnancy is associated with decreased activity levels and depression [110]. Despite these negative consequences, only 1/3 of pregnant women will report LBP to their healthcare providers during pregnancy

and even fewer providers will recommend treatment [109]. Healthcare providers often lack sufficient knowledge of treatment options for pregnancy-related LBP, are concerned with the potential negative effects on fetal health, or believe that delivery is the only effective option for alleviation of LBP [111, 112]. Unfortunately, without treatment, women have increasingly requested cesarean sections and labor induction in the hopes of LBP alleviation, and one in five affected women will avoid future pregnancies due to concern for recurrent symptoms [113].

Some uncertainty remains about risk factors for LBP in pregnancy. The only consistently reported risk factor is a prior history of LBP [113–115]. Up to 85 % percent of women with a history of pregnancy-related LBP will develop symptoms in subsequent pregnancies, and those with a history of nonpregnant LBP are 50 % more likely to develop LBP during pregnancy than women without a prior history [113, 116]. Unfortunately, despite popular belief, LBP does not always resolve postpartum. Ten percent of women with chronic LBP date their symptom onset to pregnancy [117]. Risk factors for chronicity include severity of pregnancy-related LBP, advanced maternal age, and LBP that predated pregnancy [5].

Mechanisms of pregnancy-related LBP are likely multifactorial, and may include biomechanical/musculoskeletal, hormonal and vascular etiologies. Historically, musculoskeletal complaints, including LBP, were often linked to the hormonal changes of pregnancy which promote ligamentous laxity. Relaxin is produced by the decidua and placenta during pregnancy to stimulate pelvic connective tissue remodeling in preparation for delivery, an effect that is enhanced by estrogen. Relaxin levels peak around the 12th week of gestation, decline until week 17, and then remain stable until delivery [110, 118]. Several studies have investigated the effects of relaxin levels on joint laxity and musculoskeletal complaints. Results have failed to solidify an association between relaxin levels and incidence of LBP, or a clear relationship between relaxin levels and extent of joint laxity [118–121]. Therefore, hormonal changes alone are unlikely to explain the phenomenon of pregnancy-related LBP.

The vascular theory relates to LBP in supine positioning, and the effects of the growing uterus on vascular congestion/hypoxia in the lumbar and pelvic regions through compression of the vena cava. For this reason, ACOG recommends that women avoid exercising and sleeping in a supine position during the second half of pregnancy. Recently, however, the focus has shifted to a biomechanical/musculoskeletal etiology of LBP. Weight gain of 25–35 lb is recommended for normal-weight women during pregnancy, which leads to an anterior center of gravity (COG) shift, increased anterior pelvic tilt, increased flexion moment of the lumbar spine, and increased stabilization load of the spinal musculature, and strain of the sacroiliac joints and ligaments [122]. A 20 % weight gain corresponds to 100 % increased force through a joint, a factor compounded by obesity [123]. Hyperlordosis is a controversial cause of LBP in pregnancy. One study found that lordosis does not increase in pregnancy while several others have reported an increase in lordosis (see Chap. 1). However, those with preexisting hyperlordosis might be at increased risk of pregnancy-related LBP [124].

Abdominal diameters, both sagittal and transverse, have been associated with LBP in pregnancy, possibly as a result of weakened abdominal musculature in the setting of increased stretch [124]. Additionally, these biomechanical changes place increased strain on surrounding musculature. Decreased endurance, activation or strength of lumbar extensors, lumbar flexors, lateral trunk stabilizers, hip extensors, and hip abductors have all been implicated in pregnancy-related LBP [125–129].

Many of the same mechanistic concepts of LBP in pregnancy apply to pelvic girdle pain (PGP) in pregnancy. While LBP is defined as pain occurring in the lumbar region, PGP is usually reserved for pain that occurs between the posterior iliac crests and gluteal folds, and often involves the sacroiliac joint(s) and/or pubic symphysis [130]. Risk factors for PGP in pregnancy include a history of LBP or prior pelvic trauma [130]. PGP may occur in conjunction, or separately from LBP in pregnancy. PGP is thought to be more prevalent and often more disabling than LBP in pregnancy, but it tends to resolve more rapidly postpartum [130–132]. PGP is often intermittent and aggravated by prolonged standing, sitting, and walking. Asymmetric transitional movements, stairs, and single-leg stance often exacerbate PGP, yet spinal range of motion is unaffected [130, 133]. Avoidance of asymmetric or high impact biomechanical strain during prenatal exercise should be considered.

While an exact etiology of LBP and PGP in pregnancy has yet to be defined, several therapeutic options have shown promise in regards to treating these conditions, including exercise and physical therapy. Prenatal and prepartum exercises are associated with lower rates and severity of prenatal LBP and PGP [132, 134, 135]. Water exercise in the second half of pregnancy has been found to decrease LBP severity, which may have implications for long-term LBP incidence, as LBP severity predicts chronicity [5, 136]. Given that biomechanical imbalances including trunk and hip muscle weakness or endurance deficits are associated with LBP and PGP in pregnancy, an exercise prescription that focuses on core and hip stabilization may be preventative of these conditions. A recent randomized trial supports this theory, as subjects who received physical therapy with guided stabilization exercises had greater PGP reduction in comparison to those who did not receive a stabilization program [5, 137]. Additionally, the effects of core stability on the pelvic floor and abdominal musculature during pregnancy should be considered. Further research is needed to solidify the underlying mechanisms of prenatal LBP and PGP as well as to guide exercise and physical therapy prescriptions for these potentially disabling conditions.

Prenatal and Postpartum Mental Health

Depression is a common mental health concern among US adults. The CDC reports that 9.1 % of US adults currently meet the criteria for depression, including 4.1 % with major depression [138]. Women are at a higher risk for depression than men, with a 20–25 % lifetime prevalence [139, 140]. Pregnancy is a time of heightened

depression risk among women, as up to one in five women will be affected during the prenatal period [141, 142]. Anxiety disorders are also common in pregnancy, and often occur in conjunction with depression. Pregnancy-related mood fluctuations may result from hormonal influences and psychosocial factors. Pregnancy can be a time of altered body image, decreased sleep, change in usual roles and routines and incite a sense of loss of control, all of which can contribute to maternal stress responses [5]. In addition, women with a family or personal history of depression, chronic health conditions, lower education status, and economic or other stressors are at an increased risk of perinatal depression [138, 143]. Prenatal depression increases the risk of adverse maternal health outcomes, including postpartum and lifetime depression risk, and has negative implications for offspring. Perinatal depression has been linked to preterm labor, low birth weight, longer hospital stays, and decreased breastfeeding compliance [144, 145]. Depression may decrease medical care compliance, self-care, family role functioning, income and maternal-offspring bonding. At the extreme, postpartum depression can lead to suicidal ideations and risk of physical harm to mother or child. Offspring of women with postpartum depression demonstrate negative effects in regards to physical and cognitive growth and development, stress reactivity, childhood mental disorders, and independence [146].

Given the strong association of prenatal depression to negative maternal and offspring outcomes, prevention and treatment of depression is a health priority for affected women and the physicians who care for them. In the general population, psychological counseling and antidepressant pharmacotherapy are effective treatment options for rate reduction of depression [146]. However, counseling can be cost prohibitive, and medication use during pregnancy or breastfeeding may be limited by safety concerns. For these reasons, complementary therapies, including exercise, should be considered. In the general population an inverse relationship has been reported between physical activity and incidence of depression [147]. In those with depression, physical activity is known to alleviate depressive symptoms [147, 148].

While the benefits of exercise on prevention and treatment of prenatal and postpartum depression are less clear, several studies have shown promising results. In 2010, a systematic review of observational studies found that pregnancy LTPA led to a reduction in anxiety and depression and improvements in self-esteem [149]. Improvements in body image through exercise may also be protective against depression in pregnancy [150]. A recent randomized controlled trial found significant decreases in depressive symptoms among pregnant women who participated in a 3-month supervised exercise program. In a group of pregnant adolescents, a 6-week aerobic exercise program decreased depressive symptoms and increased self-esteem in the interventional group, while the controls demonstrated increased physical discomforts during the same interval [151]. However, in a 12-week postpartum exercise and strengthening program, decreased depression rates were noted only in those who did not exercise prior to pregnancy. Studies by Da Costa and Demissie found inverse relationships between self-reported physical activity levels

in pregnancy and symptoms of depression and anxiety [152, 153]. This relationship was further supported by an NHANES study which evaluated accelerometer data, an objective measure of physical activity, in relation to depression symptoms. Women with higher levels of physical activity were less likely to report depressive symptoms. Conversely, women with depressive symptoms were less likely to meet physical activity guidelines than those without symptoms [146]. Exercise remains a promising therapy option for perinatal depression. Further research will be beneficial in regards to solidifying the FITT physical activity parameters most effective for the treatment and prevention of depression in the prenatal and postpartum periods.

Labor and Delivery

The effects of exercise on labor and delivery outcomes remain a longstanding topic of debate. Dating back to the 1960s, Hungarian athletes were found to have a 50 % lower chance of cesarean section versus their sedentary peers [154]. Continued exercise has predicted lower rates of cesarean and operative vaginal deliveries in recreational endurance athletes [155]. Hall and Kaufmann found lower a incidence of cesarean and operative vaginal deliveries in those with high levels of exercise [156]. A more recent US study of overweight and obese women failed to find a protective effect of exercise in cesarean incidence, questioning the applicability of earlier study findings to today's growing overweight/obese prenatal population [157]. The 2014 First Baby Study found no significant relationship between regular exercise (≥ 150 min/week) and cesarean deliveries, late preterm birth, or hospitalizations [14]. Additionally, conflicting data has failed to demonstrate a clear relationship between length of labor and exercise [158]. Further study is needed in the contemporary population to solidify whether a protective relationship exists between exercise and delivery outcomes.

Several studies have evaluated the effects of exercise on birth weight. To date, research has not shown an increased risk of small-for-gestational age (SGA) births in physically active mothers [159]. Exercise may actually normalize birth weight ranges by decreasing the number of large-for-gestational age births, therefore reducing birth weight extremes. Effects may be attributed to normalizing maternal blood glucose, and affecting placental blood flow and nutrient delivery [22, 160]. The Norwegian Mother and Child Cohort Study compared the effects of exercise and prepregnancy BMI on birth weight in >43,000 women. While exercise led to a 2.9 g decrease in weight per unit of exercise (once per month), BMI was associated with a 20.3 g increase per BMI unit [161]. Children of prenatal exercisers have lower weight/percent body fat at birth, and are leaner at 5 years than offspring of sedentary mothers [162]. However, in regards to prevention of extreme birth weight outcomes, BMI control may have more effects than exercise participation.

Breastfeeding

Breastfeeding imparts many health benefits to infants and is associated with decreased postpartum weight retention in mothers [48]. Exercise is an additional avenue for weight management in the postpartum period, but its potential effects on lactation should be considered, especially in the setting of caloric restriction. In a cross-sectional study of exclusively breastfeeding women, women who exercised during the study timeframe (9–24 weeks postpartum) demonstrated higher $\text{VO}_{2\text{max}}$, lower percent body fat, and higher caloric intake than sedentary mothers [163]. Breast milk composition did not differ in regards to volume, energy content, protein, lipid, or lactose concentrations. This suggests that exercise, in the setting of adequate caloric compensation, does not affect lactation performance. A study of women who were sedentary during late pregnancy and early postpartum periods found that a 12-week exercise program initiated 6–8 weeks postpartum (60–70 % heart rate maximum-(HRM), 5 days/week, 20 min increased to 45 min) without dietary changes demonstrated similar maternal weight loss, infant weight gain, and breast milk parameters to those of sedentary controls [164]. Interventional subjects demonstrated increased aerobic fitness and greater lipid profile improvements than controls. A study of overweight, sedentary, exclusively breastfeeding mothers demonstrated that a caloric restriction and progressive aerobic exercise program initiated at 4 weeks postpartum (500 kcal/day restriction, 65–80 % HRM, 4 days/week, 15–45 min) promoted greater weight loss and aerobic fitness in mothers, with no effect on infant weight or length gains [165]. A study of short-term caloric restriction in addition to exercise, or caloric restriction alone found no effects on breast milk parameters or infant growth when compared to controls. Weight loss was higher for the interventional groups. Additionally, breast milk lactic acid levels are not elevated by moderate exercise, but have been shown to increase temporarily after a maximal exercise test, although effect on infant acceptance is uncertain [166, 167]. Similarly, immunological markers appear to be unaffected by moderate exercise but may transiently decrease after maximal exertion [168, 169].

Based upon available research, exercise of moderate intensity does not have detrimental effects on lactation, including breast milk quality or infant growth parameters. The effect of exercise on lactation-related bone loss attenuation requires further study [170]. Further research is needed to determine whether timing of breastfeeding should be adjusted after vigorous activity, or whether vigorous activity should be limited during lactation.

Exercise Prescriptions: Unique Considerations

The Physical Activity Readiness Medical Examination (PARmed-X) is a convenient tool for healthcare providers to assess individual safety and readiness for prenatal exercise and for continued surveillance of the exercising pregnant patient [90].

In addition to prescreening assistance, the PARmed-X provides more detailed recommendations for physical activity prescriptions using the FITT principle, and for monitoring exertional levels [90].

After medical clearance, it is recommended that pregnant women follow the complimentary ACOG and Federal guidelines for moderate-intensity physical activity/exercise, as described above. Moderate-intensity activity is defined as 3–5.9 metabolic equivalents (METs), which corresponds to a brisk walking pace of 3–4 mph [4, 171]. While previously active individuals may meet these guidelines without difficulty, it is recommended that sedentary individuals gradually increase the length and frequency of LTPA [9, 172]. Additionally, while the ACOG and Federal guidelines recommend physical activity/exercise be performed on most or all days of the week, one study draws caution to this statement for pregnant women. This study demonstrated a higher risk of SGA babies in women who exercised more than five or less than two times per week [173]. Further research is needed to determine whether frequency recommendations should be adjusted in pregnancy.

There are multiple physiological changes that alter exertional levels in pregnancy. Left ventricular mass, stroke volume, cardiac output, and resting and submaximal heart rate are increased, while maximal heart rate declines by approximately 4 bpm. Maximal heart rate blunting is likely secondary to decreased exertional sympathoadrenal response [174]. For this reason, narrower target heart-rate zones during pregnancy (~60–80 % aerobic capacity) have been established for each decade of age, with a decrease in the top range of each age zone [172, 175]. Target zones have been validated based upon age and fitness level as outlined in the PARmed-X [90, 176].

Although target heart rates have lost favor as an accurate exercise intensity monitoring tool in pregnancy, research supports the importance of target heart-rate zones, particularly in overweight and obese women [177]. Additional target zone adjustments have been developed and validated for sedentary overweight/obese pregnant women based upon research demonstrating that $\%VO_{2\text{reserve}}$ is not equivalent to $\%HR_{\text{reserve}}$ at intensities below $70\%VO_{2\text{reserve}}$ in this population. If moderate-intensity prescriptions based on $\%HR_{\text{reserve}}$ are followed, overweight and obese pregnant women may be exercising at a higher intensity than intended for a particular heart rate [41]. Additionally, the ACSM recommends that previously sedentary overweight/obese pregnant women begin exercise programs at the lowest intensity known to demonstrate health benefits (20–39 % $VO_{2\text{reserve}}$). This range represents 13–33 % HRR in this population, which corresponds to heart-rate zones of 102–124 bpm for 20–29-year old and 101–120 bpm for 30–39-year old [41, 177]. In this sedentary population, compliance may be higher with lower intensity exercise, while still providing health benefits.

ACOG currently prefers ratings of perceived exertion (RPE) and self-regulation in lieu of heart-rate targets for determination of physical activity intensity levels. Borg's RPE spans numerical ratings from 6 to 20 [178]. For nonpregnant, healthy adults, the prescription zone for moderate-intensity fitness training corresponds to an RPE of 12–16 ("somewhat hard"). In pregnancy, an RPE of 12–14 is recommended, due to increased weight-bearing exercise energy expenditure in response

to maternal weight gain. An alternative, easily implemented measure of exertion is the “talk test,” in which activity intensity is considered appropriate as long as the participant can easily carry on a conversation [90].

The goal of physical activity in pregnancy should be to maintain appropriate fitness without aspiring to reach maximal fitness or performance levels [175]. Aerobic exercise utilizing large muscle groups is encouraged, including walking, swimming, and stationary biking. High-risk activities should be avoided (Table 15.2) and vigorous intensity physical activity should not be initiated in pregnancy [9]. Continuation of vigorous activity in appropriately trained athletes should be considered on an individual basis, under appropriate medical supervision [9]. However, some concern exists about maximal exertion in pregnancy, based on a small study of Olympic level athletes. In these women, fetal bradycardia, high umbilical artery pulsatility index, and decreased mean uterine artery volume blood flow (<50 % baseline) were noted when exercise intensity surpassed 90 % maximal maternal heart rate [179].

Injuries

Fear of injury has been cited as a barrier to physical activity participation in pregnancy, and ACOG places limitations on sports or activities felt to confer a higher risk of injury to the mother and/or fetus (Table 15.2) [9, 180]. Contact sports and sports with a high risk of abdominal injury and falls are discouraged. However, the majority of research on prenatal injury has focused on those requiring hospitalization or emergency department visits, most commonly in relation to motor vehicle collisions. Only one study has investigated the risk of ambulatory physical activity-related injuries in pregnancy [180]. Of almost 1,500 women, only 34 reported physical activity-related injuries during pregnancy. Bruises and scrapes comprised 55 % of injuries, and two-thirds of injuries occurred during non-exercise-related physical activity. Falls accounted for 64 % of injuries, most often during walking for non-exercise purposes. Given the many biomechanical and physiological changes of pregnancy, attention to safe exercise practices should be a priority. While care should be taken to avoid high-risk sports during pregnancy, overall risk of injury in pregnancy is low and may be more strongly related to activities of daily living.

Hyperthermia

Thermoregulation is improved during pregnancy, in the setting of adequate hydration, in part due to increased blood circulation and sweating responses. Despite these adaptive mechanisms, concerns exist for hyperthermia in pregnancy. Animal studies have linked congenital malformations to hyperthermia, and in women, hot tub use in the first trimester has been linked to neural tube defects (NTD), gastroschisis, and

anencephaly [181–183]. First trimester febrile illnesses have also been linked to NTD, congenital heart defects, and oral clefts, with most adverse effects noted when core temperature increases more than 1.5 or above 38.9 °C [184, 185].

Adverse fetal outcomes have not been reported in regards to exercise-induced temperature elevations, and no studies have reported more than a 1.1 °C increase in temperature during prenatal exercise [181]. Nevertheless, hot, humid exercising conditions and dehydration should be avoided in exercising pregnant women, with particular attention to temperature control in the first trimester.

Postpartum Exercise

The benefits of postpartum exercise include improved weight loss, cardiovascular fitness, and energy levels with decreased postpartum mood disturbances [170]. Despite these known benefits, physical activity guidelines and associated health provider guidance are lacking in the postpartum period. As currently defined, the postpartum period encompasses the 6–8 weeks following delivery, as reflected by the expected length of post-delivery obstetrical follow-up. However, many physical and psychological health issues persist past this 6-week follow-up period. Additionally, breastfeeding is currently recommended for 12 months, suggesting an extension of the postpartum period to 1 year may be more appropriate to provide sufficient monitoring and counseling to these mothers, including the opportunity to sufficiently promote and monitor physical activity in mothers after delivery [170].

ACOG recommends that prepregnancy exercise routines be resumed gradually, as soon as medically appropriate [9]. After uncomplicated deliveries, Canadian guidelines allow for immediate resumption of mild exercise, which includes walking, pelvic floor strengthening, and stretching. Complicated deliveries or cesarean sections require medical clearance, which is often delayed until the 6–8 week postpartum checkup [186].

Exercise programs should be increased gradually, as tolerated, following the FITT principle and with attention to exertion levels. Breastfeeding and previously inactive mothers may initially benefit from lower exertional levels to avoid fatigue, which may not be necessary in previously active mothers.

Vaginal bleeding, secondary to placenta shearing, can persist for 1–2 months postpartum. While bleeding should be minimal before exercise resumption, there is no evidence that exercise increases normal postpartum bleeding or risk of hemorrhage [170]. Stress urinary incontinence is common postpartum, yet pelvic floor retraining may decrease this risk, while improving general physical recovery [170]. Mild-to-moderate-intensity exercise in the setting of adequate nutrition has not been associated with breast milk alterations, or infant acceptance at 1 h post-exercise [167]. Higher intensity exercise may have transient effects on quality, and acceptance remains controversial.

With these factors in mind, postpartum exercise is considered safe and provides many health benefits to the mother. Regardless of intensity, postpartum exercise promotes the reduction of chronic disease risk factors [187]. Adequate hydration and nutrition should be ensured and avoidance of exhaustive exercise is recommended. Exercise after breastfeeding or when breasts are empty may be better tolerated, and a supportive bra should be worn. Sports bras promote breast compression and are not recommended [170]. Programs that include the infant promote compliance, as they negate the need for infant childcare and can enhance mother–infant bonding. Stroller walking programs and muscle conditioning programs that incorporate the infant can be enjoyable for both mother and child, and physical activity guidelines have been developed for this purpose [186].

Conclusions

Regular physical activity has numerous documented health benefits for the general population. Improved metabolic, physiologic, psychological, and cognitive health is evidenced by decreased morbidity and mortality in those who maintain an active lifestyle. Recent advances in perinatal research have demonstrated similar beneficial effects for both the mother and offspring in relation to pregnancy outcomes, chronic disease risk, and general physical and psychological well-being. Federal and ACOG guidelines now recommend regular physical activity/exercise for pregnant and postpartum women, given the many health benefits, and absence of risks, from exercise in these women. Future research will help to solidify the FITT parameters most effective for optimization of prenatal, postpartum, and offspring health outcomes.

References

1. US Department of Health and Human Services. 2008 Physical activity guidelines for Americans. Washington DC: USDHHS; 2008.
2. Melzer K, Kayser B, Pichard C. Physical activity: the health benefits outweigh the risks. *Curr Opin Clin Nutr Metab Care*. 2004;7(6):641–7.
3. Prevention C.f.D.C.a. Physical activity and health. <http://www.cdc.gov/physicalactivity/everyone/health/index.html> (2014). Accessed 10 Feb 2014.
4. Garber CE, et al., American College of Sports Medicine. American College of Sports Medicine position stand. Quantity and quality of exercise for developing and maintaining cardiorespiratory, musculoskeletal, and neuromotor fitness in apparently healthy adults: guidance for prescribing exercise. *Med Sci Sports Exerc*. 2011;43(7):1334–59.
5. Impact of physical activity during pregnancy and postpartum on chronic disease risk. *Med Sci Sports Exerc*. 2006;38(5):989–1006.
6. The American College of Obstetricians and Gynecologists. Exercise during pregnancy and the prenatal period. Washington, DC: ACOG; 1985.

7. American College of Sports Medicine position statement on the recommended quantity and quality of exercise for developing and maintaining fitness in healthy adults. *Med Sci Sports Exerc.* 1978;10(3):vii-x.
8. The American College of Obstetricians and Gynecologists. Exercise during pregnancy and the postpartum period. Washington, DC: ACOG; 1994.
9. Committee on Obstetric Practice. ACOG committee opinion. Exercise during pregnancy and the postpartum period. Number 267, January 2002. American College of Obstetricians and Gynecologists. *Int J Gynaecol Obstet.* 2002;77(1):79-81.
10. American College of Sports Medicine. ACSM's guidelines for exercise testing and prescription. 6th ed. Philadelphia: Lippincott Williams & Wilkins; 2000.
11. Joy EA, Mottola MF, Chambliss H. Integrating exercise is medicine(R) into the care of pregnant women. *Curr Sports Med Rep.* 2013;12(4):245-7.
12. Kramer MS, McDonald SW. Aerobic exercise for women during pregnancy. *Cochrane Database Syst Rev.* 2006;3, CD000180.
13. Evenson KR, Wen F. National trends in self-reported physical activity and sedentary behaviors among pregnant women: NHANES 1999-2006. *Prev Med.* 2010;50(3):123-8.
14. Tinloy J, et al. Exercise during pregnancy and risk of late preterm birth, cesarean delivery, and hospitalizations. *Womens Health Issues.* 2014;24(1):e99-104.
15. Evenson KR, Savitz DA, Huston SL. Leisure-time physical activity among pregnant women in the US. *Paediatr Perinat Epidemiol.* 2004;18(6):400-7.
16. Owe KM, Nystad W, Bo K. Association between regular exercise and excessive newborn birth weight. *Obstet Gynecol.* 2009;114(4):770-6.
17. Borodulin KM, et al. Physical activity patterns during pregnancy. *Med Sci Sports Exerc.* 2008;40(11):1901-8.
18. Pereira MA, et al. Predictors of change in physical activity during and after pregnancy: Project Viva. *Am J Prev Med.* 2007;32(4):312-9.
19. Hinton PS, Olson CM. Predictors of pregnancy-associated change in physical activity in a rural white population. *Matern Child Health J.* 2001;5(1):7-14.
20. Walsh JM, et al. Prevalence of physical activity among healthy pregnant women in Ireland. *Int J Gynaecol Obstet.* 2011;114(2):154-5.
21. Liu J, et al. Physical activity during pregnancy in a prospective cohort of British women: results from the Avon longitudinal study of parents and children. *Eur J Epidemiol.* 2011;26(3):237-47.
22. Hegaard HK, et al. Sports and leisure time physical activity during pregnancy in nulliparous women. *Matern Child Health J.* 2011;15(6):806-13.
23. Domingues MR, Barros AJ. Leisure-time physical activity during pregnancy in the 2004 Pelotas Birth Cohort Study. *Rev Saude Publica.* 2007;41(2):173-80.
24. Ventura SJ, Curtin SC, Abma JC. National vital statistics reports. *National Vital Statistics Reports.* 2012;60(7).
25. Krans EE, et al. Pregnant women's beliefs and influences regarding exercise during pregnancy. *J Miss State Med Assoc.* 2005;46(3):67-73.
26. Evenson KR, Pompeii LA. Obstetrician practice patterns and recommendations for physical activity during pregnancy. *J Womens Health (Larchmt).* 2010;19(9):1733-40.
27. Garry JP, Diamond JJ, Whitley TW. Physical activity curricula in medical schools. *Acad Med.* 2002;77(8):818-20.
28. Coleman KJ, et al. Initial validation of an exercise "vital sign" in electronic medical records. *Med Sci Sports Exerc.* 2012;44(11):2071-6.
29. Napolitano MA, et al. Mediators of physical activity behavior change: a multivariate approach. *Health Psychol.* 2008;27(4):409-18.
30. Glasgow RE, Emont S, Miller DC. Assessing delivery of the five 'As' for patient-centered counseling. *Health Promot Int.* 2006;21(3):245-55.
31. Aittasalo M, et al. Physical activity counseling in maternity and child health care—a controlled trial. *BMC Womens Health.* 2008;8:14.

32. Aittasalo M, et al. Is intensive counseling in maternity care feasible and effective in promoting physical activity among women at risk for gestational diabetes? Secondary analysis of a cluster randomized NELLI study in Finland. *Int J Behav Nutr Phys Act.* 2012;9:104.
33. President's Council on Physical Fitness & Sports. Physical activity in minority populations: overcoming a public health challenge. *Research Digest.* 2005;6(2):1-8.
34. Hoebcke R. Low-income women's perceived barriers to physical activity: focus group results. *Appl Nurs Res.* 2008;21(2):60-5.
35. Kriska AM, Rexroad AR. The role of physical activity in minority populations. *Womens Health Issues.* 1998;8(2):98-103.
36. Krans EE, Chang JC. A will without a way: barriers and facilitators to exercise during pregnancy of low-income, African American women. *Women Health.* 2011;51(8):777-94.
37. Ogden CL, et al. Prevalence of childhood and adult obesity in the United States, 2011-2012. *JAMA.* 2014;311(8):806-14.
38. Crane JM, et al. The effect of gestational weight gain by body mass index on maternal and neonatal outcomes. *J Obstet Gynaecol Can.* 2009;31(1):28-35.
39. Davies GA, et al. Obesity in pregnancy. *J Obstet Gynaecol Can.* 2010;32(2):165-73.
40. Council NR. *Weight gain during pregnancy: reexamining the guidelines.* Washington, DC: The National Academies Press; 2009.
41. Mottola MF. Exercise prescription for overweight and obese women: pregnancy and postpartum. *Obstet Gynecol Clin North Am.* 2009;36(2):301-16. viii.
42. Chu SY, Callaghan WM, Bish CL, D'Angelo D. Gestational weight gain by body mass index among US women delivering live births, 2004-2005: fueling future obesity. *Am J Obstet Gynecol.* 2009;200(3):271.e1-7.
43. Kraschnewski JL, et al. Association of prenatal physical activity and gestational weight gain: results from the first baby study. *Womens Health Issues.* 2013;23(4):e233-8.
44. Viswanathan M, Siega-Riz AM, Moos MK, Deierlein A, Mumford S, Knaack J, Thieda P, Lux LJ, Lohr KN. Outcomes of maternal weight gain. *Evid Rep Technol Assess (Full Rep).* 2008;168:1-223.
45. Alfaradhi MZ, Ozanne SE. Developmental programming in response to maternal overnutrition. *Front Genet.* 2011;2:27.
46. Ruchat SM, et al. Nutrition and exercise reduce excessive weight gain in normal-weight pregnant women. *Med Sci Sports Exerc.* 2012;44(8):1419-26.
47. Nohr EA, et al. Combined associations of prepregnancy body mass index and gestational weight gain with the outcome of pregnancy. *Am J Clin Nutr.* 2008;87(6):1750-9.
48. Rooney BL, Schauberger CW. Excess pregnancy weight gain and long-term obesity: one decade later. *Obstet Gynecol.* 2002;100(2):245-52.
49. Simas TA, et al. Impact of updated Institute of Medicine guidelines on prepregnancy body mass index categorization, gestational weight gain recommendations, and needed counseling. *J Womens Health (Larchmt).* 2011;20(6):837-44.
50. Davenport MH, Steinback CD, Mottola MF. Impact of pregnancy and obesity on cardiorespiratory responses during weight-bearing exercise. *Respir Physiol Neurobiol.* 2009;167(3):341-7.
51. Mottola MF, Campbell MK. Activity patterns during pregnancy. *Can J Appl Physiol.* 2003;28(4):642-53.
52. Gray-Donald K, et al. Intervening to reduce weight gain in pregnancy and gestational diabetes mellitus in Cree communities: an evaluation. *CMAJ.* 2000;163(10):1247-51.
53. Kinnunen TI, et al. Preventing excessive weight gain during pregnancy—a controlled trial in primary health care. *Eur J Clin Nutr.* 2007;61(7):884-91.
54. Polley BA, Wing RR, Sims CJ. Randomized controlled trial to prevent excessive weight gain in pregnant women. *Int J Obes Relat Metab Disord.* 2002;26(11):1494-502.
55. Olson CM, Strawderman MS, Reed RG. Efficacy of an intervention to prevent excessive gestational weight gain. *Am J Obstet Gynecol.* 2004;191(2):530-6.
56. Artal R, et al. A lifestyle intervention of weight-gain restriction: diet and exercise in obese women with gestational diabetes mellitus. *Appl Physiol Nutr Metab.* 2007;32(3):596-601.

57. Davenport MH, et al. A walking intervention improves capillary glucose control in women with gestational diabetes mellitus: a pilot study. *Appl Physiol Nutr Metab.* 2008; 33(3):511–7.
58. Mottola MF, et al. Nutrition and exercise prevent excess weight gain in overweight pregnant women. *Med Sci Sports Exerc.* 2010;42(2):265–72.
59. Gunderson EP, Abrams B, Selvin S. The relative importance of gestational gain and maternal characteristics associated with the risk of becoming overweight after pregnancy. *Int J Obes Relat Metab Disord.* 2000;24(12):1660–8.
60. Siega-Riz AM, et al. Sociodemographic, perinatal, behavioral, and psychosocial predictors of weight retention at 3 and 12 months postpartum. *Obesity (Silver Spring).* 2010;18(10):1996–2003.
61. Davenport MH, et al. Timing of excessive pregnancy-related weight gain and offspring adiposity at birth. *Obstet Gynecol.* 2013;122(2 Pt 1):255–61.
62. American Diabetes Association. Diagnosis and classification of diabetes mellitus. *Diabetes Care.* 2013;36(1):S67–74.
63. Metzger BE, et al. Hyperglycemia and adverse pregnancy outcomes. *N Engl J Med.* 2008;358(19):1991–2002.
64. Metzger BE, et al. Hyperglycemia and adverse pregnancy outcome study: neonatal glycemia. *Pediatrics.* 2010;126(6):e1545–52.
65. Kelly C, Booth GL. Diabetes in Canadian women. *BMC Womens Health.* 2004;4(1):S16.
66. Retnakaran R, et al. Beta-cell function declines within the first year postpartum in women with recent glucose intolerance in pregnancy. *Diabetes Care.* 2010;33(8):1798–804.
67. Ruchat SM, Mottola MF. The important role of physical activity in the prevention and management of gestational diabetes mellitus. *Diabetes Metab Res Rev.* 2013;29(5):334–46.
68. Newbern D, Freemark M. Placental hormones and the control of maternal metabolism and fetal growth. *Curr Opin Endocrinol Diabetes Obes.* 2011;18(6):409–16.
69. Metzger BE, et al. Summary and recommendations of the Fifth International Workshop-Conference on Gestational Diabetes Mellitus. *Diabetes Care.* 2007;30 Suppl 2:S251–60.
70. Iqbal R, et al. Increased body fat percentage and physical inactivity are independent predictors of gestational diabetes mellitus in South Asian women. *Eur J Clin Nutr.* 2007;61(6):736–42.
71. Madden SG, Loeb SJ, Smith CA. An integrative literature review of lifestyle interventions for the prevention of type II diabetes mellitus. *J Clin Nurs.* 2008;17(17):2243–56.
72. Yates T, et al. The role of physical activity in the management of impaired glucose tolerance: a systematic review. *Diabetologia.* 2007;50(6):1116–26.
73. Zhang C, et al. A prospective study of pregravid physical activity and sedentary behaviors in relation to the risk for gestational diabetes mellitus. *Arch Intern Med.* 2006;166(5):543–8.
74. Tobias DK, et al. Physical activity before and during pregnancy and risk of gestational diabetes mellitus: a meta-analysis. *Diabetes Care.* 2011;34(1):223–9.
75. Han S, Middleton P, Crowther CA. Exercise for pregnant women for preventing gestational diabetes mellitus. *Cochrane Database Syst Rev.* 2012;7, CD009021.
76. Oostdam N, et al. Interventions for preventing gestational diabetes mellitus: a systematic review and meta-analysis. *J Womens Health (Larchmt).* 2011;20(10):1551–63.
77. Callaway LK, et al. Prevention of gestational diabetes: feasibility issues for an exercise intervention in obese pregnant women. *Diabetes Care.* 2010;33(7):1457–9.
78. Barakat R, et al. Exercise during pregnancy improves maternal glucose screen at 24–28 weeks: a randomised controlled trial. *Br J Sports Med.* 2012;46(9):656–61.
79. Ong MJ, et al. Supervised home-based exercise may attenuate the decline of glucose tolerance in obese pregnant women. *Diabetes Metab.* 2009;35(5):418–21.
80. Hopkins SA, et al. Exercise training in pregnancy reduces offspring size without changes in maternal insulin sensitivity. *J Clin Endocrinol Metab.* 2010;95(5):2080–8.
81. Korpi-Hyovalti EA, et al. Feasibility of a lifestyle intervention in early pregnancy to prevent deterioration of glucose tolerance. *BMC Public Health.* 2011;11:179.

82. Luoto R, et al. Primary prevention of gestational diabetes mellitus and large-for-gestational-age newborns by lifestyle counseling: a cluster-randomized controlled trial. *PLoS Med.* 2011;8(5):e1001036.
83. Stafne SN, et al. Regular exercise during pregnancy to prevent gestational diabetes: a randomized controlled trial. *Obstet Gynecol.* 2012;119(1):29–36.
84. Oostdam N, et al. No effect of the FitFor2 exercise programme on blood glucose, insulin sensitivity, and birthweight in pregnant women who were overweight and at risk for gestational diabetes: results of a randomised controlled trial. *BJOG.* 2012;119(9):1098–107.
85. Jovanovic-Peterson L, Durak EP, Peterson CM. Randomized trial of diet versus diet plus cardiovascular conditioning on glucose levels in gestational diabetes. *Am J Obstet Gynecol.* 1989;161(2):415–9.
86. Bung P, et al. Exercise in gestational diabetes. An optional therapeutic approach? *Diabetes.* 1991;40 Suppl 2:182–5.
87. Brankston GN, et al. Resistance exercise decreases the need for insulin in overweight women with gestational diabetes mellitus. *Am J Obstet Gynecol.* 2004;190(1):188–93.
88. Avery MD, Leon AS, Kopher RA. Effects of a partially home-based exercise program for women with gestational diabetes. *Obstet Gynecol.* 1997;89(1):10–5.
89. Colberg SR, et al. Exercise and type 2 diabetes: American College of Sports Medicine and the American Diabetes Association: joint position statement. Exercise and type 2 diabetes. *Med Sci Sports Exerc.* 2010;42(12):2282–303.
90. Canadian Society for Exercise Physiology. PARmed-X for Pregnancy: Physical Activity Readiness Medical Examination. 2013.
91. Khan KS, et al. WHO analysis of causes of maternal death: a systematic review. *Lancet.* 2006;367(9516):1066–74.
92. Berg CJ, et al. Pregnancy-related mortality in the United States, 1998 to 2005. *Obstet Gynecol.* 2010;116(6):1302–9.
93. Report of the National High Blood Pressure Education Program Working Group on High Blood Pressure in Pregnancy. *Am J Obstet Gynecol.* 2000;183(1):S1–22.
94. Weissgerber TL, Wolfe LA, Davies GA. The role of regular physical activity in preeclampsia prevention. *Med Sci Sports Exerc.* 2004;36(12):2024–31.
95. Robertson WB, et al. The placental bed biopsy: review from three European centers. *Am J Obstet Gynecol.* 1986;155(2):401–12.
96. Stevens DU, et al. Decidual vasculopathy in preeclampsia: lesion characteristics relate to disease severity and perinatal outcome. *Placenta.* 2013;34(9):805–9.
97. Meis PJ, et al. The preterm prediction study: risk factors for indicated preterm births. Maternal-Fetal Medicine Units Network of the National Institute of Child Health and Human Development. *Am J Obstet Gynecol.* 1998;178(3):562–7.
98. Solomon CG, Seely EW. Preeclampsia—searching for the cause. *N Engl J Med.* 2004;350(7):641–2.
99. Nisell H, et al. Blood pressure and renal function seven years after pregnancy complicated by hypertension. *Br J Obstet Gynaecol.* 1995;102(11):876–81.
100. Myers J. Cardiology patient pages. Exercise and cardiovascular health. *Circulation.* 2003;107(1):e2–5.
101. Yeo S, et al. Effect of exercise on blood pressure in pregnant women with a high risk of gestational hypertensive disorders. *J Reprod Med.* 2000;45(4):293–8.
102. Marcoux S, Brisson J, Fabia J. The effect of leisure time physical activity on the risk of preeclampsia and gestational hypertension. *J Epidemiol Community Health.* 1989;43(2):147–52.
103. Sorensen TK, et al. Recreational physical activity during pregnancy and risk of preeclampsia. *Hypertension.* 2003;41(6):1273–80.
104. Saftlas AF, et al. Work, leisure-time physical activity, and risk of preeclampsia and gestational hypertension. *Am J Epidemiol.* 2004;160(8):758–65.
105. Kasawara KT, et al. Exercise and physical activity in the prevention of pre-eclampsia: systematic review. *Acta Obstet Gynecol Scand.* 2012;91(10):1147–57.

106. Palmer KT, et al. Work activities and risk of prematurity, low birth weight and pre-eclampsia: an updated review with meta-analysis. *Occup Environ Med.* 2013;70(4):213–22.
107. Yeo S, et al. A comparison of walking versus stretching exercises to reduce the incidence of preeclampsia: a randomized clinical trial. *Hypertens Pregnancy.* 2008;27(2):113–30.
108. Yeo S. Adherence to walking or stretching, and risk of preeclampsia in sedentary pregnant women. *Res Nurs Health.* 2009;32(4):379–90.
109. Wang SM, et al. Low back pain during pregnancy: prevalence, risk factors, and outcomes. *Obstet Gynecol.* 2004;104(1):65–70.
110. Borg-Stein JP, Fogelman DJ, Ackerman KE. Exercise, sports participation, and musculoskeletal disorders of pregnancy and postpartum. *Semin Neurol.* 2011;31(4):413–22.
111. Heckman JD, Sassard R. Musculoskeletal considerations in pregnancy. *J Bone Joint Surg Am.* 1994;76(11):1720–30.
112. Vermani E, Mittal R, Weeks A. Pelvic girdle pain and low back pain in pregnancy: a review. *Pain Pract.* 2010;10(1):60–71.
113. Brynhildsen J, et al. Follow-up of patients with low back pain during pregnancy. *Obstet Gynecol.* 1998;91(2):182–6.
114. Mogren IM, Pohjanen AI. Low back pain and pelvic pain during pregnancy: prevalence and risk factors. *Spine (Phila Pa 1976).* 2005;30(8):983–91.
115. Mohseni-Bandpei MA, et al. Low back pain in 1,100 Iranian pregnant women: prevalence and risk factors. *Spine J.* 2009;9(10):795–801.
116. Ostgaard HC, Andersson GB. Previous back pain and risk of developing back pain in a future pregnancy. *Spine (Phila Pa 1976).* 1991;16(4):432–6.
117. Svensson HO, et al. The relationship of low-back pain to pregnancy and gynecologic factors. *Spine (Phila Pa 1976).* 1990;15(5):371–5.
118. Kristiansson P, Svardsudd K, von Schoultz B. Serum relaxin, symphyseal pain, and back pain during pregnancy. *Am J Obstet Gynecol.* 1996;175(5):1342–7.
119. MacLennan AH, et al. Serum relaxin and pelvic pain of pregnancy. *Lancet.* 1986;2(8501):243–5.
120. Marnach ML, et al. Characterization of the relationship between joint laxity and maternal hormones in pregnancy. *Obstet Gynecol.* 2003;101(2):331–5.
121. Schauburger CW, et al. Peripheral joint laxity increases in pregnancy but does not correlate with serum relaxin levels. *Am J Obstet Gynecol.* 1996;174(2):667–71.
122. Noon ML, Hoch AZ. Challenges of the pregnant athlete and low back pain. *Curr Sports Med Rep.* 2012;11(1):43–8.
123. Ritchie JR. Orthopedic considerations during pregnancy. *Clin Obstet Gynecol.* 2003;46(2):456–66.
124. Ostgaard HC, et al. Influence of some biomechanical factors on low-back pain in pregnancy. *Spine (Phila Pa 1976).* 1993;18(1):61–5.
125. Bewyer KJ, et al. Pilot data: association between gluteus medius weakness and low back pain during pregnancy. *Iowa Orthop J.* 2009;29:97–9.
126. Foti T, Davids JR, Bagley A. A biomechanical analysis of gait during pregnancy. *J Bone Joint Surg Am.* 2000;82(5):625–32.
127. Gutke A, Ostgaard HC, Oberg B. Association between muscle function and low back pain in relation to pregnancy. *J Rehabil Med.* 2008;40(4):304–11.
128. Sihvonen T, et al. Functional changes in back muscle activity correlate with pain intensity and prediction of low back pain during pregnancy. *Arch Phys Med Rehabil.* 1998;79(10):1210–2.
129. Noren L, et al. Lumbar back and posterior pelvic pain during pregnancy: a 3-year follow-up. *Eur Spine J.* 2002;11(3):267–71.
130. Vleeming A, et al. European guidelines for the diagnosis and treatment of pelvic girdle pain. *Eur Spine J.* 2008;17(6):794–819.
131. Gutke A, Ostgaard HC, Oberg B. Predicting persistent pregnancy-related low back pain. *Spine (Phila Pa 1976).* 2008;33(12):E386–93.

132. Ostgaard HC, et al. Reduction of back and posterior pelvic pain in pregnancy. *Spine (Phila Pa 1976)*. 1994;19(8):894–900.
133. Rost CC, et al. Pelvic pain during pregnancy: a descriptive study of signs and symptoms of 870 patients in primary care. *Spine (Phila Pa 1976)*. 2004;29(22):2567–72.
134. Garshabi A, Faghih Zadeh S. The effect of exercise on the intensity of low back pain in pregnant women. *Int J Gynaecol Obstet*. 2005;88(3):271–5.
135. Mogren IM. Previous physical activity decreases the risk of low back pain and pelvic pain during pregnancy. *Scand J Public Health*. 2005;33(4):300–6.
136. Kihlstrand M, et al. Water-gymnastics reduced the intensity of back/low back pain in pregnant women. *Acta Obstet Gynecol Scand*. 1999;78(3):180–5.
137. Stuge B, et al. The efficacy of a treatment program focusing on specific stabilizing exercises for pelvic girdle pain after pregnancy: a randomized controlled trial. *Spine (Phila Pa 1976)*. 2004;29(4):351–9.
138. Centers for Disease Control and Prevention. Current depression among adults—United States, 2006 and 2008. *Morb Mortal Wkly Rep*. 2010;59(38):1229–35.
139. Kessler RC, et al. Lifetime and 12-month prevalence of DSM-III-R psychiatric disorders in the United States. Results from the National Comorbidity Survey. *Arch Gen Psychiatry*. 1994;51(1):8–19.
140. Marcotte DE, Wilcox-Gok V, Redmon PD. Prevalence and patterns of major depressive disorder in the United States labor force. *J Ment Health Policy Econ*. 1999;2(3):123–31.
141. Marcus SM, et al. Depressive symptoms among pregnant women screened in obstetrics settings. *J Womens Health (Larchmt)*. 2003;12(4):373–80.
142. Gaynes BN, Gavin N, Meltzer-Brody S, Lohr KN, Swinson T, Gartlehner G, Brody S, Miller WC. Perinatal depression: prevalence, screening accuracy, and screening outcomes. *Evid Rep Technol Assess (Summ)*. 2005;119:1–8.
143. Wisner KL, Parry BL, Piontek CM. Clinical practice. Postpartum depression. *N Engl J Med*. 2002;347(3):194–9.
144. Cooper PJ, et al. Controlled trial of the short- and long-term effect of psychological treatment of post-partum depression. I. Impact on maternal mood. *Br J Psychiatry*. 2003;182:412–9.
145. Wisner KL, et al. Major depression and antidepressant treatment: impact on pregnancy and neonatal outcomes. *Am J Psychiatry*. 2009;166(5):557–66.
146. Loprinzi PD, Fitzgerald EM, Cardinal BJ. Physical activity and depression symptoms among pregnant women from the National Health and Nutrition Examination Survey 2005–2006. *J Obstet Gynecol Neonatal Nurs*. 2012;41(2):227–35.
147. Teychenne M, Ball K, Salmon J. Physical activity and likelihood of depression in adults: a review. *Prev Med*. 2008;46(5):397–411.
148. Barbour KA, Edenfield TM, Blumenthal JA. Exercise as a treatment for depression and other psychiatric disorders: a review. *J Cardiopulm Rehabil Prev*. 2007;27(6):359–67.
149. Shivakumar G, et al. Antenatal depression: a rationale for studying exercise. *Depress Anxiety*. 2011;28(3):234–42.
150. Rauff EL, Downs DS. Mediating effects of body image satisfaction on exercise behavior, depressive symptoms, and gestational weight gain in pregnancy. *Ann Behav Med*. 2011;42(3):381–90.
151. Koniak-Griffin D. Aerobic exercise, psychological well-being, and physical discomforts during adolescent pregnancy. *Res Nurs Health*. 1994;17(4):253–63.
152. Da Costa D, et al. Self-reported leisure-time physical activity during pregnancy and relationship to psychological well-being. *J Psychosom Obstet Gynaecol*. 2003;24(2):111–9.
153. Demissie Z, et al. Physical activity and depressive symptoms among pregnant women: the PIN3 study. *Arch Womens Ment Health*. 2011;14(2):145–57.
154. Erdelyi G. Gynecological survey of female athletes. *J Sports Med Phys Fitness*. 1962;2:174–9.
155. Clapp 3rd JF. The course of labor after endurance exercise during pregnancy. *Am J Obstet Gynecol*. 1990;163(6 Pt 1):1799–805.

156. Hall DC, Kaufmann DA. Effects of aerobic and strength conditioning on pregnancy outcomes. *Am J Obstet Gynecol.* 1987;157(5):1199–203.
157. Bovbjerg ML, Siega-Riz AM. Exercise during pregnancy and cesarean delivery: North Carolina PRAMS, 2004–2005. *Birth.* 2009;36(3):200–7.
158. Melzer K, et al. Physical activity and pregnancy: cardiovascular adaptations, recommendations and pregnancy outcomes. *Sports Med.* 2010;40(6):493–507.
159. Hegaard HK, et al. Leisure time physical activity during pregnancy and impact on gestational diabetes mellitus, pre-eclampsia, preterm delivery and birth weight: a review. *Acta Obstet Gynecol Scand.* 2007;86(11):1290–6.
160. Voldner N, et al. Modifiable determinants of fetal macrosomia: role of lifestyle-related factors. *Acta Obstet Gynecol Scand.* 2008;87(4):423–9.
161. Fleten C, et al. Exercise during pregnancy, maternal prepregnancy body mass index, and birth weight. *Obstet Gynecol.* 2010;115(2 Pt 1):331–7.
162. Clapp 3rd JF. Morphometric and neurodevelopmental outcome at age five years of the offspring of women who continued to exercise regularly throughout pregnancy. *J Pediatr.* 1996;129(6):856–63.
163. Lovelady CA, Lonnerdal B, Dewey KG. Lactation performance of exercising women. *Am J Clin Nutr.* 1990;52(1):103–9.
164. Dewey KG, et al. A randomized study of the effects of aerobic exercise by lactating women on breast-milk volume and composition. *N Engl J Med.* 1994;330(7):449–53.
165. Lovelady CA, et al. The effect of weight loss in overweight, lactating women on the growth of their infants. *N Engl J Med.* 2000;342(7):449–53.
166. Wallace JP, Inbar G, Ernsthausen K. Infant acceptance of postexercise breast milk. *Pediatrics.* 1992;89(6 Pt 2):1245–7.
167. Wright KS, Quinn TJ, Carey GB. Infant acceptance of breast milk after maternal exercise. *Pediatrics.* 2002;109(4):585–9.
168. Gregory RL, et al. Effect of exercise on milk immunoglobulin A. *Med Sci Sports Exerc.* 1997;29(12):1596–601.
169. Lovelady CA, Hunter CP, Geigerman C. Effect of exercise on immunologic factors in breast milk. *Pediatrics.* 2003;111(2):E148–52.
170. Mottola MF. Exercise in the postpartum period: practical applications. *Curr Sports Med Rep.* 2002;1(6):362–8.
171. Pate RR, et al. Physical activity and public health. A recommendation from the Centers for Disease Control and Prevention and the American College of Sports Medicine. *JAMA.* 1995;273(5):402–7.
172. Davies GA, et al. Joint SOGC/CSEP clinical practice guideline: exercise in pregnancy and the postpartum period. *Can J Appl Physiol.* 2003;28(3):330–41.
173. Campbell MK, Mottola MF. Recreational exercise and occupational activity during pregnancy and birth weight: a case-control study. *Am J Obstet Gynecol.* 2001;184(3):403–8.
174. Lotgering FK, et al. Maximal aerobic exercise in pregnant women: heart rate, O₂ consumption, CO₂ production, and ventilation. *J Appl Physiol* (1985). 1991;70(3):1016–23.
175. Davies GA, et al. Exercise in pregnancy and the postpartum period. *J Obstet Gynaecol Can.* 2003;25(6):516–29.
176. Mottola MF, et al. VO₂peak prediction and exercise prescription for pregnant women. *Med Sci Sports Exerc.* 2006;38(8):1389–95.
177. Davenport MH, et al. Development and validation of exercise target heart rate zones for overweight and obese pregnant women. *Appl Physiol Nutr Metab.* 2008;33(5):984–9.
178. Borg G. Perceived exertion and pain scales. Champaign: Human Kinetics; 1998.
179. Salvesen KA, Hem E, Sundgot-Borgen J. Fetal wellbeing may be compromised during strenuous exercise among pregnant elite athletes. *Br J Sports Med.* 2012;46(4):279–83.
180. Vladutiu CJ, Evenson KR, Marshall SW. Physical activity and injuries during pregnancy. *J Phys Act Health.* 2010;7(6):761–9.
181. McMurray RG, et al. Recent advances in understanding maternal and fetal responses to exercise. *Med Sci Sports Exerc.* 1993;25(12):1305–21.

182. Milunsky A, et al. Maternal heat exposure and neural tube defects. *JAMA*. 1992;268(7):882–5.
183. Duong HT, et al. Maternal use of hot tub and major structural birth defects. *Birth Defects Res A Clin Mol Teratol*. 2011;91(9):836–41.
184. Dreier JW, Andersen AM, Berg-Beckhoff G. Systematic review and meta-analyses: fever in pregnancy and health impacts in the offspring. *Pediatrics*. 2014;133(3):e674–88.
185. Olson D, et al. Exercise in pregnancy. *Curr Sports Med Rep*. 2009;8(3):147–53.
186. Kochan-Vintinner A. Active living during pregnancy: physical activity guidelines for mother and baby. In: Wolfe L, Mottola M, editors. Ottawa: Canadian Society for Exercise Physiology and Health Canada; 1999.
187. Davenport MH, et al. Postpartum exercise regardless of intensity improves chronic disease risk factors. *Med Sci Sports Exerc*. 2011;43(6):951–8.

akusher-lib.ru

Epilogue: Where to Go from Here ...

Future Research

Colleen M. Fitzgerald and Britt Stuge

A common theme throughout the chapters presented in this text is the lack of clear evidence supporting the diagnosis and treatment of musculoskeletal conditions during pregnancy and the postpartum period. This supports the importance of and strong need for clinical research in musculoskeletal health for childbearing women. While various pain mechanisms including biomechanical [1], hormonal [2], inflammatory, and neural [3] have been proposed in the development of musculoskeletal conditions in the parturient, the etiology, pathogenesis, diagnosis, and treatment course for most remains insufficiently studied and incompletely understood. It is possible that musculoskeletal changes influenced by a dynamic hormonal state, in the context of changes in body mass magnitude and distribution, during pregnancy predispose pregnant women to acute musculoskeletal injuries. An inflammatory response in other acute musculoskeletal injuries has been well described [4] and may also occur in pregnancy-related pain, particularly given the musculoskeletal vulnerability during this time. Understanding the musculoskeletal system as whole, for example, how the external pelvis interacts with the internal pelvic floor [5–7], is paramount, particularly in how it may impact delivery and recovery.

The transition from acute to chronic pain indeed deserves attention in this population. Low back and pelvic (lumbopelvic) pain affects about 50 % of pregnant women at some time during pregnancy [8]. In most cases, women experience pain relief within 1–3 months of delivery [9]. Studies have shown, however, that recovery from pregnancy-related lumbopelvic pain is often incomplete leading to chronic pelvic pain (CPP) [10–14]. Severity and location of pain during pregnancy can determine the persistence of postpartum pain [10, 15]. Recent literature demonstrates that

C.M. Fitzgerald

Department of Obstetrics and Gynecology, Loyola University, Maywood, IL, USA

B. Stuge, PhD

Department of Orthopaedics, Oslo University Hospital, Oslo, Norway

e-mail: britt.stuge@medisin.uio.no

women with severe pelvic girdle pain during pregnancy who underwent Cesarean section were more likely to have persistent pain on 6-month follow-up [16] and those who used crutches in pregnancy (i.e., those who were the most disabled) reported ongoing pelvic girdle pain after delivery.

These findings suggest several potential alternate mechanisms that warrant further investigation. One is that perhaps a “hit to the core” with labor and delivery perpetuates ongoing mechanical dysfunction in those with severe pain during pregnancy. Whether it is the anterior core (abdominal) or the inferior core (pelvic floor) with levator ani avulsion [17], muscular disruption is inevitable in the context of delivery and can lead to dysfunctional muscle length–tension relationships and activation patterns. It is also possible that the more functionally limited women with pain during pregnancy have already developed central sensitization to pain [18] as a result of ongoing peripheral sensitization that was insufficiently treated. This baseline sensitization may then be exacerbated by a subsequent surgical insult (Caesarian section) that leads to further pain hypersensitivity—thereby precluding a typical musculoskeletal recovery. Indeed, recent research points to aberrant central pain processing in other CPP conditions [19] that also have associated musculoskeletal/pelvic floor myofascial pain [20].

A physically active and healthy lifestyle should be promoted throughout pregnancy and the postpartum period and exercise should be part of that active lifestyle [21]. At this time, there is limited evidence to prescribe patient-specific exercise in those women who have pain-related diagnoses. However, it is recommended that healthy pregnant women initiate or continue to exercise. Future research should focus on not only mechanisms of injury, but also on reasons why pregnant women are physically inactive, why they suffer from pain and what specifically can be done to reduce this pain and discomfort to maximize ongoing mobility. Additionally, most clinical trials in this population have focused on exercise and physical therapy treatments, with little attention given to medical management.

The evaluation and successful treatment of pregnancy-related pelvic girdle pain is a complex problem. Healthcare providers must recognize that there may not be a single source of dysfunction or reason for the problem. Because there might be an overlap in disorders resulting in pelvic girdle pain and pelvic floor muscle pain and dysfunction, proper diagnostic criteria are needed [22, 23]. Patient-specific diagnostics, individualized, multidimensional treatment programs, and collaborative multidisciplinary approaches to clinical research and patient care are highly recommended [24].

In October 2010, the Office of Research on Women’s Health (ORWH) convened a scientific research forum, *Issues in Clinical Research: Enrolling Pregnant Women* in partnership with several National Institutes of Health (NIH) institutes, centers, offices and the Food and Drug Administration (FDA), to address the ethical/Institutional Review Board (IRB) and recruitment issues that investigators face in the conceptualization, initiation, and conduct of clinical research studies that enroll pregnant women. During this forum, the audience was challenged to address gaps in knowledge about medical treatment and pregnancy, to increase the evidence base on the inclusion of pregnant women in clinical research, and to conduct appropriate scientifically and ethically designed clinical research. Medical ethicists, clinical investigators, academic researchers, and those with an interest in and concern about

clinical research in women provided information related to risk perception, risk reasoning, and the ethics of balancing risks and benefits in the clinical arena.

The NIH strategic plan for research on women's health identified six major goals for women's health research [25], one of which was the goal of increasing research to *actualize personalized prevention, diagnostics, and therapeutics for girls and women*. Among specific objectives listed for this goal were two objectives that directly addressed pregnancy: (1) *encourage research on safe and effective interventions for conditions affecting pregnant women*; and (2) *expand research on pregnancy-related conditions, such as preeclampsia, diabetes, and hypertension on the subsequent health of women and their offspring*.

The report from this forum (<http://orwh.od.nih.gov/resources/policyreports/pdf/ORWH-EPW-Report-2010.pdf>) made several poignant statements relevant to future research in the field.

The current approach to treatment during pregnancy has resulted in significant knowledge gaps and harms. Pregnant women are left with two unacceptable options: either take a drug of unknown safety and efficacy or fail to treat a condition, with consequences. Pregnant women deserve better.

Only 12 drugs are explicitly approved by the FDA for use in pregnancy. These drugs are approved either to prevent premature labor or to ameliorate labor pain. All medicines used for non-obstetrical treatments with pregnant women are off-label. Pregnancy is the ultimate off-label condition. This lack of knowledge has led to a profound reticence to treat pregnant women when they do fall seriously ill, and it ends up harming the women and the babies.

What is needed in the case of pregnancy research is the development of a thoughtful, careful framework to address a scientifically and ethically challenging situation.

The authors and editors of this text strongly hope that you, the reader, will consider this need for greater evidence regarding musculoskeletal health in pregnant women as a call to action. We believe that those who care for pregnant and postpartum women ought to address their musculoskeletal needs as much as any other need in pregnancy. We hope you and others will bring this evidence to the forefront of providers who are on the front lines, caring for women during this miraculous time in their lives.

References

1. Aldabe D, Milosavljevic S, Bussey MD. Is pregnancy related pelvic girdle pain associated with altered kinematic, kinetic and motor control of the pelvis? A systematic review. *Eur Spine J*. 2012;21(9):1777–87.
2. Aldabe D, Ribeiro DC, Milosavljevic S, Dawn BM. Pregnancy-related pelvic girdle pain and its relationship with relaxin levels during pregnancy: a systematic review. *Eur Spine J*. 2012;21(9):1769–76.
3. Palsson TS, Graven-Nielsen T. Experimental pelvic pain facilitates pain provocation tests and causes regional hyperalgesia. *Pain*. 2012;153(11):2233–40.
4. Ekman EF, Koman LA. Acute pain following musculoskeletal injuries and orthopaedic surgery: mechanisms and management. *Instr Course Lect*. 2005;54:21–33.
5. Fitzgerald CM, Santos LR, Mallinson T. The association between pelvic girdle pain and urinary incontinence among pregnant women in the second trimester. *Int J Gynaecol Obstet*. 2012;117(3):248–50.

6. Stuge B, Saetre K, Braekken IH. The association between pelvic floor muscle function and pelvic girdle pain—a matched case control 3D ultrasound study. *Man Ther.* 2012;17(2):150–6.
7. Stuge B, Saetre K, Ingeborg HB. The automatic pelvic floor muscle response to the active straight leg raise in cases with pelvic girdle pain and matched controls. *Man Ther.* 2013;18(4):327–32.
8. Wu WH, Meijer OG, Uegaki K, et al. Pregnancy-related pelvic girdle pain (PPP), I: terminology, clinical presentation, and prevalence. *Eur Spine J.* 2004;13(7):575–89.
9. Ostgaard HC, Zetherstrom G, Roos-Hansson E. Back pain in relation to pregnancy: a 6-year follow-up. *Spine (Phila Pa 1976).* 1997;22(24):2945–50.
10. Albert H, Godskesen M, Westergaard J. Prognosis in four syndromes of pregnancy-related pelvic pain. *Acta Obstet Gynecol Scand.* 2001;80(6):505–10.
11. Ostgaard HC, Andersson GB. Postpartum low-back pain. *Spine (Phila Pa 1976).* 1992;17(1):53–5.
12. Gutke A, Ostgaard HC, Oberg B. Predicting persistent pregnancy-related low back pain. *Spine (Phila Pa 1976).* 2008;33(12):E386–93.
13. Ostgaard HC, Roos-Hansson E, Zetherstrom G. Regression of back and posterior pelvic pain after pregnancy. *Spine (Phila Pa 1976).* 1996;21(23):2777–80.
14. Noren L, Ostgaard S, Johansson G, Ostgaard HC. Lumbar back and posterior pelvic pain during pregnancy: a 3-year follow-up. *Eur Spine J.* 2002;11(3):267–71.
15. Stapleton DB, MacLennan AH, Kristiansson P. The prevalence of recalled low back pain during and after pregnancy: a South Australian population survey. *Aust N Z J Obstet Gynaecol.* 2002;42(5):482–5.
16. Bjelland EK, Stuge B, Vangen S, Stray-Pedersen B, Eberhard-Gran M. Mode of delivery and persistence of pelvic girdle syndrome 6 months postpartum. *Am J Obstet Gynecol.* 2013;208(4):298e291–297.
17. Kearney R, Fitzpatrick M, Brennan S, et al. Levator ani injury in primiparous women with forceps delivery for fetal distress, forceps for second stage arrest, and spontaneous delivery. *Int J Gynaecol Obstet.* 2010;111(1):19–22.
18. Woolf CJ. Central sensitization: implications for the diagnosis and treatment of pain. *Pain.* 2011;152(3 Suppl):S2–15.
19. Kilpatrick LA, Kutch JJ, Tillisch K, et al. Alterations in resting state oscillations and connectivity in sensory and motor networks in women with interstitial cystitis/painful bladder syndrome. *J Urol.* 2014;192(3):947–55.
20. FitzGerald MP, Payne CK, Lukacz ES, et al. Randomized multicenter clinical trial of myofascial physical therapy in women with interstitial cystitis/painful bladder syndrome and pelvic floor tenderness. *J Urol.* 2012;187(6):2113–8.
21. Davies GA, Wolfe LA, Mottola MF, MacKinnon C, Society of Obstetricians and Gynecologists of Canada, SCPOC. Joint SOGC/CSEP clinical practice guideline: exercise in pregnancy and the postpartum period. *Can J Appl Physiol.* 2003;28(3):330–41.
22. Prather H, Camacho-Soto A. Musculoskeletal etiologies of pelvic pain. *Obstet Gynecol Clin North Am.* 2014;41(3):433–42.
23. Stein SL. Chronic pelvic pain. *Gastroenterol Clin North Am.* 2013;42(4):785–800.
24. Vleeming A, Albert HB, Ostgaard HC, Sturesson B, Stuge B. European guidelines for the diagnosis and treatment of pelvic girdle pain. *Eur Spine J.* 2008;17(6):794–819.
25. Blehar MC, Spong C, Grady C, Goldkind SF, Sahin L, Clayton JA. Enrolling pregnant women: issues in clinical research. *Womens Health Issues.* 2013;23(1):e39–45.

Index

A

- Abdominal muscles, 5, 74
 - aerobic fitness and muscle strength, 218
 - diastasis recti abdominis, 218–219
 - Joel-Cohen incision, 219
- Acetaminophen
 - breastfeeding, 234
 - pregnancy, 228–229
- Acupuncture, 88–89, 205

B

- Benzodiazepines
 - breastfeeding, 236
 - pregnancy, 230
- Brachial plexus, 59–60
- Breastfeeding, 31, 177, 204
 - AAP and WHO recommendation, 233
 - acetaminophen, 234
 - benefits of, 232
 - benzodiazepines, 236
 - corticosteroids, 237
 - and exercise, 261
 - local anesthetics, 237
 - non-steroidal anti-inflammatory drugs, 234–235
 - opiates, 235–236
 - radiologic contrast media, 237–238
 - skeletal muscle relaxants, 236–237

C

- Carisoprodol
 - breastfeeding, 236–237
 - pregnancy, 230

- Carpal tunnel syndrome, 31, 32, 58
 - anatomy, 160, 161
 - diagnostic strategies, 162–164
 - effective treatments, 164
 - etiology, 160
 - physiologic changes, 161
 - prevalence, 160
 - symptoms and presentation, 162
- Cesarean delivery, 47, 51, 59, 60, 99, 182–183
 - abdominal muscles, role of, 218–219
 - CPSP, 220–221
 - fall risk, 15
 - gynecological pain
 - abnormal uterine bleeding, 212
 - laparoscopy, 212
 - pathophysiology, 212
 - retrospective case-control analysis, 212
 - risk factors, 213
 - scar defect, 212
 - history of, 209
 - lumbopelvic pain postpartum, 210–211
 - musculoskeletal pain, 214–215
 - pelvic floor muscle dysfunction, 215–218
- Chronic pelvic pain (CPP), 194, 212, 220, 275
- Chronic postsurgical pain (CPSP), 213, 220–221
- Coccydynia
 - and coccyx fracture, 176–177
 - musculoskeletal imaging, 54
- Coccyx fracture, 176–177
- Coronary heart disease (CHD), 254–255
- Corticosteroids
 - breastfeeding, 237
 - pregnancy, 231

Cyclobenzaprine
 breastfeeding, 236
 pregnancy, 230

D

DeQuervain's tenosynovitis
 anatomy, 165
 diagnostic strategies, 167
 effective treatments, 168
 etiology, 165–166
 physiologic changes, 166
 prevalence, 164–165
 symptoms and presentation, 167

Developmental dysplasia of the hip (DDH)
 clinical implication, 150
 definition, 149
 diagnostics, 150
 epidemiology, 150
 presentation, 150
 treatment, 151

Diastasis recti abdominis (DRA), 5, 218–219

Dyspareunia, 217

E

Exercise and pregnancy
 ACOG guidelines, 244, 245
 ACOG recommendations, 244, 245
 breastfeeding, 261
 contraindications, 245
Exercise is Medicine®, 247
 gestational diabetes, 250–253
 gestational weight gain, 248–249, 251
 heart-rate augmentation, 250
 labor and delivery, 260
 low back and pelvic girdle pain, 256–258
 LTPA duration and maintenance, 247
 obesity and sedentary maternal lifestyles, 244
 postpartum exercise, 264–265
 preeclampsia, 254–256
 prenatal and postpartum mental health, 258–260
 prescriptions
 hyperthermia, 263–264
 injuries, 263
 PARmed-X, 261
 prevalence of, 246–247
 ventilatory responses, 250
 walking, 250

External anal sphincter (EAS), 103, 105, 182

Extra-articular hip pain, 135
 greater trochanteric pain syndrome, 143–147

round ligament, 136

transient osteoporosis
 clinical presentation, 138–139
 diagnostics, 139–140
 differential diagnosis, 140–141
 epidemiology, 137
 pathogenesis, 137–138
 treatment, 141–143

F

Falls, pregnancy
 biomechanical investigation, 14, 15
 incidence, 13
 postpartum falls, 15
 prevention of, 14–15
 risk factor, 13

Femoral neuropathy, 59

G

Gestational diabetes (GDM)
 definition, 251
 large-for-gestational age, 252
 management, 253
 prevention, 252–253

Greater trochanteric pain syndrome (GTPS)
 anatomy, 144
 clinical presentation, 145
 diagnostics, 145–146
 epidemiology, 143
 etiology and pathophysiology, 144
 tendinopathy and tears, 144–145
 treatment, 146–147

Gynecological pain. *See* Postcesarean
 gynecological pain

H

Hip disorders
 extra-articular hip pain, 135
 greater trochanteric pain syndrome, 143–147
 round ligament, 136
 transient osteoporosis, 136–143

intra-articular hip pain
 DDH, 149–151
 femoroacetabular impingement, 147–149
 hip labral tear, 151–153
 osteoarthritis, 154
 THA, 154

Hip labral tear, 147
 clinical implication, 151–152
 diagnostics, 153

- epidemiology, 151
- presentation, 152
- treatment, 153
- Hormones, 8, 70, 116
 - bone metabolism, 25–26
 - cartilage, 27
 - estrogen, 19, 20, 33
 - fluctuations of, 19
 - insulin-like growth factor 1, 25
 - intra-person variation, 20
 - ligament, 27–29
 - myotendinous unit, 29–31
 - nervous system, 31
 - neuromusculoskeletal tissues, 21
 - pain, 31–32
 - parathyroid hormone-related peptide, 24
 - progesterone, 21, 33
 - prolactin, 23
 - relaxin, 21–22, 33
 - sex hormone-binding globulin, 25
 - testosterone/androstenedione, 22–23, 33
 - vitamin D, 25
- I**
- Interlaminar epidural steroid injection (ILES), 125
- Internal anal sphincter (IAS), 182
- Intra-articular hip pain, 135
 - DDH, 149–151
 - femoroacetabular impingement, 147–149
 - hip labral tear, 151–153
 - osteoarthritis, 154
 - THA, 154
- L**
- Labor and delivery
 - coccydynia and coccyx fracture, 176–177
 - pubic symphysis separation, 171–173
 - sacral stress fractures, 175–176
 - transient osteoporosis of pregnancy, 173–175
- Lactation. *see* Breastfeeding
- Low back pain (LBP), 3, 32, 44–45, 83, 87–88, 275
 - definition, 115
 - differential diagnosis, 121
 - epidemiology, 115–116
 - etiology, 116
 - hyperlordosis, 257
 - injection therapy, 118, 122, 123
 - investigations, 121
 - mechanisms, 257
 - pain history, 119, 120
 - and pelvic girdle pain, 258
 - physical examination, 120
 - prevalence, 256
 - risk factors, 117, 257
 - terminology, 117
- Lumbosacral plexus, 60, 93–94, 97, 99, 106, 108
- M**
- Methocarbamol
 - breastfeeding, 237
 - pregnancy, 231
- Modified Trendelenburg test, 77
- Musculoskeletal (MSK) imaging
 - carpal tunnel imaging, 58
 - hernia and round ligament varicosities, 54–55
 - intrinsic hip pathology, 53–54
 - lower extremity neuropathies, 59
 - modalities and indications, 42–43
 - MRI and MR neurography, 57
 - MSK infection, 56–57
 - occult hernias, 55–56
 - osteitis condensans ilii, 51–52
 - osteitis pubis, 49–51
 - pelvic pain syndromes, 44
 - pubic symphysis separation and injuries, 48–49
 - sacroiliac joint inflammatory and degenerative changes, 53
 - spine and lower back, 44–45
 - stress injuries, 45–48
- Musculoskeletal pain
 - after cesarean section, 214–215
 - caudal epidural steroid injection, 123, 130
 - diagnostic/therapeutic sacroiliac joint injection, 124
 - ganglion impar and sacrococcygeal injection, 124–125, 131
 - ILES, 125
 - LBP (*see* Low back pain (LBP))
 - lumbar diagnostic medial branch block, 128
 - PGP (*see* Pelvic girdle pain (PGP))
 - radiofrequency ablation, 130
 - symphysis pubis injection, 125–126
 - TFESI, 126–127
 - therapeutic intra-articular
 - zygapophysial joint injection, 127–128

N

Neural injury

- abdominal wall and groin neuropathies, 102
- common peroneal nerve, 101
- diagnosis of
 - CT guidance, 105
 - MRI sequence, 106
 - NCS and EMG, 104, 105
- pudendal nerve terminal motor latency, 105
- femoral neuropathy, 98–99
- incidence of, 96–97
- lateral femoral cutaneous neuropathy, 97–98
- lumbosacral plexopathy, 99–100
- lumbosacral plexus, 93–94
- mechanism of, 94–96
- obturator neuropathy, 101
- prognosis, 103–104
- pudendal neuropathy, 102–103
- sciatic neuropathy, 100–101
- treatment
 - ankle-foot orthosis, 107, 108
 - corticosteroids, 107
 - neurectomy, 109
 - neurolysis, 109
 - pudendal decompression, 109
 - sciatic neuropathy, 109
 - systemic absorption, 108

Non-steroidal anti-inflammatory drugs

- lactation, 234–235
- pregnancy, 229

O

Obstetric anal sphincter injury (OASIS), 183–185, 187

Obturator neuropathy

- lower extremity neuropathies and imaging, 59
- neural injury, 101

Opiates, 235–236

Opioids, 229–230

Osteitis condensans ilii, 51–52

Osteitis pubis

- in athletes, 51
- bone biopsies, 50
- definition, 49
- insufficiency fracture, 50

Osteoarthritis (OA), 154

P

Pelvic floor disorders (PFDs)

- factor, 181
- levator ani injury, 186–187

obstetric anal sphincter injury, 181–184

- sexual function, 186–188
- urinary incontinence, 184–185

Pelvic floor muscles (PFM)

- anal incontinence, 216
- anatomic and hormonal changes, 194
- dyspareunia, 217
- function and dysfunction, 199
- levator ani muscle, 216
- nonfunctioning PFM, 199
- overactive PFM, 199
- on palpation, 199
- pelvic organ prolapse, 217
- prevalence rates, 195
- pudendal nerve injuries, 217
- underactive PFM, 199
- urinary incontinence, 216
- vaginal delivery, 216, 217
- voluntary contraction, 201
- voluntary relaxation, 201

Pelvic floor pain/dysfunction

- bracing, 203
- chronic pelvic pain, 194
- complementary therapies, 205
- diagnostic testing, 202
- epidemiology, 194–195
- history, 199–200
- injections, 204–205
- medications, 204
- neuromusculoskeletal anatomy, 195–198
- physical exam, 200–201
- physical therapist, 202–203

Pelvic girdle pain (PGP)

- definition, 69, 115
- differential diagnosis, 121
- epidemiology, 115–116
- etiology, 70–71, 116
- history, 71–72
- injection therapy, 118–119, 122, 123
- investigations, 121
- and LBP, 258
- pain history, 119, 120
- and PFM, 193
- physical examination, 120
 - abdominal muscle evaluation, 74
 - depression, 73
 - Gaenslen's test, 77
 - hypertension, 73
 - long dorsal ligament test, 76
 - Modified Trendelenburg test, 77
 - neuromuscular examination, 74
 - pain provocation tests, 75
 - patient's lumbar spine, 74
 - posterior pelvic pain provocation test, 76
 - stork test, 77, 78

- PLBP (*see* Pregnancy-related low back pain (PLBP))
- postpartum depression, 69
- PPGP (*see* Pregnancy-related lumbopelvic pain (PLPP))
- risk factors, 73, 117, 258
- terminology, 117
- Peroneal neuropathy, 59, 101
- Phalen's test, 162
- Physical Activity Readiness Medical Examination (PARmed-X), 261, 262
- Physical therapists (PT), 202–203
- Postcesarean gynecological pain
- abnormal uterine bleeding, 212
 - laparoscopy, 212
 - pathophysiology, 212
 - retrospective case-control analysis, 212
 - risk factors, 213
 - scar defect, 212
- Pregnancy, 276
- abnormalities, 227
 - acetaminophen, 228–229
 - anatomic changes
 - abdominal musculature, 4
 - arch height and rigidity index, 8
 - bone mineralization, 8–9
 - control of balance, 12–13
 - falls, 13–15
 - gait, 9–11
 - ligamentous laxity, 3
 - locomotion, 11–12
 - lower limbs, 6–7
 - muscle and anatomical impairments, 5
 - pelvic stabilizers, 2
 - pelvic tilt, 5–6
 - residual impairments, 8
 - spinal posture, 3–4
 - benzodiazepines, 230
 - carisoprodol, 230
 - corticosteroids, 231
 - cyclobenzaprine, 230
 - and exercise
 - ACOG guidelines, 244, 245
 - ACOG recommendations, 244, 245
 - breastfeeding, 261
 - contraindications, 245
 - Exercise is Medicine*®, 247
 - gestational diabetes, 250–253
 - gestational weight gain, 248–249, 251
 - heart-rate augmentation, 250
 - labor and delivery, 260
 - low back and pelvic girdle pain, 256–258
 - LTPA duration and maintenance, 247
 - obesity and sedentary maternal lifestyles, 244
 - postpartum exercise, 264–265
 - preeclampsia, 254–256
 - prenatal and postpartum mental health, 258–260
 - prescriptions, 261–264
 - prevalence of, 246–247
 - ventilatory responses, 250
 - walking, 250
- hip disorders (*see* Hip disorders)
- hormonal influences (*see* Hormones)
- local anesthetics, 231
- methocarbamol, 231
- neural injury (*see* Neural injury)
- non-steroidal anti-inflammatory drugs, 229
- opioids, 229–230
- pharmacological management, 228
- physiologic changes, 228
- radiologic contrast media, 232
- Pregnancy-related low back pain (PLBP)
- acupuncture, 88–89
 - bracing, 85–87
 - clinical findings, 82
 - labor management, 89
 - medications, 85
 - modalities, 87–88
 - patient education, 90
 - physical therapy and exercise, 83–85
 - prognosis, 89–90
 - treatment, 82
- Pregnancy-related lumbopelvic pain (PLPP)
- acupuncture, 88–89
 - bracing, 85–87
 - labor management, 89
 - ligamentous laxity, 82
 - medications, 85
 - patient education, 90
 - physical therapy and exercise, 83–85
 - prognosis, 89–90
 - treatment, 82
- Pubic symphysis, 5, 29, 48–49, 53, 55, 73, 211
- diagnosis of, 172
 - factor, 172
 - incidence of, 171
 - MRI, 172
 - treatment, 173
- Pudendal neuropathy, 60, 102–103, 109
- R**
- Round ligament of the uterus (RLU), 136
- S**
- Sacral stress fractures, 47, 52, 175–176
- Scar defect, 212

Sciatic neuropathy, 60, 100–101, 109

Skeletal muscle relaxants

breastfeeding, 236–237

carisoprodol, 230

Stress injuries

bilateral and unilateral stress injuries, 47

bilateral transient osteoporosis, 47

and fractures, 45–46

in hip, 47

parasympyseal stress fractures, 47

postpartum stress injuries/fractures, 46–47

sacrum and pubic ramus, 46

Stress urinary incontinence (SUI), 184

T

Tibial nerve, 59

Transforaminal epidural steroid injection

(TFESI), 126–127

Transient osteoporosis of pregnancy (TOP), 47

clinical presentation, 138–139

diagnostics, 139–140

differential diagnosis, 140–141

epidemiology, 137

etiology of, 174

incidence of, 173

MRI, 174

pathogenesis, 137–138

treatment, 141–143

vaginal deliveries, 174

vertebral fractures, 174, 175

Transient osteoporosis of the hip (TOH), 137

calcitonin, 142

clinical presentation, 138–139

diagnosis of, 141

femoral head and neck, 140

MRI, 139

U

Urge urinary incontinence (UUI), 184, 185

Urinary incontinence (UI), 184–185, 188, 216